

Introduction to fixed prosthodontics

Purposes (Benefits) of fixed bridges

- 1.** Correcting abnormal oral conditions.
- 2.** Restoring mastication to full functional efficiency.
- 3.** Maintaining the health of the remaining dentition & prevent further injury.
- 4.** Restoring appearance & aesthetic

Indications of fixed bridge

A) General:

- 1- Psychological: The FPDs are rapidly tolerated by patients than RPDs
- 2- Systemic: as in epileptic patients (attack of unconsciousness), the FPDs have adequate strength & retention, while in RPD, there is a potential for fracture or inhalation.
- 3- Orthodontic consideration: FPDs are indicated for stabilizing the orthodontic results (e.g., FPD used to replace missing lateral incisor after diastema between two centrals has been closed).
- 4- Speech: RPDs are bulky, which cause difficulty in speech. In contrast, in FPDs, the size of pontics are similar to the missed teeth which rarely cause difficulty in speech.

5- Periodontal reasons: FPDs can stabilize teeth with minor mobility using fixed splint (bridge), to prevent further movement that leads to drifting or over extrusion with more loss of bony support, additionally, to ensure that the mastication forces are eventually distributed over several teeth rather than overloading on a tissue that is seriously weakened by the disease.

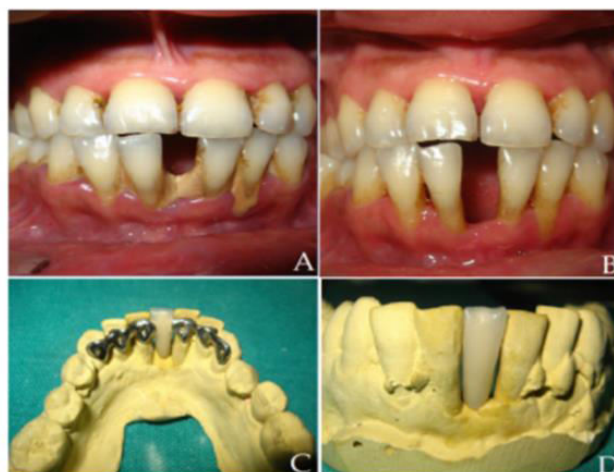

Figure 6: [A] Preoperative photograph of a periodontally compromised lower anteriors, [B] Post non-surgical periodontal therapy, [C] Resin bonded cast metal splint with ceramic pontic (Lingual view), [D] Labial view of ceramic pontic

Indication of fixed bridge

B) Local:

1) The bridges are indicated wherever there are properly distributed healthy teeth that serve as abutments.

- Vital tooth or endodontically treated with no radiographic evidence of pathology
- Adequate crown/root ratio
- Good periodontal condition
- Root configuration & angulations

2) Tooth suitable as abutment which require cast restoration (the same tooth lie adjacent to edentulous space & suitable as abutment).

Indication of fixed bridge

B) Local:

3) Unfavourable angulations of teeth for removable prosthesis (badly tilted teeth).

4) It is advisable to restore edentulous space with fixed rather than RPD, because the force of occlusion transmitted to periodontium, then to the alveolar bone (natural), while in the RPD the occlusal force is transmitted to muco-periosteum, and then the underlying bone (which is not designed this function).

Contraindication:

A- General:

- 1-** Uncooperative patient: difficult to achieve satisfactory result.
- 2-** Social problem: FPDs are more expensive than RPDs. Usually the patient must be given what he wants, which makes him sometimes unsatisfied for the results.
- 3-** Occupation: boxers, hockey players, and pipe smokers are not advisable for FPDs (fracture of teeth or restorations)

Contraindication:

A- General:

- 4-** Poor oral hygiene: The bad attitude toward dentistry limit the decision to make FPDs unless the patients are positively motivated before treatment.
- 5-** Age: FPDs are preferred to be done after the age of 18 yrs. especially in the posterior region due to the large pulp size or teeth are not fully erupted. They are not indicated for elderly patient when there is a lack of resilience of the periodontal membrane or teeth attrition which increase the size of occluding surfaces.

Contraindication of fixed bridge

B- Local:

- 1-** Absence of distal abutment.
- 2-** A considerable bone loss in the visible area of the mouth.
- 3-** Long span.
- 5-** Abutment related factors (tooth not suitable as abutment: length, shape, caries, and periodontal support).

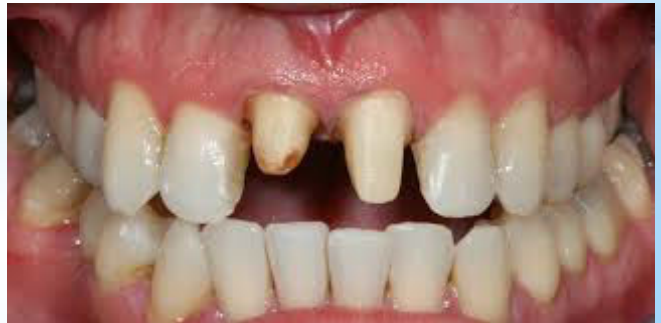Advantages of fixed bridges:

- ❖ Restore function and mastication.
- ❖ Restore esthetics.
- ❖ Maintain health and integrity of dental arch.
- ❖ Support the treatment of the problem related to TMJ.
- ❖ Restore phonetic and speech
- ❖ Periodontal splint
- ❖ A feeling of completeness
- ❖ Orthodontic retention
- ❖ Occlusal stability
- ❖ Restoring occlusal vertical dimension

Disadvantages of fixed prosthodontics treatments:

1) Damage to tooth and pulp:

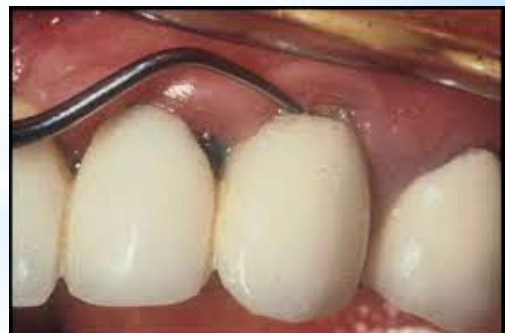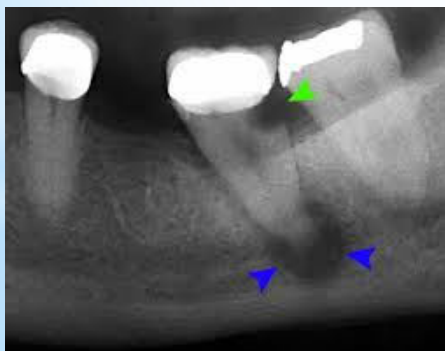Every operative procedure does cause damage, both visible and also invisible within the tooth. Every deep filling or crown or veneer preparation will irritate the nerve of the tooth. Even if done with the utmost care, approximately 10% of these teeth will suffer irreversible damage to the nerve that will require a root canal treatment in the future. This further weakens the tooth and makes durable restoration more challenging as time goes by.



Disadvantages of fixed prosthodontics treatments:

2) Secondary caries:

Secondary caries may happen underneath fixed restoration due to either improper marginal integrity or lifting primary carious lesion in the tooth under the cemented crown.



Comparison & advantages of fixed bridges over RPDs:

- 1)** More stable & comfortable because it covers less tissue surface (there is no acrylic base, flanges or clasps).
- 2)** More aesthetics.
- 3)** More stable occlusion with even distribution of the occlusal forces.
- 4)** Provide a splinting action, while the RPDs push the teeth and cause mobility.

Comparison & advantages of fixed bridges over RPDs:

- 5)** Easier cleaning using tooth brushes and dental floss (when there is a point contact between pontic & the underlying tissue), in contrast, the RPD must be removed to be cleaned.
- 6)** Do not irritate the underlying soft tissues or apply pressure on them.
- 7)** Psychological patients can easily tolerate FPD rather than removable one.
- 8)** The FPDs are preferred for handicapped, epileptic patients, and patient with Parkinson disease due to the possibility of fracture or inhalation of the RPD.

Comparison & advantages of fixed bridges over RPDs:

9) No speech difficulty in FPDs

10) Badly tilted abutment teeth may interfere with the construction of PD (due to the presence of undercut that lead to food stagnation). A telescopic bridge with metal coping, or fixed-movable bridge or proximal half-crown can be used.

11) Anatomical limitation of RPDs such as abnormally large tongue, muscular disorder, mandibular tori (torous), and palatal surface tissue.

Comparison & advantages of fixed bridges over RPDs:

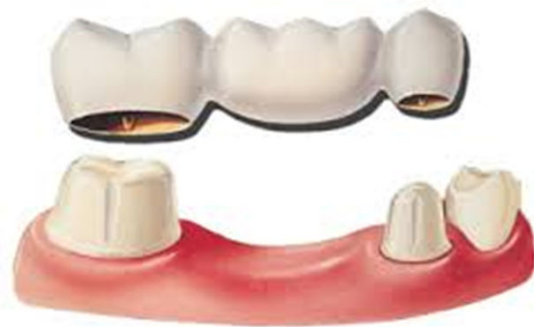9) No speech difficulty in FPDs

10) Badly tilted abutment teeth may interfere with the construction of PD (due to the presence of undercut that lead to food stagnation). A telescopic bridge with metal coping, or fixed-movable bridge or proximal half-crown can be used.

11) Anatomical limitation of RPDs such as abnormally large tongue, muscular disorder, mandibular tori (torous), and palatal surface tissue.

Classification of dental bridges (Types of bridge):

1- **Fixed-fixed bridge:** most common used anteriorly and posteriorly. The pontics are connected rigidly to the retainers at both ends of bridge by solder joint, so we have only one path of insertion.

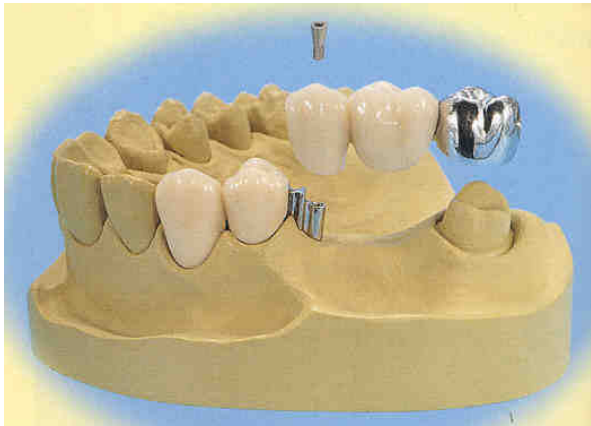


Properties of Fixed-fixed bridge

- 1- Have rigid connector at both end of the pontic.
- 2- Maximum retention & strength.
- 3- All retainers are major which require extensive tooth reduction.
- 4- Unconservative, more destruction of the tooth structure & trauma to the pulp
- 5- Must have only one path of insertion (the preparations of both abutments need to be parallel).
- 6- All retainers must have approximately the same amount of retention reducing the risk of dislodgement when the force is applied on weak retainers.

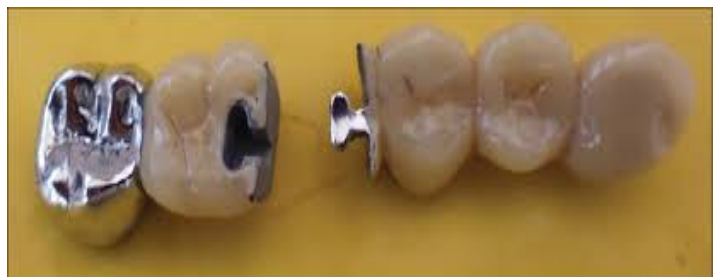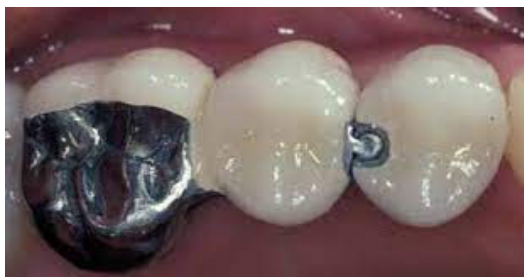2. Fixed-movable (mobile) bridge:

the pontic is attached to fixed retainer on one side while the other side is movable joint that connected with other retainer.



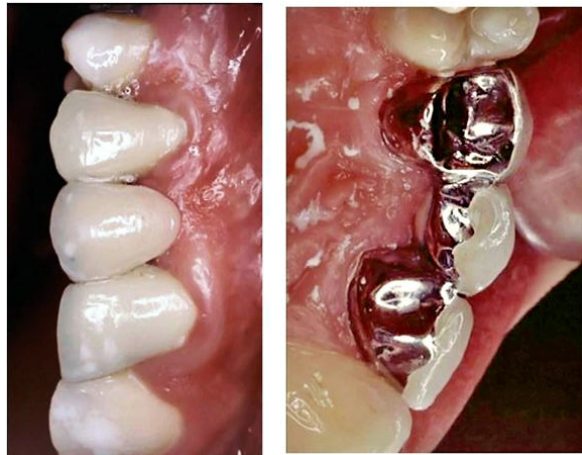Properties of Fixed-movable (mobile) bridge:

- Have rigid connector (major) at the distal end of pontic & mobile (minor) connector mesially.
- More conservative to tooth structure than fixed-fixed design, because minor retainers need less tooth reduction.
- It allows minor tooth movement (lateral & vertical).
- Minor connector can be used at the mid of bridge to break the flexing force (especially in a long span bridge)
- Parts of the bridge can be cemented separately.



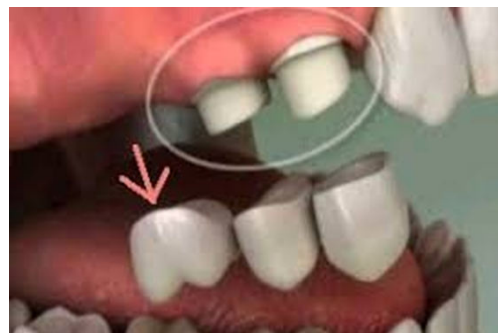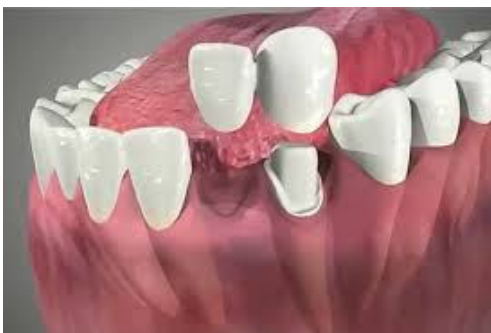Properties of Fixed-movable (mobile) bridge:

- Lab. construction is complex & difficult.
- Preparation of abutment does not need to be parallel.
- It is indicated to be used in divergent abutment teeth (unparallel), whenever a pier abutment is present (complex bridge), and for aesthetic consideration (class III inlay on distal of canine).



3. Simple cantilever bridge:

is used when support can be obtained only from one side of the edentulous space. These dentures have compromised support. The abutment teeth on the supporting side should be strong enough to withstand the additional torsional forces. Support can be obtained from more than one tooth on the same side of the edentulous space, it is simply consist of one or two retainers at one side with pontic that replace the missing tooth.



Cantilever bridge

Advantages

- 1- Very conservative design especially when a single abutment is involved (preserve tooth structure with minimal pulp trauma)
- 2- When second abutments are used, parallel preparation can be easily obtained because the abutments are adjacent to one another.
- 3- Easy to fabricate.

Disadvantages

- 1- Produces torquing forces on the abutment.
- 2- Cannot be used to restore long span edentulous spaces.
- 3- Minor design errors can affect the abutments in a large scale.
- 4- Limited cases, as in lateral incisor replacement using the canine as abutment when the occlusion is favourable. And can be used to replace premolars.

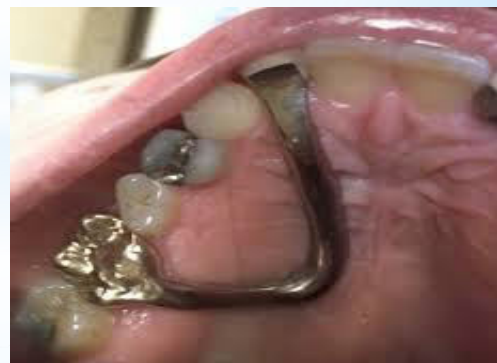4- Spring cantilever bridge

This type of bridge is specially designed to replace missing maxillary central incisor with single pontic.

The abutment is usually posterior molar or a pair of splinted premolars.

A long metal resilient bar is used to connect between the retainer and the pontic.

The bar should be well adapted on the soft tissue, thin and resilient that distribute the masticatory forces well to the soft tissues



- Tooth retained and tissue borne.
 - Forces are absorbed by the springing of the arm and by displacement of the soft tissue of the palate.
 - The abutments are usually posterior teeth (tooth need restoration is better to be used)
 - Contraindicated in V-shape palate & in the lower arch
- It is indicated only for replacing missing upper incisor when the adjacent teeth are sound, midline diastema, spacing of anterior teeth, or posterior teeth need crown.
- Not advised for the lower arch due to the instability of the sub-mucosal tissue, and a potential for plaque & calculus deposition.

Spring cantilever bridge

Advantages.

- 1- Can be used for diastema closure.
- 2- Metal crown retainers that require minimal tooth preparation, can be used in posterior teeth to replace missing incisors.

Disadvantages.

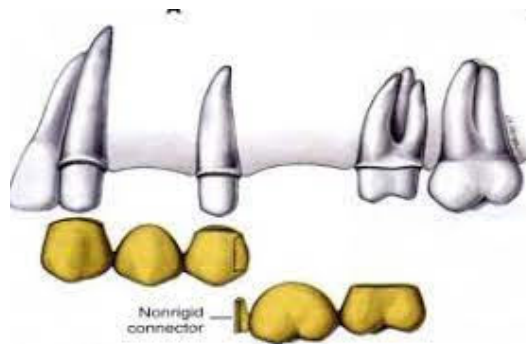
- 1- The connector bar may interfere with speech and mastication.
- 2- Deformation of the connector bar may produce coronal displacement of the pontic.
- 3- There may be food entrapment under the connector bar, which may lead to tissue hyperplasia.

5. Combination designs (Complex or compound bridge)

It is a combination of two or more of conventional designs incorporated in the general design of bridge, such as:

- Fixed-fixed with simple cantilever.
- Fixed-fixed with fixed-mobile.

It can be used for unfavourable angulation of abutments, it Simplify the preparation and conserve tooth tissues, and Easily repaired after fracture

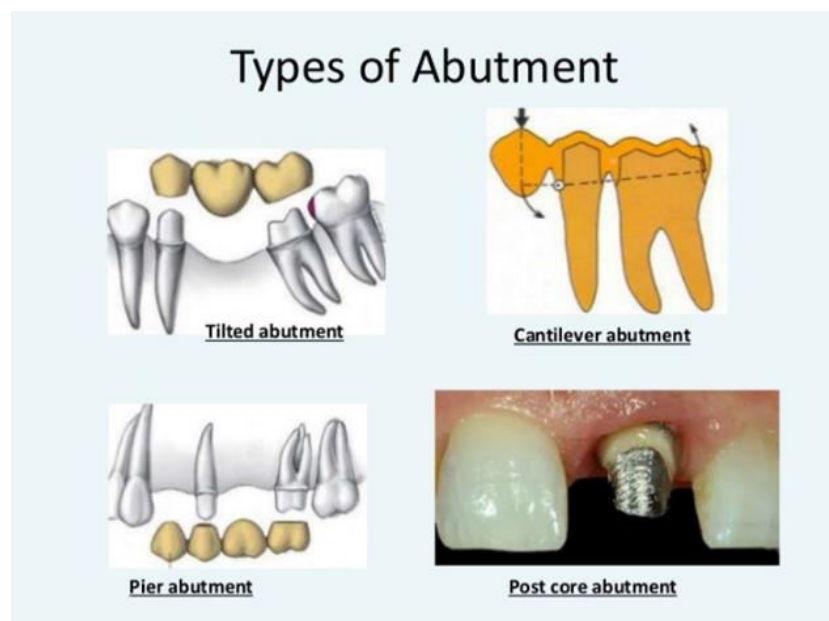


Benefits of combination designs :

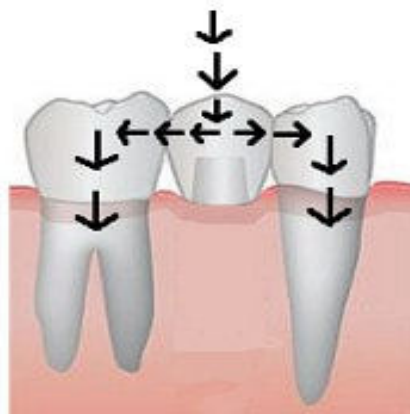
- 1- Simplify the construction of the prothesis.
- 2- Unfavourable angulation of abutments.
- 3- Simplify the preparation and conserve tooth tissues.
- 4- Easily repaired after fracture.
- 5- Precision retainers permit the seperation of two or more components.

Evaluation Abutment tooth

Abutment in fixed prosthodontic terminology is a tooth or portion of a tooth that supports and/or retains a fixed bridge or part of the bridge, to which the retainer is connected (cemented).



All forces that are absorbed by the missing tooth are transmitted, through the pontic, connectors, & retainers to the abutment teeth. Abutment teeth must withstand forces that are normally directed to the missing teeth, in addition to those usually applied to the abutments, therefore, the choice of abutment is important because it has to withstand the forces that acting on it and on the pontic.



So the clinician have to evaluate the abutment teeth carefully

Considerable time & expense are spared by thoroughly investigating each abutment tooth before proceeding the preparation. Radiographs are made & the pulpal health is assessed by evaluating the response to thermal & electrical stimulation.

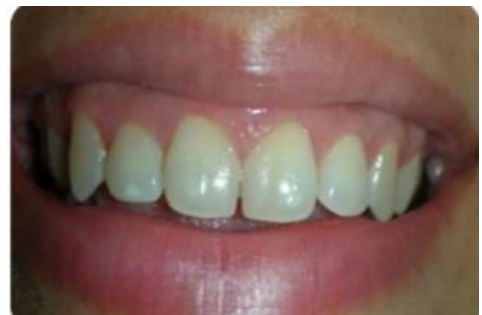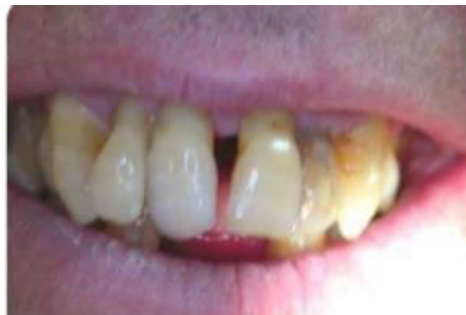Evaluation Aids:

They include; clinical examination using examination tools, vitality test, radiographs, diagnostic casts, & periodontal probe.

Requirements:

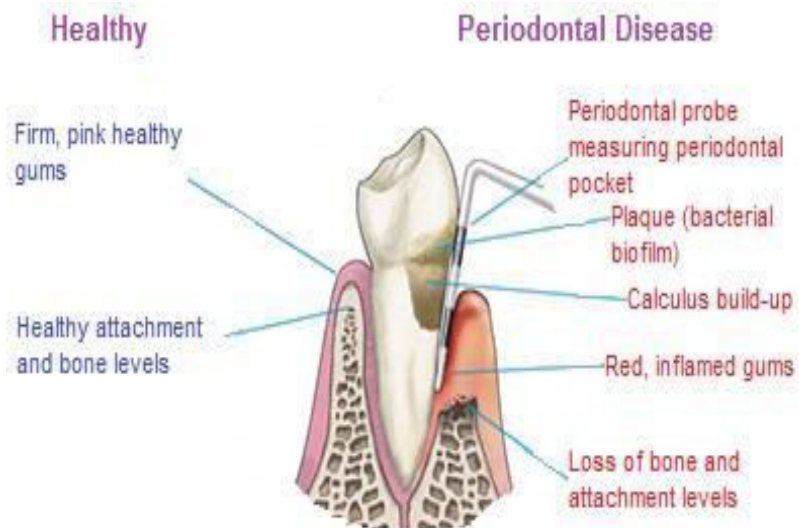1- The abutment must withstand forces normally directed to the missing teeth, whenever possible the abutment should be vital tooth.

2- A symptomatic endodontically treated teeth with a radiographic evidence of good seal & complete obturation of the canal can serve as abutment (post & core for retention & strength).

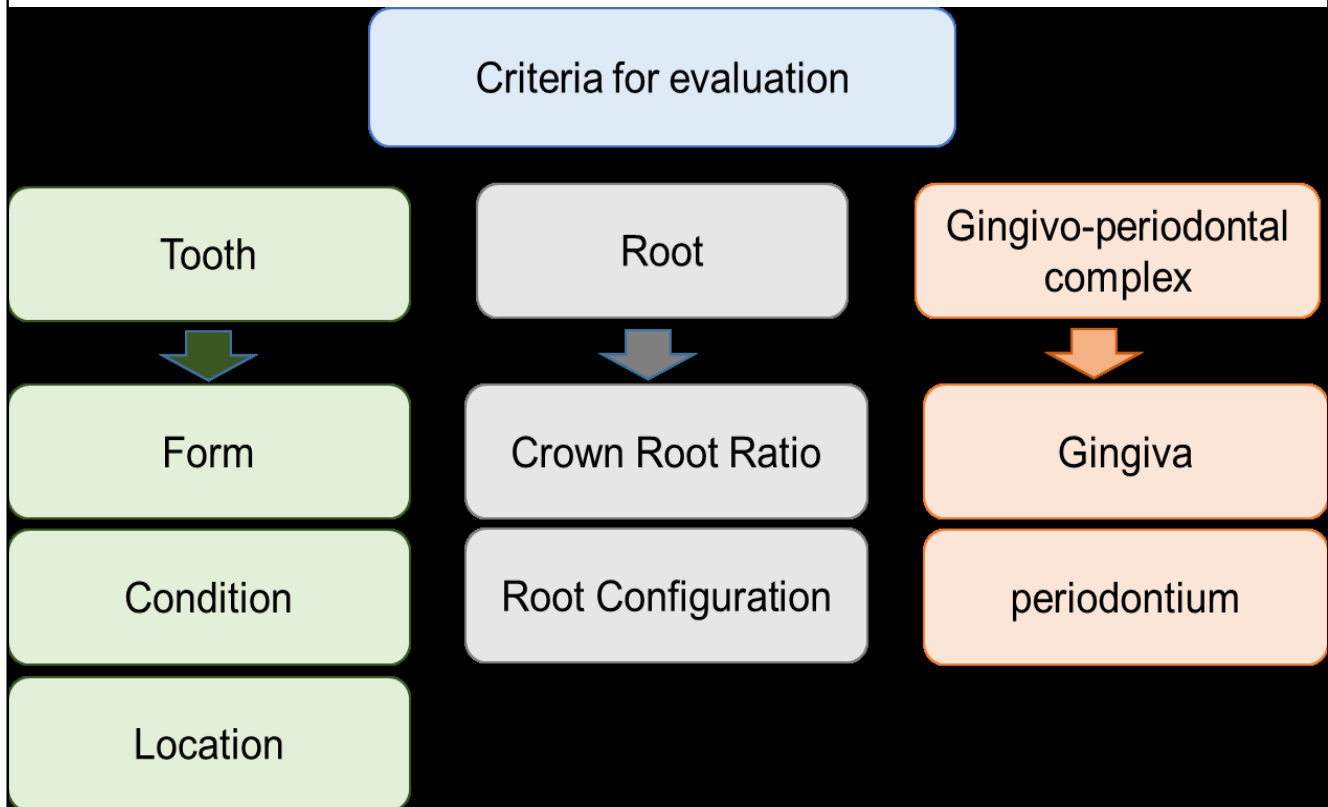


3) The supporting tissue surrounding the abutment teeth must be healthy & free of inflammation.

4) Abutment teeth must not exhibit any mobility, since they will be carrying an extra load. Sever uncorrectable periodontal disease is contraindicated for FPDs.



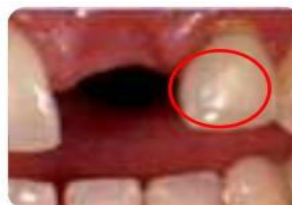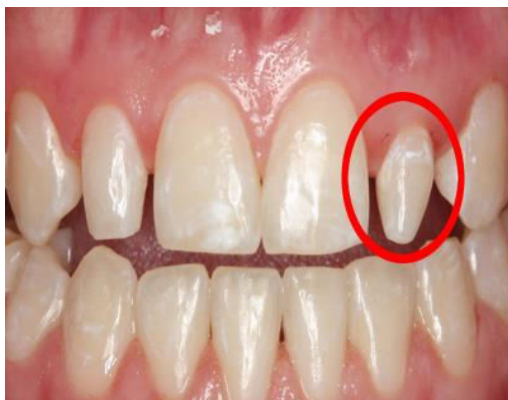Abutment evaluation (selection):



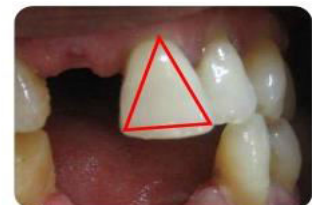Factors related to tooth (abutment)

1. Shape:

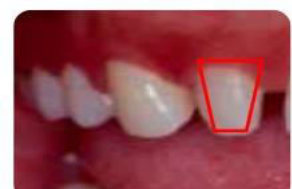Some teeth have conical, peg, bulbous or tapered crown form that interfere with the preparation parallelism, necessitating full coverage crowns to improve aesthetics and retention. Examples; Peg laterals, anterior teeth with poorly developed cingula and short proximal walls, mandibular premolars with poorly developed lingual cusps & short proximal surface, and thin incisors.



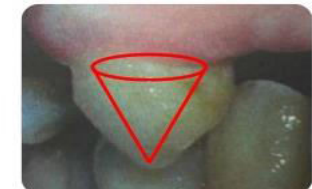Bulbous form



Tapered form



Peg form

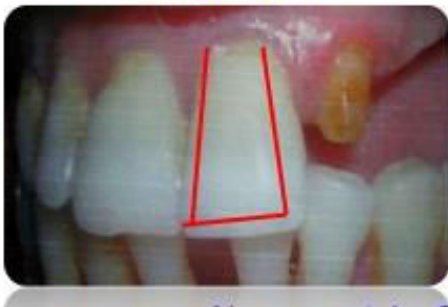

Conical form

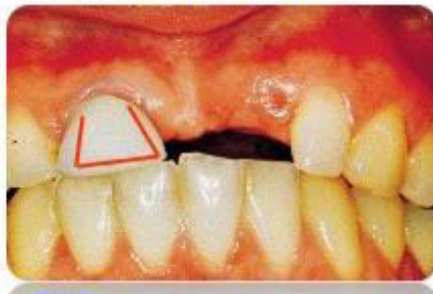
2. Crown length

- Abutment teeth must have adequate occluso-cervical crown length to achieve sufficient retention. Full coverage restorations & crown lengthening are considered with short clinical crowns to ensure adequate retention.

Long Crown

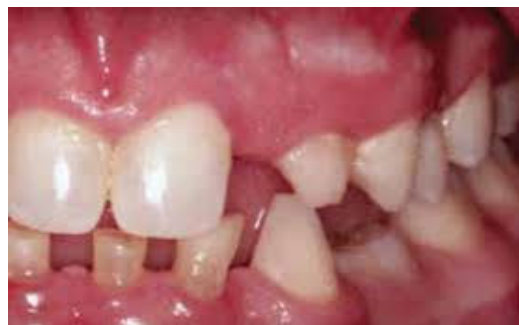
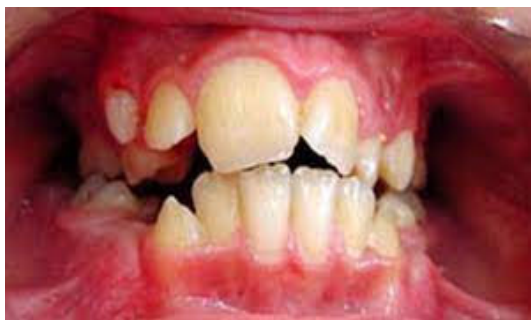
Short Crown



3. Size of the crown:

It determines the type of retainer to be used. For example: short, thin, conical, tapered teeth are poor indication for partial veneer crown.

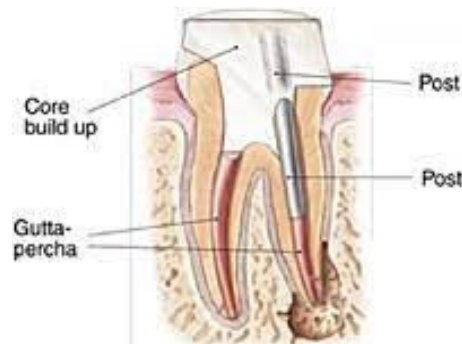
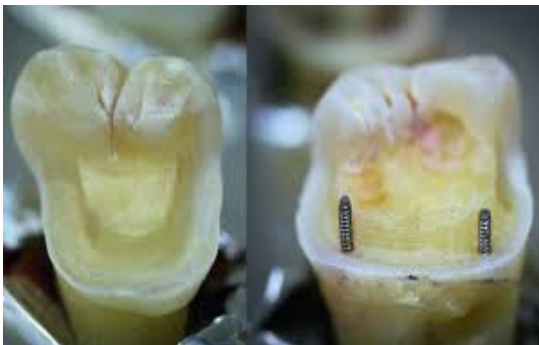

4. Health of abutment (caries or pulpal):

- A sound abutment tooth permits ideal type of preparation. Carious tooth may be used as abutment if the caries is removed with pulp protection (lining) and then restored to its original form by suitable filling material.
- Degree of mutilation of the crown: The size, number & location of the carious lesion or restorations in a tooth will influence the type of the retainer on the abutment. If the caries is small and far away from the margin, the retainer design will extend beyond the caries area. If the mutilation/fracture is severe, removal of the tooth might be indicated.

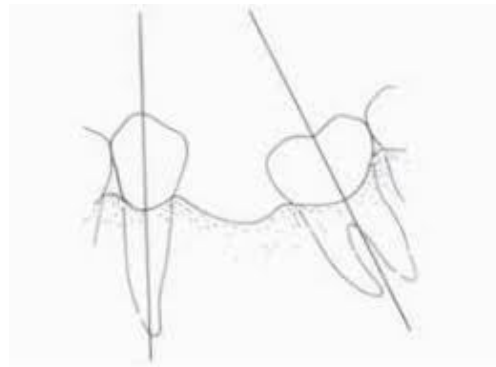
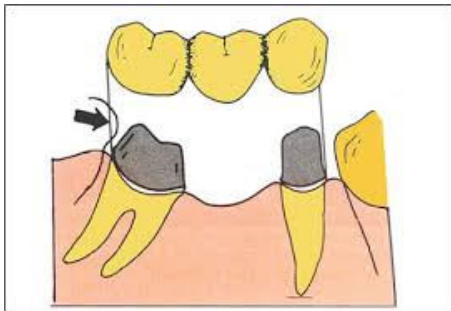
-Vital teeth are preferred, however, pulpless teeth can be used only after endodontic treatment. Pulp capped teeth should be avoided because they are under risk of requiring RCT.

- Modifications like dowel core and pin retained restorations may be needed to restore crown morphology in grossly destructed teeth.



4. Axial relationship:

- a) Rotation, tilting, overlapping, malposition might lead to a decision of excluding such a tooth to be used as abutment (because rotation or torque can damage the supporting structure or cause retainer to become loose).
- b) It may indicate the use of specific retainer (over reduction lead to weaken the tooth & endanger pulp health).
- c) Rotation lead to either increase or decrease of space available for pontic (size of pontic planned).

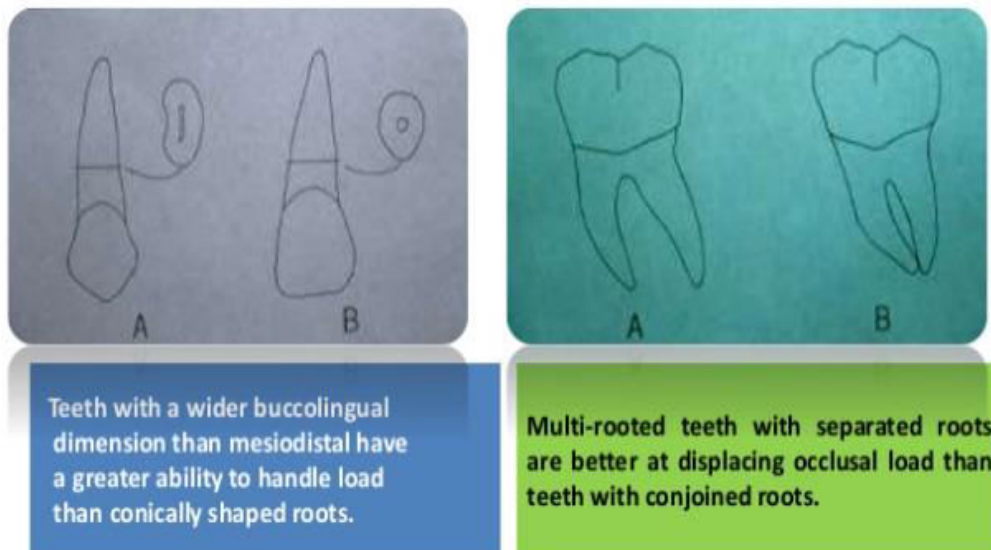


Factors related to root

1. Root configuration (root shape, angulation & length)

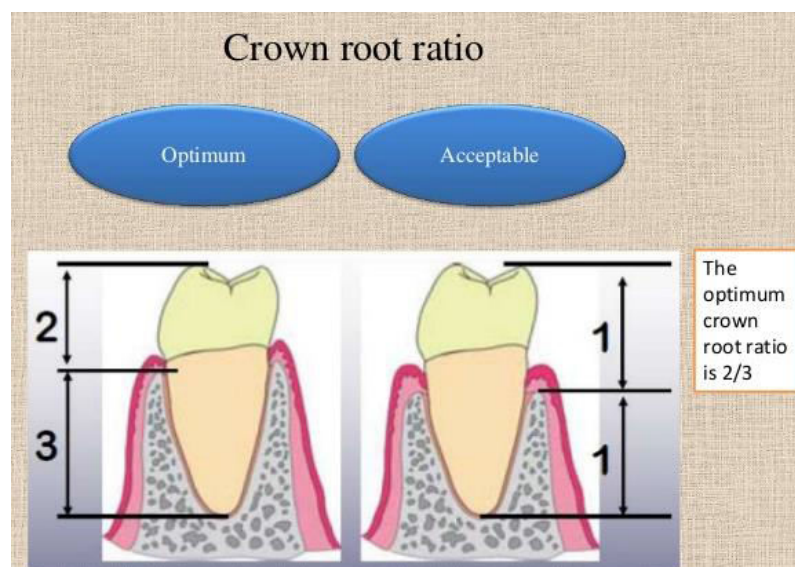
- The shape of the roots determine the ability of the roots to handle the occlusal forces. Root that is wider labiolingually than mesiodistally with elliptic cross-section offers better support than a tooth with similar root surface area but has a circular cross-section.
- Parallel-sided roots with developmental depressions are better to resist occlusal forces than smooth-sided conical roots which can be used for short span bridge, if the other factors are optimal.

- A single-rooted tooth with irregular configuration or with some curvature at the apical third of the root is preferable than tooth that has a nearly perfect taper.
- Multi-rooted teeth with separated roots provide greater stability than single-rooted teeth or teeth with conjoined roots.
- Teeth with longer root are stronger abutment than shorter one, since root length is directly proportional to the stability & strength of the prosthesis.



2. Crown - root ratio: It is a linear measurement of the length of the tooth occlusal to the crest of alveolar bone (crown) compared to the length of the tooth that is embedded in the bone (root).

- 2:3 Crown/Root ratio is the optimum for a tooth to be used as abutment.
- 1:1 Crown/Root ratio is the minimum acceptable ratio. It might be considered adequate if the opposing occlusion is mobile or periodontally involved, or it composed of artificial teeth, which reduce occlusal forces that acting on the abutment which means less stress on the abutments.

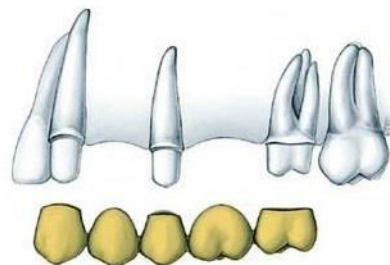


3. Root surface area (Periodontal ligament area):

- The periodontal ligament area can be used as a scale or measurement to determine the potency of an abutment for FPDs.
- Tylman stated that "Two abutment teeth could support two pontics".
- Johnston et al improvised Tylman's statement and proposed the famous ANTE's Law

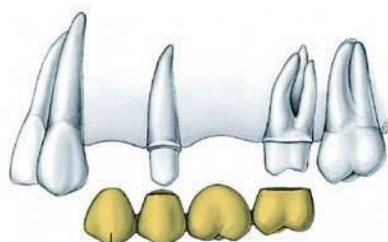
Periodontal surface area "Ante's law"

- The root surface area of abutment teeth (embedded in bone) (pericemental area) must be equal or greater than root surface area of teeth to be replaced.
- If the periodontal surface area seems inadequate, the use of multiple teeth for abutments may be indicated depending on other biomechanical factors.



Pericemental Area of abutment teeth is greater than the pericemental area of teeth being replaced - Ideal FPD design

Ante's Law



Pericemental Area of abutment teeth is equal to the pericemental area of teeth being replaced - follows Ante's law

Example: Missing 1st molar alone or with 2nd premolar, the root surface areas of both are equal to the root surface area of abutments (second molar & first premolar).

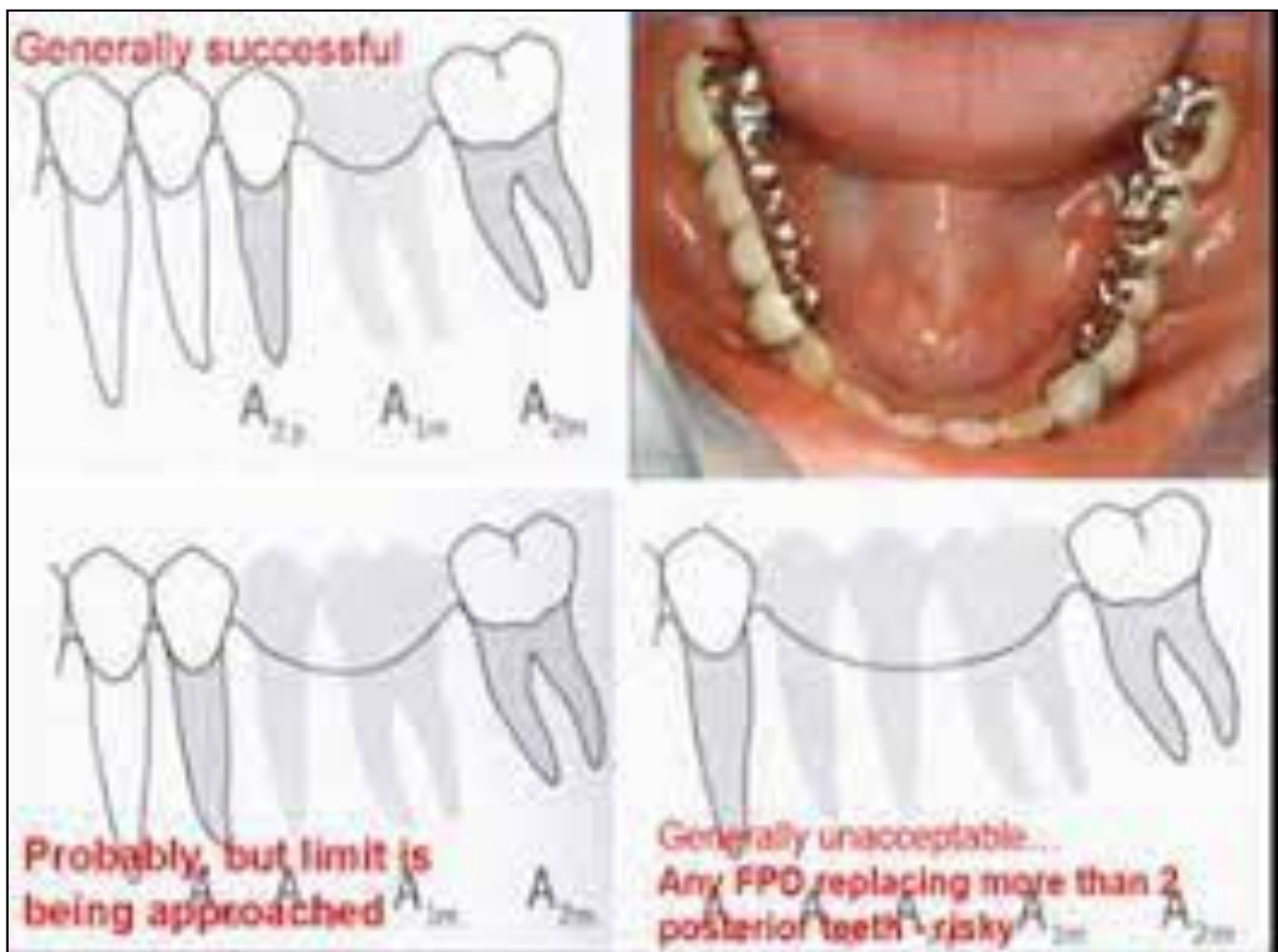According to this premise:

- One missing tooth can be successfully replaced if abutment teeth are healthy. In selected case and in order to increase the capability of the bridge to withstand the loading force 1st premolar can be

used as a secondary abutment.

If two teeth are missing, a FPD can probably replace the missing teeth but the limit is being approached.

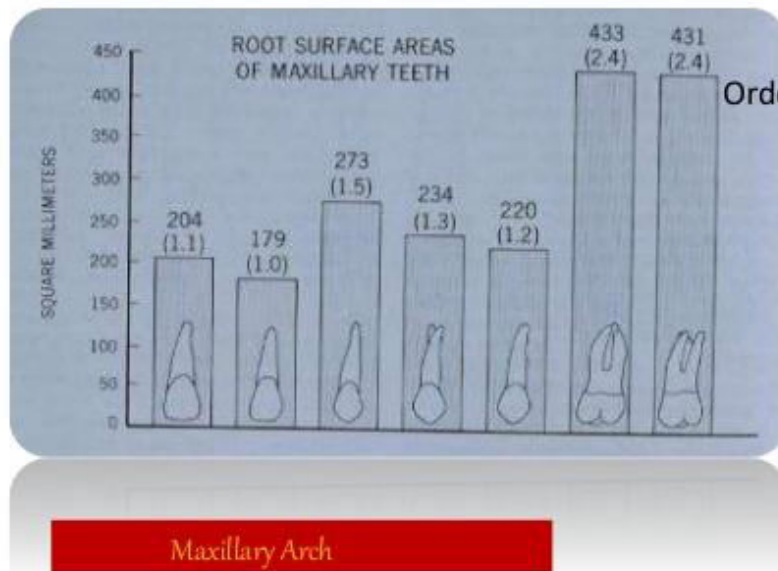
- If three missing posterior teeth (1st molar & two premolars) or when the root surface area of the teeth to be replaced by pontics are greater than that of the abutment teeth, then a high risk or an unacceptable situation for FPD is exists.



Jespen (1963) reported average measurements of root surface areas that can be used to calculate the abutment to pontic ratio

Abutment Evaluation

- Periodontal Surface Area (Ante's Law)



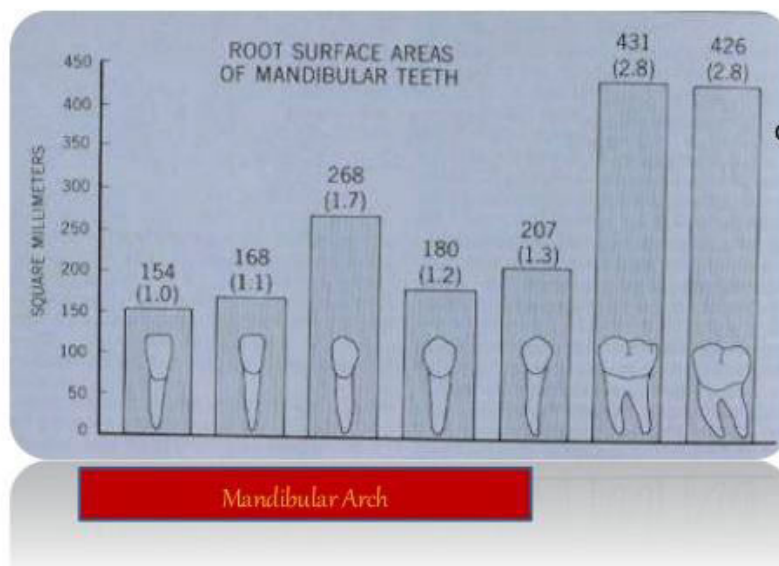
Order of Abutments concerning Periodontal Surface Area:

- First Molar
- Second Molar
- Canine
- First Premolar
- Second Premolar
- Central Incisor
- Lateral Incisor

Jespen (1963) reported average measurements of root surface areas that can be used to calculate the abutment to pontic ratio

Abutment Evaluation

- Periodontal Surface Area (Ante's Law)



Order of Abutments concerning Periodontal Surface Area:

- First Molar
- Second Molar
- Canine
- Second Premolar
- First Premolar
- Lateral Incisor
- Central Incisor

Factors related to Gingivo-Periodontal complex

- Abutment teeth must be free from periodontal disease, periodontal pockets, osseous defect, and gingival inflammation with adequate zone of attached gingiva.
- The abutment teeth should not exhibit any mobility, since they will be carrying an extra load. Intra oral radiograph should be used to evaluate bone architecture.
- The alveolar bone support is one of most important factors that aid to evaluate an abutment which must be healthy, have good trabecular architecture with no sign of bone defect or bone loss.

Biomechanical Considerations of Fixed Partial Denture

Lec. 4 5th stage

Management of the destructive forces

- The design of the bridge must handle the occlusal & dislodging forces such as torque, flexure and tension.
- Occlusion must be designed to optimize the distribution of occlusal forces evenly throughout the envelope of motion over the entire mouth.

The biomechanical considerations that may affect on the success of the constructed bridge include:

- 1- the role of span dimension.
- 2- pontics' characteristics.
- 3- the connectors or joints of the prosthesis abutment tooth
- 4- acting forces (masticatory)

Span length

span length is the distance between abutments that affects the feasibility of placing FPDs.

- One missing tooth is ideal for replacements.
- 2-3 adjacent teeth requires careful evaluation of other factors (crown-root ratio, root length & form, periodontal health, mobility, occlusal force & biomechanical factor).

The dimensions of the span (MD length and OG height) affect on:

- 1- the number of the selected abutments
- 2- type of retainers
- 3- materials that are used for bridges construction.

Consequences of increased span length:

1- increased load placed on the periodontal ligament of the abutment teeth by long span FPDs

2-longer spans are less rigid. All FPDs flex slightly when subjected to a load, the longer the span the greater the flexing.

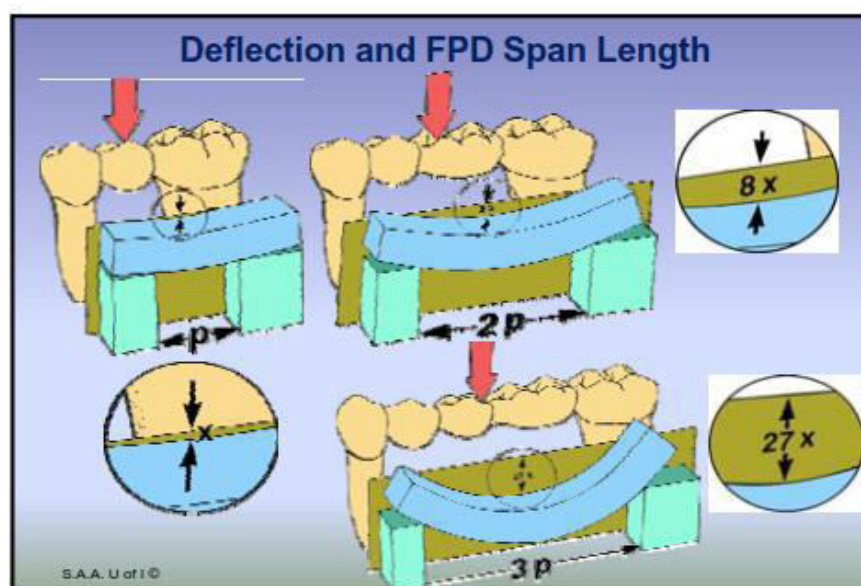
Bending or deflection varies directly with the cube of the length & inversely with the cube of the occlusogingival thickness of the pontic.

Length of the span (Law of beam)

It is an engineering principle states that as the length of the span increases, the flexure of a system will be the increase in length to the power of three (cubed)

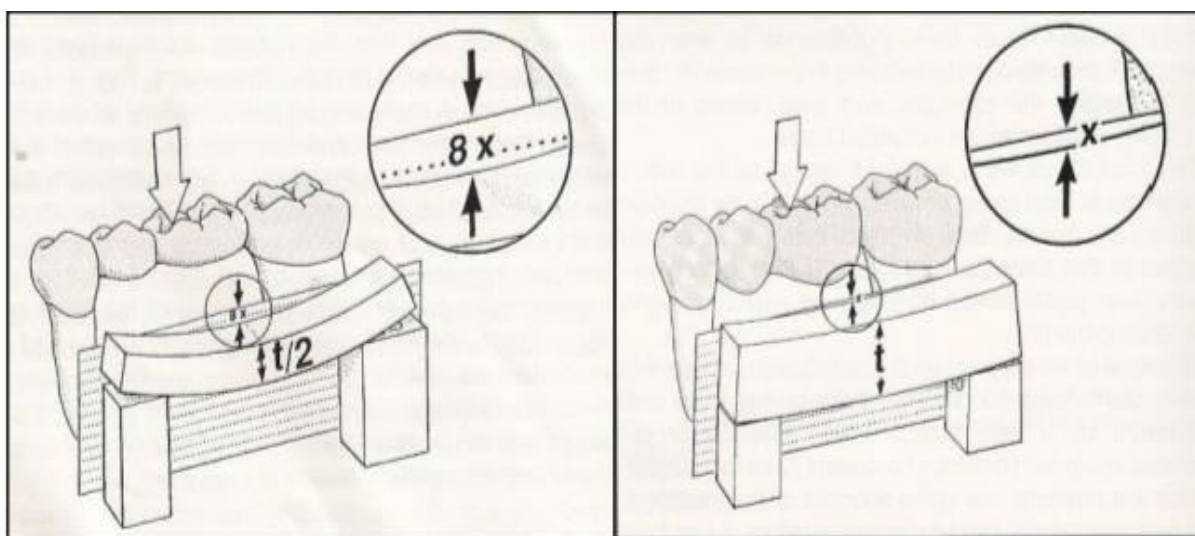
Compared with a FPD having a single-tooth pontic span, a two-tooth pontic span will bend 8 times as much. A three-tooth pontic span will bend 27 times as much as a single pontic.

This mean replacing three missing posterior teeth with FPDs rarely has favourable prognosis, especially in the mandibular arch (Treatment with RPDs or implant supported prosthesis).



Height of the connector (Law of beam)

- As the height of the span decreases, the flexure of a system will be the increase in length to the power of three (cubed). Therefore, halving the connector height would yield 8 times the flexure.
- A pontic with a given occluso-lingual dimension will bend 8 times as much if the pontic thickness is halved.
- Therefore, a long span FPD on short mandibular teeth can have disappointing results. Excessive flexing under occlusal loads may lead to failure of the long span FPDs (fracture of the porcelain veneer, connector breakage, retainer loosening and caries, or unfavourable tooth or tissue response).



To minimise flexing:

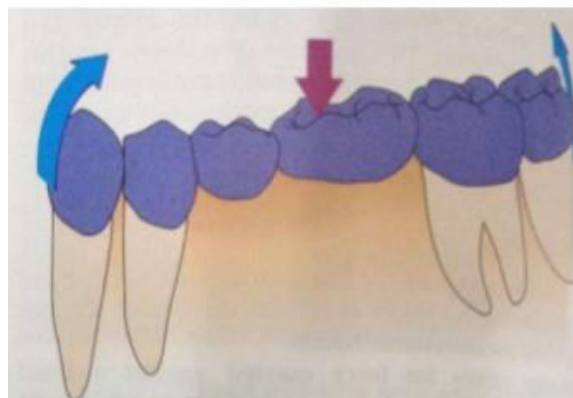
- Select pontic design with greater occlusogingival height.
- Pontics & connectors should be made as bulk as possible to ensure optimum rigidity without jeopardizing gingival health.
- Long span or unfavourable crown/root ratio then used double abutments to enhance the retention & support the long span FPD.

Double abutment

It refers to the use of two adjacent abutment teeth at one or both ends of a FPD

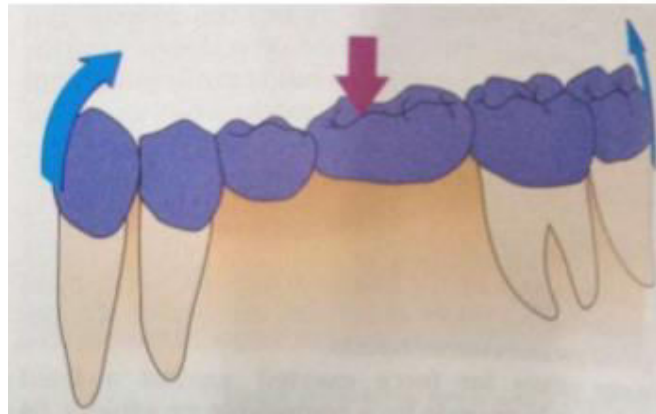
Indications

- To increase the retention of the restoration
- To increase area of supporting periodontal ligament and bone.
- Un favourable crown-root ratio
- Long span FPDs
- Splint & stabilise periodontally compromised teeth.



Criteria for double abutment

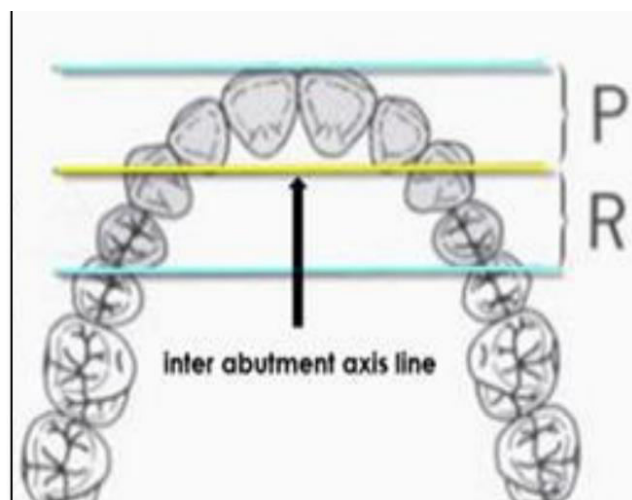
- Secondary abutments must have as much root surface area & a favourable crown root ratio as the primary abutment.
- The retainers on secondary abutment must be at least as retentive as on primary abutments because when the pontic flexes, tensile forces will be applied on the retainers of the secondary abutments.



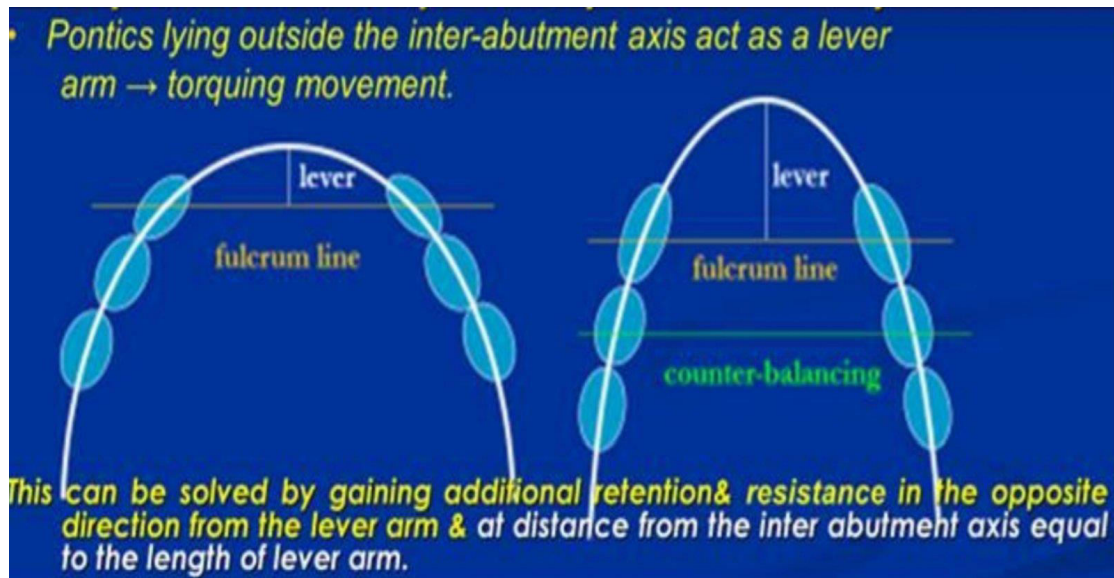
Arch curvature:

When pontics lie outside the interabutment line, they act as a lever arm, which can produce a torqueing movement.

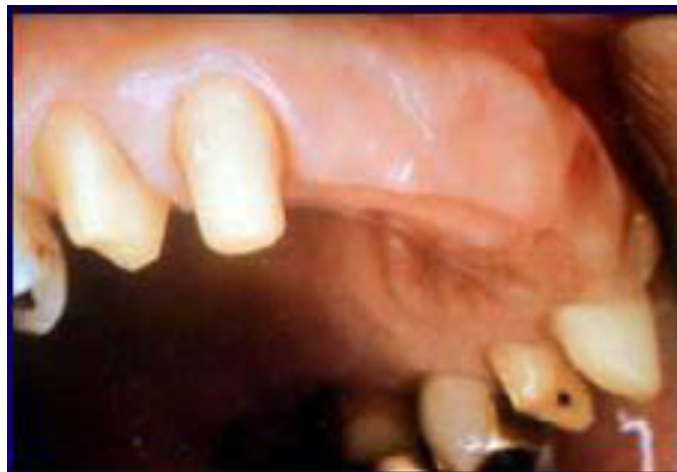- This is a common problem in replacing all four maxillary incisors with a FPD.



It is more pronounced in pointed taper arch anteriorly. The more the taper of the arch, the longer will be the lever arm, the more stress or torquing force, while the more circular arch curvature reduces such a problem.

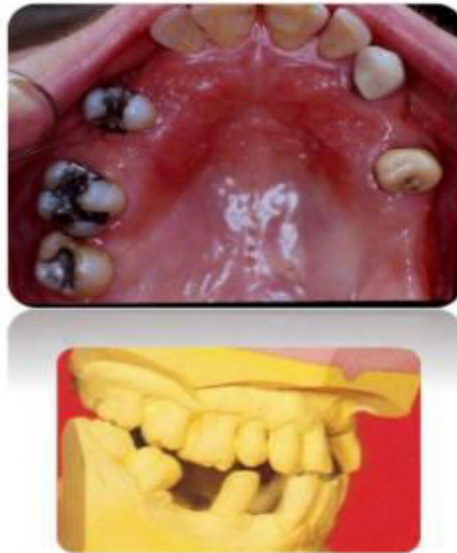

To solve such problem and offset the torque, additional retention is obtained in the opposite direction from the lever arm & at distance from the inter abutment axis equal to the length of lever arm, this mean, that **two abutment teeth at each end of long span anterior FPD** must be used in order to resist this tipping forces. This mean first premolars are used as secondary abutments for a maxillary four pontic canine-to-canine FPD.



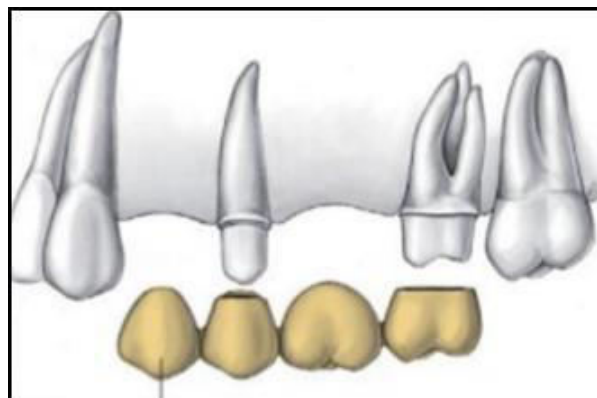
Pier (intermediate) abutment:

It is a natural tooth located between terminal abutments that serve to support fixed or removable prosthesis. Because it lies in the middle of the span, it creates huge stresses on the terminal abutments and acts as a fulcrum causing failure of the weaker retainer. These forces loosen the retainer or the casting, or may lead to leakage around the margin leading to extensive caries.



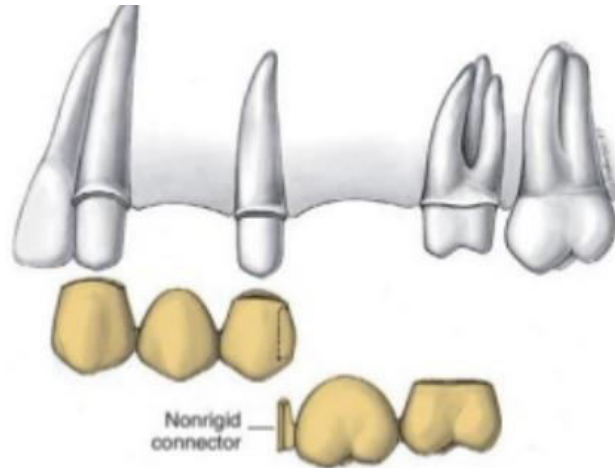
To overcome such complication, you can select one of the following approaches:

- 1) The use of extremely retentive retainers.
- 2) When periodontal support is adequate, a much simpler approach would be to cantilever one segment of the bridge on one side of pier abutment.



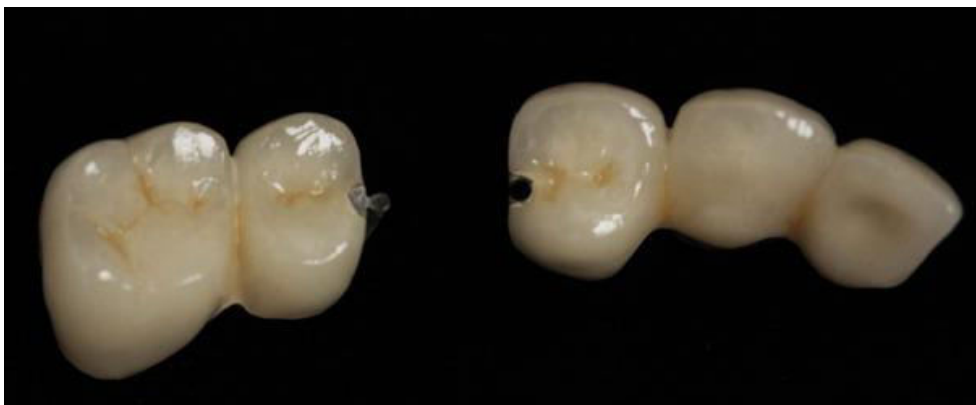3) Use of non-rigid connector.

- It is a broken stress mechanical union of retainer (dovetail keyway) & pontic (T- shaped way).
- It transfers shear stress to supporting bone rather than the connectors.
- It appears to minimize mesiodistal torquing of the abutment, while permitting them to move independently.
- The most commonly used non-rigid design T- shaped key that is attached to the pontic & a dovetail keyway placed in the retainer



Location of the key & key way:

- Keyway should be placed within the distal contours of pier abutment.
- Key should be placed on the mesial side of the distal pontic.

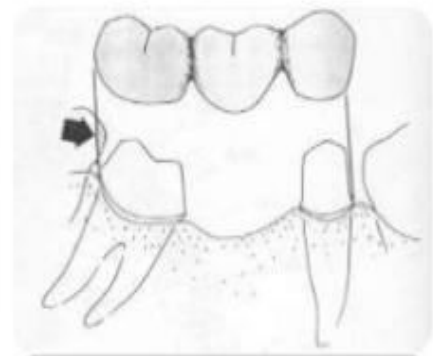



Why keyway should be placed on the distal not on mesial of pier abutment?

Long axes of posterior teeth usually lean slightly in a mesial direction and tilt more mesially when subjected to occlusal forces. **Therefore, if keyway is placed on the distal of pier abutment**, then the mesial movement seats the key into the keyway more solidly. **If placement of the keyway is on the mesial side** then it causes the key to be unseated during the mesial movement which in time can cause a pathologic mobility in the canine or failure of the canine retainer.

Tilted molar abutment: Mesially tilted second molars

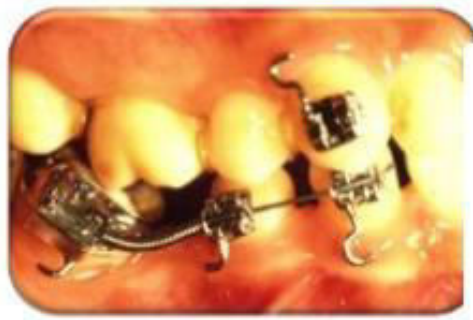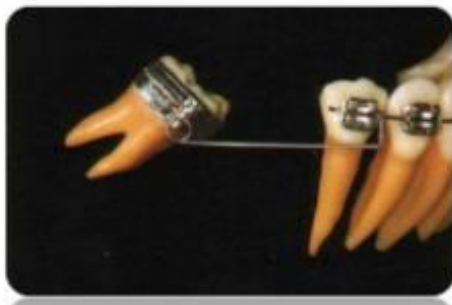The early loss of mandibular 1st molar due caries is still relatively common. If this space is ignored, the 2nd molar will tilt mesially with the eruption of 3rd molar which inturn might be drifted & tilted with the 2nd molar. Then it becomes difficult to make a satisfactory FPD, due to the positional relationship no longer allows for parallel path of insertion without interferences from adjacent teeth.



To solve this problem:

1- Ortho treatment (Uprighting the tilted tooth)

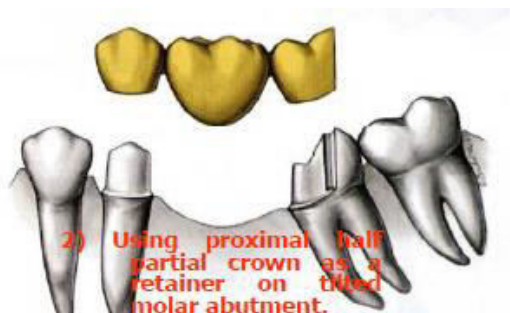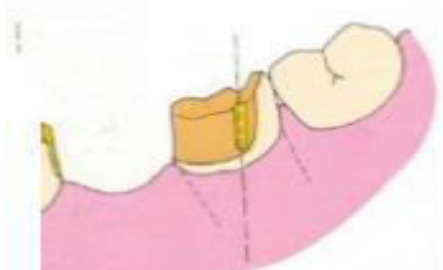
If the tilting is severe, uprighting of the molar is indicated by orthodontic treatment. This helps in distributing the occlusal forces & eliminating the bony defects along the mesial surface of the root. In such case the 3rd molars, if present, are better to be extracted to facilitate movement of 2nd molar (Average treatment time 3 months).



2- Using proximal half partial crown as a retainer on tilted molar abutment.

Proximal half-crowns can be used as a retainer on distal abutment. This is simply a three-quarter crown that has been rotated 90 degrees so that the distal surface is uncovered. It is possible only if:

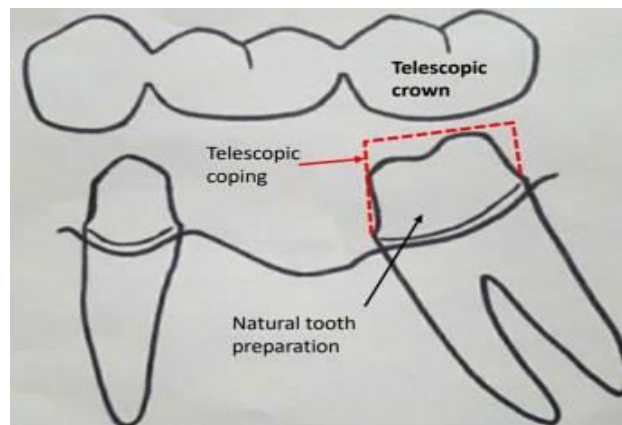
- The distal surface is caries free.
- The distal surface is not decalcified.
- There is a very low incidence of proximal caries throughout the mouth.
- The patient is able to keep the area exceptionally clean.



3- Using telescope crown & coping as retainer.

A telescope crown & coping can be used as a retainer on the distal abutment i.e. full crown preparation with heavy reduction is made to follow the long axis of tilted molar. An inner coping is made to fit the tooth preparation and a proximal half-crown that will serve as a retainer for the FPD is fitted over the coping.

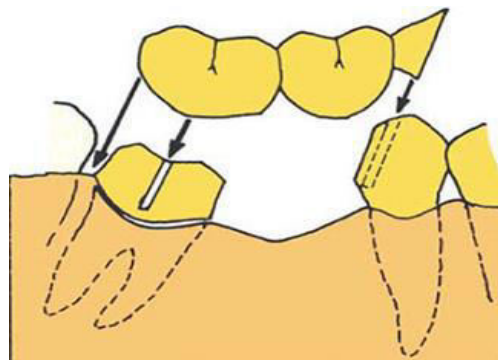
Advantages: it allows total coverage of the clinical crown while compensating for the discrepancy between the path of insertion of the abutments.



4- Non rigid connector is another solution to the problem.

A full preparation is done on the molar with its path of insertion parallel with the long axis of the tilted tooth. A box form is placed on the distal surface of the premolar to accommodate a keyway in the distal aspect of the premolar. Reasons for NOT placing the non-rigid connector on the mesial aspect of the tipped molar is that it can lead to greater tipping of the tooth.

It is indicated when the molar exhibits marked lingual as well as mesial inclination because the routine FPD in such cases will lead to drastically overtapered preparation with no retention.

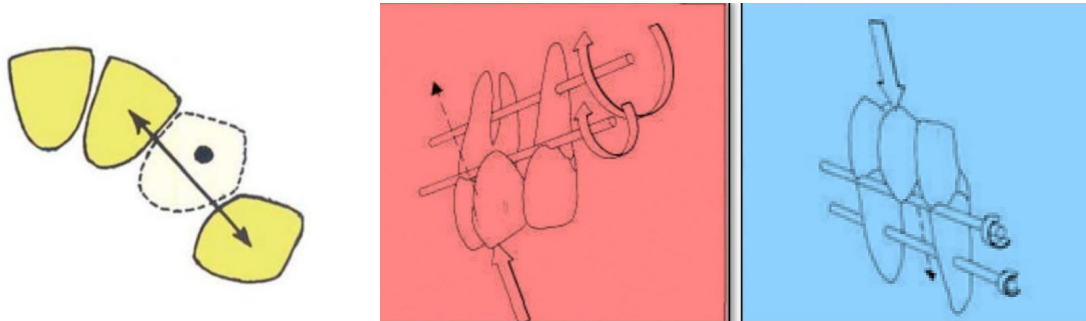


Canine replacement fixed partial denture

Fixed partial dentures replacing canines can be difficult because:

- the canine often lies outside the inter abutment axis.
- The prospective abutments are the lateral incisor usually the weakest tooth in the entire arch and the first premolar, the weakest posterior tooth.

A FPD replacing maxillary canine is subjected to more stress than that replacing a mandibular canine since forces are transmitted outward (labially) on the maxillary arch, against the inside of the curve (its weakest point), while, on the mandibular canine the forces are directed inward (lingually), against the outside of the curve (its strongest point).

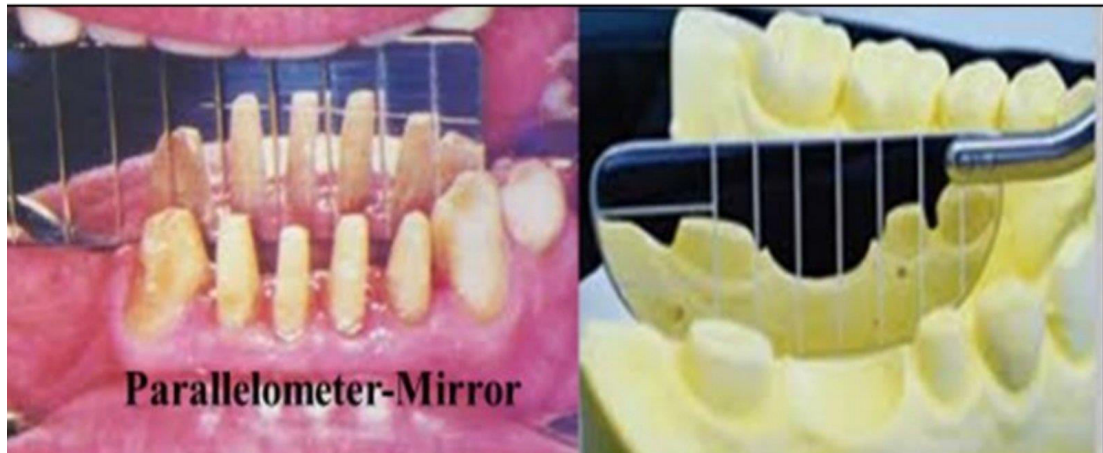

So in cases of canine replacement FPD, you should consider the following points:

- Any canine replacement FPD must be considered a complex prosthesis
- Any FPD replacing a canine should replace more than one additional tooth (the support from secondary abutments will have to be considered).
- An edentulous space created by the loss of a canine and any two contiguous teeth is best restored with Implants or a RPD.

Evaluation of the path of insertion

- Path of insertion should be checked before imprint.
- Parallelometer-mirror can easily spot the positional relationship of the prepared abutments, especially in difficult cases or inexperienced dentist.



FLUID (Moisture) CONTROL & SOFT TISSUE MANAGEMENT IN FIXED PARTIAL DENTURE

LEC. 5
5TH STAGE

Moisture control

FLUID SOURCES OF ORAL CAVITY:

- Saliva (pair of parotid & submandibular and sublingual glands). Saliva flow rate 0.26 +/- 0.16 ml/min and that of saliva while chewing different foods was 3.6 +/- 0.8 ml/min.
- Inflamed gingival tissues/ Iatrogenic soft tissue damage (Gingival bleeding during tooth preparation)
- Water / dental materials (Rotary instruments, triplex syringe, etchants, irrigant solutions). Average a high speed rotatory cutting instrument is 30 mL per minute.
- Gingival crevicular fluid (Sulcular fluid). Gingival crevicular fluid 0.05 to 0.20 μ L per minute

WHY SHOULD ISOLATE THE OPERATIVE SITE?

- *To obtain a dry clean operating field*
- *For easy access and visibility*
- *To improve the properties of dental materials*
- *To protect the patient and the operator*
- *To improve the operating efficiency*

How is moisture control important?

1. Patient related factors

- Provides comfort.
- Protects from swallowing or aspirating foreign bodies.

2. Task/technique being performed

Dental materials are moisture sensitive, success of adhesion and physical properties relies on a dry field.

3. Operator related factors

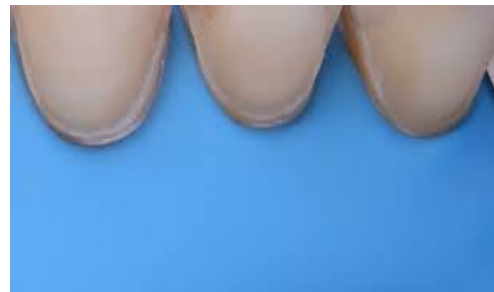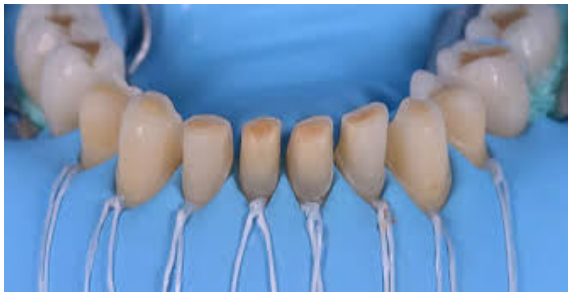- Infection control to minimize aerosol production
- Increased accessibility to operative site
- Improves visibility of the working field
- Less fogging of the dental mirror.
- Prevents contamination.

*Depending on the location of the preparations in the dental arch, a number of **techniques** can create **fluid control** & the necessary dry field of operation.*

1) Mechanical method

a) Rubber dam

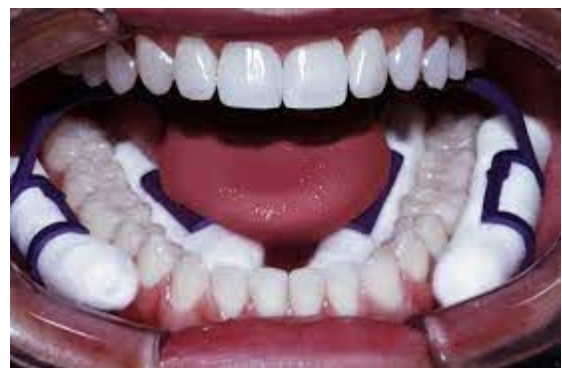When all margins are supra-gingival, moisture control with a rubber dam is probably the most effective method. In most instances, however, a rubber dam cannot be used, so a Multiple Isolation Techniques should be performed to achieve optimal saliva control. Advantages of rubber dam are Isolation of 1 or more teeth, Eliminates saliva from operating field and Retracts soft tissues



b) Cotton roll Absorbent cotton rolls must be placed at the source of the saliva, the muco-buccal fold or in the sublingual area. When a mandibular impression is made, placement of additional cotton rolls to block off the sublingual and submandibular salivary ducts is usually necessary. A horseshoe shape cotton in the maxillary and mandibular muco-buccal folds may be also effective.

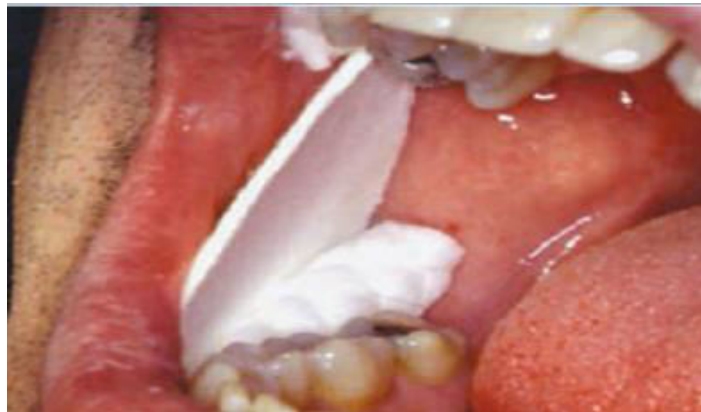c) Cotton roll Holder

Holds cotton rolls in place, have two advantages over cotton roll alone, **Cheek and tongue are slightly retracted and Enhances visibility.**



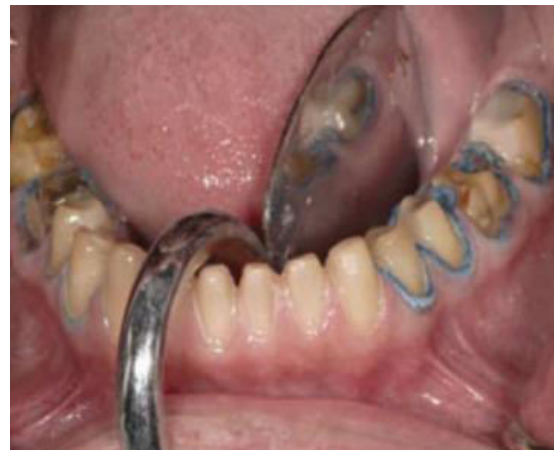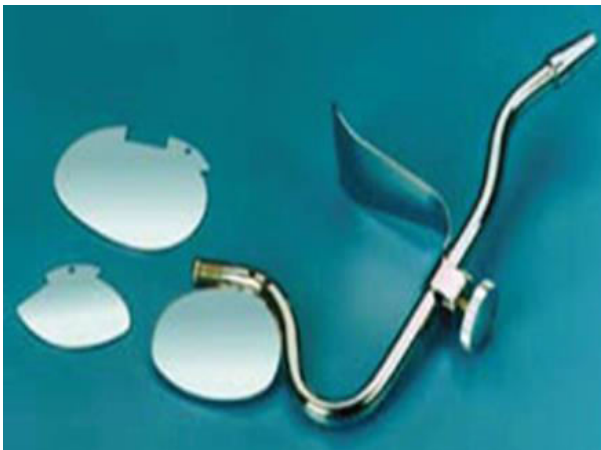d) Absorbing cards

Another method for controlling saliva flow. These cards are pressed-paper wafers that may be covered with a reflective foil on one side. The paper side is placed against the dried buccal tissue and adheres to it. In addition, two cotton rolls should be placed in the maxillary and mandibular vestibules to control saliva and displace the cheek laterally. The tongue can cause problems when work is being done in the mandibular arch. Saliva evacuators may help eliminate excess flow.



e) Saliva evacuators:

If lingually placed cotton rolls repeatedly become dislodged (or in conjunction with a conventional saliva evacuator, fail to control moisture adequately), a flange-type evacuator should be considered. To avoid the risk of soft tissue trauma, this device must be placed carefully. A cotton roll between the blade and the mylohyoid ridge of the alveolar process minimizes intraoral discomfort for the patient and avoids potential injury of the soft tissues. A disposable saliva ejector designed to displace the tongue may also be effective.



2) Chemical method

a) Local anesthesia In addition to the pain control normally needed during tissue displacement, local anesthesia may help considerably with saliva control during impression making. Nerve impulses from the periodontal ligament form part of the mechanism that regulates saliva flow; when these are blocked by the anesthetic, saliva production is considerably reduced.

b) Medications When saliva control is difficult a medication with anti-sialagogic action (drugs that inhibit parasympathetic innervation and thereby reduce secretions, including saliva) may be considered. Dry mouth is a side effect of certain anticholinergics. This group of drugs **includes atropine 1 tablet of 0.4mg per day, Methantheline bromide (banthine): 50 mg 1 hour before procedure dicyclomine, and Propantheline bromide (pro-banthine): 15 mg 1 hour before procedure.** Anticholinergics should be prescribed with **caution** in older adults and should not be administered to any patient with **heart disease**. They are also **contraindicated** in individuals with **glaucoma** because they can cause permanent blindness **Clonidine hydrochloride: 0.2 mg 1 hour before procedure, an antihypertensive drug,** has successfully **reduced salivary output.** It is **considered safer than anticholinergics** and has no specified contraindications. However, it should be used cautiously in hypertensive patients. Clonidine hydrochloride (antihypertensive)

Gingival retraction & Final impression

Gingival retraction (Displacement of Gingival Tissues) :

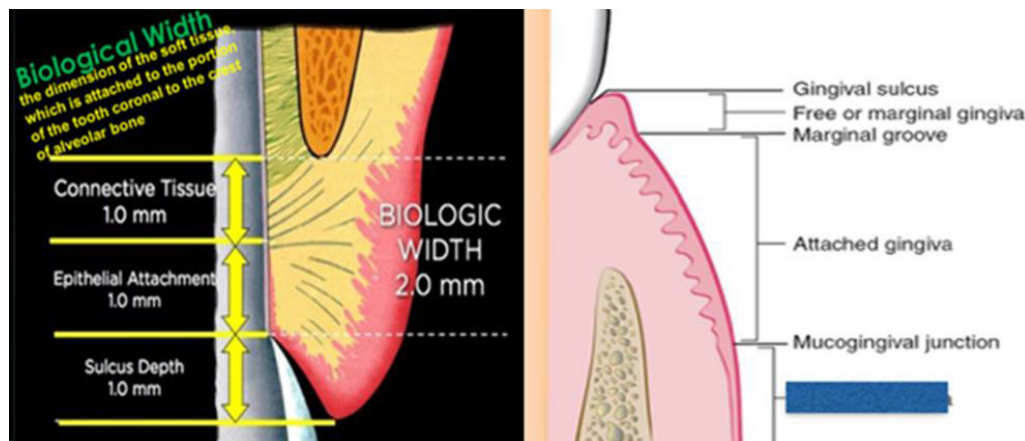
A procedure by which the finishing line is temporarily exposed by enlarging the gingival sulcus (A space both laterally and vertically between the gingival margin and gingival termination) so that printing material penetrates in sufficient quantity to obtain good impression which involves the details of the end margin of the preparation that is located subgingivally (the exact copy of the preparation).

Gingival SULCUS (Crevice)

A shallow groove around the tooth bounded on one side by the surface of the tooth and on the other by the epithelial lining of the free margin of the gingiva. It is "V" shaped with its base at the most coronal level of the epithelial attachment to the tooth root.

Biological Width

Biologic width is defined as **the dimension of the soft tissue, which is attached to the portion of the tooth coronal to the crest of alveolar bone.** There is a definite proportion between the sulcus depth, the epithelial attachment, the connective tissue attachment and the alveolar crest. The **total width of junctional epithelium** (range between **0.71 to 1.35mm**, mean **0.97mm**) and **supraalveolar connective tissue attachment** (rang **1.06 - 1.08mm**, mean **1.07mm**) forms the **biologic width** is $0.97 + 1.07 = 2.04 \text{ mm}$. They established the mean sulcular depth as 0.69



What the Function of biological width ?(its importance in restorative dentistry)

The significance of biologic width is that, **it acts as a barrier and prevents penetration of microorganisms into the periodontium.** Maintenance of biologic width is essential to preserve the periodontal health and to remove any irritation that may damage the periodontium. It is said that a minimum of 3mm space between the restoration margin and the alveolar bone is required to permit adequate healing and to maintain a healthy periodontium. This 3 mm consists of 1mm of supra alveolar connective tissue, 1mm of junctional epithelium and 1mm of sulcular depth. This allows for adequate biologic width (2.04mm) even when the margins are placed 0.5mm within the sulcus.

How to Preserve the biological width?

The location, fit and finish of restorative margins are critical factors in the maintenance of periodontal health. So, a huge consideration and care should have performed during isolation and retraction (even with digital impression techniques) besides tooth preparation to the biological width to ensure the healthy standards and maintenance the normal values of the periodontium.

Objectives of gingival retraction:

- 1.** Create an access for the impression material to the area of the preparation that is located subgingivally.
- 2.** To provide enough thickness of the impression material at the area of the finishing line to prevent distortion of the impression.
- 3.** Providing the best possible condition for the impression material, fluid control.
- 4.** Reduce fluid amount in the sulcus that might cause void in the impression.

Gingival retraction techniques:

1- Mechanical.(plain Retraction cord ,Retraction Crown, Copper band or tube , Anatomic compression caps, Matrices and wedges, Rubber dam)

2- Chemo mechanical (combination of mechanical and chemical) a a

A- Impregnated Retraction cord ,with one of following;

- aluminum sulfate
- epinephrine
- ferric sulfate
- zinc chloride
- aluminum chloride.

B - Displacement polymer & paste(Cordless technique) 3 3

3- radical or surgical means or technique (Electrosurgical,Laser).

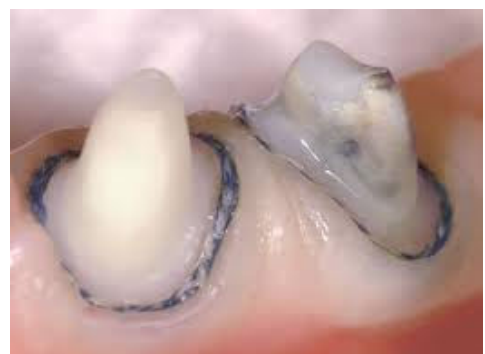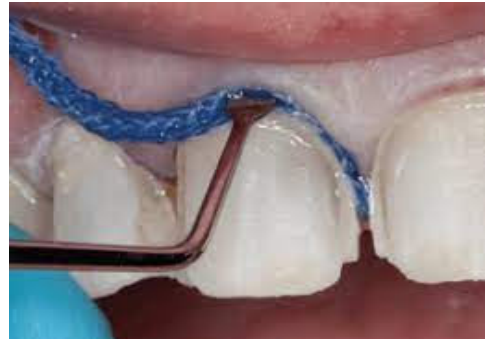1) Mechanical retraction:

It might be done by either of the followings:

- Retraction cord
- Retraction Crown
- Copper band or tube
- Anatomic compression caps
- Matrices and wedges
- Rubber dam

Generally in this technique, we apply pressure on the gingiva through gingival sulcus. This mechanical pressure, after certain period of time, physically push the gingiva away from the finishing line. It might be done by the construction of temporary crown with slightly long margin leaving it for 24 hours, or by using rubber clamp, or by using plain retraction cord(free of medicament). **The most common way by using retraction cord.**

Retraction cord is a special cord made of cotton comes either with or without medicament (vasoconstrictor). Cord without a vasoconstrictor is used to obtain a mechanical gingival retraction. it come in different size.



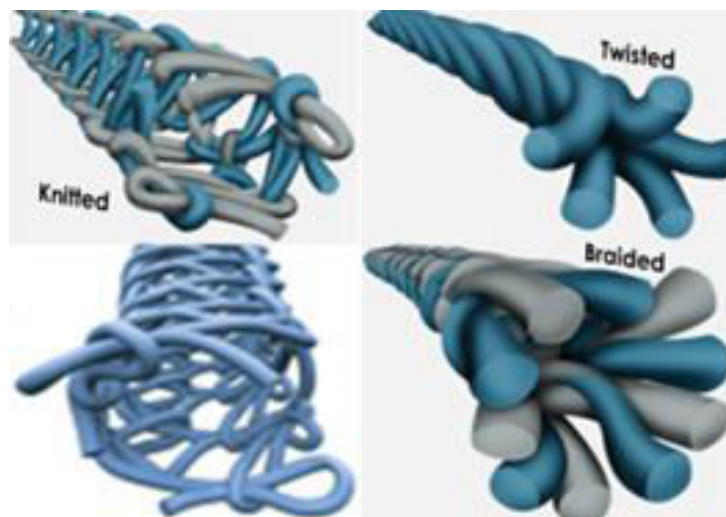
Classification of retraction cords

1. According to chemical treatment

- Plain cord: without any medicament.
- Impregnated cord: impregnated with hemostatic agent.

2. According to configuration

- Twisted (مفتول) - Knitted (محبوك) - Braided (مضفور)



Twisted and braided cords can't offer ease of packability and tissue displacement like knitted ones.

Advantages of Knitted cord over other;

- 1) Afford greater inter-thread space than braided cord.
- 2) Form an interlocking chain of thousands of tiny loops, making it
 - Easy to pack below the gingival margin
 - Stays put when packed into place.
- 3) Compresses upon packing, then expands for tissue displacement.

3. According to thickness (diameter)

According to its size, we have different thickness of retraction cord (color coded thickness): - **Black - 000** - **Yellow – 00**

Both are recommended for anterior teeth with minimal crevicular space.

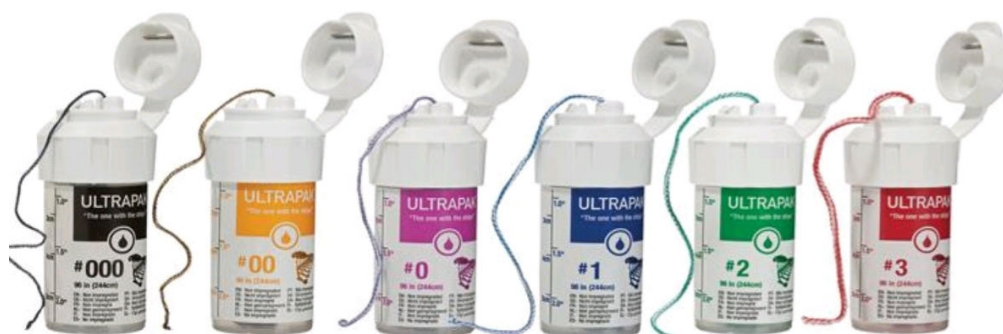Also can be used as a primary cord for the double cord technique.

- **Purple - 0** - **Blue – 1**

Both are recommended for bicuspid. Also #0 is used as the primary cord for the double cord technique, while , #1 cord is recommended to be used as the secondary cord

- **Green - 2** - **Red – 3**

Both sizes are is used for molars where tissue friability permits.



Some textbook divide retraction cord into three main size;

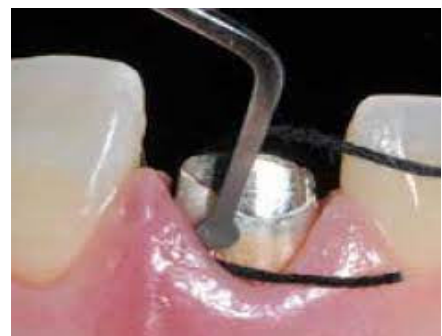- **SMALL**- involve (#000 & #00) to be used in anterior teeth, where thin firmly tissue is present
- **MEDIUM**- involve (#0, #1 & #2) to be used where greater bulk is encountered e.g. posterior teeth
- **LARGE**- involve size (#3) should be used with caution as can produce soft tissue trauma.

Cord packer instruments :

Cord packers are dental instruments used to pack gingival retraction cord into the sulcus.

.Most cord packing instruments have a slightly rounded tip with serration to hold the cord while it is positioned intrasulculary. ***Fischer packing instrument is Cord packer instrument furthermore Plastic instrument Ash No. 6 can be used as cord packer***

The cord packers with round, non serrated working ends are used for atraumatic cord placement; serrated cord packers should only be used with braided cord

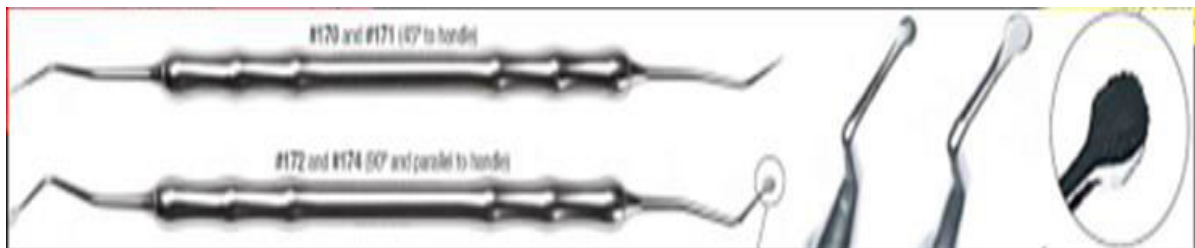


Fischer packing instrument

These specially designed packers ease the packing of Ultrapak® knitted cord. Their thin edges and fine serrations sink into the cord, preventing it from slipping off and reducing the risk of cutting the gingival attachment. It is available in two forms

45° to handle: with heads at 45° to the handle with three packing sides. Circular packing of the prep can be completed without the need to flip the instrument end to end. Use the small packer on lower anterior and upper lateral incisors.

90° and parallel to handle: Same size and three-sided heads as the 45° to handle packer, except one of the heads is in line with the shank and the other is at a right angle to the shank.



2) Chemo mechanical retraction:

Usually in this technique, we use retraction cord that contains a vasoconstrictor (adrenaline or AL.sulfat). Cords are soaked in the Hemostatic solution before placement or some cords are already impregnated with hemostatic solution eliminating this step. (adrenaline 8% , aluminum sulfate or Aluminum chloride 5-10%). Whether plain or impregnated cord, the cord packs into the gingival sulcus between the tooth and the gingival tissue, using a plastic instrument (Fischer packing instrument or Ash no.6) , the cord will physically push the gingiva away from the finishing line and the combination of the chemical action and pressure packing will cause transient gingival ischemia, this will lead to shrinkage of gingival tissue and control fluid seepage from the gingival sulcus, we put the retraction cord inside the gingival sulcus all around the tooth for 10 minutes , the area of our work should be kept dry during this period ,then, the cord can be removed leaving the gingival tissue in an expanding state and this, will provide space to inject the impression material around the tooth at the area of finishing line by the use of an impression syringe.

Step-by-Step Procedure:

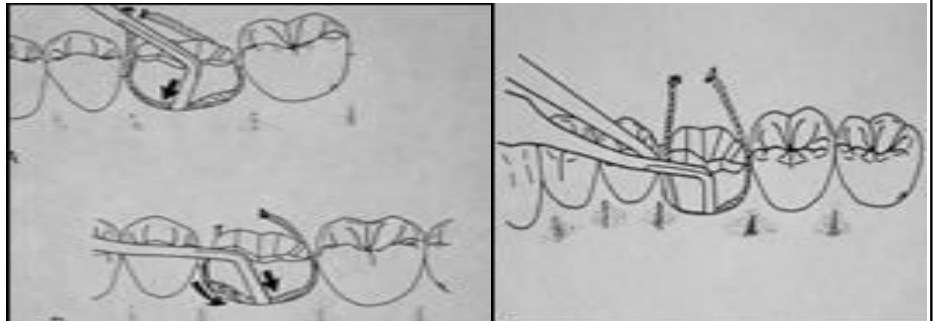
1- Isolate the prepared teeth with cotton rolls, place saliva evacuators and any other aids as required, and dry the field with air. Do not excessively desiccate the tooth because this may lead to postoperative sensitivity.

2- Cut a length of cord sufficient to encircle the tooth.

3- Dip the cord in astringent solution and squeeze out the excess with a gauze square. An impregnated cord can be placed dry but should be slightly moistened in situ immediately before removal from the sulcus, to prevent the thin sulcular epithelium from sticking to it and tearing when it is removed. A convenient way to limit the amount of moisture added is to apply water held between the tips of a dental forceps by opening it.

4- Twist non-braided cords tightly for easier placement.

5- Loop the cord around the tooth, and gently push it into the sulcus with a suitable instrument.

**These Notes should be considered during procedure:**

1- Starting Point: It is easiest to start inter-proximally, because more sulcular depth available than facial or lingual.

2- Instrument Angulation: The instrument should be angled slightly toward the tooth so that the cord is pushed directly into the sulcus, also be angled slightly toward any cord previously packed; otherwise, it might be displaced. A second instrument holding the cord may aid in subsequent placement.

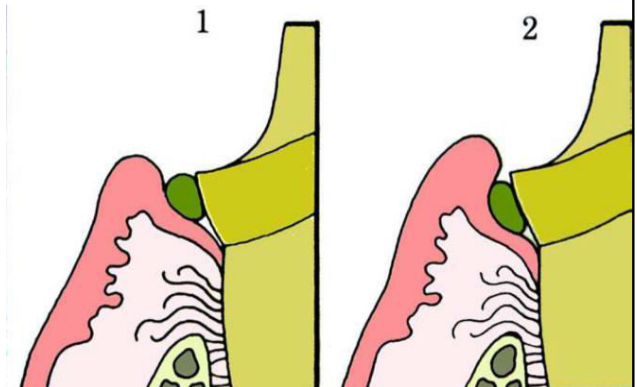
3- Placement and Pressure: Gentle and Firm Pressure applied to the cord, it should place apical to the margins of preparation.

4- Over packing and Repeated use of displacement cord should be Avoided it could cause tearing of the gingival attachment, which leads to irreversible recession.

Double (dual) Cord Technique

With a deeper subgingival preparation, after removing the cord, the sulcus 'closes' not allowing the ingress of the impression material in the subgingival area, so in such a case you might need to use 2 or double cords.

When 2 cords are need, ***it requires that about 1 mm of intact tooth structure remains between the top of the initial cord and the preparation margin. First Cord is Thin, Remain during Impression while the Second Cord is thick.*** In this technique, a thin cord is placed without overlap at the bottom of the gingival crevice. A second cord is placed on top to achieve lateral tissue displacement. The latter is removed immediately before impression making, whereas the initial cord is left in place to help minimize seepage during Impression, be careful not to exert excessive pressure on the tissues, which can damage the epithelial attachment (Biological Width).



This technique is indicated when we have

1. Impression of multiple prepared teeth
2. Impression for compromised tissue health
3. Excess gingival fluid exudates.

Advantages

- 1) The first cord remains in place within the sulcus thus reducing the tendency of the gingival cuff to recoil and displace partially set impression material.
- 2) Helps to control gingival hemorrhage and exudate.
- 3) Overcomes the problem of the sulcus impression tearing because of inadequate bulk - an especially important consideration with the hydrocolloids, which have low tear strength.

Never Pack Dry Cord ??????

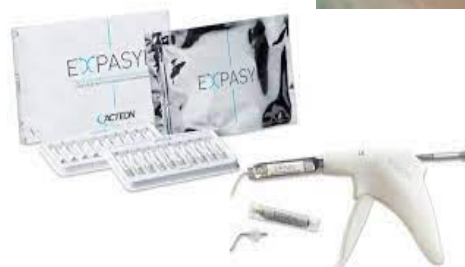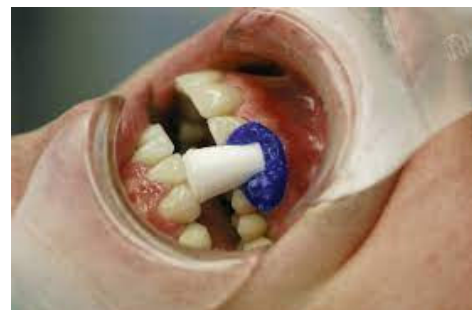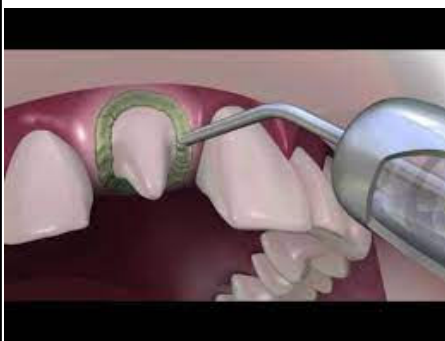
Dry cords adhere to the cervicular epithelium and their removal tears the epithelium and elicits bleeding a wound healing reaction and an unacceptable impression

Gingival retraction paste (Cordless technique)

In most cases, gingival retraction cord is the most effective method for retracting tissue to the depth of the sulcus. Unfortunately, gingival retraction cord may injure the gingival sulcular epithelium and the gingival bleeding is difficult to control when packing a cord into the sulcus making impression difficult or impossible. Using a retraction cord requires proper tissue manipulation and is technique sensitive. For this reason a new class of gingival retraction materials has been introduced in the form of retraction paste like **Expasyl (Aluminum chloride 15%)** and **Magic Foam Cord** (Polyvinylsiloxane, addition type silicone elastomer).

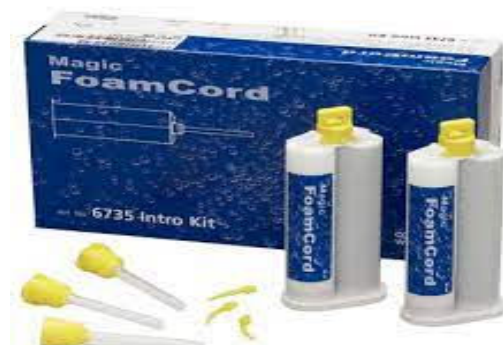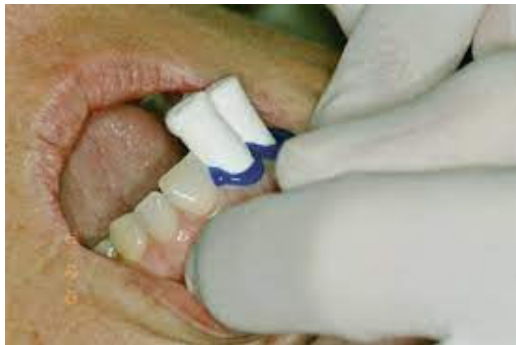Expasyl retraction paste

It is an **AlCl₃-containing paste (Aluminum chloride 15%)** is injected into the dried sulcus with a special delivery gun. Advantages of this system include good hemostasis with less discomfort than with traditional cord. However, less tissue displacement is achieved than with cord. ***Improved displacement may be achieved if the paste is directed into the sulcus by applying pressure with a hollow cotton roll.***



Magic Foam Cord(Coltène/Whaledent)

Magic foam is a polydimethylsiloxane with a tin catalyst. The resulting release of gas resulted in a fourfold(x4) volumetric expansion. When the paste was applied into the sulcus, reaction between base and catalyst take place with gas release that resulted in volumetric expansion of the material that cause an apically directed flow that enlarged the gingival sulcus and allowed impression making. *a hollow cotton roll is used to apply pressure to the expanding foam to directed expansion apically.*



Other cordless retraction materials, e.g., **Racegel** (Septodont) **Traxodent** (Premier); **GingiTrac** (Centrix) provide for excellent hemostasis and some gingival retraction.

Whatever is the material, after isolation of the area any of these material is injected inside the gingival sulcus starting from the deepest area at interproximal area, leave the material for 5 to 10 minutes then clean the area and inspect the result.

The advantage of cordless retraction technique is providing a non-traumatic, non-invasive tissue management and excellent hemostasis in the gingival sulcus for fixed prosthodontic impressions.

3) Surgical technique (radial or surgical means:

Some methods that use the surgical approaches to improve the visualization of the preparation margins of the tooth are not true retraction techniques. This is because they actually remove some part or all of the overlying gingival tissue in order to expose the finish line of the preparation and/or control haemorrhage. These techniques are more invasive and should only be used in cases where there is adequate amounts of attached gingiva. These methods include the following:

1- ROTARY GINGIVAL CURETTAGE (GINGETTAGE)

It is a troughing technique involves preparation of the tooth sub-gingivally while simultaneously curetting the inner lining of the gingival sulcus(a portion of the epithelium within the sulcus is removed to expose the finish line). It should be done only on the healthy gingival tissue

CRITERIA TO BE FULLFILLED FOR GINGETTAGE

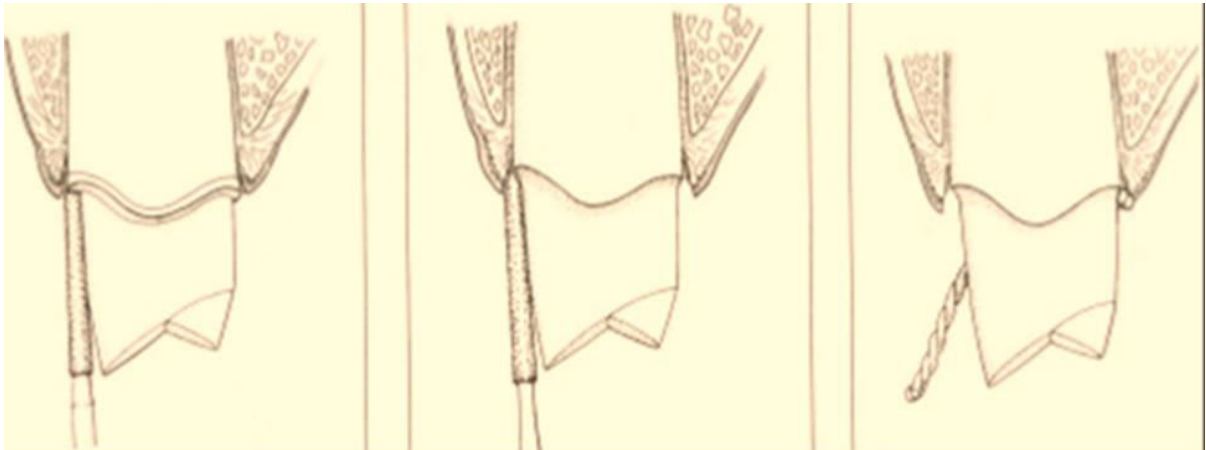
- 1- There should be no bleeding on probing
- 2- The depth of the sulcus should be minimum of 3 mm

DISADVANTAGES OF GINGETTAGE

- 1- Instrument has poor tactile sense so this technique is very sensitive
- 2- It can potentially damage the periodontium

TECHNIQUE OF GINGECTAGE

- 1- It is usually done simultaneously along with finish line preparation.
- 2- Portion of sulcular epithelium is removed using a torpedo diamond bur.
- 3- To improve tactile sense handpiece is run very slowly.
- 4- Abundant water should be sprayed during the procedure.
- 5- A retraction cord is impregnated with AlCl₃ can be used to control bleeding.



Prior to rotary curettage a shoulder F.L. is formed to the level of the gingival crest

A torpedo diamond point simultaneously form a chamfer F.L. and removes the epithelial lining of the sulcus

A cord is placed in the troughed sulcus for hemostasis

2- Electro-surgical method

In this technique, an electro-surgical unit could be used to remove the gingival tissue from the area of the finishing line with the advantage of **controlling the post-surgical hemorrhage**. However, electrosurgery is contraindicated when there is gingival inflammation or periodontal disease. In this case, **gingivectomy** could be performed. **There is the potential for gingival tissue recession after treatment .**

Indications;

- 1- For minor tissue removal before taking impression, toughing the inner epithelium lining of gingival sulcus, improving access for the subgingival margin.
- 2- Control post-surgical hemorrhage.

Main Contra Indications

- 1- Thin attached gingivae (lower anterior, upper canines)
- 2- Electronic medical devices Cardiac Piece Makers
- 3- Metallic restoration & Instruments

3- Soft Tissue Laser:

Soft tissue lasers have been introduced into dentistry and can provide an excellent adjunct for tissue management before impression making. For gingival retraction, Nd- YAG lasers are used.

Advantages of laser:

1. Certain laser dentistry procedures do not require anesthesia.
2. Laser procedures minimize bleeding because the high-energy light beam aids in the clotting (coagulation) of exposed blood vessels, thus inhibiting blood loss.
3. Bacterial infections are minimized because the high-energy beam sterilizes the area being worked on.
4. Damage to surrounding tissue is minimized.
5. Wounds heal faster and tissues can be regenerated.

Disadvantages:

1. Slow technique.
2. Expensive.

Final Impression (Conventional & Digital Impression) in fixed prosthodontic

Lect 6
5th stage

Conventional impression:

An impression is a negative likeness or an imprint of the form and the relationship of the teeth and the surrounding oral tissues. In crown and bridge.

Requirements for a good impression in crown and bridge prosthodontics:

- 1) It should be an exact duplication of the prepared tooth, including all of the preparation, and enough uncut tooth surface beyond the preparation to allow the dentist and technician to be certain of the location and configuration of the finish line.
- 2) Other teeth and tissue adjacent to the prepared tooth must be accurately reproduced to permit accurate articulation of the cast and to allow proper contouring of the restoration.
- 3) The impression of the preparation must be bubble free, that might result in inaccuracy especially in the area of the finish line.

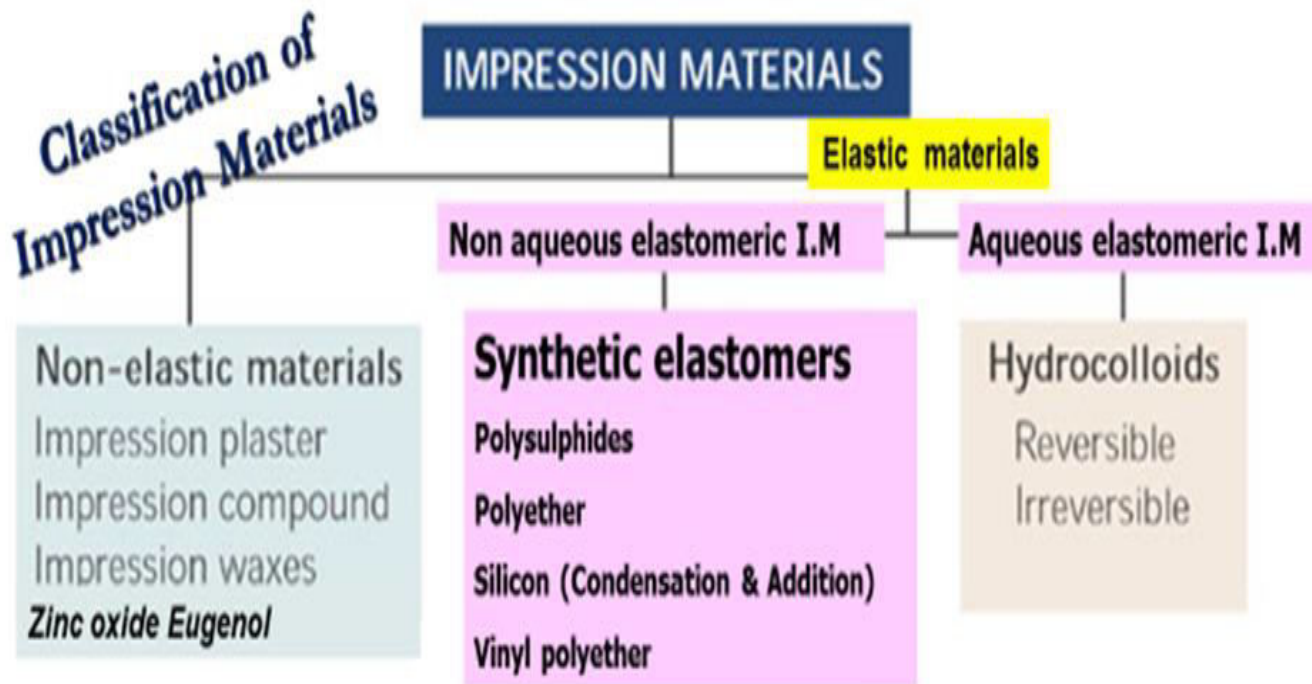
Properties of material used for final impression in crowns and bridges:

- 1) It must be elastic after placement in the mouth because it must be withdrawn from the undercut regions that exist on the external tooth surface adjacent to the prepared tooth. A satisfactory impression must register some of these undercut surfaces without distortion or fracture.
- 2) The hydrophilicity of impression material, hydrophilic materials have a high affinity for moisture, provide good surface wetting, and allow for a high degree of surface detail. Hydrophobic impression materials have a low affinity for moisture, provide poor surface wetting, and a lower degree of surface detail.
- 3) It must have adequate strength to resist breaking or tearing on removal from the mouth.

Properties of material used for final impression in crowns and bridges:

- 4) It must have adequate dimensional stability, accuracy and reproduction of the details so that it is exact negative imprint of the prepared and unprepared teeth. The dimensional stability of the material, which is critical for accurate replication of the intraoral structures. **Dimensional changes** may occur due to:
 - (1) contraction from polymerization.
 - (2) liberation of a by-product or accelerator component.
 - (3) water absorption from a wet or humid environment.
 - (4) a change in temperature.
- 5) It must have handling and setting properties that meet the clinical requirements.
- 6) It must be free of toxic or irritating components.

Classification of impression materials



Non-aqueous elastomeric impression materials (Elastomers):

The elastomeric impression materials, set by chemical reaction, and usually supplied in different consistencies: putty, heavy, medium and light bodies.

In crown and bridge work, we use the light consistency as syringe material to inject over the prepared teeth, remaining dental arch, while, putty and heavy consistency used as tray material to seat over the light consistency during final impression procedure. Whatever the consistency of the elastic material, it is supplied as two containers or tubes: base and catalyst.

1) **Polysulfide impression material:**

The material is supplied as a two-paste system (base and accelerator or catalyst).

Available in a range of viscosities: **light body, medium or regular body, heavy body.**

Advantages:

- 1) Accurate if poured without delay (maximum storage time is 48 hours)
- 2) Long working time (multiple preparations cases)
- 3) Excellent tear resistance (high tensile strain before tearing)

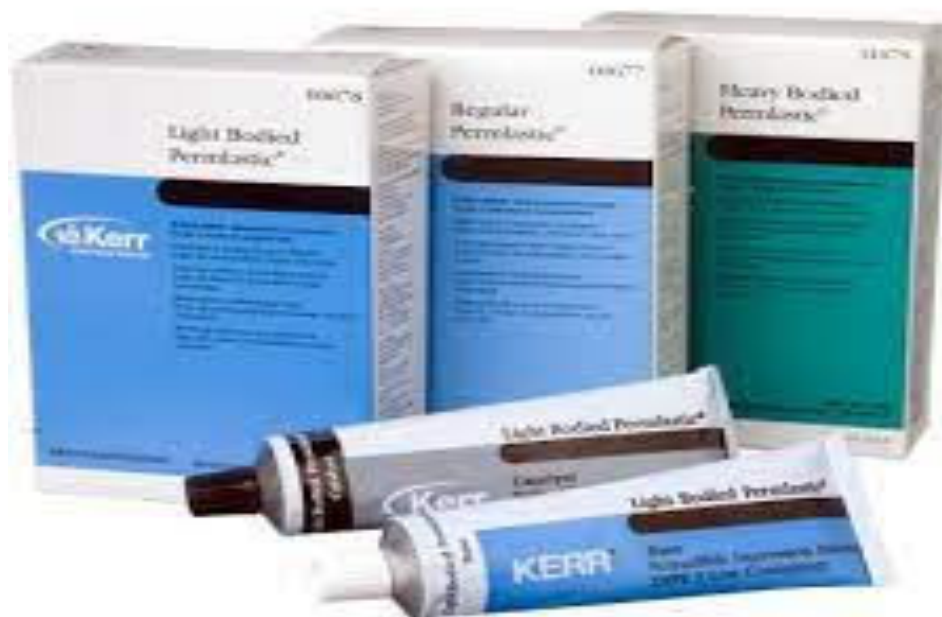Disadvantages:

- 1) Messy with objectionable odor
- 2) Long setting time
- 3) Shrinkage towards the tray (wider and shorter preparation)
 - Evaporation of water as a setting by-product
 - Continuous setting reaction after apparent setting time
 - Unrecovered strain

Recommendations:

- Use a special tray with a 4 mm spacer
- Remove impression in a single swift pull.

Polysulfide impression material:



2) Polyether impression material:

Polyether impression material has excellent dimensional stability (upon polymerization mechanism unlike other elastomers. No volatile by-product), was **initially available in single “regular” viscosity (Impregum)** A recently heavy light bodied system has been introduced

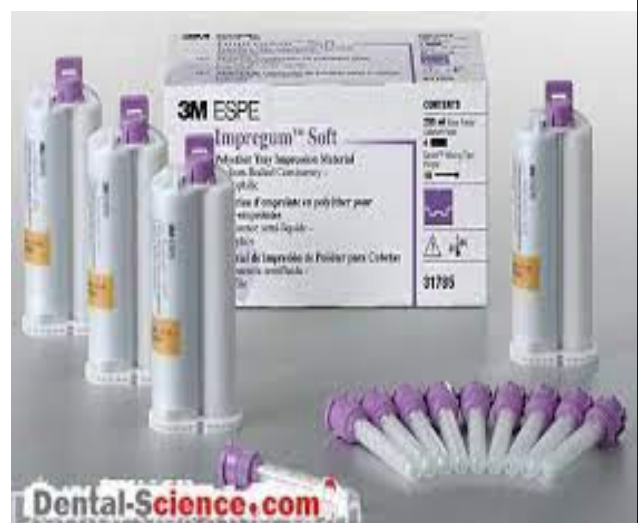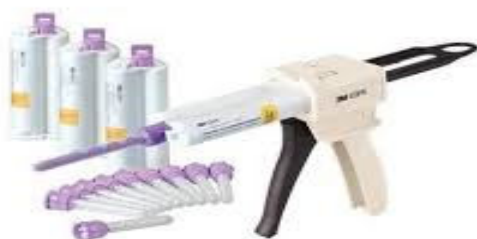Advantages

- 1) Fast setting time of less than 5 minutes
- 2) Has no setting reaction byproducts
- 3) Dimensionally stable
- 4) Relatively hydrophilic
- 5) Adequate tear resistance and very good elastic properties

Disadvantages:

- 1) If stored in high humidity conditions, they tend to swell due to water absorption.
- 2) Relatively rigid material when set, thus considerable force is required to remove the impression from the mouth and stone cast

Polyether impression material



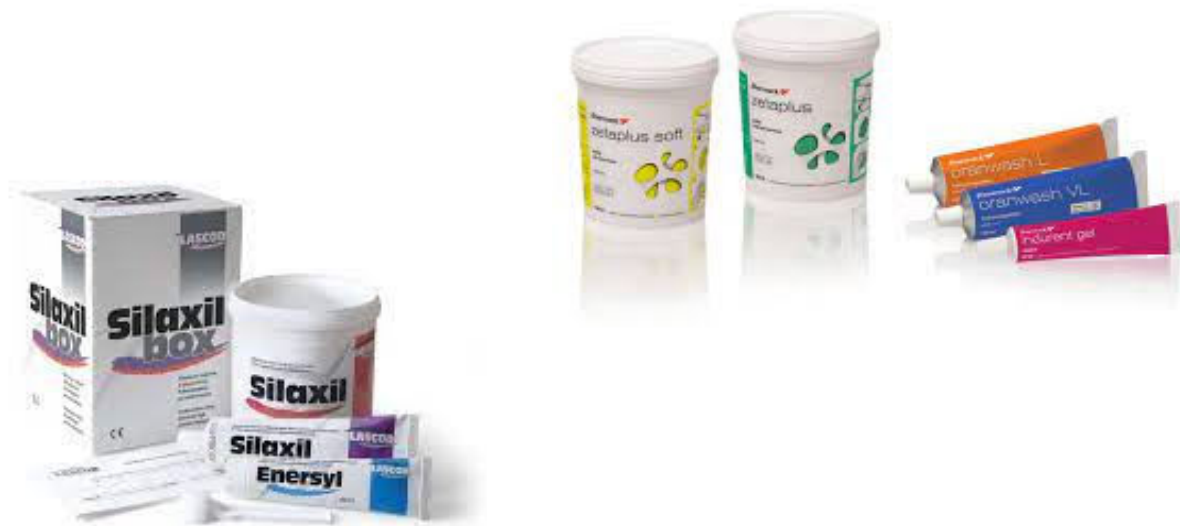3) Silicon impression material:

A. Condensation Silicon impression material:

Condensation silicone has been developed to overcome some of the disadvantages of polysulfide.

- It is odorless and can be pigmented to virtually any shade.
- An additional advantage of condensation silicone over polysulfide is its relatively short setting time in the mouth (typically 6-8 minutes).
- As a result patient acceptance is better than polysulfide.
- It is also less affected by high operatory temperatures and humidity.
- Unfortunately, its dimensional stability is less than that of polysulfide although greater than that of reversible hydrocolloid.
- The material **available in all viscosities (Present in four viscosities ranging from very high (putty) to low.**

Condensation Silicon impression material



Condensation Silicon impression material

Advantages:

- 1) Accurate if regular or heavy body are cast within 6 hours of recording
- 2) Very good elastic properties, recovery of strain, adequate tear strength, neutral color and taste

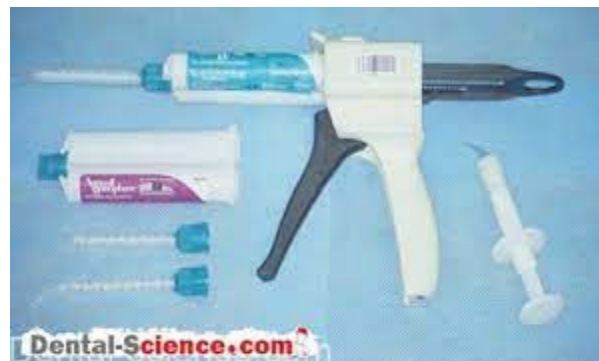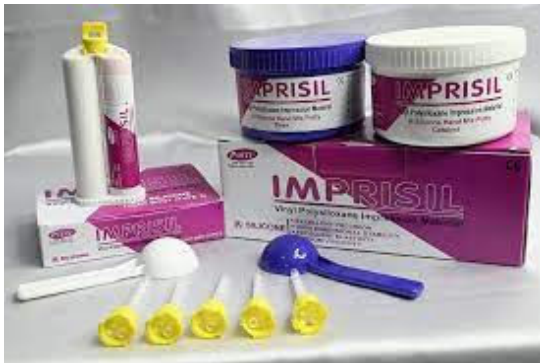Disadvantages:

- 1) poor wetting characteristics because it is extremely hydrophobic
- 2) Volatile by-products (ethyl alcohol) result in weight loss and shrinkage on storage

B. Addition Silicon impression material(vinyl polysiloxane silicon): . .

The main difference between the addition silicone and the condensation silicone is that it has much greater dimensional stability than the condensation type as its polymerization reaction does not give off any by-product. The material is also supplied as a two-paste system (base and accelerator or catalyst). The material available viscosities are extra low, low, medium, heavy, and very heavy (putty) consistencies.

Addition Silicon impression material(vinyl polysiloxane silicon



Addition Silicon impression material(vinyl polysiloxane silicon

Advantages:

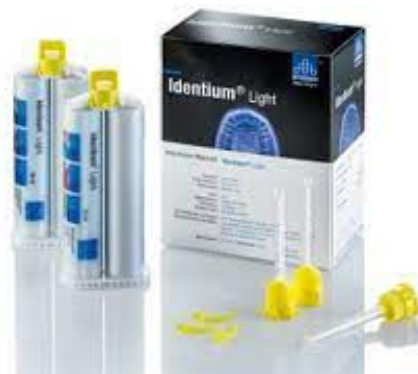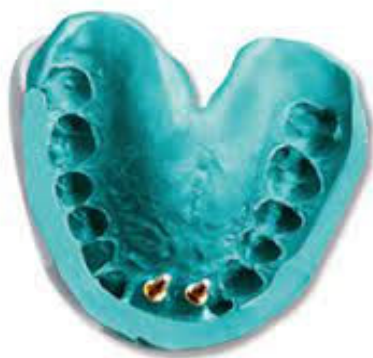- 1) The most dimensionally stable material (no by-product).
- 2) Accurate, high elastic properties, adequate tear resistance, non toxic, neutral color and taste.

Disadvantages:

- 1) Hydrophobic thus strict moisture control is mandatory.
- 2) New hydrophilic addition silicone (Take 1, Kerr).
- 3) Surfactants improve surface wettability.
- 4) Sulfur contamination from natural latex gloves inhibits the setting of addition silicone, so touching the tooth with latex gloves before seating the impression can inhibit the setting of critical surface next to tooth

4) Vinyl Polyether Silicon:

- It is formulation that combines the properties of the addition silicones and polyethers .
- The material has dimensional properties similar to those of the addition silicones and polyethers.



General factors that affect most of elastomeric rubber impression materials:

- 1) The rubber impression materials shrink during polymerization, so we must be sure about complete setting of the material before we remove it from the patient mouth.
- 2) The impression must be poured within one hour after removal.
- 3) The rubber impression material are most accurate when they are used in thin section and this will necessitates the use of special tray when taking the impression to reduce the amount of the impression material so that we reduce the dimensional change that will occur.
- 4) The temperature and humidity reduce the setting time.
- 5) Alteration in the ratio of catalyst to base, will affect the setting time of the material.

For the final impression we need 1- special tray, 2- special impression syringe 3- and the impression material .The special tray is made on the study cast.

Advantages of the study cast:

- 1) Diagnosis and treatment planning.
- 2) Construction of provisional restoration.
- 3) Construction of special tray.

Advantages of special tray:

- 1) It allows the use of impression material in minimum thickness to reduce its dimensional changes.
- 2) It reduces the discomfort of the patient because it is well fitted to the patient's mouth.
- 3) Its small size prevents the forcible opening of the mouth.

impression syringe :

Most of time it is made from clear plastic and should be available with different nozzle sizes, we need this syringe to carry light body impression material from the mixing slab and inject it, then, to the different areas of preparation.



Impression techniques:

According to the Viscosity Of impression Materials used during impression registration we have;

1. One step Impression technique

I. Monophase Single Viscosity

II. Heavy-Light

2. Two steps Impression technique

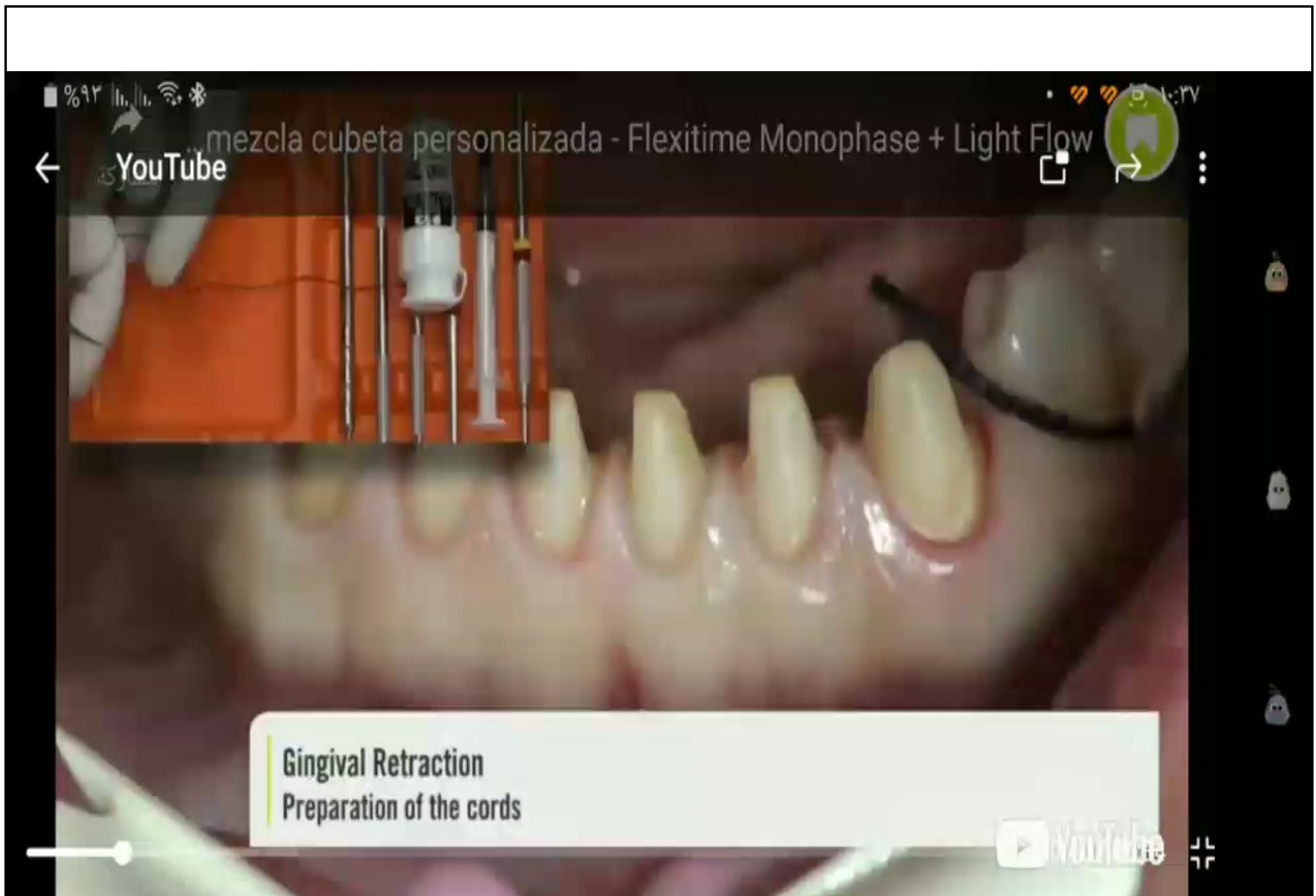
I. Spaced Putty Wash

II. Un Spaced Putty Wash

1) One step (monophase Single viscosity) technique:

Most of the time, we use this technique when we have impression material with single viscosity (medium body with polyether impression material) after we mix the material, part of the impression material is loaded in the syringe from the mixing slab, the other mixed part of the material is loaded into the tray.

The impression material is injected from the syringe around the preparations starting with the most critical parts (pin holes, finishing lines then, the preparations and the remaining part of the dental arch then), the special tray loaded with impression material were then inserted inside the patient mouth and seat over the whole dental arch., wait for complete setting of the impression material then, it can be removed from the patient's mouth.

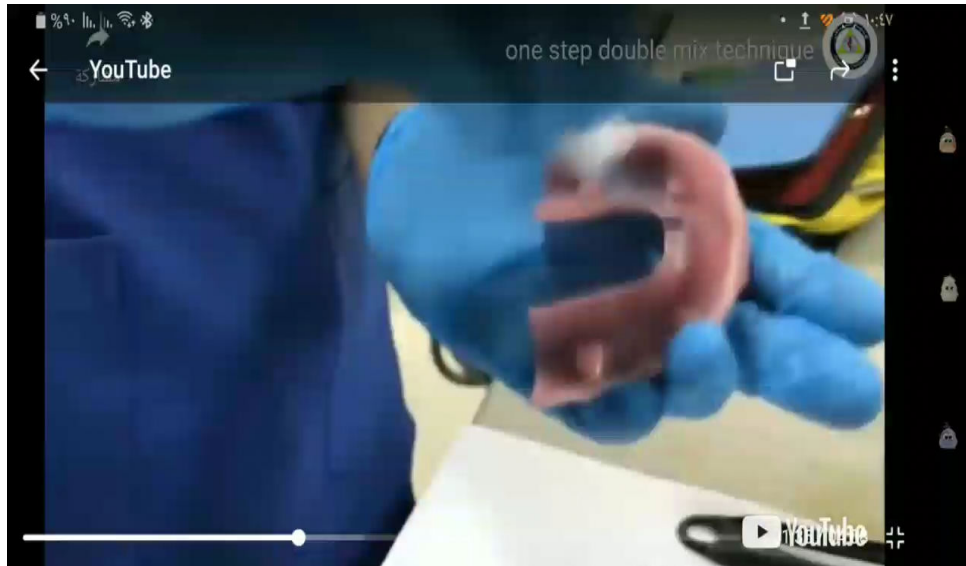


2) One step (heavy light or Double mix) technique:

Usually used with materials that have two viscosities (heavy and light bodies), we mix the heavy and light bodies at the sometime then, the light body is loaded in the syringe while, the heavy body is loaded in the special tray.

We start to inject the light body on the dental arch starting with the prepared tooth then, the special tray with heavy body is inserted inside the patient's mouth and seated over the dental arch. The pressure created by the heavy body will create

- An intimate contact of light body with the prepared tooth surface.
- make direct flow of the light body into details of the preparation.



3) Two steps Putty wash technique:

This technique uses a high viscosity putty material, we start taking the impression with the putty body which could be before or after tooth preparation. Putty impression be:

1) Unspaced putty impression; putty impression is recorded first after tooth preparation, then, after setting it relined with a thin layer or wash of light body impression material.

2) Spaced putty impression: as for un-spaced except a space is created inside the putty impression for the wash (light body) layer. **Space could be created by:**

- I. Record with putty before teeth preparation
- II. Record with putty after teeth preparation. Create space using polyethylene spacer .
- III. Record with putty after teeth preparation. Create a space and escape channels using a scalpel.

Impression Procedure

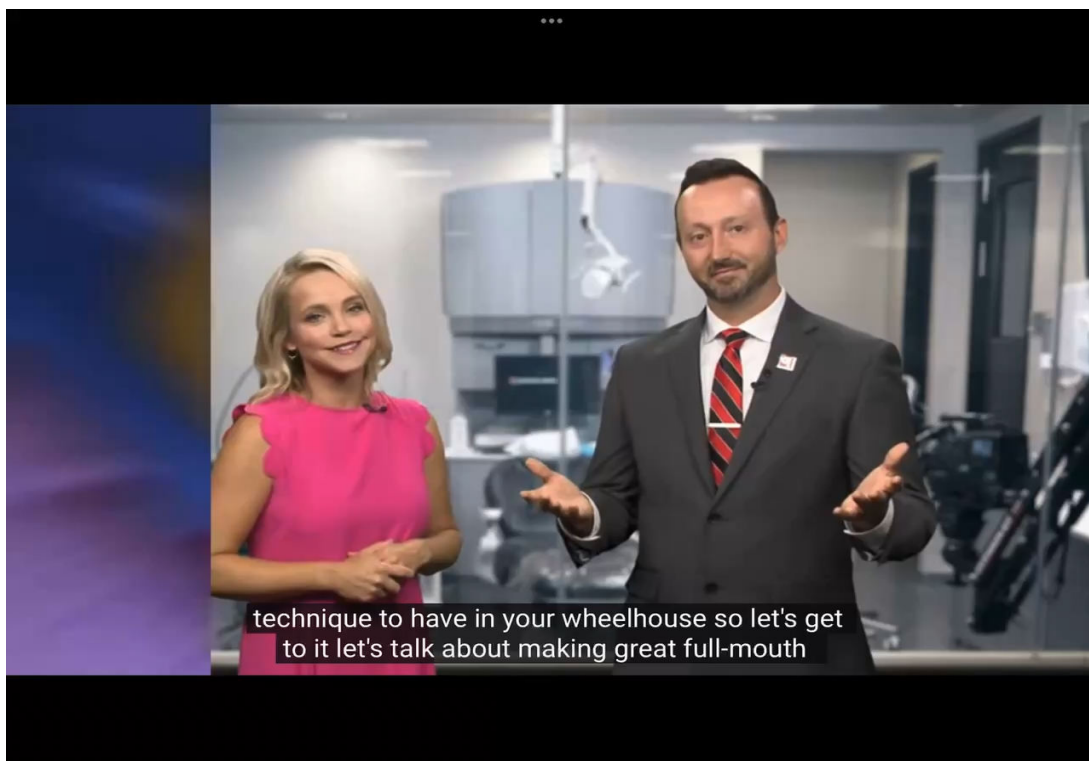
Step one:

Spaced technique:

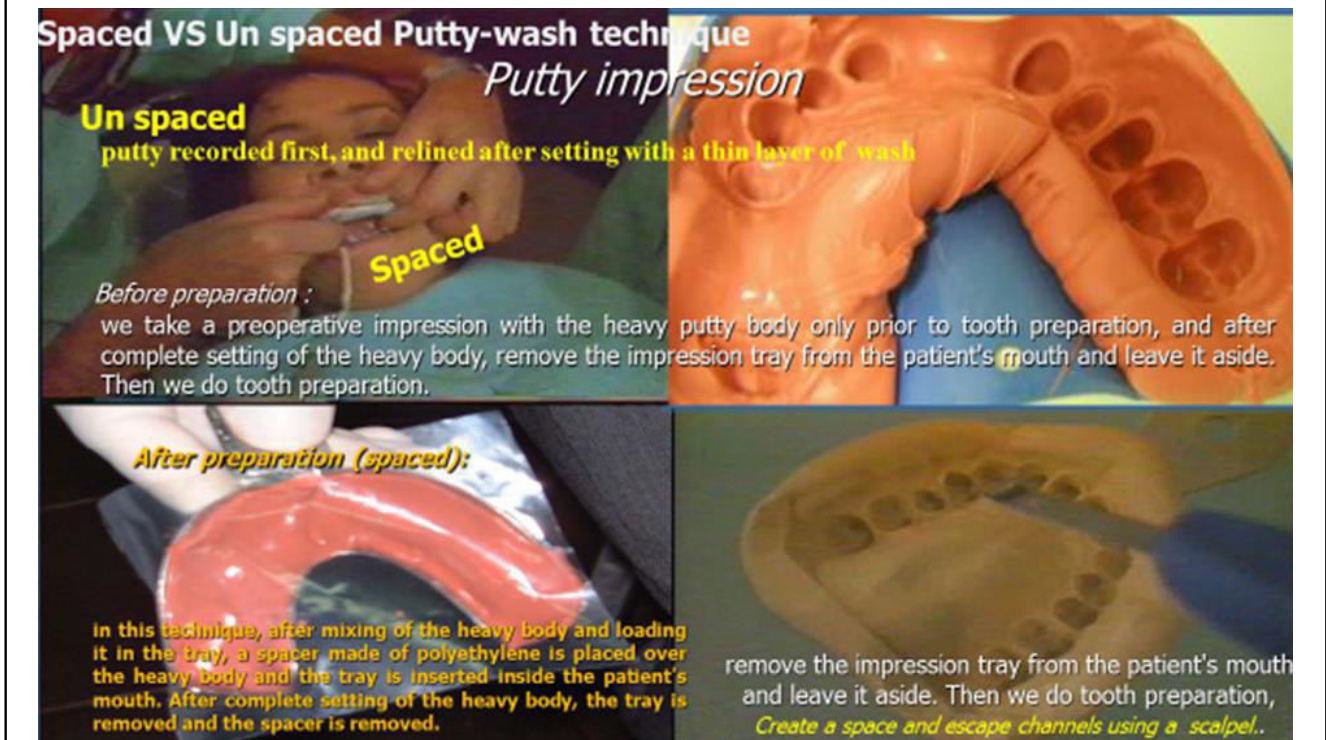Putty impression of dental arch including the prepared tooth or teeth is firstly taken, space inside impression is created by one of following means:

- 1) **Before preparation:** we take a preoperative impression with the putty body only prior to tooth preparation, and after complete setting of the heavy body, remove the impression tray from the patient's mouth and leave it aside. Then we do tooth preparation.
- 2) **After preparation:** in this technique, after mixing of the putty body and loading it in the tray, a spacer made of polyethylene is placed over the heavy body and the tray is inserted inside the patient's mouth. After complete setting of the heavy body, the tray is removed and the spacer is removed.
- 3) Or you can take putty impression after teeth preparation without spacer, then, after removal of the putty impression tray from the patient's mouth create a space and **escape channels** by removing from inside using a scalpel.

Spaced impression technique after preparation

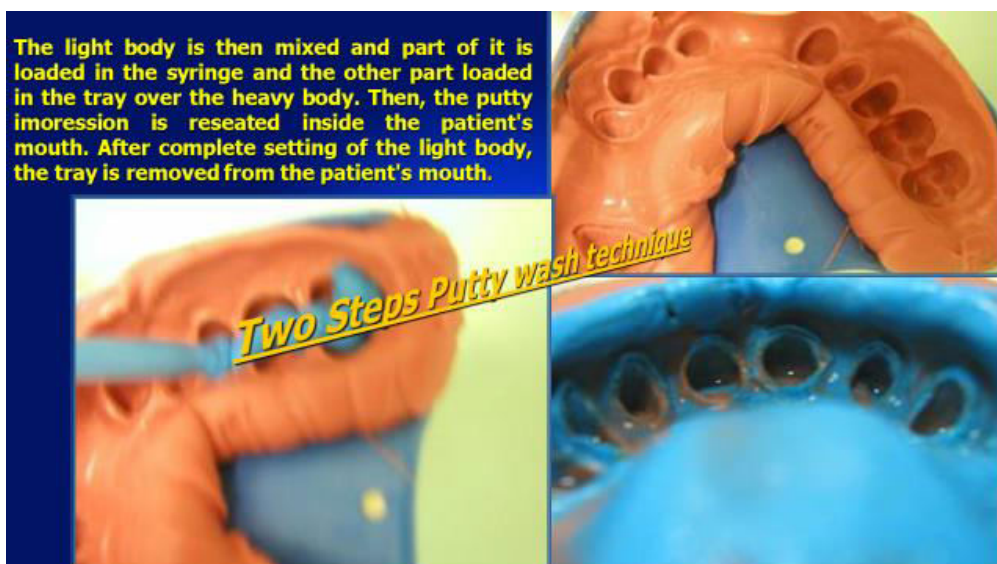


Un spaced technique : as previous except that putty impression recorded after teeth preparation , no space is created her whether by using spacer or removal of surface layer of putty by scalpel, then, after complete setting, it is removed from the patient's mouth and left a side .



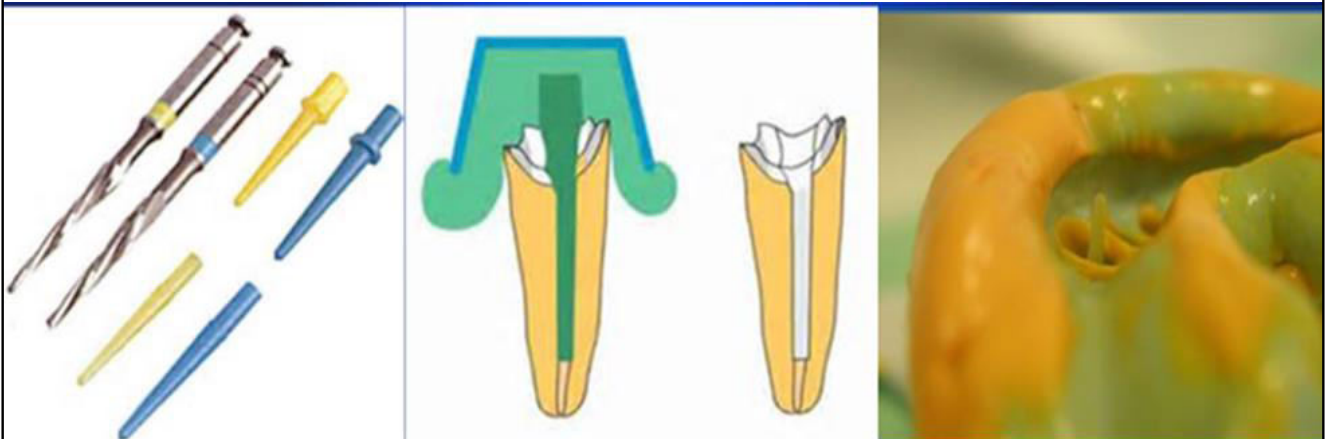
Step two:

Whether spaced or un spaced putty wash technique ,The next step is to mix the light body impression material, part of the mix loaded into the impression syringe while the remaining portion of the mix is place into the tray over the heavy body impression. The light body were then injected around the preparation and the whole dental arch, the heavy body impression were, then, reseated inside the patient's mouth over the injected light body imp.mat. and wait for the complete setting of the light body.



Impression for the post crown:

We need an impression for the root canal space, so, the impression material most of the time is difficult to be inserted inside the tiny canal and even when it fills the canal it might tear during removal or might be distorted during pouring with die stone(during construction of working cast). Therefore, So the impression material need a type of reinforcement, this can be obtain either by a plastic post or by stainless wire, which is inserted into the canal after injecting the light body inside the canal, this will support the impression material and prevents its tearing or distortion during removal of the impression, after the setting of the material, from the patient mouth



HOW TO MAKE IMPRESSION FOR CUSTOM POST

POST SPACE PREPARATION

WITH FERRULE

0:10 1:51

YouTube

المشاركة المشاهدة لاحقاً

Back

اللاثين ٢٦ كانون ١

15 15

The impression should be inspected for the following:

1. Finishing line should be continuous from one side to another.
2. Presence of air bubble in the area of preparation.
3. Good attachment of the impression material to the tray.

Remember that you need the following requirements to obtain a good final impression:

- 1) Special tray.
- 2) Impression syringe.
- 3) Gingival retraction when needed.
- 4) Good understanding of the physical properties of the impression material which results in good handling of the material.
- 5) Dry field of operation. This is because all elastic impression materials, except hydrocolloids, are hydrophobic. i.e., they don't displace moisture; therefore, any moisture if present will result in voids or folds within the final impression.

Digital impression

Digital impression represents the most recent development in Dentistry. It is procedure of recording the information related to the prepared teeth using scanning device that going to convert the shape of the prepared teeth into three dimensional (3-D) image display on the computer monitor.

The operator were then designs a restoration shape using a special computer software, which is connected with a milling machine. This procedure is termed CAD-CAM (Computer Aided Designing - Computer Aided Manufacturing). The CAD/CAM system utilize a process chain consisting of scanning, designing and milling phases.

The introduction of CAD/CAM systems in 1980s to dental field resolved a wide range of these limitations founding in the conventional impression techniques that required many steps; preparation of the abutment teeth, tray selection, impression making ,impression disinfection, wax up and finally casting. As a result, several factors could effect on the accuracy of the traditional impression technique , furthermore ,CAD CAM provide speed, storing the captured images with no distortion , 3D pre-visualization and checking the preparation and restoration before cementation .

Digital impression

The introduction of CAD/CAM systems in 1980s to dental field resolved a wide range of these limitations founding in the conventional impression techniques that required many steps; preparation of the abutment teeth, tray selection, impression making ,impression disinfection, wax up and finally casting.

As a result, several factors could effect on the accuracy of the traditional impression technique , furthermore ,CAD CAM provide speed, storing the captured images with no distortion , 3D pre-visualization and checking the preparation and restoration before cementation .

Based on their production methods the Digital scanning can be divided into:

1) Indirect (extra oral) digital impression (Dental laboratory models):

The indirect systems scan a stone cast or die of the prepared tooth, in the dental lab (eg Cerec-in lab).Many of this system produce copings which require the dental technician to add esthetic porcelain for individualization and characterization of the restoration.

Dis-advantages:

- A cast need to be fabricated so, impression making is must, however master cast fabrication is time consuming and error prone method.
- Shadowing effect limits use of extra oral digitization method.

2) Direct (intra oral) digital impression :

Most widely and commercially used System. This system can scan the tooth preparation intraorally using an intra-oral camera (scanner) to capture the desired image (optical impression). This image is then electronically transferred either to in office CAD CAM or in lab CAD CAM (a manufacturing facility) and by selecting appropriate materials, the restoration can be fabricate and seat within a single appointment. This procedure is termed CAD-CAM (Computer Aided Designing - Computer Aided Manufacturing).

The main advantages of Direct (intra oral) digital impression, It allows the dental care professional to take the data directly from the prepared tooth and there is no necessity of taking an impression and fabricating a cast, however , the only disadvantage of this technique that Tongue and saliva may pose some problems

Based on data files created intra oral camera (scanner) might be:

1) Open-system software:

Architecture files, typically termed STL files , are not dependent on the manufacturer, and can be used virtually in any design software to fabricate a final restoration(Allow the adoption of the original digital data by CAD software and CAM devices from different companies)

2) Closed-system software:

Architecture collects and manipulates data modules by the same manufacturer, offering laboratory owners security and a one-stop for resolving problems(All the steps are integrated into one system, and there is no interchangeability between different systems from other companies

Scanning procedure

After the tooth preparation is complete and the tissues are retracted to visualize the tooth margins, the tooth is dried and readied for scanning. Some scanning systems require the use of an oxide powder on the tooth to remove optical highlights from the surface of the preparation and to enhance the scan quality. Scanners use either a series of static images or a stream of video images to capture the geometry of the tooth preparation.

Advantages of digital impression

1. Digital impressions eliminate the uncomfortable experience of making a physical impression.
2. Evaluation of your preparation.
3. The image on the monitor shows you if you have captured all the needed details before sending it to the lab.
4. The accuracy of the mounting, bite registration, and stability of the dies create a model that allows the laboratory technician to fabricate a final restoration that has excellent marginal fit and incredibly accurate occlusion.
5. The ability to see if proper occlusal reduction has been achieved.
6. Recordkeeping. The digital impression can be stored and saved in PCs.
7. Disinfection of impressions is now a non-issue with a digital system.
8. Reducing Chairside time

Disadvantages of Digital impression.

- 1- The large size and the weight of the camera head and the device size.
- 2- Digital equipment's are complex and trained operator is required to operate and maintain the device.
- 3- High Cost.

Disinfection of Impressions

Set impressions are a source or reservoir for pathogens. They have been found to contain microorganisms – bacteria, fungi and viruses – following their removal from the patient's mouth, through transport to the laboratory and have also been shown to transmit microorganisms into stone and plaster while models are being poured.

As such, they represent a risk for disease transmission to dental healthcare workers, transporting personnel, and laboratory personnel through indirect contact.

Therefore, Irrespective of the purpose, an appropriate infection prevention protocol must be followed before, during and after impression taking to avoid cross-contamination and the risk of disease transmission.

Disinfectants VS Antiseptics

Antiseptics, define as, Chemicals that destroy or inhibit the growth of microorganisms on living things (cell).

While, **Disinfectants** are, Stronger Chemicals that destroy or inhibit the growth of microorganisms on object or non-living things .Accordingly, disinfection of impression is The process of destruction or removal of all pathogenic organisms, or organisms capable of giving rise to infection from impression.

Disinfectant protocol & Types of Impression Materials

Impression materials include the use non-elastic (such as compound) and elastic impression materials. The vast majority of procedures use elastic impression materials – aqueous hydrocolloids (typically alginate) and non-aqueous elastomeric materials including vinylpolysiloxanes (VPS or addition reaction silicones) (e.g., Aquasil), condensation reaction silicones (e.g., Xantopren), polysulfides (e.g., Permlastic) and polyethers (e.g., Impregum).

The characteristics of these materials with respect to their

(1) hydrophilicity, (2) the presence or absence of surfactant and (3) their tolerance of immersion in water or other fluids are key elements in understanding disinfection protocols for impression materials.

For example, VPS is hydrophilic and will absorb water and other liquids, changing its dimensions, and surfactant may also leach out affecting the wettability of the impression; polyether is also hydrophilic and can leach; and alginates are sensitive to wet and dry environments.

An Overview of the Disinfection Procedure

Impression materials cannot tolerate heat and must therefore be chemically treated, as with heat-sensitive instruments (except handpieces). However, while instruments can be cold sterilized by immersing them in a hospital-level disinfectant for several hours (the number depending on the chemical), impression materials are sensitive to long-term immersion and are therefore disinfected, as opposed to cold-sterilized which takes longer.

Disinfectant materials

Glutaraldehyde / Cidex (2% alkaline NaHCO_3):- It is a high level disinfectant. Especially active against tubercle bacilli , fungi and viruses. Less toxic than formaldehyde. Exposure time: > 10hrs.

Phenols: Acts by cell membrane damage thus releasing cell contents and causing lysis. Eg. Cresol (LYSOL) ,chlorhexidine (SAVLON),chloroxylenol (DETTOL) and hexachlorophen. Phenol is commonly found in mouthwashes, scrub soaps and surface disinfectants. Low efficiency disinfectant

Halogens : Bleaching powder or hypochlorite solution mostly used disinfectant for HIV infected material. In concentration of 0.05 or 0.5% used for surface material and instruments disinfection. Should be prepared daily because of instability of sodium hypochlorite solution. Active against bacteria, spores, fungi and viruses (HB, HIV)

Iodophors & Iodine Active against bacteria, spores & some viruses & fungi. (7.5% Povidone+iodine= Betadine The manufacturer's directions for disinfection must be followed.

Interocclusal Record (Bite Registration Record)

Lecture7

Interocclusal Record (Bite Registration Record)

an imprint of the positional relation of opposing teeth or jaws to each other, made of the surfaces of occlusal rims or teeth with a bite registration material such as plaster of paris, wax, zinc oxide-eugenol paste, acrylic resin, or silicon impression material

Objective of bite registration:

- 1)** To transfer the relation between the upper and lower dental arches from the patient's mouth to the articulator we need bite registration. Proper interocclusal record is important to orient the die (s) of the same arch to the opposing arch.
- 2)** Allow the laboratory technician to create proper contours and alignment of the metal substructure of the restoration as well as the proper contour and intercuspation of the teeth in porcelain.
- 3)** Failure to capture an accurate interocclusal record will result in time-consuming chairside adjustments, the need for remounting casts and possible refabricating of the prosthesis

Accuracy of an interocclusal record Influenced by the following factors:

- 1)** Material properties.
- 2)** Recording technique.
- 3)** Reliability of the mandibular position influenced by the occlusal contacts.
- 4)** Muscular action.
- 5)** Tissue changes within the TM joints.

According to Dawson criteria for accuracy in making interocclusal records (requirements)

- 1- The recording material must not cause any movement of teeth or displacement of soft tissues.
- 2- The recording material must fit on the casts as accurately as it fits the teeth intra-orally.
- 3- The accuracy of the jaw relation record should be checked in the mouth and on the casts.

Bite Registration Materials

Characteristics of ideal registration material:

To be ideal, bite registration material must have the following properties;

- 1) Limited resistance before setting to avoid displacing teeth or mandible during closure.
- 2) Rigid after setting
- 3) Minimum dimensional change
- 4) Accurate record of incisal & occlusal surfaces
- 5) Easy to manipulate
- 6) No adverse effect on tissue
- 7) Records should be verifiable

Bite Registration Materials:

1) Impression plaster (soluble plaster)

- 1- Type 1 modified with addition of accelerators to decrease setting time & setting expansion
- 2- Records are accurate , rigid after setting , do not distort with extended storage ,
- 3- Difficult to handle, record is brittle.
- 4- Not used now

2) Bite registration waxes

- 1- Ease of manipulation.
- 2- High coefficient of thermal expansion
- 3- High resistance to closure.
- 4- Distortion of wax during removal is also very common.
- 5- Dimensionally Inaccurate , may interfere with active & passive movements

It has been classified as most inaccurate material among the interocclusal records studied. Therefore, zinc oxide eugenol or resin was added to wax impression in a very thin layer to improve poor detail transfer and displacement of wax.

4) Zinc oxide eugenol paste

- 1- Fluidity before setting – is a critical factor because it ensures minimal interferences with mandibular closure during recording.
- 2- Adhesion to carriers
- 3- Rigid and inelastic after setting
- 4- Accuracy in recording occlusal and incisal surfaces
- 5- High degree of reproducibility
- 6- Brittle(vital portion may be lost by breakage)
- 7- Sticks to tissues
- 8- Unless trimmed ,flash around the teeth may prevent accurate seating of casts

5) Acrylic Resin

The most frequent application of acrylic resins for interocclusal records is in the fabrication of single stop centric occlusion records. Acrylic resin is both accurate and rigid after setting.

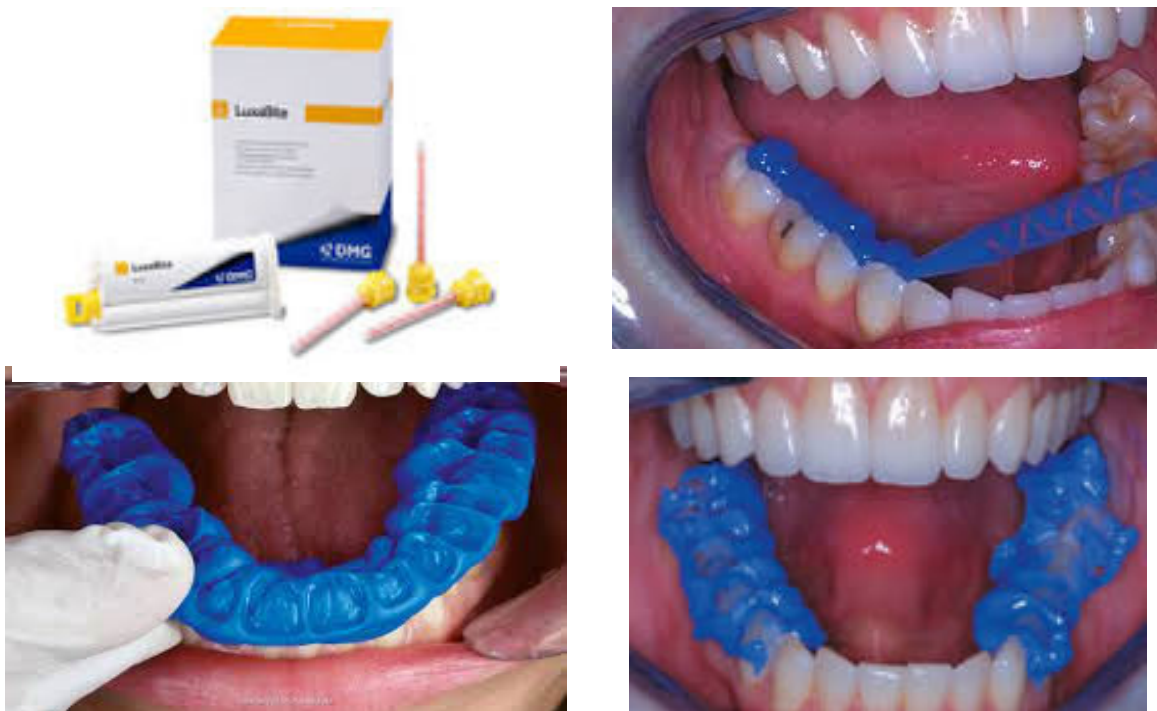Disadvantages:

- 1- Dimensional instability due to polymerization shrinkage.
- 2- Rigidity of the material can damage plaster cast and dies during mounting on the articulator.

6) Elastomers for IOR (luxabite):

- 1- Least error among the materials studied. They are easy to manipulate and offer little or no resistance to closure.
- 2- Set to a consistency that makes them easy to trim without distortion, and accurately reproduce tooth details. Furthermore, among the elastomers, addition silicones exhibit least amount of distortion.
- 3- The excellent dimensional stability of addition silicones is attributed to the fact that it sets by addition polymerization reaction. Therefore, no by-products and no loss of volatiles occur in addition silicones.
- 4- Dimensional stability, accuracy and elastic recovery, with short working time.

Elastomers for IOR (luxabite)



OCCLUSION

The contact of the opposing surfaces of teeth of the two jaws". It is a relationship of the mandibular and maxillary teeth when closed or during side to side movements of the mandible; when the teeth of the mandibular arch come in contact with the teeth of the maxillary arch in any functional or parafunctional relationship.

DETERMINANTS OF OCCLUSION:

Anterior Determinants of Occlusion

The teeth of the maxillary and mandibular arches represent the Anterior Determinants of Occlusion, it involves;

1) The anterior teeth: (canine to canine)

Determine the movement of the anterior portion of the mandible (guide the mandible in right and left lateral excursive movements and in protrusive movements).

Anterior guidance is variable since it can be altered by: restorations, extractions, orthodontics, attrition, etc.

2) The posterior teeth:

- Vertical stops for mandibular closure.
- Guide the mandible into the position of maximum intercuspation.

Posterior Determinants of Occlusion

Temporomandibular joint, right and left, represent the posterior determinants of occlusion. Condylar guidance is a fixed factor, and the TMJs are the posterior controlling factor in mandibular movement.

CLASSIFICATION OF OCCLUSION

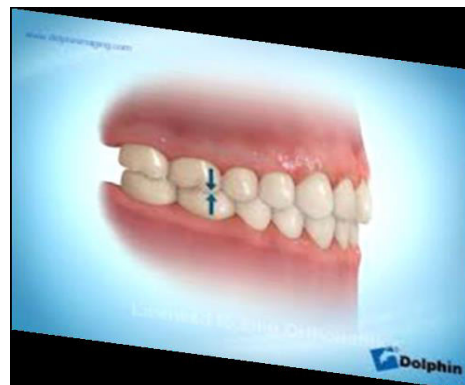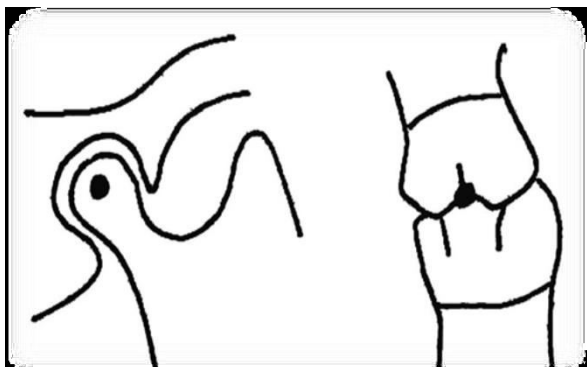1. BASED ON MANDIBULAR POSITION

According to the position of mandible occlusion can be divided into two main subdivisions centric and eccentric occlusion.

A. Centric Occlusion (CO):

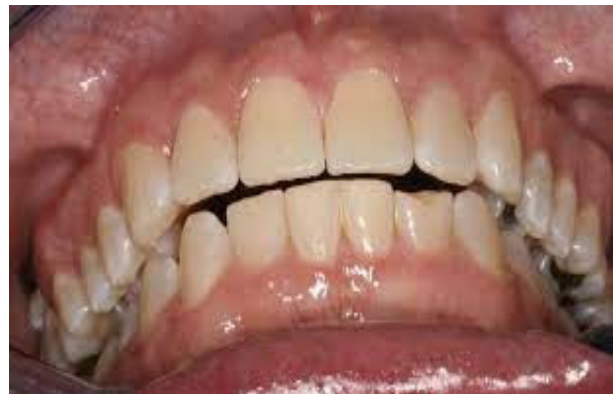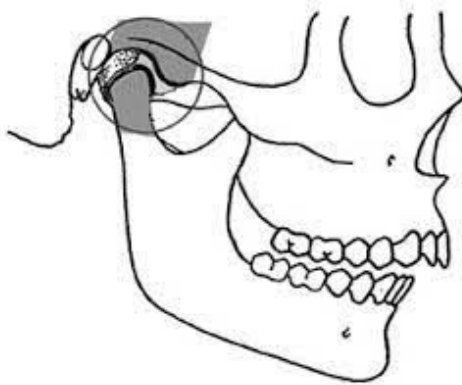
The occlusion of teeth as the mandible closes in centric relation.

- It's a tooth-to-tooth relation.
- It is a reference point from which all other relations are eccentric.



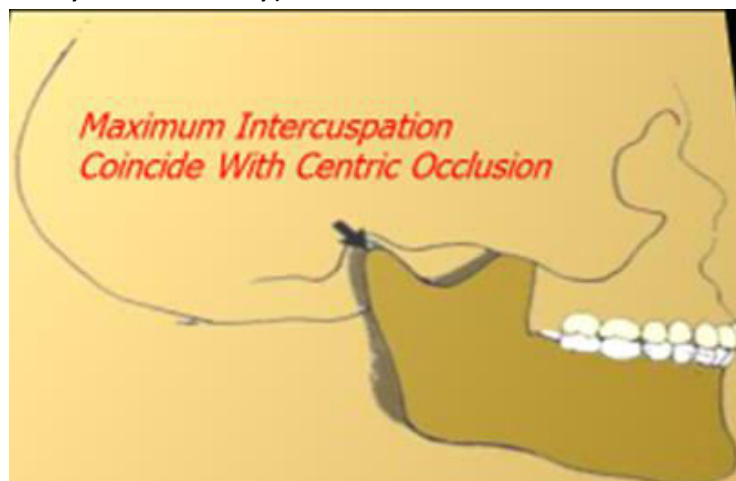Centric relation (CR)

Centric relation is a bone-to-bone relation. It is the relation between the maxilla and the mandible when the condyles are in the rear most upper most mid most in the glenoid fossae.



Maximum Intercuspation (MI): It Is The Most Closed Complete Interdigitation Of Mandibular And Maxillary Teeth Irrespective Of Condylar Centricity. In Other Words, Maximum Intercuspation May or May Not Coincide With Centric Occlusion, Depending On the Position Of The Condyle.

If maximum intercuspation occurs with the condyles being out of centricity, then both positions would not coincide, with the maximum intercuspation in that case, referred to as the **habitual or physiological occlusion or closure**, and is considered as an eccentric position. On other hand, low percentage of population have their maximum intercuspation coincide with centric occlusion (condyles centricity) such a case referred as **ideal occlusion**.



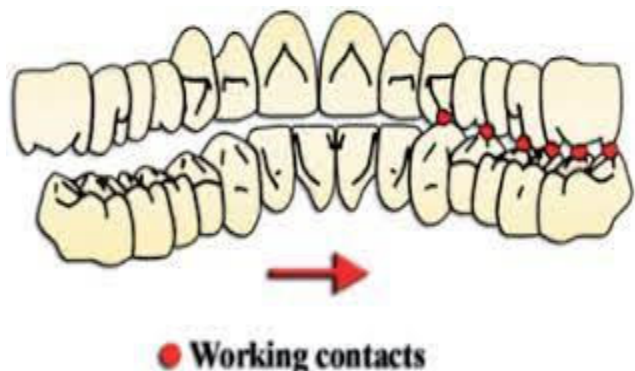
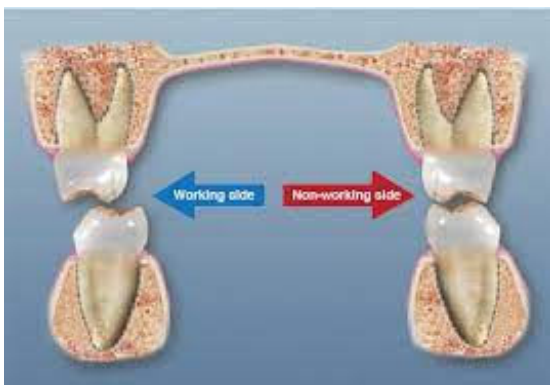
You should keep in your mind the following points:

- 1) Centric relation should not be confused with the centric occlusion.
- 2) Centric relation is not a relation about teeth. (The edentulous mandible is in centric relation if the condyle-disk assemblies are completely seated.)
- 3) Centric relation is not just a convenience position that is used because it is repeatable. It is the universally accepted jaw position because: **It is physiologically and biomechanically correct. Secondly it is the only jaw position that permits an interference-free occlusion.**

B. Eccentric Occlusion: . .

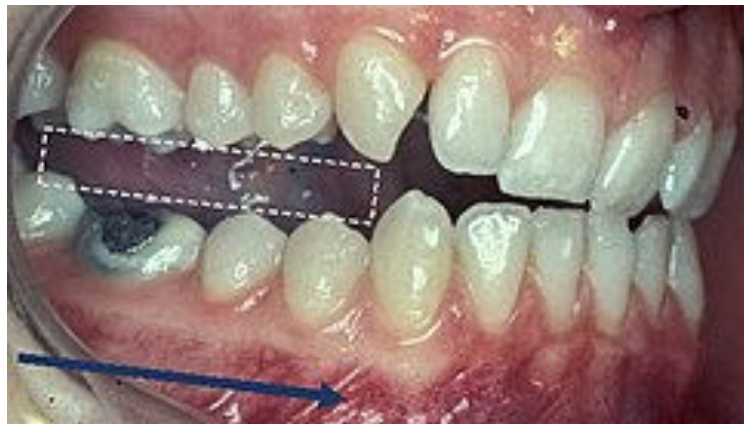Occlusion other than centric occlusion refer to contact of teeth that occurs during movement of mandible.

Lateral occlusion: (working or functional side occlusion) It is defined as the contact between opposing teeth (canines and posterior teeth) when the mandible is moved right or left of the midsagittal plane. The contacts occur on the sides towards which the mandible moves (working side).



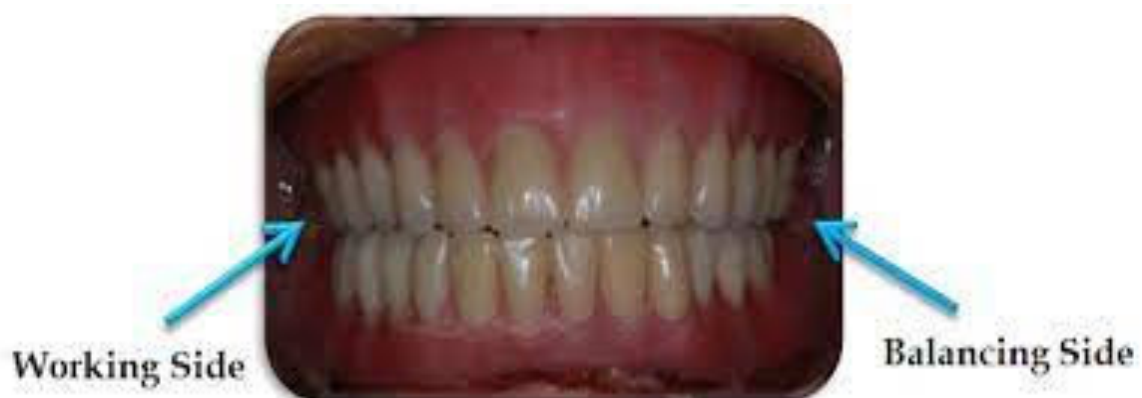PROTRUDED OCCLUSION

The occlusion of the teeth when the mandible is protruded (It includes eccentric contacts that occur when the mandible moves forward). The position of the mandible is anterior to centric relation. Ideally the six anterior teeth contact along the lingual inclines of the maxillary anterior teeth while the posteriors disocclude.



Balancing (nonfunctional) side occlusion

They are tooth contacts that occur in the segment away from which the mandible moves. For example if the mandible is moved to the left side, contact occur on right side.

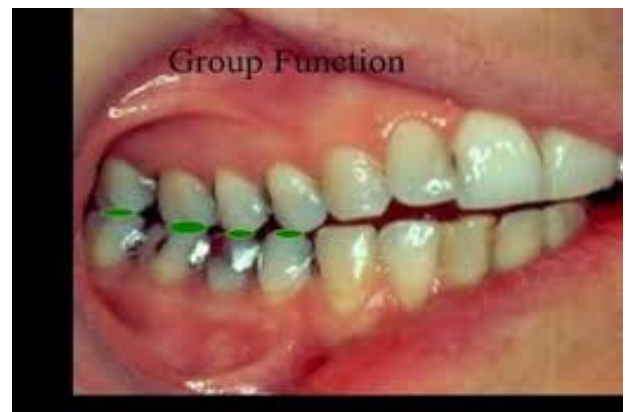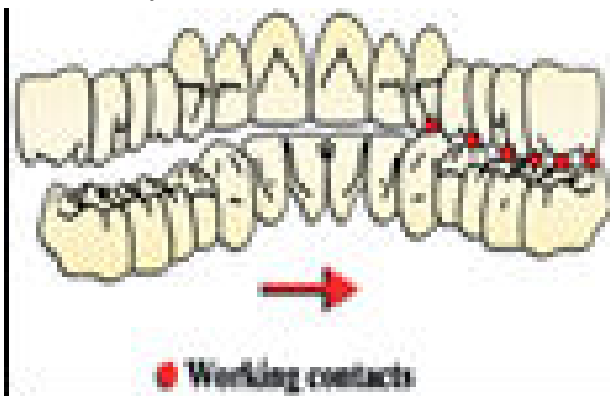


2. BASED ON THE ORGANIZATION OF OCCLUSION

According to the pattern of occlusal relation of opposing teeth during lateral movement of mandible , occlusion can be divided into

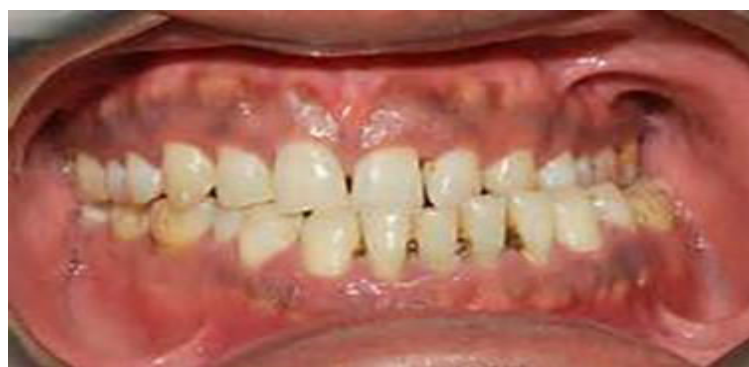A. Unilateral Balanced Occlusion:(Group Function)

Simultaneous contact of maxillary and mandibular teeth on working side as they glide over each other during lateral movement of the mandible from centric relation to the right or left side acting as a group to share & distribute forces ,however , teeth on the balancing side (non working) are free from any contact. It is widely accepted and used concept in fixed restorative dentistry.



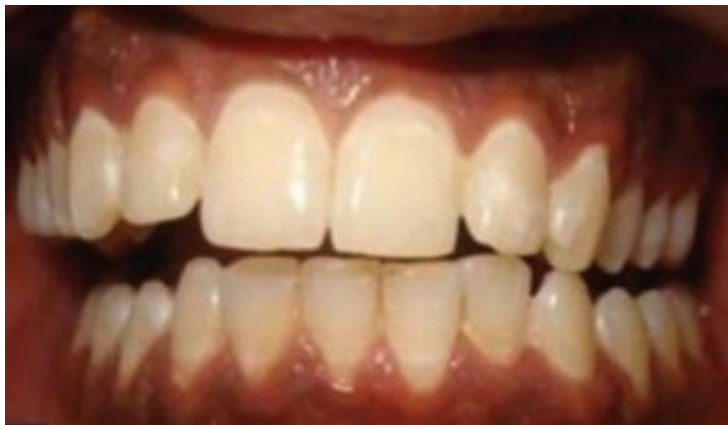B. Bilateral Balanced Occlusion

The simultaneous contact of maxillary and mandibular teeth on working and balancing side as they glide over each other on the right and left , in anterior and posterior occlusal area when the mandible moved from centric relation to eccentric occlusal relations (balanced and equal contacts are maintained throughout the entire arch during all excursions of mandible). This type of occlusion rarely found in natural dentition , however, generally consider necessary for denture stability.



C. Canine guided (protected) Occlusion

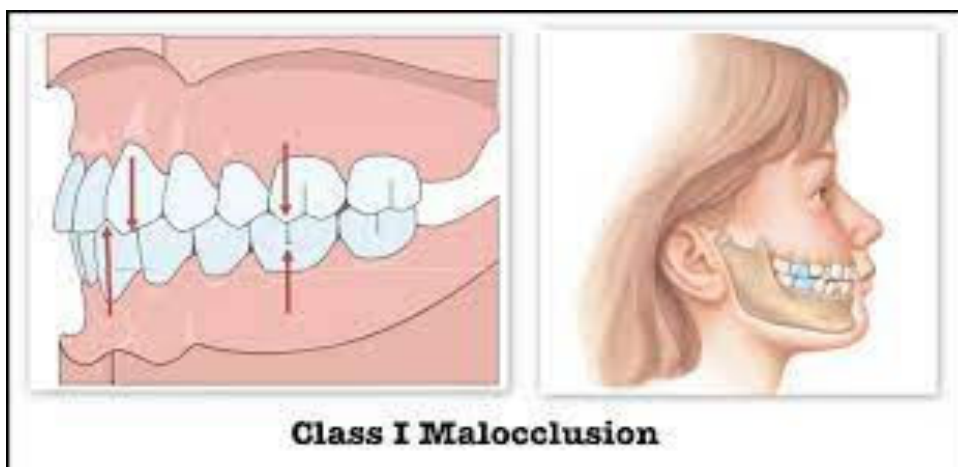
During lateral mandibular movements, the opposing upper and lower canines of the working side contact thereby causing disclusion of all posterior teeth on the working and balancing sides (The anterior teeth protecting the posterior teeth in all mandibular excursions and the posterior teeth protecting the anterior teeth at the intercuspal position). It is widely accepted, easy fabricated & greater tolerance by patients.



3. Based on relationship of first maxillary permanent molar

a) Class I : Neutro Occlusion

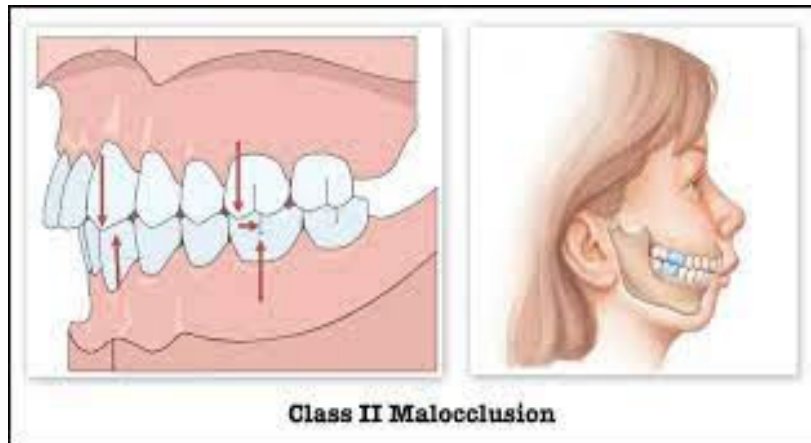Mesiobuccal cusps of the upper first permanent molar occludes with the mesiobuccal groove of the lower first permanent molar. This is called the key of occlusion.



b) Class II : Disto Occlusion

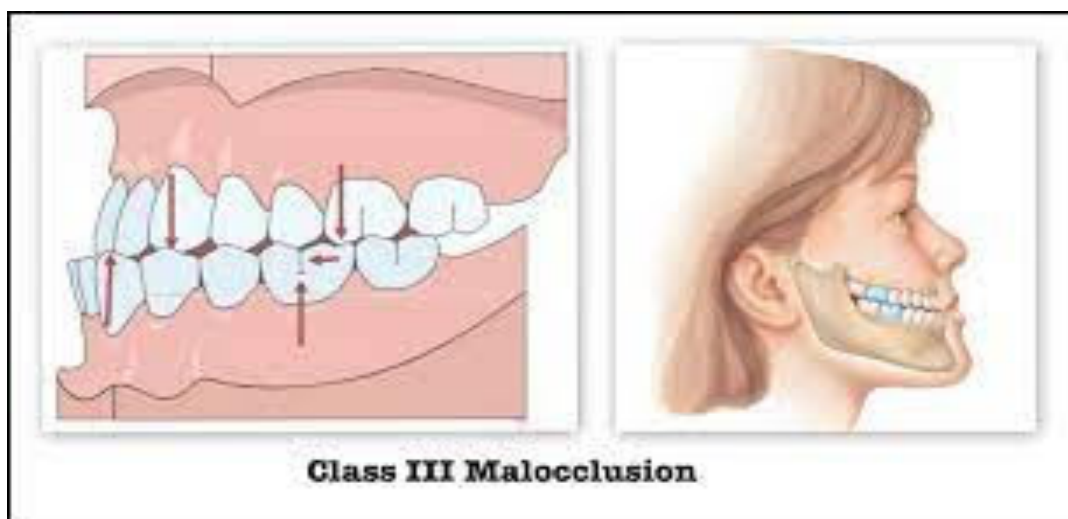
Condition in which the mandibular first Permanent molar is placed posterior in relation to the normal class I condition

- Division I
- Division II



c) Class III : Mesio Occlusion

Condition in which the mandibular first Permanent molar is placed anterior in relation to the normal class I condition.



Types of Interocclusal Records

Basically, there are three main categories of interocclusal registration:

- 1- Centric intercuspal records (centric occlusion or maximum intercuspation)
 - 2- Centric interocclusal record (centric relation)
 - 3- Eccentric interocclusal records.
- A - lateral inter occlusal records
- B - protrusive inter occlusal records

What we need to record in fixed prosthodontics? Centric relation CR or CO or IP ????

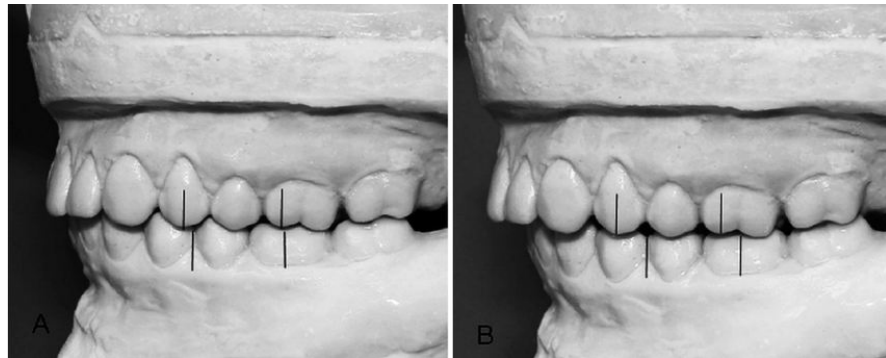
Most of time, in fixed prosthodontics:

- 1- If the patient has a stable intercuspal position (whether it coincide with centric occlusion or not) and the treatment is restricted to the restoration area while all the remaining teeth didn't not involve in the treatment plan with no signs and symptoms of trauma to the occlusion, **the goal of treatment should be directed toward maintaining pre-treatment intercuspation and occlusal vertical dimension (OVD) .**
- 2- However In cases of occlusal reconstruction or complete mouth rehabilitation treatment furthermore if the patient have un stable intercuspal position, with signs and symptoms of trauma from occlusion , **the goal of treatment should be directed toward using centric relation as treatment position.**

Recording centric occlusion or maximum intercuspal position

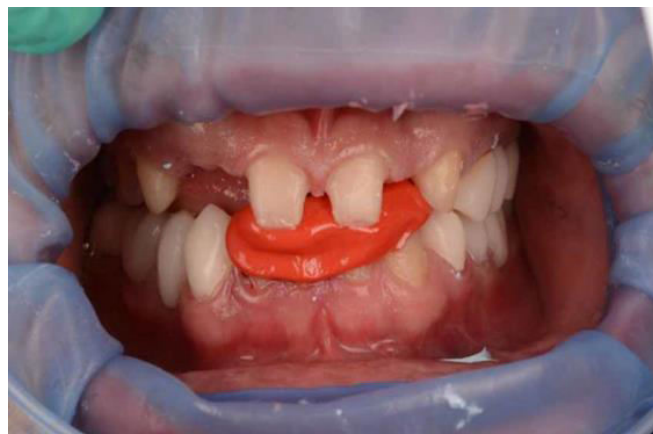If the patient has an adequate number of teeth and a stable intercuspal position, no signs and symptoms of trauma to the occlusion and the goal of treatment is to maintain pre-treatment intercuspation and occlusal vertical dimension (OVD). Most accurate method of articulation is to occlude opposing casts by hand, without intervening bite registration material.

Recording material placed between teeth in this case often prevents casts from maximal intercuspation and an interocclusal record is registered at an increased OVD.

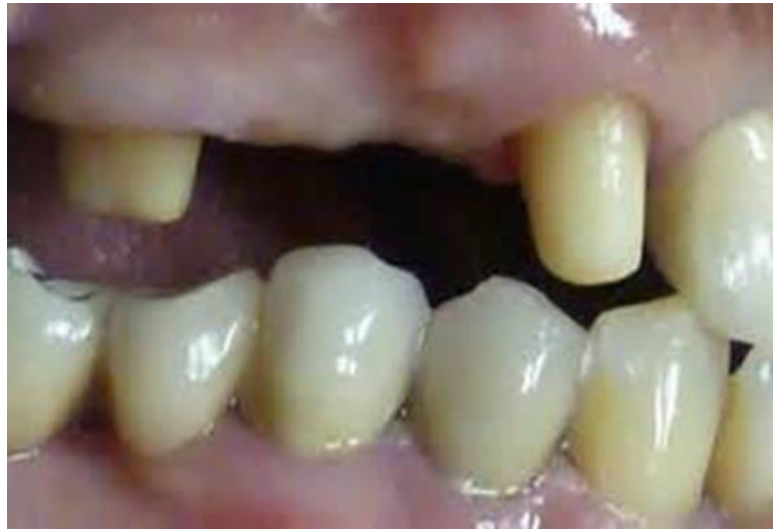

Indications for Interocclusal Records

1) When a segmental restorative is planned & remaining teeth are insufficient to produce hand articulation of the casts, an interocclusal record is needed (as there is insufficient horizontal stability of the casts for hand articulation and mounting, for opposing casts to occlude accurately, a tripod of vertical support and horizontal stability must exist between the casts. The patient's pre-treatment maximum intercuspal position (MIP) is usually maintained.



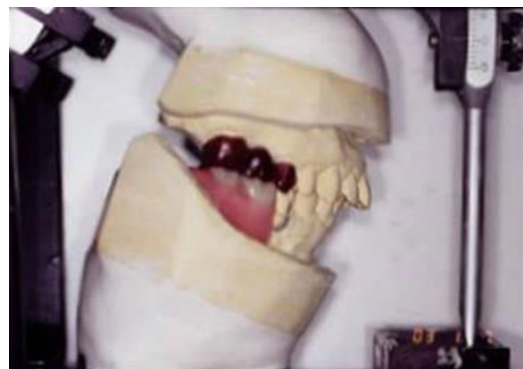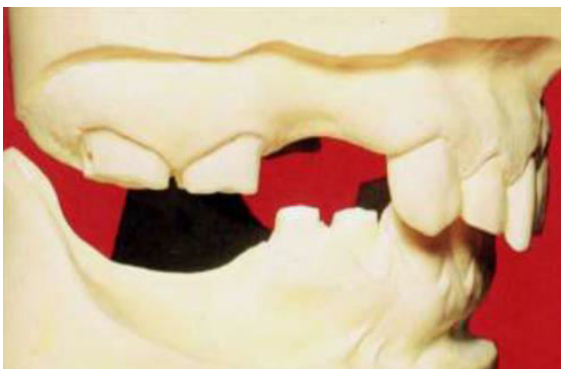2) When a unilateral fixed partial denture (FPD) involving terminal teeth is prepared, the dentist must fabricate an interocclusal record to recapture the lost leg and create a tripod of vertical support to mount casts accurately.



3) Interocclusal record is capture after construction of bite rim when fixed partial denture (FPD) planned for a patient have

A - Missing posterior teeth (Free end saddle) & need to restore the anterior teeth.

B - Insufficient teeth to obtain accurate interocclusal record.

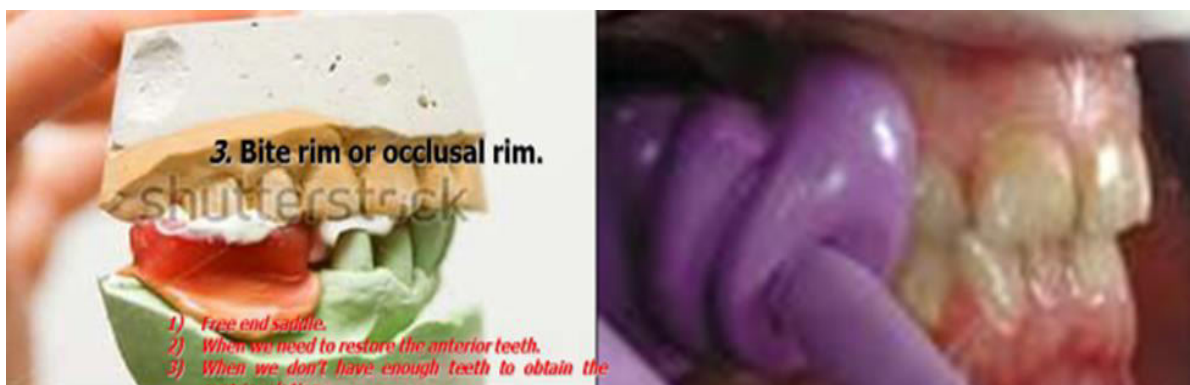
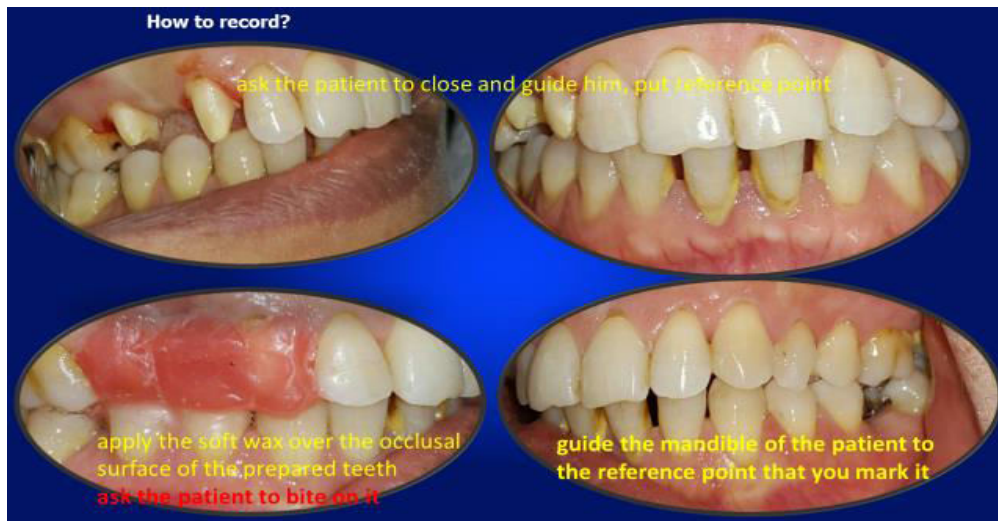
Factors that influence inter occlusal record procedure;

- 1- Amount and equalization of pressure, which depends on uniform consistency of recording material.
- 2- Comfort of patient, which depends on stability & compatibility of record bases. Artificial teeth are more compatible to mandibular movements than occlusion rims.
- 3- An inter occlusal record with multiple points of references made by styli or cusp tips is more satisfactory than with occluding surfaces of wax or non-cusp form teeth.

How TO Record The Bite

- 1- Whatever the material used to record the relation, you have to guide the mandible to the required relation (centric or eccentric).
- 2- ask the patient to close and guide him, put reference point (occlusion of the teeth opposite to the side of treatment).
- 3- then put the record material and register the relation.
- 4- The recording material should place over the area between the prepared teeth only. The most widely used material to record the occlusal relation is pink base plate wax or elastomer.
- 5- The procedure is by softening the wax at first, then apply the soft wax over the occlusal surface of the prepared teeth, then, ask the patient to bite on it.
- 6- keeping in your mind that you have to guide the mandible of the patient to the reference point that you mark it, to have the correct registration.
- 7- The patient is asked then to mold the wax at the lingual area by his tongue, while by your finger adapt the wax on the labial side.
- 8- In case of using elastomer you can ask the patient to close, then you can inject the material at the area of treatment.
- 9- After complete setting remove the record from the patient mouth, trim the excess and attach it to the cast and transfer it to the articulator



Recording centric relation

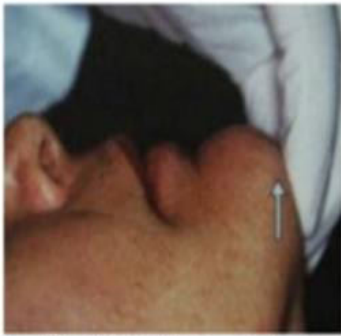1- Dawson Technique (Bimanual manipulation technique).

He used bilateral manipulation to guide the mandible to centric relation and used following recording techniques:

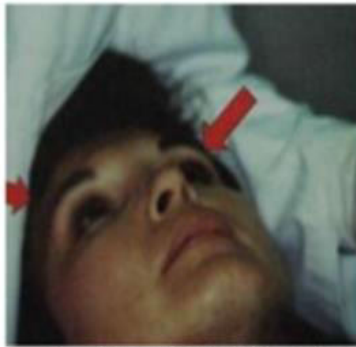How to record?

Dowson in 1914 suggest to place dental chair in reclined position and the patients head fixed by dentist standing behind the patient with both thumbs on chin and the figures resting on the inferior border of the mandible (Bimanual manipulation technique), then, by gentle downward pressure by thumbs and upward pressure by fingers, the patient mandible will bring into centric, ask the patient to bite on the bite registration material. After complete setting remove the record from the patient mouth, trim the excess and attach it to the cast and transfer it to the articulator.

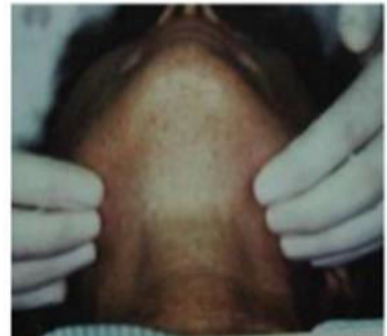PROCEDURE – BILATERAL MANIPULATION



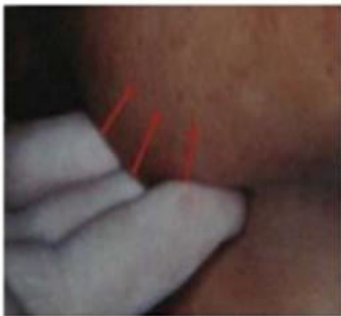
1 . Recline the patient all the way back



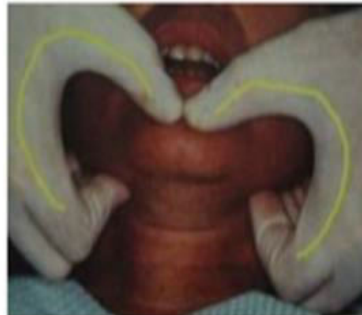2 . Head stabilization



3 . Stretch the neck by lifting the patient's chin



4 . Place the four fingers on the lower border of the mandible



5 . Bring the thumbs together to form a 'c' with each hand

71% Wi-Fi ١٢:٢٣ ص الثلاثاء ٢٨ شباط Chrome

< Back

المشاركة المشاهدة لاحقاً

How to get a Dental CR Record - Bimanual Manipulation

CENTRIC RELATION RECORD - BIMANUAL MANIPULATION

TRIAD JIG TECHNIQUE

0.02 2:57

YouTube

15 15

2- anterior- jig programmer

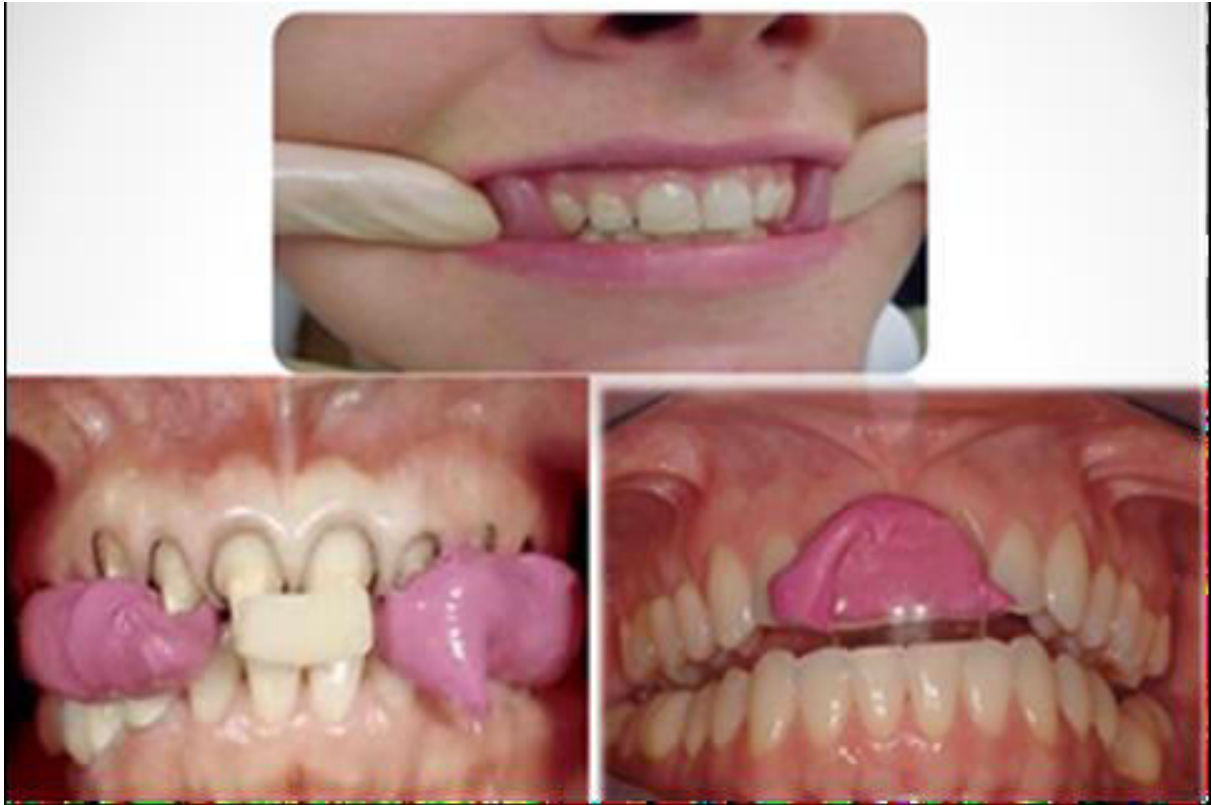Procedure for making an interocclusal record without the use of record bases.

It involve Separation of the posterior teeth immediately prior to centric relation record fabrication using anterior- jig programmer , mostly Acrylic resin anterior stop,

This results in the patient “forgetting” established protective reflexes that are reinforced each time the teeth come together, making mandibular hinge movements easier to reproduce. Acrylic resin anterior stop (anterior- jig programmer) is used to hold the desired vertical dimension of occlusion. Pink Base plate Wax or elastomer inter occlusal recording paste can be used then to record inter occlusal relation. If properly executed, use of a deprogramming device allows the patient to close into an operator-defined repeatable position unassisted.

How to record?

When the mandible is closed, the lower incisors strikes against a stop that is precisely fitted against the upper incisors. **The stop should be thin enough so that the first point of tooth contact barely misses but under no circumstances should any posterior tooth be allowed to contact when the anterior stop is in place.** A firm setting bite registration paste is injected between the posterior teeth and allowed to set.



13:10 ص الاثنين ٢٧ شباط

Back

المشاهدة لاحقاً مشاركة

Fabricating a Lucia Jig

Fabricating a Lucia Jig

YouTube

0.01 2:18

15 15

Bite registrations for CAD/CAM procedures

Bite registration can be digitally recorded in the same way as that used for digital impression, both procedures are employed in conjunction with the computer-aided design/computer-aided manufacturing (CAD/CAM). Digital Bite registration are taken either:

- 1- Indirectly using extra oral scanner (In lab).
- 2- Directly in the mouth at chairside using an intraoral digital camera (In office).

Articulators

Articulator is a mechanical device which represents the temporomandibular joints and the jaw members to which maxillary and mandibular casts may be attached to simulate jaw movements.

PURPOSE OF AN ARTICULATORS

- 1) To hold the maxillary and mandibular casts in a determined fixed relationship.
- 2) To simulate the jaw movements like opening and closing.
- 3) To produce border movements (extreme lateral and protrusive movements) and intra border movements (within the border movement) of the teeth similar to those in the mouth.

USES OF AN ARTICULATOR

- 1- To diagnose the state of occlusion in both the natural and artificial dentition.
- 2- To plan dental procedures based on the relationship between opposing natural and artificial teeth eg; evaluation of the possibility of balanced occlusion.
- 3- To aid in fabrication of restorations and prosthodontic replacement.
- 4- To correct and modify completed restoration.
- 5- To arrange artificial teeth.

TYPE OF ARTICULATORS:

1. Nonadjustable articulator

- They can open and close in a fixed horizontal axis.
- Have a fixed condylar path along which the condylar ball can be moved to simulate lateral and protrusive jaw movement.

2. Semi adjustable articulator

They have adjustable condylar path, adjustable lateral condylar paths, adjustable incisal guide tables and adjustable intercondylar distances.

Semi adjustable articulator types:

Arcon vs. Nonarcon

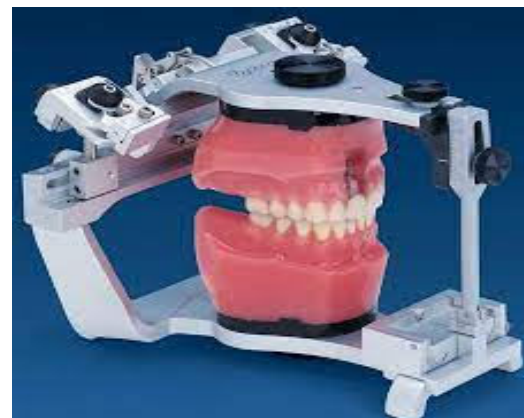1- **Arcon:** in this type the condylar element (condylar spheres) is attached to the lower member of the articulator and the condylar guidance (mechanical fossae) is attached to the upper member. This articulator resembles TMJ.

2- **Nonarcon:** in these, the articulators have the condylar element (glenoid fossae) attached to the lower member, condylar elements on the upper . This articulator is reverse of the TMJ.

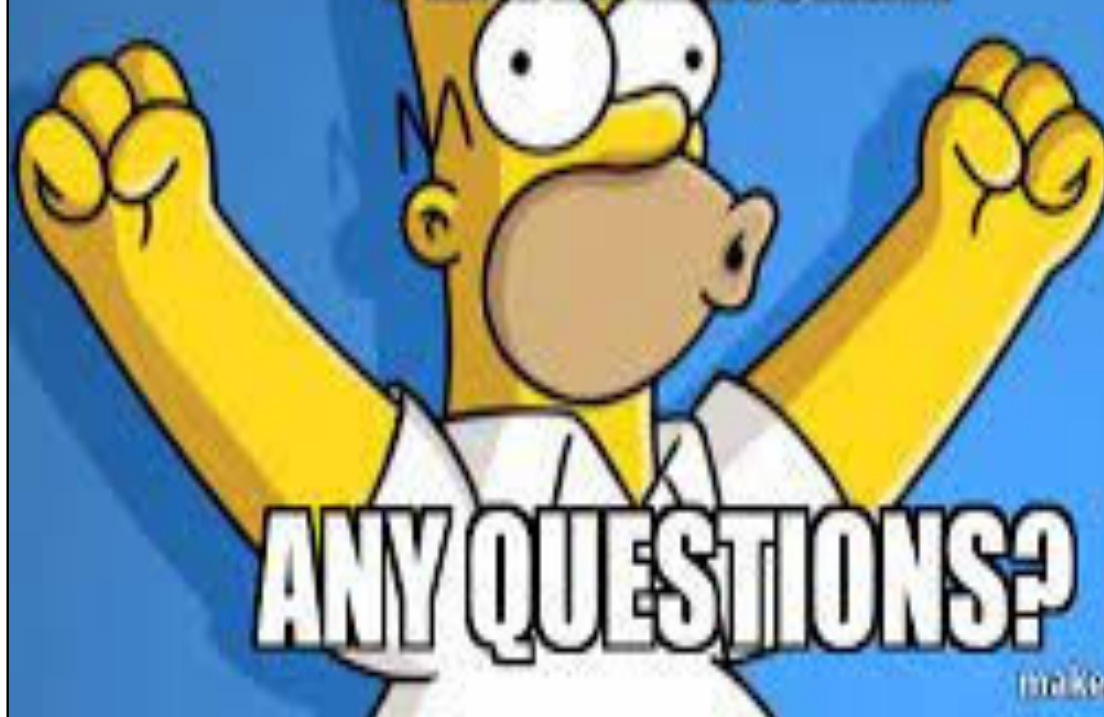

3. Fully adjustable articulator

Capable of being adjusted to follow the mandible movement in all direction. These articulators have a number of readings which can be customized for each patient. They do not have condylar guidance, instead have receptacles in which acrylic dough can be contoured to form a customised condylar and incisal guidance.



**THANK YOU FOR LISTENING TO OUR
PRESENTATION!!!!**



ANY QUESTIONS?

makeameme.org

Crown And Bridge Prosthodontics

Lecture. 12

Prof. Adel F. Ibraheem

Components of Bridge Connector

It is that part bridge or F.P.D which joins the individual components (retainers or pontics) together, retainer with pontic, retainer with retainer or pontic to pontic. This can be accomplished by non-rigid movable (flexible) connector or, most commonly, rigid (fixed) connector.

■ Materials used in pontic fabrication

- Maximum esthetics vs. maximum strength
- all metal Connector can be used to provide maximum strength when esthetic is not critical
- Metal ceramic or All ceramic, can be used to provide maximum esthetic when strength is not critical

■ Types of Connectors

■ Rigid

- All metal
- Metal-ceramic
- All ceramic

■ Non Rigid

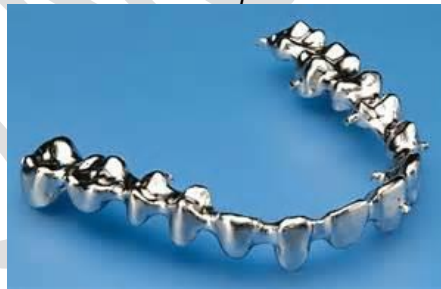- Prefabricated in plastic or metal and incorporated into the wax pattern
- Milled into the wax pattern or casting

RIGID CONNECTORS

Rigid connectors in metal can be divided into (according to fabrication technique):

a) cast connectors:

It made by casting multiunit bridge in one single piece. Cast connectors are stronger than soldered and possible to carve them so that to provide maximum appearance bridge is often cast.



b) Soldering connectors:

Here the pontic and connector have to be made separately. Then after casting we solder then together by using of intermediate metal alloy whose melting temperature is lower than that of the parent's metal.



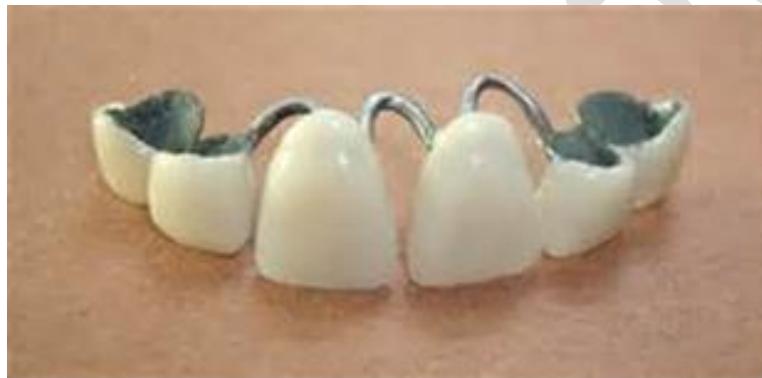c) Welded connectors:

Melting adjacent surfaces with heat or pressure



d) Loop connectors

Sometimes required when an existing diastema is to be maintained in a planned fixed prosthesis.



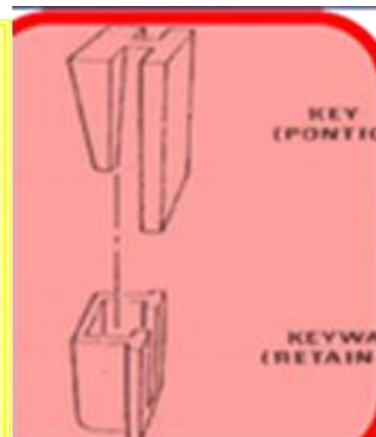
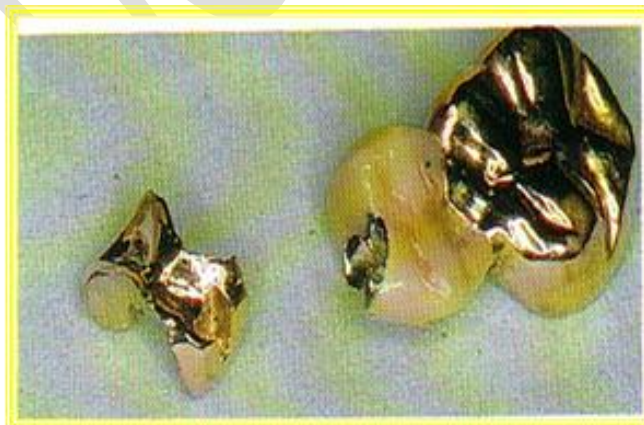NON RIGID CONNECTORS

Is indicated when it is not possible to prepare two abutment for an (FPD) with a common path of placement. So segmentally the design of large, complex (FBD) into shorter compartments (multiple pieces) to make bridge seating more easier, furthermore, it can be used in cases that need reduction of occlusal force that acting on abutment (weak).

Movable Joint (key-key way, slide channel):

This is stress breaking design of joints that allows some movement between the components of the joint, of 2 pieces:

- 1) The piece that is attached to the mesial terminal of the pontic (key slide)
- 2) Key is fitted in the second piece (key way channel) that is attached to the distal aspect of anterior abutment (minor retainer).



PRINCIPLES CONNECTORS DESIGN

1-size

Connectors must be sufficiently large to prevent distortion or fracture during function. but not too large to prevent interference with plaque, periodontal tissue disturbance over time.

2-shape

The shape of the tissue surface of the connector should be curved faciolingually and highly polished and smooth to facilitate cleaning and patient should be satisfied with the appearance.

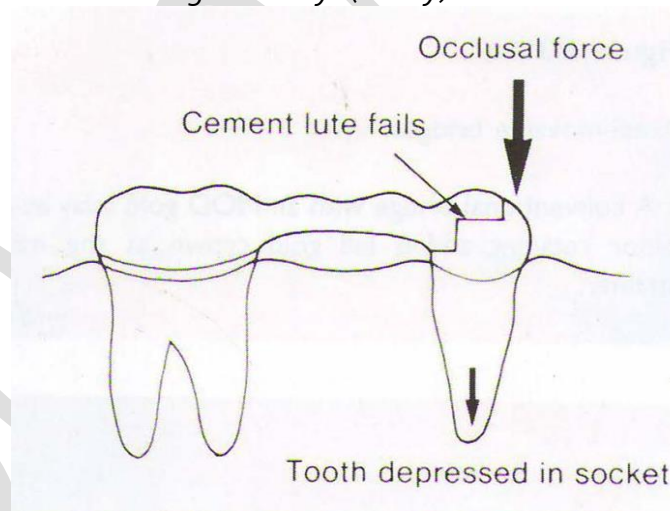
3-position

The location of the contact area should be established correctly to influence the success and stability of the prosthesis. In the anterior teeth, the connector should place lingually. In the posterior teeth, located in the occlusal third of the crown and more lingually



Occlusal coverage:

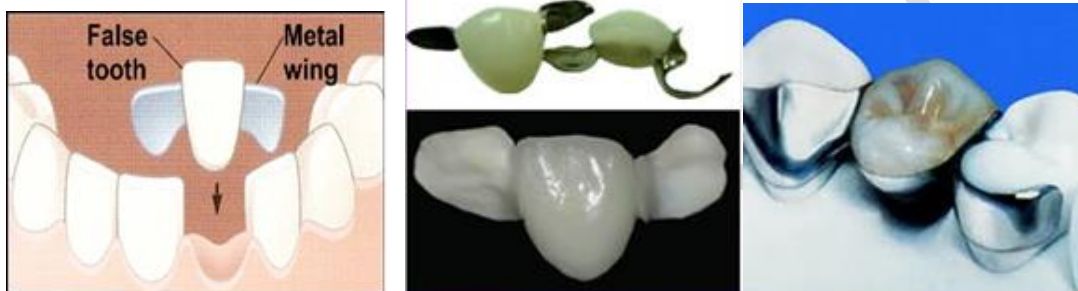Major Retainer that is rigidly connect to the pontic (fixed-fixed bridge design) need full occlusal coverage while Minor Retainer that have movable connection with pontic doesn't need that. Full Occlusal Coverage is always (nearly) indicated because :



Adhesive bridge (Resin bonded bridge, acid etched bridge)

Fixed dental prosthesis that is luted to the unprepared or minimum preparation surface of abutment teeth permanently by acid etching of enamel with some type of resin bonding agent.

1. It is alternative for the conventional bridge.
2. It is involve attaching the pontic via a metal plate to the unprepared lingual surface of the abutment teeth.
3. The attachment to the abutment is made by composite resin material after acid etch of the enamel.
4. It is the most conservative methods.
5. It is used when the abutment teeth have sufficient intact enamel, & usually used in younger patient.



Indications:

- 1) *Adolescents with single missing teeth (traumatic or congenital).*
- 2) *Caries- free abutment teeth and good oral hygiene.*
- 3) *Maxillary incisor replacements (most favorable prognosis) and Mandibular incisor replacements.*
- 4) *Periodontal splints.*
- 5) *Post orthodontic fixed retention*
- 6) *Short span edentulous areas(Single posterior tooth replacements).*

Contra Indications:

- 1) Small sized abutments – Peg Laterals
- 2) Extensive caries.
- 3) Heavily restored abutments.
- 4) Deep vertical overbite.
- 5) Mal-aligned abutments
- 6) Parafunctional habits
- 7) Long span edentulous area
- 8) Allergy to base metal alloys

Advantages:

- 1) *Conservative.*
- 2) *Saving clinical chairs time.*
- 3) *Not expensive.*
- 4) *Lab procedure is easy & short.*
- 5) *It can be re-cemented if failure occurs.*
- 6) *Good appearance.*

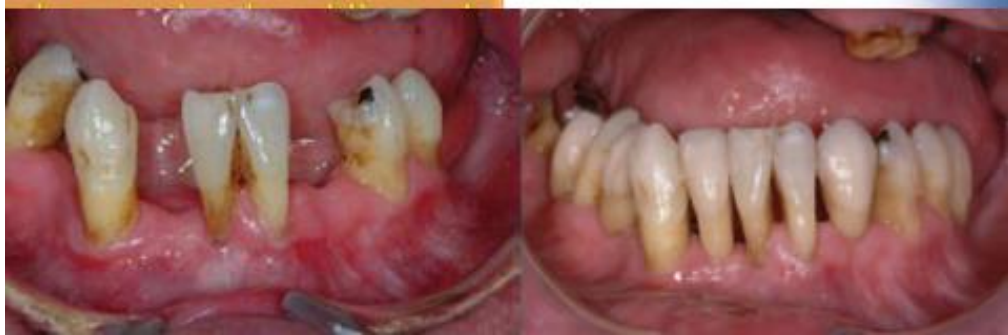Disadvantages:

- 1) *Not strong as conventional bridge.*
- 2) *Limited use because abutment teeth should have sufficient enamel for etching.*
- 3) *Tendency to de-bond.*
- 4) *Increase thickness of tooth surface by the metal plate.*

Types:

1. Direct:

This type is made by using the crown of patient own tooth as a pontic, for example rapid replacement of a tooth that lost by traumatic injury. In order to increase the strength of the bridge (attachment) we add metal mesh or wire (temporary replacement).



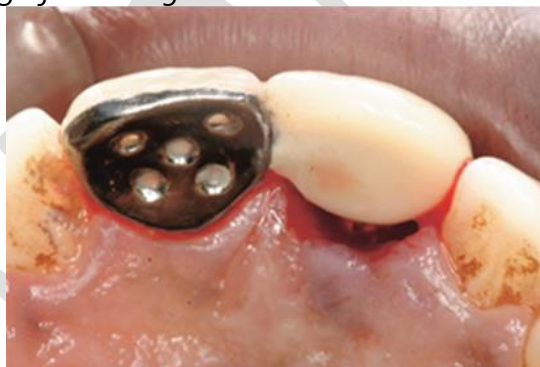2. Indirect adhesive bridge:

According to the mean or way of retention of the metal frame work to the abutment teeth we have different types:

- a) Macro mechanical retention (Rochette).*
- b) Medium mechanical retention (Virginia).*
- c) Micro mechanical retentive (Maryland).*
- d) Chemically retention (Panavia).*

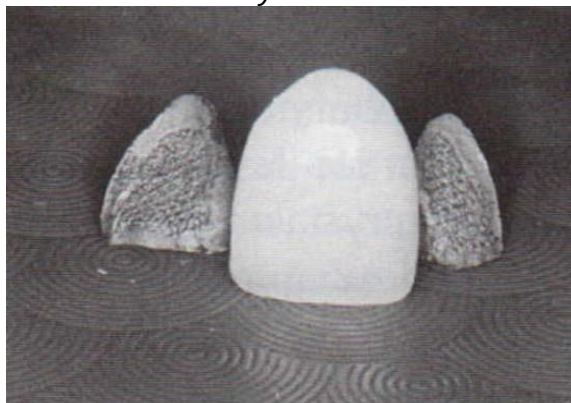
a. Macro mechanical retention (Rochette) :

In this types there is multiple funnel shaped undercut perforations in the cast metal frame of the retainer is used for retention & through which composite flow during cementation and make mechanical interlocking after setting



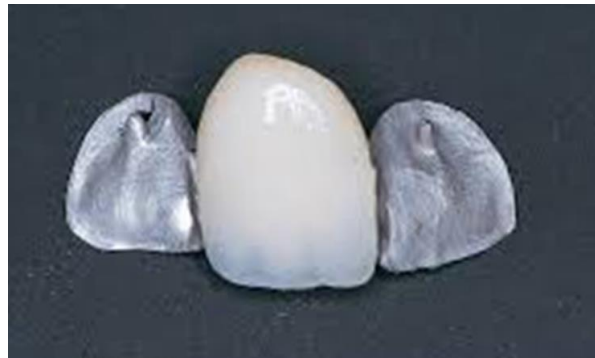b. Medium mechanical retention (Virginia):

Retentive feature cast as a part of the metal frame work (non undercut lumps, mesh, on the fit surface of the retainer). The size of the retentive feature is intermediate between macro mechanical & micro mechanical retentive system



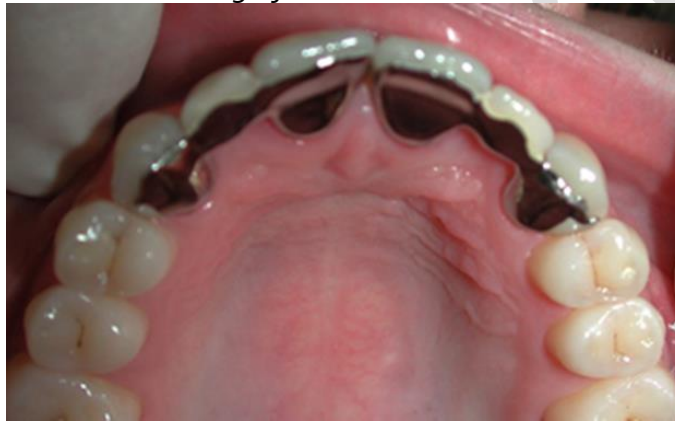c. Micro mechanical retentive (Maryland):

In state of perforations, the tooth side of the frame work is electrolytically etched, with hydrofluoric acid , which produce a microscopic undercuts, the bridge attached with a resin luting agent that lock into the microscopic undercut of both the etched retainer & etched enamel.



d. Chemically retention (Panavia):

The resin adheres chemically to recently sand-blasted metal surface and is retained on the tooth by conventional acid etching of the enamel.



DIAGNOSIS AND TREATMENT PLANNING IN FIXED PROSTHODONTICS

Successful management of cases begin with a thorough assessment of the patient's physical and psychological condition and determining a treatment that will satisfy the realistic expectations of the patient

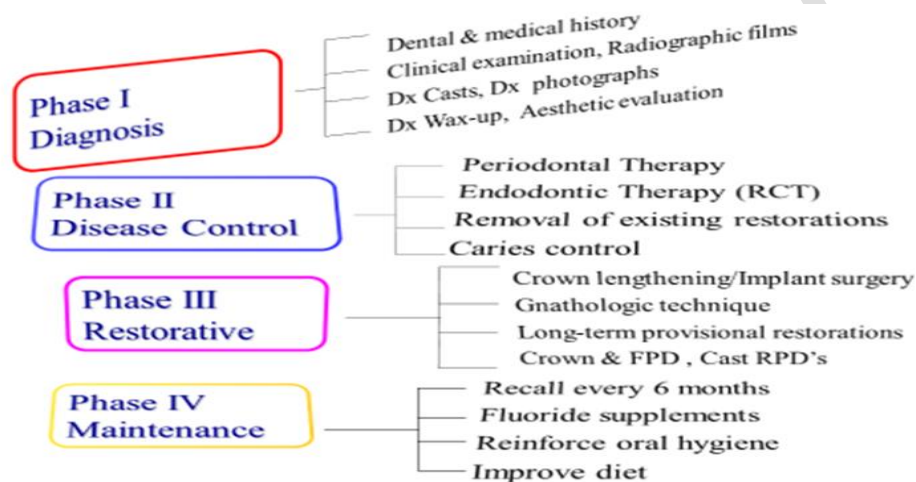
■ Diagnosis

- ⊙ The determination of the nature of a disease.

■ Treatment plan

- ⊙ The sequence of procedures planned for the treatment of a patient after diagnosis

Treatment Plan by Phases



FIVE ELEMENTS OF DIAGNOSIS

- HISTORY
 - Clinical examination
 - TMJ & EXTRAORAL EVALUATION
 - INTRA ORAL EXAMINATION
- DIAGNOSTIC CASTS
- RADIOGRAPHIC EXAMINATION
- Dx photographs, Dx Wax-up, Aesthetic evaluation

DATA COLLECTION (HISTORY)

All pertinent information concerning the reasons seeking treatment, along with any personal information, including relevant previous medical and dental experiences. The chief complaint should be recorded preferably in patient's own words.

- 1) Personal information: Name, Sex, AGE, Address, Telephone No, Family history, Socio-economic status, Physician tel.ph.no.
- 2) Dental History
- 3) Medical History

CHIEF COMPLAINT

The accuracy and significance of the patient's primary reason or reasons for seeking treatment should be analyzed first

FOUR CATEGORIES of chief complaint

- **COMFORT** (pain, sensitivity, swelling)
- **FUNCTION** (Difficulty in mastication or speech)
- **SOCIAL** (Bad taste or odor)
- **APPEAREANCE** (Fractured or unattractive teeth or restorations, discoloration)

CLINICAL EXAMINATION

consist of the clinician's use of sight, touch, and hearing to detect conditions outside the normal range. Clinical examination involve the following:

General appearance:

- *Gait and weight are assessed.*
- *Skin color: Anemia or jaundice.*
- *Vital signs: Respiration, pulse, temperature and blood pressure are measured and recorded.*

EXTRAORAL EXAMINATION

- *FACIAL ASYMMETRY*
- *CERVICAL LYMPHNODES*
- *TMJ*
- *MUSCLS OF MASTICATION (palpated)*

DIAGNOSTIC AIDS

- *RADIOGRAPHS*
- *VITALITY TEST*
- *DIAGNOSTIC CASTS*
- *PERIODONTAL PROBE*

Pulpal health must be measured before restorative treatment to

- *PERCUSSION and*
- *THERMAL STIMULATION*
- *VITALITY TESTS*

RADIOGRAPHIC EXAMINATION;

The radiograph should be examined carefully for caries , presence of P.A lesion , the quality of the previous endodontic treatment , alveolar bone level, crown-root ratio , root configuration ,direction of root, Number can be examined ,also the presence of retained root in edentulous areas should be recorded

Summary of supplement information, to clinical information, provides by radiographic examination, during this diagnosis phase, are

- *Extent of bone support*
- *Root morphology*
- *Peri apical pathology*

PANOROMIC RADIOGRAPHS

- *Presence or absence of teeth*
- *Assessing third molars impactions,*
- *Evaluating the bone before implant placement.*
- *Screening edentulous arches for buried root tips.*

Diagnostic Casts Examination;

They should be mounted on a semi adjustable articulator

Advantages;

- 1) *Allow an un obstructed view of the edentulous space*
- 2) *Allow accurate assessment of the span length and the curvature of the ridge or arch in the edentulous region*
- 3) *The shape and length of the abutment teeth can be measured to determine which preparation design will provide adequate retention and resistance.*
- 4) *Evaluate path of insertion (axial inclination of abutment) to determine the need for any modification.*

- 5) No., size and location of wear can be evaluated.
- 6) Over erupted teeth can be easily spotted and the amount of correction needed can be determine.
- 7) Evaluate occlusion and Interocclusal space necessary to re-establish a proper occlusal plane.
- 8) Evaluate the need for any occlusal correction.
- 9) Used for diagnostic wax-up.
- 10) Construction of special try and provisional restoration.

Diagnostic photographs

There is much diagnostic information to be gained by including photography to comprehensive treatment planning. It allows the practitioner to show the patient a photograph (s) concerning his complain or problem immediately , thereby helping the patient to co-diagnose, understand their needs and complications much better when they can see a picture of their own pathology work with the patient chairside while showing his problem and discus the treatment.

What is an Ideal Treatment plan?

Treatment plan that achieves the best possible long-term outcomes for the patient, while addressing all patient concerns and active problems, with the minimum necessary intervention.

MOUTH PREPARATION

Mouth preparation refers to the dental procedure that need to be accomplished before fixed prosthodontics can be properly undertaken. As a general plan, the following sequence of treatment procedures in advance of fixed prosthodontic should be adhered to;

- 1) Relief of symptoms (chief complaint)
- 2) Removal of etiological factors (eg; excavation of caries removal of deposits)
- 3) Repair of damage.
- 4) Maintenance of dental health.

The following list describes the sequence in the treatment of a patient with extensive dental disease including missing teeth, retained roots, caries and defective restorations.

- Preliminary assessment
- Emergency treatment of presenting symptoms
- Oral surgery
- caries control and replacement of existing restorations
- Definitive periodontal treatment
- Orthodontic treatment
- Definitive occlusal treatment
- Fixed prosthodontics
- Removable prosthodontics
- Follow up care .

SELECTION OF THE TYPE OF THE PROSTHESIS

FACTORS CONSIDERED

- BIOMECHANICAL
- PERIODONTAL
- ESTHETIC
- FINANCIAL and PATIENTS WISHES.

*Selection should not be less than optimum just because the patient cannot.
Sound alternative to the preferred treatment plan and not apply pressure.*

SELECTION OF THE TYPE OF THE PROSTHESIS

➤ **CONVENTIONAL TOOTH SUPPORTED FIXED PARTIAL DENTURE**

- 1) *Abutment teeth are periodontally sound.*
- 2) *Edentulous span is short and straight.*
- 3) *Expected to provide a longlife of function for the patient.*
- 4) *No gross soft tissue defect in the edentulous ridge.*
- 5) *Reserved for patients who are both highly motivated and able to afford*

➤ **RESIN BONDED TOOTH SUPPORTED FIXED PARTIAL DENTURE**

- 1) *Defect free abutments where single missing tooth.*
- 2) *A single molar (muscles are not well developed).*
- 3) *Mesial and distal abutment are present.*
- 4) *Moderate resorption and no gross soft tissue defects on edentulous ridges.*
- 5) *Younger patients whose immature teeth with large pulps are poor risks for endodontic free abutment preparation.*
- 6) *Tilted tooth can be accommodated only if there enough tooth structure to allow a change in the normal alignment of axial reduction.*
- 7) *Periodontal splints*

➤ **Removable partial denture abutment**

- 1) *Edentulous spaces greater than two posterior teeth.*
- 2) *Anterior space greater than four Incisors.*
- 3) *Edentulous space with no distal abutment.*
- 4) *Multiple edentulous spaces.*
- 5) *Tipped teeth adjoining edentulous spaces and prospective abutments with divergent alignment*

➤ **IMPLANT SUPPORTED FIXED PARTIAL DENTURE**

- 1) *Insufficient number of abutments.*
- 2) *Partial attitude and or a combination of intra oral factors make a removable partial denture or FPD a poor choice.*
- 3) *No distal abutment.*
- 4) *Alveolar bone with satisfactory density and thickness in a broad, flat ridges.*
- 5) *Configuration that permit implant placement.*
- 6) *Single tooth where defect free adjacent teeth.*
- 7) *A span length of two or six teeth can be replaced by multiple implants.*
- 8) *Pier in an edentulous span (three or more teeth long).*

It is not uncommon to combine two types in the same arch.

In cases where the choice between a fixed partial denture and a removable partial denture is not clear cut, two or more treatment options should be presented to the patients along with their advantages and disadvantages

The prosthodontist is the best person to evaluate the physical and biological factors present , while the patients feelings should carry considerable weight on matters of esthetics & finances

NO PROSTHETIC TREATMENT ?????????!!!!!!

- 1) *Long standing edentulous space into which there has been little or no drifting or elongation of the adjacent teeth.*
- 2) *If the patients perceives no functional, occlusal or esthetic impairment.*

ENDODONTIC DIAGNOSIS

The pulp, root canal, and periapical/periradicular tissues are all inter-related and the conditions within the pulp or root canal have a direct effect on the periapical and periradicular tissues.

Diagnosis is the art and science of detecting and distinguishing deviations from health .

The purpose of a diagnosis is to determine what problem the patient is having and ultimately, this will directly relate to what treatment will be necessary

Medical History

The patient should be questioned at each treatment visit to determine whether there have been any changes in the patient's medical history or medications .

Baseline **blood pressure and pulse** should be recorded for the patient at each treatment visit. Elevation in blood pressure or a rapid pulse rate may indicate an anxious patient who may require a stress reduction protocol, or it may indicate that the patient has hypertension or other cardiovascular health problems.

The **temperature** of patients presenting with subjective fever or any signs or symptoms of a dental infection should be taken .

Dental History

The history should include any past and present symptoms, as well as any procedures or trauma that might have evoked the chief complaint .

EXAMINATION AND TESTING

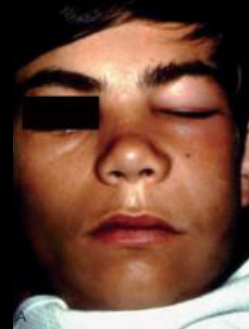Extraoral Examination

Signs of physical limitations may be present, as well as signs of facial asymmetry that result from facial swelling .

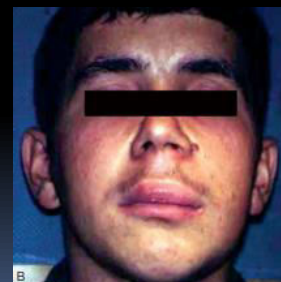Visual and palpation examinations of the face and neck are warranted to determine whether swelling is present .

Palpation of the cervical and submandibular lymph nodes : If the nodes are found to be firm and tender along with facial swelling and an elevated temperature, there is a high probability that an infection is present .

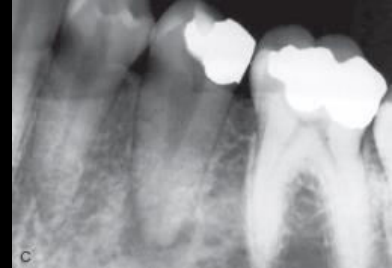
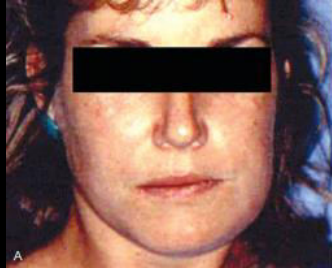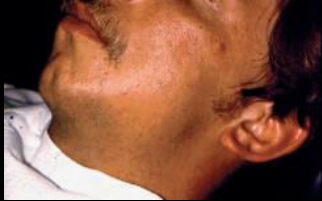Swellings of non-odontogenic origin must always be considered in the differential diagnosis, especially if an obvious dental pathosis is not found .



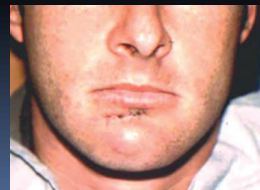Most extraoral swellings associated with the maxillary centrals express themselves as a swelling of the upper lip and base of the nose



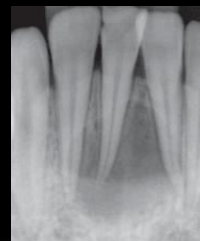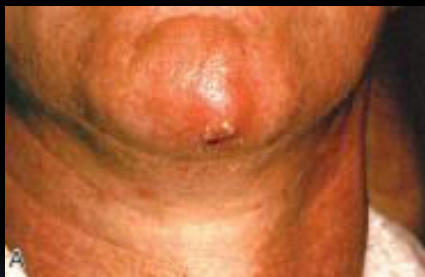If the buccal space becomes involved, the swelling will be extraoral in the area of the posterior cheek .



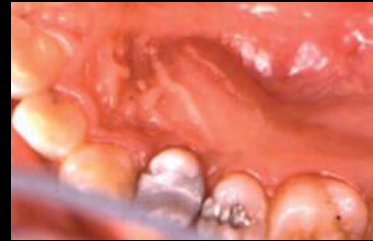Extraoral swelling associated with mandibular incisors will generally exhibit itself in the submental or submandibular space.



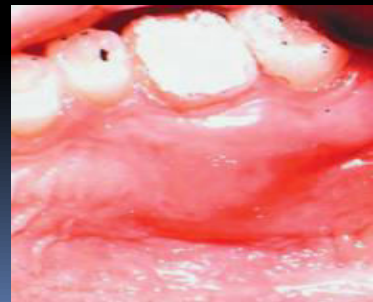Sinus tracts of odontogenic origin may also open through the skin of the face. These openings in the skin will generally close once the offending tooth is treated and healing occurs .



Swelling in the anterior part of the palate is most frequently associated with an infection present at the apex of the maxillary lateral incisor or the palatal root of the maxillary first premolar .

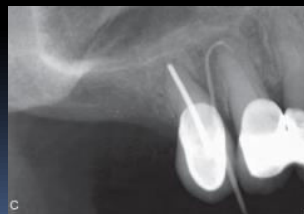
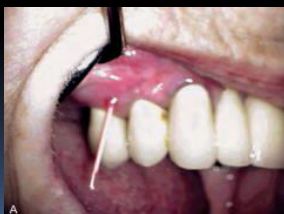
A swelling in the posterior palate is most likely associated with the palatal root of one of the maxillary molars .



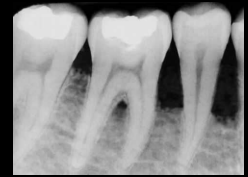Intraoral Sinus Tracts

A chronic endodontic infection may drain through an intraoral communication to the gingival surface and is known as a sinus tract . This pathway extends directly from the source of the infection to a surface opening, or stoma, on the attached gingival surface . Tracing the sinus tract will provide diagnosing the location of the problematic tooth. To trace the sinus tract, a size #25 or #30 gutta-percha cone is threaded into the opening of the sinus tract .

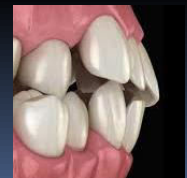
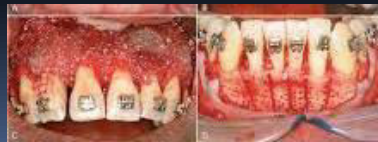
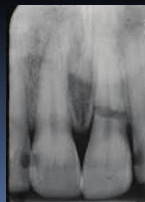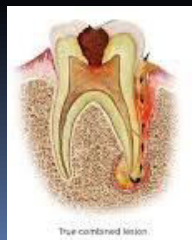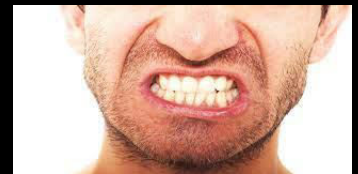Mobility Test

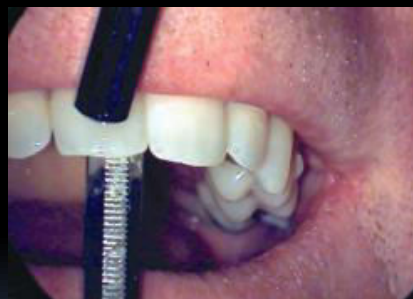An increase in tooth mobility is merely an indication of a compromised periodontal attachment apparatus .



This compromise could be the result of acute or chronic physical trauma, occlusal trauma, parafunctional habits, periodontal disease, root fractures, rapid orthodontic movement, or the extension of pulpal disease, specifically an infection, into the periodontal ligament space .



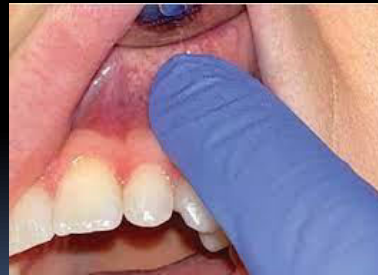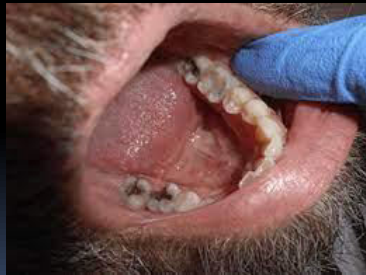Tooth mobility test can be performed by the back ends of two mirror handles , one on the buccal aspect and one on the lingual aspect of the tooth.



Any mobility that exceeds + 1 mm should be considered abnormal .

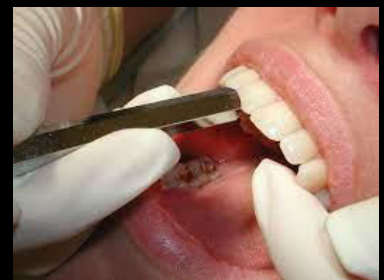Palpation

A positive response to palpation may indicate an active periradicular inflammatory process. This test does not indicate, however, whether the inflammatory process is of endodontic or periodontal origin



Percussion

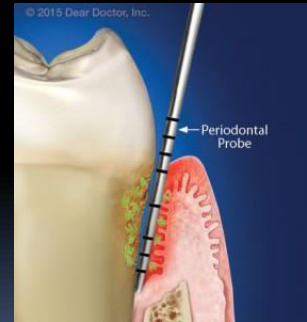
Pain to percussion does not indicate that the tooth is vital or nonvital but is rather an indication of inflammation in the periodontal ligament (i.e., symptomatic apical periodontitis). This inflammation may be secondary to physical trauma, occlusal prematurities, periodontal disease, or the extension of pulpal disease into the periodontal ligament space .



The contralateral tooth should first be tested as a control, also the adjacent teeth that are certain to respond normally .

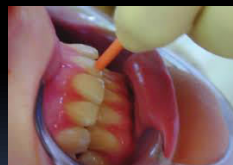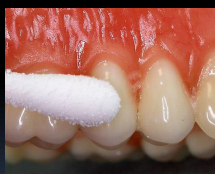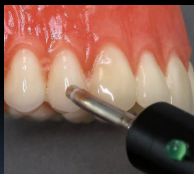Periodontal Examination

The measurement of periodontal pocket depth is the distance between the height of the free gingival margin and the height of the attachment apparatus below, using a periodontal probe.



Pulp Tests

The tests involve thermal or electrical stimulation of a tooth in order to obtain a subjective response from the patient (i.e., to determine whether the pulpal nerves are functional), or the tests may involve a more objective approach using devices that detect the integrity of the pulpal vasculature.



Thermal

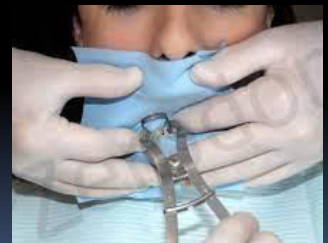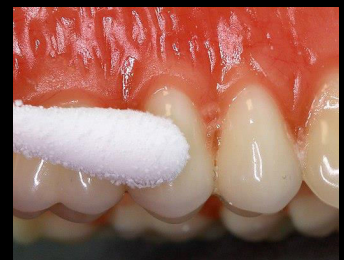Regardless to the materials and methods, the response to the cold and hot is the basic

The baseline or normal response to either cold or hot is a patient's report that a sensation is felt but disappears immediately upon removal of the thermal stimulus.

Abnormal responses include a lack of response to the stimulus, a lingering or intensification of a painful sensation after the stimulus is removed, or an immediate, painful sensation as soon as the stimulus is placed on the tooth .



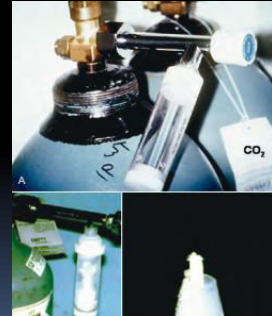Cold testing is the primary pulp testing method used by many clinicians today. It is especially useful for patients presenting with porcelain jacket crowns or porcelain-fused-to metal crowns where no natural tooth surface is accessible. If a clinician chooses to perform this test with sticks of ice, then the use of a rubber dam is recommended, because melting ice will run onto adjacent teeth and gingiva yielding potentially false-positive responses.



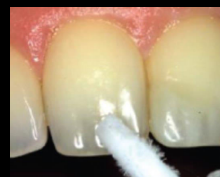Frozen carbon dioxide (CO₂) also known as dry ice or carbon dioxide snow , or CO₂ stick , has been found to be reliable in eliciting a positive response if vital pulp tissue is present in the tooth

CO₂ stick is applied to the facial surface of either the natural tooth structure or crown.

The teeth should be isolated and the oral soft tissues should be protected with gauze or cotton roll so the frozen CO₂ will not come into contact with these structures.



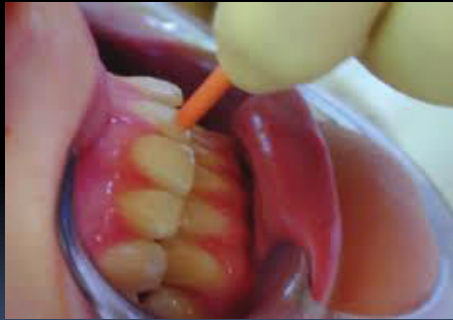
The most popular method of performing cold testing is with **a refrigerant spray**. It is readily available, easy to use, and provides test results that are reproducible, reliable, and equivalent to that of frozen CO₂



Commonly the **use of the dental triple syringe or cold water** are questionable unless good isolation with rubber dam.

Another thermal testing method involves the use of **heat**.

A method for heat testing is to apply **heated gutta -percha or compound stick** to the surface of the tooth.



Electric Pulp Tester

Electric pulp testers of different designs and manufacturers have been used for this purpose.

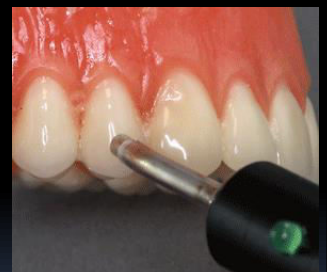Potential Common Interpretation Errors of Responses Obtained from Electric Pulp Testing

False-Positive Responses

- Partial pulp necrosis
- Patient's high anxiety
- Ineffective tooth isolation
- Contact with metal restorations

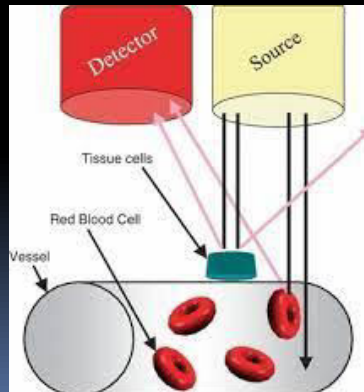
False-Negative Responses

- Calcific obliterations in the root canals
- Recently traumatized teeth
- Immature apex
- Drugs that increase patient's threshold for pain
- Poor contact of pulp tester to tooth



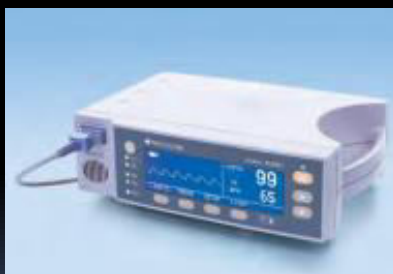Laser Doppler Flowmetry

The Doppler principle states that the light beam's frequency will shift when hitting moving red blood cells but will remain unshifted as it passes through static tissue. The average Doppler frequency shift will measure the velocity at which the red blood cells are moving .



Pulse Oximetry

The pulse oximeter is another noninvasive device widely used in medicine, it is designed to measure the oxygen concentration in the blood and the pulse rate.

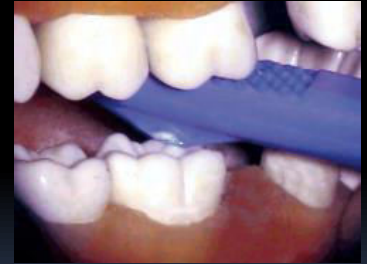

Special Tests

Bite Test

Percussion and bite tests are indicated when a patient presents with pain while biting. The tooth may be sensitive to biting when the pulpal pathosis has extended into the periodontal ligament space, or the sensitivity may be present secondary to a crack in the tooth.

A variety of devices have been used for bite tests, including cotton tip applicators, tooth picks, and rubber polishing wheels. As with all pulp tests, adjacent and contralateral teeth should be examined.

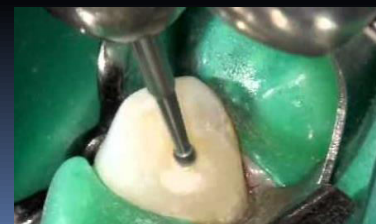

Test Cavity

The test cavity method for assessing pulp vitality is not routinely used since, by definition, it is an invasive irreversible test. This method is used only when all other test methods are deemed impossible or the results of the other tests are inconclusive.

This is accomplished with a high-speed #1 or #2 round bur with proper air and water coolant. The patient is not anesthetized while this procedure is performed, and the patient is asked to respond if any painful sensation is felt during the drilling procedure. If the patient feels pain once the bur contacts sound dentin, the procedure is terminated and the class I cavity preparation is restored.

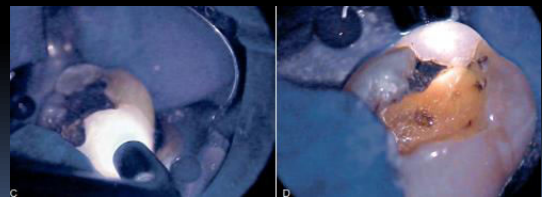
If the patient fails to feel any sensation when the bur reaches the dentin, this is a good indication that the pulp is necrotic and root canal therapy is indicated.



Staining and Transillumination

To determine the presence of a crack in the surface of a tooth, the application of a stain to the area is often of great assistance. It may be necessary to remove the restoration in the tooth to better visualize a crack or fracture. Methylene blue dye, when painted on the tooth surface with a cotton tip applicator, will penetrate into cracked areas. The excess dye may be removed with a moist application of 70% isopropyl alcohol. The dye will indicate the possible location of the crack.

Directing a high-intensity light directly on the exterior surface of the tooth at the cementum-enamel junction (CEJ) may reveal the extent of the fracture. Teeth with fractures block transilluminated light. The part of the tooth that is proximal to the light source will absorb this light and glow, whereas the area beyond this fracture will not have light transmitted to it and will show as gray by comparison.

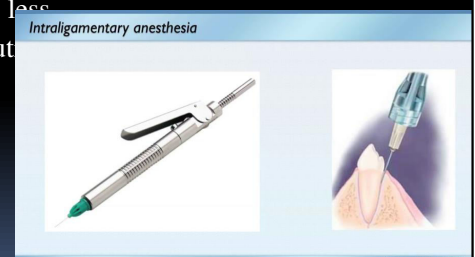
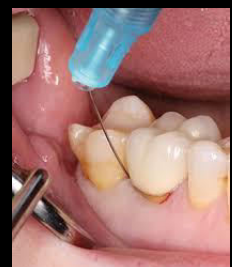
Selective Anesthesia

When symptoms are not localized or referred, the diagnosis may be challenging. Sometimes the patient may not even be able to specify whether the symptoms are emanating from the maxillary or mandibular arch. In these instances, when pulp testing is inconclusive, selective anesthesia may be helpful.

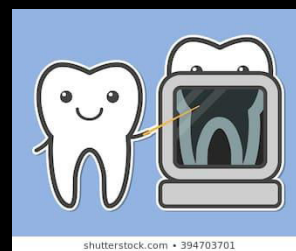Selective anaesthesia can be useful in cases of referred pain to distinguish whether the source of pain is mandibular or maxillary in origin. It is less useful for distinguishing pain from adjacent teeth, as the anaesthetic solution may diffuse laterally.

This should be accomplished by using a periodontal ligament (intraligamentary) injection. It should be understood that periodontal ligament injections may anesthetize an adjacent tooth and thus are more useful for identifying the arch rather than the specific tooth.



Radiographic Examination

The radiographic interpretation of a potential endodontic pathosis is an integral part of endodontic diagnosis and prognosis assessment.

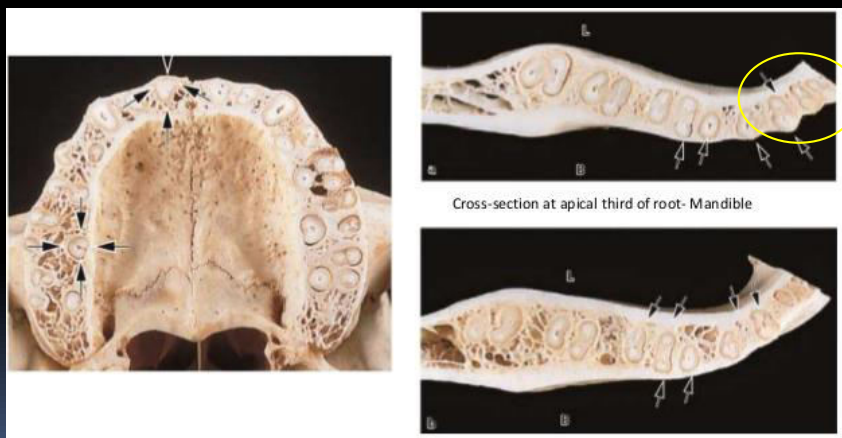


When not coupled with a proper history and clinical examination and testing, the radiograph alone can lead to a misinterpretation of normality and pathosis .

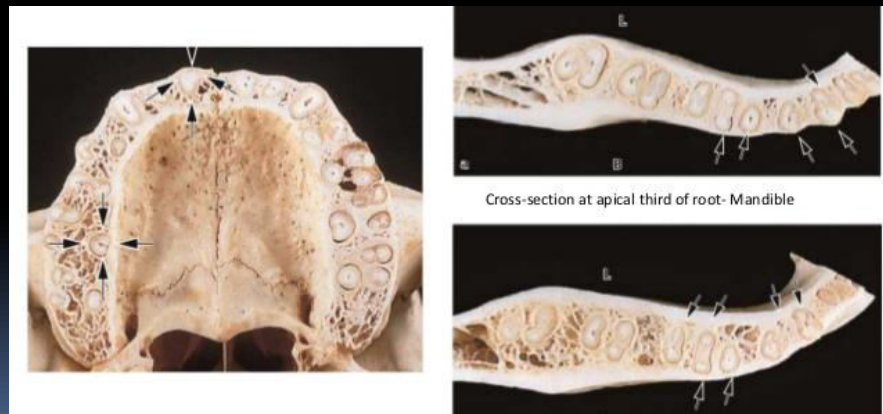
Radiographic changes from bone loss will not be detected if the loss is only in cancellous bone. However, the radiographic evidence of pathosis will be observed once this bone loss extends to the junction of the cortical and cancellous bone.



The apices of most anterior and premolar teeth are located **close** to the cortical-cancellous bone junction. Therefore, periapical pathosis from these teeth is exhibited **sooner** on the radiograph .



By comparison, the distal roots of mandibular first molars and both roots of mandibular second molars are generally positioned more centrally within the cancellous bone, as are maxillary molars, especially the palatal roots. Periapical lesions from these roots must expand more before they reach the cortical-cancellous bone junction and are recognized as radiographic pathosis.



For these reasons, it is important *not* to exclude the possibility of pulpal pathosis in situations in which there are no radiographic changes.

THE END

CROWN & BRIDGE PROSTHODONTICS

Prosthodontics (prosthetic dentistry or prosthodontia)

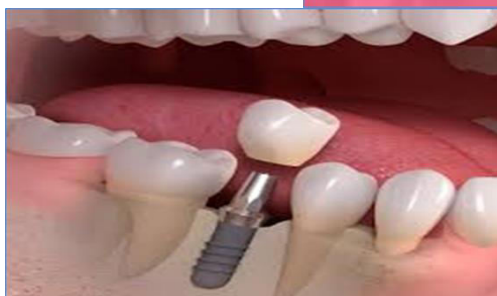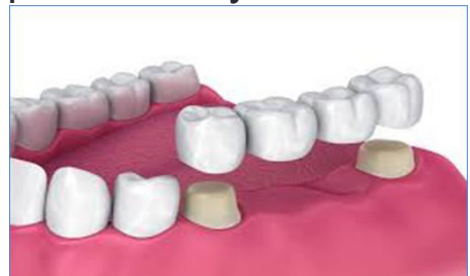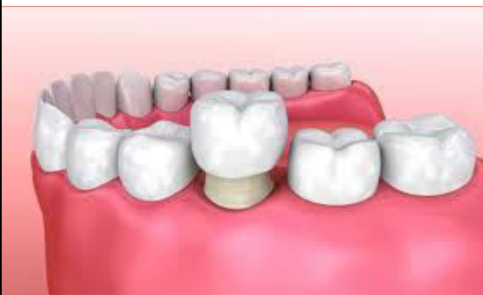- The dental speciality that concerned with restoring & maintaining oral functions, comfort, appearance & health of the patients by making artificial replacements for missing parts of the mouth and jaw.

Branches of Prosthodontics

1. Fixed Prosthodontics FPDs
2. Removable Prosthodontics
 - a) Complete Denture
 - b) Removable Partial Denture RPDs
3. Implant Prosthodontics
4. Maxillofacial Prosthodontics

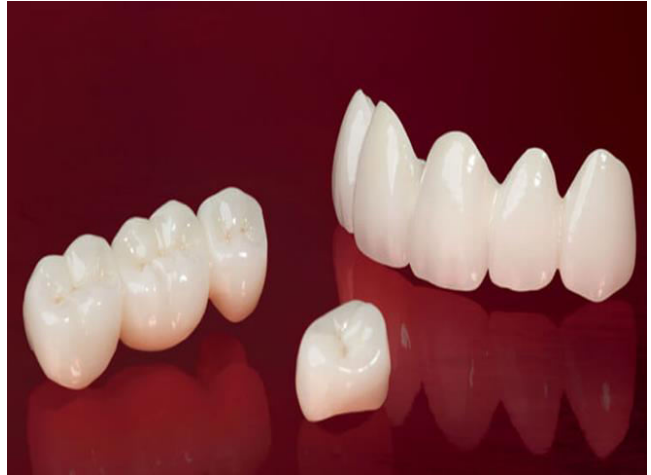Fixed prosthodontics (Crown & Bridge Prosthodontics):

It's a branch of dental science that deals with restoring damaged teeth with artificial crown & replacing the missing natural teeth by a dental prosthesis permanently cemented in place (Fixed partial denture).

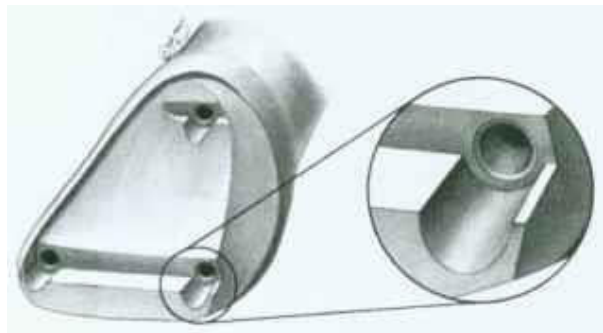
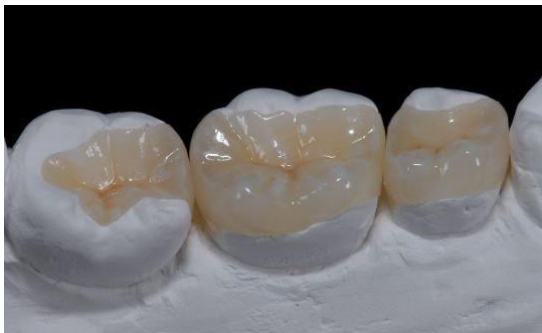

Types of Fixed Prosthesis

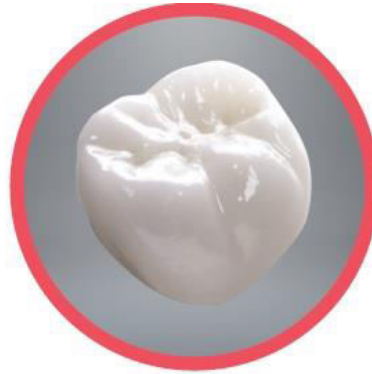1) Extracoronaral: It involves all restorations that seat over the tooth such as all types of crown restorations (Full metal crown, partial crown, PFM, all ceramic crown) & direct or indirect veneer restoration.



2) Intracoronal: It involves all restorations that seat inside the tooth such as inlay, onlays, pinlage.



The Crown: It's a fixed extracoronary artificial restoration for the coronal portion of a natural tooth. It must restore morphology, function & the contour of the damaged portion of a tooth and must protect the remaining tooth structure from further damage.

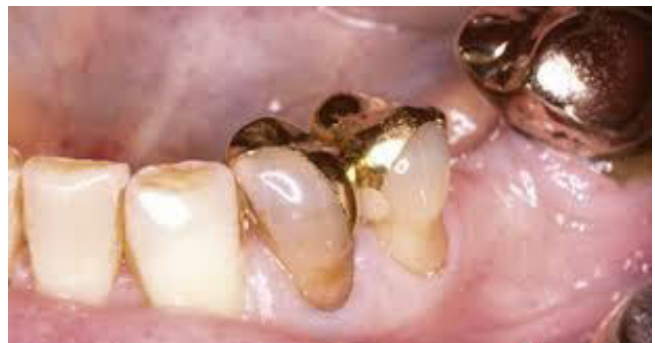
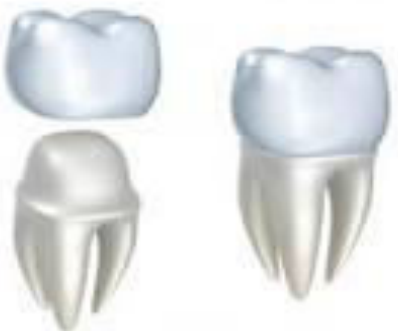
Types of crowns: (Classifications)

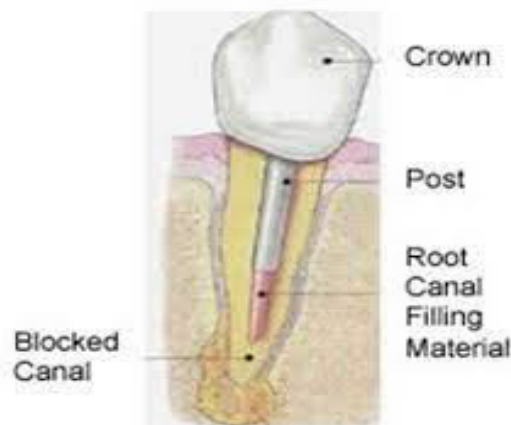
A) According to the coverage area

1. Complete crown: It covers the coronal portion of the tooth, such as full metal crown, All-ceramic crown (made of ceramic material).

2. Partial Crown: It covers part of the coronal portion of the tooth such as 3/4 Crown, 7/8 Crown.

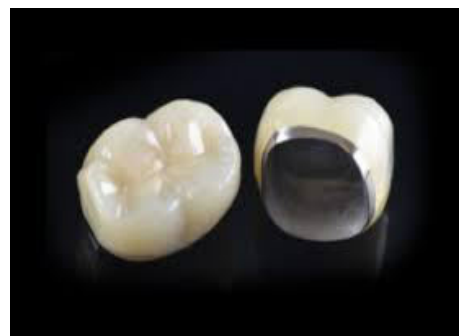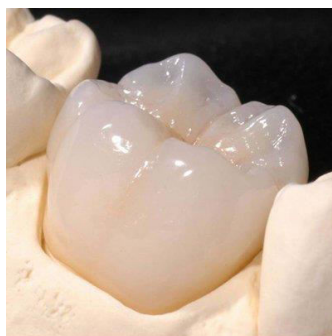

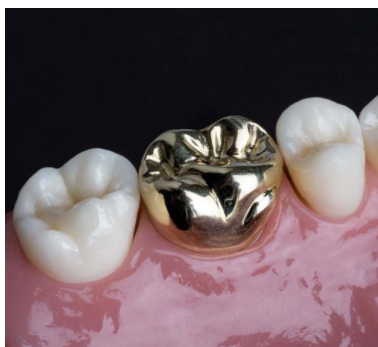
- **3. Complete replacement:** it involves those which replace the natural crown entirely while retains itself by means of a metal extended inside the root canal space of the tooth such as a post crown.



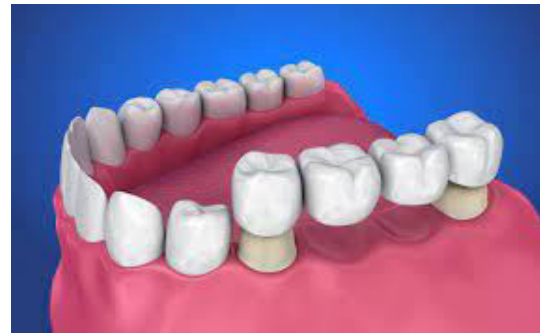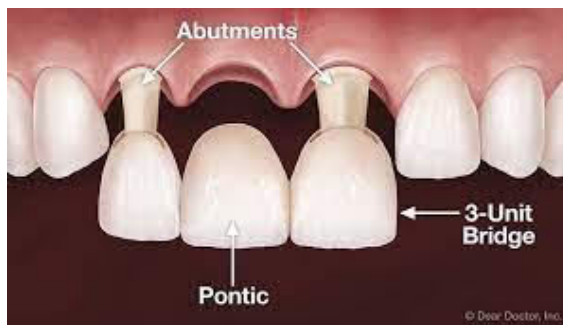B) According to materials used in the construction of C&B restorations

1. **Metal Crowns:** Gold alloy and its alternatives
2. **Non-Metal crowns:** Acrylic resin, Zirconium or Porcelain as in jacket crown.
3. **A combination:** of metal and plastic materials as in PFM crown restorations.



Fixed Partial Denture (Bridge)

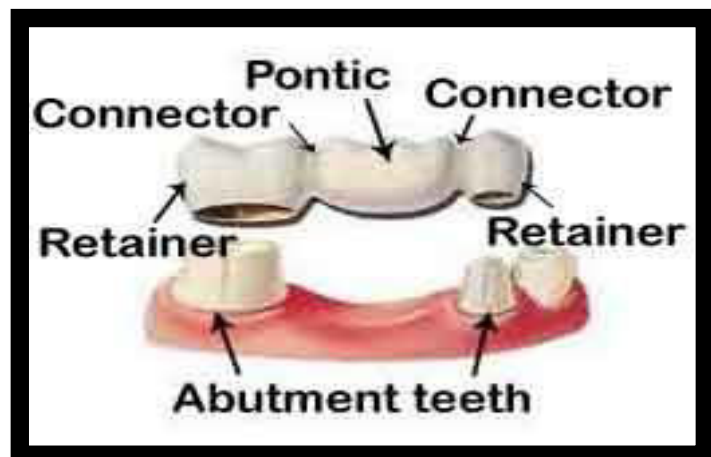
It is a fixed dental prosthesis (appliance) which replaces and restores function and aesthetic of one or more missing natural teeth. It cannot be removed from the mouth by the patient and primarily supported by natural teeth or root.



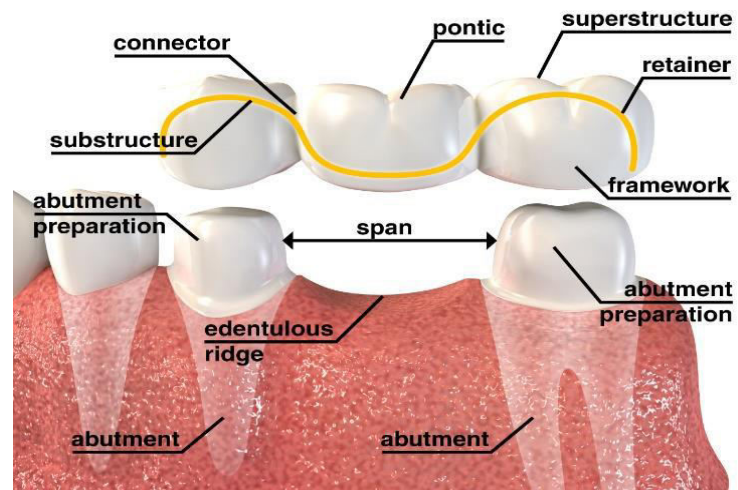
Components of the bridge:

1. Retainer: It's the part that seat over (on or in) the abutment tooth connecting the pontic to the abutment. It is either major or minor retainer, or it could be crown, inlay, post & core.

2. Pontic: It is the suspended member of fixed partial denture that replaces the missing tooth or teeth, usually it occupies the position of the missing natural tooth.



3. Connector: It's the part that join the individual components of the bridge together (retainer & pontics), which could be fixed (rigid) or movable (flexible) connector. When the retainer is attached to a fixed connector it's called a major retainer, but when it is attached to a flexible (movable) connector it is called a minor retainer.

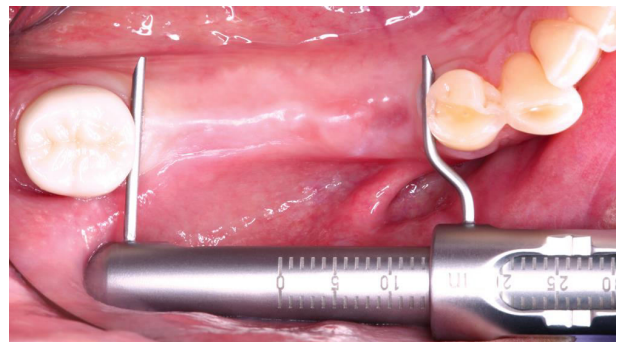
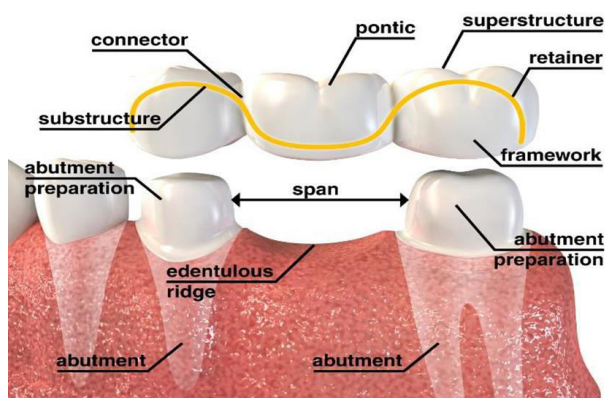


Definitions (terminology)

Abutment: a tooth to which a bridge is attached.

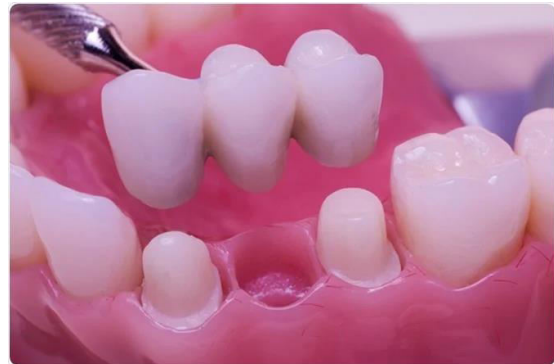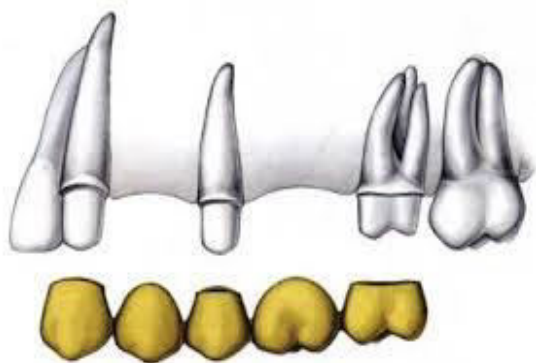
Span: is the space between natural teeth that is to be filled by pontics.

Saddle: is an area of the edentulous ridge over which the pontic lies.

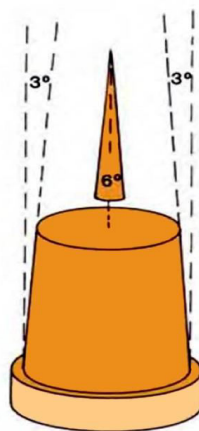


Pier: is an abutment standing between two abutments & supporting two pontics, each pontic being attached to further abutment.

Unit: when applied to bridgework, means either a retainer or a pontic, thus a bridge that replaces a premolar using two abutments is referred as three Unit Bridge.



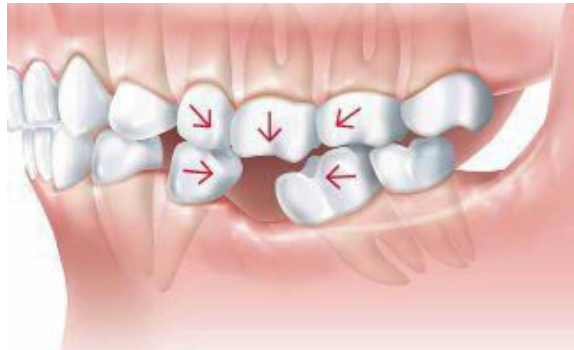
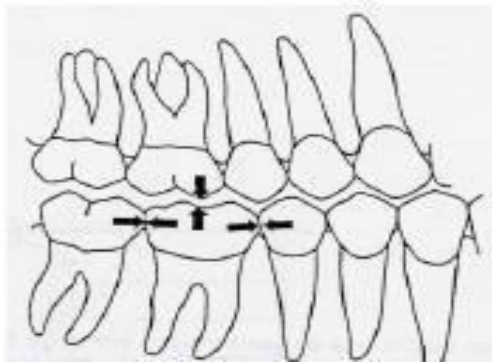
Path of insertion: An imaginary line along which the restoration can be inserted and removed without any interferences or causing lateral force on the abutment.



The ***path of insertion*** is an imaginary line along which the restoration will be placed onto or removed from the preparation.

Why do a Fixed Partial Denture?

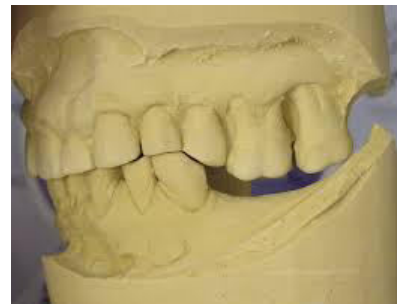The stability of an individual tooth depends on a balance of the forces exerted on that tooth by the adjacent, opposing teeth, supporting tissue & by the soft tissue of the cheek, lips & tongue



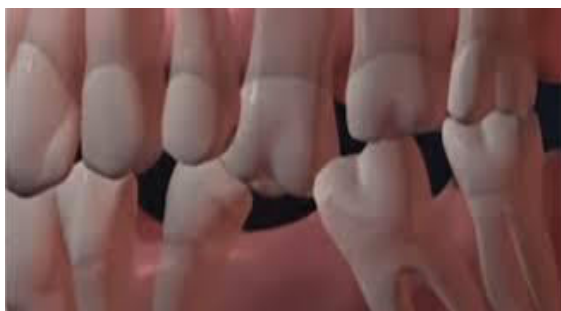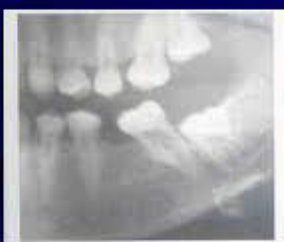When a single tooth is not replaced (after loss), this balance is upset, & the consequence may be:

1. Super eruption of the opposing tooth or teeth:

- a) Gingival recession
- b) Traumatic occlusion or lacking of bite
- c) Loss of bony support for that tooth.
- d) Loss of the proximal contact



Sequelae of tooth loss



2. Loss of function on the affected side:

- a) Diffuse atrophy.
- b) Heavy deposition of plaque & this lead to gingivitis & periodontal disease.
- c) Trauma to the soft tissue during function.
- d) Loss of tissue (contraction of both soft tissue & alveolar bone).

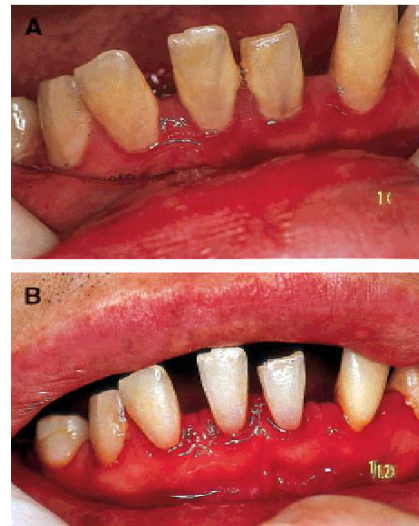
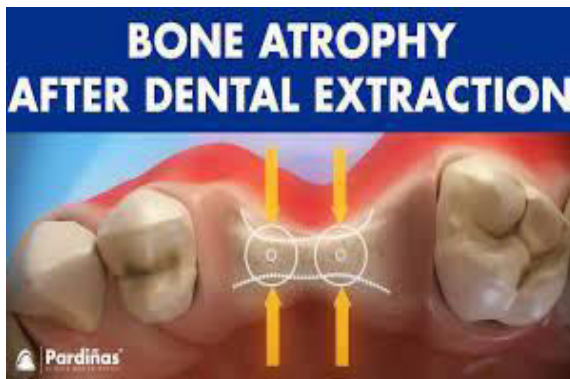
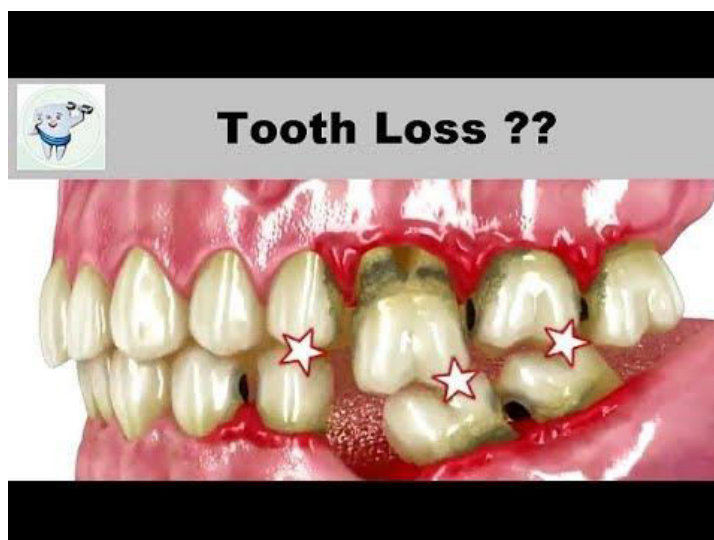
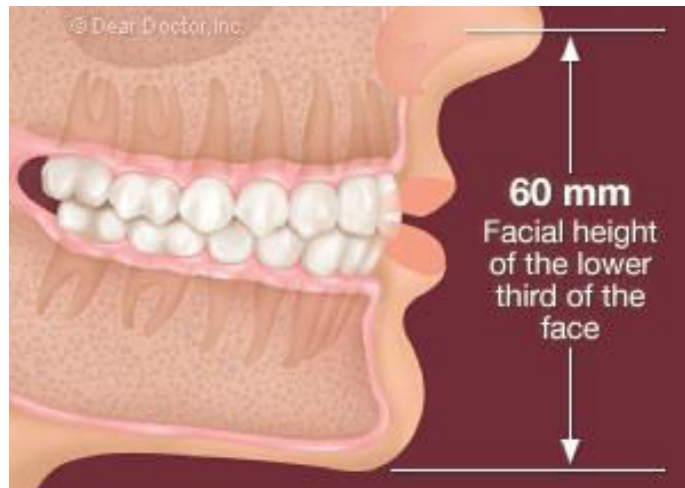
Figure 2 Calculus formed by calcification of plaque

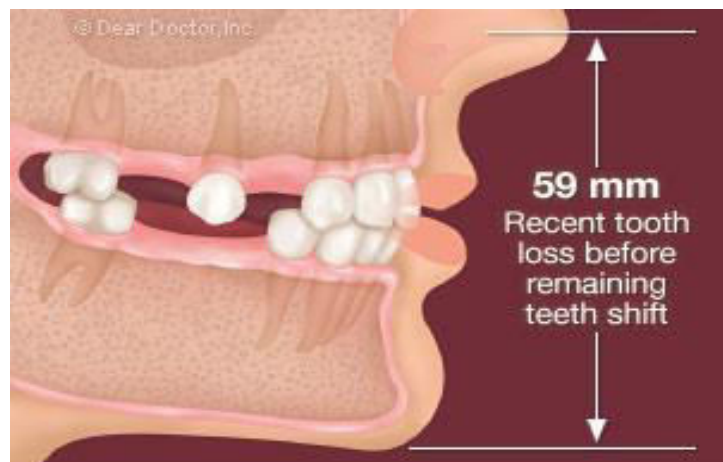
- 3. Tilting (drifting) of the adjacent teeth.
- 4. Loss of the proximal contact to:
 - a) Food stagnation & pocketing
 - c) Sub-gingival caries
- 5. Periodontal problem & mobility



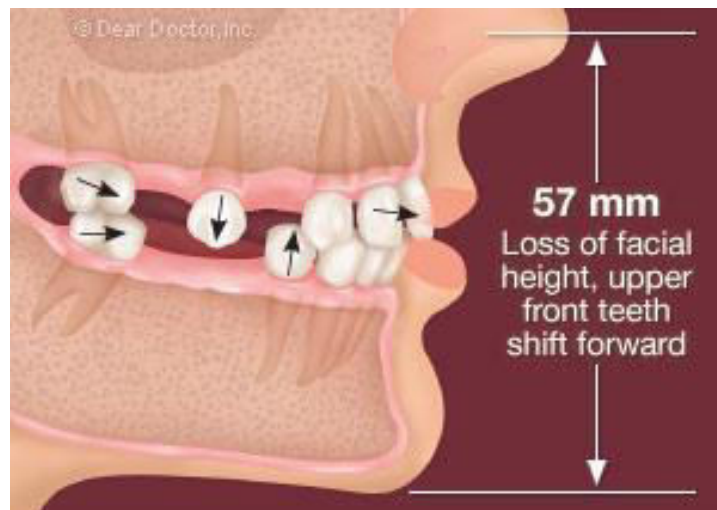- The back teeth and front teeth work in harmony. The back teeth support facial height & chew food while the front teeth cut food, protect the back teeth in lateral jaw movements and provide your smile



The loss of the back teeth place excessive pressure on the front teeth causing shifting of teeth and slight loss of facial height.



Without replacement of the back teeth, the teeth start to shift and excessive pressure causes the front teeth to spread forward. Loss of facial height occurs



The general effects of tooth loss:

- 1) Generalized collapse of lower & upper dental arches.
- 2) Premature contact causing deviation in the normal movement of the mandible which might lead to TMJ dysfunction & muscle spasm that cause pain.
- 3) Tooth loss may lead to unilateral mastication on the opposite side of the dental arch which results in periodontal problems, caries on the affected side due to deficient mechanical cleaning afforded by the act of mastication.

4- Posterior Bite Collapse:

The posterior teeth support the vertical height of the face. If they are lost, the face tends to lose height and close down; this is called “posterior bite collapse”

Treatment at this stage prevents further disruption, it may be insufficient to return back to full health, it needs extended treatment plans including, ortho. Treatment, additional cast restoration to correct the disturbed occlusal plane.

Reasons for treating tooth loss

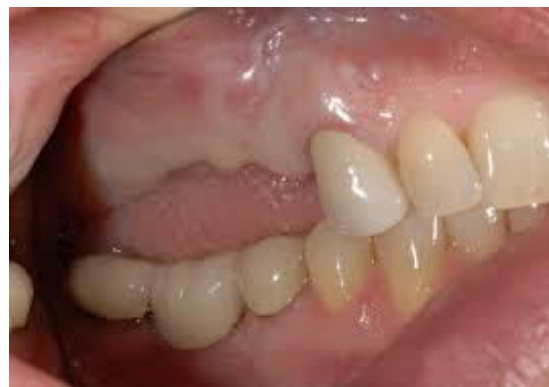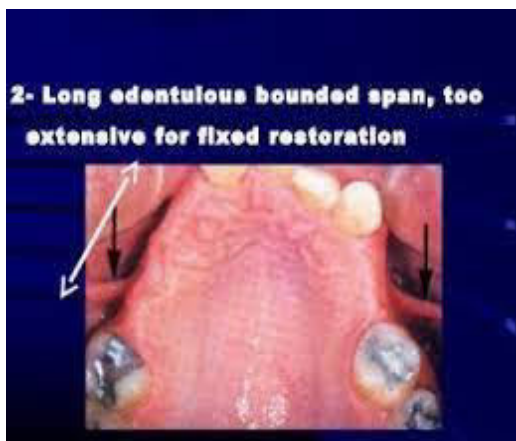- 1) Aesthetic.**
- 2) Function (ability to eat).**
- 3) Pain due to TMJ dysfunction & muscle spasm**
- 4) Maintenance of dental arch (occlusal stabilization & prevent tilting)**
- 5) Speech (particularly lower incisors).**

Methods of treating tooth loss

- Orthodontic.
- Removable partial denture.
- Fixed partial denture (tooth supported partial denture).
- Implant (Osseo-integrated implant).
- Combination (mouth rehabilitaion)

In some cases the decision might be no prosthetic treatment

- 1) Long standing edentulous space (long span) into which there has been little or no drifting or elongation of the adjacent teeth.
- 2) Lack of distal abutment.



Clinical Try-In & Cementation of Crown & Bridge

Lecture 9

Clinical Try- In & Adjustment

After the lab. Procedure has been completed, the crown restoration is now ready to be tried in (checked on the prepared tooth inside patient mouth) prior to final finishing & cementation.

Try-in procedure involves three stages:

firstly pre-operative evaluation of crown or fixed bridge on its die, secondly seating on the tooth and finally evaluation of the seated restoration.

Pre-operative evaluation of crown or bridge on its die

It is always worth checking the fit of the crown on the cast before trying it in the patient. In this way problems involving marginal fit, aesthetics and articulation can be anticipated prior to try in.

- Checking of the crown on the cast before trying it in the patient.
- Preferable with a good light and under magnification
- The restoration should be seated on the die without any pressure

Prior to Try in procedure, the inner surface of the restoration is inspected for:

1- nodules, bubbles might interfere with seating of the restoration on the die should be removed using a small round bur

2- No contact (pressure area) should exist between the die and the internal surface of the restoration. A uniform space is necessary for the luting agent to spread evenly. Any contact(s) must be identified and relieved by selective grinding of the internal surface.

Seating The Restoration on the prepared tooth(teeth) :

Remove temporary restoration and clean the prepared tooth from any remnant of cement because it will interfere with seating of restoration.

Seat the restoration on the prepared tooth with pressure.

Evaluation Sequence of the seated crown:

- 1. Proximal contacts*
- 2. Marginal integrity*
- 3. Retention & Stability*
- 4. Occlusion*
- 5. Polishing or Characterization and glazing*

1- Checking the Proximal contacts

- 1- The location, size, and tightness of a restoration's proximal contacts should resemble those of the natural teeth.
- 2- Excessive contact prevent the complete seating of the restoration and cause marginal discrepancy
- 3- Open contact lead to food impaction
- 4- The use of unwaxed floss is a method to compare the contacts with others in the dentition
- 5- The use of 0.05 mm shim stock (thin Mylar film) is probably a more reliable indicator of proximal contact.
- 6- **Satin finish** helps to identify Excessive tightness in metal restoration, Shiny spot will appear where binding occurs Shiny spot will appear, where adjustment is necessary.

How to Examine the inter proximal contact area

It should be tight as the other in the mouth. Dental floss is used to check the interproximal contact by passing it between the restoration and the adjacent natural teeth, **it should have slight resistance** otherwise we have either;

a) Heavy resistance; the dental floss can not pass through the contact, this indicate that the contact is heavy and it must reduced.

b) No resistance; however if the floss passes easily, it indicate that the contact area is under contoured (deficient contact).

How to correct

- A **metal crown** or retainer with a deficient proximal contact can usually either you have to **repeat** the restoration or to **correct** this defect by adding solder to that area.

- Porcelain restoration

- The area of contact can be identified with red pencil or thin marking tape.
- A tight proximal contact in unglazed porcelain is easily adjusted with a cylindrical stone.
- If adjustment of a glazed restoration is needed, it can be done with diamond-impregnated silicone points or diamond polishing paste
- A deficient proximal contact correct by adding porcelain (lab)

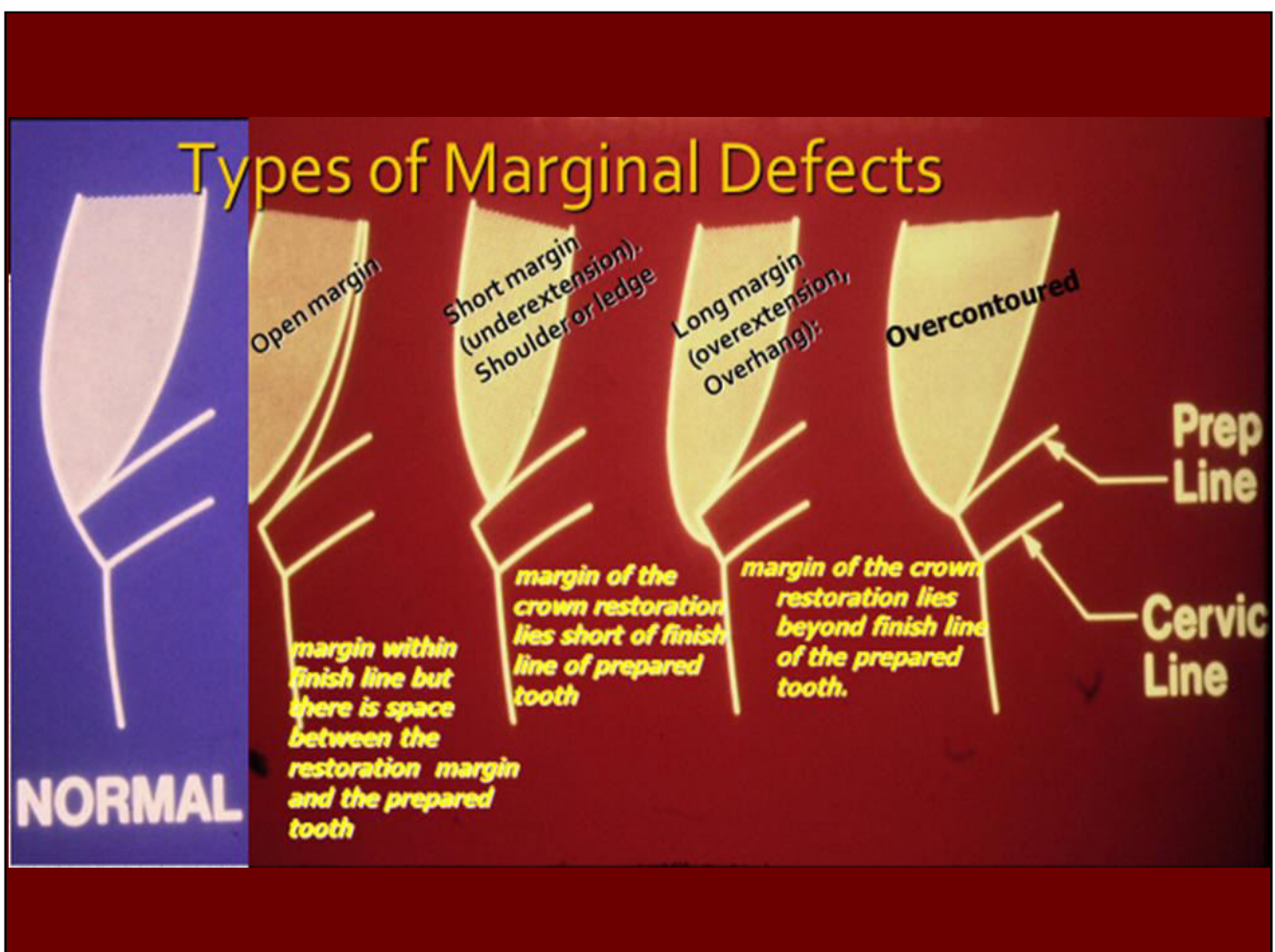If the contact area is perfect and the crown is not seat completely this might mean that, **there is interference** from inside (metal bubbles or undercut) we use **pressure indicating paste** (special elastomeric detection pastes such as silicon wash) or spray to identify the interferences. We place it into the inner surface of the crown restoration, the crown were then seated on the prepared tooth with pressure , the restoration then removed and inspected for any pressure (shiny) area which indicates an interference area that should relieved

2. Evaluating Complete Seating (marginal integrity);

The margin of the restoration is the most critical area of the restoration, we should have complete fitness between the restoration margin and finishing line of the preparation.

Types of Marginal Defects

1. Short margin (under extension, Shoulder or ledge); Margin of the crown restoration lies short of finish line of prepared tooth
2. Long margin (overextension, Overhang); Margin of the crown restoration lies beyond finish line of the prepared tooth.
3. Open margin; Margin within finish line but there is space between the restoration margin and the prepared tooth
4. Overcontoured; Margin within finish line but the contour of gingival third show excessive bulk.



Poor fitting margins will lead to:

1- Cement dissolution

2- Plaque retention and affect the health of gingiva

3- Recurrent caries

How to check the marginal integrity:

To check the marginal integrity of the crown restoration

1-Visual

This indicate especially for the supra gingival margin or margin that have easy access to evaluate by the operator eyes that might be:

a- Direct or indirect visual (mirror)

b- Use of Magnification apparatus such as eye loops or microscope.

2- Radiographic

A- Use to detect Interproximal margins that cannot seen by eye

b- Angle of beam (parallel technique to detect interproximal margin)

3- Explorer

A- Size of tip


B- Angle of approach

Probe can be used to check the marginal integrity of the crown restoration, especially subgingival margin, varying tip size probes should be used. Varying approaching angle should be apply during checking with probe.

Varying Sizes of Tips



Angles of Approach



3. Retention and stability

The restoration should then be assessed for Stability on the prepared tooth. And it should not **rock** or **rotate** when force is applied. If instability is due to a small positive nodule it can usually be corrected, however. If instability due to distortion, remake will be necessary.

4. Occlusion

- After complete seating, adjust the occlusal relationship in all mandible movements (centric and eccentric) using articulating paper.
- Any occlusal Prematurity should be relieved
- Occlusal adjustment can be done using high speed diamond burs
- For those that are out of occlusion, the treatment is remaking (metal) or refiring (Porcelain)

5. Polishing or Characterization and glazing

Metal restoration.

Objective is to provide smooth shiny restoration surface that will be less susceptible to plaque accumulation or deposition. polishing provide a restoration that have (purposes);

- 1) Glossy surface
- 2) Plaque resistant
- 3) Tarnish/corrosion resistant
- 4) Good appearance

Surface defects and roughness are removed by grinding with abrasive particles bound on grinding stone or rubber wheel or paper discs or it applied as abrasive paste. The most commonly used abrasive is Tripoli on soft Robinson bristle brush.

Porcelain in PFM and all ceramic crown restorations

Contour & Shade of the restoration

- the evaluation should be done before glazing
- Moistened with water or saliva (to reflect the light same to glazed restoration)
- Verify shade & contour of the gingival third
- Excessive bulk might cause periodontal disease

Surface Texture Characterization

- should duplicate the surface detail & reproducing natural defects of the patient's natural teeth.
- Avoid over characterizing restorations (lead to artificial appearance)

Glazing:

It is the application colorless glass powder to the fired crown or bridge surface produce a glossy surface & duplicate natural tooth surface luster and characterization.

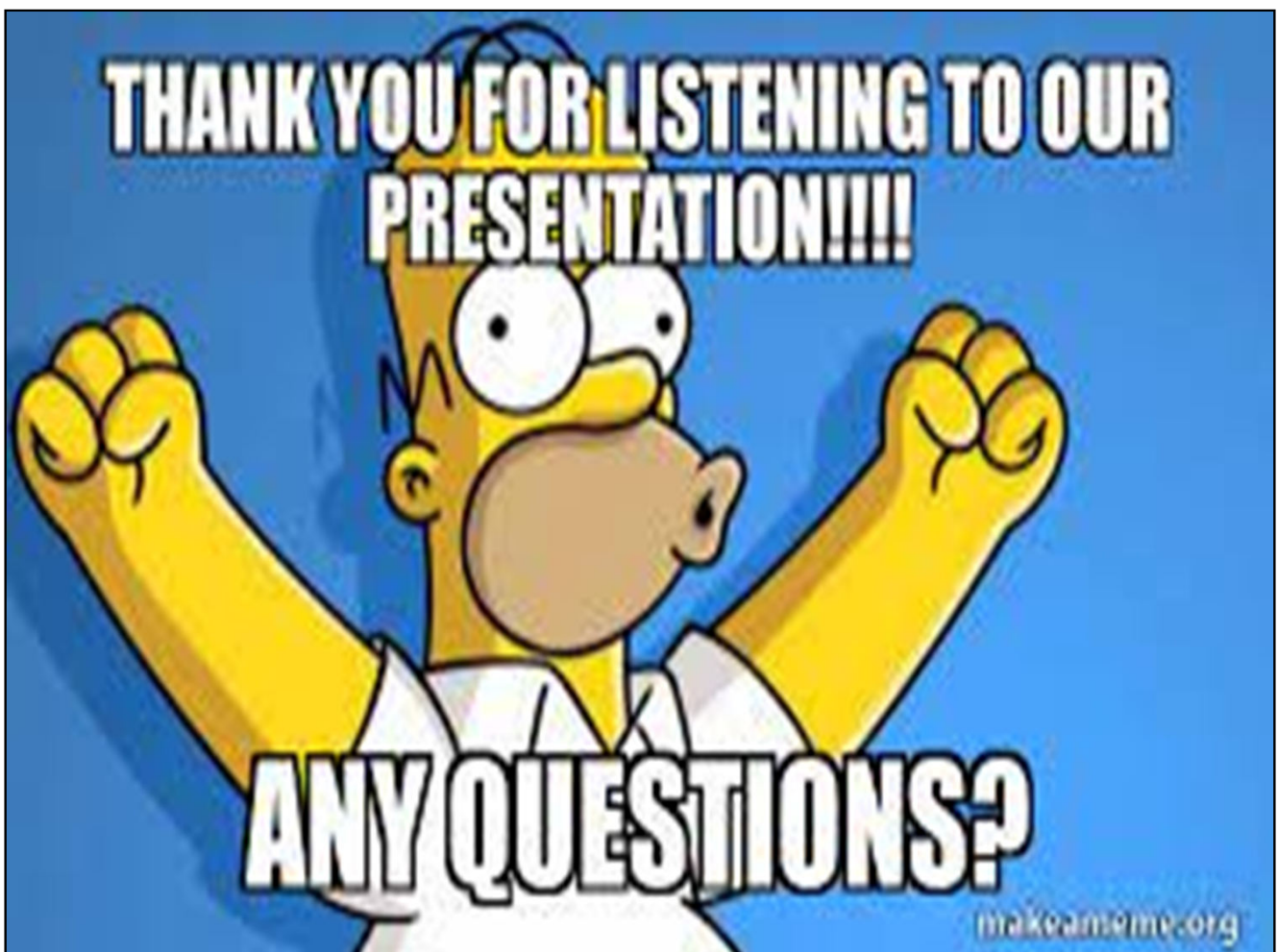Insufficient glazing will lead to:

- 1- Rough surface may lead to abrasive wear of the opposing dentition
- 2- Increase the rate of plaque accumulation.
- 3- Inflammation of the soft tissues it contacts.
- 4- Reduction in the strength of a ceramic restoration.

Polishing

An alternative to glazing is to polish the porcelain surfaces of the restoration.

- 1- provides precise degree of luster and distribution than glazing.
- 2- Polishing dental ceramics as way of restoring luster after adjusting by grinding.
- 3- polishing can be done using : silicone wheels or diamond polishing paste.



Cementation of crowns and bridges

Lecture 10

Having successfully negotiated the planning, preparation, impression and prescription of your crown, the cementation stage represents the culmination of all your efforts. This stage is not difficult, but a successful outcome needs as much care as the preceding stages. Once a restoration is cemented there is no scope for modification or repeat.

Permanent Cementation

The mechanisms of holding a crown restoration on a prepared tooth using specific luting material (agent). it could be **nonadhesive (mechanical) luting, micromechanical bonding , and molecular adhesion**. Dental cement doesn't contribute to the retention of the restoration.

Luting Agent:

A material that acts as an adhesive to hold together the crown restoration to the tooth structure. Luting agents are designed to be either permanent or temporary.

Bonding Mechanisms

1- Nonadhesive (mechanical) luting

Involves filling of the macro-spaces between the tooth structure and the restoration with luting agent, when it sets (into the small irregularities between the opposing surfaces), it provides a mechanical bond (interlocking) that prevent the restoration from removal.

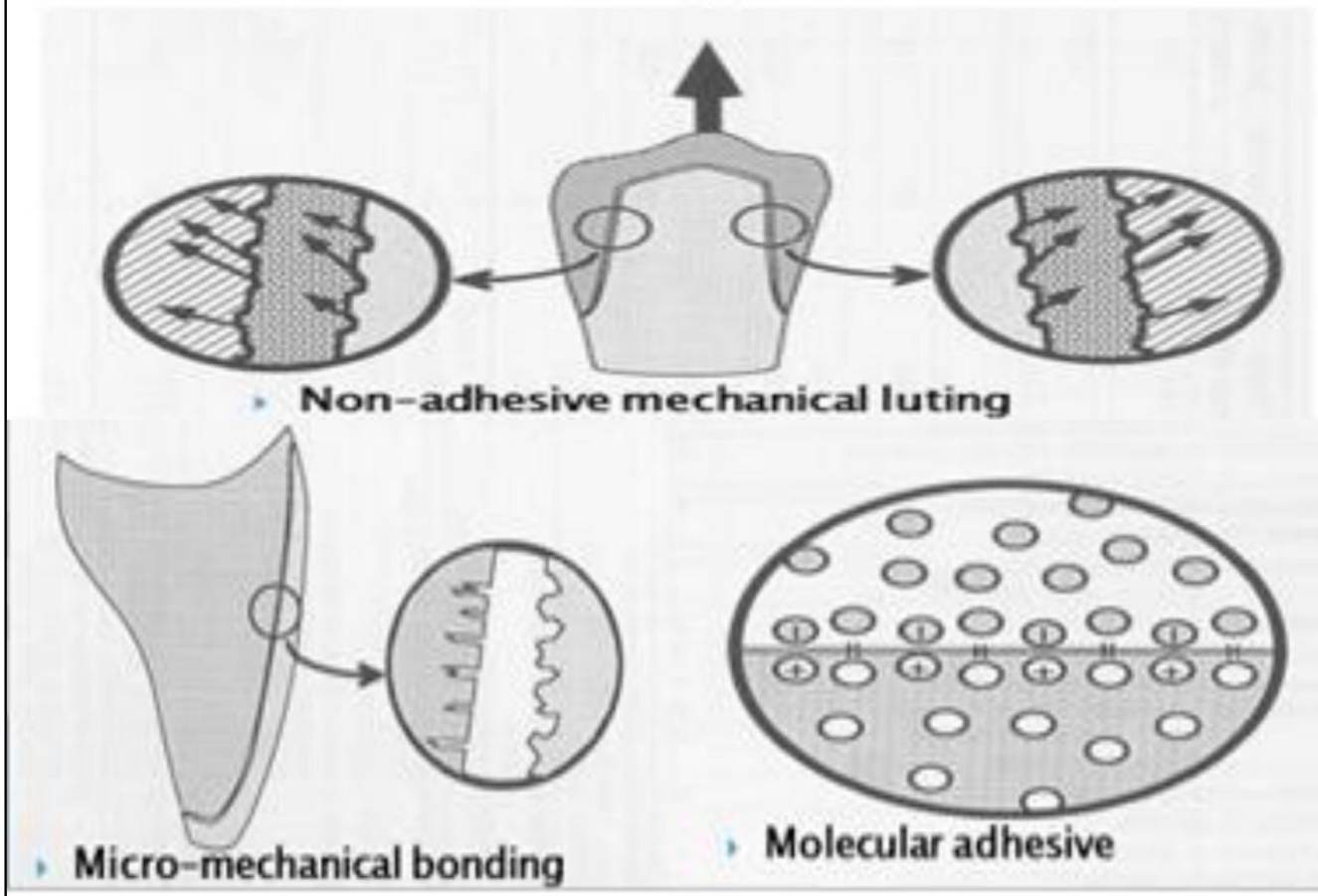
2- Micromechanical bonding

Involves deep irregularities that can be produced on enamel surfaces by etching with phosphoric acid solution or gel; on ceramics, by etching with hydrofluoric acid; and on metal, by electrolytic / chemical etching, and sandblasting

3- Molecular adhesion

Involves physical forces and chemical bonds between molecules of two different substances

Cements bonding mechanisms



Ideal properties of luting agent:

- 1) Low film thickness($\leq 25\mu\text{m}$)
- 2) Adequate strength(minimum 70 MPA)
- 3) Low viscosity & solubility
- 4) Adequate working time
- 5) Reasonable setting time
- 6) Should provide good sealing. And must be non-toxic to the pulp (Biocompatible)
- 7) Radiopaque
- 8) Adhesion to tooth structure and restorative materials

Function of cement:

- 1) To secure a lasting retention of the restoration to the prepared tooth.
- 2) To seal the gap against penetration of fluid and bacteria from oral cavity.
- 3) To act as an insulating barrier against the thermal and galvanic activity.

Factors affecting the retention of the cemented cast restoration

1. Geometrical relations of the preparation; retentive properties of the preparation (taper, height, surface area.....etc).
2. Biophysical factors relating to the restoration ; such as accuracy of fit, metallurgical characters, inside surface texture of the casting restoration
3. Mechanical properties of the luting agent; such as compressive strength, tensile strength, shear strength , adhesive property and film thickness
4. Difference in the coefficient of thermal expansion between tooth, restoration and cement.

Dental Cementing (luting) Agents

Cements may be classified as soft or hard.

- 1) Soft cements can be used for provisional cementation of definitive crowns when a trial assessment period is needed, for example if the occlusion or aesthetics is being significantly altered.
- 2) Hard cements There are used for definitive (permanent) cementation. There are essentially three types of hard cement: conventional, resin or a hybrid of the two.
 - a) Conventional cements , rely on an acid-base reaction resulting in the formation of an insoluble salt (the cement) and water (e.g. zinc phosphate, zinc polycarboxylate and glass ionomer).
 - b) Resin cements, set by polymerization.
 - c) Hybrid cements relay on acid base reaction and polymerization

Zinc phosphate cement

It is the traditional luting agent that have proven itself after years of work, it has compressive strength of pulp (cavity varnish used to decrease that's effect) 14000-16000 PSI, with low PH at the time of cementing (about 3.5) which might irritate the pulp, come in two separate containers; powder and the liquid.

- 1- Oldest Luting agent
- 2- Little effect on the retention of the restoration
- 3- Irritant to the

Recommendations:-

1. Good default cement for conventional crowns and posts with retentive preparations.
2. Working time can be extended for cementation of multiple restorations by incremental mixing and cooled slab.

Zinc silicophosphate cement

Has compressive strength of 22000 PSI but it has highly acidic PH and affect the health of the pulp (irritant).

1. Mixture of zinc phosphate & silicate cement.
2. Film thickness, compressive strength & tensile strength in the range of ZPHC with slight lower solubility.
3. Anti cariogenic property due to fluoride content.
4. Low PH & pulpal irritation, doesn't use now a day.

Poly-carboxylate cement

adhere to enamel, dentine and stainless steel but not to gold alloy, high bond strength to enamel (1300 PSI) but its binding to dentine is considerably less 480 PSI. the setting PH is (4.8) , Attains a relatively neutral pH level after setting ,because of the large size of poly-acrylic acid molecule, it has less effect on the pulp, Low film thickness optimizes fit and marginal integrity of the crowns.

Recommendations:-

- 1- Traditionally used for vital or sensitive teeth, but no evidence to support efficacy (dentine bonding agents used to seal preparation prior to cementation may be a better option).
- 2- Occasionally useful to retain an unretentive provisional crown.

Glass ionomer cement

As for polycarboxylate cement but cement has similar acidity to zinc phosphate on mixing, has compressive strength of 18600 PSI (Low tensile strength), it bonds to enamel and dentine (to enamel more), it releases fluoride after setting which is indication of an ability to inhibit secondary caries. Sensitive to early moisture contamination. Has been accused of causing post-operative sensitivity but a controlled trial reports it is no worse than zinc phosphate

Recommendations:-

- 1- general prosthodontic use. Fluoride release may be beneficial for some patients. Avoid using glass ionomer with hypersensitive teeth.
- 2- Used empirically for conventional crowns where patient has had a previously high caries rate.
- 3- May be used as an alternative to zinc phosphate.

RESIN LUTING CEMENT

They have wide range of formulation , can be classified basis of polymerization method (chemical, light cure, dual cure) & the presence of dentin bonding mechanisms. Chemical cure for metal restoration , light cure for ceramic restorations.

Advantages

1. chemical Bond to the tooth structure
2. High strength
3. Reduce fracture of ceramic restoration
4. Low solubility

Disadvantage

1. Difficult to remove excess after setting
2. High cost
3. Irritant to the pulp

Recommendations:-

1. Must be used with or incorporate an effective dentine bonding agent.
2. Material of choice for porcelain veneers, ceramic crown & composite restoration and resin bonded ceramic crowns.
3. May be used to improve retention where preparation geometry sub-optimal.

Types

1) Adhesive Resin Cement

- Two component system - one bottle (self-etch), one syringe.
- Time-consuming, etching, bonding.
- Sensitive procedure

2) Self-adhesive resin cement

- One component type
- Time-saving, no etching, or bonding.
- Easy to use

Resin modified glass ionomer cements and compomers

- Resin modified glass ionomer (RMGI) cements are a hybrid of traditional glassionomer cement with small additions of light curing resin and generally have the advantages of both , combine the strength and insolubility of resin with the fluoride release of GIC. They were introduced with the aim of overcoming the moisture sensitivity and the low strength of conventional glassionomers.
- The use of RMGIs for luting purposes is becoming more popular because of (1)their relatively high bond strength to dentine, and (2)their ability to form a very thin film layer. (3)RMGIs leach fluoride, but it is unclear how useful this is in preventing secondary caries formation.

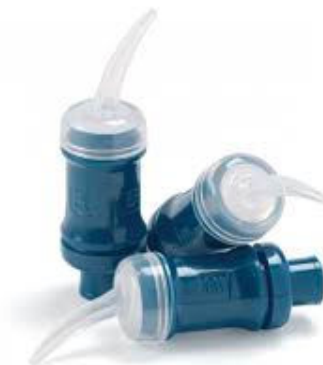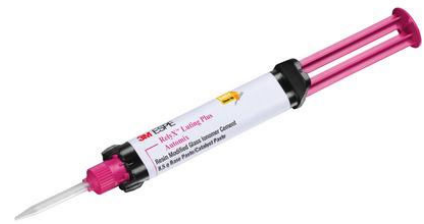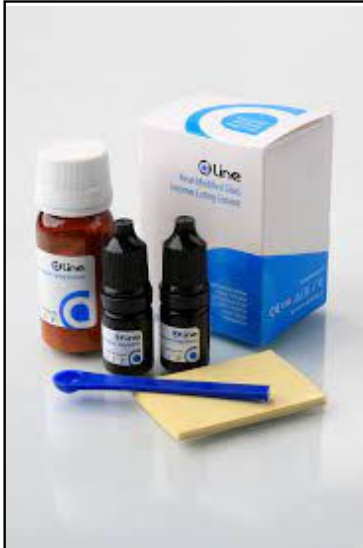Advantages:

- 1- Sustained fluoride release.
- 2- Moisture tolerant.
- 3- Low solubility
- 4- Low microleakage
- 5- Less post cementation sensitivity

Delivery system

1)Hand mixing **2)**Applicap / maxicap capsule **3)**Auto mix (syringe or clicker dispenser)

The selection of cement for placement of cast restoration is not clear cut decision.



Restoration Material Types

Choosing of cement material Depend on the strength of the restoration so;

- 1- Weak restorations, e.g. all porcelain or all-composite crowns, inlays, onlays, and veneers, must be adhesively bonded with strong cements.
- 2- strong (metal) have sufficient strength to allow the use of any cement type.
- 3- Most porcelain-fused-to metal crowns are cemented with traditional luting cements

Non-adhesive mechanical luting Zinc phosphate cement is used

- 1) When maximum mechanical retention is required
- 2) The pulp of the tooth is of no concern
- 3) Also we use it on endodontically treated teeth or teeth with heavy amalgam or composite filling.

Temporary Cements

Plain ZnOE Cements based on zinc oxide and eugenol are classical soft cements. The eugenol acts in a bacteriostatic or bactericidal function and arrest the production of toxin by the microorganism. **Eugenol limited application because it will inhibit the polymerization of resin.** ZnOE is **not used for permanent cementation** because:

1. It has poor oral durability due to continuous eugenol loss.
2. Also it possess low compressive strength, so we use it for temporary cementation.

Temporary cement zinc oxide non-eugenol

- 1- Eugenol free for universal application because it will not inhibit the polymerization of resin
- 2- Should have low film thickness help ensure an optimal fit

Cementation Technique

When ZPC is used as luting (for metal & PFM) :(mechanical bonding)

1. Remove the temporary crown, cleaning of the prepared tooth pumice and water from any residues of cement. Finally rinse and dry-do not dessicate
2. Isolate the prepared tooth or teeth with cotton roll (dry field of operation).
3. Partial protection of pulp can provided by application of two layer of cavity varnish.
4. Start mixing cement, mix slowly and over a wide area on a cool glass slab to insure that a maximum amount of powder can be incorporated to reduce acidity.
5. Apply a coating of the cement to the inside of clean dry casting restoration.
6. Seat the casting crown on the tooth with pressure and have the patient to apply force to the occlusal surface of the casting by biting on wooden stick or cotton roll for 3-4 minutes (to ensure complete seating).
7. After cement setting, remove any excess cement from the interproximal area, gingival cervical and underneath the bridge using dental probe and dental floss.
8. Check occlusion

Cementation procedure for All-Ceramic Crown and bridge:

Luting of all ceramic crowns or bridges is dependent on the substrate being used. Ceramic restorations available today are either etchable or non-etchable based on the core material.

1- Etchable are the silica-based ceramics: feldspathic, Leucite-reinforced feldspathic porcelain (IPS Empress®), and lithium-disilicate glass-ceramic (IPS e-max®).

Using of 5% HFL gel is applied to the inner surface of the crown or bridge retainer for 20 seconds and then copiously rinsed with water. A primer is applied for 60 seconds. This primer allows bonding of the resin-based cement to the restorative material. Depending on the type of luting agent used (self-etch adhesive resin/adhesive resin) the tooth may or may not need to be pre-conditioned.

2- Non-etchable are the non-silica-based ceramics, such as aluminum oxide (Procera® AllCeram) and zirconium oxide.

Just micro sand blasting, application of silica bond and adhesive resin

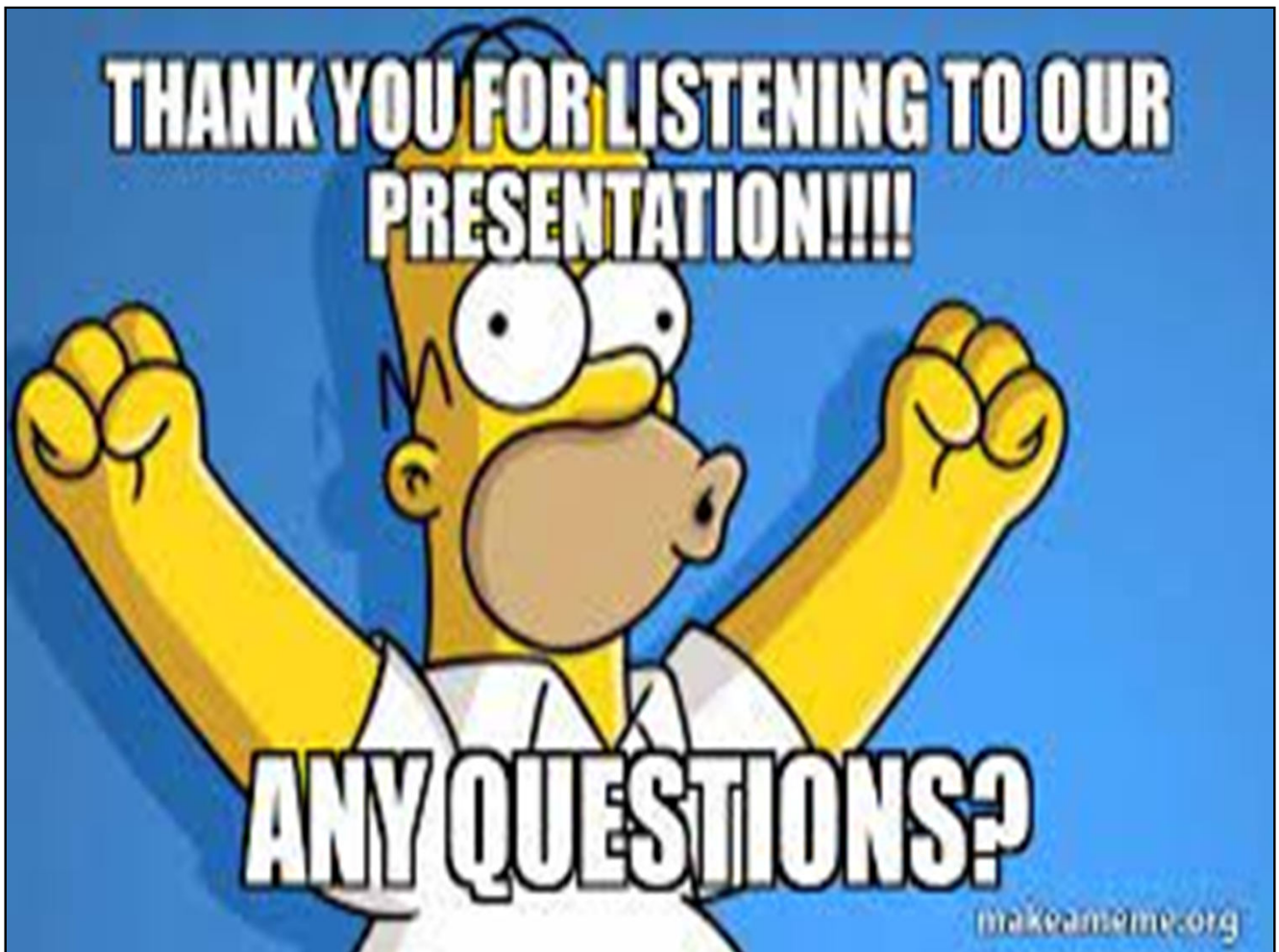3- follow the same steps 5 to 8 listed in Cementation technique when ZPC was used as luting agent:(mechanical bonding)

Factors that influence the complete seating of restoration after cementation:

- 1) Viscosity of the cement.
- 2) Morphology of the restoration.
- 3) Vibration.
- 4) Seating force.
- 5) Venting.

Technique Tips

- 1- Fluff powder before dispensing. Hold liquid bottle vertically, and release each drop slowly to ensure equal size drops.
- 2- For any powder/liquid cement, incorporate the powder thoroughly. Insure mix is homogeneous.
- 3- Load the crown evenly with cement.
- 4- As the cement loses its gloss and start to set, it will have a stringy, non-sticky consistency. Start removing excess cement before it hardens.
- 5- After removal of excess, use a piece of knotted floss and run it through the interproximal areas to remove remnant cement.
- 6- Instruct patients to wait 1 hour after cementation.



Shade Selection in fixed prosthodontics

Lecture 11

Shade Selection

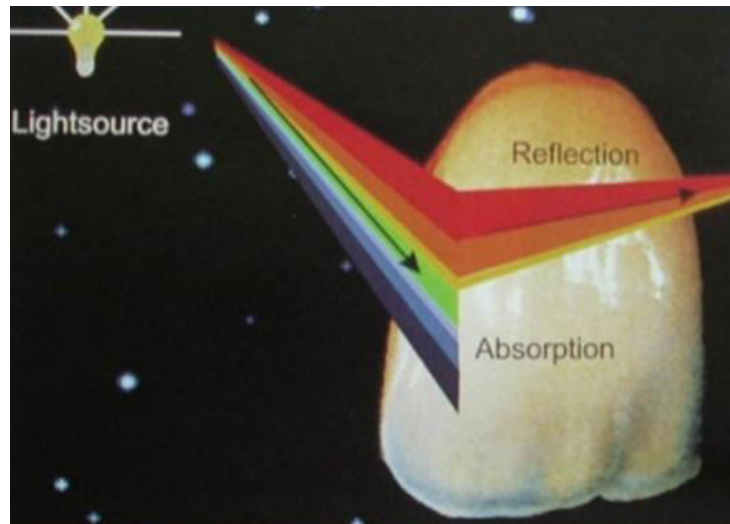
Process of replicating of the color of the adjacent teeth in an artificial prosthesis. The success of dental treatments as perceived by our patients is often evaluated on appearance, rather than long-term health, function and comfort. Everyone, it seems, is primarily interested in color, Color is light, modified by an object as perceived by an eye”.

Color is the result of a light source, *the object that absorbs, transmits, reflects or scatters the light from the source*, and the interpretation of the result by the human visual system. Without Light Color Does Not Exist.

Color & Light

The color of an object is determined by the light that enters the human eye from that object

What is commonly called "the color of a tooth" is actually the color of the reflected light.

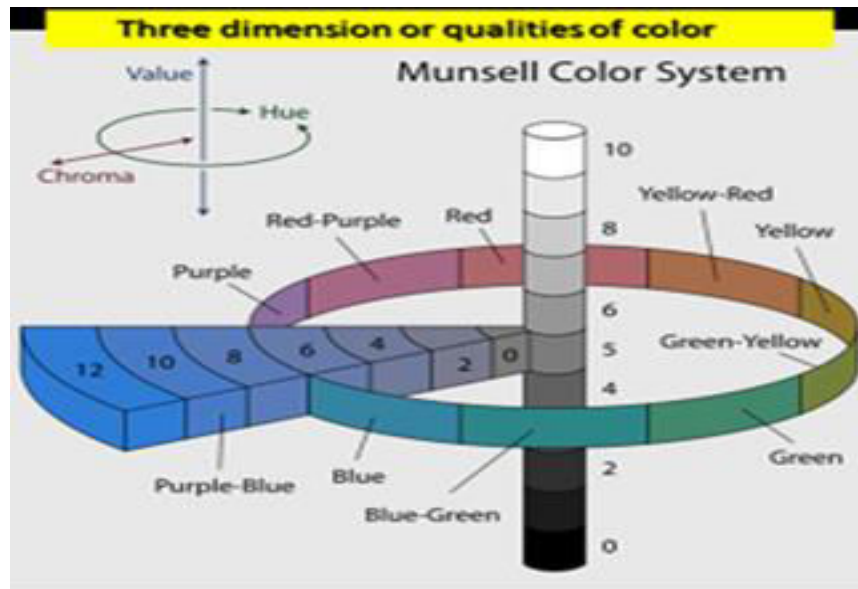


How To Describe Color

Albert Munsell described **three dimensions** of color as **hue, chroma, and value**. It is possible to vary each of these qualities without disturbing the other. The ability to understand each of these dimensions and separate them from one another is fundamental to an understanding of color as it relates to dentistry

Munsell Color System (visual color order system)

Used to describe a definite color system in a visual order system. It looks like an irregular cylinder with its central core representing **Value**, horizontal ring surrounding the central core representing the **hue** and as you move from the center toward the horizontal ring representing the **chroma** ring



Munsell define three dimension or qualities for color

1. Hue

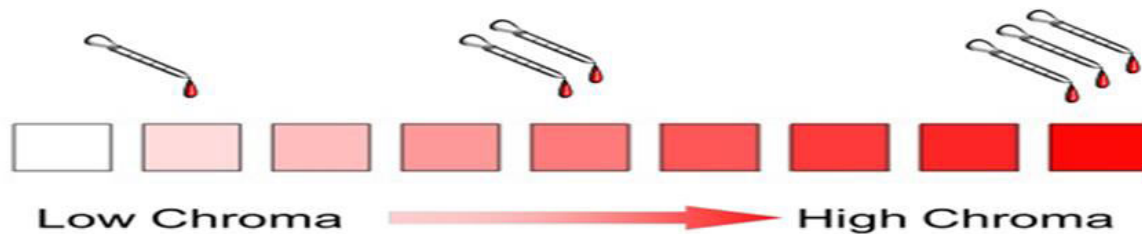
Quality by which we **distinguish one color family from another** (variety of color). We have ten hue color families; **1.R-red 2.YR-yellowgreen 3.Y-yellow 4.GY-greenyellow 5.G-green 6.BG-bluegreen 7.B-blue 8.PB-purpleblue 9.P-purple 10.RP-redpurple.**

Each of these ten hues is further subdivided into ten numbered segments.



2. Chroma

Quality of color by which we **distinguish a strong color from a weak one (the intensity or purity or saturation of hue)**. The degree of departure of a color sensation from that of white or gray ; the intensity of a distinctive hue, **color intensity _Range= 0 – 12**



3. Value

Quality by which we **distinguish a light color from a dark one or the relative brightness of object** (lightness or darkness), range from zero to ten, black is zero(0) and white is ten (10)



Value is generally considered to be the most important of the three dimensions of color, because that:

1- the lightness and darkness differences are readily detected by individuals untrained in color perception

2- Another reason is that value differences are more easily detected at a variety of viewing distances (both close-up and at a distance), whereas differences in hue and chroma become more difficult to quantify as the viewing distance increases

Factors influence the apparent color of an object (teeth):

1) Nature of light

We have three light source **Incandescent Light, Fluorescent Light and Natural Daylight**. Most dental offices are outfitted with incandescent and fluorescent lights. **Incandescent Light** Emits high concentration of yellow waves matching. while, **Fluorescent Light** Emits high concentration of blue waves.

Both of two Not suitable for shade matching. **Chair light** not recommended for colour matching as it is over powering and interferes with fine discrimination of three dimensions of colour.

Natural Daylight considered the best Closest to emitting the full spectrum of white light Used as the standard by which to judge other light sources.

At Morning and evening light spectrum rich in yellow/orange and lacks of blue/green because Shorter wavelengths scatter before penetrating atmosphere, While. **At Mid-day time (Hours around noon) where Full spectrum of colors visible consider ideal time for color matching**

2) Physical properties of object

When light strikes an object, and according to the physical properties some wavelengths are absorbed by the object, while other transfer throw it, the remaining are reflected.

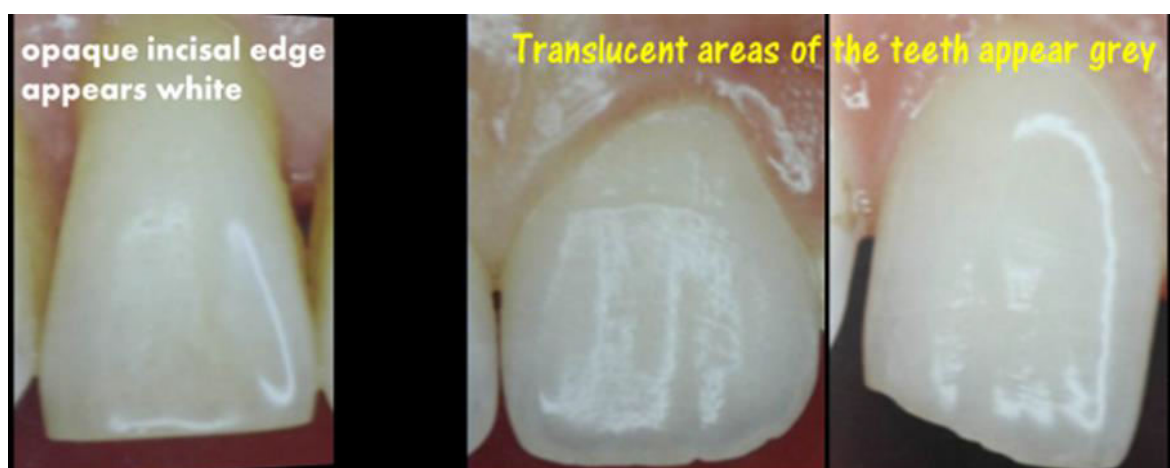Color of an object is the light that is actually reflected by the object.

True color characteristic and appearance of depth translucency in a natural tooth cannot be correctly perceived unless the tooth is free of plaque and surface stains.

With increasing opacity of teeth the grey scale value decreases and the brightness(value) increases , The Higher the brightness (value) the lower the transparency becomes. The more transparent a tooth the more grey it appears.

Opal Effect:

Fine particles in enamel (hydroxyapatite crystals) responsible for opal effect
Fine particles reflect short wave lengths and allow longer wave lengths to pass through. Hence areas within a tooth or a restoration with higher translucency will have a lower value because light transilluminates through. When evaluating enamel translucency, the translucent areas of the teeth appear grey while opaque incisal edge appears white.



Tooth must be kept moist during shade selection. The color environment surrounding an object influences our color perception of the tooth significantly (gum, lip color and color behind the object).

Metamerism

phenomenon occurring when the color of the two objects appear to match under one lighting source but not under a different source, **that is why , shade selection must be evaluate under multiple light sources (different light sources)**

3) Subjective assessment of observer

The rods and cones of the retina form the chief component of the retinal receptor complex. The rods detect only lightness and darkness (value). The cones perceive the chromatic aspects of an object (hue and chroma) .In Color - Deficient person which is Defect in color vision attack 8% males 0.5% females ,Several variations exist.

Achromatism – The state of being free of colors, not emitting or separating into colors.

Dichromatism – phenomenon where a material or solution's hue is dependent on both the concentration of the absorbing substance and the depth or thickness of the medium traversed

Anomalous Trichromatism – hues.it is a form of color blindness or color weakness in which affected individuals have three types of retinal cone but one of these has a color sensitivity that is different from that of the corresponding normal cones.

Dentists should have their color vision evaluated. If any deficiency is detected, a dentist should seek assistance when selecting tooth shades

Shade Selection:

Traditional shade taking involves matching one or more selected colors from a range of shade tabs to the teeth adjacent or contralateral to the teeth to be restored. This serves as a guide to the lab technician fabricating the crown or the bridge. **i.e it is Process of replicating of the color of the adjacent teeth in an artificial prosthesis, we have different methods for shade selection:**

- 1) *Visual shade matching.***
- 2) *Digital shade matching.***

1) Visual shade matching.

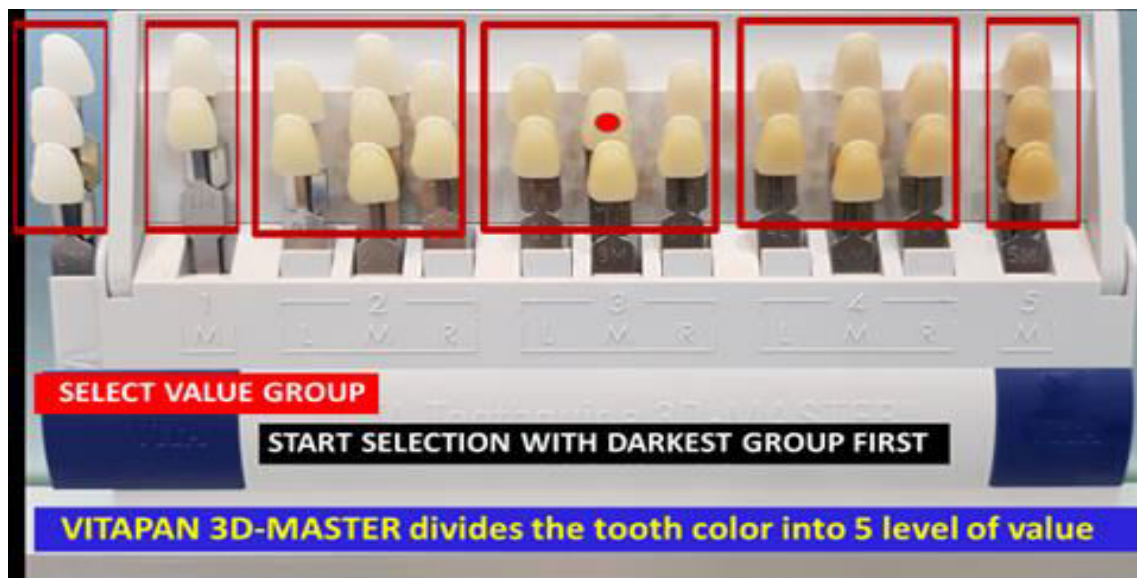Visual shade selection by comparison of a patient's tooth with a color standard (i.e. commercially available shade guide) .

A Dental Shade Guide is a set of simulated teeth used to select prosthetic teeth by color. Shade guide are Examples of various color combinations available from manufacturers of denture teeth, restorative resins and porcelains. These samples are compared with the natural teeth and the closest color match is determined, most commonly use shade guide in fixed prosthodontics;


- a) Vita Classic Shade Guide
- b) Vita-3D –Master shade guide
- c) VITA Linearguide 3D-MASTER

How to use Vita-3D –Master shade guide

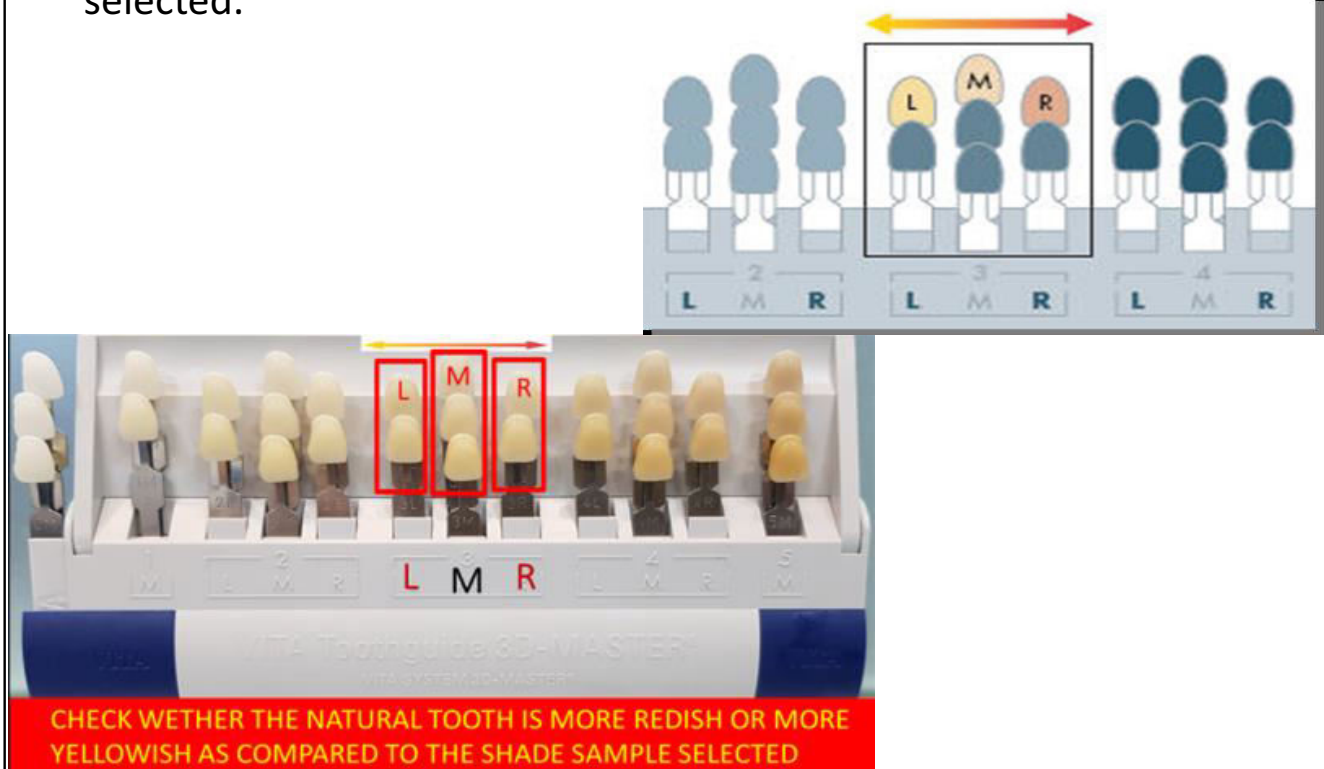
Step 1 Determine the lightness level (value). Hold shade guide to patient's mouth and start with darkest group moving to left . Select Value group 1, 2, 3, 4, or 5



Step 2 Select the chroma from your selected Value group, remove the middle tab (M) and spread the samples out like a fan Select one of the three shade samples to determine chroma.



Step 3 Determine the hue and Check whether the natural tooth is more yellowish or more reddish than the shade sample selected.



Principles of Shade Selection:

1. Teeth to be matched must be clean & moist
2. Remove bright colors from field of view
 - - makeup / tinted eye glasses
 - - bright gloves
3. View patient at eye level
4. Evaluate shade under multiple light sources
5. Make shade comparisons at beginning of appointment
6. Shade comparisons should be made quickly to avoid eye fatigue.
7. selection distance- a selection made at 3-6 feet from the oral cavity is often more useful, since it is representative of the conditions under which the patient teeth will most often be observed.
8. Shade tap position; Shade tap should be held above the mand tooth or below the max tooth to be match and aligned as close as possible to the plane of orientation of the facial surface of the tooth being matched.

Photography & shade matching

- Consider as effective technique for shade matching
- Photography greatly simplifies the shade taking process, particularly for treatment in the aesthetic zone; providing the ceramist with a “palate” of shades rather than trying to match a single shade. (technicians need more information than just a single shade tab)
- A shade tab with the shade that is closest to the shade of the tooth is placed next to the tooth in question and is photographed with the tooth.
- If needed, several photographs can be taken with different shade tabs.

2) Instrumental color analysis (Digital shade-scanning devices)

Digital devices are available that can be used to select the shade

- 1- Tooth should be clean & free of debris
- 2- Need to hold probe perpendicular to tooth
- 3- There is variation in the color depending on where the probe is located
- 4- Tip centered (1 – 2 mm from gingiva and incisal edge) or do 3 zones (gingival, middle, and incisal)

The advantages of a digital shade-matching system include objective readings and accuracy. There are two types of digital shade-matching devices commonly used in dentistry: the **spectrophotometer** and the **colorimeter**.

The **spectrophotometer** consistently and accurately measures natural tooth coloration in reference to any known specific color or can be based on any shading system.

It measures the color characteristics of the natural tooth precisely and scientifically, indicating the deviations and gradations of value, chroma, and hue from a standard and provides all the information that is necessary to create an accurate restoration, or to modify an existing one such that it will accurately match the tooth.

spectrophotometer develops an accurate interpretation of the tooth shade on a given color system, which can then be related to an existing shade tab within dentistry or to a color that is interpolated between the shade tabs. In either case a lab technician is given all the color clues to recreate a shade that is very natural in appearance and very close to the target coloration.

The **colorimeter** analyzes the tooth coloration based on preloaded data that is related to a shade system. It determines the shade tab that is closest to the actual color of the tooth. The colorimeter is typically **less accurate** than the spectrophotometer but may suffice in most dental situations.

Because both spectrophotometers and colorimeters tend to eliminate ambient light by standardizing the immediate environs of the target tooth, the shade can be taken in any operatory with any kind of lighting streaming in through the window.

Digital shade taking therefore is:

more easier, more practical, and more accurate than shade taking using color tabs and the naked eye in a variable environment.

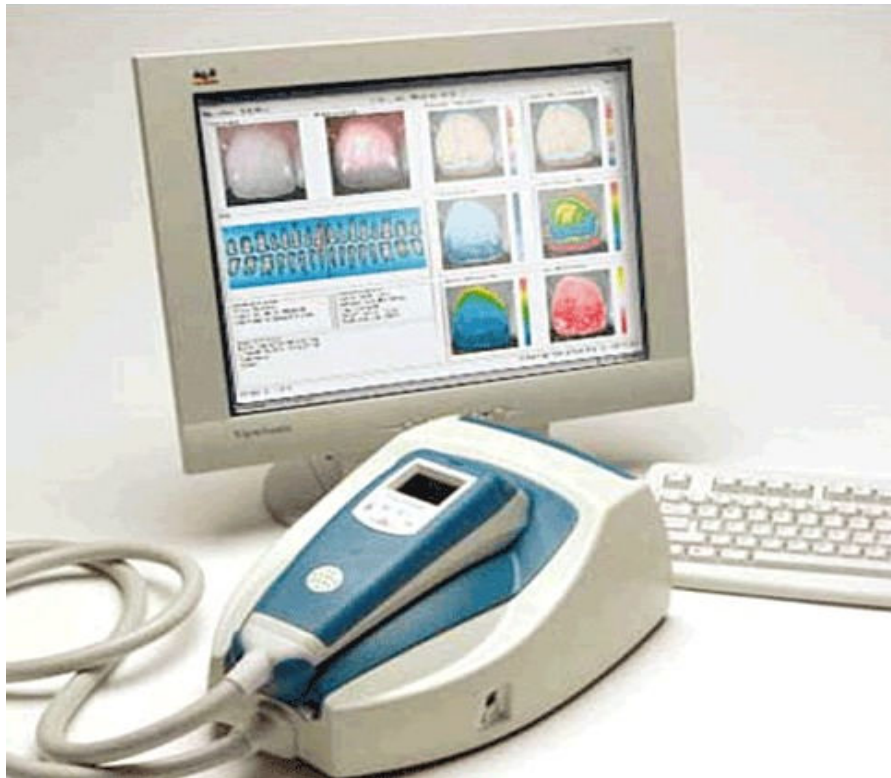An example of digital shade scanning devices

- a) VITA EASYSHADE
- b) VITA EASYSHADE COMPACT
- c) MHT SPECTROSHADE SYSTEM

CYNOVAD SHADESCAN

The system is user friendly and is integrated with computed-aided design and manufacturing (CAD/CAM) technologies. The shade is measured by a handheld optical device from a single image of the whole tooth at the click of a button. The dentist can instantly obtain a shade map of the whole tooth with various established and popular shade systems.

CYNOVAD SHADESCAN



Fixed Partial Denture (Bridge)

Components of Bridge

General factors in tooth preparation

Lecture 12

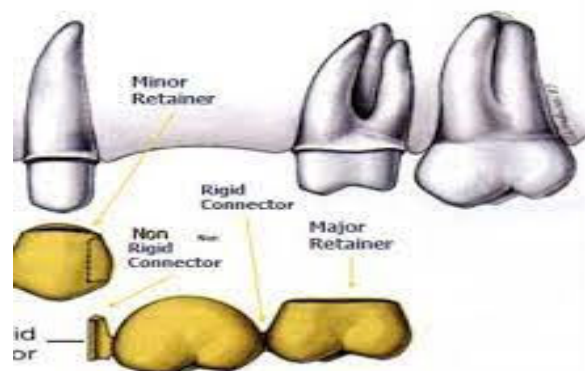
Bridge Retainer:

That component of an FPD which unites the abutment to the remainder of restoration takes support from the abutment tooth and provides stabilization & retention to the prosthesis. It takes support from the abutment tooth and provides retention to the prosthesis. It could be seat over (on or in) the abutment tooth, connecting the pontic to the abutment.

Bridge retainer could be (divided into);

1. Major retainer: Which are all these used in fixed-fixed, spring, and cantilever bridge. Fixed-mobile Bridge has one major retainer at one end of the pontic. Major retainer preparation must be retentive & with conventional bridge must cover the whole occluding surface of the tooth. (rigid connec.to pontic)

2. Minor retainer: Represent the lesser retainer of fixed-mobile bridge into which a movable connector from a pontic seated or attach. It doesn't need full occlusal coverage. (flexible connec. to pontic)



Types of retainers:

Major or Minor Retainer Designs;

1. Based on preparation design

- 1) Extra coronal retainer (complete crown, partial crown)
- 2) Intra coronal (Inlay, onlay).
- 3) Intra radicular (Post & cor).

2. Based on material used

- 1) All metal retainers.
- 2) Metal ceramic retainers.
- 3) All ceramic retainer.
- 4) Zirconium retainers.
- 5) Acrylic retainers.

All metal retainers are most conservative, the simplest, & the least expensive to produce. Most of the time they used in posterior region when the esthetic is not critical or patient does not mind about appearance. Metal ceramic, All Ceramic and Zirconium are used for replacement of anterior teeth where esthetic is critical. Acrylic retainer used with temporary bridge

Criteria for choosing suitable retainer (assessment factors):

- 1. Alignment of abutment teeth**
- 2. Retention required**
- 3. Appearance (esthetic)**
- 4. Condition of abutment teeth**
- 5. Periodontal condition**
- 6. Conservation of tooth structure**
- 7. Cost**
- 8. Caries susceptibility**

Factors affecting the amount of required retention:

1) Length of span & rigidity:

The longer the span the greater the stresses on the retainer & the more will become un cemented. Further more the casting will be more liable to flex.

2) Type of bridge:

Thus strong retainers are required fixed-fixed than fixed-mobile bridge. In deed, little retention is needed for the minor retainer of fixed-mobile bridge design. Thus when it is desirable to preserve tooth tissue, the fixed-mobile design is normally indicated as for lighter retainer can be used. For example ; replacement of upper 4 by fixed-mobile bridge using 3/4 crown or fully coverage on upper 5 as major retainer & a class III inlay on the distal of canine as the minor retainer. Such design will be:

- 1. Conservative**
- 2. Esthetic**
- 3. Incisal edge not included.**

3) Strength of the bite:

The strength of the bite determines to large extent the degree of retention required to resist it, this will vary with age, sex, & muscular development of the patient concerned. The heavier the bite the stronger & thicker the retainer material needed to prevent failure of the retainer or pontic.

4) Tooth or teeth to be replaced:

The size & position of the pontic have direct effect on the type of retainer required (stress amount). Thus the replacement of a molar cause greater stress to the abutment than lower incisor. Also forces acting on canine are more likely than that acting on an incisor.

5) Occlusal coverage:

There are several reasons for full. occlusal coverage, It is always (nearly) indicated because :

- a)** It gives abutment complete protection during mastication.
- b)** There is no fear of cusp fracture (M O D inlay, or endo. Treated teeth).

Full occlusal coverage always indicated in fixed-fixed bridge. Occlusal reduction must be sufficient to provide enough thickness for material to be rigid.

6) Habits of patient:

Various habits might induce stress on the bridge retainer such as pipe smoking, clenching; most important is grinding in (Bruxism). So if large number of patient natural teeth is severely worn, then the occluding surface of the retainers will similarly worn unless the habit can be corrected. There for retainer must be thicker & stronger than normal (very hard alloy lead to wear off does not proceed at the same level as natural teeth do).

Requirements of ideal retainer:

- 1)** Provide maximum retention.
- 2)** Give maximum esthetic.
- 3)** Preserve health and vitality of the prepared tooth.
- 4)** Need conservative preparation (less amount of traumatic reduction).
- 5)** Biologically accepted to the surrounding tissue.
- 6)** Withstand masticatory forces.
- 7)** Easily constructed.

General factors in tooth preparation

In order to obtain these ideal retainer requirements as far as related to tooth preparation, if the case permit, the design of the preparation of abutment tooth for a metal or porcelain crown restorations are limited by five principles:-

- 1. Preservation of tooth structure.**
- 2. Retention and resistance form.**
- 3. Structural durability of the restoration.**
- 4. Preservation of periodontium.**
- 5. Marginal integrity.**

Factors affecting retention and resistance of crown preparations

1) Taper of the preparation.

The more nearly parallel the opposing walls of preparation the greater will be the retention. (leaving undercut & seating problems) (5-6) degree convergence angle is mostly used to provide the needed retention.

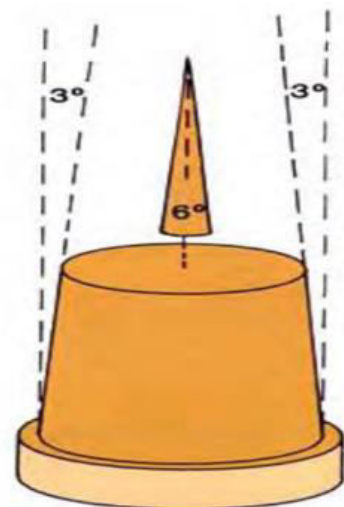
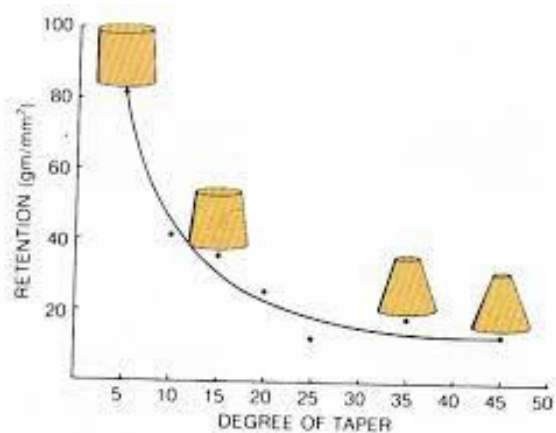
2) Surface area of the preparation,

3) Length and height of the preparation.

4) Diameter of the tooth (tooth width).

5) Texture of the preparation.

6) Accessory mean.

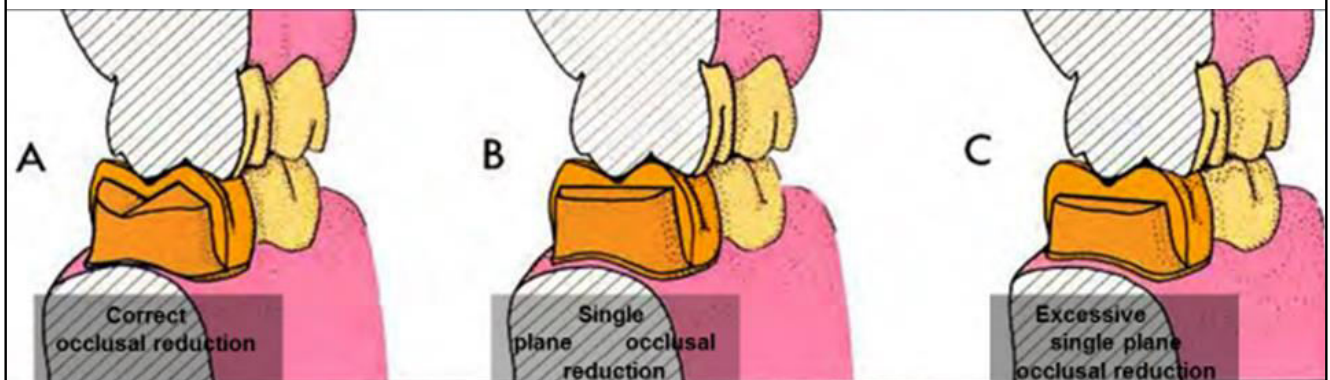


Structural Durability:

The preparation must be designed so that it provide structural durability. to the restoration i.e. the crown restoration must be rigid enough to not flex, perforate or even fracture.

For restoration to be rigid it need bulk....to provide enough bulk to the crown restoration sufficient tooth structure must be removed during preparation to create enough space.

By doing so the restoration allowed to withstand the forces of occlusion, prevent wearing in the restoration and allow proper contouring and carving of anatomy in the restoration.



Preservation of periodontal tissue;

1-Whenever possible the margin of the preparation should be supragingivally.

2-The casting should have proper contact, Embrasure form, Occlusion and a healthy occluso-gingival contour.

Margin(Finishing line) placement:

Finishing line can be placed either:

1. Supragingival:

Placing the margin above the gingival tissue for these reasons:-

- a- can easily prepared and finished.
- b- To provide good vision for the dentist during preparation.
- c- impression can be easily made.
- d- the patient can keep the area clean easily.
- e-most of the time such position is situated on hard enamel.
- f-Less destructive

The factors that influence such position of finish line are :-

- a- When the esthetic is a factor.
 - b- When we need extra retention.
 - c- When we have carries or filling at the area of finish line.
- 2. Subgingival:** Placing the margin below the gingival tissue.
- 3. Placing the margin with in the level of the gingiva.**

Marginal Integrity:-

The restoation can survive in the biological environment of the oral cavity only if the margins are closely adapted to the margine of the prep. The configuration of the F.L. determine the shape and the bulk of the rest. Margin that affect both marginal adaptation and the degree of seating of the restoration. The restoration margins should:

- a-** Fit as closely as possible against the finishing line of preparation.
- b-** They must have sufficient strength.
- c-** Whenever possible they should be placed in an area where the dentist can finish and clean them properly.

Finishing line of the preparation (f.l):

Requirement of F.L. :-

1. It must be clear ,smooth and well defined.
2. It must be continuous from one surface to the other.
3. It must lie on sound tooth structure

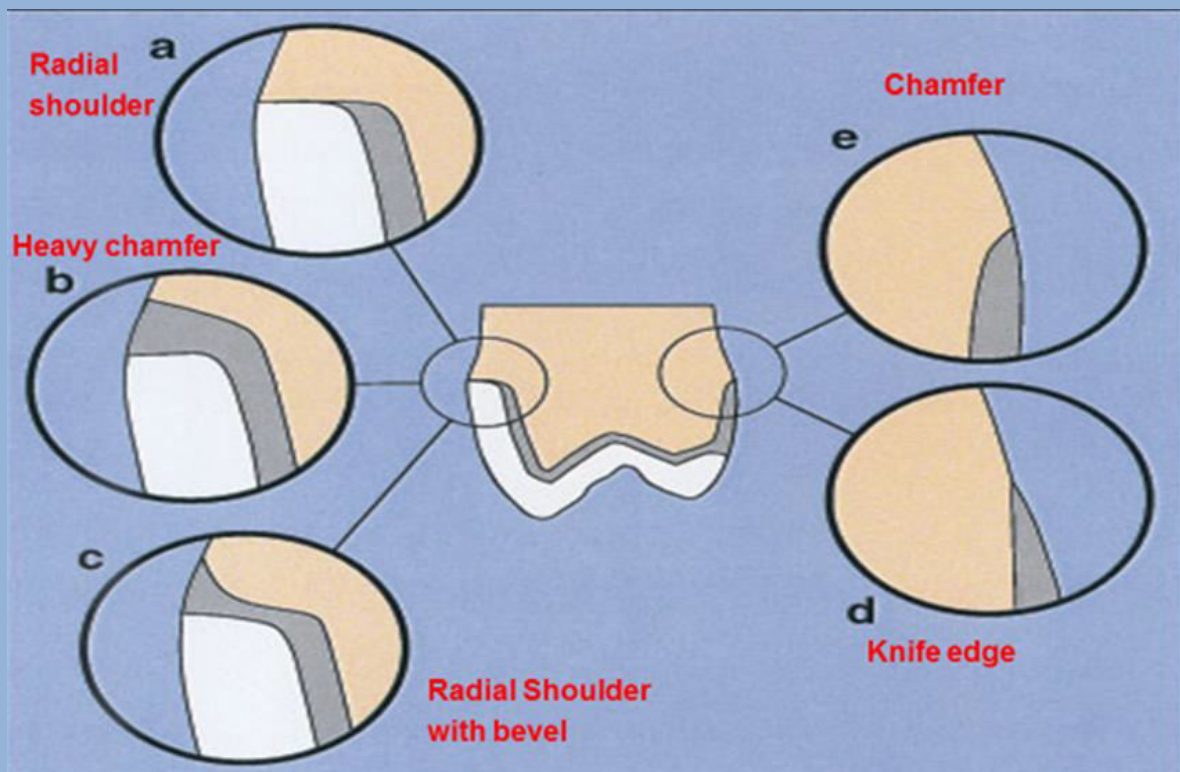
Factors affecting selection of F.L. Design;

- 1) Type of the restoration
- 2) Materials used in construction
- 3) The amount of occlusal force (stress) the restoration will bear

Types (design or configuration) of finish line:

The following designs for finish line(margin of preparation) could be used: depending on the type of the crown restoration:

1. Knife edge
2. Shoulder
3. Shoulder with bevel
4. Radial shoulder
5. Chamfer
6. Heavy chamfer



Complete Cast Crown (Full metal crown)

It is one of the most commonly used retainer for the posterior teeth. Because it made of metal, it should be used when the patient doesn't mind the appearance of metal or when esthetic not a factor. This type of retainer provides better retention and resistance because all the axial surfaces of the teeth are including in the preparation(full coverage).

Indications

- 1) It is indicated when the bridge located posteriorly .
- 2) When the patient doesn't interested with esthetic.
- 3) As a retainer on teeth receive clasp.
- 4) Need for superior retention and strength.

Contra-Indications

- 1) When the abutment teeth located in an esthetic zone.
- 2) Patient with low caries index.
- 3) Whenever a more conservative retainer is feasible

Advantages;

- 1) Provide greater retention and resistance
- 2) high resistance to deformation (Strong)
- 3) Less tooth structure is removed and easy to prepared (conservative).
- 4) Strong even in thin sections

Disadvantages

- 1) Poor esthetic.
- 2) Difficulty to test the vitality of the abutment tooth especially by electrical pulp tester
- 3) Interfere with taste
- 4) Tarnish and corrosion so it needs prophylactic measures.

Porcelain Fused to Metal

The most widely used retainer when esthetic is a factor. This type has the strength of F.M.C. and esthetic of All ceramic crown.

Indications

- 1) Use when the abutment teeth located in the appearance zone.
- 2) Excessive retention and resistance is needed.

Contra-Indications

- 1) Large pulp chamber.
- 2) More conservative retainer can be used.

Advantages;

This type has the strength of F.M.C. and esthetic of All ceramic crown.

Disadvantages

- 1) Removal of substantial tooth structure.
- 2) Subject to porcelain fracture because of brittle nature of porcelain.
- 3) Inferior esthetic compared to All Ceramic Crown.

All Ceramic Crown :

Since it made entirely from ceramic substance the most esthetically pleasing retainer. Because, there is no metal understructure to block light transmission, it can resemble natural tooth in term of color and translucency than can any other restoration.

Indications

1. High esthetic requirement.
2. Considerable proximal caries
3. Endodontically treated teeth with post & core.
5. Favorable distribution of occlusal load.

Contra-Indications

- 1) Superior strength requirement.
- 2) Thin teeth faciolingually.
- 3) Unfavorable distribution of occlusal load
- 4) Insufficient coronal tooth structure
- 5) Bruxism

Partial veneer crown (three quarter crown):

It's a cast restoration which cover 3/4 of the clinical crown (occlusal, incisal, lingual and proximal surfaces) leaving the buccal or labial surface untouched. It has less retention and resistance to displacement compared to full metal, full veneer with facing.

Indication:

- 1) Short span bridge.
- 2) On teeth with clinical crown of good (average) length and thickness labio-lingually.
- 3) Patient with good oral hygiene and low caries index.
- 4) When the abutment tooth in good axial relationship to facilitate the path of insertion.

Contra-indication:

- 1) Short clinical crown.
- 2) Poor oral hygiene, grossly caries teeth.
- 3) Long span bridge.
- 4) Poorly align abutment (poor axial relationship).
- 5) Endodontically treated teeth.

Advantages:

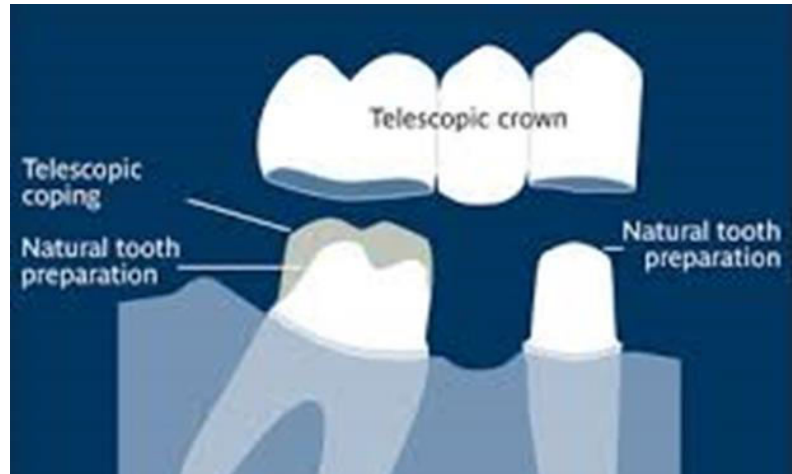
- 1) Conservation of tooth structure (Tooth structure is saved)
- 2) Better esthetic than other types..
- 3) Reduced pulpal and periodontal insult during tooth prep..
- 4) Less chance of periodontal irritation because all the margins of the crown is supragingival..
- 5) Vitality tests can be done on the exposed labial or buccal surface of the tooth..
- 6) Improved access for finishing by dentist & oral hygiene by patient

Disadvantages:

- 1) Possibility of recurrent caries along to cavosurface line angle.
- 2) Possibility of showing gold especially in the lower anterior and posterior teeth.
- 3) Difficulty in preparation compared to other types of crowns (limited adjustment can be made in the path of placement).

Telescopic retainers

- Design involves fabrication of two copings one over the other
- Internal or primary coping function to modify the morphology of tooth —path insertion changed
- Secondary or external coping designed to fit over primary
- Used when path of insertion of FPD does not coincide with long axis of abutment.



Post crown:

It is a fixed artificial restoration which replaced the coronal portion of the natural tooth completely. It retained itself by a mean of post (dowel) that extended and cemented to the root canal space of endodontically treated tooth.

The post crown will reinforce the remaining tooth structure against forces by distributing the forces to the supporting tissue.

Indication:

- 1) It commonly indicated for endodontically abutment tooth.
- 2) Abutment tooth with short clinical crown.
- 3) Re-alignment of malposed abutment. When the preparation of full metal and full veneer will cause exposure of the pulp.

The retention of the post crown depends on:

1) Taper of the root canal.

parallel sided prep. Is more retentive than tapered (divergence occlusally)

2) Post length.

Longer length more retention (2/3 length of root, Equal to length of clinical crown, 4-5 mm from apex, 8 mm deep from CEJ)

3) Post diameter.

one third the root diameter at C.E.J .and should be at least 2mm less than root diameter at mid root area)

4) Post surface texture.

For multi-rooted posterior teeth, the post should be placed in the largest canal.

For the maxillary molar use the **palatal canal** and for the mandibular molar use the **distal canal**.

For the maxillary premolar, the post should be placed in the **buccal canal**.

Factors affect the selection of a tooth for post crown retainer:

1- The root of the abutment should be of sufficient length, width and without sharp angulations in the middle third.

2- The root should be without internal or external resorption.

3- Quality of the root-filling: the canal should be filled with well-condensed gutta-percha especially in the apical 3rd of the canal.

Resin bonded retainers

- 1- Require minimal tooth preparation
- 2- Acid etched
- 3- Esthetically appealing
- 4- Economical , conservative , functional & do not irritate soft or hard tissues

Indication

- 1) As retainers of FPD for abutment with sufficient enamel to etch
- 2) Splinting of periodontally compromised teeth
- 3) Stabilizing dentition after orthodontic treatment.

Contraindication

- 1) When facial esthetic of abutment require improvement
- 2) Inadequate enamel surface to bond eg; caries, existing restoration, attrition
- 4) Incisor with extremely thin facio-lingual dimension

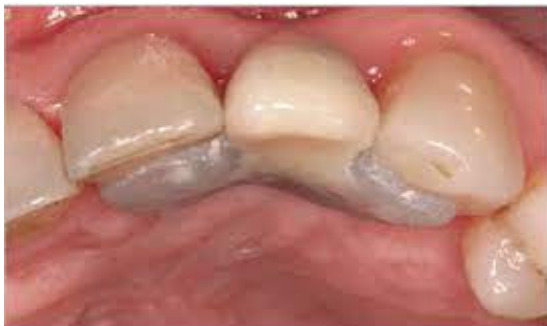
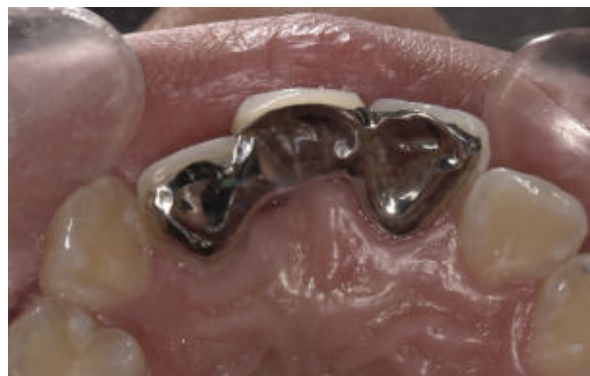
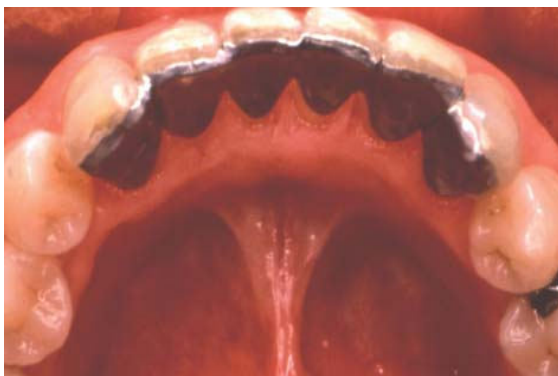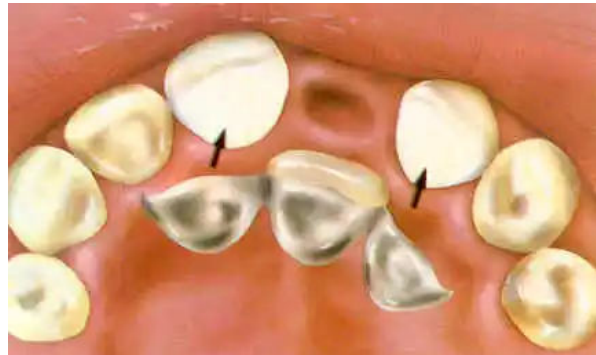Fig 3 Removable wax-up during intraoral try-in.

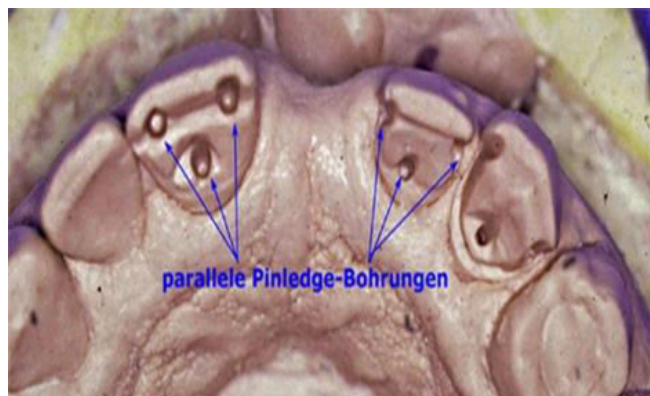


Pinledge

A partial veneer retainer preparation incorporating pins holes to provide retention.

Indications

- 1) High esthetic requirement
- 2) Undamaged anterior teeth
- 3) When proximal grooves are impossible to prepare
- 4) To alter lingual contour of maxillary anterior teeth



INLAY

A fixed intracoronal restoration; a dental restoration made outside of a tooth to correspond to the form of the prepared cavity, which is then luted into the tooth. Inlay may be used as

1- a single tooth restorations for proximo-occlusal or gingival lesions with minimal to moderate extensions.

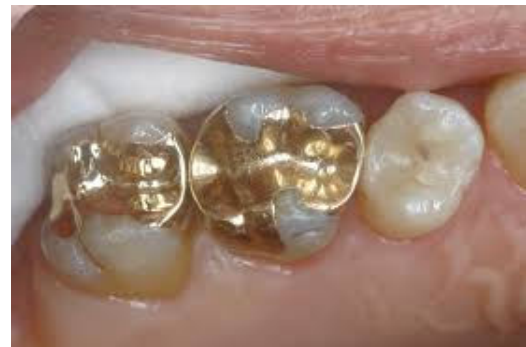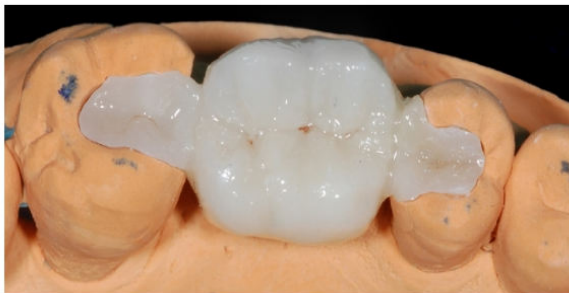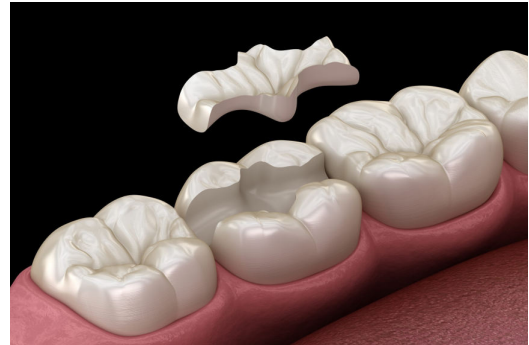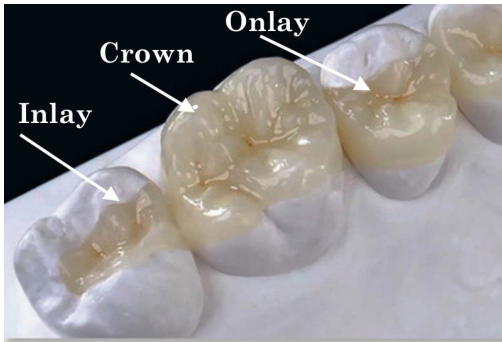2- Minor retainer for fixed partial denture

They may be made up of gold alloy or ceramic material.

Contraindications

- 1) high caries index
- 2) Poor plaque control
- 3) MODs
- 4) Poor dentinal support require wide preparation

Inlay



ONLAY

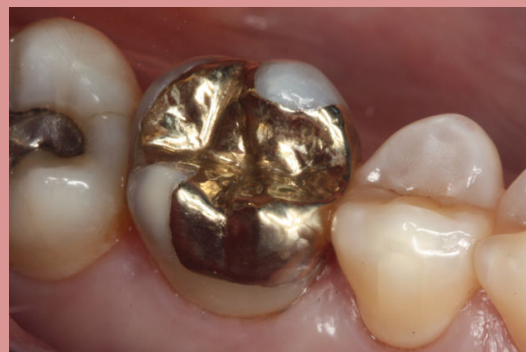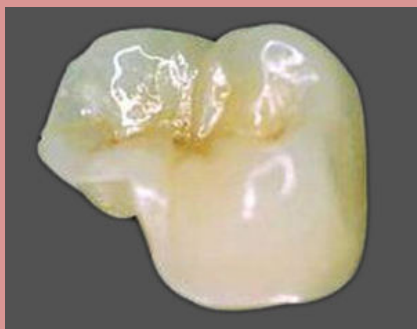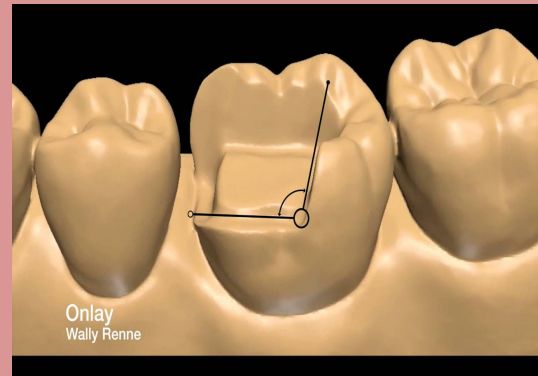
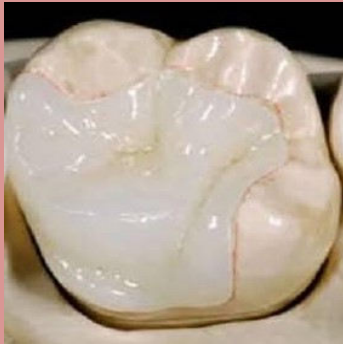
A restoration that restores one or more cusps and adjoining occlusal surfaces or the entire occlusal surface and is retained by mechanical or adhesive means. It is used for restoring more extensively damaged posterior teeth needing wide mesio-occluso-distal restorations.

It can be used as a retainer for fixed partial denture

Contraindications

- 1) High caries risk
- 2) poor plaque control
- 3) Short clinical crown/extruded tooth
- 4) Bruxism

ONLAY



Components Of Fixed Partial Denture (Bridge) Pontics

Lecture 13

pontic

It is the suspended portion of the fixed partial denture (bridge) replacing the lost natural tooth or teeth , restoring its function, and usually occupying the space of missing natural tooth.

☐ The pontic is connect to the bridge retainer , which is attached to the reaming natural teeth , this union of pontic and retainer may be accomplished by mean of **rigid connection** such as solder joint or by mean of **non rigid, flexible connection** such as key and key way in the stress breaker type of bridge construction.

Components of the pontic (PFM):

1-Metal backing.

2-Solder joint

3-Facing.

Materials used in pontic fabrication

The pontic may be made entirely of **cast metal** or **porcelain** or **Zirconium**. A **combination** of metal backing and porcelain or acrylic facing can be used also. Usually full **metal pontic** is used for the **posterior region** while the **combination** of metal and facing is used in **anterior region**.

Functions of the pontic

1) Mastication The pontic provides hard surfaces against which food can be chewed by teeth in the opposing arch

2) Speech (phonetics) A space created by the loss of tooth alters the pattern of airflow making normal speech difficult. pontic helps to restrict air passage through edentulous area to aid in the reestablishment of normal sounds

3) Esthetics (appearance) Pontics , fill in the empty spaces that would be observed during talking and smiling, provide support for lips and cheeks to allow normal facial form.(well -aligned teeth and a pleasing smile afford a positive social status!)

4) Maintenance of tooth relationship Pontics maintain the integrity of dental arches by preventing teeth that are adjacent to and opposing an edentulous area from moving out of their relationship. when missing teeth are not replaced, the teeth posterior to edentulous areas can move forward from their normal position , its also possible for teeth anterior and to opposing edentulous spaces to drift distally and occlusally into open area.

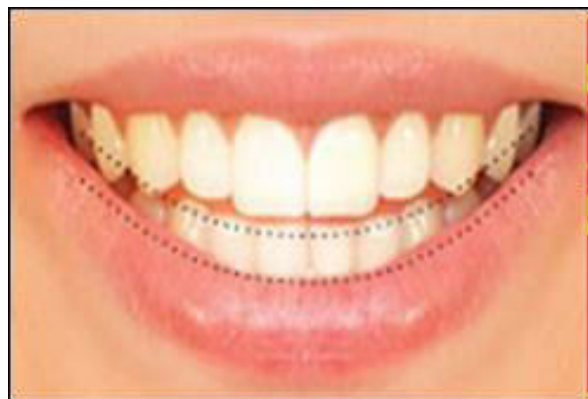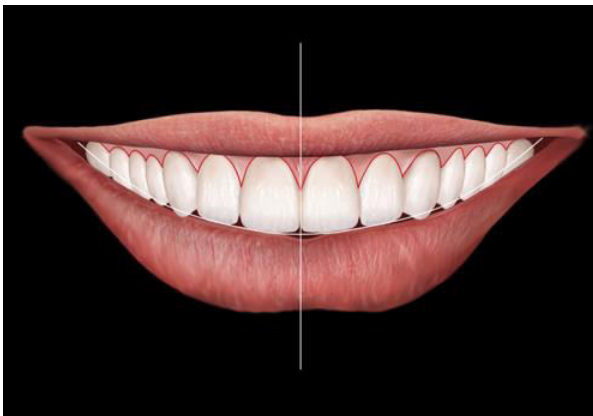Ideal Pontic Requirements

Esthetic requirements

1. The pontic should meet the demand of esthetic and comfort the deciding factor for esthetic value is smile line (The smile line is an imaginary line running from the incisal edges of the maxillary incisors and coinciding with the curvature of the lower lip). it locate the appearance zone of the facial aspect of the teeth, this quite true for the upper teeth ,however for the lower teeth , most of the time only the higher portion of the facial aspect as well as the occlusal surface lie in the appearance zone.

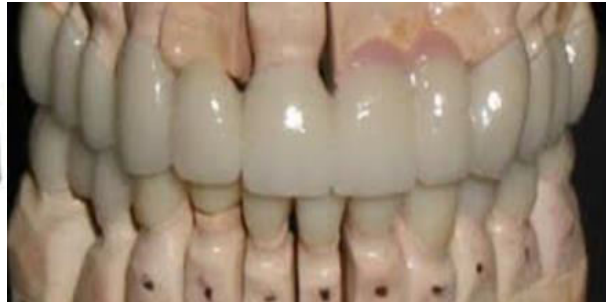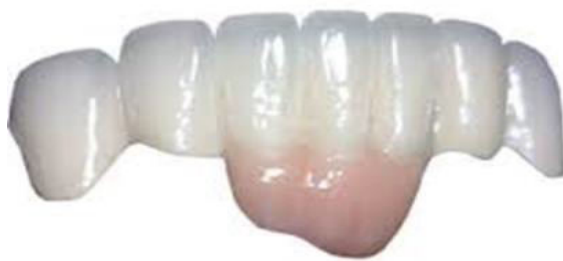The matter of concern here is the form of the facial aspect of pontic as related to appearance so to fulfill esthetic requirement pontic must;

- Looks like the tooth it replaces
- Tissue contacts appear as normal tooth.
- Lower lip line helps to evaluate buccolingual position of the incisal edge and the curvature of the incisal plan



In excessive bone loss it is possible to construct pontic with a length coincide with clinical requirement for that patient but for esthetic reason you can add pink porcelain to the apical portion of pontic to simulate gingival tissue

- Root can be stained to simulate exposed dentine.
- Pink porcelain can used to simulate the gingival tissues



Biologic Requirements

1. The pontic must be hygienic; permit maintenance of high standard of oral hygiene by the patient through providing good access for cleaning pontic underlying soft tissue, furthermore, pontic should prevent soft and hard tissue irritation. Pontic design should allow the patient to use devices such as brushes ,super floss and dental floss without difficulties.

2. The tissue surface of the pontic should design so that it should not cause any problem to the underlying soft tissue (ulceration and inflammation) by pressure, a pressure free contact is indicate (passive contact, thickness of a film of saliva is sufficient when esthetic demand pontic facial surface to be lies within appearance zone)

3. The tissue surface of the pontic should be constructed smooth and not cause any food stagnation and plague accumulation and made from ceramic Glazed porcelain and highly polished metal (gold) are the preferred materials for tissue contact The glazed porcelain is the preferable material that should be used on those portion of pontic which approximate the edentulous ridge.

Because their porous nature and difficulty in obtaining a highly polished surface , resins should not be used as near the soft tissue

Mechanical Requirements:

1. The pontic must be strong enough to withstand the force to which it is subjected without deformation (Rigid & resistant to deformation). Part of pontic that subject to force usually made of metal or supported by it. All metal pontic may be needed in situation of high stress rather than metal ceramic pontic which is more susceptible to fracture. Mechanical problems may be due to:

- Improper choice of material.
- Poor framework design.
- Weak connectors
- Poor occlusion
- Poor tooth preparation

2. It should restore the function of teeth it replaced i.e. masticatory function efficiency must be restored to the proper limit

3. Sometime it is desirable to reduce the occlusal surface width by 20% to reduce torque on retainers and abutments and simplify the cleaning with minimal soft tissue contact, however, width of the pontic required will be governed by esthetic, span length, abutment teeth strength, ridge form and occlusion

Summary of pontic Requirements

Esthetic

- 1- Looks like the tooth it replaces
- 2- Tissue contacts appear as normal tooth

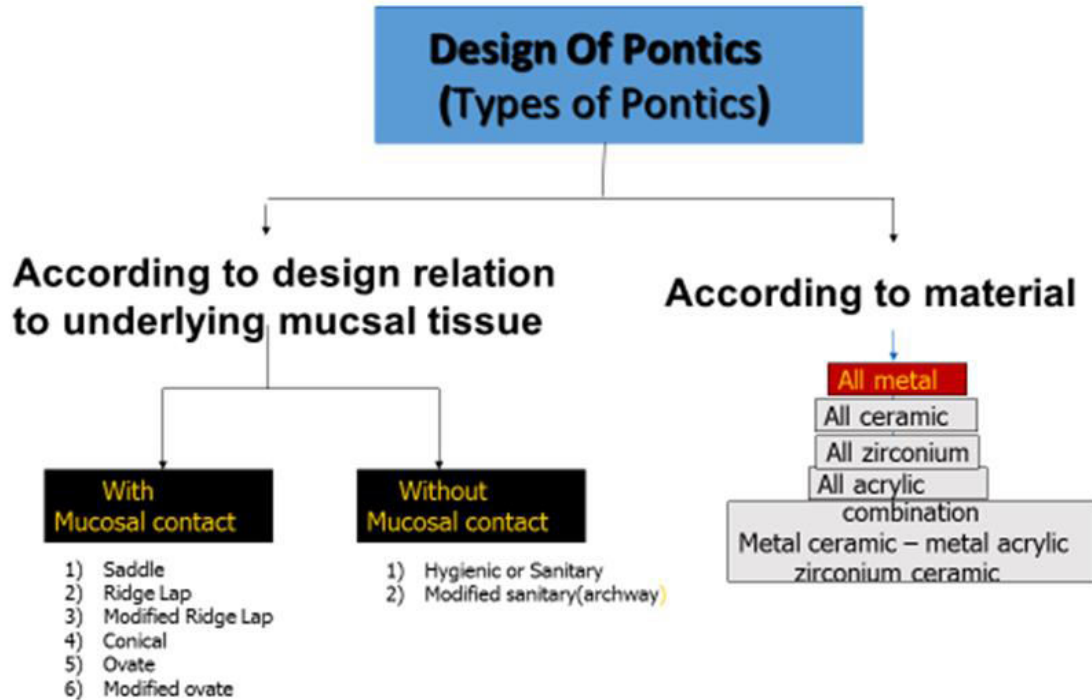
Biologic

- 1- Can maintain healthy tissues
- 2- Cleansable

Mechanical

- 1- Strong enough to withstand functional forces
- 2- Rigid & resistant to deformation
- 3- Provides normal function

Designs (Types) Of Pontic:




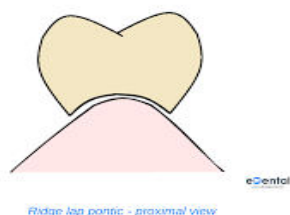
(A) Pontics with mucosal contact:

1. Saddle Pontic (full ridge lap)

- Overlaps the ridge (largest area of contact)
- Most natural feeling
- Most difficult to clean (concave tissue surface overlying residual ridge BL)
- Should never be used


Used for

- Limited occlusal-gingival space
- Patients who object to lingual space





2. Ridge Lap Pontic

- Like saddle on buccal
- Convex on the lingual
- More cleansable than saddle design
- Potential for tissue irritation minimized
- Give the illusion of being tooth
- Combines best features of saddle & hygienic pontics
- Used when the tooth lie in the appearance zone (max & man.)



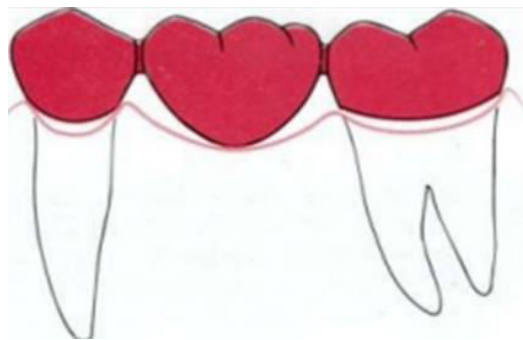
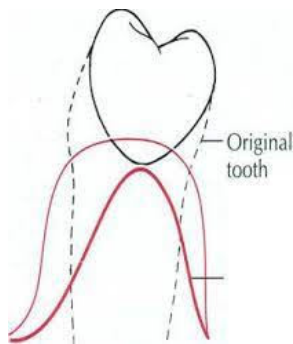
3. Modified Ridge Lap Pontic

- Contacts tissue only on most facial surface of the pontic
- Most cleansable
- Least tissue irritation
- Space between pontic and tissue on lingual can be unacceptable to the patient
- Used when the tooth lie in the appearance zone (max & man.)



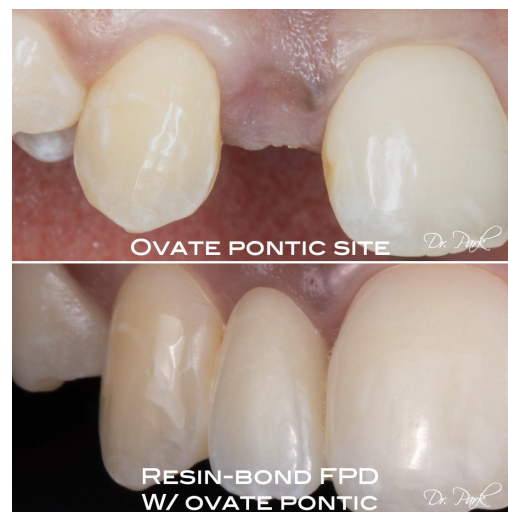
4. Conical Pontic (bullet, spheroid)

- egg shaped or spheroid shape.
- used as pontic in non esthetic areas.
- convex shape with only one point touches the residual ridge.
- The most easiest design to clean.
- Used when occlusal 2/3 of the facial surface lie in the appearance zone but not gingival 1/3 (lower incisors, premolars and molars).
- if used with broad ,flat ridge, this lead to debris trapping embrasure space.



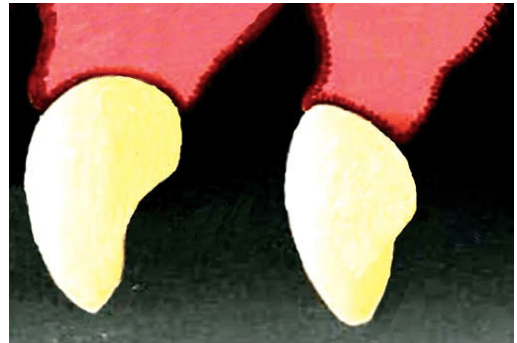5. Ovate Pontic

- Placed in convexity on edentulous ridge
- Appears to be growing out of tissue
- Natural feeling for patient
- Difficulty in cleaning
- Potential for tissue irritation
- Used for Maxillary incisor and premolars
- Requires surgical preparation



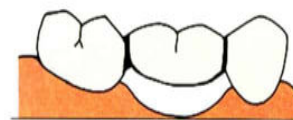
6. Modified Ovate Pontic

- The modification of the ovate pontic involves moving the height of contour at the tissue surface from the center of the base to a more labial position 1-1.5mm apical and palatal to gingival margin
- The modified ovate pontic does not require as much faciolingual thickness to create an emergence profile.
- Excellent esthetics.
- Fullfilled functional requirements
- Greater ease of cleaning compared with the ovate pontic owing to the less convex design
- Its major advantage over the ovate type is that often there is little or no need for surgical augmentation of the ridge.



7. Hygienic Pontic (sanitary, wash through)

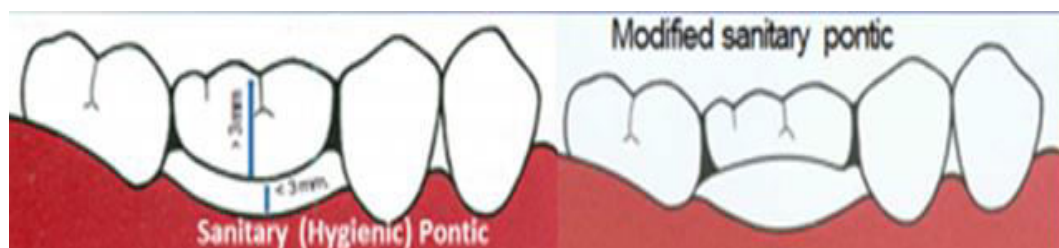
- Made entirely from metal
- Doesn't have any contact with underlying tissue
- Primary design for the non appearance zone in mandibular posterior regions
- Most cleansable
- Convex shaped
- No tissue contact
- 3 mm space
- 3 mm thickness
- Patient acceptance ? questionable



Sanitary or hygiene Pontic

8. Modified Hygienic Pontic (Archway pontic)

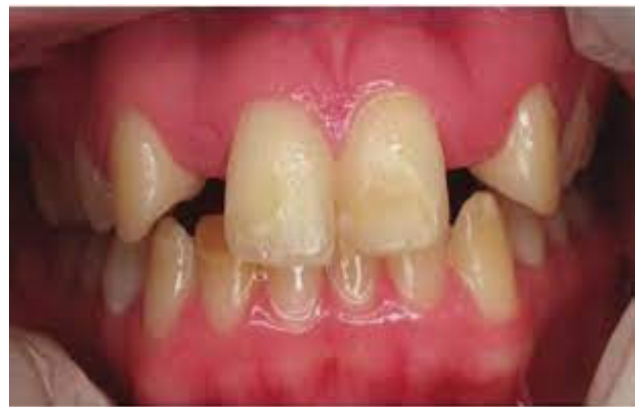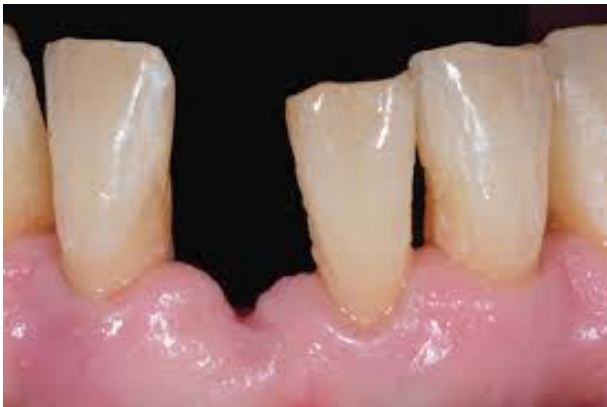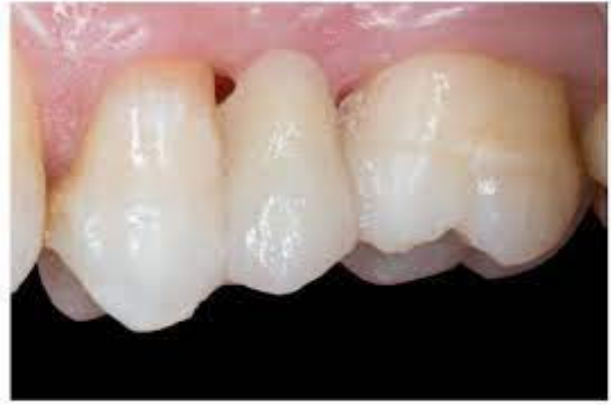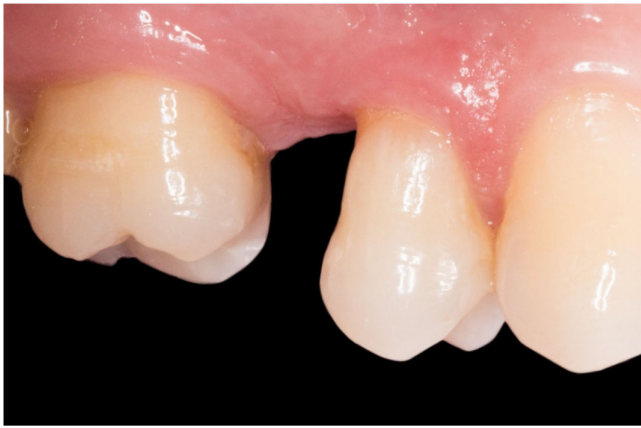- A modified version of the sanitary pontic.
- Its gingival portion is shaped like an archway between the retainers
- This geometry adds bulk for strength in the connectors while decreasing the stress concentrated in the pontic and connectors
- Made entirely from metal
- Doesn't have any contact with underlying tissue
- Primary design for the non appearance zone in mandibular posterior regions
- Access for cleaning is good, also, tissue susceptible to proliferation that can occur when the pontic is too close to the residual ridge
- No tissue contact
- Patient acceptance?



Pretreatment assessment of Pontic area

1) Available pontic space

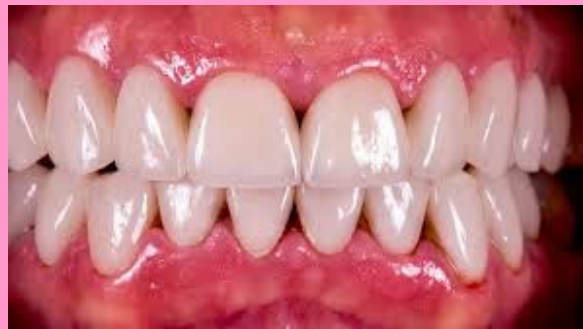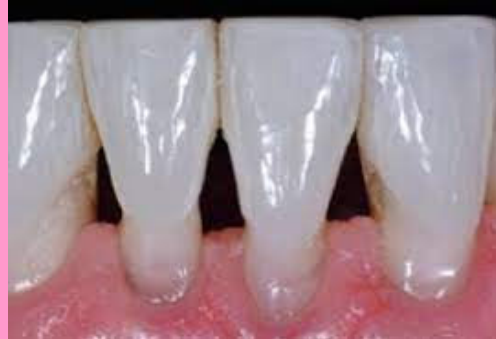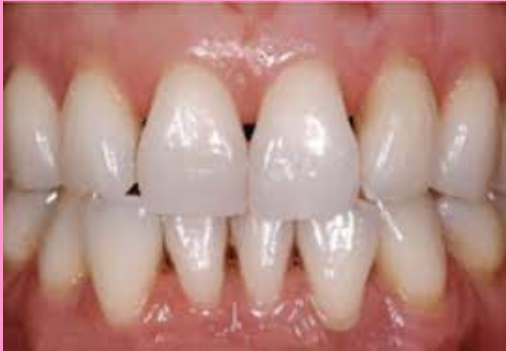- One function of the fpd is to prevent tilting or drifting of the adjacent teeth into the edentulous space.
- If such movement has already occurred, the space available for the pontic may be reduced and its fabrication complicated.
- Space discrepancy (reduce pontic space) less problem in posteriors,, Overly small pontics are undesirable because they trap food and are difficult to clean, furthermore, in anterior its unacceptable essthetically
- Orthodontic repositioning, modification of abutments with complete coverage retainers can be made rather than doing bridge



2) Residual ridge contour

- An ideally shaped ridge has smooth, regular surface of attached gingiva, which facilitates maintenance of a plaque-free environment..
- Should have sufficient height to allow placement of pontic such that it appears to emerge out from the ridge (mimics appearance of neighbouring teeth).
- Loss of residual ridge contour may lead to unesthetic open gingival embrasures (black triangles). This leads to food accumulation and saliva percolation(food entrapment)

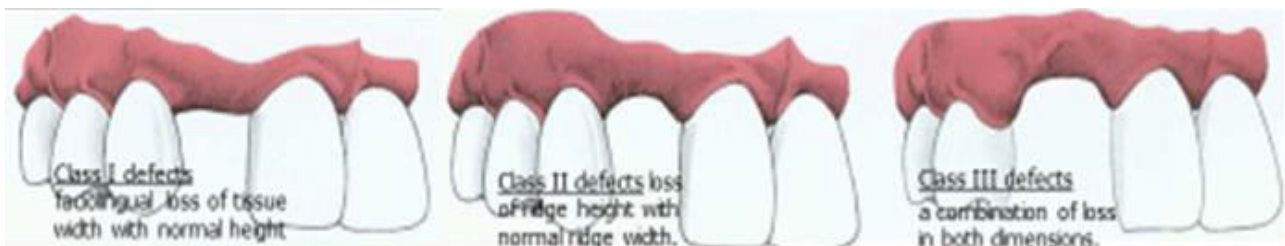Black triangle



Classification of residual ridge deformities

Siebert has classified residual ridge deformities into:

- 1-Class I defects faciolingual loss of tissue width with normal height.
- 2-Class II defects loss of ridge height with normal ridge width.
- 3- Class III defects a combination of loss in both dimensions.



Residual ridge Preservation

Residual ridge Preservation can be achieved using the following techniques:

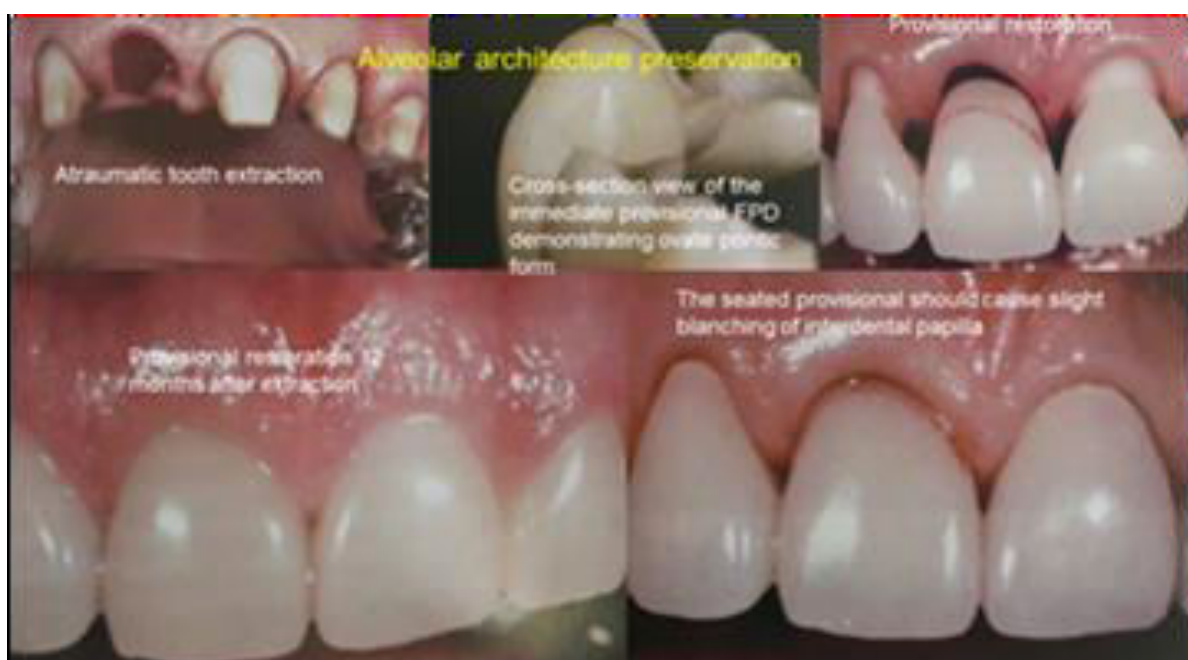1) Alveolar architecture preservation technique

Preservation of the alveolar process can be achieved through immediate restorative and periodontal intervention at the time of tooth removal.

The procedure involve preparing the abutment teeth prior to extraction and provisional FPD can be fabricated indirectly, to be ready for immediate insertion. The tissue-side of the pontic should be an ovate form. *After preparation of the extraction site, a carefully shaped provisional FPD is placed and seat it on the abutments.*

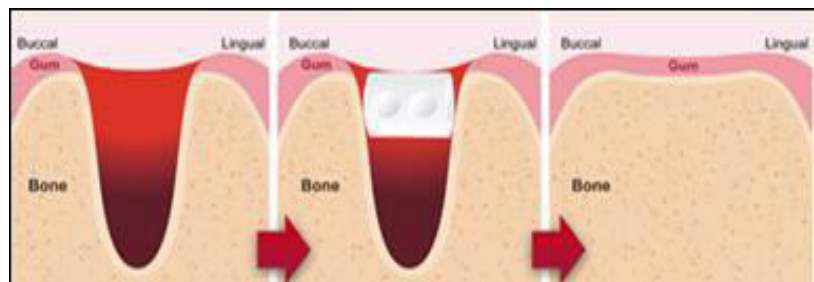
The bridge should extend approximately 2.5 mm apical to the facial free gingival margin of the extraction socket.

The contour of the ovate tissue- side of the pontic is critical and must conform to within 1 mm of the interproximal and facial bone contour to act as a template for healing.



2) Conditioning the extraction site (Alvelac pack)

Also Preservation of the alveolar process can be achieved by conditioning the extraction site and providing a matrix for healing, the pre-extraction gingival architecture (or "socket") can be preserved. **Alvelac can be used at** the time of tooth removal, it is a porous, osteoconductive, biocompatible and biodegradable synthetic scaffold that is synthesized from polylactic co glycolic acid (PLGA) and polyvinyl alcohol.



Alvelac

- It is a rigid structure specifically designed to prevent collapse of the buccal and lingual walls in achieving width maintenance.
- It is designed to maintain socket height and width, which will allow for natural bone healing. In addition, it will be resorbed in approximately two to six months
- It is strategically placed in extraction socket with the top of scaffold in line with the crest of the socket in order to raise the forming blood clot to that level thus achieving height maintenance.
- The size of Alvelac™ does not occupy the whole socket thus allowing maximum space for blood to fill the socket. This allows for the patient's own bone to form naturally within that space
- Within a short period of time, patient's own bone will form fully in the socket, achieving the speed of alveolar ridge preservation required

For pre existing residual ridge, it might need Ridge Modifications that involve:

1) Ridge Reduction, Indications:

A- Excessive or irregular soft tissue

- Recent extraction
- Ill fitting prosthesis
- Other irritations

B- In adequate space for pontic

C- Poor cleansable area

2) Ridge Augmentation

A- Indicated to treat a Defect in pontic space

- Bone resorption after extraction
- Require long, unaesthetic pontic

B- Periodontal surgery using fibrous, osseous or synthetic materials to augment space

Failure in crown & bridge

Lecture 14

Failure in crowns and bridges should be regarded as a disadvantages and balanced against advantage, some bridges are failure from the day they inserted while others last over decades.

Manifestations of failure

Failure might manifested itself in one or more of following patient complaint;

- Pain
- Inability to function
- Dissatisfaction with esthetics
- Broken teeth and/or restoration
- Inflammatory swelling
- Bad taste
- Bad breath
- Bleeding gums
- Anxiety

Patient complaint might be Immediate or Delayed

Causes of fixed prosthesis failure

- 1- Improper case selection
- 2- Faulty diagnosis and treatment plan
- 3- Inaccurate clinical or laboratory procedures
- 4- Poor patient care and maintenance following insertion

For purpose of discussion the reasons for failure of fixed prosthesis may be divided into biological and mechanical problems, while mechanical in general, are more directly under the control and influences of clinician the biological problems are not easily controlled and in some instances may be unrelated to the prosthesis, however it is true and many time that, the biological problems may be a consequence of the treatment procedure (pulpal) or of the restoration itself (periodontal or caries).

A) Biological problem

1. Caries;

It is the most common cause of failure of fixed restorations, its detection very difficult whether clinically or radiographically practically when complete coverage is used

Causes;

- a) Open and over or under extended margin (short or long margin); her fluid seepage could occur lead to dissolution of cement that give an area for food debris impaction this defiantly result in caries.
- b) Lose of retention as result of marginal seepage.
- c) High risk patient (high caries index) because of poor oral hygiene.
- d) Reduce salivary flow.
- e) Perforation of restoration (structural durability)

2. Pulpal injury (problem)

Pulpal problem is not uncommon complication in bridge work.it might be the outcome of microbial, chemical, mechanical and thermal irritation. It should be always expected and most often associate with small teeth, in favor of structural duality and periodontal health a massive reduction is necessary so good evaluation is important.

Teeth with questionable pulp go and do root canal treatment, anyhow, pulpal pain and discomfort should expected to last sometime to sex months. To verified pulpal pain, vitality test should done thermal, electrical, or adiographical to see periapical whether infected or not

Causes of pulpal problem

***I.* Overheating and heat generation**

a) Lack of coolant.

b) Very high speed

c) Insufficient bur

d) direct temporary crown

***II.* Improper or absence of temporary protection**

***III.* Irritating cementing agent**

***IV.* Over reduction ,insufficient tooth structure to protect pulp or microscopic pulpal exposure**

***V.* Recurrent caries under full crown, microbial irritation.**

***VI.* Traumatic occlusion.**

3. Periodontal and soft tissue problems

Periodontal breakdown may lead to loss of abutment. **Patient suffer from;**

- 1- Mobility of abutment
- 2- Periodontal pocket formation
- 3- Periodontal abscess
- 4- Pain which prevent mastication at the side of restoration
- 5- Bad odour and taste

The most common cause for periodontal problems are

- 1- Over contouring of crown.
- 2- Insufficient interproximal clearance, reduction or overcontour
- 3- Deficient interproximal contact
- 4- Increased cervico occlusal length of connector
- 5- Improper tissue pontic relation (saddle design)
- 6- Overextended subgingival positioning of finish line
- 7- Irregular or rough edges of crown might cause irritation to the gingival tissue
- 8- Failure of contact (food impaction)
- 9- Ill-fitting crown might cause irritation to gingival tissue
- 10- Presence of foreign body irritating soft tissue
- 11- Improper pontic design (continuous food accumulation and soft tissue pressure)
- 12- Improper connector design

B) Mechanical problems

1. Looseness of crown or bridge (Cementation Failure), most common cause is

a) Poor retention because of inadequate preparation or faulty preparation (convergence angle, length, surface areaetc.)

b) Faulty cementation

The causes of inadequate cementation might be

1- Poor mixing of cement. 2- Failure to have a dry field.

3- Poor seating 4- Type of cement

c) Faulty restoration

1- Open or overhang margin 2- Wear or perforation

3- Deformation of restoration (structural durability)

d) Premature contact (torque)

e) Caries

f) Poor retainer design select on such as ceramic crown in state of fused metal restoration.

II. Mechanical failure of crowns and bridges

a. Porcelain fracture

1. Ceramic crown.....

- Faulty laboratory technique such as improper condensation , air bubbles, inadequate firing, ,faulty protocol for cad cam crown

- Faulty preparation

2. Porcelain fused to metal

- Faulty technique.....poor coping design

- Metal framework flexing

b. Distortion or fracture

c. Faulty structural durability of restoration

d. Occlusal wear or perforation

e. Failure of solder joint

III. Restoration Failure

a-Retainer failure;

- 1- Perforation
- 2- Marginal discrepancy
- 3- Veneering separation, fracture or wearing

b- Pontic failure;

- 1- Pontic fracture (Porcelain) with unfavorable occlusal load
- 2- Limited occluso cervical height due to over eruption

C. Connector failure;

- 1- Improper designing of connector size and position
- 2- Thin metal at the connector
- 3- Incorrect selection of solder
- 4- Porosity

IV. Marginal deficiencies of restoration

The cause might be due to:

- 1)** Poor preparation (ill define finish line)
- 2)** Impression with ill define margin (not clear) of preparation
- 3)** Technical faults
- 4)** Cementation errors

V. Fracture of abutment tooth

Over reduction and tooth health state might be the cause

VI. Design failure

- a)** Selection of inadequate bridge design
- b)** Inadequate abutment preparation design

VII. Failure related to esthetic

One of the objective in replacing missing tooth is esthetic, definitely failure of this objective lead to failure of bridge. Shape, size , position and shade of restoration collectively play important role in esthetic value so factors that might cause faulty esthetic are;

- a)** Improper shade selection
- b)** Poor harmony between restoration and natural teeth (improper contour might be the fault of dentist or lab technician)
- c)** Failure to mask metal color
- d)** Un necessary metal display
- e)** Irregular and rough surface which may cause discoloration

VIII. Discomfort of the patient

- a)** Soft tissue irritation by pressure which might be from improper pontic design or food staff accumulation
- b)** Deficient interproximal contact that cause food impaction
- c)** Traumatic occlusion
 - 1- Faulty construction such as occlusal surface with high marginal ridge or deep incline plan
 - 2- Faulty diagnosis and treatment plan such as
 - 3- Use of teeth that lack of alveolar support
 - 4- Overloading of abutment
 - 5- Premature contact

d) Retention of food on occlusal surface (poor design)

e) Poor contouring of the retainer and pontic

1- Overcontour.....overprotection and under stimulation

2- Under contour.....over stimulation and under protection....gingival tissue trauma

f) Sensitive cervical margin to hot or cold application

1- Long margin that might cause gingival recession

2- Over displacement of gingiva

3- Temporary restoration with long margin cemented for long period of time

4- Retainer with short or open margin

g) Seating failure

1- Too thick cement

2- Insufficient pressure during cementation

Maintenance Failure

1- Poor oral hygiene and improper maintenance of a well done restoration may lead to failure of prosthesis.

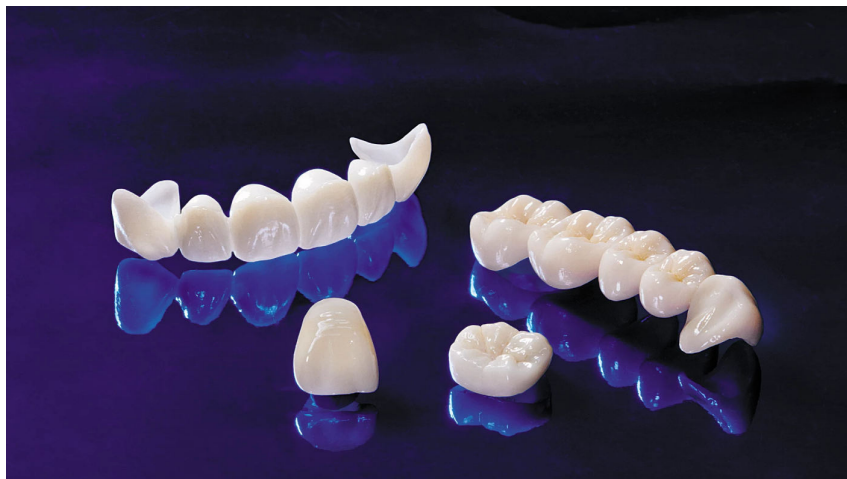2- The patient must be fully informed about his responsibility in success or failure of restoration

3- The dentist must recall the patient for periodic clinical and radiographic examination to detect early any harmful changes that might occur.

Dental Ceramic

Lecture 15

Ceramic is derived from GREEK word “KERAMI KOS” meaning Burnt earth. Generally the word ceramic is used to name any material having both metallic and non-metallic ions (usually silicon, boron, oxygen) in its compositional formula which are obtained by the action of heat and whose final structure is partially or completely crystalline example. Cements, gypsum, porcelain and glasses.



Dental porcelain are the material from which the most esthetic restoration are made, it is compatible with the soft tissue.

Most dental porcelains are glasses and are used in fabrication of teeth for dentures, pontics & facings, crowns, inlays, onlays and other restorations.

Dental porcelain is superior over polymers and reinforced polymers regarding tooth shade reproduction, translucency, biological compatibility, chemical stability and abrasion resistance.

Porcelain is very hard material but it is extremely brittle, can fracture easily.

In order to overcome this disadvantage, porcelain fused to metal restoration is used to combine the strength and the accuracy of cast metal with the esthetic of porcelain.

P.F.M. composed of a metal casting (copping) that fit over the tooth and porcelain fuse on to that coping.

This combination is stronger than porcelain alone. However, metal substrate can affect aesthetic by decreasing light transmission comparing to all ceramic crown, expose metal rim, and periodontal health.

That's why, researches continue trying to develop new ceramic system (combine strength and esthetic) that can use without metal substructure. Development follow 2 paths:

1) Developing of ceramic that combine esthetic with high strength

A- Extrinsic

Involve using one of following techniques

1) Ion exchange 2) Thermal tempering. 3) Thermal compatibility

B- Intrinsic

Involve adding Toughening particles Al_2O_3 , MgO Crystals particles (zirconia)

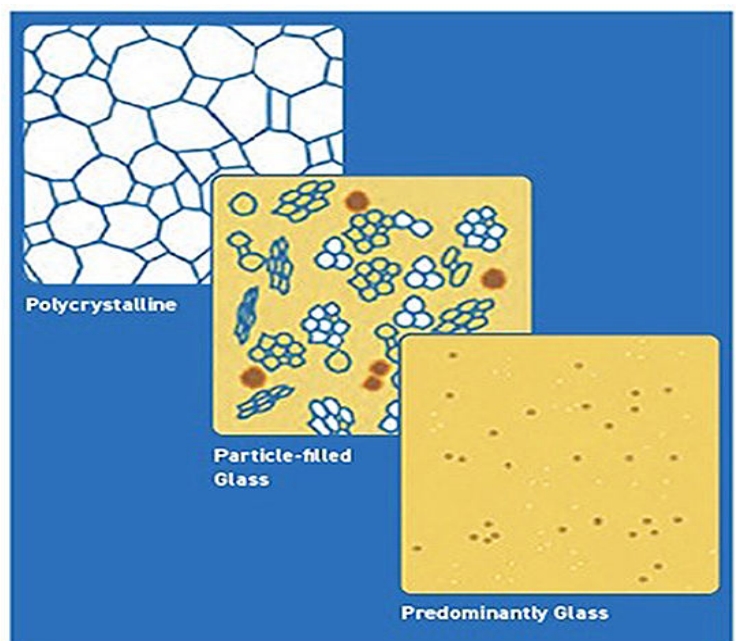
2) High strength but not esthetic core, veneered with low strength esthetic ceramic.

Alumina have been added (40% Hi-Ceram) (In-Ceram 85%) to porcelain to increase it strengths enable it using alone (without metal substructure), also MgO Crystals and zirconium oxide have been added to porcelain to increase it strengths, enable it using alone as in all ceramic crowns ,bridges, inlays and onlays.

TYPES OF DENTAL CERAMICS

Kelly and Benetti, classify ceramic according to their glass content into three main divisions:

- 1) Predominantly glassy materials,**
- 2) Particle filled glasses---- Glass ceramics**
- 3) Polycrystalline ceramics.**




1) Predominantly glassy materials

- Best mimic the optical properties of enamel and dentine:


Glassy material

- Glasses: 3D network of atoms having no regular pattern to the spacing between nearest atoms, thus they are amorphous or without form.
- Derived principally from a group of minerals called FELDSPAR: based on silica and alumina: Aluminosilicate glasses.
- Resistant to crystallization during firing, long firing ranges, biocompatible.





2) Particle filled glasses---- Glass ceramics

- Filler particles are added to the base glass composition to improve mechanical properties and to control optical effects like Opalescence, Color, and opacity.
- This filler was added to create porcelains that could be successfully fired on metal substructure.
- Adding 17-25% Leucite filler (feldspar forms crystalline mineral Leucite, potassium-aluminum-silicate mineral with large coefficient of thermal expansion, when mixed with metal oxides & fired to high temperature) to base glass creates porcelains that are thermally compatible with dental alloys.
- Moderate strength increases can also be achieved with appropriate fillers added and uniformly dispersed: "Dispersion Strengthening"

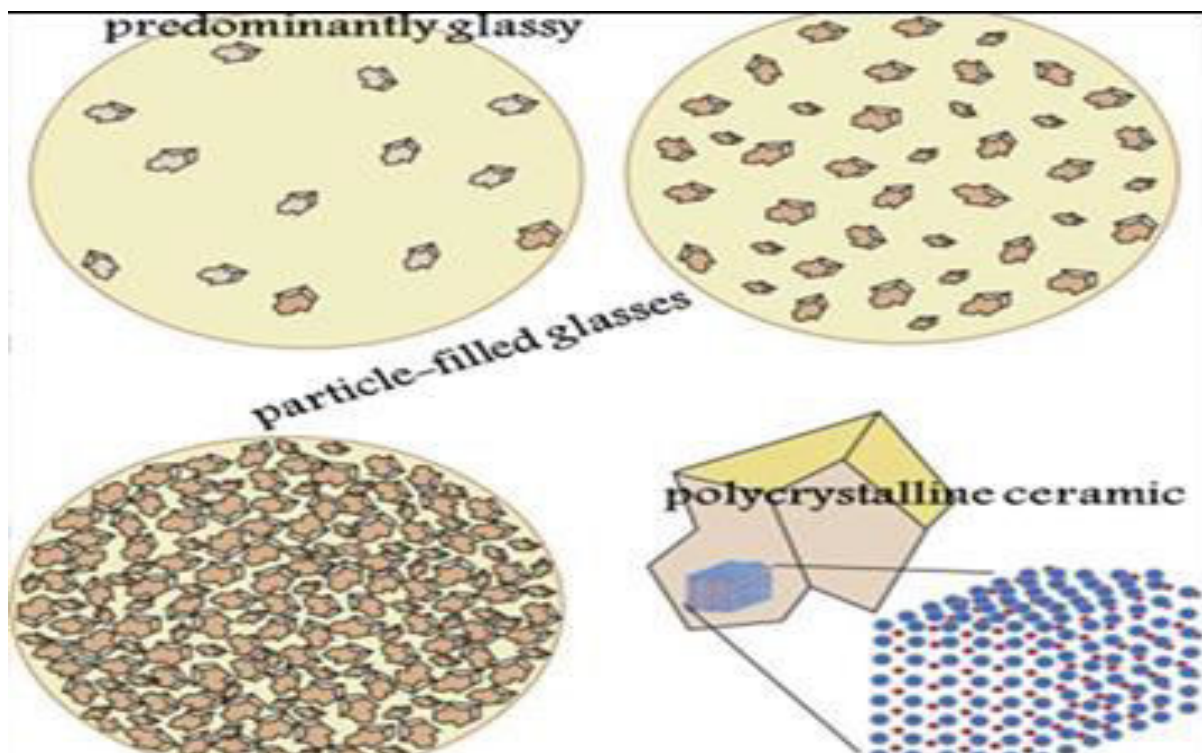


3) Polycrystalline ceramics

- No glassy components, atoms are densely packed, regular network: Crack propagation difficult.
- Tougher and stronger than glassy ceramics.
- Difficult to process, CAD-CAM.
- Relatively opaque, core substructure.
- E.g. Aluminum oxide, partially stabilized Zirconia.
- Procera, Cercon, Lava.



DENTAL CERAMICS



Since the existing classification systems does not include resin-matrix materials that are highly filled with ceramics, these are now available from various manufacturers and are recommended as esthetic alternative for a variety of clinical indications. In the light of this considerations a new classification system of ceramics include:

1. Glass-matrix ceramics: nonmetallic inorganic ceramic materials that contain glass phase.
2. Polycrystalline ceramics: nonmetallic inorganic that do not contain any glass phase.
3. Resin-matrix ceramics: polymer-matrices contain predominantly inorganic refractory compounds like porcelains, glass, ceramics and glass-ceramics.

Composition (traditional porcelain)

1) Kaolin 11—12%

- It is a white clay like material (hydrated aluminum silicate).
- Increases the ability of the porcelain mold before baking
- Facilitates mixing with water while maintaining the form during drying and firing.
- Make the material workable Reacts with the feldspar and gives rigidity
- Being sticky in nature , bind the particles
- Material can be carved
- Give opacity to the fired porcelain

2) Feld Spar 70 – 90% (Alkaline aluminum potassium silicate)

- It constitutes the bulk of dental porcelain
- Translucent glossy matrix
- Bind small particles of Kaolin and Quartz together
- Alumina may replace silica –increase strength & opacity – use as core material under a regular translucent porcelain in all ceramic crown (jacket crown).

Aluminous porcelain

The porcelain material contains 40-50% alumina crystals (Al_2O_3) in a low-fusing glass matrix. High-Ceram ;The dispersed alumina particles are much stronger with higher modulus of elasticity and coefficient of thermal expansion than those of the glassy matrix.

Presence of alumina makes the material opaque. (used only as coping beneath regular porcelain)

3) Quartz

- Form refractory skeleton about which the other material fuse and flow
- A form of silica is used as filler
- Help the crown holding itself during firing
- Increase the strength of the material
- Tissue contacts appear as normal tooth
- Constitutes the crystalline face
- Hardening of the mass

4) Fluxes

- Alkalies such as sodium, potassium and calcium
- Increase fluidity
- Lower firing temperature
- Acting as glass modifier (called glass modifiers).

5) Pigments

- Added to color the porcelain (to provide proper shade)
- Involve metal oxide such as titanium oxide – yellowish brown , iron or nickel oxide – brown , copper oxide – green , manganese oxide (lavender), cobalt oxide (blue), etc
- They are fused together with regular feldspar and then reground and blended to produce a variety of colors.

6) Opacifiers

Since pure feldspathic porcelain is quite colorless, opacifiers are added to increase its opacity in order to simulate natural teeth. Oxides of zirconium, titanium and tin are commonly used opacifiers.

CHARACTERS OF DENTAL PORCELAIN

1. Biological Properties:

- Inert has no interaction with surrounding soft tissue (biocompatible)

2. Interfacial Properties:

- Not adhere chemically to dental cements

3. Chemical properties:

- Not soluble in oral fluids and resist acid attack
- Both hydrofluoric acid and stannous fluoride can cause an increase in surface roughness

4. Mechanical Properties:

- Brittle
- Low Dimensional tensile strength and fracture toughness
- Hard, can cause wearing of opposing dentition

5. Thermal Properties:

- Low thermal diffusivity
- Coefficient Of thermal expansion similar or slightly higher than to that of enamel and dentine, not exhibit micro leakage (acrylic 4 –6 more).

6. Esthetic properties:

- porcelain exhibit the best (Excellent) esthetic quality, and color matching
- Difficult to be stained
- Differ from acrylic which is esthetically poor because of light absorbent).

7. Practicability:

- Sensitive manipulation technique, Requiring skilled operator and Special equipments
- Firing shrinkage is always, So operator should build up the restoration to a bigger size that allows shrinkage

8. Color stability;

Porcelain is the most stable tooth colored restorative material. Glaze porcelain provide smooth glassy non porous surface that is resistant to adherent of exogenous stain (acrylic is not stable due to water absorption and porosity).

Disadvantages of dental porcelain

- 1)** Abrasive to antagonists.
- 2)** Complex techniques need (fabrication).
- 3)** Difficult to adjust and polish intra-orally.
- 4)** May degrade supporting structure.
- 5)** Low fracture resistance.

Techniques of firing

- 1.** Pressure technique
- 2.** Diffusible gas technique
- 3.** Vacuum firing technique

Vacuum firing is one of greatest practical value to the dental ceramist because

- 1.** It is easy to manipulate
- 2.** Porcelain of greater translucence is achieved (decrease in the No. of gas bubbles)
- 3.** Strength qualities somewhat more

Porcelain reaction to firing (Phases of maturation)

1. Biscuit stage;

- Little shrinkage in the body of porcelain
- Appear like opaque white mass with porous surface , no translucency
- Contamination of porcelain at this stage is easy (oil and dust)

2. Maturity stage:

- It divides into low , medium and high
- Maturation of porcelain is evident at this stage
- The amount of translucency and color shine depend on the degree of maturation
- At the end of maturation it will appear non porous glaze where the surface reflect light and cluster

3. Coalescence stage:

- If we continue firing we reach this stage in which we loss the form of porcelain

Classification of dental porcelain

According to fusing temperature

1) High fusing porcelain 2350 – 2500 F (<1,300°C)

Usually used for manufacture of porcelain denture teeth and aluminous cores production

2) medium fusing porcelain 2000 – 2300 F (1,101°C to 1,300°C)

Usually used for porcelain jacket crown & porcelain inlay and onlay

3) Low fusing porcelain 1600 – 2000 F (850°C to 1,100°C)

Usually used for porcelain fused to metal restoration

4) Ultra-low fusing less than 850 (used with titanium) (< 850°C)

According to type of restoration

- 1) All ceramic crown
- 2) Porcelain fused to metal crown
- 3) Inlay
- 4) Onlay

According to Microstructure

- 1) Glass
- 2) Crystalline
- 3) Crystal containing glass

According to composition

- 1) Glass-matrix ceramics.
- 2) Polycrystalline ceramics.
- 3) Resin-matrix ceramics.

According to porcelain Type

- 1) Feldspathic or conventional porcelain
- 2) Aluminous porcelain
- 3) Leucite reinforced
- 4) porcelain Glass infiltrated alumina
- 5) Glass infiltrated spinell
- 6) Glass ceramic

According to Processing Method

- 1) Sintered porcelain
- 2) Cast porcelain
- 3) Machined porcelain.

According to their clinical applications

- 1) Core porcelain: Used to form the basal layer of jacket crown
- 2) Dentine or Body porcelain: More translucent, used to build the body of crowns
- 3) Enamel porcelain: The most translucent, used to form the incisal edges

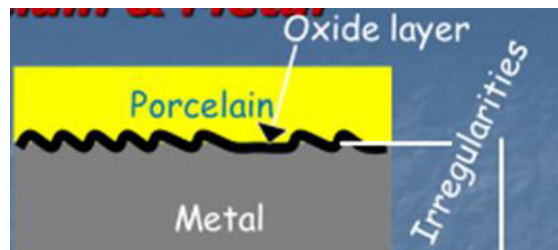
Nature of Bond between Porcelain & Metal

1. Mechanical bond

- Achieved by minute irregularities on the surface of the metal (rough surface)
- Mechanical interlocking occur only when wetting is efficient

2. Vander woals bond

- Represent attraction between atoms or molecules which are not primarily of same chemical nature
- It is more physical in nature
- It represent 1/3 of bonding



3. Chemical bond

- It is either covalent or ionic bond
- It mean formation of a new substance between metal and porcelain which is combination of both
- There will be direct electron transfer between the oxygen of the glass and the oxidizable metal in the coping alloy
- It depend on the ability of alloy to form oxide layer between the coping and porcelain.

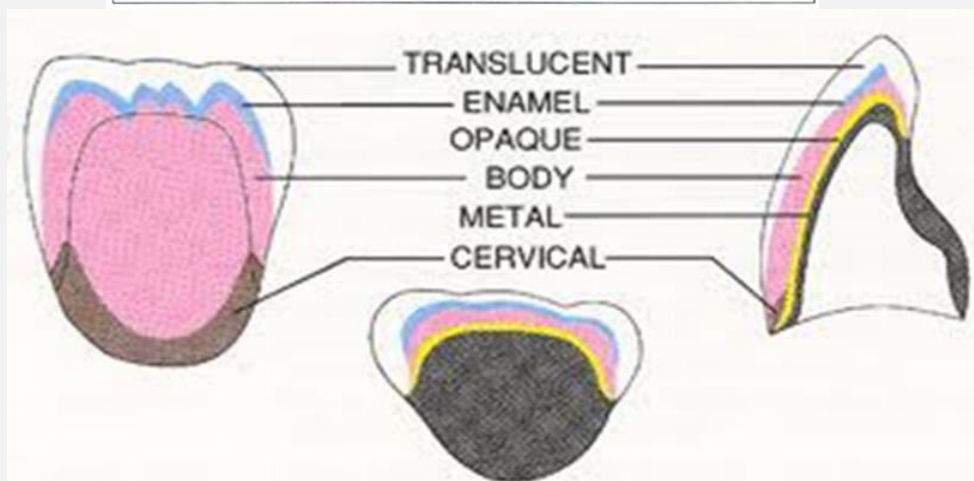
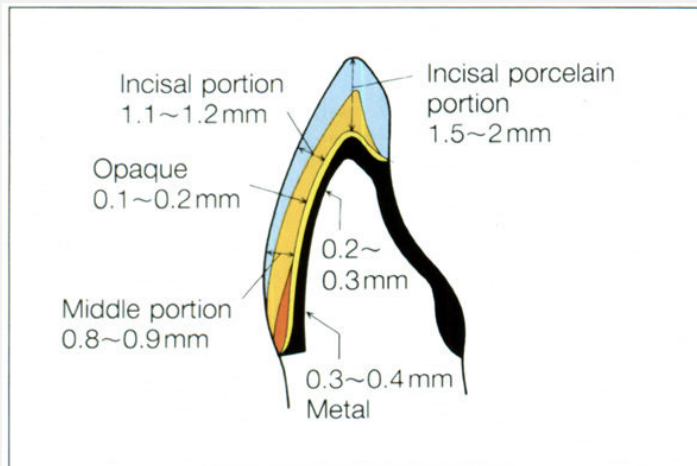
Layers of porcelain in P.F.M

1. Opaque porcelain: It is applied as a first porcelain layer , it initiate the development of shade . it perform two major function: it masks the color of the alloy, and it play an important role in the development of the metal porcelain bond.

2. Body porcelain (Dentin): this is fired onto the opaque layer, make up the bulk of the restoration , providing the most of the color or shade of the final restoration. It provide some translucency. Body porcelains are available in a wide selection of shades, to match adjacent natural teeth.

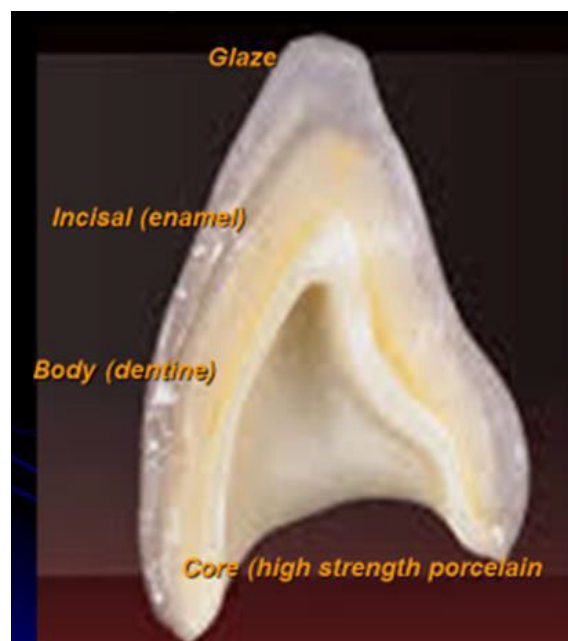3. Incisal porcelain (Enamel) : A translucent , lightly – pigmented dental ceramic used on a base of dentine ceramic to simulate the natural tooth enamel

4. Glaze: Translucent, low fusing porcelain which may applied to the surface as final stage in the firing cycle



Layers of porcelain in All Ceramic Crown

1. Core (high strength porcelain)
2. Body (dentine)
3. Incisal (enamel)
4. Glaze



Requirements of the alloys

1. The alloy should have high melting range point to withstand the porcelain firing temperature without melting or creep
2. The alloy should be sufficiently rigid and have high modulus of elasticity so that it resist deformation during firing veneer bonded to the metal or during masticatory function where occlusal force acting (to support a very brittle porcelain veneer) otherwise fractures of the veneer is inevitable.
3. The alloy should be capable of forming a bond with the porcelain veneer in order that the latter does not become detached (capable of forming oxide layer).
4. The alloy should have a value of coefficient of thermal expansion similar to that for the porcelain to which it is bonded.
5. The alloy should have good castibility.
6. The alloy should have fine grain structure to resist corrosion

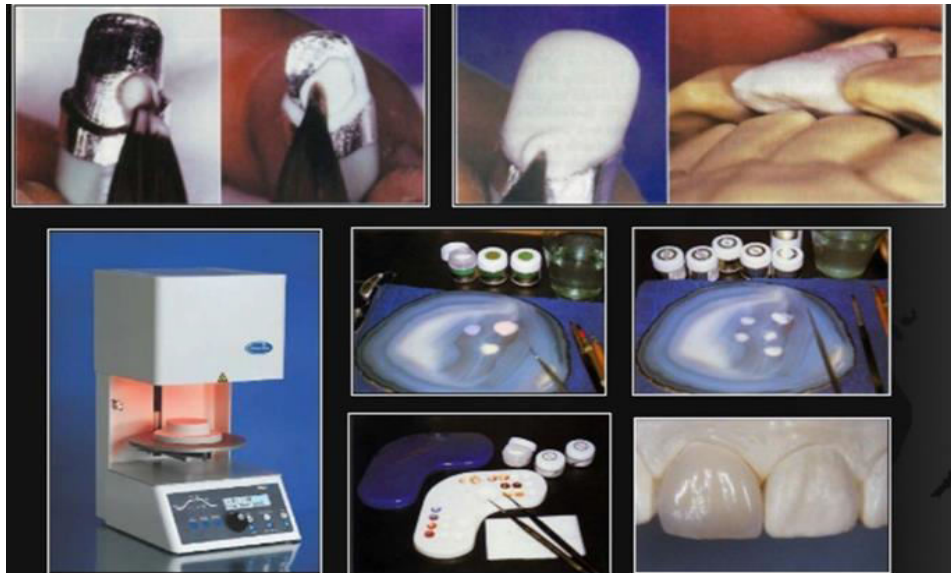
available alloy for porcelain bonding

- Noble alloys (gold platinum alloy).
- Low noble alloys (gold palladium alloy).
- Silver-palladium alloys.
- Nickel-chromium alloys.

Families of all-ceramic restorations

ALL CERAMIC SYSTEMS can be classified According to fabrication technique into:

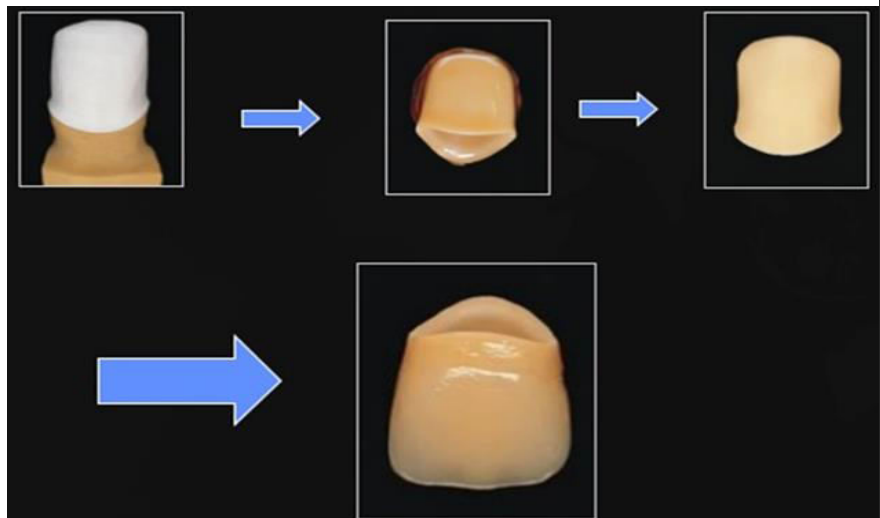
1. Powder-slurry (Sintering)ceramics (Conventional Ceramic Crown) The material presents as powder to be mixed with liquid (water) forming a slurry that is used to build the restoration up upon layer on the die of the prepared tooth to form the contour of the restoration.



2. Infiltrated ceramic


Powder is used to form a porous crystalline core by fusion of Metallic particles at high temperature, then, A Glass coat is then fused over the porous slip to infiltrate (at high temperature) into the pores (porous substrate) to give high strength restoration.

Veneering porcelain is then required to provide the desired shade and contour.



3. Castable ceramic

The restoration fabricate by casting technique, to cast the molten ceramic material (the product supplied as a solid ceramic block) into previously prepared mold cavity.



4. Machinable ceramic

A. Copy milling technology

A resin pattern is directly fabricated on the prepared tooth or on the master die, scanner were then used to scan the pattern , the pattern were then used as a coping guide for the milling machine




B. CAD/CAM system (computer aid machine / computer aid design)

Computer aided design and computer aided manufacturing (CAD/ CAM) technologies. The prepared tooth is optically impressed (pictured using intra-oral camera). The restoration is design over that image by the aid of computer.....Then Ceramic blocks are carved into restorations by the aid of computer-controlled milling machine



5. Pressable ceramic

The restoration fabricate by injection or pressing the molten ceramic material into a mold cavity made by lost wax technique (after waxing and investing).



Pain Control in Endodontics

The pain reaction threshold (PRT) is defined as that point at which a person will feel the pain. With endodontic therapy hyper response to stimulation is significantly increased.

Factors that lower the PRT include:

- 1- Presence of pain in the beginning of treatment.
- 2- Fatigue.
- 3- Fear and anxiety.

By increase of pain sensation, blood level of catecholamine suddenly elevates with an increase in blood pressure and heart rate. This might induce fainting, angina pectoris, asthma and psychiatric reactions. To reduce the possibility of such conditions happening the anaesthesia has to be introduced slowly and in supine position.

Differential diagnosis of dental pain

Pain in the facial region may be of different origins as:

Dental: This type is due to reversible pulpitis, irreversible pulpitis and symptomatic apical infection.

Musculoskeletal: As temporo mandibular joint disease.

Neuropathic: Pain may be due trigeminal neuralgia or herpes infection.

Neurovascular conditions: As migraine.

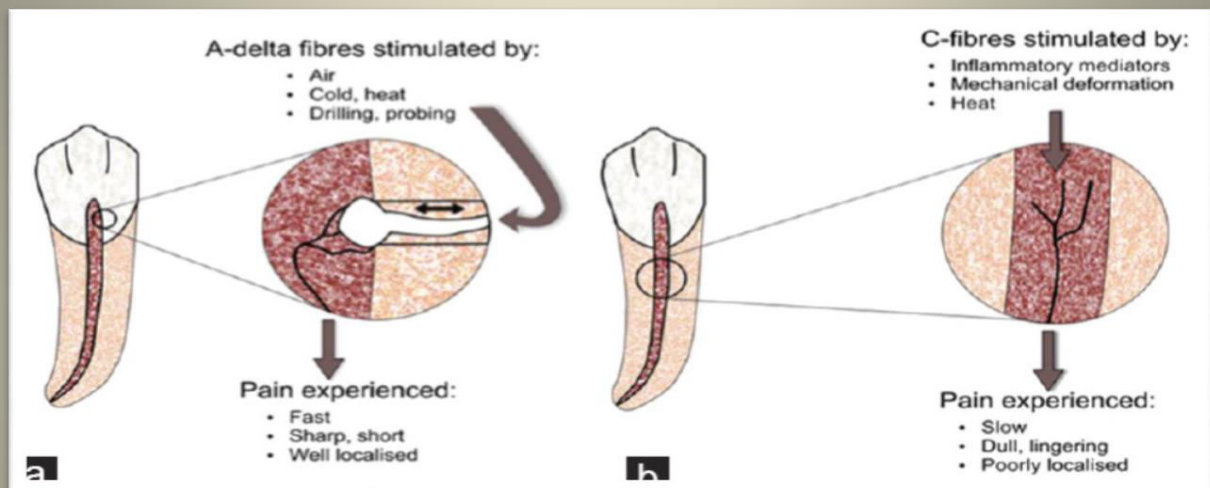
Inflammatory conditions: As sinusitis.

Systemic disorders: As cardiac pain.

Psychogenic.

Dental Pain

A-fibres in the pulp are responsible for the sensitivity of dentine and thus for the mediation of the sharp pain induced by dentinal stimulation. Prepain sensations induced by electrical stimulation result from activation of the lowest threshold A-fibres some of which can be classified as A beta-fibres according to their conduction velocities. Therefore in reversible pulpitis the A fibres are sensitized. Intradental C-fibres are activated only if the external stimuli reach the pulp proper. Their activation may contribute to the dull pain induced by intense thermal stimulation of the tooth and to that associated with extensive pulpal inflammation.



Local anesthesia

It is the temporary loss of sensation or pain in a certain part of the body produced by a topically applied or injected agent without depressing the level of consciousness. Prevention of pain during dental procedures eliminates fear and anxiety.

Knowledge of the anatomy prevents problems during anesthetic injection as muscle trismus, hematoma and intravascular injection.

There are 2 general types of local anesthetic chemical formulations:

- 1- Esters as procaine, benzocaine.
- 2- Amides as lidocaine, mepivacaine, prilocaine and articaine.

Local anesthetics are vasodilators, absorbed in the circulation and have a systemic effect directly to the blood plasma level. Vasoconstrictors in the local anesthetic constrict the blood vessels to lower the absorption of the local anesthetic into the blood stream to prolong the anesthetic effect in the area and decreasing the possibility of toxicity. It may be used to stop bleeding by infiltration of few drops in the bleeding area.

If the local anesthetic is injected in an infected area, its onset will be delayed. The inflammatory process in an area of infection lowers the pH of the extracellular tissue from its normal value to 5-6 or lower. This low pH inhibits anesthetic action because little of the free base form of the anesthetic is allowed to cross into the nerve sheath to prevent conduction of nerve impulses. Inserting a needle into an active site of infection may spread the infection.

Techniques for mandibular anesthesia

1- Inferior alveolar nerve block.

The site of deposition is near the mandibular foramen before the entry of the inferior alveolar nerve. It anesthetizes the mandibular teeth with the buccal and lingual soft tissues.

2-The Gow-Gates mandibular nerve block.

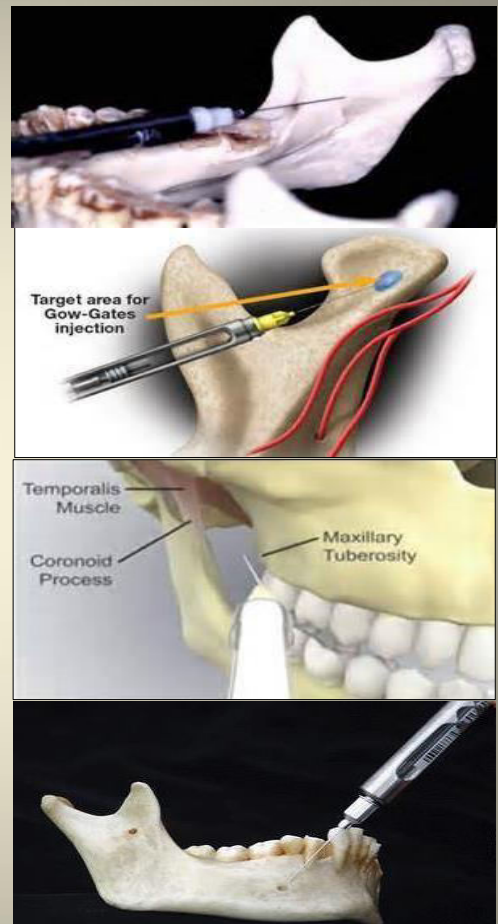
The site is the lateral aspect of the neck of the mandible condyle. It is a V3 nerve block anesthetizing all the mandibular teeth in the region with the buccal and lingual soft tissues. It provides sensory anesthesia of the buccal and mylohyoid nerve.

3-The Akinosi-Vazirani nerve block.

The site is the height of the mucogingival junction of the maxillary third molar near the maxillary tuberosity. This is used where there is limited mouth opening.

4-The Incisive nerve block.

The site is buccally between the mandibular two premolars. It provides anesthesia to the premolars and anterior teeth in the region.



Techniques for maxillary anesthesia

1-The posterior superior alveolar nerve block.

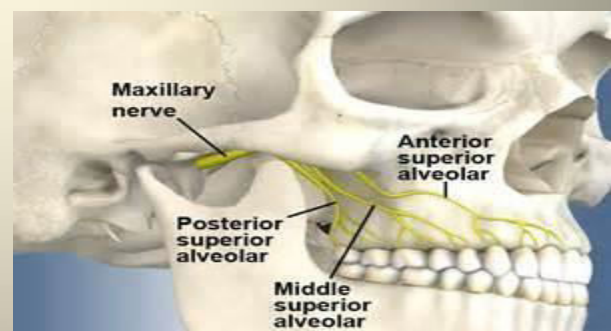
The site is in buccal fold of the maxillary 2nd molar. It anesthetizes the maxillary molars and buccal soft tissues.

2-The middle superior alveolar nerve block.

It anesthetizes the 2nd maxillary premolars and the site of injection is in the buccal fold of the premolars.

3-The anterior superior alveolar nerve block.

The site is the buccal fold of the first maxillary premolar and aimed at the infraorbital foramen. The areas anesthetized are the anterior teeth and premolars with overlying soft tissues.



Supplemental injection techniques

1- Periodontal ligament (PDL) injection

The needle is inserted between the tooth and PDL with bevel of needle toward the root. Anesthetic solution of 0.2 ml is placed per root. Onset of anesthesia is immediate but duration is variable.

2- Intraosseous anesthesia

Local anesthetic is directed into the bone surrounding the root. A small perforation is made in the cortical plate of bone with a small bur and the needle is inserted to introduce the LA.

3- Intra pulpal anesthesia

When full anesthesia is not gained by other techniques, intra pulpal approach is used. The needle is inserted directly in the pulp and LA introduced with force. Onset is immediate.

Dental and referred pain

Most of oral and dental pain can be traced to its source. There are cases whereby pain might be experienced away from its source as the same side but other jaw, ears, eyes and sinus. Careful diagnosis reveals the affected tooth or related anatomic structure (in non dental pain).

Intracanal Instruments

Classification of intracanal instruments :

They are divided into six groups:

Group I: Manually-operated instruments

Group II: Low-speed instruments

Group III: Engine-driven nickel-titanium rotary instruments .

Group IV: Engine-driven instruments that adapt themselves three-dimensionally to the shape of the root canal .

Group V: Engine-driven reciprocating instruments.

Group VI: Ultrasonic instruments.

Group I: Manually-operated instruments

a. Barbed Broaches

They were the earliest endodontic instruments used to extirpate the pulp and to remove cotton or paper points that have accidentally become lodged in the root canal. They are manufactured by hacking a round, tapered wire with a blade to form sharp, projecting barbs that cut or snag tissue. A barbed broach does not cut or machine dentin and not forced inside canal.

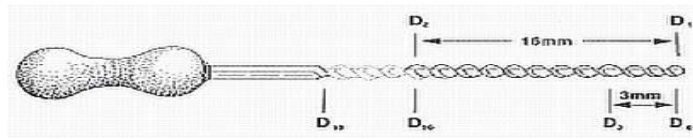


b. K-type instruments

The K-file and K-reamer are the oldest useful instruments for cutting and shaping dentin. They are made from a stainless steel wire that is ground to a tapered square or triangular cross-section and then twisted to create either a file or a reamer. A file has more flutes per length unit than a reamer. K-type instruments are useful for penetrating and enlarging root canals.

Generally, a reaming motion (constant file rotation) causes less transportation than a filing motion. Transportation is the excessive loss of dentin from the outer wall of a curved canal in the apical segment. As the instrument is increased in width its flexibility is decreased.





Three common features

cutting length of 16 mm and an increase in diameter by 0.02 mm per millimeter. This increase in diameter is termed a taper of 2%.

In addition, the cutting edges are always positioned at equal intervals so that all endodontic instruments of this type are basically designed to be similar to a screw.

K-flex file

It has a cross-section that is rhomboid in shape. It is a twisted instrument and has a series of cutting flutes. It has acute edges and obtuse edges. The acute angle cuts into the dentin while the obtuse angle provides more area for debris collection and removal. The cutting efficiency and flexibility is greater than the K-type file.



*K-Flex (large)

Flex-O-File

This instrument resembles the K-type file but it is triangular in cross-section. There is better cutting action and more room for the debris, better flexibility and more resistance to fracture. The tip of the instrument is non-cutting so no apical ledge formation is possible.



Outstanding flexibility and cutting efficiency enhanced with a non-cutting tip make them the first choice for curved and narrow canals.

Flex-R-file

The design of the tip of this instrument eliminates the possibility of ledge formation by removing the cutting surface of the tip's leading edge. This guides the instrument in the canal rather than cut. It has a triangular cross-section which increases its flexibility. It cuts more efficiently in anti-clockwise motion and can be used for filing action.

H-type instruments.

An H-type instrument has spiral edges arranged to allow cutting only during a pulling stroke. An example is a Hedström file. An H-type instrument is better for cutting than a K-type instrument, because it has a more positive rake angle and a blade with a cutting rather than a scraping angle. They are more likely to fracture when bending or used aggressively.

S-file (Uni-file)

This instrument is a ground S-shaped cross-section instrument. This is stiffer than the Hedstrom file. The cutting mode may be with filing or reaming action.



Traditional instruments modifications

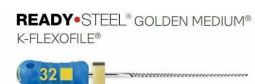1. Nickel titanium file.

Files made from nickel titanium showed greater elastic flexibility and resistance to torsional fracture than stainless steel. This file has a non-cutting tip and it tends to maintain the curvature of the root canal.



2. Golden mediums

These instruments are a series of intermediate size instruments. They correspond in size to halfway between standard ISO sizes.



3. Canal Master U

This hand instrument is used to **prepare the apical third** of the canal. It has a non-cutting pilot tip, **1mm length cutting blade** and a narrow parallel sided shaft. It is used to allow for better cutting with more space for debris accumulation and further removal. It reduces the possibility of ledge or transportation.

Group II: Low-Speed Rotary Instruments

Many types of rotary instruments are used during endodontic procedures. In addition to conventional burs, burs with extended shanks for low-speed contra-angle handpieces are useful for providing good visibility during deep preparation of the pulp chamber. This is particularly important when using an operating microscope. Straight-line access to the initial point of curvature can be accomplished using rotary instruments such as Gates-Glidden burs and Peeso instruments. Use of these instruments should be limited to the straight portion of the canal preparation. The risk of perforation with these instruments is a possibility. The risk of lateral cutting resulting in perforation is lower with Gates-Glidden burs than with the Peeso drills. The Peeso reamer is used mostly for space preparation.

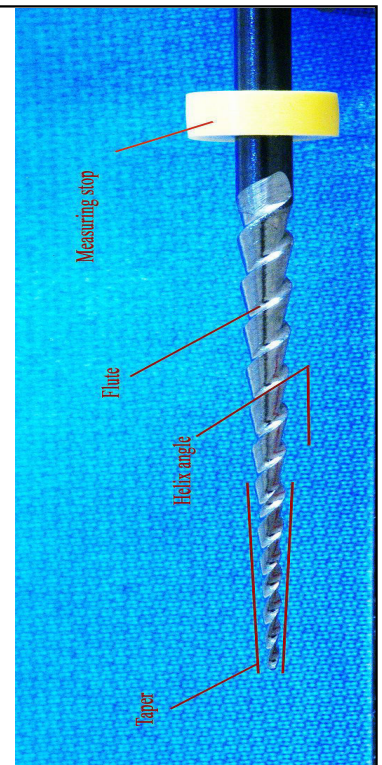


Group III: Rotary Instruments for Canal Preparation

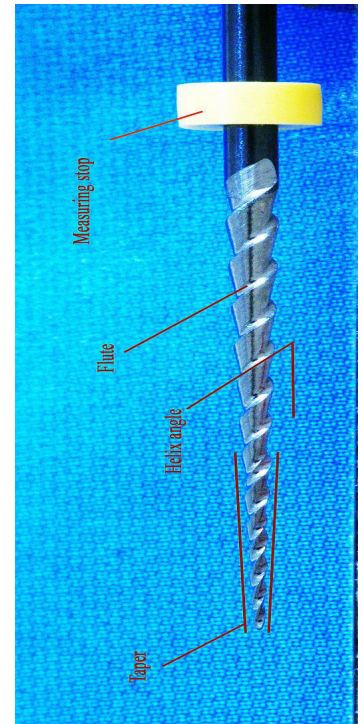
Components of a file

Taper – The taper of a file refers to the **gradual increase in diameter along its working surface**. NiTi rotary files usually have a higher taper compared to the taper of standard traditional hand files which is. Different systems are sometimes classified according to their taper which can be constant or variable.

Flutes – **Flutes are the grooves on the working side of the files** which can be produced either by twisting or grinding a wire. Flutes provide cutting edges and also space for debris collection. Therefore, their presence turns a wire into a shaping instrument which both cuts the tooth structure and acts as an **auger**. The depth, width, number, arrangement and the direction of the flutes play an important role on the behavior of a file.




Helix angle – Helix angle is an angle between the cutting edge and the long axis of a file. Helix angle plays an important role in debris collection and it also determines the direction of rotation. Helix angle can be constant or accelerating (changes along the length of a file). Accelerating helix angles decreases the screw in effect when most of the working surface of a file is engaged and it can decrease the torsion stress on a file.




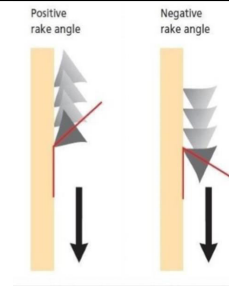
Relief:

Surface area of land that is reduced to a certain extent to reduce frictional resistance.




Rake angle If a file is sectioned perpendicular to its long axis, the angle formed by the leading edge and the radius of the file is called the rake angle. If the angle formed by the leading edge and the surface to be cut is obtuse, the rake angle is said to be positive or cutting. If the angle formed by the leading edge and the surface to be cut is acute, the rake angle is said to be negative or scraping.

Pitch of the file is the distance between a point on the leading edge and the corresponding point on the adjacent leading edge. The smaller the pitch or the shorter the distance between corresponding points, the more spirals the file has .


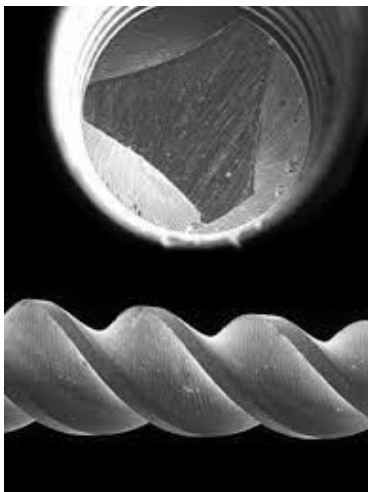


The ProTaper file utilizes a negative angle of incidence to enlarge the canal. The surface of the file blade meets the canal wall with an acute angle resulting in a scraping action. More pressure is required when enlarging the canal in this manner.



•**Measuring stop** – Measuring stop is a piece of rubber that an operator can use to mark certain desired length on a file while using it. Measuring stops are referred to as stoppers and they can also be color coded corresponding to the size and number of a file.

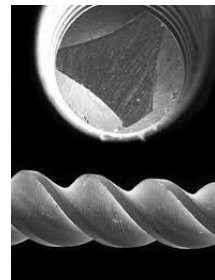
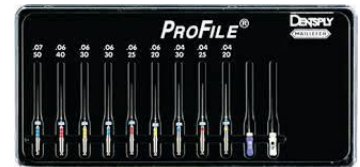•**Radial land** – The radial land is the peripheral portion of a rotary instrument that is flat and smooth designed to center the instrument in the central space.



Rotary Instrumentation systems using Nickel Titanium

ProFile system

The ProFile system was introduced in 1994. ProFile instruments have increased tapers to 29% compared with conventional hand instruments. Cross section of a ProFile instrument has a U-shape design with radial lands and a parallel central core. Lateral views show a degree helix angle, a constant pitch, bullet-shaped noncutting tips and with a neutral or slightly negative rake angle. This configuration facilitates a reaming action. Debris is transported coronally and is effectively removed from the root canals. The preferred speed is 225-325 rpm.




ProFile GT Files.

The Greater Taper (GT) file was introduced in 1994. This instrument also has the U-shape file design. The instruments come in four tapers: 0.06, 0.08, 0.10, and 0.12, (and the maximum diameter of the working part coronally is 1 mm).

The instruments have a variable pitch and an increasing number of flutes in progression to the tip; the apical instrument diameter is 0.2 mm. Instrument tips are noncutting and rounded.

ProTaper Universal system.

The ProTaper system is based on another concept and composed of six instruments: three shaping files and three finishing files. In cross section, ProTaper shows a modified K-type file with sharp cutting edges and no radial lands; this creates a stable core and sufficient flexibility for the smaller files. The difference in design of this system is the varying tapers.



RaCe, Bio Race

The RaCe was manufactured since 1999 by FKG. The name stands for **reamer with alternating cutting edges**. This design aimed at reducing the tendency to thread the file into the root canal. Cross sections are triangular or square. The tips are round and noncutting.

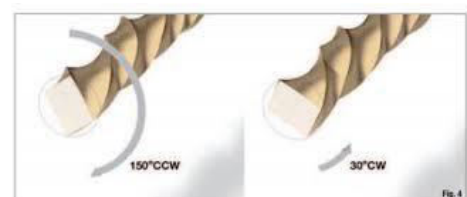


Wave One single file reciprocating system

This system is a single-use, single file system to shape the root canal using the reciprocation motion. The file is made with M-wire technology which improves strength and resistance to cyclic fatigue about four times the traditional rotary NiTi files. The system is composed of:

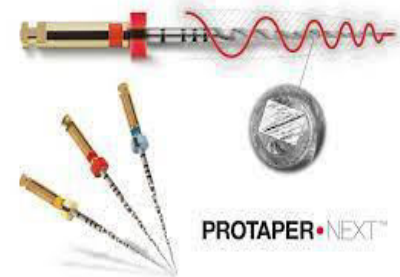- The Wave One **small** file. It is used in narrow canals. The tip has an ISO of 20 with a continuous taper of 6.°
- The Wave One **primary** file. It is used in the majority of canals. The tip has an ISO of 25 with an apical taper of 8 °that reduces towards the coronal end.
- The Wave One **large** file. It is used in wide canals. The tip has an ISO of 40 with an apical taper of 8 °that reduces towards the coronal end.

The instruments are designed to work with a reverse cutting action .



ProTaper Next

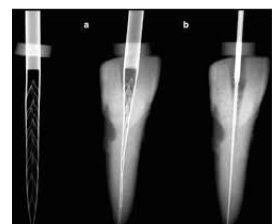
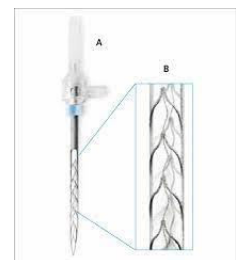
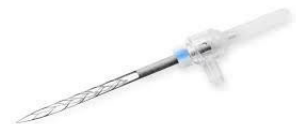This system is composed of 5 files, namely X1 ,X2 ,X3 ,X4 and X5 .These files correspond to sizes 20/.4, ,25/.6 ,30/.7, ,40/.6 and 50/.6 respectively. The X1 and X2 have variable tapered design whereas X3-X5 files have a fixed taper This system has a rectangular cross section which allows 2 points contact with the dentin wall and the rest of the space free for storing debris which will be removed by the file **swaggering motion.**



Group IV: Engine-Driven Three-Dimensionally

Adjusting Files (Self-adjusting file)

The self-adjusting file (SAF) represents a new approach in file design and mode of operation. The file is a hollow device, designed as a cylinder of thin-walled, delicate NiTi lattice with a lightly abrasive surface. An initial glidepath is established with a #20 K-file to allow the insertion of the SAF file. The file is proposed to be compressed from its 1.5 mm diameter into dimensions equivalent to those of a #25 K-file. The handpiece generates in-and-out vibrations with 5000 vibrations per minute . The compressed file will adapt itself to the root canal walls, applying a uniform cutting action gradually removing a uniform dentin layer from the canal walls. There is a continuous flow of irrigant which removes the tissue debris and the dentin powder generated by the file.



Group V: Engine-Driven Reciprocating Instruments :

Endo-eze reciprocating files

The Giromatic handpiece, a rotary instrument in use since 1969 ,delivers 3000 quarter-turn reciprocating movements per minute. Rasps and barbed broaches are most often used in Giromatic handpieces, but K-type and H-type instruments also can be used. The endo-eze file system (Ultradent) is a recently introduced addition for Giromatic handpieces .



Group VI: Sonic and Ultrasonic Instruments

A very different way of instrumenting root canals was introduced when files or ultrasonic tips of different shapes and sizes were activated by electromagnetic ultrasonic energy.

Piezoelectric ultrasonic units are also available for this purpose. These units activate an oscillating sinusoidal wave in the file with a frequency of about 30 kHz.

Two types of units, ultrasonic and sonic, are primarily available. Ultrasonic devices, which operate at 25 to 30 kHz, include the magnetostrictive (Cavi-endo), and the piezoelectric (Enac). Sonic devices operate at 2 to 3 kHz (Sonic Air MM 1500).

Ultrasonic devices use regular types of instruments (e.g., K-files), where as sonic devices use special instruments known as Rispi-Sonic, Shaper- Sonic, Trio-Sonic, or Heli-Sonic files.

Although similar in function, piezoelectric units have some advantages over the magnetostrictive systems. For example, piezoelectric devices generate little heat, so no cooling is needed for the electric handpiece. The magnetostrictive system generates considerable heat, and a special cooling system is needed in addition to the irrigation system for the root canal.

The file in an ultrasonic device vibrates in a sinus wave–like fashion. Files must be used only for a short time, must remain passive within the canal, and the power must be controlled carefully.

Ultrasonic devices have proved very efficient for irrigating root canal systems. During free ultrasonic vibration in a fluid, two significant physical effects are observed: cavitation and acoustic streaming. During oscillation in a fluid, a positive pressure is followed by a negative pressure causing implosion. This is cavitation. Acoustic streaming creates small, intense, circular fluid movement around the instruments.

Endodontic Radiography

The dental radiograph allows indirect vision to the dentition and supporting structures, and provides standardization of intra canal procedures. As a result, radiographs are a very important aid for endodontic diagnosis and treatment.

Basic radiographic concepts

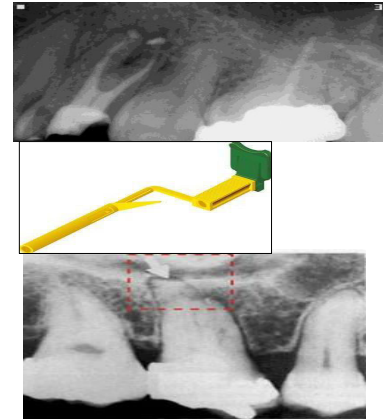
- 1-** X-rays are similar to light rays in that both travel in a straight line until deflected or absorbed . Deflected rays reduce image clarity.
- 2-** The radiograph is a shadow image representing differences in a density of objects in the x-rays path. Therefore, the radiograph is a two dimensional image of a three dimensional structure.
- 3-** The size, shape and contrast of the shadow image are subjected to many distortions since they are dependent on the physical properties of:
 - a)The object through which the x-ray passes.
 - b)The radiation source.
 - c)The film on which the image is recorded.

Disadvantages of Radiographs

- Radiographs are 2D shadow of a 3D Object .
- They are only suggestive and not the final evidence in judging a clinical problem .
- Bucco-lingual dimension cannot be assessed in an IOPA radiograph .
- Chronic inflammatory tissues cannot be differentiated from healed fibrous scar tissue .
- Lesions of the medullary bone are undetected in the radiographs till there is substantial bone loss and the involvement of cortical bone .
- Over exposure to X rays are harmful to the body and strict precautions are to be maintained for the patient and the operator .

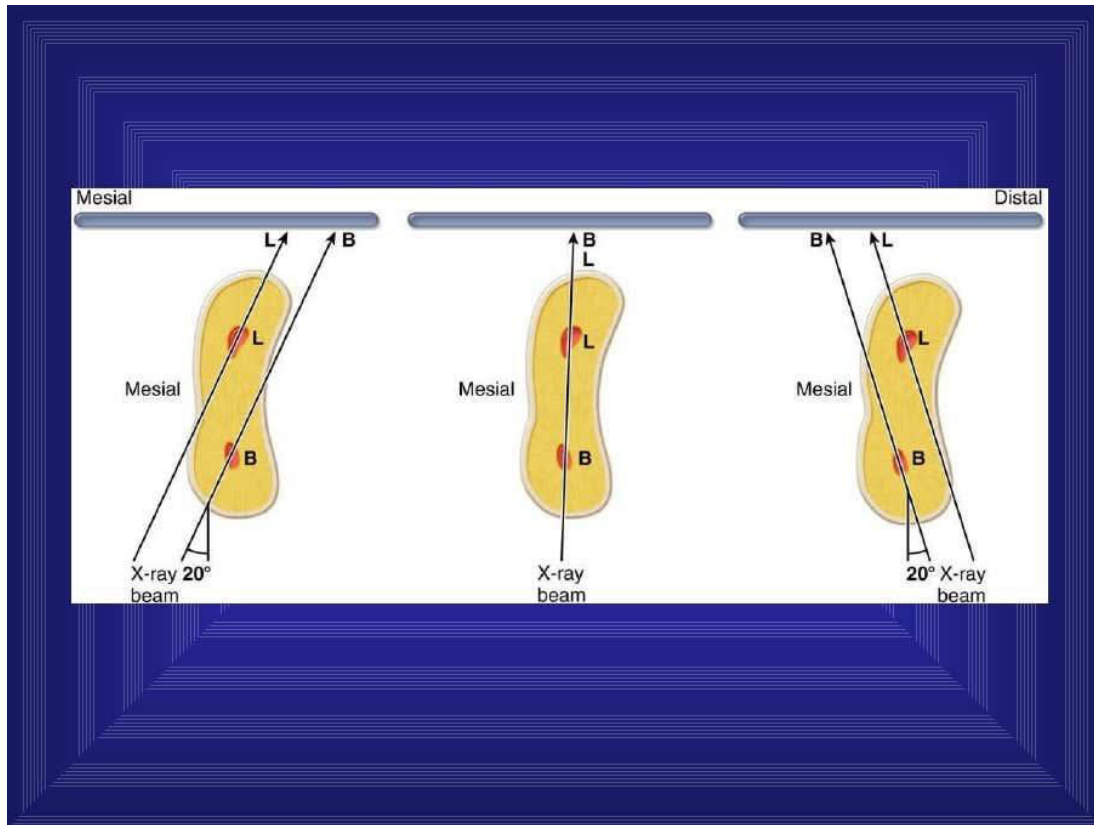
Suggestions for good endodontic radiography

- 1- For periapical exposures the edge of the film is positioned parallel to and near the incisal or occlusal surface of the teeth so that the tooth apices are near the center of the film.
- 2- The plastic film holder facilitates standardization of a radiographic technique by aiding in film positioning and preventing movement of the film during exposure.
- 3- Because of the angle of the hard palate the films that are held by the finger usually show maxillary molars with short buccal roots and very long palatal root.



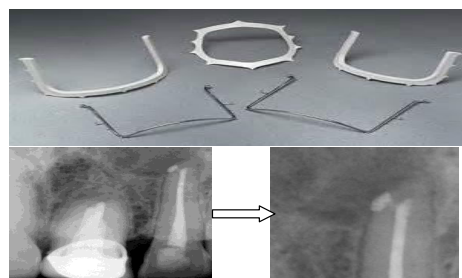
Buccal object rule

When treating premolars and molars, it is often difficult to recognize radiographically which canal is nearer buccal side. When the exposure is done to multicanaled tooth, the canals may be superimposed and difficult to differentiate them. If the x-ray cone is deviated mesially or distally with a given angle the roots will separate in the film. Therefore, when the cone is moved distally the buccal canal appears mesial to the lingual or palatal canal and when the cone is moved mesially the buccal canal appears distal to the lingual or palatal canal. .



Factors that affect the quality of the radiograph and its interpretation

- 1-** Radiolucent rubber dam frames do not interfere with taking radiography. Metal frames may mask important structures on the film.
- 2-** A quick automated processing technique offers a clear radiograph. It maintains a water bath heated by a thermostatically controlled heater that maintains the developer and fixer at 100 F, so shortening the time needed to process a radiographic film. The exposed film is immersed in the developer for 5-10 seconds, rinsed with water and then placed in the fixer until it becomes clear (15-20 seconds).
- 3-** All endodontic radiographs must be dated and mounted in chronological sequence to allow for immediate reference.
- 4-** Film magnification is essential to see clearly detailed structures in the film and this is done a magnifying lens. Nowadays, there is no need for this lens because digital radiography allows detailed picture that can be zoomed in clearly.



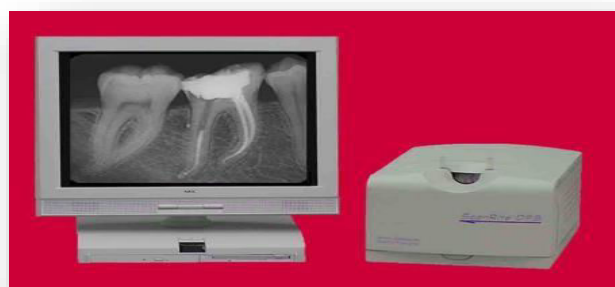Informations gained from the radiograph

- 1-**The crown and pulp anatomy.
- 2-**Hard tissue alterations in the tooth (sclerosis or resorption) .
- 3-** Number, size, location and direction of the roots.
- 4-**Estimation of the working length.
- 5-**Related anatomical structures as mental foramen, maxillary sinus ,etc...
- 6-** Confirm position of master cone.
- 7-**Evaluation of success of obturation.
- 8-**Instrument separations or perforations.

Digital radiography

As dentistry moves to more precise quality so does diagnosis, therefore it was important to change the traditional x ray films to a more precise film and here digital radiography entered the diagnostic field. Digital radiography used in dentistry is available in three variations:

- 1-Direct digital system:** It uses a solid-state sensor such as a charge coupled device (CCD). These systems have a cable that connects the sensor to the computer and in turn to screen monitor.
- 2-Storage phosphor system:** It uses a photo- stimulable phosphor plate that stores the image in the phosphor for subsequent readout by an extra-oral laser scanner.
- 3-Indirect digital system:** It uses a scanning device connected to a computer for digitizing traditional silver halide dental films.

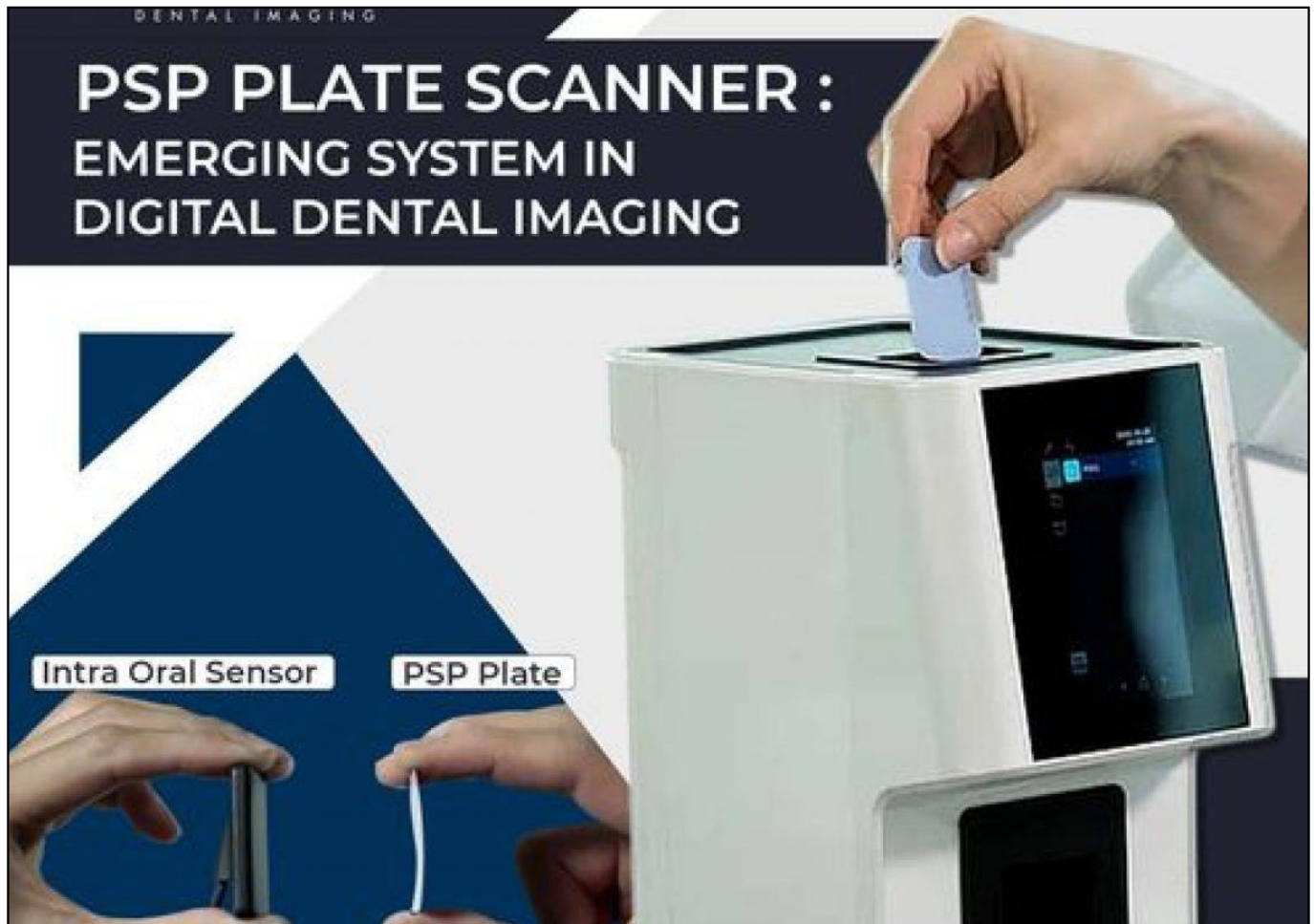

Intraoral X ray Sensors



11





Advantages of digital radiography

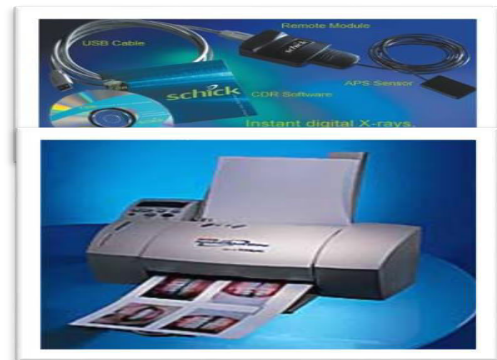- 1-**Image enhancement, contrast stretching and reversing.
- 2-**Storage for further use and evaluation.
- 3-**Retrieval immediately.
- 4-**Transmission of images to remote sites in a digital format.
- 5-**Radiation exposure is reduced from 50% to 90% compared with conventional film- based radiography.

Direct digital systems have three components

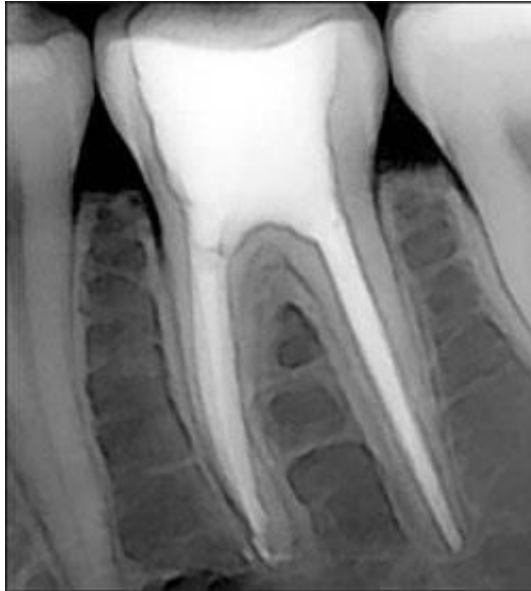1-Radio component: It consists of a high resolution sensor with an active area that is similar in size to conventional film. For infection control, disposable plastic sheaths are used to cover the sensor when it's in use.

2-Visio component: It consists of a video monitor and display-processing unit. As the image is transmitted to the processing unit, it's digitized and stored by the computer.

3-Printing component: High resolution printer providing a hard copy of the screen image.



Root canal filling materials



Root canal filling materials

Sealers

They are paste like material that is essential to seal the space between the dentinal wall and the gutta percha.

Functions of the root canal sealer

- 1-** Cementing the core material to the canal wall.
- 2-** Filling and marking irregularities that can not be filled by gutta percha (lateral and accessory canals).
- 3-** Act as a lubricant to ease the placement of the master cone.
- 4-** Act as a bactericidal agent.

Properties of an Ideal Sealer

- 1- Exhibits tackiness when mixed to provide good adhesion.
- 2- Produce a hermetic seal.
- 3- Radiopaque.
- 4- Very fine powder to get a smooth mix with the liquid.
- 5- No shrinkage on setting.
- 6- No staining of tooth structure.
- 7- Bacteriostatic.
- 8- Exhibits a slow set.
- 9- Insoluble in tissue fluids.
- 10- Tissue tolerant.
- 11- Soluble in common solvents.

Zinc Oxide and Eugenol

Zinc oxide–eugenol sealers have been used for many years.
They have certain properties as:

- 1-** Exhibit a slow setting time.
- 2-** Shrinkage on setting.
- 3-** Solubility especially when extruded outside the root canal.
- 4-** Stain tooth structure.
- 5-** It has antimicrobial activity.

Types of zinc oxide eugenol sealers

1- Rickert sealer: This powder/liquid sealer contains silver particles for radiopacity. It stains tooth structure if not completely removed. This sealer is popular when using thermoplastic techniques.

2- Procosol sealer: It is a modification of Rickert's formula in which the silver particles have been removed.

3- Roth's sealer: This is a modification of the Rickert' sealer as it is nonstaining.

4- Tubli-Seal: It is a catalyst/base zinc oxide–eugenol sealer. It has a faster setting time when compared with the liquid/powder sealers.

Calcium Hydroxide Sealers

They were developed for their antimicrobial activity and osteogenic–cementogenic potential. These actions were very limited. From the types of this group are Sealapex (catalyst/base system), Apexit and Apexit Plus.

Non eugenol Sealers

They are root canal sealers without the irritating effects of eugenol.

Glass Ionomer Sealers

The glass ionomers have been developed in root canal obturation because of their dentin-bonding properties. An example from this group is *Ketac-endo*.

Properties of this group:

- 1-** It enables adhesion between the material and the canal wall.
- 2-** It is difficult to properly treat the dentinal walls in the apical and middle thirds with modifying agents to receive the glass ionomer sealer.
- 3-** It has minimal antimicrobial activity.

Resin sealers

These sealers provide adhesion, and do not contain eugenol.

Types of this group are:

- 1- Ah-26:** It is a slow-setting epoxy resin that releases formaldehyde when setting.
- 2- Ah Plus:** It is a modified formulation of Ah-26 in which formaldehyde is not released. It exhibits a working time of approximately 4 hours.
- 3- EndoreZ:** It is a methacrylate resin with hydrophilic properties. When used with endoreZ resin-coated gutta-percha cones the dual cure endoreZ sealer bonds to both the canal walls and the core material.
- 4- Diaket:** It is a polyvinyl resin sealer.
- 5- Epiphany and Real Seal:** They were introduced for use with the resilon filling material.

Silicone Sealers

1- RoekoSeal is a polyvinylsiloxane that is supposed to expand slightly on setting.

2- GuttaFlow is a cold flowable matrix that is triturated. It consists of guttapercha added to roekoSeal. Sealing ability is comparable to other techniques.

Bioceramic sealers

It is composed of zirconium oxide, calcium silicates, calcium phosphate monobasic, calcium hydroxide, and various filling and thickening agents.


Properties of this group:

- 1-** It is a hydrophilic sealer it utilizes moisture within the canal to complete the setting reaction.
- 2-** It does not shrink on setting.
- 3-** It is biocompatible.
- 4-** It exhibits antimicrobial properties during the setting reaction.

Semi Rigid types materials for obturation of the root canal

1- Gutta-Percha

Gutta-percha is the most commonly used root canal filling material. It is a linear crystalline polymer that melts at a set temperature, with a random but distinct change in structure resulting. It occurs naturally as 1,4- polyisoprene and is harder, more brittle, and less elastic than natural rubber.



The crystalline phase has two forms, the alpha phase and the beta phase. The alpha form is the material that comes from the natural tree product. The processed, or beta, form is used in gutta-percha for root fillings.

When heated, gutta-percha undergoes phase transitions. The transition from beta phase to alpha phase occurs at around 46° C. An amorphous phase develops at around 54° C to 60° C. When cooled very slowly gutta-percha crystallizes to the alpha phase.

Normal cooling returns the gutta-percha to the beta phase. Gutta-percha cones soften at a temperature above 64° C.

These cones can easily be dissolved in many solvents as chloroform, halothane and xylene. Modern gutta-percha cones that are used for root canal fillings contain only about 20% gutta-percha. The major component is zinc oxide (60% to 75%). The remaining 5% to 10% consists of various resins, waxes, and metal sulfate.

Antiseptic gutta-percha with various antimicrobial agents as chlorohexidine and calcium hydroxide may be seen.

Gutta-percha cannot be heat sterilized, therefore NaOCl can be used to disinfect the cones by dipping them for 1 minute.

Pressure applied during root canal filling procedures does not compress gutta-percha, but rather compacts the gutta-percha cones to obtain a more three- dimensionally complete fill of the root canal system. After heating, while cooling, there is a slight shrinkage of approximately 1% to 2% when the gutta-percha has solidified.

Gutta-percha cannot be used alone as a filling material; it lacks the adherent properties necessary to seal the root canal space.

Therefore, a sealer is always needed for the final seal. Gutta-percha cones are available in tapers matching the larger tapered rotary instruments (#.02, #.04, and #.06).

Advantages of gutta percha

- 1- Inert
- 2- Dimensional stability
- 3- Non allergic
- 4- Antibacterial
- 5- Non staining to dentin
- 6- Radiopaque
- 7- Compactable
- 8- Softened by heat
- 9- Softened by organic solvents

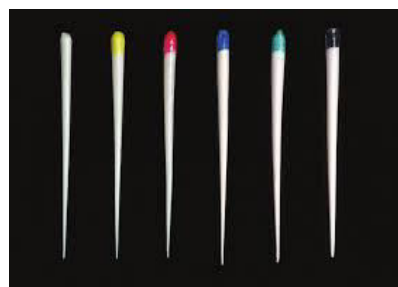Disadvantages of gutta percha

- 1- Lack of rigidity
- 2- No adherence to dentin
- 3- No complete adaptation to narrow areas

2- Resilon

It is a thermoplastic, synthetic, polymer-based root canal filling material. It was developed to create an adhesive bond between the solid-core material and the sealer.

Resilon can be supplied in the same ISO sizes and shapes (cones and pellets) as gutta-percha. When manufactured in cones, Resilon's flexibility is similar to that of gutta percha. Based on polyester polymers, Resilon contains bioactive glass and radiopaque fillers (bismuth oxychloride and barium sulfate) with a filler content of approximately 65%. It can be softened with heat or dissolved with solvents such as chloroform.



Mineral trioxide aggregate (MTA)

It was developed for use as a dental root repair material by Dr. Mahmoud Torabinejad and was formulated from commercial Portland cement combined with bismuth oxide powder for radiopacity.

MTA is used for:

- 1-** Creating an apical plug during apexification.
- 2-** Repairing root perforations during root canal therapy.
- 3-** Treating internal root resorption.
- 4-** Root-end filling material.
- 5-** Pulp capping material.

Composition

MTA is composed of:

- 1- tricalcium silicate.
- 2- dicalcium silicate.
- 3- tricalcium aluminate.
- 4- tetracalcium aluminoferrite.
- 5- calcium sulfate.
- 6- bismuth oxide.

The later 4 phases vary among the commercial products available .

Characteristics and products

1. Biocompatible with periradicular tissues
2. Non cytotoxic to cells, but antimicrobial to bacteria
3. Non-resorbable
4. Minimal leakage around the margins.
5. Very basic AKA alkaline (high pH when mixed with water).
6. As a root-end filling material MTA shows less leakage than other root-end filling materials, which means bacterial migration to the apex is diminished.
7. Treated area needs to be infection free when applying MTA, because an acidic environment will prevent MTA from setting.
8. Compressive strength develops over a period of 28 days, similar to Portland cement. Strengths of more than 50 MPa are achieved when mixed in a powder-to-liquid ratio of more than 3 to 1.

Originally, MTA products required a few hours for the initial and final setting but newer materials are available that set more quickly and have added characteristics.

Solid type materials for obturation of the root canal

1- Semi rigid materials as silver cones which are not used now. They are flexible and fill narrow curved root canals. When silver cones contact tissue fluids or saliva, they corrode. The corrosion products are cytotoxic.



2- Rigid materials as Vitalium cones which are inflexible and were used as endodontic implants.

Obturation of the root canal system

Objectives of canal obturation

- 1-** Prevention of percolation of periapical exudates into the root canal space.
- 2-** Prevention of reinfection of the root canal during transient bacteremia.
- 3-** Creation of a favorable biological environment for the process of tissue healing.

Criteria for root canal obturation

- 1-** Asymptomatic tooth .
- 2-** Dry canal .
- 3-** No sinus tract .
- 4-** No foul odor .
- 5-** Negative culture .

Heat softened gutta percha techniques

Warm lateral condensation

This technique depends on a heated spreader to soften the gutta percha during lateral condensation to improve the adaptation of the gutta percha to the wall of the root canal.

Technique:

- 1- Heating the spreader is done by hot glass beads which is then inserted in the root canal.
- 2- Lateral condensation is done to create space for the accessory cones.
- 3- This procedure is repeated until the canal is completely filled.
- 4- An electrically heated spreader may be used.

Warm vertical gutta percha filling technique

It is a method of filling the radicular space in three dimensions. The canal should be with a continuously tapering funnel and keeping the apical foramen as small as possible. The armamentarium includes a variety of pluggers and a heat source.

Technique:

1- The master cone should fit short of the corrected working length (0.5 to 2 mm) with resistance to displacement. This ensures that the cone diameter is larger than the prepared canal.

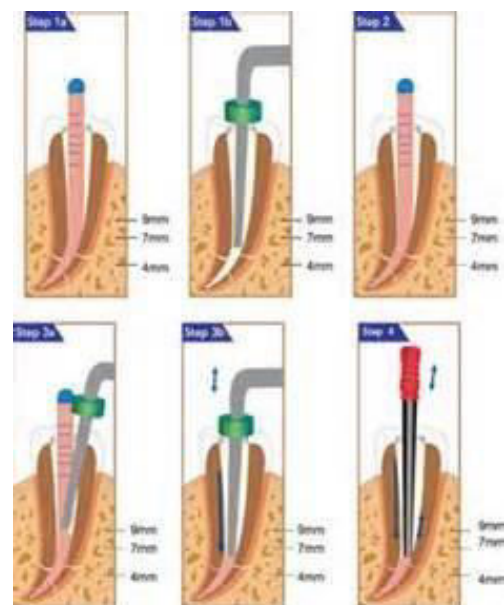
2- After the adaptation of the master cone it is removed and sealer is applied in the root canal.

3- The cone is placed in the canal and a heated spreader or plugger is used to remove portions of the coronal gutta-percha and soften the remaining material in the canal.

4- A plugger is inserted into the canal and the gutta-percha is compacted, forcing the plasticized material apically.

5- The process is repeated until the apical portion has been filled.

6- The coronal canal space is back-filled, using small pieces of gutta-percha. The sectional method consists of placing 3-4 mm sections of gutta-percha approximating the size of the canal, applying heat, and compacting the mass with a plugger.

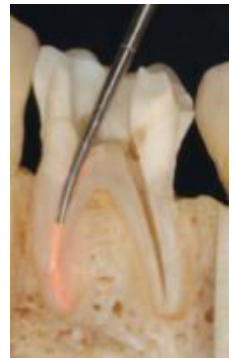
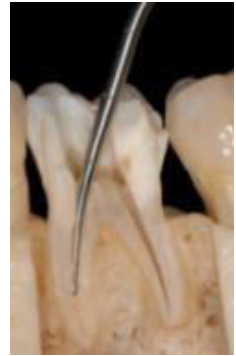


Continuous Wave Compaction Technique

It is a variation of warm vertical compaction. The manufacturing of cones to resemble the tapered preparation using rotary instrumentation permits the application of greater hydraulic force during compaction when appropriately tapered pluggers are used.

Technique:

- 1- After selecting an appropriate master cone, a plugger is prefitted to fit within 5 to 7 mm of the canal length.
- 2- The heat source (ex. System B unit) is set to 200 °C.
- 3- The plugger is inserted into the canal orifice when the master cone is present in the root canal and activated to remove excess coronal material.
- 4- Compaction is initiated by placing the cold plugger against the gutta-percha in the canal orifice.
- 5- Firm pressure is applied and heat is activated with the device. The plugger is moved rapidly (1 to 2 s) to within 3 mm of the binding point.
- 6- The heat is inactivated while firm pressure is maintained on the plugger for 5 to 10 seconds.



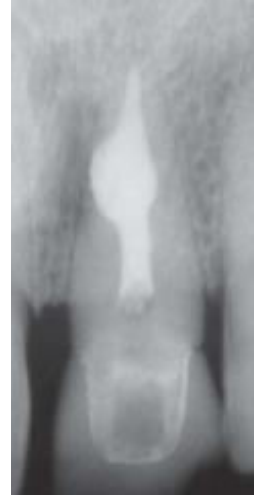Thermoplastic Injection Techniques

Heating of gutta-percha outside the tooth and injecting the material into the canal is an additional variation of the thermoplastic technique. This technique is used to obturate irregularities difficult to fill by other techniques as internal resorption. The obtura III, Calamus, Ultradent and Guttaflow devices and systems are examples of this type.



Technique:

- 1- Canal preparation is similar to other obturation techniques and the apical foramen should be as small as possible to prevent extrusion of gutta-percha.
- 2- The canal walls are coated with sealer using the master apical file.
- 3- A gutta-percha pellet is preheated in the gun, and the needle is positioned in the canal so that it reaches within 3 to 5 mm of the apical preparation.
- 4- Gutta-percha is then gradually, passively injected by squeezing the trigger of the “gun.”
- 5- The needle backs out of the canal as the apical portion is filled.
- 6- Pluggers dipped in alcohol are used to compact the gutta-percha. Compaction should continue until the gutta-percha cools and solidifies to compensate for the contraction that takes place on cooling.
- 7- Both overextension and underextension are common results.




Carrier-Based Gutta-Percha

Thermafil and Soft Core cones were introduced as a gutta-percha obturation material with a solid core. The technique has a central plastic core which facilitates the adaptation of the α -phase gutta-percha to the root canal walls apically and laterally.

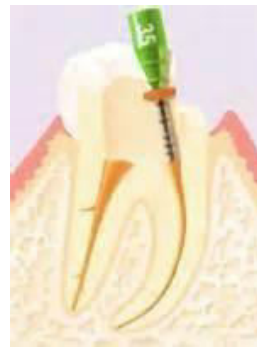Advantages included ease of placement and the pliable properties of the gutta-percha.

Technique:

- 1- Size verifiers should fit passively at the corrected working length.
- 2- After drying the canal a light coat of sealer (Grossman sealer) is applied and a carrier is marked, set to the predetermined working length.



- 3- Removal of the smear layer is strongly recommended because it enhances the seal.
- 4- The carrier is disinfected with 5.25% NaOCl for 1 minute and rinsed in 70% alcohol.
- 5- The carrier is then placed in the heating device to the specified temperature.
- 6- When the carrier is heated, it has approximately 10 seconds to be inserted it into the canal. This is accomplished without rotation or twisting.
- 7- The position of the carrier is verified radiographically.
- 8- The gutta-percha is allowed 2 to 4 minutes to cool before resecting the coronal portion of the carrier.
- 9- Vertical compaction of the coronal gutta-percha can be accomplished.
- 10- An advantage to this technique is the potential for movement of gutta-percha into lateral and accessory canals but extrusion of material beyond the apical extent of the preparation is a disadvantage.



Solvent Techniques

Gutta-percha can be plasticized with solvents such as chloroform, eucalyptol, and xylol. A gutta-percha cone is softened and placed into the canal to adapt better to the root canal wall, the mass hardens as the solvent evaporates.

Disadvantages of this technique include:

- 1- Shrinkage occurs with the evaporation process causing voids.
- 2- Irritation of periradicular tissues by the solvent.

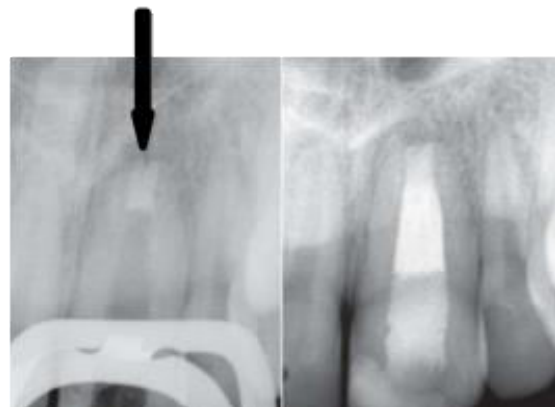Pastes

Pastes have some requirements of the root canal obturating materials. They can adapt to the complex internal canal anatomy; however, the flow characteristic can result in extrusion or incomplete obturation. Some pastes are toxic because they include paraformaldehyde therefore they are not used now.

Apical foramen Obturation

Apical barriers (arrow in radiograph) may be necessary in cases with immature apical development, external apical root resorption and where instrumentation extends beyond the confines of the root.

There are several materials that can seal the apical area of the root canal as dentin chips, calcium hydroxide, lyophilized bone, tricalcium phosphate, hydroxyapatite, and collagen.



The barriers are designed to permit obturation without extrusion of materials into the periradicular tissues but are often incomplete and do not seal the canal.

1- Dentin chips : It is taken from shaving the internal wall of the root canal after instrumentation. It is applied in the apical end of the root canal to act as a biologic seal to enhance healing. Contaminated dentin with bacteria decreases the success of the treatment.

2- Calcium hydroxide: It is extensively used as a common apical barrier. Calcium hydroxide has been shown to induce an apical barrier in apexification. It is free of bacterial contamination and may provide a better but imperfect apical seal. It enhances healing by inducing cementum and bone formation.

3- Mineral trioxide aggregate (MTA): It has been successfully employed as an apical barrier material before obturation. MTA is sterile, biocompatible, and capable of inducing hard tissue formation.

Technique:

- a-** After the cleaning and shaping procedures the canal is dried and MTA is placed.
- b-** The material is compacted into the apical portion of the root to form a barrier.
- c-** After the material sets, gutta-percha can then be compacted without extrusion.

Pulp regenerative techniques including revascularization

This technique aims to regenerate the vitality of the pulp and induce apical root development and apex.

Technique:

- 1- Copious irrigation.
- 2- Minimal canal preparation.
- 3- Use of an antibiotic paste as an interim medication.
- 4- At the next visit bleeding is induced in the canal to induce a clot that is covered with MTA.
- 5- When the MTA is set a definitive restoration can be placed to ensure a coronal seal.

Endodontic Emergency Treatment

- Emergency conditions in endodontics induce infection which is expressed as pain and /or swelling. Any irritation to the tissues results in inflammation and release of chemical mediators which with pressure induce pain.
- Chemical mediators cause pain by lowering pain threshold of the sensory nerve fibers or by increasing vascular permeability and producing edema. Increased fluid pressure resulting from edema directly stimulates the pain receptors.

The classification of endodontic emergencies includes (Walton):

A- Pretreatment

1. Dentin hypersensitivity
- 2- Pain of pulpal origin
 - a) Reversible pulpitis
 - b) Irreversible pulpitis
- 3- Acute apical periodontitis
- 4- Acute apical abscess

5. Traumatic injury
6. Cracked tooth syndrome

B- Patients under treatment

1. Mid treatment flare-up.
2. Exposure of pulp
3. Fracture of tooth
4. Recently placed restoration
5. Periodontal treatment

C- Post endodontic treatment

1. Overinstrumentation
2. Overextended obturation
3. Underfilling
4. Fracture of root
5. High restoration

Irreversible acute pulpitis

The diagnosis of irreversible pulpitis can be subcategorized as:

- 1. Asymptomatic:** Asymptomatic irreversible pulpitis means a tooth that has no symptoms, but with deep caries or tooth structure loss that, if left untreated, will cause the tooth to become symptomatic or nonvital.
- 2. Symptomatic:** Pain from symptomatic irreversible pulpitis is often an emergency condition that requires immediate treatment.

These teeth exhibit

intermittent or spontaneous pain, whereby exposure to extreme temperatures will elicit intense and prolonged episodes of pain, even after the source of the stimulus is removed.

- Teeth with irreversible pulpitis with definite periapical inflammatory extension, occlusal reduction is recommended. Antibiotics are not recommended for the emergency management of irreversible pulpitis.

Steps of treatment

1. Clean the root canal(s) to the working length.
2. Place a suitable medicament in the pulp canal and chamber (ex. Calcium hydroxide).
3. Close the access opening with a temporary filling.
4. Check occlusion of the tooth.
5. Prescribe a pain analgesic.

Acute apical periodontitis

It is inflammation of the apical periodontal tissue caused from extension of pulpal infection periapically. It is characterized by the following features:

1. Elevated tooth from its socket because of build up in fluid pressure in the periodontal ligament.
2. Discomfort on biting.
3. Sensitivity to percussion.

Steps of management

- 1- Access opening preparation.
- 2- Total pulp extirpation.
3. Cleaning the root canal.
4. Thorough irrigation and dryness.
5. Placement of intracanal medicament as Calcium hydroxide.
6. Close the tooth with a temporary filling material.
7. Relieve occlusion.
8. Prescribe analgesics.

Acute periapical abscess

Extrusion of bacteria from the root canal to the periapical area induces infection ending in formation of a collection of pus. Acute periapical abscess is characterized by the following features:

1. Clinically a swelling is evident with pain and a sensation of tooth elevation.
2. Radiographic evidence varies in size of lesion.
3. Systemic fever.

Steps of management :

1. Pulp debridement of its contents.
2. Incision and drainage (if swelling is present)
3. If pus is oozing the tooth may be left open for 1 day for drainage.
4. Antibiotics may be prescribed only if systemic features are present as fever.
- 5- Relieve the tooth out of occlusion.
- 6- Analgesics should be prescribed.

Local anaesthetic is contraindicated to be used because:

1. Pain caused by injection in distended area.
2. Chance of spread of microorganisms.
3. Ineffectiveness of local anaesthetics.

Cracked tooth syndrome

It is incomplete fracture of a tooth with vital pulp. It is commonly seen with teeth with large restorations. Pain is experienced when the patient chews laterally a cotton roll.

Steps of treatment

1. Immediately reduce the occlusal contact with the cracked area.
2. Analyze the extent of the crack to preserve the pulpal health.
3. If the pulp is involved and the crack is superficial to the alveolar bone endodontic treatment is necessary.
4. If the crack is below the alveolar bone extraction of the tooth is necessary.

Intra-treatment flare-up

Flare-up is the occurrence of pain, swelling or both during the course of root canal treatment.

Risk factors contributing to flare-ups:

1. Overinstrumentation and overobturation.
2. Inadequate debridement.
3. Periapical extrusion of debris.
4. Preoperative pain, percussion sensitivity and swelling.
5. One visit endodontics in cases of acute apical periodontitis.
6. Retreatment.
7. Apprehension.
8. History of allergies.

Steps of management

1. Reassurance of the patient .
2. Complete debridement of the root canal with no over instrumentation or extrusion of debris.
3. Establishment of drainage if pus is present.
4. Relief of occlusion
5. Calcium hydroxide intracanal medication.
6. Analgesic and antibiotic prescription.

Over-extended treatment beyond the apex

Any extension of an instrument or filling material induces acute inflammation and with the presence of extruded debris will cause infection. Pain is magnified because of the limited area between the bone and the tooth.

Steps of treatment

1. Care should be taken in consideration not to extend instrumentation beyond the apex.
2. Reinstrumentation to the exact working length should be done to insure a apical stop area to prevent extrusion of gutta percha.
3. If gutta percha is extended beyond the apex then retreatment should be performed by special retreatment kits as ProTaper retreatment and D-Race systems.
4. Analgesic should be prescribed.

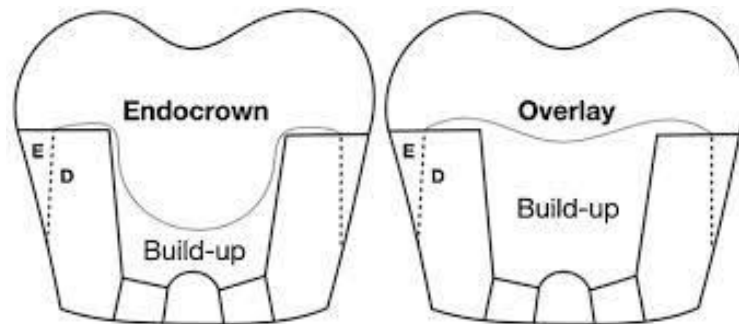
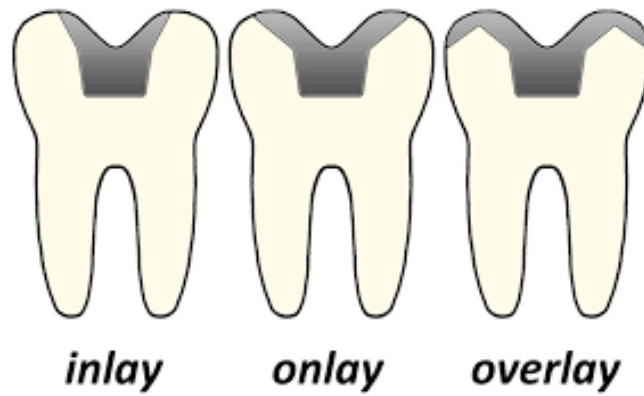
Fracture of tooth

During the course of treatment or after it the tooth may be subjected to force and it might fracture. The treatment depends on the extent of the fractured area (in crown or including root). The steps of treatment resemble that of the cracked tooth syndrome.

Restoration Of Endodontically Treated Teeth

After endodontic treatment, dentin is significantly weakened in shear strength and toughness. This is due to loss of moisture (9%) in dentin and brittleness of the tooth after loss of its vitality.

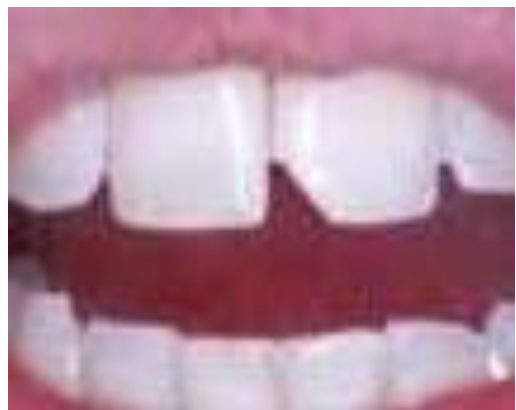Restoring a tooth after endodontic treatment needs to conserve as much remaining tooth structure as possible. Posterior teeth should be restored with restorations that cover and protect the occlusal surface of the tooth as onlay. Crown coverage of teeth is only indicated when the tooth has multiple large restorations or it lost great amount of tooth structure.



Types of treatments according to tooth loss:

Direct Composite Restorations

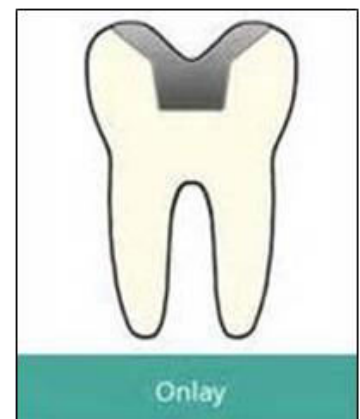
When a minimal amount of coronal tooth structure has been lost after endodontic therapy, a direct resin composite restoration can be done.



Indirect Restorations: Composite or Ceramic Onlays

Ceramic or resin composite onlays can be used to restore endodontically treated teeth. Endocrowns combine the post in the canal, the core, and the crown in one component. Both onlays and endocrowns allow for conservation of remaining tooth structure, whereas the alternative would be to completely eliminate cusps and perimeter walls for restoration with a full crown.

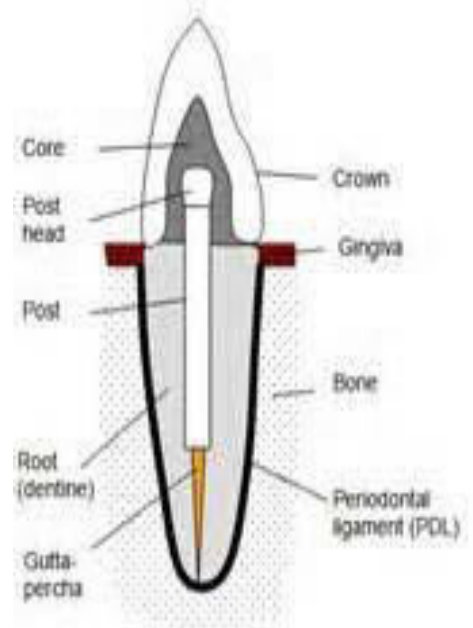
Onlays are constructed in the laboratory from either hybrid resin composite or ceramics. Onlays, overlays, and endocrowns can also be fabricated from resin composites processed in the laboratory. Using various combinations of light, pressure, and vacuum, these fabrication techniques may increase the conversion rate of the polymer and consequently the mechanical properties of the restorative material.



Full Crowns

When a significant amount of coronal tooth structure has been lost by caries, restorative procedures and endodontics, **a full crown** may be the restoration of choice. The crown can be built on the remaining coronal structure which has been prepared accordingly.

In case of **post and core restoration** a **post** inside the root canal is necessary to provide retention for the core material and the crown. The **core** is anchored to the tooth by extension into the root canal through the post and replaces missing coronal structure. The **crown** covers the core and restores esthetics and function of the tooth. An additional role of the post and core is to protect the crown margins from deformation under function therefore preventing coronal leakage. The post and its luting material, the core and the crown will all influence the longevity of the tooth.

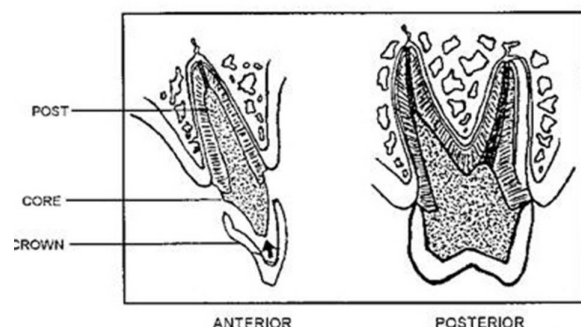


When a post is needed it gives retention to the core but it does not strengthen the tooth against fracture especially metal posts. Adequately condensed gutta percha can be safely removed immediately after endodontic treatment. Both rotary and hot instruments can be safely used to remove gutta percha.

Tapered posts are the least retentive posts and ***threaded posts*** are the most retentive but these threads increase the possibility of stress concentration at the edges of the post and end in root fracture.

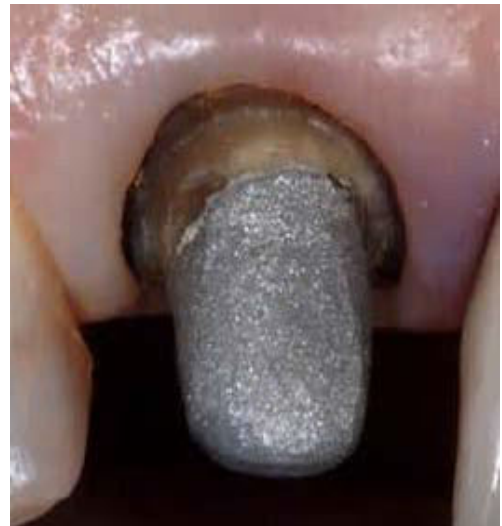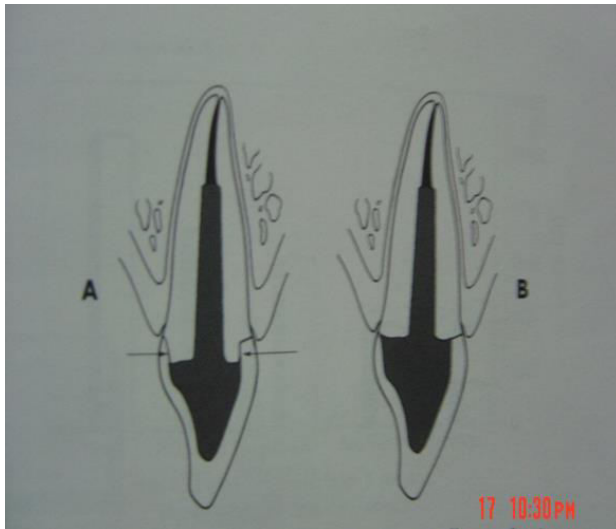
Clinical guidelines for post dimension

1. The post should be $\frac{3}{4}$ the length of the root when treating long rooted teeth or keeping 5 mm of apical gutta percha.
2. The post should be confined to the straight part of the root canal.
3. Post width should be as wide as the width of the treated root canal without extra widening to keep as much tooth structure as possible.



The Ferrule

The more tooth structure that remains, the better the long-term prognosis of the restoration. The coronal tooth structure located above the gingival level will help to create a ferrule. The ferrule is formed by the walls and margins of the crown, encasing at least 2 to 3 mm of sound tooth structure.



A properly made ferrule significantly **reduces the incidence of fracture** in endodontically treated teeth by reinforcing the tooth at its external surface and dissipating forces that concentrate at the narrowest circumference of the tooth. A longer ferrule increases fracture resistance significantly. **The ferrule also resists lateral forces from posts and leverage from the crown in function and increases the retention and resistance of the restoration.**

Requirements of crown shape and crown preparation

1. The ferrule (dentin axial wall height) must be at least 2 to 3 mm.
2. The axial walls must be parallel.
3. The restoration must completely encircle the tooth.
4. The margin must be on solid tooth structure.
5. The crown and crown preparation must not invade the adjacent tissues.

Posts

Dentin has a degree of flexibility and posts can be flexible or stiff. Although no material can behave exactly like dentin, a post with functional behavior similar to that of dentin is beneficial when the post must be placed next to dentin.

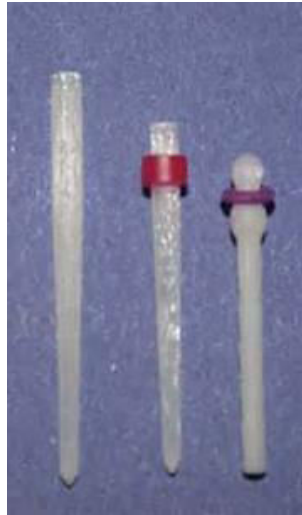Fiber posts have a modulus of elasticity closer to dentin than that of the metal posts. An ideal post should be resilient enough to cushion an impact by stretching elastically, thereby reducing the resulting stress to the root. It would then return to normal without permanent distortion. Therefore, the perfect post would combine the ideal degree of flexibility and strength in a narrow-diameter structure.

Classification of posts

1- Custom made posts (gold or base metal alloys)

2- Prefabricated posts

- a. Metal (gold, stainless steel or titanium posts)
- b. Carbon fiber
- c. Glass fiber
- d. Quartz
- e. Zirconia

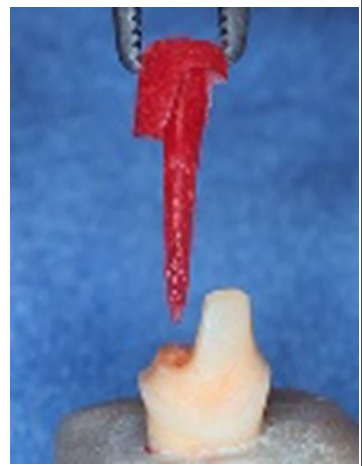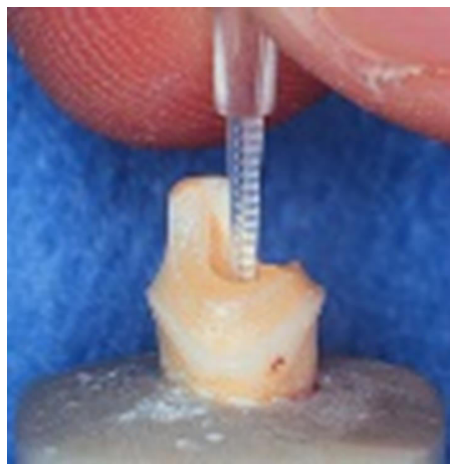
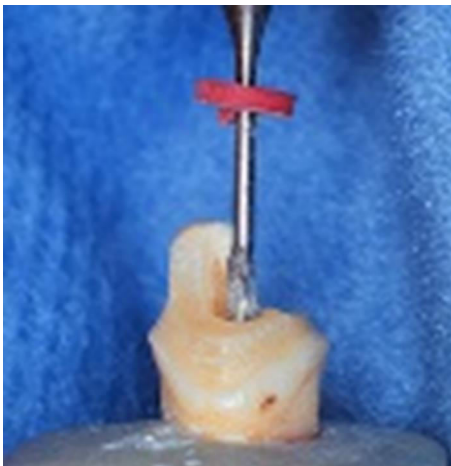


Posts should provide as many of the following clinical features as possible

- 1. Maximal protection of the root from fracture.
- 2. Maximal retention within the root and retrievability .
- 3- Maximal retention of the core and crown.
- 4- Maximal protection of the crown margin seal from coronal leakage .
- 5- Pleasing esthetics, when indicated.
- 6- High radiographic visibility.
- 7- Biocompatibility.

Procedure for post space preparation and post placement

1. Take an x ray to evaluate the condition, length and width of the tooth.
2. Preserve as much as possible of the tooth structure coronally but at the same time offer an easy access of the Pecho drill to the root canal.
3. The gutta percha is removed by the Pecho drill with as minimum tooth structure removal as possible.
4. A suitable sized post should be placed to fit the space in the root canal.
5. The post is cemented in the root canal with a luting agent (composite luting cement or glass ionomer cement) in the root canal.
6. The core is built up with a suitable material as composite or amalgam.



Microbiology in Endodontics

In 1894, Miller's hypotheses stated that bacteria are the causative agent of apical periodontitis. Although there are other reasons such as chemical and physical irritation to the pulp can affect the pulp. This results in various degrees of inflammation.

More than 400 different microbial species have been found in infected root canals, usually in combinations. Fungi have been occasionally found in endodontic infections.

Change in the composition of the microbiota is due to changes in environmental conditions, particularly regarding oxygen tension and nutrient availability.

In the very initial phases of the pulpal infectious process, facultative bacteria predominate. After a few days or weeks, oxygen decrease within the root canal as a result of pulp necrosis and consumption by facultative bacteria. Oxygen supply is affected with loss of blood circulation in the necrotic pulp which develops an obligate microbiota.

Root canal microbes

The most prevalent named bacterial species detected in primary infections belong to diverse genera of

1. Gram-negative bacteria: Fusobacterium, Dialister, Porphyromonas, Prevotella, Tannerella, Treponema, Campylobacter and Veillonella.

2. Gram-positive bacteria: Parvimonas, Filifactor, Pseudoramibacter, Olsenella, Actinomyces, Peptostreptococcus, Streptococcus, Propionibacterium, and Eubacterium bacteria.

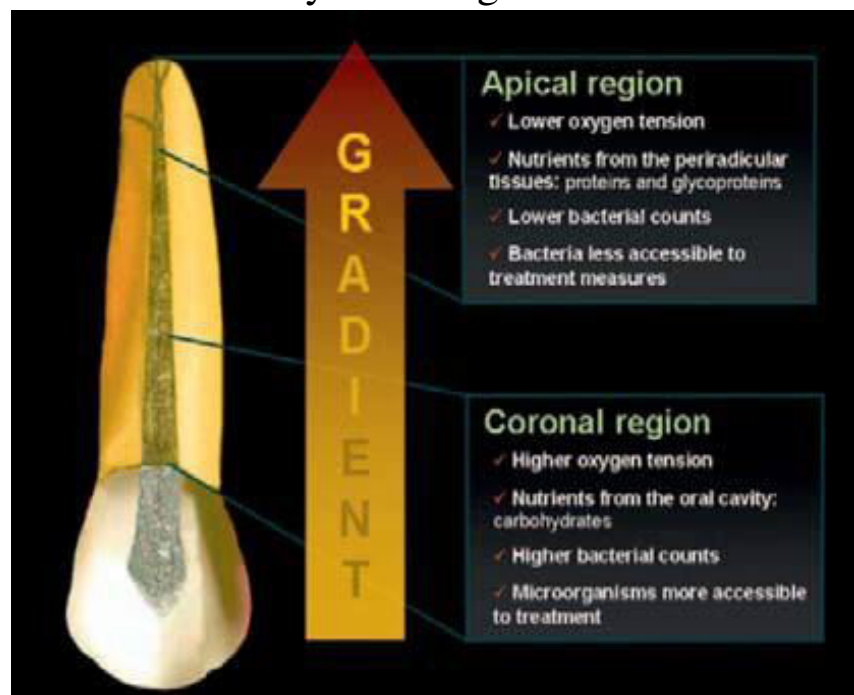
Nutrition of Bacteria

The main sources of nutrients for bacteria colonizing the root canal system include:

1. Necrotic pulp tissue.
2. Proteins and glycoproteins from tissue fluids and exudate that seep into the root canal system via apical and lateral foramens.
3. Components of saliva that penetrate coronally into the root canal.
4. Products of the metabolism of other bacteria.

Pulpal pathways

Bacteria, usually from dental caries, is the main source of injury to the pulpal and periradicular tissues and they enter either directly or through dentine tubules.



Modes of entry for bacteria to the pulp are as follows:

- 1.** Through the carious cavity.
- 2.** Through the dentinal tubules as in contamination during cavity preparation, through exposed root surface, and surfaces with erosion, abrasion and attrition.
- 3.** Through the apical foramen as in advanced periodontitis where microorganisms reach the apical foramen and then the pulp.
- 4.** Through the blood stream (anachoresis). Following trauma or inflammation to the pulp any bacteria in the blood might be attracted to the pulp causing pulpitis.
- 5.** Through faulty tooth restoration.
- 6.** Through extension of a periapical infection from adjacent infected tooth.

Host-parasite interaction

This interaction depends on:

1. Microbial virulence factors

These are microbial products, structural components, or strategies (biofilm formation) in the microorganism that gives it the capability to cause tissue damage. The ability of a microorganism to cause disease is regarded as pathogenicity. Virulence indicates the degree of pathogenicity of a microorganism. Some microorganisms cause disease in a host and are called primary pathogens while other microorganisms cause disease only when host defenses are decreased which are called opportunistic pathogens.

Microbial products as endotoxins, endotoxin enzymes, metabolic end products affect the microbial virulence.

2. Host resistance factors

The reaction of the host to the presence of bacteria or their products can be effective such as:

- a.** Platelet factors.
- b.** Serum factors as antibodies (IgG, IgM)
- c.** Leukocytic factors as lysozymes which hydrolyzes bacterial cell wall of Gram +ve bacteria.
- d.** Macrophages factors.
- e.** Lymphocytic factors as lymphotoxin and macrophage activating factor.
- f.** Salivary factors as lysozyme, antibodies (IgA)

Biofilm and Bacterial Interactions

The community-forming ability is essential for microbial survival in all environments. Most of the microorganisms in nature grow and function as members of metabolically integrated communities called the biofilms.

Biofilm can be defined as a multicellular microbial community embedded by cells that are firmly attached to a surface and enmeshed in a self-produced matrix of extracellular polymeric substance, usually polysaccharide. The ability to form biofilms is regarded as a virulence factor and biofilm infections account for an estimated 65% to 80% of bacterial infections. Biofilms are structurally and dynamically organized complex biologic systems.

Bacterial cells in biofilms form microcolonies ($\pm 15\%$ by volume) that are embedded and non randomly distributed in the extracellular polymeric matrix ($\pm 85\%$ by volume) and separated by water channels.

The matrix is not only important physically as part of the scaffold that determines the biofilm structure, but it is also biologically active and can retain nutrients, water, and essential enzymes within the biofilm.

The matrix can also protect the biofilm community from external danger and may participate in adherence to the surface.

Spread of bacteria in the body

1. Bacteremia

Bacteria especially alpha hemolytic streptococci can enter the blood stream during routine dental treatment. In normal person the bacteria are killed within 10 minutes by the body defense mechanism. Infective endocarditis happens in bacteremia to patients with a history of rheumatic fever with cardiac murmur or mitral valve prolapse.

2. Septicemia

It is a serious life-threatening bacterial (and their products) invasion of the bloodstream. It happens when body defense is low or when the infection overwhelming. It is associated with severe signs and symptoms.

3. Cellulitis

It is an acute infection of the alveolar and loose connective tissue and it is a diffused spread of infection. Clinically in endodontics cellulitis is called flare-up and it happens during access opening because of the environmental change of oxygen level in the root canal which enhances the action of the facultative bacteria and during instrumentation and obturation when debris or obturation material extrude the apical foramen.

Bacterial culturing in endodontics

There are three reasons for culturing root canal contents:

- 1.** To determine the bacteriologic status of the root canal.
- 2.** To assess the efficiency of the debridement procedure.
- 3.** To isolate microbial flora for antibiotic sensitivity and resistance profiles in cases of persistent infections.

Intracanal medicaments

The main use of an intracanal medicament is to help destroy microbes.

- 1. Phenol:** It is an effective medicament in root canal.
- 2. Camphorated phenol:** It is phenol liquefied in camphor. It is less toxic of the phenolic compounds.
- 3. Camphorated monochlorophenol (CMCP) :** It is more toxic than phenol but it is also more active antiseptic but does not last for more than 3 days. It is less irritating than tricresol formalin.

4. Tri cresol formalin: The compound is a mixture of three isomers. It has a powerful antibacterial action that last for upto 7 days.

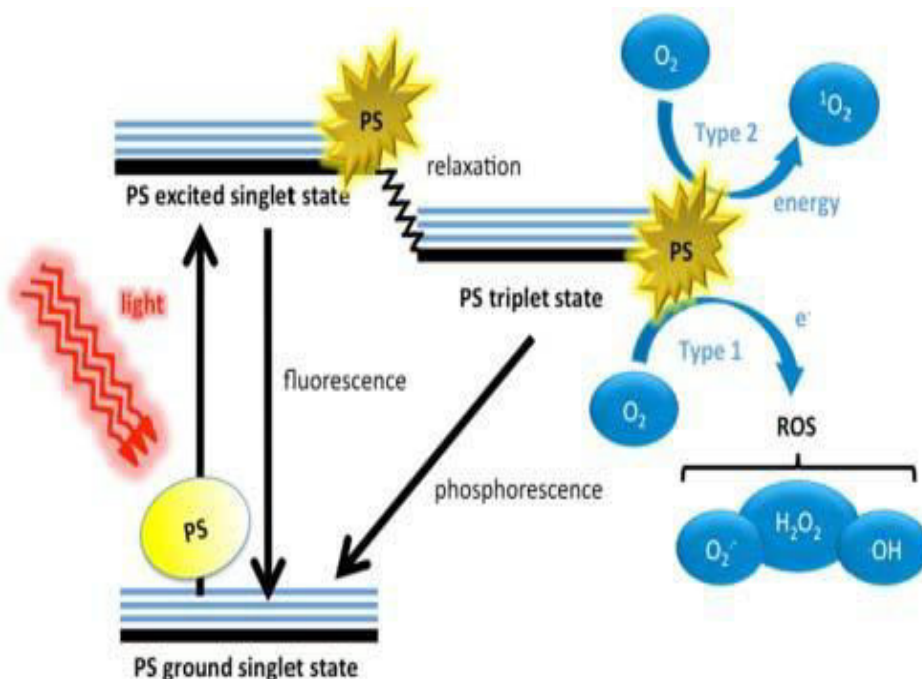
5. Calcium hydroxide: This is biocompatible and can be used to disinfect the root canal for more than one week. The antimicrobial activity of calcium hydroxide is related to of (OH-) in an aqueous environment. Hydroxyl ions(OH-) are highly oxidant free radicals that show extreme reactivity, reacting with several biomolecules .

6. Photoactivated disinfection (PAD)

Is a medical treatment that utilizes light to activate a photosensitizing agent (photosensitizer) in the presence of oxygen. The exposure of the photosensitizer (PS) to light results in the formation of oxygen species, such as singlet oxygen and free radicals, causing localized photo damage and cell death.

Mechanism:

PAD involves **three** components: **light, a photosensitizer, and oxygen.** A PS is administered to the root canal. Upon irradiation with light of a specific wavelength, PS undergoes a transition from a low-energy ground state to an excited singlet state. Then the PS may decay back to its ground state, with emission of fluorescence, or may undergo a transition to a higher-energy triplet state. The triplet state can react with endogenous oxygen to produce singlet oxygen and other radical species, causing a rapid and selective destruction of the target tissue.



Antibiotics in endodontics

Antibiotics are used when infection spreads to the alveolar bone with swelling of the area above the accused tooth and drainage does not relieve the swelling.

Most of the bacterial species involved with endodontic infections are susceptible to **penicillins**, which make them first-line drugs of choice. In more serious cases, including life-threatening conditions, combining **amoxicillin with clavulanic acid or metronidazole** can achieve optimum antimicrobial effects as a result of the extended spectrum of action to include penicillin-resistant strains. **Erythromycin is used in cases of penicillin allergy.**

As a conclusion unnecessary use of antibiotics increases the risk for developing resistant species of bacteria.

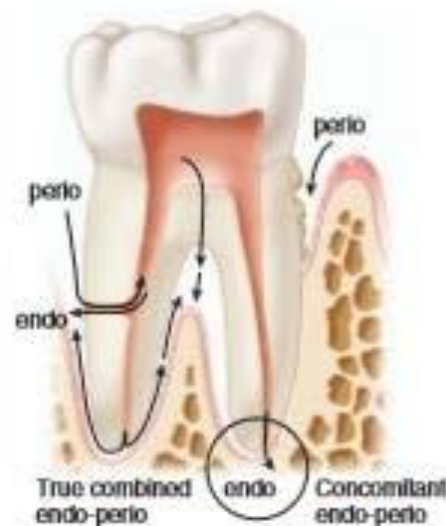ENDODONTICS

Endodontic-Periodontal Relation

The function of the tooth depends on the health of the periodontium (gingival, cementum, periodontal ligament and alveolar bone).

Lateral canals

They are normal anatomical landmarks in the root of a tooth. They differ in their incidence according to their location in the root. They are present more in the apical and bifurcation region. They are a connection between the pulp and periodontal tissue therefore any infection happens in any of these tissues the inflammation spreads to the other. Radiographically the lesion may appear lateral to the root which may be extended coronally to the crestal area of the attachment apparatus or to the bifurcation area.



Dentinal tubules

Interradicular lesions of the attachment apparatus may be seen from inflamed and necrotic pulp tissue connected through the dentinal tubules.

Classification of endodontic-periodontal lesions

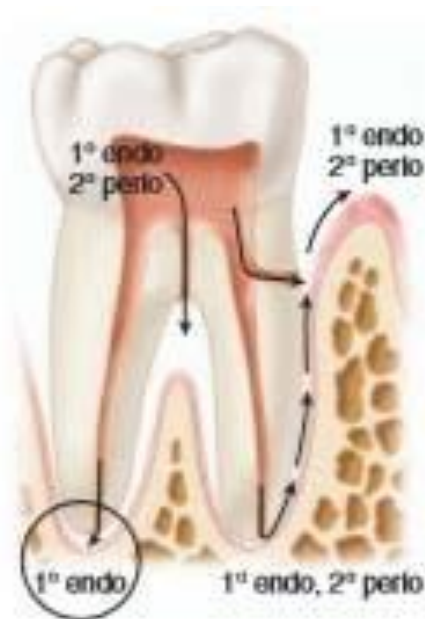1- Primary endodontic lesion.

A sinus tract originating from the apex or lateral canal of the tooth may form along the root surface and exit or drains through the gingival sulcus.

Radiographically. This drainage is seen as a radiolucency along the side of the tooth or in the bifurcation area.

Clinically. Pus oozing through the sulcus area with the presence of localized swelling in the gingival area. The sulcus can be probed by gutta percha cone or periodontal probe to see the extent of bone loss and source of infection. Pain is not often experienced. Vitality tests should reveal necrotic tooth or in multirooted teeth one of the root canal necrotic.

Treatment. Because the source is endodontic, root canal treatment is essential.



2- Primary endodontic lesions with secondary periodontal involvement

If the primary endodontic lesion is untreated, it may become involved with periodontal infection.

Clinically. There is a necrotic root canal with presence of plaque and calculus.

Treatment. Both endodontic and periodontal treatment is necessary to completely heal the infected area.

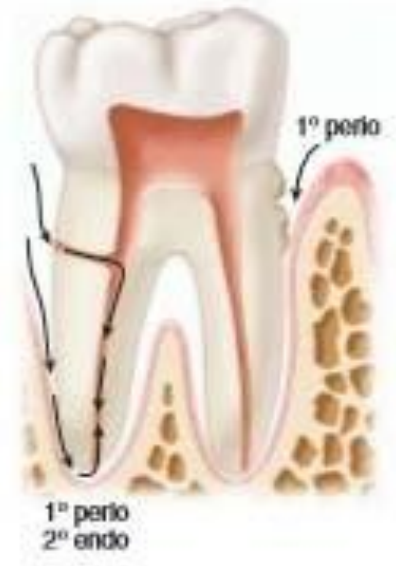3- Primary Periodontal Lesions

Periodontal disease has a progressive nature. It begins in the sulcus and migrates to the apex as deposits of plaque and calculus produce inflammation, causing loss of surrounding alveolar bone and supporting periodontal soft tissues. This leads to a loss of clinical attachment and formation of a periodontal pocket.

Osseous lesions of periodontal origin are usually associated with tooth mobility, and the affected teeth respond positively to pulp testing. The bony lesion is usually more widespread and generalized than are lesions of endodontic origin.

Radiographically there is lateral bone loss indicating a periodontal pocket.

Treatment depends on the extent of the periodontitis and the prognosis depends exclusively on the outcome of periodontal therapy.



4- Primary Periodontal Lesions With Secondary Endodontic Involvement

Periodontal disease can have an effect on the pulp through dentinal tubules, lateral canals, or both. Primary periodontal lesions with secondary endodontic involvement differ from the primary endodontic lesion with secondary peri-odontal involvement only by the sequence of the disease processes. The tooth with primary periodontal and secondary endodontic disease exhibits deep pocketing, with a history of extensive periodontal disease. When the pulp is involved, the patient experiences pain and clinical signs of pulpal disease. This situation exists when the apical progression of periodontal disease is sufficient to open and expose the pulp to the oral environment by way of lateral canals or dentinal tubules.

Radiographically, these lesions can not be distinguished from primary endodontic lesions with secondary periodontal involvement.

Treatment. The prognosis depends on continuing periodontal treatment with endodontic therapy.

5- True Combined Lesions

Pulpal and periodontal disease may occur independently or concomitantly in and around the same tooth. Once the endodontic and periodontal lesions join, they may be clinically indistinguishable. The prognosis of multi-rooted teeth with combined pulpal

and periodontal lesions depends on the extent of the destruction caused by the periodontal disease component.

Differential Diagnosis Between Pulpal and Periodontal Disease

	PULPAL	PERIODONTAL
CLINICAL		
<i>Etiology</i>	Pulp infection	Periodontal infection
<i>Vitality</i>	Nonvital	Vital
<i>Restorative</i>	Deep or extensive	Not related
<i>Plaque/calculus</i>	Not related	Primary cause
<i>Inflammation</i>	Usually Acute	Chronic
<i>Pockets</i>	Single, narrow	Multiple, wide coronally
RADIOGRAPHIC		
<i>Pattern</i>	Localized	Generalized
<i>Bone loss</i>	Wider apically	Wider coronally
<i>Periapical</i>	Radiolucent	Not often related
<i>Vertical bone loss</i>	No	Yes
HISTOPATHOLOGY		
<i>Junctional epithelium</i>	No apical migration	Apical migration
<i>Gingival tissue</i>	Normal	Some recession
TREATMENT	Root canal treatment	Periodontal treatment

Other pathological conditions of enddo-perio. Relations

1- Vertical fracture. A tooth with vertical fracture may have bone loss along the fracture line and affect the pulp and periodontal tissue. Treatment is extraction of the tooth due to poor prognosis of the condition.

2- Developmental grooves. They re present mostly in the palatal surface of the maxillary lateral incisor. This groove extends apically therefore causing localized periodontitis and bone loss along the root surface.

Clinically they are asymptomatic until the epithelial attachment is invaded by plaque and if it reaches the groove then periodontal infection extends rapidly. The pulp may be secondarily infected.

Treatment. Surgical correction of the groove and periodontal treatment. If the pulp is affected then endodontic treatment is necessary.

3- Hemisection and root amputation

When part of a tooth is untreatable it is possible to extract this part and leave the rest of the tooth functional. These procedures are possible due to mny reasons:

- a) Endodontic reasons (separated instrument, root perforation and obstructed canals)
- b) Periodontal reasons (furcation involvement, severe periodontal disease of one root)

c) Restorative reason (caries destruction or erosion of a large portion of the crown and root, perforations during post endodontic preparation or fracture)

Before starting with these procedures, a complete root canal treatment should be done. Hemisection means removal of half of a tooth as a mesial root of the mandibular first molar. In severe bifurcation involvement separation of the mesial and distal roots is possible and later on crowning is done to each root separately. This will ensure a good access for cleaning the furcation area.

Root resection means removal of one root from multirooted teeth without removal any of the coronal tooth structure. This may be in the maxillary molars.

CLINICAL DIAGNOSIS – Radiographic appearance

Radiolucent lesions with gingival sulcus intact Eliminates periodontal disease as cause of lesion

Radiographic appearance of a periodontal lesion RCT completed 4 yr recall – resolution of radiolucency

Walton RE, Torabinejad M. Periodontal endodontic Considerations. Principles and Practice of Endodontics, 3rd Ed. WB Saunders 2002. Pg 466-64

35

CLINICAL DIAGNOSIS – Radiographic appearance

Lesions with narrow sinus type probing

Bone loss from crest around apices & furcation RCT completed 1yr recall, resolution of radiolucency

Walton RE, Torabinejad M. Periodontal endodontic Considerations. Principles and Practice of Endodontics, 3rd Ed. WB Saunders 2002. Pg 466-64

38

CLINICAL DIAGNOSIS – Radiographic appearance

Independent periodontal & periapical lesions that do not communicate

Radiolucency involving distal root surface & extends around apices up mesial root, angular coronal radiolucency at mesial root surface Completed root canal treatment 8 Month recall – marked reduction of distal radiolucency caused by necrotic pulp, mesial lesion same as before

Walton RE, Torabinejad M. Periodontal endodontic Considerations. Principles and Practice of Endodontics, 3rd Ed. WB Saunders 2002. Pg 466-64

40

CLINICAL DIAGNOSIS – Radiographic appearance

True combined perio-endo lesions

Mandibular incisor with large lesion 11 year recall shows resolution of lesion around apex. Angular defect remains

Walton RE, Torabinejad M. Periodontal endodontic Considerations. Principles and Practice of Endodontics, 3rd Ed. WB Saunders 2002. Pg 466-64

42

PERIODONTAL LESIONS OF BONE THAT CAN BE CONFUSED WITH PULPALLY INDUCED BONY LESIONS

Lesions of chronic periodontitis

Both apical & periodontal pathosis evident on second PM Sinus tract exploration with GP cone- source of drainage is periodontal lesion Completed root canal treatment will only resolve the periapical lesion

Gutmann JL, Lovdahl P. Problem Solving in the Differential Diagnosis of Bony Defects Resulting from Pulpal and Periodontal Pathosis. Problem Solving in Endodontics: Prevention, Identification and Management. 5th ed. Mosby 2010. pg 70-86

48

LESIONS FROM PERIODONTIUM THAT DO NOT ORIGINATE FROM PULPAL OR PERIODONTAL PATHOSIS

Vertical root fractures

Radiograph indicating previous root canal treatment and periapical lesion on a mandibular central incisor

Normal probing depth on mesial-labial line angle Normal probing on distal-labial line angle Sinus tract-type probing diagnostic for vertical root fracture

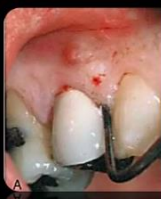Gutmann JL, Lovdahl P. Problem Solving in the Differential Diagnosis of Bony Defects Resulting from Pulpal and Periodontal Pathosis. Problem Solving in Endodontics: Prevention, Identification and Management. 5th ed. Mosby 2010. pg 70-86

61

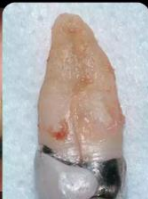LESIONS FROM PERIODONTIUM THAT DO NOT ORIGINATE FROM PULPAL OR PERIODONTAL PATHOSIS

Vertical root fractures

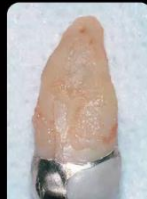Clinical examination showed draining tracts & deep Interproximal probing



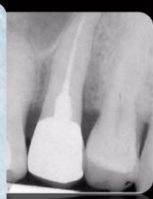Probing on the tooth demonstrates deep, narrow indicating periodontal defect



view of extracted tooth, showing fracture line extending from crown to midroot level



indicating periodontal defect in mesial and distal extending to midroot level

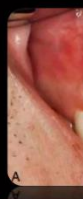

Gutmann J.L., Lovdahl P. Problem Solving in the Differential Diagnosis of Bony Defects Resulting from Pulpal and Periodontal Pathosis. Problem Solving in Endodontics: Prevention, Identification and Management, 5th ed. Mosby, 2010; pg 70-96

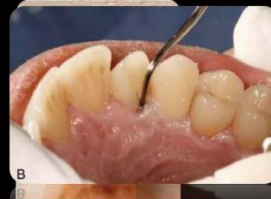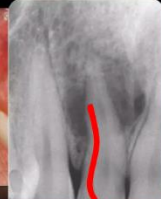60

LESIONS FROM PERIODONTIUM THAT DO NOT ORIGINATE FROM PULPAL OR PERIODONTAL PATHOSIS

Developmental grooves



Sinus tract on labial surface of maxillary lateral incisor



Circumferential probings are demonstrated on an extracted tooth groove

Gutmann J.L., Lovdahl P. Problem Solving in the Differential Diagnosis of Bony Defects Resulting from Pulpal and Periodontal Pathosis. Problem Solving in Endodontics: Prevention, Identification and Management, 5th ed. Mosby, 2010; pg 70-96

62