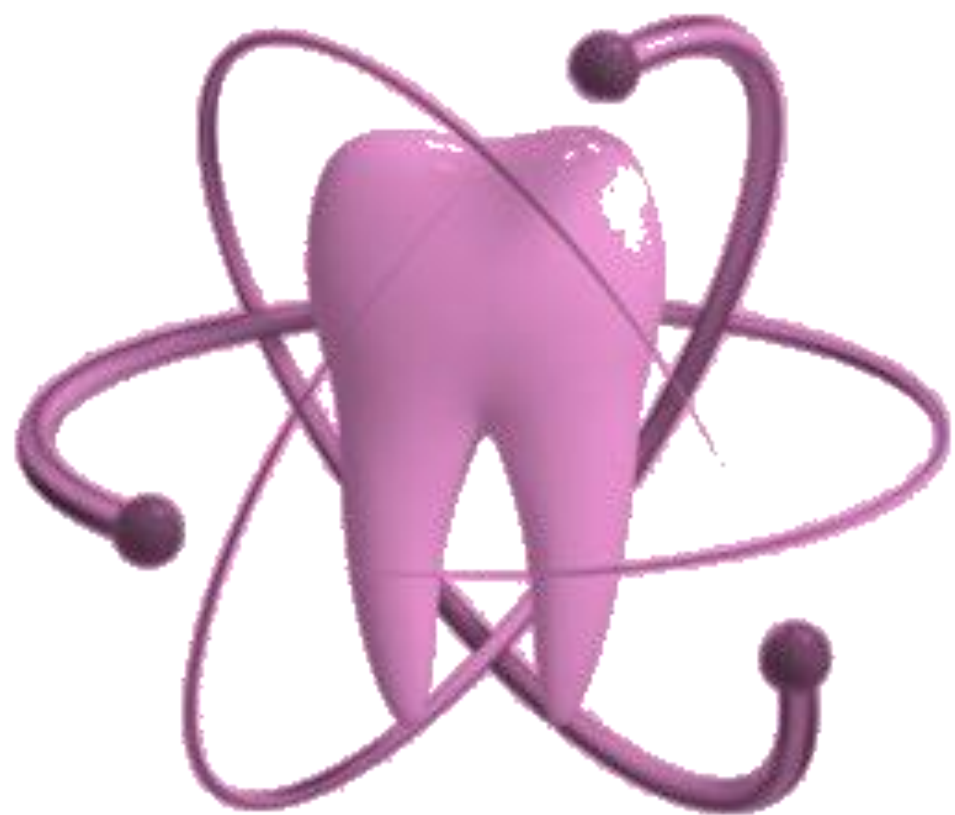


Coloration of Maxillofacial Prosthesis



Abdullah J. Mohammed

**Department of
Prosthodontics**

Maxillofacial appliances fail in two distinct ways:

(1) degradation of static and dynamic physical properties of the elastomers.

(2) color instability in a service environment.

Chromism is a process that leads to a change in the colors of certain compounds. The change is usually reversible. External stimuli, which transfer energy, give rise to an alteration in the density of the electron state of the molecules. The energy is selectively absorbed, and the subsequent reflection of light in different wavelengths is seen as a color change. Temperature, light irradiation, polarity of solvents, gain or loss of electrons, ion exchange, mechanical pressure or friction, and moisture are examples of energy transferring stimuli. Thermochromism is defined as the ability of a substance to change color due to a change in temperature. There are different kinds of thermochromic pigments: liquid crystals, metal oxides or polymer based pigments

Currently Available Materials

- 1. Acrylic Resin**
- 2. Acrylic Co-Polymers (Palmed)**
- 3. Polyvinyl Chloride & Copolymers**
- 4. Polyurethane Elastomers**
- 5. Silicone Elastomers**
 - A.High Temperature Vulcanized Silicone**
 - B.Room Temperature Vulcanizing Silicones (RTVS)**

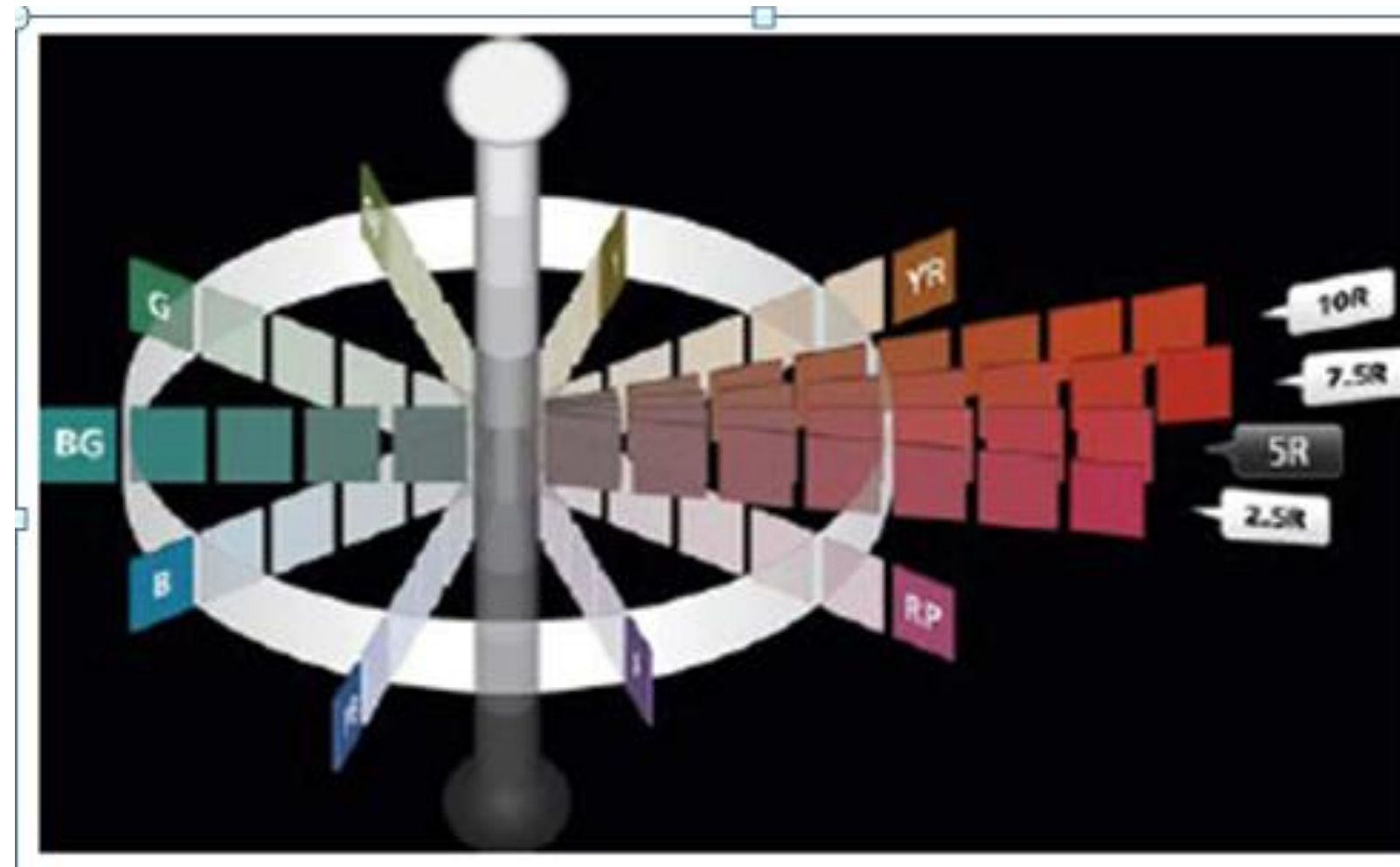


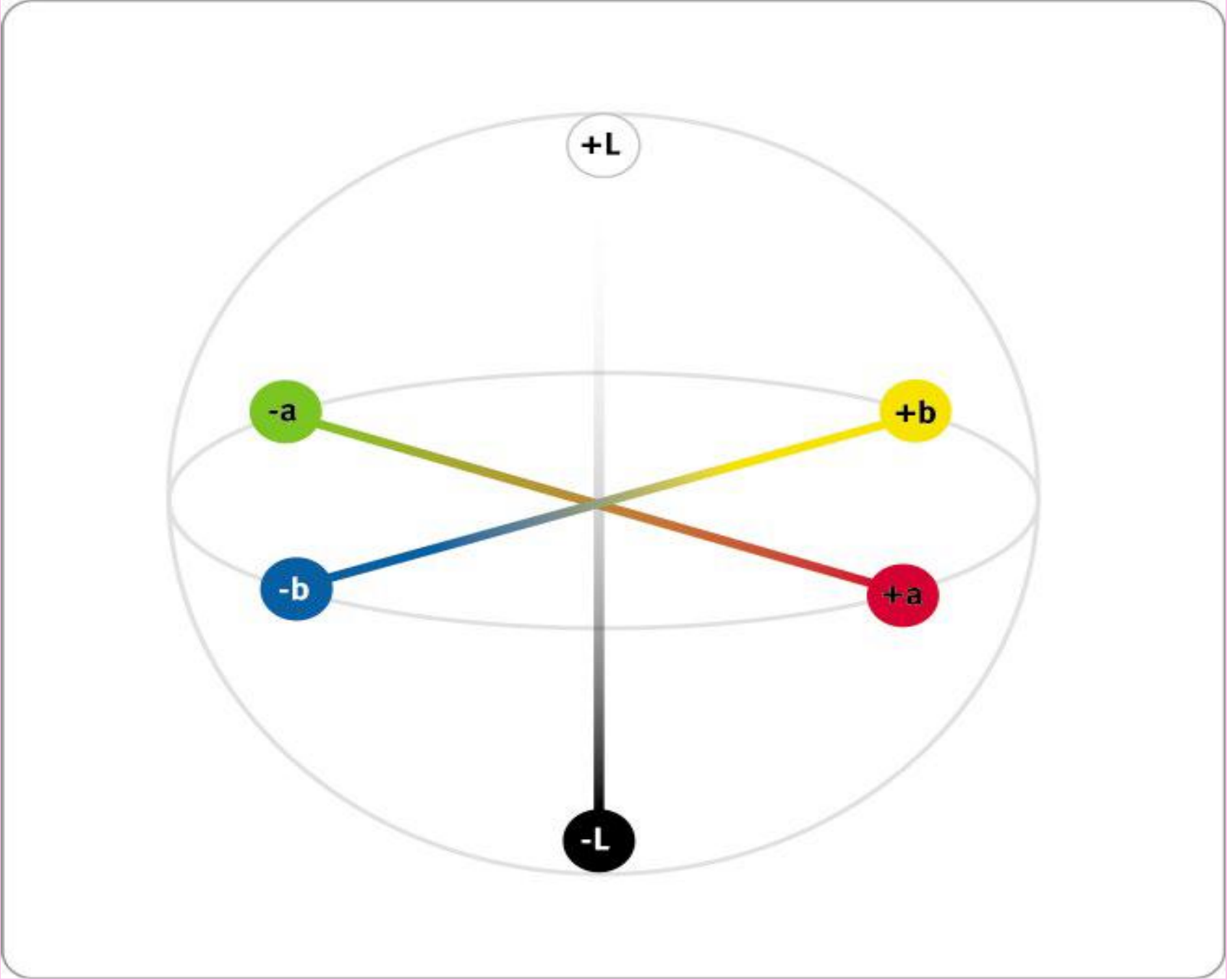
Basic color
theories

Additive
method

Subtractive
method

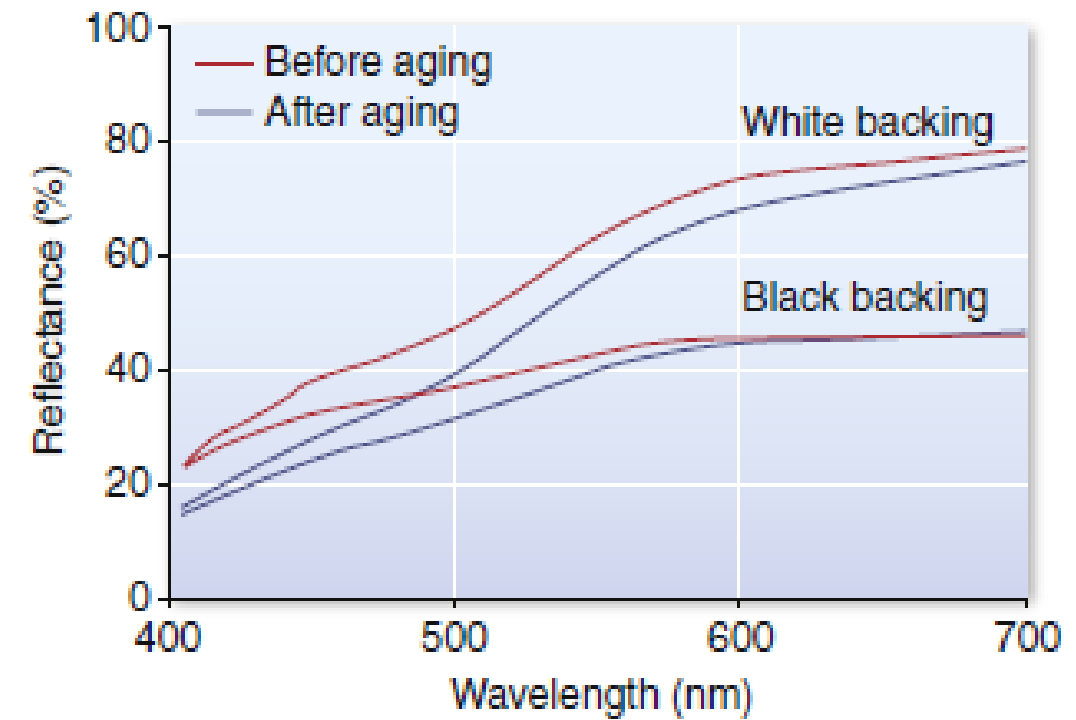
Dimensions of color:





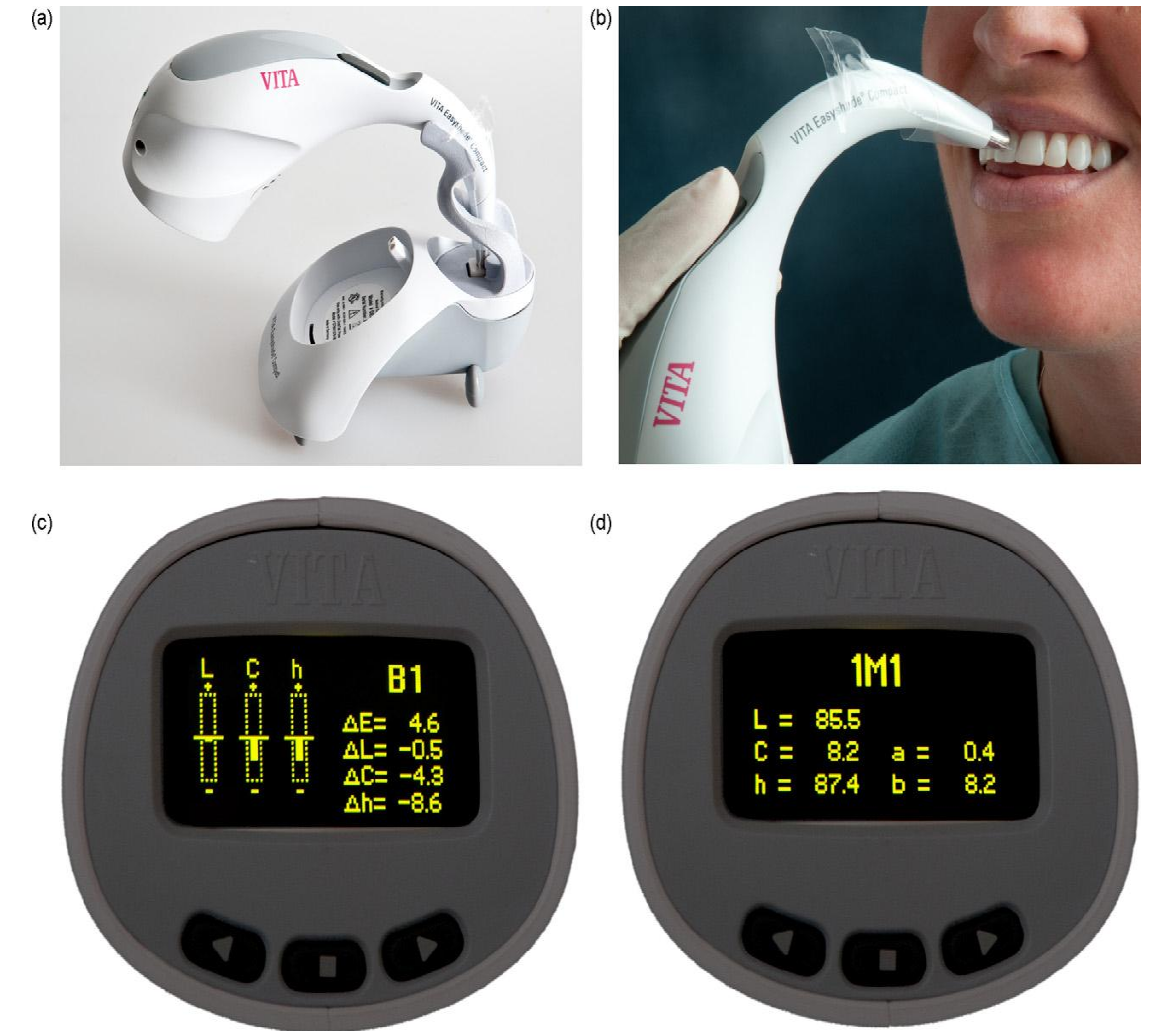Factors affecting maxillofacial prostheses color

1. Humidity
2. Ultra-violet radiation
3. Dust
4. Cleaning, maintenance, disinfection
5. Human secretions
6. Time dependent changes (i.e aging)




Color measurement methods

1. Visual inspection
2. Spectrophotometers
3. Colorimeters
4. Digital cameras and imaging systems



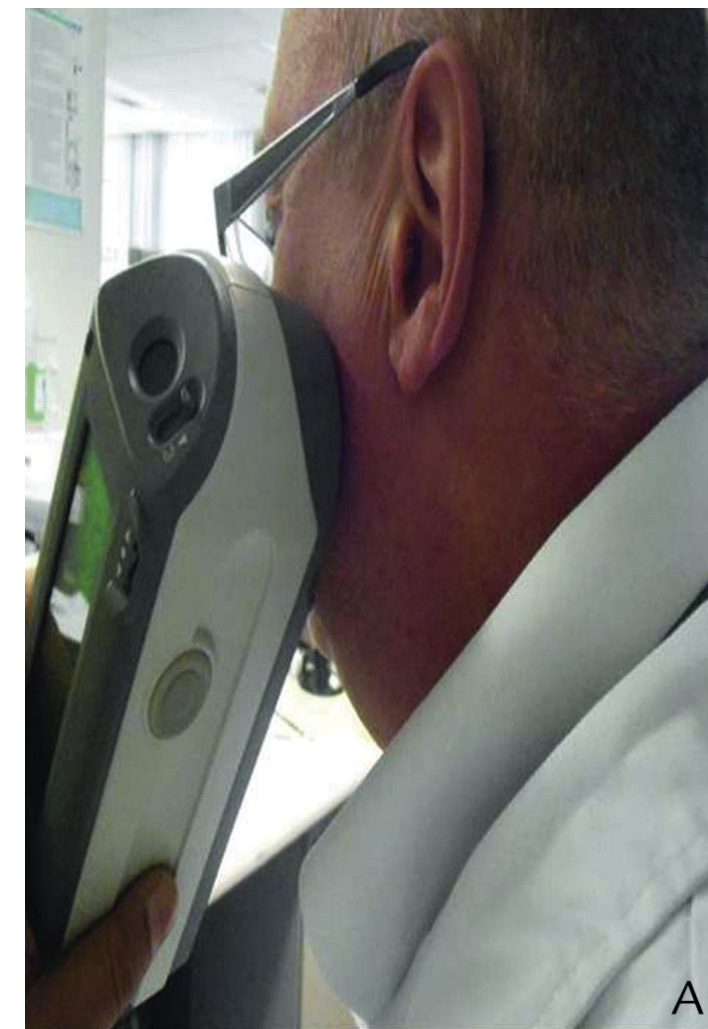
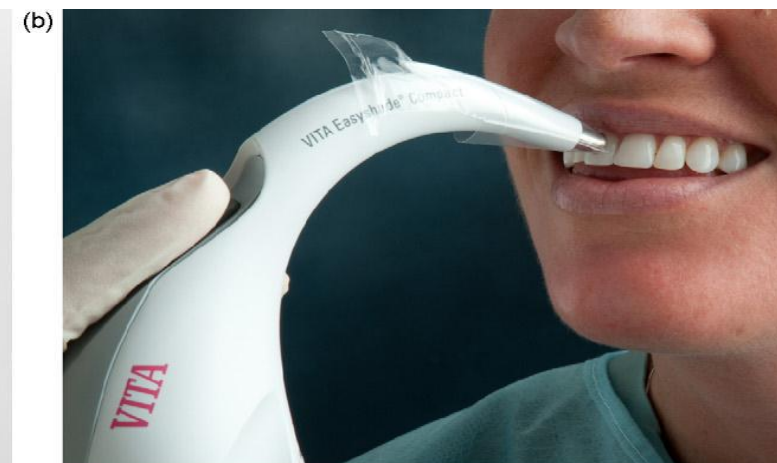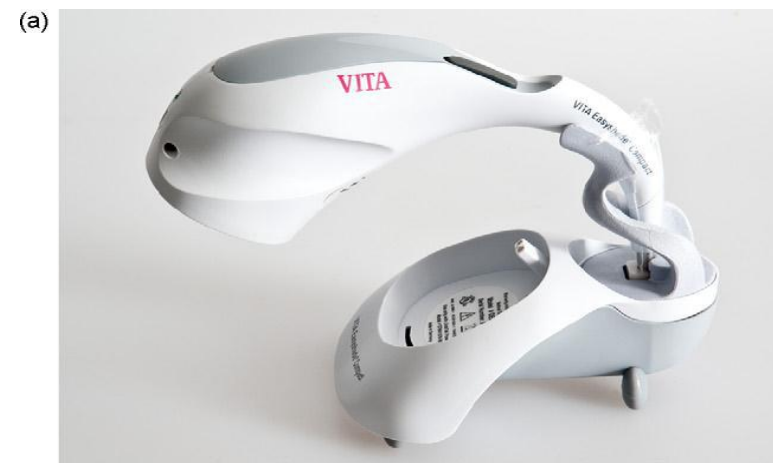Visual inspection

Historically, assessing shade visually has been characterized by several innate difficulties: metamerism, suboptimal color matching conditions, tools and method as well as the receiver's age fatigue, mood and drugs/medications. Despite these difficulties, the human eye can discern very small differences in color. However, the ability to communicate the degree and nature of these differences is lacking .



Spectrophotometers

Spectrophotometers are amongst the most accurate, useful and flexible instruments for overall color matching and color matching in dentistry. They measure the amount of light energy reflected from an object at 1–25 nm intervals along the visible spectrum. A spectrophotometer contains a source of optical radiation, a means of dispersing light, an optical system for measuring, a detector and a means of converting light obtained to a signal that can be analyzed. Compared with observations by the human eye, or conventional techniques, it was found that spectrophotometers offered a 33% increase in accuracy and a more objective match in 93.3% of cases

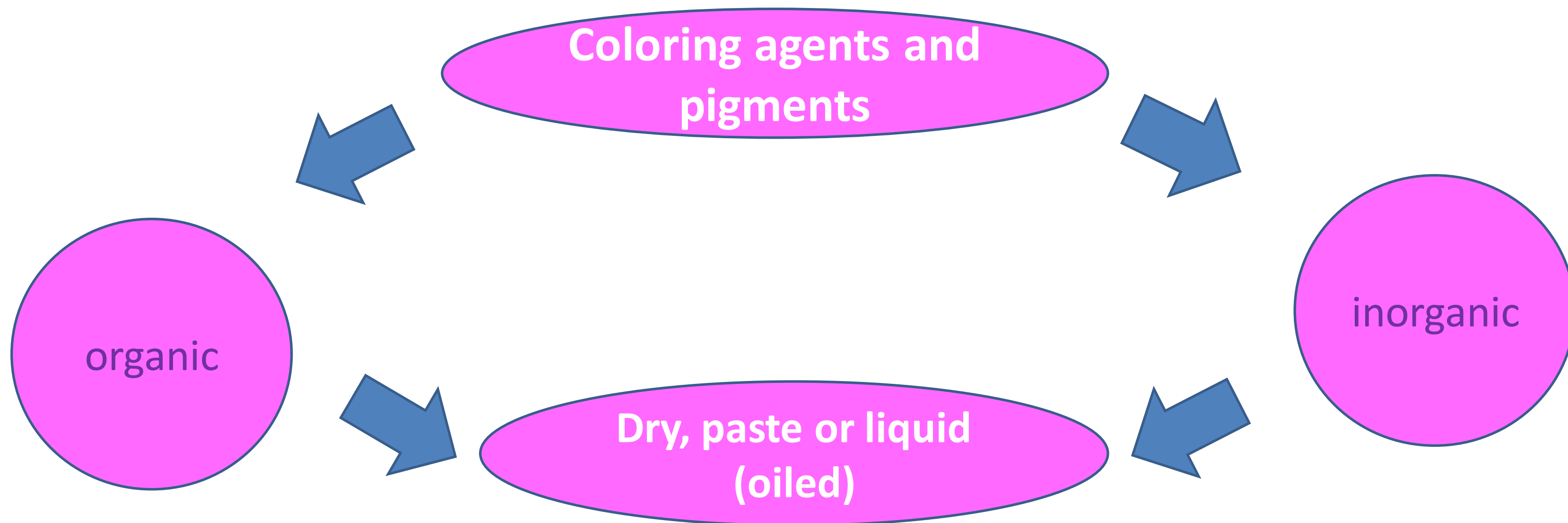


Colorimeters

Colorimeters measure tristimulus values and filter light in red, green and blue areas of the visible spectrum. Colorimeters are not registering spectral reflectance and can be less accurate than spectrophotometers (aging of the filters can additionally affect accuracy)

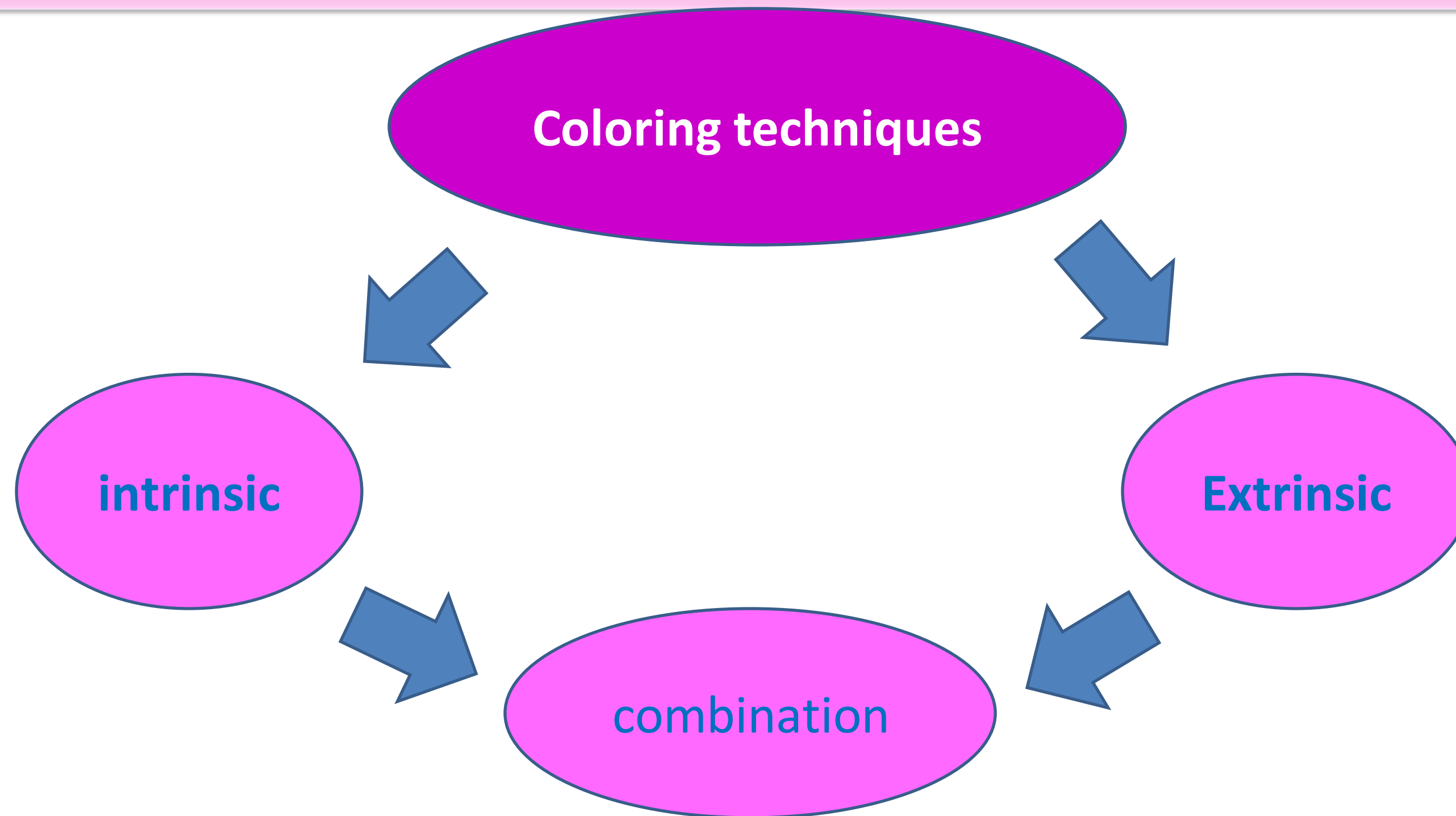
Digital cameras and imaging systems

Most consumer video or digital still cameras acquire red, green and blue image information that is utilized to create a color image. The RGB color model is an additive model in which red, green and blue light are added together in various ways to reproduce a broad array of colors. Digital cameras represent the most basic approach to electronic shade taking . Various approaches have been used to translate this data into useful color information.



Coloring agents and pigments

A maxillofacial prosthesis is characterized and colored with dry pigments, pigment suspensions, dyes or pastes to match the color of adjacent facial structures. The prosthesis should also possess a certain translucency to obtain a life like appearance. Usually the combination of intrinsic and extrinsic coloring makes the color of a pigmented prosthesis match that of human skin. Intrinsic coloration plays an important part in this process since it sets the basic color and translucency. Intrinsic coloring is less vulnerable to environmental conditions and handling than extrinsic coloring. Extrinsic coloration may be applied on the surface of a cured pigmented prosthesis which originally does not exhibit an acceptable appearance match.



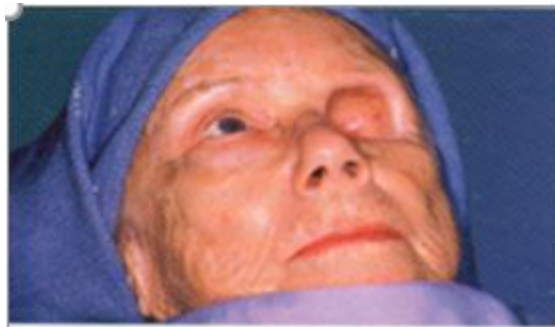Coloration process

Steps of orbital prosthesis fabrication:

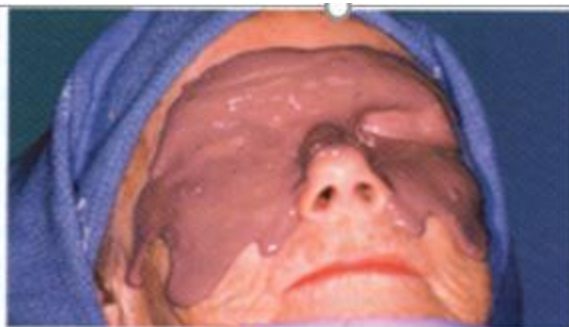
- 1.impression and working cast fabrication.
- 2.sculpture and formation of the pattern.
- 3.mold fabrication.
- 4.processing of the prosthesis material.

Impression:

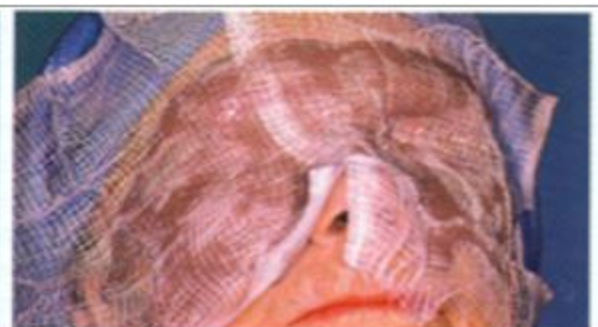Accurate impressions of orbital defects are difficult to obtain because the periorbital tissues are easily displaced. The purpose of the facial impression is to record the orbital and periorbital tissue bed as accurately as is possible. To do so, the patient must be placed in a semi-upright position. During the procedure, the patient should close the remaining eye in a relaxed manner. This will prevent undesirable contraction of residual lid musculature on the defect side and prevent distortion of the defect.



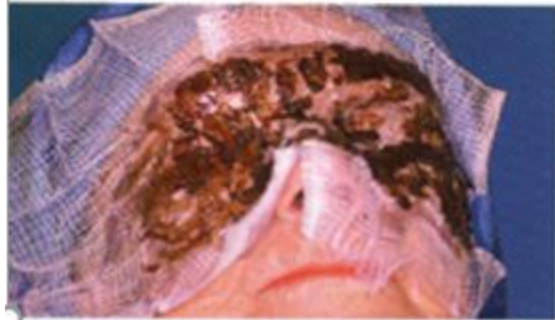
a



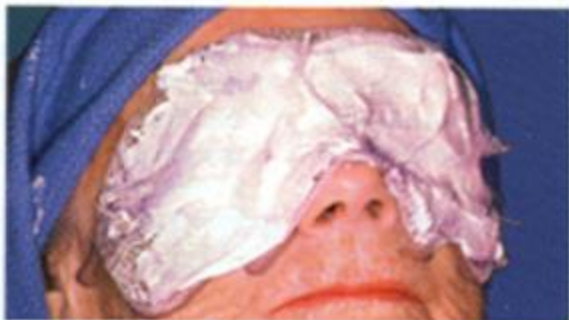b



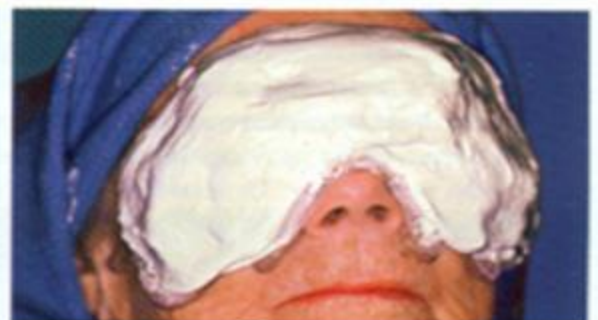c



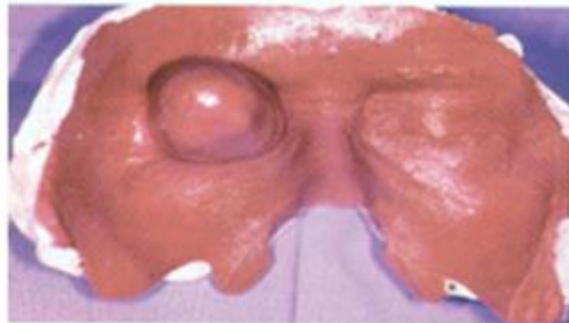d



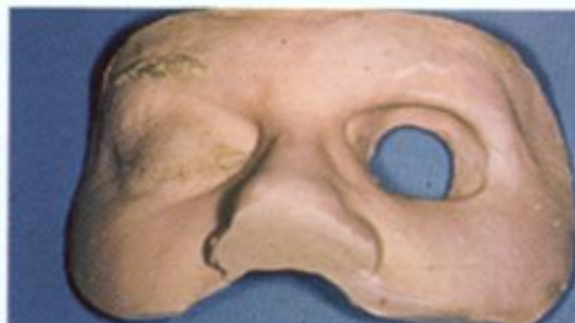e



f



g

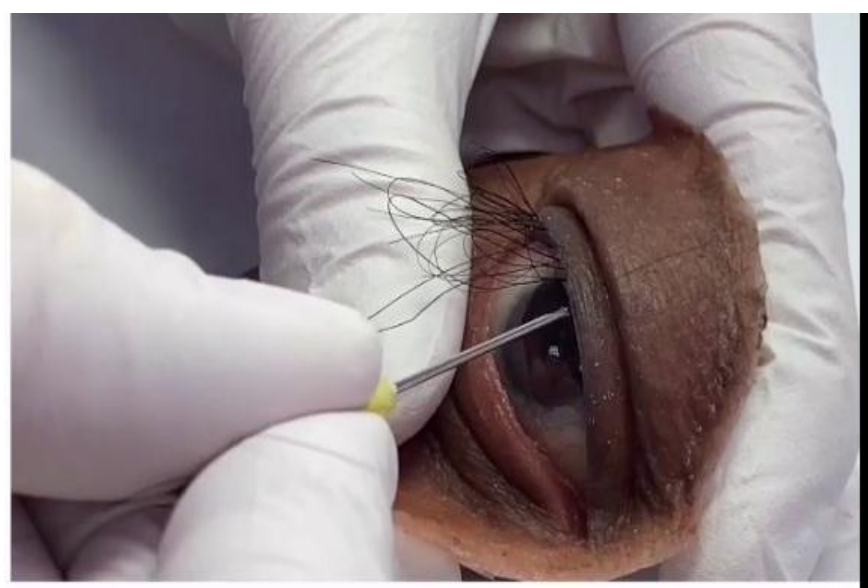

h

Figure 10 orbital impression a:field isolated b:thin layer of impression material applied. c:layer of gauze. d:layer of adhesive e and f: several layers of impression plaster applied to support the impression material. first layer is kept thin to avoid distortion of impression. g: completed impression. h: master cast.

The mold preparation

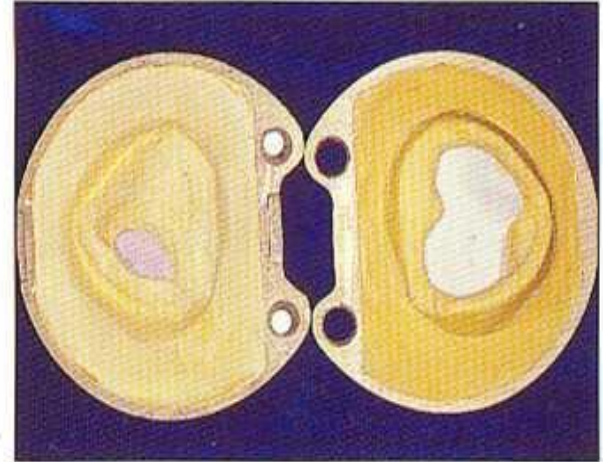
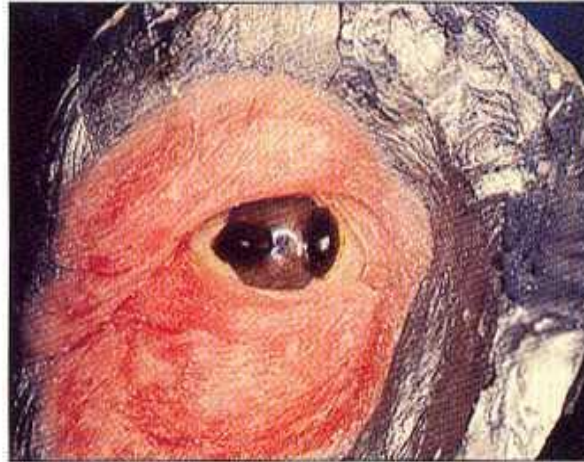
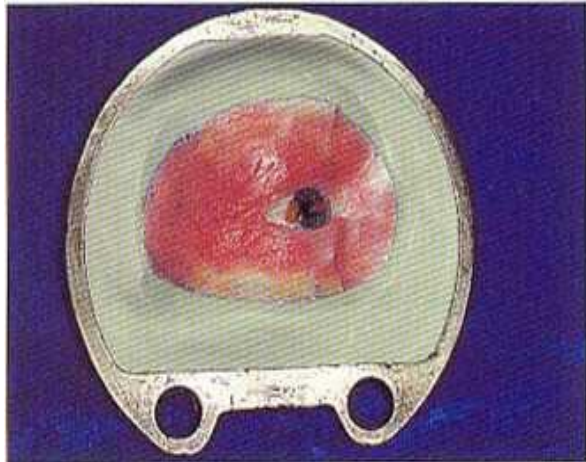
At this step the eyelashes and eyebrows that is ready made or custom made according the preferences of the operator they attach to the wax pattern or could be incorporated in the silicone.



After finishing the try-in step the wax pattern is returned to the stone cast the peripheries of which should be sealed with utility wax to prevent tissue surface contamination.

After this step the stone cast should be cut from all boundaries to make it smaller to match the size of the flask

The cast should be leveled in the cast in such way that the wax pattern in the same level of the upper border of the flask after setting of the 1st layer the stone of the it should be painted without touching the wax, to avoid the adhesion between the stone layers.



The 2nd part of the flask is returned into position and the 2nd layer of the stone is poured.

After setting of the stone layers the wax can be eliminated with heat or hot bath.



The mold now is ready to receive the silicone material.

Usually the presence of the patient is preferable in this stage of lab procedure.

The color of the skin should be matched now with spectromatch device or visually.

The proper color should be matched with proper pigments selected.

The acrylic ocular prosthesis now should be treated to increase the adhesion of the silicone material to the acrylic.

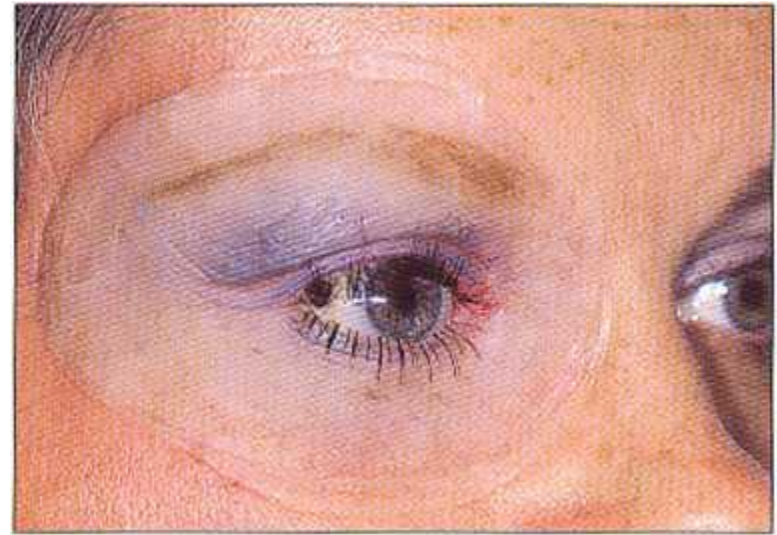
The 1st step is cleaning of the ocular prosthesis for 2 minutes with alcoholic compound like acetone to remove any debris or residues of wax oil or water.

The 2nd step is adding the primer with a brush to the acrylic part that intended to contact with the silicone part the primer layer should be thin and left for 30 minutes

After that the silicone part is added to the mold in the specific areas noting that the ocular prosthesis is not covered entirely with silicone material

If the silicone is room vulcanized one the flask is closed now with a pressure that is recommended by the manufacturer and left for 24 hour for curing

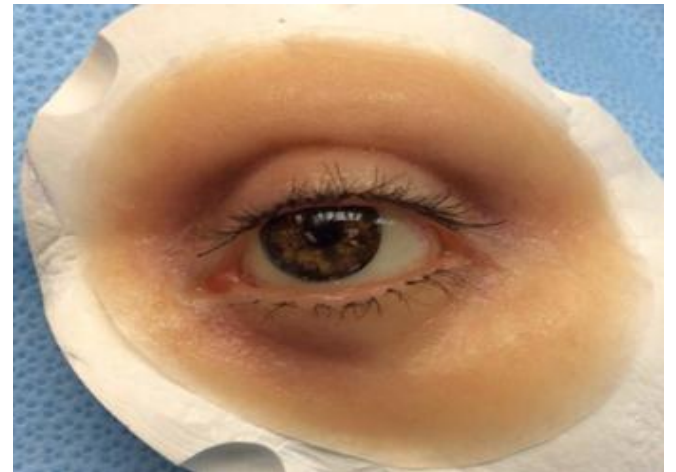
Or if the silicone used is heat cured the flask is pressed and then placed in water bath for 1 hour at 100°C.



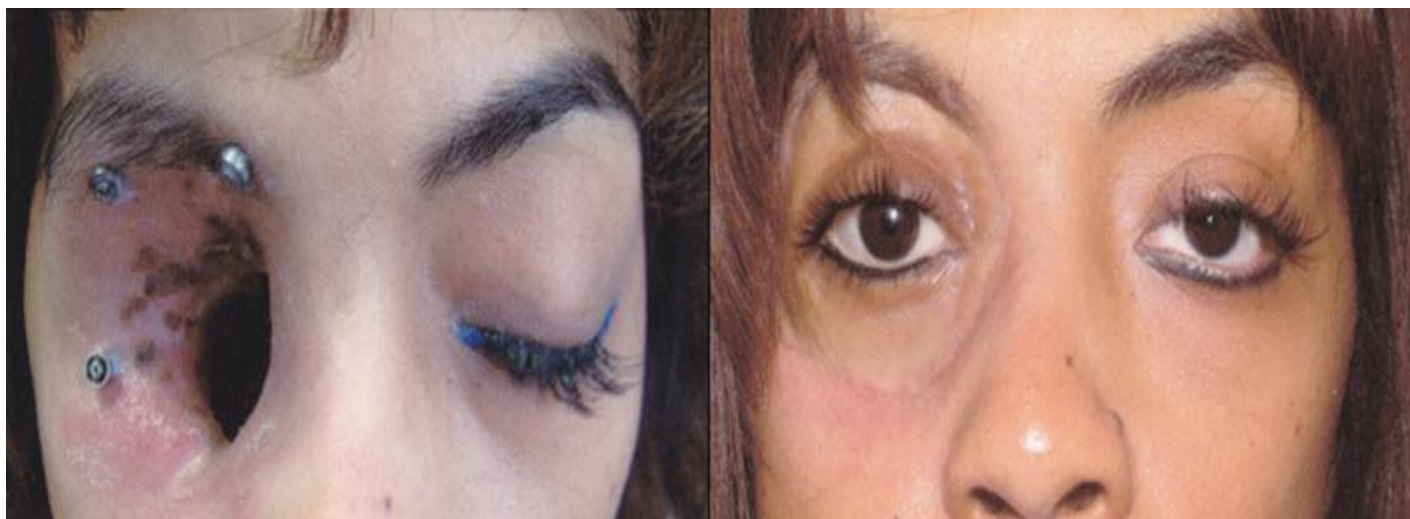Orbital prosthesis

Restoration of Orbital defect

Fabrication of esthetic orbital prostheses is a most difficult challenge. Because slight discrepancies in the position of the eye, lid contour, or color of the prosthesis are immediately noticed by the observer. Surgical resection of orbital tumors is dependent on the nature and extent of the tumor.



Resections that are confined to removal of the orbital contents result in defects that are easier to restore esthetically. As the surgical margins extend beyond the confines of the orbit, prostheses are less esthetic because of the inability to camouflage the lines of juncture between skin and prosthesis and movable tissue beds resulting in further exposure of the lines of juncture



MATERIAL OF PROSTHESIS

An ideal ocular prosthesis must possess optimal durability, flexibility, weight, color, hygiene, thermal conductivity, ease of use, biocompatibility, texture and availability. There is no such prosthetic material that possesses all of the above mentioned properties. Polymethyl methacrylate (PMMA) is considered better than most other ocular prosthetic materials with regard to its durability, biocompatibility, light weight, adjustability, strength, translucency, ease of fabrication, coloring capabilities, availability and cost.

However, acrylic can result in allergy leading to irritation, redness, excessive secretions, swelling etc. Ocular prosthesis made of cold or heat polymerizing acrylic resin, tooth colored acrylic resin, Room Temperature Vulcanizing(RTV) silicone has been recommended for making ocular prostheses, since they provide better esthetics compared with acrylic due to their flexibility and less weight. Glass made eyes is difficult in handling and adjustment.

Maxillofacial Materials

Ideal requirements of Maxillofacial Materials

1. These materials must be biocompatible, easy and inexpensive to fabricate, strong and durable.
2. The prosthesis must be skin-like in appearance and texture.
3. It must be color stable as it is subjected to sunlight (including ultraviolet light) heat, and cold.
4. It must be easy to clean and manage by the patient.
5. Facial prosthesis are often constructed with thin margins to enable blending to the skin. This is then attached to the skin with adhesives. On removing at night, the thin edges can tear. It must be resilient enough to prevent tearing.

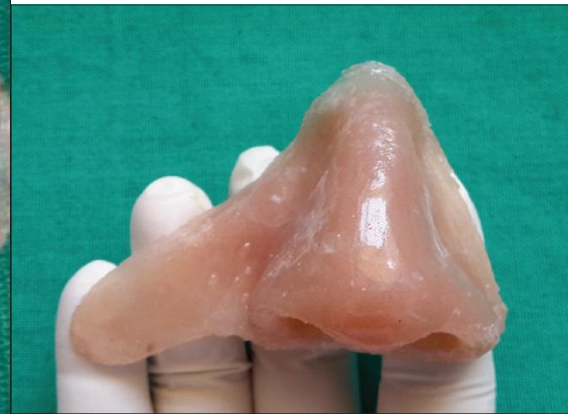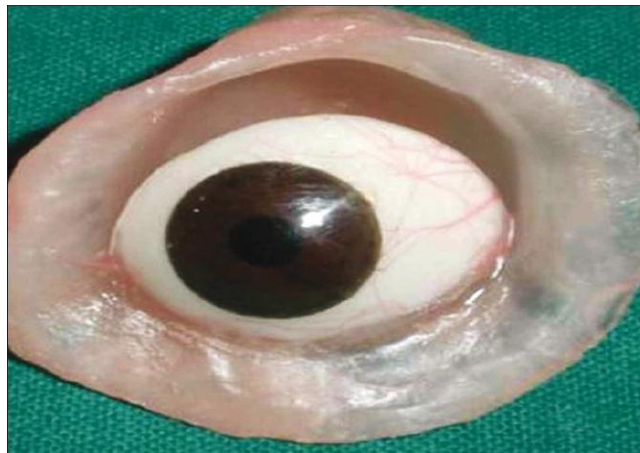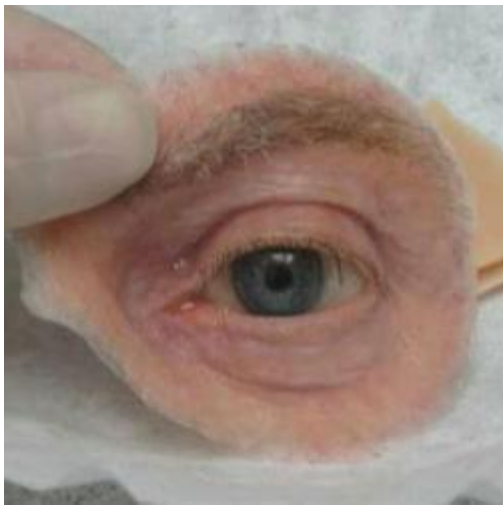6. The water absorption of the prosthetic material is important since facial prosthesis may absorb saliva or sweat from surrounding facial tissue. During washing, the prosthesis can absorb water. Any absorbed water may affect the physical properties and also affect the perception of color matching to the surrounding facial tissue.

7. It should be hygienic and prevent growth of microorganisms.

8. It should have translucent properties of the part it is replacing.

Poly (Methyl Methacrylate) (1940–1960)

It was once commonly used for maxillofacial prosthesis. It is readily available, easy to manipulate, strong, color stable, hygienic and durable. Its usefulness in extra-oral prosthesis is limited because acrylic is hard and heavy, does not move when the face moves and does not have the feel of skin. Particularly used in cases where there is least movement of tissue bed during function.



Acrylic resin has been used in cases when the least movement of the tissue bed is expected during function. It has various advantages including color stability, easy to process, can be relined and repaired, has good strength, can be fabricated with feather margin, and a good shelf-life of about 2 years. However, this material lacks flexibility or the ability to absorb water or adaptability to adjacent soft tissues

Methods of retention

surgical

Surgical
pocketing or
wiring

Bone anchorage
(implants)

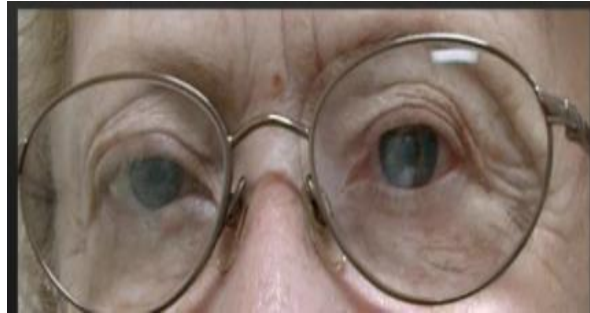Magnets

Bar and clips

Non-surgical

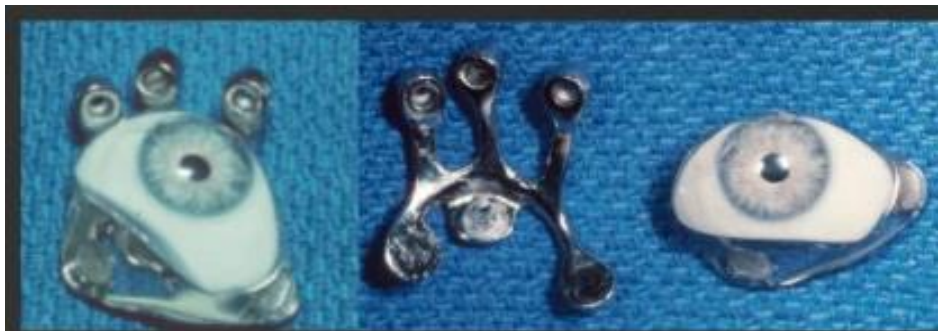Mechanical aids
like glasses

Chemical
adhesives

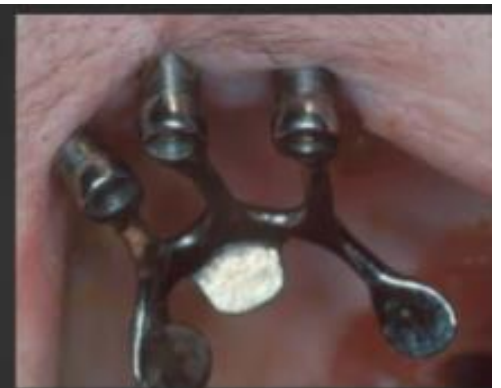

Retention of orbital prosthesis:

Tissue adhesives and/or engagement of undercuts provide suitable retention for most defects. If the resection extends onto the cheek and movable tissues, the use of osseointegrated implants is preferred, may be in addition to bar or magnets, or connected to the maxillary prosthesis



Ocular portion fits within the confines of the silicone prosthesis.



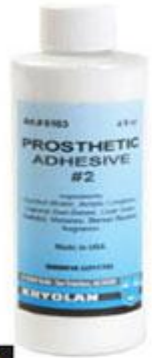Bar secured

- Adhesive

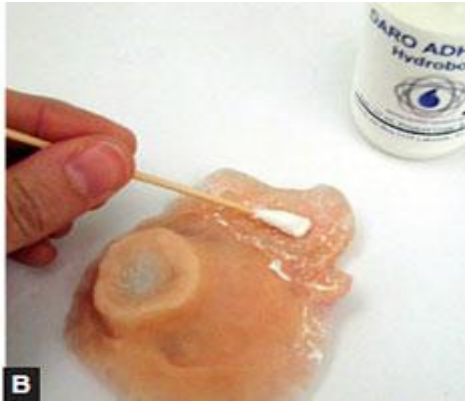Medical adhesives are more often classified according to their use. double-sided tape, glue, sprayers, pastes, and liquid systems are classified according to the silicone substrate. Double-sided tape is the most highly preferred type of adhesive due to its ease of application, easy removal, and renewability, but it has low flexibility and the need for frequent reassembly due to the loss of stickiness. Adhesives and solvents may adversely affect the physical and optical properties of the maxillofacial elastomers.

Disadvantages of using adhesive

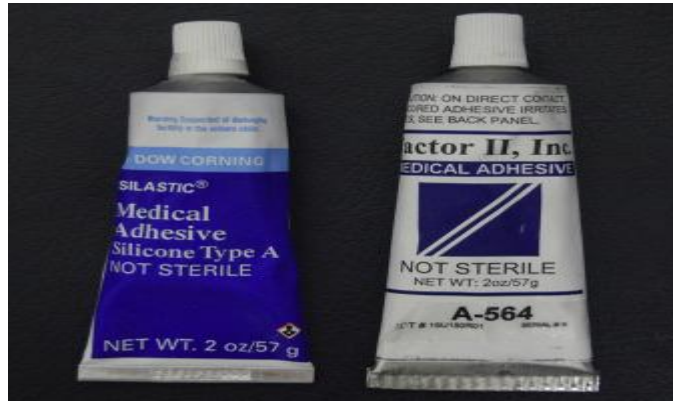Damage both the prosthesis surface and the skin during insertion and removal. They do not provide sufficient adhesion against gravity, sweating, and tissue movement, cause contact dermatitis, cause a change in the color of the prosthesis



A



B



Implant

The most significant problem in the placement of facial implants is insufficient bone volume. Bone thickness in the temporal and supraorbital regions, suitable places for implant placement, ranges between 3 and 6 mm; hence, extraoral implants were designed to be 3–4 mm long and 5 mm in diameter. Extraoral implants have wing extensions and holes to provide mechanical stability and retention. It has been reported that these wings may cause bacterial involvement, debris accumulation, and infection



An anatomical illustration of a human skull, specifically the maxilla (upper jaw). A large, dark, oval-shaped implant is positioned in the center of the maxilla. Several green, cylindrical structures, likely representing dental implants or screws, are visible around the perimeter of the main implant. The background is a light tan color, and the overall image has a slightly grainy, medical illustration quality.

Primary implant site

- Supraorbital rim
- Thick cortical bone
- Periosteal blood supply

Other retention methods

In cases where an implant or adhesive systems cannot be used for a variety of reasons, eyeglasses can be used effectively. When eyeglasses have thick, opaque frames, they help to camouflage the prosthetic margins, however, the patient's prosthesis is removed when the eyeglasses are removed, an unacceptable situation.

Overview of Prosthetic Eye Making and Fitting

A prosthetic eye is made up of two basic components – an iris/corneal unit and the white scleral body of the prosthesis. An iris disc is painted to match the patient's companion iris and a cornea is added to this to make up the iris/corneal unit. This is then incorporated into a wax pattern that has been formed from an impression of the eye socket. The wax is molded to suit the socket and used as a pattern for the final PMMA prosthesis. There are usually four clinical sessions interspersed with laboratory processing that make up the process of prosthetic eye making and fitting .

At the first clinical session, an impression is taken of the socket, and a PMMA disc is trimmed to the diameter of the iris. The iris colors are matched directly to the patient's natural eye and applied to the disc using finest grade oil paints and the smallest of sable hair brushes. When dry, a clear PMMA cornea is processed over the top of the painted iris, and an iris/corneal unit is produced.

During the second clinical session, this iris/corneal unit is imbedded into a wax pattern made from the impression of the socket, and the whole is inserted into the eye socket. The wax is shaped and molded until the size of the eye, direction of gaze and the eyelid contour are established. After the session, a plaster mold is made, and the wax pattern is replaced faithfully with white PMMA. The surface is roughened and the cornea is cut back leaving a thin layer covering the painted iris beneath.

The third clinical session involves applying a second coat of paint to the iris and coloring the sclera with yellows, blues and greys fine veins, teased from cotton thread are then added to the sclera. Once this is done, a clear PMMA veneer is processed over the surface of the prosthesis and finished off with a high polish.


At the fourth clinical session, the completed prosthetic eye is inserted into the socket, and final adjustments are made. The majority of prosthetic eyes are successfully completed within these four clinical sessions, but if the appearance and/or function is not satisfactory, further fittings and sometimes further surgery are required to achieve an optimum result.

Creating the Iris/Corneal Unit

The process begins by measuring the iris diameter of the patient's companion eye using calipers. The actual iris diameter is about 0.5 mm greater than the physical iris diameter due to magnification by the cornea, and this should be taken into account by using an iris disc about 0.5 mm smaller than the measurement. Techniques for creating an iris/corneal unit range from ordering finished units from a catalogue or ordering kit, to purchasing premanufactured clear




corneal buttons (with or without a pupil) used in conjunction with ready to paint iris discs, to making up the iris/corneal unit without any premanufactured components. Whichever method is used for creating the iris/cornea, the process starts with the patient seated in a comfortable position facing good light.



Premanufactured Iris Discs and Corneas

Iris discs with accompanying clear corneal buttons with pupils are available in various sizes from ocular supply companies. A major advantage of using premade components is that it avoids the need for iris discs and corneal buttons to be made from metal dies which are also available. A rod of sticky wax is attached to an appropriately sized iris disc so that it can be easily handled during the painting of the iris colors. A drop of water maybe applied periodically to the center of the iris and the corneal button placed over it.

This will enable the colors to be seen as they will appear when the cornea is permanently sealed to the iris disc. On completion of the painting, the corneal button is cemented to the iris disc using monomer-polymer syrup, cyanoacrylate adhesive or Dentsply triad light cure gel with bonding agent. The completed iris/corneal unit is now set aside ready for the next stage.




Ocular prosthesis:

Anophthalmia, is the medical term for the absence of one or both eyes. Both the globe and ocular tissues are missing from the orbit. The absence of the eye will cause a small bony orbit, a constricted mucosal socket short eyelids, reduced palpebral fissure. Anophthalmia is an extremely rare disease and is mostly rooted in genetic abnormalities. It can also be associated with other syndromes.

Etiology of eye loss:

- **Congenital anophthalmia:**
- Primary anophthalmia is a complete absence of eye tissue due to a failure of the part of the brain that forms the eye.
- Secondary anophthalmia the eye starts to develop and for some reason stops, leaving the infant with only residual eye tissue or extremely small eyes which can only be seen under close examination.
- Degenerative anophthalmia the eye started to form and, for some reason, degenerated. One reason for this occurring could be a lack of blood supply to the eye

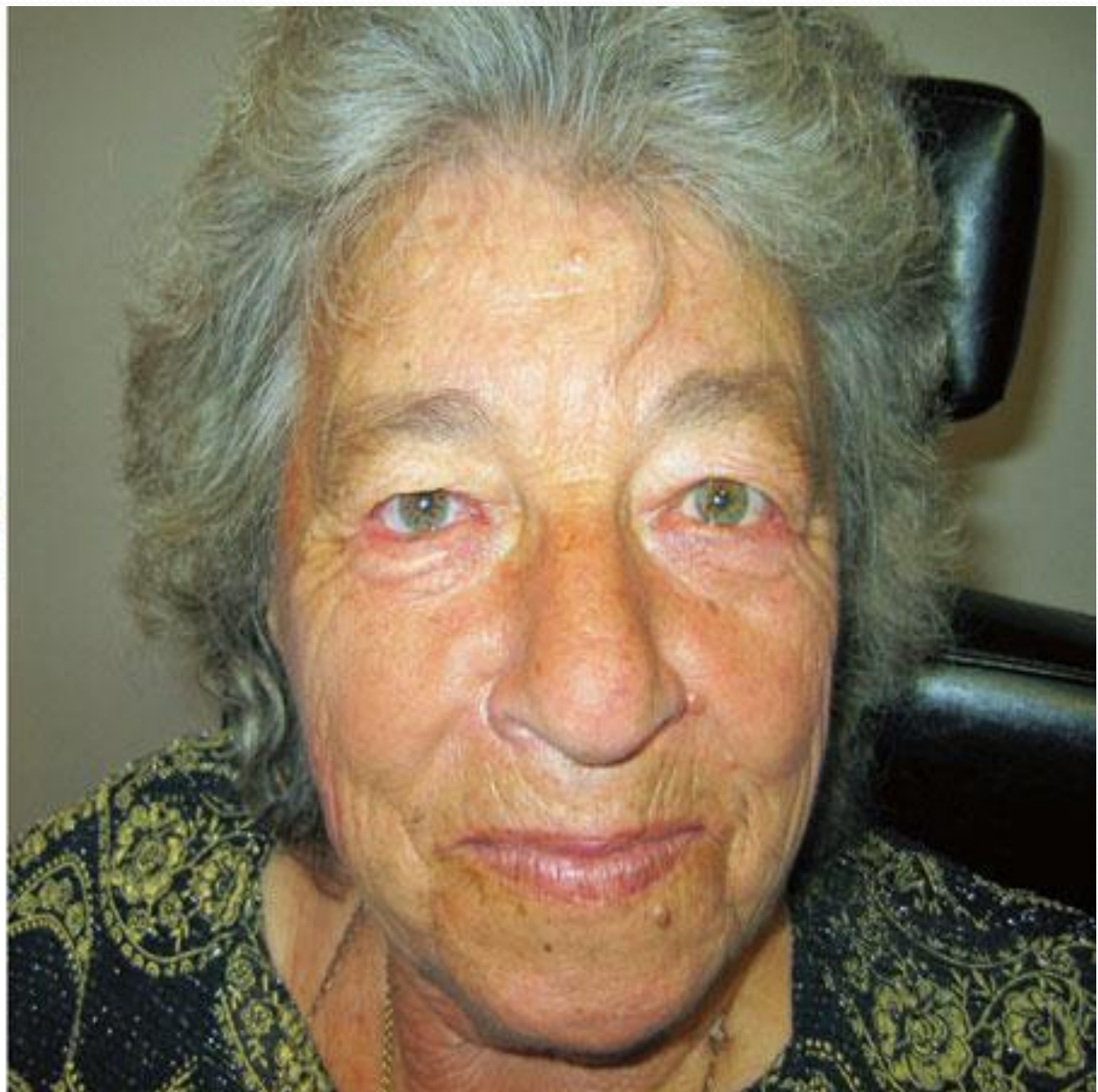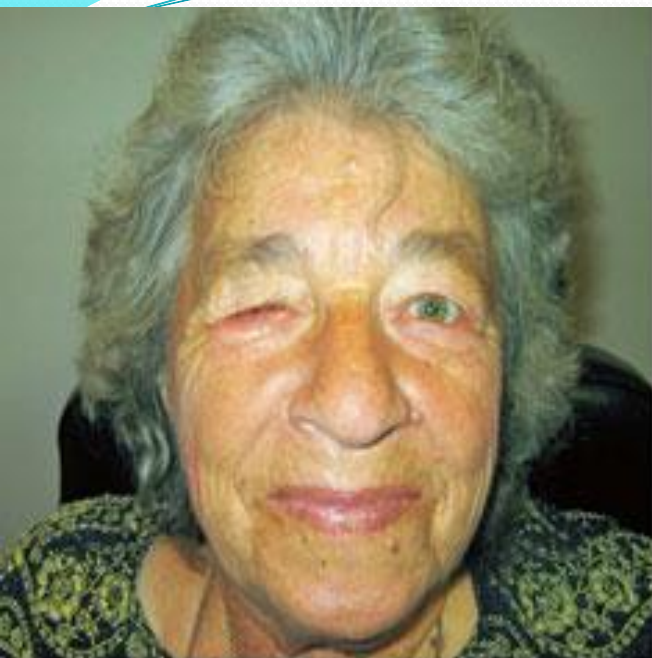- 
- **Acquired anophthalmia:**
 - Due to accidents
 - Due to surgical removal, because of diseases like glaucoma (inflammatory mass), and carcinoma which leads surgical removal either partially or completely.

Perceptual Changes Accompanying Eye Loss:

The loss of an eye requires perceptual adaptations because of the loss of binocular cues to depth and the reduction in visual field on the affected side. The following personal comments from patients describe some of the problems they have experienced with judging . The loss of cues to depth perception as a result of loss of binocular vision occurs at distances less than 7–8 m (and especially at distances less than 1 m), but at greater distances there is little or no change. Binocular cues that are lost are retinal disparity where objects are projected onto each eye at different angles: convergence, where the two eyes focus on the same object. This results in anophthalmic people needing to turn their heads more frequently than people with binocular vision in order to make up for the lost portion of the field.

The Psychological Importance of Prosthetic Eye Comfort and Convenience

Ocular prostheses attempt to restore the physical and cosmetic characteristics of the original eye. However, the psychological success of prosthetic restoration depends on both the physical appearance and the convenience of wearing the prosthesis. This is why patients with implant-retained facial prostheses have better quality of life scores than those with adhesive-retained facial prostheses and why patients with nasal prostheses show worse psychological and social adjustment than those with ocular, orbital (eye with eyelids) or auricular (ear) prostheses




Anatomy:

A sound appreciation of the characteristics of the face and the anatomy (structure) and physiology (function) of the orbital tissues is a necessary precursor to understanding prosthetic eye performance and the response of the anophthalmic socket to prosthetic eye wear.

Facial Architecture

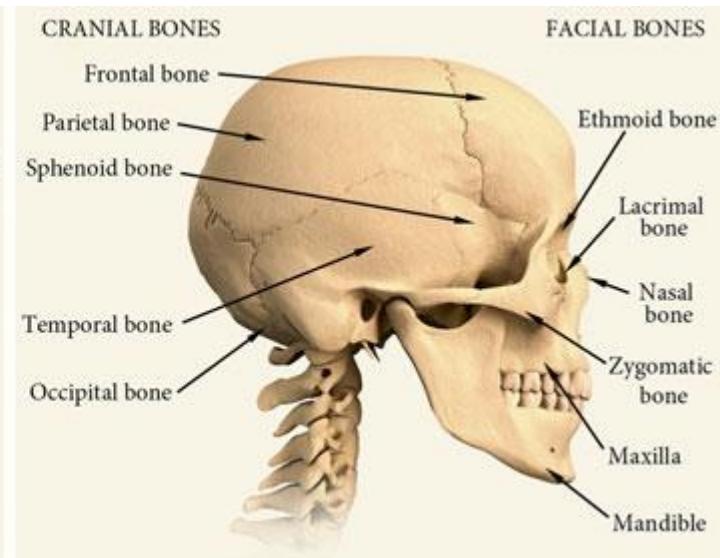
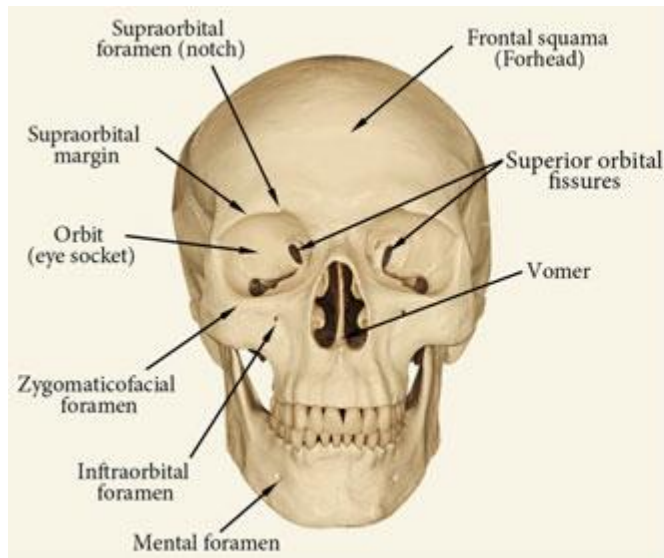
Overall facial dimensions and proportions are important in the context of prosthetic eye fitting as the eyes and eyelids are the main aesthetic units that determine facial symmetry and expression. The 'ideal' face may be divided into horizontal thirds: the hairline to the eyebrows, the eyebrows to the base of the nose and the base of the nose to the chin. The width of the ideal face may be divided into vertical fifths: the outside. fifths extend from each ear to the nearest lateral canthus, the next innermost fifths span the eyes from each lateral canthus to the corresponding medial canthus and the central fifth extends between the medial canthi across the bridge of the nose. Palpebral fissures (the elliptical spaces between the open eyelids) may be used as measuring units for the face. The 'ideal' face is five palpebral fissure widths wide

and eight palpebral fissure widths high . Adult palpebral fissures are 7–11 mm high and 28–30 mm wide.



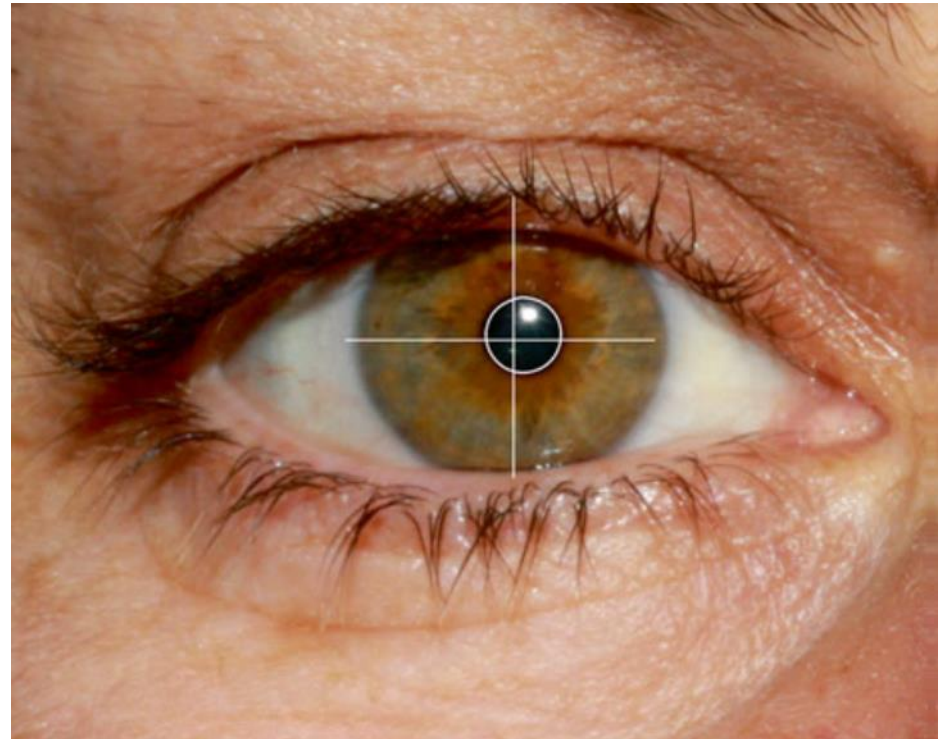
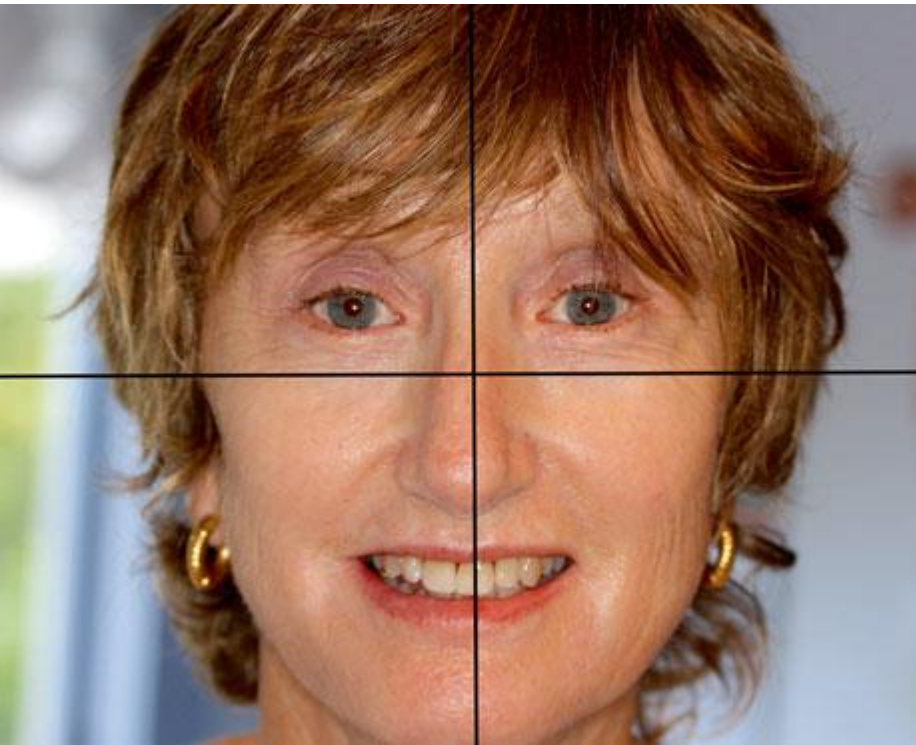
The Skull

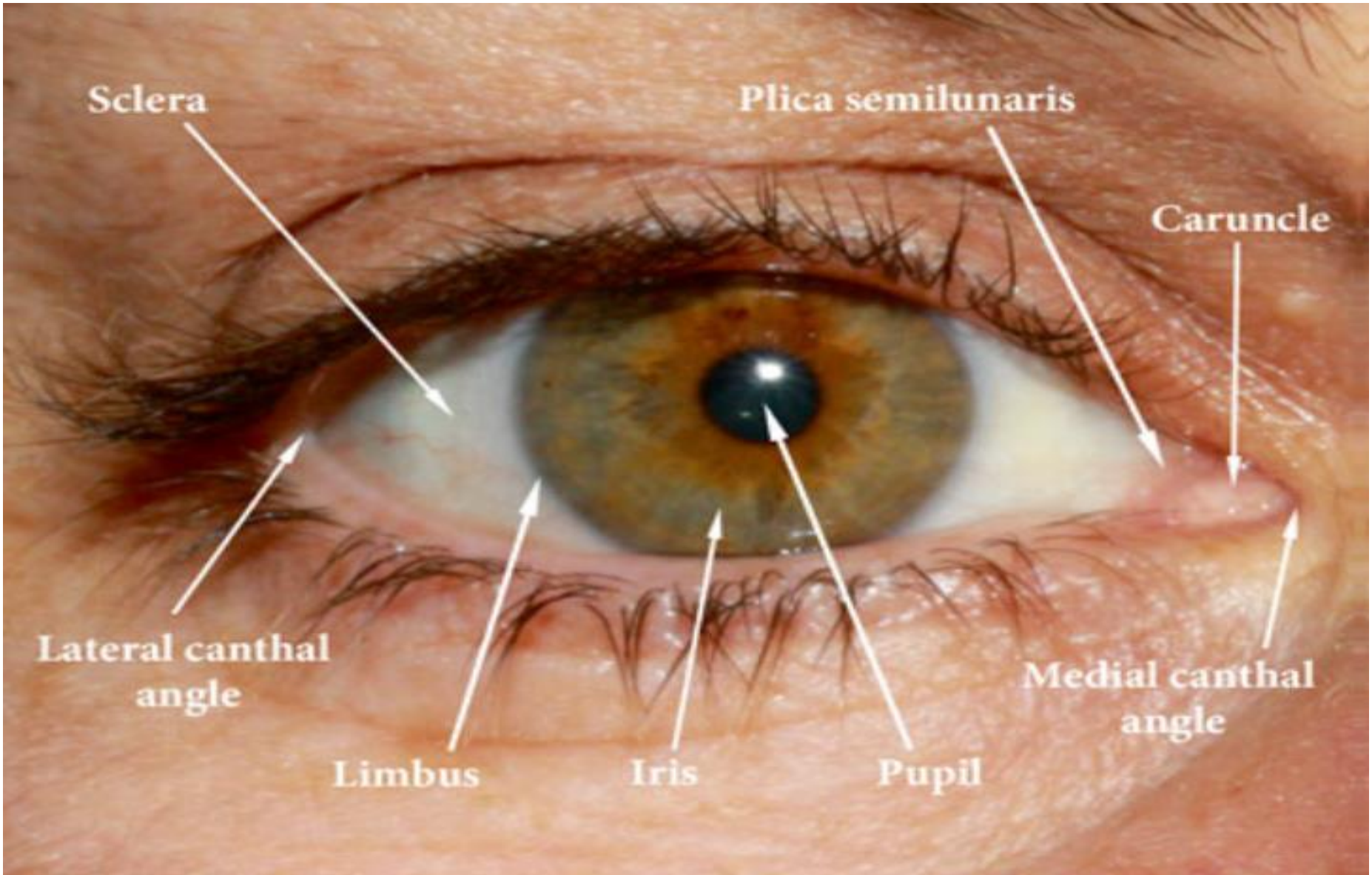
The skull comprises the cranium which houses and **protects** the brain and the face which forms the antero-inferior aspect. The cranium is made up of eight bones: the occipital, the frontal, two parietals, two temporals, one sphenoid and one ethmoid. The skeleton of the face consists of 13 bones immovably joined together and one movable bone, the mandible. The 13 bones are two each of nasal, maxillae, lacrimal, zygomatic, palatine, inferior nasal concha (total 12) and one vomer



Surface Anatomy of the Eye and Eyelids

the main anatomical features of the eye and eyelids.
where the position of the pupil, usually supero-medial
to the center of the iris.





Sclera

Plica semilunaris

Caruncle

Lateral canthal
angle

Medial canthal
angle

Limbus

Iris

Pupil

The margin of the upper eyelid hangs over the superior limbus of the cornea by 1–2 mm. The arch of the upper eyelid is asymmetrical as its highest point is medial to the center of the eyelid margin . This peak gradually moves laterally with age, changing the palpebral aperture to a more fusiform shape over time.

The corneal bulge lifts the upper eyelid margin, but this local elevation is independent of the position of the eyelid peak. The lowest point of the arch of the lower eyelid is just lateral to the pupil at the inferior limbus. During youth and middle age, the eyelids typically slope upwards laterally, with the lateral canthus 2 mm higher than the medial canthus.

The Orbit

The orbit is a bony cavity that can be thought of as a four-sided pyramid, with a floor, a medial wall, a lateral wall and a roof.

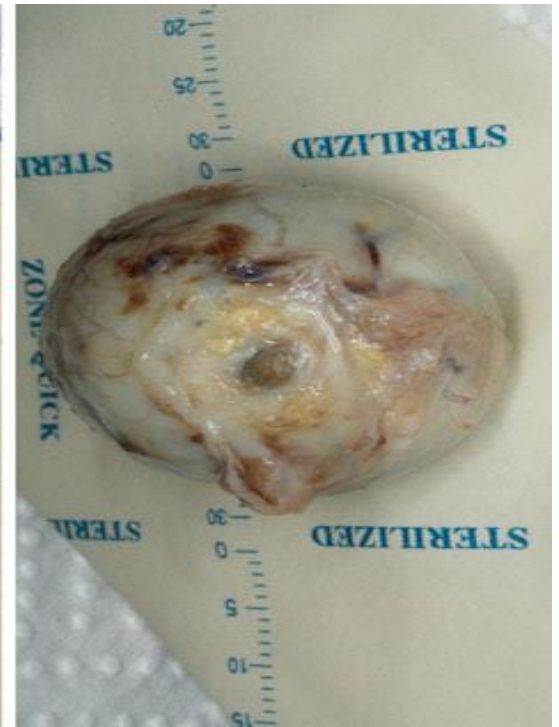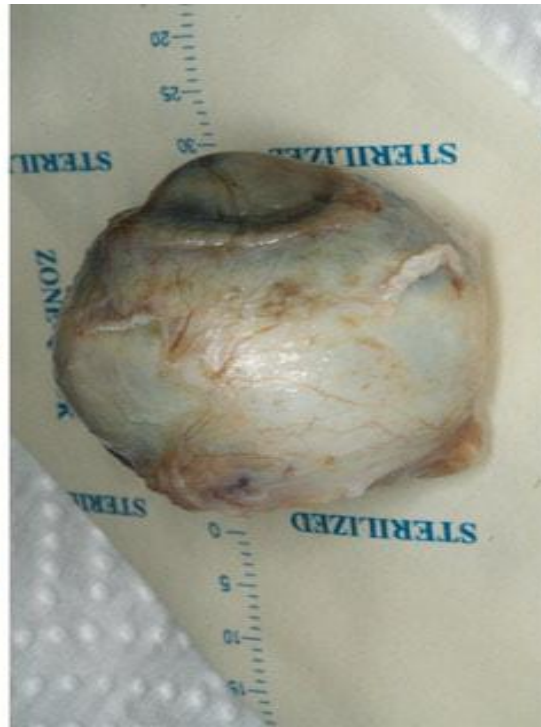
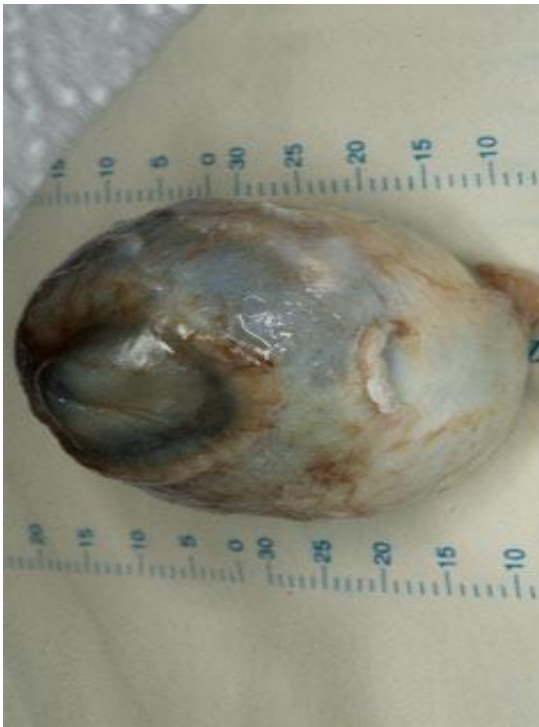- The roof of the orbit forms the floor of the anterior cranial fossa which contains the frontal lobes of the brain.
- The medial orbital wall is the thinnest and most delicate and separates the orbit from the ethmoid sinuses. It runs approximately parallel to the midline and extends approximately 45 mm from the rim to the optic foramen posteriorly.
- The floor of the orbit forms the roof of the maxillary sinus and carries the infraorbital nerve and artery in a groove or canal.
- The lateral wall of the orbit is formed mainly by the outer wing of the sphenoid bone and is stoutest of the four walls. The lateral wall is shorter than the medial wall and diverges from it at an angle of about 45°.

Orbital Contents

The contents of the orbit are the eye and optic nerve, the extraocular muscles, the levator muscle, lacrimal gland, lacrimal sac, orbital fat, nerves and blood vessels.

The Eye

The eye is roughly spherical with a diameter of approximately 24 mm, a volume of 6–7 ml and a weight of about 7.5 g . The eye grows rapidly from birth, its diameter reaches 22.5–23 mm by age three and is usually fully grown by age 13.

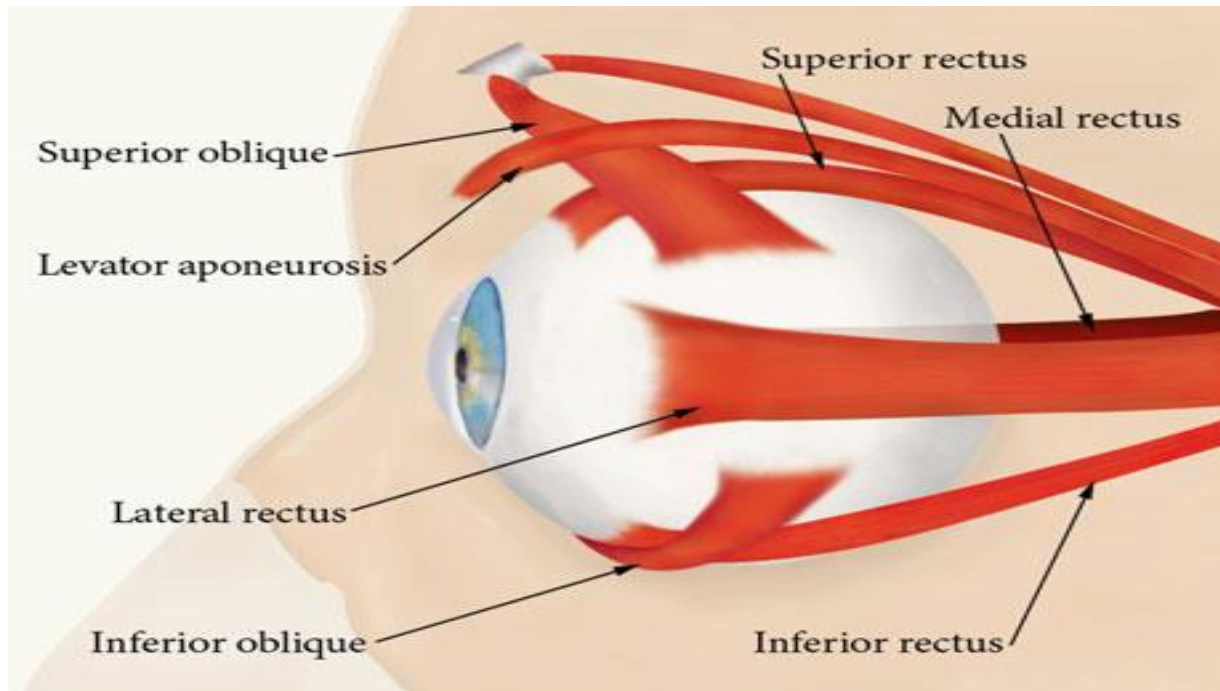


The Extraocular Muscles:

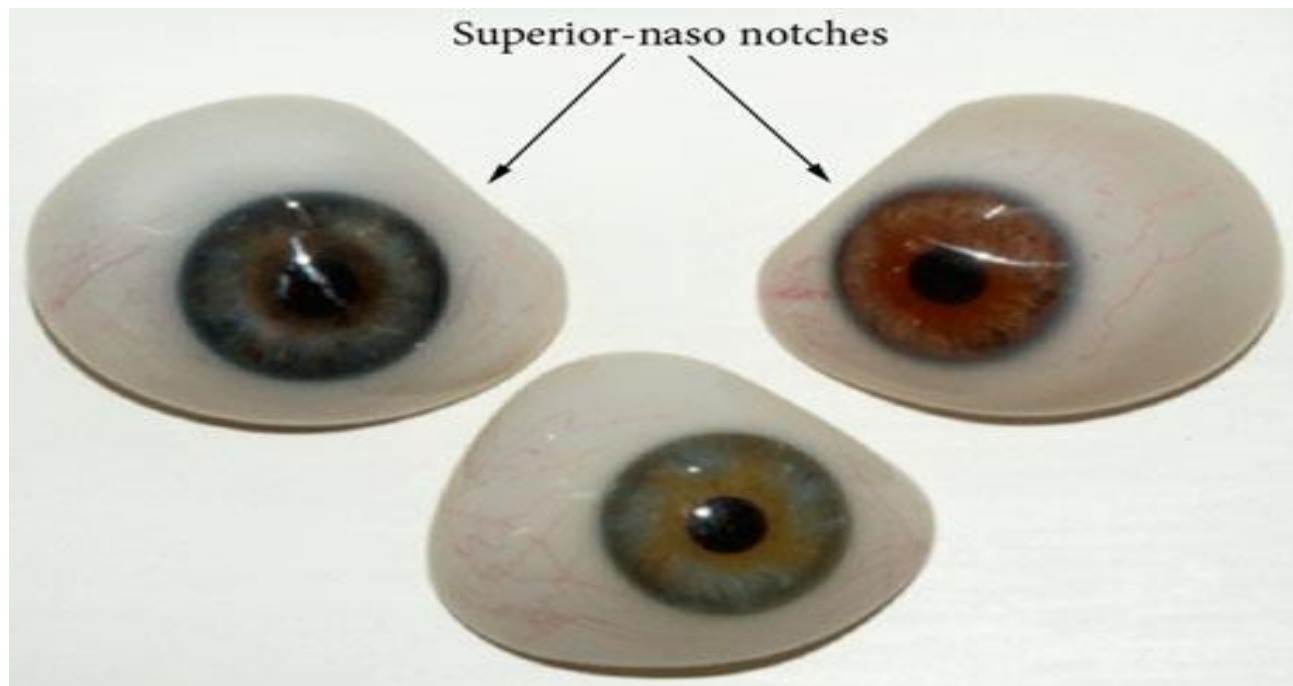
The extraocular muscles move the eye. They comprise the superior, inferior, medial and lateral rectus muscles and the superior and inferior obliques . The four rectus muscles and the superior oblique muscle arise from the orbita apex, while the inferior oblique arises from the antero-medial floor of the orbit just inside the orbital rim. The tendons of these muscles insert themselves into the superficial layers of the sclera and merge with it.

The Rectus Muscles

The superior, inferior, medial and lateral rectus muscles each arise from the corresponding part of the **annulus of Zinn** – a circular band of fibrous tissue surrounding the optic nerve at the orbital apex. Each rectus muscle passes forwards in the orbit, pierces Tenon's fascia and inserts into the sclera anterior to the equator of the eye.



The trochlea is a u-shaped pulley made of fibrocartilage which is attached to the frontal bone just behind the orbital margin. The superior oblique narrows into a tendon enclosed in a synovial sheath as it passes through the trochlea. The pulley action allows the muscle to bend downwards and backwards and then laterally through Tenon's capsule where it spreads out to its fan-like attachment on the sclera. ***The trochlea influences the shape of prosthetic eyes in this area***



Lacrimal Gland

The lacrimal gland occupies a shallow depression in the anterior lateral part of the roof of the orbit. The gland wraps around the lateral horn of the levator aponeurosis which separates the gland into orbital and palpebral lobes, which are continuous posteriorly.

Lacrimal Sac

The lacrimal sac collects the tears draining from the front of the eye. It is situated in the medial canthus and drains inferiorly through the nasolacrimal duct into the nose. Blockage of the nasolacrimal duct and stagnation of its contents can result in abscess formation in the lacrimal sac, which presents as a tender inflamed swelling just below the medial canthal tendon.

Orbital Fat

Orbital fat fills up the space in the orbit not otherwise occupied and is a major contributor to intraorbital volume. Injury or disease which damages the fat in an anophthalmic socket therefore contributes to volume deficiency

Tears

Tears are essential for the health of the natural eye and serve many of the same functions in the anophthalmic socket such as lubricating the eyelids, cleansing the socket, wetting the prosthesis and protecting against bacteria.

Function of Tears

In the normal eye the tear fluids with their antibacterial and lubricating properties are essential for the health and optical properties of the cornea. The tears transport atmospheric oxygen and ions to the cornea and flush away environmental debris.

Tear Output

The onset of lacrimation (including reflex lacrimation) occurs in most infants during the first 4 weeks of life in response to hunger or pain. Basic tear secretion gradually decreases as people get older.

Etiology of eye loss:

Congenital anophthalmia:

Congenital causes of anophthalmia can be a product of mutation during gestation period or it can be as a result of genetic factors either causes can make the following:

Primary anophthalmia is a complete absence of eye tissue due to a failure of the part of the brain that forms the eye.

Secondary anophthalmia the eye starts to develop and for some reason stops, leaving the infant with only residual eye tissue or extremely small eyes which can only be seen under close examination.

Degenerative anophthalmia the eye started to form and, for some reason, degenerated. One reason for this occurring could be a lack of blood supply to the eye

Acquired anophthalmia:

Due to accidents

Due to surgical removal, because of diseases like glaucoma (inflammatory mass), and carcinoma which leads surgical removal either partially or completely.

Causes of the eye damage

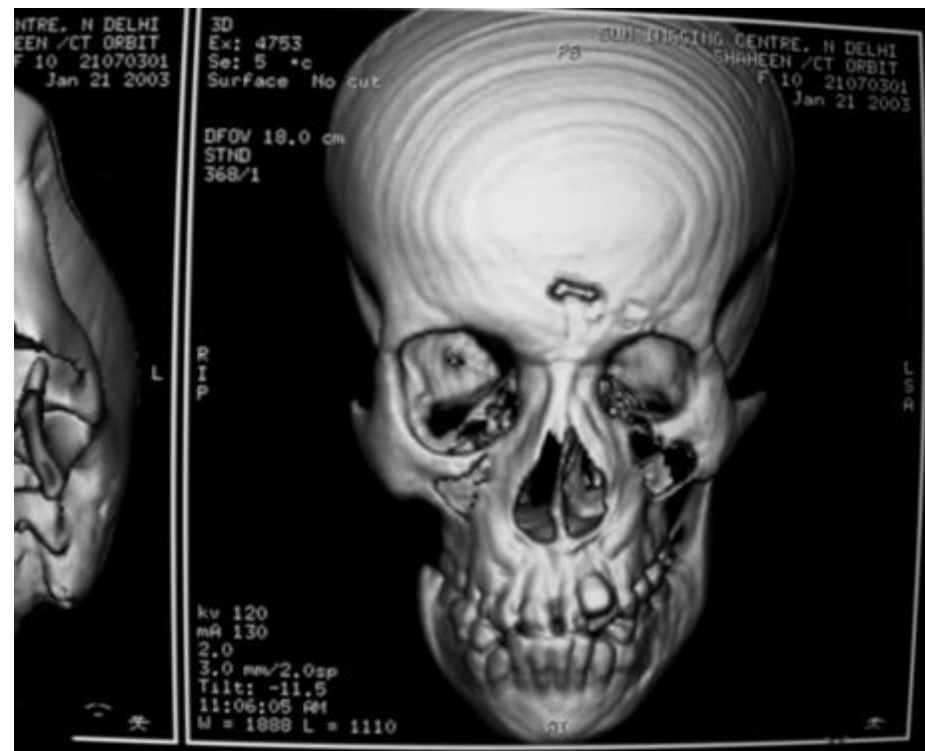
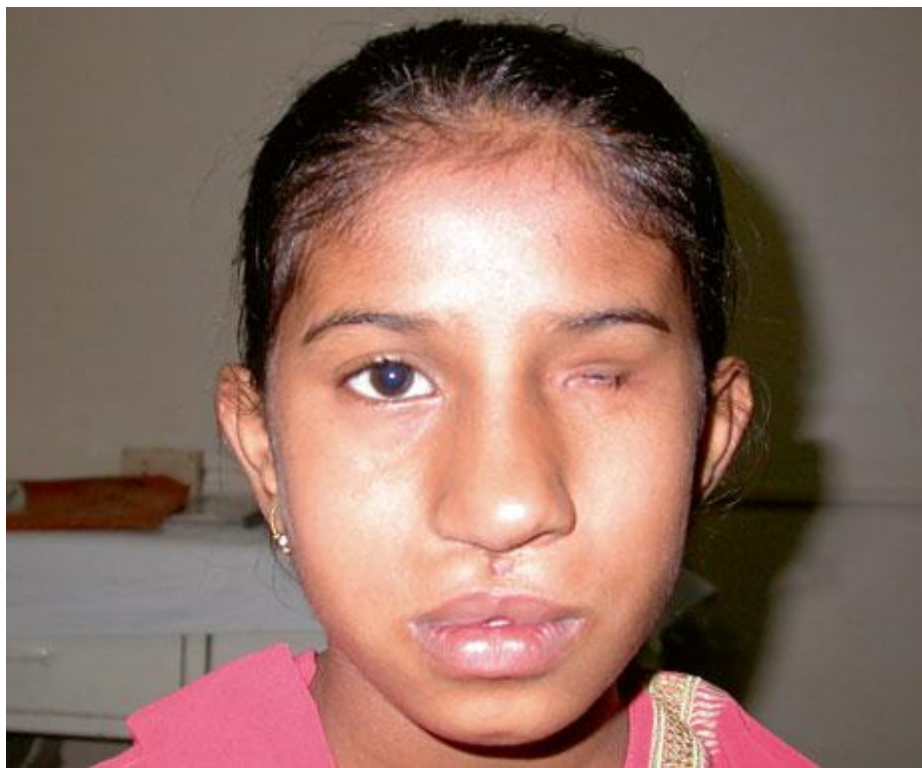Anophthalmia (the absence of one or both eyes) may be congenital or it may be due to trauma or disease requiring the surgical removal of the eye. Disfigurement of the eye may also result from other congenital defects, trauma or disease, and in these cases, it may be appropriate to use an ocular prosthesis to disguise the disfigurement. Sometimes it will be more appropriate to remove the disfigured eye, and an understanding of the surgical procedures employed is important for those dealing with these patients.

Congenital Anophthalmia and Microphthalmia

Congenital anophthalmia is the complete absence of the ocular globe while congenital microphthalmia is an underdeveloped or small eye. Cases of congenital anophthalmia exhibit no clinically apparent eye tissue, but histologic sectioning or CT scans often reveal remnants of lens epithelium and fibrovascular, neuroretinal and choroid-like tissue, indicating severe microphthalmia rather than true anophthalmia.

Congenital microphthalmia affects about 1.5 per 10,000 people, and results from a developmental abnormality of the optic vesicle which may be unilateral or bilateral. Congenital anophthalmia or microphthalmia may be isolated or part of a syndrome with other associated abnormalities and can be caused by inherited conditions or by exposure of the developing foetus to the rubella virus or to drugs including alcohol

The development of a normal eye in utero appears to be required to drive normal development of the ocular adnexa. The small or absent eye associated with congenital anophthalmia or microphthalmia is therefore generally accompanied by reduced growth of the soft tissues of the orbit, the eyelids, the bony orbit and surrounding face. In unilateral cases, this will significantly distort facial symmetry if left untreated, and, in bilateral cases, the asymmetry may be minimal, but the effects on facial structure can range from barely noticeable to profound.

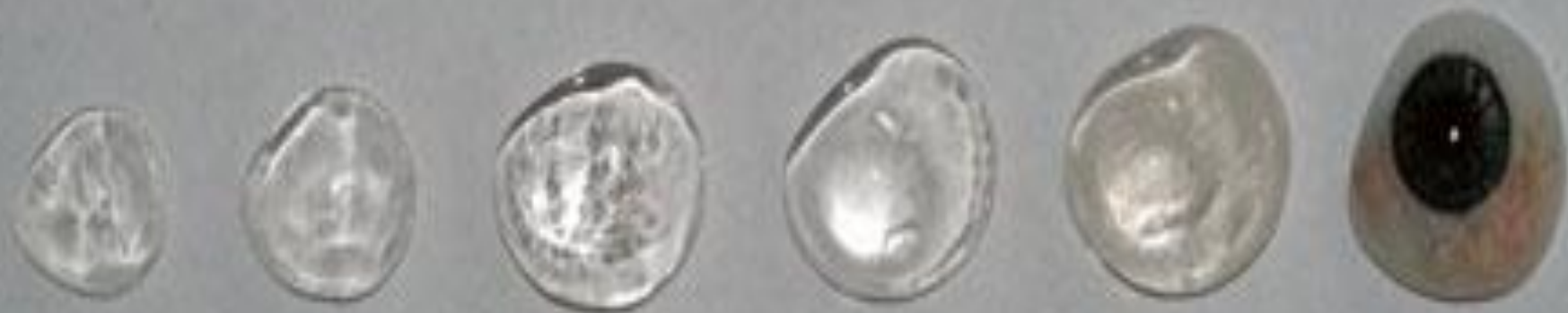

Treatment for Anophthalmia and Microphthalmia in Children

For children with severe microphthalmia or anophthalmia who have no useful visual potential, the goal of treatment is to stimulate hard and soft tissue growth of the orbit to reduce any asymmetry of the face as much as possible as the child grows into adulthood. The growth of the eye mostly occurs during the first 3 years of life (it is especially rapid in the 1 year), and the microphthalmic eye grows by a variable amount during this time depending upon the severity of the condition. It is important therefore to start treatment as soon as practical after birth – within the first month if possible.

The main treatment method is to support the eyelids in their natural position. The presence of the conformer stimulates orbital and adnexal growth and a series of conformers of increasing size are fitted over the course of the 1 year so that normal sizes and relationships can be maintained. Initially, conformers need to be replaced weekly, then monthly, then at longer intervals until the socket is finally ready for a more permanent ocular prosthesis.

Adequate prosthesis. In cases where the anophthalmic or microphthalmic socket will not retain a conformer, it may be necessary to hold it in place by suturing the eyelids together (tarsorrhaphy). After 6 weeks or so, it may be possible to replace the initial conformer with a larger one that is self-retained. If the second conformer will not stay in place, another tarsorrhaphy will be necessary.



CM 1 2 3 4 5 6 7 8 9 10 11 12 13 14 15 16

Surgical procedures:

Other surgical approaches include the early insertion of orbital implants which are then replaced with larger implants after a few years. Dermis fat grafting has also been used as a self-expanding dynamic implant.

When dermis fat grafts are used in adults, there is always significant but variable loss of tissue volume.

Balloon expander orbital implants which expand over time have also been used to provide ongoing stimulation of orbital growth. These dynamic implants contain a fluid chamber into which saline is injected to expand it. The technical complexities of this technique largely limit its use to the experimental setting at present.

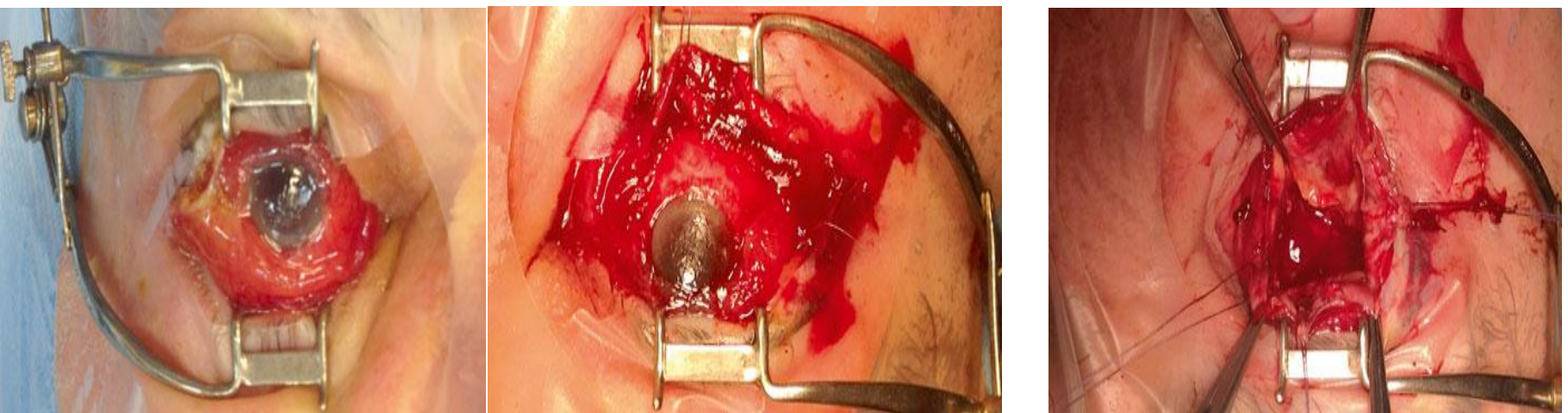Surgical Removal of the Eye

The eye can be surgically removed by evisceration, enucleation or exenteration. Evisceration is removal of the contents of the eye, leaving only the sclera, with or without the cornea; enucleation is the removal of the entire globe; and exenteration is the removal of the eye and a variable amount of orbital and adnexal tissue. The operation chosen depends on the underlying disease and, to a certain extent, individual surgeon preference.

Enucleation

A description of the enucleation of an eye was first recorded in a renaissance manuscript entitled *Ophthalmodouleia Dasist Augendienst* written by German ophthalmologist Dr Georg Bartisch in 1583. The surgical technique described in the book involved securing the ocular globe with a suture threaded through the eyeball with a needle and then pulling on the suture to draw the eye out while at the same time cutting it from the extraocular muscles and optic nerve with a curved knife.

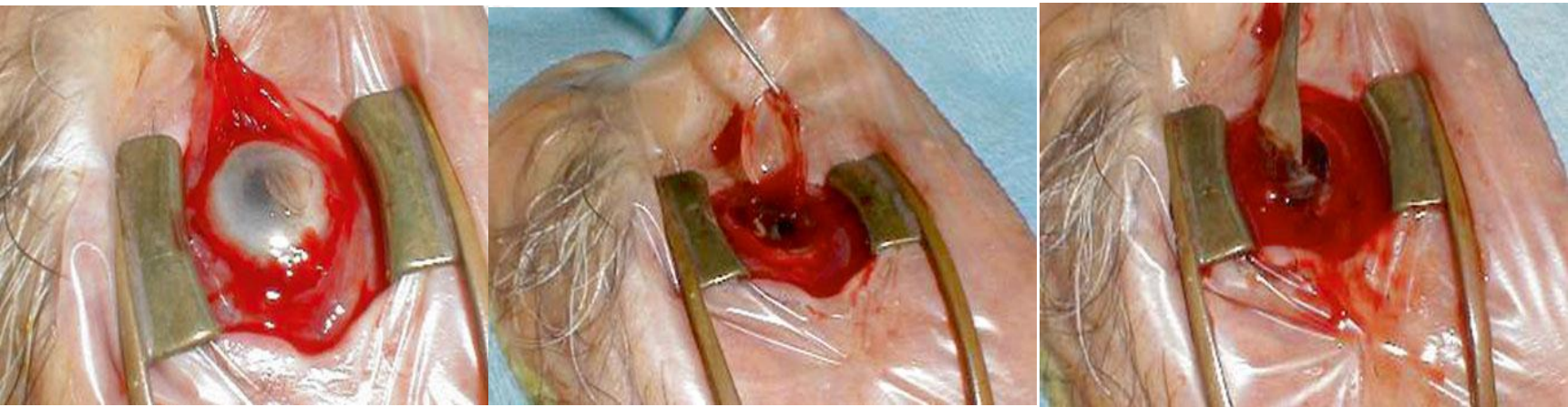The modern enucleation procedure usually takes about 60 min to perform and is usually carried out under general anaesthetic, often as an outpatient procedure. In most cases, an orbital implant is placed into the socket at the time of enucleation ('primary' orbital implant). The implant is placed in the empty Tenon's capsule. The tagged extraocular muscles are attached to the implant or its wrapping. Tenon's capsule and the conjunctiva are closed carefully in separate layers over the orbital implant.



Evisceration

The first evisceration of an eye appears to have been carried out unintentionally by James Beer in 1817 when treating a patient with a choroidal hemorrhage. J.F. Noyes completed the first planned evisceration in 1874, and in 1884, P.H. Mules inserted an orbital implant for the first time. Evisceration takes around 40 min to perform. It can be done under general anaesthetic but can also be performed under local anaesthetic with a retrobulbar anaesthetic injection. This makes it a useful option for patients who are too unwell to undergo a general anaesthetic. A 360° incision is made around the cornea, and Tenon's capsule is undermined back to the insertions of the extraocular muscles. Most surgeons then remove the cornea, often en bloc with the anterior segment. If the cornea is to be preserved, the corneal endothelium must be removed from its posterior surface to prevent the development of cysts. The remainder of the globe's contents is then scraped out with a sharp evisceration spoon.

The sclera is cleaned. Some surgeons wipe the scleral cavity with 100 % ethanol to denature any residual uveal tissue. A series of radial slits are then made through the sclera, allowing it to expand to accommodate an orbital implant which is then inserted. The edges of the scleral wound are then overlapped and secured with mattress stitches, and finally, Tenon's layer is drawn forwards and sutured and the conjunctiva is closed




Postsurgical Care Following Enucleation and Evisceration

Pain or discomfort following both enucleation and evisceration surgery is different for each patient, depending on their tissue sensitivity and the complexity of the surgery. Nausea may be present for a day or 2 after surgery and some discomfort may result from moving the eye. Many patients, however, have much less pain in their eye after surgery than they had before it, which is often why the eye needed to be removed in the first place. The post-operative care required by patients following enucleation or evisceration depends on the surgeon and can be considered in terms of systemic and topical medications and wound care. Antibiotics are usually given intravenously at the time of surgery, and there is good evidence that this is all that is required. Some surgeons will favour a short course of oral antibiotics (3–7 days) post-operatively.

In the first few days, potent pain relief may be required, but simple analgesia is sufficient within the first postoperative week. Antibiotic drops or ointment (or both), with or without steroid, is usually prescribed to use two to four times per day once the dressings are removed. The socket is patched for 1–5 days after surgery to reduce bleeding and swelling. A conformer shell is used by many surgeons (see below), and a temporary tarsorrhaphy (suturing the eyelids together) may also be employed. After 4 weeks the swelling has usually subsided enough for a prosthetic eye to be fitted but it is normal to wait between 6 and 8 weeks to ensure that the socket is completely healed and stable.

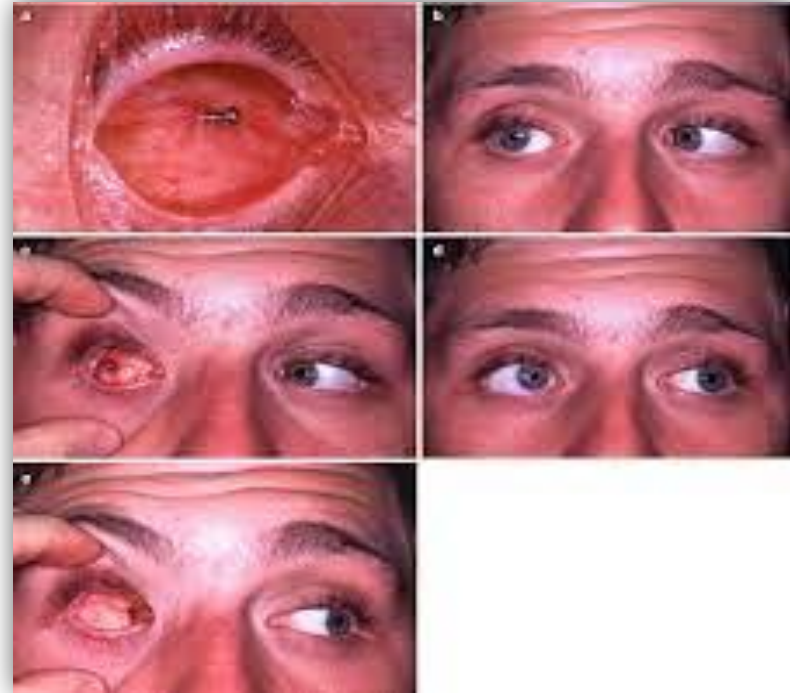
Postsurgical Conformer Shells

Conformer shells are made of soft silicone or rigid (poly)methyl methacrylate (PMMA) and often have holes which are claimed to facilitate the flow of socket secretions. Advocates for the conformer shell suggest that it protects the sutured wound and maintains the fornices. However, to achieve the latter, a conformer would need to stretch out the conjunctival folds and place unnecessary tension on the wound edge. Clearly, the fornices are not maintained by loose-fitting conformers and their benefit is questionable. The conformer shell shields the raw wound but the drainage holes often irritate the conjunctiva, causing inflammation and excessive mucoid discharge.



IDEAL ANOPHTHALMIC SOCKET

- 1. Centrally placed, well- covered, buried implant of adequate volume.
- 2. Socket lined with healthy conjunctiva.
- 3. Fornixes deep enough to retain a prosthesis
- 4. Eyelids with normal position & appearance, & adequate tone to support a prosthesis
- 6. Normal position of the eyelashes & eyelid margin
- 7. A comfortable ocular prosthesis that looks similar to the sighted, contralateral globe & in the same horizontal plane.



Impression Taking

- Anophthalmic sockets range from soft deep cavities and shallow fornixes to those with shallow cavities containing convex or flat posterior aspects and deep fornixes. The shape of the prosthetic eye is initially determined by the impression .
- A good impression extends fully into the fornixes without over stretching the conjunctiva and accurately records the shape of the posterior aspect of the socket.
- Over extended: may restrain the movement .
- Under extended: may result unstable.
- The anterior shape is moulded free hand to achieve its final contour .

Two methods for impression

- 1. An ocular tray impression technique.
- 2. Mixing gun impression technique.

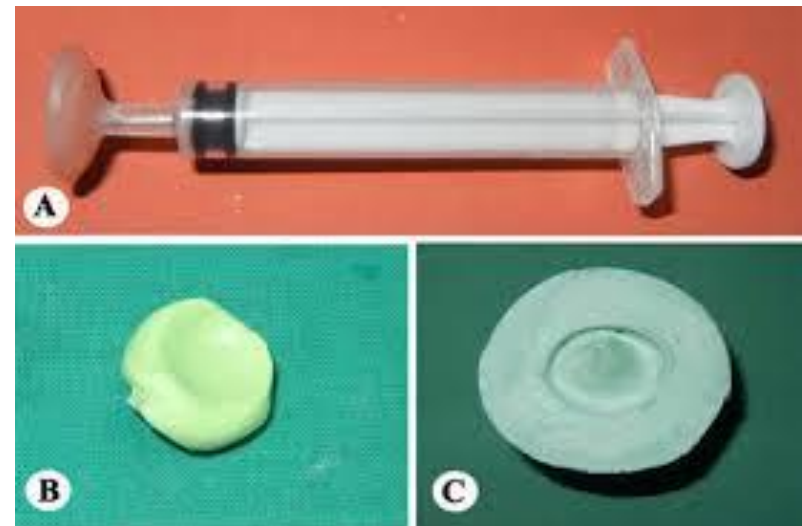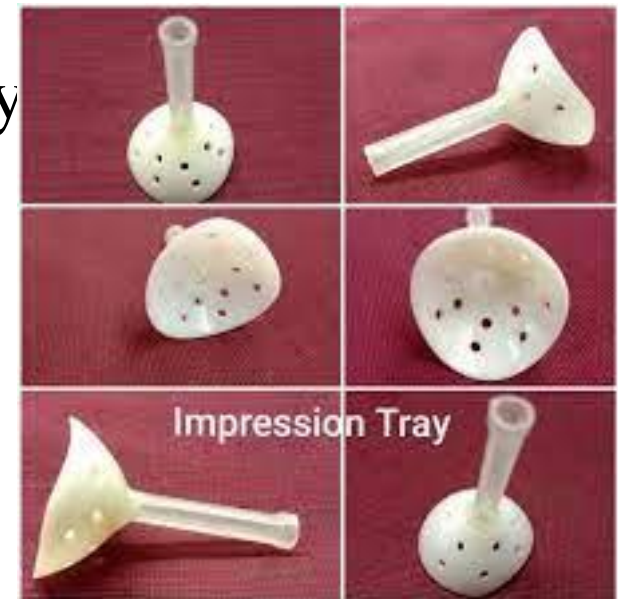Patient seated in an upright position with the head supported by a headrest.

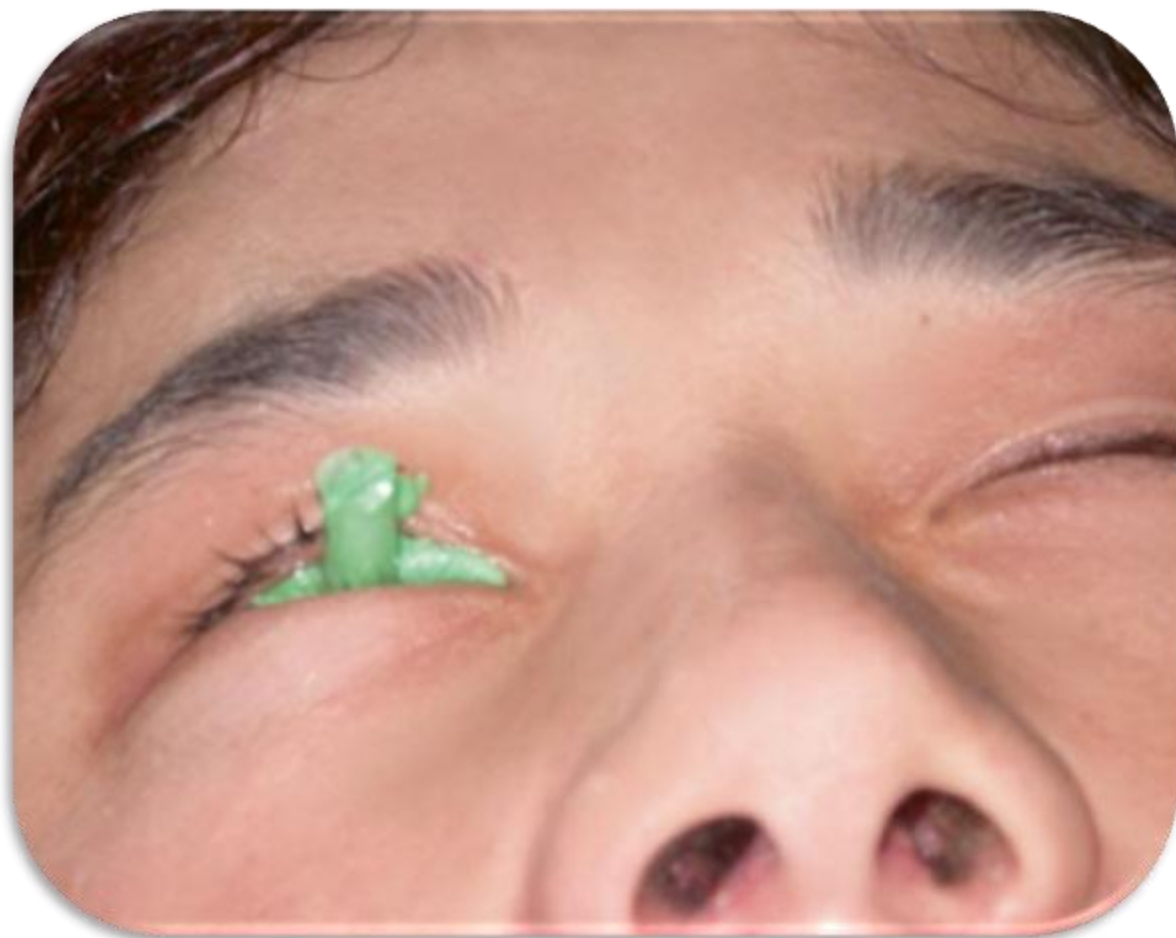Use a cool, comforting gel that is entirely painless and only requires about 60 s to set.

no need to anaesthetise the socket prior to taking an impression for a prosthetic eye unless the patient is very sensitive and anxious.

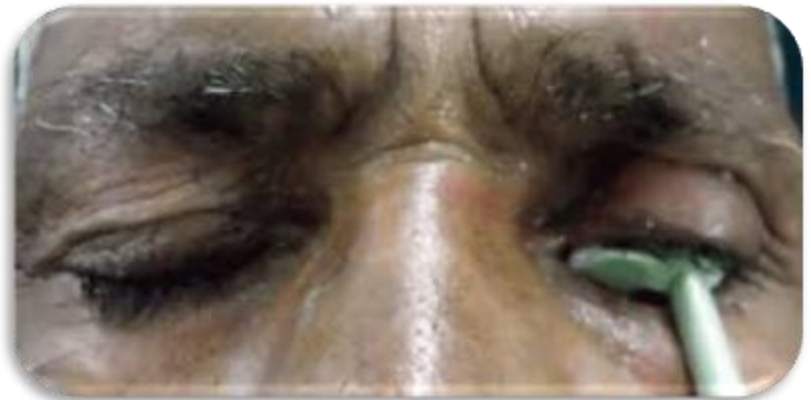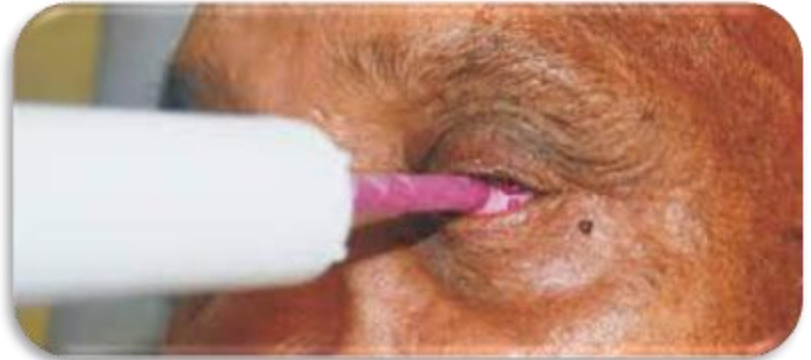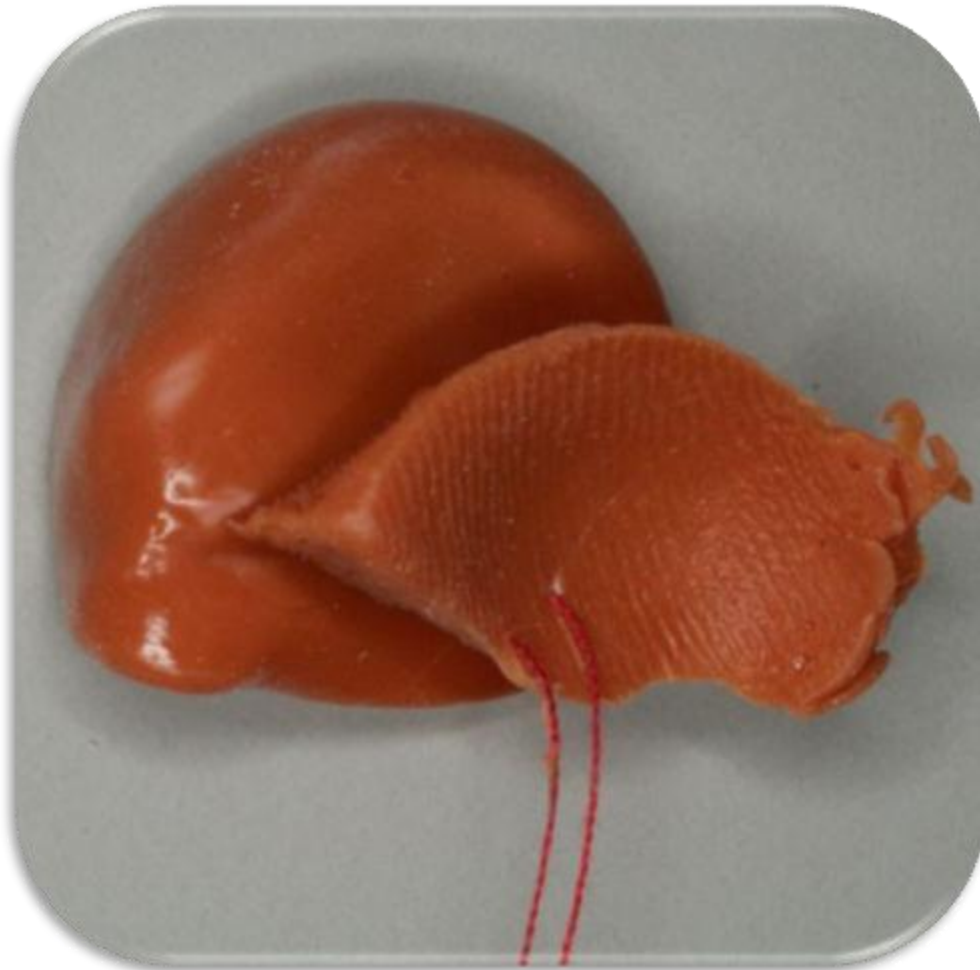
Ocular Tray Impression Technique

- various systems





Impression Mixing Gun Technique



Adv. mixing gun technique

fast and simple

causes minimum discomfort for the patient.

It produces a functional impression of the eye socket that is not distorted by a tray.

Used with children

and a general anaesthetic is to be avoided.



THANK YOU

CASTING THE IMPRESSION



- ❖ trimmed of excess material and fully immersed in a one-part silicon or two-part gypsum plaster mould in preparation for reproducing the shape in wax



❖ impression is removed by sectioning the mould



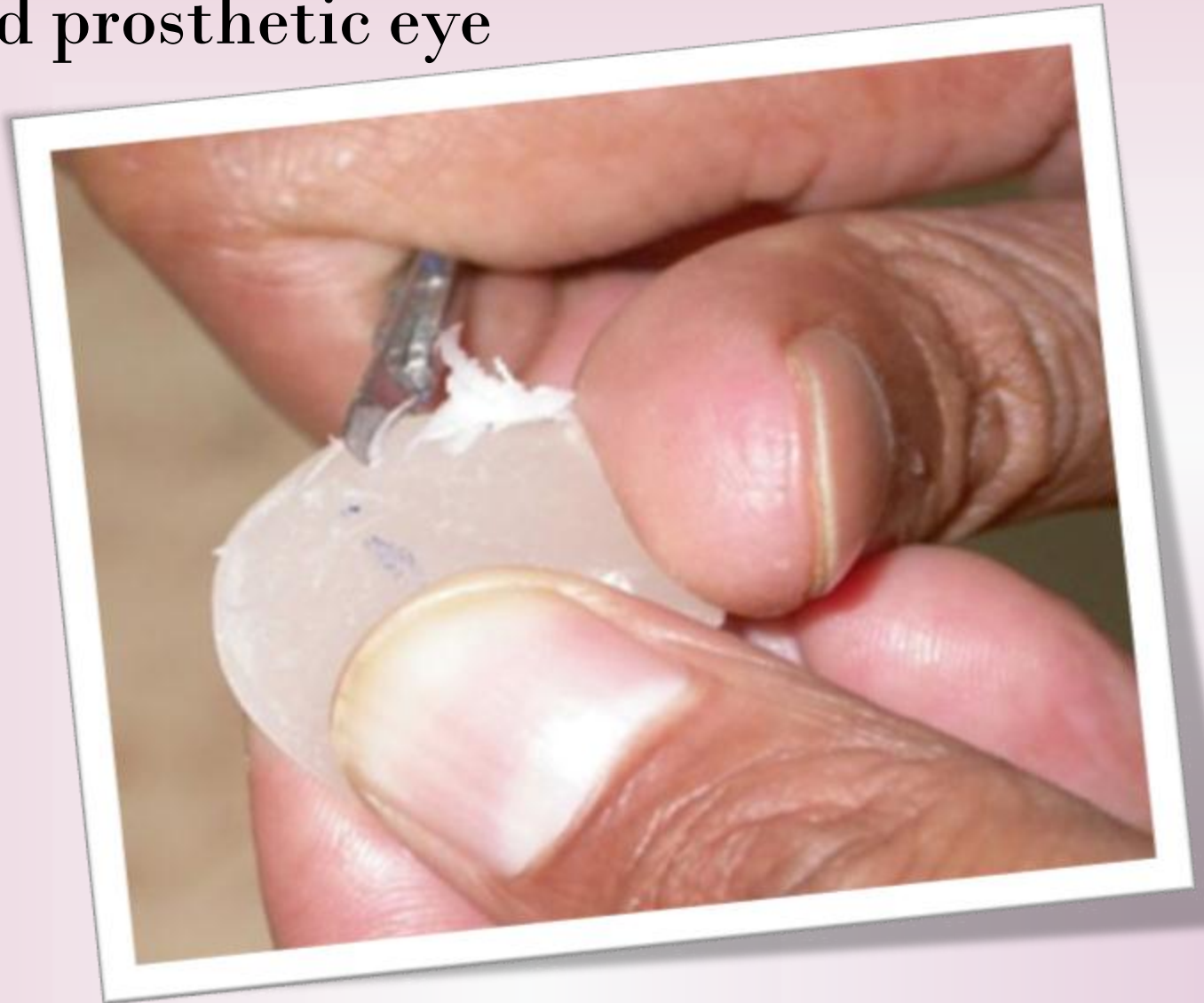❖ Preheated
white ocular
wax is
poured into
the mould



❖ The wax pattern is cooled down and removed



❖ The anterior surface of the wax pattern is being trimmed to approximate the shape of the anticipated prosthetic eye

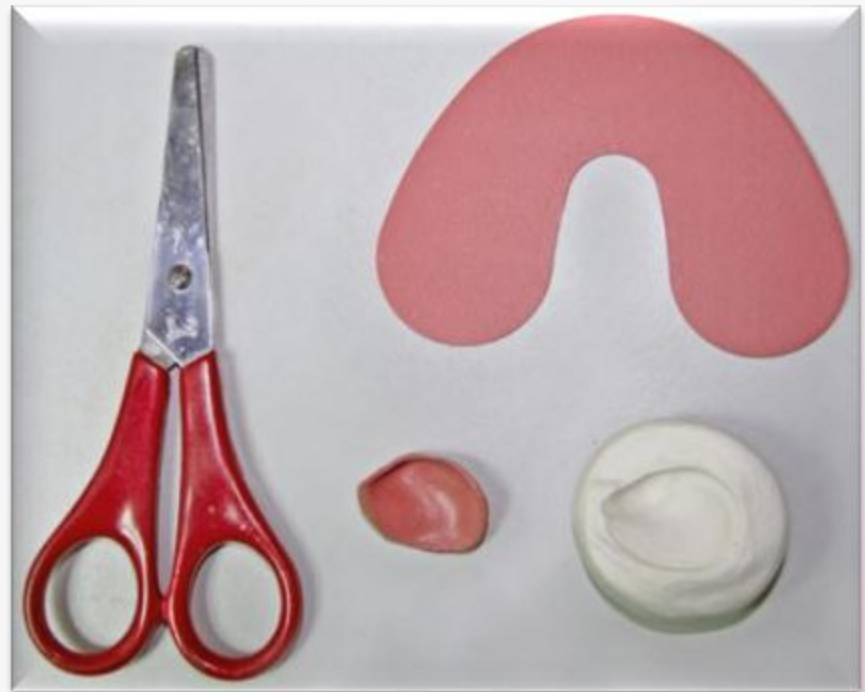

- ❖ The completed wax pattern is ready to be inserted into the eye socket



ALTERNATIVE METHOD FOR CREATING THE WAX PATTERN FROM AN IMPRESSION

- ❖ cast the posterior half of the impression in a one-part gypsum plaster mould
- ❖ Backing for the wax pattern is made from shellac base plate. The backing supports the wax pattern during the try-in stage



THE WAX PATTERN IS TRIED IN THE SOCKET

- ❖ When a backing is used, more pliable, more workable waxes as an alternative to hard, brittle waxes that are necessary to maintain shape when no backing is used



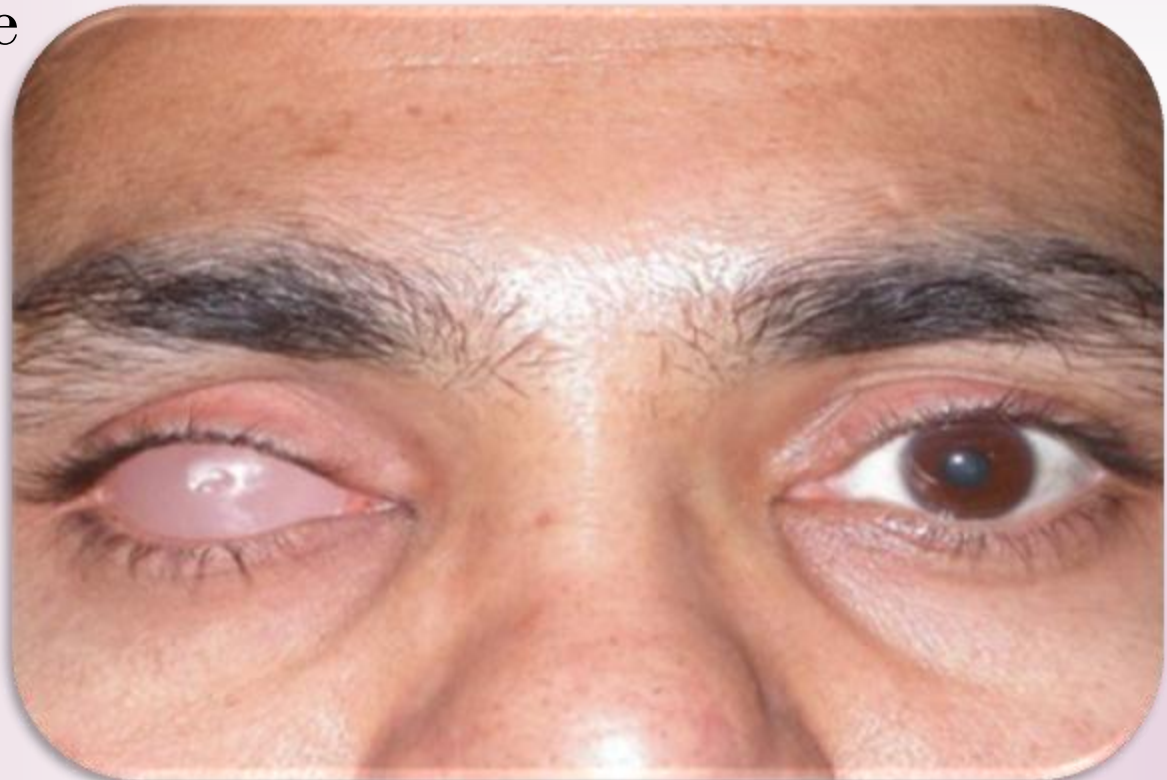TRYING IN THE WAX PATTERN AND POSITIONING THE IRIS/ CORNEAL UNIT

❖ In wax try-in stage check:

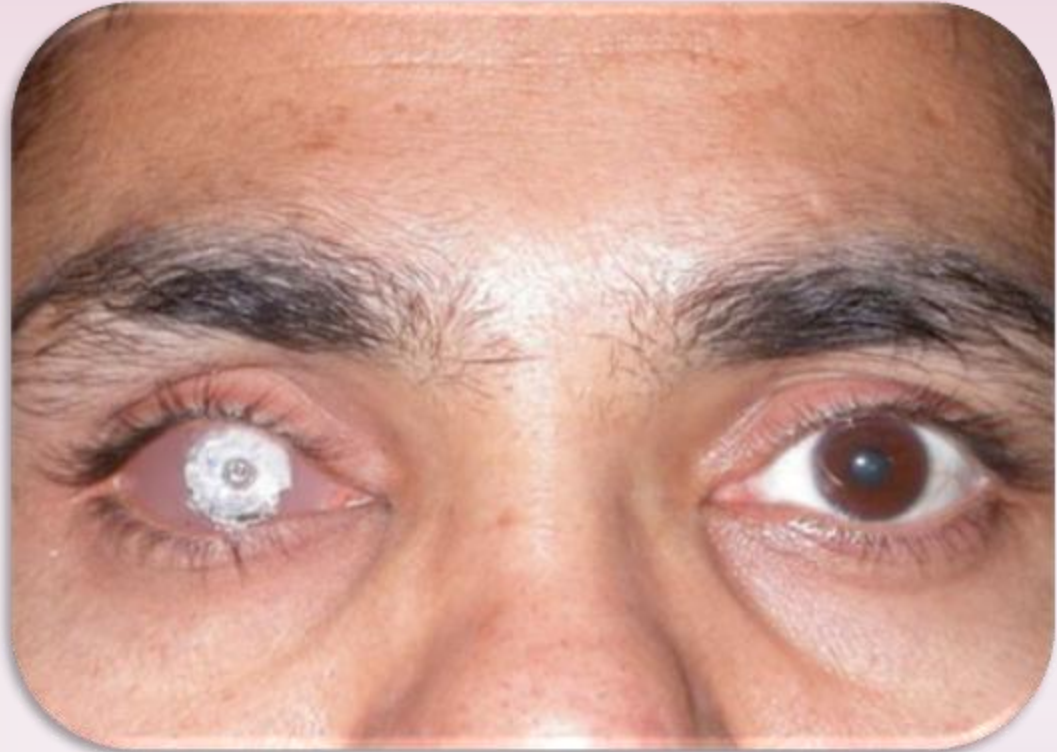1. The size of the eye
2. the direction of gaze
3. the curvature of the globe
4. the contour of the eyelids



- ❖ The wax pattern is inserted into the socket, assessed and removed.
- ❖ shape and volume :modified,
- ❖ repeated until the palpebral fissure and the anterior curvature of the globe are as similar to the companion eye as possible

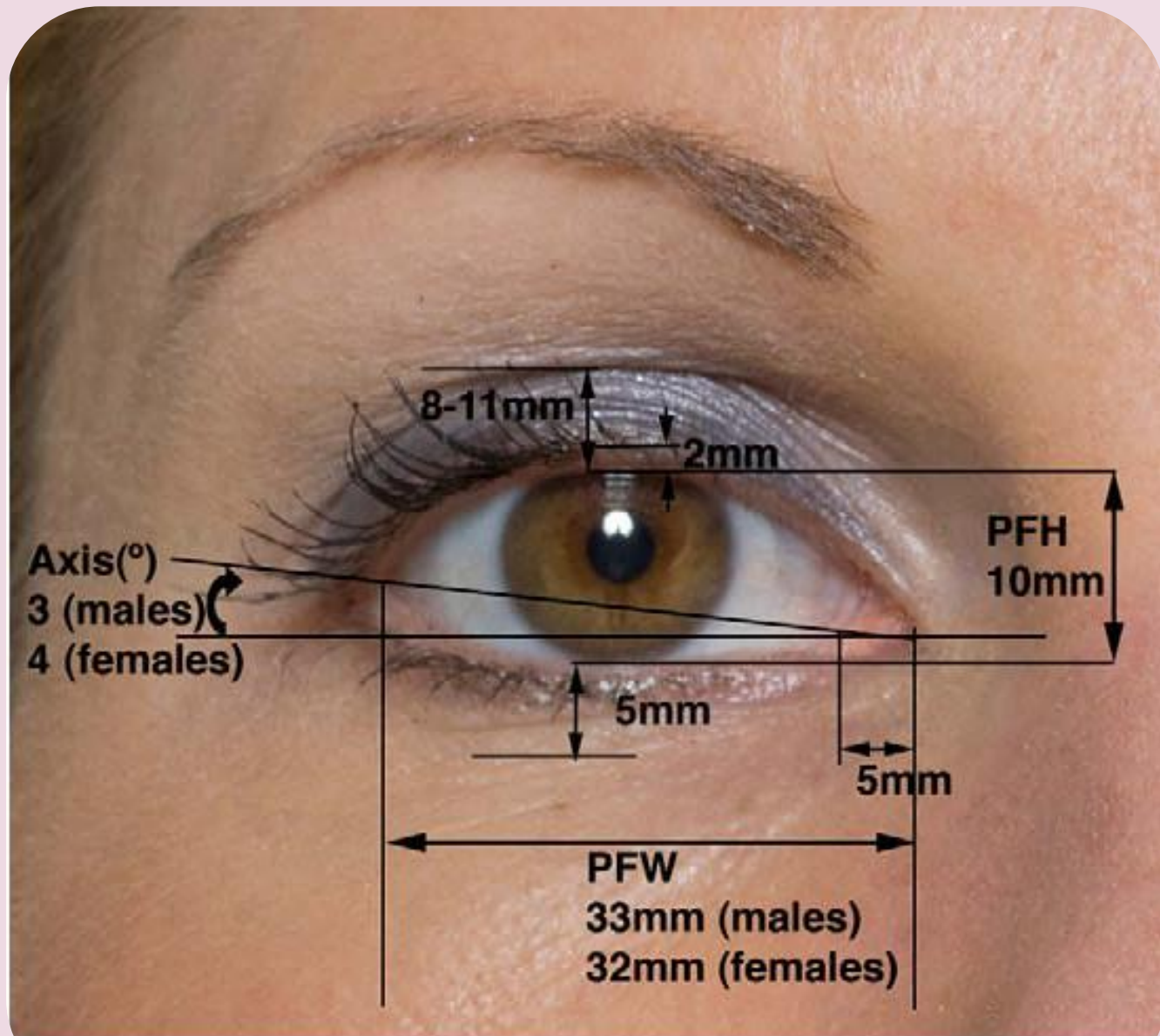


- ❖ A clear plastic iris/ corneal blank is positioned with the rod aligned in central gaze



- ❖ Once the position of the iris has been determined, a 2 mm strip of wax is added to the lower edge of the wax prosthesis.





1 Anthropometric norms of the eyelid BL



COMPROMISES AND TRADE-OFFS AT THE TRY IN STAGE

Recommendations	Trade-offs solutions
Size of the palpebral fissure vs. eyelid contour and size of the companion eye	A smaller palpebral aperture is preferable if it achieves a relaxed upper eyelid that closes completely on blinking. A smaller aperture is also preferable to one that is too large although an exception to this might be where a deep upper eyelid sulcus can be made less noticeable by widening the palpebral fissure
Increased anterior curvature vs. minor upper eyelid ptosis	Increasing the anterior curvature and volume of the prosthesis to provide more support to the upper eyelid is preferable to ptosis, even if the prosthesis protrudes a little as a consequence
Horizontally balanced iris vs. an iris that has been lowered to better relate to a lax lower eyelid	Balance is important and should not be sacrificed lightly. It is better to have a horizontally balanced iris, regardless of the position of the lower eyelid

Recommendations	Trade-offs solutions
<p>The relationship between the iris and the upper eyelid vs. its relationship with the lower eyelid</p>	<p>The relationship between the iris and the upper eyelid is more important, especially if the horizontal balance is also maintained</p>
<p>Fully moulded posterior surface vs. stability of the prosthesis in the socket</p>	<p>Stability of the prosthesis is paramount, and this can often be improved if the back is hollowed. Hollowing should be the minimum required to achieve stability so that there is minimal space for socket secretions to pool</p>



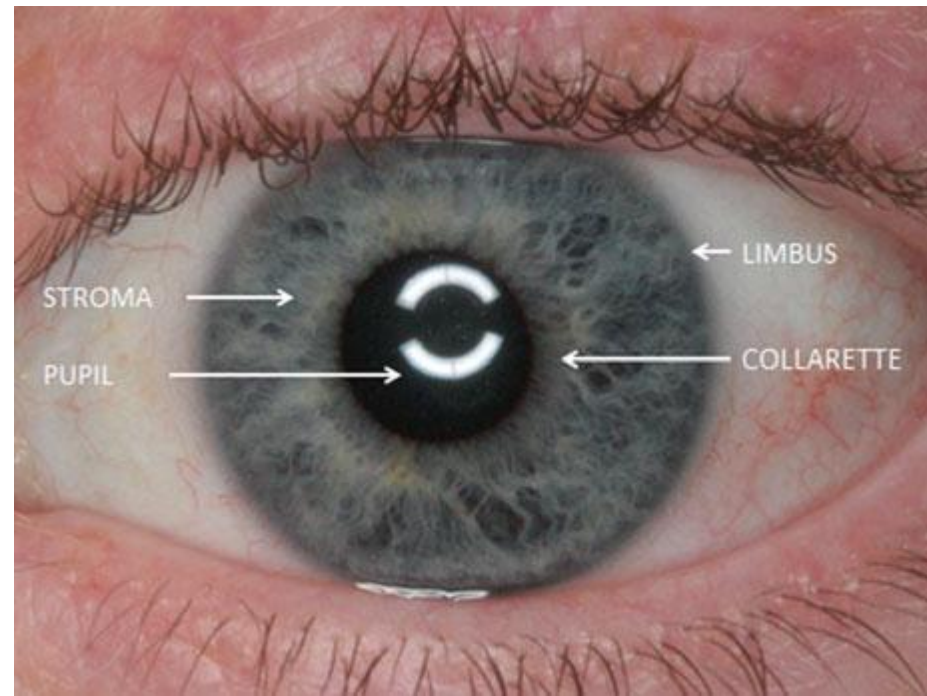
THANK
YOU



The Collarette

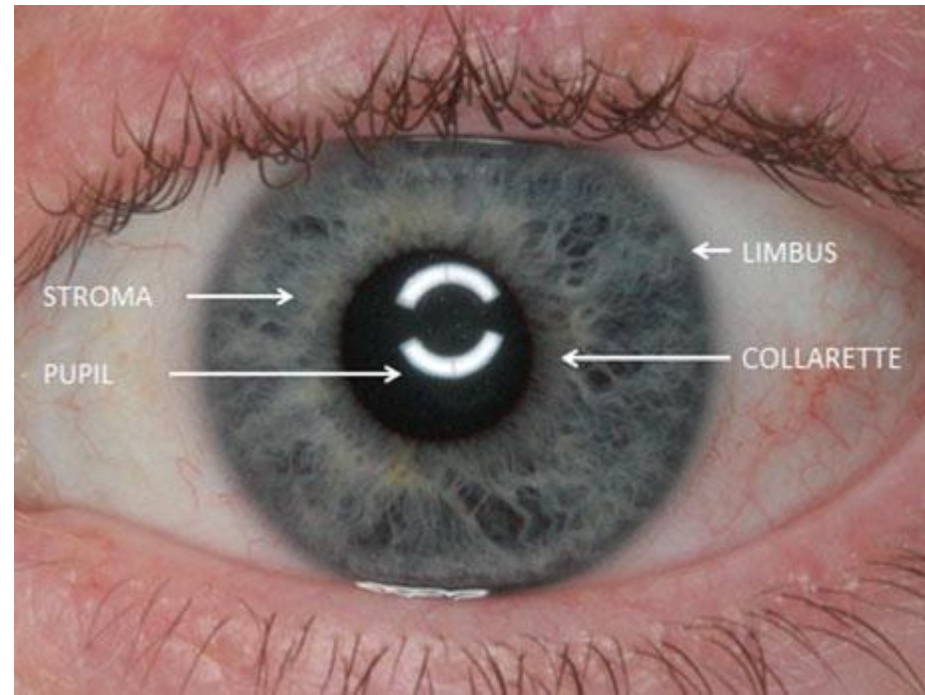
The collarette is the area where the sphincter muscle (sphincter pupillae) contracts the pupil in a circular motion. It is bounded on the inside by the soft edge of the pupil and on the outside by the set of dilator muscles (dilator pupillae) which pull the iris radially to enlarge the pupil.

The colour of the collarette is often different from the rest of the iris and should be mixed separately.

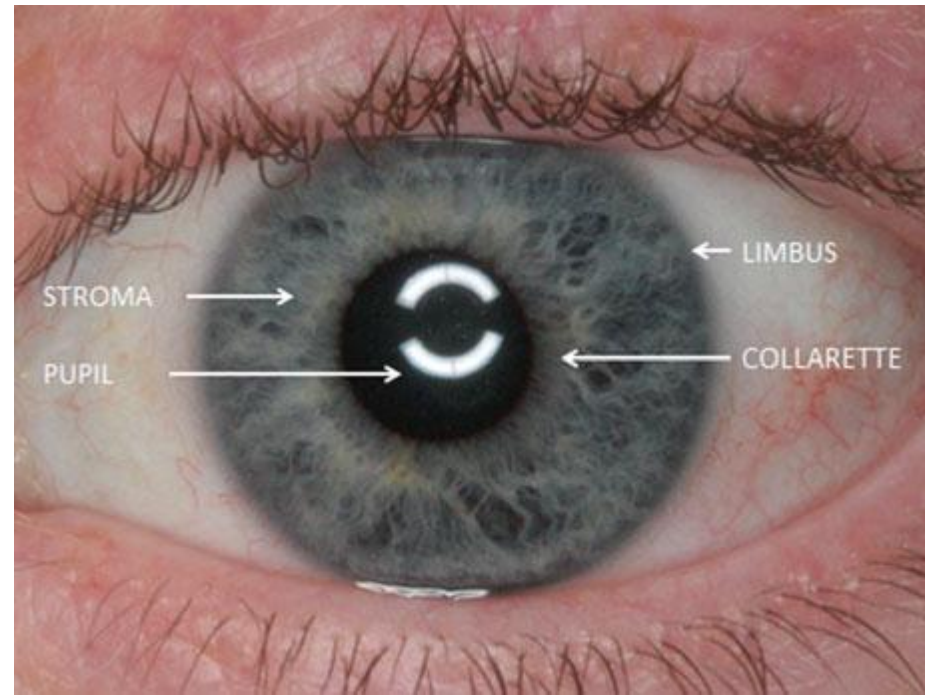


The Stroma

The stroma is the fibrovascular anterior layer of the iris containing striations which are visible to a greater or lesser extent in all eyes but are virtually invisible in black or dark brown eyes where the stroma is heavily pigmented. In lighter coloured eyes, the pattern of the striations need not be copied exactly because no two eyes have identical designs.

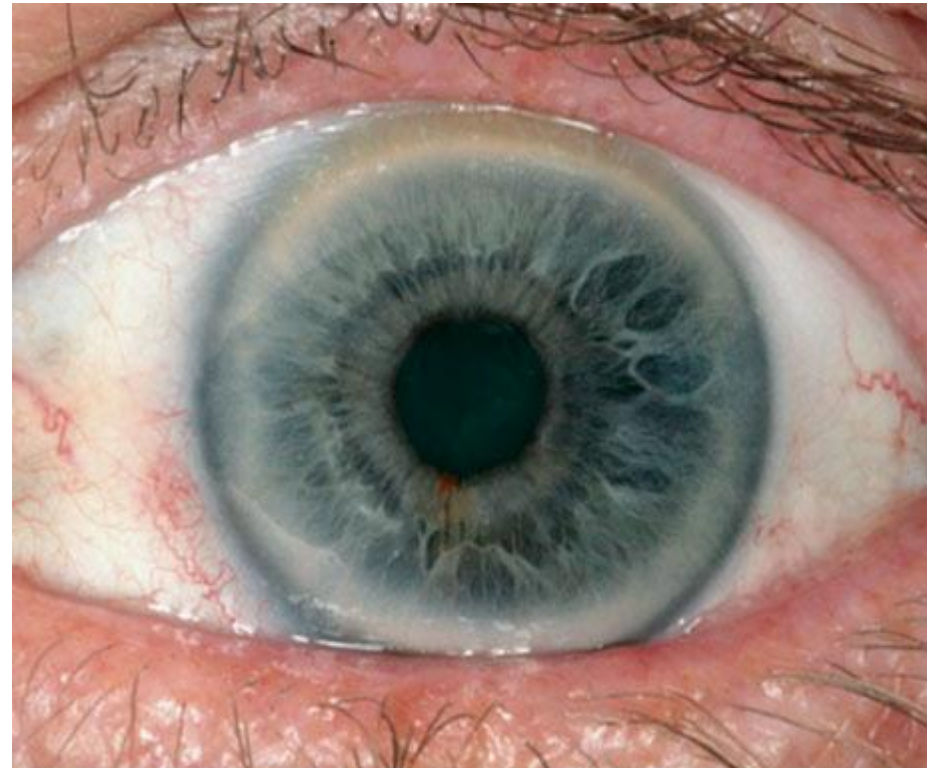

However, the pattern of the striations along with spots, smears, cloudy areas and an arcus senilis should be copied if present, as they strongly characterise the iris. The collaret is often distinguishable from the rest of the iris as is the band of colour at the limbus.




The Limbus

The stroma is thinnest at the limbus where the underlying pigmented epithelial cells show through and blend with the sclera. The outer edge of the limbus, like that of the pupil, is an area that requires particular attention as the degree of diffusion is an important feature in determining whether the prosthesis will appear natural or artificial. It is sharper in young patients and more diffuse in older patients where it may be influenced by a developing arcus senilis.

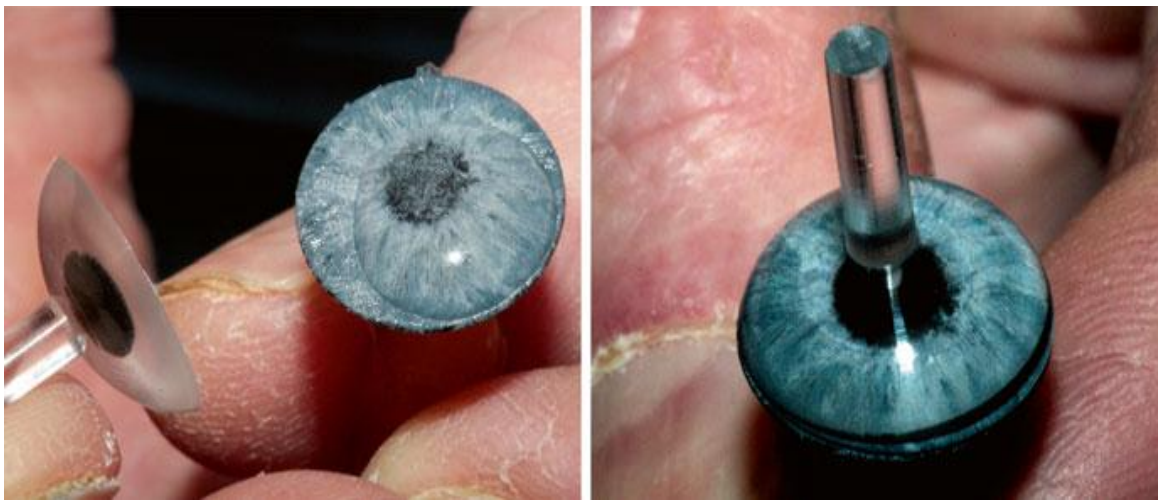

Alternative Methods for Creating the Iris/Corneal Unit

Alternative methods for creating iris/corneal units include painting iris discs stamped out of artists' water color paper. Black tinted cold-cure PMMA is poured into the mold, and the resultant blank is turned on a small lathe to the required iris diameter.



The iris blank is smoothed with a rubber wheel before being painted to match the patient's iris. When this is completed, the painted iris blank is dried before being returned to the metal mold. Clear PMMA is mixed, packed into the mold over the painted iris blank, pressed, clamped and processed in a curing tank. When curing is complete, the processed iris/corneal unit is removed from the metal mold and turned on the lathe to the required iris diameter and polished.



Painting the Iris

Oil pigments, such as Windsor and Newton, permanence AA can be used to paint the iris – often mixed with monomer–polymer syrup to facilitate rapid drying of the initial layers. The iris disc is painted to match the natural iris.

The Pupil

The pupil is arguably the most prominent feature in light-coloured eyes but of lesser importance in dark eyes where it may sometimes be almost invisible. Its size changes according to the amount of light available, and the patient should be observed in a range of lighting conditions before an average pupil size is chosen. In some cases the provision of night and day prostheses may be necessary to overcome the difference in pupil size at these different times.

The pupil creates the direction of gaze, and if it is placed in the center, in most cases, the prosthetic eye will appear to gaze outwards requiring the fit to be adjusted later to compensate.

Glass eyes versus acrylic eyes

Colours and colouring techniques

The manufacture of glass eyes which were common before the advent of PMMA eyes in the 1940s is not described even though some ocular prosthetists still make and fit glass eyes claiming greater wearing comfort due to their superior wetting properties. Not everybody has the skill or the ability to make and fit prosthetic eyes, and an enormous amount of practice is required before even a modest level of competency can be achieved in this field. Patience and perseverance are critical success factors for ocular prosthetists, and it is essential that these traits are applied to each step of the construction process so that critical standards are met before moving on to the next stage.

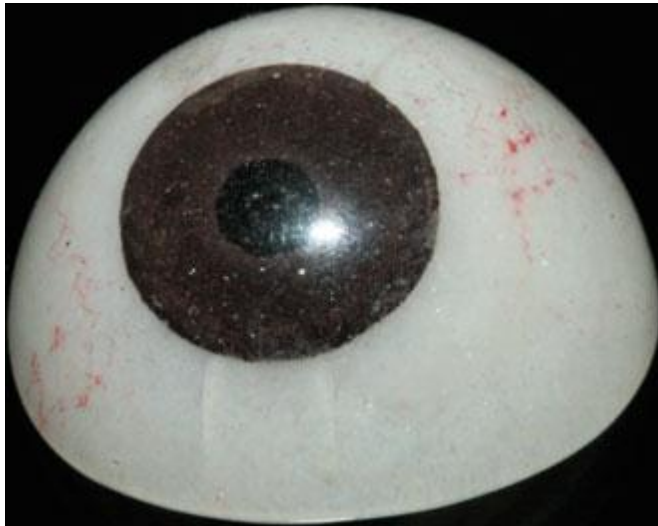
Stock Versus Custom-Fit Prosthetic Eyes

There are two types of prosthetic eye – stock and custom made. Unlike custom-fit prosthetic eyes, stock eyes, whether made from glass or PMMA, are premade and come in a range of colours and sizes with a right and left standard shape. They are usually deeply concave at the back. The hollow back accommodates a variety of orbital implant shapes and sizes but may allow socket secretions to pool and stagnate in the spaces that are inevitable between the back of the prosthesis and the orbital tissue.

This space (if large) may also lead to tissue lesions. The colour, fit, size and direction of gaze of a set of stock prosthetic eyes are necessarily limited, but the prosthesis fitting can be successful if there is large selection to choose from. The ability to modify the size and shape of stock prosthetic eyes during fitting greatly enhances success.

The main advantage of stock prosthetic eyes is that they are inexpensive to manufacture and, provided the selection is large enough, do not need to be fitted or adjusted by an ocular prosthetist. This is an important consideration in countries whose populations do not have access to custom-fit PMMA prosthetic eyes because of cost. Few western countries use stock prosthetic eyes but provide either custom molded prosthetic eyes or partially premanufactured eyes with, for example, prepainted iris/corneal units.

The chief advantage of custom-fit PMMA prosthetic eyes is that they can be moulded and coloured for individual patients. This greatly improves the patient's prospects for receiving a comfortable and aesthetically pleasing prosthesis with optimum motility. There are numerous techniques for manufacturing and fitting custom-fit PMMA ocular prostheses



Basic Colour Theory

It is outside the scope of this book to describe theories of colour in depth, but a rudimentary understanding of colour is a necessary precursor to being able to match iris and scleral colours during the creation of a prosthetic eye. Anybody considering becoming an ocular prosthetist should be assessed for defective colour vision and undergo additional colour tests to determine his or her strengths and weaknesses in this area.


Visual perception in humans depends upon two types of light-sensitive cells in the retina of the eye: rods and cones. Rods are highly sensitive to low levels of light, but cannot provide high-resolution images or signal the colour of an object. The rods dominate the regions of the retina away from the line of sight and are responsible for peripheral vision. Cones are sensors that require higher levels of light and complement rods by providing high-resolution images and detecting colour. Cones are divided into three types each of which is most sensitive to a different region of colours on the visual spectrum.

The three types are red-sensitive cones, green-sensitive cones and blue-sensitive cones. The ability of red-sensitive, blue-sensitive and green-sensitive cones to detect individual colours determines which colours are the primary colours in an additive method for producing a range of colours. The additive process is used in television and computers which generate images by mixing the colours of red, green and blue. When these colours of light are mixed together in appropriate proportions, they are perceived as white light.

The additive method for producing colours is very different from the subtractive method which is used by traditional artists and ocular prosthetists who create colour by mixing pigments in paint. The primary colours in the subtractive method are cyan (a blue-green colour), magenta (a pink-purple colour) and yellow which when all mixed together theoretically absorb all colour and produce black. However, because absorbance is not complete, the mixture produces grey, and an additional pigment (black) is added as part of the subtractive colour system. The subtractive method of colour production creates its effect by blocking out parts of the colour spectrum and preventing unwanted colours from reaching the retina.

The Colour Wheel

Primary colours are sets of colours (three per set because human vision is trichromatic) that, when mixed together, are able to make a range of useful colours. They are 'primary' because one primary is not able to be made from a mixture of the other two primaries. In the additive system, the primary colours are usually chosen to be red, green and blue. In the subtractive system, the primary colours are taken to be cyan, magenta and yellow (black can be added). A different set of primary colours.



Characteristics of Colour

The following terms and definitions describe the factors that are taken into account by the prosthetist when painting the iris of a natural eye. The hue is the colour of the pigments used. The value is the lightness or darkness of a colour and is a measure of the amount of light reflected from its surface (reflectance). For example, adding Vandyke brown to blue delivers a darker value of blue that reflects less light from a painted iris. The chroma is the purity or saturation of a colour. This is thought of as a measure of how little white, black or grey is in the colour. The more pale a colour is, the less saturated or less pure it is. For example, a grey/blue iris is less saturated (less pure) than a high intensity blue iris which is more noticeable (more pure).

A tint is the base colour added to white. A tone is the base colour added to grey. A shade is the base colour added to black. Ocular prosthetists often have their own preferred colour palettes with which they are familiar and which may be tailored to the ethnic origins of their patients. A basic palette might include the colours: ivory black, titanium white, Vandyke brown, cobalt blue, yellow ochre, raw sienna and burnt sienna.



Acrylic co-polymers

Although this material is soft and elastic, they have not received wide acceptance due to the poor edge strength, poor durability, subject to degradation when exposed to sunlight, processing coloration is difficult, completed restoration often become tacky, predisposing to dust collection and staining. The new generation of acrylic monomers, oligomers, and macromeres. They are thermal, chemical and photo-initiated. They can eliminate the shortcomings of traditional acrylic co-polymers.

Latexes

Latexes are soft, inexpensive and easy to manipulate. They are realistic and form lifelike prosthesis. However, the finished product is weak, degenerates rapidly with age and changes color. Latex is no longer a major facial prosthetic material.



Plasticized Polyvinyl chloride (PVC) and copolymer

Polyvinyl chloride is a rigid plastic and is made more flexible by adding a plasticizer. Other ingredients added to polyvinyl chloride include cross-linking against (for strength) and ultraviolet stabilizers (for color stability). Color pigments can be incorporated to match individual skin tones.

When the mix is cooled, an elastic solid is formed. The prosthesis becomes hard with age because the plasticizers are lost from the surface of the prosthesis.

Chlorinated polyethylene

This material was introduced in the 1970s and 1980s as an alternative to silicone. Processing involves high heat curing pigmented sheets in metal molds. Dow chemicals' chlorinated polyethylene elastomer is an industrial grade thermoplastic elastomer. It is less irritating to the mucosa than silicone, less toxic than thermosetting silicone materials and noncarcinogenic. Chlorinated polyethylene elastomer appears to be a suitable substitute for silicones for the fabrication of extraoral maxillofacial prosthesis in situations where cost of silicone is limiting factor.

- **Advantages** Higher edge strength, permanent elasticity and lower fungus growth.

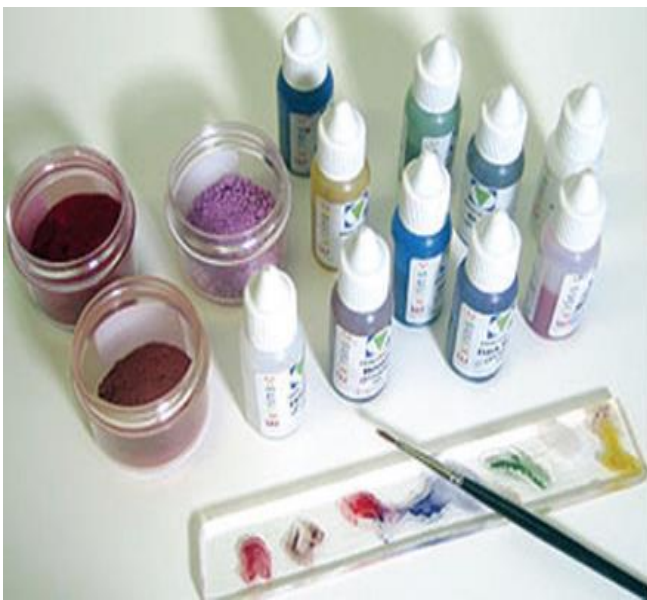Polyurethane Polymers

It is the most recent addition. One of its components is acrylate, which needs careful handling to prevent a toxic reaction to the operator. Although the material is cured at room temperature, it requires accurate temperature control because a slight change in temperature can alter the chemical reaction. A metal mold is used to avoid moisture in the air affecting the processing. It has lifelike feel and appearance and the color stability is better than that of polyvinyl chloride. But it is susceptible to deterioration with time.

Silicone Rubber

Silicones were introduced as a maxillofacial material in the 1950s. Currently silicone based maxillofacial materials are the most widely used. Based on curing mechanism, two types of silicone rubber are available. Both types are widely used.

- RTV – Room Temperature Vulcanized
- HTV – Heat Vulcanized Silicones



- Supplied as

Both HTV and RTV silicones are available as fluid, semisolid, gel-like or putty-like material.

They are generally supplied as clear or translucent materials though occasionally they may be supplied pre-pigmented (e.g. flesh colored - 2009 by Factor II).

They are usually provided as base and catalyst where the base-catalyst ratio is 10:1 (most common ratio).

However base-catalyst ratio of 1:1 is also available.

