

Fundamental of Occlusion

Crown and Bridge III

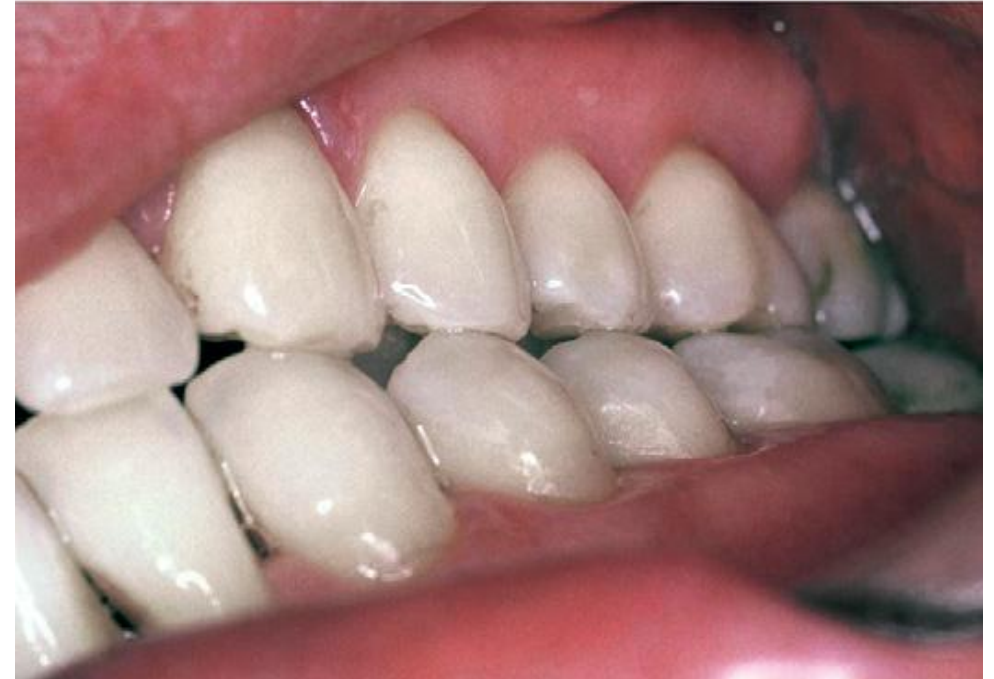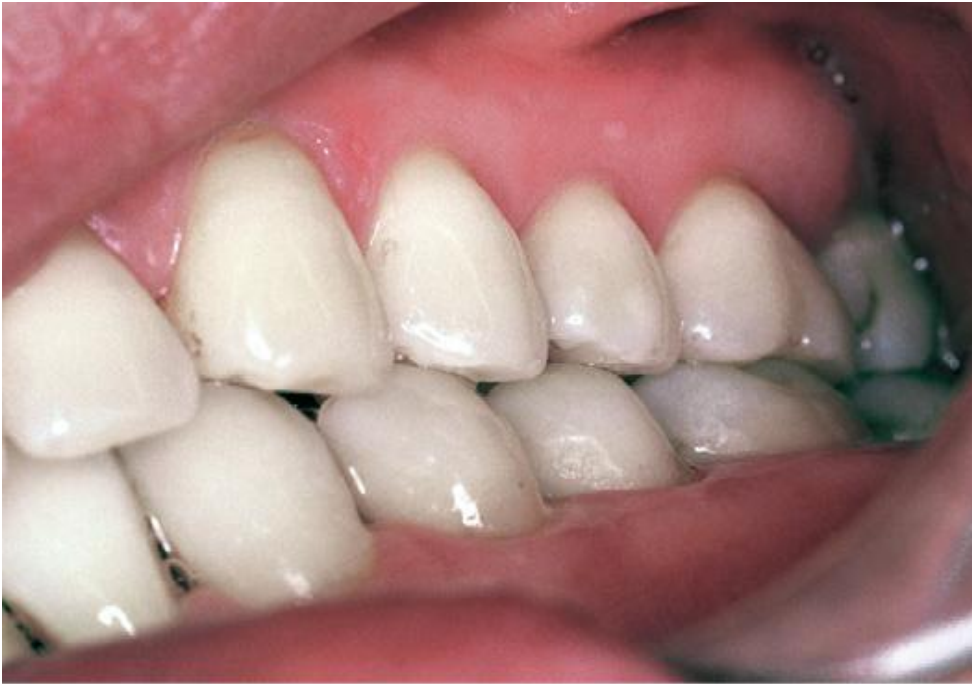Lecture 1

15/10/2022

Occlusion mean



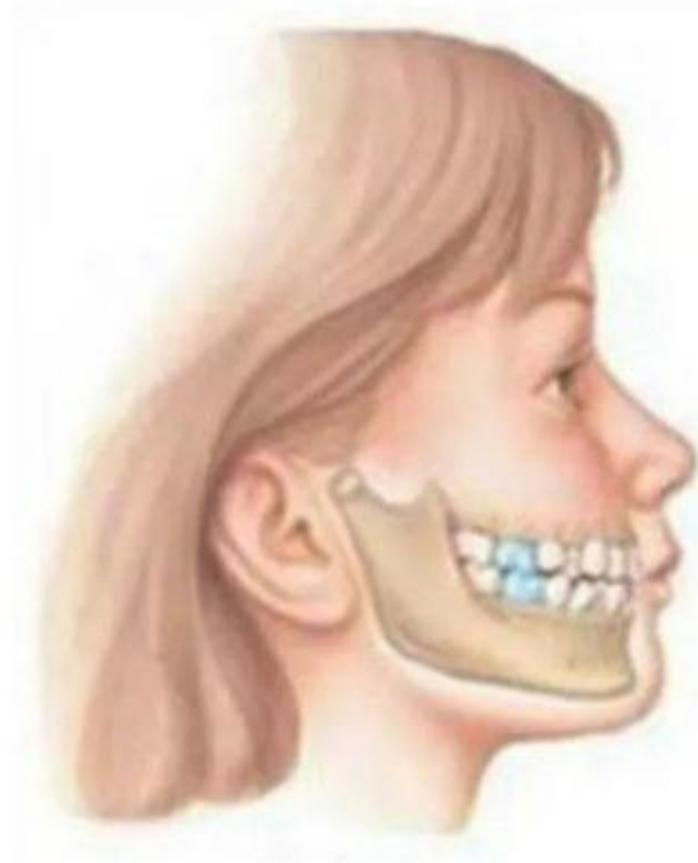Tooth Contact



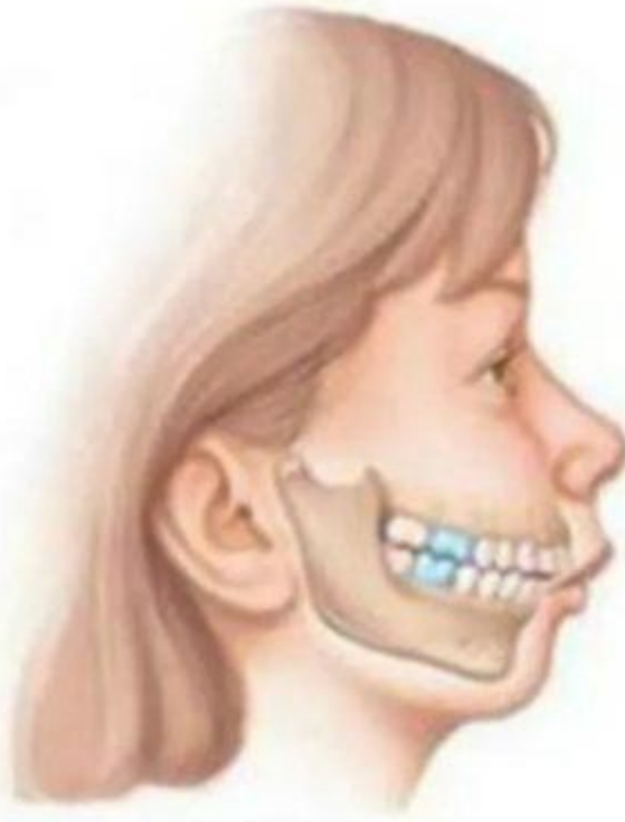Angle classification

Key of occlusion is upper first molar.

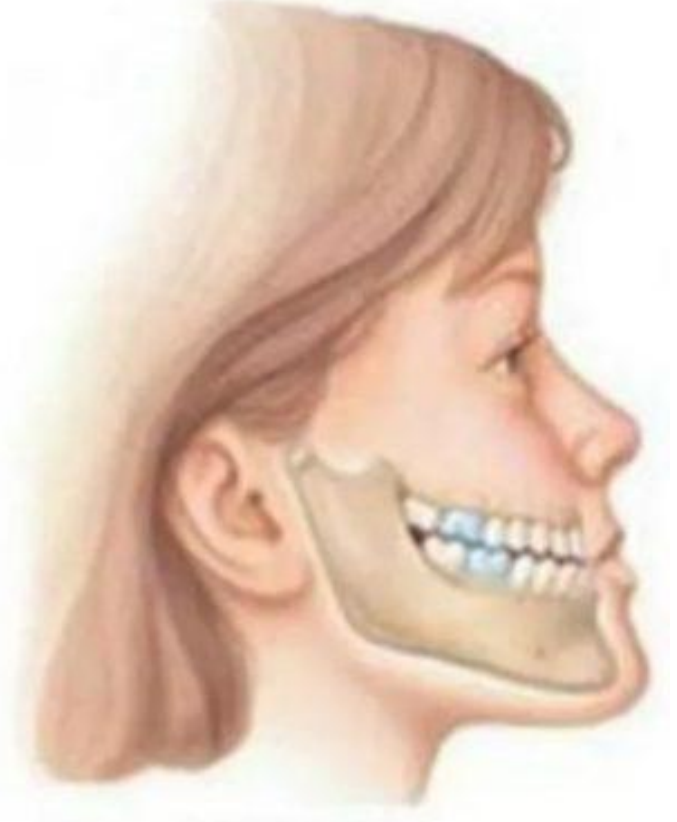Class I



Class II

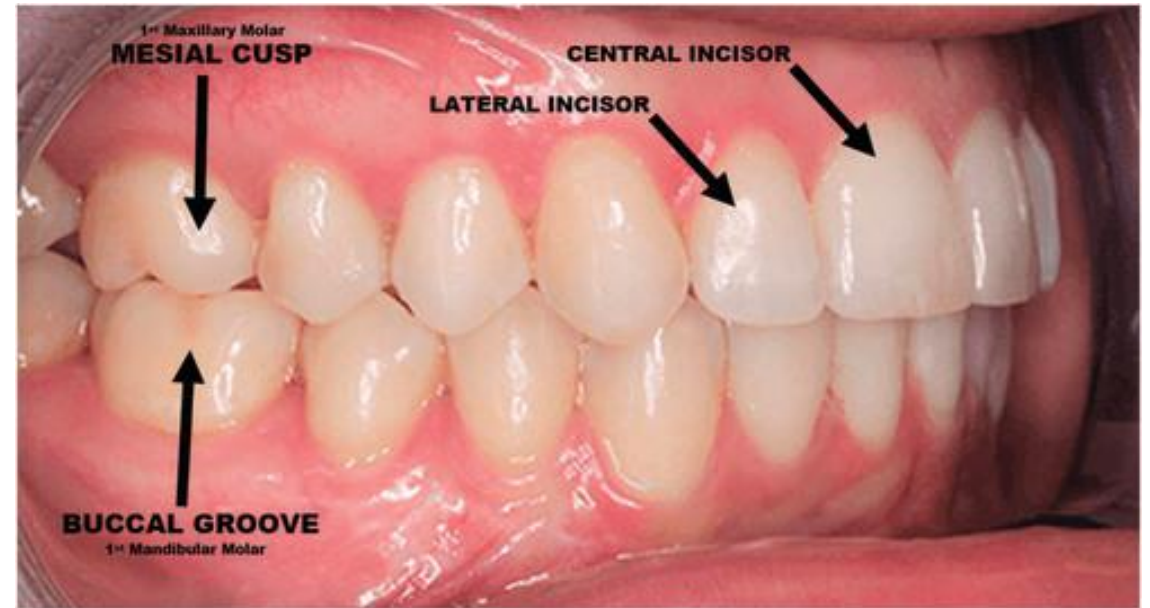
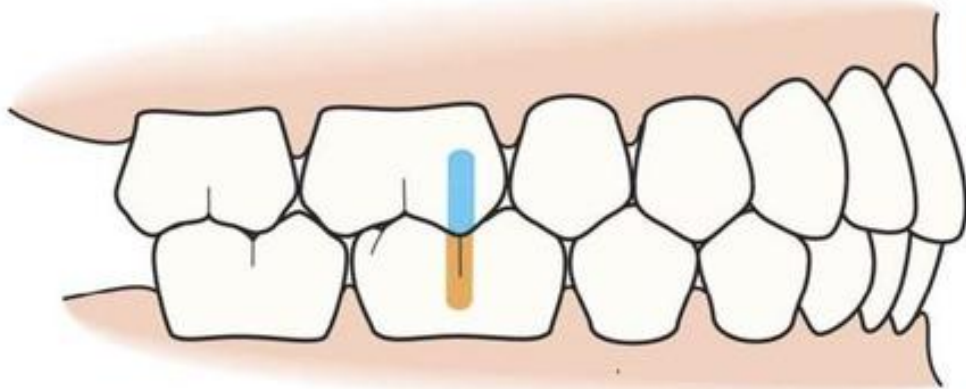


Class III

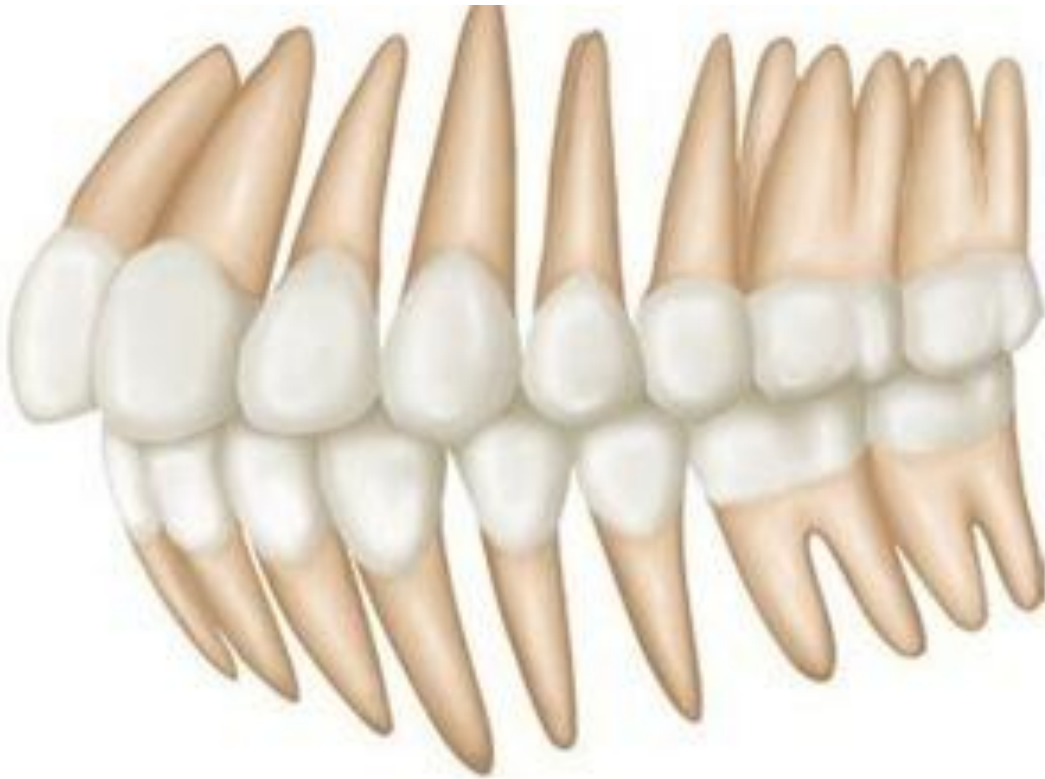


Class I Occlusion: Mesiobuccal cusp of upper 6 occlude **with the buccal groove of lower 6**

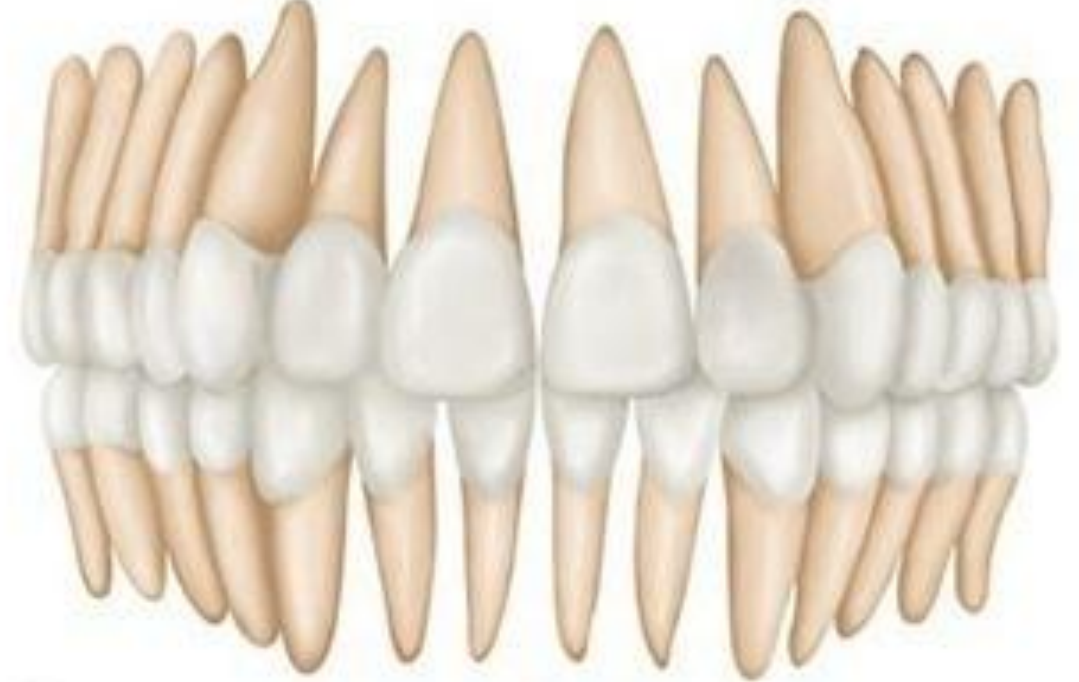Class I



It is considered normal. In such a relationship, the anterior teeth overlap both horizontally and vertically.

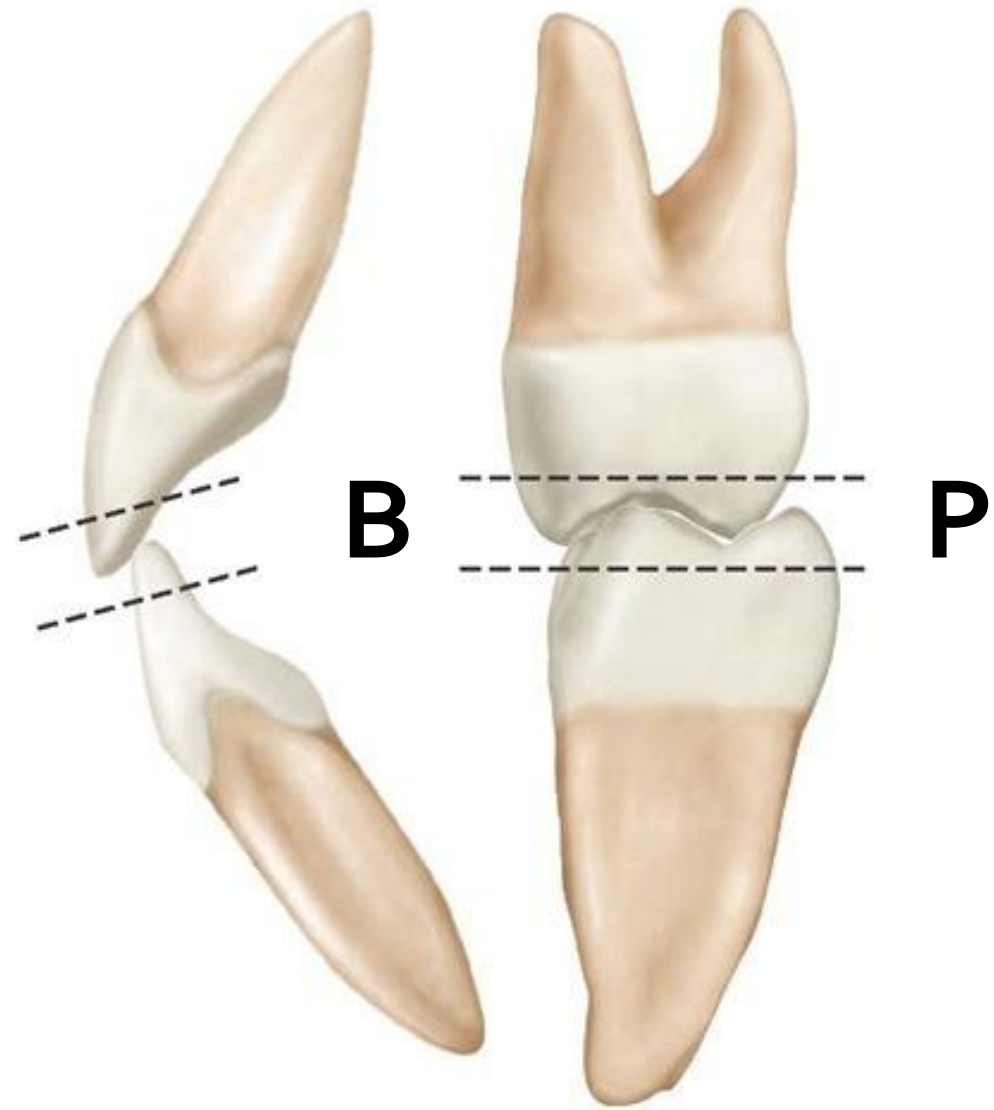


A



B

This means that the maxillary lingual and mandibular buccal cusps of the posterior teeth are evenly distributed and in stable contact with the opposing occlusal fossae.

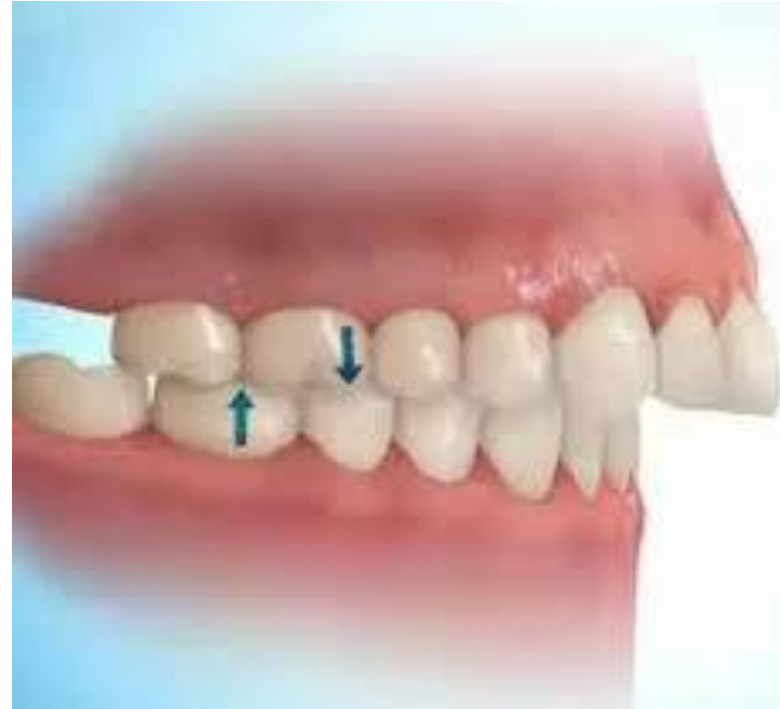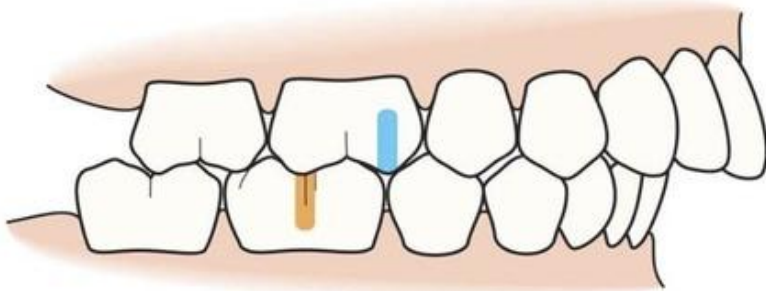


Class II Occlusion:

Mesiobuccal cusp of upper 6 occlude

anterior to the buccal groove of lower 6

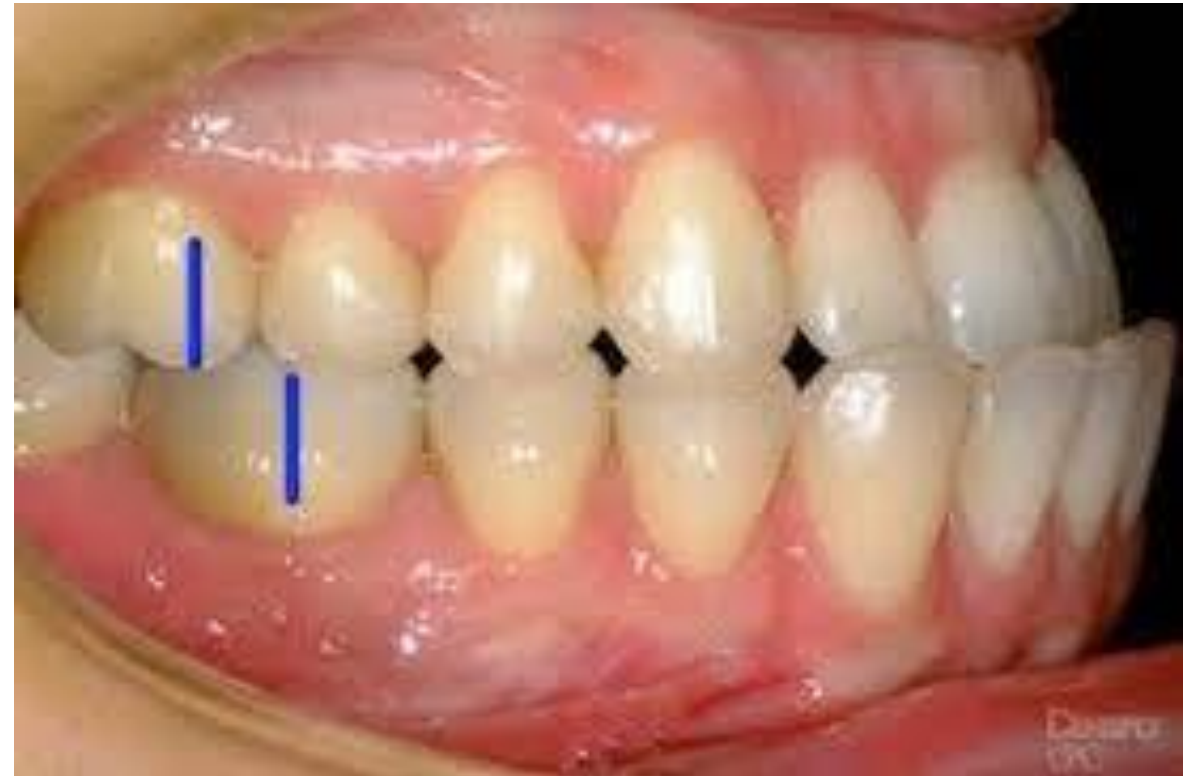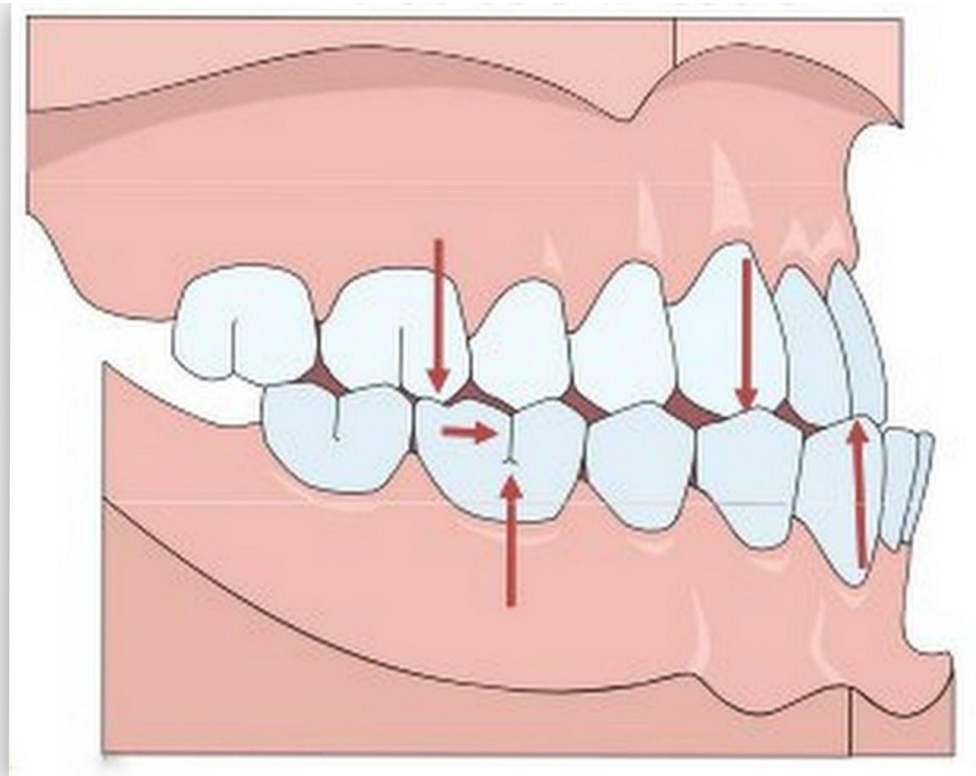
Class II, Division I



Class III Occlusion:

Mesiobuccal cusp of upper 6 occlude

posterior to the buccal groove of lower 6

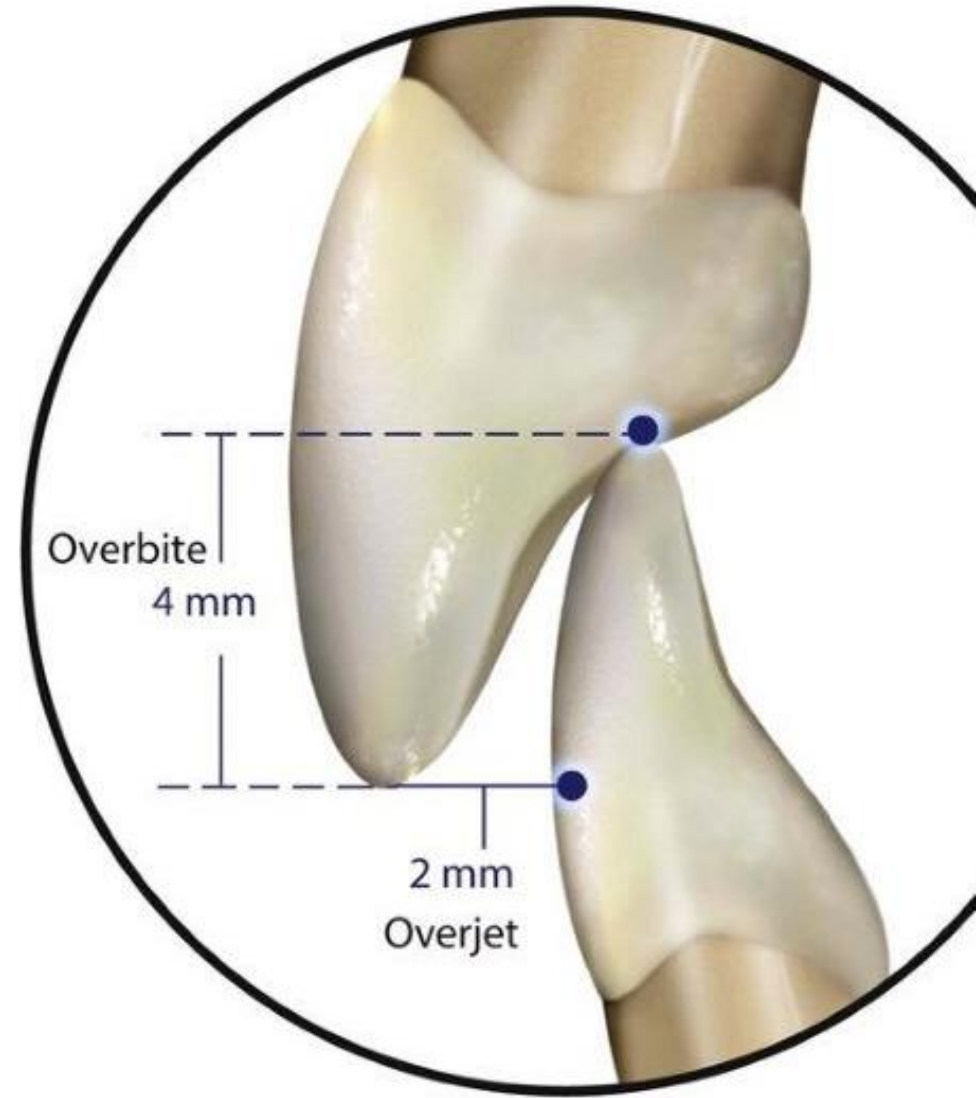


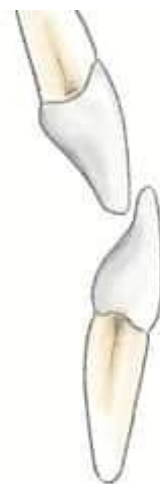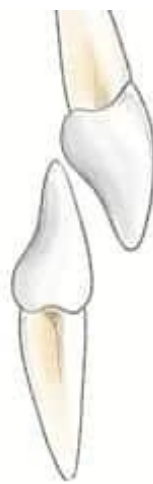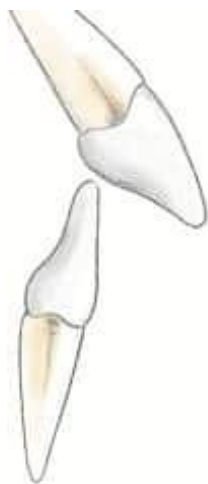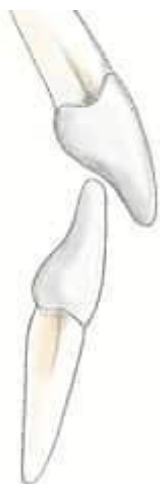Over jet: it is the horizontal

overlap of maxillary central incisors over the mandibular central incisors. The normal overjet is considered to be 2-3 mm.

Over Bite: it is the vertical

overlap of maxillary central incisors over the mandibular central incisors. The normal overbite is considered to be 2-4 mm.

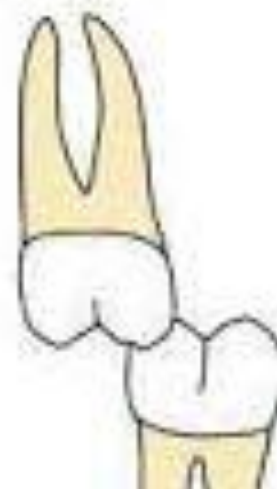
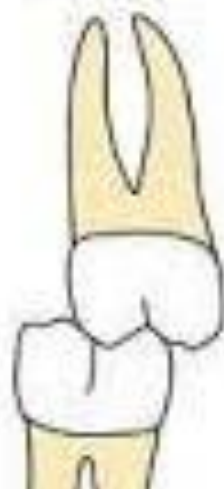
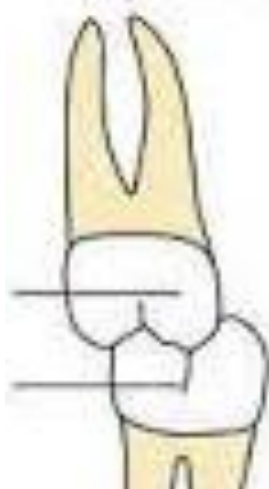




Class I

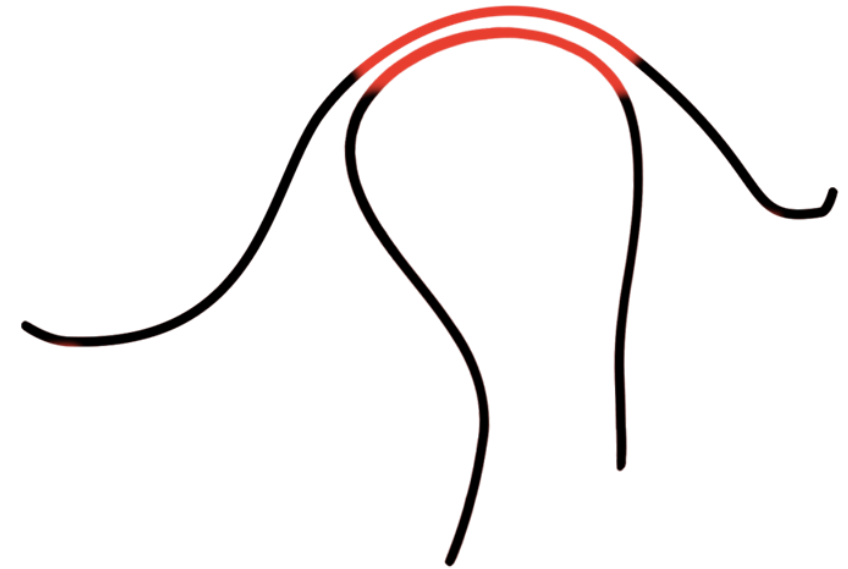
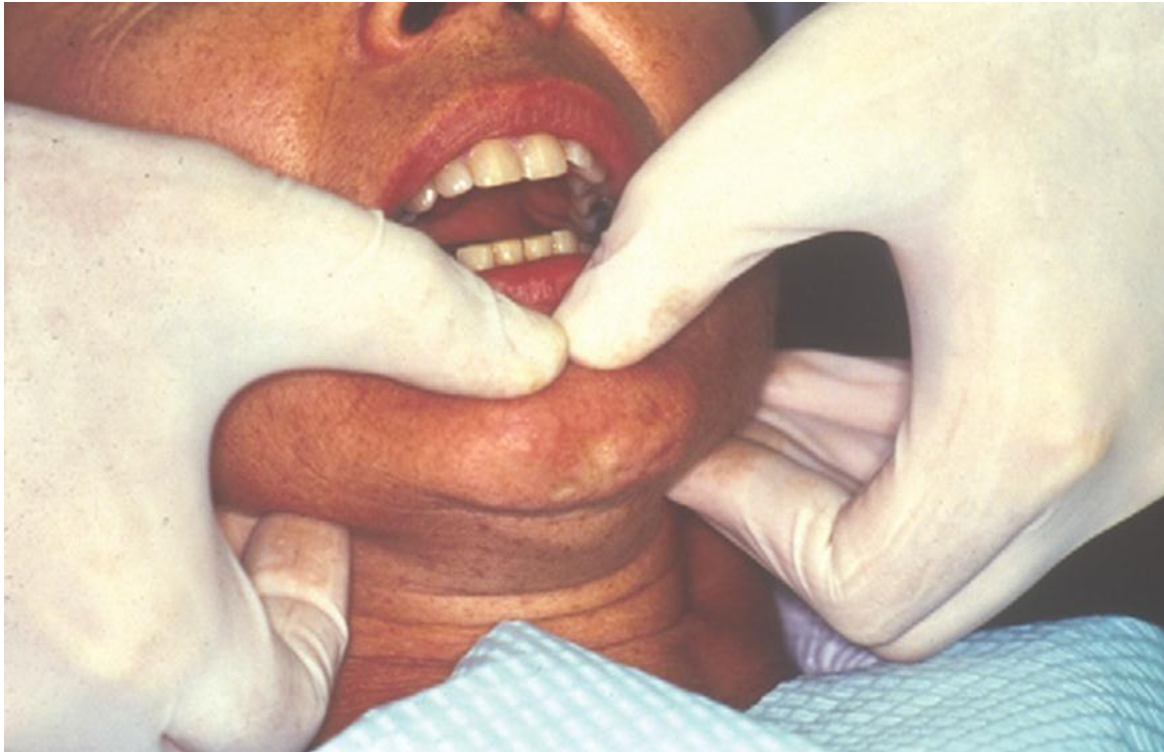Class II

Class III

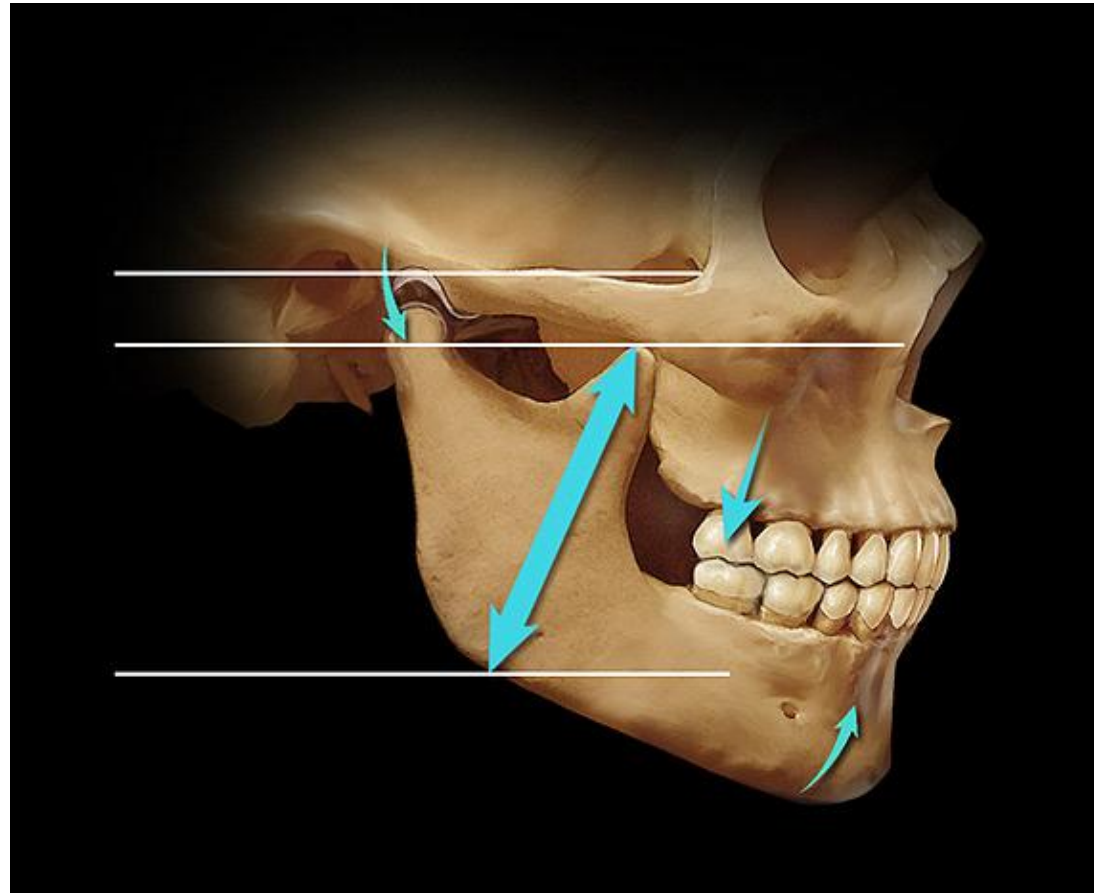


Centric Relation

Centric relation is the most posterior relation of the mandible to the maxilla and the anterosuperior relation of condyle to the glenoid fossa.



- ❖ Centric relation should not be confused with centric occlusion or maximum intercuspation. Centric relation refers to the fully seated condylar position regardless of how the teeth fit.



It is bone to relation It is bone to relation

The centric relation has the following salient features:

- It is **learnable**, **repeatable** and **recordable** position which remains **constant throughout life**.

It acts as a center from which all movements can be made.

- The muscles are arranged in such a way that it is easy to move the mandible to the centric position.

Maximum Intercuspatation

It is the complete intercuspation of the opposing teeth independent of condylar position.

In many patients, maximal intercuspatal contact occurs with the condyles in a slightly translated position. This position is sometimes referred to as the best fit of the teeth regardless of the condylar position.

Optimum occlusion

- In an ideal occlusal arrangement, the load exerted on the dentition should be distributed optimally.
- Any restorative procedures that adversely affect occlusal stability may affect the timing and intensity of elevator muscle activity.
- Horizontal forces on any teeth should be avoided or at least minimized.
- loading should be predominantly parallel to the long axes of the teeth.
- This is facilitated when the tips of the functional cusps are located centrally over the roots and when loading of the teeth occurs in the fossae of the occlusal surfaces rather than on the marginal ridges.

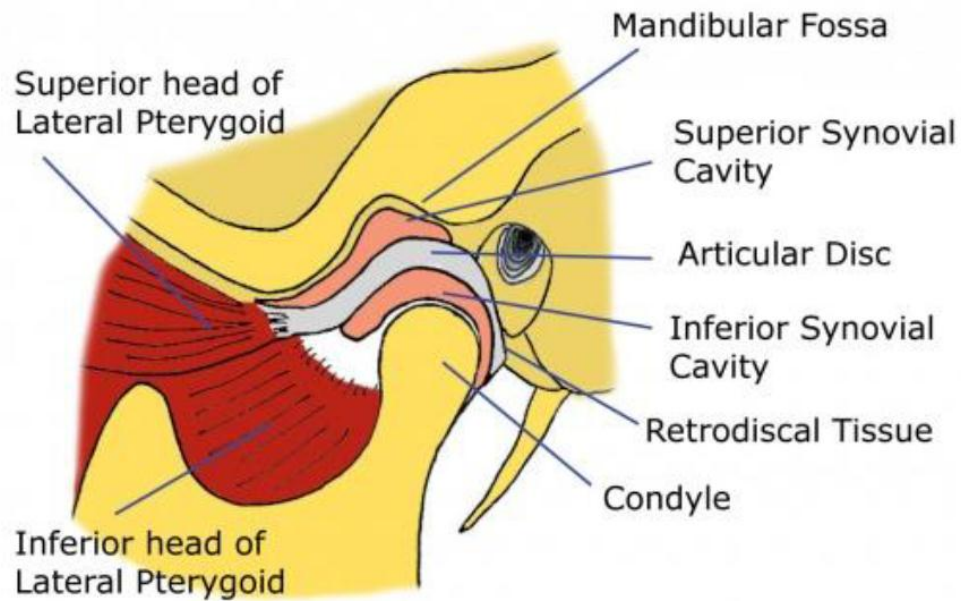
Mandibular Movement

Crown and Bridge III

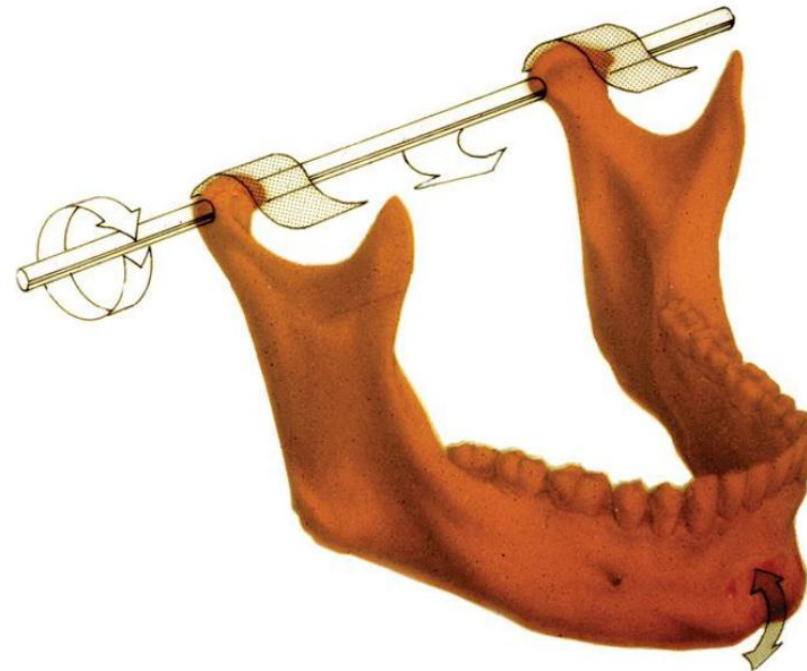
Lecture 2

TMJ Anatomy

The temporomandibular joint: is a bilateral bicondylar synovial arthrodiar joint. The joint has a capsule and an articulating disk. The glenoid fossa and the condyle of the mandible form the articulating surfaces. The joint cannot function independently on each side. Their movements are synchronized and act together to produce the various mandibular movements.



The Temporomandibular Joint

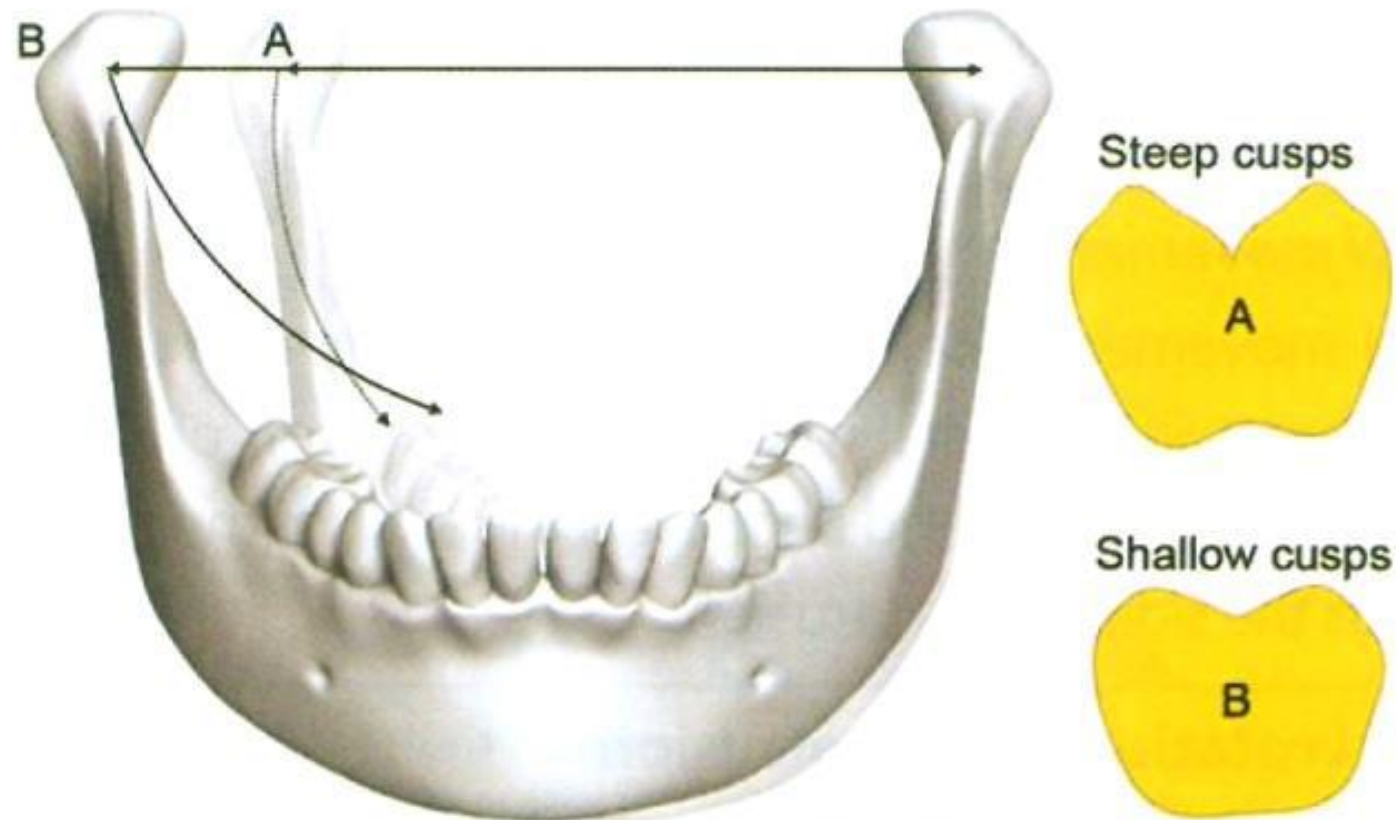


Determinants of Mandibular Movements

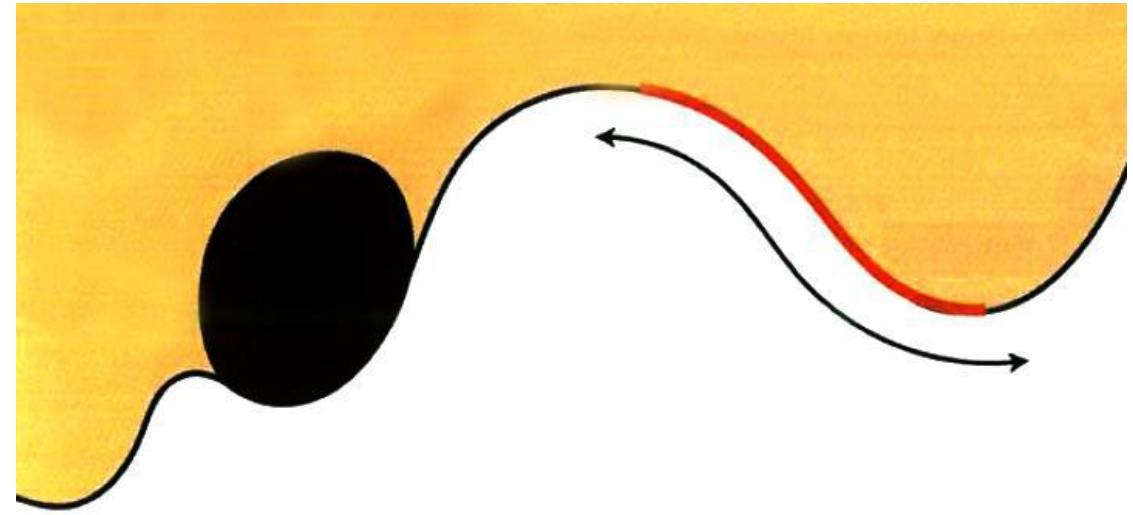
- Condylar guidance: mandibular guidance generated by the condyle and articular disc traversing the contour of the articular eminence.**
- Incisal guidance: The influence of the contacting surfaces of the mandibular and maxillary anterior teeth on mandibular movements.**
- Neuromuscular factors: The muscles of mastication are the most important determinants of mandibular movements Muscular dysfunction should be evaluated before performing jaw relation.**

Intercondylar distance: the distance between the two condyles can also affect the range of mandibular movement and occlusion.


Small inter condylar distance can accommodate steep cusps, while larger intercondylar distance can accommodate shallow cusps.



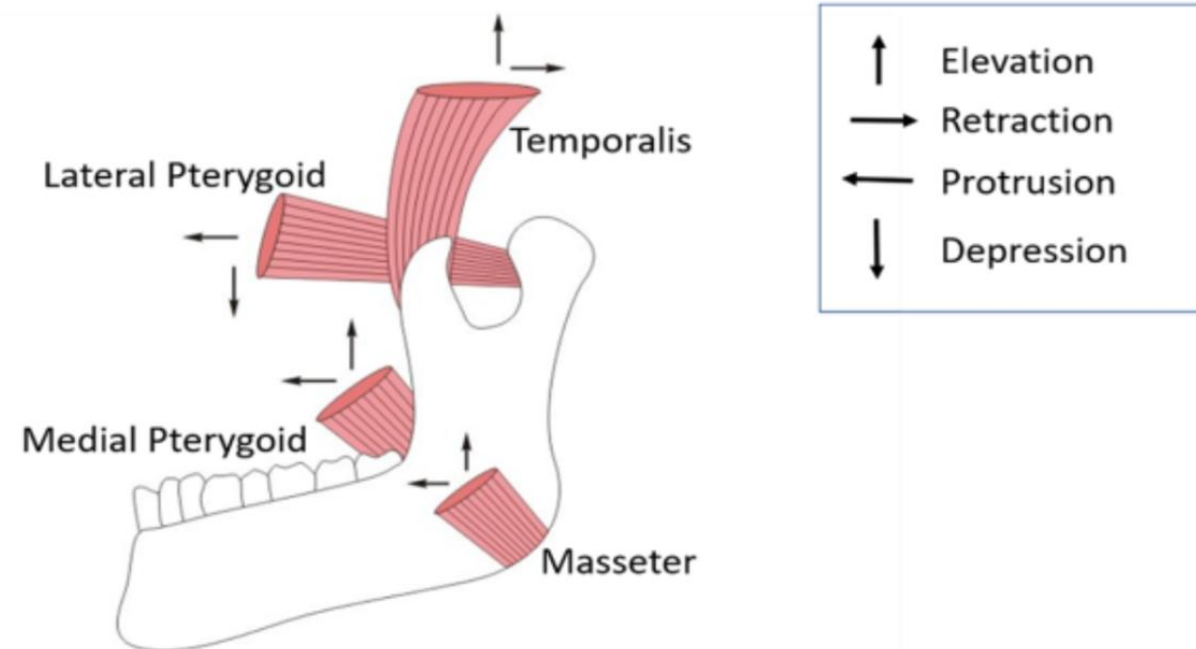
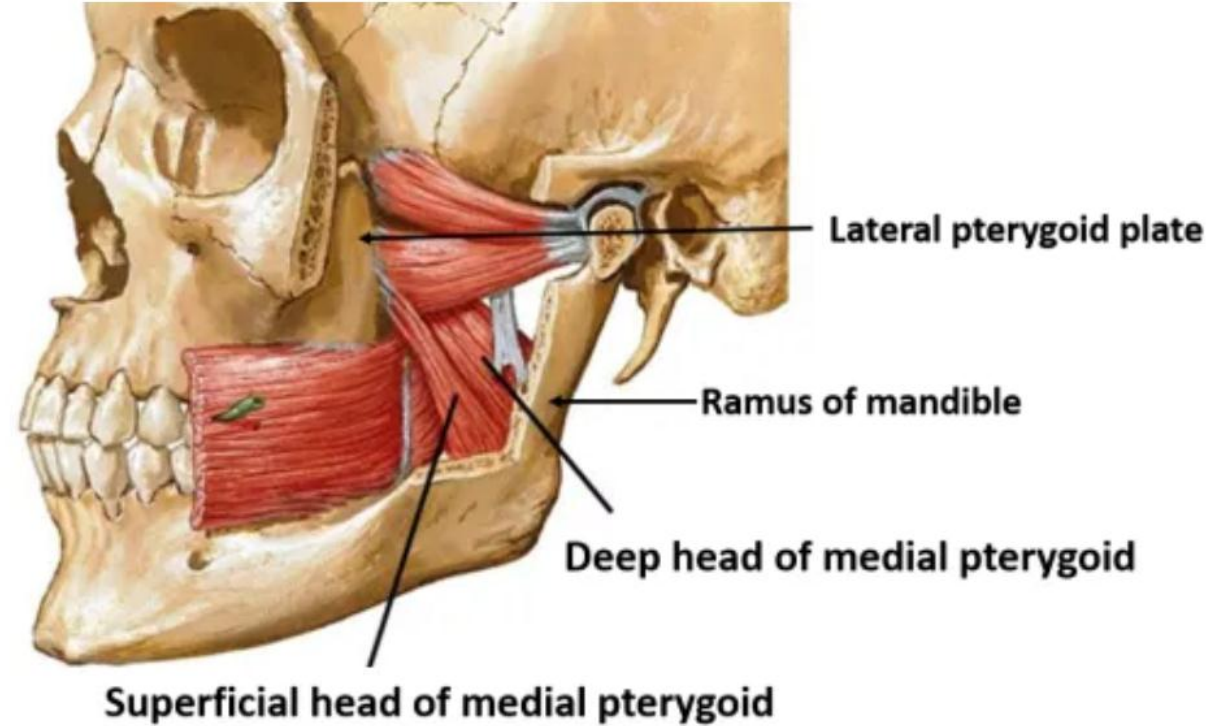
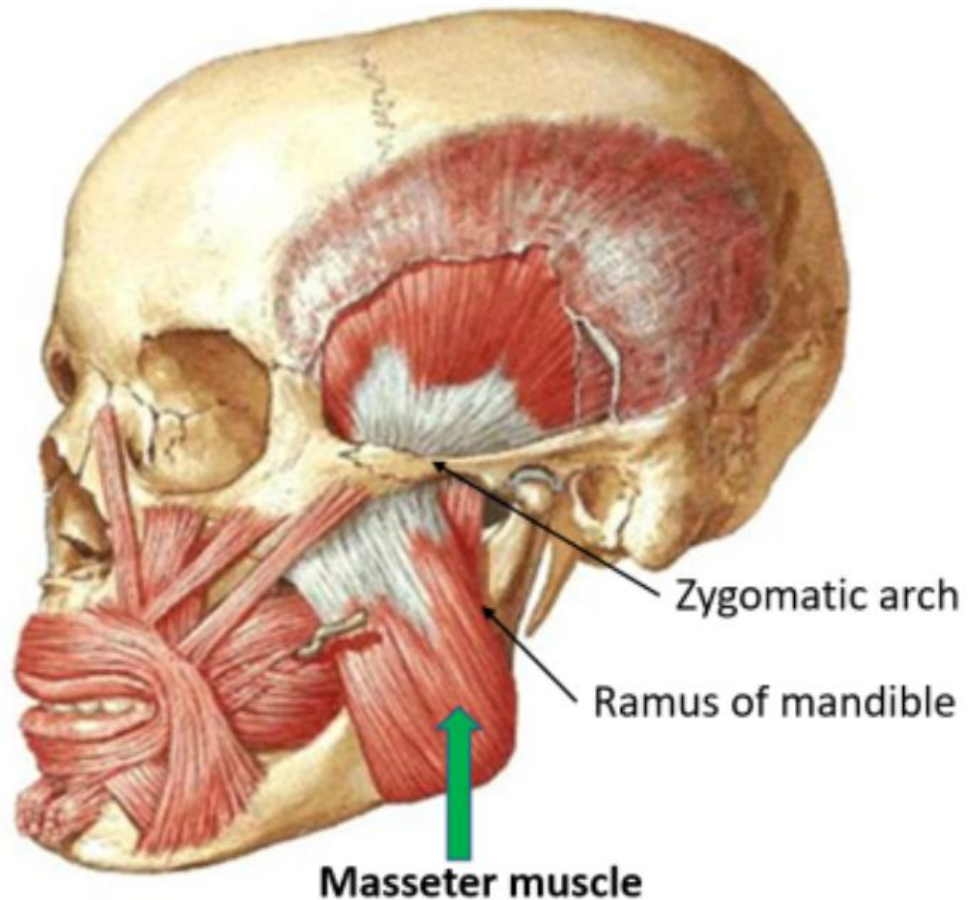
Condylar guidance: The slope of the glenoid fossa is not straight; instead it is an "S" bend.



Incisal guidance: The anatomy of palatal surface of upper incisors and there relationship with the lower incisors.

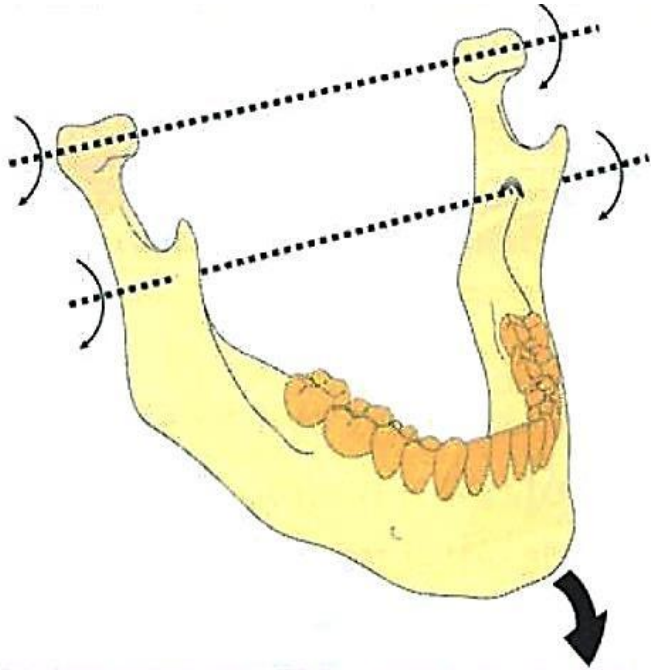


Neuromuscular factors:
The muscles of mastication are the main group responsible for the mandibular movement

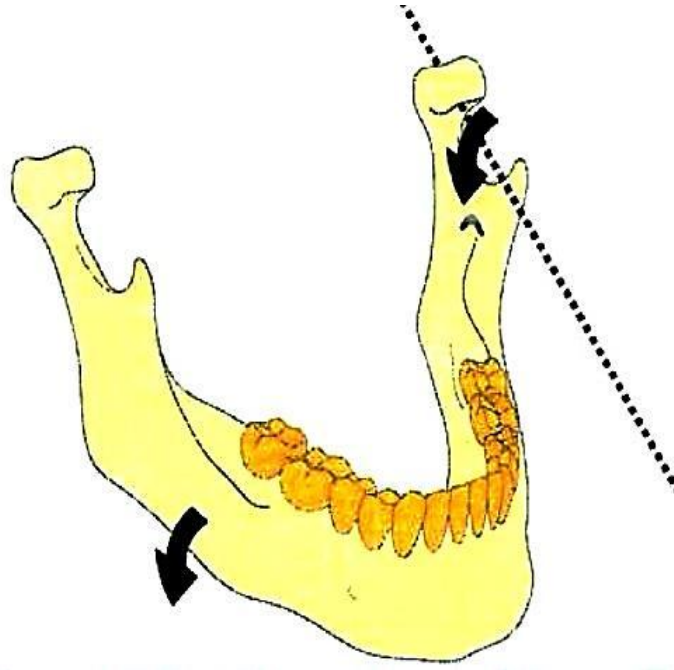


Types of Mandibular Movements

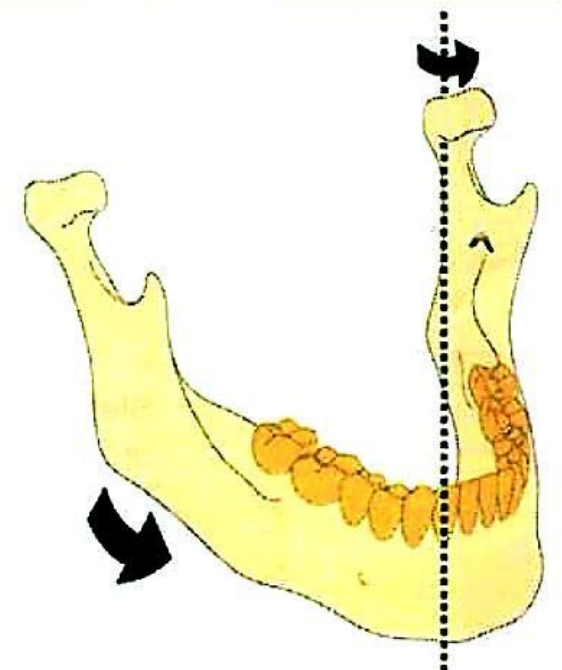
Based on the dimension involved in the movement:



Transverse axis



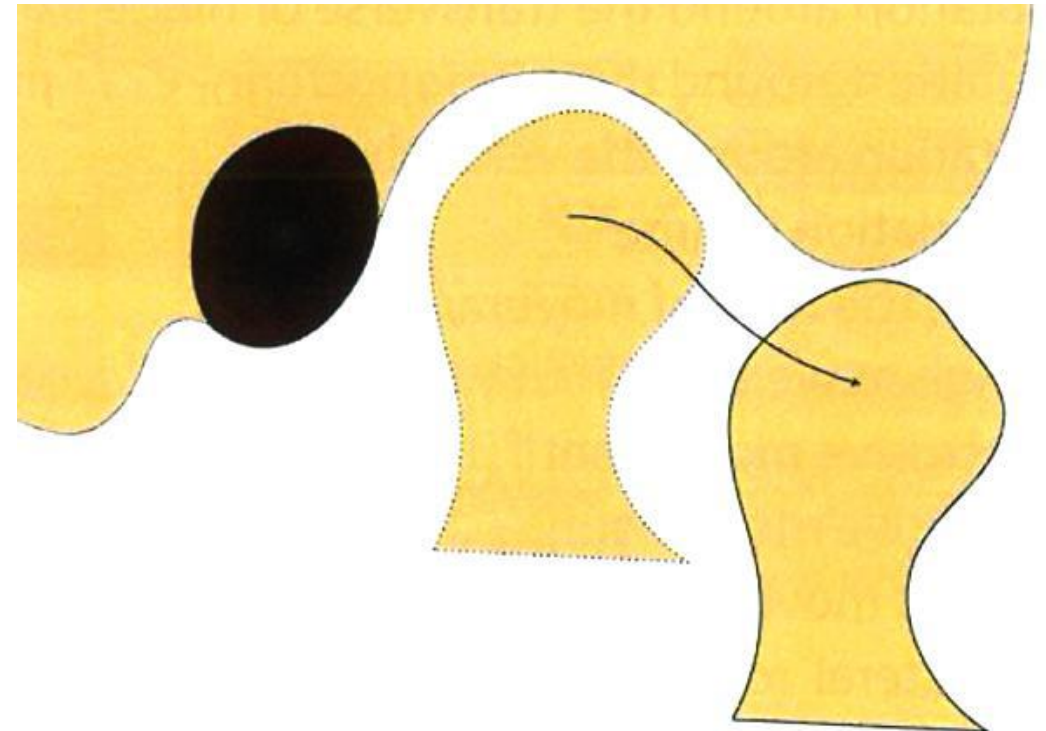
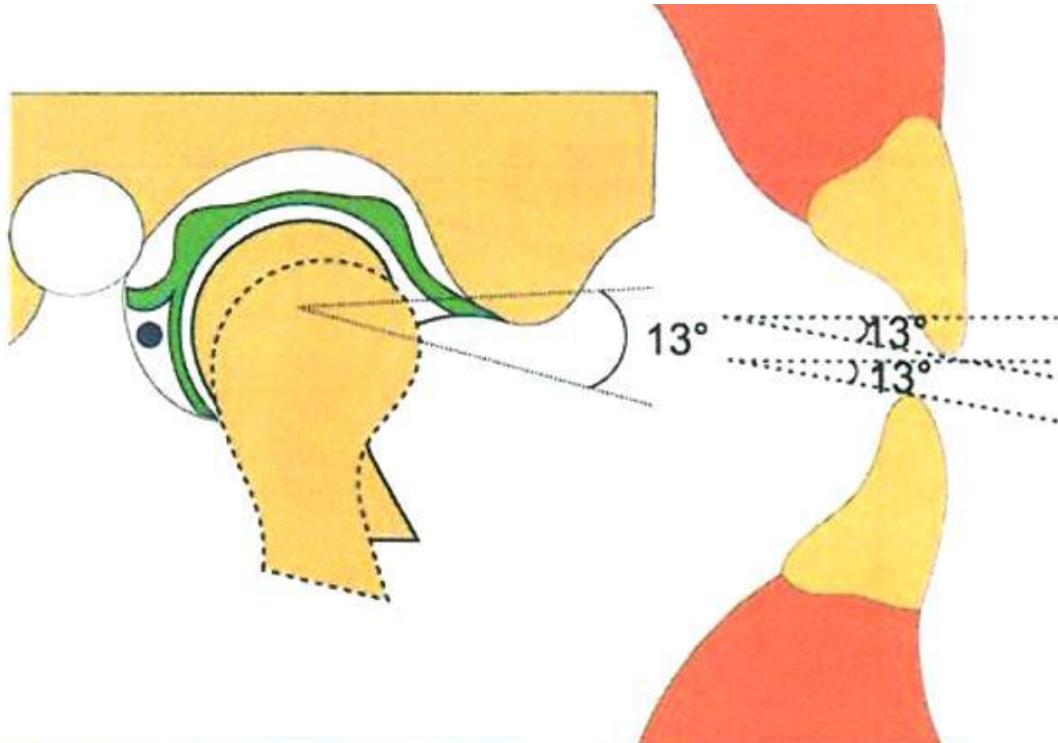
Sagittal axis



Vertical axis

Based on the type of movement:

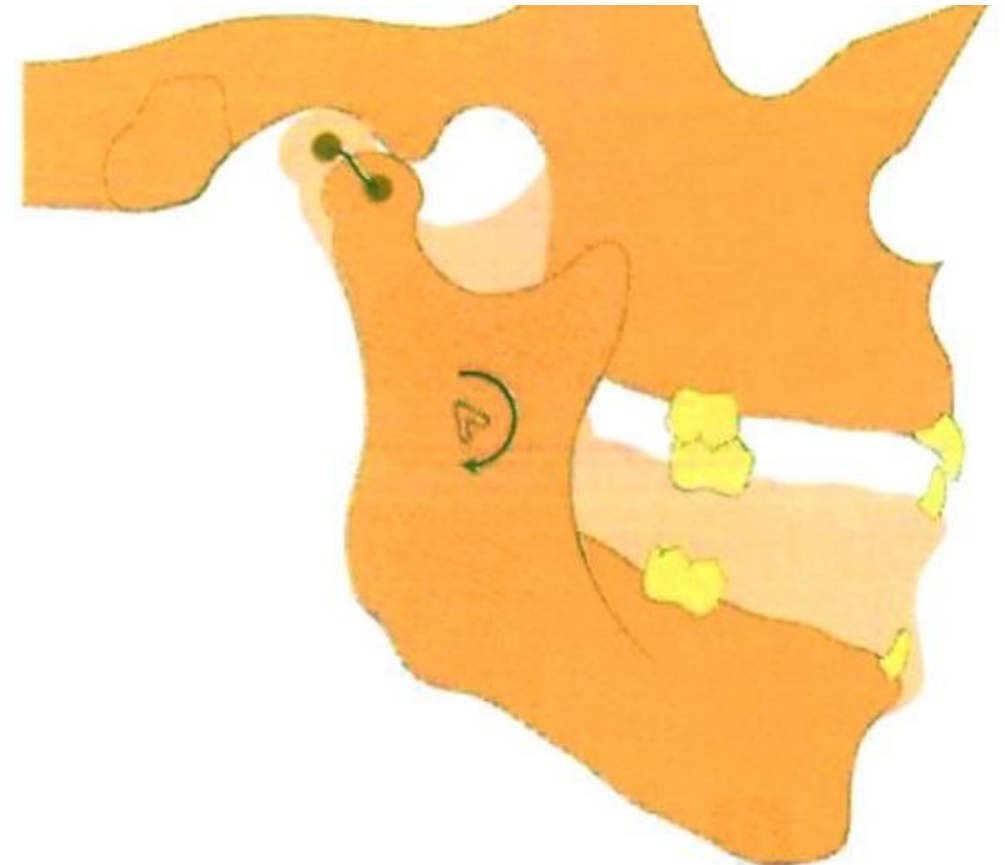
Hinge movement: This is a **purely rotational** movement of the joint, which takes place around a horizontal axis till the patient opens his mouth to about 20-25 mm. The condyle begins to glide after a certain amount of mouth opening (beyond 13° rotation) and this is not considered as a hinge movement.



Based on the type of movement

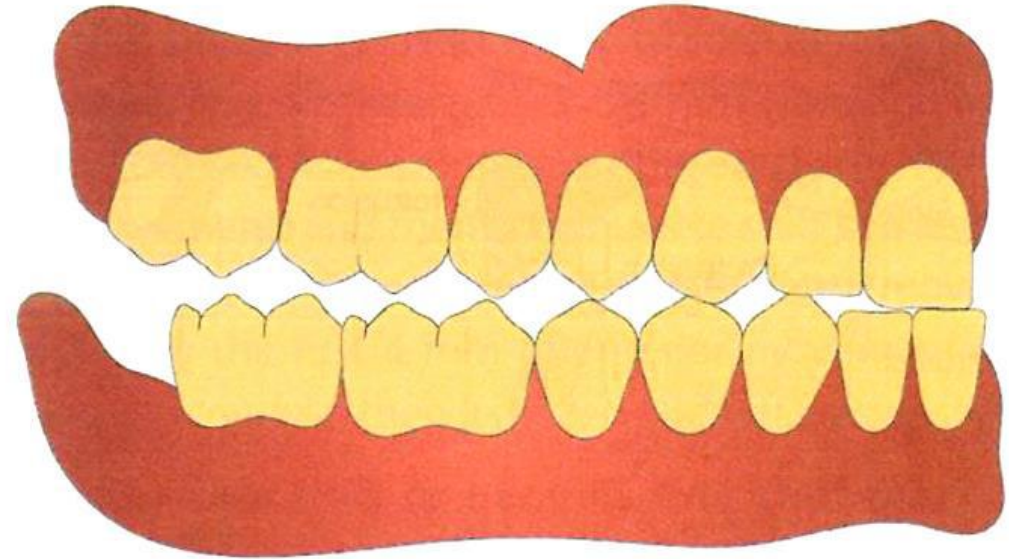
Protrusive movement: When the mandible **slides forwards** and the mandibular and maxillary anterior teeth are in an edge-to-edge relation, the protrusive movement is said to be complete. This movement occurs after the condyles rotate for more than 13° in the temporomandibular joint.

The mandible moves forwards and downwards while rotating in its new hinge axis. Usually the mandible is guided by the anterior teeth during protrusive movement, which is followed by complete disocclusion (separation) of the posterior teeth.



Based on the type of movement

This characteristic posterior separation seen during anterior protrusion is called *Christensen's phenomenon*.

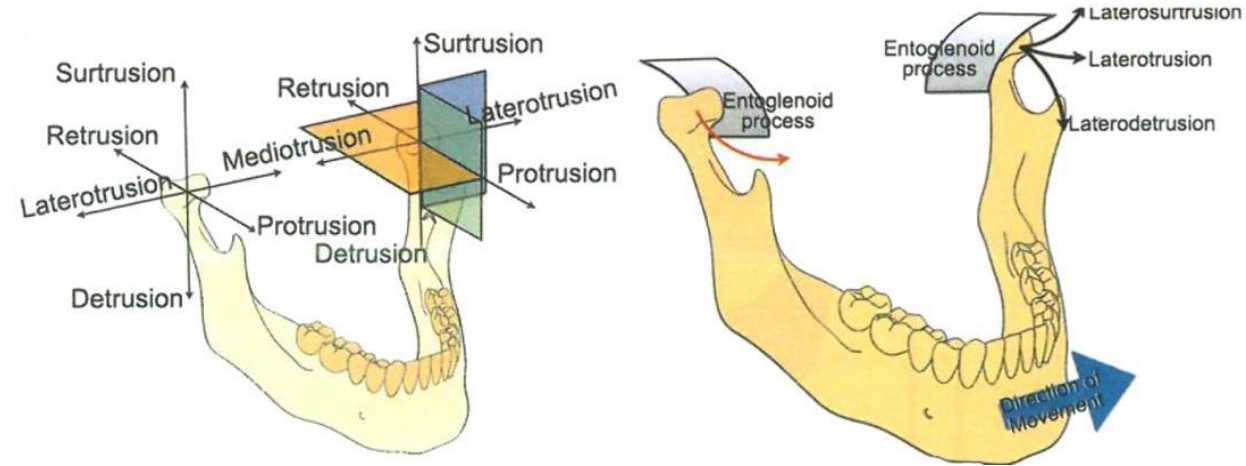


Retrusive movement: This occurs when the mandible is forcefully moved behind its centric relation. The magnitude of this movement is about 0.5 mm. It is usually not a common movement and the patient cannot voluntarily reproduce it.

Based on the type of movement

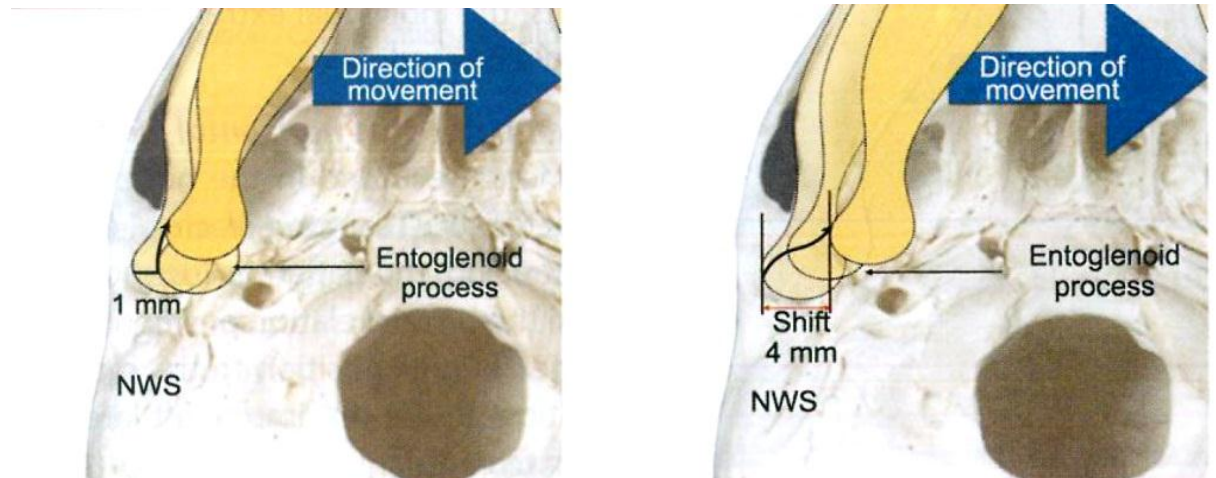
Lateral movement:

Lateral rotation: (Right and left lateral movement) Lateral rotation is the rotation of the mandible to any one side



Lateral translation: or ***Bennett*** movement:

It is the bodily side shift of the mandible which, when it occurs, During lateral movement, the mandible shifts (as a whole) by 1-4mm towards the working side



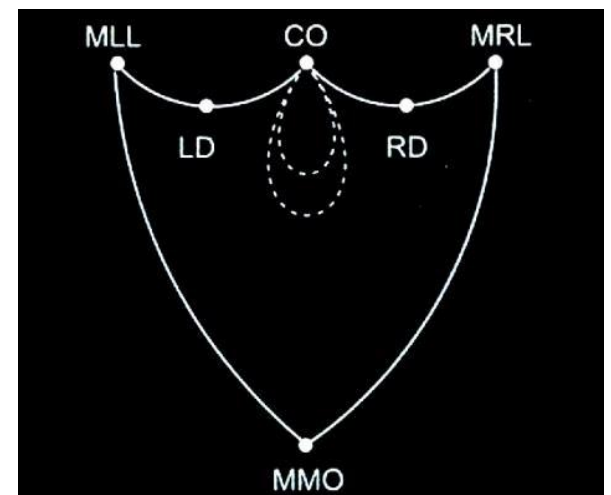
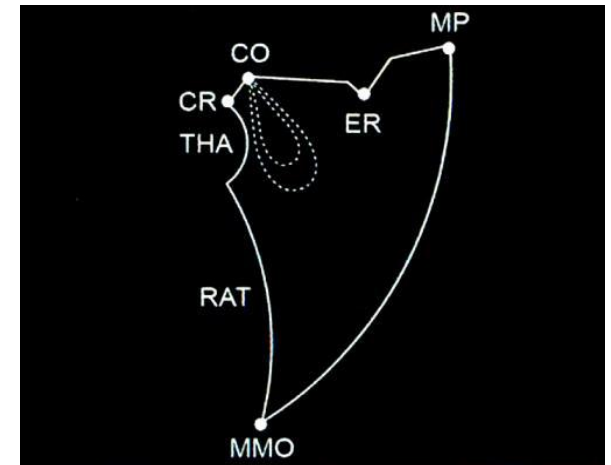
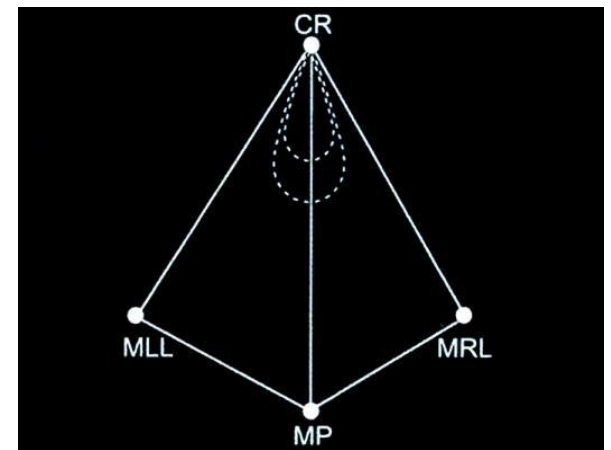
Based on the extent of movement

Border movements: mandibular movement at the limits dictated by anatomic structures, as viewed in a given plane.

Extreme movements in the **horizontal plane:**
produced a characteristic "***Diamond tracing***"

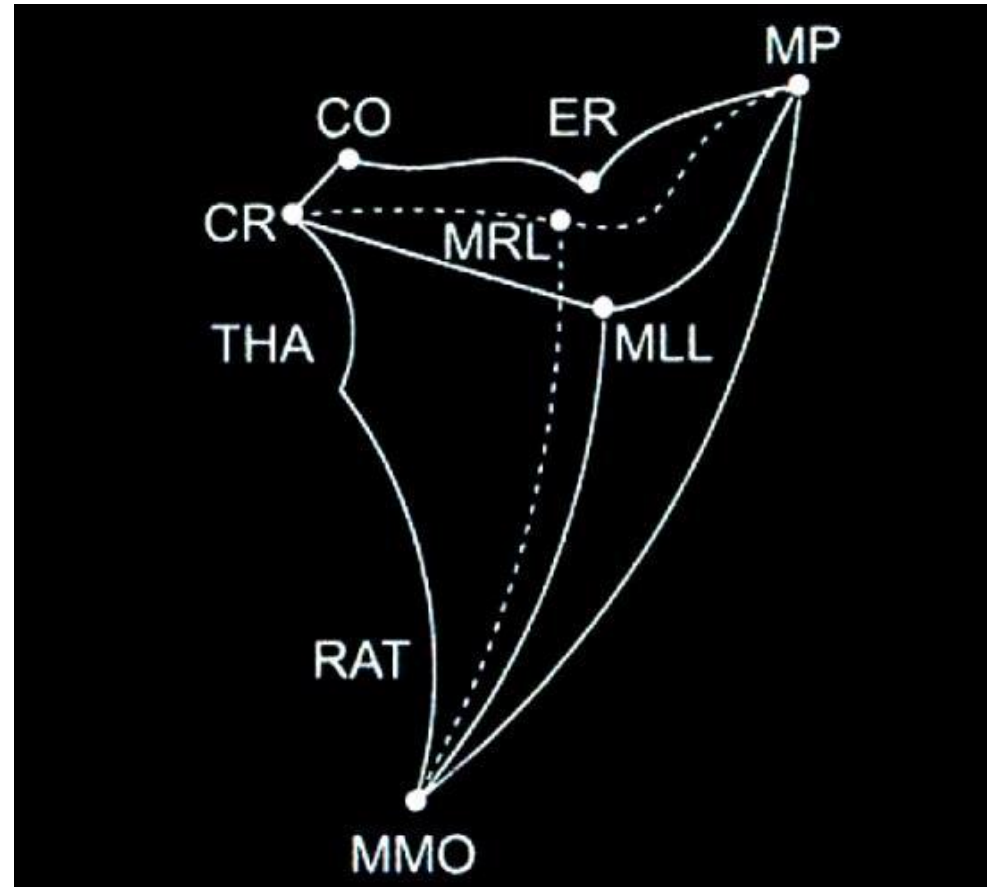
Extreme movements in the **sagittal plane:**
produced a characteristic "***Beak tracing***"

Extreme movements in the **coronal plane:**
produce a characteristic "***shield tracing***"



extent

Envelope of motion: When we combine the border movements of all the three planes, we get a three- dimensional space within which mandibular movement is possible.



Based on the extent of movement

Intraborder movements:

Functional movements

- Chewing cycle
- Swallowing
- Speech

Para-Functional movements

- Clenching
- Bruxism
- Other habitual movements

RECORDING of JAW RELATION

29/10/2022

Abdulrahman



SEQUENCES of RECORDING

Orientation jaw relation

This record gives the angulation of the maxilla in relation to the base of the skull. The plane of the maxilla may be tilted in some patients, in such cases; the plane of the mandible will not be altered because it articulates with the base of the skull.

Vertical jaw relation

Combination of more than one method is recommended in routine practice to overcome the limitations of each individual method.

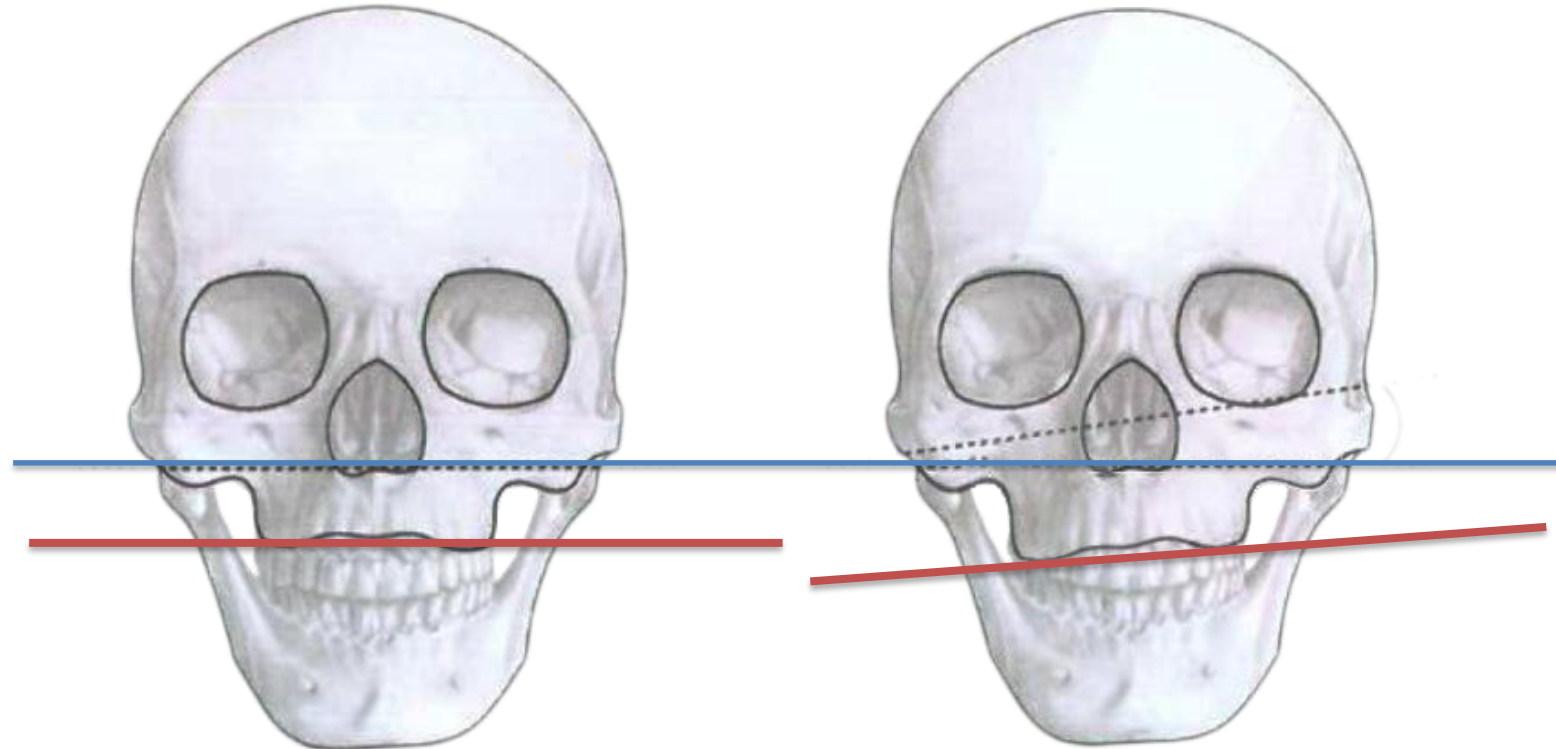
Horizontal jaw relation

Can be of two types namely **centric** and **eccentric** jaw relations

Orientation jaw relation

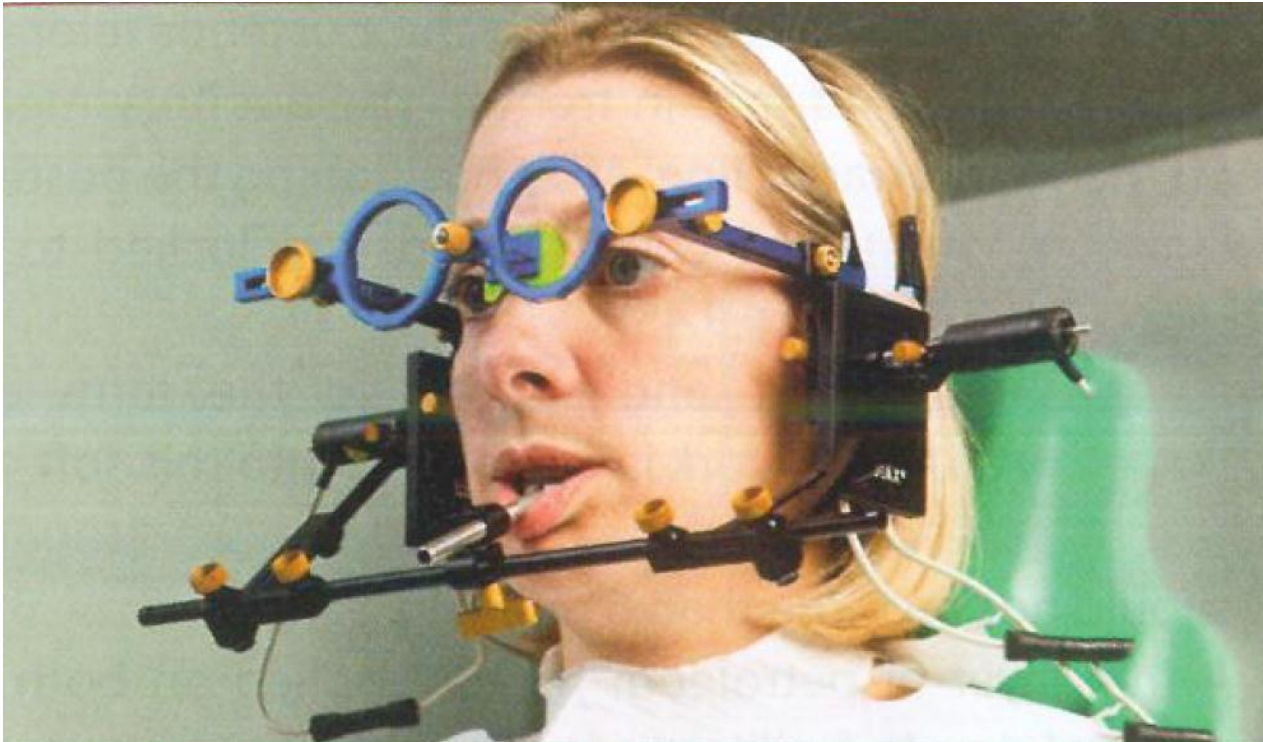It is necessary to do orientation jaw relation before carrying out other jaw relations.

Orientation jaw relation can be recorded with **a face-bow**.



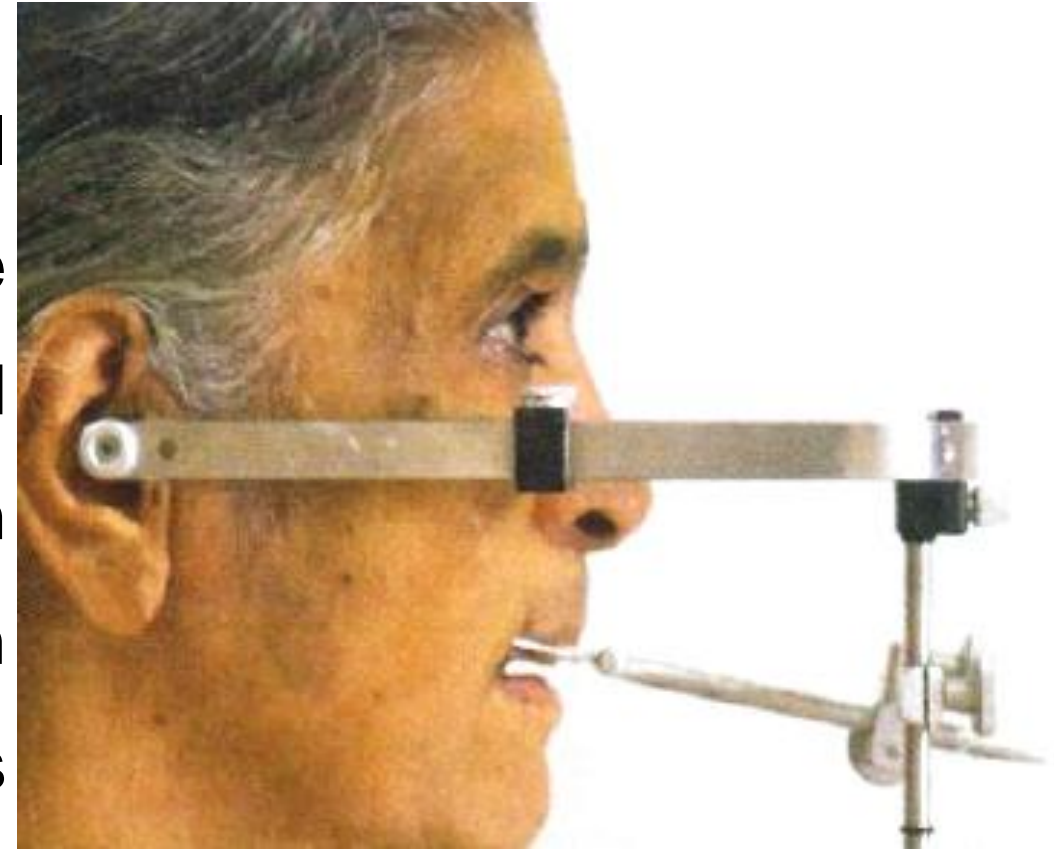
Orientation jaw relation

It is necessary to do orientation jaw relation before carrying out other jaw relations. Orientation jaw relation can be recorded with **a face-bow**.



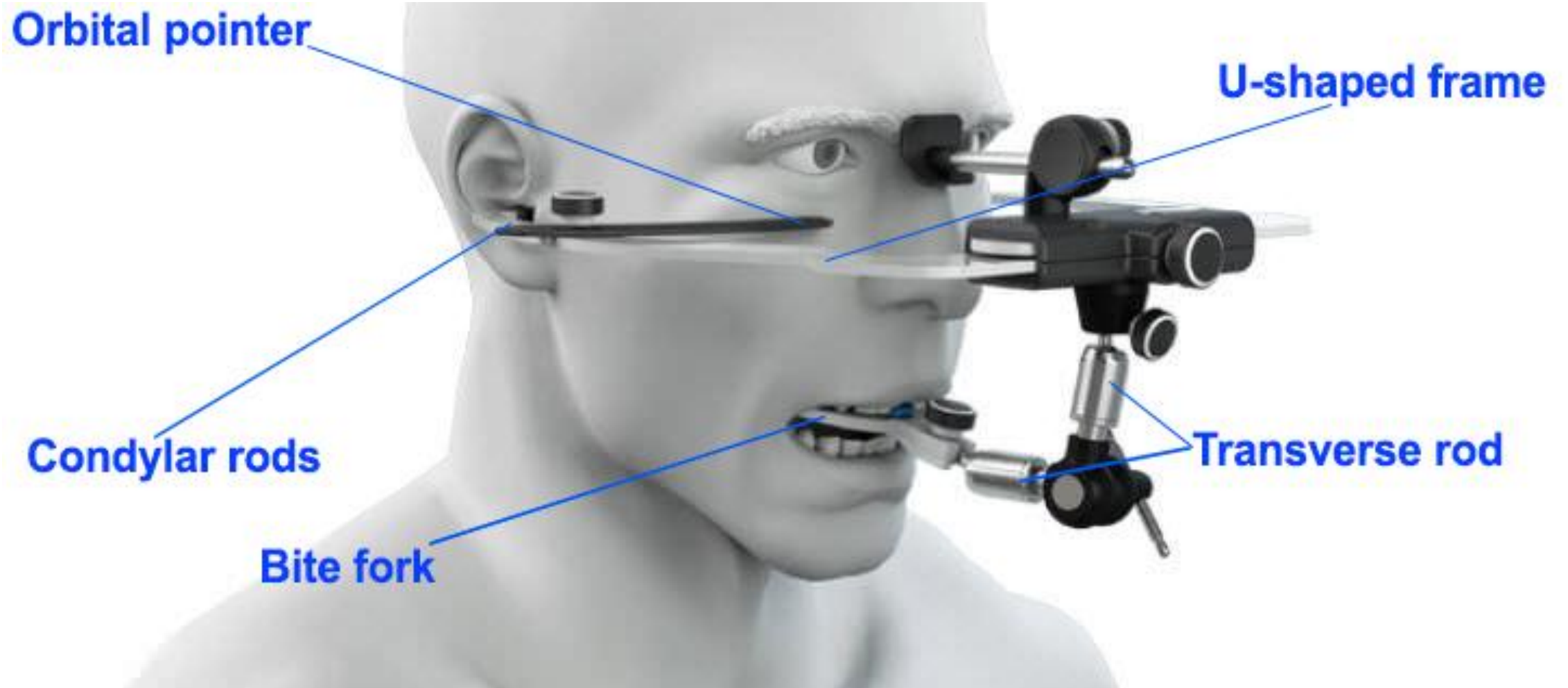
FACE-BOW

an instrument used to record the spatial relationship of the maxillary arch to some anatomic reference point or points and then transfer this relationship to an articulator; it orients the dental cast in the same relationship to the opening axis of the articulator.



Even the most perfect centric relation bite record is inaccurate if used without relating it to the condylar axis. A facebow is a necessity for

The component parts of a Face-bow



Face- bows can be classified as follows



ARBITRARY FACE-BOW

- It is the most commonly used face-bow in **complete denture** construction



KINEMATIC FACE-BOW

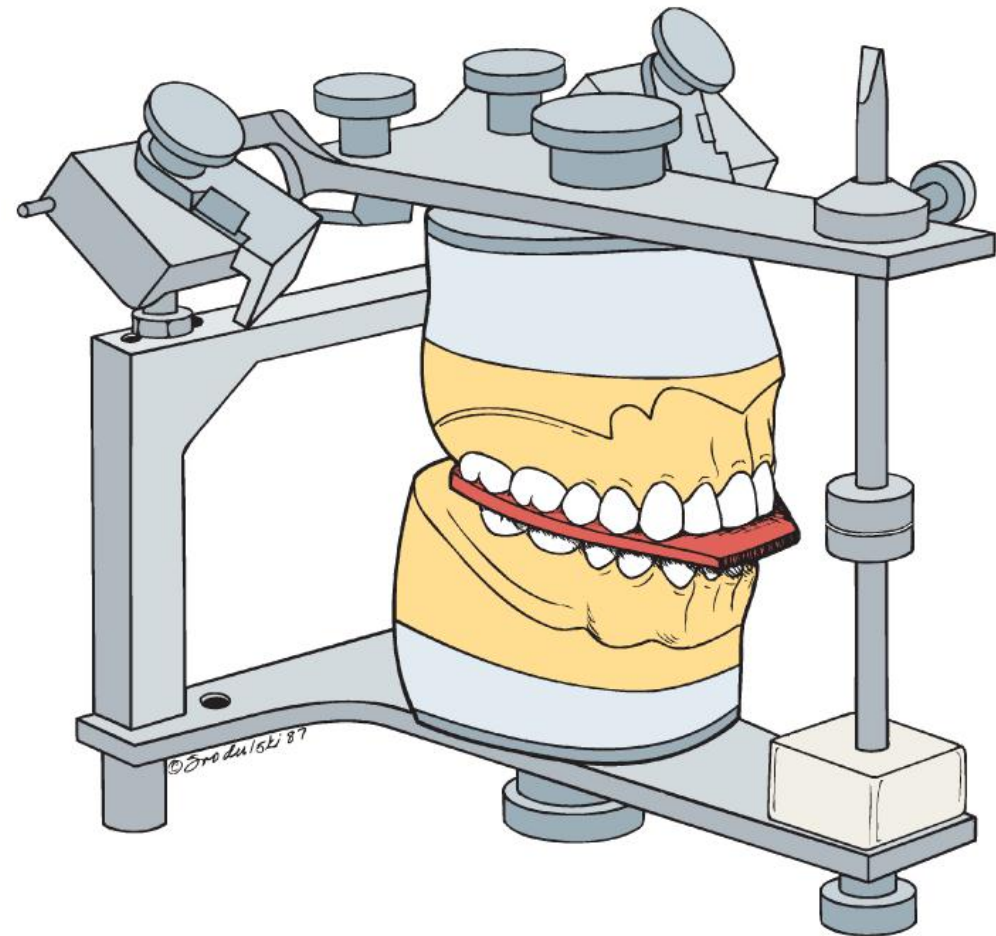
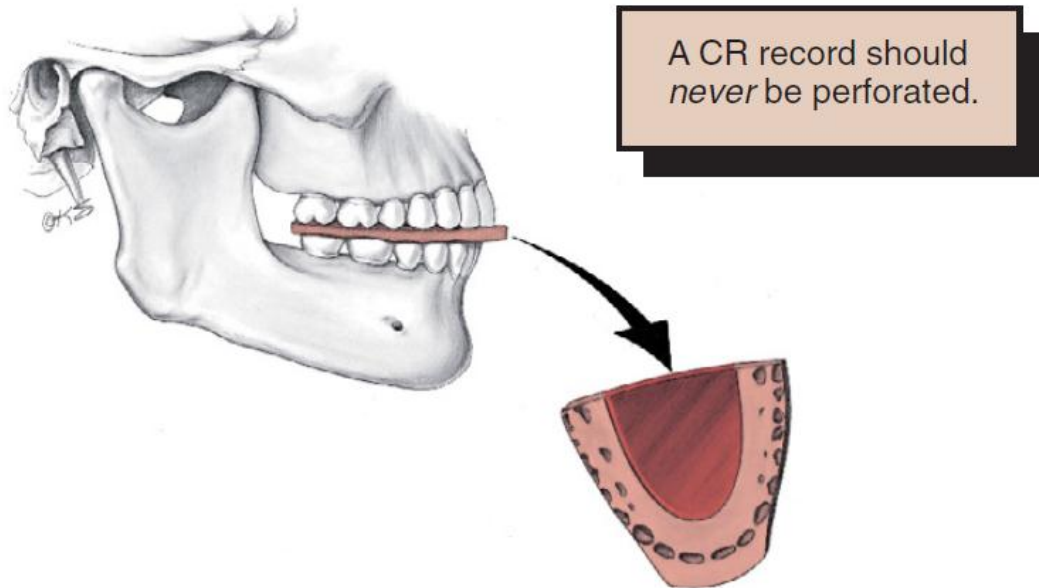
- This face-bow is generally used for the fabrication of fixed partial denture and full-mouth rehabilitation.
- It requires a long and complex procedure to record the orientation jaw relation.
- This face-bow requires a fully adjustable articulator to accept the true hinge axis

Crown and Bridge III

Lecture 4

5/Nov/2022

Articulators: a mechanical device that simulates mandibular movement.



- ❖ If an articulator closely reproduces the actual border movements of a given patient, chair time is significantly reduced because the dental laboratory can then design the prosthesis to be in functional harmony with the patient's movements.
- ❖ Instrument selection depends on the type and complexity of treatment needs

ARTICULATOR CLASIFICATION

They are classified according to how closely they can reproduce mandibular border movements.

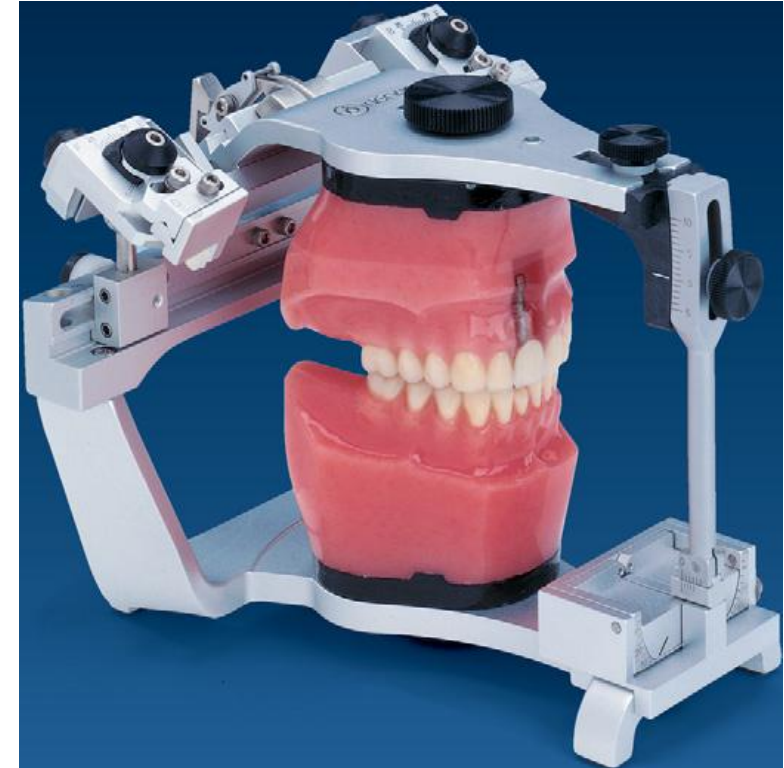Small Nonadjustable Articulators



Semi adjustable articulators

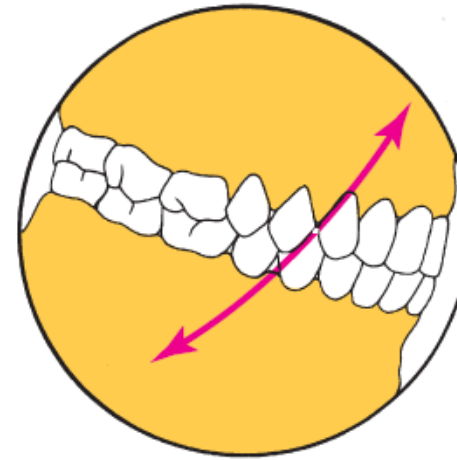
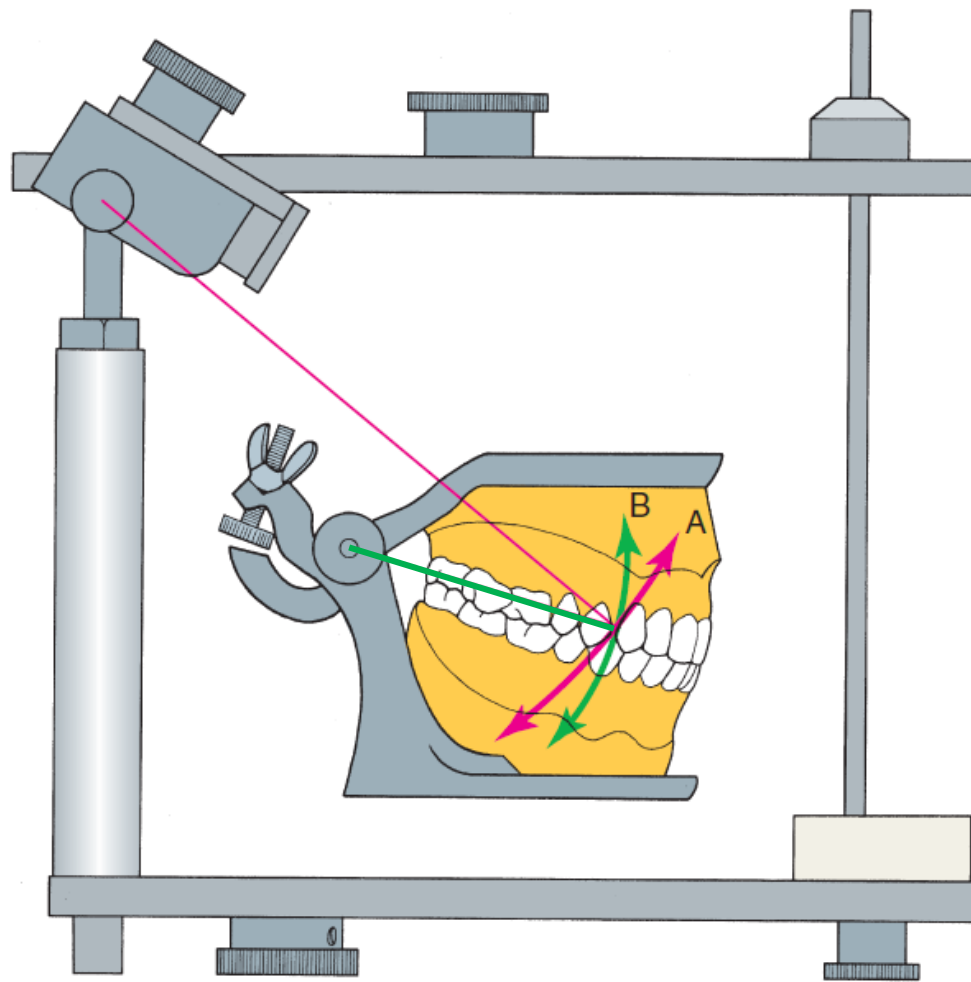


Fully adjustable articulators



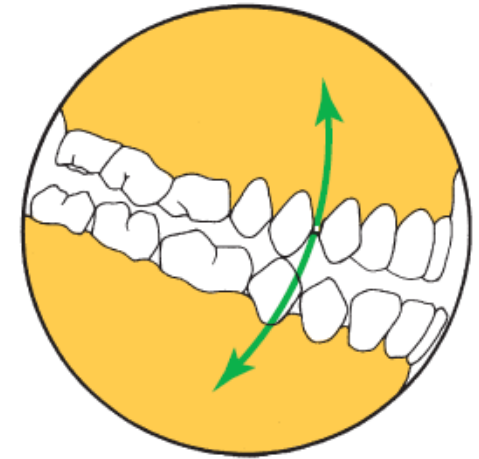
Small Nonadjustable Articulators

- ❖ Nonadjustable do not have the capacity to reproduce the full range of mandibular movement.
- ❖ Their use often leads to restorations with occlusal discrepancies.
- ❖ Some discrepancies can be corrected intraorally.
- ❖ The distance between the hinge and the tooth to be restored is significantly less on most nonadjustable articulators than in the patient.



A

Anatomically accurate articulator



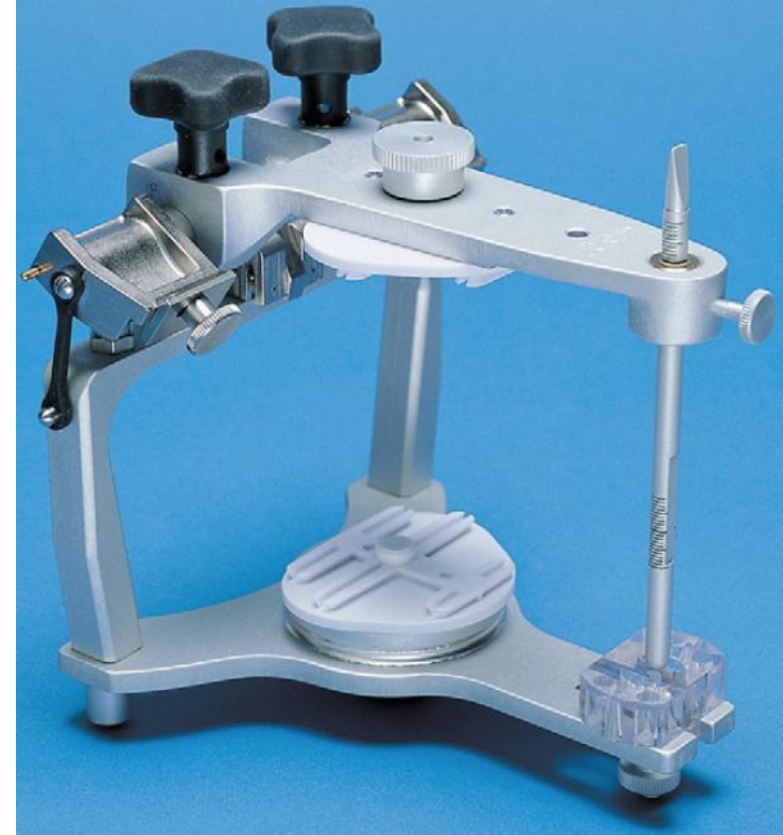B

Nonadjustable articulator

❖ The small nonadjustable instrument has a smaller radius Closure path, which results in premature contact at the clinical try-in between the premolars during hinge closure.

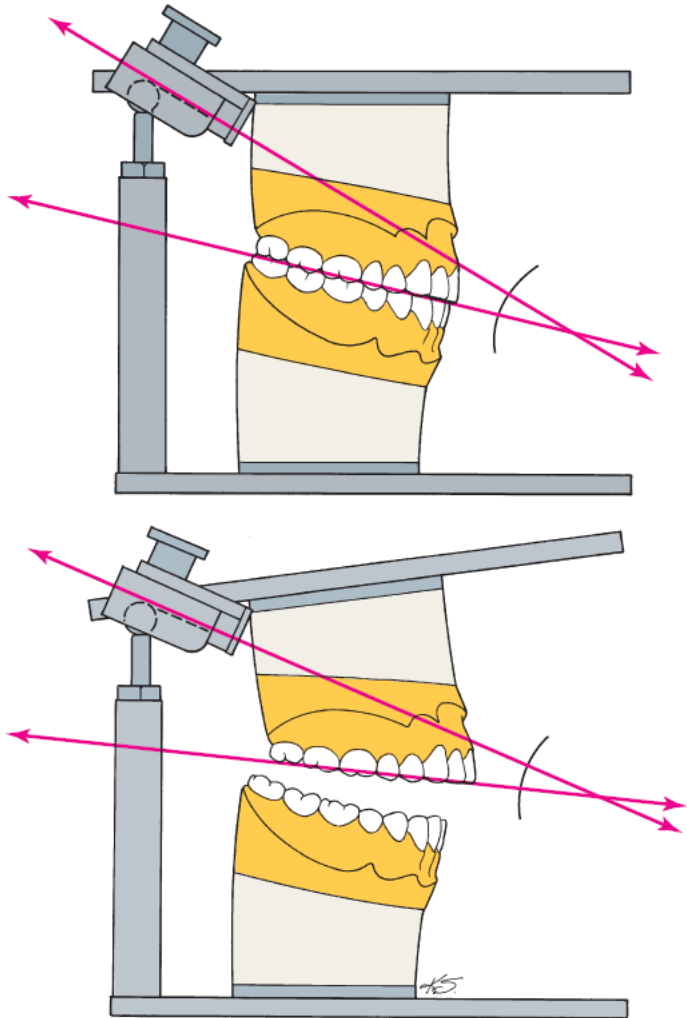
Semiadjustable Articulators

- ❖ It is a practical approach to providing the necessary diagnostic information while minimizing the need for clinical adjustment during treatment.
- ❖ They are about the same size as the anatomic structures they represent.
- ❖ Minimal time should be required for chairside adjustments of fabricated prostheses.



There are two basic designs

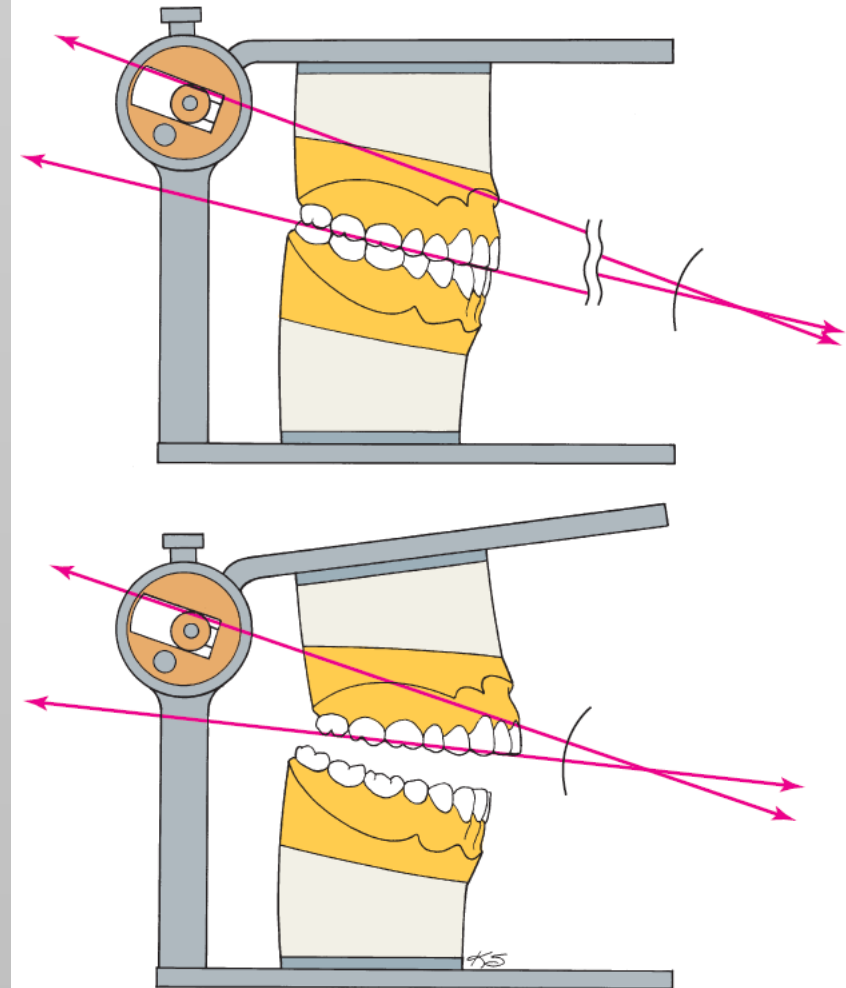
The arcon



An advantage of the *arcon* design is that the condylar inclination of the mechanical fossae is at a fixed angle to the maxillary occlusal plane.

With the *nonarcon* design, the angle changes as the articulator is opened, which can lead to errors when a protrusive record is being used to program the articulator.

The nonarcon



The arcon

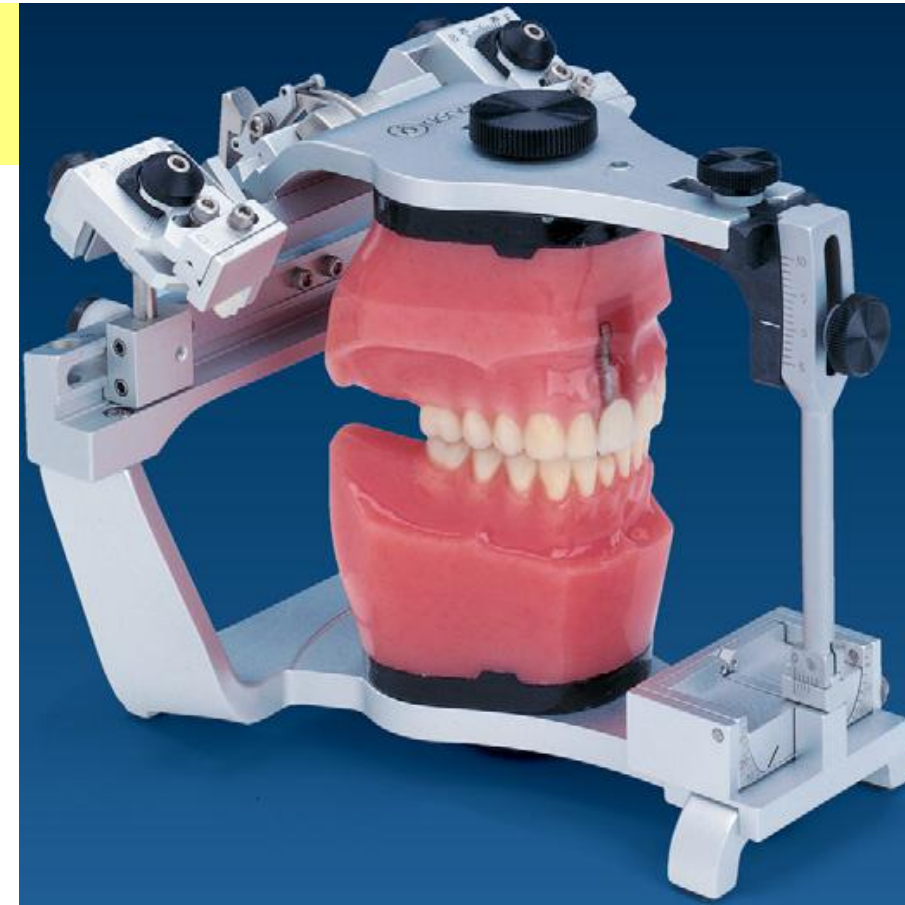The condylar spheres are attached to the lower component of the articulator, and the mechanical fossae are attached to the upper member of the instrument. Thus, the arcon articulator is anatomically “correct,” which makes understanding of mandibular movements easier.

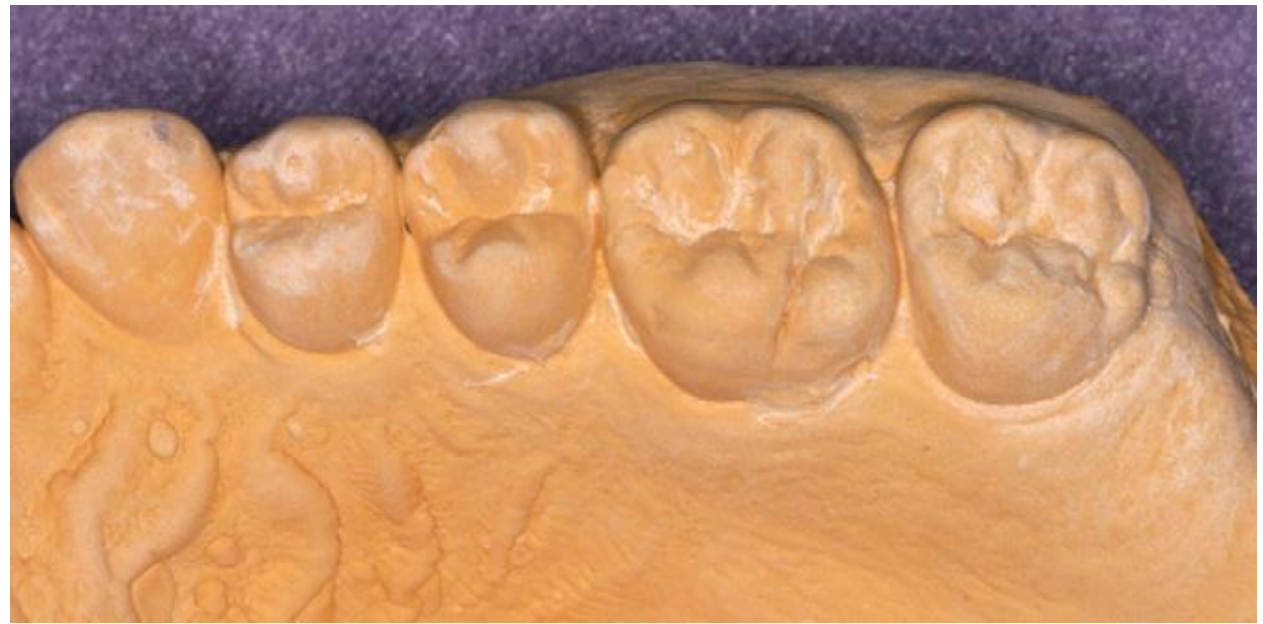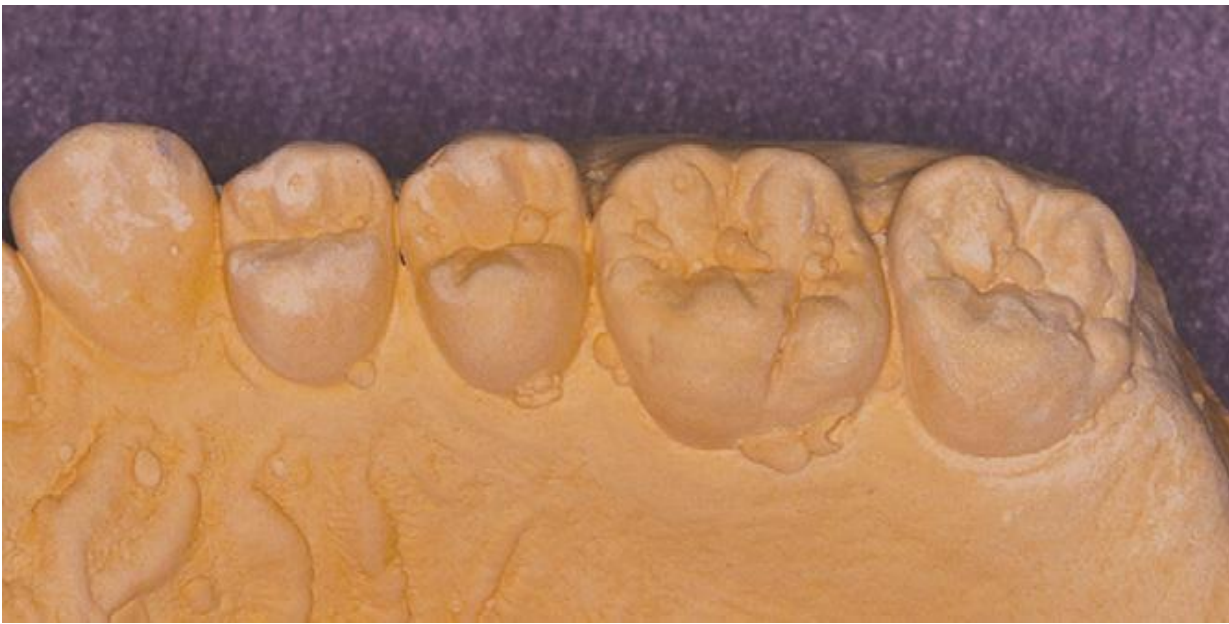The nonarcon

Mostly used in complete denture prosthodontics because the upper and lower members are rigidly attached, enabling easier control when artificial teeth are positioned. As a consequence of their design, however, certain inaccuracies occur

Fully Adjustable Articulators

- ❖ A fully (or highly) adjustable articulator has a wide range of positions and can be set to follow a patient's border movements.
- ❖ special pantographic tracings are used to record the patient's border movements in a series of tracings.
- ❖ The ability of fully adjustable instruments to track irregular pathways of movement enables the fabrication of complex prostheses, which require minimal adjustment.





- ❖ Diagnostic casts must be accurate if they are to articulate properly. Occlusal nodules may make proper occlusal analysis impossible. Proper technique ensures a satisfactory cast.

Occlusal Plane Design

Crown and Bridge III

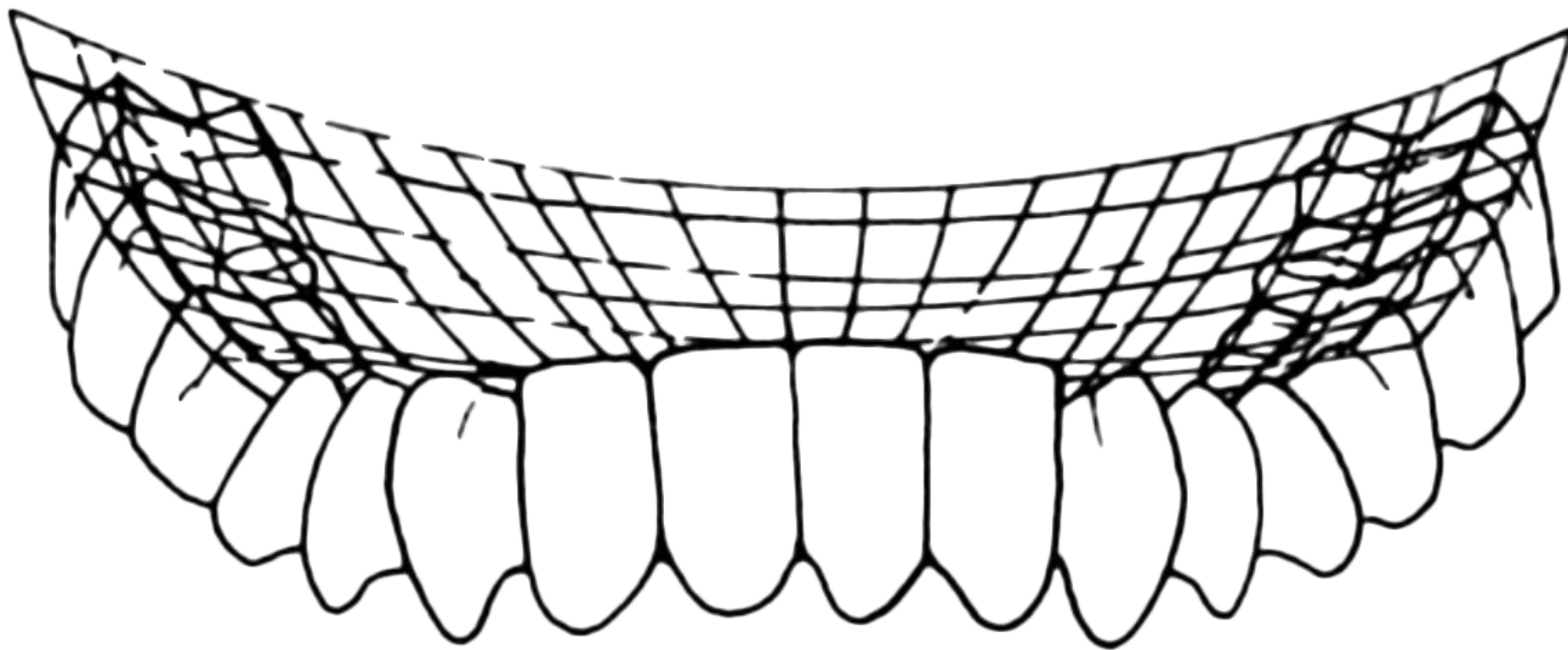
Lecture 5

OCCLUSAL PLANE

The term plane of occlusion refers to an imaginary surface that theoretically touches the incisal edges of the incisors and the tips of the occluding surfaces of the posterior teeth.

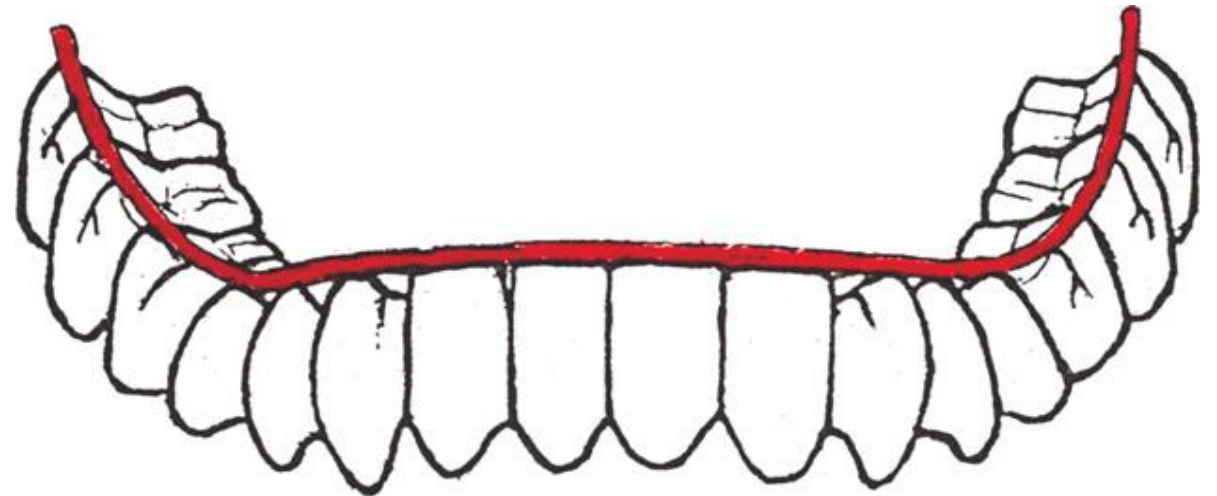
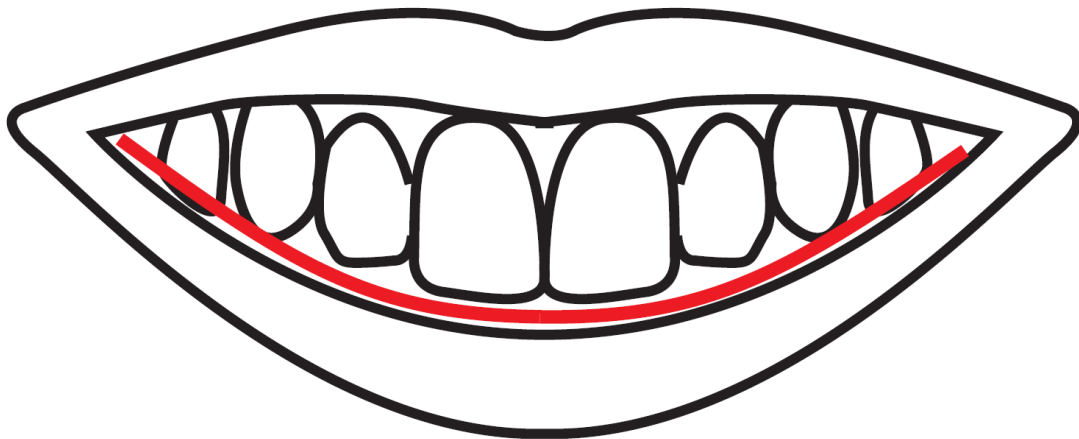
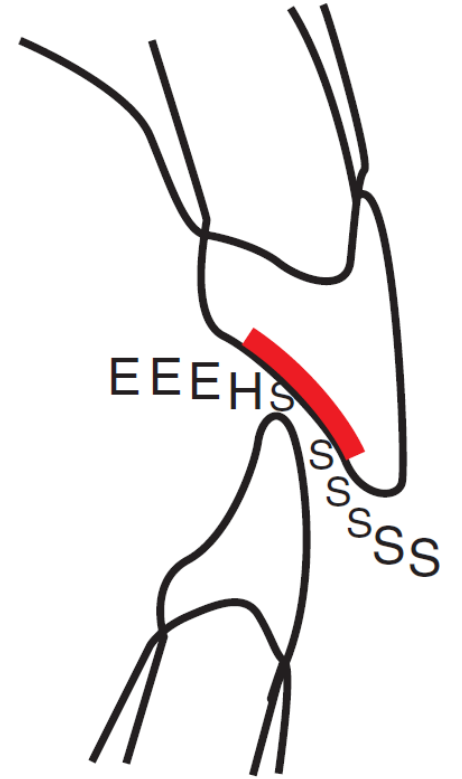
The plane of occlusion represents the average curvature of the occlusal surface. Each curvature of the plane is related to specific effects it should produce. Its acceptability should be analyzed on that functional basis rather than on its conformity to a set ideal.

OCCLUSAL PLANE



Anterior Teeth Curvature Determination

The curvatures of the anterior teeth are determined by the establishment of an esthetically correct **Smile line** on the upper and the relationship of the lower incisal edges to the anterior guidance and the requirements for phonetics.



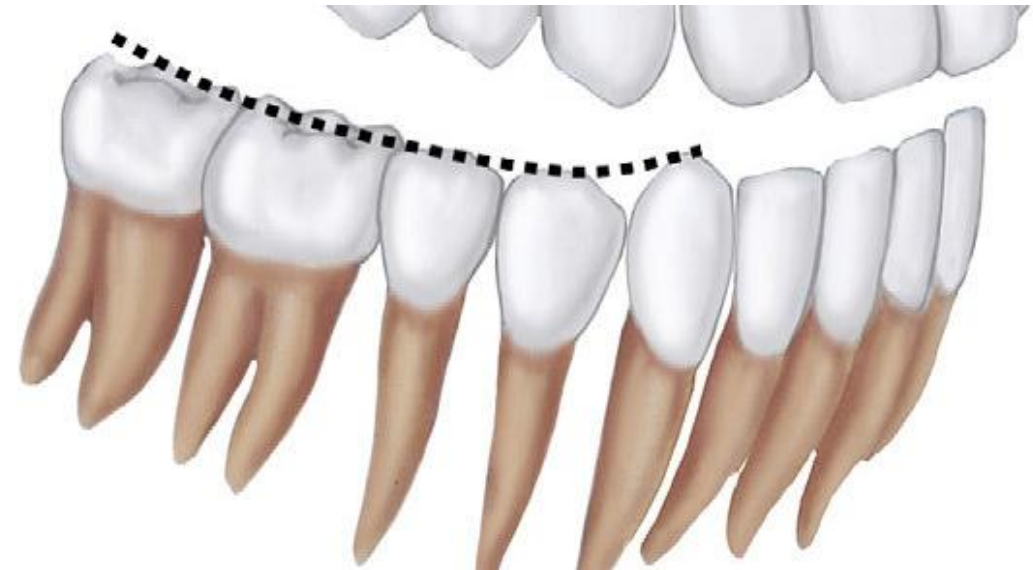Posterior Teeth Curvature Determination

The curvatures of the posterior plane of occlusion are divided into:

- (1) Anteroposterior curve called the **curve of Spee**.
- (2) Mediolateral curve, referred to as the **curve of Wilson**.

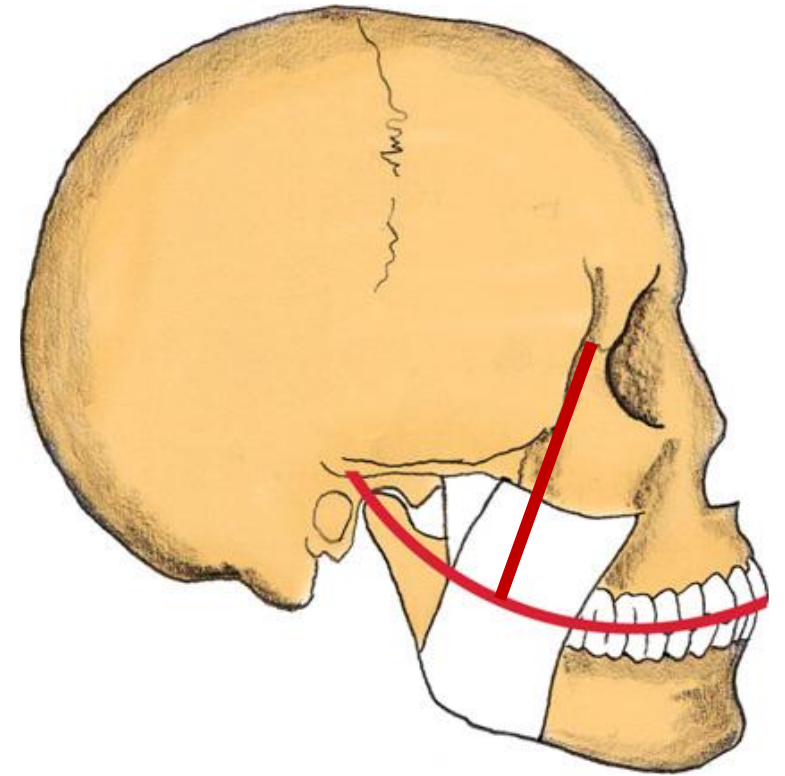
Curve of Spee

is the anteroposterior curve. It begins at the tip of the canine, and touches the cusp tips of all the posterior teeth.

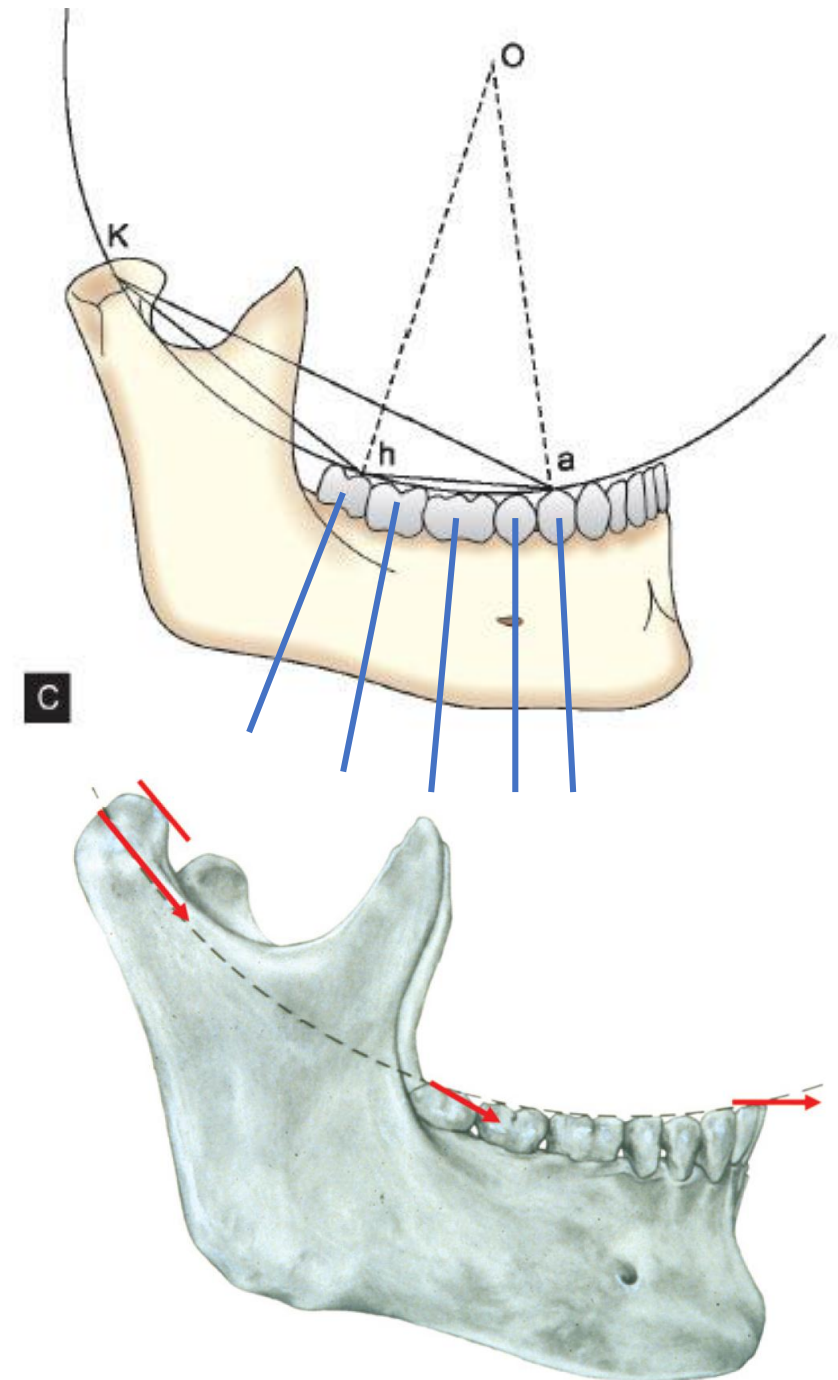


If the curved line continued further back, it would ideally follow an arc through the condyle. The curvature of the arc would relate, on average, to part of a circle with a 4-inch radius.

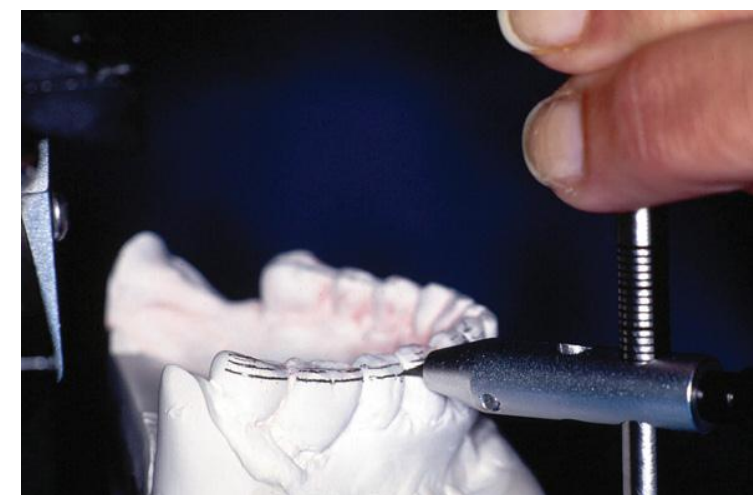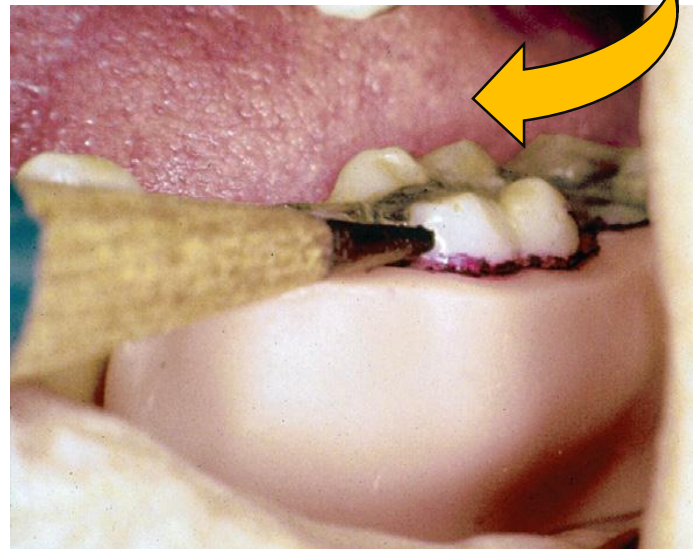
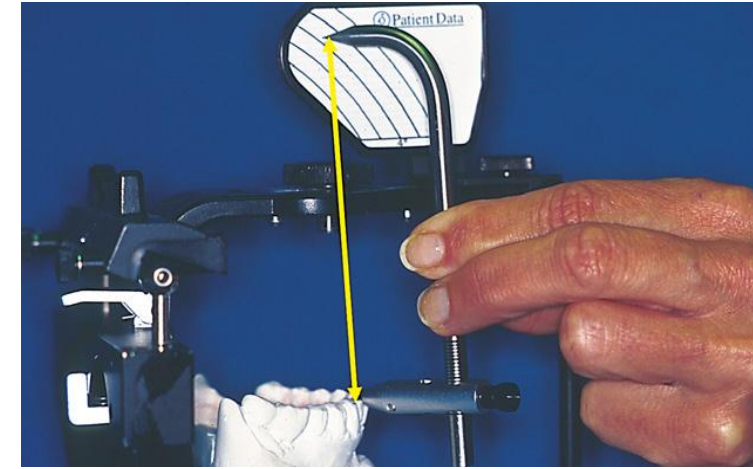

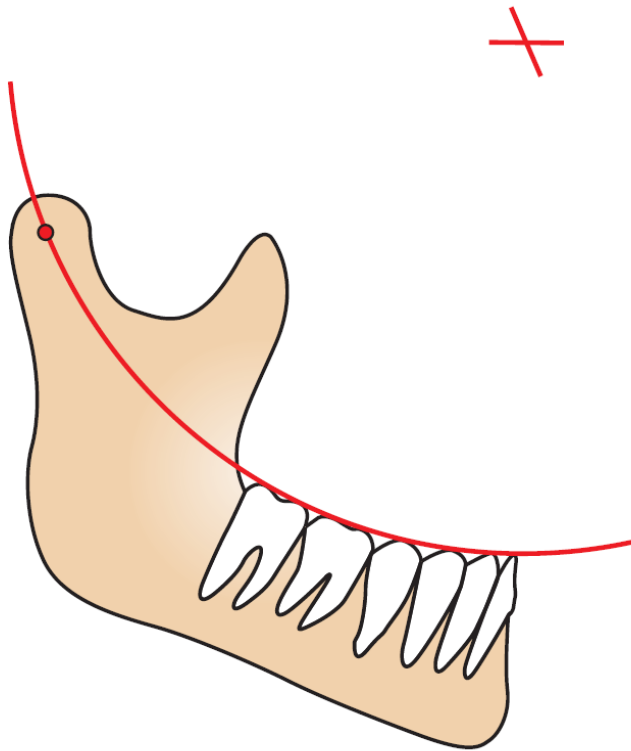
The anteroposterior curvature of the occlusal plane is designed to permit protrusive Disclusion of the posterior teeth by the combination of anterior guidance and condylar guidance. The separation of posterior teeth during excursive contact of the anterior teeth results in more efficient incisive function



- There is a purpose behind the curve of Spee design as well as its location in relation to the condyle.
- The curve results from variations in axial alignment of the lower teeth. To align each tooth for maximum resistance to functional loading, the long axis of each lower tooth is aligned nearly parallel to its individual arc of closure around the condylar axis.
- This requires the last molar to be tilted forward at the greatest angle and the forward tooth to be at the least angle.



PROCEDURE: Using a simplified occlusal plane analyzer (SOPA)

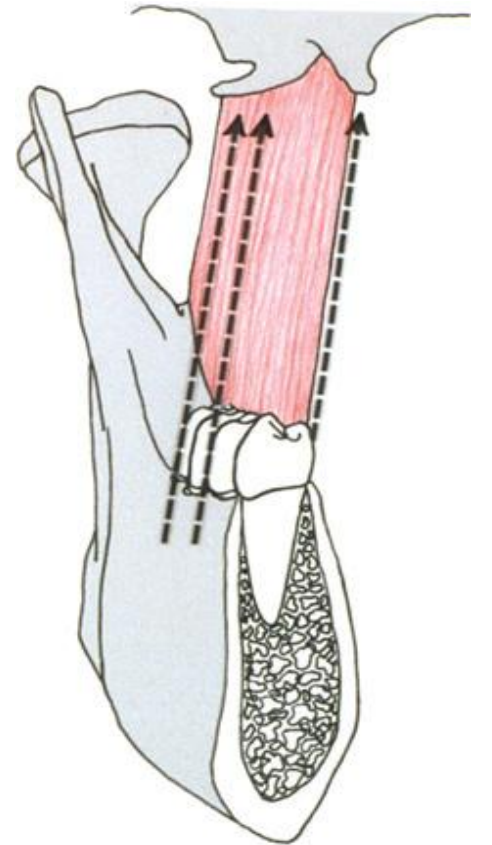
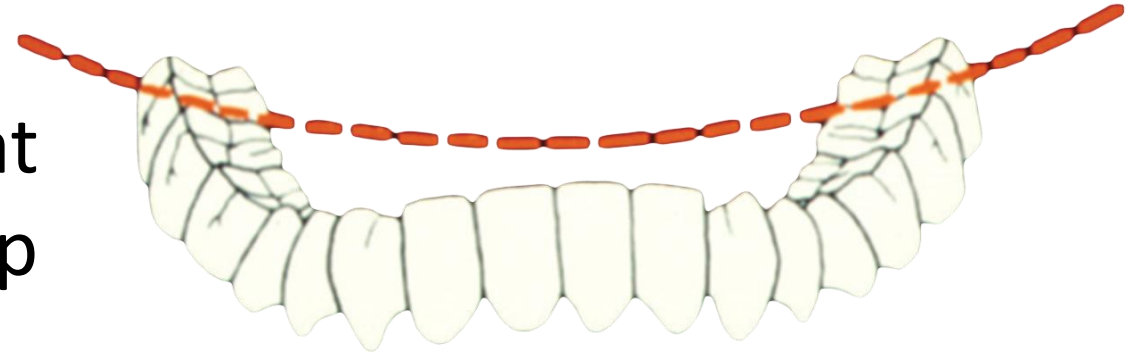


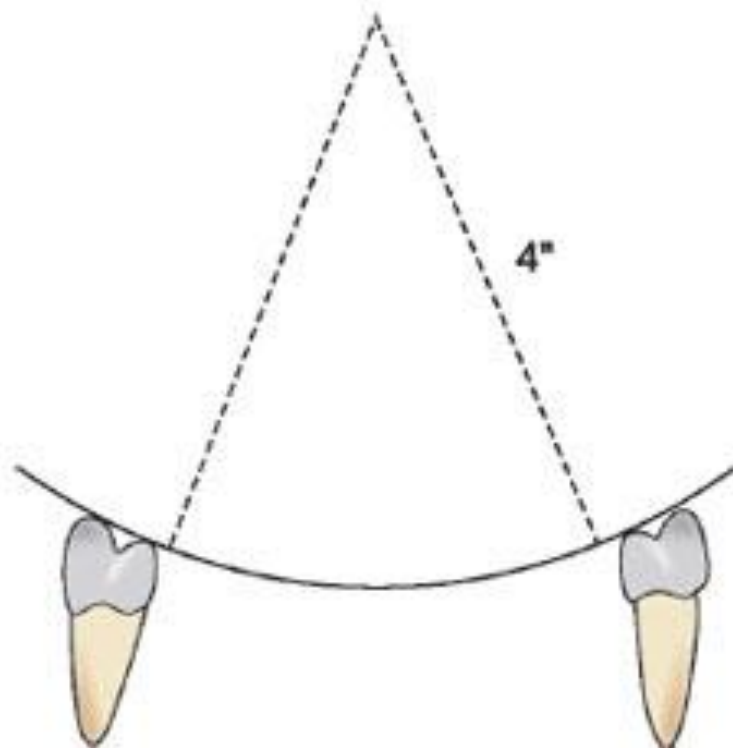
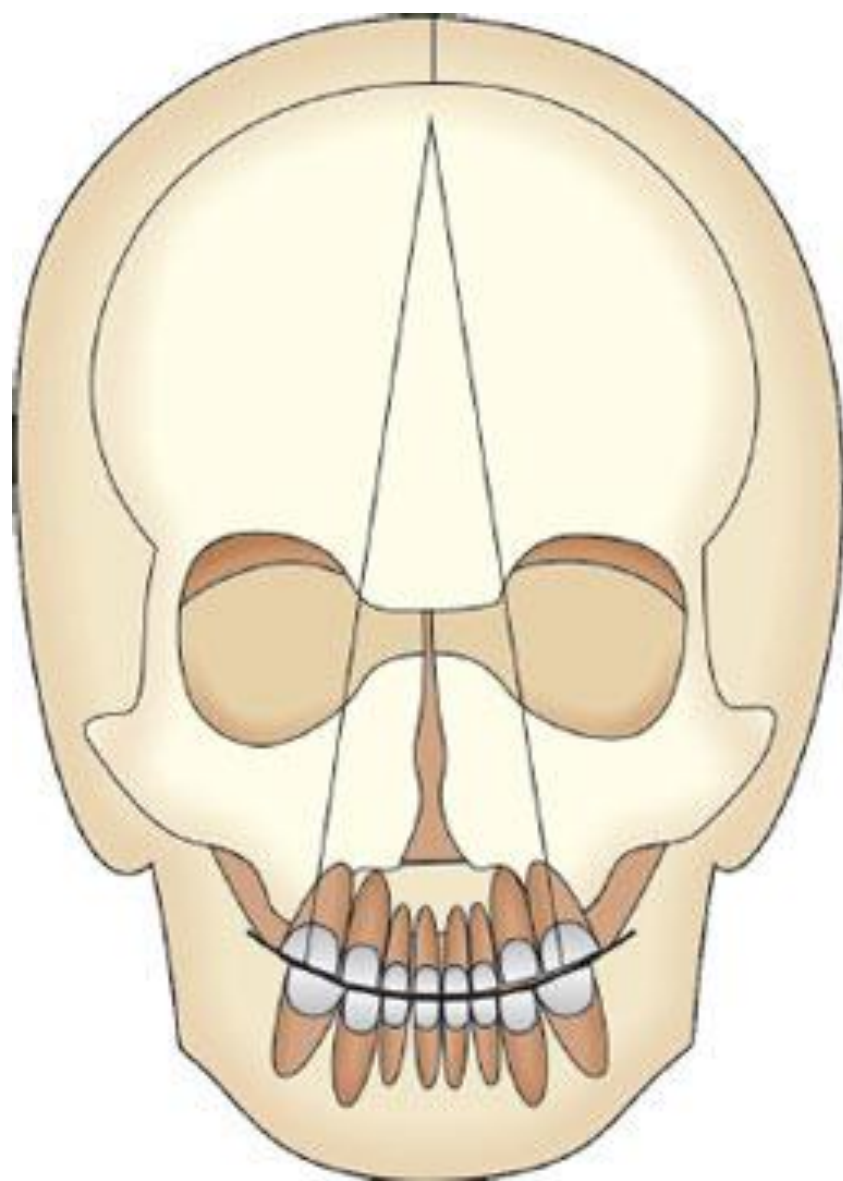
Curve of Wilson

is the mediolateral curve that contacts the buccal and lingual cusp tips on each side of the arch.

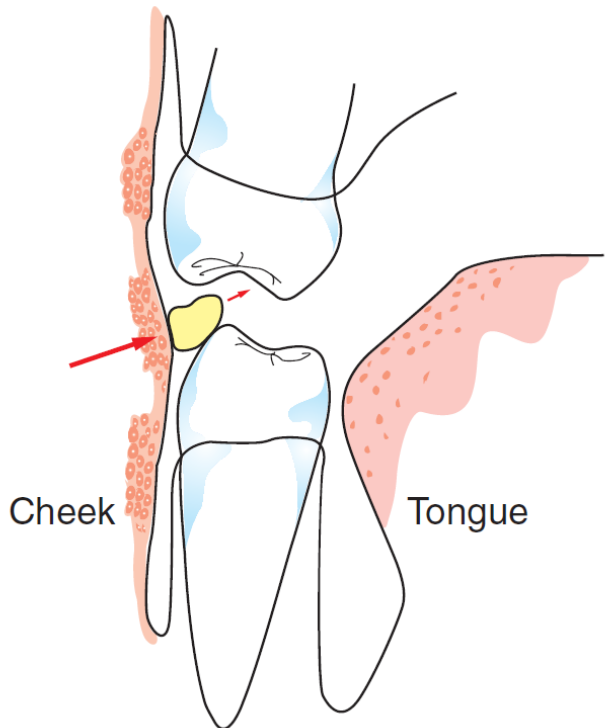
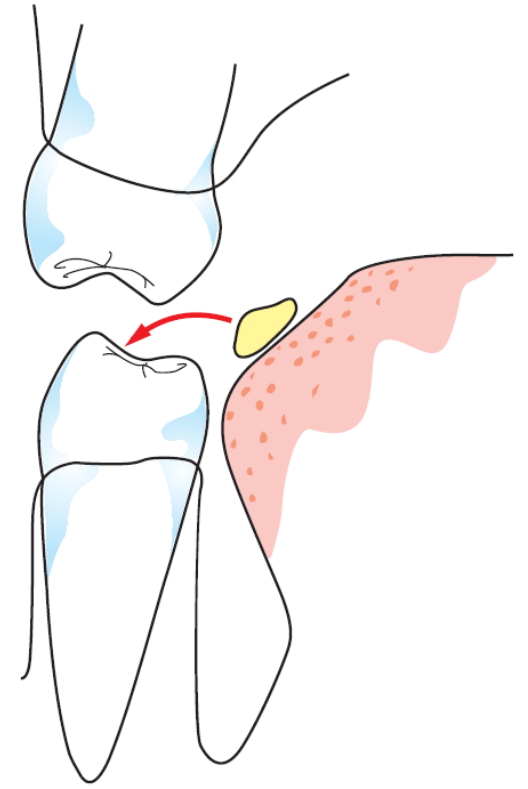
It results from inward inclination of the lower posterior teeth, making the lingual cusps lower than the buccal cusps on the mandibular arch

There are two reasons for this inclination of posterior teeth. One has to do with resistance to loading, and the second has to do with masticatory function.

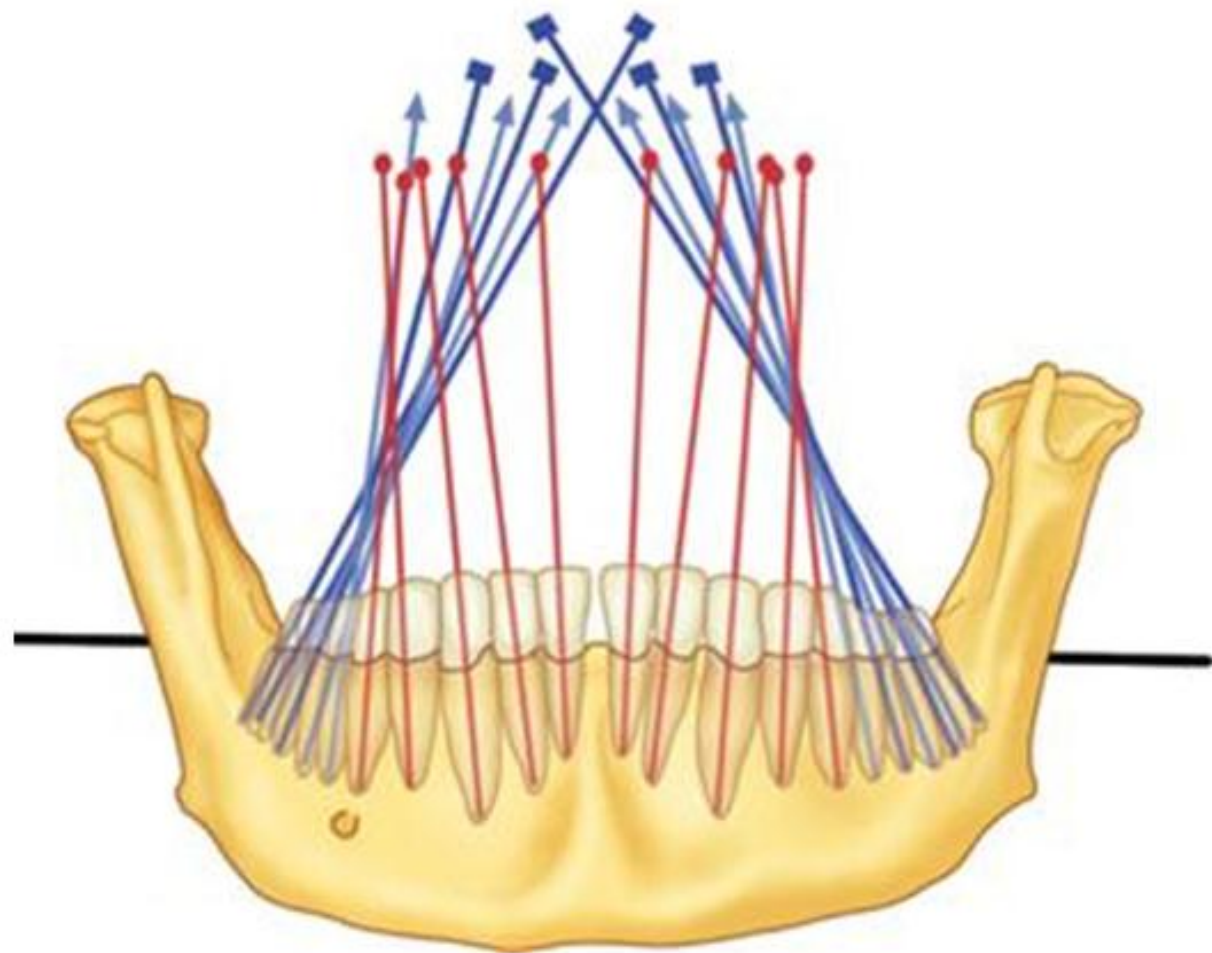
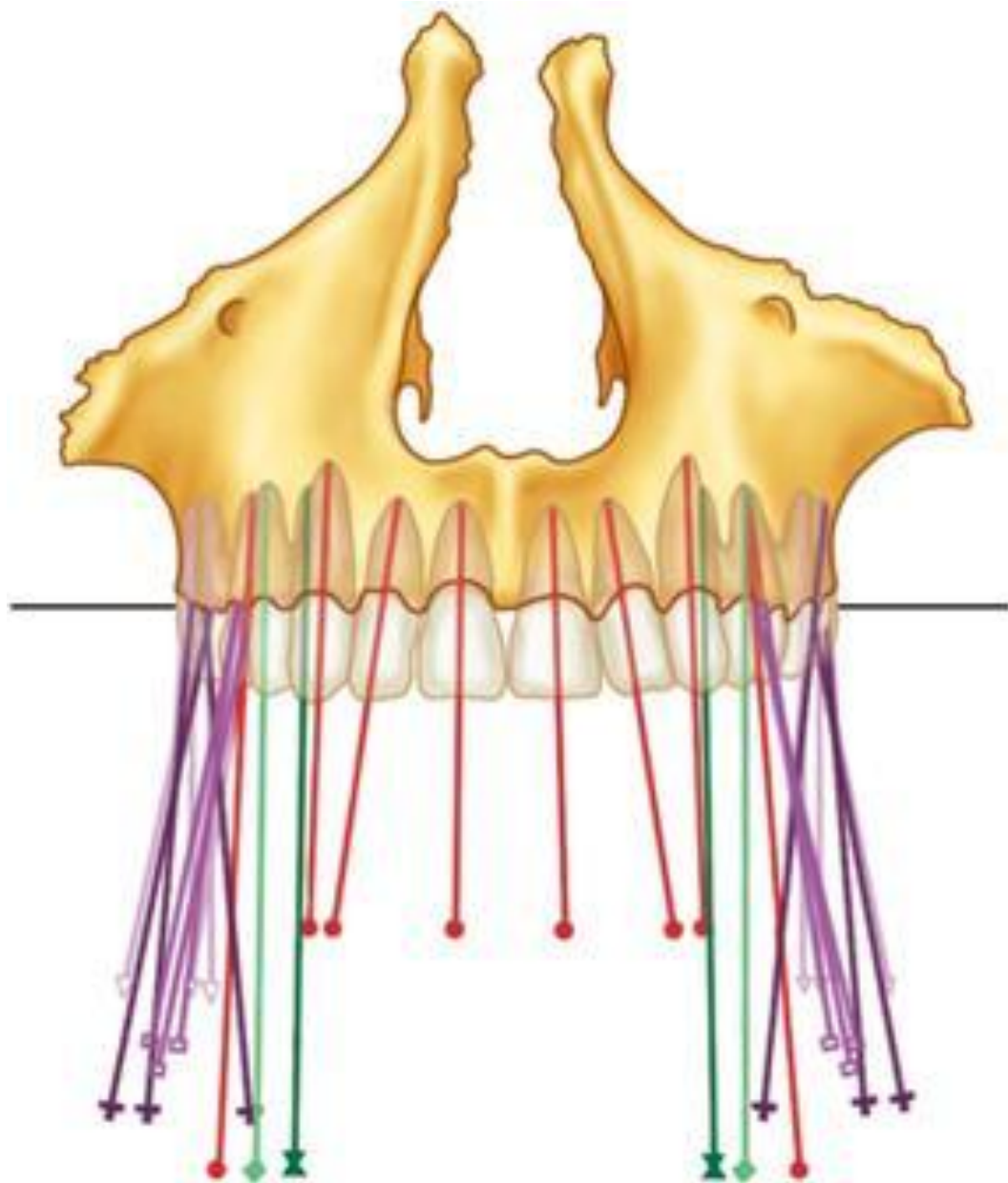




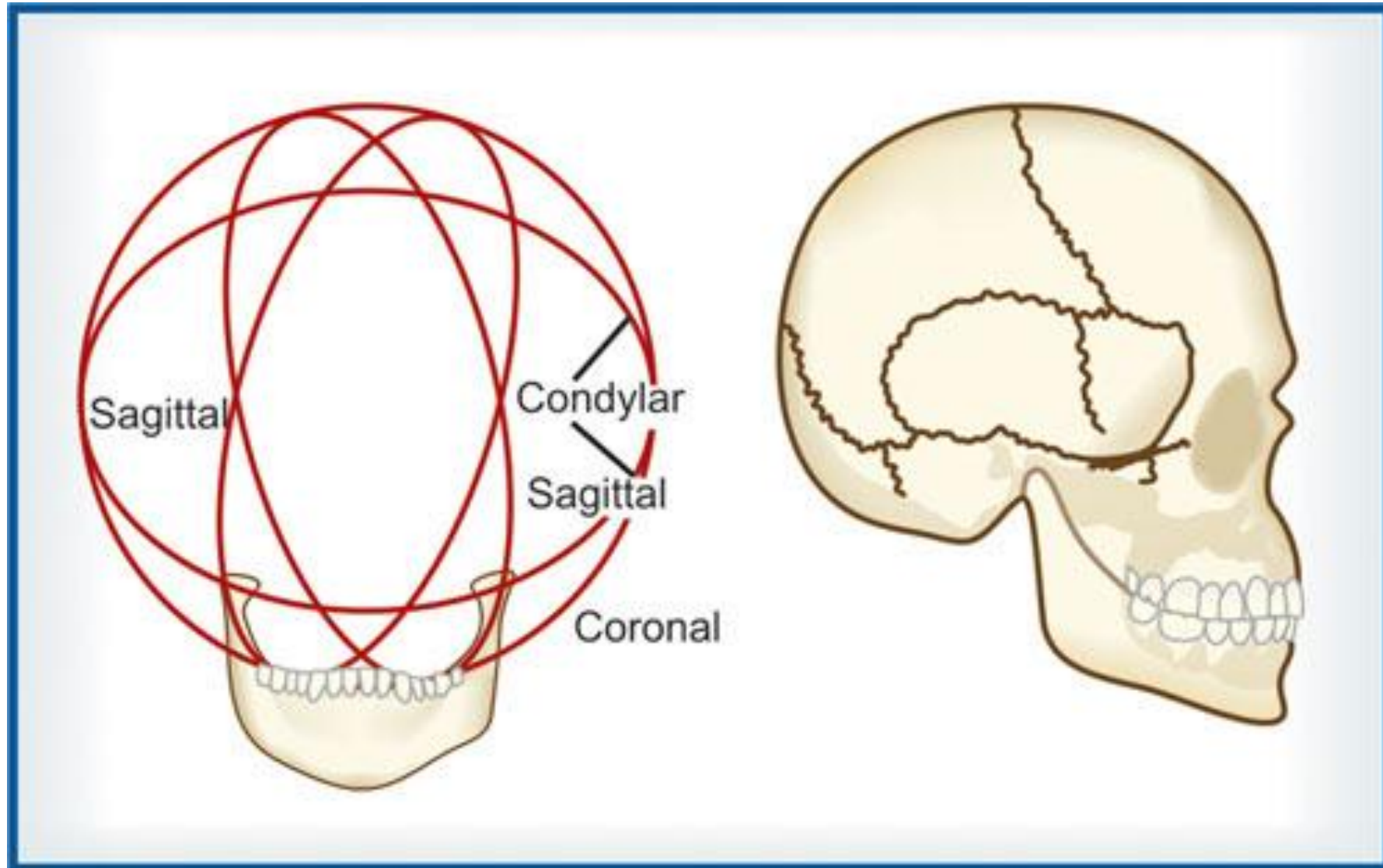
The lingual inclination of the lower posterior teeth positions the lingual cusps lower than the buccal cusps. This design permits easy access to the occlusal table. As the tongue lays the food on the occlusal surfaces, it is stopped from going past the chewing position by the taller buccal cusps.

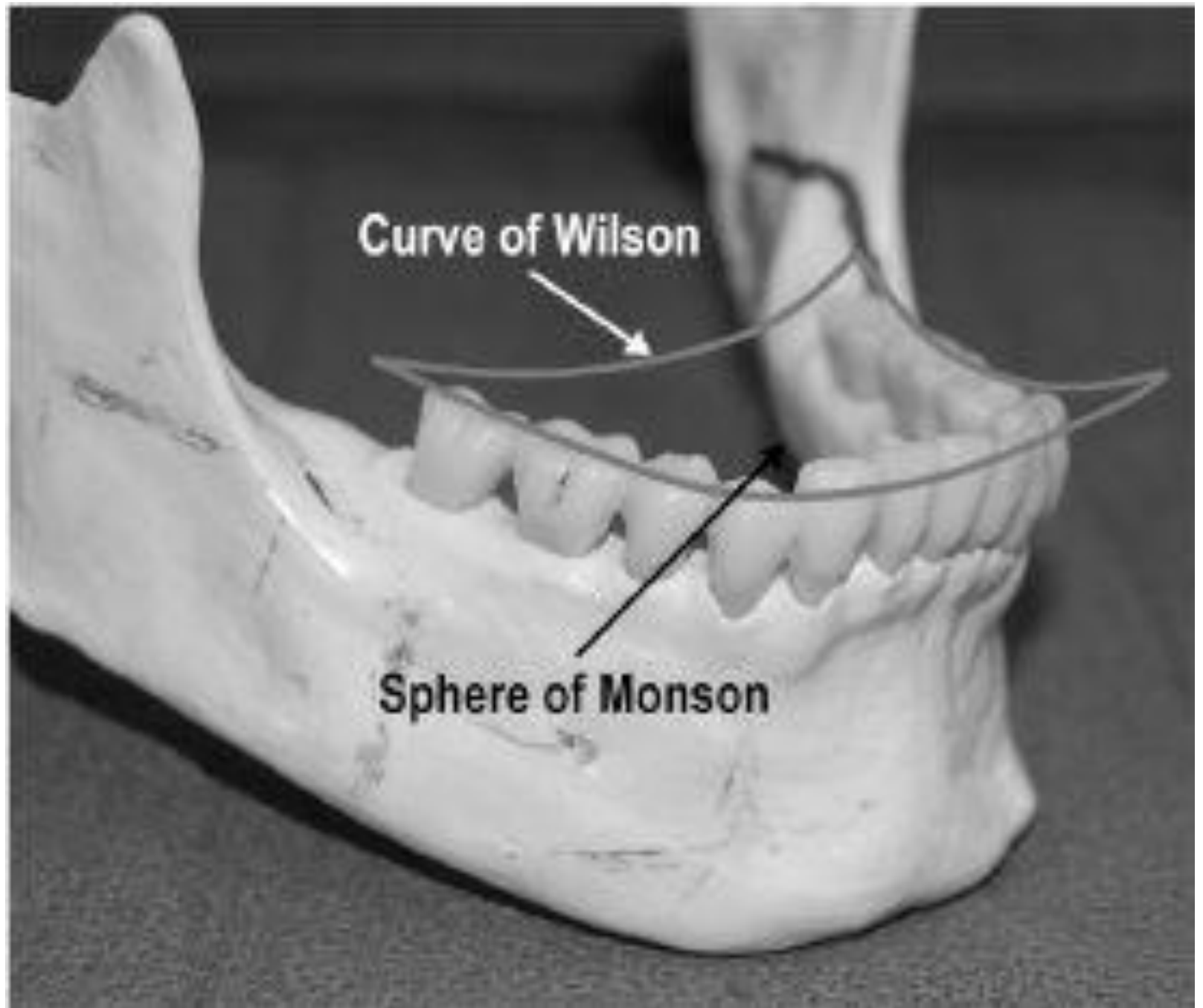
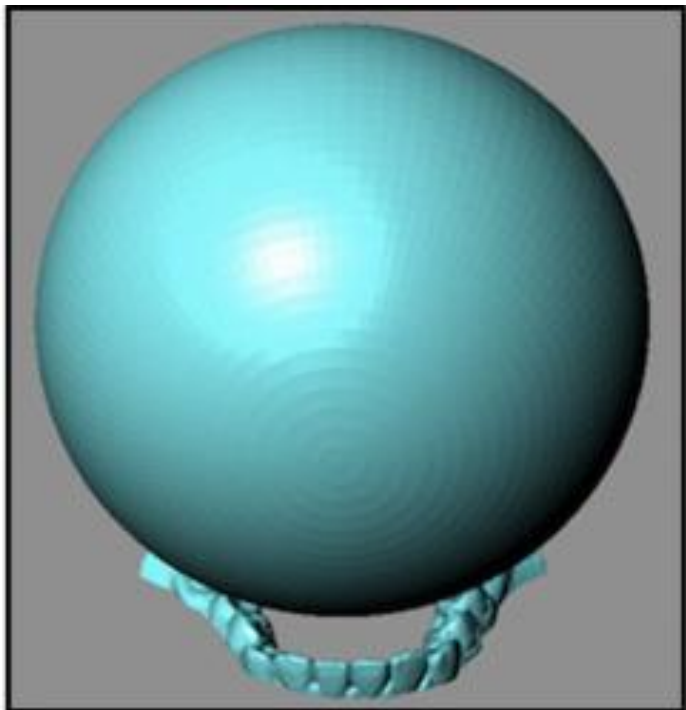



The outer inclination of the upper teeth positions the buccal cusps higher for easier access from the buccal corridor. The buccinator muscle squeezes the bolus onto the occlusal table where it is stopped by the longer lingual cusp.



Sphere of Monson





Five Requirements for Occlusal Stability:

- 1. Stable stops on all teeth when the condyles are in centric Relation.**
- 2. Anterior guidance in harmony with the border movement of the envelope of function**
- 3. Disclusion of all posterior teeth in protrusive movements.**
- 4. Disclusion of all posterior teeth on the nonworking (balancing) side.**
- 5. Non interference of all posterior teeth on the working side, with either the lateral anterior guidance, or the border movements of the condyle.**

2- Literature Review

2.1. Definition and Classification

2.1.1. Smile design refers to the many scientific and artistic principles that considered collectively can create a beautiful smile. These principles are established through data collected from patients, diagnostic models, dental research, scientific measurements, and basic artistic concepts of beauty.

2.1.2. Smile classification:

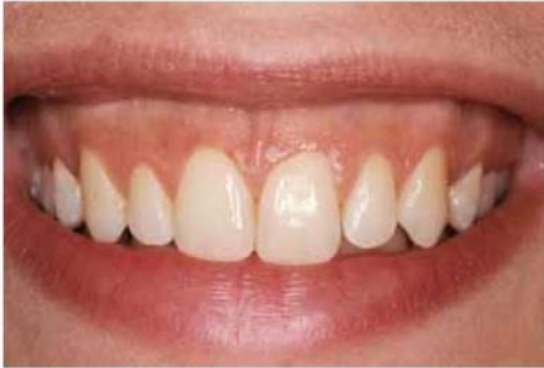According to the level of periodontium and teeth exposed:

Class I. Very high lip line: more than 2 mm of marginal gingiva visible or more than 2 mm apical to the cemento-enamel junction visible for the reduced but healthy periodontium. This could be the 'gummy smile' (Fig. 3.a).

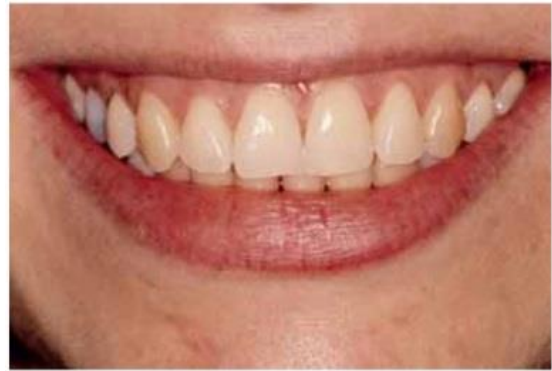Class II. High lip line: between 0 and 2 mm of marginal gingiva visible or between 0 and 2 mm apical to the cemento-enamel junction visible for the reduced but healthy periodontium (Fig 3.b).

Class III. Average lip line: gingival embrasures only visible (Fig. 3.c).

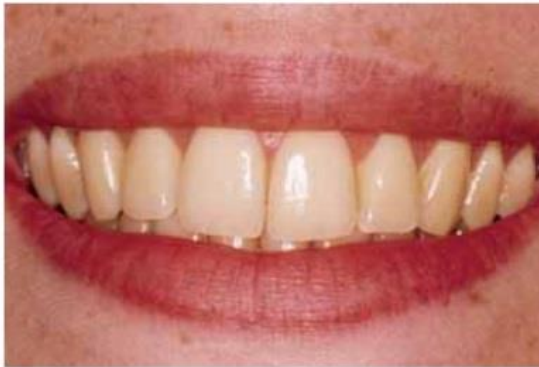Class IV. Low lip line: gingival embrasures and cemento-enamel junctions not visible (Fig. 3.d).



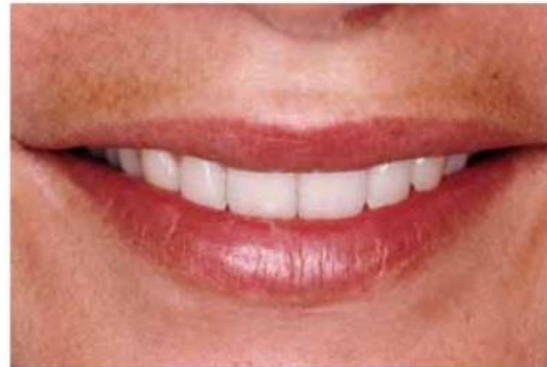(Fig. 3.a. Class I)



(Fig. 3.b. Class II)



(Fig. 3.c. Class III)



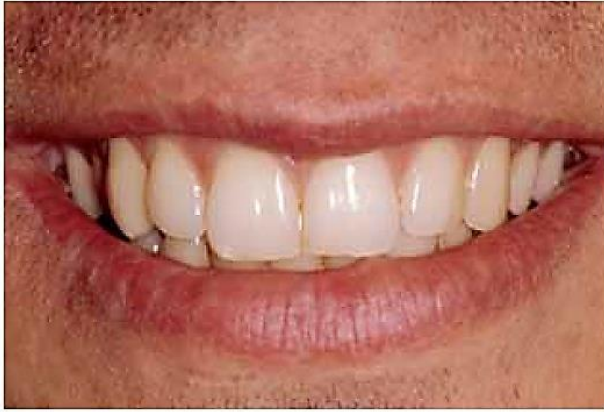(Fig. 3.b. Class IV)

Stages of a Smile: There are four stages in a smile cycle:

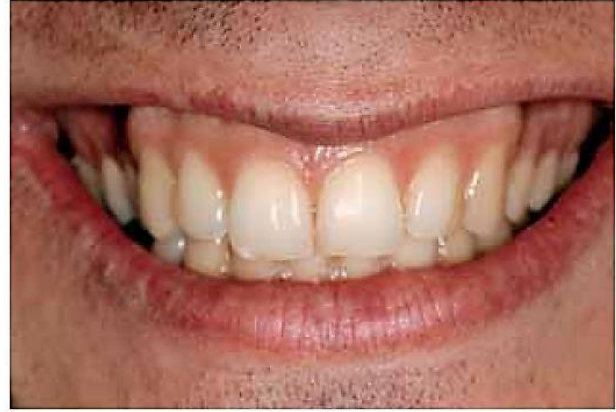- Stage I lips closed
- Stage II resting display
- Stage III natural smile (three-quarters)
- Stage IV expanded smile (Forced smile or full)

The practitioner needs to consider both the natural smile (Fig. 4.a) and the forced smile (Fig. 4.b) when evaluating the position of the smile line. When the practitioner asks a patient to smile, the patient

usually takes a cautious attitude and reveals a more or less natural smile.



(Fig. 4.a. Natural smile)

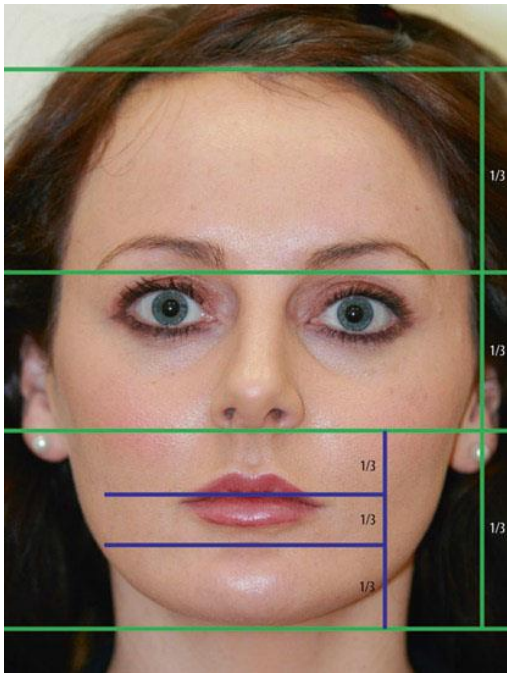


(Fig. 4.b. Forced smile)


The principles of smile design require an integration of esthetic concepts that harmonize facial esthetics with the dental facial composition and the dental composition. The dental facial composition includes the lips and the smile as they relate to the face.

2.3. Components of smile Design:

2.3.1. Facial features: in smile design include facial height, facial shape, facial width, facial profile, gender, and age. In classical terms, the face height is divided into three equal thirds: from forehead to brow line, from brow line to the base of the nose, and from the base of the nose to the base of the chin. The width of the face is typically the width of five “eyes” (Fig 6.a&b)



(Fig. 6.a Horizontal facial thirds)



(Fig. 6.b Vertical facial fifths)

As viewed from the frontal position, the four basic facial shapes recognized square, oval, tapered and ovoid (Fig. 7. a.b.c.d)



a. square face



b. oval face



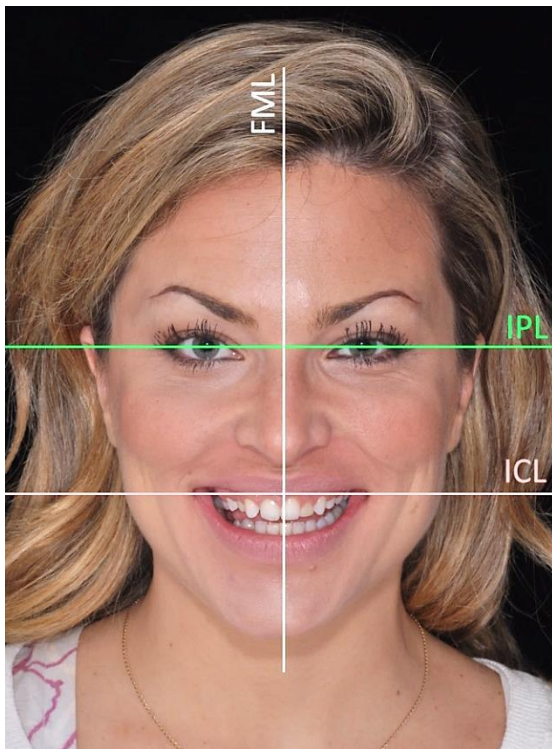
c. tapered face



d. ovoid face

(Fig.7 facial shapes from frontal view)

Facial features that have a particularly important impact on the dental– facial composition are those that relate the interpupillary plane with the commissure line and the occlusal plane. The interpupillary line should be parallel with the horizon line and perpendicular to the midline of the face. In addition, the interpupillary line should be parallel with the commissure line and occlusal plane. (Fig. 8)



(Fig. 8. The first green horizontal line from the top is the interpupillary line. It passes through the center of the pupil of each eye.

The horizontal line below this is called the commissural line, which passes through the corners where the upper and lower lips meet.

These lines should normally be parallel to the incisal and occlusal planes of the patient's teeth.

A vertical white line is drawn through the glabella (centered between the eyebrows), the tip of the nose, through the center of the philtrum, the center of Cupid's bow, and finally to the center of the chin. The resultant vertical line is the facial midline and is identified and analyzed as normal or curved.

2.3.2. Dental facial composition:

A- Lip analysis: The position of the lips in the rest position should be evaluated for lip contact as well as for the range of lip mobility when smiling. When smiling, the inferior border of the upper lip as it relates to the teeth and gingival tissues is called the lip line. In most cases, the lip line is acceptable if it is within a range of 2 mm apical to the height of the gingiva on the maxillary centrals.

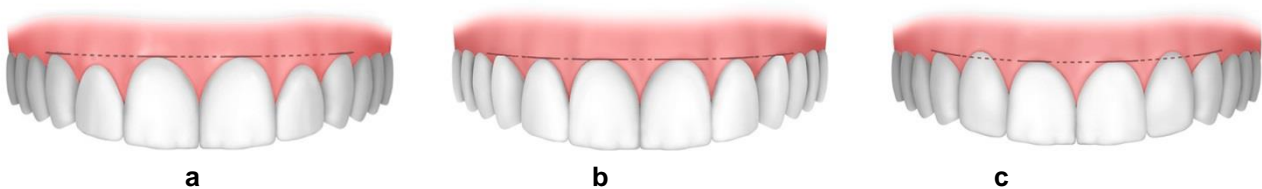
With age, the amount of incisal display of the maxillary centrals diminishes and the amount of incisal display of the mandibular centrals increases. Therefore, the amount of incisal display is an important factor in a youthful smile.

B-Gingival role:

Vertical and Horizontal gingival zenith position:

The marginal gingival tissues of the maxillary anterior teeth should be located along a horizontal line extending from cuspid to cuspid. Ideally, the laterals reach 1 mm shorter than that line. (Fig. 11.a)

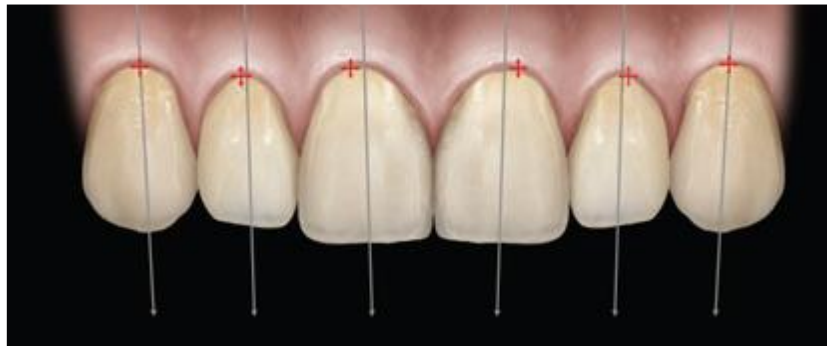It is also acceptable, although not ideal, to have the gingival height of all six anteriors equal in gingival height on the same plane (Fig. 11.b). However, the smile may appear too uniform to be esthetically pleasing. A gingival height of the laterals that is more apical to the centrals and cuspids is considered unattractive. (Fig. 11.c)



(Fig. 11. A.b.c. Marginal gingival tissues of the maxillary anterior teeth in relation with the horizontal line extending from cuspid to cuspid.)

(Courtesy of American Academy of Cosmetic Dentistry, Madison, WI; with permission.)

The mean distal distances of the gingival zenith position (GZP) to the vertical bisected midline (VBM) of the clinical crown of central incisors, lateral incisors, and canines were 1.1, 0.4, and 0 mm, respectively. (Fig. 12)



(Figure 12. The mean distance of the gingival zenith position of the central incisor teeth was about 1 mm distal to the vertical bisected midline of the clinical crown. Clinically, the gingival zenith position of the lateral incisor and canine teeth are coincident with the vertical bisected midline along the axial inclination of the teeth.) (Chu et al., 2009)

C- Teeth position, size, shape, form and color:

Position: regarding the facial and lip analysis in addition to gum role consideration we will create an outline for the teeth positions and size.

- **-Inferior border:**

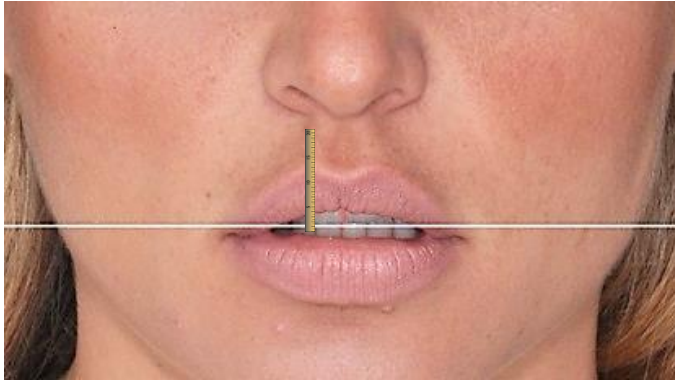
We must begin with the position of the maxillary central incisors relative to the upper lip. This assessment is made with the patient's upper lip at rest. (Fig. 13.a)

Level of the incisal line: The average amount of maxillary incisor exposure at rest position in men is 1.91 mm. In women almost twice as much maxillary tooth exposure is noted, 3.40 mm. Nothing of particular significance was found in the variability of races. Gradual decrease in exposure of the maxillary central incisor with age.

There is a significant predominance of parallelism between the incisal plan and the interpupillary line ($p=0$). (Fig. 13.b)

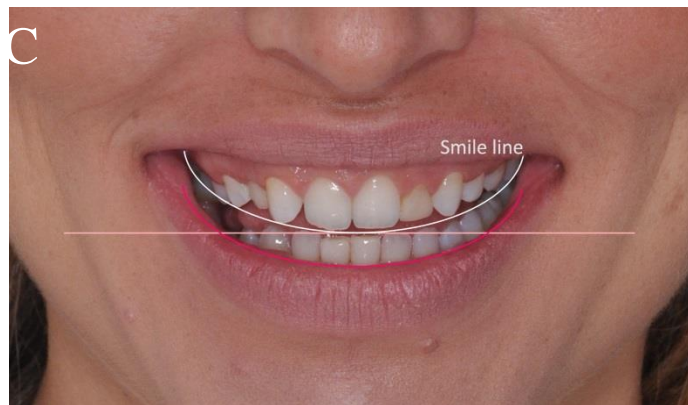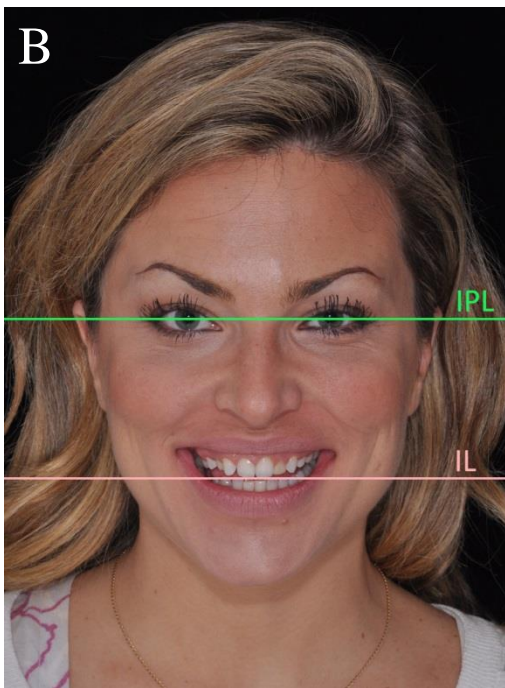
Both orthodontists and general dentists could detect a 1-mm incisal plane asymmetry. Lay people were less able to detect an incisal plane asymmetry.

Smile line is one of the most important features of a pleasing smile. The smile line can be defined as an imaginary line drawn along the incisal edges of the maxillary anterior teeth. In an ideal tooth arrangement, that line should coincide or follow the curvature of the lower lip while smiling. (Fig. 13.c)



(Fig. 13.a. The measurement of the amount of exposure of the maxillary central incisors at rest.)

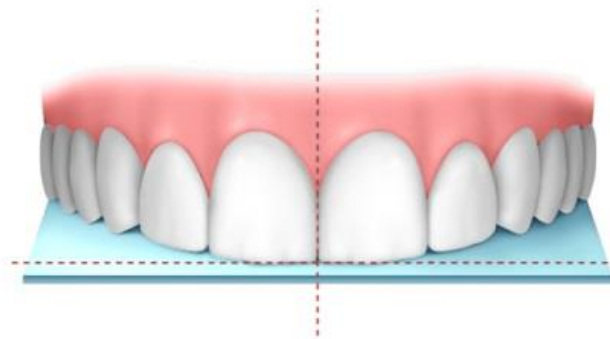
The centrals are most likely too long if they interfere or impinge on the lower lip causing dimpling or entrapment during the formation of the “F” and “V” sounds. The length of the incisors can also be evaluated using the occlusion.



(Fig. 13.b. The parallelism between the incisal plan and the interpupillary line. c. The smile line drawn along the incisal edges of the maxillary anterior teeth. In an ideal tooth arrangement, that line should coincide or follow the curvature of the lower lip while smiling.)

- **-Dental midline:** the reference to a vertical line drawn through the tip of the incisal embrasure between the two maxillary central incisors and parallel to the vertical lines of the esthetic frame of the face.

The midline should be perpendicular to the incisal plane. it considered as a key element in smile design. The midline as it unites the face and its features with dentition and the anterior teeth in particular. (Fig. 14)

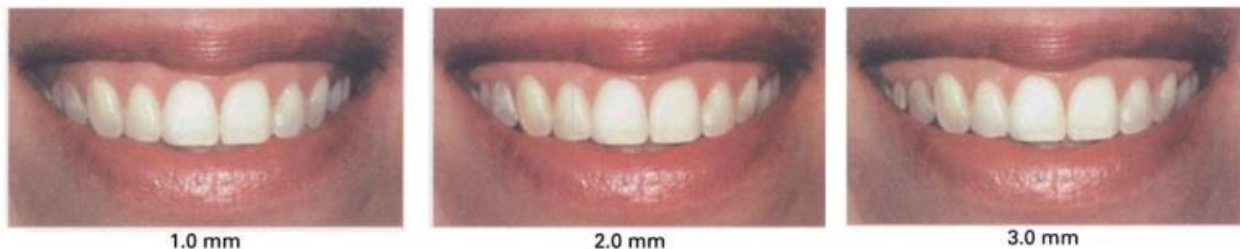

(Fig. 14. The midline should be perpendicular to the incisal plane.)

Dental midline and facial midline relation:

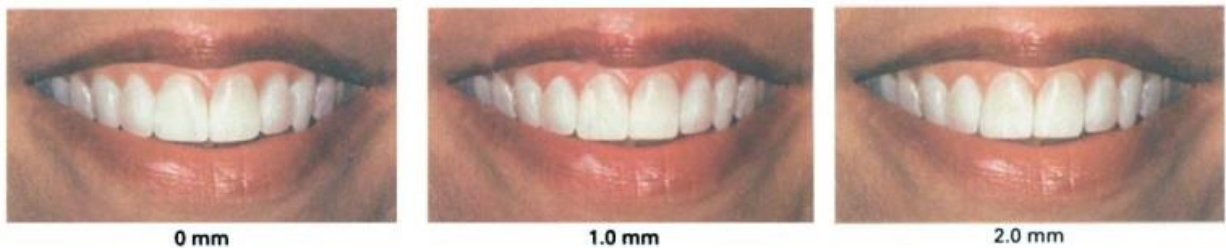- **Parallelism:** Varying thresholds of acceptability of midline deviation exist among individuals; the same 2-mm or 3-mm deviation may be considered acceptable in one person and unacceptable in another, depending on other facial characteristics.

The maxillary dental midline had to be shifted as much as 4 mm- to one side before it became consistently noticeable. There is no a significant difference in esthetics even with a 4-mm deviation. (Fig.15)



(Figure 15. The entire maxillary dental segment was shifted in 1 .0-mm increments to the patient's left in test photographs to assess esthetics of midline position.)

- **Canting:** A canted midline, however, is a more perceptible deviation from the normal and should be avoided. (Fig. 16)

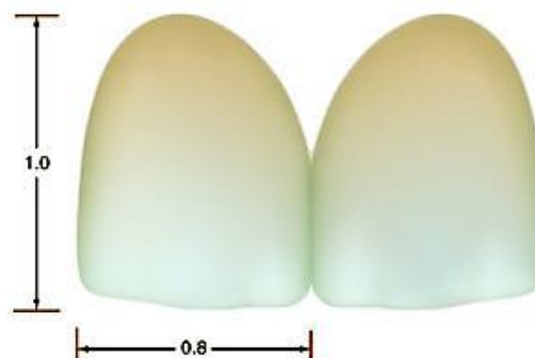


(Figure 16. Incisor crown angulation of maxillary canine and incisor crowns was angled to the patient's right in 1.0mm increments in test photographs to assess esthetics of crown angulation.) (Kokich et al., 1999)

- **-Central incisor dimensions:** The central incisor is the logical choice.

In any smile the central incisors dominate because its central location and it's the bigger size.

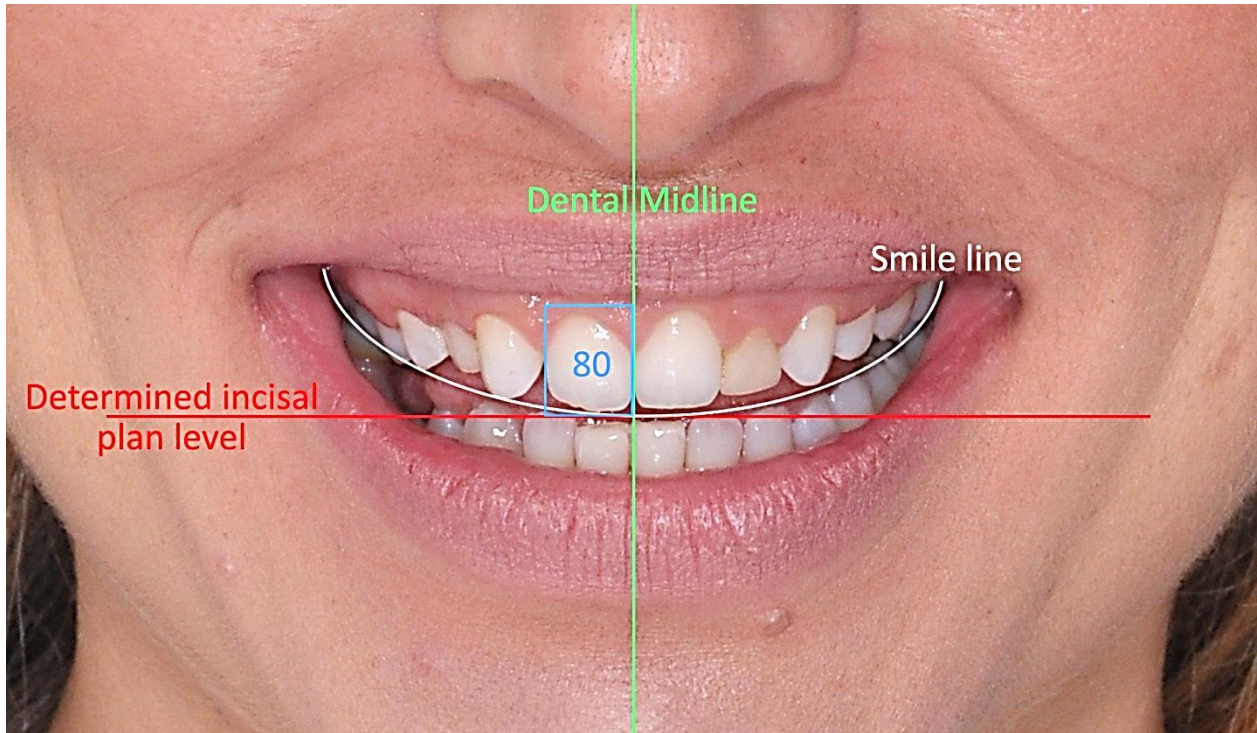
Central incisor length is approximately one sixteenth of the facial height. The ratio of width to height is 4:5 or 0.8:1. In general, the accepted range for the width of the central is 75% to 80% of the height. For esthetic purposes, the height of the central incisors can vary depending upon the incisal display and the influence of the smile line. (Fig. 21)



(Figure 21. Proportion of centrals.) (Davis. 2007)

Measuring the width / length proportion of the central incisors is the first step toward understanding how to best redesign the smile. A rectangle is then placed over the edges of both central incisors (Fig 22). The proportions of the patient's central incisors can be compared to the ideal proportions described in the literature.

(Coachman & Calamita, 2012)



(Fig. 22. A rectangle with ideal length/width proportion (80%) is placed over the central incisor to compare the actual pretreatment proportion with the ideal one.) (Coachman & Calamita. 2012)

- *-Lateral borders for each tooth position*

The relative proportions of the maxillary six anterior teeth to each other:

The Golden Proportion: an ideal mathematical proportion of 1:1.618. Where applied to dentistry, this relates the apparent widths of the maxillary six anterior teeth from a frontal view. This concept was first mentioned by Lombardi and later developed by Levin.

(Davis, 2007)

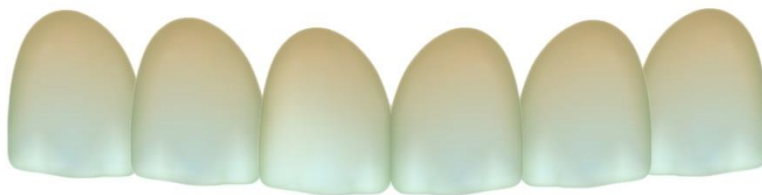Unity: is the prime requisite of a good composition.

Dominance: is the prime requisite to provide unity.

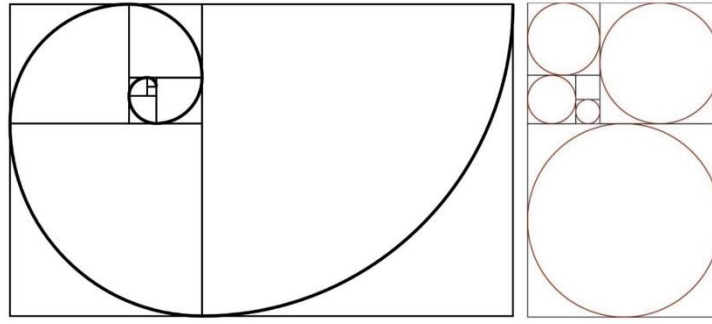
A grouping of similar visual weights in a composition produces incoherence (Fig. 23 a.) unless they are arranged in a definite pattern which then produces a static composition. This leaves only one possibility for the dentist to achieve dominance in the denture. One tooth must dominate the anterior tooth arrangement by virtue of its size. The central incisor is the logical choice (reality). The central incisor selected should be enough larger than the lateral incisor to dominate the composition and bring order and coherence to it. The cuspid size is not a factor because only its mesial aspect is seen.

The most satisfactory surface division, therefore, is one in which interest and unity are produced by dividing the plane into parts that, although contrasting in shape or size.

The repeated ratio: This is accomplished by the use of a continued proportion or repeated ratio. For example, the so-called "golden mean," 1.618, was known to the Greeks and appears in their architecture. It is the approximate constant factor in the summation series 1, 2, 3, 5, 8, 13, 21, 55, 89. It is best expressed as a mathematical proportion: $89/55$. The width of the golden mean rectangle is one side of a square; its length is one half the square plus the diagonal of half the square. This results in a rectangle in which the length/width ratio is 1.618/1. (Fig.23. b)

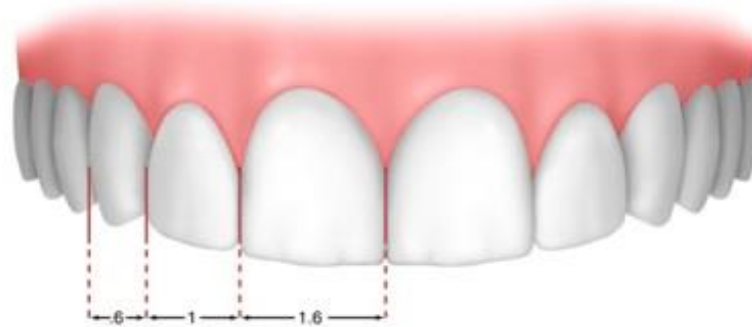


(Fig. 23.a. similar visual weights in a composition produces incoherence.)



(Fig. 23. b. The width of the golden mean rectangle is one side of a square; its length is one half the square plus the diagonal of half the square.)

The width of the central incisor is in the golden proportion to the width of the lateral incisor. The width of the lateral incisor to the width of the canine is also in the golden proportion (Fig. 24) as is the width of the canine to the first premolar. The widths of the incisors are in the golden proportion to each other as seen from the front. (Levin, 1978)



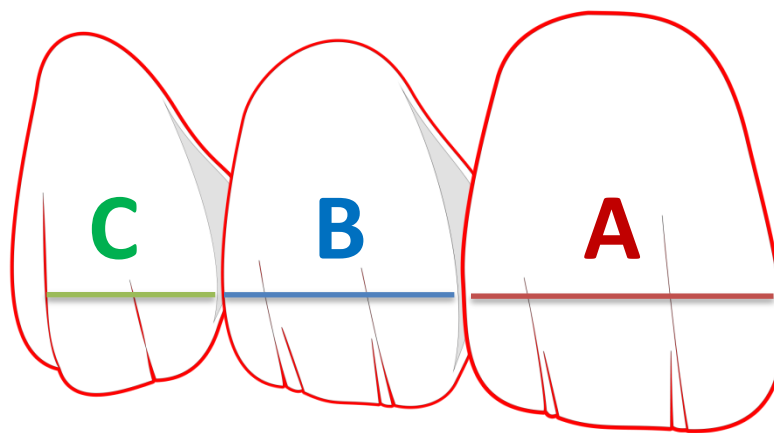
(Fig. 24. The widths of the anterior teeth are in the golden proportion.)

Recurring Esthetic Dental (RED) proportion:

The golden proportion as defined by Levin' is limited to use of the 62% proportion. (The 62% proportion comes from the golden proportion of 0.618). The author believes that when the golden proportion is used, the lateral incisor appears too narrow, and the resulting canine is not prevalent enough. (Preston, 1993) reported that the golden proportion was found in the relationship between the maxillary central and lateral incisors in only 17% of the casts of patients he studied

when viewed from the frontal. The concept of evaluating the frontal view is useful, however. The idea of a continuous proportion or repeated ratio as defined by (Lombardi.1973) opens up the idea of using a continuous proportion not necessarily limited to the 62% proportion. This idea implies, however, that the ratio of the widths established between the central and lateral incisors then must be used as one moves distally. If the elements of both concepts are combined, one derives what the author has defined as the recurring esthetic dental (RED) proportion. The RED proportion states that the proportion of the successive widths of the teeth as viewed from the frontal should remain constant as one moves distally (Fig. 25). Rather than being locked into using the 62% proportion, the dentist can use the proportion of his or her own choosing as long as the dentist is consistent while moving distally. Instead of having to accept the proportion already defined by the widths of the central and lateral incisors, the dentist can define his or her desired RED proportion. The use of the RED proportion gives greater flexibility.

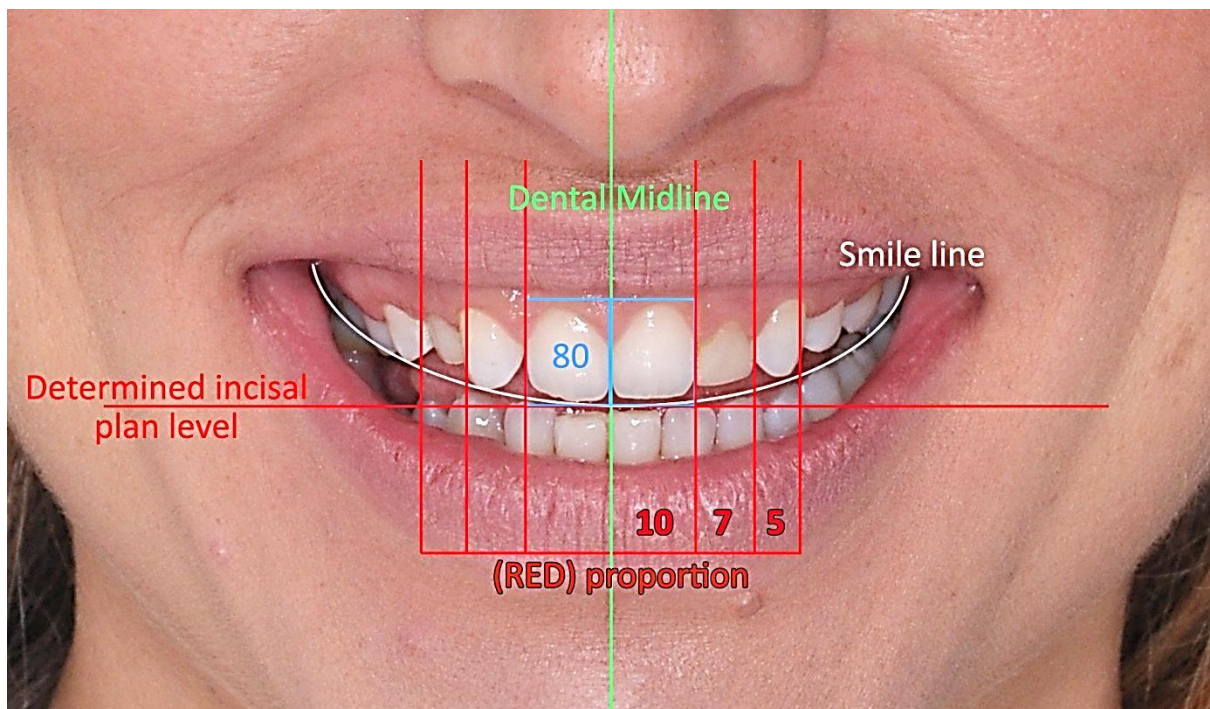
(Ward, 2001)



$$A/B = B/C = \text{Constant}$$

(Fig. 25. Recurring esthetic dental (RED) proportion. The RED proportion states that the proportion of the successive widths of the teeth as viewed from the frontal should remain constant as one moves distally.)

Although an approximate 70% RED proportion is preferred by the author, the RED proportion should be modified to fit the face, skeletal structure, and general body type of the patient. A person who is an ectomorph would be more likely to be able to use a smaller RED proportion, and an endomorph would use a larger RED proportion. (Fig. 27) **(Ward, 2001)**



(Fig. 27. Application of the red proportion to determine the lateral borders for each tooth position.)

- **-Gingival borders for each tooth position:**

Described in pages 9, 10 the level, symmetry and contour of the gingiva of the anterior teeth.

Papilla proportion (PP): Percentages of interdental papilla heights of maxillary anterior teeth from the gingival zenith, along with clinical crown lengths. Papilla proportions is approximately 40%, No significant differences were found between Mesial PP and Distal PP for maxillary incisors ($P \geq .5$). Canines demonstrated a trend toward increased distal papilla heights. (Fig. 28)

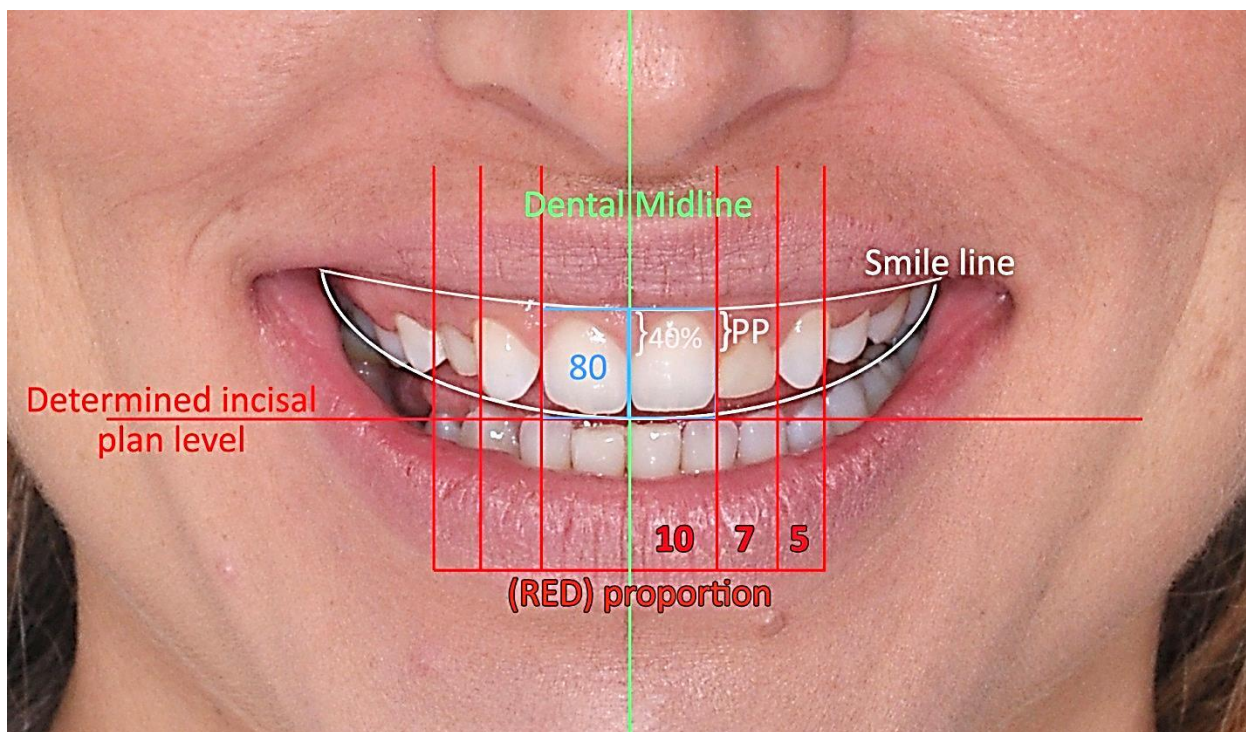
(Chu *et al.*, 2009)



(Fig. 28)

Tooth position and size is determined: From this step on, all drawings may be performed depending on what needs to be visualized or communicated for each specific case. For example, tooth outlines can be drawn over the photograph, or premade tooth outlines can be copied and pasted. The selection of tooth shape will depend on factors such as the morphopsychologic interview and the patient's desires, facial features, and esthetic expectations.

(Coachman & Calamita, 2012)

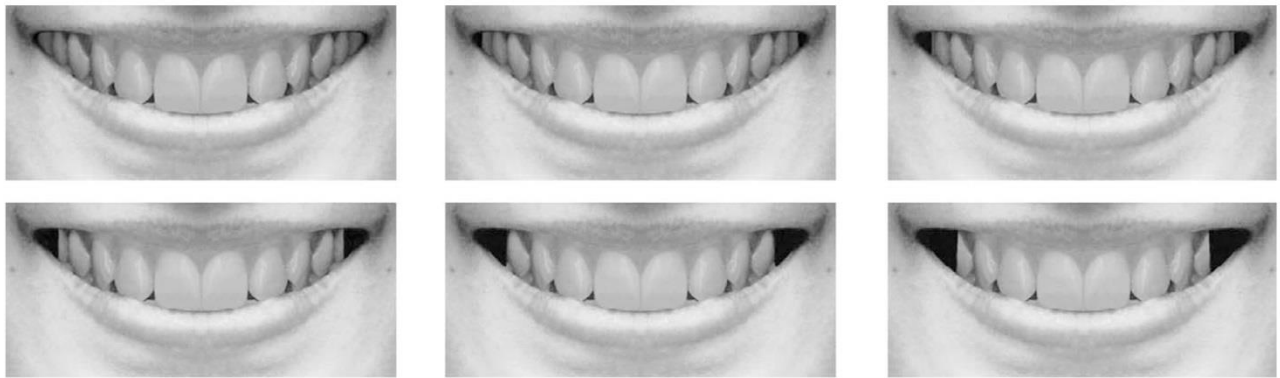

(Fig. 29. Outline borders for each tooth position and size is determined in addition to the gingival level.)

Once again, the lips together with the teeth form another esthetic area that should be considered in smile design. The area between the corners of the mouth during smile formation and the buccal surfaces of the maxillary teeth (particularly the bicuspids and molars) form a space known as the buccal corridor. A full and symmetric buccal corridor is an important element of an esthetic smile. Any

discrepancy between the value of the bicuspid and the six anterior teeth will increase this negative space is often accentuated when smile rejuvenation is limited to the maxillary six anterior teeth and the hue and value of newly restored teeth do not blend with the untreated teeth. The result is an unwanted exaggeration of the sense of depth, darkness, and the prominence of the buccal corridor.

In these posterior segments, the artistic perception of esthetics can be used to alter the typical inclinations to produce an enhanced esthetic affect through slightly upright the cuspids and the inclination of the posterior segment, the smile can be made to appear wider. These inclines should not exceed a perfectly vertical orientation. (Fig. 30) (Davis, 2007)



(Figure 30. Series of six images illustrating the range of buccal corridors created: extra broad (0% buccal corridor), broad (5% buccal corridor), medium-broad (10% buccal corridor), medium (15% buccal corridor), medium-narrow (20% buccal corridor), and narrow (25% buccal corridor).

(loi et al., 2009)

- ***-Teeth shape and form selection:***

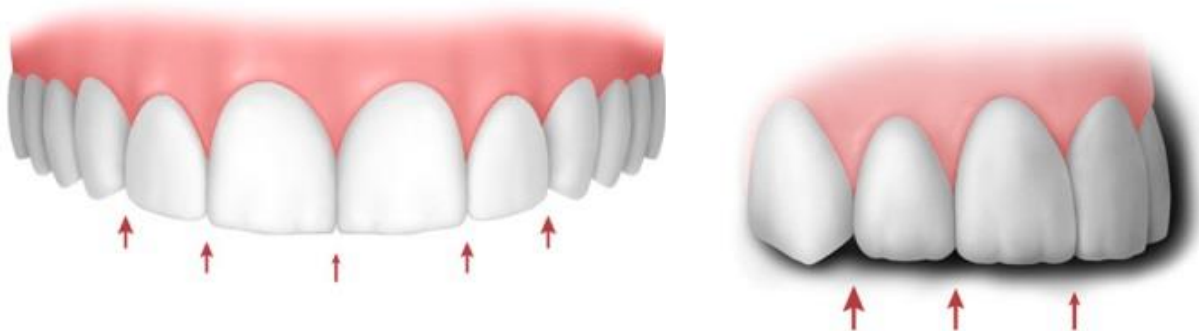
“Form” and “shape”: define objects situated in space. The basic difference, though, between “shape” and “form” is that “form” is in 3D while “shape” is plain 2D. The latter is simply defined by lines. ... When you see typical art drawn on simple drawing, printing, or painting surface, you immediately see shapes. (Fig. 31)



(Fig. 31. Form vs shape.)

An important anatomic determinant of the final tooth shape expression is the *incisal embrasure* is an open space is formed between the proximal surfaces of incisal edges from the contact points. The incisal embrasure space between the centrals is slight. The contact point between the central and lateral incisor approaches the junction of the middle and incisal thirds of each crown, making it slightly deeper than the junction between the centrals. The contact point of the lateral incisor and the cuspid is approximately at the middle third. (Fig. 32)

(Davis, 2007)



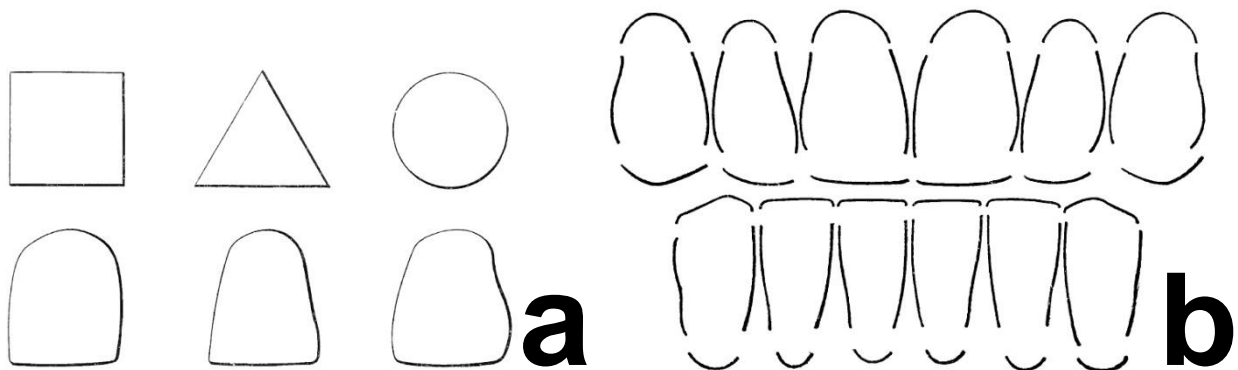
(Fig. 32. Incisal embrasures (arrows). Size increases progressively from the central to the cuspid..)

The geometric theory and its opponents:

In 1914 Williams stated that: *“So this discovery which I have made of three primary forms of teeth is one of those ultimate facts of nature.”*

The essential feature of which is the three primary or primitive forms of the upper central incisors common to all races of men and the anthropoid apes. In all that we have to say about tooth form, it is always to be understood that we are speaking of the upper central incisors. It is these teeth that are the chief factor in determining harmony with the face, and they also govern the type of all other teeth in the set.

And the essence of that principle is the direct adaptation of tooth form to facial contour. A square tooth for a square face ; an oval tooth for an oval face ; an ovoid tooth for an ovoid face, and teeth with proximal lines converging toward the neck for the tapering faces with lines converging toward the chin.(Fig. 33.a&b)

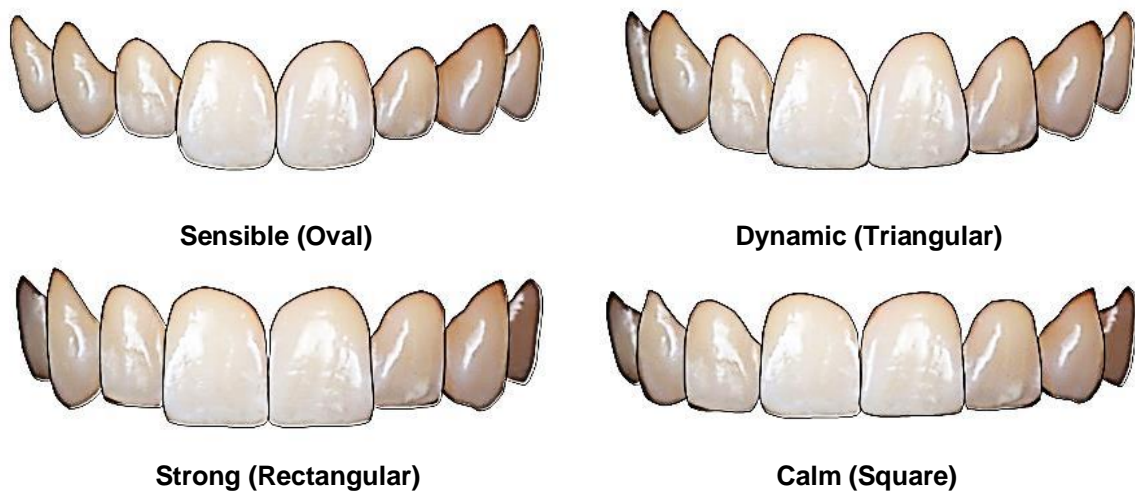


(Fig. 33.a The three simple forms from which all other forms are made. b. Elements of design, partly assembled.) (Williams, 1914)

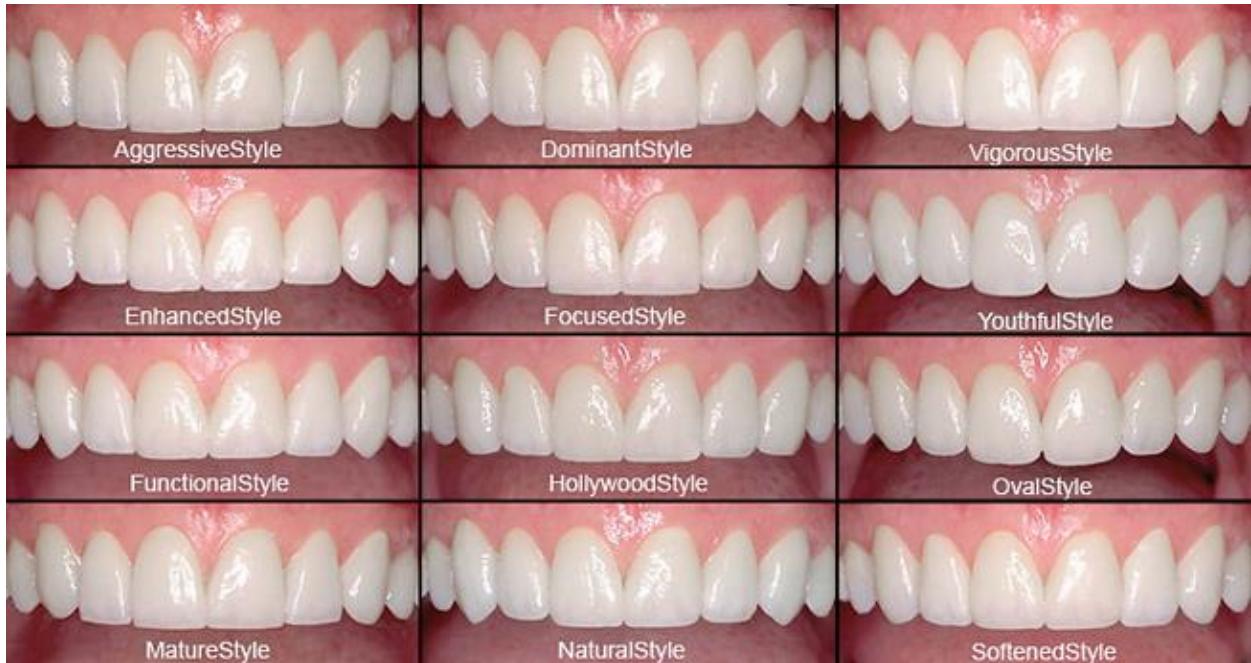The selection of artificial teeth for dentures is to a large degree based on the subjective judgment of the dentist. As a result, selection of artificial teeth is one of the most unscientific processes in dentistry. In 1936, Wright studied the geometric theory and found that 60.7% of his subjects had natural maxillary incisors that were not similar in form to the facial form; 30% were generally like the facial form, but only 13% were identical. None of the significance levels are low enough to establish any correlation between the form of the face and the form of the maxillary central incisors. Therefore, the geometric theory is invalid. Tooth size and arrangement are apparently far more important than tooth form. **(Bell, 1978)**

The morphopsychologic interview and the patient's desires:

The anatomy of the anterior teeth plays an important role in a natural appearance and the individuality and personality of a smile. Some anterior teeth are flat and some are convex. Some have a square appearance while others have a fan-shaped appearance. These and other distinctive contours give each patient's smile individuality. (Fig. 34&35) **(Davis, 2007)**



(Fig. 34. Morpho psychology – Visagism) (Christian Coachman 2010)



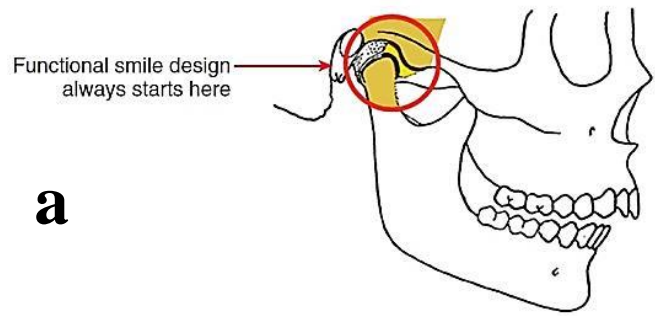
(Fig. 35. In using the Smile Library it is often important to understand the basic meaning of the shapes of the teeth. Teeth that have rounded edges are often considered to be softer and younger and more feminine. Enhanced, Natural, Oval, Softened, and Youthful styles will be excellent choices for women. Teeth that are either flat or squarish are more masculine, aggressive, dominant, and older. This is excellent for men and Aggressive, Dominant, Hollywood, Mature, and Vigorous styles will be great choices. The Functional and Natural Styles of smiles can work well on both men and women in any culture because the styling produces both rounded edges and stronger and sharper lines of the canines.) (Cited by Dickerson, 2017)

• -2.4. Functional considerations in smile Design:

Design of cosmetic restorations that does not consider the entire temporomandibular joint (TMJ)/occlusion condition is shortsighted and an invitation for problems.

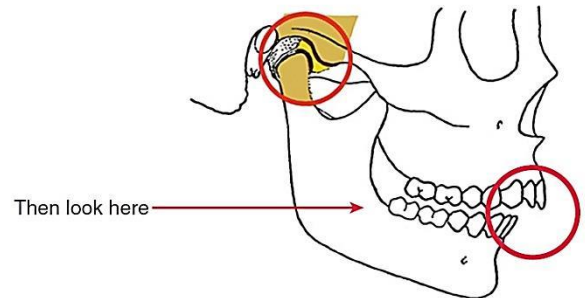
(Fig. 38.

a. You must determine if the TMJs can be completely seated into centric relation. If there is any sign of tenderness or tension in either joint, you are not ready to proceed with planning for anterior restorations.



a

b. The goal is anterior contact in centric relation (or adapted centric posture) without interference or premature contact of the posterior teeth.



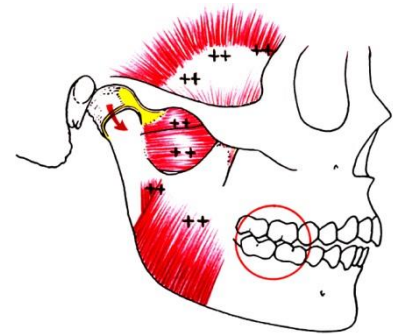
b

c. If there are posterior interferences that require displacement of the TMJs to achieve anterior contact, the result will be the potential for any or all of the following:

1. Overload on posterior teeth
2. Hyperactive uncoordinated muscles
3. Mandibular slide forward into anterior overload
4. Excessive wear, hypermobility, and tooth migration (unstable dentition)

(Dawson, 2007)

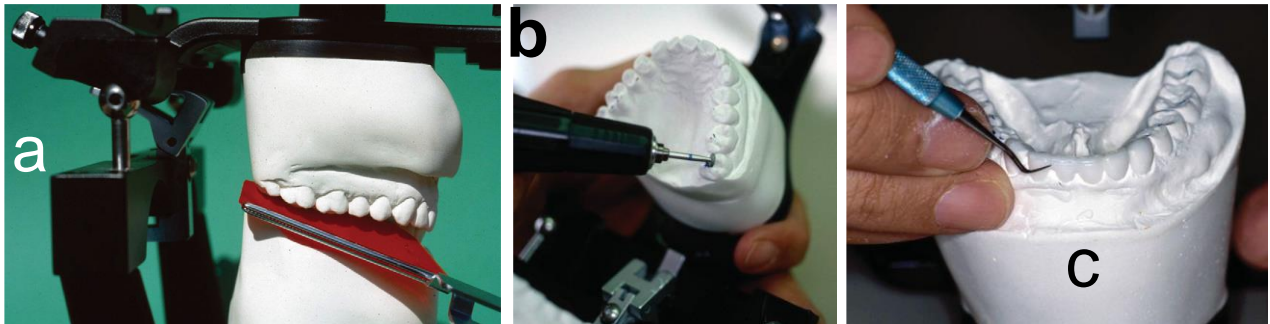
c



2.4.2. Reshaping the cast and Wax up build up depending on centric articulated casts:

Before smile design can be achieved with accuracy, the best option for getting the back teeth out of the way has to be determined. Analysis of the posterior occlusion can be done on the casts mounted in centric relation. Marking ribbon is used to mark interferences that prevent anterior contact in centric relation. The articulator should be locked in centric relation for this step (Fig. 39.a). If reductive reshaping is selected as the best option, the posterior teeth can be equilibrated to close the VDO and bring the anterior teeth closer together for centric relation contact (Fig. 39.b). The diagnostic wax-up on the lower anterior teeth is an

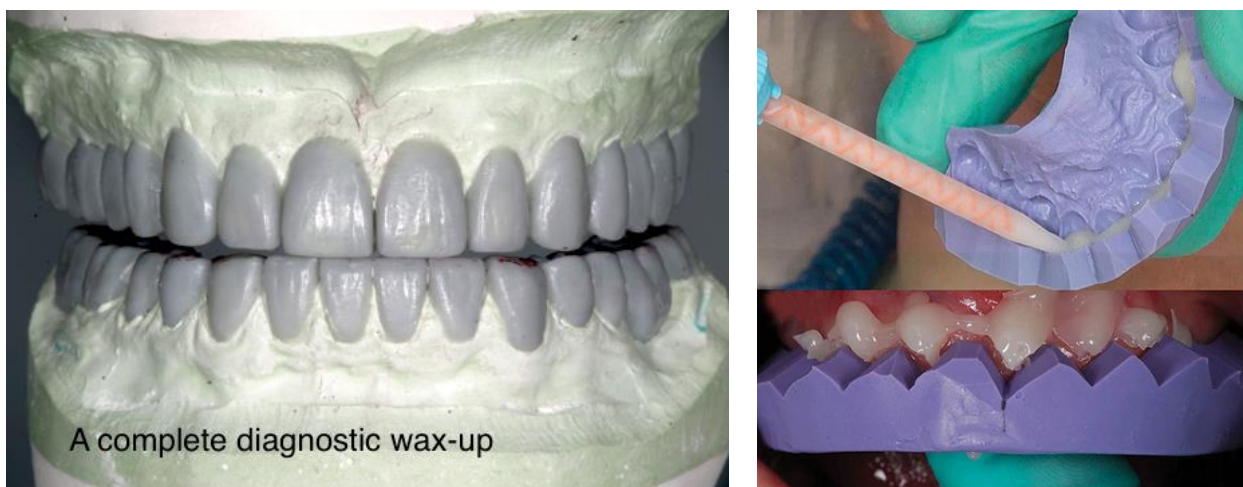important planning step to get an idea of what can be accomplished by restorative reshaping to achieve anterior contact in centric relation (Fig. 39.c).



(Fig. 39. Reshaping the cast)

The completed diagnostic wax-up is a very good guide for selecting the best option for treatment, and it will be used to fabricate a matrix for the provisional restorations when the teeth are prepared. But final determination of the incisal edges, labial contour, and anterior guidance must be worked out in the mouth. One of the main advantages is that the wax-up provides an ideal starting place for refinement of all the anterior teeth contours, including the precise location of the incisal edges and the anterior guidance. A putty silicone matrix is made from the wax-up, to be used for fabricating the provisional restorations after the teeth are prepared. (Fig. 40)

(Dawson, 2007)



(Fig. 40. A. Completed Wax up. b. silicone key and provisional mock up administration)

2.5. Digital Smile Design (DSD):

2.5.1. Definition:

The Digital Smile Design is a multi-use tool that can assist the restorative team throughout treatment, improving the dental team's understanding of the esthetic issues and increasing patient acceptance of the final result. The placement of references lines and other shapes over extra- and intraoral digital photographs widens the dental team's diagnostic vision and helps to evaluate the limitations, risk factors, and esthetic principles of a given case. These critical data will lead to improved results in all phases of treatment. (Coachman & Calamita, 2012)

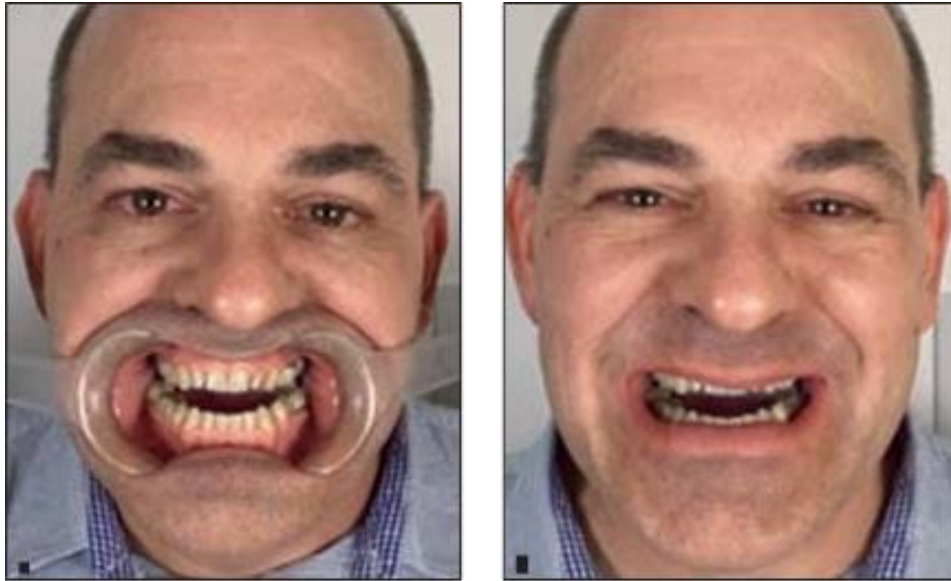2.5.3. Dynamic Documentation of the Smile and the 2D/3D Digital Smile Design Process:

Photographs taken with digital single lens reflex (DSLR) cameras are still the gold standard to fabricate beautiful documentation for lectures and publications. When it comes to image quality, smartphone cameras are not as good as DSLR cameras. However, they are adequate for smile design, treatment planning, patient education, and the digital workflow, allowing the team to deliver optimal routine dentistry on a daily basis.

Photo recording requirements:

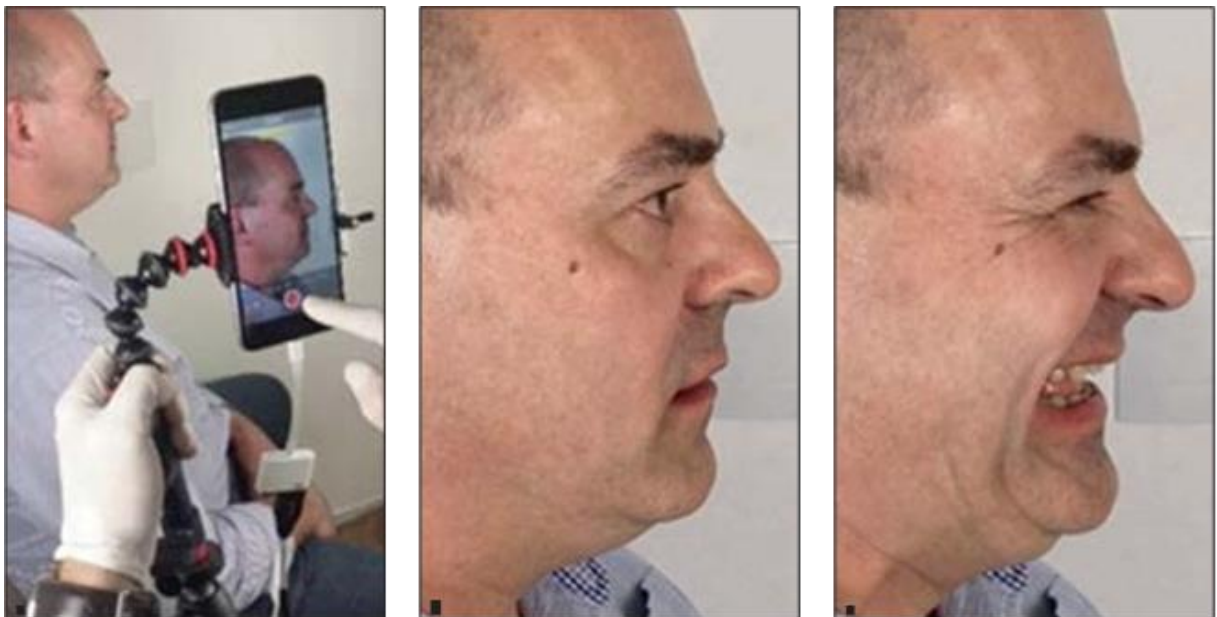Four videos should be taken from specific angles for ideal development of the facially guided smile frame:

- a- **A facial frontal video** should be recorded, including with and without retractor smiling. The key is to keep the camera and the patient's head still to create photos with and without retraction from similar distances, angles, and distortions. Both images then can be overlapped on the DSD process, linking the facial analysis to the intraoral analysis. (Fig 45) (Coachman, *etal.*, 2017)



(Fig. 45 Facial frontal video. (a) Retracted. (b) Smiling.)

b- A **facial profile video** should be taken with the lips at rest and in a wide E smile. The key is to provide a total profile view. The reference should be the upper lip. (Fig 46)



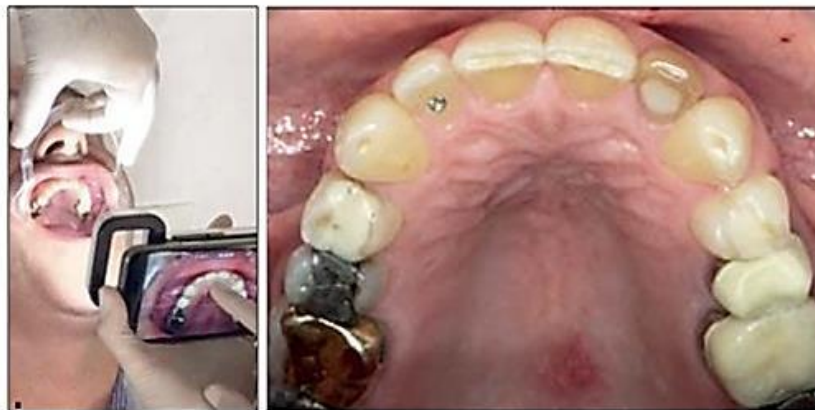(Fig. 46. Facial profile video. (a) Patient positioning. (b) At rest. (c) Smiling.)

c- A **12 o'clock video** should also be taken from above the head at the most coronal angle that still allows visualization of the incisal edge of the six anterior maxillary teeth with the patient retracting the upper lip with both thumbs. This image should show the relationship between the facial midline, interpupillary line, inter commissural line, angles of the mandible, menton, arch form, and vermilion of the lower lip. (Fig 47) (Coachman, *etal.*, 2017)



(Fig. 47. 12 o'clock video.)
(Coachman, *etal.*, 2017)

d- An **anterior occlusal video** should be made without a mirror and perpendicular to the occlusal plan. The goal is to capture the maxillary teeth from second premolar to second premolar with the palatine raphe as straight line. (Fig 48)

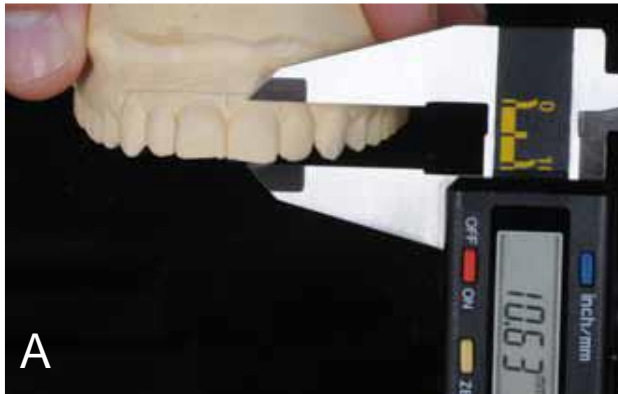

(Fig. 48. Anterior occlusal video. (a) Patient positioning. (b)Close-up view.)

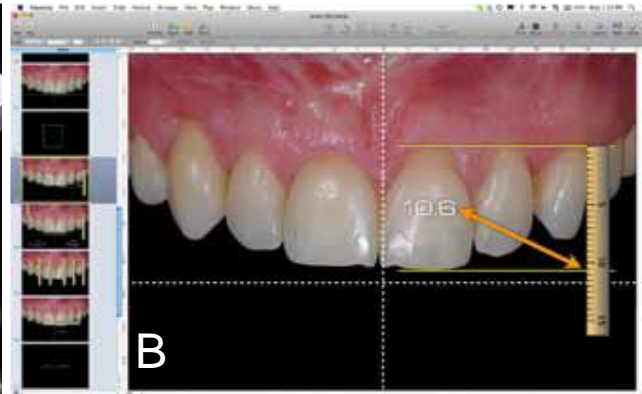
(Coachman, *etal.*, 2017)

2.7. DSD guided manually fabricated wax up (Coachman & Calamita, 2012):

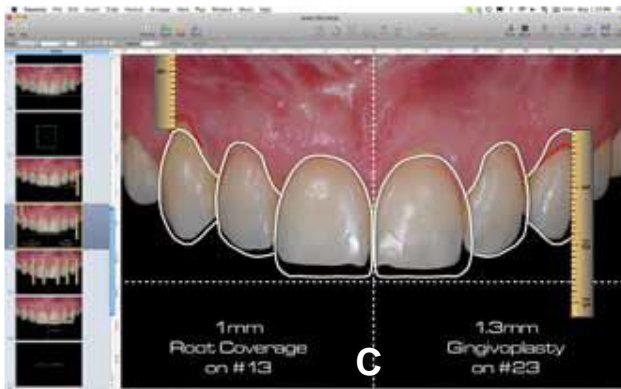
The digital ruler can be calibrated over the intraoral photograph by measuring the length of one of the central incisors on the cast (Fig. 54.A) and transferring this measurement to the computer (Fig. 54.B). Once the digital ruler is calibrated, then can make any measurements needed over the anterior area of the image (Fig.54.C).



(Fig. 54.A. Measuring the length of the left central incisor (10.6 mm) on the cast. This measurement will be transferred to the computer for calibration of the digital ruler.)

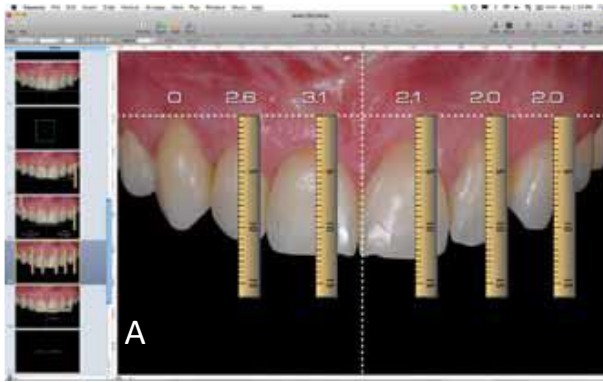


(Fig. 54.B. Calibrating the digital ruler on the slide by shrinking/stretching until it matches the measurement done on the cast. The digital ruler is a photograph of a ruler (JPEG file)

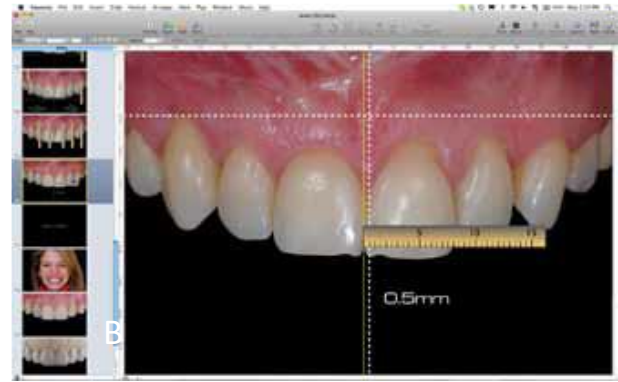


(Fig. 54.C. Measurements can be taken of the difference between the preoperative location of the cervical areas of the canines compared to the ideal location. In this case, one maxillary canine needed crown lengthening and the other required root coverage. (Coachman & Calamita, 2012)

First, the horizontal line over the intraoral photograph should be moved above the gingival margin of the six anterior teeth. The distance between the horizontal line and the gingival margin of each tooth is measured using the digital ruler, and these measurements are written down on the slide (Fig. 55.A).



(Fig. 55.A. The horizontal line is placed randomly above the gingival margin of the anterior teeth. This distance is then measured and transferred to the stone cast using the digital ruler.

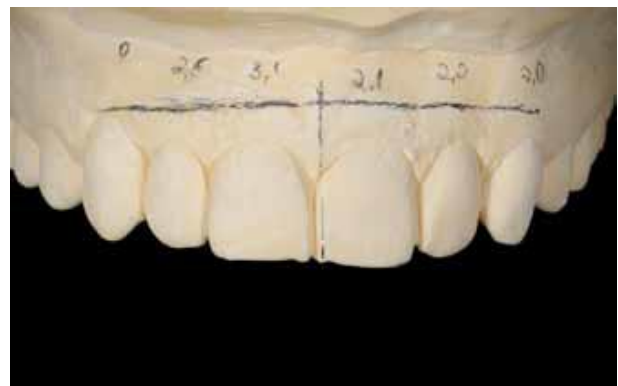

(Fig. 55. B. Measuring the discrepancy between the facial midline and dental midline.)

(Coachman & Calamita, 2012)

The measurements are then transferred to the cast with the aid of a caliper. Pencil marks are made the cast at the same distances above the gingival margins as shown on the digital images. Those dots are then connected, creating a horizontal line above the teeth. The next step is to transfer the vertical midline. Because the vertical line must be perpendicular to the horizontal line, only one point is necessary to determine its location. The distance between the dental midline and the facial midline at the incisal edge is measured on the computer, and the distance is then transferred to the cast with the caliper (Fig.55.B). Subsequently, the line can be drawn perpendicular to the horizontal line passing over this reference point. After drawing the cross on the cast (Fig. 56), it is possible to transfer any necessary information, such as gingival margins, root coverage, crown lengthening, incisal edge reduction, and tooth width.

(Coachman & Calamita, 2012)

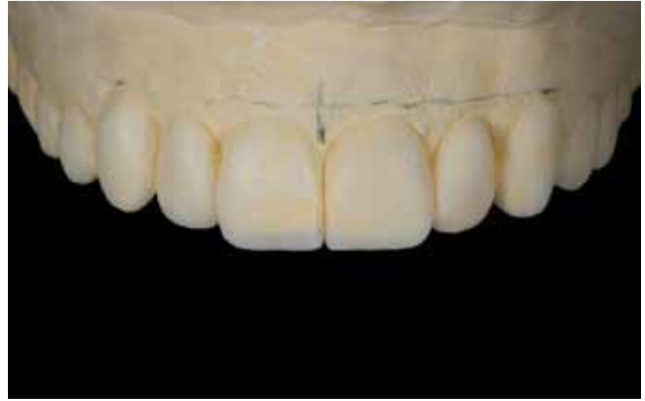

(Fig. 56. All the measurements are transferred to the cast, and the cross is drawn.

(Coachman & Calamita, 2012)

At this stage, all information the technician will need to develop a precise wax-up is available on both the slides and cast (Fig. 57).

(Fig. 57. The diagnostic wax-up is fabricated using the cross and morphopsychologic design as guides. The new incisal length is measured on the computer and transferred to the wax-up with a caliper. (Coachman & Calamita, 2012)

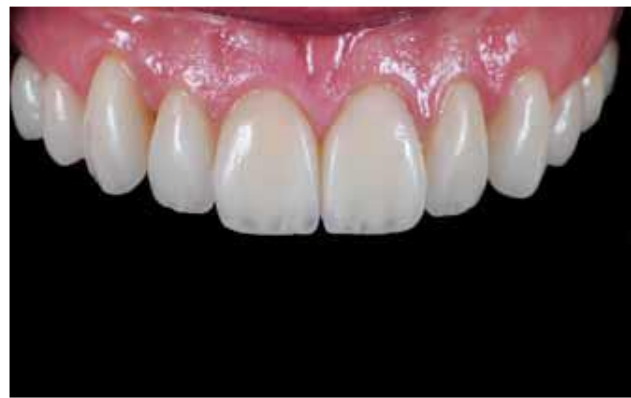

The guided diagnostic wax-up will be an important reference for any surgical, orthodontic, and restorative procedures. Several guides can be produced over this wax-up to control the procedures, such as surgical stents, orthodontic guides, implant guides, crown lengthening guides, and tooth preparation guides.

The next important step to evaluate the precision of the DSD protocol and the wax up is to perform a clinical try-in (Fig. 58). The clinical try-in can be carried out using a direct mock-up or a provisional restoration depending on the complexity of the case. (Coachman & Calamita, 2012)



(Fig. 58 Try-in provisional made with bis-acrylic resin is obtained from a silicone index fabricated on top of the diagnostic wax-up.) (Coachman & Calamita, 2012)



(Fig. 59 Ceramic veneers after bonding.

(Coachman & Calamita, 2012)

Ceramic: refers to any product made from a nonmetallic inorganic material usually processed by firing at a high temperature to achieve desirable properties.

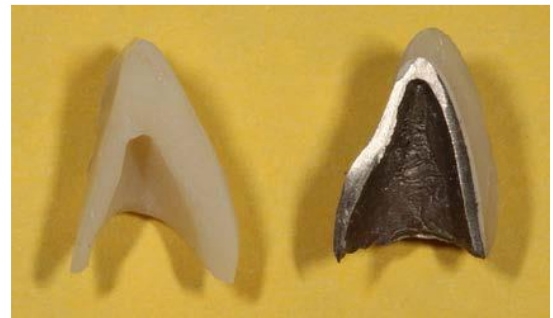Porcelains: a specific compositional range of ceramic materials originally made by mixing kaolin (hydrated aluminosilicate), quartz (silica), and feldspars (potassium and sodium aluminosilicates), and firing at high temperature.

Dental porcelains: Dental ceramics for metal-ceramic restorations belong to this compositional range.

CLASSIFICATION OF DENTAL CERAMICS

Classification by Application:

- 1- Ceramics for metal-ceramic crowns and fixed dental prostheses.
- 2- All ceramic materials for crowns, inlays, onlays, veneers, and FDPs. (Fig. 1)



(Fig. 1) Cutaways of all-ceramic crown (left) and Porcelain fused to metal crown (right).

Classification by Fabrication Method:

- 1- Soft machined
- 2- Hard machined
- 3- Heat pressed
- 4- Sintered

Classification by Crystalline Phase:

After firing, dental ceramics are composed of a glassy (or vitreous) phase and one or more crystalline phases, together with various amounts of **porosity**. Depending on the nature and amount of crystalline phase and porosity present Increasing the amount of crystalline phase may lead to crystalline reinforcement and increase the resistance to crack propagation but also can decrease translucency.

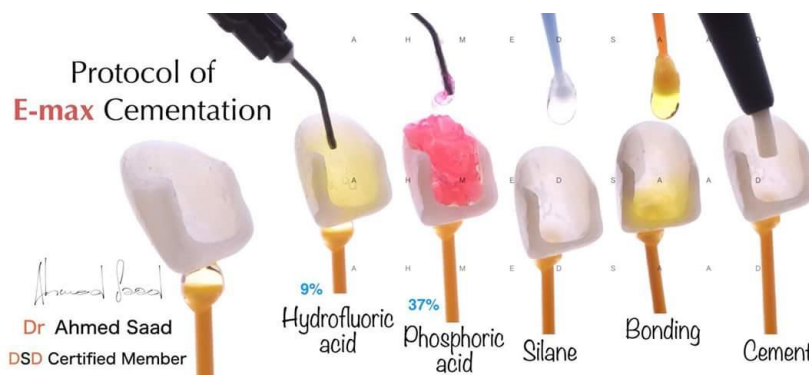GENERAL APPLICATIONS OF CERAMICS IN PROSTHETIC DENTISTRY

- 1- **Metal-Ceramic Crowns and Fixed Dental Prostheses:** successfully matching the coefficients of thermal expansion of porcelain with that of metal alloys achieving a proper metal-ceramic bond.
 - The finished glazed restoration is color stable.
 - Tissue friendly
 - Biologically inert
 - Chemically durable

Although the survival rate of most all-ceramic crown compares favorably to that of metal-ceramic crowns for single restorations, the long-term survival rate of multiunit all-ceramic FDPs remains lower.

2- All-Ceramic Crowns, Inlays, Onlays, and Veneers:

- **Ceramic inlays and onlays:** have better abrasion resistance than posterior resin composites and therefore are more durable. Occlusal adjustments are more difficult and can lead to subsequent wear of the opposing tooth if not properly polished.
- **Ceramic esthetic veneer (lamine veneer):** is a layer of ceramic bonded to the facial surface of a prepared tooth often for cosmetic reasons. Initially, ceramic veneers were made of feldspathic porcelain and sintered. Currently, most ceramic veneers are fabricated by heat-pressing or machining, using either a leucite-reinforced or lithium disilicate ceramic. To obtain sufficient adhesion, the tooth enamel is etched with phosphoric acid and the bonding surface of the ceramic is etched with 5% to 9% hydrofluoric acid gel and treated with a silane coupling agent. Resin composites specifically formulated for bonding to ceramic are used as the adhesive.(Fig. 2)



(Fig. 2 protocol of Emax cementation chemical treatment)

MECHANICAL AND THERMAL PROPERTIES OF DENTAL CERAMICS

Toughening Mechanisms: Toughening mechanisms for glasses and ceramics are either:

- 1- **“Built-in” (intrinsic):** Crystals can act as crack deflectors when their coefficient of thermal expansion (CTE) is greater than that of the surrounding glassy matrix. As they contract more than the surrounding glassy matrix.

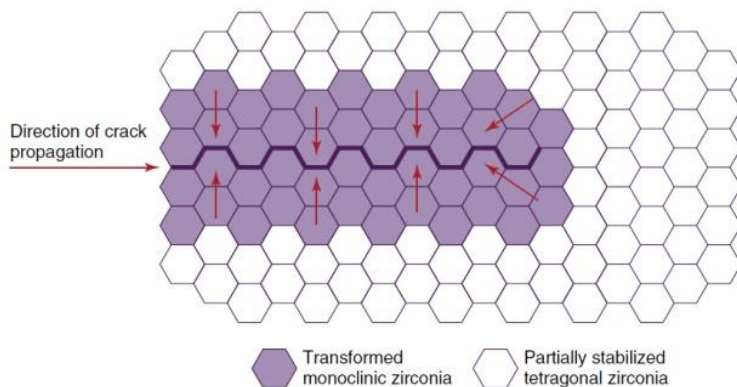
(ZrO₂) exists under several crystallographic forms:

The monoclinic form is stable at all temperatures below 1170°C.


The tetragonal form is stable between 1170° and up to 2370°C.

The transformation from the tetragonal to the monoclinic form upon cooling is associated with **a volume increase** of the unit cell.

Transformation toughening is responsible for the excellent mechanical properties of 3Y-TZP. (Fig.3). (Fig. 4) Shows a Vickers indentation in a 3Y-TZP dental ceramic under a 98.1-N load. Only one short crack can be seen emanating from one corner of the indentation, indicative of an excellent resistance to crack propagation.



(Fig.3 Schematic of transformation toughening mechanism in partially stabilized zirconia)



(Fig. 4)

Zirconia-based dental ceramics produced by machining followed by sintering at high temperature consist of tetragonal zirconia polycrystals (TPZ), partially stabilized with 3 mole percent yttrium (3Y-TZP)

2- Extrinsic processing steps such as

- **Tempering** and **Chemical strengthening** are extrinsic strengthening techniques based on the creation of a compressive stress layer at the surface of a glass or a ceramic. Glaze application has also been used in the past to achieve strengthening. these techniques are no longer used for dental ceramics due to:
 - controllability issues
 - potential elimination and benefit loss from grinding adjustments
- **Glazing** is the final step in the fabrication of metal-ceramic restorations. This standard technique, also called **self-glazing**, does not significantly improve the flexural strength of feldspathic dental porcelains.
This layer is also known to reduce depth and width of the surface flaws, thereby improving the overall resistance of the ceramic to crack propagation.

Test Methods

Studies of the influence of test method on the failure stress of brittle dental materials have shown that important test parameters are:

- **Specimen thickness**
- **Contact zone at loading**
- **Homogeneity and porosity of the material**
- **Loading rate**

Manufacturers evaluate dental ceramics using a standard (ISO 6872) published and regularly revised by the International Organization for Standardization.

Set protocols are proposed to quantify:

- Radioactivity
- Flexural strength
- Linear coefficient of thermal expansion (**CTE**)
- Glass transition temperature
- Chemical solubility.

Testing protocols and fixtures aimed at stimulating dental morphology experimental variables can become extremely complex and difficult to reproduce in this type of testing.

Finite element analysis constitutes another approach to the simulation of clinical conditions.

Fractography is well established as a failure-analysis technique for glasses and ceramics. It has been recognized as a powerful analytical tool in dentistry.

Comparative Data:

Feldspathic porcelains for metal-ceramic restorations have a mean flexural strength between 60 and 80 MPa. This value is lower than those listed for all-ceramic materials. However; because metal-ceramic restorations are supported by a metallic framework have survival usually higher than that of leucite-reinforced or lithium disilicate–based glass-ceramics.

TABLE 11.2 Flexural Strength of Selected Dental Ceramics

| Processing Technique | Crystalline Phase | Flexural Strength (MPa) | Percent Crystallinity |
|----------------------|---|-------------------------|-----------------------|
| Soft machined | Zirconia (3Y-TZP) | 1087 ± 173 | Highly crystalline |
| | Zirconia (cubic + tetragonal) | ≈700 ^a | Highly crystalline |
| Hard machined | Feldspar ([Na, K]AlSi ₃ O ₈) | 122 ± 13 | ≈30 |
| | Lithium disilicate (Li ₂ Si ₂ O ₅) | 262 ± 88 | 65 |
| | Lithium silicate (Li ₂ Si ₂ O ₅ and Li ₂ SiO ₃) | ≈420 ^a | >50 |
| | Leucite (KAlSi ₂ O ₆) | ≈160 ^a | ≈35 |
| | Leucite (KAlSi ₂ O ₆) | 106 ± 17 | 35 |
| Heat pressed | Lithium disilicate (Li ₂ Si ₂ O ₅) | 306 ± 29 | 65 |
| | Leucite (KAlSi ₂ O ₆) | 104 | 35–40 |
| Sintered | Fluorapatite (Ca ₅ [PO ₄] ₃ F) | ≈80 ^a | 10 |
| | Leucite (KAlSi ₂ O ₆) | 61 ± 5 | 15–25 |

OPTICAL PROPERTIES OF DENTAL CERAMICS

Porcelain is amorphous in structure **cannot match** the optical properties of crystalline enamel completely.

Light rays are reflected, refracted, and absorbed **unevenly** by the combination dentin/enamel, compared with porcelain. As a consequence, restorations viewed from one incidence angle may not appear the same as they do when viewed from a different incidence angle.

The cementing medium is an important factor in the final appearance of an **all-ceramic restoration**.

Zirconia based all-ceramic opacity may permit cementation with various luting agents **without** the need for specific shade matching.

Because the range of shades existing in natural teeth is much greater than the range available in a kit of premixed porcelains, modifier porcelains are also available for precise shade adjustments. These modifiers are strongly pigmented porcelains usually supplied in blue, yellow, pink, orange, brown, and gray.

The main disadvantages of surface staining compared with intrinsic staining are a **limited durability** and the **reduction of translucency**.

The translucency of opaque, dentin (body), and enamel (incisal) porcelains differs considerably.

By design:

Opaque porcelains have **very low** translucency, allowing them to efficiently mask metal substructure surfaces.

Enamel porcelains have the **highest** values of translucency.

The **translucency** of materials for all-ceramic restorations varies with the **nature and amount** of the **reinforcing crystalline phase**.

Alumina and zirconia based ceramics are **opaque**, whereas **leucite-reinforced** and **lithium disilicate** based ceramics are **more translucent**.

Recently, zirconia ceramics with increased translucency have become available.

Opalescence is a form of light scattering and occurs when the size of crystalline phase particles is **equal to or shorter** than the wavelength of light. Both **zirconium oxide** and **yttrium oxide** have been shown to **increase opalescence** in base dentin ceramics due to their light **scattering effect**.

Dental enamel also exhibits **fluorescence**. This characteristic is achieved in dental porcelains by adding rare earth oxides (such as cerium oxide).

For **metal-ceramic** restorations, shade mixing results from combining the light reflected from the inner, opaque porcelain surface and the light transmitted through the body porcelain. The **thickness** of the body porcelain layer determines the final shade obtained with given opaque porcelain.

ALL-CERAMIC RESTORATIONS

The **nature, amount, and particle size distribution** of the **crystalline phase** directly influence the **mechanical, thermal and optical** properties of the ceramic material.

- **Sintered All-Ceramic Materials**

- 1- **Alumina-Based Ceramic:** The aluminous core ceramic is a typical example of strengthening by dispersion of a crystalline phase. Alumina has a high modulus of elasticity and relatively high fracture toughness, compared with feldspathic porcelains.

Aluminous core ceramic can be **baked on a platinum foil** and later veneered with matched expansion porcelain.

Aluminous core ceramic can also be **sintered directly on a refractory die**.

Densely sintered alumina-based ceramics were also produced by **dry pressing**.

A **high-purity** alumina-based ceramic was fabricated by **dry pressing and sintering** at high temperature.

- 2- **Leucite-Reinforced Ceramic:** Leucite acts as a **reinforcing phase**; the **greater leucite content** (compared with conventional feldspathic porcelain for metal-ceramic restorations) leads to **higher flexural** strength and **compressive** strength.

The large amount of leucite in the material can act as crack deflectors and contribute to increased resistance of the ceramic to crack propagation (fracture toughness)

- **Heat-Pressed All-Ceramic Materials** Heat pressing relies on the application of external pressure at high temperature to sinter and shape the ceramic.

The mechanical properties of heat pressed ceramics are maximized in addition to **higher crystallinity**, and **smaller crystal size**, compared with sintered all-ceramics.

- 1- **Leucite-Based Ceramic:** First-generation heat-pressed ceramics contain tetragonal leucite (KAlSi_2O_6 or $\text{K}_2\text{O} \cdot \text{Al}_2\text{O}_3 \cdot 4\text{SiO}_2$) as a reinforcing phase.

The flexural strength of these ceramics is almost double that of conventional feldspathic porcelains.

The **main advantages** of leucite-reinforced ceramics are their **excellent esthetics** and **translucency**, whereas their **limitations** lie in their modest **mechanical properties** restricting their use to **anterior single-unit** restorations.

- 2- **Lithium Disilicate–Based Materials:** The second generation of heat-pressed ceramics contains lithium disilicate ($\text{Li}_2\text{Si}_2\text{O}_5$) as a major crystalline phase.

Heat-pressed restorations are later veneered with ceramics of matching thermal expansion, or stained.

Compared with first generation leucite-based ceramics, **the main advantage** of the lithium disilicate–based ceramics is their **enhanced flexural strength** and **fracture toughness**.

The enhanced mechanical properties make it possible to **fabricate multiunit FDPs**.

- **Machinable All-Ceramic Materials**

- 1- **Hard machining:** All-ceramic materials can be machined in the **fully sintered** state. The restorations produced in this way are machined directly to **final size**.

Machinable ceramics can be milled to form inlays, onlays, veneers, and crowns using the CAD/CAM technology to produce restorations in one office visit.

The restoration is machined from ceramic blocks by a computer controlled milling machine. The milling process takes only a few minutes. Restorations are bonded to the tooth preparation with **resin cements**.

Several machinable glass-ceramics are presently available for hard machining: **feldspar-**, **leucite-**, and **lithium disilicate**-based.

- 2- **Soft machining:** Some all-ceramic materials can also be machined in a **soft, partially sintered** state and later fully sintered. This technique requires milling of **enlarged** restorations to compensate for **sintering shrinkage**.

Material consists of tetragonal zirconia polycrystals partially stabilized by addition of 3 mole percent yttrium (3Y-TZP).

Single or multiunit restorations are produced by direct ceramic machining (DCM) of presintered 3Y-TZP blocks.

These blocks are soft and **easy to mill**, thus leading to substantial **savings in time** and **tool wear**, compared with fully sintered zirconia.

A digital impression of the preparation is made, and the restoration design is accomplished by computer restorations were oversized at the design and machining stages, to compensate for the large shrinkage that occurs during the sintering process at high temperature.

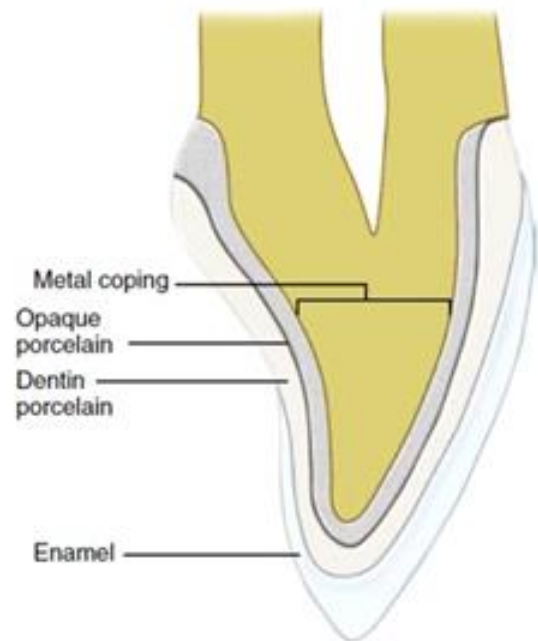
Zirconia ceramics exhibit the **highest flexural strength** (900 to 1500 MPa) and **highest fracture toughness** of all currently available dental ceramics. They can serve as core ceramics that are veneered with porcelain of matched thermal expansion.

The **negative impact** of the **high opacity** of zirconia is attenuated by the ability to **decrease coping thickness** to 0.4 to 0.5 mm. In addition, more **translucent zirconia compositions** have been recently introduced. The increase in translucency is obtained either by decreasing the amount of alumina present, or by adding higher amounts of yttria.

However, all-ceramic materials available with these techniques exhibit only low to moderate strength, restricting the applications to single-unit restorations, or short-span FDPs.

METAL-CERAMIC RESTORATIONS

Metal-ceramic restorations consist of a cast metallic framework on which at least two layers of ceramic are baked (Fig.5). The first layer applied is a thin opaque layer, consisting of porcelain modified with opacifying oxides. Its role is to mask the dark gray appearance of the oxidized metal framework to permit the achievement of adequate esthetics. This thin opaque layer also establishes the metalceramic bond. The next step is the buildup of dentin and enamel (most translucent) porcelains to obtain an esthetic appearance similar to that of a natural tooth.



(Fig.5 Cross section of a metal-ceramic crown showing metal coping, opaque porcelain layer, dentin, and enamel porcelain layers.)

The porcelain buildup has to be oversized to compensate for the large shrinkage (25% to 30%)

After building up of the porcelain powders, metal-ceramic restorations are slowly dried to allow for adequate water diffusion and evaporation, and sintered under vacuum in a porcelain furnace. Sintering under vacuum helps eliminate pores.

When fabricated by skilled technicians, these restorations provide excellent esthetics, along with adequate strength because of the metal framework support.

Requirements for a Metal-Ceramic System:

1. The alloy must have a **high melting temperature**, higher than the firing temperature of the veneering porcelain and solders used to join segments of an FDP.
2. The veneering porcelain must have a low **fusing temperature** so that no creep, sag, or distortion of the framework takes place during sintering.
3. The porcelain must **wet the alloy readily** when applied to prevent voids forming at the metal-ceramic interface.
4. A **strong bond** between the ceramic and metal is essential and is achieved by **chemical reaction** of the opaque porcelain with metal oxides on the surface of metal and by **mechanical interlocking** made possible by roughening of the metal coping.
5. **CTEs (coefficient of thermal expansion)** of the porcelain and metal must be **compatible** so that the veneering porcelain never undergoes tensile stresses, which would lead to cracking.
6. **Adequate stiffness** and **strength** of the metal framework are especially important for FDPs and posterior crowns. High strength is essential in the **interproximal connector** areas of FDPs.
7. **High resistance** to deformation **at high temperature** is essential. Metal copings are relatively thin (0.4 to 0.5 mm); no distortion should occur during firing of the porcelain, or the fit of the restorations would be compromised.
8. **Adequate design** of the restoration is critical. The preparation should provide for **adequate thickness** of the metal coping, as well as enough space for an adequate thickness of the porcelain to yield an esthetic restoration.

Metal-Ceramic Bonding:

The bond between porcelain and metal can be achieved by

- **Diffusion** between the surface oxide layer on the alloy and the porcelain.
- The **surface roughness** at the metal-ceramic interface has a large effect on the quality of the metal-ceramic bond.
- Porcelains and alloys are formulated to have adequately **matched thermal expansion coefficients**.

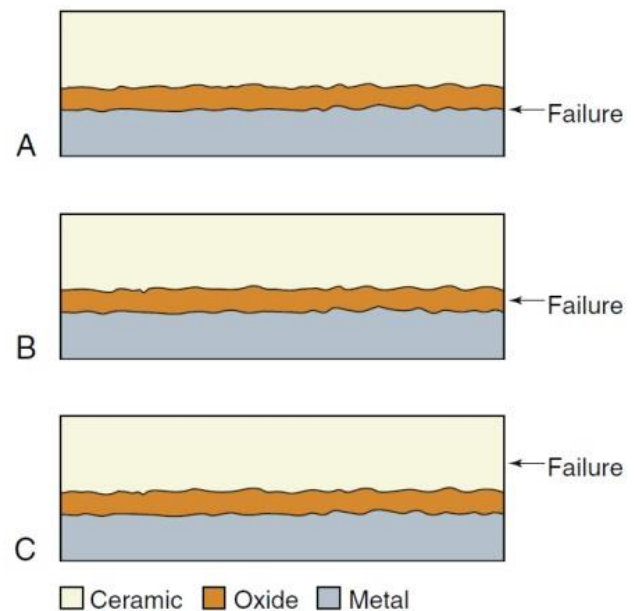
A metal-ceramic bond may fail in any of three possible locations (Fig. 6)

(Fig. 6 Diagram showing three observed types of bond failure in metal ceramic systems.)

(A) Metal-metal oxide (adhesive)

(B) Metal oxide-metal oxide (cohesive)

(C) Ceramic-ceramic (cohesive).



Ceramics for Metal-Ceramic Restorations

Ceramics for metal-ceramic restorations must fulfill five requirements:

- (1) Must simulate the appearance of natural teeth.
- (2) Must fuse at relatively low temperatures
- (3) Must have thermal expansion coefficients compatible with alloys used for metal frameworks
- (4) Must age well in the oral environment
- (5) Must have low abrasiveness.

Effect of Design on Metal-Ceramic Restorations

The metal framework must be rigid to minimize deformation of the porcelain. However, copings should be as thin as possible to allow space for the porcelain to mask the metal framework without over contouring the porcelain.

- **The labial margin** of metal-ceramic prostheses is a **critical** area regarding design because there is **little porcelain thickness** at the margin to mask the appearance of the metal coping and to resist fracture. **Recommended margin designs** include a **90-degree shoulder**, a **120-degree shoulder**, or a **shoulder bevel**. Provided that the shoulder depth is at **least 1.2 mm**, these designs should all provide for sufficient porcelain thickness to minimize the risk of porcelain fracture.
- **When using partial porcelain coverage**, such as when a metal occlusal surface is desired, the position of the metal-ceramic joint is critical. Because of stresses occur at the interface when the restoration is loaded. These stresses should **be minimized** by placing the metal-ceramic **junction** at least 1.5 mm from **centric occlusal contacts**.
- **The geometry** of the **interproximal connector** area between abutment crown and pontic is critical in the design of a metal-ceramic FDP. The **incisocervical thickness** of the **connector** should be **large enough** to prevent deformation or fracture because deflection is decreased as the cube of the thickness; greater thickness will minimize deflection of the framework, which may lead to debonding or fracture of the porcelain.

Failure and Repair of Metal-Ceramic Restorations

Metal-Ceramic Restorations have a **10-year success rate** of about **95%**.

The majority of **retreatments** are due to **biological failures**, such as *tooth fracture, periodontal disease, and secondary caries*.

Prosthesis fracture and **esthetic failures** account for **only 20%** of retreatment cases for single-unit restorations.

For metal-ceramic FDPs, prosthesis **fracture** is the most common reason for retreatment, **with long-span FDPs (*five or more units*)** having approximately **twice** the incidence of failure compared with short-span FDPs.

When metal-ceramic prosthesis fails, it is often due to adhesive failure between porcelain and metal or cohesive failure within the ceramic near the metal-ceramic interface.

(Ideally, the prosthesis should be retrieved, metal surfaces should be cleaned, and a new oxide layer should be formed on the exposed area of metal prior to porcelain application and firing)

However, **this cannot be achieved intraorally**, and **removal of the prosthesis** is both **unpleasant** for the patient and **time consuming**.

Thus a variety of techniques have been developed for porcelain repair **using resin composites**. All of these techniques present the **challenge of bonding chemically dissimilar materials**.

When porcelain fragments are available and no functional loading is exerted on the fracture site, **silane coupling** agents can be used to achieve good adhesion between the composite and porcelain.

Metal alloys have no such bonding agent and **this type of repair is considered only temporary**:

Systems are available for coating the metal surface with **silica particles** through **airborne particle abrasion**. The particles are embedded in the metal surface upon impact, and then a **silane coupling agent** can be applied. Alternatively

Base metal alloys can be **coated with tin** followed by the application of an **acidic primer**.

Both methods achieve adequate bond strength and may delay the eventual need for remaking the prosthesis.

T

emporary

C

rown

F

IXE

PROCEDURES

D

R

estorations

LECTURE 16

Conventional Work

1- Primary Cast: We need a primary impression to make primary stone cast.

- a. No editing needed: using the present dentition for the final shape and size of the restoration.
- b. Changes needed: the changes for aesthetic or occlusal adjustment can be done either manual by wax up or digital after scanning of the cast editing then printing the intended final shape.

2- Copping of the final external surface: making mold to the intended shape of the restoration.

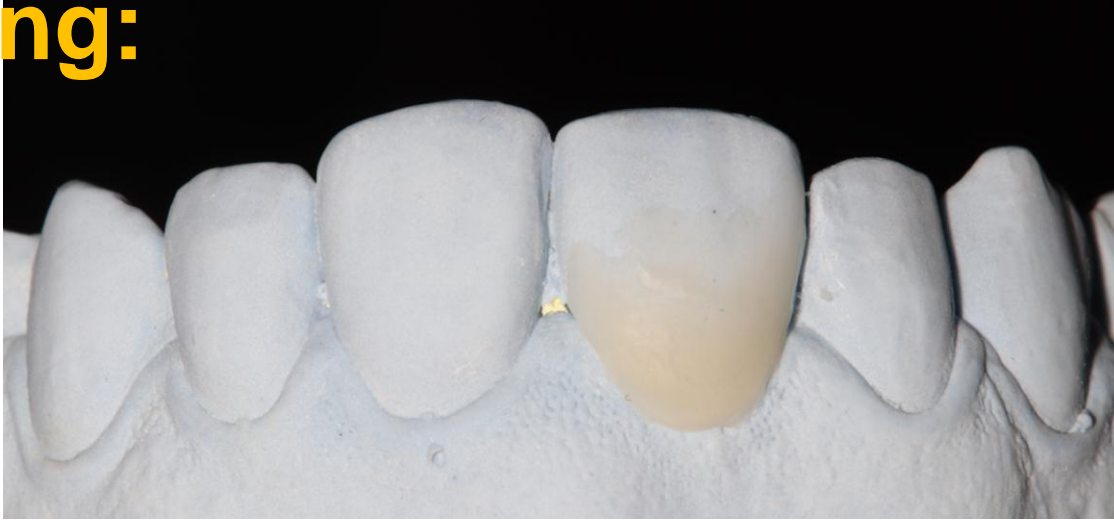3- Internal surface making: tissue surface the prepared teeth or saddle area either :

- a. Direct on patient mouth.
- b. Indirect on the cast.
- c. Direct indirect technique.

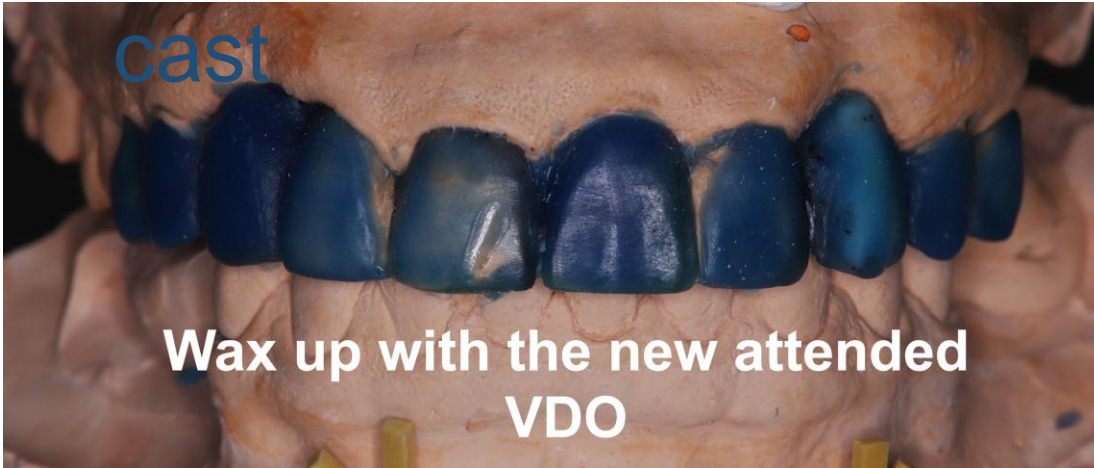PROCEDURES

- It is a helpful principle that all the procedures have in common the formation of *a mold cavity into which a plastic material is poured or packed*.
- The mold cavity is created by two correlated parts: one forming the external contour of the crown or FDP, the other forming the prepared tooth surfaces and (when present) the edentulous ridge contact area.

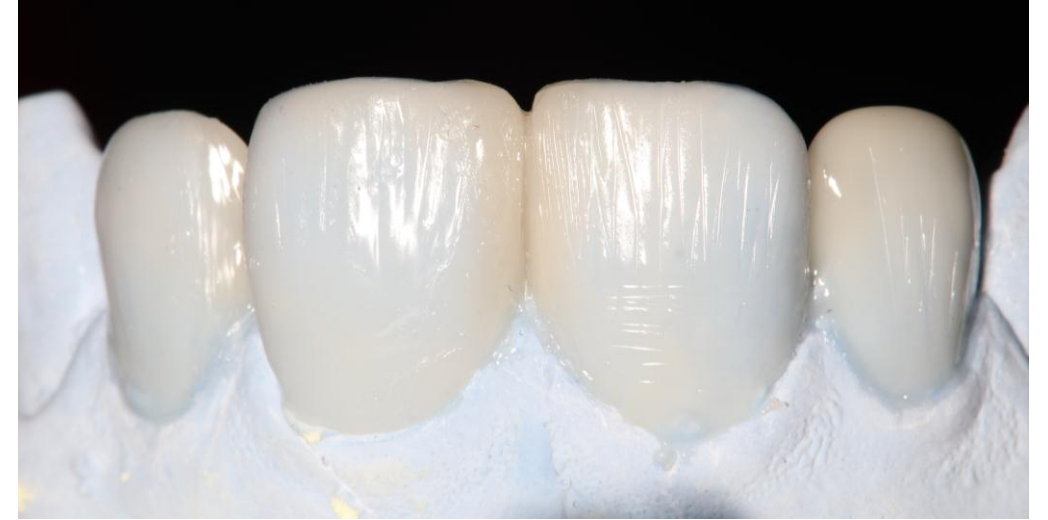1. Final external contour making:



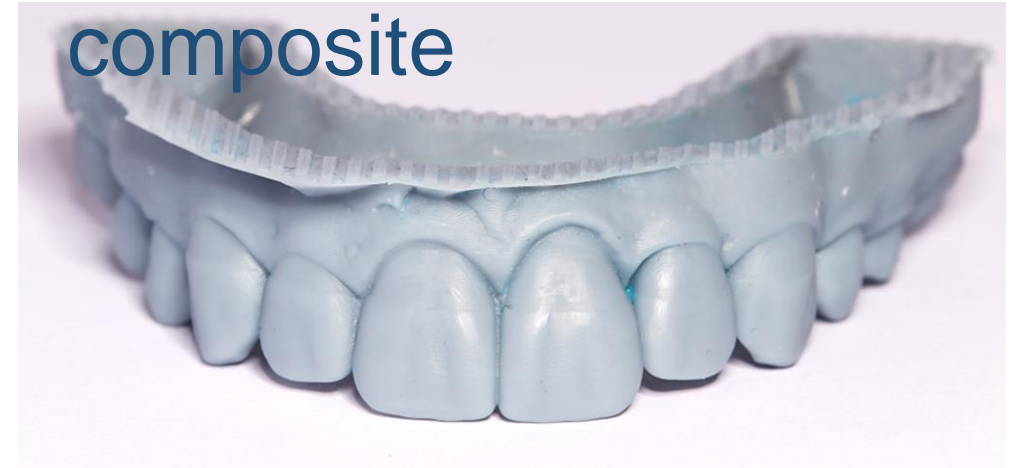Minor editing on the
cast



Wax up to replace missing



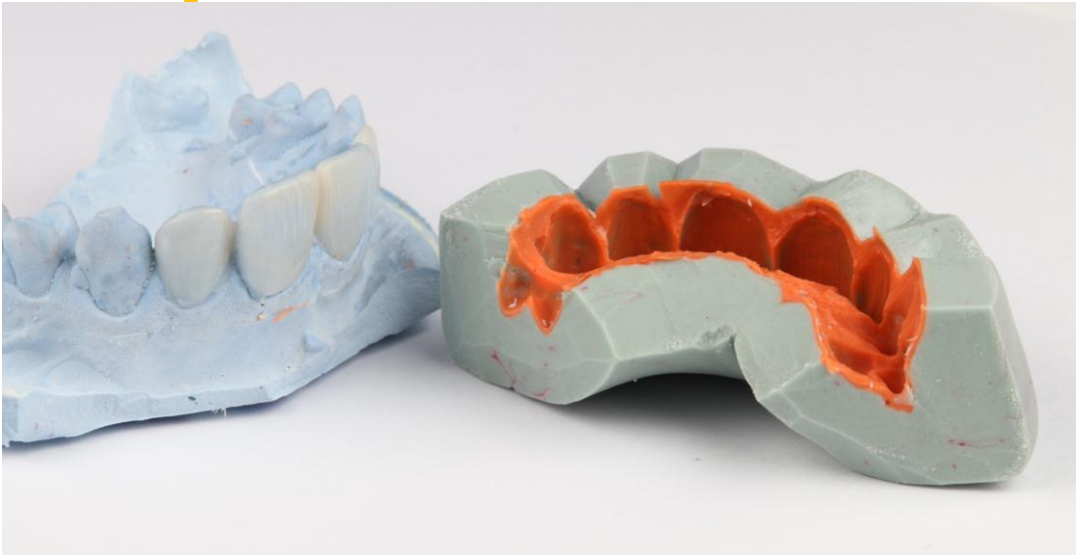Mock up with
composite



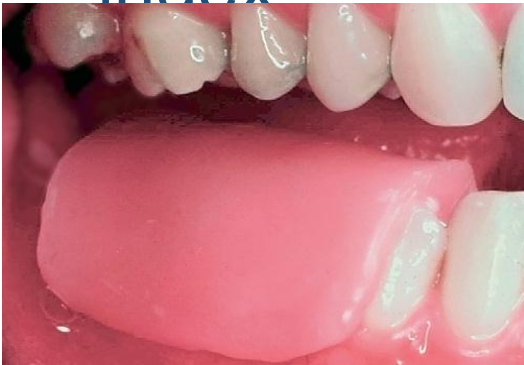3D printed model

2. Final external contour

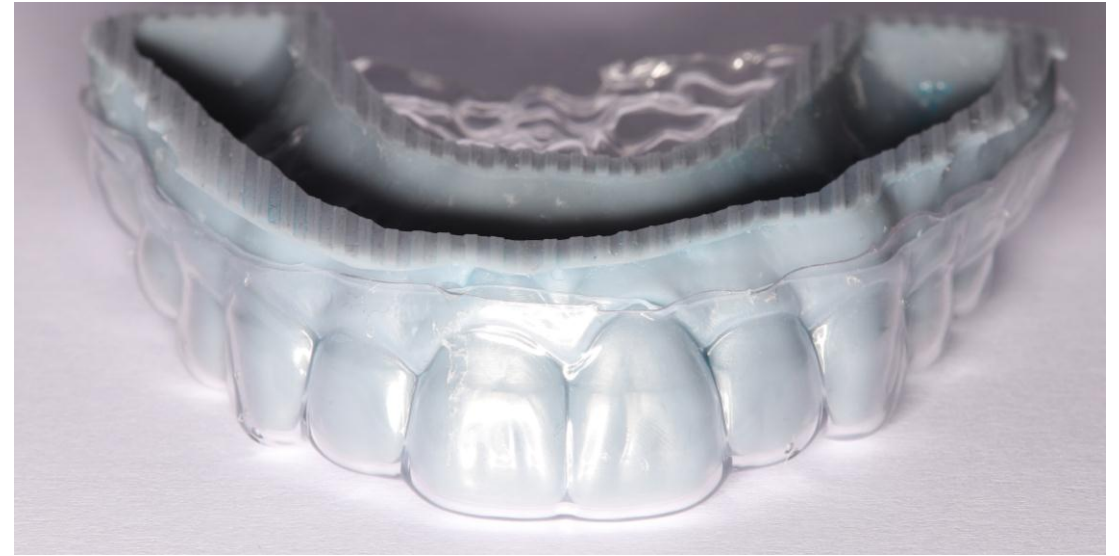C



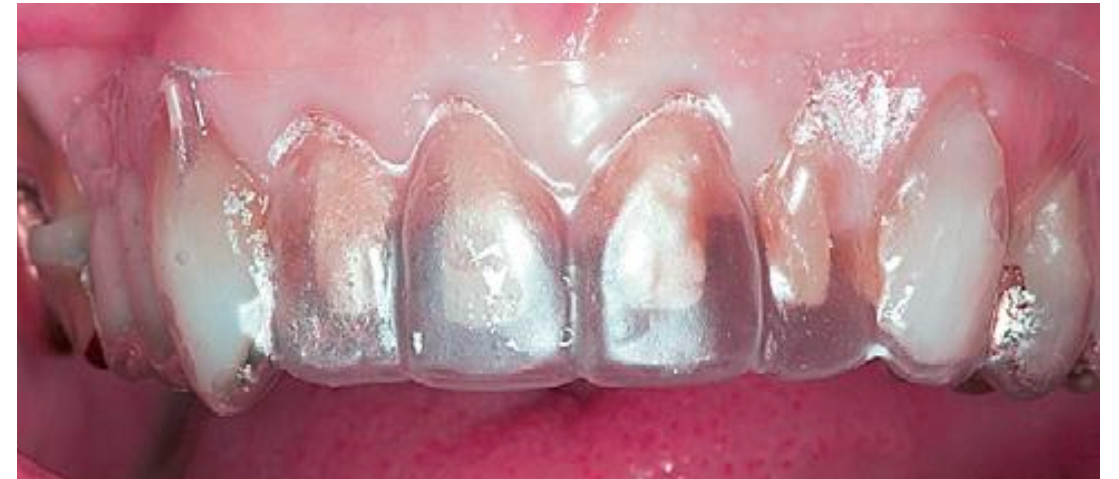Silicone Key C-silicone
index



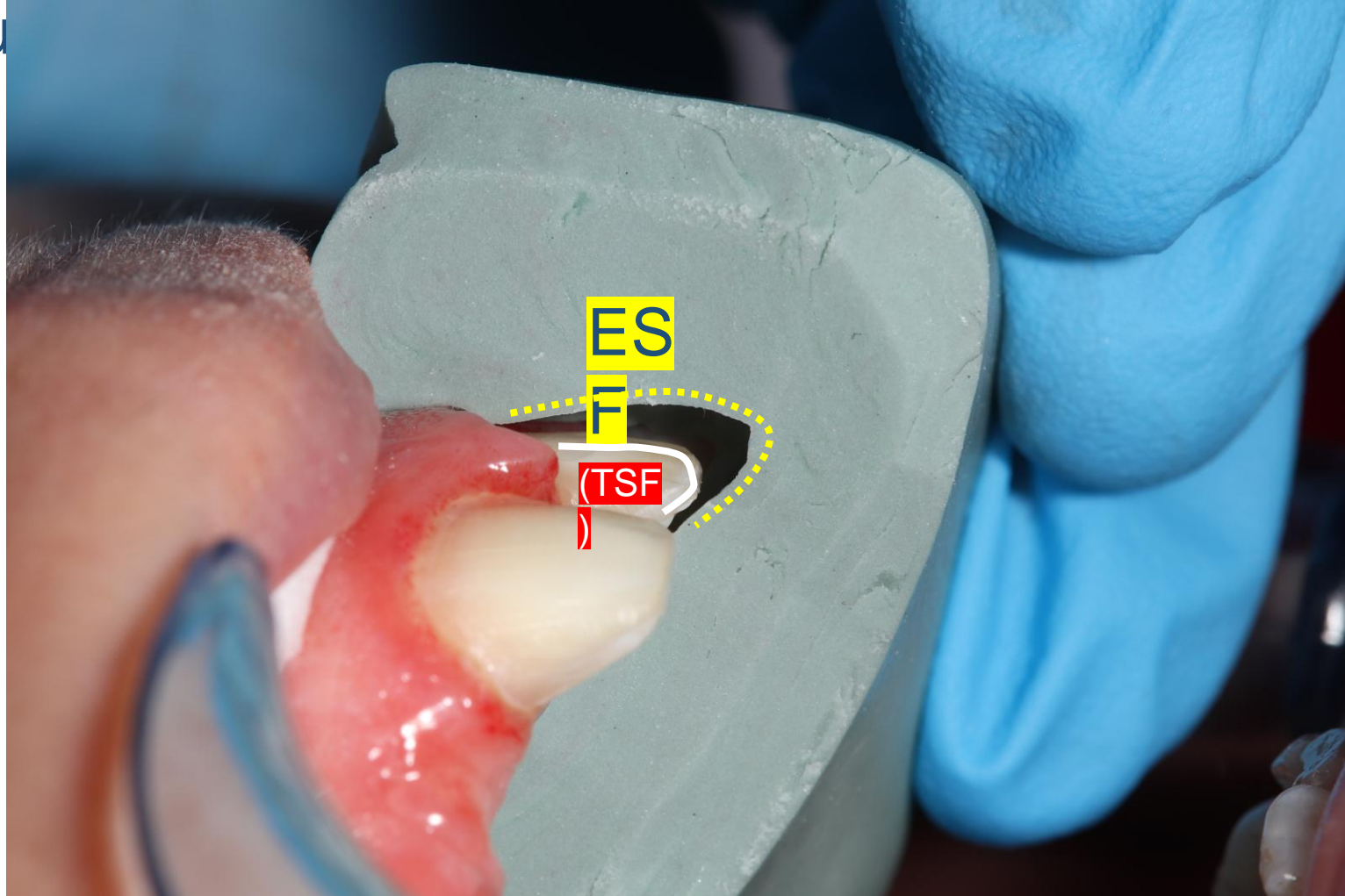
baseplate wax
impression



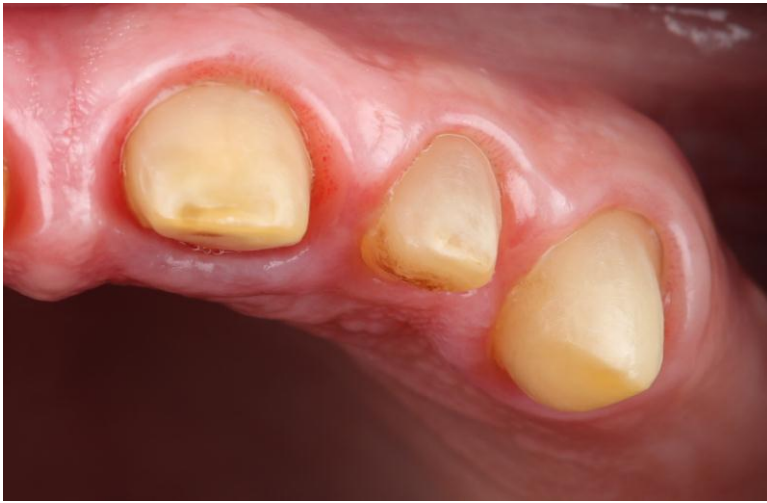vacuum-formed acetate sheet



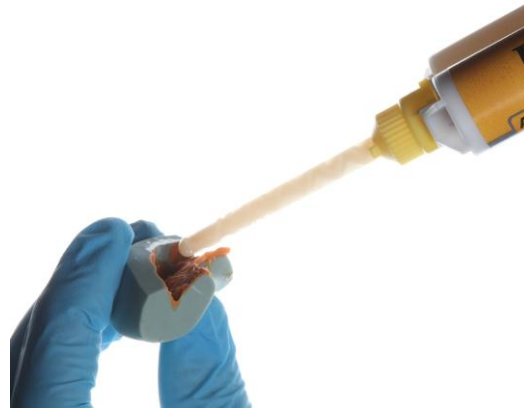- The terms **external surface form (ESF)** and **tissue surface form (TSF)** are suggested for these mold parts. This terminology is used in the ensuing discussion.



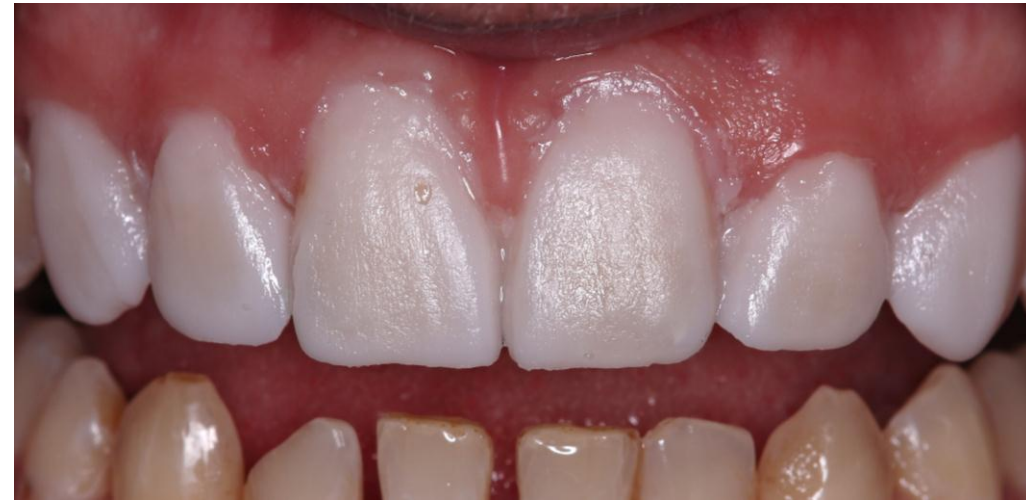Direct



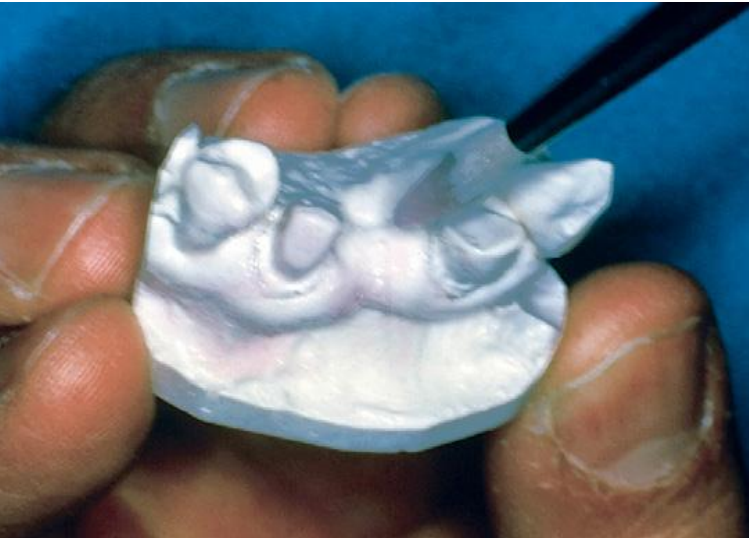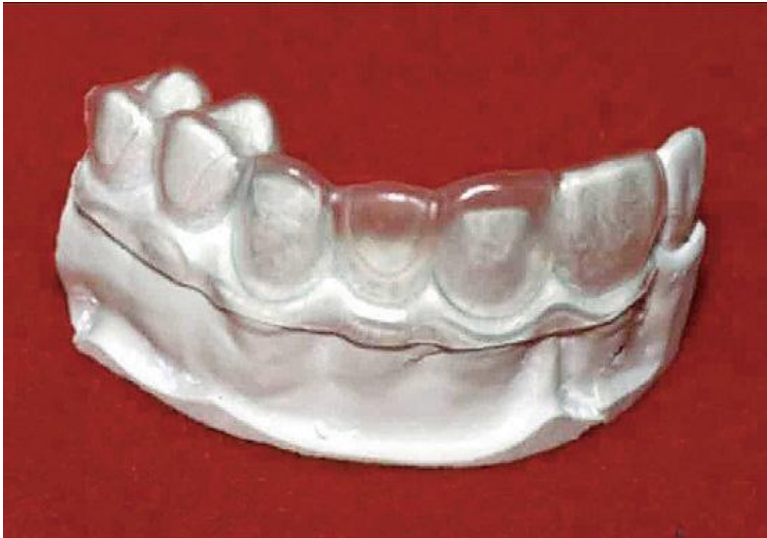Paint the teeth uniformly with separating medium



Fill the silicone key with resin, then place it on the teeth. A small amount of excess resin appears around the entire periphery.

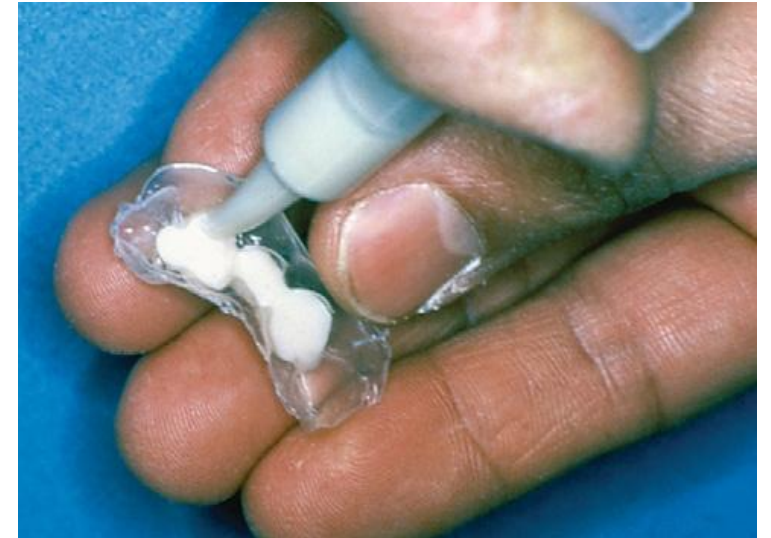

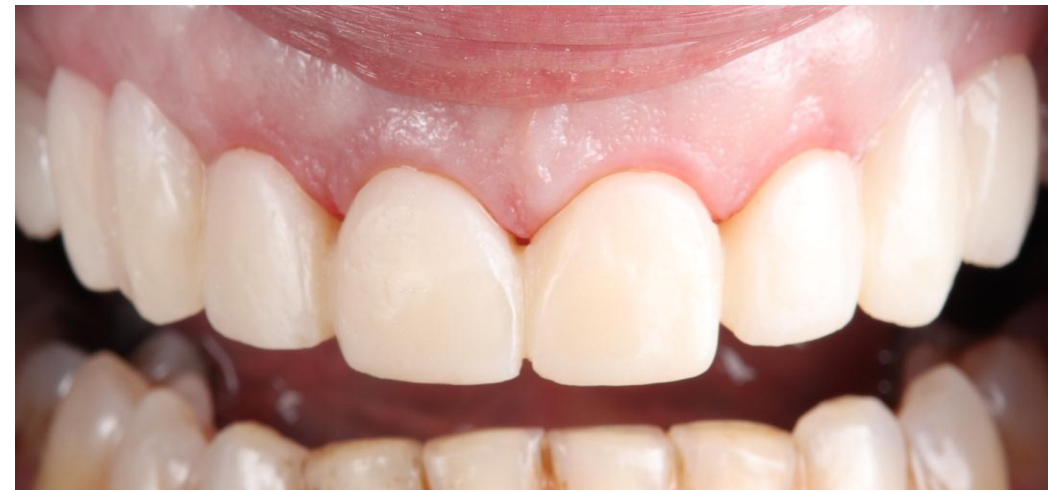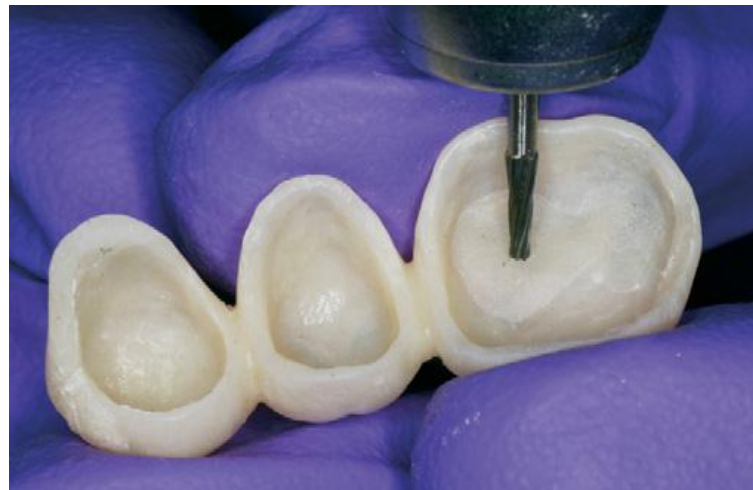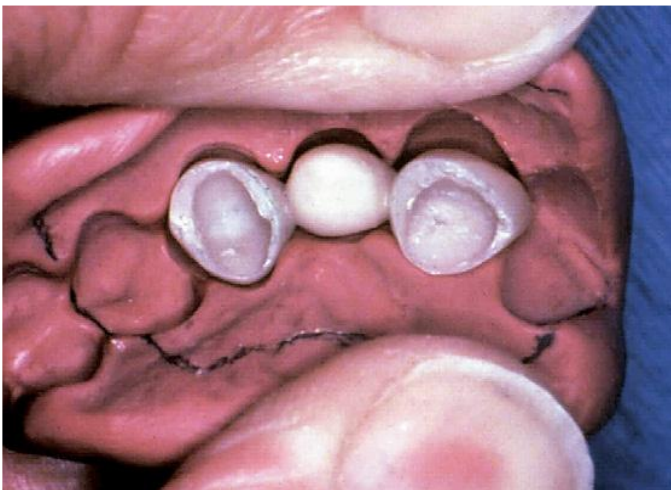
Indirect



Paint the cast uniformly with separating medium

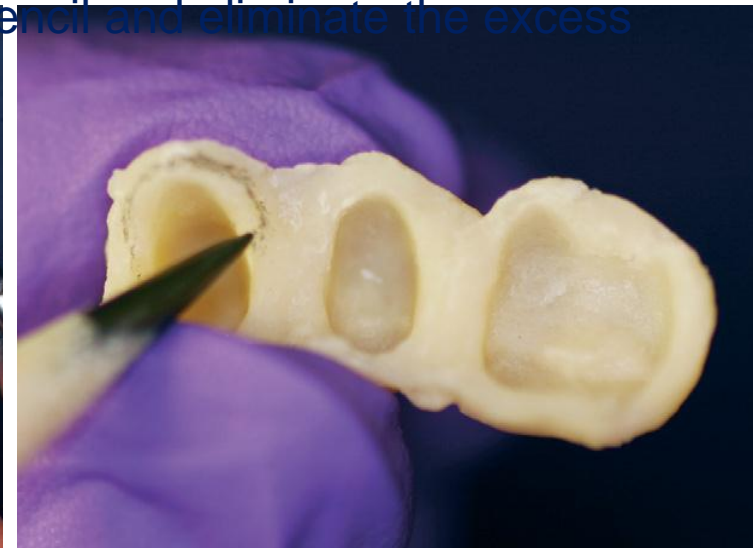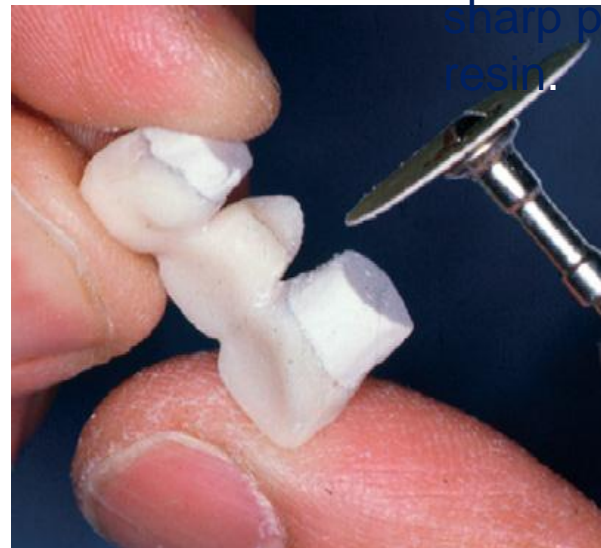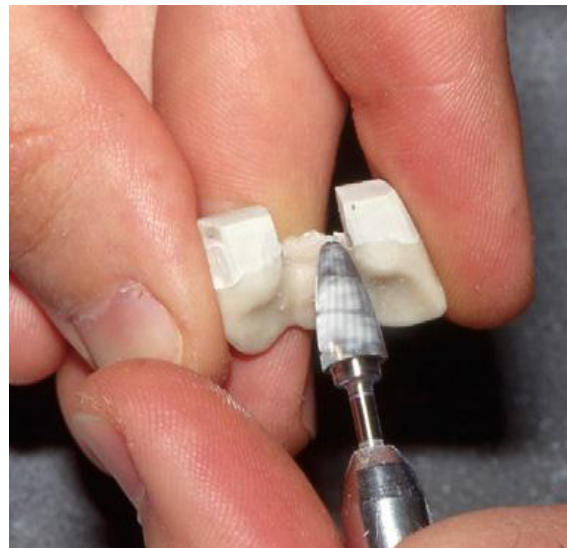
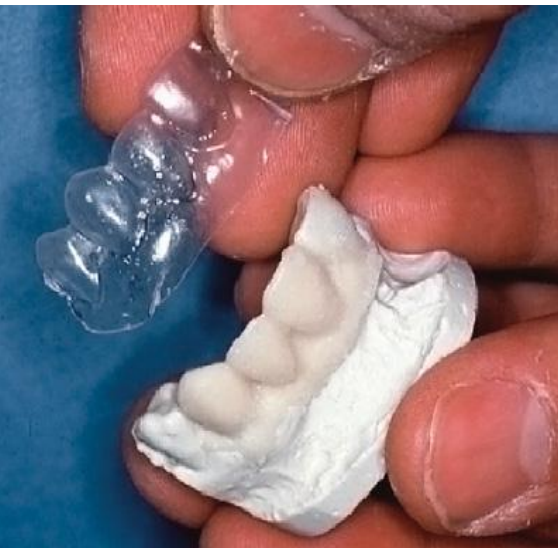Mix auto polymerizing resin and load it into the mold.



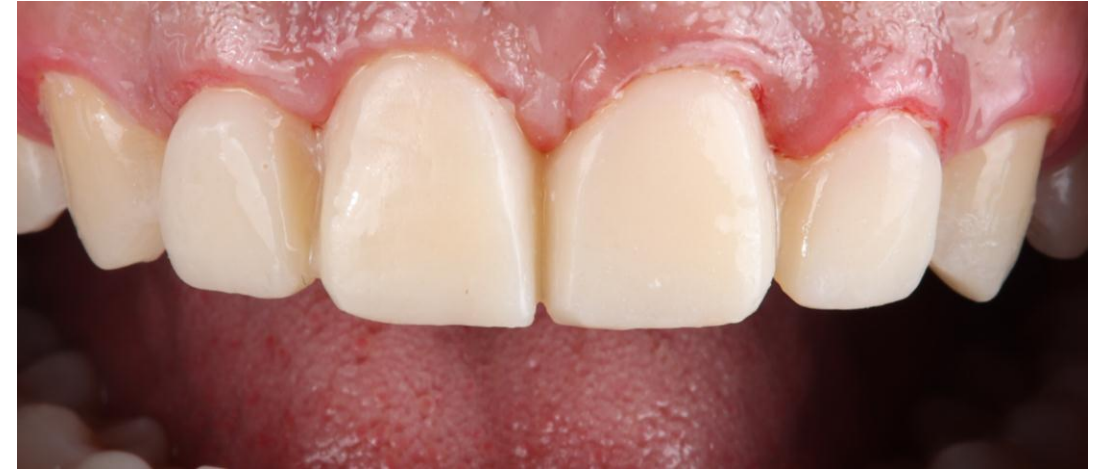

When the partial FDP is loosened at both ends, remove it from the patient's mouth

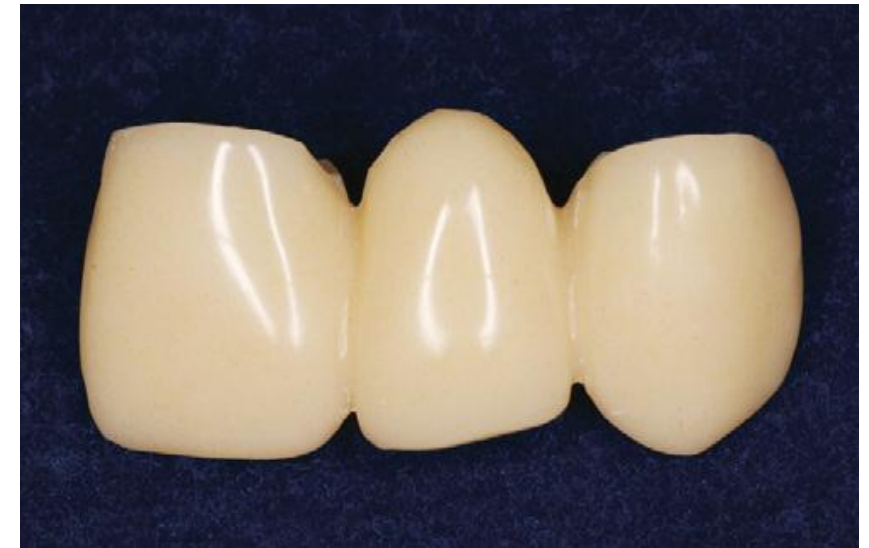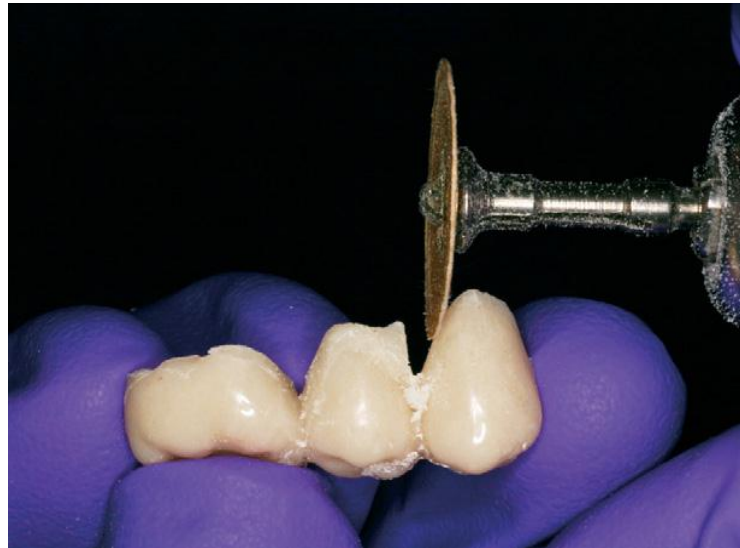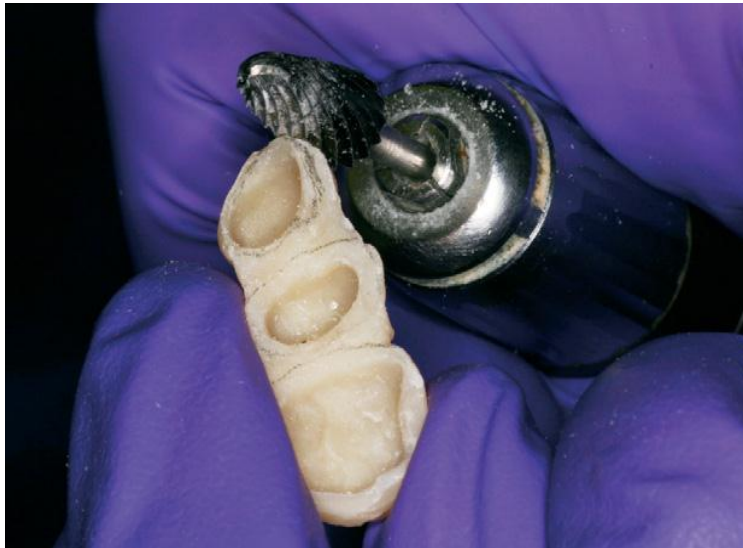After 3 to 5 minutes, mark the margins with a sharp pencil and eliminate the excess resin.



The interim partial FDP should be evaluated in the patient's mouth for proximal contacts, contour, surface defects, marginal fit, and occlusion. Deficient proximal contacts, imperfections in contour, or surface defects can be corrected by adding resin through the bead-brush technique



The final axial contours, connectors, and marginal fit are perfected with an abrasive disk rotating toward the margin to prevent debris from obscuring the pencil line. Accurate trimming to the margins can be simplified by holding the disk parallel to the desired final contour.



Digital work flow

1- Scanning : to start digital work the first step is to make virtual cast either by:

- a. Intra oral scanner : direct scanning of the patient mouth.
- b. Cast scanning: after pouring the impression with stone.

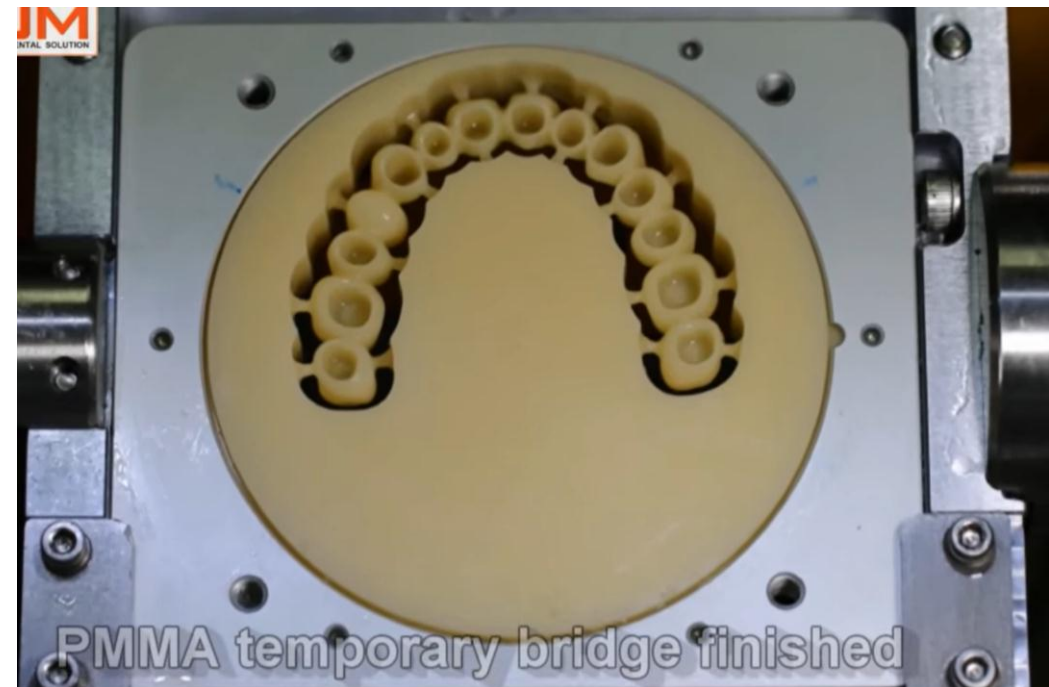
2- Designing: Using the suitable digital dental designing program:

- a. Restoration Material selection
- b. Intended teeth selection
- c. Finishing line determination
- d. Cement gap path of insertion checking
- e. Orientation, proximal and occlusal final size editing.
- f. Export the file to the milling machine or printer .

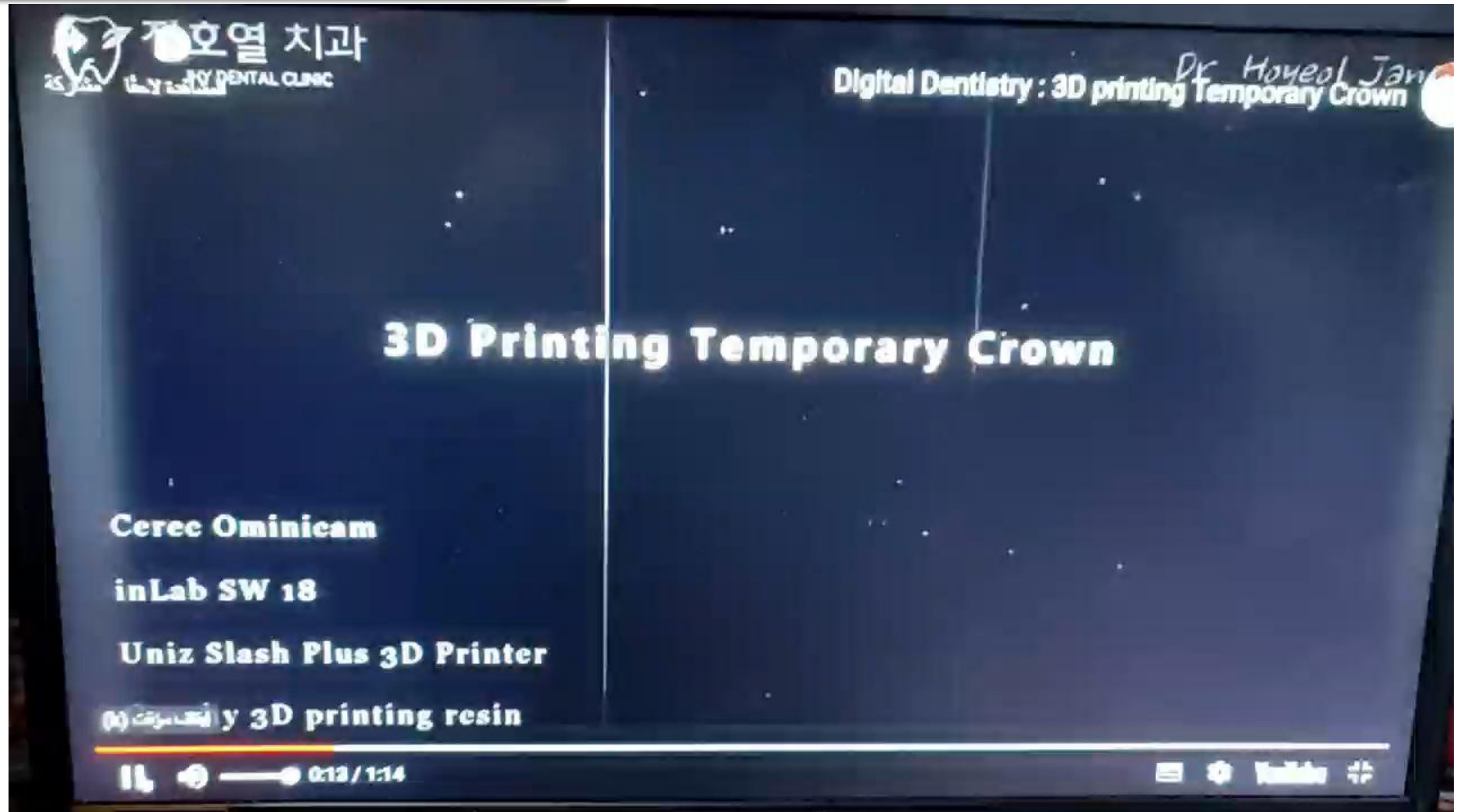
Digital work flow

CAD-CAM PMMA

milling PMMA, disc (Polymethylmethacrylate) are tough, shaded industrial resins that provide multiple options for long or short term temporary restorations. This ultra aesthetic temporary material is available in various shades, giving the restoration the most natural look possible.



3D Printing



T

emporary

C

rown

F

IXE MATERIALS

D

R

estorations

LECTURE 17

Materials for Interim Fixed

Ideal properties

- 1) • **Convenient handling:** adequate working time, easy molding, rapid setting time.
- 2) • **Biocompatibility:** nontoxic, nonallergenic, nonexothermic.
- 3) • **Dimensional stability** during solidification
- 4) • **Ease of contouring and polishing.**
- 5) • **Adequate strength and abrasion resistance.**
- 6) • **Good appearance:** translucent, color controllable, color stable
- 7) • **Good acceptability to patient:** nonirritating, odorless.
- 8) • **Ease of adding to or repairing.**
- 9) • **Chemical compatibility with interim luting agents**

CURRENTLY AVAILABLE MATERIALS

As yet, an ideal interim material has not been developed.

- 1) A major problem still to be solved is dimensional change during solidification. These materials shrink and cause marginal discrepancy, especially when the direct technique is used.
- 2) Also, the resins are exothermic and not entirely biocompatible.

The materials can be divided into four resin groups:

The overall performances of the groups are similar, with no material being superior in all Categories:

1. Poly(methyl methacrylate)
2. Poly(Rø methacrylate)*
3. Micro filled composite
4. Light-cured


Choosing a material should be based on optimally satisfying the requirements or conditions of each case.

For example, materials with the least toxicity and least polymerization shrinkage should be chosen for a **direct technique**.

Alternatively, when a long-span prosthesis is being fabricated, **high strength** is an important selection criterion.

Composition:


The material used for fabrication of an interim restoration consists of *monomers*, *fillers*, *an initiator* and *pigments*, all combining to form an esthetic restorative substance



Polymerization



Shrinkage
Heat generation
Free Monomer



Cementation:

The primary function of the interim luting agent is to

- 1) *Provide a seal*
- 2) *Preventing marginal leakage*
- 3) *Decrease pulp irritation*

Displacement of an interim restoration is frequently caused by a nonretentive tooth preparation or excessive cement space rather than the choice of luting agent.

Available materials

Zinc oxide–eugenol (ZOE) cements appear to be the most satisfactory.

Zinc phosphate, zinc polycarboxylate, and glass ionomer cements are not recommended because their comparatively high strength makes intentional removal difficult.

Using high strength cements frequently damages the restoration

or even the tooth when removal is attempted

Available materials

A good compromise would be reinforced ZOE; another might be eugenol free zinc oxide, which has slightly greater strength than cements containing eugenol


mutual responsibilities

Lecture 18

key of Success

Good communication is the key to the technical success of the dental team. This requires a *close working relationship* between the dentist and laboratory technician. The dentist have to has a reasonable amount of **experience** with, and a thorough **understanding** of, dental laboratory procedures.

guidelines



The Dentist Responsibilities

1. The dentist should provide written instructions to the dental technician. The written instructions should detail the work, describe the materials which are to be used, and be written in a clear and understandable fashion.

SIU
SCHOOL OF DENTAL MEDICINE
DENTAL LABORATORY
WORK AUTHORIZATION
School of Dental Medicine, 2800 College Avenue, Alton, IL 62002-4700

Student _____ Rec. by SDM Lab _____ Units Rec. _____
Patient _____ F. P. Sec. Head _____ Begin _____
Patient # _____ Technician _____
Lab _____ F. P. Sec. Head _____ Complete _____
Received by Student _____

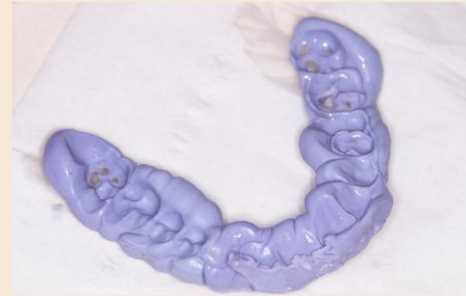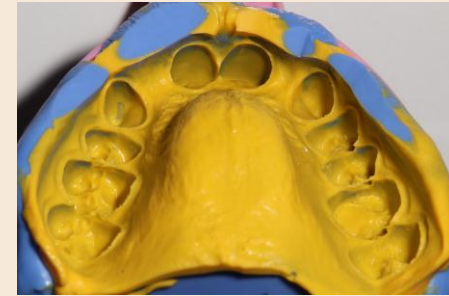
Date _____ Due _____ (Name & Date for each of the above)

SHADE GUIDE
INDICATE CHARACTERIZATIONS
PONTIC DESIGN (circle)
MODIFIED RIDGE LAP CONICAL HYGIENIC

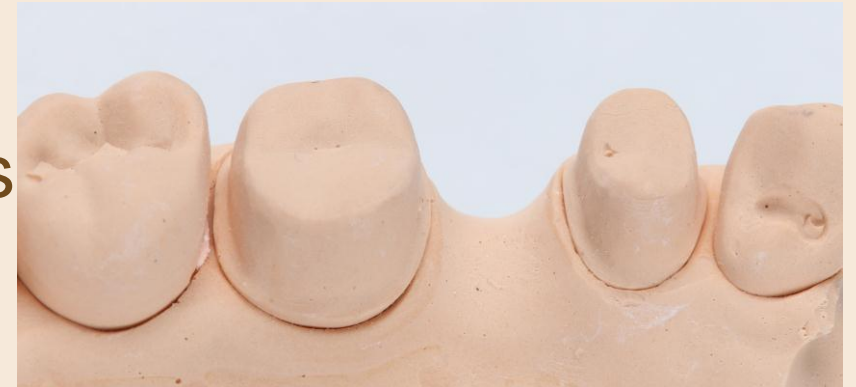MAXILLARY MANDIBULAR

| Porcelain Shades | | | | | | | | | | Articular Number | | |
|------------------|------------|-----|-------|--------|----------|--------------|----------------|-----|-----------|--------------------|---|---|
| Tooth # | Rest. Type | Met | Guide | Instal | Gingival | 0.3 mm metal | Porc. Shoulder | Met | Porcelain | Articular Settings | R | L |
| | | | | | | | | | | Cond. Guid. | | |
| | | | | | | | | | | Inc. Guid. | | |
| | | | | | | | | | | SS | | |
| | | | | | | | | | | PSS | | |

2. The dentist should provide the laboratory technician with accurate impressions, casts, occlusal registrations and/or mounted casts.



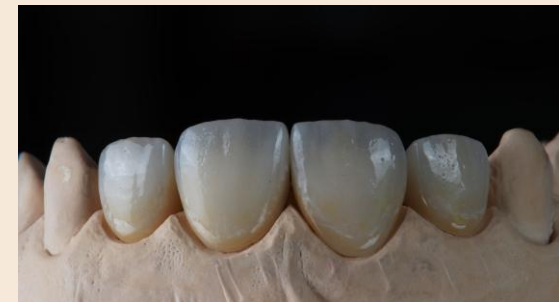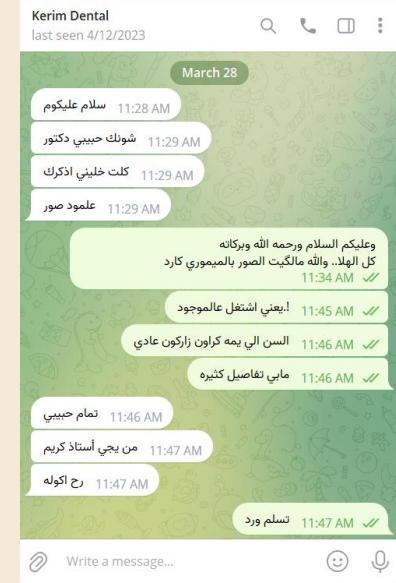3. The dentist should identify, the crown margins post palatal seal, denture borders.



4.The dentist should provide verbal or written approval to proceed with a laboratory procedure, when notified by a laboratory/dental technician that a case may have a questionable area with respect to paragraphs.

5.The dentist should clean and disinfect all items according to current infection control standards. Use a good container and packaged adequately to prevent damage and maintain accuracy.

6.The dentist should return all casts, registration, and prostheses/ appliances to the laboratory/technician if a prosthesis/appliance does not fit properly or if a shade selection is incorrect.



Technician Responsibilities

1. The laboratory technician should manufacture dental prostheses/appliances which follow the guidelines set in the written instructions provided by the dentist and should fit properly on the casts and mounting provided by the dentist.
2. The laboratory should return the case to the dentist to check the mounting if there is any question of its accuracy or of the bite registration furnished by the dentist.
3. The laboratory/technician should notify the dentist within two (2) working days after receipt of the case, if there is a reason for not proceeding with the work. Any changes or additions to the written instructions must be agreed to by the dentist.

4. The laboratory/technician should match the shade which was described in the original written instructions.

5. If written instructions are not accepted, the laboratory/technician should return the work in a timely manner and include a reason for the denial.

6. The laboratory should follow current infection control standards. Should clean and disinfect all incoming items from the dentist's office; e.g., impressions, occlusal registrations, prostheses, etc.

7. The laboratory/technician should not bill the patient directly unless permitted by the applicable law. The laboratory should not discuss any business arrangements between the dentist and the laboratory with the patient.