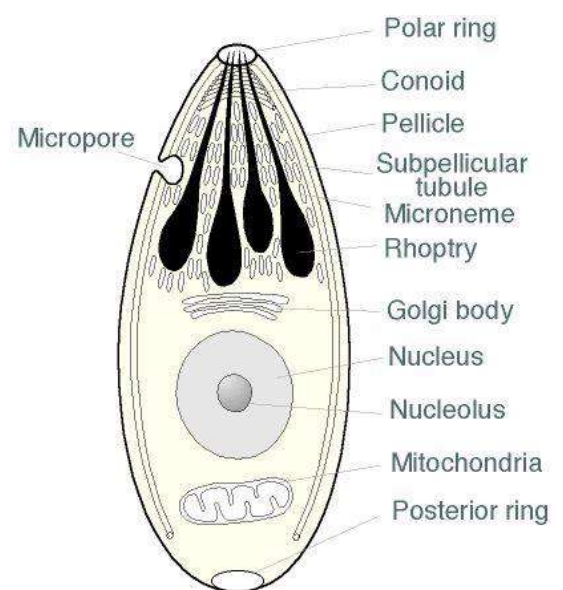


## Phylum Apicomplexa

The **Apicomplexa** (also called Apicomplexia) are a large phylum of parasitic alveolates. Most of them possess a unique form of organelle that comprises a type of plastid called an apicoplast, and an apical complex structure. The organelle is an adaptation that the **apicomplexan** applies in penetration of a host cell.

### APICAL COMPLEX

- **Micronemes.**
- **Rhoptries.**
- **Polar rings.**

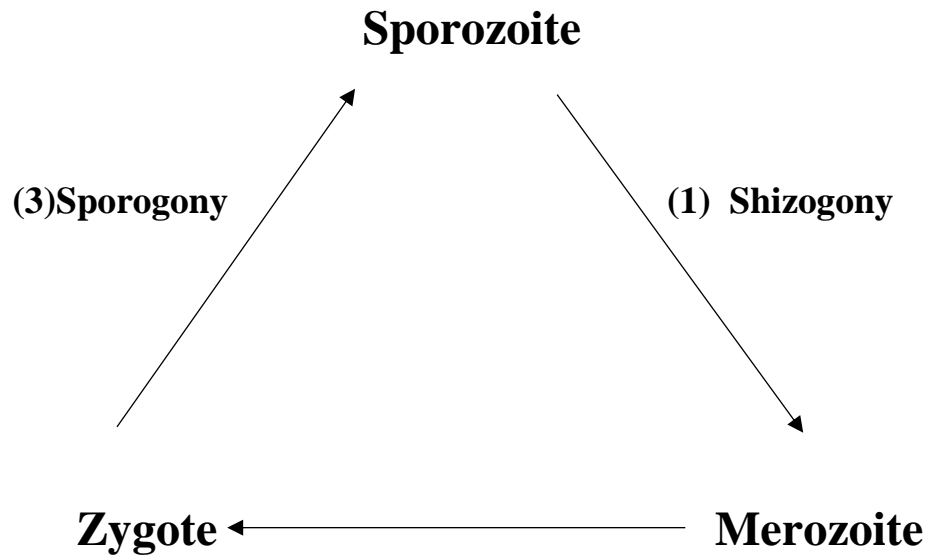


### Generalized Apicomplexan Life Cycle

Apicomplexan life cycles include both sexual and asexual development.

- **Merogony ( Schizogony):** production of **merozoites**.
- **Gametogony:** formation of gametes.
- **Sporogony:** the product of a large number of **sporozoites**.

**The meront, gamont and sporont multiply asexually by schizogony.**



**Apicomplexa:** Divided into two classes:

**1- Coccidia:** Intestinal Apicomplexa.

**2- Haemosporidia:** Blood Apicomplexa.

**1- Class: Coccidia:** Intestinal Apicomplexa

*Isospora belli*

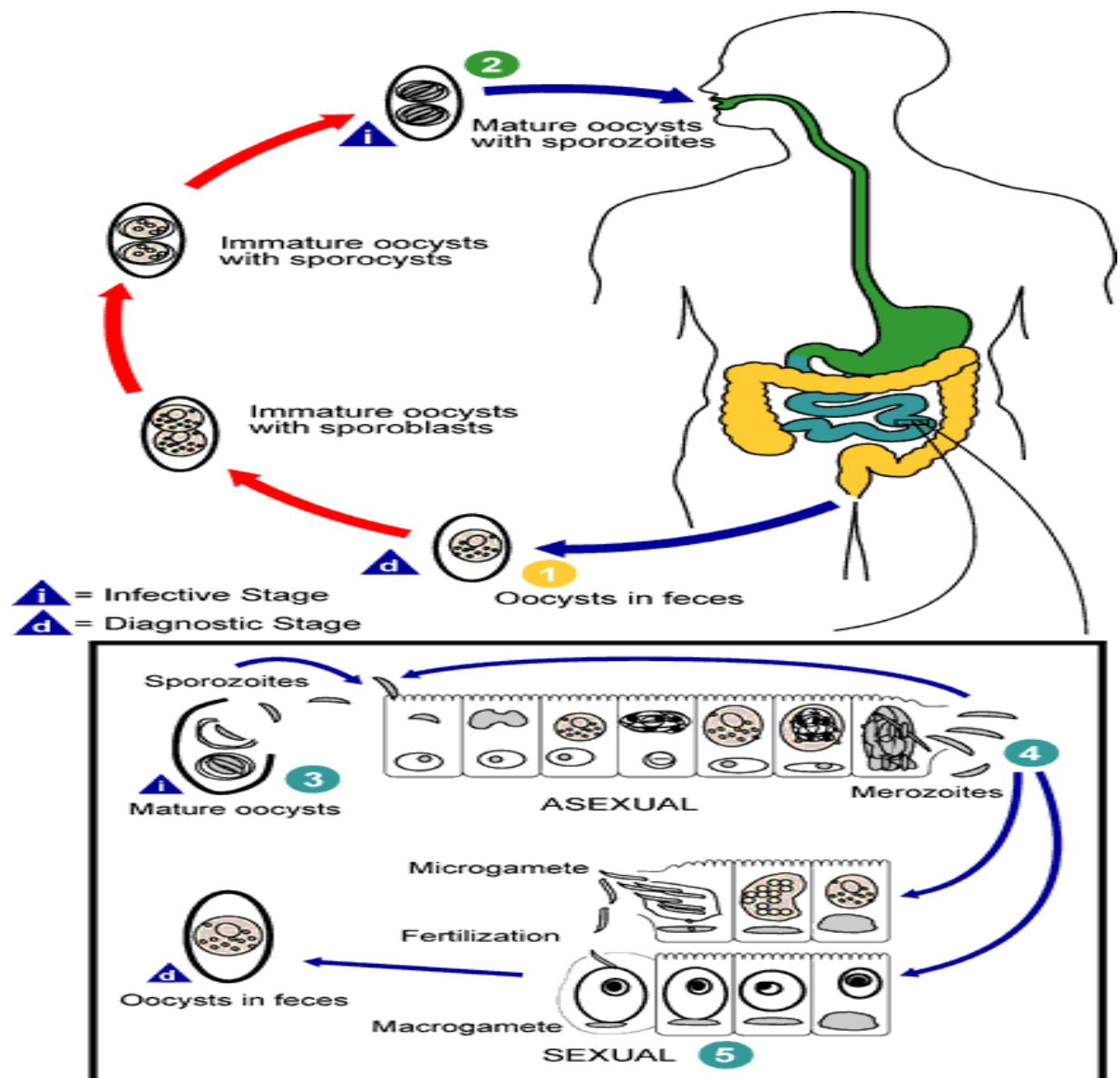
**Disease: Isosporiasis, intestinal coccidiosis**

- Worldwide geographical distribution.
- Usually produces a self-limiting diarrhea in **immunocompetent** people (**can be asymptomatic**).
- Only a few hundred cases described before being recognized as an **opportunistic infection** in **immunocompromised**.

- **Habitat:** the parasite inhabit the intestinal tract, but the exact site is in doubt, probably the ileum and cecum. Its oocyst have been obtained by intubation tubes from the terminal portion of jejunum, and from duodenum

## Life Cycle

Each mature **sporocyst** contain four **sporozoites** and a residual mass of cytoplasm. The life cycle is complete in human volunteers in 9 ~ 16 days.



## Pathogenesis and Symptoms

The incubation period: 3-14 days.

- Profuse, watery, non-bloody, offensive smelling diarrhea, which may contain mucus.
- Cramping abdominal pain, vomiting.
- Malaise, anorexia, weight loss.
- Low-grade fever.
- Steatorrhea in protracted cases.

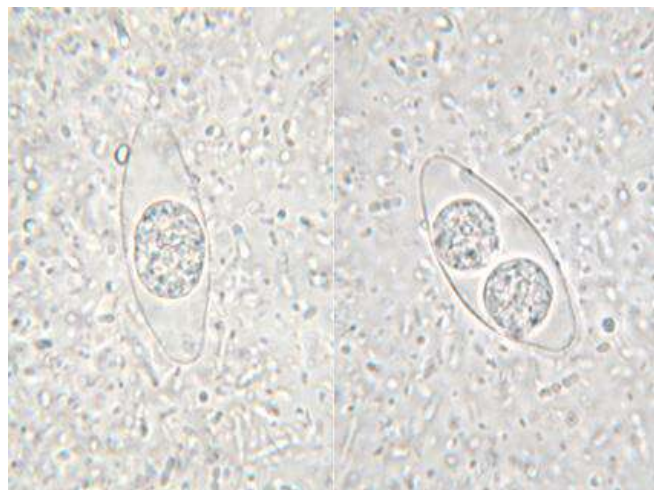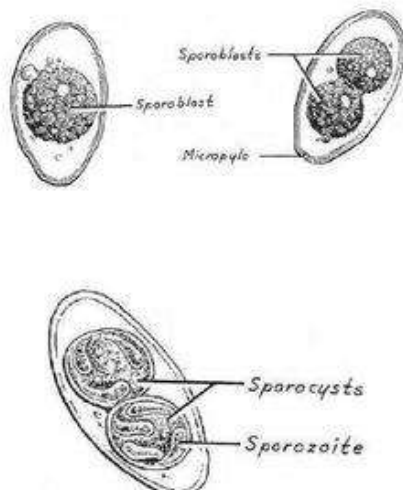
*Isospora* infection is endemic in tropical regions, particularly of Central and South America, Africa, and Southeast Asia.

One study found positive examination findings in up to 15% of Haitians infected with **AIDS**.

In developing countries, 8-40% of patients with **AIDS** are infected.

## Diagnosis:

*Isospora belli* is diagnosed by detection of the **oocysts** in stool or rarely bile samples. Universal precautions should be followed when handling fresh stool samples. **Oocysts** can be observed in **wet preparations, iodine stained** preparations or **acid-fast** stained smears of concentrated stool specimens.



**Genus: *Sarcocystis spp.*,**

**Disease: Sarcocystosis**

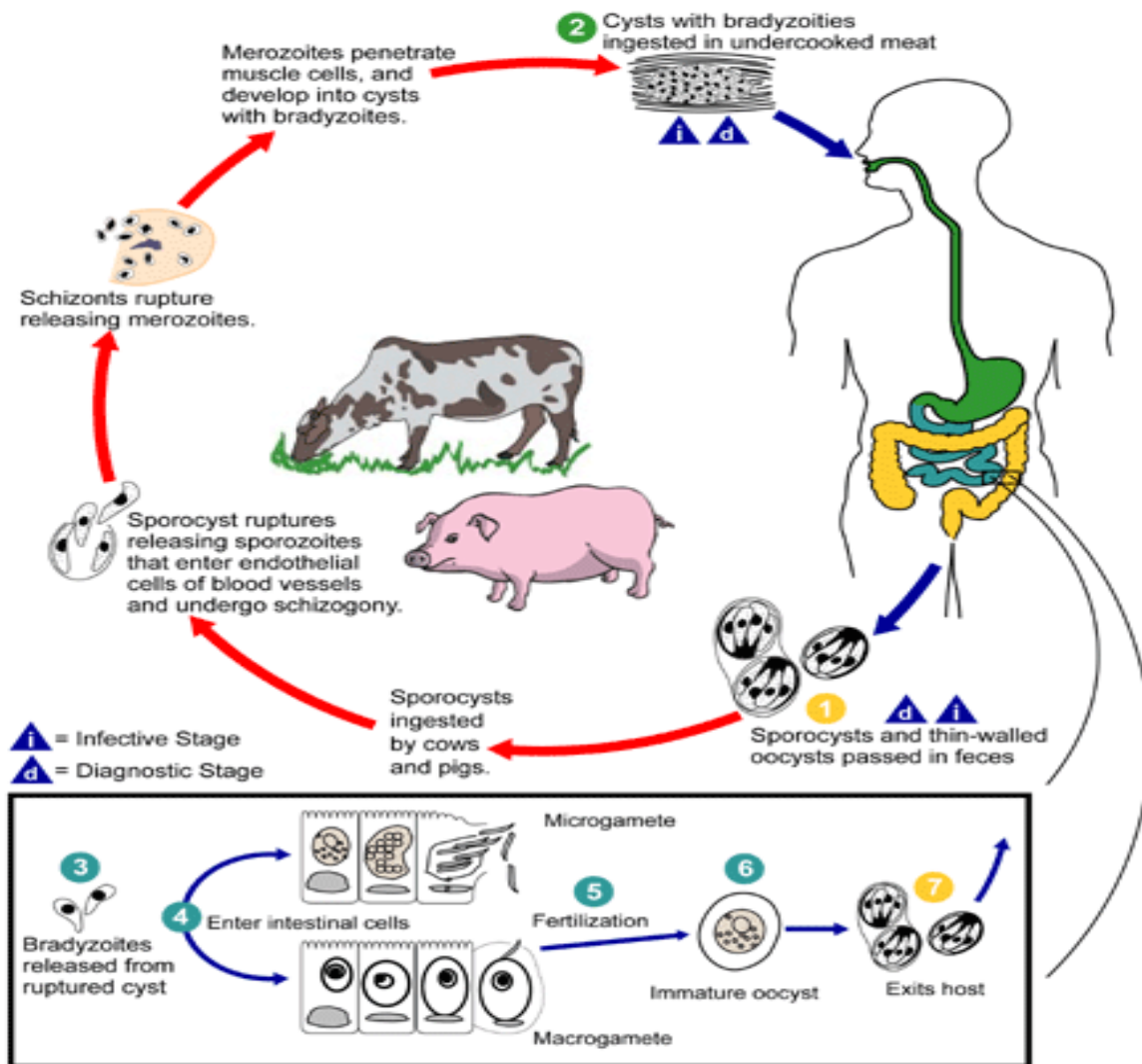
*Sarcocystis hominis* and *S. suis* use humans as definitive hosts and are responsible for intestinal **sarcocystosis** in the human host. Humans may also become dead-end hosts for non-human *Sarcocystis spp.* after the accidental ingestion of oocysts.

### Life Cycle

Both sporulated **oocysts** (containing **two sporocysts**) and **individual sporocysts** can be passed in stool, due to the **fragile nature** of the **oocyst wall**.

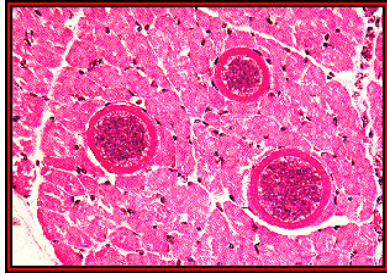
1. **Sporocysts** contain **four sporozoites** and a refractile residual body. **Sporocysts** ingested by the intermediate host (**cattle** for *S. hominis* and **pigs** for *S. suis*) rupture, releasing **sporozoites**. **Sporozoites** enter **endothelial cells of blood vessels** and undergo **schizogony**, resulting in **first-generation schizonts**. **Merozoites** derived from the **first-generation** invade small capillaries and blood vessels, becoming **second-generation schizonts**. The **second generation merozoites** invade **muscle cells** and develop into **sarcocysts** containing **bradyzoites**, which are the **infective stage** for the **definitive host**.
2. Humans become infected when they eat undercooked meat containing these **sarcocysts**. **Bradyzoites** are released from ruptured cysts in the small intestine.
3. Which invade the **lamina propria** of the intestinal epithelium.
4. There, they **differentiate** into **macro-** and **microgametocytes**.
5. Fusion of **male** and **female gametes**, results in the formation of **oocysts**.

6. **Oocysts** sporulate in the intestinal epithelium and are shed from the host in feces.



### Pathology:

Infection usually is asymptomatic, but occasional patients have transient diarrhea, abdominal pain, or anorexia. Intestinal infection is self-limited because asexual multiplication occurs in the intermediate host and is not repeated in the definitive host.



**Slide:** *Sarcocystis* tissue section. This image shows a cross section of a tongue showing three sarcocysts.

## Laboratory Diagnosis

For intestinal **sarcocystosis** caused by *S. hominis* and *S. suihominis*, diagnosis is made by the observation of **oocysts** or **sporocysts** in stool. They are easily overlooked as they are often shed in small numbers. Also, the two species cannot be separated by **oocyst** or **sporocyst** morphology. When humans serve as dead-end hosts for non-human *Sarcocystis spp.*, diagnosis is made by the finding of **sarcocysts** in tissue specimens.

# *Toxoplasma gondii*

**Diseases:** Toxoplasmosis, subacute encephalomyelitis and chorioretinitis

- **Definitive host:** Cat family
- **Intermediate host:** Mouse, Sheep, Goats, swine and Human.

## Life cycle:

**Different forms of *Toxoplasma*:**

1. **Tachyzoites (Trophozoites)**
2. **Bradyzoites (in Tissue cyst)**
3. **Oocyst (resistant form in cat feces via sexual reproduction)**



## Parasites in definitive host (Cat):

### 1. Intra intestinal stage (Cat):

@ **Cat** ingests **mouse** with tissue **cysts**: releasing **bradyzoites** in small intestine:

### Penetration to epithelial cells:

I) **Asexual** reproduction (Schizogony = Schizonts) = Tachyzoites

II) **Sexual** reproduction: (**Male Female**) gametes= **zygote** with **two** walls  
**oocyst**: **Excrete** in **feces**.

Any **cat**, no matter how well fed, may be passing oocysts of **T. gondii**, for only a few days ( 1-3 weeks) after infection, as a result of development of immunity to new infection.

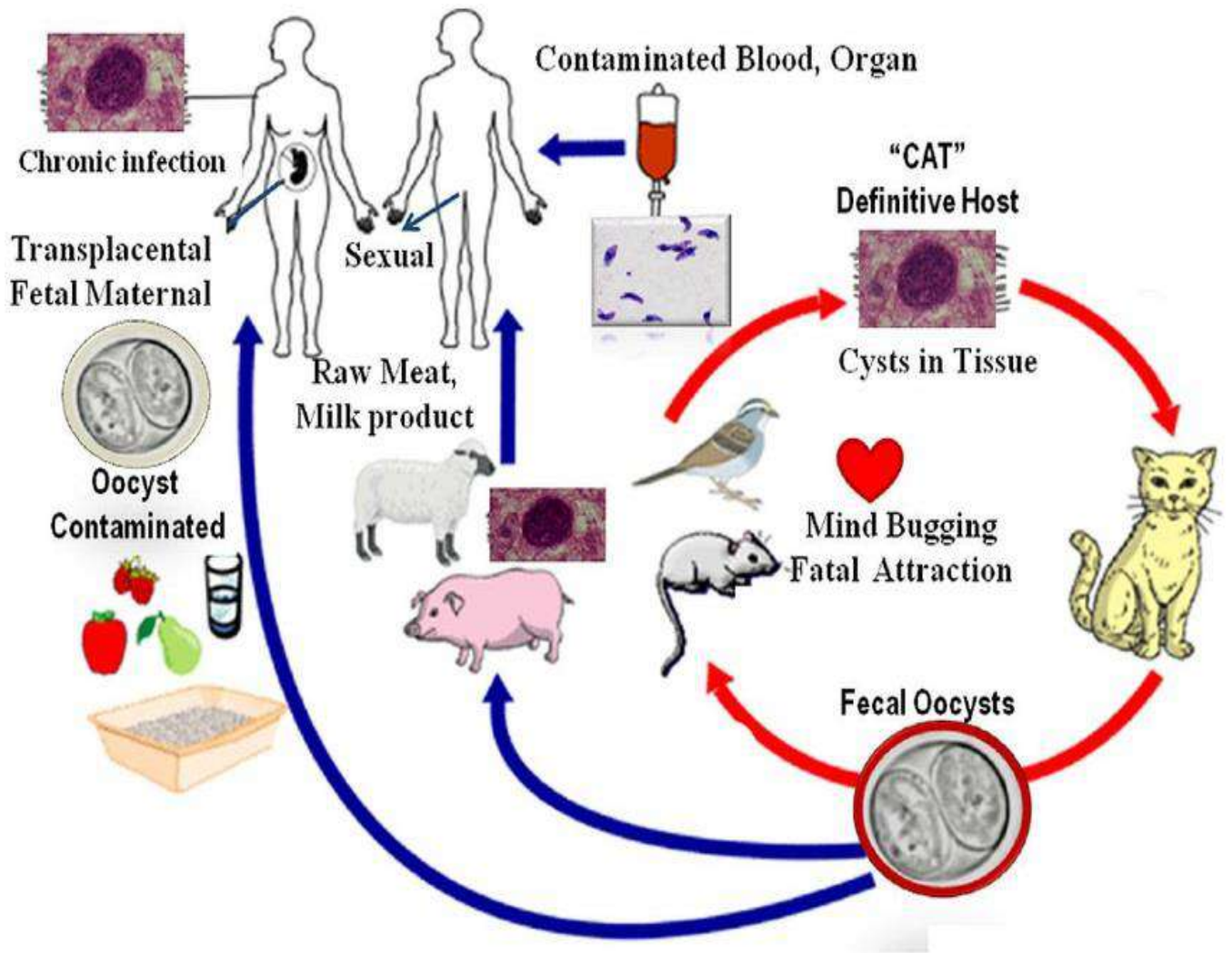
III) **Sporulation** outside the **cat body** maturation after 1-5 days, similar appearance to **Isospora** remain infectious in soil for **months**.

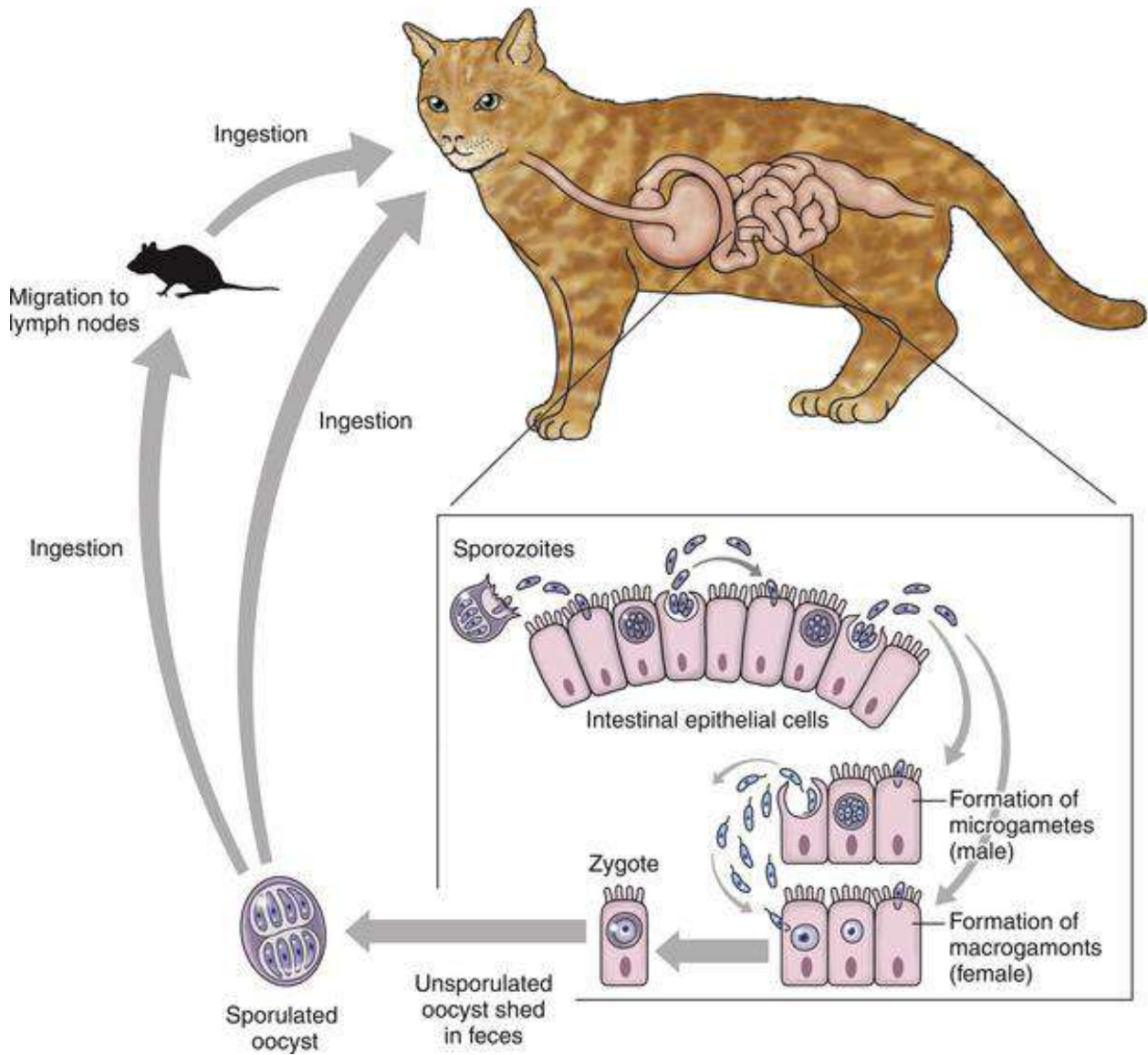
### 2. Extra intestinal stage (Cat):

•**Cat** ingests (**mouse**) or herbivores with tissue **cysts**: releasing **bradyzoites** in small intestine:

- Penetration to lamina propria:
- Asexual reproduction= **Tachyzoites**.
- Transfer by lymph & blood.
- Enter any types of cat cells.
- Multiplication.
- Host cells filled by **tachyzoites** & die.
- Tachyzoites** released & enter new cells.
- Tissue necrosis.
- Cat immunity** overcome this stage.
- Changing to **bradyzoites** in **cysts** in different tissues.







### Human infection by *Toxoplasma gondii*:

#### Only Extra intestinal stage (all intermediate hosts)

1. Tissue **cyst** ingestion in herbivores: **Bradyzoites**.
2. **Oocyst** ingestion via food contaminated with **cat** feces: **Sporozoites**  
Tissue necrosis by intracellular multiplication of **Tachyzoites**.
3. Congenital **toxoplasmosis**: **Tachyzoites**

### Humans may be infected *Toxoplasma gondii* by:

- Eating undercooked meat of animals harboring tissue cysts.
- Consuming food or water contaminated with **cat** feces or by contaminated environmental samples (such as fecal-contaminated soil or changing the litter box of a pet **cat**)
- Blood transfusion or organ transplantation.
- Transplacentally from mother to fetus.

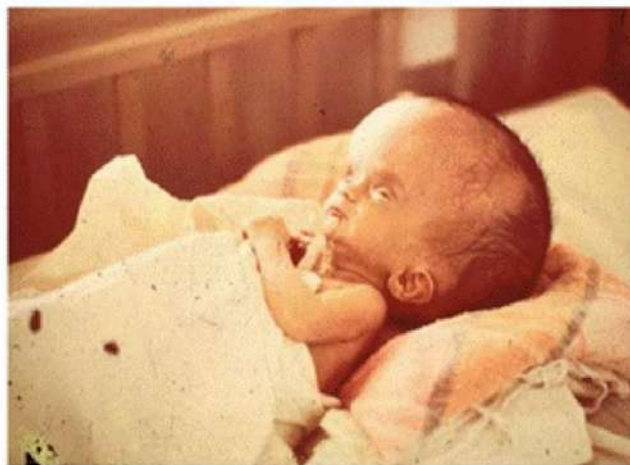### Pathology:

Infections in the **first trimester** and early **second trimester** may lead to **spontaneous abortion, stillbirth** or **severe neonatal disease**. The most severely affected organ is the brain, where focal necrosis and perivascular mononuclear inflammation is seen, with intracellular and extracellular **tachyzoites** and early cysts. Resolving lesions may show **microglial** nodules and **calcification**.

Ocular disease (posterior chamber) sometimes-entire eye

- Proliferation in retina
- Inflammation of chorioretinitis.
- Lesions yellow, white, Cotton like patches.

### Congenital toxoplasmosis



**Clinical manifestations.** Hydrocephalus, lesions in the organs of the vision (chorioretinitis), cirrhosis of the liver and enlargement of the spleen.

## Epidemiology:

- Worldwide spread (0.5 billion of human have antibody to **T.gondii**)

Oocysts, which are shed in feces of recently infected cats, are resistant to desiccation and heat. Oocysts are less dense than water and remain in the upper soil horizon, where they may contaminate skin and may be ingested, either directly by hand-to-mouth transmission or on raw vegetables. Oocysts require exposure to air, after cat feces are deposited in soil, for at least 12 hours but up to several days in order to complete sporulation, after which they are infectious by mouth. This information is useful in the management of cat litter boxes, which have a lower chance of harboring infectious oocysts if the feces are removed daily.

## Diagnosis:

### I. Serologic examination:

#### Sabin-Feldman test:

**Tachyzoites** (Ag): dilutions of test serum (sensitive, high cost)

Titration:

[Human serum – Antibody – (**live** virulent *Toxoplasma*)]

If: Ab (**high**) > *Toxoplasma* (to be **killed**) > not stainable in **blue field**

If: Ab (**low**) > *Toxoplasma* (**Alive**) > highly stainable in blue field

#### Indirect fluorescent antibody test (IFAT):

Titration

A) [Human serum – Antibody – (**Killed** *Toxoplasma*)] commercially available

**Microscopic observation** by **UV light**

B) Finding **Ab** in undiluted serum > indicates ocular **Toxoplasmosis**

## Histocytologic examination:

**Host tissue biopsy > impression smears of lesions**

- on glass slides : 10-30 min smear fixed in methyl alcohol & stained with **Geimssa**

In this section > **Tachyzoites** > oval to round

**Cysts** > spherical > silver positive walls

**Bradyzoites** > stain strongly with Acid Schiff stain

**Electron microscopy**

### **Treatment:**

- Sulfonamides & Prymethamine) synergistically blocking metabolic pathways involving para amino benzoic acid and folic acid cycle.
- During drug using > Thrombocytopenia & Leukopenia.
- Sulfonamides for acute stage of disease.
- Spiramycin used for pregnant women.
- No vaccine

### **Control:**

1. Meat > cooked (66°C) before eating
2. Hands, after handling meat > washing with soap & water
3. **Cats** feeding > not raw meat (canned food & cooked meat)
4. Keeping **cats** > Indoors, litter boxes change daily
5. **Cat** feces > flushed down to toilet or burned
6. Garden working > with gloves

### **Order: Adeleida**

#### ***Cryptosporidium parvum***

#### **Disease: Cryptosporidiosis**

***Cryptosporidium parvum*** is a protozoan and an obligate intracellular parasite (a parasite that cannot survive without a host) that commonly causes an **opportunistic infection** in **immunocompromised** hosts. *C. parvum* is considered the most important **waterborne** pathogen in **developed countries**. Both the disease and the parasite are commonly known as "Crypto".

### **Morphology**

*Cryptosporidium* is a genus of apicomplexan parasites that infect a wide range of vertebrates (humans included). Typically, the parasite infects the microvillus border of the gastrointestinal epithelium causing persistent diarrhea (Cryptosporidiosis). However, among immunosuppressed



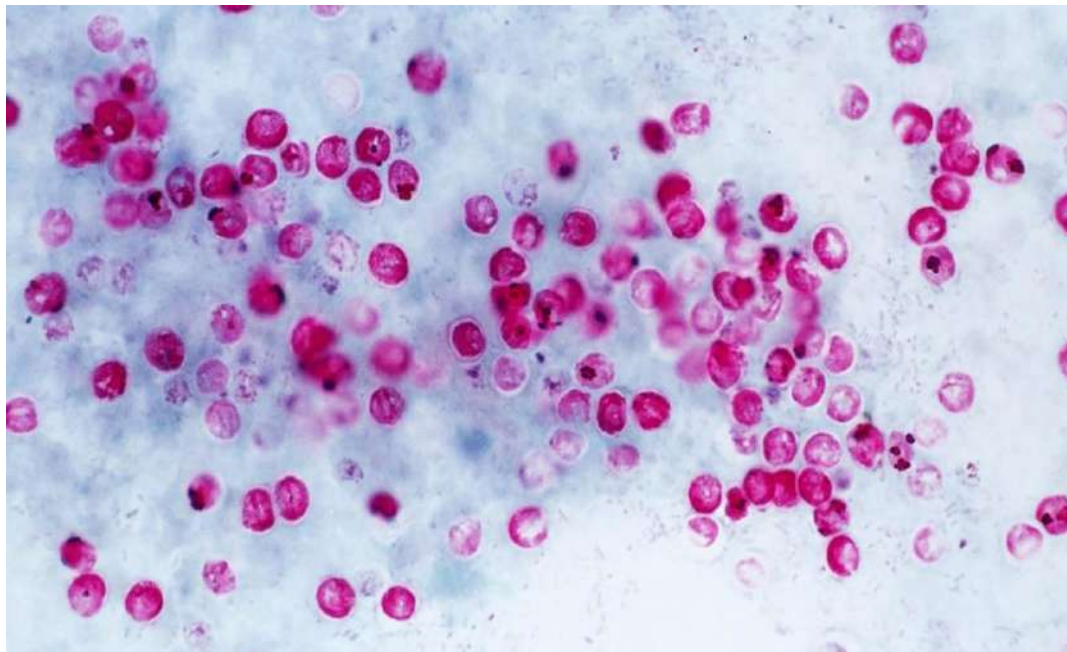
individuals, the infection may spread to other parts of the body (e.g. respiratory tract, pancreatic duct, stomach).

While the infection is asymptomatic in many animals (which then act as reservoirs), it can be life threatening among children, the malnourished and those with a weakened immune system. The parasites form three developmental stages: **meronts**, **gamonts** and **oocysts**. Endogenous developmental stages appear as small basophilic bodies (3-6µm) attached to the **luminal surface** of host epithelial cells (**it infects the apex of the epithelial cells, beneath the cell membrane but outside the cytoplasm**) while **exogenous oocysts** appear as ovoid phase-bright ovoid bodies (5-7 x 4-6µm) containing four sporozoites and an eccentric residual body.

**Mer'ont**: A stage in the life cycle of sporozoans in which multiple **asexual fission (schizogony)** occurs, resulting in production of **8 merozoites**.

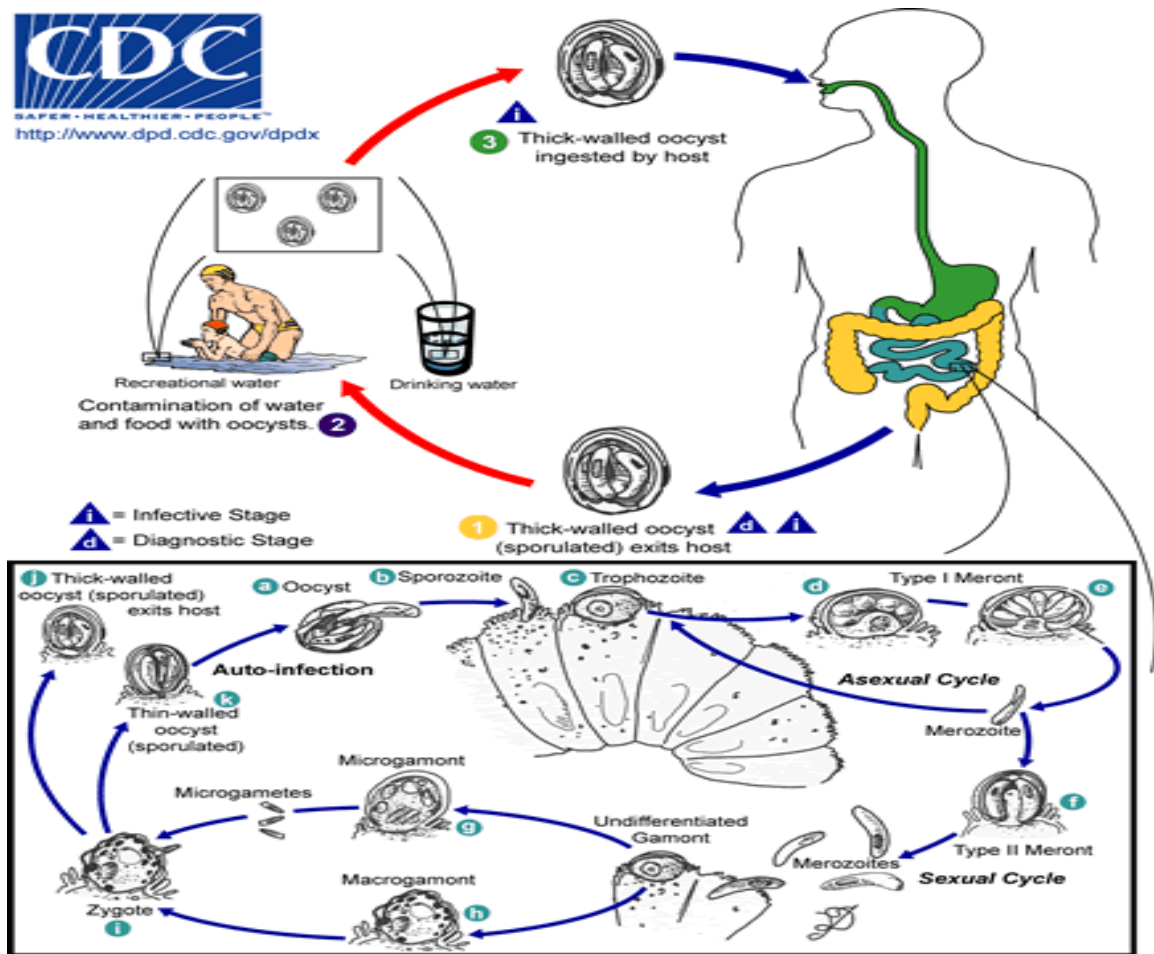
### Oocysts

- Size: **4-6** µm.
- Morphology: round, oval.
- They are mainly located in the jejunum.
- Without **sporocyst**, contain only **4 sporozoites**.



**Oocysts of *C. parvum***

## Life Cycle



- Crypto begins its life cycle as sporulated **oocysts** (1) which enter the environment through the feces of the infected host.
- The infective **oocysts** reside in food and water (2).
- Infection occurs when the **oocysts** are ingested by a suitable host (3).

## Mode of transmission

- ❖ Swallowing pool water that has been contaminated with the parasite.
- ❖ In contaminated food or drink (called heteroinfection).
- ❖ By **faeco-oral route** (hand to mouth) in already infected patient (called external autoinfection).



## Pathogenesis

- Increased intestinal secretion of sodium and chloride, water absorption is inhibited.
- Epithelial cells damaged by:
  - Parasite invasion and multiplication.
  - May produce up to 10-20 liters of watery stools per day.
  - Bowel movement ranges from 6-25 per day.

## Diagnosis & Detection

Diagnosis of **cryptosporidiosis** is made by examination of stool samples. Because detection of *Cryptosporidium* can be difficult, patients may be asked to submit several stool samples over several days. Most often, stool specimens are examined **microscopically** using different techniques (e.g., **Kinyoum acid-fast staining, Direct Fluorescent Antibody [DFA], and/or enzyme immunoassays for detection of *Cryptosporidium* sp. antigens**).

**Molecular methods (e.g., Polymerase Chain Reaction – PCR) are increasingly used in reference diagnostic labs, since they can be used to identify *Cryptosporidium* at the species level.**

## Order: Haemosporidia

### Genus: *Plasmodium*

**Malaria**, a disease that infects 300 million people throughout the world and kills more than a million people, mostly children in sub-Saharan Africa. The word **malaria** literally means “**bad air**” reflecting the ancient belief that the disease was contracted by breathing bad air (**swamp gas**), another name for the disease, **paludism** (marsh disease). **Mimiking** a viral **syndrome**.

Human malarial parasites belong to the **following four species**:

- ***Plasmodium vivax***: cause **benign tertian malaria**.
- ***P. falciparum***: cause **malignant tertian, sub-tertian malaria; estivo-autumnal malaria**.
- ***P. malariae***: cause **quartan malaria**.
- ***P. ovale***: cause **ovale benign tertian malaria**.

### Epidemiology:

Malaria is distributed worldwide throughout the tropics and subtropics.

### Sporozoan parasites of blood has 2 Hosts:

- I. **Mosquito (Sexual reproduction stage) = gametogenesis (final host)**
- II. **Human (Asexual reproduction stage)=Schisogony (intermediate host)**

## Life cycles:

### I. Human stage:

#### 1. Exoerythrocytic cycle (Preerythrocytic cycle= liver phase)

- Infected *Anopheles* biting human > sporozoites > circulatory system > liver paranchymal cells > Asexual **reproduction: Schizogony**.

**Note:** *P.vivax* & *p.ovale* > dormant hepatic phase > sporozoites change to sleeping forms or **Hypnozoites** without dividing, after months to years > Relapsing Malaria.

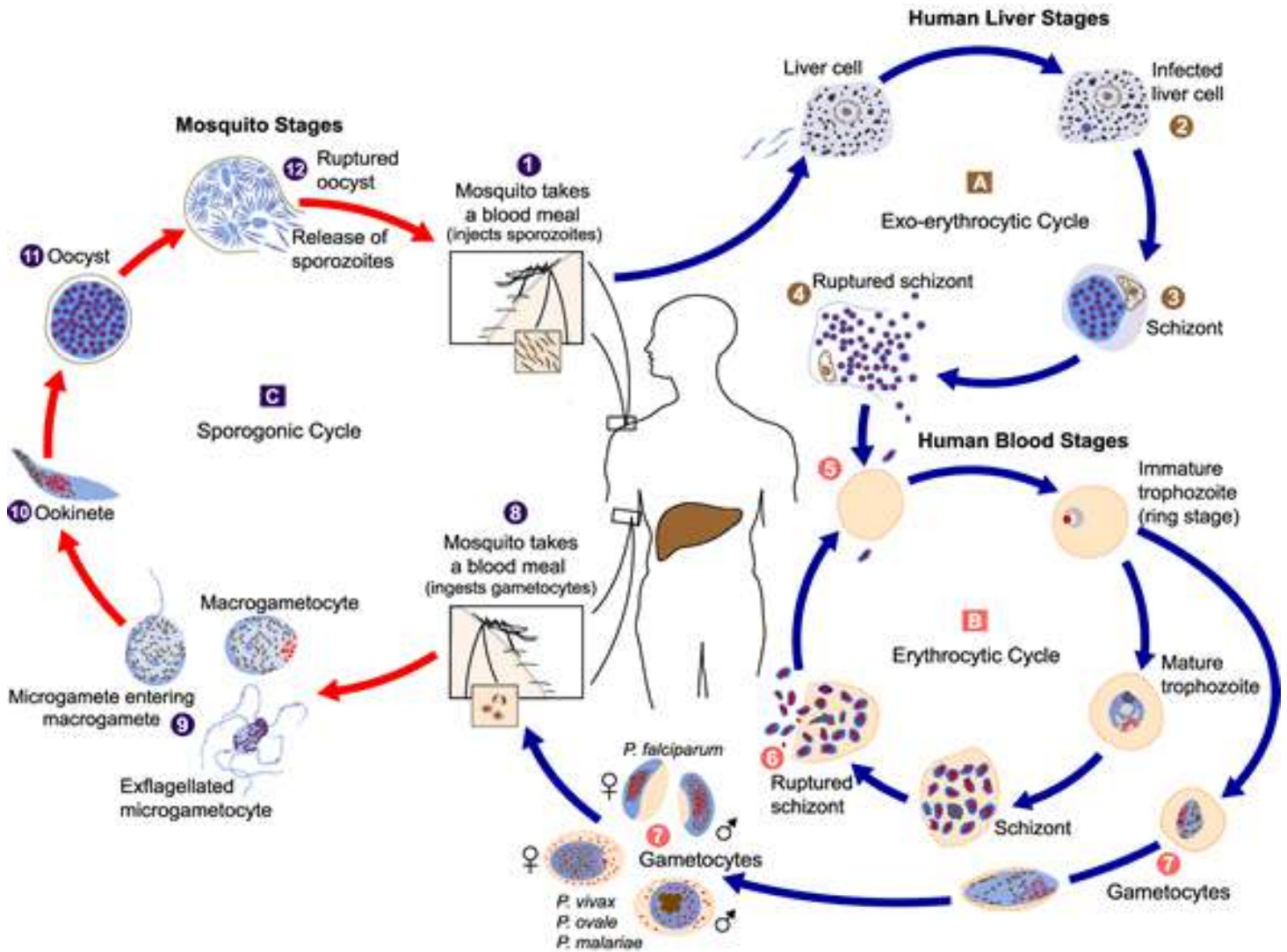
• **Hepatocytes** > Schizonts rupture liberating 2000 to 40000 merozoites > attach to receptors of **RBC**. *P. vivax* and *P.ovale* have more than one cycle in the liver cells, while *P. malariae* and *P. falciparum* have only one cycle in the liver cells.

### 2. Erythrocytic cycle:

- **Asexual reproduction** > series stages > (ring stages: trophozoites > amoeboid stages > schizonts growth dividing > merozoites **RBC** rupture) > initiate another **EC**.

The **Erythrocytic merozoites** never re-invade the liver cells. Therefore, malaria transmitted by **blood transfusion** reproduces only **erythrocytic cycle**.

- Some merozoites in **RBC** > **male & female gametes** in blood of human.



1. *Anopheles* intestine lumen: Gametogenesis occurs within 10–15 min

I. **Male Microgametocyte** → dividing 3 times → **6 – 8** nuclei >

Several flagellated Microgametes (**Exflagellation**)

II. **Female Macrogamete** → without division → **Macrogamete**

I + II → **flagelated Microgamete + Macrogamete** → **zygote**.

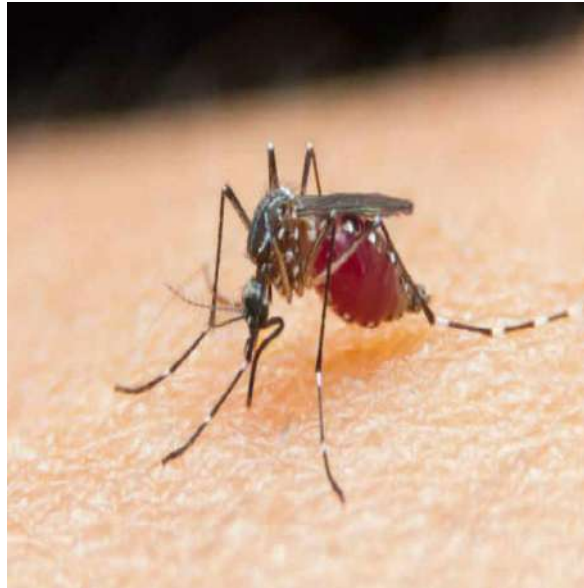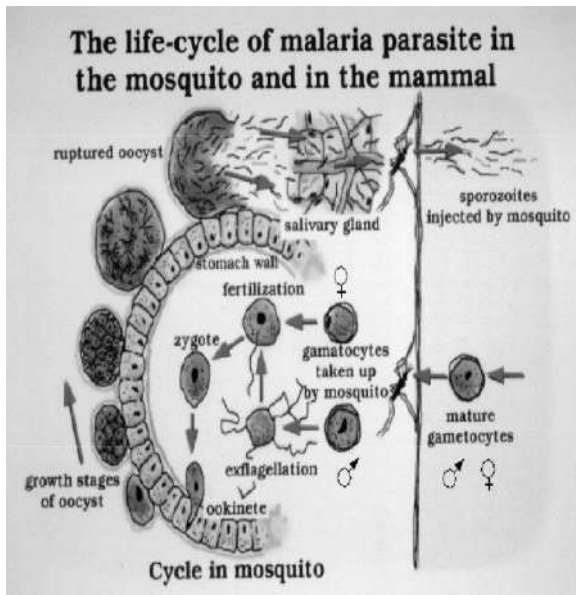
Remaining inside intestine **12 – 24** hrs.

2. *Anopheles* intestine cells:

- **Ookinete** (motile) > **oocyst** containing **sporozoites**. The sporozoites are not enclosed within sporocysts.

3. **Anopheles** body cavity:

- Releasing **sporozoites** → migration to **salivary glands**
- Pathway in **Anopheles**: **10 – 17** days



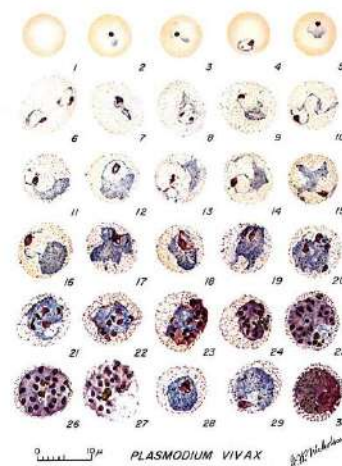
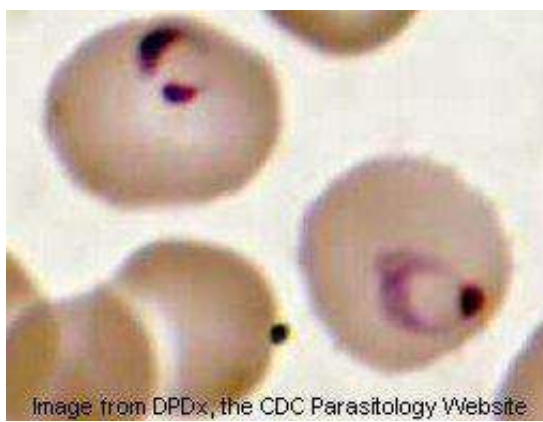
**Anopheles** species responsible for **malaria in Iraq** are ***A. stephensi*** and ***A. pulcherrimus***.

Adult females live for 4-5 months especially if they undergo a period of hibernation. During hot summer months of greatest activity, females live about only 2 weeks. Males live about a week, but, under optimal conditions of food and humidity, their life span may extend to more than a month.

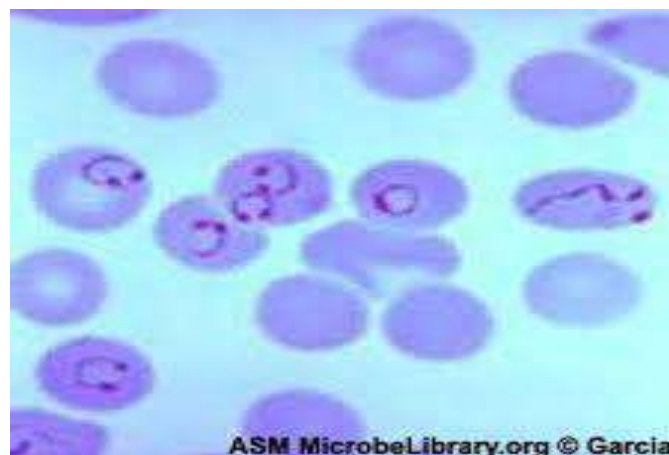
**Anopheles gambiae** has been called "**the most dangerous animal in the World**" because it is such an excellent vector for ***Plasmodium falciparum***, this mosquito is strongly attracted to humans and is especially adept at breeding in places created by human activities. As a result, in part of rural Africa, each villagers may suffer 50 - 100 bites/ night, with 1-5 of these

mosquitos carrying sporozoites. However, *A. gambiae* rests on walls after feeding, and thus is vulnerable to residual insecticides.

**Blood smear of *Plasmodium vivax*:** can be recognized by its variable ring stage. **Schizonts** contain about **16 merozoites** and the infected cell is enlarged and contains **Schuffner's dots**.

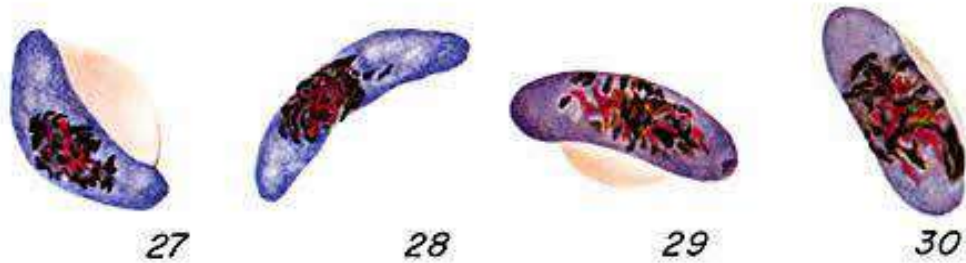


**Blood smear of *Plasmodium falciparum*:** has a **very neat ring** stage **trophozoite**. Multiply infected cells are common. **Schizonts** contain about **16-24** small **merozoites** having **Maurer's dots**.





It is **gametocytes** are crescent shaped.



### Pathogenesis:

*Plasmodium falciparum* demonstrates no selectivity in host erythrocytes, i.e. it invades young and old RBCs cells. The infected red blood cells also do not enlarge and become distorted.

- Multiple sporozoites can infect a single erythrocyte, and show multiple infections of cells with small ring forms.
- The trophozoite is often seen in the host cells at the very edge or periphery of cell membrane at accolé position.
- Occasionally, reddish granules known as **Maurer's dots** are observed.
- Mature (large) trophozoite stages and schizonts are rarely seen in blood films, because their forms are sequestered in deep capillaries, liver and spleen.
- Peripheral blood smears characteristically contain only young ring forms and occasionally crescent shaped gametocytes.



### Clinical features:

Of all the four Plasmodia, *P. falciparum* has the shortest incubation period, which ranges from 7 to 10 days. After the early flu-like symptoms, *P. falciparum* rapidly produces daily (**quotidian**) chills and fever as well as severe nausea, vomiting and diarrhea. The periodicity of the attacks then becomes tertian (36 to 48 hours), and fulminating disease develops. Involvement of the brain (**cerebral malaria**) is most often seen in *P. falciparum* infection. Capillary plugging from an adhesion of infected red blood cells with each other and endothelial linings of capillaries causes **hypoxic injury** to the brain that can result in coma and death. Kidney damage is also associated with *P. falciparum* malaria, resulting in an illness called —**black water fever**. Intravascular hemolysis with rapid destruction of red blood cells produces a marked hemoglobinuria and can result in acute renal failure, tubular necrosis, nephrotic syndrome, and death. Liver involvement is characterized by abdominal pain, vomiting of bile, **hepatosplenomegaly**, severe diarrhea, and rapid dehydration.

*Plasmodium vivax*: is selective in that it invades only young immature erythrocytes. Infections of *P. vivax* have the **following characteristics**:

- Infected red blood cells are usually enlarged and contain numerous pink granules or **schuffner's dots**.
- The trophozoite is ring-shaped but amoeboid in appearance.
- More mature trophozoites and erythrocytic schizonts containing up to merozoites are present.
- The gametocytes are round.

### Clinical features:

After an incubation period (usually 10 to 17 days), the patient experiences vague flu-like symptoms, such as headache, muscle pains, photophobia, anorexia, nausea and vomiting. As the infection progresses, increased numbers of rupturing erythrocytes liberate merozoites as well as toxic cellular debris and hemoglobin in to circulation. In combination, these substances produce the typical pattern chills, fever and malarial rigors. These paroxysms usually reappear periodically (generally every 48 hours) as the cycle of infection, replication, and cell lyses progresses. The paroxysms may remain relatively mild or may progress to severe attacks, with hours of sweating, chills, shaking persistently, high temperatures (1030F to 1060F) and exhaustion. Since *P.vivax* infects only the reticulocytes, the **parasitemia** is usually limited to around 2 to 5% of the available **RBCs**.

### *Plasmodium malariae*:

In contrast with *P.vivax* and *P.ovale*, *P.malariae* can infect only mature erythrocytes with relatively rigid cell membranes. As a result, the parasite's growth must conform to the size and shape of red blood cell. This requirement produces no red cell enlargement or distortion, but it results in distinctive shapes of the parasite seen in the host cell, —**band** and **bar** forms as well as very compact dark staining forms. The schizont of *P.malariae* is usually composed of **eight** merozoites appearing in a **rosette**.

### Clinical features:

The incubation period for *P. malariae* is the longest of the plasmodia, usually **18** to **40** days, but possibly several months to years. The early

symptoms are flulike with fever patterns of **72 hours (quartan or malarial)** in periodicity.

***Plasmodium ovale***: is similar to ***P. vivax*** in many respects, including its selectivity for young, pliable erythrocytes. As a consequence the classical **characteristics include**:

- The host cell becomes enlarged and distorted, usually in an oval form.
- **Schuffner's dots** appear as pale pink granules.
- The infected cell border is commonly fimbriated or ragged.
- Mature schizonts contain about **10** merozoites.

#### **Clinical features:**

The incubation period for ***P.ovale*** is **16-18** days but can be longer. Clinically, ovale malaria resembles vivax malaria with attacks recurring every **48-50** hours. There are however, fewer relapses with ***P.ovale***. Less than **2% of RBCs** usually become infected.

#### **Sum up:**

1. 1st symptoms & signs > rupture of **RBCs** (after **schizogony** & maturation in **RBCs**) > host immune response > **cytokinins** & other cellular products > responsible for fever
2. ***P.falciparum*** causative most deaths > parasites adhere to endothelium capillaries & post capillary venules > obstruction of microcirculation & local tissue anoxia
  - In brain: **Cerebral Malaria**

- In kidney: **Renal failure**
  - In intestine: **Ischemia & ulceration** > gastrointestinal bleeding > **Bacteremia** > secondary infections in circulatory system.
3. Severity of Malaria associated **anaemia** > degree of **parasitemia** > haemolysis or **phagocytosis** of parasitized **RBC** > phagocytosis of uninfected **RBC** > **Autoimmune** haemolytic **anaemia** > Massive intravascular haemolysis > haemoglobinuria & renal failure > Syndrome called Black water fever.

## Host defences:

- Susceptibility to Malaria-

### I. hereditary factors:

1. **Sickle cell trait** (sickle cell anemia) > protect against ***P. falciparum***
2. **Most blacks** (no **Duffy blood group antigens**) > no receptor for ***P. vivax***
3. **G6PD deficiencies & thalassemia** > protect to malaria

### II. Acquired factors:

- In malaria areas** > prevalence & severity of Malaria decrease with age > Adults suffer repeated malaria infections
- Individuals** mostly exposed to malaria > **T helper** & **Abs** against **sporozoites**, blood stages, **sexual** stages
- These **Abs** decrease susceptibility to reinfections
- Abs** against **sexual** stages (**gametes**) > decrease malaria transmission
- Cytokines** against all stages; cytotoxic **T cells** against **liver** stages

- **Ab** mediated immunity transfer from mother to fetus
- **Immunity** in new borns lost within 6 – 9 months
- **Pregnant** women > more susceptible

## **Epidemiology:** (anopheles, patient, normal human)

1. **Transmission** mostly by female anopheles in tropic & subtropics areas
  2. **Transmission** by needle (intravenous drug abuser)
  3. **Congenitally** > mother to offspring
- **In many regions** > *P.falciparum* > resistant to chloroquine.

## **Diagnosis of malaria**

- 1- **Clinical diagnosis:** is based on the patient's symptoms and on physical findings at examination. The first symptoms of malaria most often fever, chills, sweats, headaches, muscle pains, nausea and vomiting.
- 2- **Microscopic Diagnosis:** malaria parasites can be identified by examining under the microscope a drop of the patient's blood, spread out as a "blood smear" plasmodia (1. Thin blood smear 2. Thick blood smear).

Microscopic examination of thick and thin films of blood is the method of choice for confirming the clinical diagnosis of malaria and identifying the specific species responsible for disease. Malaria parasites in thick and thin blood films are best stained at pH 7.1 – 7.2 using a **Romanowsky** stain (contains **azure** dyes and **eosin**). The thick film is a concentration method that may be used to detect the presence

of organisms. The thin film is most useful for establishing species identification.

• Since *P.falciparum* sequestered in microcirculation of deep organs > blood smear > every **6 – 12** hours for **48** hours.

On a microscope slide. Prior to examination, the specimen is stained (most often with the **Giemsa stain**) to give the parasites a distinctive appearance. This technique remains the gold standard for laboratory confirmation of malaria. However, it depends on the quality of the reagents, the microscope, and on the experience of the laboratorian.

**3- Antigen Detection:** various test kits are available to detect antigens derived from malaria parasites. Such immunologic (“**immunochromatographic**”) tests most often use a dipstick or cassette format, and provide results in 2-15 minutes. These “Rapid Diagnostic Tests” (**RDTs**) offer a useful alternative to microscopy in situations where reliable microscopic diagnosis is not available.

**4- Molecular Diagnosis:** Parasite nucleic acids are detected using **polymerase chain reaction (PCR)**. Although this technique may be slightly more sensitive than smear microscopy, it is of limited utility for the diagnosis of acutely ill patients in the standard health care setting. **PCR** results are often not available quickly enough to be of value in establishing the diagnosis of malaria infection.

**PCR** is most useful for confirming the species of malarial parasite after the diagnosis has been established by either smear microscopy or **RDT**.

**5- Serology:** serology detects antibodies against malaria parasites, using either indirect immunofluorescence (**IFA**) or enzyme-linked

immunosorbent assay (**ELISA**). Serology does not detect current infection but rather measures past exposure.

## **Control:**

### **I. Blood schizonticides:**

- For clinical cure (elimination of symptoms & signs of Malaria attack)

#### **1. Mefloquine**

#### **2. Pyrimethamine / sulfadoxin**

#### **3. Quinine**

#### **4. Quinidine**

### **II. Tissue schizonticides:** (e.g. **Primaquine**)

- For radical cure (elimination of parasites from tissues)
- Specially for **hypnozoites** of *P.vivax* & *P.ovale* > therapy against liver stage.

## **Prevention of Malaria:**

### **I. Avoiding exposure to Anopheles: (From dusk to dawn)**

- 1. Wearing protective cloths**
- 2. Staying & Spraying in screened area**
- 3. Insect repellent use (e.g. N, N – diethyl – m toluamide)**

### **II. Chemoprophylaxis: using drugs against asexual Erythrocytic stage.**



## PHYLUM: Axostylata

With an axostyle made of microtubules.

e.g *Trichomonas*, *Dientamoeba*.

### Intestinal and Atrial Flagellates

- *Trichomonas vaginalis*: (pathogenic)- occurs in reproductive and urinary system of people.
- *Trichomonas tenax*: endocommensal found in mouth (tooth sockets).
- *Trichomonas hominis* (*Pentatrichomonas hominis*) endocommensal found in large intestine and cecum.
- *Dientamoeba fragilis*: lives in the large intestine of people.
- *Chilomastix mesnili*: (endocommensal) lives in the large intestine.
- *Giardia lamblia*: (pathogenic) lives in small intestine.

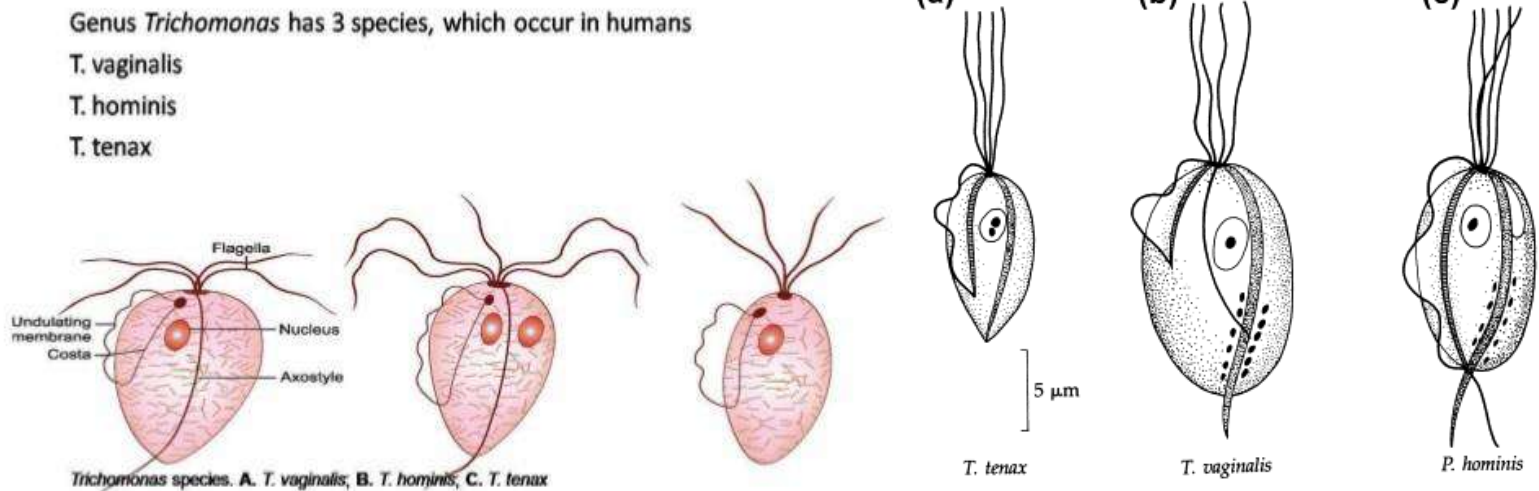
### *Trichomonas*:

The genus *Trichomonas* comprises flagellates that have 3-5 anterior flagella, an undulating membrane, an axostyle, and usually a cytosome. Trichomonads are widely distributed and infect nearly every mammal associated with human. There are three species in man:

- *Trichomonas vaginalis* of the vagina.
- *Trichomonas hominis* of the intestine.
- *Trichomonas tenax* of the mouth.

These species may be differentiated by:

- 1- Morphology ( on the bases of length of undulating membrane).
- 2- Habitat.
- 3- Cultural characteristics and failure to cross infection.



## *Trichomonas vaginalis*

Disease: **Trichomonad vaginitis.**

**Urethritis.**

**Prostato-vesiculitis.**

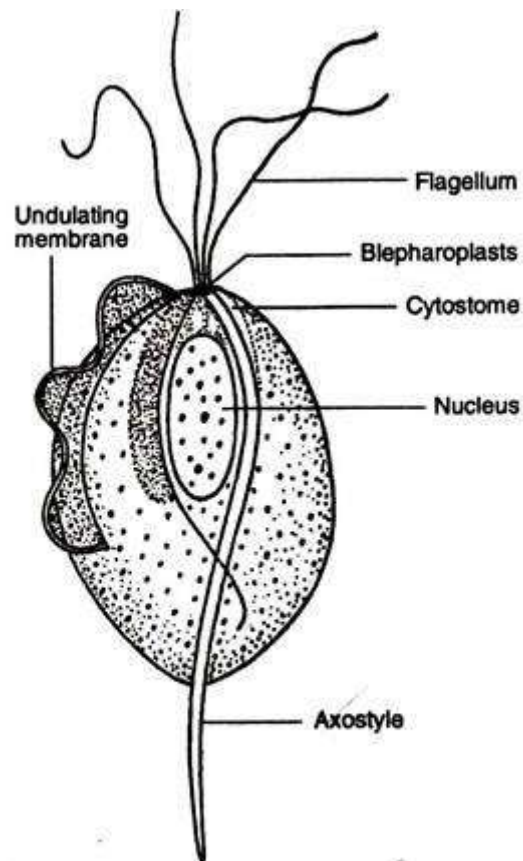
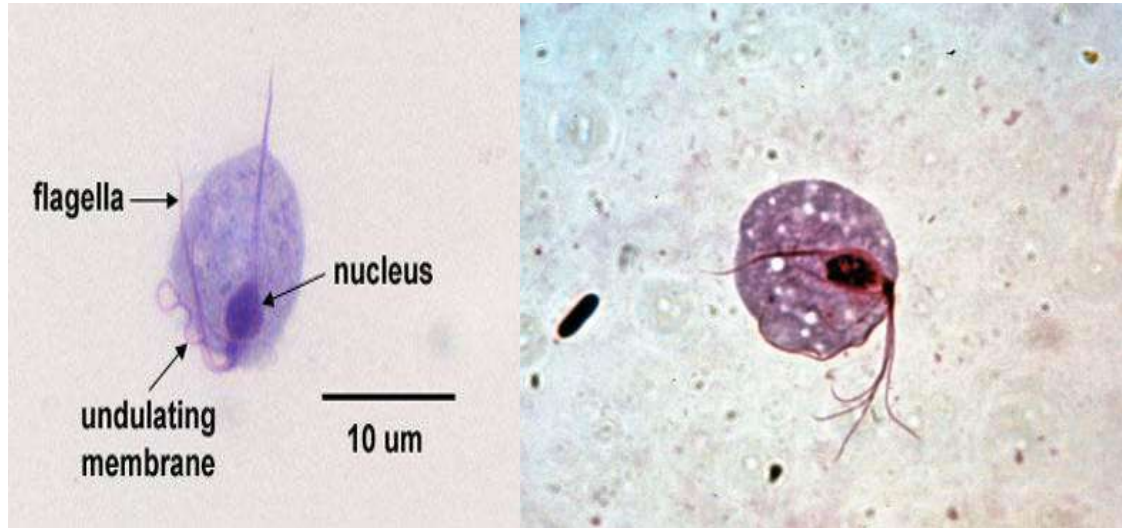
Morphology

Trophozoite:

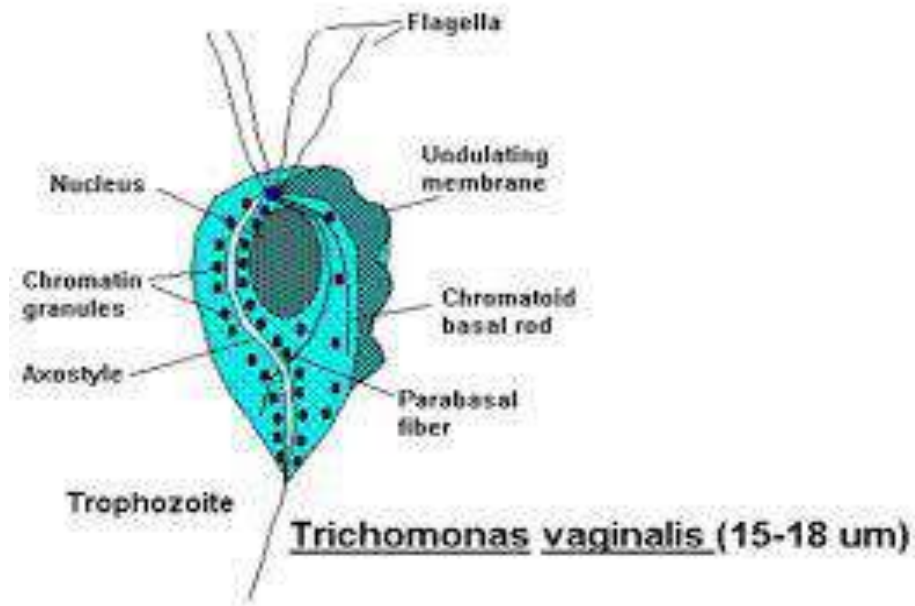
- Is 7-32µm long by 5-12µm wide.
- **It lives in the reproductive and urinary system of people.**
- More specifically it is found in the **vagina** and **urethra** of women, and in the **prostate, seminal vesicles, and urethra** of men.
- It is more common in women, and hard to find in men because most are asymptomatic.
- It is cosmopolitan in distribution, however prevalence is not uniform because of sanitary and hygiene habits (depends on surroundings).
- **20-40% in Women**
- **15% in Men**
- All *Trichomonas* species are found **only** in the **trophozoite** stage, multiplies

and divide by longitudinal binary fission every 5-8 hours.

- No cysts have been found.
- *Trichomonas vaginalis* frequently produces pseudopodia.

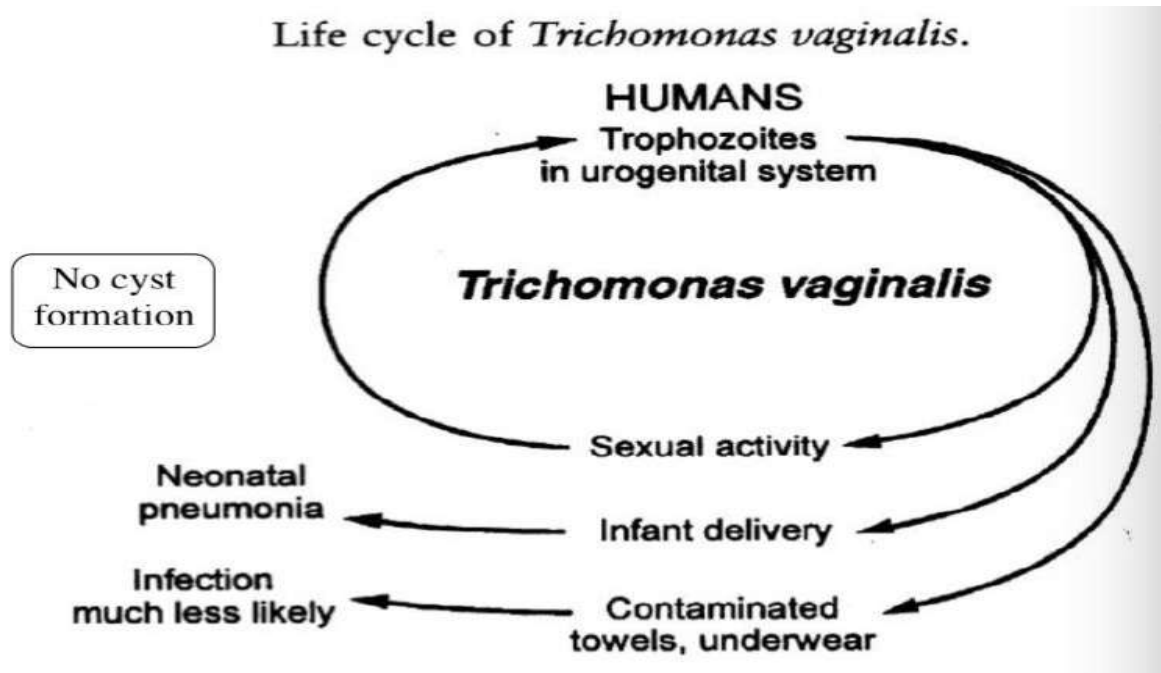


**Fig. 10.9:** *Trichomonas vaginalis*, a flagellate which remains as parasite in the reproductive tracts of women (after Kudo).



## Life cycle:

Species of the genus *Trichomonas* are parasites of human and other animals such as monkeys, are transmitted from host to host in **a trophozoite** form.



## Symptoms

- Usually none.
- Particularly in males. They don't show symptoms.
- **leukorrhea** In females it ranges from: chaffing, itching, frothing/clear/creamy, white, pus-like discharge resulting from the infection that is profuse from vagina.

## Pathology

*Trichomonas vaginalis* lives in the **vagina** and **urethra** of **women** and in the **prostate**, **seminal vesicles**, and **urethra** of **men**. It is transmitted primarily by **sexual intercourse**, although it has been found in newborn infants. Its presence occasionally in very young children, including virginal females, suggests that the infection can be contracted from soiled washcloths, towels, and clothing. Viable cultures of *T. vaginalis* have been obtained from damp cloth as long as 24 hours after inoculation .

Acidity of the normal vagina (pH 4.0 to 4.5) ordinarily discourages infection, but, once established, the organism itself causes a shift toward alkalinity (pH 5 to 6), which further encourages its growth .

Most strains are of such low pathogenicity that an infected person is virtually asymptomatic. However, some strains cause **intense inflammation**, with **itching** and a copious **white discharge (leukorrhea)** that is swarming with trichomonads. They feed on **bacteria** ,**leukocytes**, and cell exudates and are themselves ingested by **monocytes**.

## Epidemiology

- **Sexual contact.**
- Soiled clothing/linens; sharing of wash cloth, clothing, etc.
- *T. vaginalis* can live in moist clothing for one day!
- Human and primates are the only known natural hosts.

## Diagnosis

### 1- Clinically:

By the symptoms appeared on the patient, life history, age and position.

### 2- Laboratory:

- a. Detect the trichomonad in urine, pus, urine exudates and secretions.
- b. Swap of vagina or urethra.

### 3- Cultivation:

- a. Special tissue culture.
- b. Monoclonal tissue culture.
- c. Chick embryo extract.

### 4- Antigenic method.

### 5- DNA probe.

### 6- PCR.

## *Pentatrichomonas hominis*

Traditionally, it has been called *Trichomonas hominis*, but because most specimens actually bear 5 anterior flagella, the organism has been assigned to the genus *Pentatrichomonas*.

1. It is actively motile.
2. Pear-shaped with 3-5 anterior flagella and an undulating membrane along the length of the body.
3. This is a commensal of the large intestine and cecum, where it **divides by binary fission** building up incredible numbers, its feeds on bacteria and debris.
4. The organism apparently **can survive acidic conditions** of the stomach, and transmission occurs by contamination.

## *Trichomonas tenax*

1. It is like *Trichomonas vaginalis* but smaller and mor slender.
2. Has 4 free flagella, the fifth one is on the margin of the undulating membrane, which does not reach up to the posterior end of the body.
3. The axostyle is thick.

4. They are seen in pus in cases of pyorrhoea alveolaris.

### *Dientamoeba fragilis*



*Dientamoeba fragilis* is a parasite that lives in the large intestine of people. This protozoan parasite produces **trophozoites**; cysts have not been identified. The intestinal infection may be either asymptomatic or symptomatic.

### **Life Cycle**

Most likely, people get infected by accidentally swallowing the parasite; (**trophozoite**) this is called **fecal-oral transmission**. The parasite is fragile; it probably cannot live very long in the environment (after it is passed in feces) or in stomach acid (after it is swallowed). An unproven possibility is that **pinworm eggs (or the eggs of another parasite) help protect and spread *D. fragilis***.

### **PHYLUM: RETORTAMONADA**

Mitochondria and dictyosomes absent, three anterior flagella and one recurrent flagellum, the latter lying in a cytosomal groove; intestinal parasites or free living in anoxic environment.

e.g. *Chilomastix*, *Giardia*, ... etc.



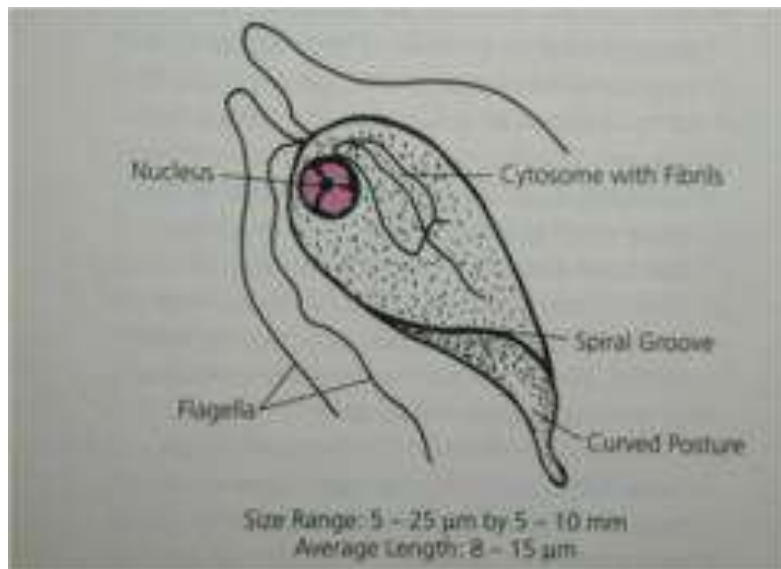
### *Chilomastix mesnili*

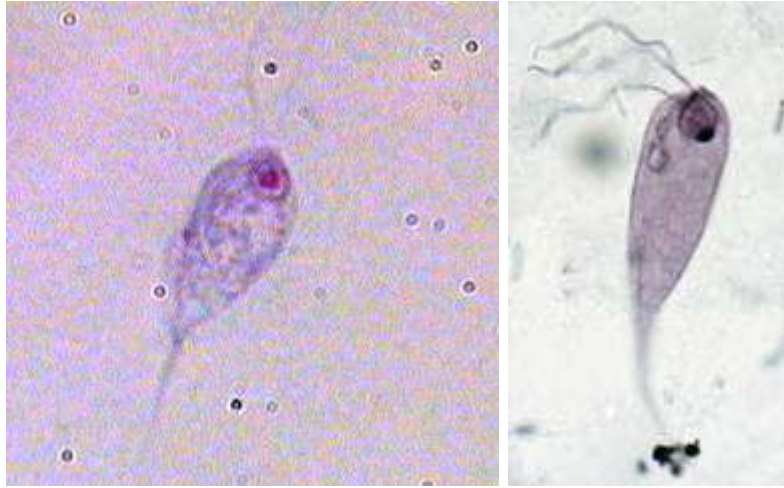
- Non-pathogenic; endocommensal.
- Trophs and cysts in the life cycle.
- Lives in the cecum.
- Divides by binary fission.
- Water borne parasite → infected by contaminated water.

**Trophozoite. It is broadly rounded at the anterior end and tapers to pointed posterior extremity with a spiral torsion (groove) of the body.**

Size: 6-24  $\mu\text{m}$  long by 3-20  $\mu\text{m}$  wide.

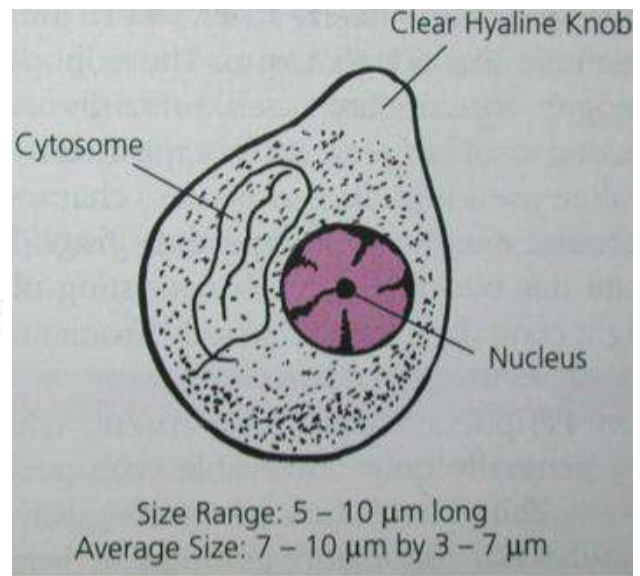
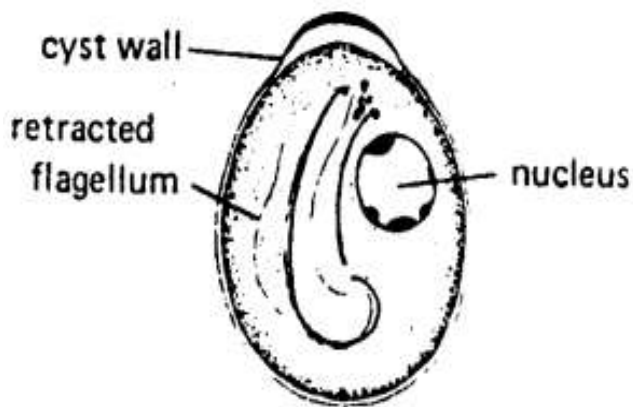
- 4 flagella arise from kinetosomes at anterior end; 3 flagella extend anteriorly, 1 extends into the cytostome (flagella are difficult to see in stained trophozoites).

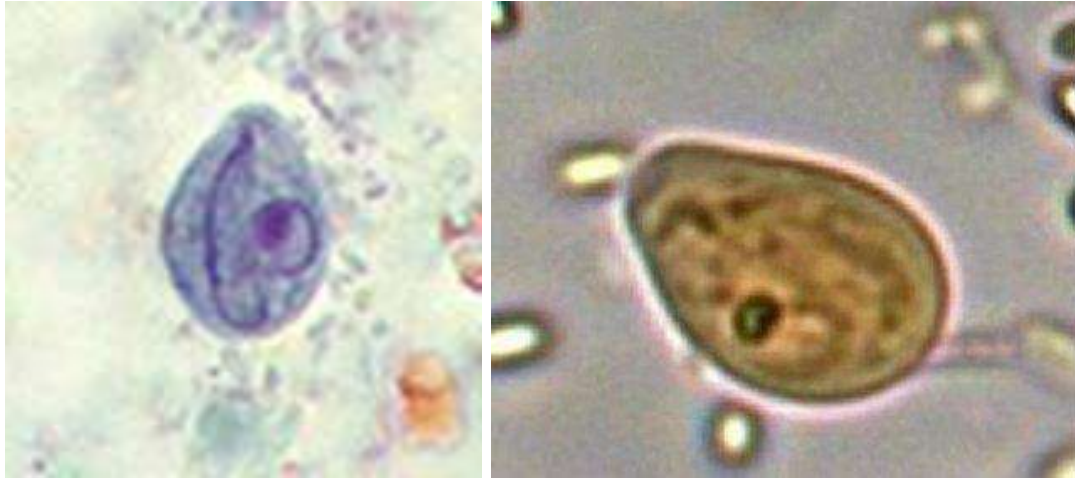



**CYST:** Is lemon-shaped, the cyst wall is thin at the narrow anterior end and hyaline.

- It is 6 to 10  $\mu\text{m}$  in diameter.
- Contains single nucleus, chromatin is clumped at one pole, giving a signet ring appearance, cytostome, and retracted flagella.





Human get infection with *Chilomastix mesnili*, by ingestion the cyst of the parasite which will produce one trophozoite, which will then divide longitudinal binary fission.

### Treatment

Flagyl- 3 times a day for 4-5 days.

– Reinfection can happen almost immediately.

### *Giardia lamblia*

Synonym: *G. duodenalis*; *G. intestinalis*

Disease:

- Giardiasis.
- Lambliasis.
- Flagellate diarrhea.

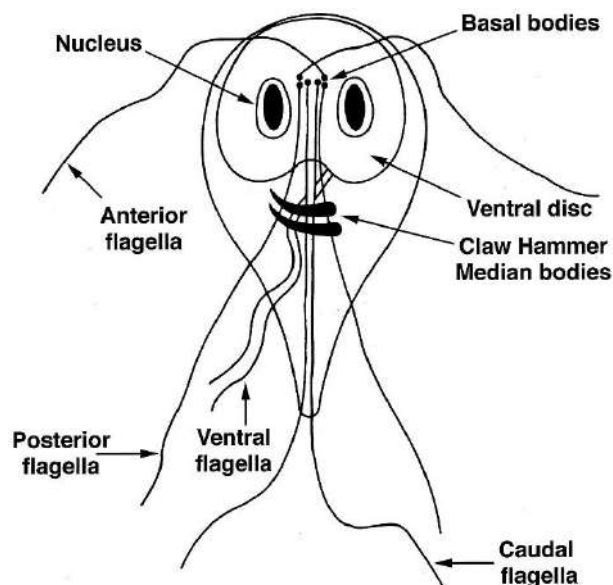
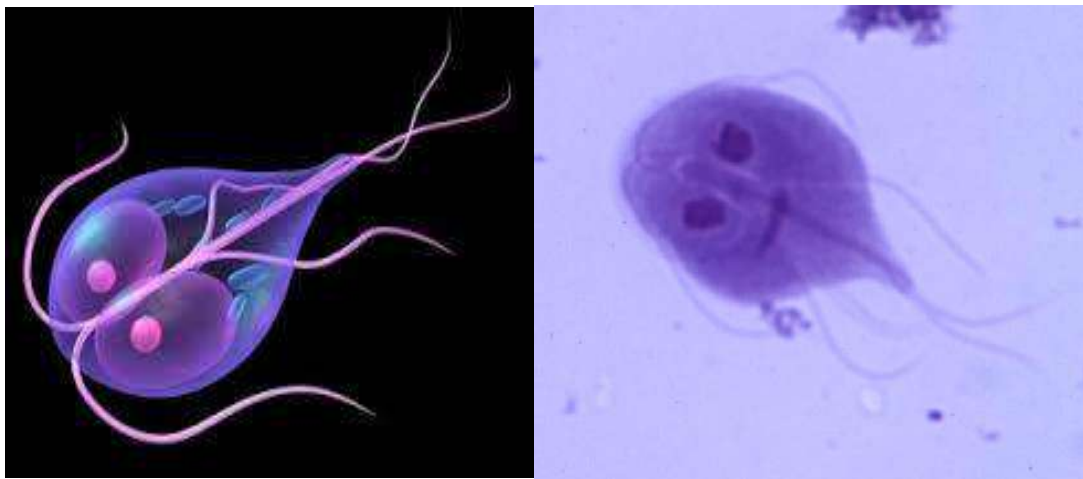
### Morphology.

Has both a trophozoite and cyst stage.

**Trophozoites** are **binucleated** (looks like a face). 12-15  $\mu\text{m}$ .

- Ventral surface bears adhesive disk to adhere to surface of intestinal cell.

- 8 flagella (2 anterior, 2 posterior, 2 ventral, and 2 caudal) - all arise from kinetosome.
- Median bodies occur behind adhesive disk.
- Lives in the upper part of the small intestine (**duodenum, jejunum, and upper ileum**). The trophozoites attach to the epithelial cells with an adhesive disk.
- Feeds on mucous that forms in response to irritation.
  - *Giardia* can also interfere with host **absorption of amino acids, lipids, and Vitamins A &D**.



### Cyst:

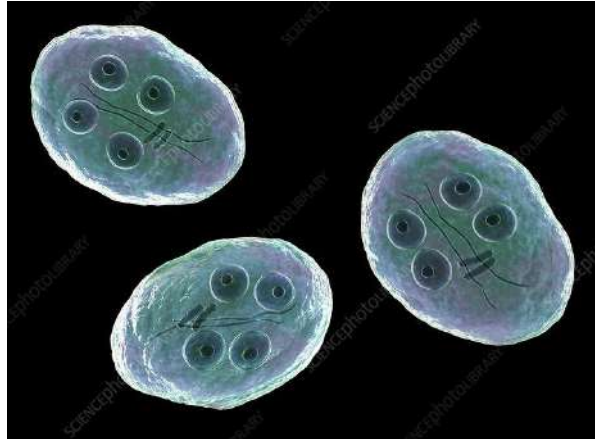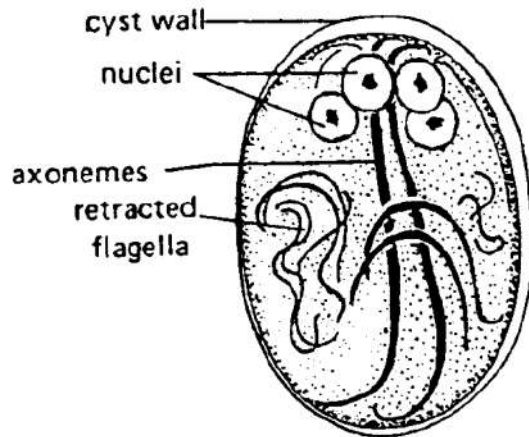
As *Giardia* pass through the small intestine to the colon they **encyst**, forming a rigid filamentous shell that allows them to survive outside the host.



**cyst** is ovoid in shape; 8-12  $\mu\text{m}$  long x 7-10  $\mu\text{m}$  wide and has a thin cyst wall.

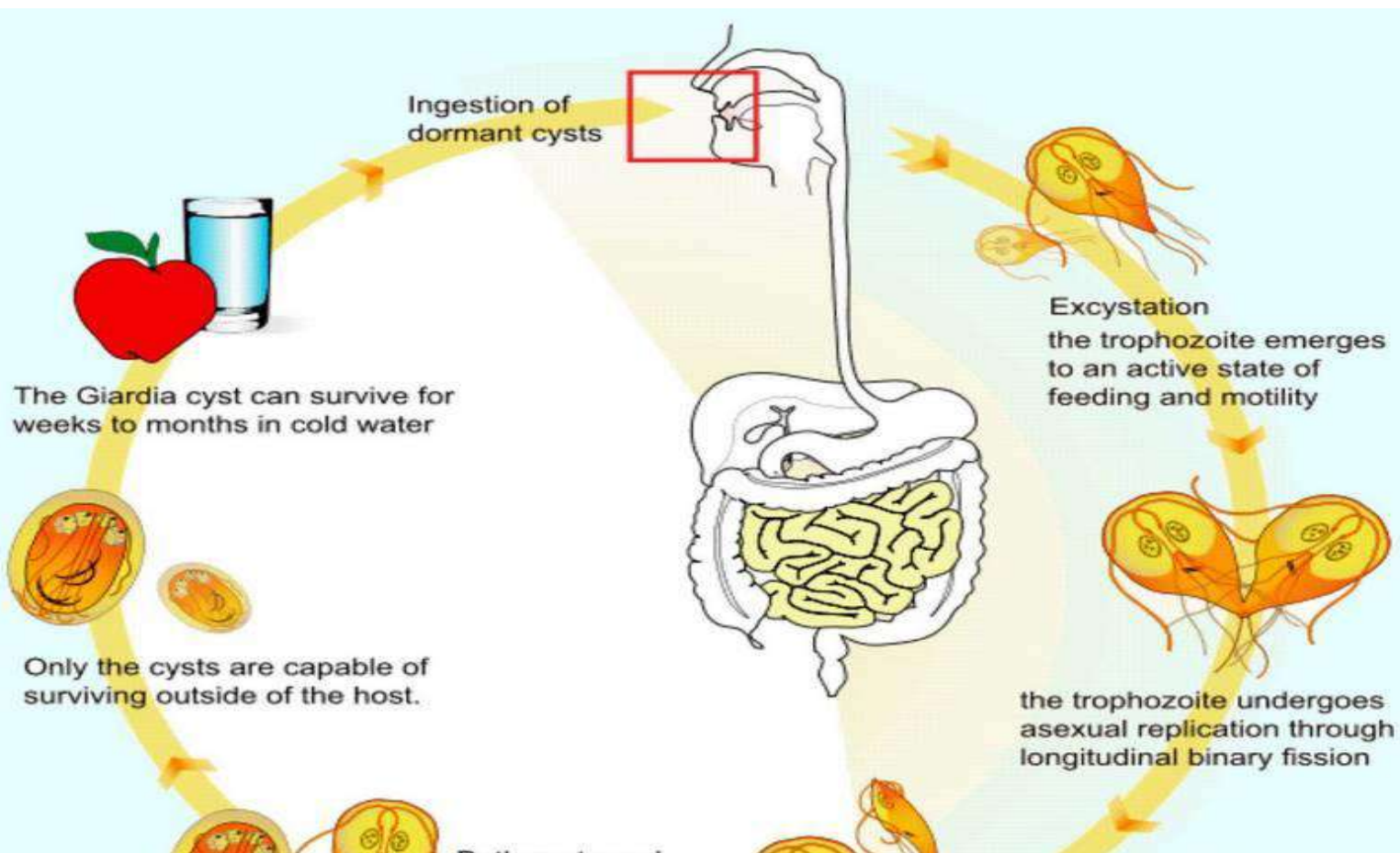
Flagella retracted within cyst. Axonemes provide internal support.

**Cyst has four nuclei.**



Cysts can remain viable in the external environment (usually water) for many months. 300 million cysts can be found in a moderate infection, but 14 billion cysts can be passed in 1 stool sample.

## Life Cycle



After ingestion by a host, excystation occurs when the cysts are exposed to gastric acid, pancreatic enzymes and the induction of a parasite-derived cystine protease. The process of **excystation** is a highly coordinated by sequence of structural, physiological and molecular events, initiated when the parasite detects the appropriate environmental stimuli.

Each cyst will give **only 2 trophozoites** when ingested by man, which multiply by longitudinal binary fission.

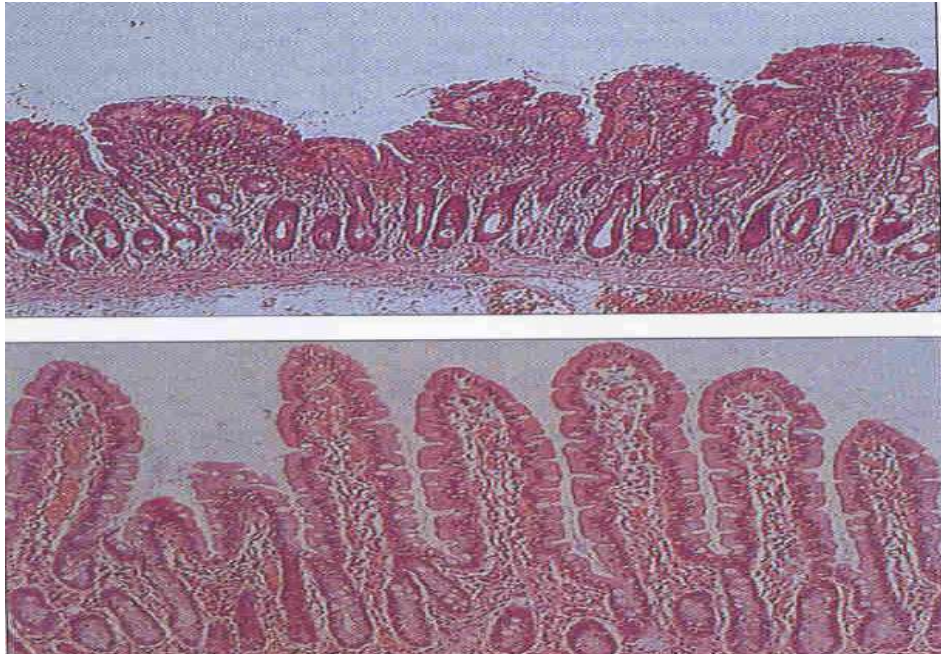
### Symptoms

- Range from none to abdominal discomfort causing acute or chronic diarrhea and other GIT signs.
- **Gray, greasy, voluminous malodorous diarrhea, which does not contain blood.**
- **Flatulence.**
- *Giardia* trophs are attracted to bile salts. The gall-bladder may become infected which can cause jaundice and colic. The disease is not fatal but can be intensely discomforting.

### Pathogenesis and Pathology

- Nutrient **malabsorption** and physical blockage and damage to **microvilli**.
- Trophs attach to small intestine → cause damage (**mechanical and toxins**).
- 1) **Fat/CHO** digestion decreases and causes **maldigestion**.
- 2) **Absorption** decreases due to **villus blunting** causing **malabsorption**.
- 3) Uptake of bile salts by *Giardia* inhibits the digestion of fats by pancreatic **Lipase** - collectively these lead to **Malabsorption syndrome**. Greasy stool clinically refer as **Steatorrhea** and maldigestion causes **diarrhea**.

- 4) **Physical damage: clubbing of villi; decreases villus-to-crypt ratio; brush borders of cells are irregular.**
- 5) The gallbladder (**biliary tract**) may be infected, which can cause chronic **jaundice** and colic (**Colecystics**).



## Epidemiology

- Get infected by ingesting cysts through contaminated water.
- Most common intestinal flagellate of people.
- Worldwide distribution; prevalence ranges from 2.4-67.5%.
- Reservoir hosts can play a significant role, e.g , beaver which pollute the water with cysts of *Giardia*...Hence the giardia disease is also called **beaver disease**.
- There are hot spots: Vacations and Travels → Camping.
- Day care centers.

## Laboratory diagnosis

- 1- The diagnosis is based on clinical symptoms and confirmed by the identification of trophozoite and cyst stage in fecal sample.
- 2- Formed stool sample to look for cyst stage while diarrheic stool sample to find

trophozoite stage . Repeated sampling is recommended to increase test sensitivity.

- 3- The direct wet mounts preparation for detection of characteristic falling leaf motility of trophozoite.
- 4- Diagnosis of *Giardia lamblia* **microscopically** after the application of fecal concentration procedures, especially **zinc sulphate flotation and centrifugation** remains a relatively **reliable** indicator of infection.
- 5- Obtaining duodenal fluid sample by **string test** is more comfortable test than some of the other tests to detected *Giardia lamblia* organism from duodenal content.
- 6- Histological test used to determine the mucosal invasion and villous atrophy.
- 7- Antigen detection test by Enzyme immunoassay (**ELISA**) test as immunodiagnostic test to detect *Giardia* cyst wall (Ag) in stool sample.
- 8- Polymerase chain reaction (**PCR**) procedure has high sensitivity to identified the nucleic acid of *Giardia lamblia*.

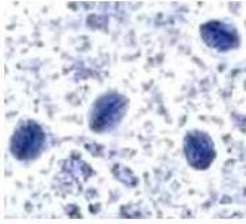
### **Entero-test/string test**

1. Gel capsule with string inside
2. Free end of string is taped to the face
3. Capsule swallowed
4. 4-6 hours later, capsule dissolves and the end of the string is in the SI
5. String pulled out and examined for trophozoites of *Giardia lamblia*

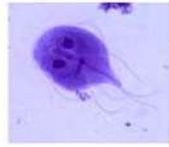

## Diagnosis

- Direct stool examination



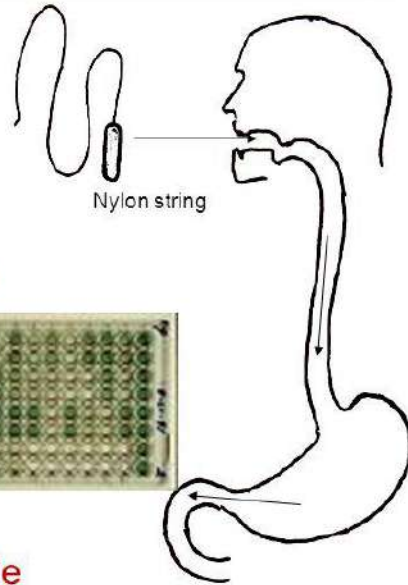

Cysts in **formed** stool



Trophozoite in  
diarrhoeic stool

N.B: Negative stool samples is strongly suspected cases (Excretion is irregular) – must repeated

- String test (Enterotest).
- Serological tests:  
Coproantigen detection.



Treatment: **Metronidazole OR Tinidazole**  
**Recently Albendazole.**

Control: **As Amoebiasis.**

## Phylum :Ciliophora

- Is a phylum of alveolates that have short hair like cilia through entire life cycle that move in an undulating pattern.
- Having **two different types of nuclei: one vegetative macronucleus** and **one or more generative micronuclei**.
- **Contractile vacuoles** typically present.
- ***Balantidium coli*** is the only ciliate infects man sporadically in many places.

## ***Balantidium coli***

**Disease: Balantidiasis, Balantidiosis, Balantidial dysentery**

**Balantidium means little bag.**

**Habitat :**

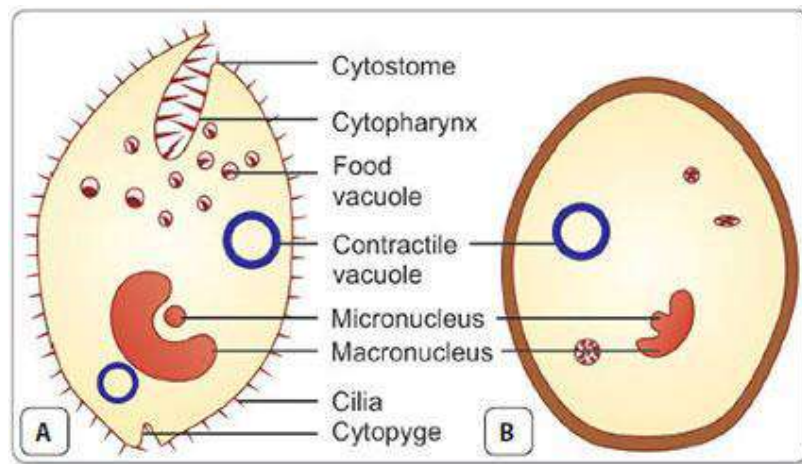
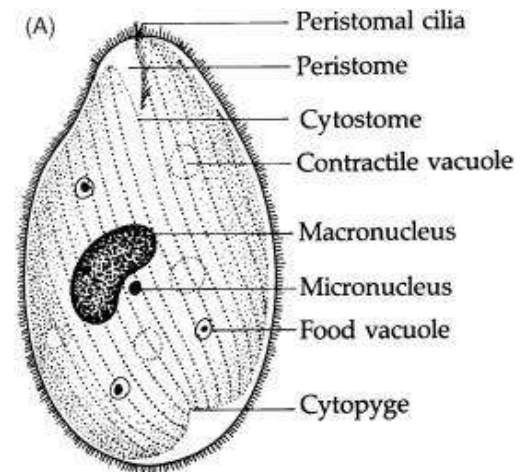
***Balantidium coli*** inhabits the large intestine, chiefly the cecal sigmoidorectal regions, and more rarely the terminal ileum.

**Morphology**

**Trophozoite stage:**

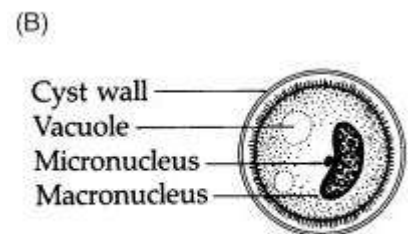
- ***B.coli*** is the largest protozoan of man 30-300 µm in size.
- Its shape is **like a sac**.
- It has **two nuclei**, reniform large **macronucleus** and smaller **micronucleus** in the concavity of **macronucleus**.

- 2 contractile vacuoles.
- **Cytostome** locate at anterior end as funnel-shape.
- Locomotion with cilia, embedded in pellicle in longitudinal rows these rows (kineties) can be seen under phase contrast or interference contrast microscopy or by silver staining.
- At the posterior end is an indistinct **excretory opening**, the **cytopyge**, through which the solid waste material is discharged.
- Living trophozoites and cysts are yellowish or greenish.

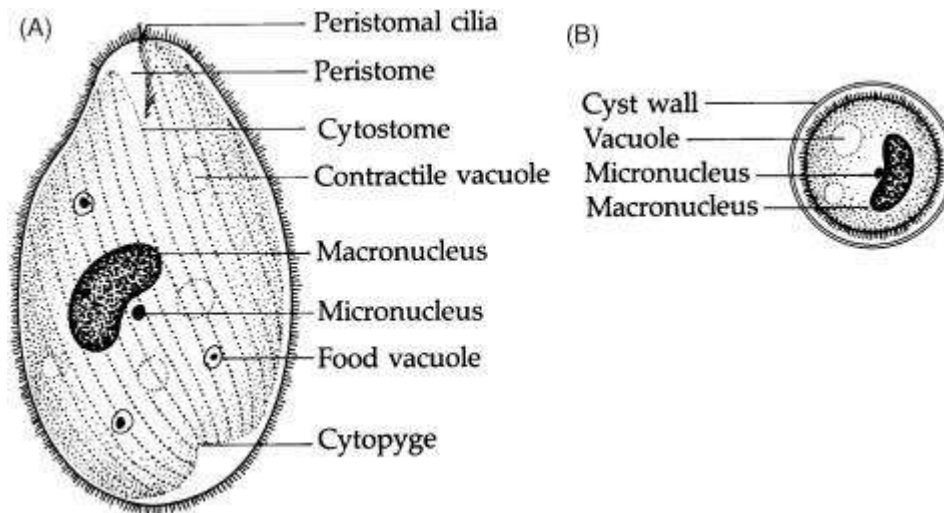


### Cystic stage:

- Spherical or ovoid, 40-60  $\mu\text{m}$  in diameter.
- Thick and transparent cyst wall.
- The cilia get absorbed.
- Contractile vacuoles, macro- and micro-nucleus, other structures are similar to trophozoites.



- Encystment is instigated by **dehydration** of feces as they pass posteriorly in the rectum.
- This parasite **can encyst** after being passed in stools----**an important factor in epidemiology of disease.**
- Unencysted trophozoite may live up to 10 days and may possibly be infective if eaten.



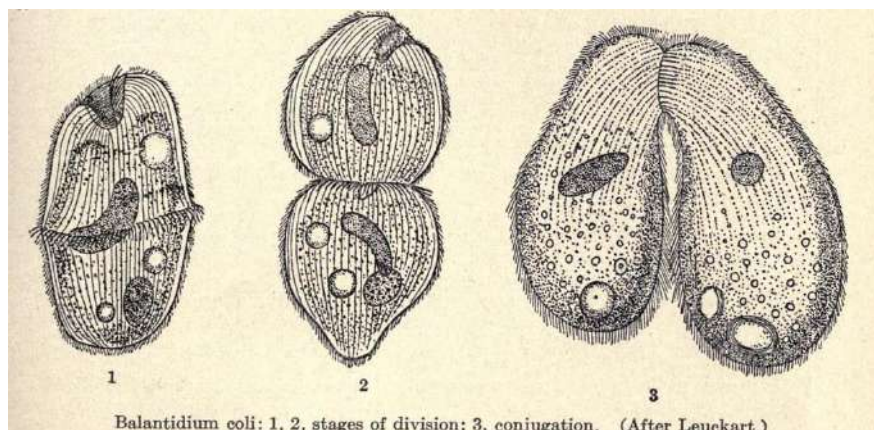
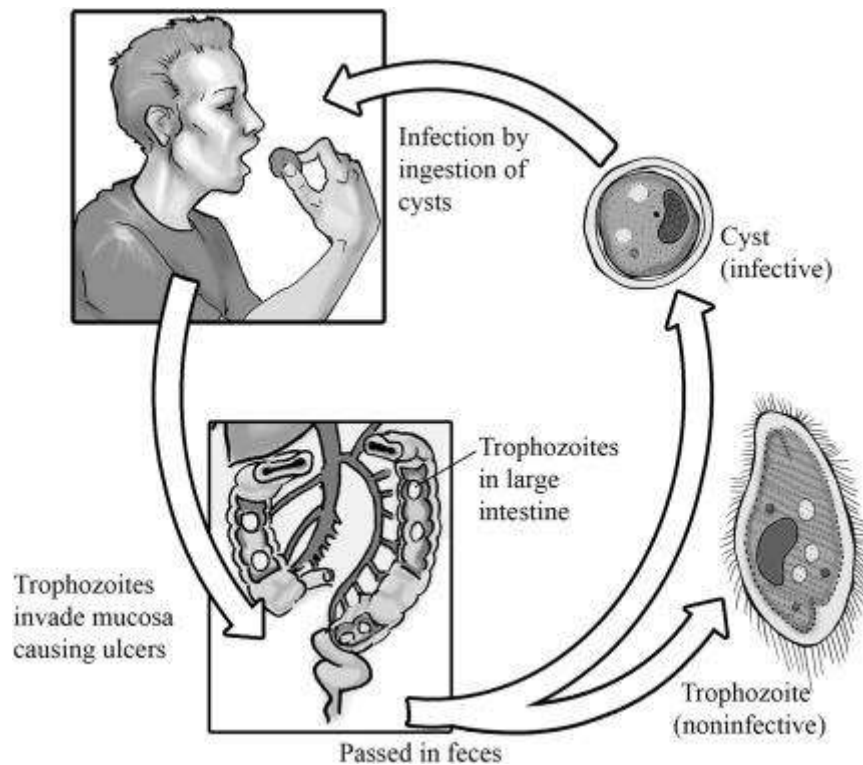
### Reproduction:

- 1- **Asexual reproduction** consists of **transverse binary fission**, in which micronucleus first divides mitotically, then the macronucleus amitotically, followed by the cytoplasm, resulting in two daughter organisms.
- 2- **Sexual reproduction**: By **conjugation**, occur at the anterior end for a few minutes.

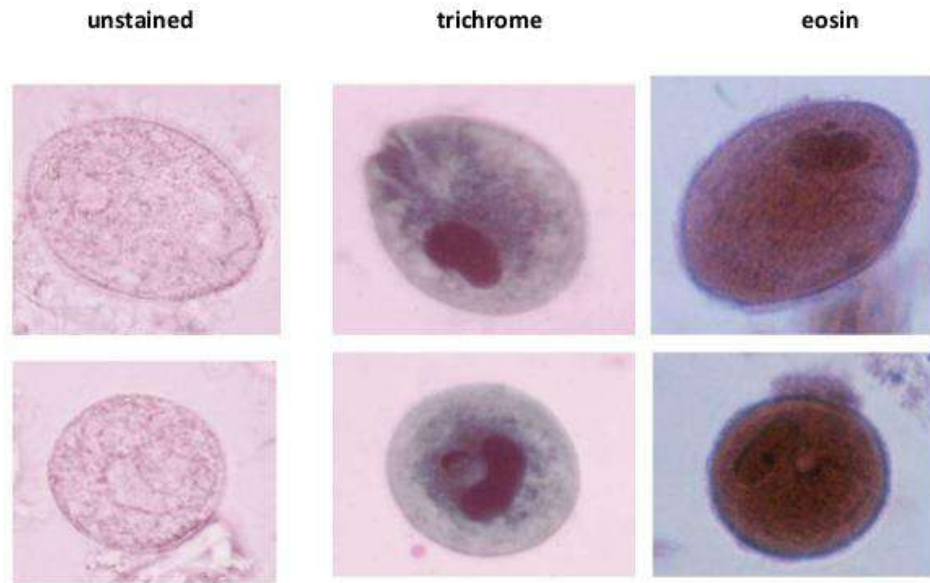
### Life Cycle

- Infection occurs from close association with **pigs**.
- Human to human transmission may also occur.

- **Cyst** is the **infective stage** of this parasite.
- Yet, **trophozoites** also at times may be a source of infections, since under favorable conditions they may **survive several days** outside the host, and pass unharmed through the **stomach** of **guinea pigs**.
- **Excystation** occurs in small intestine.
- Multiply in large intestine by **transverse binary fission**.







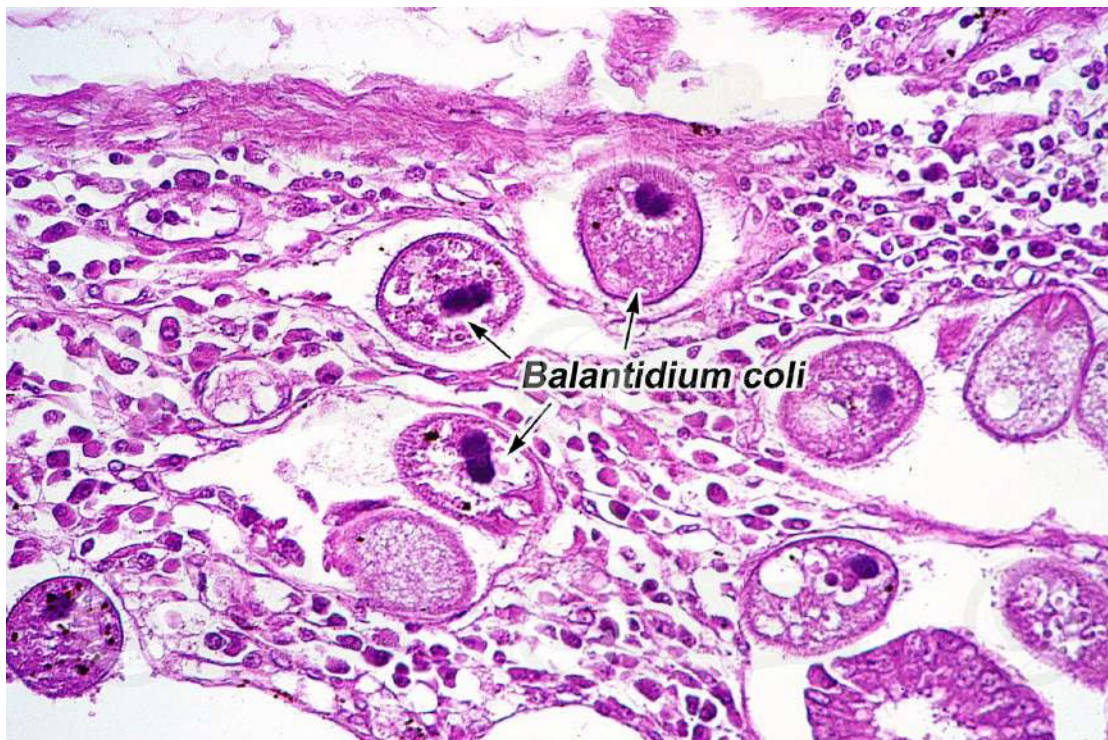## Epidemiology

Hogs harbors *B.suis*, while man harbor *B.coli*.

## Pathogenesis:

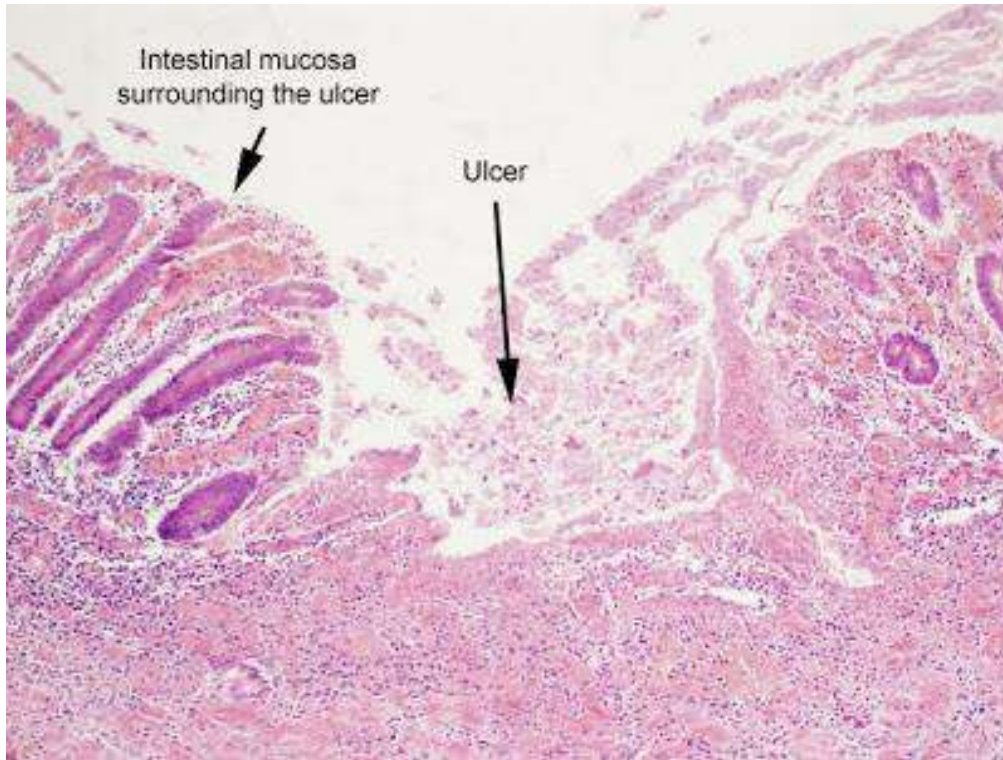
- Under ordinary conditions, the trophozoites feed on ingesting particles such as **starchy food**. *B. coli* does not invade the **epithelial cells** of the intestine in the **presence of starch food** and this probably explains the harmless behavior of the parasite.
- The **starch** and **erythrocytes** are **favorite** items of diet. It can ingest *Trichuris trichiura* ova, and occasionally one *Balantidium* will ingest another.
- Similar to amoebiasis in pathology and clinical symptoms.
- The **ulcers are like those of amoebic ulcers; round, avoid or irregular in shape** with undetermined edges and the floor is covered with pus and necrotic material.
- Production of hyaluronidase has been detected, and this enzyme could help enlarge the ulcer.

- **Extraintestinal pathogenesis** occasionally may occur leading to perforation of the large intestine or appendix, as in amoebic dysentery.
- Trophozoites are often located in the **submucosa** of infected intestine.
- Fulminating cases may produce necrosis and sloughing of the overlying mucosa and occasionally perforation of the large intestine or appendix.



- Death often follows at this stage.
- Secondary foci, such as the **liver** or **lung** may become infected.
- **Urogenital organs** are sometimes attacked after contamination, and **vaginal, uterine, and bladder** infections have been discovered.
- Infections often disappear spontaneously in healthy persons, or they can become symptomless, making infected person **carriers**.





## Diagnosis

Faeces examination.

Trophozoites or cysts.

Actively motile trophozoites in acute dysentery.

Easy to recognized by their characteristic macronucleus.

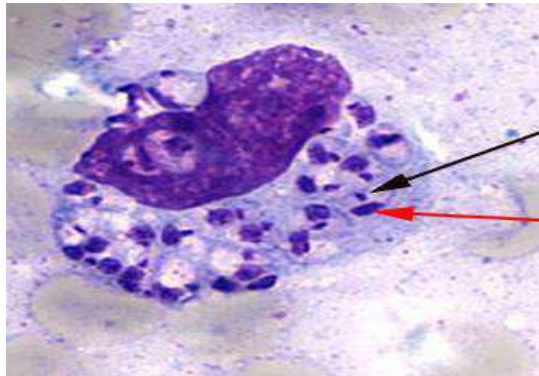
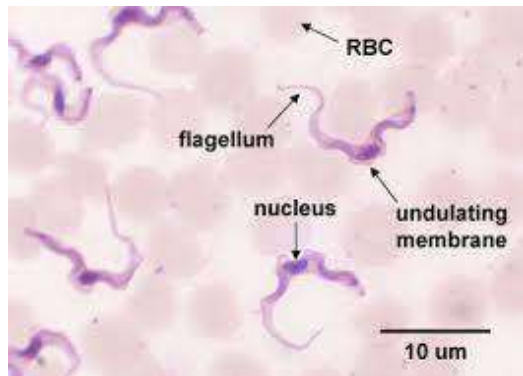
## PHYLUM: EUGLENOZOA

With cortical microtubules; flagella often with paraxial rod; mitochondrion with discoid cristae ; nucleoli persist during mitosis.

*e.g. Leishmania spp., Trypanosoma spp.,... etc.*

## BLOOD & TISSUE FLAGELLATES (HEMOFLAGELLATES)

- These are the parasites that inhabit the tissue and the blood of human with the aid of a **phoretic vector**.



### Characteristics:

- 1) **Fusiform body – spindle shaped body.**
- 2) Nucleus centrally located.
- 3) Single flagellum.
- 4) **Kinetoplast** - an accessory body found in many protozoa, primarily the Mastigophora; It contains DNA and replicates independently. Function – coordination of movement.

**Parabasal body** - A structure near the nucleus in certain parasitic flagellates.

**Blepharoplast** - A basal body in certain flagellated protozoans that consists of a minute mass of chromatin embedded in the cytoplasm at the base of the flagellum.

5) **Axoneme** – found at inner portion.

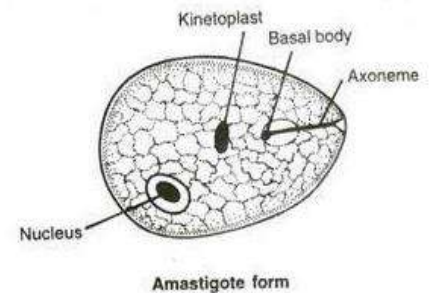
### Evolutionary stages of Leishmania and Trypanosomatid flagellates

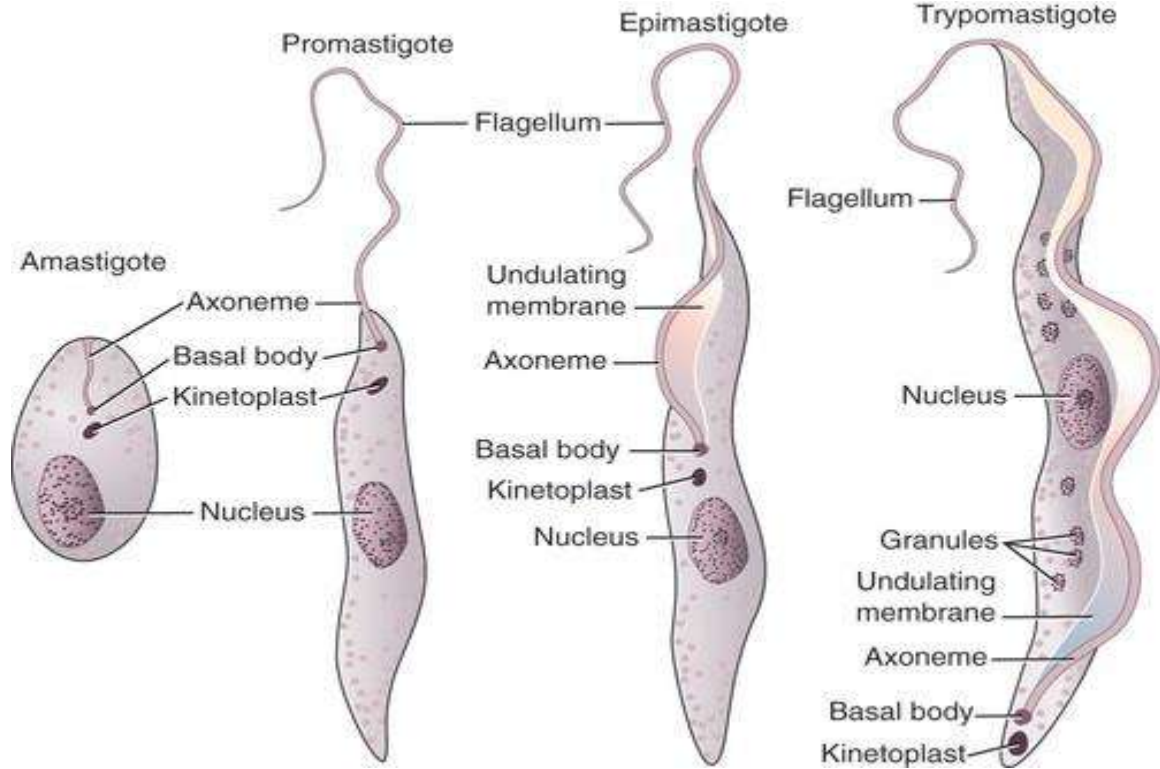
Which are based on characteristic of flagella as well as the point of emergence of flagella in relation to the Kinetoplast. These are described as follows:

1. **Amastigote – formerly Leishmania.**
2. **Promastigote – formerly Leptomonas.**
3. **Epimastigote – formerly Crithidia.**
4. **Trypomastigote – formerly Trypanosoma.**

**AMASTIGOTE:** also known as Leishman-Donovan (L-D) body.

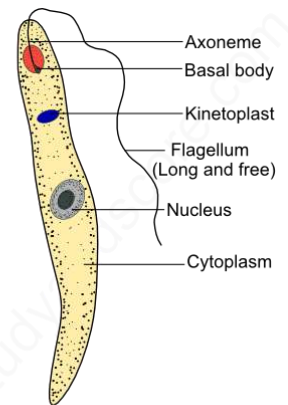
- **“LEISHMANIA STAGE”.**
- **Ovoidal** shaped.
- Single nucleus with karyosome.
- Parabasal body.
- Blepharoplast.
- Axoneme.
- Found intracellularly in monocytes, endothelial cells of man and other vertebrate.
- **NON-FLAGELLATED STAGE**
- Non-motile.



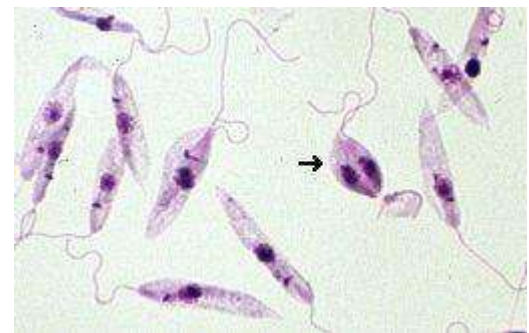


## PROMASTIGOTE

- **“LEPTOMONAS STAGE”.**
- **Spindle – shaped body.**
- Presence of single free flagellum arising from kinetoplast and kinetosome at anterior end.
- 15 – 20 um 1.5 – 3.5 um.
- No undulating membrane.
- Found in insects hosts and culture media.



LEISHMANIA: PROMASTIGOTE FORM



## EPIMASTIGOTE

- **“CRITHIDIA STAGE”.**
- **Spindle-shaped**, longer.

- Parabasal body. The kinetoplast and kinetosome are still located between the nucleus and the anterior end.
- Blepharoplast.
- Axoneme □ flagellum.
- A Short Undulating membrane lies along the proximal part of the flagellum.
- Flagellum - found/starts at the center of the body.

### TRYPOMASTIGOTE

- **“TRYPANOSOMA STAGE”**
- Nucleus located anterior to kinetoplast.
- Full body length undulating membrane.
- Body of the parasite is curved.
- Flagella – start at the posterior part of its body from kinetoplast and kinetosome.
- This stage is characteristic of blood-stream forms of the genus *Trypanosoma* as well as of the infective metacyclic stages in the tsetse fly vector.

## Hemoflagellates

### Family: Trypanosomatidae

#### Genus *LEISHMANIA*

1. There are three species recognized according to clinical entities:

1. *Leishmania tropica* : causes: **Cutaneous Leishmaniasis**
2. *Leishmania braziliensis* : causes: **Mucocutaneous Leishmaniasis**.
3. *Leishmania donovani* : causes: **Visceral Leishmaniasis**.

Differentiation among species causing disease in human is difficult, based on Clinical grounds.

### ***Leishmania* appears in two morphological stages**

#### **1. Amastigote**

- Found intracellularly in vertebrate host (human).
- The saliva of sand flies contains factor(s) that enhance their infectivity for macrophages by inhibiting the L-arginine-dependent nitric oxide killing mechanism of macrophages.

#### **2. Promastigote**

- Found in midgut of intermediate host female (sand flies).

### **In Iraq, the following species of *Phlebotomus* are found:**

- 1- *Phlebotomus papatasi*. ----- *L.donovani*.
- 2- *Phlebotomus sergenti*. ----- *L.tropica*, *L.major*.
- 3- *Phlebotomus alexandri*. ----- *L.tropica*.
- 4- *Phlebotomus sergentomyia* ----- *L.tropica*.

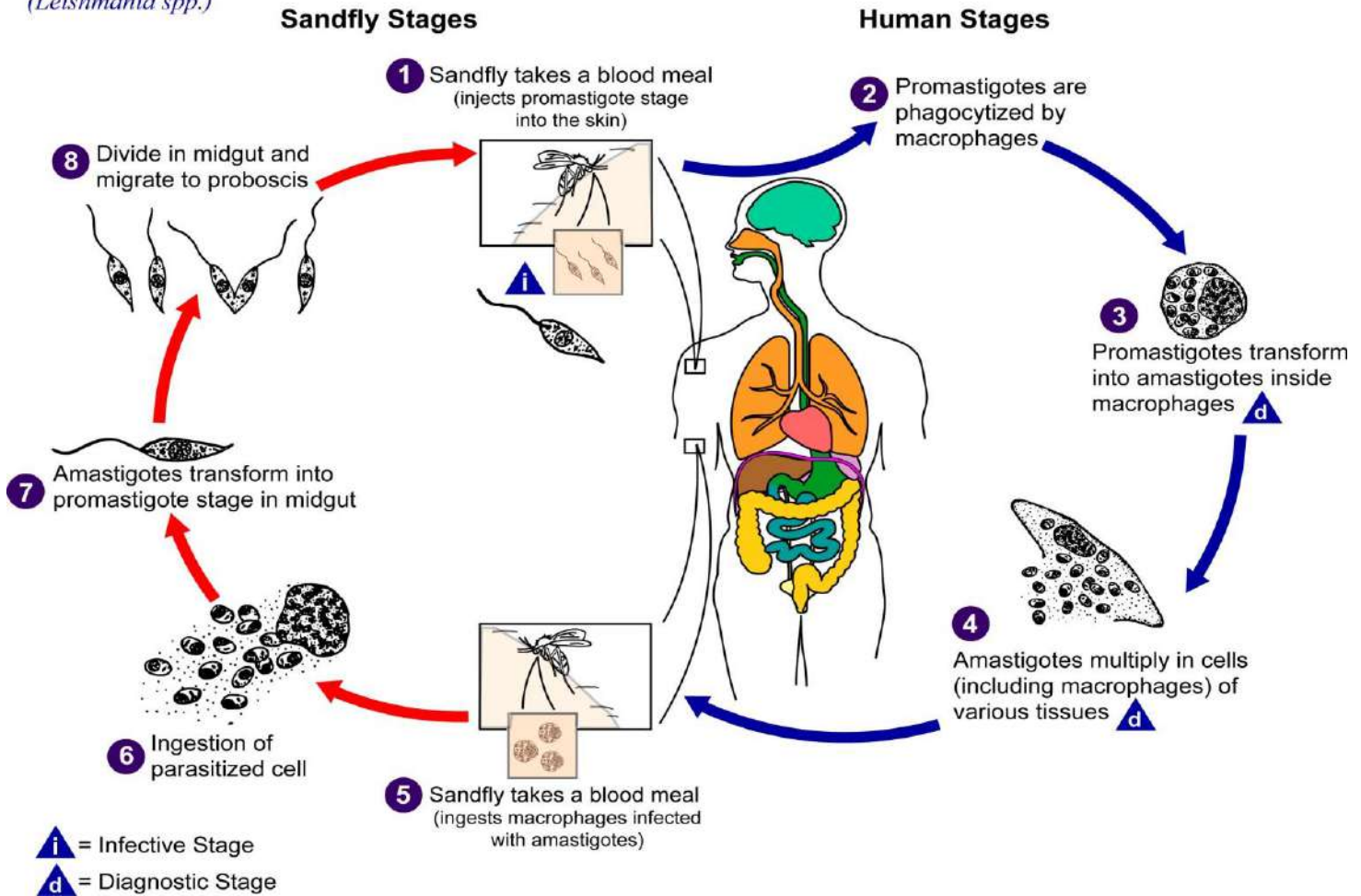
### **Life cycle**

*Leishmania* are transmitted by the biting of the insect sandflies of the genus *Phlebotomus*, which are the intermediate hosts and vectors for *Leishmania* species. When the fly take blood containing **amastigote** stages, the parasites multiply in the **midgut** and move forward to the esophagus and pharynx of the fly in the form of **promastigotes**, by the **fourth** or **fifth** day after feeding. They are then inoculated into the next mammalian victim including human. There, they are multiply in the **reticuloendothelial** system and **lymphoid cells** of the skin by **binary fission** in the farm of **amastigote**.



# Leishmaniasis

(*Leishmania spp.*)



## *Leishmania tropica*

- ❖ Causative agent of CUTANEOUS LEISHMANIASIS
- ❖ Old World Cutaneous Leishmaniasis ,Oriental Sore, Delhi boil, Baghdad boil, Jerico boil, Aleppo button.

## Geographical distribution:

- ❖ Palestine, Jordan, Iran, Portugal, Spain, Southern France, North Africa, Southern France, North Africa, Southeast Asia, Countries in the mediteranean, Europe, & Central America.



**Habitat:**

- *Leishmania tropica* is a parasite of skin of human.
  - 1– **Endothelial** cells of capillaries of infected areas.
  - 2– Nearby **lymph nodes**.
  - 3– Within **mononuclear cells, neutrophilic leukocyte**.
- Not found peripheral blood.
- Rarely disseminate.
- **Mainly cutaneous.**

**FINAL HOST:** man

**INTERMEDIATE HOST:** Sandfly (*Phlebotomus spp.*)

- 1- *Phlebotomus papatasi*
- 2- *Phlebotomus sergenti*
- 3- These are riverine insects.

**There are two types** of oriental sore (cutaneous Leishmaniasis) distinguished on the basis of **clinical, immunological and epidemiological grounds:**

#	City form or Dry lesion / Urban area	Village form or Moist (Wet) lesion / rural area
1	A chronic course with numerous parasite in the lesion	Acute course with scanty parasite in the lesions
2	The skin remains unbroken for months before ulceration takes place	lesions ulcerate in about a week or two

- 1- *Leishmania tropica* causes **City** form or **Dry** lesion / **Urban** area.
- 2- *Leishmania major* causes **Village** form or **Moist (Wet)** lesion / **Rural** area.
- 3- *Leishmania aethiopica* causes **Village** form or **Mosit (Wet)** lesion/**Rural** area.

***Leishmania major*** species is found In **Iraq**.

**Reservoir hosts:** Dogs, cats, cattle, sheep, jackals, and ground squirrels.

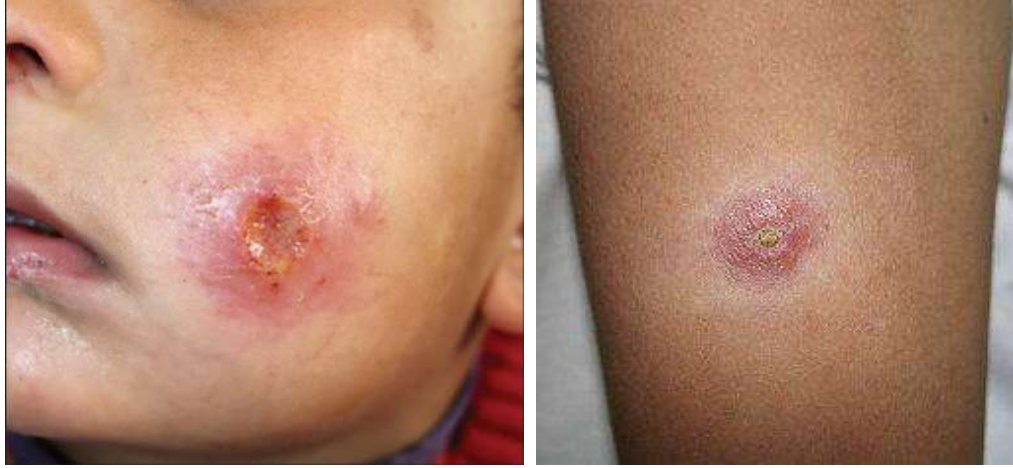In Iraq, gerbils are important reservoir hosts.

#### **Mode of Transmission:**

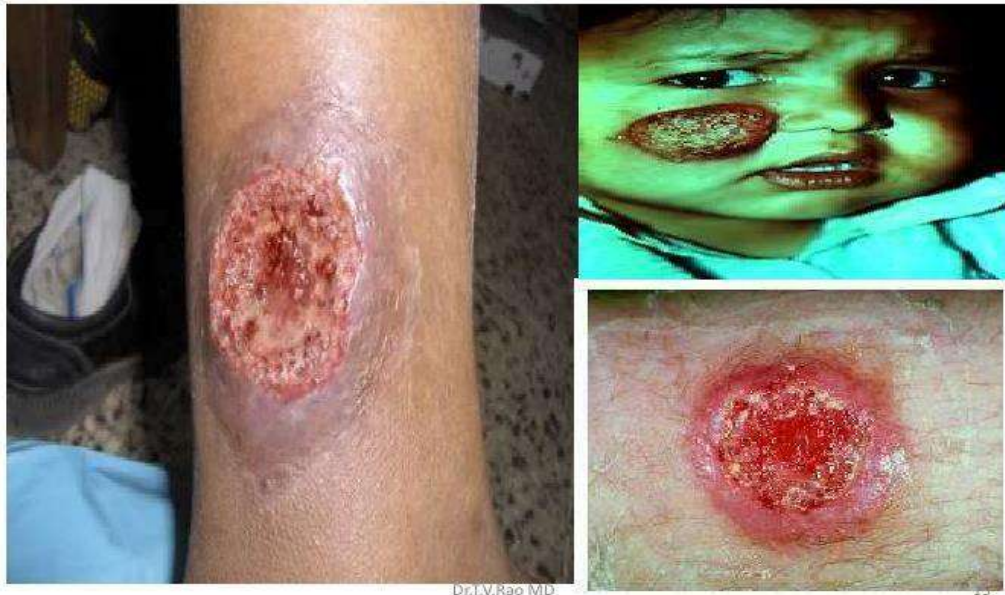- **Cyclical or biological** transmission by insect vector.
- **Mechanical** transmission by various means.
- **Blood** transfusion.

#### **PATHOLOGY:**

- **Incubation period:** 2 – 4 weeks.
- **Lesion** □ reddish papule, itchy, gradually enlarges, soft at center □ rupture □ ulcer formation (large raised with indurated edges).
- **Ulcer may be single / multiple.**
- Most often seen on exposed area of body.
- Bacterial infection are common.



## Cutaneous leishmaniasis



### DIAGNOSIS:

**Smear** of **exudate ulcer edge** stained with Wright/Giemsa / Leishman stain to demonstrate amastigote stage in the macrophages.

1. **Culture**- Novy MacNeal Nicole (NNN).
2. **Biopsy** of ulcer.
3. **Serology**.
4. **Intradermal** test.

## ***Leishmania donovani***

Causative agent of **VISCERAL LEISHMANIASIS**

- **Kala-azar disease.**
- **Dum-dum fever.**
- **Black disease.**

### **Geographical Distribution:**

Worldwide – India, Asia, Southern, Russia, Northern China, East Africa, all countries bordering Mediterranean.

### **HABITAT:**

- **Visceral organ.**
- **Reticuloendothelial cells.**
- **Bone marrow.**
- **Spleen.**
- **Lymph node.**
- **Liver.**

**FINAL HOST:** Man

**INTERMEDIATE HOST:** Sandfly (*Phlebotomus spp.*)

- *Phlebotomus argentipes*
- *Phlebotomus chinensis*
- *Lutzomyia*

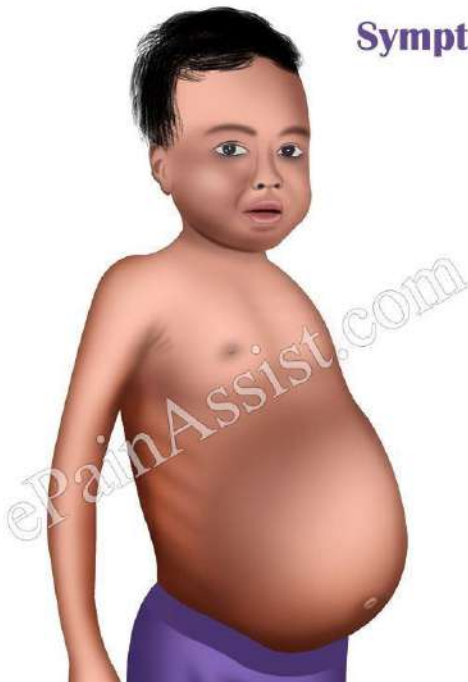

## MODE OF TRANSMISSION:

- 1- **Insect bite, biological of cyclical.**
- 2- **Blood transfusion, mechanical.**
- 3- **Congenital transmission.**
- 4- **Accidental needle stick injury, mechanical.**

## PATHOLOGY

- **Papule formation** at site of bite □ bloodstream □ engulf by macrophages & endothelial cells.
- **Incubation period:** 2 – 4 months.
- Headache, malaise, bleeding mucous membrane spleens & hepatomegaly.
- **Kala-azar - black fever.**
- **Splenomegaly.**
- **Hepatomegaly.**
- **Leukopenia.**



## Symptoms of Visceral Leishmaniasis

- Enlargement of the spleen
- Enlargement of the liver
- Night sweats
- Severe temperature or irregular bouts of fever that can last for weeks
- Bleeding
- Blackening of the skin
- Scaly skin
- Dark and ashen skin
- Cough
- Weakness
- Substantial weight loss

For More Information, Visit: [www.epainassist.com](http://www.epainassist.com)

- . **Death may occur**, in untreated cases in **2-3** years.
- . In some cases the symptoms may be more acute in onset with chills, fever up to **40<sup>0</sup> C** and vomiting and death may occur within **6-12** months.
- . A certain proportion of cases, especially in India, recover spontaneously.

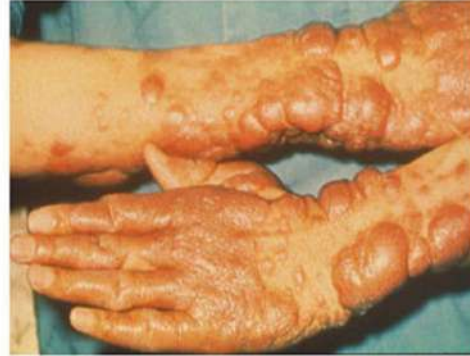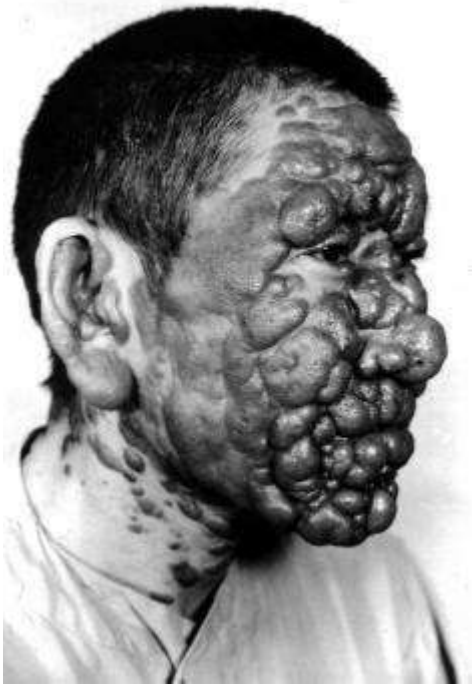## DIAGNOSIS

- **Demonstrate parasite** from blood & tissue Smear □ Amastigote.
- **Splenic puncture.**
- **Bone marrow aspiration.**
- **Hepatic/ Lymph node puncture.**
- **CULTURE MEDIUM: NNN (Novy MacNeal Nicole)**

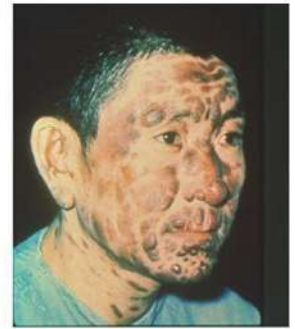## Dermal Leishmanoid (Post-Kala-Azar dermal Leishmanoid)

It is a condition of infective granuloma of the skin caused by *Leishmania donovani* subsequent to the cure of visceral affection. In **Bengal** it has been estimated that about 5-10% of the cured cases of kala azar disease show this complication. The condition usually becomes apparent in about 1-2 years after inadequate treatment, sometimes become quite disfiguring.





Post kala- azar dermal leishmaniasis



### ***Leishmania braziliensis***

- ❖ Causative agent of **MUCOCUTANEOUS LEISHMANIASIS**
- ❖ New World Cutaneous Leishmaniasis o Espundia, Bubas, Chiclero ulcer (*Leishmania mexicana*), Uta (*Leishmania peruviana*), American leishmaniasis

**Synonym : *L. tropica* var. *americana* .**

There are 3 nosologic types of disease evidently due to different strains.

Ulcerative ulcers:

- Peruvian Leishmaniasis or **Uta** on the ear.
- Mexican Leishmaniasis or **chiclero** ulcer on ear, but **Uta** persist longer in absence of treatment.
- **Espundia**: typical mucocutaneous Leishmaniasis, confined to **nasopharyngeal** tissue found in Brazil.
- Non ulcerative ulcer : Cauliflower like ulcers(warts).



**Geographical Distribution:** Central & South America.

**Morphology:** resembles *L. tropica*.

**Habitat:**

- **Tissue cell, endothelial cell, monocyte, mucous membrane, nose (nasal septum), mouth& pharynx.**
- Not found peripheral blood.
- Rarely localized in visceral organ.

**FINAL HOST:** Man

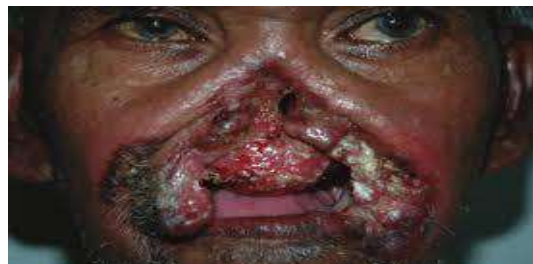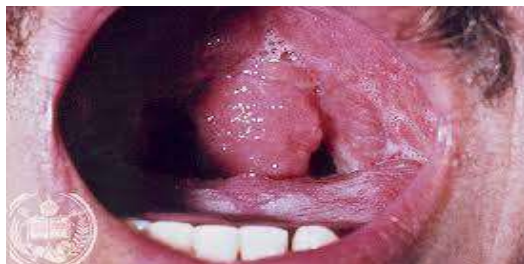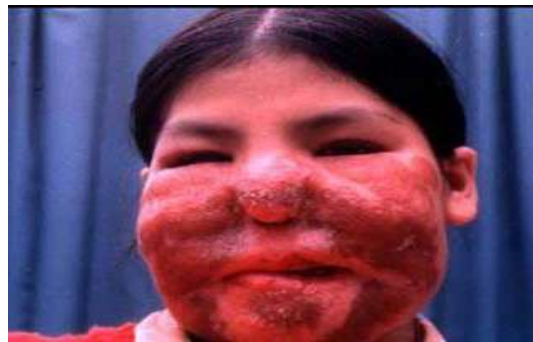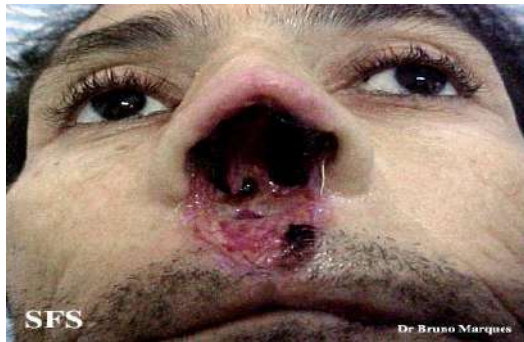**INTERMEDIATE HOST:** Sandfly (*Phlebotomus spp.*)

-*Phlebotomus peruensis*

-*Phlebotomus verucarrum* , *Lutzomyia*

**PATHOLOGY:**

- **Weeping lesion** (face, mouth, nasal cartilage of the facial bone).
- Erosion of nasal septum and palate (**Tapir nose**).

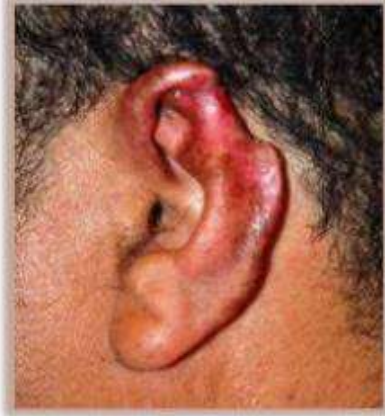

#### 4. "Uta"

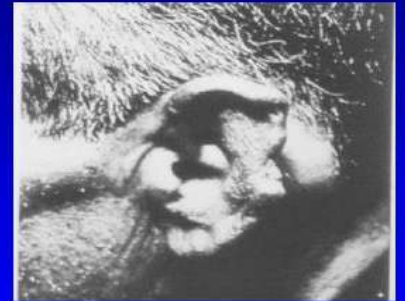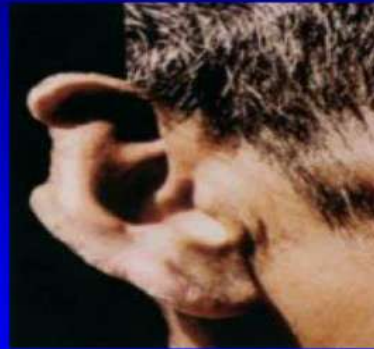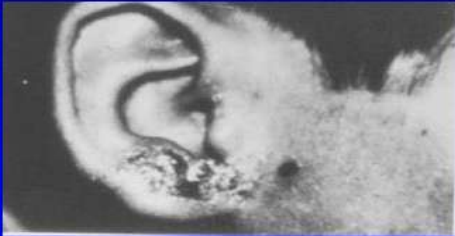- Occurs in the mountains of Peru
- Skin lesions occur
- No mucous membrane invasion

#### 5. Chiclero ulcer

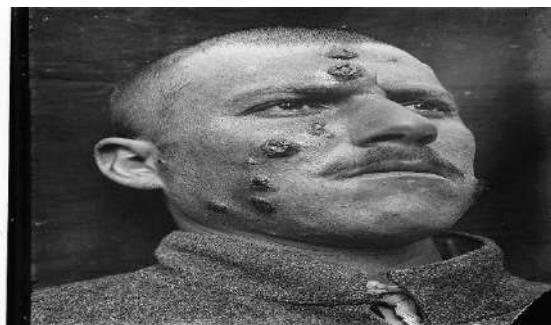- *L. tropica mexicana*
- Southern Mexico and Guatemala
- Small skin lesions
- Cause disfigurement of the ear
- chronic condition lasting for several years



## **Chiclero Ulcer *Leishmania mexicana* and *Leishmania tropica***



**Yucatan Peninsula and Central America.**  
**Sand flies in the genus *Lutzomyia* serve as vectors.**



Non-ulcerative cauliflower like ulcer- warts like

**DIAGNOSIS:**

- 1- **Smear from ulcer ® demonstrate amastigote stage.**
- 2- **Serology – CFT.**
- 3- **Culture – Novy MacNeal Nicole (NNN).**
- 4- **Montenegro Skin Test**

## Hemoflagellates

### Family: Trypanosomatidae

Trypanosoma. **Greek: trypanon** auger, borer.

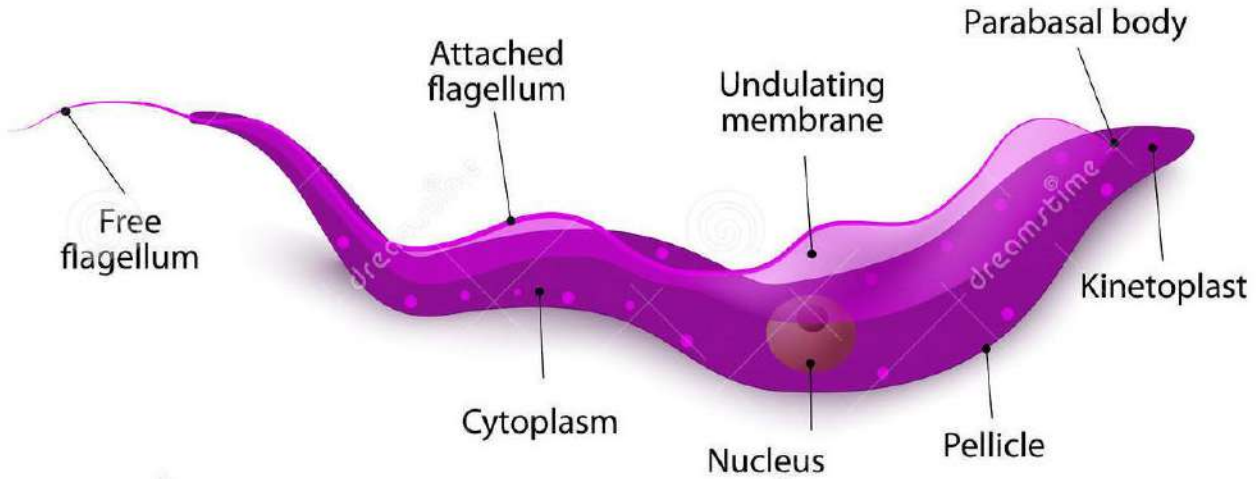
- Members of the **genus *Trypanosoma*** are parasites of all classes of vertebrates.
- Most live in the blood and tissue fluid, but some important ones, such as ***T.cruzi*** occupy intracellular habitats as well.
- Although other means of transmission exist, the majority are transmitted by blood- feeding invertebrates.

### The genus include:

- A. *Trypanosoma brucei gambiense*.
- B. *Trypanosoma brucei rhodesiense*.
- C. *Trypanosoma cruzi*.

### TRYPANOSOMA

- Elongated spindle – shaped body with more or less rounded posterior end & tapering anterior end.
- Single flagellum arising from blepharoplast & runs anterior to form the margin of undulating membrane.
- Oval nucleus at center with central karyosome.



**Transmission:** by the vector may take place:

- 1- Through the mouthparts of the insect vector (anterior station) **Salivaria**.
- 2- By the faecal contamination of the parasite of the invertebrate host (posterior station) **Stercoraria**, contaminating the puncture wound made by the vector in the skin or mucous membrane of the host.
- 3- In **T.equiperdum** of the horse, however, the transmission occurs through **coitus** with an infected animal and the insect vector is not needed in this case.

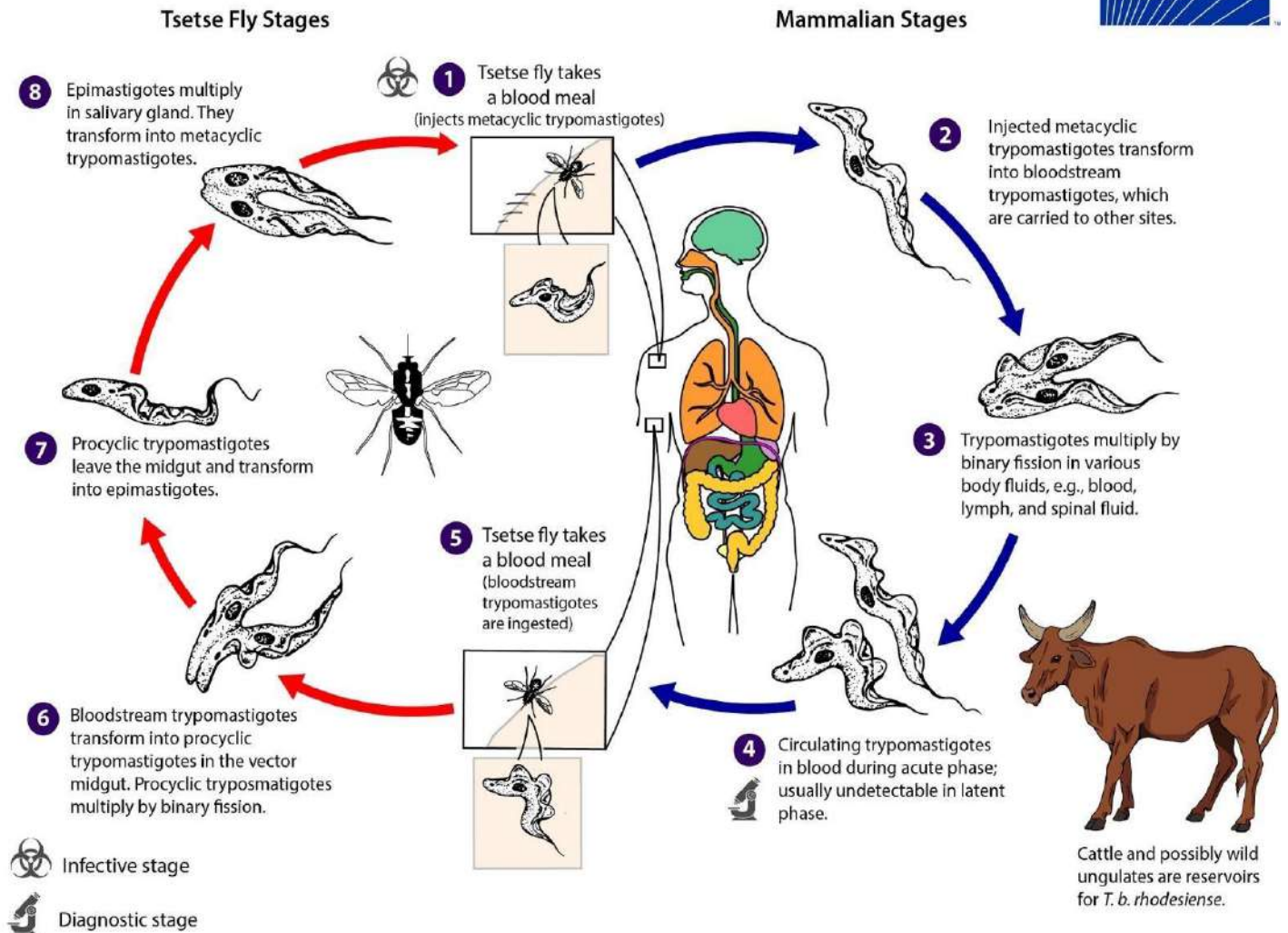


## Life Cycle



### African Trypanosomiasis

*Trypanosoma brucei gambiense* & *Trypanosoma brucei rhodesiense*



## MODE OF TRANSMISSION:

1. **Bite blood-sucking invertebrate, *Glossina* flies** (scientific name) or Tse – tse fly (common name).
2. Entrance / inoculation of parasite through **abrasion** / break skin.



## ***Trypanosoma brucei gambiense***

### **Disease:**

- **Gambian Sleeping Sickness.**
- **West African Trypanosomiasis.**

**Geographical Dist:** Central & West Coast of Africa.

### **Habitat:**

- **FEBRILE STAGE (Blood & Lymph nodes).**  
-fever, nausea, etc.
- **SLEEPING SICKNESS (Cerebrospinal fluid).**  
-the parasite can be found in the brain.

**Reproduction: Longitudinal binary fission every six hours.**

**Final Host:** Man.

**Intermediate Host:** Tse- tse fly (*Glossina spp.*)

- Glossina palpalis*
- Glossina fuscipes*
- Glossina tachinoides*.

**Infective Stage:** Metacyclic trypomastigote.

**Diagnostic Stage:** Trypomastigote (in blood).

**African *Trypanosoma* appears in two stages of development:**

- 1- **Trypomastigote** □ vertebrate host.
- 2- **Epimastigote** □ Invertebrate host.

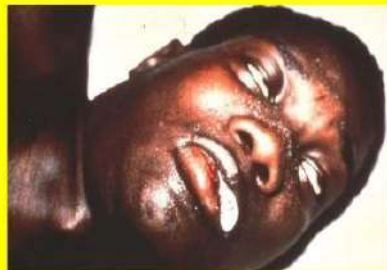### Habitat:

- **Blood.**
- **LN (lymph node).**
- **CSF.**
- **Connective tissue Intracellular space brain.**
- **Lymph channels throughout body.**

### PATHOGENESIS

- Adenitis – inflammation of lymph nodes.
- Tachycardia – rapid heart beat.
- Dizziness.
- Muscle pain.
- **Meningoencephalitis**
  - ❖ **1st year of infection: FEVER (ON/OFF)**
  - ❖ **2nd year of infection: SLEEPING**
  - ❖ **3rd year of infection: SLEEP (COMA) & DEATH**

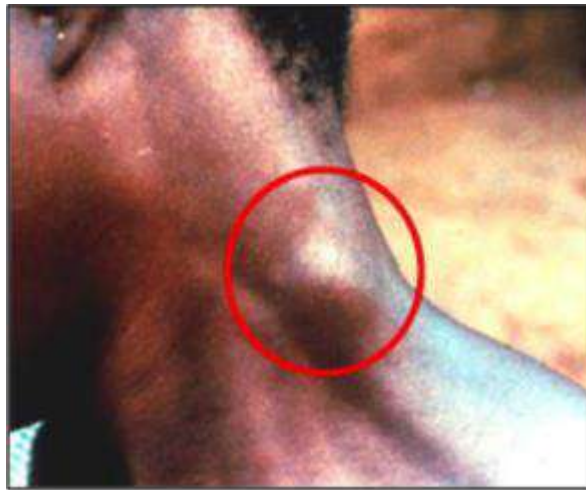### Human African Trypanosomiasis (African Sleeping Sickness)



- **Chancre** – location where the fly bite.
- **Winterbottom's sign** is a swelling of lymph nodes (lymphadenopathy) along the posterior cervical lymph node **chain**,

associated with the early phase of African trypanosomiasis (African sleeping sickness), a disease caused by the parasites *Trypanosoma brucei rhodesiense* and *Trypanosoma brucei gambiense*. The symptoms of illness usually are more marked in newcomers than in people native to endemic areas.

- **Tremore** of the tongue, hand and trunk is common, and paralysis or convolutions usually follow.
- **Sleepiness** increases, with the patient falling asleep even while eating or standing.
- **Finally**, comma and death ensue. Death may result from any one of a number of related causes including malnutrition, pneumonia, heart failure, other parasitic infections or a severe fall.



- **Kerandel's sign** – a delayed sensation of pain with deep hyperesthesia and pain over ulna.

## DIAGNOSIS

- **Microscopic examination smear from lymph.**
- **Blood (febrile) & CSF (sleeping sickness).**
- **Detect anti-trypanosome Antibodies**

### A. **Immunofluorescences test**

## B. Indirect hemagglutination test (IHAT)

**CULTURE MEDIUM:** NNN (Novy MacNeal Nicole) is a culture medium used to grow *Leishmania* and *Trypanosoma*. It consist of:

- 1- Agar 14 gm.
- 2- NaCl 6 gm.
- 3- D.W. 900 ml.

These components are put in a conical flasx mixed well, boiled and cooled, then poured into test tubes and closed by cotton. The tubes put in autoclave for sterilization at 15 pound pressure, and 110~120 C<sup>0</sup> for 20 minutes, then incubated in refrigerator for sterility and application.

## TREATMENT

- Pentamidine & Suramin: very effective if given during blood - lymphatic stage.
- Tryparsamide: 2-3 grams □ 15-20 weeks.
- Metarsoprol - for late stage with CNS involvement.

## *Trypanosoma brucei rhodesiense*

### Disease:

- East African Sleeping Sickness.
- Rhodesian Sleeping Sickness.

**Geographical Dist:** East Africa.

**Course of infection:** 1 year.

## Morphology, Pathogenesis, Life cycle

**Symptomatology** resembles *T. gambiense*:

- **More severe manifestation.**
- **Course rapid.**
- **Death early if CNS is involved.**
- **Fever, myalgia, rigor, lethargy, mental disturbance.**


**FINAL HOST:** Man

**INTERMEDIATE HOST:** Tse-tse fly (*Glossina spp.*)

-*Glossina morsitans*.

-*Glossina pallidipes*.

- *Glossina swynertoni*.



## **PREVENTION**

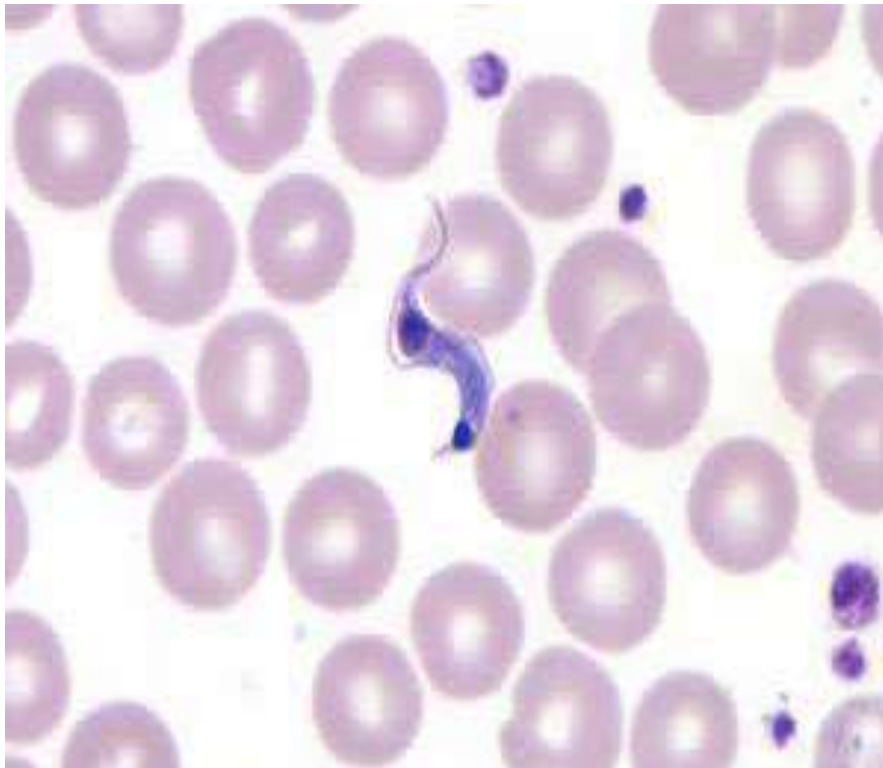
1. Reduction of contact with Tse-Tse flies through control measures against them (traps, screen, **insecticide**).
2. Reduction of human infection by diagnosis & treatment of infected person

## **Clinical Features:**

**Infection occurs in three stages.**

- A trypanosomal chancre can develop on the site of inoculation.
- This is followed by a hemolymphatic stage with symptoms that include fever, lymphadenopathy, and pruritus.
- In the **meningoencephalitic stage**, invasion of the central nervous system can cause headaches, somnolence, abnormal behavior, and lead to loss of consciousness and coma. The course of infection is much more acute with *T. b. rhodesiense* than *T. b. gambiense*.

**Thin blood smear stained with Giemsa.**



- The two *Trypanosoma brucei* species that cause human trypanosomiasis, *T. b. gambiense* and *T. b. rhodesiense*, are **undistinguishable morphologically**.



## ***Trypanosoma cruzi***

### **Synonym:**

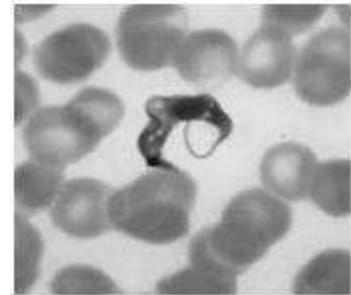
1. *Schozitypanum cruzi.*
2. *Trypanosoma escomele.*
3. *Trypanosoma triatoma.*

**Disease: South American Trypanosomiasis.**

**Chagas disease.**

### **Habitat:**

- **Reticulo endothelial cells.**
- **Cardiac muscle.**
- **Central Nervous system.**



### **Geographical Distribution:**

#### **Central & South America**

- ❖ ***T. cruzi***: American trypanosomiasis was first described by **Carlos Chagas** in Brazil in 1909. The infection, Chagas' disease, is caused by the hemoflagellate *T. cruzi*.
- ❖ ***T. cruzi***: the disease is a public health threat in most Latin American countries, although cases due to blood derivatives or blood transfusion has been reported in non-endemic regions.

### **Method of Transportation (MOT) Life cycle:**


- 1- **Bite of reduviid bug which defecate at site of inoculation.**

- 2- Accidental ingestion of bug.
- 3- Blood transfusion.
- 4- Infection can also be acquired by congenital transmission (transplacentally).
- 5- Organ transplantation.



### Intermediate host:

- Reduviid bug.
- Virgin bug.
- Triatomid bug.
- Assassin bug.
- Kissing bug.
- Cone nose bug.
- *Triatoma rubro fasciata* (scientific name).



### Final host: Man.

### Reservoir hosts:

Many kinds of wild and domestic mammal such as **dogs, cats, opossums, armadillos, and wood rats**, are particularly important in the epidemiology of Chaga's disease.

### Morphology:

- It is slender, **16 ~ 20  $\mu\text{m}$**  long.

- It posterior end is pointed.
- The free flagellum is moderately long.
- The undulating membrane is narrow.
- The kinetoplast is subterminal and is the largest of any trypanosome, it sometimes causes the body to bulge around it.
- It dies in a question mark shape, the appearance is retains in stained smears.
- The amastigote develop in muscles and other tissues.

## Life Cycle

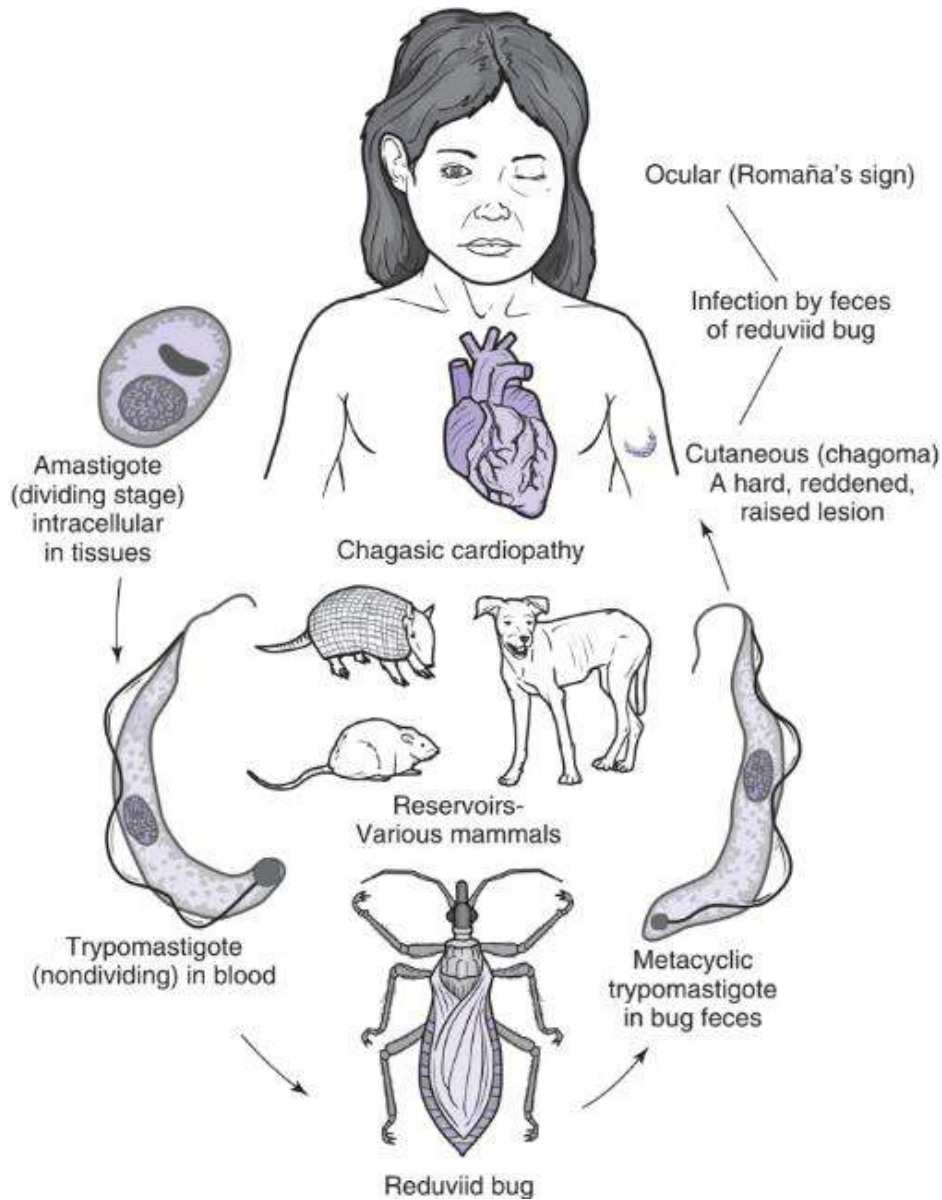
### i. In bugs :

- 1- Kissing bugs (larva, nymph and adult) bite people during the night around the eye region.
- 2- The **trypomastigotes** found in ingested blood transformed to epimastigotes in the (Mid gut) of the bugs.
- 3- These **epimastigotes** transformed to **metacyclic trypomastigotes** in the (Hind gut) of the infected bugs.

### ii. In human and other vertebrates:

- 4- During the feeding of bugs on human, they injected him with the **metacyclic trypomastigotes** ———→ via blood circulation reached (cardiac, muscle, liver, brain.....etc.)
- 5- These **metacyclic trypomastigotes** loose their flagella, undulating membrane and become smaller and (**Intracellular Amastigotes**). Multiply by binary vision and destroy the human cells. Return to the blood again in **trypanosome forms**.

6- These **trypanosome forms** either attack new other human cells repeatedly; or to be ingested by bugs to repeat new cycle.

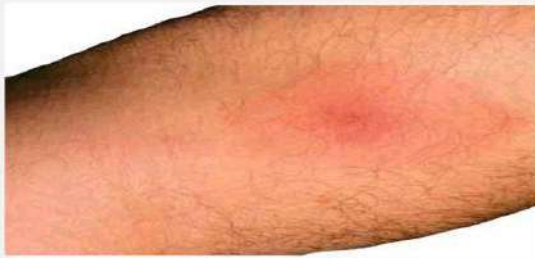

## **PATHOGENESIS**

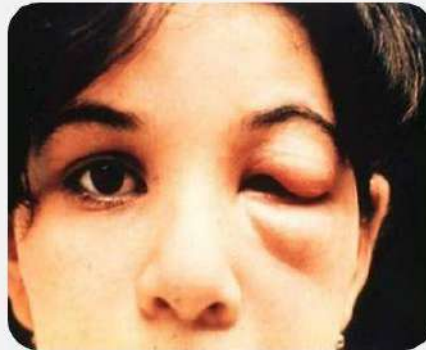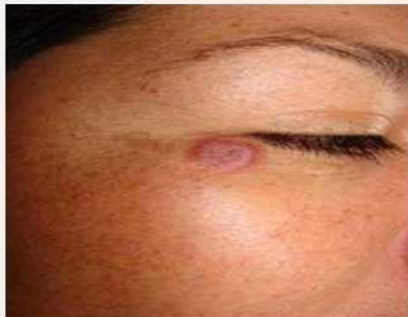- Chagas disease manifests **acute** and **chronic** phases, which may last 20 years or longer. It is serious and often fatal in young children, but less severe and to be chronic in older children and adults.
- The acute phase is initiated by inoculation into the wound of the trypanosomes from the bug's feces / bites.

- The local inflammation produces a small red nodule known as **CHAGOMA**, with swelling of the regional lymph nodes.
- When the trypanosomes enter through the conjunctiva of the eye, causing edema of the eyelid and conjunctiva and swelling of the preauricular lymph node. The symptom is known as **ROMAÑAS SIGN**, Peri orbital swelling of one side of the eyelid on the face near the wound or where the bug feces were deposited, or accidentally rubbed into the eye.
  - Allergic reaction.
  - Bite of the bug.

#### Clinical presentation of acute stage of Chagas' disease



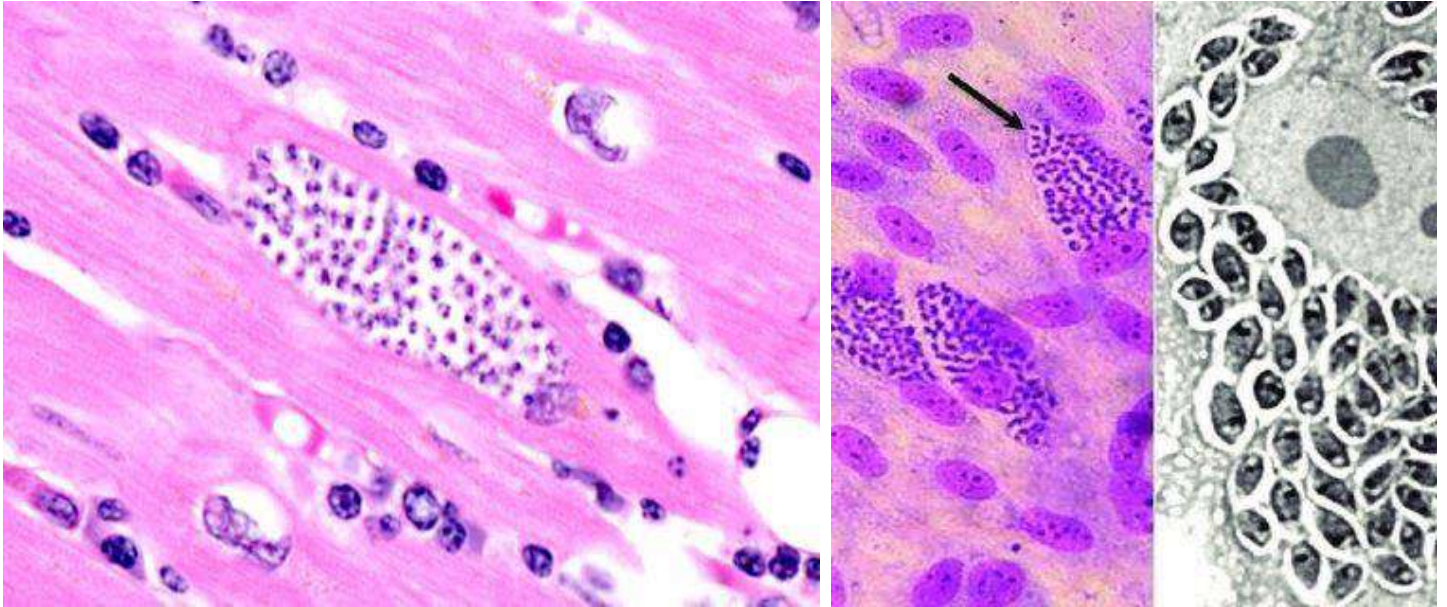
**Chagoma in skin**



**Romaña's sign:** swelling of eyelid in acute Chagas disease due to bug feces being accidentally rubbed into the eye, or because the bite wound was on the same side of the face.

- **EARLY STAGE: Few motile organism in the blood**
  - **ACUTE STAGE: Febrile stage.**
  - **CHRONIC STAGE: Sleeping sickness.**
- **Can invade heart, colon, spleen, and esophagus.**
- **MYOCARDITIS.**





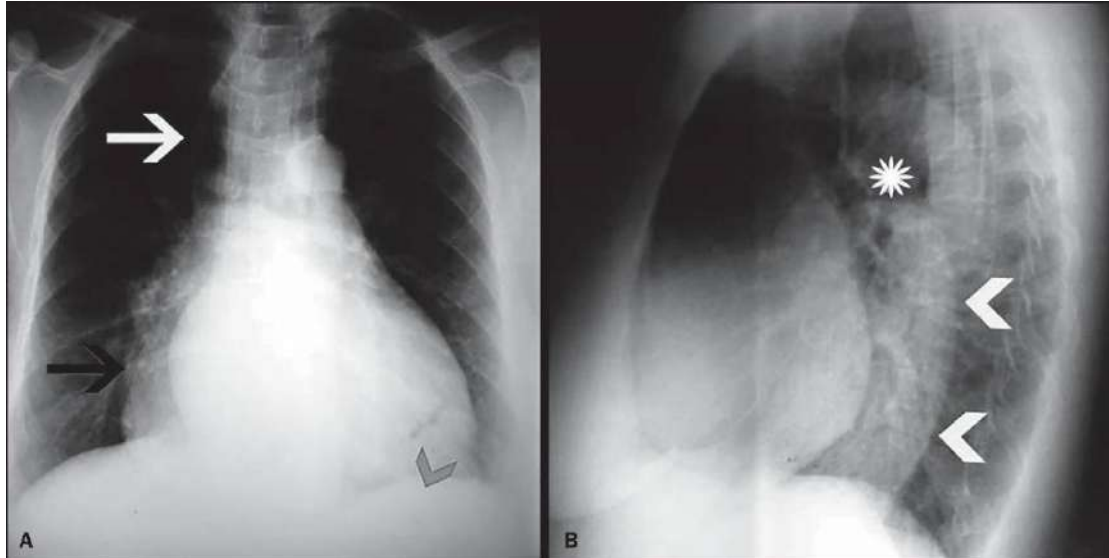
- **MEGACOLON**: In some region of South America, it is common for autonomic ganglia of the esophagus or colon to be destroyed. This ruins the tone of the muscle layer resulting in deranged peristalsis and gradual flabbiness of the organ, which may become huge in diameter and unable to pass material within it.

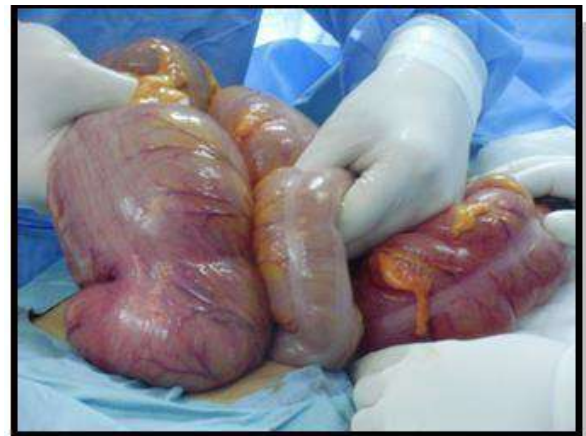
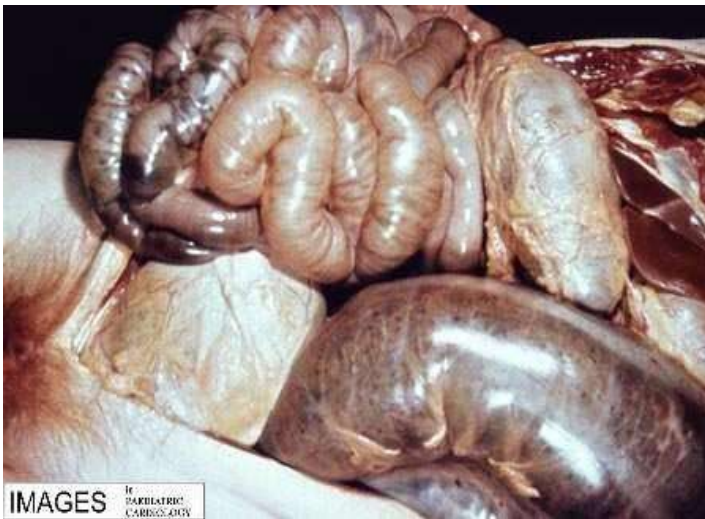
Figura 1. Dolicomegasigma, megacolon chagásico, sigmoides elongado y dilatado.

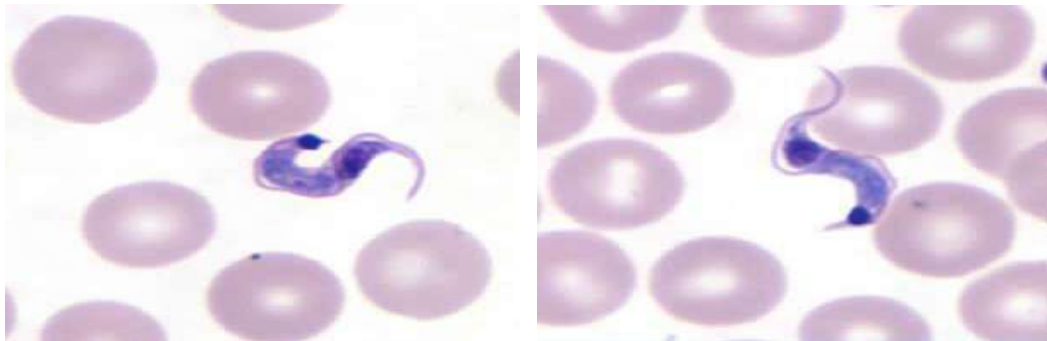
- **MEGAESOPHAGOUS**: Advanced megaesophagous may be fatal when the patient can no longer swallow.





### LAB DIAGNOSIS:

- **Microscopic** demonstration of parasite stained blood smear / lymph node aspirate.



- **Culture** NNN med or Chang's medium.
- **Serological**: CF (Complement Fixation).
- **XENODIAGNOSIS** – uses virgin bug (cultured in the lab) for the diagnosis.
- **Cruzin's test**.

### PROGNOSIS:

- **Bad if CNS & Heart involved.**

## Developmental stages of species of Trypanosomatidae pathogenic for man.

	Amastigote	Promastigote	Epimastigote	Trypomastigote
<i>Leishmania tropica</i>	+	+	-	-
<i>Leishmania donovani</i>	+	+	-	-
<i>Leishmania braziliensis</i>	+	+	-	-
<i>Trypanosoma rhodesiense</i>	-	-	+	+
<i>Trypanosoma gambiense</i>	-	-	+	+
<i>Trypanosoma cruzi</i>	+	+	+	+

## TREATMENT

- Primaquine (partially effective).
- Nifurtimox (acute cases) o there is no entirely available drug for treatment / prevention of the disease.

# PARASITOLOGY

## How to study human parasitology?

- listen to the teachers in class carefully.
- Observe the specimens in laboratory carefully.
- Review the knowledge points frequently.
- Discuss with teachers or other students actively.
- Read textbooks or related websites extensively.

## Teaching requirements

- (Knowledge points)
  - GRASP (KNOW VERY WELL):
  - Morphology and life cycle of parasites;
  - FAMILIARIZE (KNOW WELL):
  - Pathogenesis and diagnosis of parasitic diseases.
  - UNDERSTAND (KNOW):
- Prevalence, and the prevention and control of parasitic diseases.

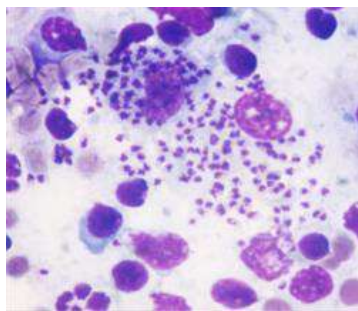
**Parasitology:** is the science, which deals with organisms that take up their abode, temporarily or permanently, on or within other living organisms (hosts) for procuring food. It is a dynamic field because the relationships between the parasites and their hosts are constantly changing.

**Parasites:** are organisms adapts themselves to live in or on another organisms termed host.

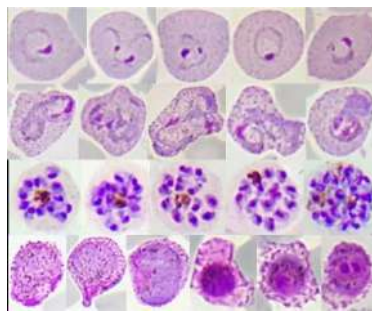
Parasite (para = beside, sitos = food).

The parasite must live on the interest (host secretions and tissues) not on the capital (the host itself)

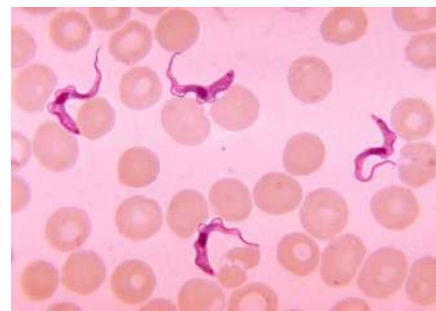The parasites may be either **Intracellular** (inside the cells) or **Intercellular** = **Extracellular** (between the cells).



*Leishmania*  
(Intracellular)



*Plasmodium*  
(Intracellular)



*Trypanosoma*  
(Intercellular)

As a role **Parasite** cannot survive or even exists without a host.

Parasites of animal kingdom are divided into three main groups, namely:

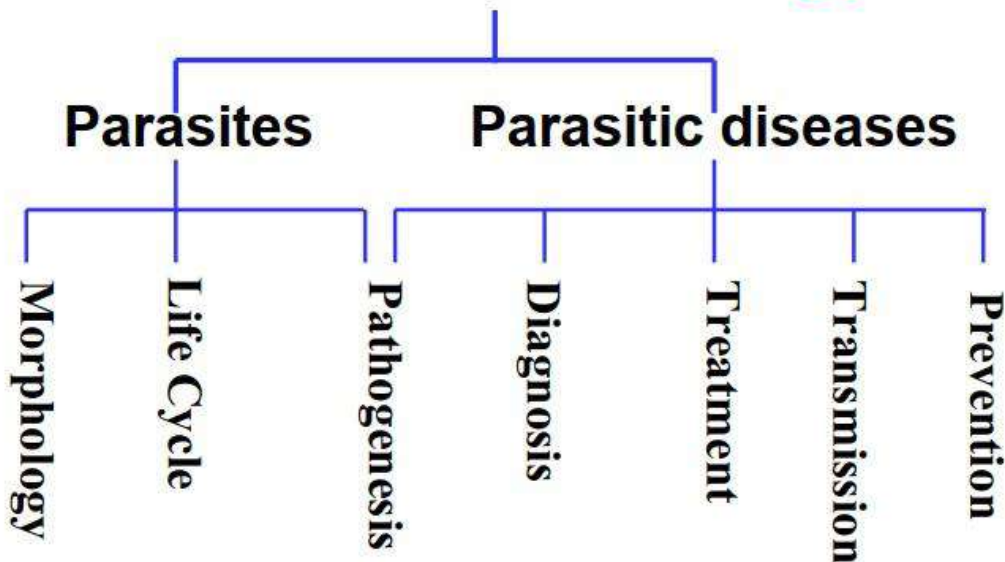
- **Protozoa.**
- **Helminths.**
- **Arthropods.**

Accordingly parasitology may be divided into three sections:

- **Medical Protozoology.**
- **Medical Helminthology.**
- **Medical Entomology.**

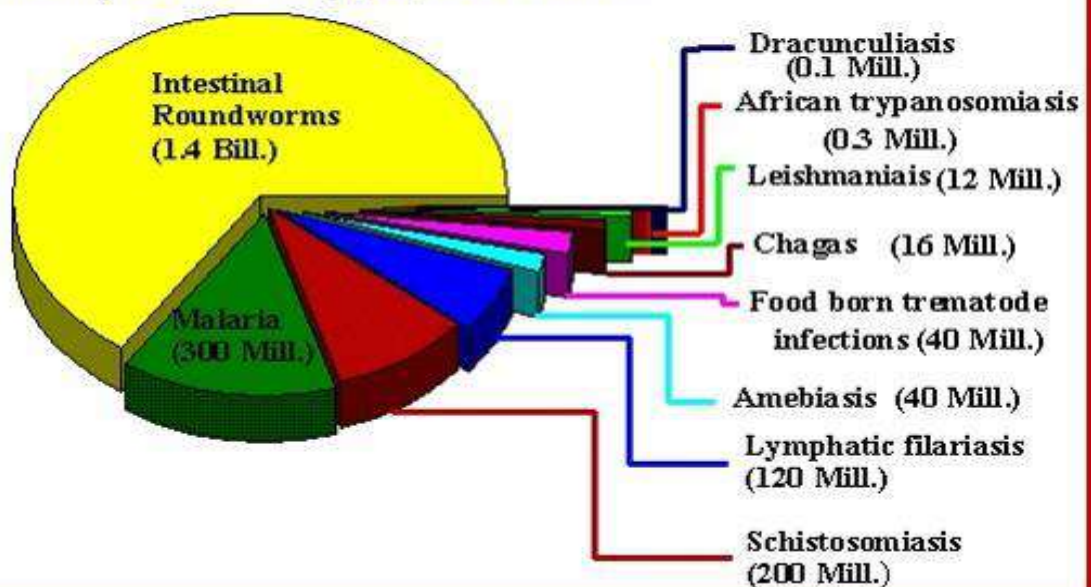
**Parasitism** is literally meaning beside food, it adapted from ancient Greeks who describe a person who came to dinner uninvited as a parasite.

## Medical Parasitology



### Parasitic infections

What are they and how many people have them?



### Types of parasites:

- **Ectoparasite:** lives outside on the surface of the body (infestation), e.g. **Ticks**.
- **Endoparasite:** lives inside the body of host (infection), e.g. **Helminths**.
- **Temporary or intermittent parasite:** visits the host from time to time for food, e.g. **mosquitoes**.
- **Permanent parasite:** remains on or in the body of the host for its entire life, e.g. **T.saginata**.
- **Facultative parasite:** organism that can exist in a free-living state or as a parasite, e.g. **Naegleria**, **Acanthamoeba**.
- **Obligatory parasite:** cannot survive without a host i.e. completely adapted for parasitic existence, e.g. **P.vivax**.
- **Opportunistic parasite:** produces disease only in immune deficient or immuno-suppressed patients (**AIDS**). In immunocompetent individuals, the organisms may exist in latent form producing no symptoms, e.g. **I.belli**, **Cryptosporidium parvum**.
- **Coprozoic or spurious parasite:** foreign organisms which have been swallowed merely pass along alimentary canal of man (**without establishment**) to be recovered in faeces, e.g. eggs of animal helminths.
- **Accidental or incidental parasite:** when a parasite attacks unusual host and survive, e.g. **Hymenolepis diminuta** (rat tapeworm) attacks man.
- **Aberrant parasite:** organism attacks the host when they cannot live or develop further, e.g. **Toxocara canis** in man.
- **Errantic parasite:** is one that wanders into an organ in which it is not usually found, e.g. **Entamoeba histolytica** in the liver and brain of humans.



## Host- parasite relationships or Association of organisms

There are **two** general categories of organisms within the ecosystem based on whether or not they enter into **intimate association** with another organism of a different species during all or part of their life cycles.

- 1) **Free-living organisms**: they do **not enter** into intimate association.
- 2) **Symbionts**: they do **enter** into intimate association, which called **symbiosis**, which mean to live together. The **symbiosis** includes the following relationships:

**Mutualism**: An association, in which both host and parasite are so dependent upon each other that one cannot live without the help of the other, depends metabolically/ physiologically on each other. Neither of the partners suffers from any harm from this association, e.g. ciliated protozoa living in the gut of ruminants.

**Commensalism**: an association in which only parasite may benefit without detectable damage to the host as in case of *Entamoeba coli* in the large intestine of man, (One partner benefits but the other is not hurt).

**Parasitism**: one partner (the parasite) harms or lives on the expense of the other (host) metabolically/ physiologically. The degree of dependence of a parasite on its host varies.

## Hosts

**Host:** is an organism that harbours a parasitic, a mutualistic, or a commensalist guest (**symbiont**), the guest typically being provided with nourishment and shelter.

### Types of hosts:

- A. Definitive or final host:** host with adult stage or sexually reproducing forms of the parasite.
- B. Intermediate host:** host with the larval stage or asexually reproducing forms of parasite.
- C. Reservoir host:** with respect, to human parasites, are hosts that are infected with a parasite and keep it alive even if the parasite wiped out in humans, and can spread the parasite and reintroduce it to human population.
- D. Vector:** an arthropod, which carries the parasite from one host to another.
- E. Paratenic or transport host:** is one in which the parasite does not undergo any development, but in which it remain alive and infective to other host. Paratenic hosts may bridge an ecological gap between the intermediate and definitive hosts.

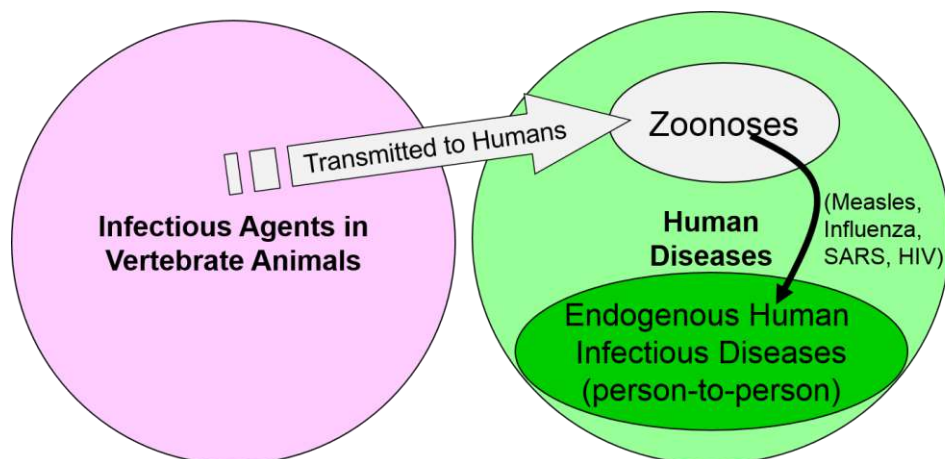
### Common pathways for the transmission of parasites:

- **Paroral** by food or water contamination (e.g., roundworm, amoebae)
- **Percutaneous**, i.e., skin penetration (e.g, hookworms, blood flukes)

- **Transmissible** by insect vectors (e.g., mosquito - malaria, sand fly - leishmaniasis, housefly- Amoebic cysts).
- **Transplacental** from pregnant woman to fetus (e.g., malaria, toxoplasma).
- **Sexual intercourse** (e.g., trichomonas, amoebae)
- **Air-borne**, i.e., inhalation of contaminated dust or air (e.g, pinworm)

## Zoonosis

- Disease transmitted from animals to man are known as zoonotic diseases



**Health** is a state of complete physical, mental and social well-being and not merely the absence of disease or infirmity.

**Disease** is a particular abnormal condition, a disorder of a structure or function that affects part or all of an organism.

## Important terminology

Prevalence = % of infection.

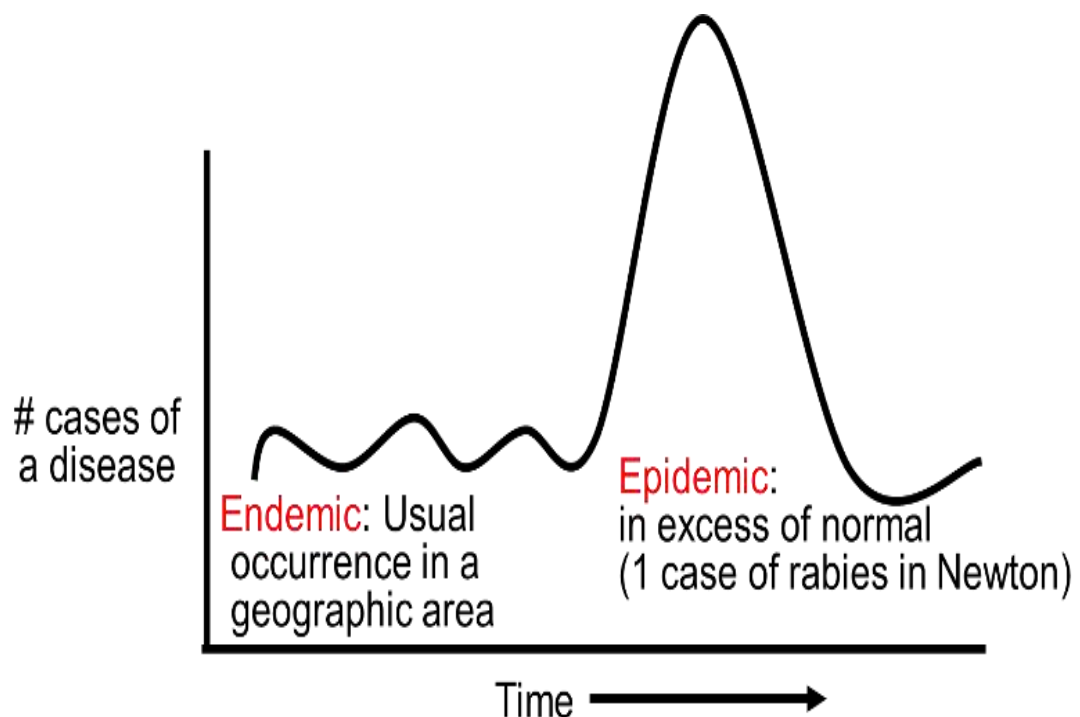
Intensity = number of parasite in the host.

**Incidence = % of new infection**

### **Endemicity (Epidemiology)**

The branch of medicine, which deals with the incidence, distribution, and possible control of diseases and other factors relating to health. It may be as **follow**:

- ❖ **Endemic infection**: when a steady rate of parasitic infection is prevalent all year around in a particular area causing a low rate of morbidity in population of this area.
- ❖ **Hyper - endemic infection**: when prevalence is high causing a high rate of morbidity.
- ❖ **Epidemic infection**: when there is a sharp increase in the incidence, prevalence and morbidity rates. Epidemic outbreaks are usually due to introduction of a new parasite or vector in a non-immune population.
- ❖ **Sporadic infection**: when a parasite appear occasionally in one or few members of a community.



## Nomenclature of parasites

All known parasites are classified and named according to **binomial nomenclature** or **Trinomial nomenclature**.

- 1- In **binomial nomenclature**: each parasite has two names: a **genus** and **species** name. The **generic** name of the parasite always begins with an **initial capital letter** and **species** name with a **small letter**, e.g. *Entamoeba histolytica*, *Homo sapiens*, etc....
- 2- In **Trinomial nomenclature**: when the parasite has three names: a **generic, specific and sub-specific** name, e.g. *Trypanosoma brucei gambiense*, *Trypanosoma brucei rhodesiense*, etc....

### Life cycle and type of life cycle

- ❖ **Life cycle**: The whole process of parasite growing and developing.
- ❖ **The direct life cycle**: When a parasite requires only one host to complete its development, it is referred as direct/simple life cycle. **Life cycle with one host.**
- ❖ **The indirect life cycle**: When a parasite requires two hosts (one final host and intermediate host) to complete its development, it is indirect/ complex life cycle. **Life cycle with more than one host.**

## Classification of animal parasites

Parasites of medical importance come under the kingdom called **Protista** and **Animalia**. **Protista** includes the microscopic single-celled eukaryotes known as **protozoa**. In contrast, **helminthes** are macroscopic, multicellular worms possessing **well-differentiated** tissues and complex organs belonging to the kingdom Animalia.

Phylum: Subphylum: Class: Order: Family: Genus: Species.

## Laboratory diagnosis

Depending on the nature of the parasitic infections, the following specimens are selected for laboratory diagnosis:

**A) Blood** – in those parasitic infections where the parasite itself in any stage of its development circulates in the blood stream, examination of blood film forms one of the main procedures for specific diagnosis. For example, in malaria the parasites are found inside the red blood cells. In Bancroftian and Malayan filariasis, microfilariae are found in the blood plasma.

**B) Stool** – examination of the stool forms an important part in the diagnosis of intestinal parasitic infections and also for those helminthic parasites that localize in the biliary tract and discharge their eggs into the intestine. In protozoan infections, either trophozoites or cystic forms may be detected; the former during the active phase and the latter during the chronic phase. Example, Amoebiasis, Giardiasis, etc. In the case of helminthic infections, the adult worms, their eggs, or larvae are found in the stool.

**C) Urine** – when the parasite localizes in the urinary tract, examination of the urine will be of help in establishing the parasitological diagnosis. For example in urinary Schistosomiasis, eggs of *Schistosoma haematobium* are



found in the urine. In cases of chyluria caused by *Wuchereria bancrofti*, microfilariae are found in the urine.

**D) Sputum** – examination of the sputum is useful in the following:

- In cases where the habitat of the parasite is in the respiratory tract, as in Paragonimiasis, the eggs of *Paragonimus westermani* are found.
- In amoebic abscess of lung or in the case of amoebic liver abscess bursting into the lungs, the trophozoites of *E. histolytica* are detected in the sputum.

**E) Biopsy material** - varies with different parasitic infections. For example spleen punctures in cases of kala-azar, muscle biopsy in cases of Cysticercosis, Trichinelliasis, and Chagas' disease, Skin snip for Onchocerciasis.

**F) Urethral or vaginal discharge** – for *Trichomonas vaginalis*

**Indirect evidences** – changes indicative of intestinal parasitic infections are:

**a. Cytological changes in the blood – eosinophilia** often gives an indication of tissue invasion by helminthes, a reduction in white blood cell count (**leukopenia**) is an indication of kala-azar, and anemia is a feature of hookworm infestation and malaria.

**b. Serological tests** – are carried out only in laboratories where special antigens are available.

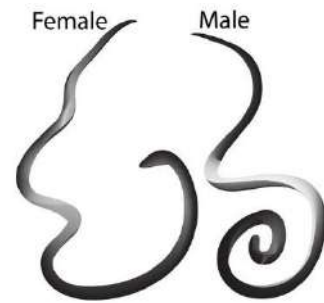
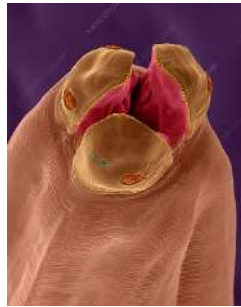
## Phylum Nematoda = Nemathelminthes

### Characters:

- 1- Bilateral symmetry.
- 2- Body unsegmented.
- 3- Digestive tract: complete. mouth, intestine and anus.
- 4- Pseudocoel present.
- 5- Excretory system in the form of lateral canals.
- 6- Nerve ring in the esophagus and 3 pairs of nerves.
- 7- Circulatory and respiratory organs lacking.
- 8- Sexes separate, female much larger than the male.
- 9- Size, varying (*Ascaris* =15-30 cm, *E.vermicularis*= 2-5 mm).

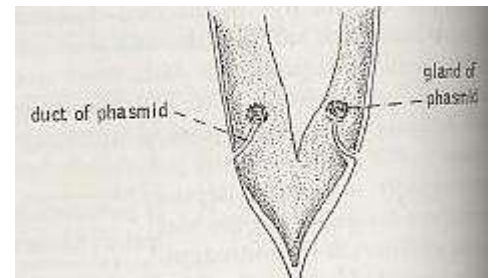
### Mouth modifications:

- 1- Lips- 1-6.
- 2- No lips.



**Phasmid:** caudal chemoreceptor organs (special sensory organs) situated on minute papillae behind the anus.

- 1- Phasmid nematodes
- 2- Aphasmid nematodes.

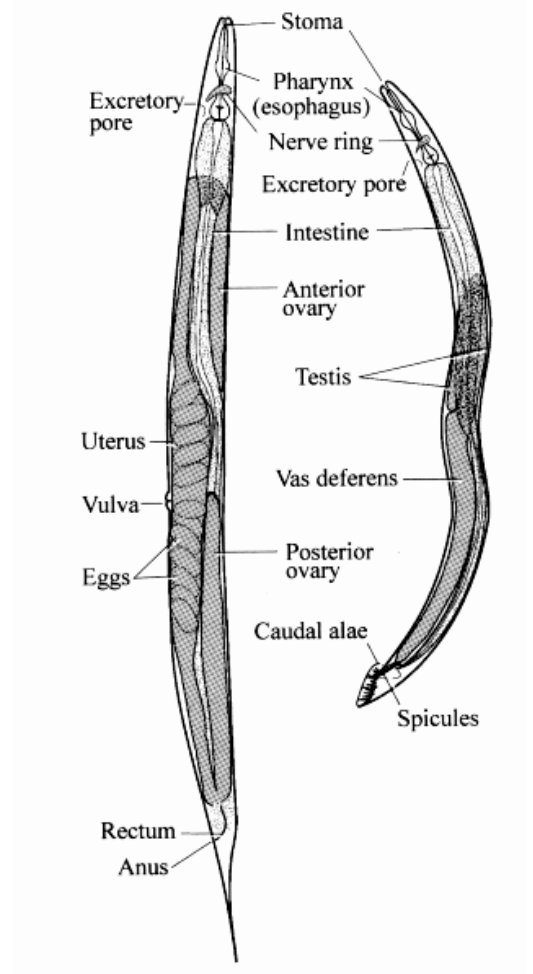


### Male reproductive organs:

- Single testis= Monarchic or Monodelphic .
- Vas deferens.
- Enlarged seminal vesicle.
- Ejaculatory duct.
- Spicules (if present) 1-2.

### Female reproductive organs :

- 1- Ovary (1 or 2)=Diorchic or Didelphic.
- 2- Oviduct.
- 3- Seminal receptacle.
- 4- Uterus.
- 5- Ovejector.
- 6- Vagina.
- 7- Vulva.



Female nematodes can be classified according to **Oviposition** (egg laying):

- 1- **Vivi-parous = Larviparous = Laying larvae**, e.g. *Dracunculus medinensis* , *Wuchereria bancrofti* , etc.
- 2- **Ovi-parous = Egg laying**, e.g. *Ascarsis*, *Trichuris*, etc.
- 3- **Ovo-oviparous =Egg** having larvae which hatched outside the body, e.g. *Strongyloides Stercoralis*.

**Digestive System:** The nematodes have a complete digestive tract. Find the mouth opening at the blunt end of the worm. The mouth opens into the characteristic **pharynx**. In most cases, the pharynx is highly muscular -- it often has a terminal bulb where it joins the intestine. A nerve ring encircles a constriction of the pharynx, but it is seldom visible. The pharynx is continuous with the thin-walled **intestine** (which lacks any musculature). The digestive system terminates near the end of the worm at the **anus**. (In male nematodes the reproductive and digestive system join together forming a **cloaca**, which terminates at the anus.)

## Classifications of phylum nematoda

Members of phylum nematode can be distinguished from other pseudocoelomate groups by their possession of spicules and a ventral excretory pore.

### 1- Class Enoplea= Adenophorea = Aphasmidea

#### Order Trichurida

#### Families:

#### Trichinellidae.

#### Trichuridae.

#### Examples

*Trichinella spiralis* and *Trichuris trichiura*

### 2- Class Rhabditea

#### Subclass Rhabditia = Phasmidea= Secernentea.

Include other human parasitic nematods.

## *Trichinella spiralis*

Disease: Trichinosis, trichiniasis, trichinelliasis.

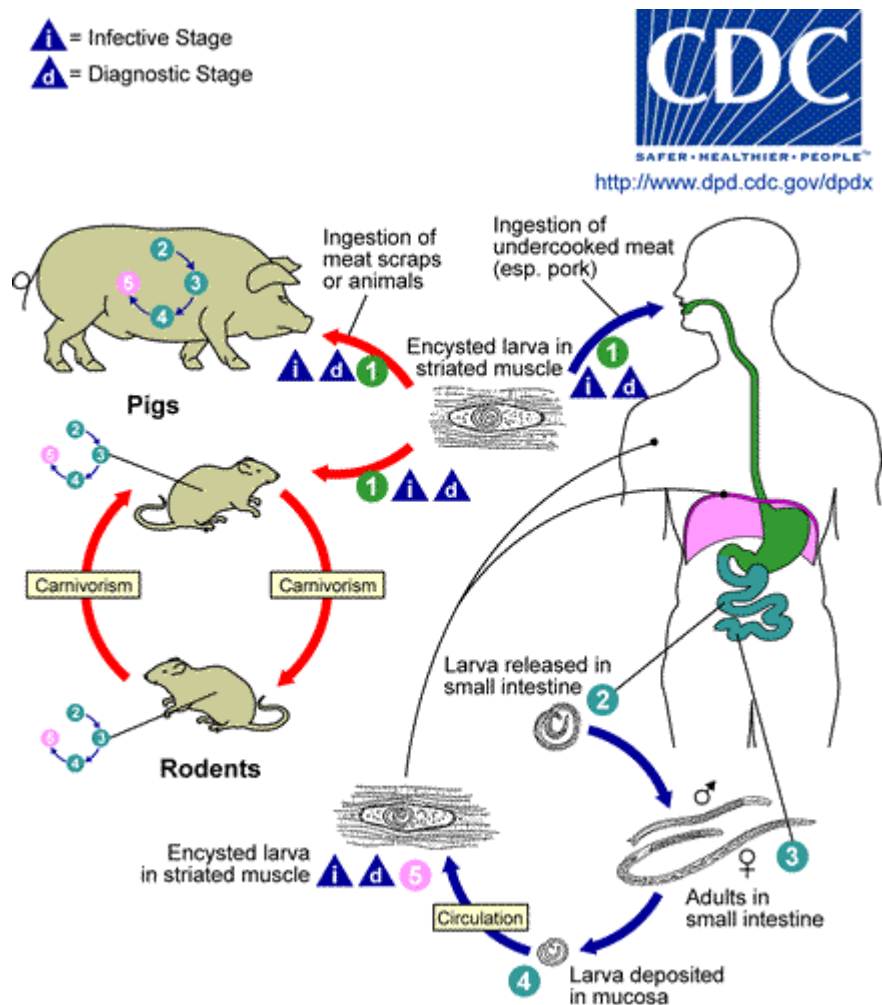
Distribution:

- 1- Cosmopolitan.
- 2- More prevalent in western countries, due to feeding habits.

### *Trichinella spiralis*,

The trichina worm, is one of the most studied of all nematodes. It is the smallest nematode parasitic in humans, has one of the most unique life cycles, is one of the most widespread, and is one of the most medically important parasites in the world.

Adult worms lie buried in the mucosa of the small intestine. Males die shortly after copulation. Females are viviparous, giving birth to living young in the tissues of the intestine.




Juvenile nematodes are transported via the lymph or blood to all parts of the body. Further development only occurs in striated muscle, especially those muscles that are active. They penetrate individual muscle fibers, absorb nutrients from the muscle cell, and increase in length to about 1.0 mm in eight weeks, at which time they are infective. During this time they assume a spiral shape and become encysted by infiltrating leukocytes. They may remain viable for many years.

Transmission is through ingestion of the larvae infected meat. Upon ingestion by a host, the cycle repeats; therefore, one animal serves as both definitive and intermediate host, with the juvenile and adult inhabiting different organs. Most mammals are susceptible to infection. *Trichinella spp.* generally have reduced host specificity, although some species tend to occur in different host associations. The life cycle depends on scavenging food chains: first stage larvae embedded in muscle ingested by a predator or scavenger and develop to adulthood and produce infective larvae in the muscles of the scavenger.

Humans usually acquire infections through eating undercooked pork. Pigs maintain infections because agricultural practices often facilitate transmission (feeding of offal to pigs). See attached life cycle.

### ***Trichinella spiralis*, adult male and female**

The females are twice as large (about 3.0 mm) as the males (about 1.5 mm), and are therefore quite easy to separate. In both sexes note the **stichosome** type of pharynx.





**In the male:**

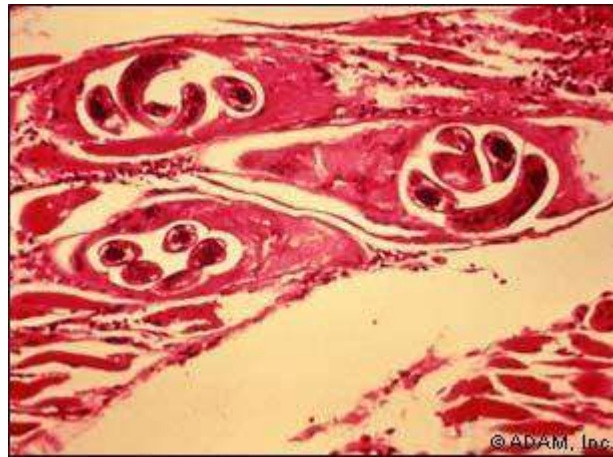
- The greatly enlarged seminal vesicle should be evident beginning just posterior to the junction of the pharynx and intestine. Also note the two large **genital papillae**.
- A spicule is absent.

**On a female:**

- Locate the vulva that opens in the anterior third of the body.

***Trichinella spiralis* encysted:**

Look at encysted juveniles of *T. spiralis* in tissue section. Larvae penetrate individual striated muscle cells and will provoke formation of a **nurse cell** with stichosomal secretions. The nurse cell nurtures and protects the parasite inside the cell. Note the characteristic shape the juvenile assumes, and observe the nature of the cyst wall.



Encysted juveniles

Muscle tissue


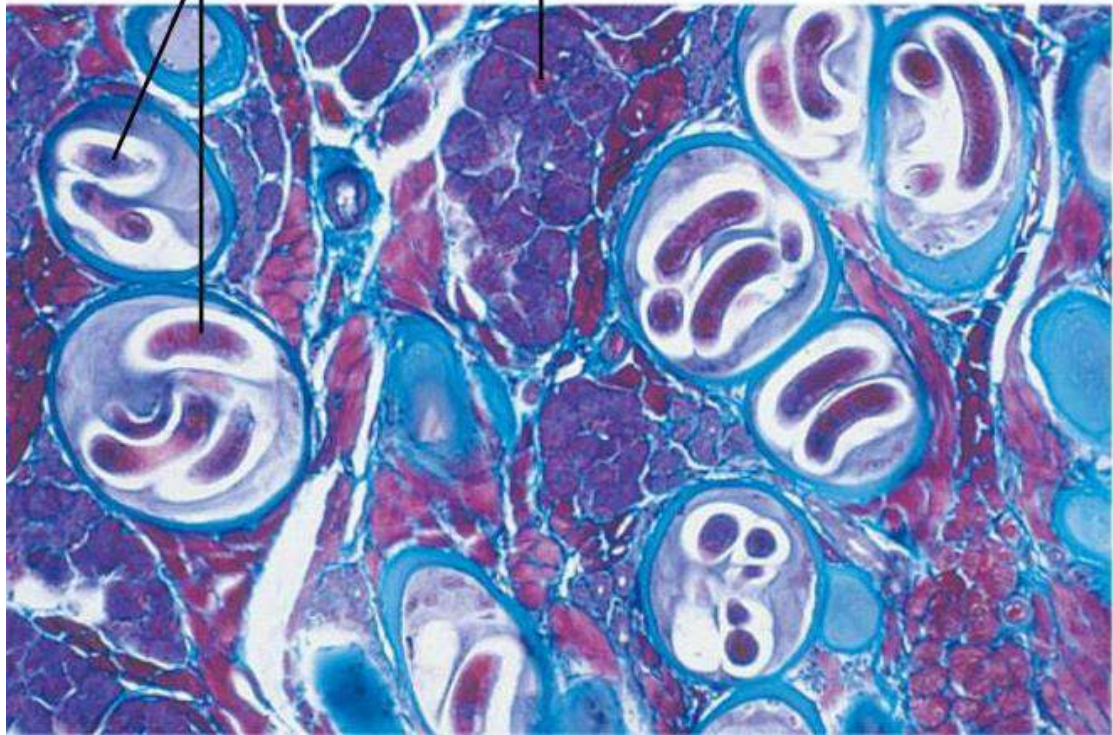


Bild 1: Trichinella spiralis (eingekapselt)



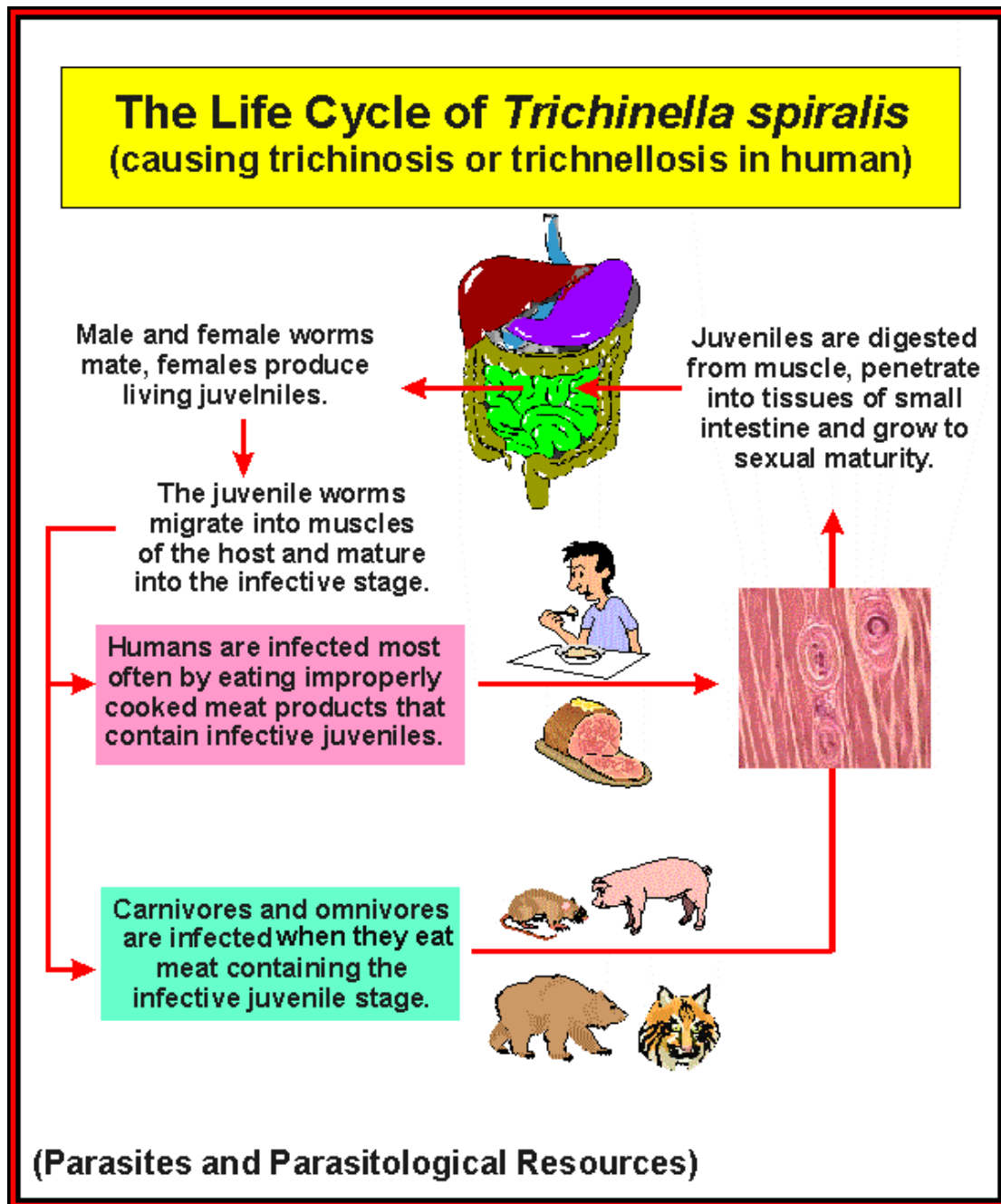
Bild 2: Trichinella pseudospiralis (nicht eingekapselt)

50 µm



### *Trichinella spiralis* larvae sec

See entire larvae in a muscle cell.



## Diagnosis

- 1- Routine examinations rarely detected juveniles in feces ,blood, milk or other secretions .
- 2- Muscle biopsy .
- 3- Pressing the tissue between glass plates and examining it by low – power microscopy it useful , although the digestion of the muscle in artificial gastric enzymes for serval hours provides much more reliable diagnostic technique .
- 4- Serval immunodiagnostic tests are available .

### ***Trichuris trichiura***

**Disease:** Trichuriasis , Trichocephaliasis , Whipworm infection.

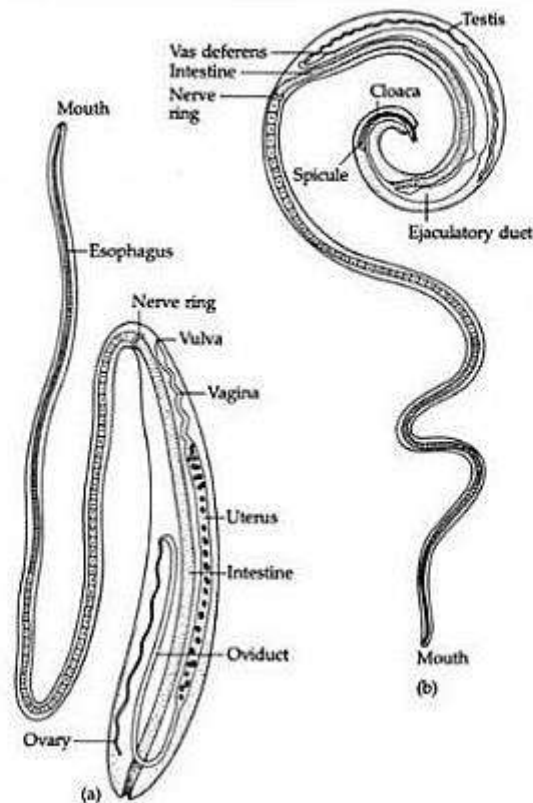
The human whipworm, is a human parasite found throughout the world, but most prevalent in the tropics. The incidence of infection may reach 25% in parts of the southeastern United States. Typically, infections involve fewer than 100 worms and are relatively symptomless. However, in more intense infections, the mortality rate can be 1 in 1000.

The worms are relatively large (30-50mm), with an extremely narrow anterior end and broader posterior ends, hence the name “whipworm”. These parasites occur in the large intestine where they embed their anterior ends beneath the mucosal surface and feed on cells in the lamina propria. The protruding posterior ends of the worms find each other for mating and females deposit eggs into the intestinal lumen so they pass out with the feces.

#### **Adult *Trichuris trichiura*, male and female (w.m.)**

Study the adult worm:

- Distinguish the long filiform anterior end from the fusiform posterior.
- Note the single row of large cells (stichocytes) surrounding the long, thin pharynx. The entire structure is referred to as the **stichosome**. **Stichocytes** secrete material that aid in digestion and that modulate the host reaction to the parasite.
- The pharynx occupies about two thirds of the body length.
- The anterior end of the pharynx lacks stichocytes.
- The anus is located near the tip of the tail.



### In the male:

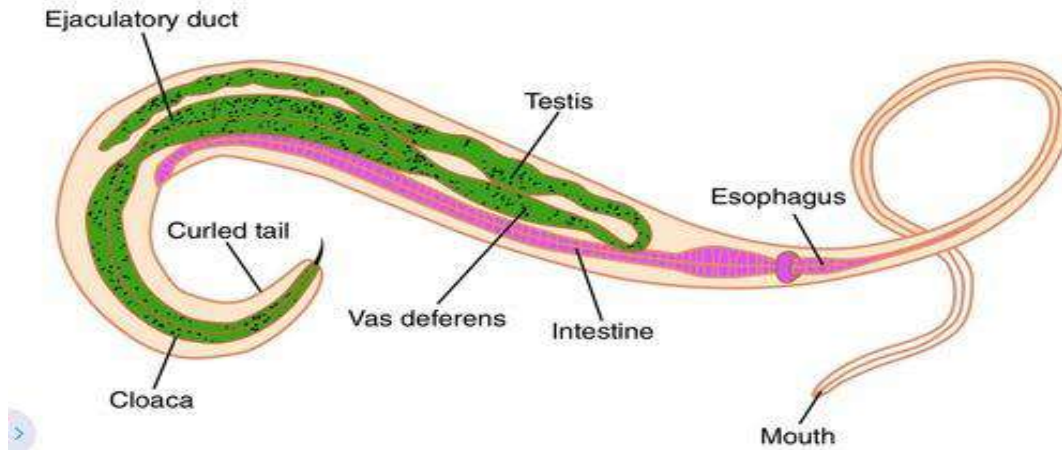
- Note the coiled tail
- The single **spicule** surrounded by a spiny spicule sheath.
- The **testis** is singular, long, and convoluted, and gives the appearance of square shaped compartments along its length.
- Follow the testis forward from the region of the cloaca to a point near the termination of the stichosome. The tube now turns back on itself as a large uncoiled vas deferens.
- Posterior, the vas deferens narrows, then widens again to form an ejaculatory duct that joins the intestine to form the cloaca.

### In the female

- Note the bluntly rounded posterior end.
- The vulva is located near the anterior end of the fusiform body region, near the junction of the pharynx and intestine.
- A coiled vagina runs to the posterior from the vulva to its junction with a wider uterus.
- The uterus runs to a coiled oviduct and sacculate ovary.

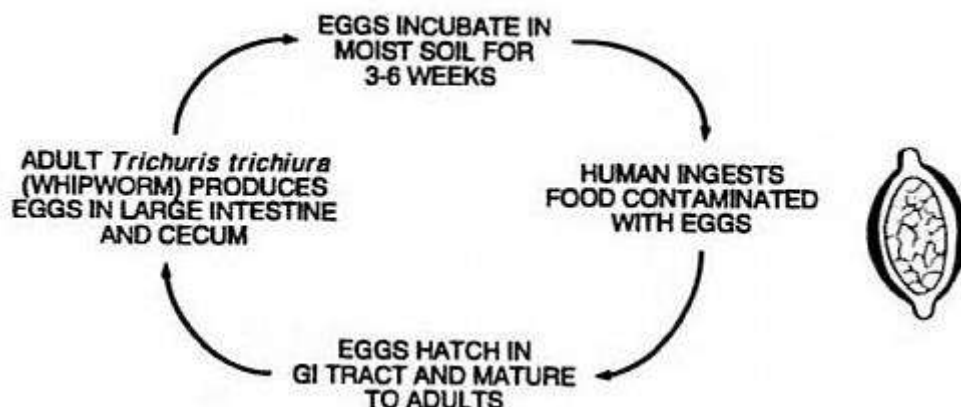


- Eggs within the uterus are unembryonated, and have a characteristic barrel shape with a plug at each end.



### *Trichuris* eggs:

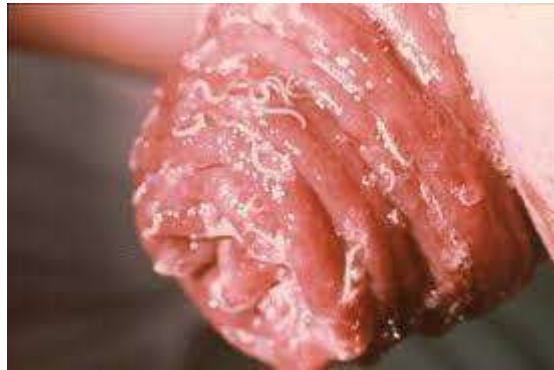*Trichuris* eggs are easily recognized by their prominent **bipolar plugs** and large size. Females produce 3000 to 20,000 eggs per day. Eggs embryonate within three weeks after leaving the host's body and can remain infective for months if they are deposited in moist soil in the shade. Infection is acquired when a suitable host ingests embryonated eggs. Adults live for several years, so large numbers may accumulate in a person, even where the rate of new infection is low.





## Diagnosis

- 1- Specific diagnosis depends on demonstrating a worm or egg in the stool.
- 2- Worm can be demonstrated dramatically by colonoscopy.
- 3- Prolapse of the rectum.



## Order: Ascaridida

Nematodes in this Order:

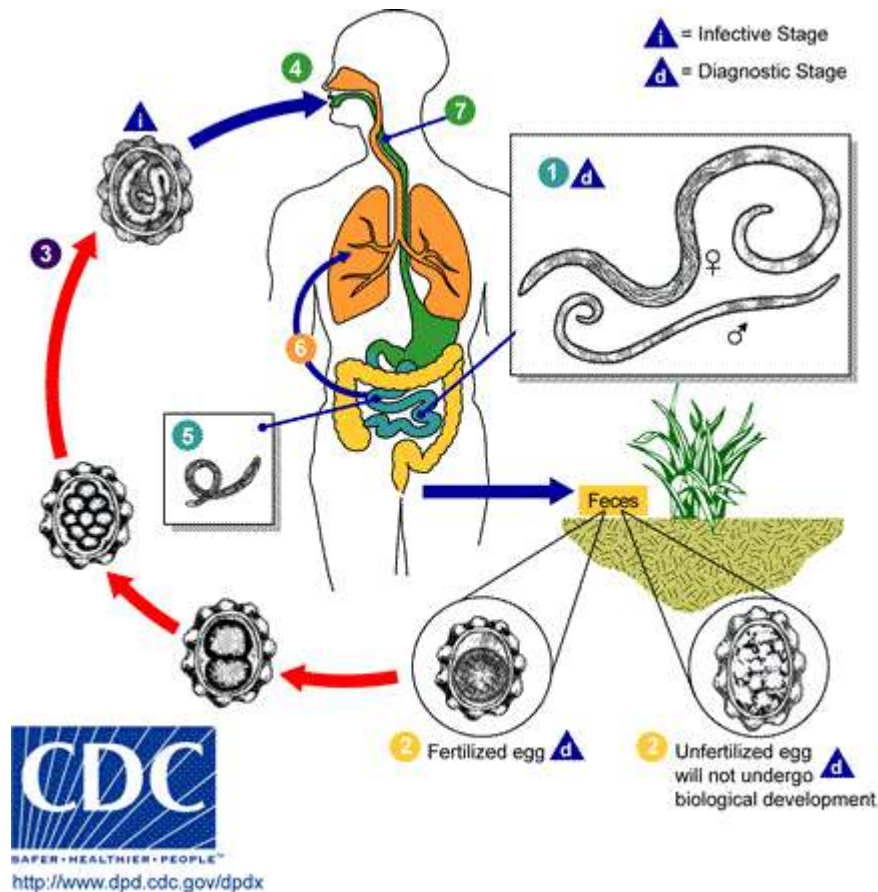
- Mostly large, stout parasites of vertebrates.
- The mouth is surrounded by three conspicuous lips.
- A buccal capsule and pharyngeal bulb is absent in most species.
- Males have two copulatory spicules of equal or unequal length, and a pointed, ventrally coiled tail.
- Females are oviparous, possess a double reproductive system, and have a blunt tail.
- Eggs are thick-shelled and require a long period of incubation before they become infective.
- Development is usually direct.

### *Ascaris lumbricoides*

**Disease :** Ascariasis , Ascaris infection , Roundworm infection .

*Ascaris lumbricoides* is one of the largest and most common parasites

found in humans. The adult females of this species can measure up to half a meter long (males are generally shorter), and it is estimated that 25% of the world's population is infected with this nematode.



1. The adult worms live in the small intestine and eggs are passed in the feces. About two weeks after passage in the feces the eggs contain an infective larval or juvenile stage.
2. Moulting in life cycle occurs four times:
  - 1<sup>st</sup> moulting- in soil
  - 2<sup>nd</sup> and 3<sup>rd</sup> moulting- in lungs
  - 4<sup>th</sup> moulting- in intestine.
  - 2<sup>nd</sup> stage larva enters the lungs and 4<sup>th</sup> stage larva comes out of the lungs.
3. Humans are infected when they ingest infective eggs. The eggs hatch in the small intestine; the juvenile penetrates the small intestine and enters the circulatory system, and eventually entering the lungs.
4. In the lungs the juvenile worm leaves the circulatory system and enters the air passages of the lungs.
5. The juvenile worm then migrates up the air passages into the pharynx where it is swallowed, and once in the small intestine the juvenile grows into an adult worm. This process is called the **bronchial escalator**.

## Pathology

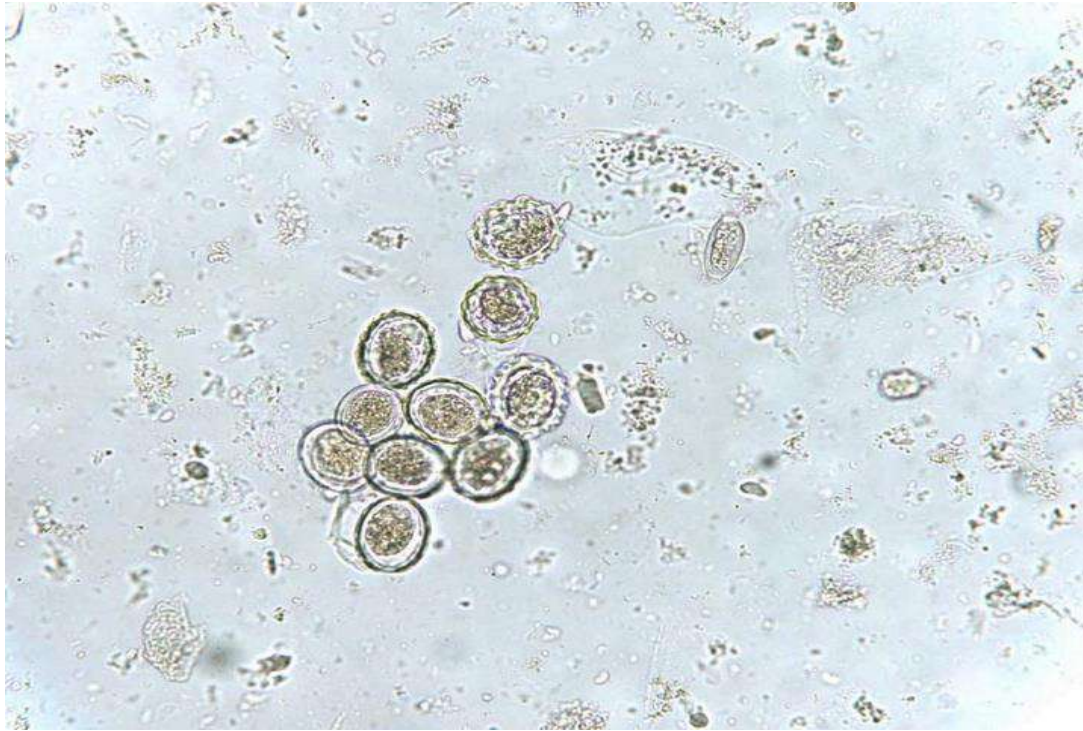1. *Ascaris* infections in humans can cause significant **pathology**. The migration of the larvae through the lungs causes the blood vessels of the lungs to **hemorrhage**, and there is an inflammatory response accompanied by **edema**. The resulting accumulation of fluids in the lungs results in "ascaris pneumonia," and can be fatal.
2. Heavy infections can obstruct the bowel and lead to perforation.



### *Ascaris* eggs:

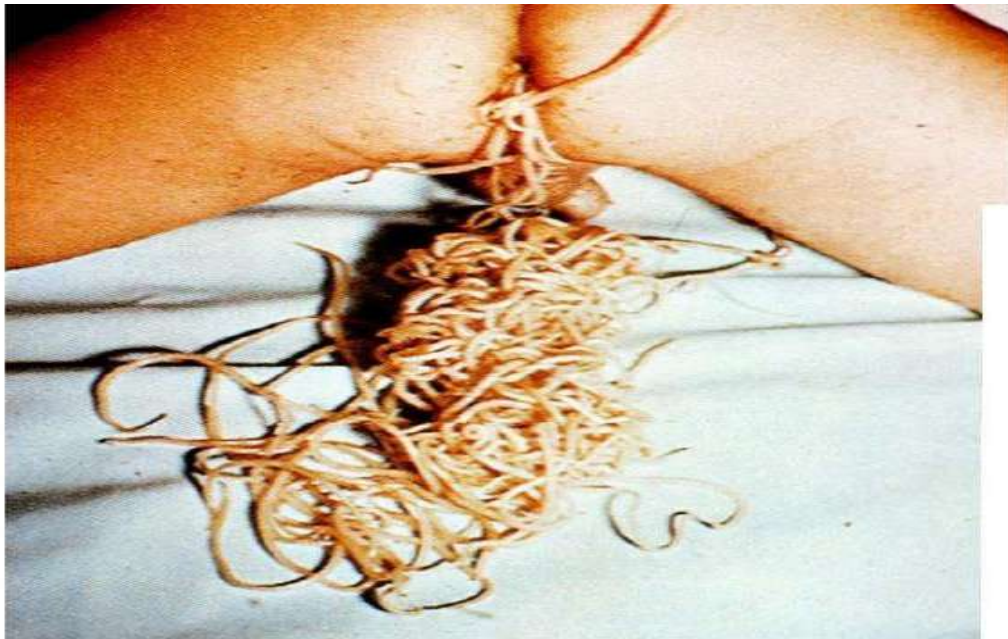A single female can produce up to 200,000 eggs each day! The eggs have a characteristic convoluted outer shell; these fertilized eggs become infectious after two weeks in soil; they can persist in soil for 10 years or more.

The eggs have a lipid layer which makes them resistant to the effects of acids and alkalis, as well as other chemicals. This resilience helps to explain why this nematode is such a ubiquitous parasite.



## Diagnosis

- 1- Is made by finding the fertile or infertile eggs in feces, by either direct examination or concentration technics.
- 2- The adult worm may be detected radiologically.
- 3- Vomiting of adult worm .
- 4- Spontaneous elimination of spend individuals from the anus.





## Oxyurida

Oxyuroid nematodes:

- Are small pin-shaped parasites of vertebrates and invertebrates.
- Are called pinworms because females have characteristically long, pointed tails.
- Have a small buccal capsule leading to a pharynx with a well-developed end bulb (=oxyuroid type of pharynx).
- Males have one or two **spicules** of equal length.
- They are usually parasites of the cecum or large intestine of their hosts.
- No intermediate hosts are required in the life cycle.

### *Enterobius vermicularis*

**Disease:** Enterobiasis, oxyuriasis, pinworm, seatworm.

**Geographic distribution:** cosmopolitan in cool and temperate zone.

## Morphology

The female worm measures 8 to 13 mm long and has a pointed tail (hence the common name "pinworm"). The male worm is inconspicuous, about 2 ~5 mm long. The eggs are oval, compressed laterally, and flattened on one side and measure 50 to 60  $\mu\text{m}$  long by 20 to 30  $\mu\text{m}$  wide.

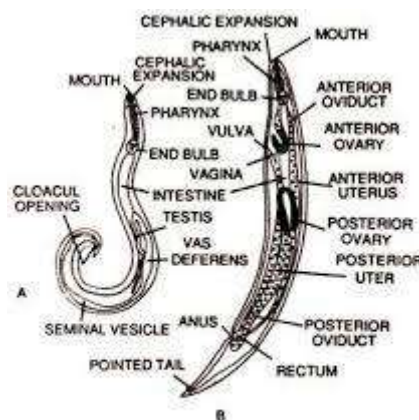
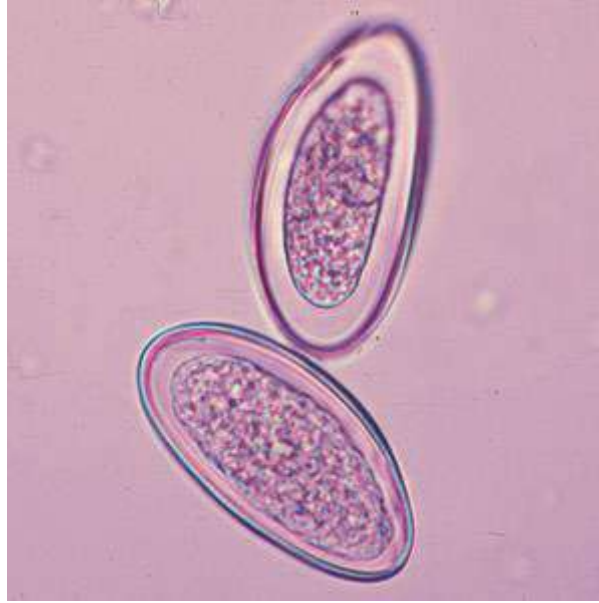

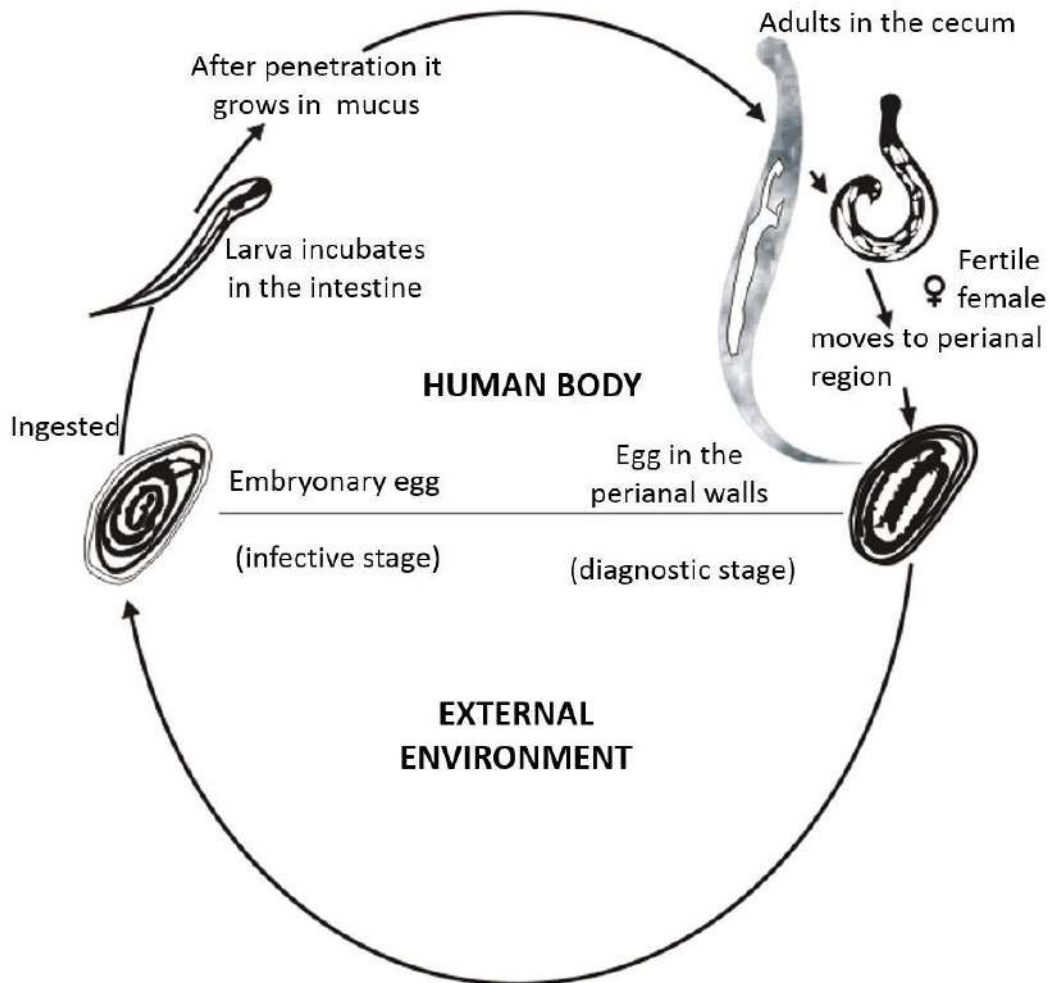
Fig. 11.1 Enterobius  
A. male B. Female

## Life cycle

Human is the only known host of *E. vermicularis*. The usual habitat is the colon. Pinworm infection in human is initiated by the ingestion of the infective eggs, which hatch in the intestine, where they develop into the adult worms. In gravid females, almost of the entire body is filled with the eggs. The female worms migrate down to the colon and out of the anus, where the eggs are deposited on the perianal and perineal skin. Occasionally, the female worm migrates into the vagina.







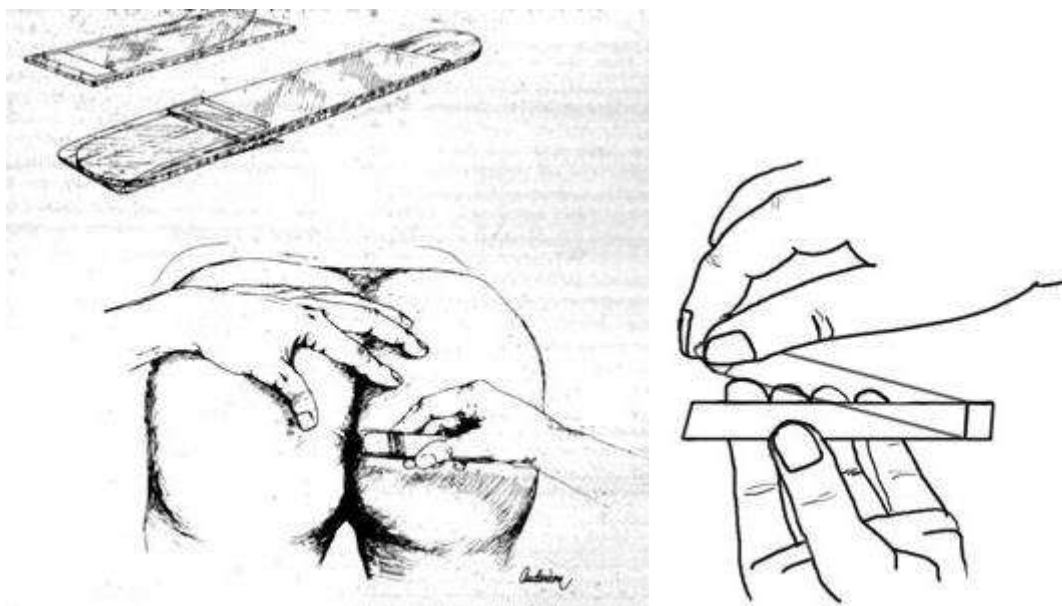
*Enterobius vermicularis* Life Cycle, Nematode (Pinworm)

### Pathology and clinical symptoms.

Many cases of *E. vermicularis* infection are asymptomatic. The most striking symptom of this infection is pruritus, which is caused by the migration of the female worms from the anus onto the perianal skin.

### Diagnosis.

Diagnosis is normally accomplished by sampling the perianal and perineal skin with cellulose adhesive tape. It is important to note that multiple samples may be required to confirm the presence of a light infections as well as to conclude that a patient is free of infection.



### **Treatment.**

The treatment of choice for the enterobiasis is mebendazole and albendazole. It should be repeated 2 weeks later. All of the family members should be treated together at the same time.

### **Prevention.**

Proper personal hygiene: hand washing, applying ointment, perianal area to avoid dispersal.

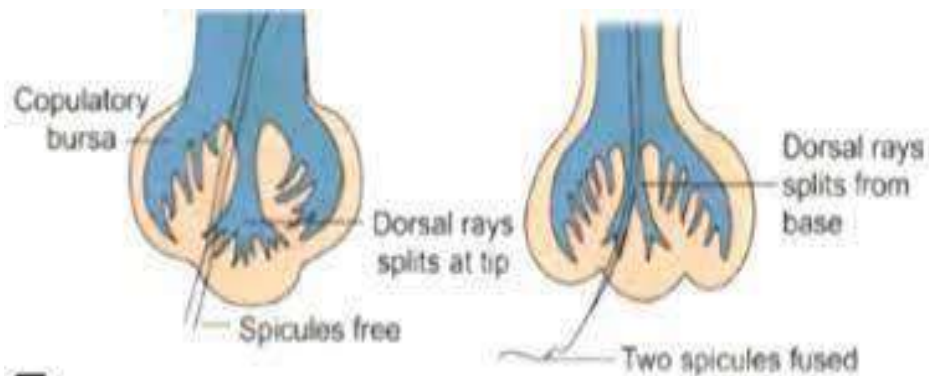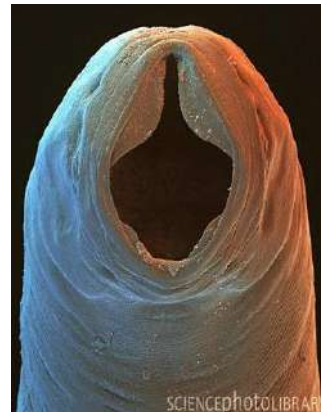
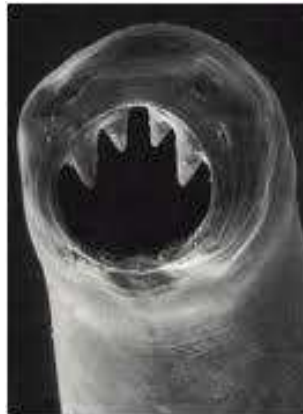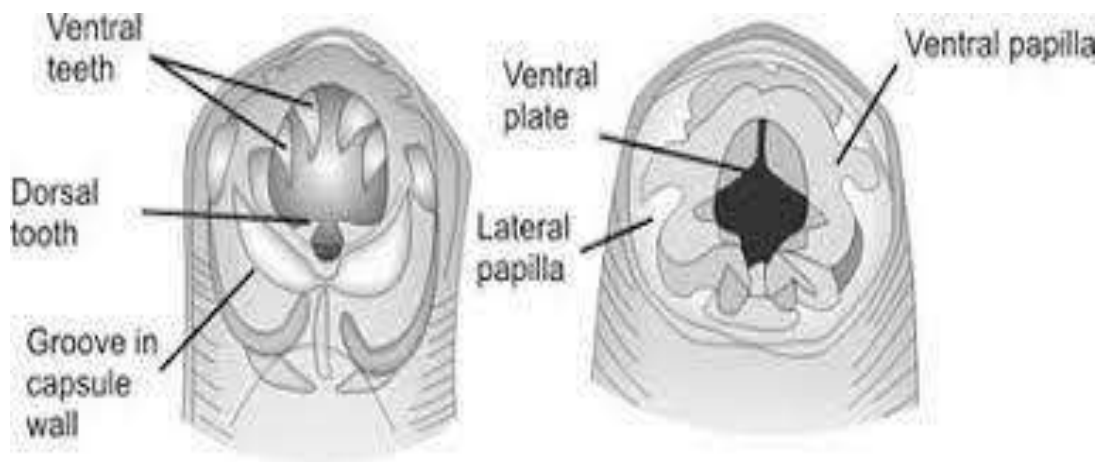
## ***Necator americanus* and *Ancylostoma duodenale*** **(Hookworms)**

### **Epidemiology**

Hookworms parasitize more than 900 million people worldwide and cause daily blood loss of 7 million liters. **Ancylostomiasis** is the most prevalent hookworm infection and is second only to ascariasis in infections by parasitic worms. *N. americanus* (new world hookworm) is most common in the Americas, central and southern Africa, southern Asia, Indonesia, Australia and Pacific Islands. *A. duodenale* (old world hookworm) is the dominant species in the Mediterranean region and northern Asia.

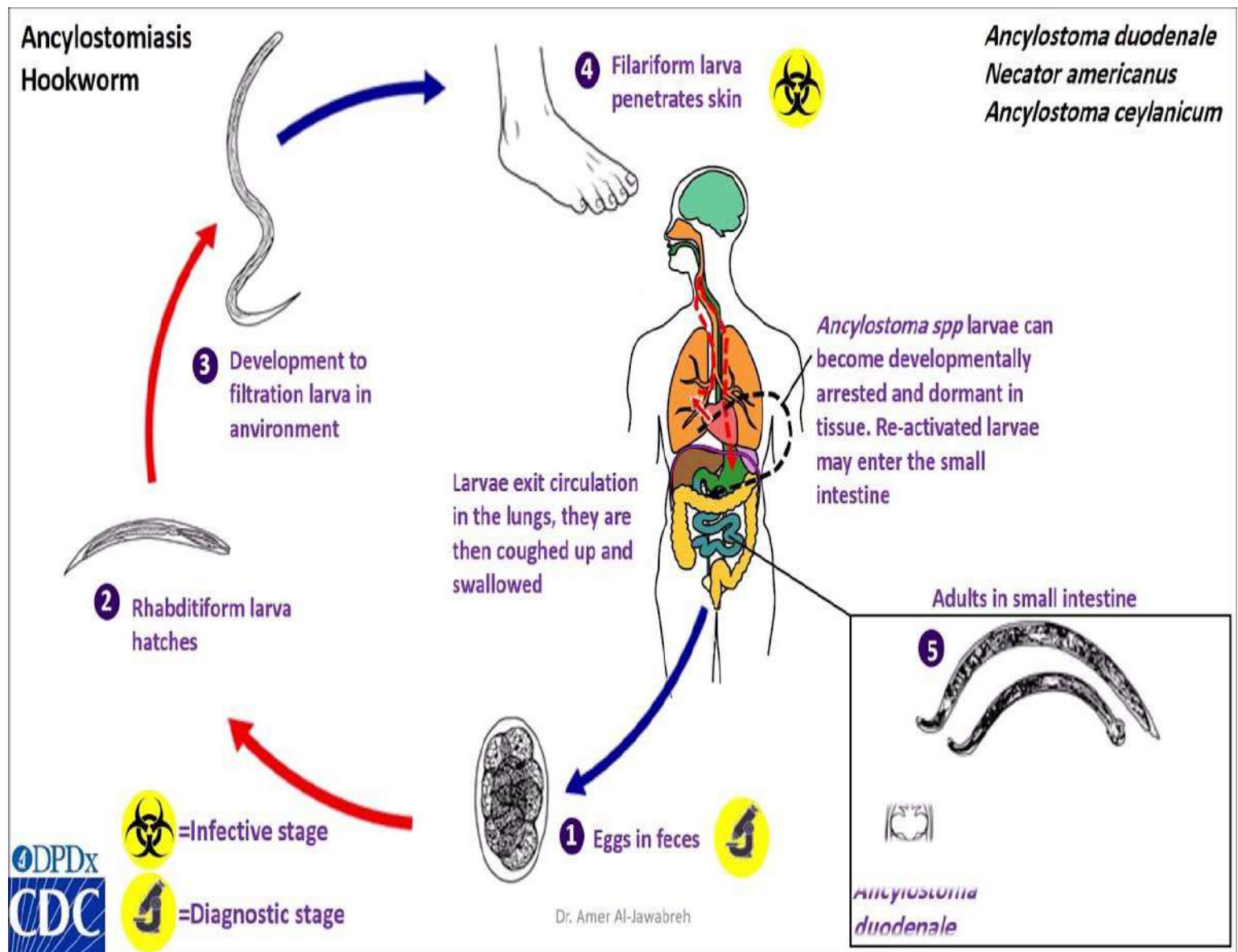
## Morphology

Adult female hookworms are about 11 mm x 50 micrometers. Males are smaller. The anterior end of *N. americanus* is armed with a pair of curved cutting plates whereas *A. duodenale* is equipped with one or more pairs of teeth. Hookworm eggs are 60 micrometers x 35 micrometers.



## Life cycle

The life cycle of hookworms is identical to that of threadworms, except that hookworms are not capable of a free-living or auto-infectious cycle. Furthermore, *A. duodenale* can infect also by oral route.



## Symptoms

Symptoms of hookworm infection depend on the site at which the worm is present and the burden of worms. Light infection may not be noticed.

## Diagnosis

Diagnosis is made by identification of hookworm eggs in fresh or preserved feces. Species of hookworms cannot be distinguished by egg morphology.

## Treatment and control

Mebendazole, 200 mg, for adults and 100 mg for children, for 3 days is effective. Sanitation is the chief method of control: sanitary disposal of fecal material and avoidance of contact with infected fecal material.

### ***Ancylostoma braziliensis* (cutaneous larva migrans, creeping eruption)**

Creeping eruption is prevalent in many tropical and subtropical countries and in the US especially along the Gulf and southern Atlantic states. The organism is primarily a hookworm of dogs and cats but the filariform larvae in animal feces can infect man and cause skin eruptions. Since the larvae have a tendency to move around, the eruption migrates in the skin around the site of infection. The symptoms last the duration of larval persistence which ranges from 2 to 10 weeks. Light infection can be treated by freezing the involved area. Heavier infections are treated

with Mebendazole. Infection can be avoided by keeping away from water and soil contaminated with infected feces

### ***Strongyloides stercoralis***

**Disease : Strongyloidiasis, Cochin-China diarrhea.**

#### **Life Cycle.**

Man is the principal host of ***Strongyloides stercoralis***. The parasitic female 2.20 by 0.04 mm, is a small, colorless, semitransparent **filariform** nematode with a finely striated cuticle. It has a short buccal cavity and a long, slender, cylindrical esophagus. The paired uteri contain a single file of thin-shelled, transparent, segmented eggs. The free-living female, smaller than the parasitic one, resembles a typical free-living **rhabditoid nematode** and has paired reproductive organs. The free-living male is smaller than the female and has a curved tail. The eggs of the parasitic form, 54 by 32 u, are deposited in the intestinal mucosa; they hatch into **rhabditiform** larvae, which penetrate the glandular epithelium and pass into the lumen of the intestine and out in the feces. The eggs are seldom found in the stool except after violent purgation. This parasite has three types of life cycle.

#### **I. DIRECT CYCLE, LIKE HOOKWORM.**

After a short feeding period of 2 to 3 days in the soil, the **rhabditiform** larva 225 by 16 m, molts into a long, slender, **nonfeeding**, infective, **filariform** larva about 700 m in length. The infective **filariform** larvae penetrate the skin of man, enter the venous circulation, and pass through the right heart to the lungs, where they penetrate into the alveoli. From the lungs the adolescent parasites ascend to the glottis, are swallowed, and reach the upper part of the small intestine, where they develop into adults. Occasionally some larvae pass through the pulmonary barrier into the arterial circulation and reach various organs of the body. During their migration in the host, the larvae pass through two molts to become adolescent worms. Mature ovipositing females are produced in about 28 days after the initial infection.

#### **II. INDIRECT CYCLE.** In the indirect cycle, the rhabditiform larvae develop into sexually mature free-living males and



females in the soil. After **fertilization** the free-living female produces eggs that develop into rhabditiform larvae. These may become infective **filariform** larvae within a few days and enter new hosts, or they may repeat the free-living generations. The indirect method appears to be associated with the optimal environmental conditions for a free-living existence in tropical countries, while the direct method is more frequently followed in the less favorable, colder regions. **Strains** may show chiefly one or the other type of development or a mixture of both types.

### III.

**AUTOINFECTION.** At times, the larvae may develop into the **filariform** stage in the intestine and, by penetrating the intestinal mucosa or the perianal skin, establish a developmental cycle within the host. **Autoinfection** explains persistent strongyloidiasis, as long as 36 years, in patients living in nonendemic areas.

**"Pathology and Symptomatology.** The parasitic females penetrate the mucosa of the intestinal villi, where they burrow in **serpentine channels** in the **mucosa**, depositing eggs and securing nourishment. The worms are most frequently found in the **duodenum** and upper **jejunum**, but in heavy infections the pylorus, both the small and large intestine, and the proximal biliary and pancreatic passages may be involved.

Many *Strongyloides* infections are light and go unnoticed by their human host as they produce no symptoms. Moderate infections with the parasitic females embedded primarily in the duodenal region may cause a burning, dull or sharp, non-radiating midepigastric pain. Pressure to this area may elicit pain and tenderness.

Nausea and vomiting may be present; diarrhea and constipation alternate. Longstanding and heavy infections result in anemia, weight loss, and chronic dysentery accompanied by a low-grade fever. The latter suggests secondary bacterial invasion of the intestinal lesions. In heavy infections, all of the signs and symptoms are more marked, and death may ensue.

There is often a moderate **leukocytosis** and **eosinophilia**, although in many infections the eosinophil count is normal. Intestinal strongyloidiasis differs from hookworm infection in that the parasite causes an immediate

inflammatory irritation of the intestine, whereas in hookworm disease marked symptoms do not occur until anemia has developed.

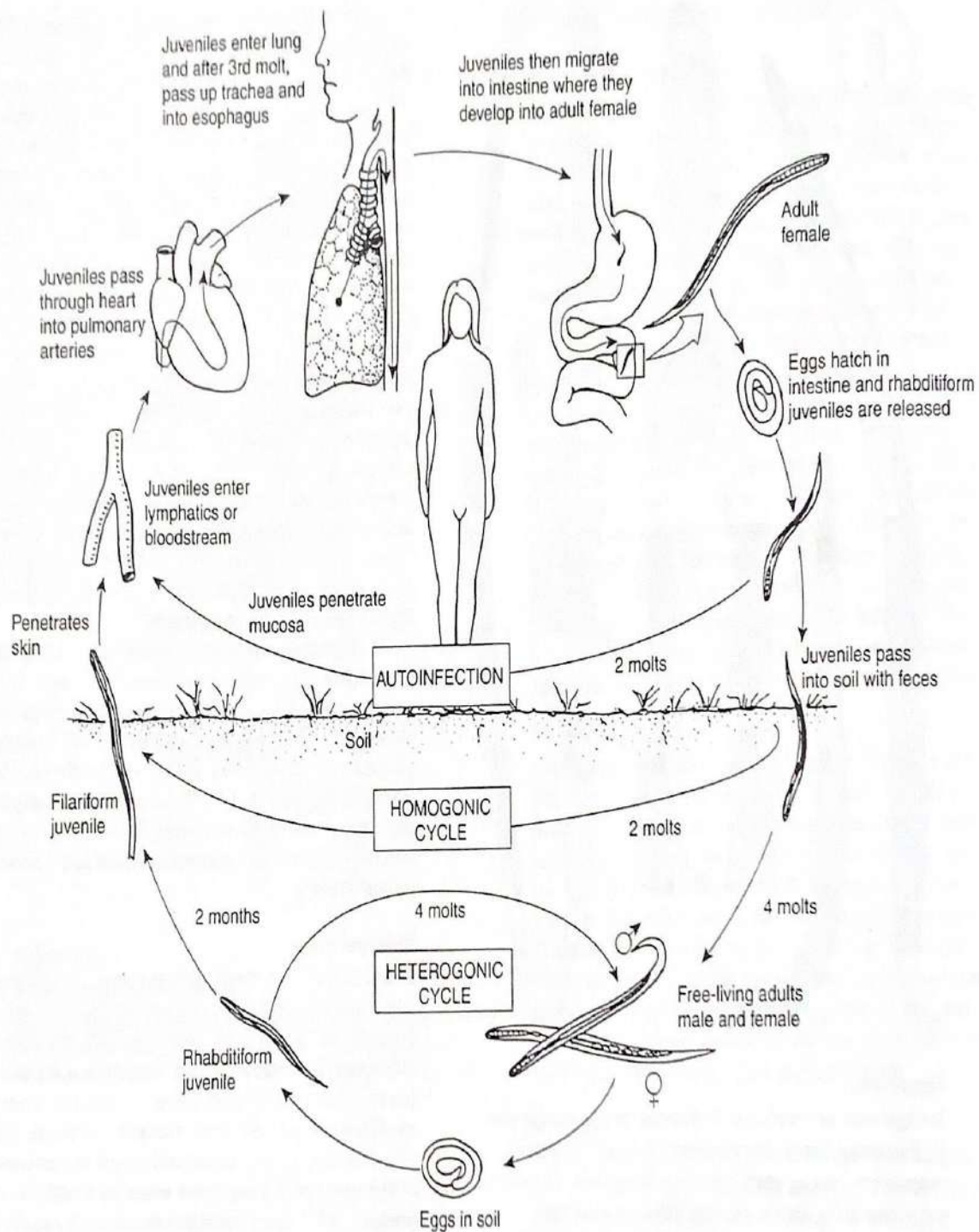
**Prognosis** is favorable except in severe cases involving autoinfection. The chemotherapeutic eradication of the worms, however, is relatively easy.

### **Diagnosis.**

Clinical diagnosis is uncertain, since strongyloidiasis presents no distinctive clinical picture. The sequence of an atypical bronchitis or pneumonitis followed in a few weeks by a mucous or watery diarrhea, epigastric pain, and eosinophilia is suggestive.

**Laboratory diagnosis** includes the examination of the feces and duodenal contents by direct or concentration methods. The presence of characteristic **rhabditiform** larvae in fresh feces is diagnostic; in heavy infections, they may be found in simple film preparations. The duodenal fluid of suspected subjects should be examined if the feces are negative, as the duodenal fluid gives slightly higher positive findings. The **rhabditiform** larvae of *Strongyloides* differ morphologically from those of hookworms, which are rarely found in fresh feces while the embryonated *Strongyloides* eggs, slightly smaller than those of **hookworms**, can only be obtained by a drastic **purge** or by **duodenal intubation**.

**Cultivation** of the feces for 48 hours will produce filariform larvae and free-living adult *Strongyloides*, but only **rhabditiform** hookworm larvae.



## BLOOD AND TISSUE HELMINTHS

The major blood and tissue parasites of man are **microfilaria**. These include *Wuchereria bancrofti* and *W.(Brugia) Malayi*, *Onchocerca volvulus*, and *Loa loa* (eye worm).

### *Wuchereria bancrofti* and *W. (Brugia) malayi* (elephantiasis)

#### Epidemiology

*W. bancrofti* is strictly a human pathogen and is distributed in tropical areas worldwide, whereas *B. malayi* infects a number of wild and domestic animals and is restricted to South-East Asia. **Mosquitoes** are vectors for both parasites.

#### Morphology

These two organisms are very similar in morphology and in the diseases they cause. Adult female *W. bancrofti* found in **lymph nodes** and **lymphatic channels** are 10 cm x 250 micrometers whereas males are only half that size. **Microfilaria** found in blood are only 260 micrometers x 10 micrometers. Adult *B. malayi* are only half the size of *W.bancrofti* but their microfilaria are only slightly smaller than *W. bancrofti*.

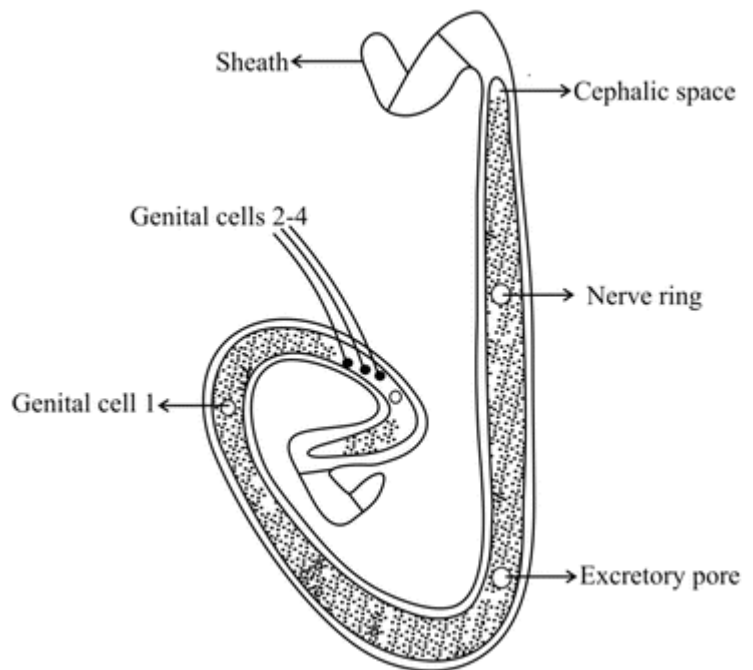
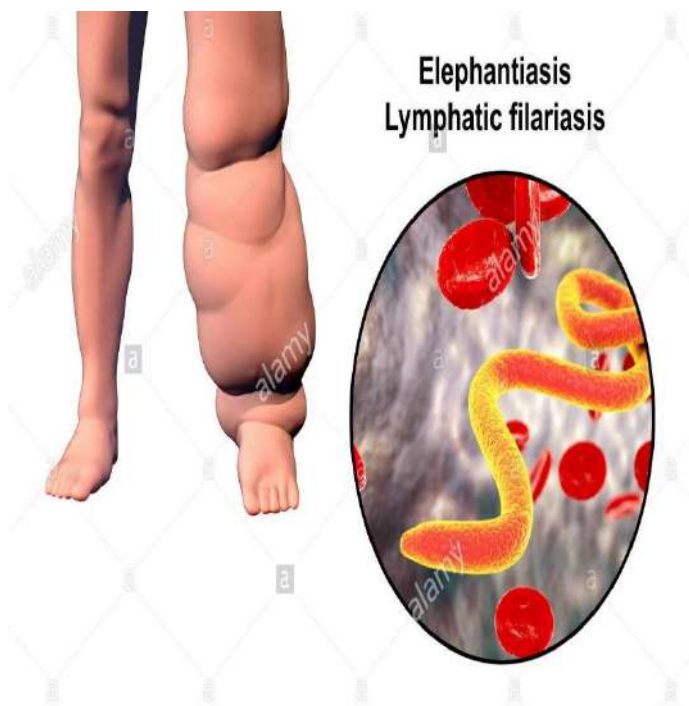
#### Life cycle

**Filariform** larvae enter the human body during a mosquito bite and migrate to various tissues. There, they may take up to a year to mature and produce **microfilaria** which migrate to lymphatics and, at night, enter the blood circulation. **Mosquitoes** are infected

during a blood meal. The microfilaria grow 4 to 5 fold in the **mosquitoes** in 10 to 14 days and become infective for man.

## Symptoms

Symptoms include lymphadenitis and recurrent high fever every 8 to 10 weeks, which lasts 3 to 7 days. There is progressive lymphadenitis due to an inflammatory response to the parasite lodged in the **lymphatic channels and tissues**. As the worm dies, the reaction continues and produces a fibro-proliferative **granuloma** which obstructs lymph channels and causes lymphedema and **elephantiasis**. The stretched skin is susceptible to traumatic injury and infections. **Microfilaria** cause eosinophilia and some splenomegaly. Not all infections lead to elephantiasis. Prognosis, in the absence of **elephantiasis**, is good.



## **Diagnosis**

Diagnosis is based on history of mosquito bites in endemic areas, clinical findings and presence of microfilaria in blood samples collected at night.

## **Treatment and control**

Diethylcarbamazine quickly kills the adults worms or sterilizes the female. It is given 2 mg/kg orally for 14 days. Steroids help alleviate inflammatory symptoms. Cooler climate reduces the inflammatory reaction.

## ***Onchocerca volvulus* (Blinding filariasis; river blindness)**

### **Epidemiology**

Onchocerciasis is prevalent throughout eastern, central and western Africa, where it is the major cause of blindness. In the Americas, it is found in Guatemala, Mexico, Colombia and Venezuela. The disease is confined to neighborhoods of low elevation with rapidly flowing small streams where black flies breed. Man is the only host.

### **Morphology**

Adult female onchocerca measure 50 cm by 300 micrometers, male worms are much smaller. Infective larvae of *O. volvulus* are 500 micrometers by 25 micrometers.

### **Life cycle**

Infective larvae are injected into human skin by the female black fly (*Simulium damnosum*) where they develop into adult worms



in 8 to 10 months. The adults usually occur as group of tightly coiled worms (2 to 3 females and 1 to 2 males). The gravid female releases **microfilarial** larvae, which are usually distributed in the skin. They are picked up by the black fly during a blood meal. The larvae migrate from the gut of the black fly to the thoracic muscle where they develop into infective larvae in 6 to 8 days. These larvae migrate to the head of the fly and then are transmitted to a second host.

## Symptoms

Onchocerciasis results in nodular and erythematous lesions in the skin and subcutaneous tissue due to a chronic inflammatory response to persistent worm infection. During the incubation period of 10 to 12 months, there is eosinophilia and urticaria. Ocular involvement consists of trapping of microfilaria in the cornea, choroid, iris and anterior chambers, leading to photophobia, lacrimation and blindness.

## Diagnosis

Diagnosis is based on symptoms, history of exposure to black flies and presence of microfilaria in nodules.

## Treatment and control

Diethylcarbamazine is effective in killing the worm. Destruction of microfilaria produces extreme allergic reaction which can be controlled with corticosteroids. Prevention measures include vector control, treatment of infected individuals and avoidance of black fly.

### ***Loa loa* (eye worm)**

Loasis is limited to the areas of African equatorial rain forest. The incidence in endemic areas varies greatly (8 to 75 percent). The larger, female organisms are 60 mm by 500 micrometers; males are 35mm by 300 micrometers in size. The circulating microfilaria are 300 micrometers by 7 micrometers; the infective larvae in the fly are 200 micrometers by 30 micrometers. The life cycle of *Loa loa* is identical to that of *Onchocerca* except that the vector for this worm is the deer fly. The infection results in subcutaneous (**Calabar**) swelling, measuring 5 to 10 cm in diameter, marked by erythema and angioedema, usually in the extremities. The organism migrates under the skin at a rate of up to an inch every two minutes. Consequently, the swelling appears spontaneously, persists for 4 to 7 days and disappears, and is known as **fugitive** or **Calabar** swelling. The worm usually causes no serious problems, except when passing through the orbital conjunctiva or the nose bridge. The diagnosis is based on symptoms, history of deer fly bite and presence of eosinophilia. Recovery of worms from the conjunctiva is confirmatory.

**Treatment and control** are the same as those for onchocerciasis.

## ***Dracunculus medinensis* (Guinea worm; fiery serpent of the Israelites)**

**Disease: Dracontiasis, Dracunculosis, Dracunculiasis, Fiery serpent of the Israelites**

### **Morphology**

The adult female worm measures 50-120 cm by 1 mm and the male is half that size.

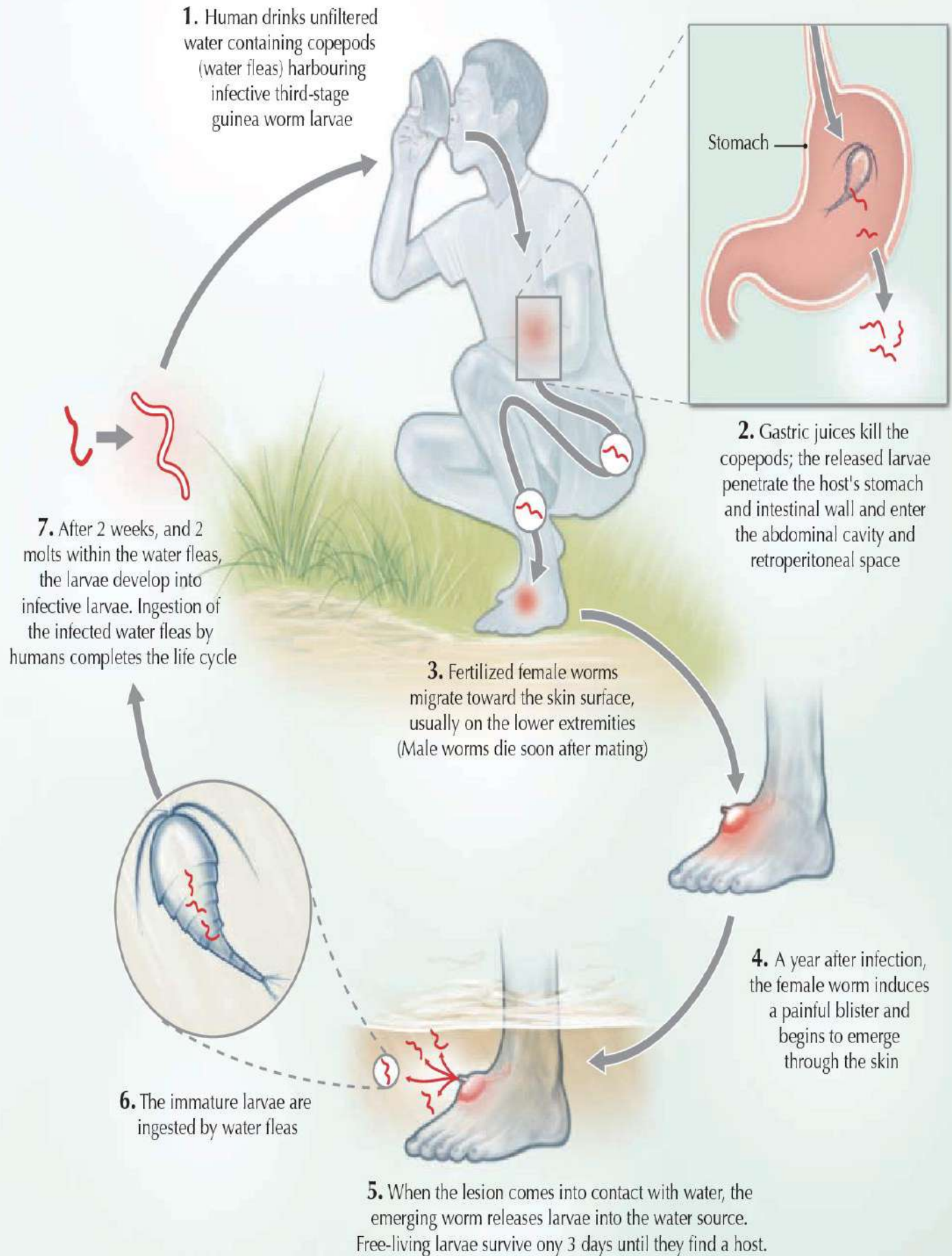
### **Life cycle**

The infection is caused by ingestion of water contaminated with water fleas (*Cyclops*) infected with larvae.

The **rhabtidiform** larvae penetrate the human digestive tract wall, lodge in the loose connective tissues and mature into the adult form in 10 to 12 weeks.

In about a year, the gravid female migrates to the subcutaneous tissue of organs that normally come in contact with water and discharges its larvae into the water.

The larvae are picked up by *Cyclops*, in which they develop into infective form in 2 to 3 weeks.



## **Symptoms**

If the worm does not reach the skin, it dies and causes little reaction. In superficial tissue, it liberates a toxic substance that produces a local inflammatory reaction in the form of a sterile blister with serous exudation.

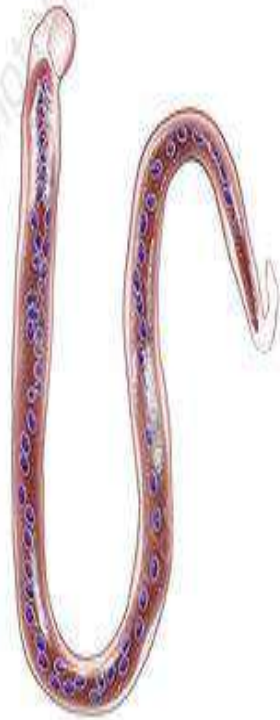
The worm lies in a subcutaneous tunnel with its posterior end beneath the blister, which contains clear yellow fluid. The course of the tunnel is marked with induration and edema. Contamination of the blister produces abscesses, cellulitis, extensive ulceration and necrosis.

## **Diagnosis**

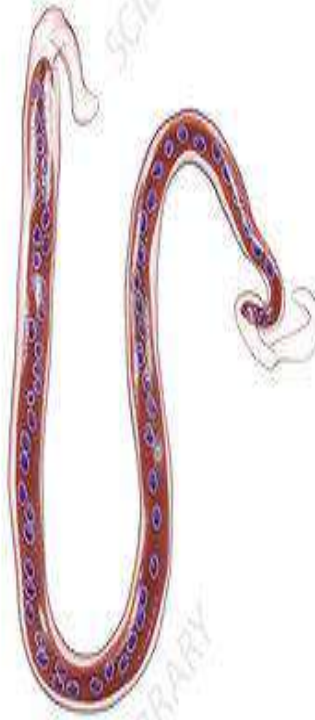Diagnosis is made from the local blister, worm or larvae. The outline of the worm under the skin may be revealed by reflected light.

## **Treatment**

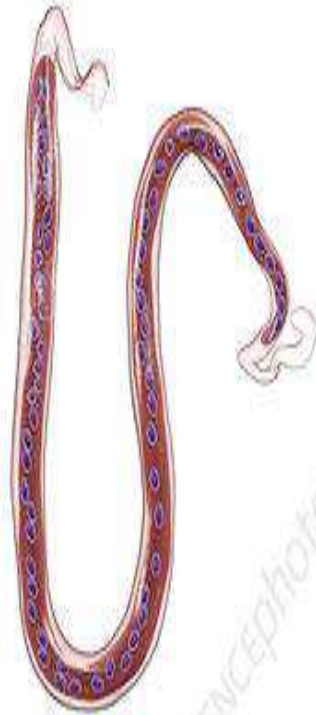
Treatment includes the extraction of the adult guinea worm by rolling it a few centimeters per day or preferably by multiple surgical incisions under local anaesthesia. Metronidazole is effective in killing the worm. Protection of drinking water from being contaminated with Cyclops and larvae are effective preventive measures.



**Wuchereria bancrofti**



**Brugia malayi**



**Loa loa**



**Mansonella ozzardi**



**Mansonella perstans**



**Mansonella streptocerca**



**Onchocerca volvulus**



## Platyhemintbes: Cestoda

### Platyhelminthes (Flatworms): Tapeworms

The Cestodes (tapeworms):

#### Morphology

The adult tapeworm consists of:

1. **Scolex** (head) equipped for attachment, by the presence of sucking disks or lateral grooves. Some have hooks (armed).  
**Rostellum** - A small button-like structure on the scolex of “armed” tapeworms from which the hooks protrude. It may be retractable.
2. **Neck**, it is the posterior portion follow the **scolex**, which is the region of growth of proglottides.
3. **Strobila** a chain of progressively developing segments or proglottides.

In **cestodes**, the whole body except for the head and the neck undergoes **strobilization** continuously, reflecting the important role reproduction plays in the parasitic mode of life. The **strobilization** section is called strobila.

“**Destrobilization**” that occurs when a tapeworm undergoing stress in the intestine drops most or all of its segments and then grows new segments. Sudden change in diet has been associated with **destrobilization**.

**Proglottides:** the Proglottides vary in number, size and shape according to species and stage of development. Each Proglottid is essentially a functioning individual, a member of a colonial **chain** or **strobila**. Proglottides are of three types:

1. Immature Proglottides.
2. Mature Proglottides.
3. Gravid Proglottides, which are from 1/3 to 1/2 of the total proglottides

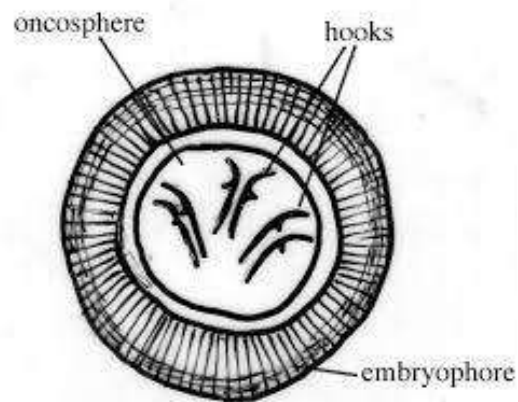
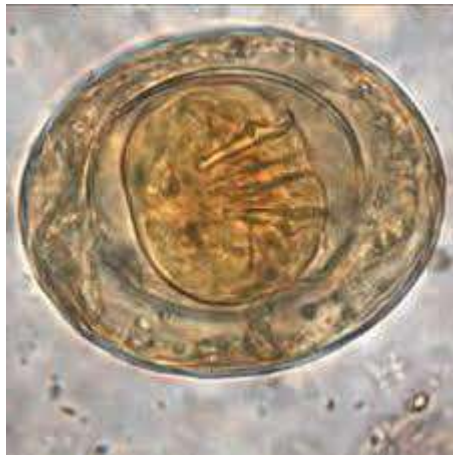- Monoecious - each proglottid has both male & female reproductive organs; can fertilize itself.
- Reproductive organs: most cestodes are hermaphroditic. Each mature proglottides contain at least one set of male and female reproductive organs.

Male testes are (3-1200) spread throughout the segment; sperm is collected in the seminal vesical; delivered to female organ via cirrus organ.

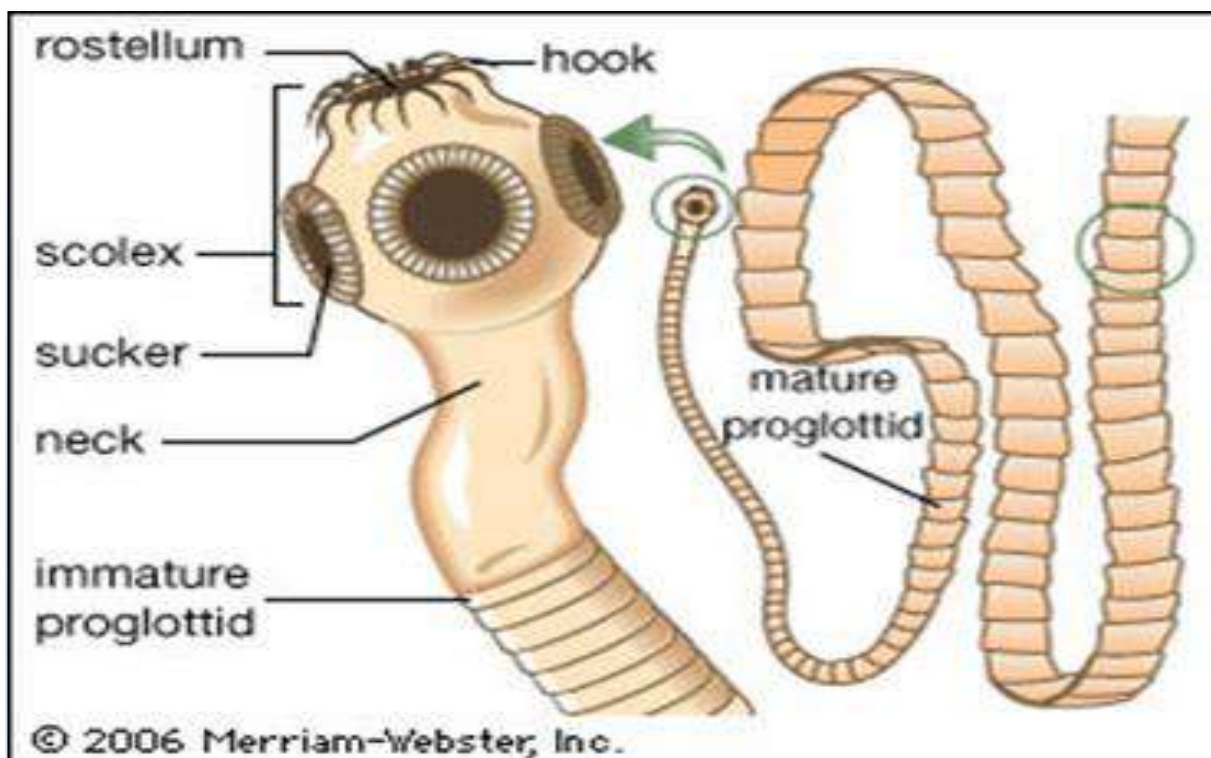
Female: ovaries produce hexacanth eggs, which are stored in the uterus.

- **Development of proglottides :** the proglottides originate in the posterior part of the neck and develop progressively
- As they are pushed back, they mature & eggs are produced.
- When filled with eggs, they are “gravid” proglottids. Eggs are sometime released in feces, but often are retained within the segment. Hexacanth embryos (oncospheres) develop within the eggs. The hexacanth egg has

central pair of hooks used for penetration and the lateral pairs for propulsion.



- **Proglottides** - a few are usually shed every 2-3 days.



## Order: Pseudophyllidea

*Diphyllobothrium latum* – The Broad Fish Tapeworm:

Disease Diphyllbothriasis, fish tapeworm infection, broad tapeworm infection.

### Morphology:

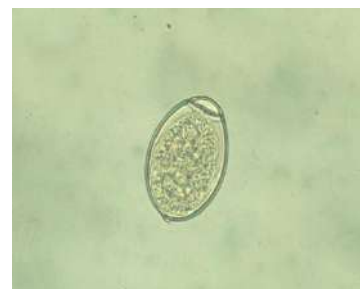- Adult worms are up to 15 meters in length.
- Scolex is an almond or finger shaped with a pair of suckorial grooves, known as bothria on dorsal and ventral surface.
- Proglottides has a rosette shaped uterus; the uterine pore is centrally located on ventral surface, not lateral as with *Taenia spp.*
- Eggs shed up to a million eggs a day, measure 30 x 60 microns, and exhibit an operculum (this is the only cestode with an operculated egg). Shed up to million eggs per day.



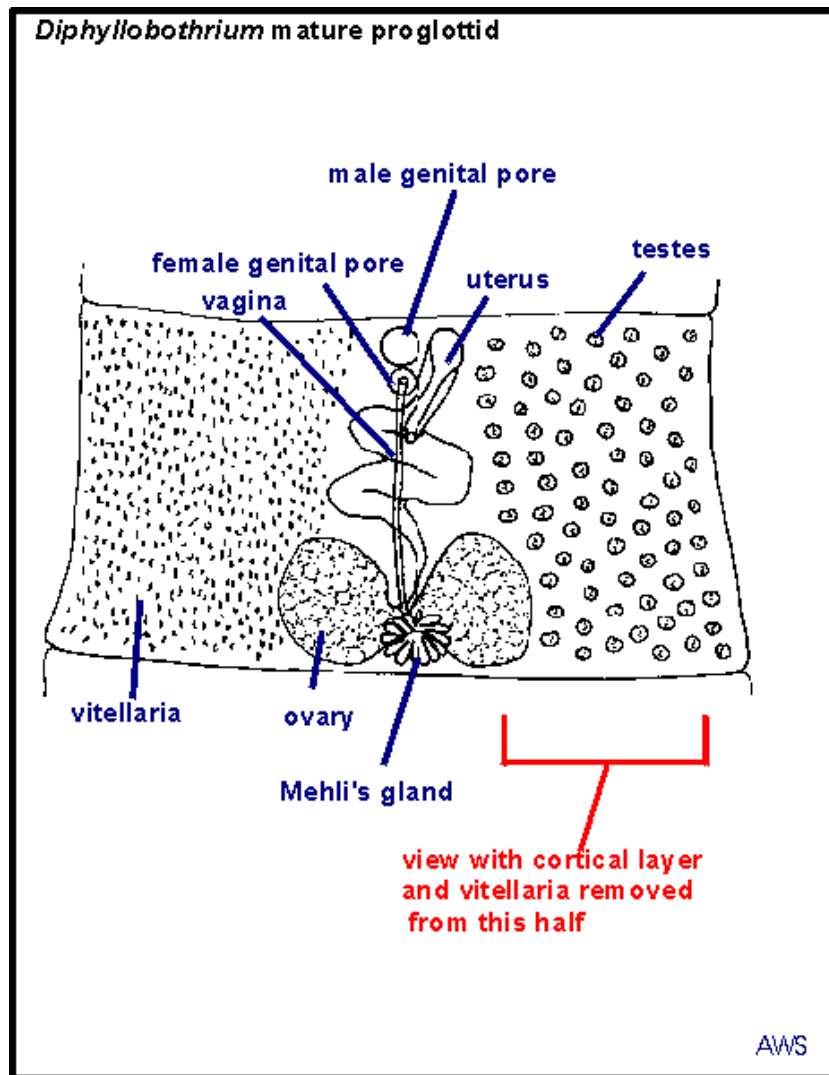
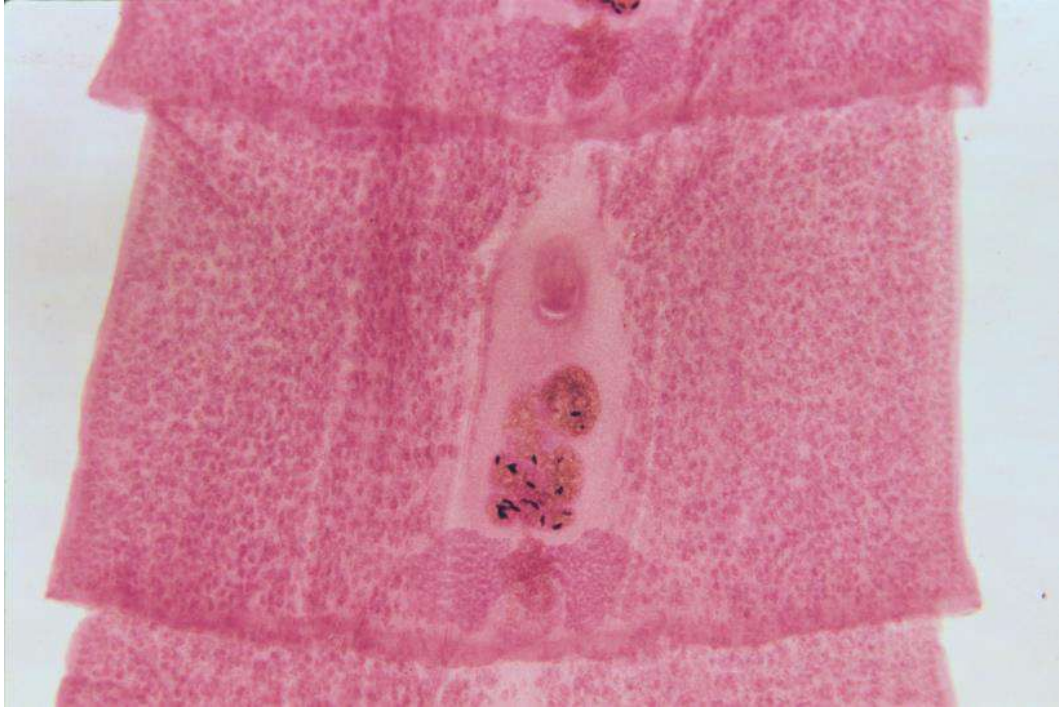Scolex



Proglottid



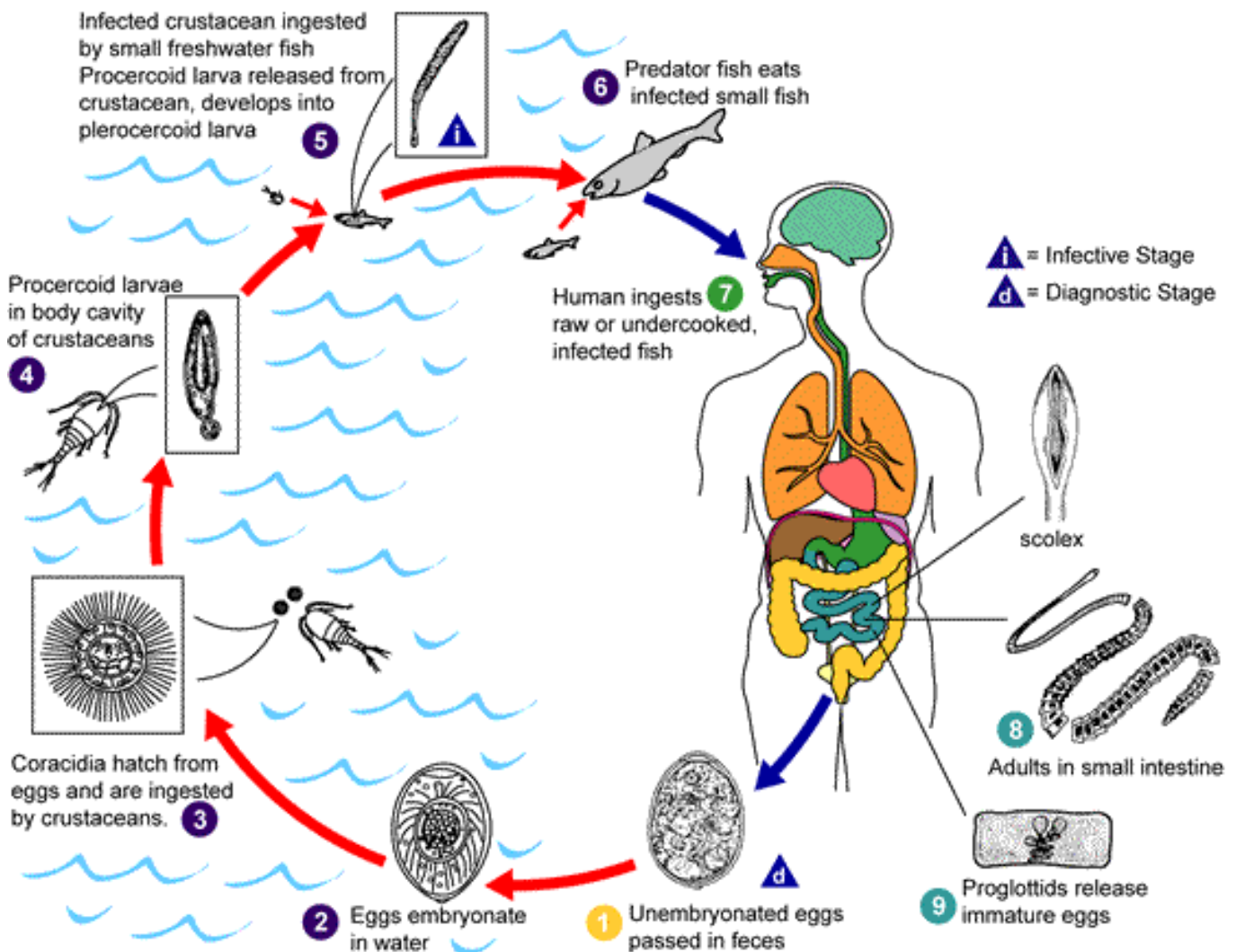
Egg





### Life cycle:

- Two intermediate hosts are required, copepods (water flea) and fish.
- Several fish-eating mammals serve as definitive hosts: bears, cats, dogs and humans.
- The infective stage for mammals is the plerocercoid larva, which is ingested in raw or undercooked fish.
- Larvae attach to the mucosa lining of the small intestine, grow rapidly and may begin egg production in 7-14 days and develop to adults.
- Its life span covers up to 20 years.





### **Pathology:**

- Intestinal obstruction.
- Many people exhibit vague diagnostic symptoms such as weight loss and weakness.
- May cause a macrocytic anemia and eventual nervous system disturbances due to vitamin B12 deficiency. The worm has affinity for vitamin B-12, and can selectively absorb it.

### **Diagnosis**

- Diagnosis made by finding the typical brown, oval, operculate eggs in feces using standard recovery techniques
- Eggs: measure 58 - 76  $\mu\text{m}$  by 40 - 51  $\mu\text{m}$  and in addition to the operculum, have a small round knob-like projection on the abopercular end.
- Scolex: elongated; displays a pair of longitudinal grooves known as bothria, which replace the usual suckers
- Evacuated gravid proglottides: wider than long, have genital pores located midventrally, adjacent to centrally located, rosette shaped uterus

## **Order: Cyclophyllidea**

**Family :** Taeniidae.

### ***Taenia saginata* – The Beef Tapeworm**

Disease: Taeniasis, beef tapeworm infection.

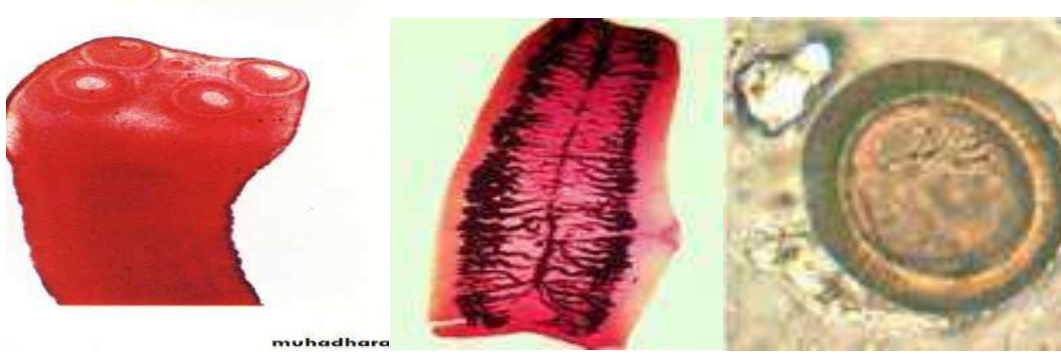
- Man is the only definitive host.
- Infection - ingestion of *cysticercus bovis* in flesh of cow. The *cysticercus* undergoes degeneration and calcification in about a year,

although cysticerci have been found 150 weeks after infection of cattle.

- Size – over 20 meters in length.
- Man have only a single adult worm (although 70' worms have been reported).
- Life expectancy - 25 years or more.

### **Morphology:**

- Scolex - unarmed (no hooks); 4 sucking disks.
- The inside of each mature proglottid is filled with muscular layers and complete male and female reproductive systems, including the tubular unbranched uterus, ovary, irregularly unilateral genital pore, testes, and vitelline gland.
- Gravid proglottides - one inch or slightly longer; uterus contains 15 to 20 primary branches filled with eggs. The uterine pore is located in a lateral position.
- Eggs are identical to *T. solium*, measuring about 40 microns in diameter.
- *T. saginata* adults usually have 1,000 to 2,000 proglottides, while *T. solium* adults have an average of 1,000 proglottides. The eggs contained in the gravid proglottides are released after the proglottides are passed with the feces. *T. saginata* may produce up to 100,000 and *T. solium* may produce 50,000 eggs per proglottid respectively.



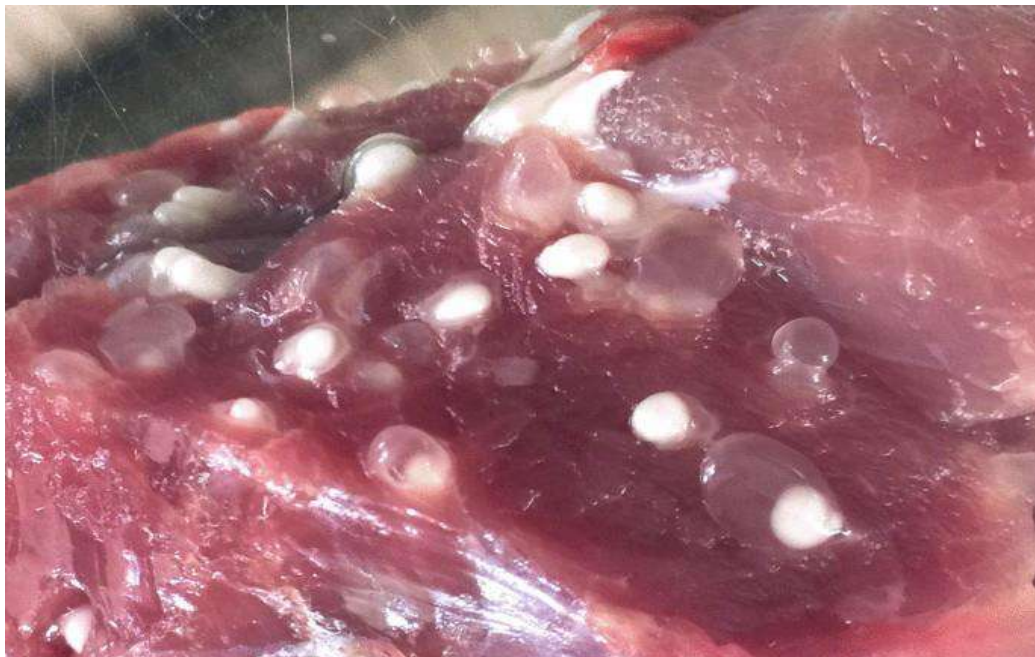
Scolex

Gravid proglottid

Egg

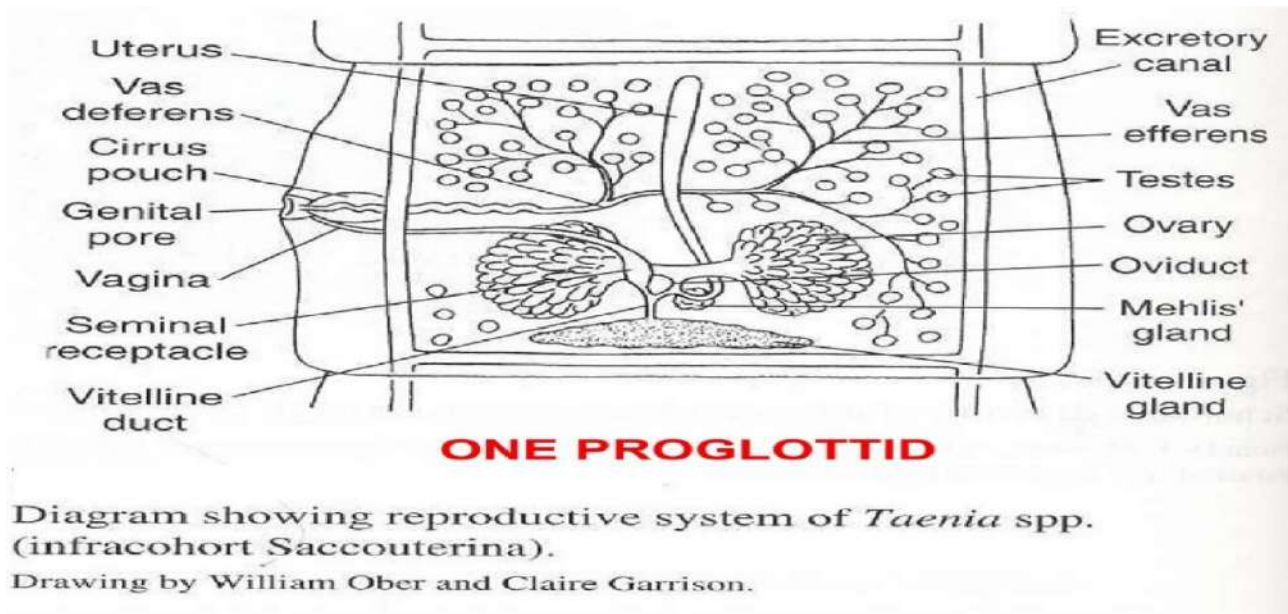
### Life cycle:

- Infective eggs (from human feces) are ingested by the intermediate host (cow or pig).
- The oncosphere hatches and penetrates the intestinal mucosa of the intermediate host. It is delivered to various parts of body via the circulatory or lymphatic systems. Most localize & encyst in muscle.
- Infective stage - the encysted larva, called a cysticercus develops within 2 months.



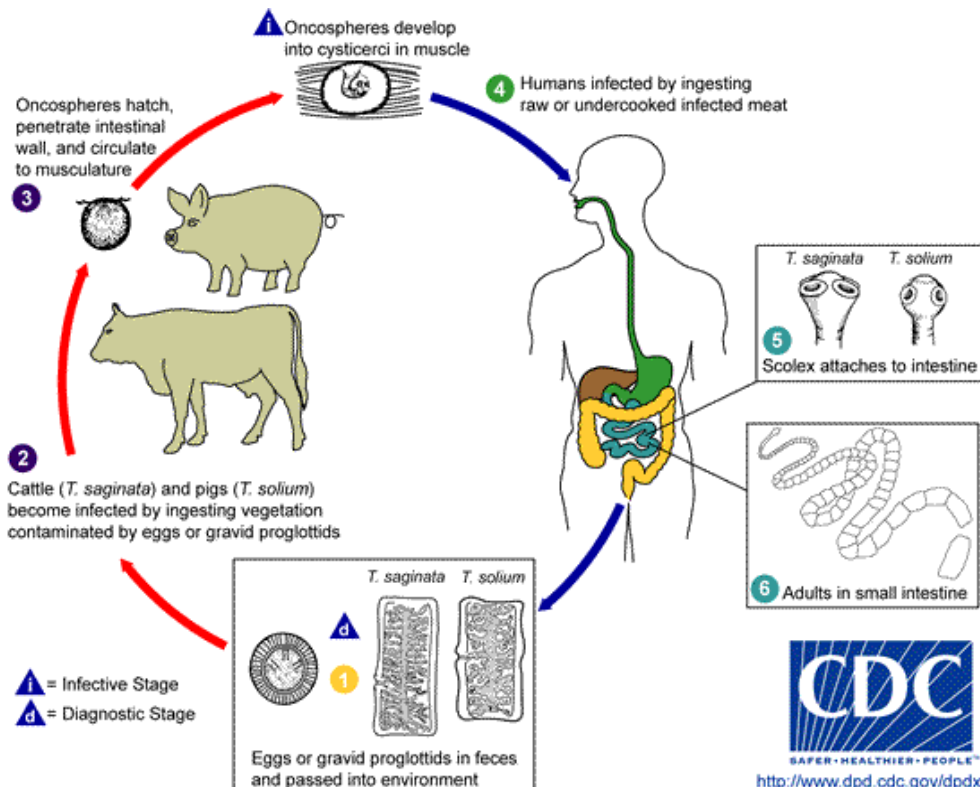
*Cysticercus bovis*

- Human infections take place when uncooked or undercooked meat containing larvae is ingested.



## Epidemiology:

Cattle are coprophagous and often will eat human dung, wherever they find it. In India, where cattle roam at will, it is common for a cow to follow a person into the woods, in hopes of obtaining a fecal meal.



## Pathology

- Scolex - attaches to human intestine causing irritation of the intestinal mucosa.
- Toxic substances produced causing necrosis of the tissue.
- Epigastric pain and awareness of the movement of the worm.
- 1/3 of the patients fell giddiness specially when hungry.
- Anemia mild in about 10% of cases.
- Eosinophilia in about 6-12% of cases.

## ***Taenia solium* – The Pork Tapeworm**

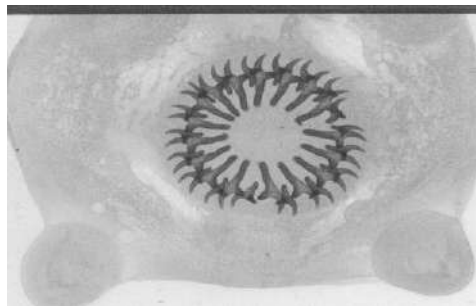
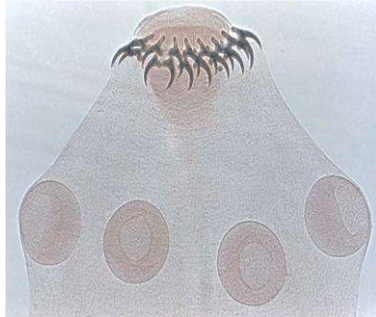
Disease: Taeniasis, pork tapeworm infection.

### General:

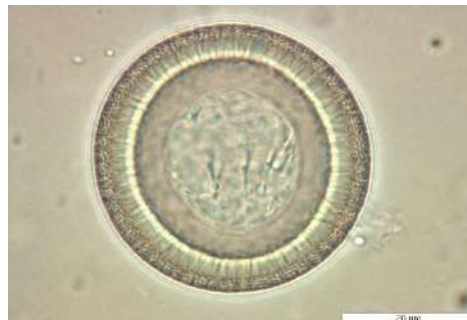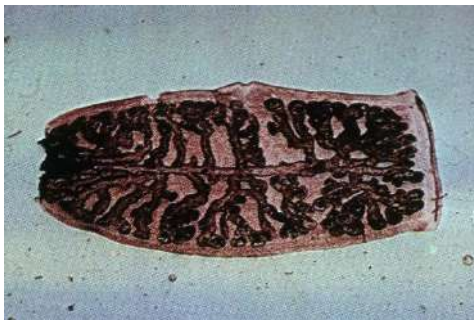
- Man is the only definitive host.
- Infection - ingestion of *cysticercus cellulosae* in flesh of swine.
- Size - up to 7 meters in length.
- Life expectancy - 25 years or more.
- Autoinfection – called cysticercosis, due to ingestion of eggs from feces if infected with adult worm.
- Racemose form of infection may develop in the brain. A Racemose is a larva which is branching, spreading throughout tissue.

## Morphology:

- Scolex - armed, with 4 sucking disks.
- Gravid proglottid has 7-13 primary uterine branches.
- Eggs are identical to *T. saginata*, measuring about 40 micrometer in diameter.

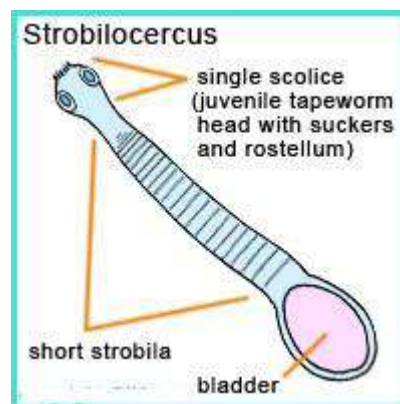
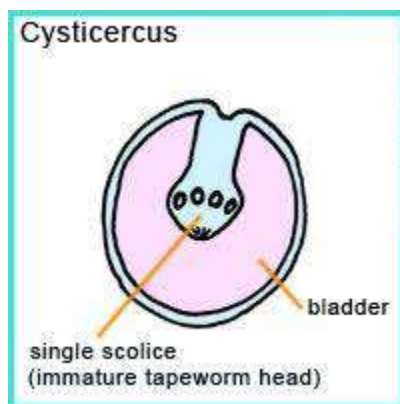


Scolex



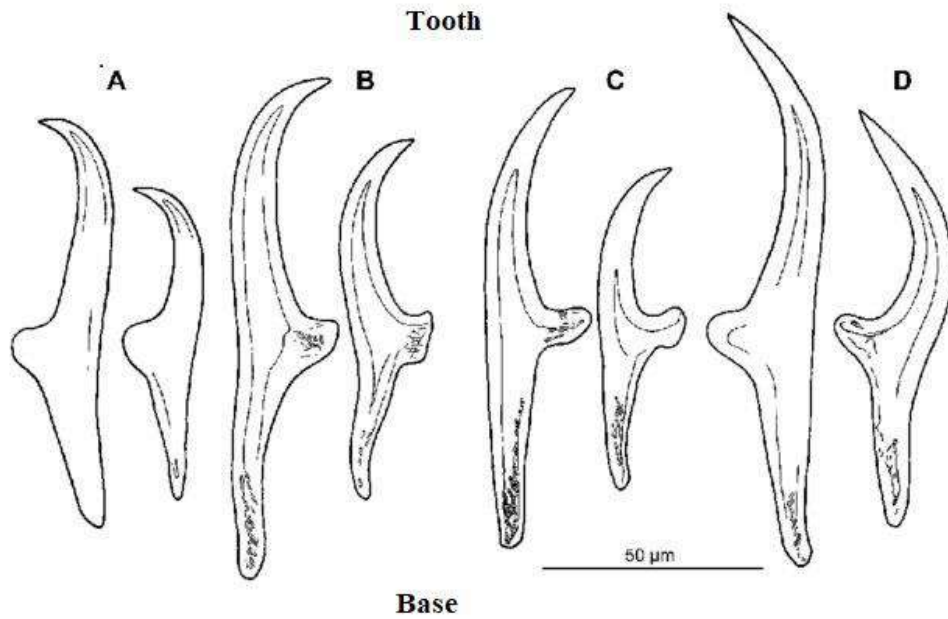
Gravid proglottid

Egg



Life cycle: illustrated in life cycle of *Taenia saginata*

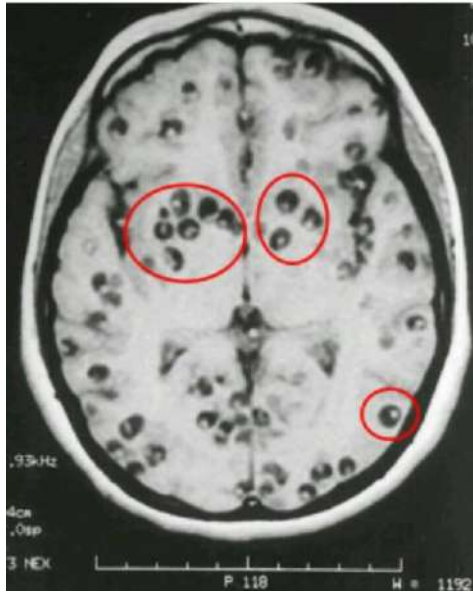



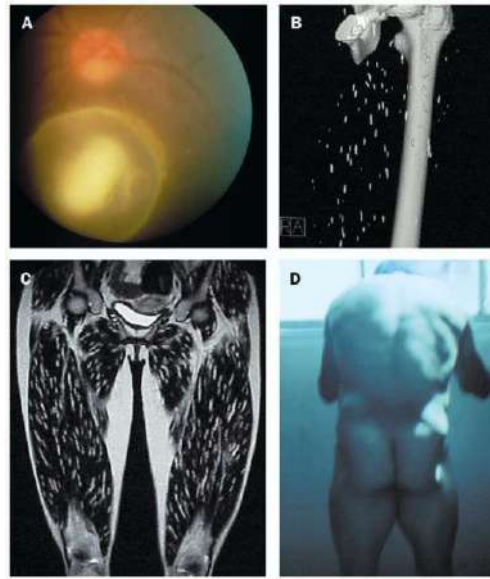
Rostellar hooks

### Pathology:

- Similar to that of *Taenia saginata*, with Cysticercosis – results when humans become the intermediate host. More serious than infections with the adult stage alone. This condition only occurs with the pork tapeworm, *Taenia solium*.
- **Cysticercosis:** An infection caused by the pork tapeworm, *Taenia solium*. Infection occurs when the tapeworm larvae enter the body and form cysts called cysticerci. When cysticerci are found in the brain, the condition is called **neurocysticercosis**.
- Orbital/ocular cysticercosis (OOC) is a preventable cause of blindness.
- Virtually every organ and tissue of the body may harbor cysticerci.



Neurocysticercosis



Cysticercosis

	<i>T.Saginata</i>	<i>T.solium</i>
<b>Strobila</b>	1000 – 2000 proglottides.	800 - 1000 proglottides
<b>Length</b>	4-10 m	3-4 m
<b>Scolex</b>	4 suckers without hooks	4 suckers with 30 hooklets
<b>uterine branches</b>	15-30	7-12
<b>Eggs</b>	100.000 / day	30.000-50.000 / day
<b>Infective stage</b>	Cysticerci	cysticerci – eggs
<i>Cysticercus</i>	<i>C. bovis</i>	<i>C. cellulosae</i>
<b>Gravid proglottid</b>	2X 0.7 cm	1.5 – 0.8
<b>Testes</b>	<b>880-1200</b>	<b>375-575</b>
<b>Ovary</b>	<b>2 lobes</b>	<b>3 lobes</b>

### **Diagnosis of *Taenia saginata* and *Taenia solium***

Diagnosis of *Taenia* tapeworm infections is made by examination of stool samples; individuals should also be asked if they have passed tapeworm segments. Stool specimens should be collected on three different days and examined in the lab. for *Taenia* eggs using a microscope. Tapeworm eggs can be detected in the stool 2 to 3 months after the tapeworm infection is established.

Perianal swabbing with cellophane tape swabs give a much higher recovery of eggs than examining the feces by direct smear and concentration methods.

The diagnosis of neurocysticercosis usually requires MRI (magnetic resonance imaging) or CT (Computerized tomography) brain scans. Blood tests may be useful to help diagnose an infection, but they may not always be positive in light infections.

## **Extra intestinal larval tapeworms of man**

### ***Echinococcus granulosus* – The Hydatid Tapeworm**

Disease: Echinococcosis, hydatid disease.

- Adults are only in canines. Eggs are shed in the feces of infected animals.
- Humans accidentally ingest eggs from close contact with an infected animal or from canine feces.

- Hexacanth embryo penetrates the intestinal mucosa and migrates to tissues.
- The hexacanth develops into the larval stage (hydatid cyst) in the tissue (liver, lung or brain, most often).
- Viscera containing hydatid cysts are eaten by canines. Adult worms develop.

### **Morphology:**

- Adult worm - Small, consists of only 3-5 segments.
- Hydatid cyst - a thin walled larva, its estimated that an average fertile cyst contain 2 million protoscolices, which when eaten by a dog would produce innumerable mature adult tapeworm in about 7 weeks. Hydatid without brood capsules and protoscolices are known as sterile or **acephalocysts**.

### **Life cycle**

*Echinococcus granulosus* is a cestode whose life cycle involves dogs and other canids, as definitive hosts for the intestinal tapeworm, as well as domestic ungulates as intermediate hosts for the tissue-invading metacestode (larval) stage. This is known as **domestic echinococcosis**. The worms matures in about 56 days, and may live for 5-20 months.

The life cycle of *E. granulosus* in wild animals may involve a wolf, moose, wolf reindeer, dingo wallaby, lion-warthog or other carnivore-herbivore relationship, which is known as **sylvatic echinococcosis**

### **The role of bile in infection with adult *E. granulosus***

The composition of bile varies substantially within different vertebrate groups and, in some cases at least, these difference may play a part in determining host specificity.

Cholic acid is the commonest acid found in bile but other common acids are **deoxycholate, chenocholic, hypocholeic** and **lithocholic**.

- ❖ Carnivore biles contain largely salts of cholic acids, where as,
- ❖ Herbivores contain high levels of salts of deoxycholic acid.
- ❖ Since the protoscoleces of *E. granulosus* is very rapidly lysed by sodium deoxycholate but unaffected by cholate
- ❖ Therefor it is clear that this species could not established its self in a herbivore gut as well as human gut.

### **Hydatid cyst**

In man hydatid cysts are of three types:

1. Unilocular. A mojority of human hydatids are unilocular .
2. Osseous. Hydatids found in bony tissues with no limiting membranes.
3. Alveolar of *E.multilocularis*.

The Unilocular cyst grows slowly and requires several years for development. In man the completely developed cysts, if uninfluenced by pressure are more or less spherical and are usually 1-7 cm in diameter, and may reach 20cm. the cyst has:

1. An external laminated nonnucleated hyaline, supporting cuticula, 1mm thick.
2. An inner, nucleated germinal layer, 22-25 micrometer.
3. Colorless or light-yellow sterile fluid that causes distention of the limiting membranes.
4. Brood capsules which have only the germinal layer, containing protoscolices.
5. Daughter cysts which are replicas of the mother cysts.

When the brood capsule ruptures, the protoscolices escape into the hydatid fluid, where they are known as **hydatid sand**.

If a large abdominal cyst bursts, either spontaneously or following a blow on the abdomen, protoscolices spilled out the cystic cavity will become implanted on the peritoneum and produce multiple secondary growths (secondary echinococcosis)



كلية النور الجامعة/قسم تقنيات المختبرات الطبية/محاضرات مادة الطفيليات النظري/المرحلة الثانية  
مدرس المادة : أ.د. إبراهيم احمد عبد الله

*Echinococcus granulosus* causes hydatid disease

Cyst in offal, esp. liver

Intermediate host:  
Sheep, cattle etc. and  
other herbivores

Definitive host:  
dog and other  
canines

Adult

30 – 36 hooks in two rows  
4 suckers

Immature

Mature

Gravid

Proglottids

Length 3–8 mm

Ovum  
30 – 37  $\mu$ m

Hydatid cyst

Surrounding host  
tissue reaction  
forming false  
capsule

Laminated  
membrane  
Germinal  
membrane

From  
parasite

Brood capsule

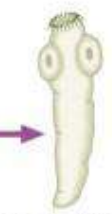
Scolices

Hydatid sand  
Remains of germinal  
epithelium  
Brood capsules  
Protoscolices

Cyst fluid  
Salts  
Enzymes



Invaginated  
in cyst



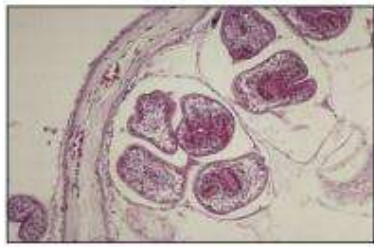Evaginated on  
entry into host

Contamination by  
food and fingers

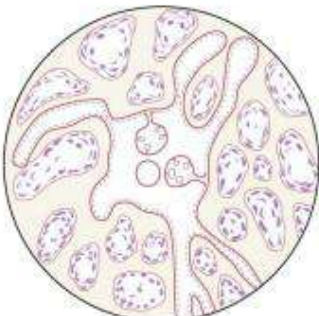Human  
intermediate  
host

Secondary  
seeding from  
ruptured cyst

Liberated embryo  
penetrates mucosa,  
carried by bloodstream  
to various sites



Brood capsules of *Echinococcus granulosus*



Intraosseous cyst

Intraosseous cyst  
Spreads along medulla by  
budding outside cyst.  
Semisolid; no fibrosis.

## **Pathology**

Hydatid disease in humans is potentially dangerous depending on the Location of the cyst. Some cysts may remain undetected for many years until they become large enough to affect other organs. Symptoms are then of a space occupying lesion. Lung cysts are usually asymptomatic until there is cough, shortness of breath or chest pain.

Serious allergic sequelae, including anaphylactic shock, may occur if there is fluid leakage from the cyst in a patient previously sensitized by small fluid leaks into the circulation.

## **Diagnosis.**

*E.granulosus* is endemic suggests a diagnosis of cystic echinococcosis.

Imaging techniques, such as CT scans, ultrasonography, and MRIs, are used to detect cysts. After a cyst has been detected, serologic tests may be used to confirm the diagnosis. Alveolar echinococcosis is typically found in older people.

## **Treatment of *Echinococcus granulosus***

Chemotherapy, cyst, and PAIR (Percutaneous puncture, Aspiration, Injection of chemicals and Respiration) with the guide of ultrasonic have been used to replace surgery as effective treatments for cystic echinococcosis. However, surgery remains the most effective treatment to remove the cyst and can lead to a complete cure.

## *Echinococcus multilocularis*

### **Disease: Alveolar echinococcosis**

Alveolar echinococcosis, caused by *E multilocularis*, is less common than cystic echinococcosis, but it is very serious and more difficult to treat. The larvae of this organism grow as multiple, budding cysts, which can infiltrate entire organs and disseminate to distant sites including the brain. As well as affecting people, alveolar echinococcosis is reported to cause serious disease in animal intermediate hosts including dogs. The occurrence of this organism in a wildlife cycle between foxes and small mammals makes it difficult to prevent.

### **Life cycle**

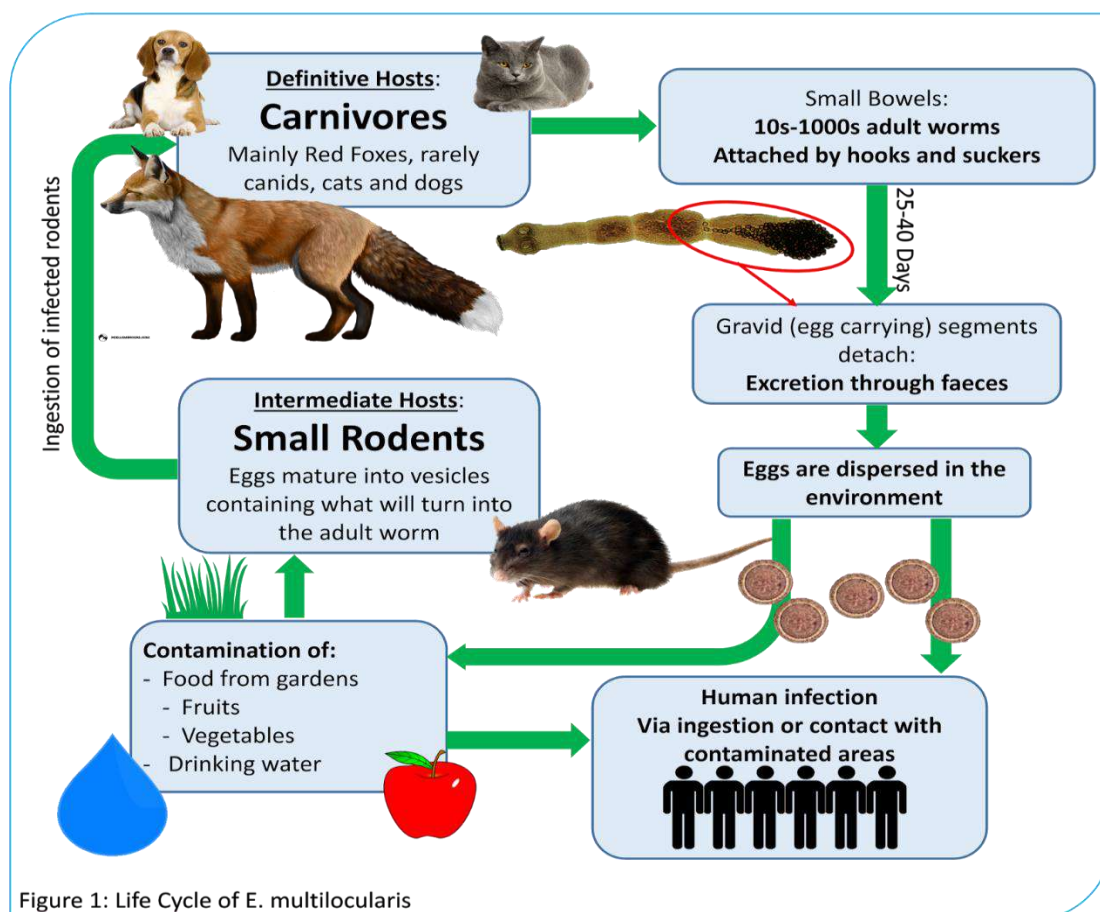


Figure 1: Life Cycle of *E. multilocularis*

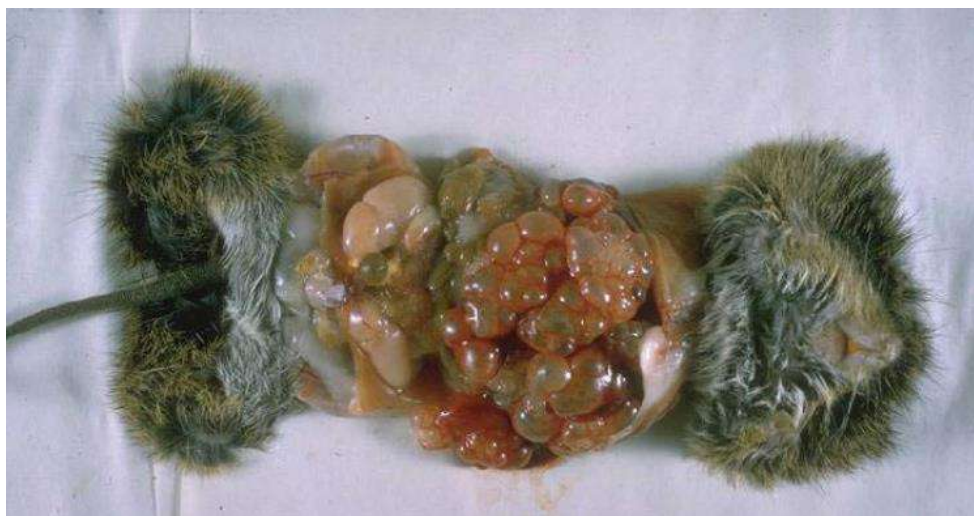

Differences btn <i>E. granulosus</i> & <i>E. multilocularis</i>		
	<i>E. granulosus</i>	<i>E. multilocularis</i>
Strobila	3 segment only	3-5 segment
Size	3 - 9mm long	1.2 – 5.5 mm long
Genital pore	Behind the middle line of gravid segment	Anterior to the middle of gravid segment
Length of gravid segment	> ½ of the body length	< ½ of the body length
Hydatid cyst	Unilocular Contain scolices	Alveolar No scolices
Testis	46 – 60	16 – 26
Host	Sheep, Cattle, Horses etc.	Rodents, foxes, Wolves etc.

20

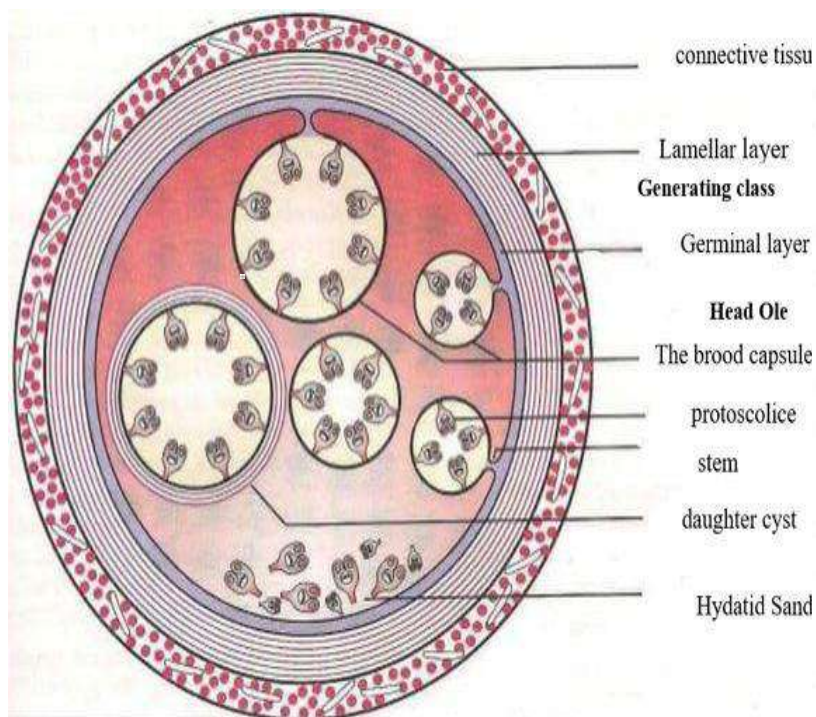
## Pathology

*Echinococcus multilocularis* is a tapeworm of foxes that may cause a zoonotic infection resulting in a highly pathogenic and potentially fatal chronic liver infestation called human alveolar echinococcosis.

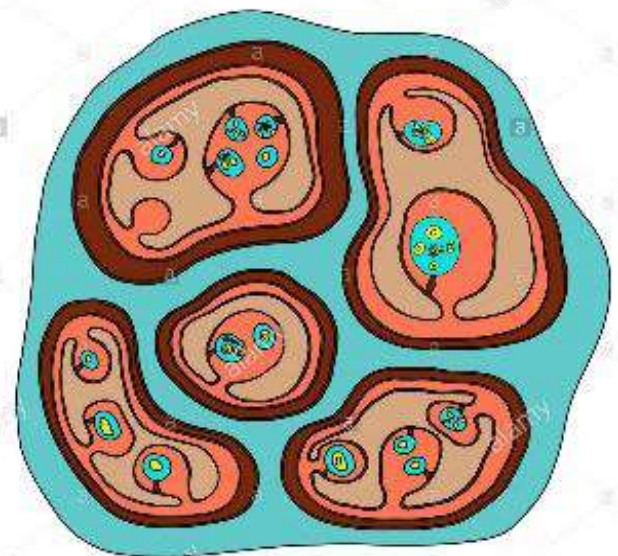


## Diagnosis

- 1- ELISA was evaluated using rabbit and chicken polyclonal antibodies against *E. multilocularis* antigens.
- 2- A Polymerase Chain Reaction (PCR)
- 3- Detection of circulating anti-Em2 antibodies by ELISA may be useful for primary screening of fox populations but antibody prevalence rates do not correlate with prevalence rates of the intestinal infection with *E. multilocularis*.



C.S of *E. granulosus* hydatid cyst



C.S of *E. multilocularis* cyst

## Family : Dilepididae

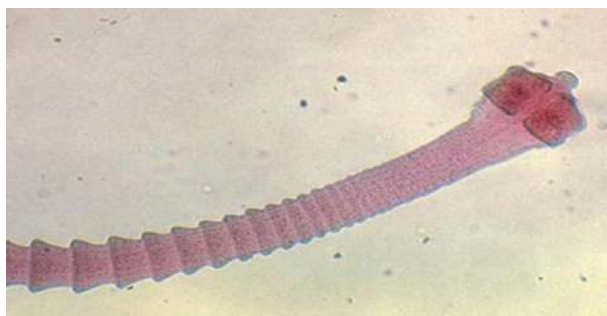
### *Dipylidium caninum* - The Double-Pored Tapeworm

**Disease:** Dipylidiasis, dog tapeworm infection.

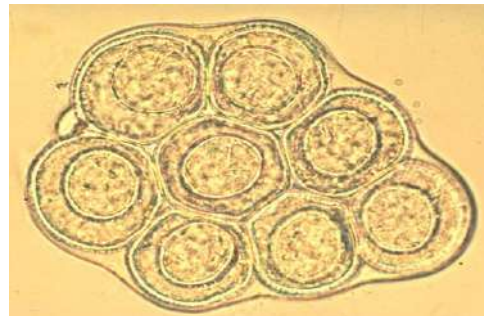
- Rare in humans, occurring primarily in infants and small children closely associated with pets .
- Eggs are ingested by fleas (dog or cat fleas are intermediate hosts); larvae develop within fleas .
- The definitive host (dog, cat, human) is infected by ingestion of larvae within fleas. The worm develops in the small intestine of the definitive host, in about 20 days.

### **Morphology:**

- Adult - the adult is up to 70 centimeters in length, having 60-175 proglottides.
- Scolex - armed rostellum with 30-150 hooks arrange in transverse rows 1-7.
- 4 sucking disks.
- Gravid proglottides - are the size of rice grains, and exhibit a genital pore on each side.
- Eggs - contained within packets or egg capsules (up to 15-25 eggs/packet).

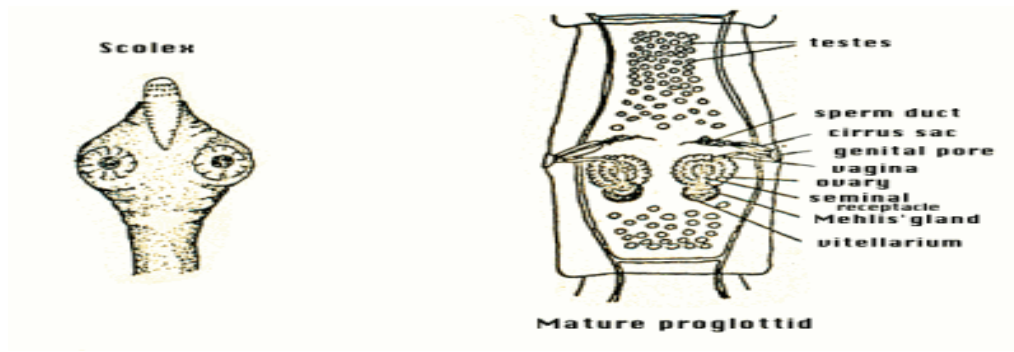


Scolex



Egg capsules

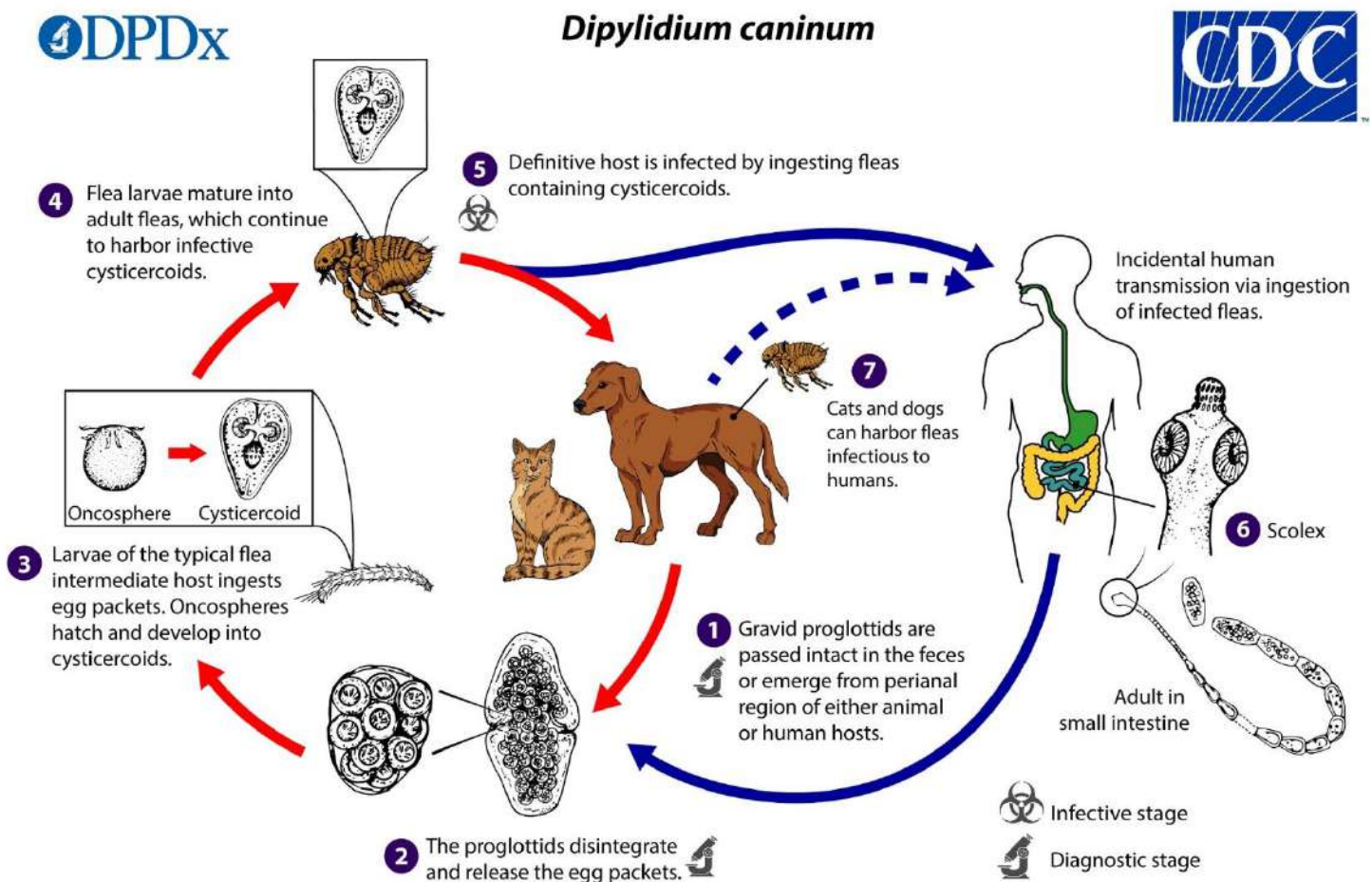




Mature proglottid

## Life cycle

- Usually tapeworm eggs are ingested by flea larvae, which infest areas frequented by dogs or cats.
- Cysticeroid larvae persist as the flea undergoes metamorphosis to the adult stage.
- Dogs, cats and humans ingest the adult flea containing the infectious cysticeroid.
- Children are at highest risk for infection because of their close contact with pets.
- Worms mature in the human small intestine in about 20 days and grow up to 70 cm in length.
- Infection produces few symptoms.



## Diagnosis

- Based on finding characteristic eggs, egg packets or proglottides in feces.
- Spherical eggs contain a six hooked embryo, measure from 24 - 40  $\mu\text{m}$  in diameter and occur singly or in packets.
- Scolex (head) is somewhat elongated with four suckers and a small retractable rostellum.
- Proglottides are barrel shaped and possess two genital pores, one on each lateral margin, which give rise to the common name double pored tapeworm.

## Family : Hymenolepididae

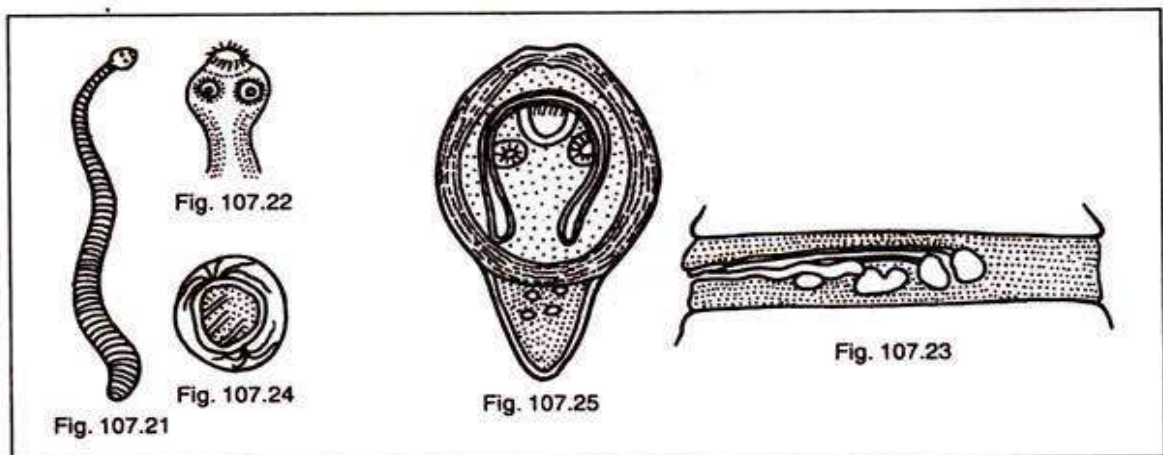
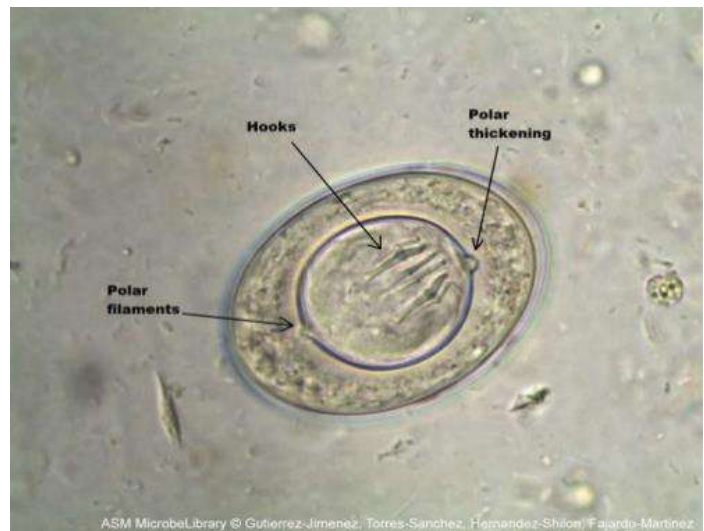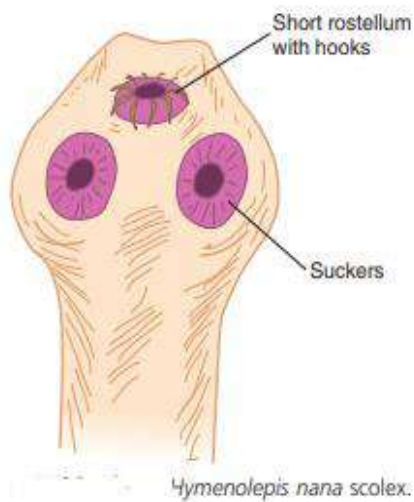
### *Hymenolepis nana* – The Dwarf Tapeworm

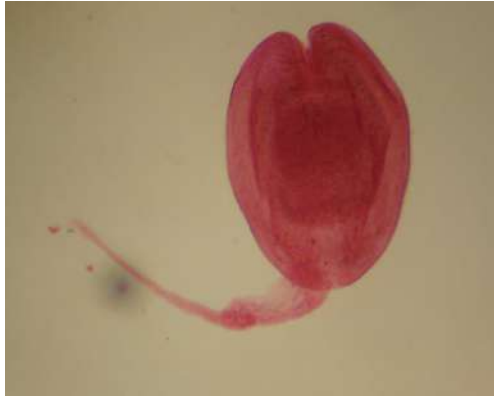Disease: hymenolepiasis, dwarf tapeworm infection.

- Frequency - most common tapeworm infection in humans.
- Requires no intermediate host - can use insects such as fleas or beetles, but these are not required.
- Definitive hosts - man, rodents.
- Autoinfection - infected humans can ingest eggs from their own feces.
- Mode of Infection - Ingestion of eggs or insects containing larvae.

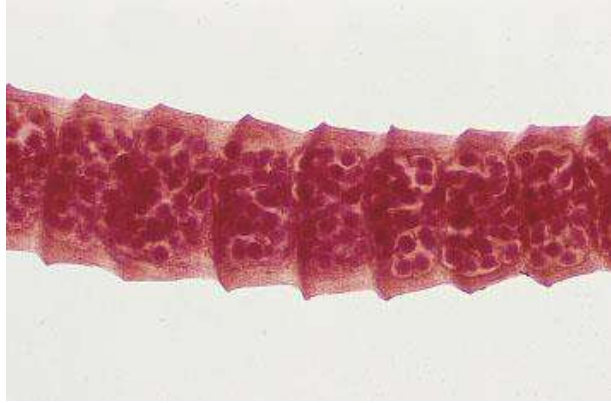## Morphology

- small, 2 to 4 cm in length, may have 200 proglottides.
- Scolex - 4 sucking disks & short rostellum with single row 20-30 hooks.
- Male reproductive system have 3 round testes.
- Proglottides - are broader than long; rarely seen in feces specimens (usually disintegrate in intestine). Genital pores are regularly unilaterally.
- Eggs - most often seen stage in specimens, measuring 45 to 50 microns in diameter and exhibiting polar thickening and 4 pairs of filaments lying between the egg shell and the hexacanth embryo.





Cysticercoid



Gravid proglottid

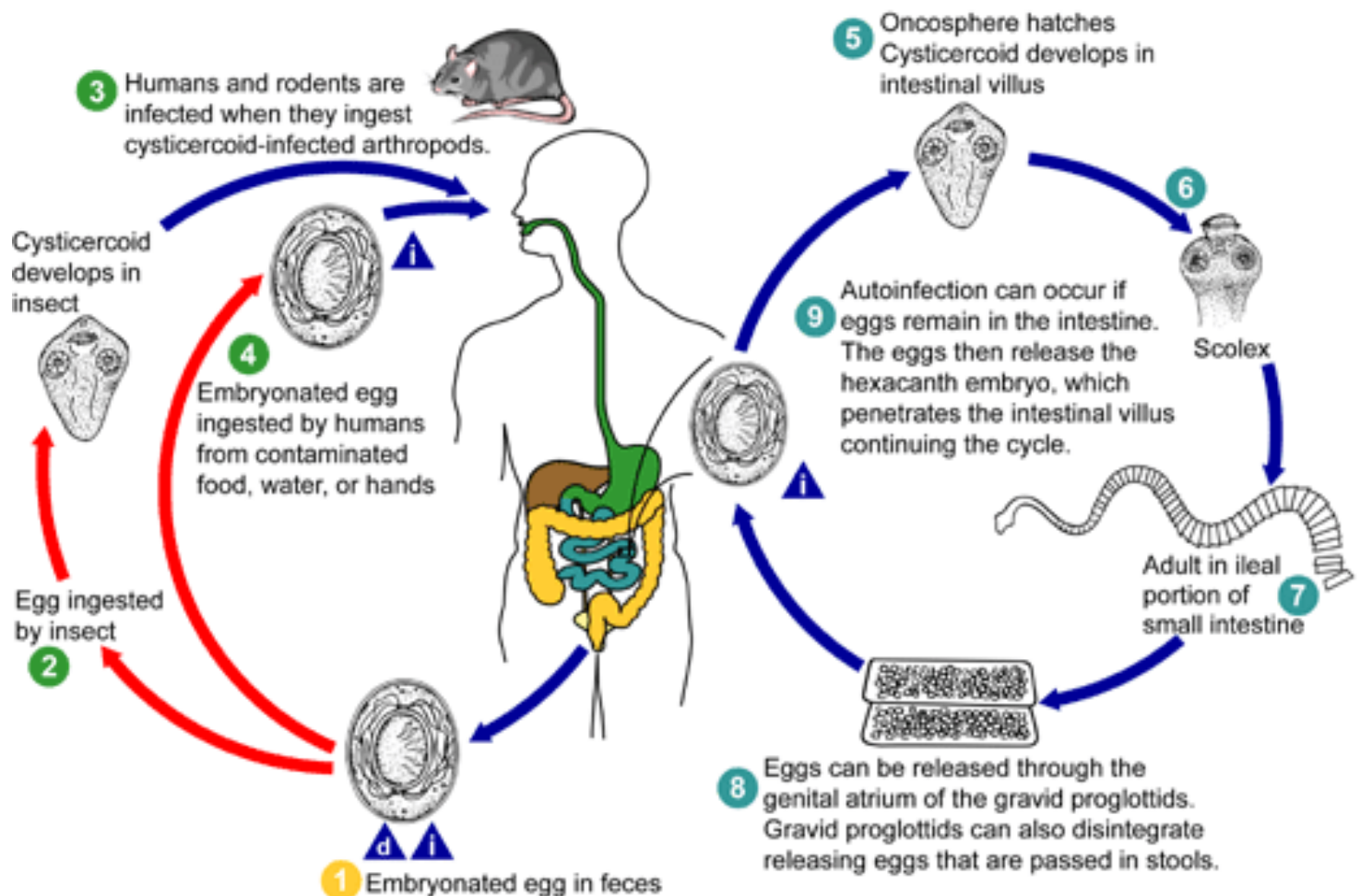
### Life cycle

Eggs of *Hymenolepis nana* are immediately infective when passed with the stool and cannot survive more than 10 days in the external environment. The life span of adult worms is 4 to 6 weeks, but internal autoinfection allows the infection to persist for years.





**i** = Infective Stage  
**d** = Diagnostic Stage



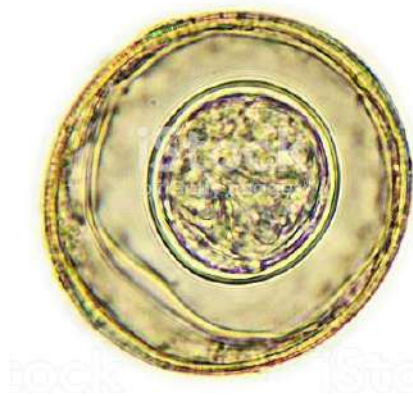
## Diagnosis

The diagnosis depends on the demonstration of eggs in stool specimens. Concentration techniques and repeated examinations will increase the likelihood of detecting light infections.

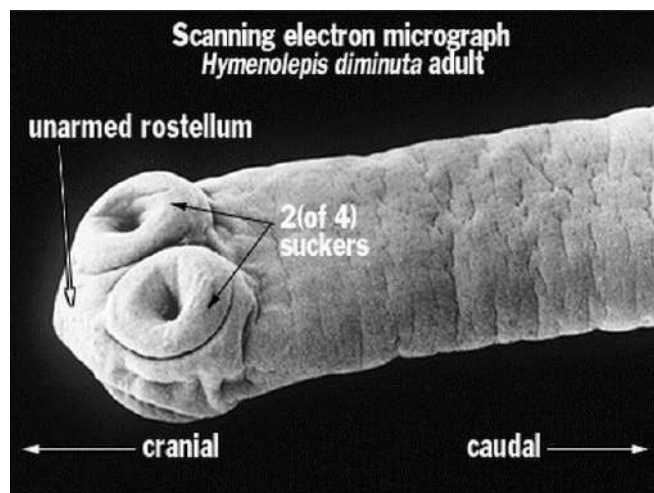


### *Hymenolepis diminuta*

- *Hymenolepis diminuta*, a common parasite of rats throughout the world, occasionally parasitizes humans.
- A single worm may reach a length of 90 cm (800-1000 proglottides). The scolex in this species is unarmed, and the width of each proglottid is greater than its length. The morphology of proglottides is markedly similar to that of *H. nana*.
- The eggs are usually yellowish-brown and spherical. Unlike that of *H. nana*, the embryophore in these eggs does not bear conspicuous knobs and filaments at the poles.



Egg



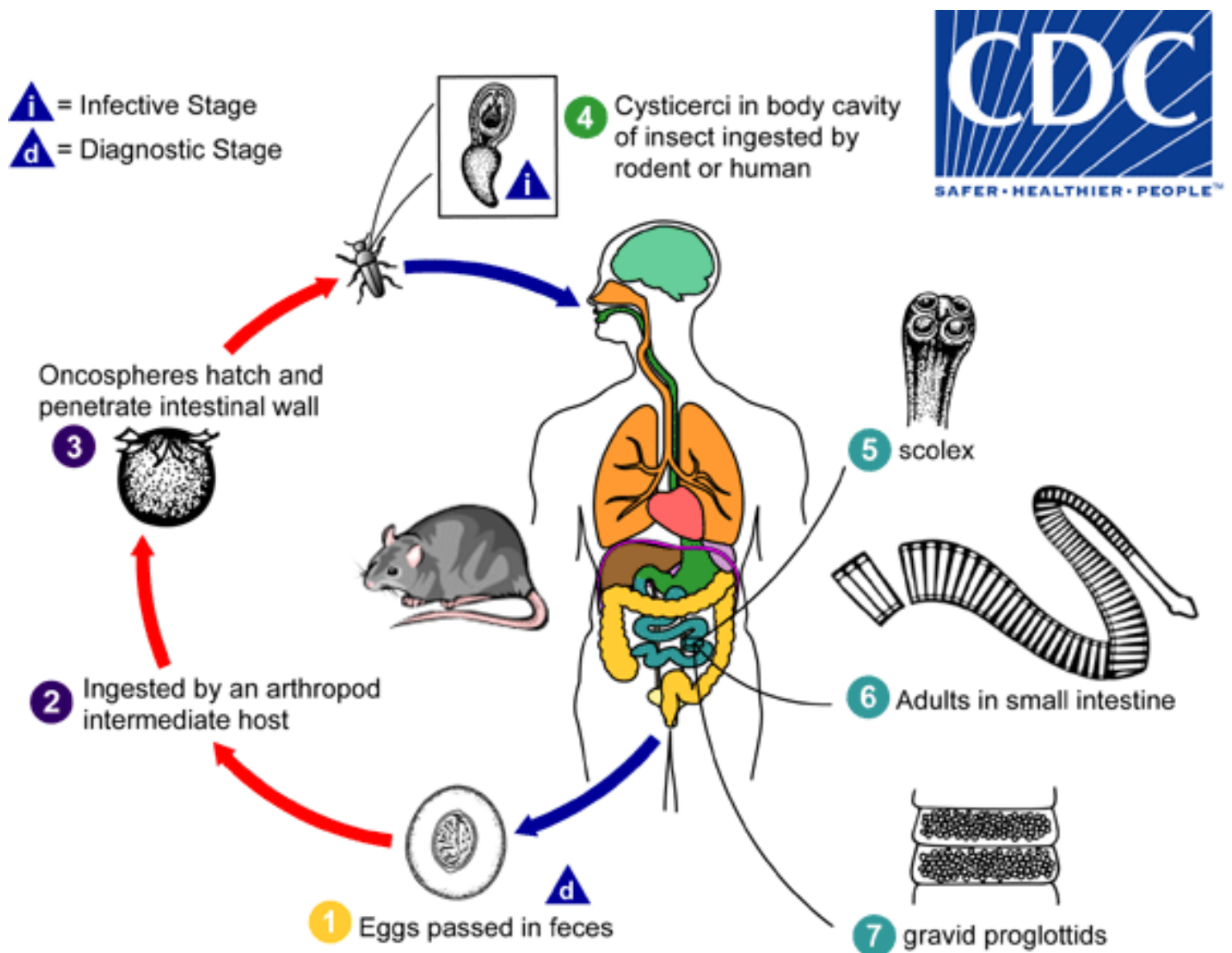
Scolex

### Life cycle

- Insects are infected when they consume rodent feces containing either gravid proglottides, which have become detached from the strobila, or eggs. The oncosphere, utilizing its hooks and secretions from the penetration glands, penetrates the intestinal wall of the

insect and enters the hemocoel where it develops to the cysticercoid stage.

- The most common intermediate hosts are grain beetles belonging to the genera *Tribolium* and *Tenebrio*.
- Humans acquire infection by eating cereals, dried fruits, and other similar foods contaminated with infected insects. The cysticercoid, once ingested by the definitive host, is freed from the insect's tissues in the small intestine.



	<b>Hymenolepis nana</b>	<b>Hymenolepis diminuta</b>
Common name	Dwarf tapeworm (smallest tapeworm)	Rat tapeworm
Scolex	Armed rostellum	Unarmed rostellum
eggs	With 4 to 8 polar filaments	Without filaments
Infective stage	Eggs (direct) Cysticercoid larvae (indirect)	Cysticercoid larvae
Intermediate host	Fleas (Ctenocephalides canis, Xenopsylla cheopis, Pulex irritans) Flour beetles (Tenebrio molitor, T. obscurus, Tribolium confusum)	Insects
Final host	man	Norway rats

## Diagnosis

**Stool:** The standard O&P (ova and parasite) examination is the recommended procedure for recovery and identification of *H. diminuta* eggs in stool specimens, primarily from the wet preparation examination of the concentration sediment. The eggs are most easily seen on a direct wet smear or a wet preparation of the concentration sediment.

**Adult worms** the scolex has four suckers and a short rostellum without hooks. The adult worm is rarely seen in the stool.

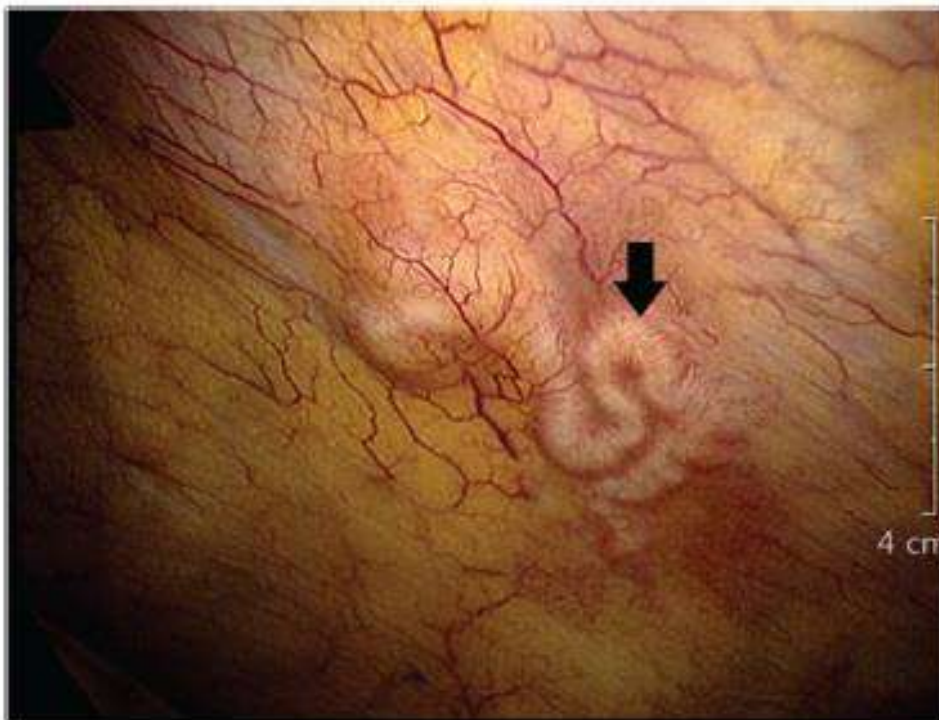### Types of cestode metacestodes (infective larval, juvenile stages)

Infective stage	Representative cestode
1. Plerocercoid (sparganum)	<i>Diphyllbothrium latum</i>
2. Cysticercus	<i>Taenia saginata, T. solium</i>
3. Unilocular hydatid cyst	<i>Echinococcus granulosus</i>
4. Multilocular (alveolar) hydatid cyst	<i>Echinococcus multilocularis</i>
5. Cysticercoid	<i>Dipylidium caninum</i> <i>Hymenolepis nana</i> <i>Hymenolepis diminuta</i>

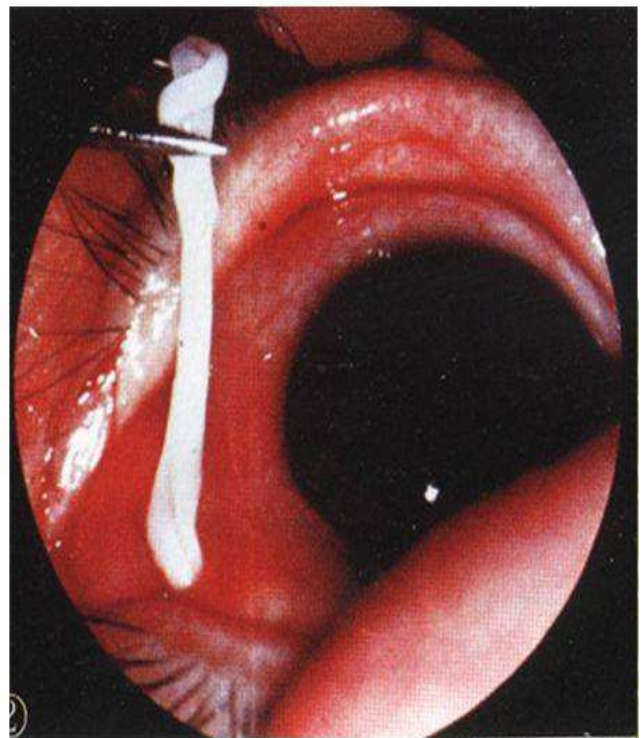
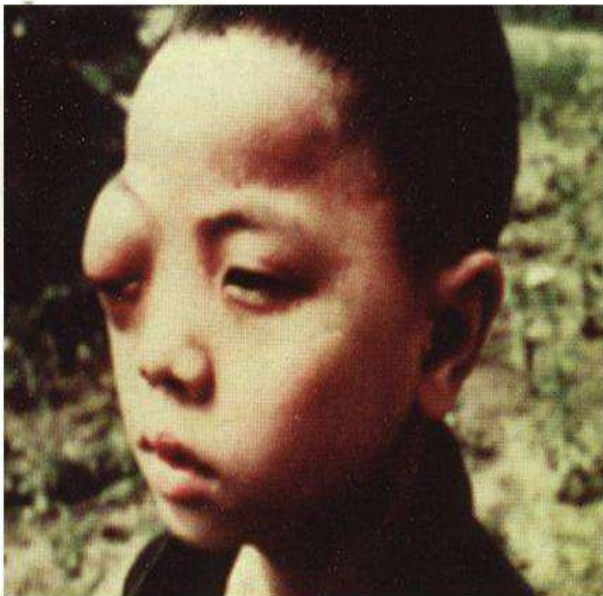
## Sparganosis

Sparganosis is infection by the third-stage plerocercoid larva (sparganum) of pseudophyllidean cestodes of the genera *Spirometra* and *Sparganum*, the latter of which may be an aberrant *Spirometra* sp. The definitive hosts for *Spirometra* spp. are *canids* and *felids*, and humans serve as only paratenic or second intermediate hosts for the parasites. Spargana can be found in many organs in the human host, including the pleural cavity, eyes, pericardium, abdominal cavity and viscera, and the central nervous system.





Sparganum larva migrating along the parietal pleura found by thoracoscopy.



## Ocular Sparganosis

## Phylum: Platyheminthes

### General characters

- 1- Dorso-ventrally flattened bilateria.
- 2- Without Coelom (Acoelomate).
- 3- Organs are embedded in paranchymatous tissues.
- 4- Without anus.
- 5- No circulatory, respiratory or skeletal structures are present.
- 6- Excretory system is of the type of proto-nephridia.

### Classes

- 1- Turbellaria (free living).
- 2- Trematoda.
- 3- Cestoda.

## Sheep liver fluke

- Common liver fluke or *Fasciola hepatica*.
- Inhabits the bile ducts and sometimes invades other organs.
- Commonest in sheep and cattle but is sometimes found in other mammals and occasionally in humans, producing the disease known as liver rot or fasciolosis.
- One of the largest flukes of the world, reaching a length of 30mm and a width of 13mm.
- The anterior sucker is terminal surrounding the mouth, and close behind is the ventral (posterior) sucker for attachment in host.
- Digestive system: mouth, muscular pharynx, short esophagus, and two branched enteron.

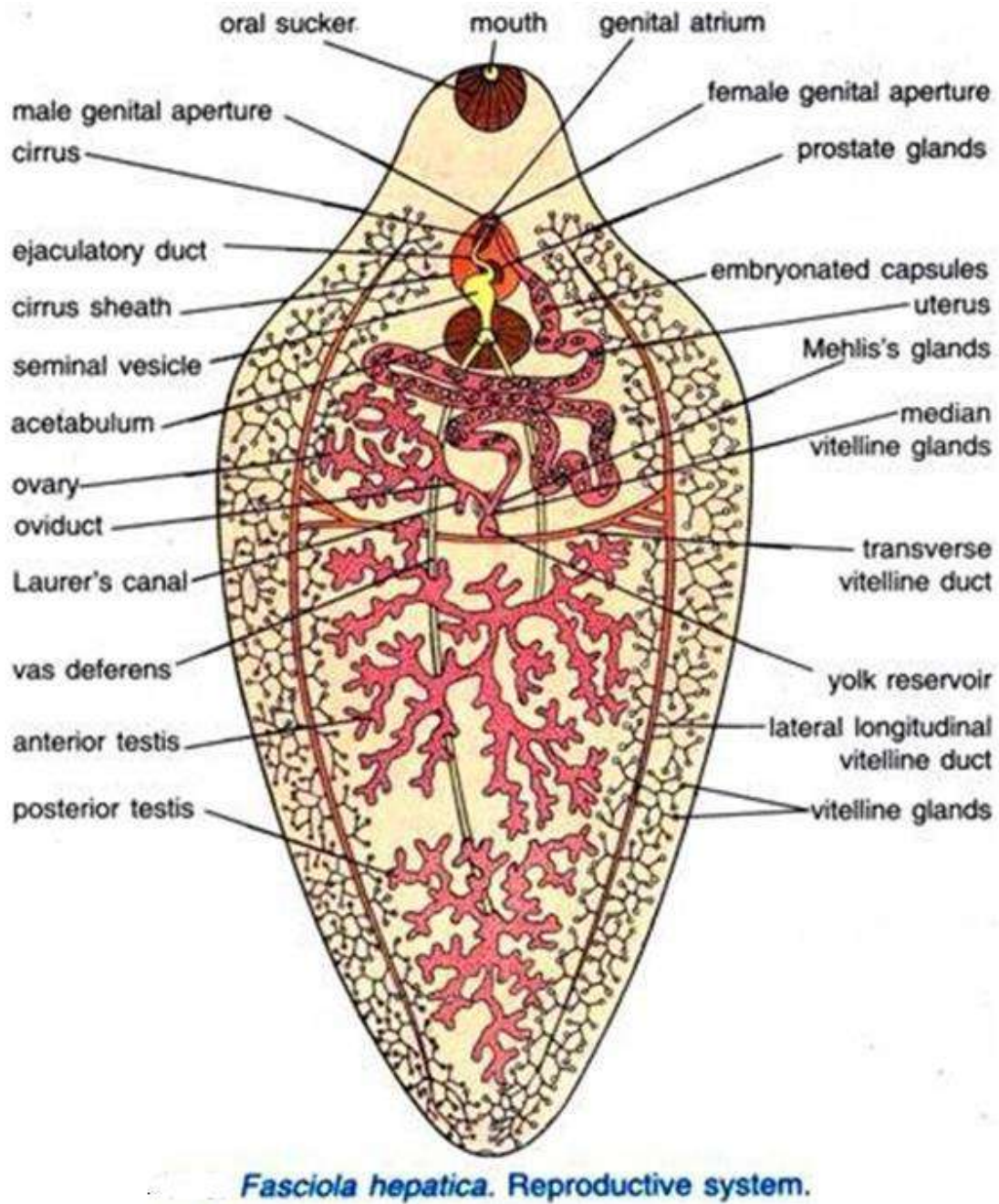


- Excretory has many flame cells.
- Hermaphroditic.
- The testes are two large and greatly branched, arranged in tandem behind the ovary.
- The smaller, dendritic ovary lies on the right side, uterus coiling between the ovary and the preacetabular cirrus pouch. Vitelline follicles are extensive, filling most of the lateral body and becoming confluent behind the testes.

## ***Fasciola hepatica***

**Disease: fascioliasis, liver rot.**

- Commonly known as the sheep liver fluke.
- Important parasite of sheep and cattle (other grazers) can be found in humans.
- Morphology:
  - Large size, frequently over 30 mm long.
  - Characteristic cone-shaped projection at anterior end followed by wide shoulders.
  - The oral and ventral suckers are large.



### *Fasciola hepatica*: Life Cycle Representative

- Ova or eggs.
- Miracidium.
- Sporocyst.
- (Daughter sporocyst, or redia).
- Cercaria.

- Metacercaria.
- Adult.

### Stages of Life Cycle

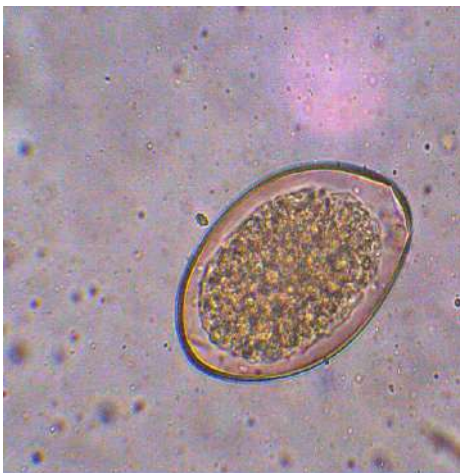- **Ova or eggs** - shelled embryo.
  - Contains miracidium inside shell.
  - Under appropriate conditions, the operculum (cap on shell) opens to allow miracidium to escape.
  - Many of flukes have very distinctive eggs.
- **Miracidium**
  - Ciliated organism that can be mistaken for a ciliated protozoan.
  - In species that hatch in water, it contains penetration glands that release histolytic or proteolytic enzymes to help penetrate snail.
  - Some species do not hatch until eaten by snail host.
- **Sporocyst**
  - The miracidium develops into sporocyst often in the digestive gland of the snail.
- The sporocyst is an embryonic bag or germinal sac.
- The sporocyst will produce many daughter stages called **rediae** or in some cases daughter sporocysts.
- **Rediae or Daughter Sporocyst**
  - In function they are very similar to sporocysts.
  - Contain digestive tract and are more active.
  - Asexually reproduce to yield many cercariae.
  - Some species they can live for many years.
- **Cercariae**
  - Usually escape snail and often swim by some means of tail structure.
  - Responsible for transmission from snail to the next host.

- **Metacercaria**

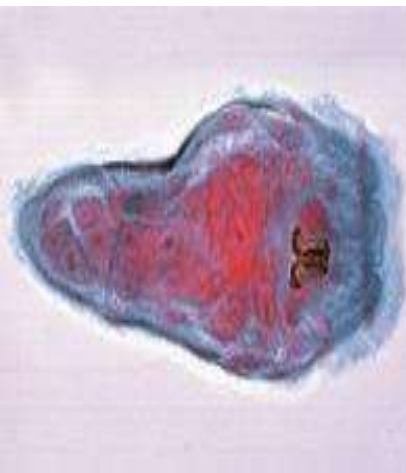- Resistant stage that is formed in many species.
- Cercaria that have this stage contain cystogenic glands that helps the organism encyst on vegetation.
- Cercaria that form metacercaria in second intermediate hosts, often have penetration glands that enable them to penetrate the second intermediate host.

- **Adult**

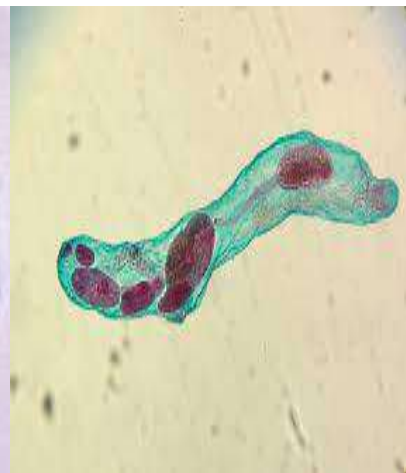- Always found in the definitive host.
- Responsible for sexual reproduction.
- Often restricted to specific region of host. Often very host specific.



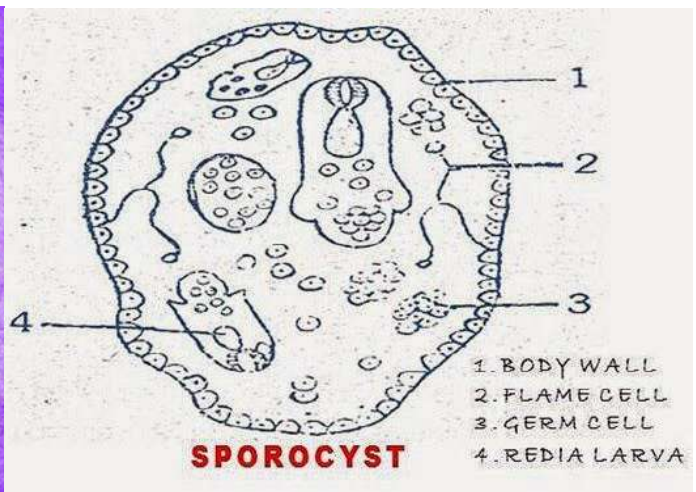
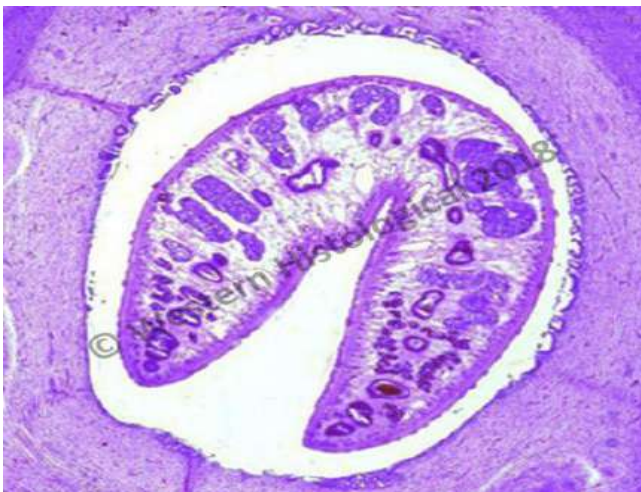Egg



Miracidium

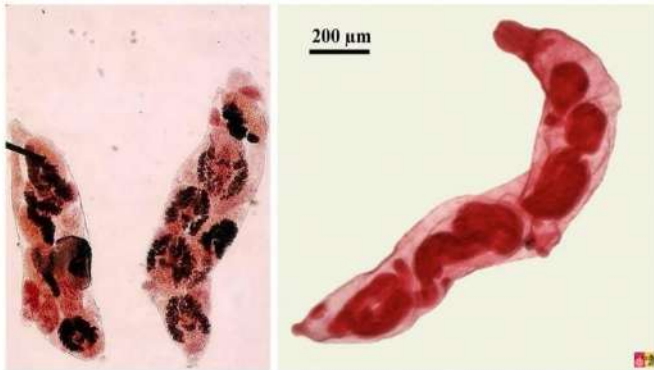

Sporocyst

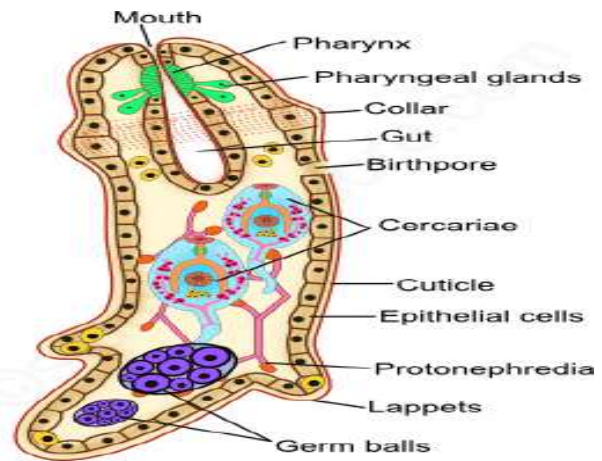




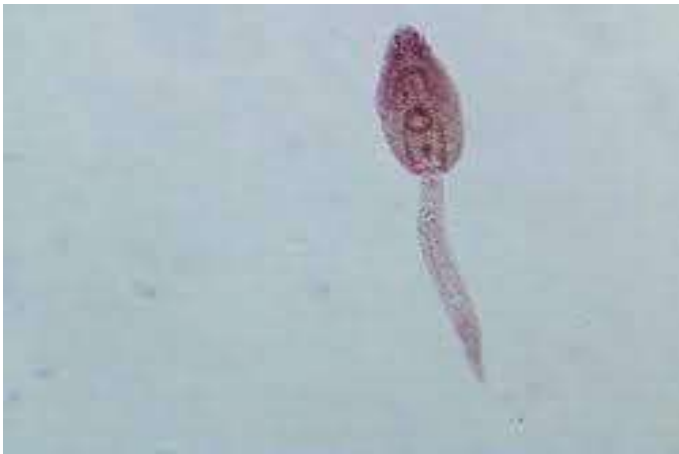C.S. in snail liver showing sporocyst



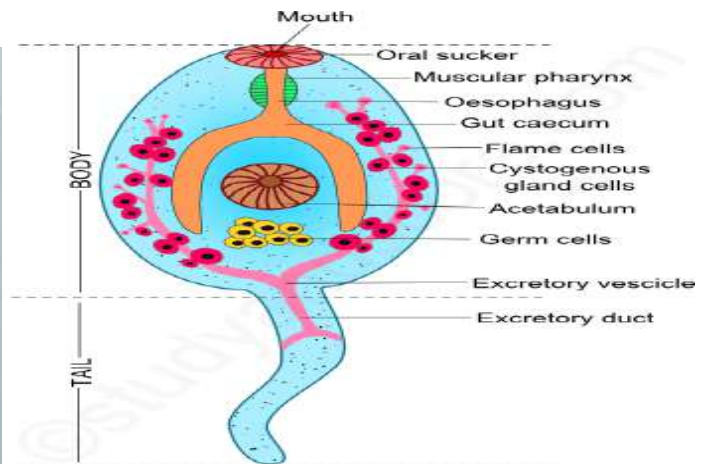
Rediae



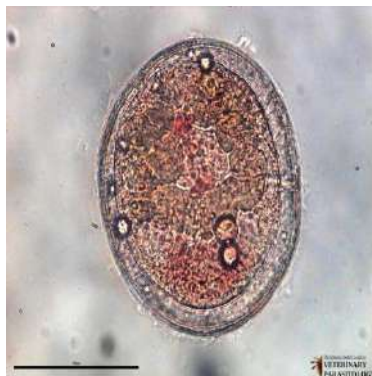Redia



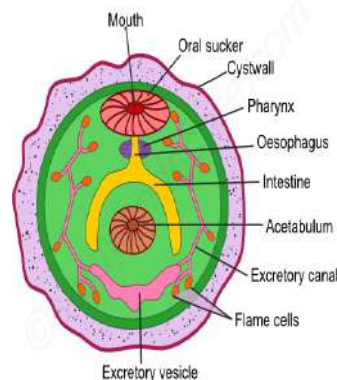
Cercaria



Cercaria



Metacercaria

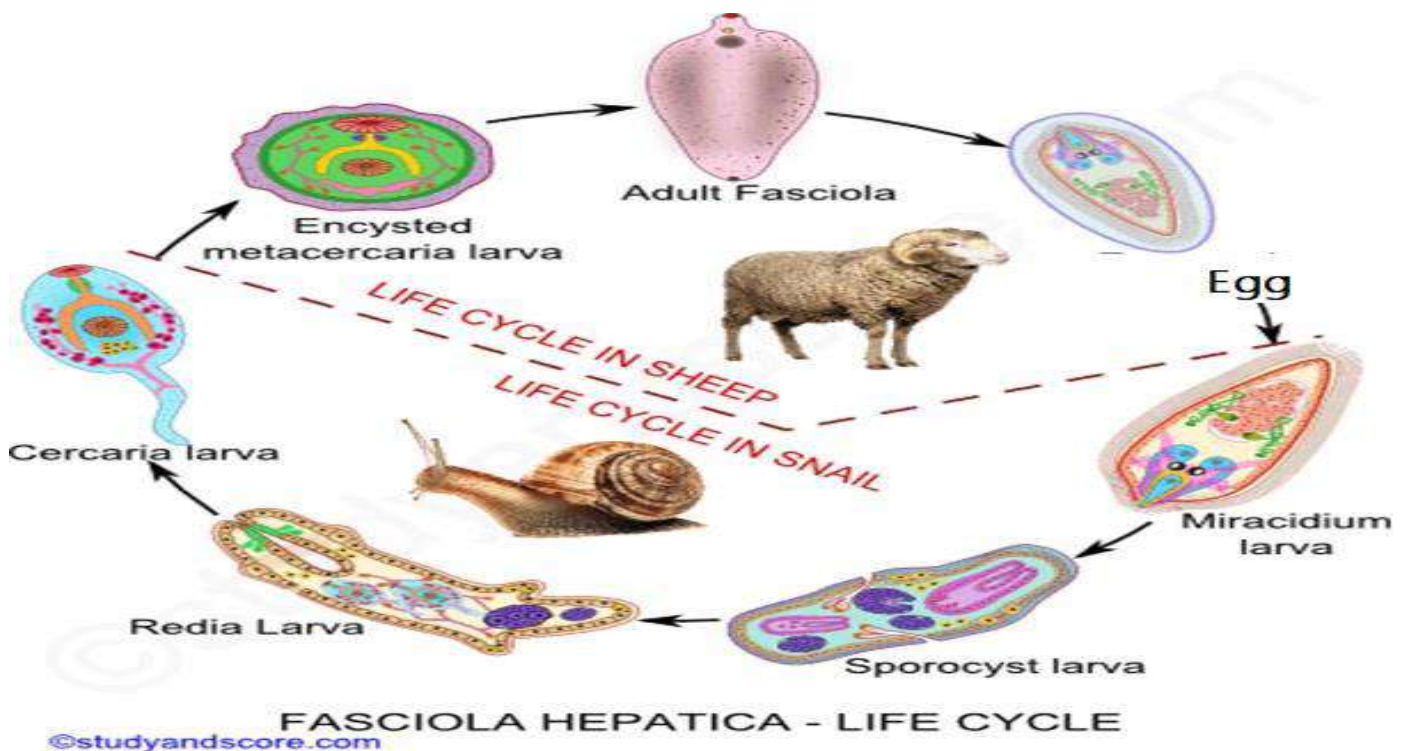


Metacercaria

### *Fasciola hepatica*

- Adult in bile duct of definitive host passes eggs in feces.
- If eggs land in water, they hatch into miracidium that actively swims until it finds an appropriate snail, e.g., *lymnaea*, *Galba*, *Fossaria*.
- Penetrates snail, develops into germinal sac (sporocyst), asexual stages of rediae and cercariae formed.
- Cercariae leave snail, encyst on vegetation, and form metacercaria.
- Herbivore infected when it ingests vegetation with metacercaria.
- Metacercaria develop into adult penetrates gut wall, moves to the liver.
- Humans infected by eating watercress that has metacercaria on it.

The life span of mature worms is (3-4 years), while for immature worms (3 months).





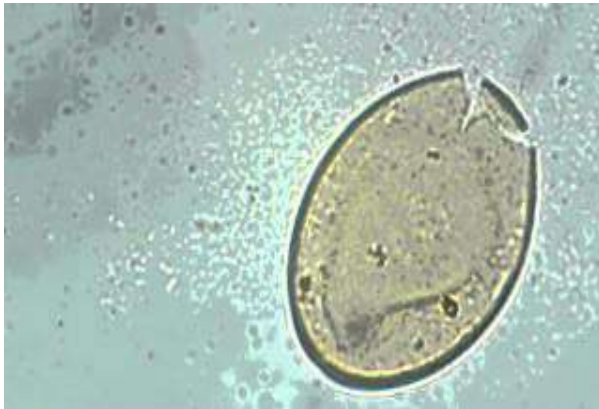## Pathogenicity:

**In sheep**, it causes fetal disease called liver rot, with enlargement of the bile duct. Cirrhosis of the liver and ascites.

**In man**, it causes biliary colic, vomiting and diarrhea.

## Diagnosis:

1. Finding of ova in stools. If eggs are absent in stools, biliary drainage should be done to detect the egg.



- A false record can result when the patient has eaten infected liver with the parasite and *Fasciola hepatica* eggs pass through with the feces(which type of parasite it represent, see lecture one). Therefore, if you find eggs in human feces, he may or may not be infected, but if you find eggs in sheep and cattle feces, they are certainly infected. Why?
2. CFT, is of doubtful value.
  3. ELISA.
  4. Excretory/secretory (E/S) antigens are also potentially useful in immunodiagnostic tests.

## The blood flukes of man (Schistosomes)

The blood flukes. The most important trematode of man, belong to the family Schistosomatidae. Schistosomes—so called because of the **split body** on the ventral side of the male, in which the female is held during insemination and egg laying.

All blood flukes of man are dioecious.

Three species of the genus *Schistosoma* produce serious human diseases:

*Schistosoma haematobium*: causes vesical schistosomiasis, bilharziasis, and urinary schistosomiasis.

*S. mansoni*: causes intestinal schistosomiasis.

*S.japonicum*: causes Oriental intestinal schistosomiasis, Katayama disease.

## Morphology

- The schistosomes differ from the typical trematodes in their narrow elongated shape and separate sexes.
- Adult worms are found in blood vessels of digestive tract or urinary bladder thus called blood flukes
- Male worm has a split body called the **gynecophoric canal**. The female is usually found within this canal “safe in the arms of her lover.” She leaves only during the egg-laying period.
- Schistosomes testes varies from 3 ~13, which are ovoid in shape.

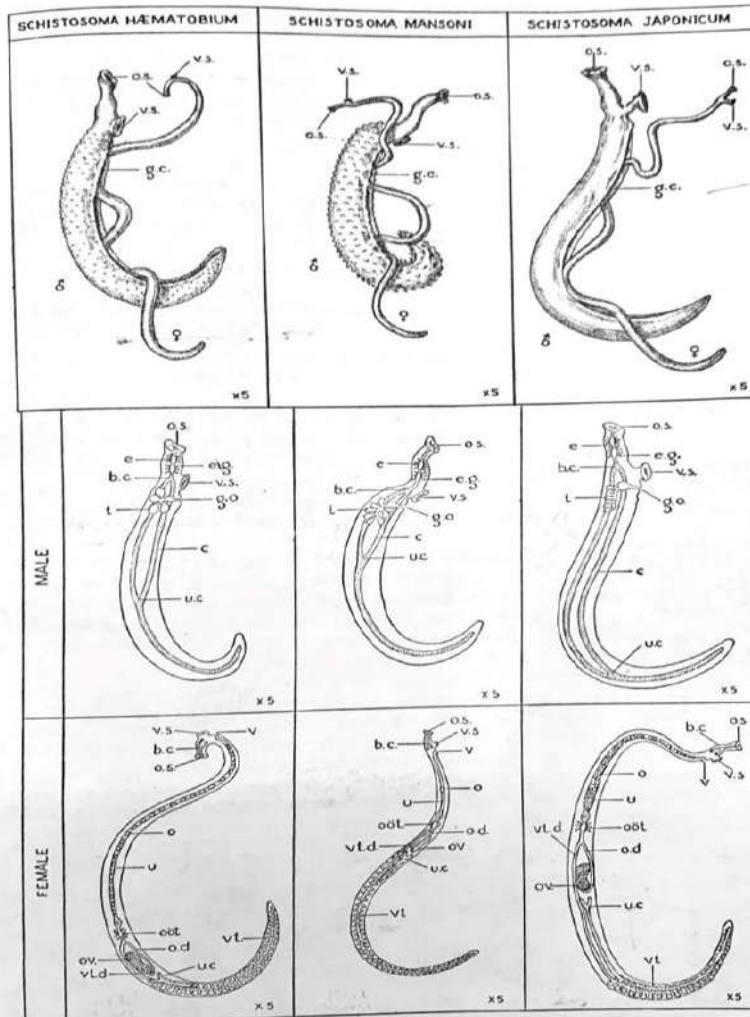


Fig. 95. Schematic representation of important schistosomes of man. b.c., bifurcation of ceca; c., ceca; e., esophagus; e.g., esophageal glands; g.c., gynecophoric canal; g.o., genital orifice; o., eggs; o.d., oviduct; o.t., ootype; o.s., oral sucker; ov., ovary; t., testes; u., uterus; u.c., union of ceca; v., vulva; v.s., ventral sucker; vt., vitellaria; vt.d., vitelline duct.

235

## Life cycle:

*Schistosoma* eggs are eliminated with feces or urine, depending on species <sup>1</sup>. Under appropriate conditions the eggs hatch and release miracidia <sup>2</sup>, which swim and penetrate specific snail intermediate hosts <sup>3</sup>. The stages in the snail include two generations of sporocysts <sup>4</sup> and the production of cercariae <sup>5</sup>. Upon release from the snail, the infective cercariae swim, penetrate the skin of the human host <sup>6</sup>, and shed their forked tails, becoming schistosomulae <sup>7</sup>. The schistosomulae migrate via venous circulation to lungs, then to the heart,

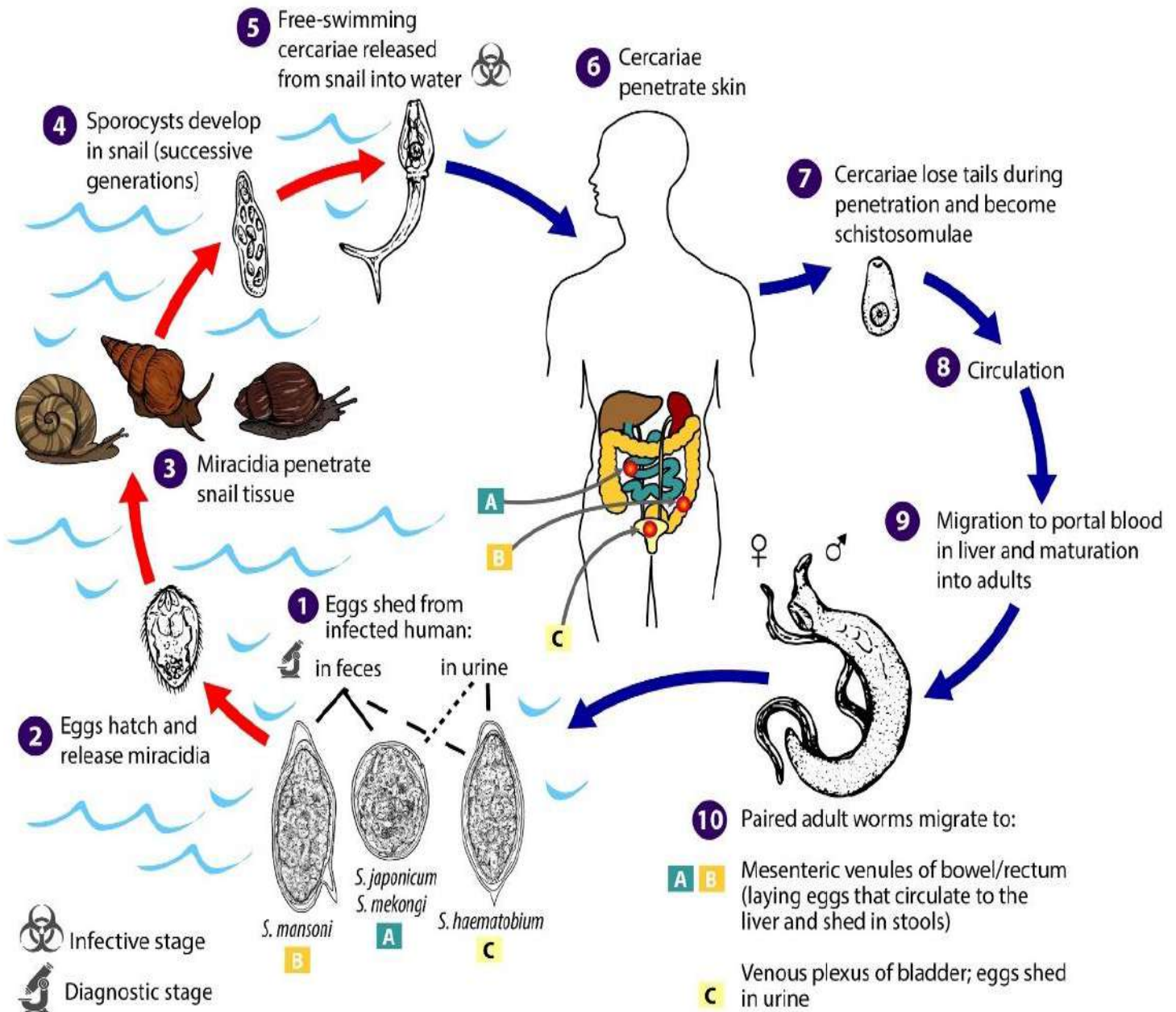
and then develop in the liver, exiting the liver via the portal vein system when mature, <sup>8</sup> <sup>9</sup> . Male and female adult worms copulate and reside in the mesenteric venules, the location of which varies by species (with some exceptions) <sup>10</sup> .

Life span: The life span is from 20-30 years.

- ❖ Man can also be infected with schistosomes, if he drink water having cercariae, hence it can penetrate the mucous membranes of the mouth and throat before reaching stomach and enter circulation, completing its life cycle. Cercariae require 1/2 an hour or less to completely penetrated the epidermis.

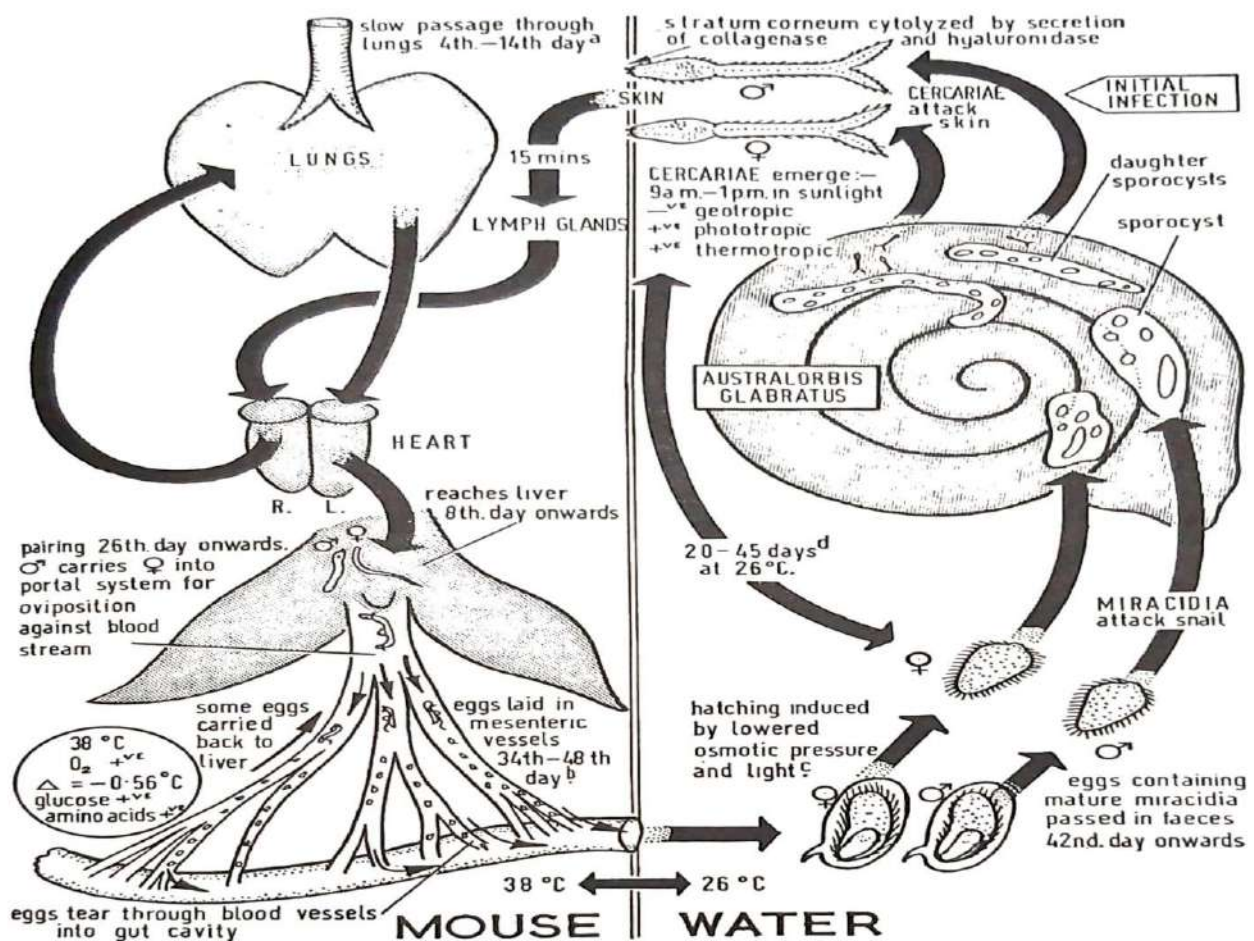
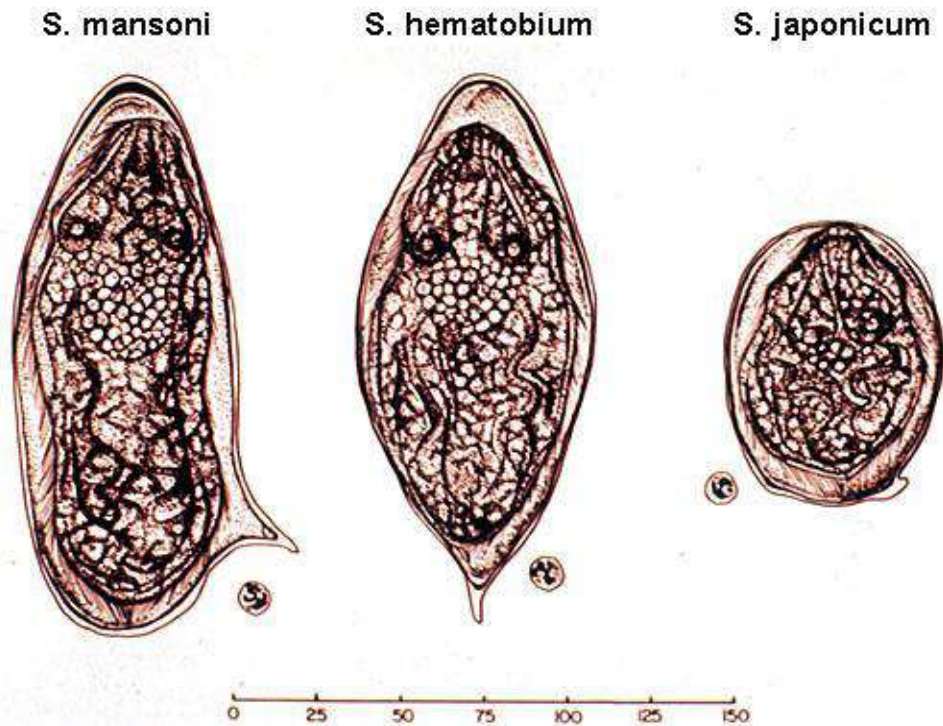
In schistosomes, especially in *S.mansoni*, in unisexual infection, the male produces viable sperms in absence of the female, but females do not achieve sexual maturation in the absence of the male, since the vitellaria and ovary do not become functional. All species of human schistosomes appear to be capable of cross- mating with one another. Homosexual pairing also occurs between males. Sex reverse also occurs in these worms.

## *Schistosoma* spp.

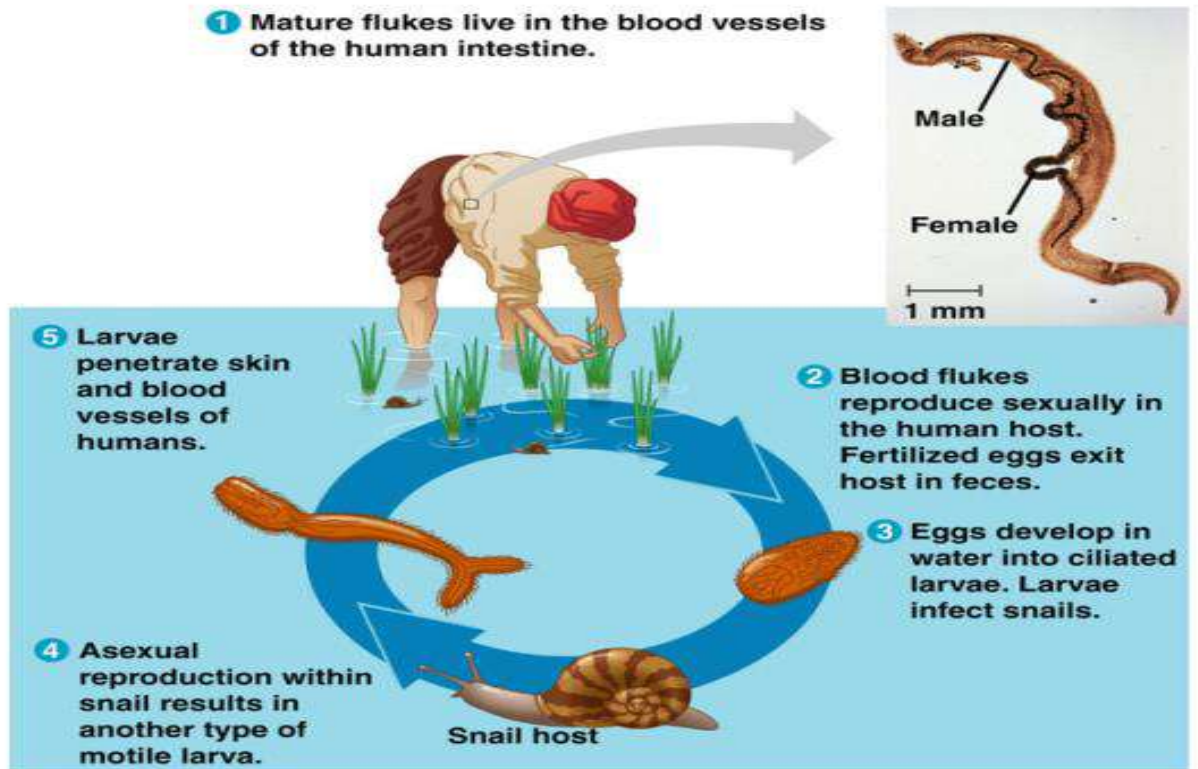





## COMPARISON OF THREE SCHISTOSOMA OVA







*Schistosoma haematobium*: Use *Bulinus* snail as intermediate host.



*S. mansoni*: Use *Tropicorbis* snail as intermediate host.

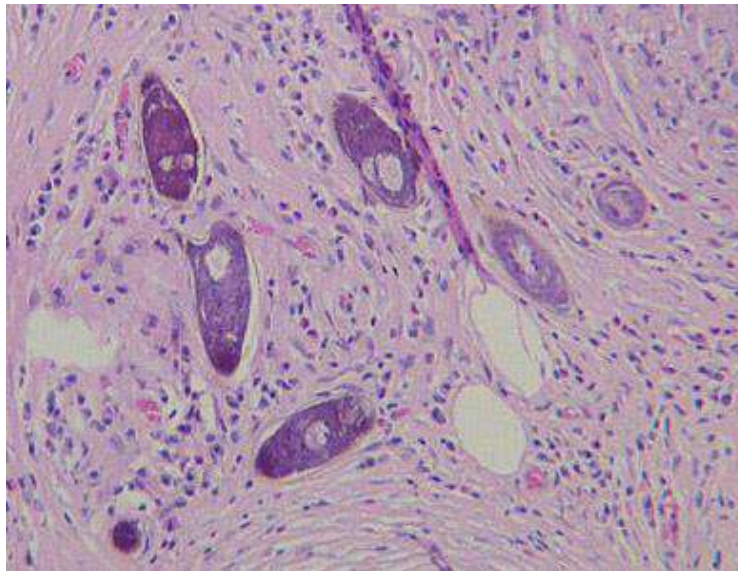


*S.japonicum*: Use *Oncomelania* snail as intermediate host.



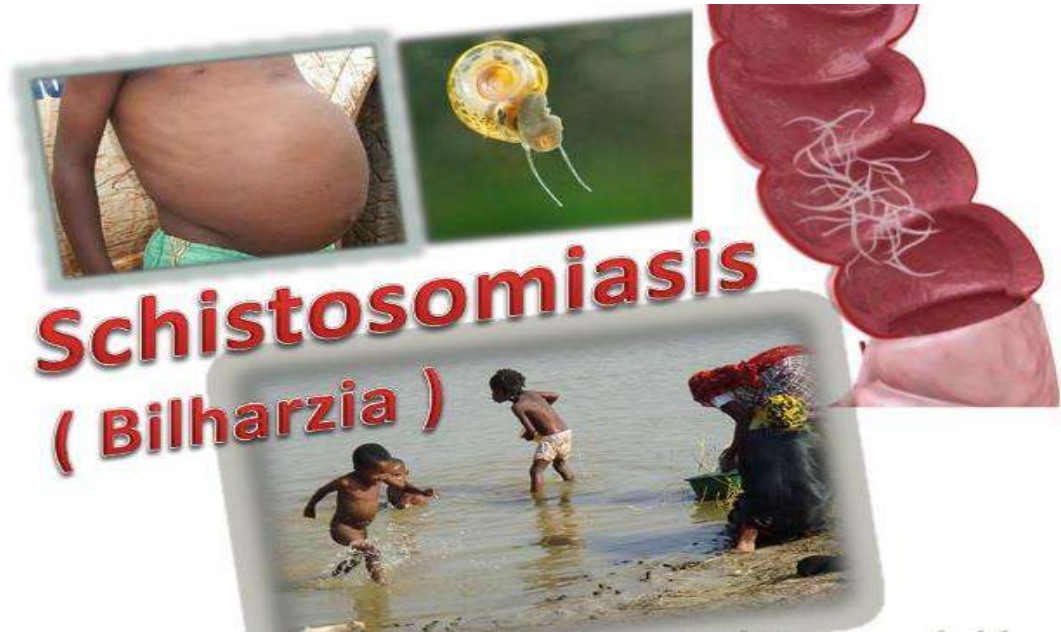## Pathogenesis

- Migratory phase - 4-10 weeks after infection. Is characterized by fever and toxic or allergic reactions resulting from migration of immature organisms. Often results in bronchitis, hepatomegaly, splenomegaly, and diarrhea.
- Acute phase - 10 weeks to years. Eggs can become trapped and produce granulomas and scar tissue.
  - Form fibrous nodules called pseudotubules.
  - Eggs may lodge in gastrointestinal, renal, neural, and other systems.



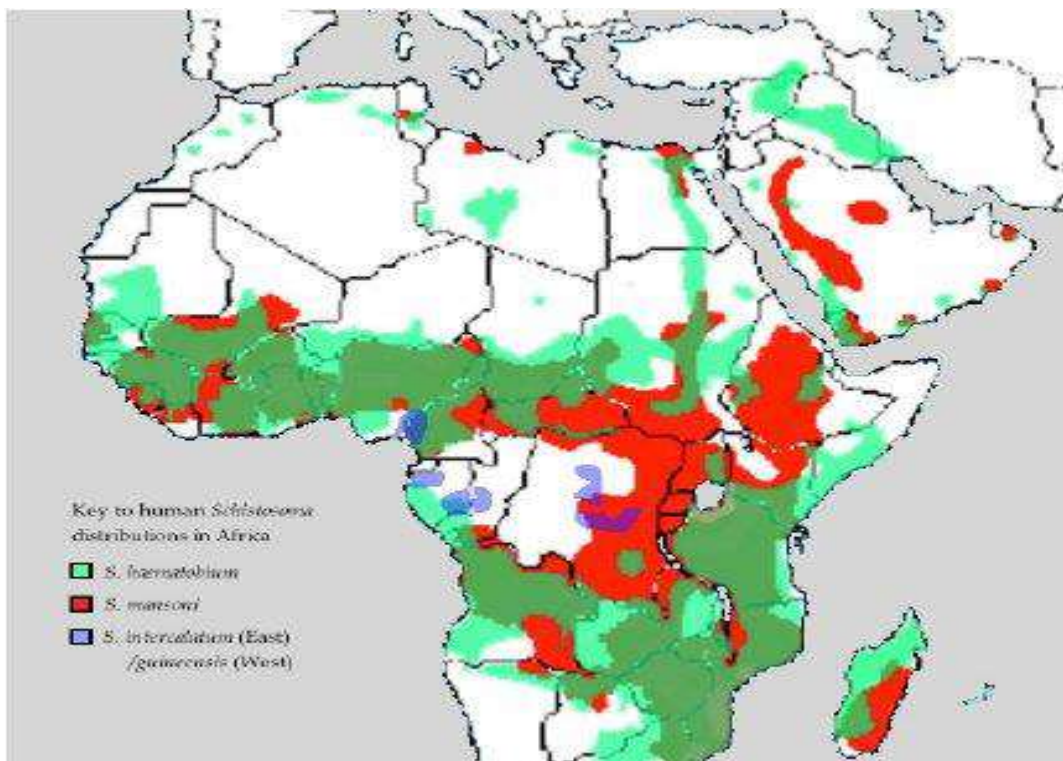
- A person infected with 50 mating pairs would be exposed to about 15,000 eggs per day for several years.  
1/2 of eggs might remain trapped in tissues.
- Chronic phase - persons living in endemic regions are often asymptomatic. May have mild, chronic bloody stools or urine. Often have formation of granulomas. Hepatomegaly, Splenomegaly, Ascites (accumulation of fluid in abdominal cavity).





## Epidemiology

- Human waste into water.
- Use of night soil (human feces).
- Before the Aswan Dam was built, the region between Cairo and Aswan was subject to annual floods. The prevalence of Schistosomiasis was only about 5%. Four years after completion of the dam the prevalence ranged from 19%-75% (average 35%) or a 7 fold increase.



### *Schistosoma haematobium*

- Often referred to as Bilharzia after Theodore Bilharz who discovered it.
- Found in parts of Africa, and parts of the Middle East, southern Europe and some parts of Asia.
- Found primarily in the veins of the urinary bladder. Eggs released in urine.
- They are least pathogenic.

### *Schistosoma mansoni*

- Common in Egypt, the Middle East, parts of Africa, and parts of South and Central America.
- Found in portal veins draining large intestine.
- The sharp lateral spine is distinctive.
- Primary pathological effects come from the damage done by eggs.
- In heavy infections eggs become trapped in the mucous and submucosa of the gut and cause granuloma formation.
- If extensive, they can cause colon blockage and significant blood loss.
- In liver can cause hepatomegaly.
- Destruction of lungs and heart tissue.
- Reservoir hosts are of limited or no importance.

### *Schistosoma japonicum.*

- Common in parts of Japan, China, Taiwan, Philippines, Thailand, and other parts of Southeast Asia.
- Most pathogenic and most difficult to control.

- Located in blood vessels of small intestine.
- Eggs may lodge in brain causing CNS damage, coma, and paralysis.
- Low host specificity.

## Diagnosis and Control

- Stool or urine samples can be examined microscopically for parasite eggs (stool for *S. mansoni* or *S. japonicum* eggs and urine for *S. haematobium* eggs). The eggs tend to be passed intermittently and in small amounts and may not be detected, so it may be necessary to perform a blood (serologic) test. Serologic testing for antischistosomal antibody is indicated for diagnosis of travelers or immigrants from endemic areas who have not been treated appropriately for schistosomiasis in the past. Commonly used serologic tests detect antibody to the adult worm. For new infections, the serum sample tested should be collected at least 6 to 8 weeks after likely infection, to allow for full development of the parasite and antibody to the adult stage.
- Biopsy - in chronic cases if eggs not passed.
- Control is very difficult:
  - Customs and traditions.
  - Agricultural practices.
  - Socioeconomics.

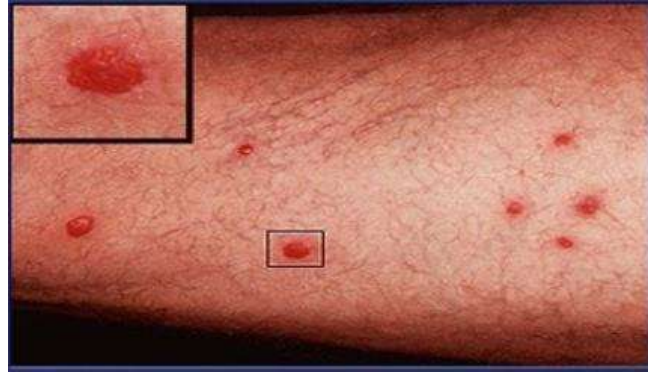## Schistosome cercarial dermatitis or swimmers itch

- Schistosomes of animals other than man (usually rodents and birds) try to penetrate the skin of man, they can not establish themselves in the blood vascular system of man.



- Often cause a dermatitis which can be severe and in some cases life threatening.
- Allergic reaction.

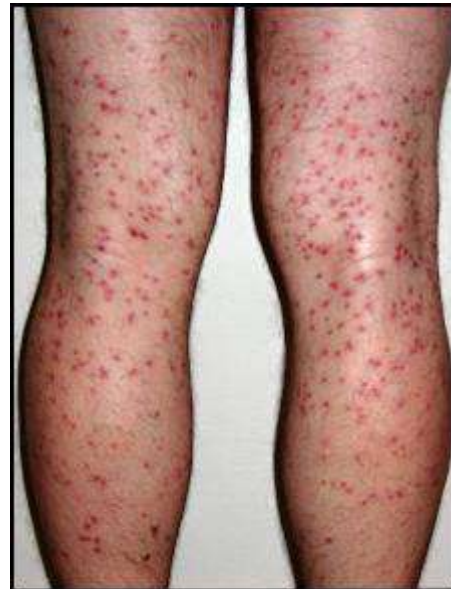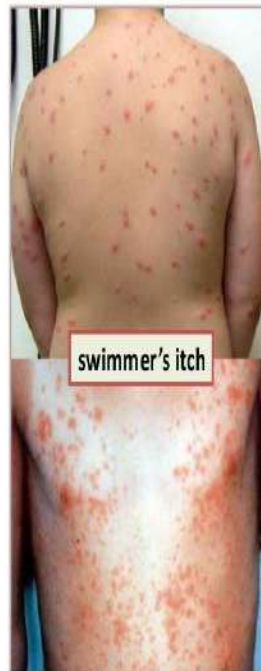### Swimmer's Itch



#### Clinical Features:

##### Acute manifestations:

- Generalized lymphadenopathy.
- Pruritic rash ( swimmer's itch ).
- Mild Fever & Headache.
- Hepatosplenomegaly.
- Katayama syndrome (↓).
- Diarrhea.
- Urticaria.
- Cough.



## Introduction to Protozoology

### GENERAL CHARACTERISTICS OF MEDICALLY IMPORTANT PARASITES

Medically important protozoa, helminths, and arthropods, which are identified as causes and propagators of disease have the following general features. These features also differ among parasites in a specific category.

- 1- PROTOZOA:** Protozoan parasites consist of a single "cell-like unit" which is morphologically and functionally complete and can perform all functions of life. They are made up of a mass of protoplasm differentiated into cytoplasm and nucleoplasm. The cytoplasm consists of an outer layer of hyaline ectoplasm and an inner voluminous granular endoplasm. The ectoplasm functions in protection, locomotion, and ingestion of food, excretion, and respiration. In the cytoplasm, there are different vacuoles responsible for storage of food, digestion and excretion of waste products. The nucleus also functions in reproduction and maintaining life. The protozoal parasite possesses the property of being transformed from an active (trophozoite) to an inactive stage, losing its power of motility and enclosing itself within a tough wall. The protoplasmic body thus formed is known as a cyst. At this stage, the parasite loses its power to grow and multiply. The cyst is the resistant stage of the parasite and is also infective to the human host.
- 2- HELIMINTHS:** The helminthic parasites are multicellular, bilaterally symmetrical animals having three germ layers. The helminthes of importance to human beings are divided into three main groups with the peculiarities of the different categories: **CESTODE, TREMATODE, and NEMATODE.**

### 3- ARTHROPODS

Arthropods, which form the largest group of species in the animal kingdom, are characterized by having a bilaterally symmetrical and segmented body with jointed appendages. They have a hard exoskeleton, which helps enclose and protect the muscles and other organs. An open circulatory system, with or without a dorsally situated heart pumps the blood (hemolymph) via arteries to the various organs and body tissues. Blood is returned to the heart through body spaces known as hemocoeles. In addition, respiratory, excretory, and nervous systems are present. Arthropods affect the health of humans by being either direct agents for disease or agents for disease transmission.

The arthropods of medical importance are found in **Classes Insecta, Arachnida, and Crustacia** which have their own distinguishing features.

In **Class insecta** the body is divided into **head, thorax, and abdomen**, with **one pair of antennae**. Insects primarily transmit diseases like **malaria, yellow fever, onchocerciasis, and trypanosomiasis**.

### Classification of protozoa

On the basis of light and electron microscopic morphology, the protozoa are currently classified into six phyla. Most species causing human disease are members of the phyla.

This classification, emphasizing the groups of parasitic members.

**Phylum: Sarcodina .... e.g *Entamoeba, Iodamoeba*.**

**Phylum: Axostylata.... e.g. *Trichomonas, Dientamoeba*.**

**Phylum: Retortamonada....e.g. *Chilomastix, Retortamonas*.**

**Phylum: Euglenozoa.... e.g. *Trypanosoma*, *Leishmania*.**

**Phylum: Ciliophora ..... e.g. *Balantidium*.**

**Phylum: Apicomplexa.... e.g. *Plasmodium*, *Toxoplasma*.**

## Life Cycle Stages

The stages of parasitic protozoa that actively feed and multiply are frequently called **trophozoites**; in some protozoa, other terms are used for these stages. **Cysts** are stages with a protective membrane or thickened wall. Protozoan cysts that must survive outside the host usually have more resistant walls than cysts that form in tissues.

## Reproduction

The methods of reproduction or multiplication among the parasitic protozoa are of the following types:

### 1. Asexual multiplication:

- (a) **Simple binary fission** – in this process, after division of all the structures, the individual parasite divides either longitudinally or transversely into two more or less equal parts.
- (b) **Multiple fission or schizogony** – in these process more than two individuals are produced, e.g. asexual reproduction in Plasmodia.

### 2. Sexual reproduction:

- (a) **Conjugation** – in this process, a temporary union of two individuals occurs during which time interchange of nuclear material takes place. Later on, the two individuals separate.
- (b) **Syngamy** – in this process, sexually differentiated cells, called gametes,

Unite permanently and a complete fusion of the nuclear material takes place. The resulting product is then known as a zygote.

## Locomotory Organelles in Protozoa

Protozoa are divided into four types classified based on their organs of locomotion. These classifications are amoebas, ciliates, flagellates, and sporozoans.

	Protozoa	Organ of Locomotion	Important Human Pathogen
1-	Rhizopoda (Amoeba)	Pseudopodia	<i>Entamoeba histolytica</i>
2-	Mastigophora (Flagellates)	Flagella	<i>Trypanosomes</i> <i>Leishmania</i> <i>Trichomonas</i> <i>Giardia</i>
3-	Sporozoa	None, exhibit a slight Amoeboid movement	<i>Plasmodium.Spp</i>
4-	Ciliates	Cilia	<i>Balantidium coli</i>

### Phylum: Sarcodina

These organisms have streaming cytoplasm and use temporary cytoplasmic extensions called pseudopodia in locomotion (called amoeboid movement) and feeding.

**Karyosome:** A structure within the nucleus of amoebae having a relatively constant size and location in each species. According to karyosome, amoebae can be differentiated into three genera: *Entamoeba*, *Iodamoeba* and *Endolimax*.

***Entamoeba*:** Karyosome usually small and compact; centrally located or eccentric.

***Iodamoeba*:** Nucleus with a large central karyosome.

***Endolimax*:** Nucleus with a characteristically large, irregularly shaped, blot-like karyosome.

## Phylum: Amoebozoa (Sarcodina)

### Class: Lobosea

### *Entamoeba histolytica*

### Disease :

- 1- **Amoebiasis.**
- 2- **Amoebic dysentery; primary or intestinal lesion.**
- 3- **Amoebic liver abscess; secondary or metastatic lesion; extra-colonic or extra intestinal lesion.**

*Entamoeba histolytica* is a common protozoan parasite found in the large intestine of human. The parasite is responsible for amoebiasis and liver abscesses. It is the **third** leading parasitic cause of **death (mortality)** in the developing countries, after **malaria** and **schistosomiasis**.

**Incubation period** is generally four or five days.

### Morphology:

- Parasite occurs in three stages; trophozoite, precyst and cyst

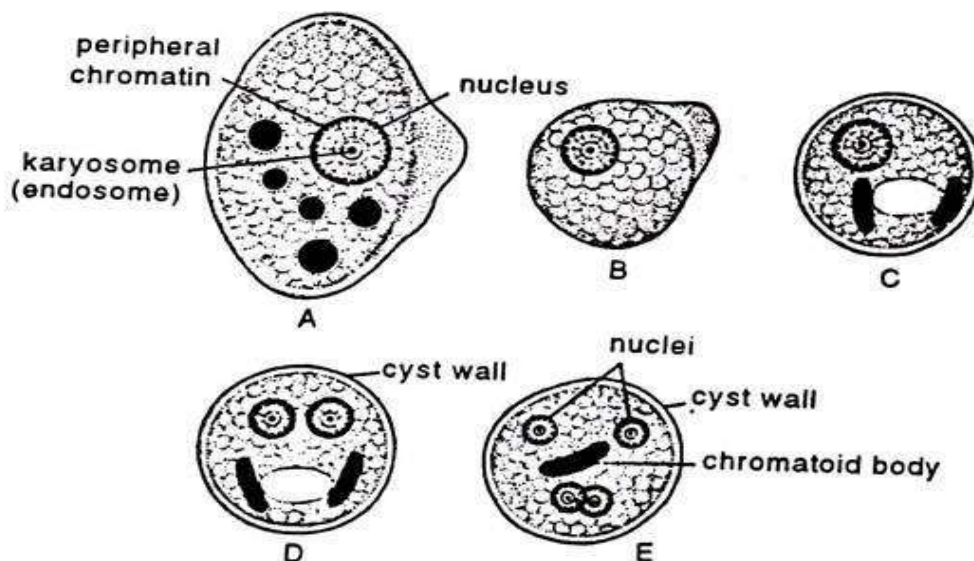


Fig. 18.4. *Entamoeba histolytica*. A. Trophozoite stage. B. Precystic stage. C-E. Cysts, C. Uninucleate. D. Binucleate. E. Quadrinucleate stage



### 1. Trophozoite or vegetative stage:

- **It is the growing and feeding stage of parasite.**
- Shape; not fixed because of constantly changing position.
- Size: ranging from 18-40  $\mu\text{m}$ ; average being 20-30  $\mu\text{m}$ .
- **Cytoplasm: is divided into two portion; a clear transparent ectoplasm and a granular endoplasm. Ingested RBCs, tissue granules and food materials are also found in endoplasm.**
- **Nucleus: It is single, spherical shape and size ranging from 4-6 $\mu$ . Nucleus contains central karyosome and fine, evenly distributed peripheral chromatin.**
- Trophozoites are actively motile (rapid) with the help of pseudopodia, progressive, and unidirectional.
- Trophozoites are anaerobic parasite, ( present in large intestine).

### 2. Precyst:

1. **It is the intermediate stage between trophozoite and cyst.**
2. It is smaller in size; 10-20 $\mu$ .
3. It is round or slightly ovoid with blunt pseudopodium projecting from periphery. The karyosome condense more than the trophozoite.
4. **No RBC or food materials are found on its endoplasm.**

### 3. Cyst:

- **It is the infective form of parasite.**
- Shape: It is round or oval in shape.
- Size: 12-15  $\mu\text{m}$  in diameter.
- It is surrounded by a highly retractile membrane called **cyst wall**. The cyst wall is resistant to digestion by gastric juice in human stomach.
- **Nucleus: A mature cyst is quadri-nucleated.**
- Cytoplasm: Cytoplasm shows chromatid bars and glycogen masses but **no RBCs or food particles.**
- **Mature cyst passed out in stool from infected patient and remained without**

further development in soil for few days, and can survive in a moist environment for several weeks.

- The nuclei and **chromatoidal bodies** appear more prominently in stained preparations. With iron **hematoxylin stain**, nuclear chromatin and **chromatoid bodies** appear **deep blue or black**, while the **glycogen mass** appears unstained. When stained with **iodine**, the **glycogen mass** appears **golden brown**, the nuclear chromatin and karyosome bright yellow, and the **chromatoid bodies** appear as clear space, being unstained.

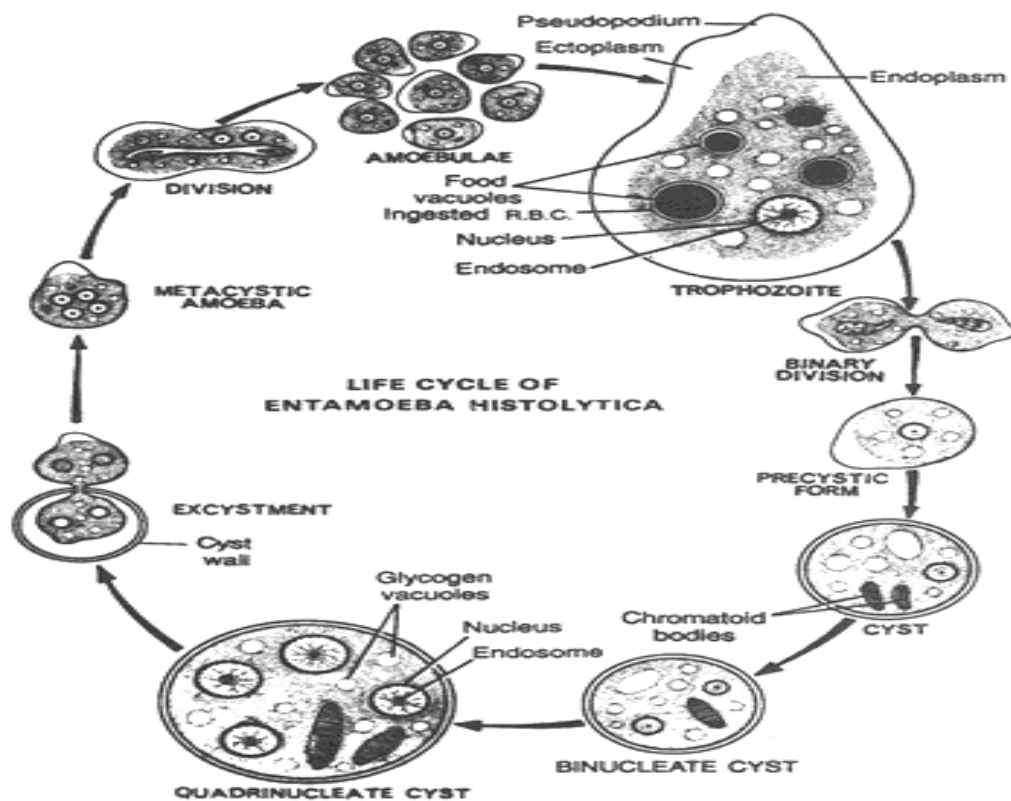
### Life cycle:

It passes its life cycle in only one host. Cysts are passed in faeces. Man acquires the infection by:

- 1- Ingestion of **mature quadrinucleate cysts** in faecally contaminated food or water. Trophozoites can also be passed in diarrhoeal stools, but are rapidly destroyed once outside the body, and if ingested would not survive exposure to the gastric environment. In contrast, cysts may remain viable in a humid environment and stay infective for several days. **Flies** and **cockroaches** can also serve as vectors for the transmission of *E. histolytica* cysts.
- 2- In the small intestine the cyst wall is lysed by trypsin and a single **tetranucleate amoeba (metacyst)** is liberated.
- 3- Each nucleus divides by **binary fission** giving rise to **eight nuclei**, thus from each mature cyst **eight small metacystic trophozoites(amebulae)** are produced. This process is known as **excystation**. **Metacystic** trophozoites are carried in the faecal stream into the caecum.
- 4- They invade the mucosa and ultimately lodge in the **submucous tissue** of **large intestine**. Here they grow and multiply by **binary fission**. During growth, *E. histolytica* secretes a **proteolytic enzyme** which brings about destruction and necrosis of tissue and produces **flask- shaped ulcers**.
- 5- **Encystation**: occurs in the intestinal lumen in which chromatin materials

are concentrated into bars (chromatoidal bodies) in the cytoplasm of the cyst. The nucleus of cyst divides into two , then each of the two daughter nuclei divided once again so mature cyst has four nuclei. **The amoebae are mostly present at the periphery of the lesion.** A large number of trophozoites are excreted along with blood and mucus in the stool leading to **amoebic dysentery**. In a few cases, erosion of the large intestine may be so extensive that trophozoites gain entrance into the **radicles of portal vein** and are carried away to the **liver** where they multiply leading to **amoebic hepatitis** and **amoebic liver abscess**.

6- It has been established that the invasive and noninvasive forms represent two separate species, respectively *E. histolytica* and *E. dispar*. These two species are **morphologically indistinguishable** unless *E. histolytica* is observed with ingested **red blood cells** (**erythrophagocytosis**).



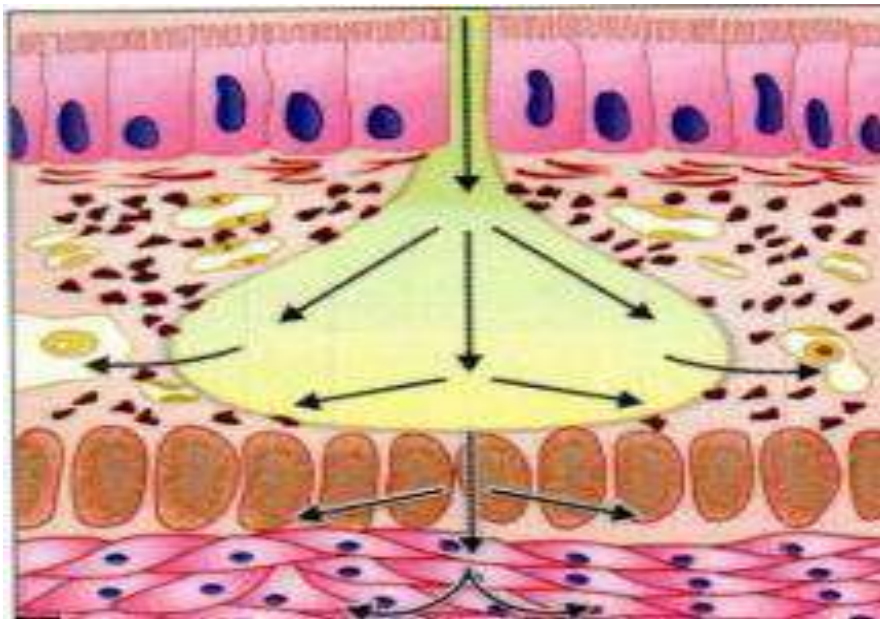
*Entamoeba histolytica* : Reproductive and life history

**Distribution:** Parasite has worldwide distribution but is most common in the tropical and subtropical areas of the world.

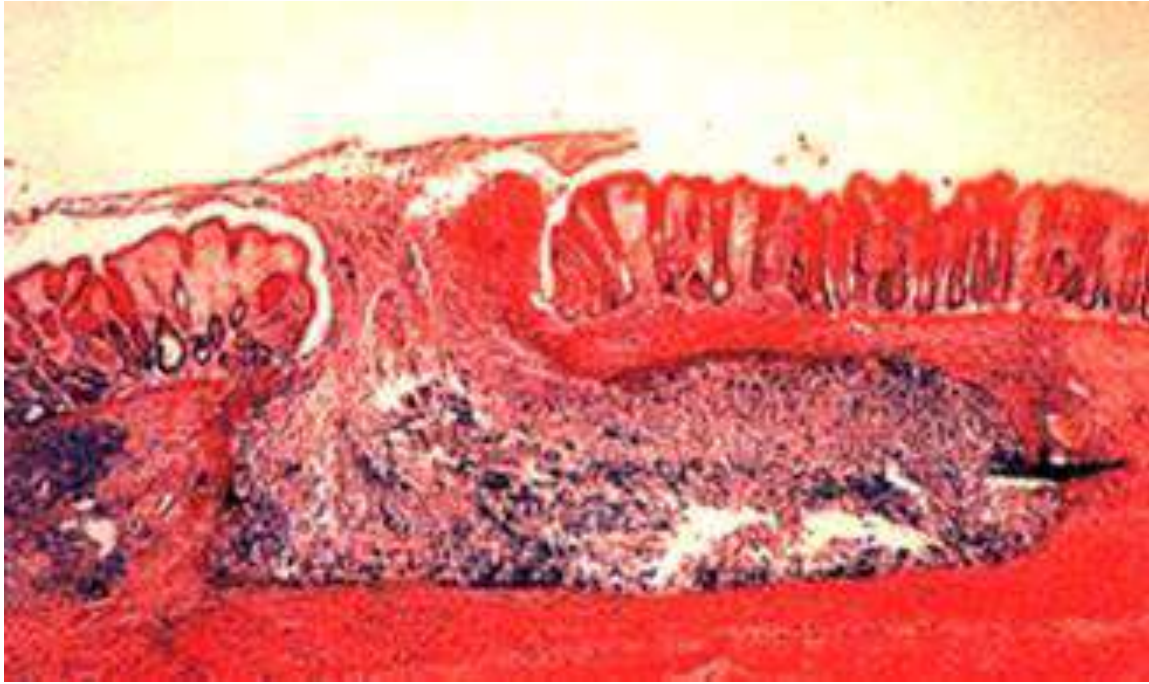
- ~ 500 million people may be affected.
- ~ 100,000 deaths each year.

## Pathogenesis

**Intestinal amoebiasis:** After an incubation period of 1-4 weeks, the amoeba invade colonic mucosa. During growth, *E. histolytica* secretes a proteolytic enzymes, producing **flask- shaped ulcers** and profuse bloody diarrhea (amoebic dysentery). Ulcers may be deep or superficial. *E. histolytica* may also cause **amoebic appendicitis** and **amoebomas** (pseudotumoral lesions associated with necrosis, inflammation and oedema).



Flask-shaped amoebic ulcer



**Extraintestinal amoebiasis:** About 5-10% individuals with intestinal amoebiasis, 1-3 months after disappearance of dysentery, develop **hepatic amoebiasis**. Trophozoites are carried from the ulcer in the large intestine and multiply in the liver, lead to cytolytic action then small abscesses merge to form big liver abscesses. The abscesses may grow in various directions; it may enter into general circulation involving lungs, brain, spleen, skin, etc.

**Pathogenicity depends on:**

1. Virulence of strain.
2. Resistance of the host (depends on the innate immunity).
3. State of nutrition of the host.
4. Infection with other agents (free of other infections mean less susceptible to infection).
5. Some drugs may irritate the intestinal wall so irritated intestine is more susceptible to infection.
6. Bacterial flora (metabolic processes can enhance the invasiveness).



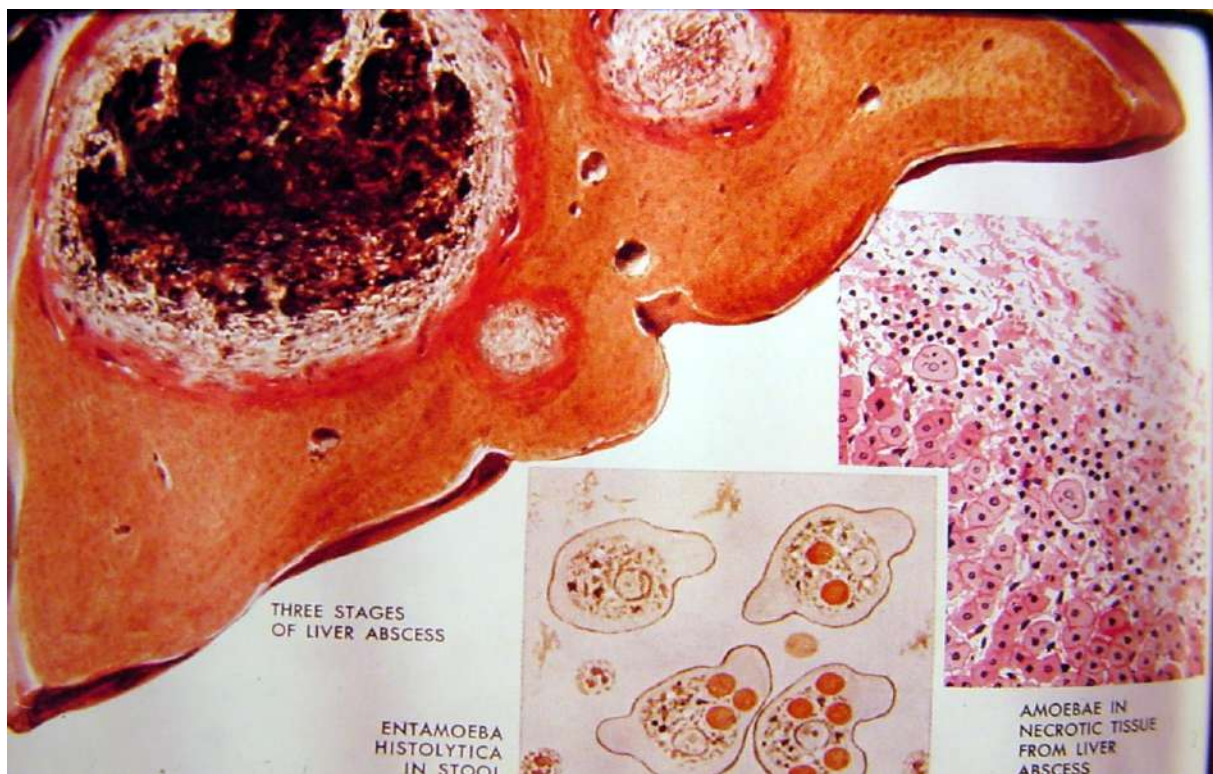
Sometimes a granulomatous mass called an **ameboma**, forms in the wall of the intestine and may obstruct the bowel. It is the result of cellular responses to a chronic ulcer and often still contains active trophozoites.

**Trophozoites can move from large intestine to liver via hepatic portal vein**

**Primary or Intestinal lesions-** Infection is confined only to large intestine:

- Ascending
- Descending

**Secondary or Metastatic Lesions-** Infections are seen in liver, lung, brain, spleen, pericardium, penis, skin, and eyes.



## Symptoms

- Cramps, vomiting, malaise, abdominal discomfort (mimics appendicitis), rectal tenesmus, and Dysentary - diarrhea with blood.



- 10% of people in the world infected with amebas, but only 3% ever have some sort of clinical signs. This means that most people infected with *E. histolytica* do not know it– Dangerous!

## **Transmission**

### **1) Contaminated water.**

- Most people in the world don't have indoor plumbing/running water.
- Get water by ground/surface water.

### **2) Contaminated food.**

- Defecation in vegetable gardens, fields.
- Night soil (human excrement used as fertilizer).
- The practice of humans using their bare hands to clean toilet pits continues to this day-"night soil men".

### **3) Mechanical contamination.**

- Medical Equipment.
- Flies, roaches, etc.
- Hand to mouth (fingernails, contaminated objects, toys, etc.).
- Hand to eye (**ectopic**).
- Hand to open sore (**ectopic**).
- Anal sex (**ectopic**).

**Laboratory Diagnosis:** *Entamoeba histolytica* must be differentiated from other intestinal nonpathogenic amebae. The nonpathogenic *Entamoeba dispar* is morphologically identical to *E. histolytica*, and differentiation must be based on isoenzymatic or immunologic analysis. Molecular methods are also useful in distinguishing between *E. histolytica* and *E. dispar*. - **Microscopic identification** of cysts and trophozoites in the **stool** is the common method for diagnosing *E. histolytica*.

This can be accomplished using **wet mount** and permanently **stained** preparations as **Iodine** or **trichrome** or by **Flotation** or **Sedimentation**

method for stool samples.

**Blood examination:** shows moderate **leukocytosis**.

**Serological tests:** in later stages of invasive amoebiasis, antibodies appear.

Tests include **ELISA**, **IHA** and **IFA**.

**Histology:** trophozoites can be identified in aspirates or **biopsy** samples obtained during colonoscopy or surgery.

**Molecular methods:** **DNA** probe and **PCR**.

**Stool microscopy** by **wet** mount, permanent stain to detect cyst and trophozoite by iron haematoxylin.

**Concentration method** when the infection is scanty it include:

- Centrifugation method (precipitation).
- Zinc sulphate technique (Floation).
- $ZnSO_4$  → 333 gm.
- D.W. → 1000 ml.
- SP. Gravity → 1.018.

**Nonspecific: Charcot Leyden crystal** in stool moderate leucocytosis in blood.

**Colonoscopy**

## Non pathogenic associated Amebae

- *Entamoeba coli*.
- *Iodamoeba bütschlii*.
- *Endolimax nana*.

All these amebae are non-pathogenic and have the same life cycle as *E. histolytica*, reproduce and multiply by binary fission in their trophic stages.

### *Entamoeba coli*

- Life cycle and location identical to *E. histolytica*.

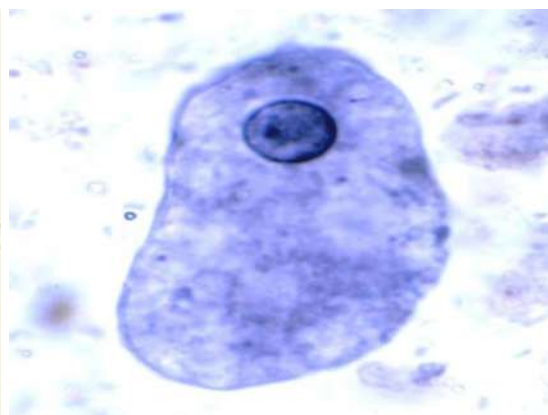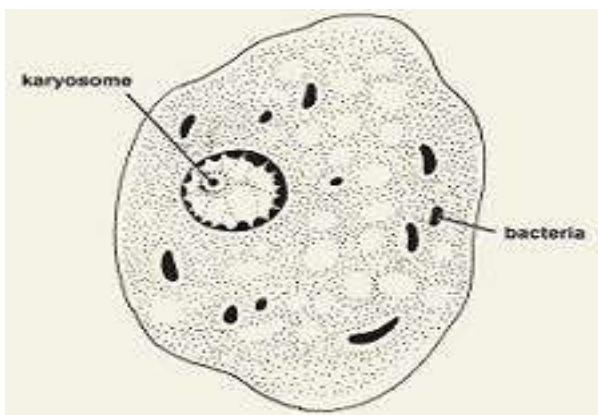
- Most common endocommensal in people; has a worldwide distribution and 10-50% of the population can be infected in different parts of the world.
- Not pathogenic.
- Feeds on bacteria and any other cells available; does not invade tissue.
- The presence of these organisms in patient's stool is a useful indication of fecal-oral exposure.
- *Entamoeba coli* is more common than *E histolytica*, partly because of its superior ability to survive in putrefaction.
- The **diagnostician** must identify this species **correctly**, if it is incorrectly diagnosed as *E histolytica*, the patient may be submitted to unnecessary drug therapy.

### Trophozoite

**Size: 20-30  $\mu\text{m}$  in diameter (15-50  $\mu\text{m}$ ).**

The **karyosome** of the trophozoite is **eccentric**,

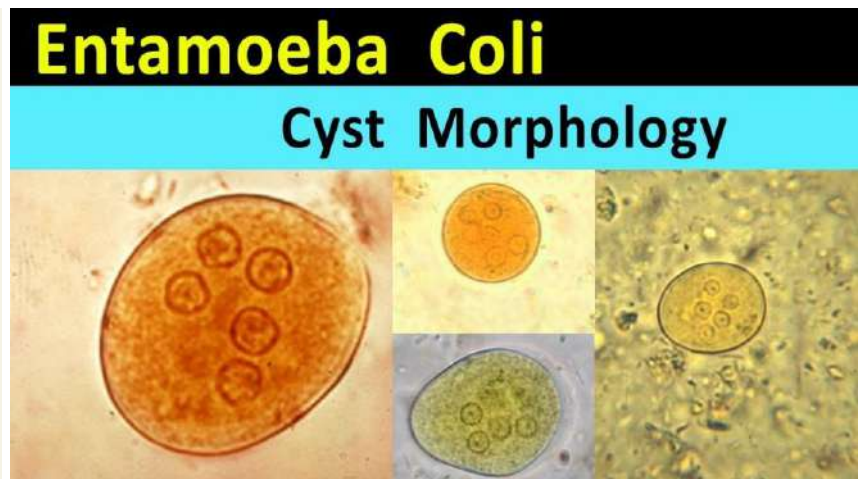
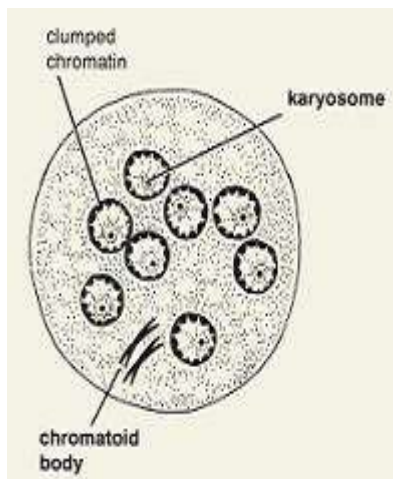
The chromatin lining the nuclear membrane is ordinarily **coarser**, with larger granules than that of *E histolytica*.



## Cyst

### Size 10-30 $\mu\text{m}$

- As the cyst mature, the nucleus divides repeatedly to form **8 nuclei**, rarely as many as 16 nuclei may be produced.
- The octanucleate metacyst produce 8-16 metacystic trophozoites which first colonize the **caecum** and then the general **colon**.

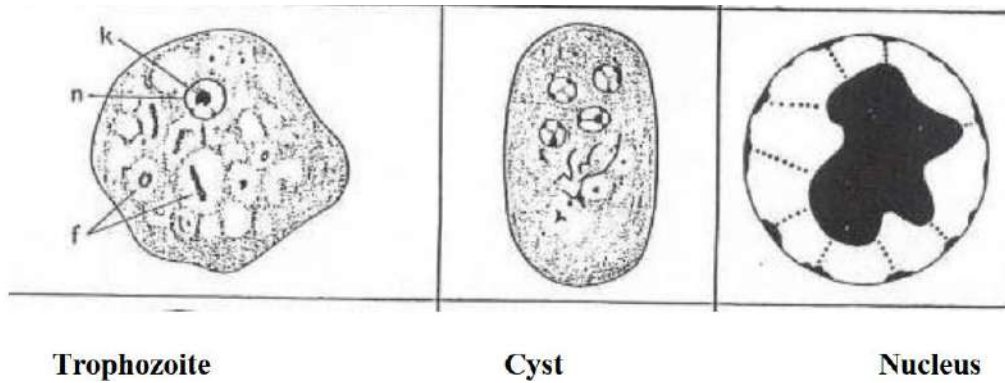


## ENTAMOEBA HISTOLYTICA VERSUS ENTAMOEBA COLI

ENTAMOEBA HISTOLYTICA	ENTAMOEBA COLI
The agent of amebic dysentery, a disorder with inflammation of the intestine and ulceration of the colon	A non-pathogenic species of the genus Entamoeba that reside in the gastrointestinal tract of humans and other mammals
Trophozoite has finger-like pseudopodia	Trophozoite lacks pseudopodia
Trophozoite is actively motile	Trophozoite is sluggishly motile
Ectoplasm is prominent trophozoites	Ectoplasm is not prominent trophozoite
Endoplasm of trophozoites is finely granular with ingested RBCs	Endoplasm is coarsely granular loaded with bacteria, yeasts, etc.
The nucleus of the trophozoites is small and indistinct	The nucleus of the trophozoites is large and distinct
Nuclear membranes of the trophozoites contain uniformly stained chromatin	Nuclear membranes of the trophozoites contain irregularly stained chromatin
The karyosome of trophozoites is central	The karyosome of the trophozoites is eccentric
The cystic stage has one or four nuclei, which are not visible when unstained	The cystic stage has two or eight nuclei, which are visible when unstained



### *Endolimax nana* “The dwarf internal slug”

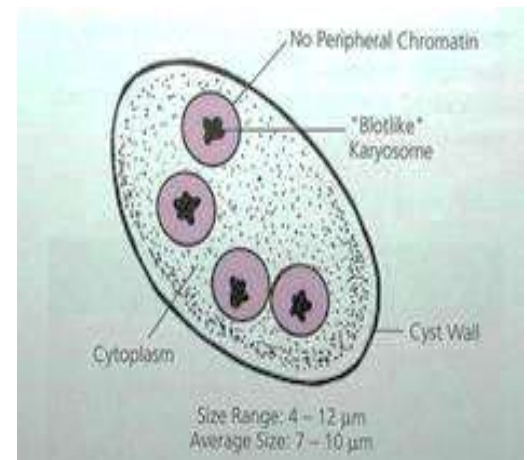


#### Trophozoite

- Tiny 6-15  $\mu\text{m}$  in diameter.
- The nucleus has a large karyosome which is a centric or eccentric pleomorphic shape, attached to the nuclear membrane by achromatic threads.

#### Mature cyst

- 5 – 14  $\mu\text{m}$  in diameter.
- Contains 4 nuclei.
- Shape is round to elliptical.
- ❖ Man will be infected with four trophozoites from each cyst.

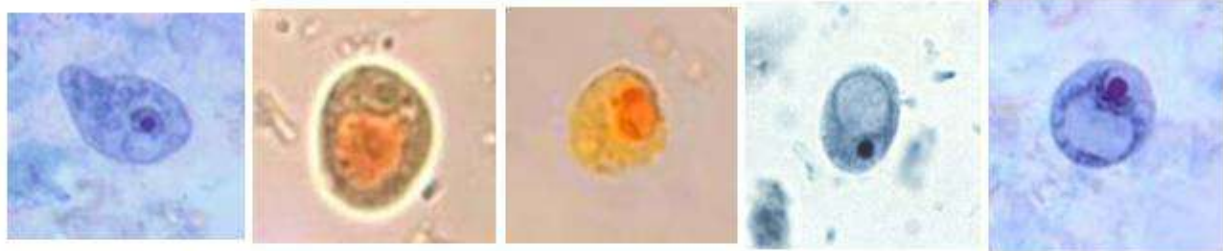
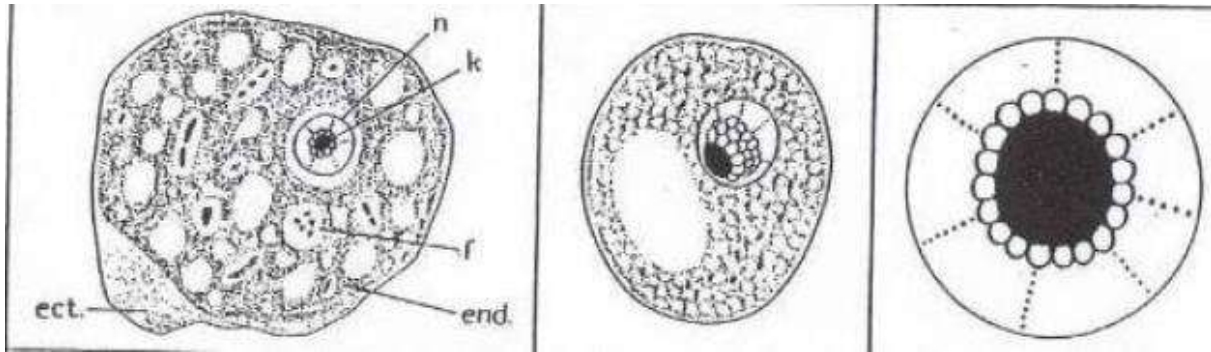


### *Iodamoeba bütschlii*

#### Trophozoite

2. 9-14  $\mu\text{m}$  long but may be as large as 20 $\mu\text{m}$ .
3. The nucleus is characterized by a large central karyosome surrounded by a layer of granules from which linin fibrils extended to the nuclear membrane.





Trophozoite

Cysts in iodine

Cysts, stained

## Cyst

- 6-15  $\mu\text{m}$  long.
- have a large glycogen vacuole.
- Human will be infected with one trophozoite from each cyst.

### Nonpathogenic amoebae:

<i>Entamoeba dispar</i>	Morphologically identical to <i>E. histolytica</i> . It must be separated by isoenzymatic, immunologic or molecular analyses.
<i>Entamoeba hartmanni</i>	Some consider this a separate species. It differs from <i>E. histolytica</i> by being smaller in size.
<i>Entamoeba coli</i>	Distinguished from <i>E. histolytica</i> by having an eccentric endosome, in mature cysts with 8 nuclei. If chromatoidal bodies are present, they have splintered ends, rather than rounded as in <i>E. histolytica</i> .
<i>Endolimax nana</i>	This is a very small amoeba (6-15 $\mu\text{m}$ ) with a large, eccentric endosome and thin nuclear envelope. Mature cysts contain 4 nuclei.
<i>Iodamoeba butschlii</i>	Both the trophozoite and cyst have one nucleus with a large endosome. The cyst contains a large glycogen vacuole that stains darkly with iodine.