

# Selection of posterior teeth

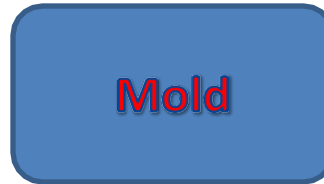Dr. Saraa Almallah

# Posterior teeth are selected for:

- Shade

- Size

- Occlusal form



# Shade

- Shade of posterior teeth should be harmonized to the shade of anterior teeth, maxillary first premolars are sometimes used for esthetic more than function, so it is advisable to select premolar teeth with lighter color than the other posterior teeth, but not lighter than anterior teeth.

- Generally the shades of posterior teeth are slightly darker than anterior teeth.



# Size

- A) occlusogingival height
- It is determined by the available interarch distance. The occlusal plane should be located at the midpoint of the interocclusal distance. The length of the maxillary first premolar should be comparable to that of maxillary canine to have the proper esthetic effect.

- The height of posterior teeth usually divided into long, medium, and short. Long posterior teeth are generally more esthetic in appearance than are shorter teeth.

- B) buccolingual width
- The buccolingual width of posterior teeth should be slightly narrower than natural teeth, because the broader occlusal surfaces which direct more stress during function to supporting tissue, leading to increase in the rate of ridge resorption.

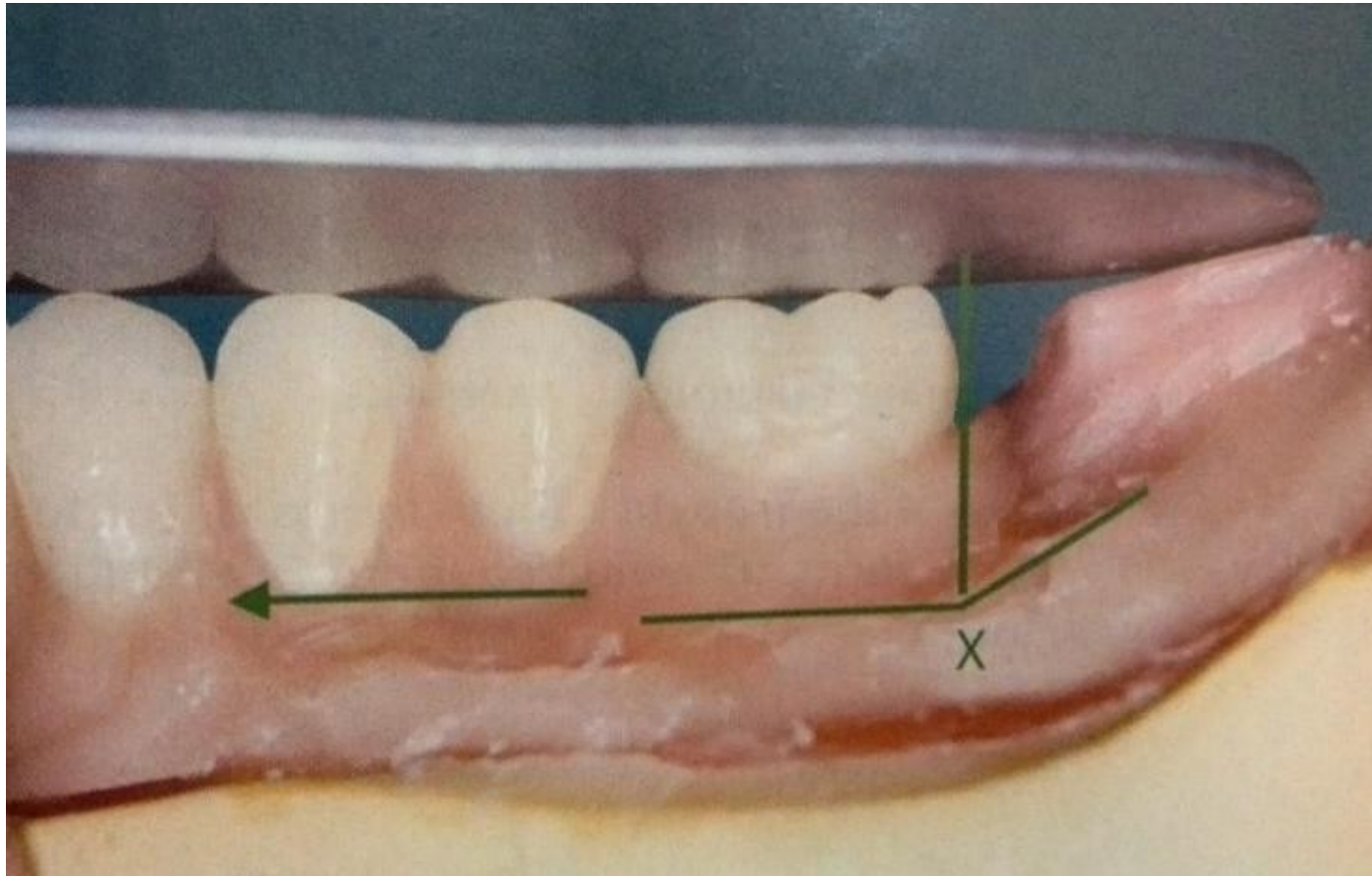
- Broader teeth encroach into the tongue space leading to instability of the denture. Also, the teeth should not encroach into the buccal corridor space to avoid cheek biting.

- C) mesiodistal length
- The combined mesiodistal lengths of all maxillary posterior teeth in that side of the arch should be equal to the distance between canine line, and anterior border of maxillary tuberosity.

- For mandibular posterior teeth, the mesiodistal lengths should be equal to distance between the canine line and anterior border of retromolar pad.

- Placing a tooth on an inclined plane (*steep anteroposterior ridge slope*) should be avoided, otherwise this would lead to forward displacement of the denture and dislodgment of denture occurs.
- Similarly the teeth should not be placed over displaceable tissues like the retromolar pad as it will cause tipping of the denture during function.
- In case with inadequate mesiodistal length, the premolar can be omitted.

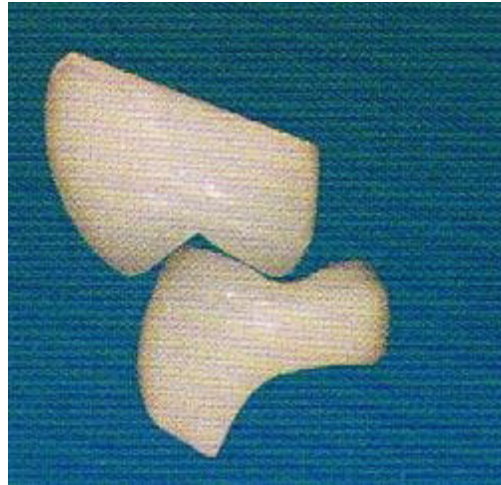
**X indicates the beginning of the steep slope. The arrow indicates the potential movement of the denture during the function if the second molar were placed on the slope.**



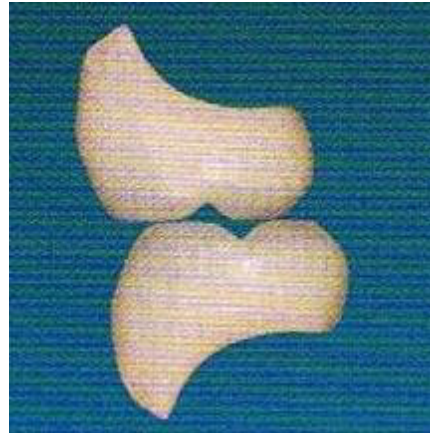


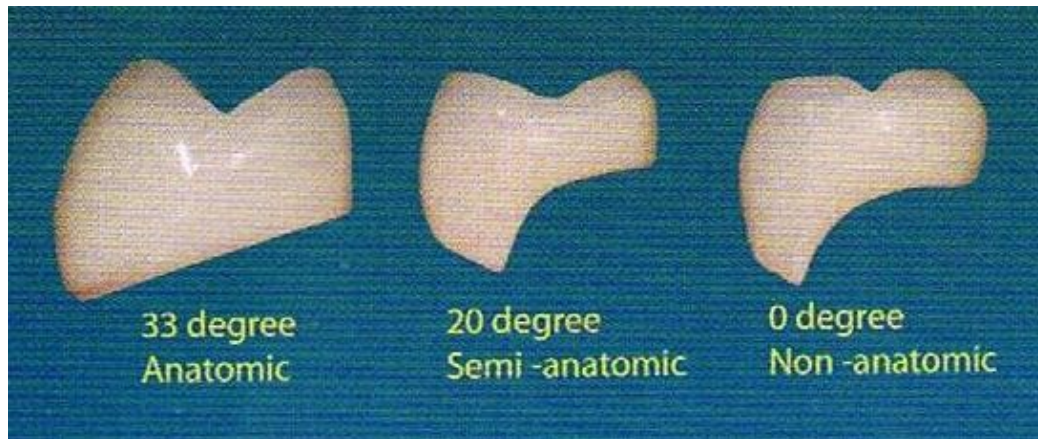
# Occlusal form

- *There are two forms*
- *A) cusp form ( anatomical teeth) :They have anatomical teeth (have cusp angles)*



- B) non cusp form (cusplless form) : They also called *monoplane, flat plane, or zero degree*.





# Advantages of cusp form teeth

- More efficient in chewing.
- The **cusp** - **fossa** relationship between the maxillary and mandibular posterior teeth forms a definite point for return to centric occlusion.
- More acceptable esthetically.
- More compatible with surrounding oral environment.

# Advantages of non cusp form teeth

- Offer less resistance in non-masticatory movement like (bruxism); **therefore less damaging to the supporting structure.**  
.
- Offer less resistance to lateral forces therefore, they are **indicated in excessively resorbed ridges.**
- They can be used with less damaging effect than cusp form teeth in patient with uncoordinated neuromuscular control in which jaw relation records are not repeatable

# *Jaw Relation*

Dr.Hussein AlDewachi

- *Jaw relation (maxillomandibular relationship)*: -any relation of the mandible to the maxilla .
- *Jaw relation record (maxillomandibular relation record)*: It is a registration of any positional relationship of the mandible relative to the maxilla.

# Types Jaw relation:-

1- **Orientation jaw relation:-** Establish the relation of maxilla to some anatomical landmarks in the cranium.

2- **Vertical jaw relation (at rest &at occlusion):-**

Establish the amount of jaw separation allowable for use for dentures

3- **Horizontal jaw relation(Centric &Eccentric):-**

Establish front –to-back and side to side relations of one jaw to the other.



## The aim of recording the jaw relation

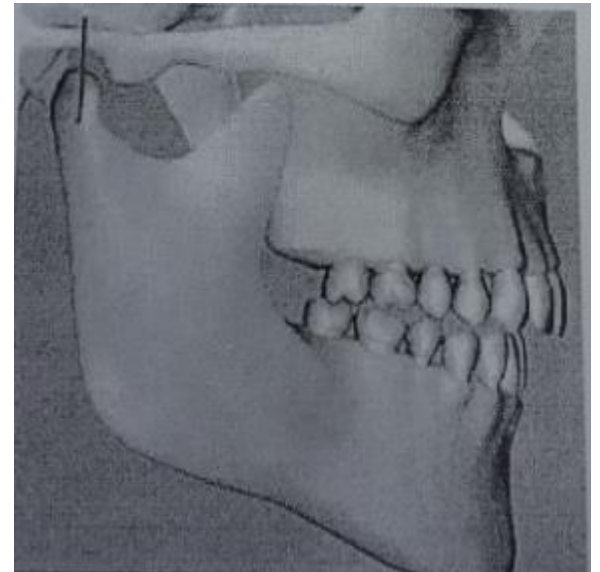
- The aim of recording the jaw relation is to facilitating the adaption of the complete dentures to the masticatory system to give them optimal and comfortable function

## Orientation jaw relation

- **Orientation jaw relation:** it is the jaw relation when the mandible is kept in its most posterior position it can rotate around an imaginary transverse axis passing through the condyle.

## Orientation jaw relation

- This record gives the angulation of the maxilla in relation to the base of the skull it is necessary to do orientation jaw relation before carrying out other jaw relations.



## Orientation of occlusal plane:

- The occlusal rims are inserted into the patient mouth and the following factors are checked:

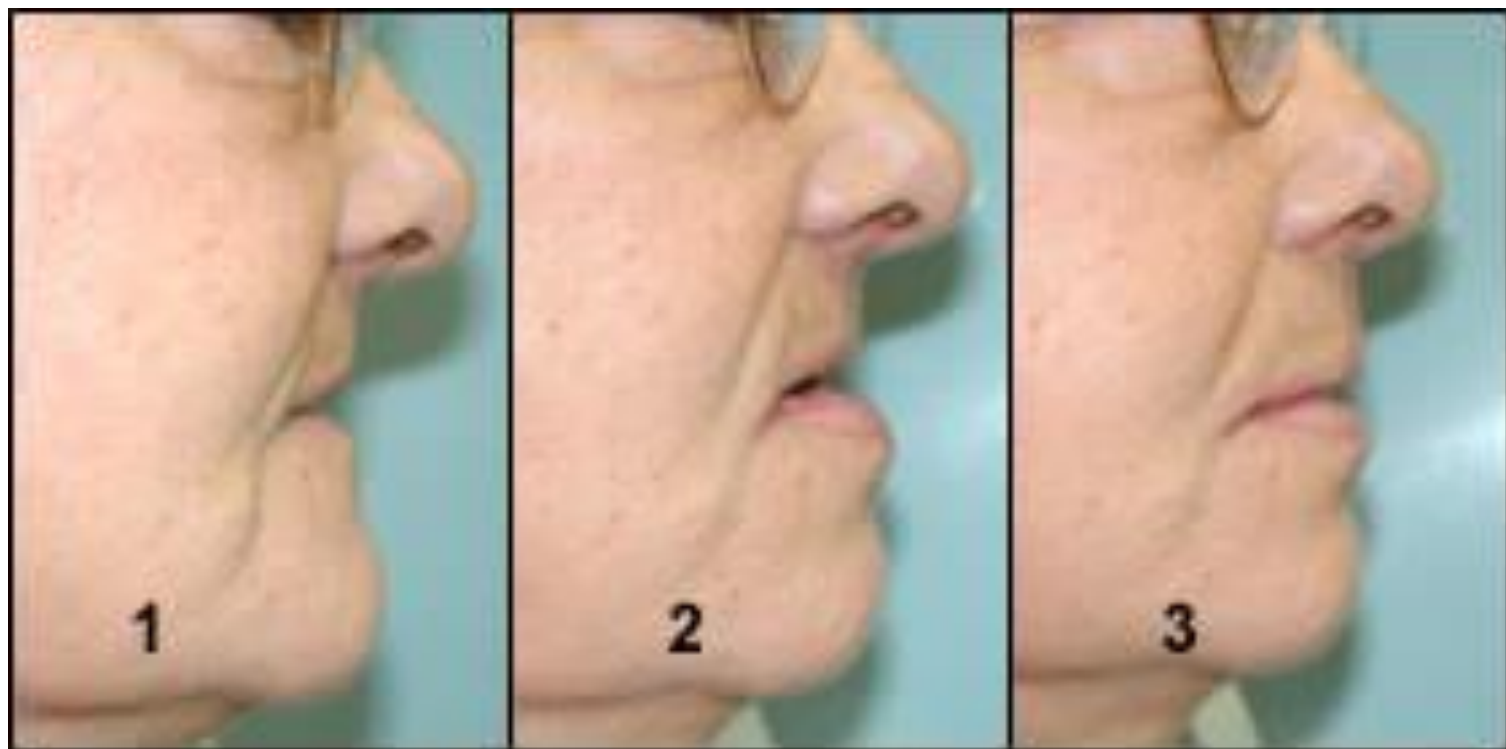1- lip Support or labial fullness.

2-over-jet.

3-cheek support and buccal fullness.

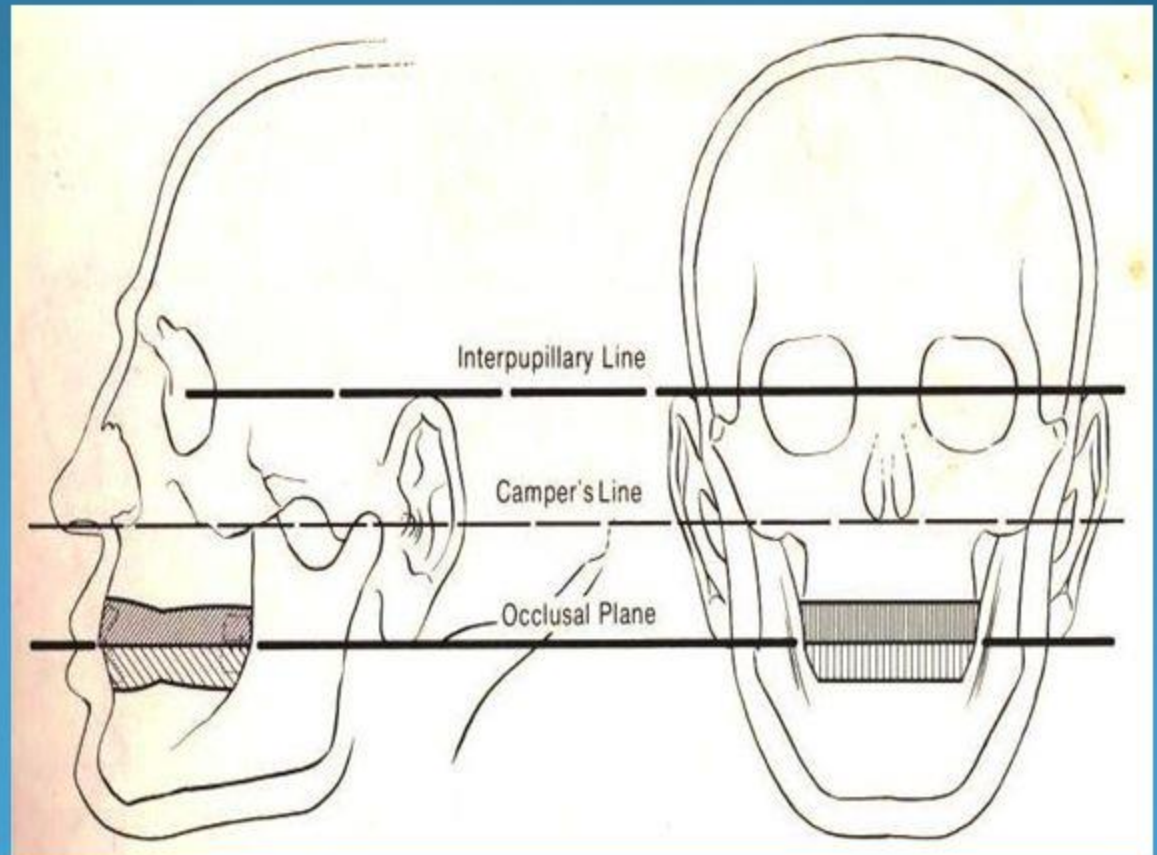
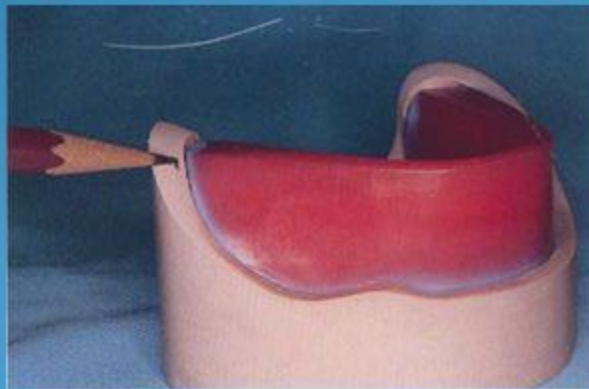
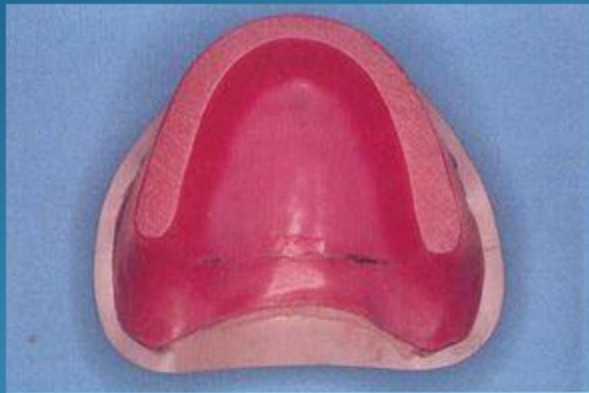4-level of the occlusal plane.

5-orientation of plane of occlusion.



# Orientation of Occlusal Plane

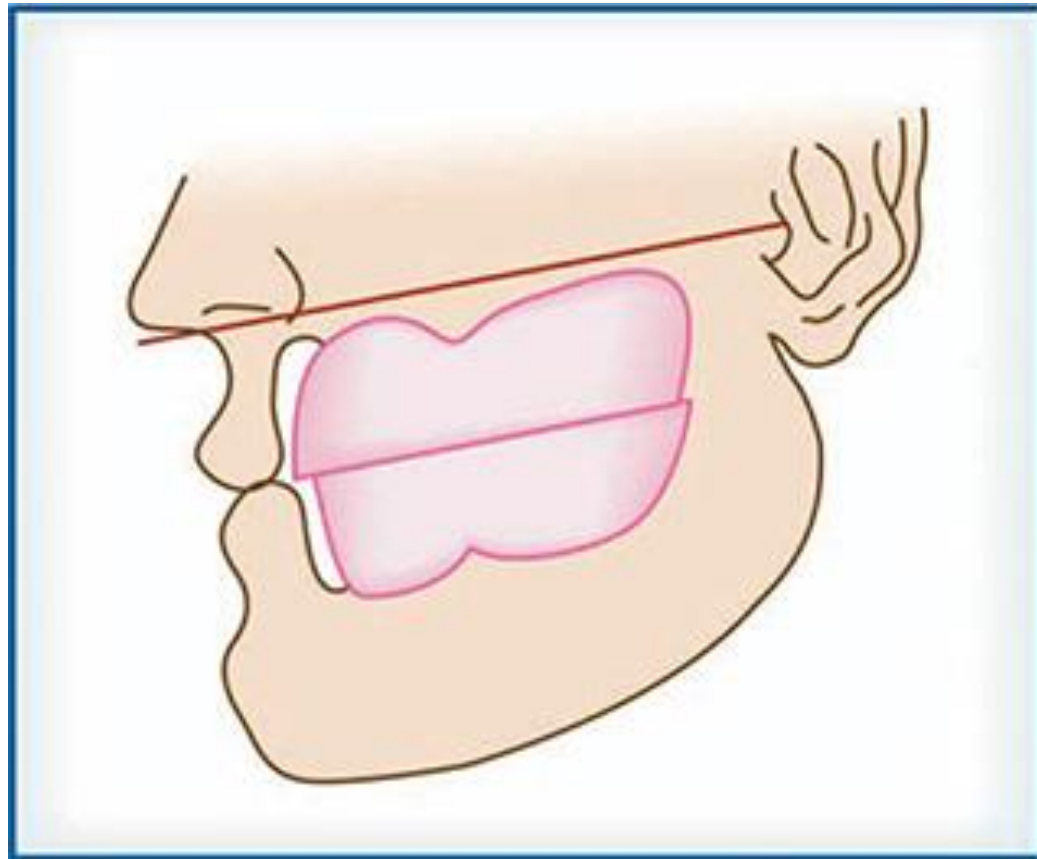
The occlusal plane is defined as the average plane established by the incisal and occlusal surfaces of the teeth".



# Establishment of occlusal plane

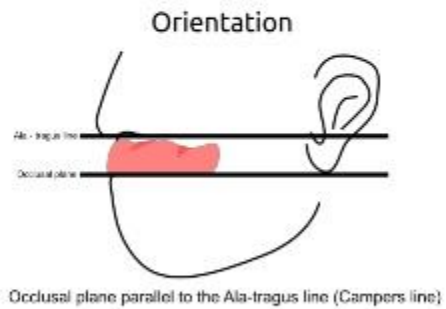
- *The occlusal plane established by the incisal and occlusal surfaces of the teeth*, the plane of the occlusal rim should be **parallel** to the maxilla. The plane of the maxilla is determined anteriorly by **inter pupillary line** and posteriorly by **ala tragus line**, this line extends from the upper border of the tragus of the ear to the lower border of the ala of the nose.

## ala tragus line

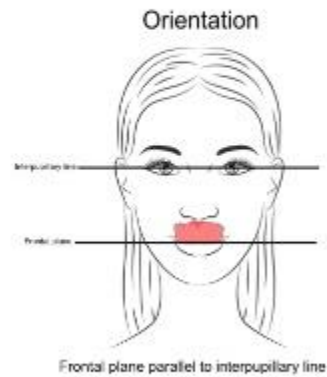




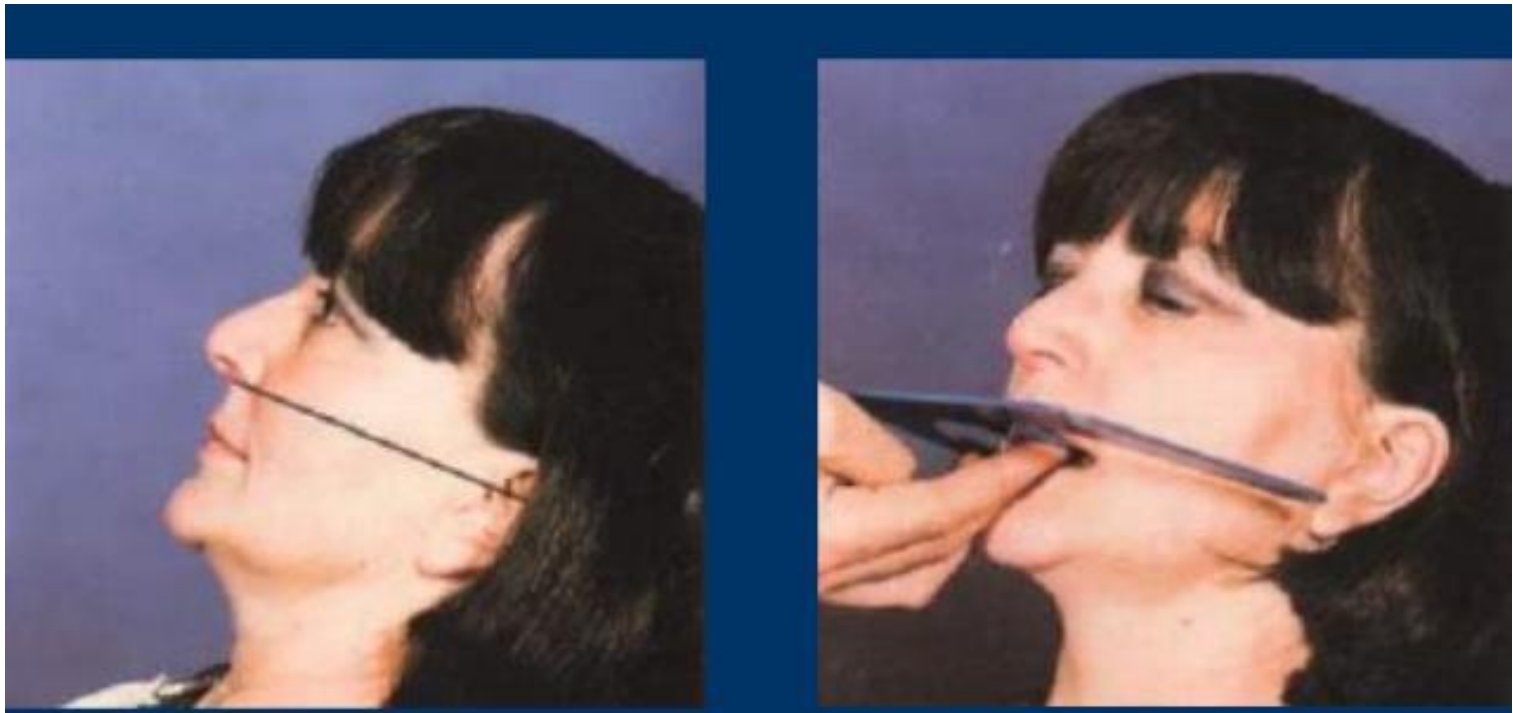## Interpupillary line + Ala Tragus Line



Occlusal plane parallel to the Ala-tragus line (Campers line)

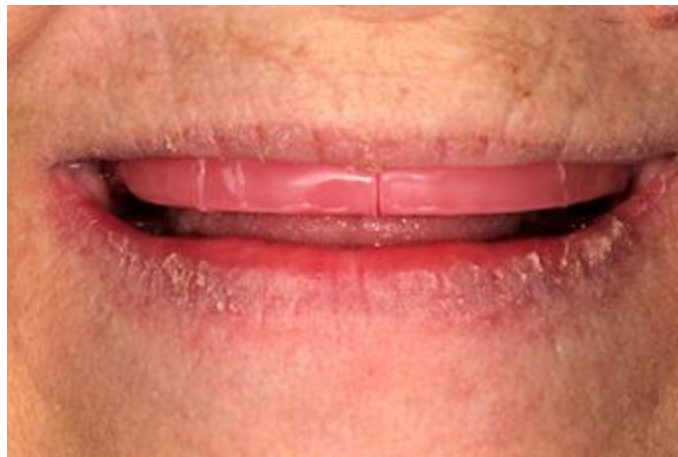

Frontal plane parallel to interpupillary line

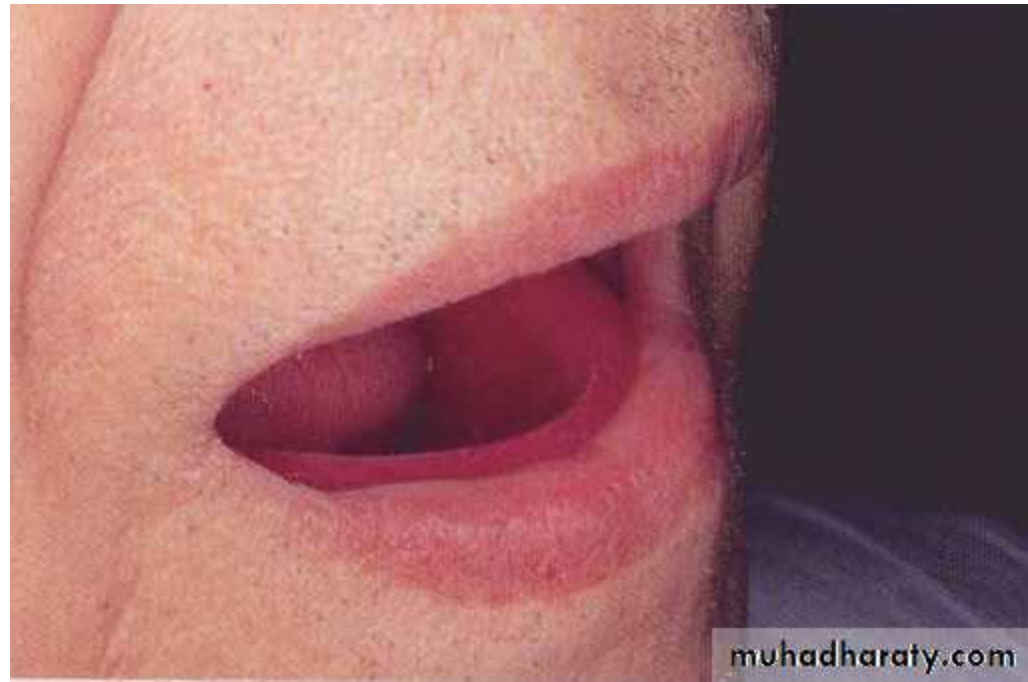

## Level of occlusal plane:

- The occlusal plane should be located at the **mid-point of the inter-arch distance**.
- The upper occlusal rim should be reduced up to or 2mm *below* the level of upper lip during speech.



- The lower occlusal rim should be at the level of the lower lip and the angle of the mouth, posteriorly it should be two third the height of the retromolar pad.



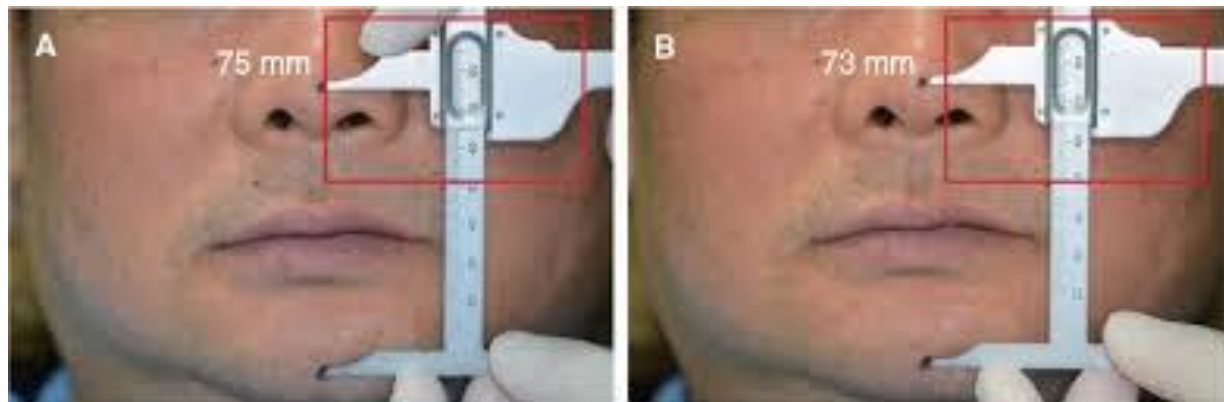
- Orientation Relation can be recorded with a face bow.
- *Face bow*: a caliper like device which is used to record the relationship of the maxilla and or the mandible to the temporomandibular joints and to orient the casts on the articulator to the relationship of TMJ.

# Vertical Jaw Relation:

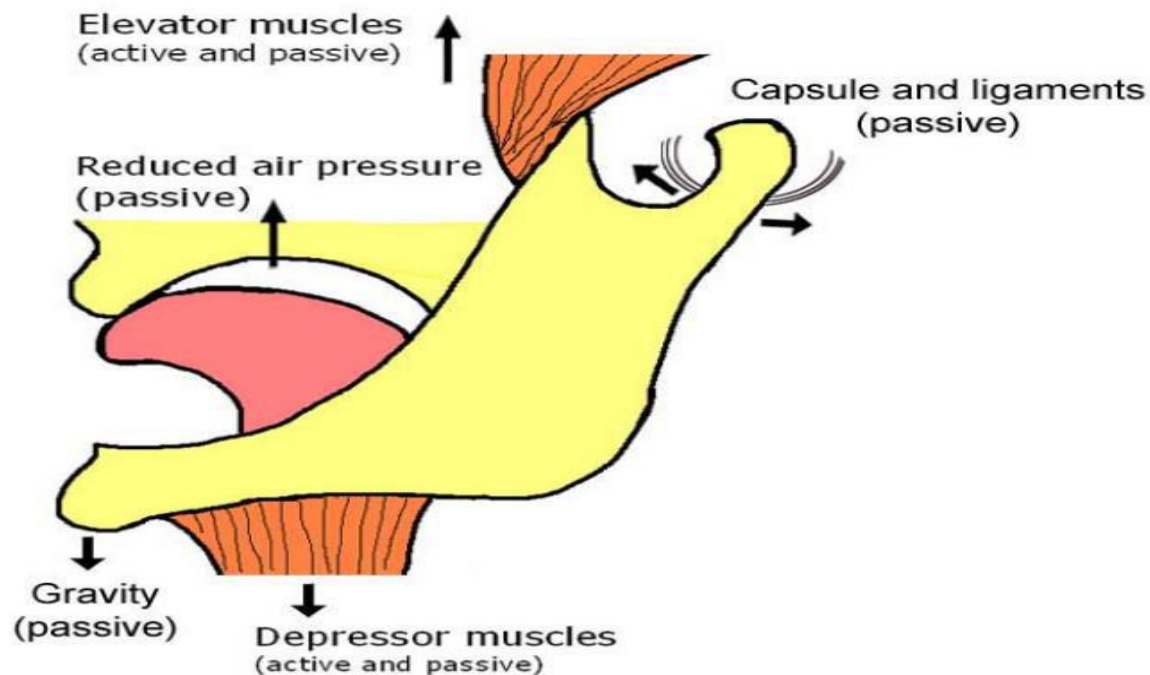
- **Vertical Jaw Relation:** : It is the amount of separation between the maxilla and the mandible in a frontal plane.

## Vertical dimension

- **Vertical dimension:** It is the distance between two selected points, one
- on a fixed and one on a movable member.
- In general, the vertical measurement of face could be recorded between any two arbitrary selected points which are usually located one above the mouth (*at the tip of nose*) and the other below the mouth (*at the tip of chin in the mid line region*).



- **Physiological rest position:** It is the postural position of the mandible when an individual is resting comfortably in an upright position and the associated muscles are in a state of minimal contractual activity.





- **Rest vertical dimension:** It is the distance between two selected points (one at the tip of nose and the other at the tip of chin in the mid line region) measured when the mandible is in the physiologic rest position.

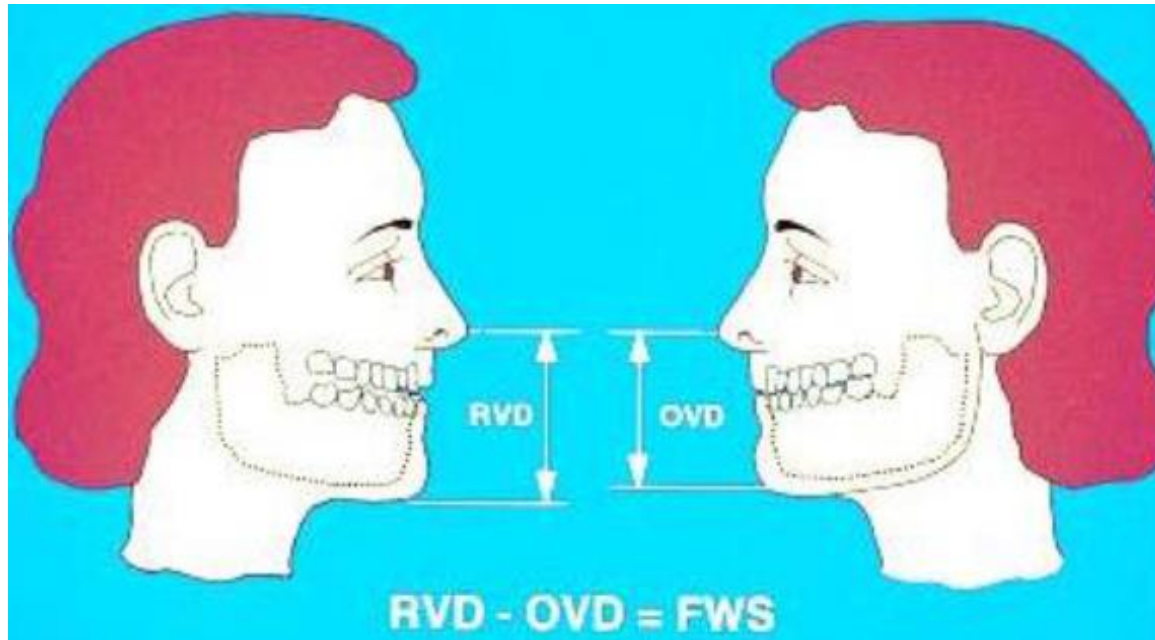
- **Occlusal vertical dimension:** It is the distance measured between two points when the occluding members (teeth or occlusal rims) are in contact.

- **Interocclusal distance (interocclusal gap):** It is the distance between the occluding surfaces of the maxillary and mandibular teeth when the mandible is in a specified position.

- **Interocclusal rest space (freeway space):** It is the distance between the occluding surface of maxillary and mandibular teeth when the mandible is in its physiological rest position. It is the difference between the vertical dimension of rest and the vertical dimension of occlusion.

# Freeway space

- $RVD - OVD = \text{Freeway space } \textit{normally} \approx (2-4 \text{ mm})$



# Increased vertical dimension

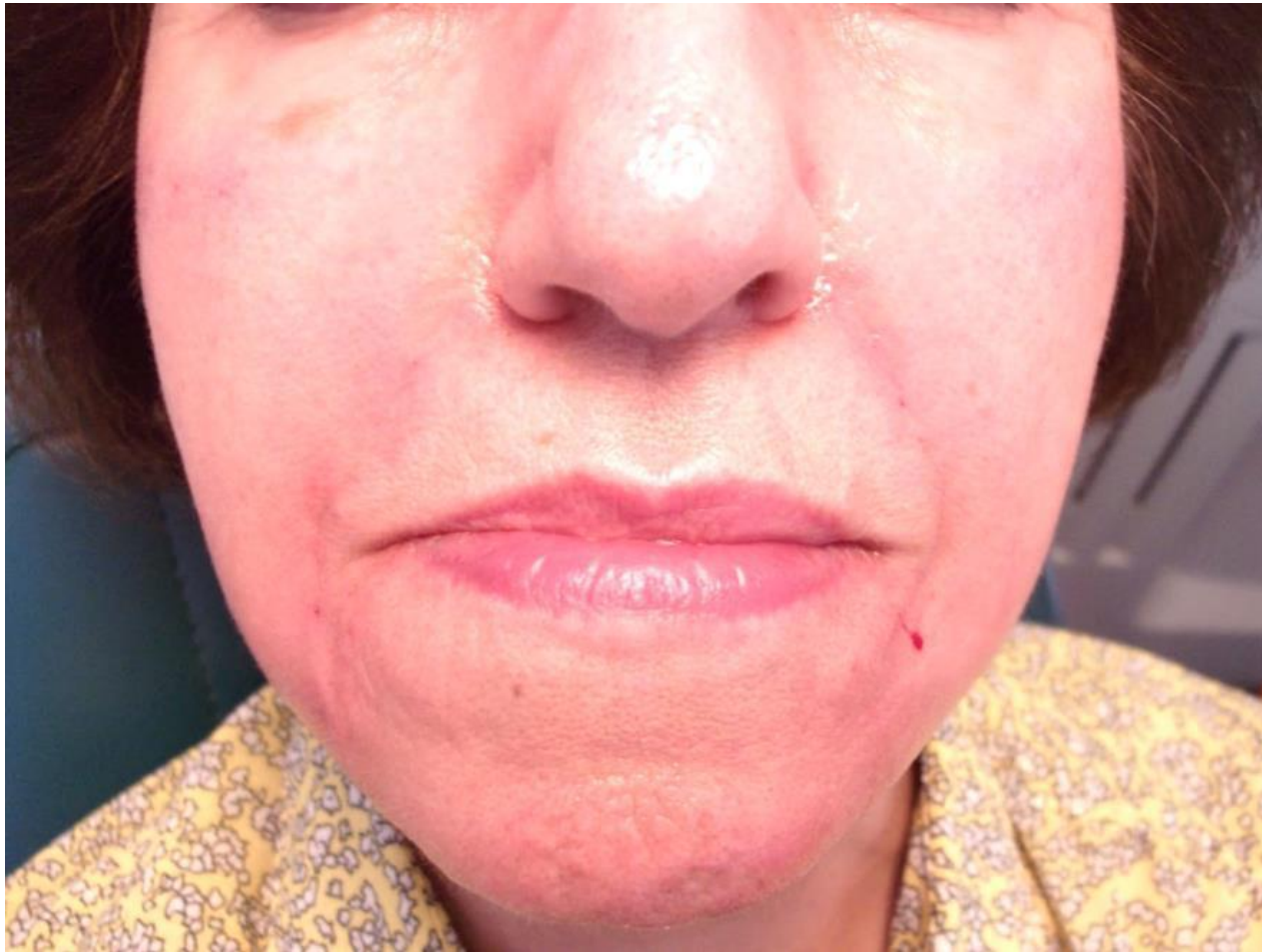
1. Increased trauma to the denture bearing area (acceleration of residual ridge resorption).
2. Inharmonious facial proportion (increased lower facial height).
3. Difficulty in swallowing and speech.
4. Pain and clicking in the temporomandibular joint and muscular fatigue.

5. Stretching of the facial muscles and skin.
6. Increase space of the oral cavity.
7. Loss of biting power.
8. Increase nasolabial angle.
9. Sensation of bulky denture.
10. Premature contact of upper and lower teeth.

11. Instability of dentures due to their excessive height.
12. Clicking of teeth in speech and mastication.
13. Separated upper and lower lip with poor esthetic and difficulty in
14. bilabial sound (*/p/b/m/*).
15. Seem unable to open the mouth widely.
16. Excessive display of artificial teeth and gum



# Increased vertical dimension



# Decreased vertical dimension

1. Comparatively lesser trauma to the denture bearing area.
2. Inharmonious facial proportion (decreased lower facial height).
3. Difficulty in swallowing and speech.
4. Pain and clicking in the temporomandibular joint and muscular fatigue.
5. Loss of muscle tone and presence of wrinkles and folds that is not due to age.

6. Decreased space of the oral cavity, and pushing the tongue backward.
7. Loss of biting power.
8. Nasolabial angle is less than  $90^{\circ}$ .
9. Angular cheilitis due to folding of the corner of the mouth.
10. Cheek biting.

11. Thinning of the vermilion borders of the lip.

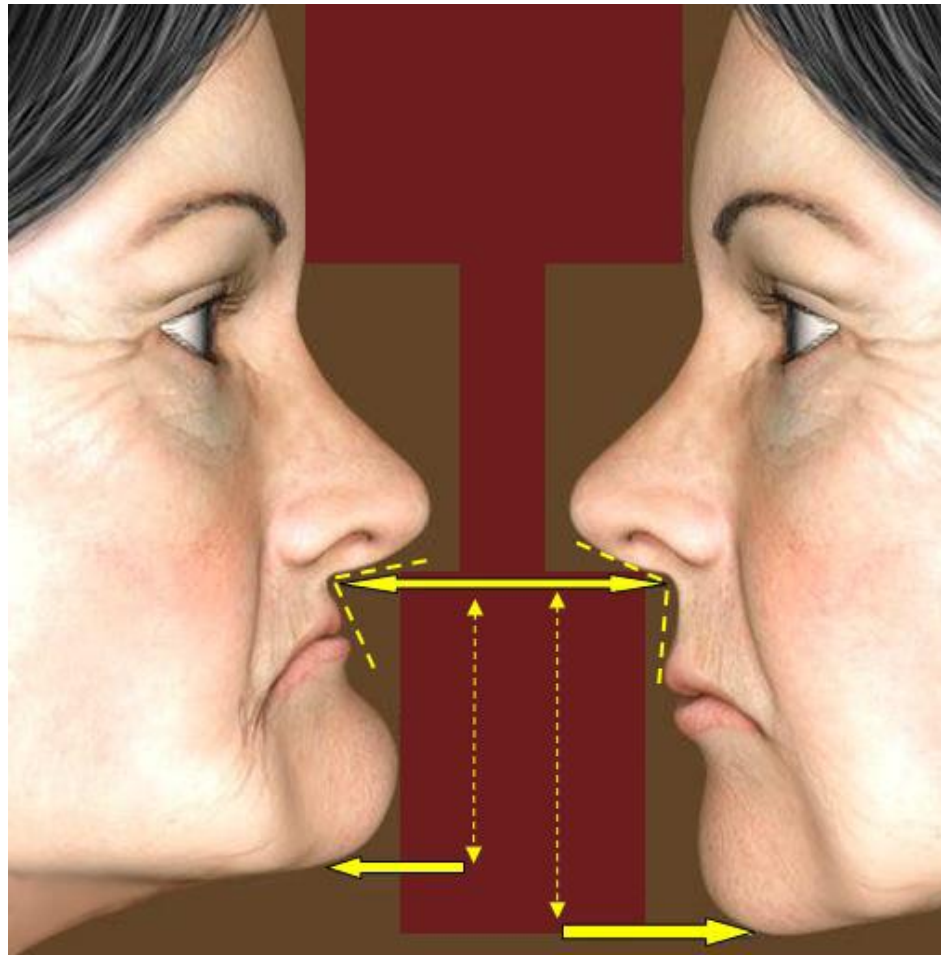
12. Prominence of lower jaw and chin.

13. Obstruction of the opening of the *Eustachian tube* due to elevation of the soft palate due to elevation of the tongue and mandible.

# Decreased vertical dimension



# ***The differences between increased and decreased vertical dimension***



# Importance of vertical dimension

- **Functional roles**; include:
  - a- Mastication.
  - b- Deglutition.
  - c- Phonetics.
  - d- Respiration.
- **Physiological role**, by maintenance health of tissue (mucosa, bone, muscles, and temporomandibular joint); also called **Comfortable role**.
- **Esthetic role**.
- **Psychological role**.

# Complete Denture – Anatomical Landmarks

Presented by  
Dr. Saraa Almallah



The landmarks of an edentulous jaw are grouped into **limiting structures, supporting structures and relief area.**

## A) Limiting structures

These are the sites that will guide us in **having an optimum extension** of the denture so as to engage maximum surface area without encroaching upon the muscle actions.

**Encroaching upon these structures** will lead to dislodgement of the denture and/or soreness of the area **while failure to cover the areas up to the limiting structure** will imply decreased retention stability and support.

## B) Supporting structures / Stress-bearing areas

Supporting structures are the load bearing areas. The denture should be designed such that most of the load is concentrated on these areas.

Support is the resistance to the displacement towards the basal tissue or underlying structures.

## C) Relief area

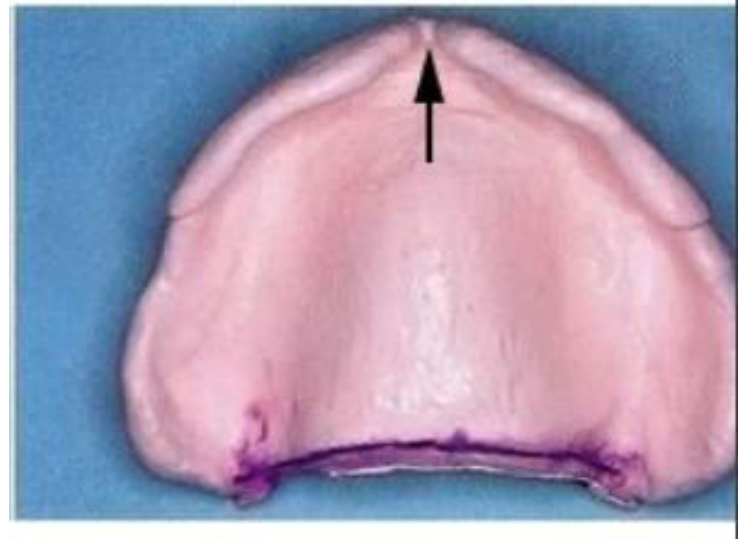
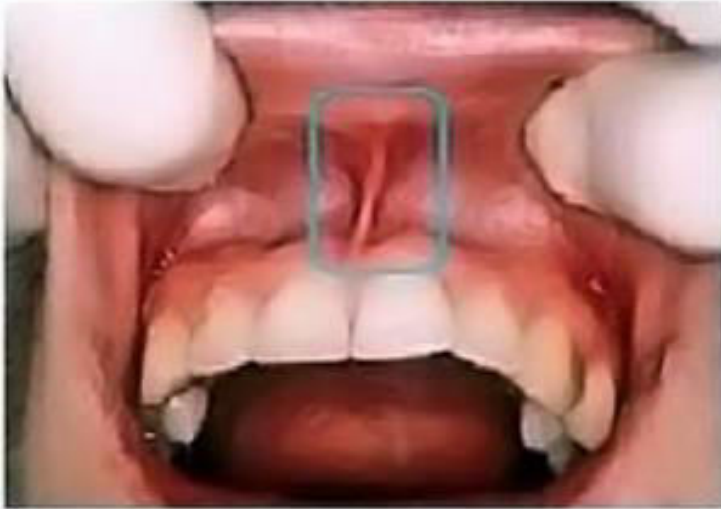
Relief areas are areas where **they are either resorb under constant load, having fragile structures within or covered by thin mucosa** which can be easily traumatized.

It should be designed in such away that the masticatory load is not concentrated over these area

# Anatomical Landmarks – MAXILLA

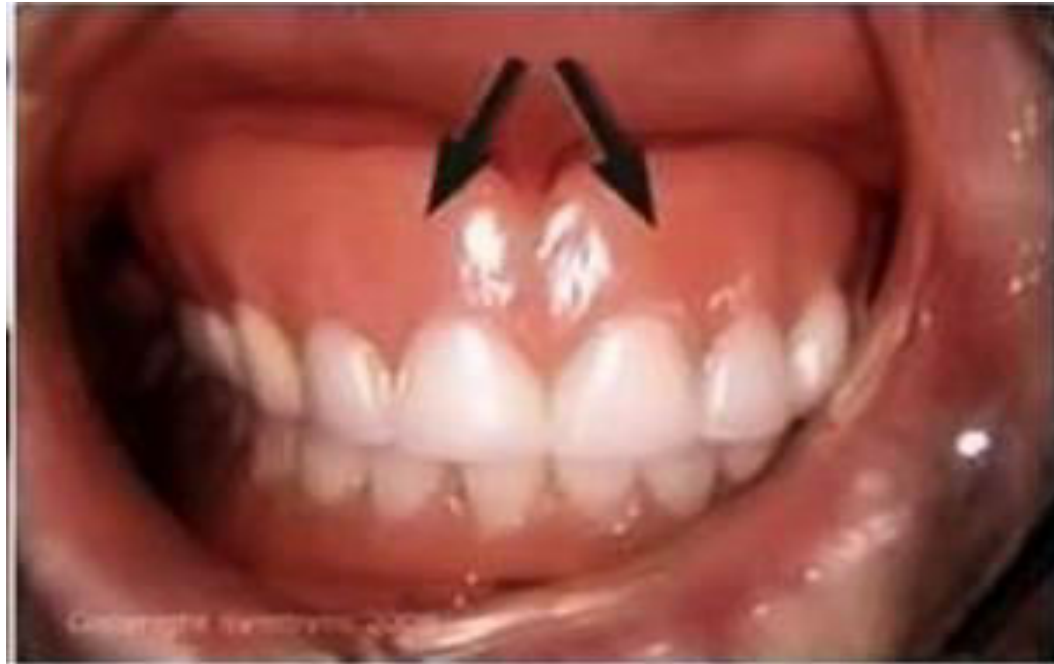# LIMITING STRUCTURES

## A) Labial & buccal frenum

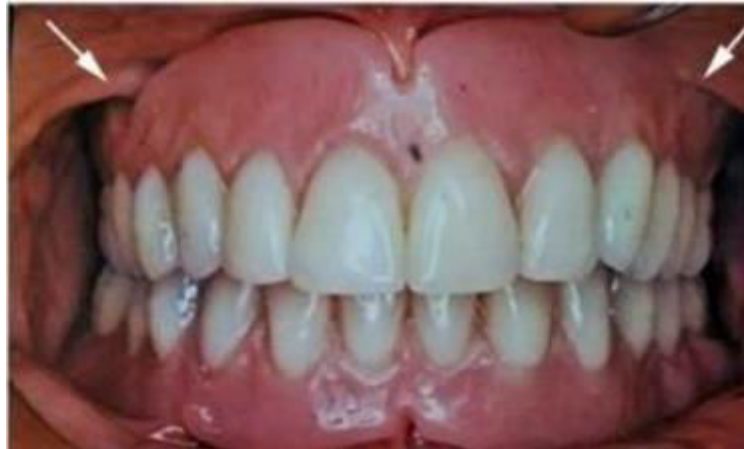

- Fibrous band covered by mucous membrane.
- Labial frenum extends from the labial aspect of the residual ridge to the lip.

**A v-shaped notch (labial notch)** should be provided very carefully which should be narrow but deep enough to avoid interference and should snugly around frenum if peripheral seal is to be achieved.



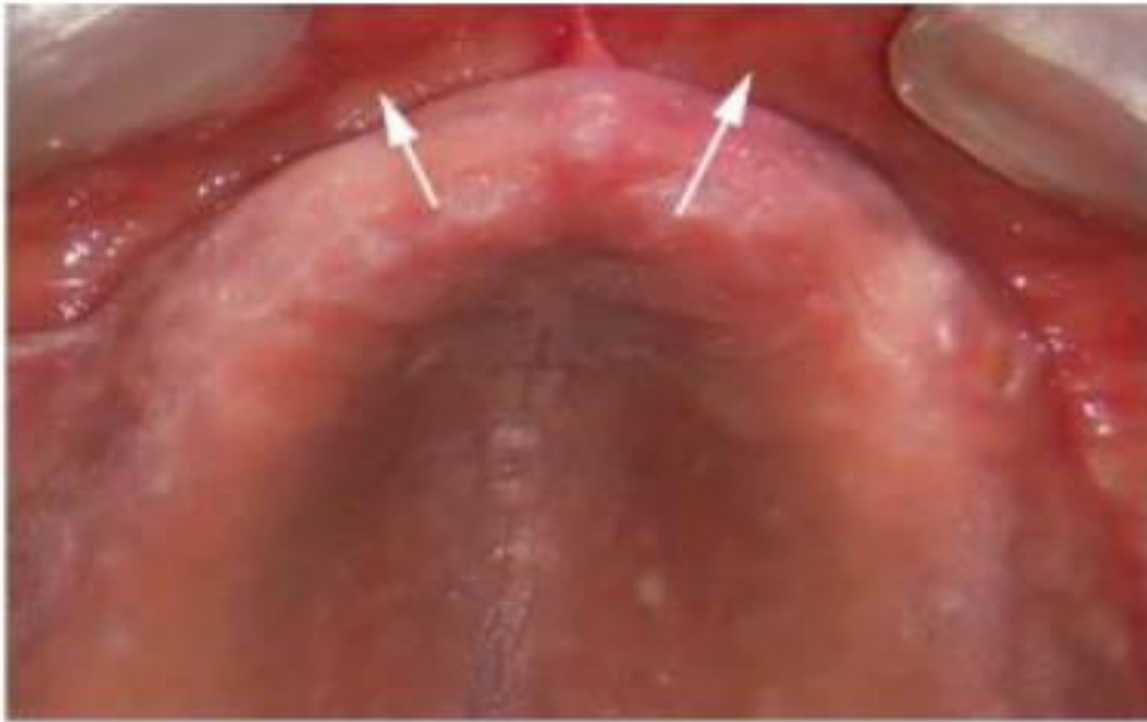**Buccal frenum** has the attachment of following muscles; levator anguli oris, orbicularis oris and buccinator.



It needs greater clearance on buccal flange of the denture (**shallower and wider**) than the labial frenum.



## B) Labial & buccal vestibule (sulcus)

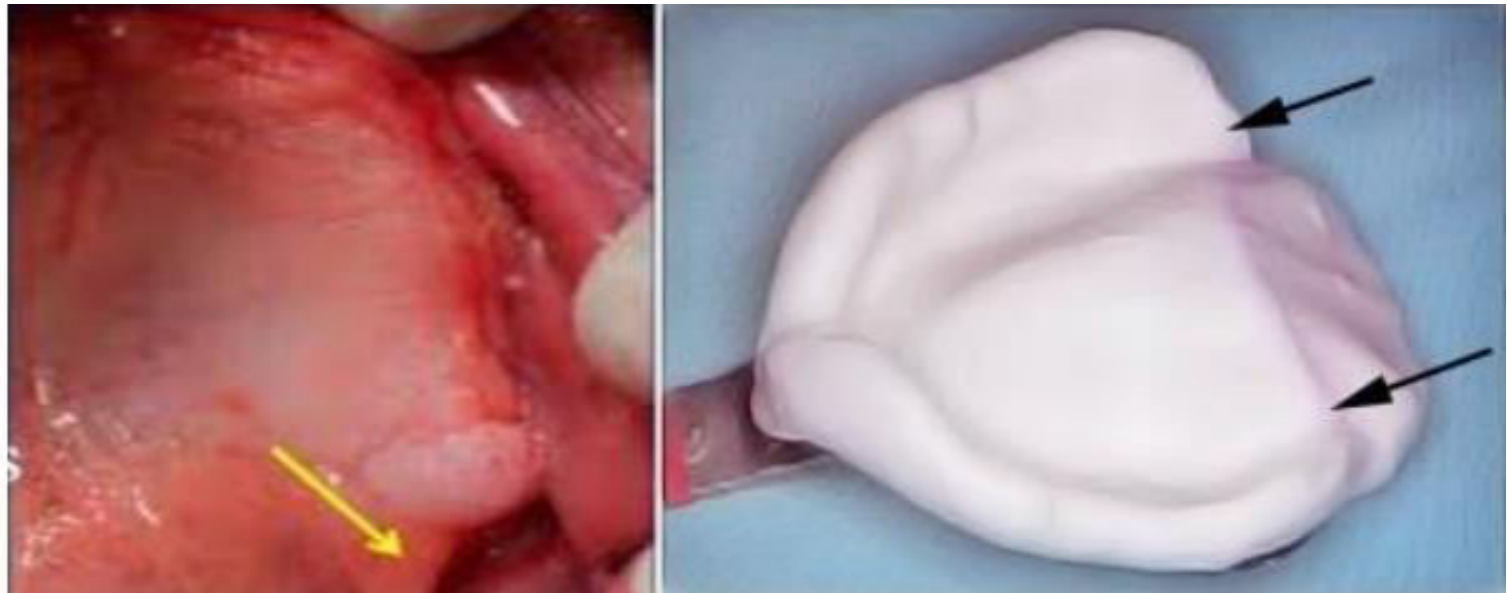


Labial sulcus is bounded on one side by the teeth, gingiva and residual alveolar ridge and on the outer side by lips.

It runs from one side of the buccal frenum of one side to the other side ; dividing in two compartments-left and right by the labial frenum.

## C) Hamular notch

It is depression situated between the maxillary tuberosity and the hamulus of the medial pterygoid plate. It is a soft area of loose connective tissue.

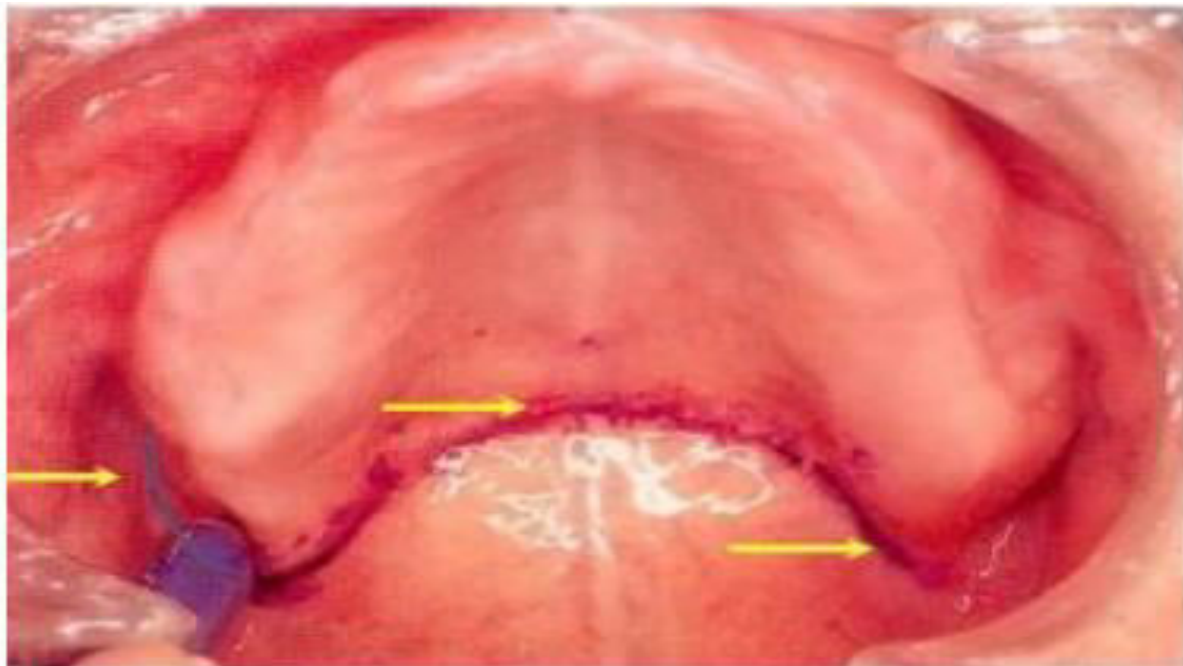


# Significance

- it houses the disto-lateral termination of the denture.
- Aids in achieving posterior palatal seal.
- **Overextension** causes soreness.
- **Underextension** poor retention

## D) Posterior palatal seal area (post-dam)

It is a soft tissue area at or beyond the junction of the hard and soft palates on which pressure within physiological limits can be applied by a complete denture to aid in its retention.



# Functions of the posterior palatal seal:

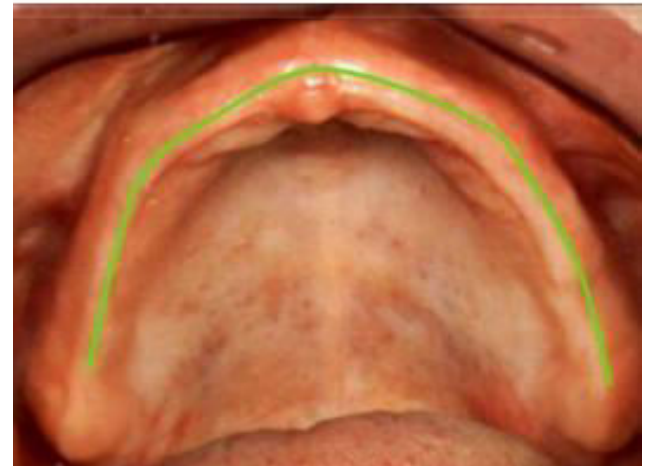
- Aids in retention.
- Prevents food accumulation.
- Compensation for polymerization shrinkage.
- Reduces the tendency for gag reflex as it prevent the formation of the gap between the denture base and soft palate during functional movement.

# SUPPORTING STRUCTURES

## A) Primary stress bearing area / Supporting area

1. Posterior part of the palate
2. Posterolateral part of the residual alveolar ridge

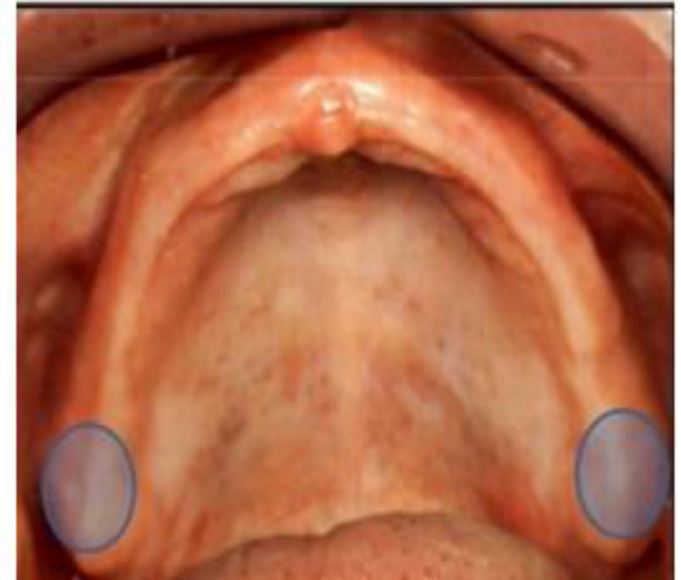
The bony process that remain after teeth have been lost is known as **Residual alveolar ridge** which is covered by mucous membrane.



## B) Secondary stress bearing area / Supporting area

1. The palatal rugae area
2. Maxillary tuberosity

**Maxillary tuberosity** It is the area of the alveolar ridge that extends distally from the second molar to the hamular notch

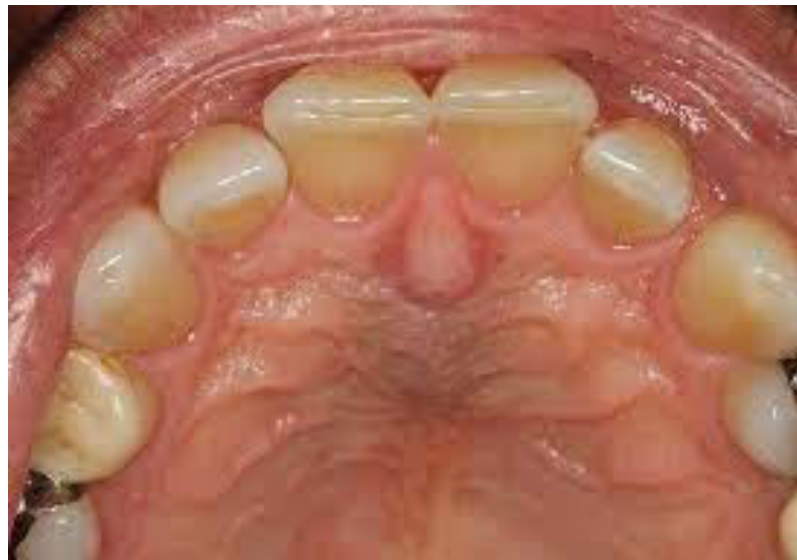



# RELIEF AREAS

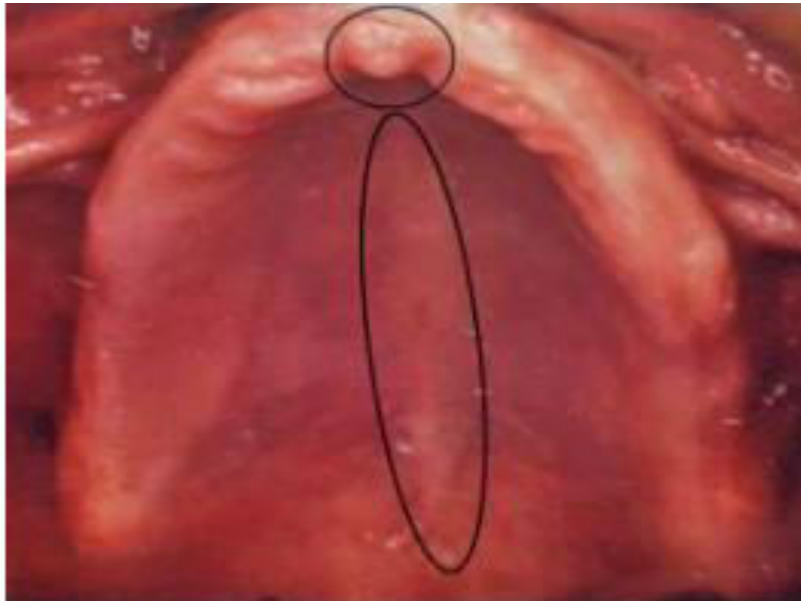
## A) Incisive papilla

- Midline structure situated behind the central incisors.
- It is an exit point of nasopalatine nerves and vessels.
- It should be relieved if not, the denture will compress the nerve or vessels and lead to necrosis of the distributing areas and paresthesia of anterior palate.



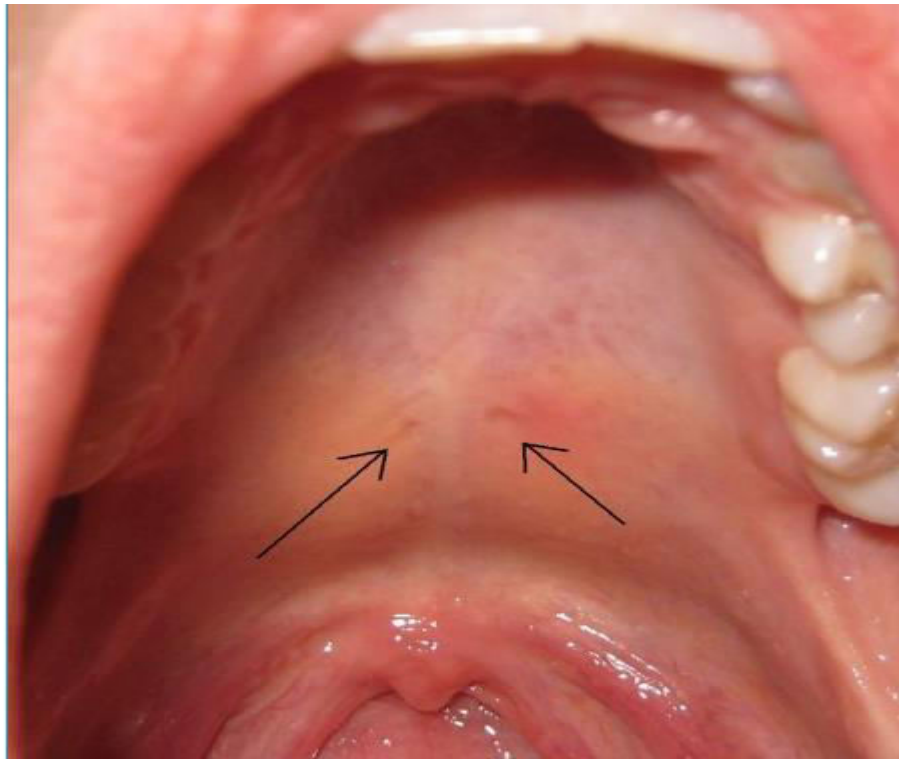
## B) Mid-palatine raphe

- Extends from incisive papilla to distal end of hard palate.
- Median suture area covered by thin submucosa
- Relief is to be provided as it is supposed to be the most sensitive part of the palate to pressure



## c) Fovea palatinae

These are two indentations on each side of the midline formed by a coalescence of several mucous gland ducts.



بِسْمِ اللَّهِ الرَّحْمَنِ الرَّحِيمِ

## Complete denture prosthesis (Definition and Objectives)

Dr. Saraa Almallah

**Prosthodontics** :Is (the branch of dental arts and science pertaining to the restoration and maintenance of oral function by the replacement of missing teeth and structures by artificial devices).

The term **Prosthodontics** is a combination of the words prosthesis and dentistry.

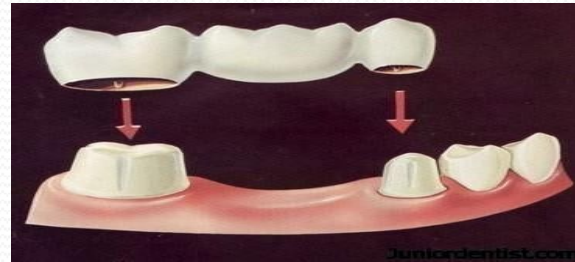
**Prosthesis**: Is defined as the replacement of an absent part of the human body by an artificial part.

*Thus, any dental restoration is a prosthesis.*

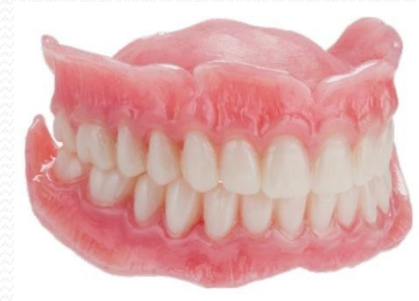

# Branches of prosthodontics:

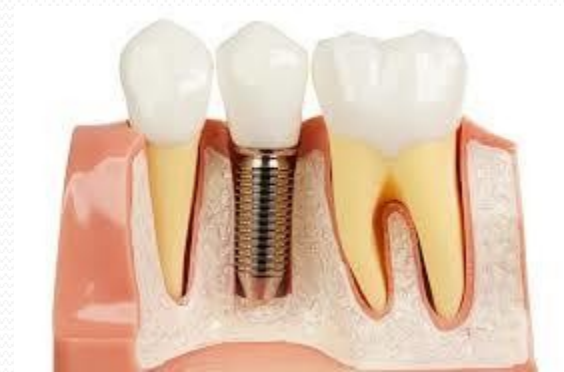- 1. Fixed prosthodontics



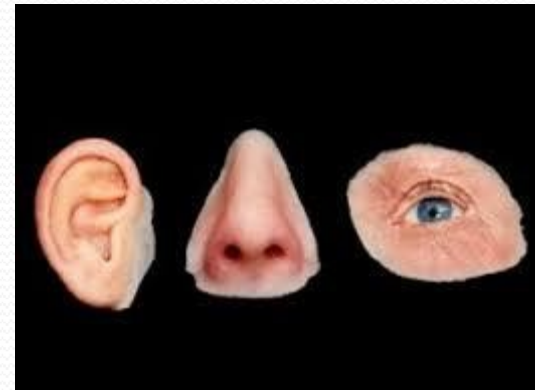
- 2. Removable prosthodontics a) complete denture prosthodontics b) partial denture prosthodontics .




- 3. Implant prosthodontics



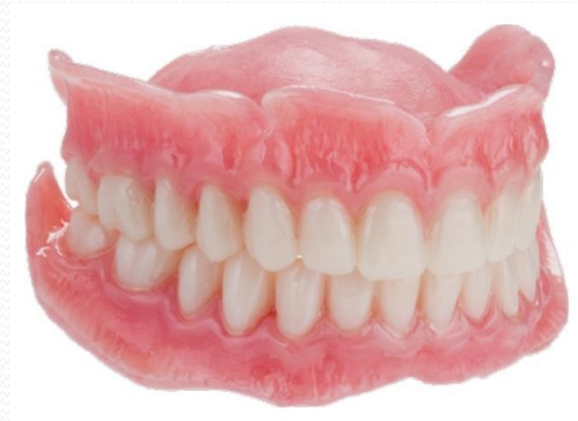- 4. Maxillofacial prosthetics





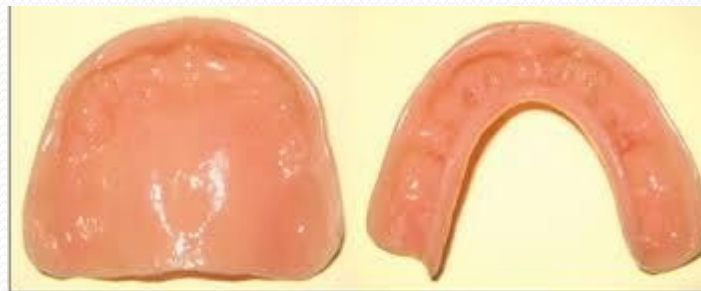- 
- **Dentulous** : a condition in which natural teeth are present in the mouth.
  - **Edentulous**:- a condition in which the mouth is without teeth .
  - **Partially edentulous**:- a condition in which some of the natural teeth are present and some are lost.

- **Complete denture:-** A removable dental prosthesis that replaces the entire dentition and associated structures of the maxilla or mandible.

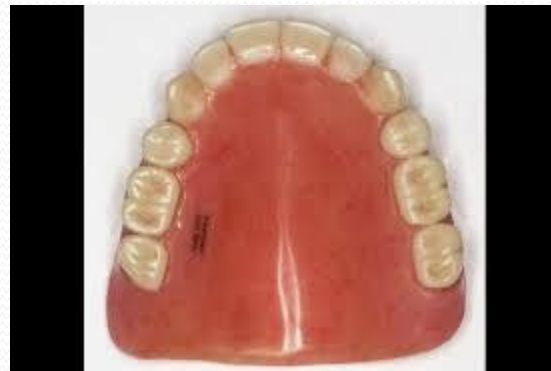

# Surfaces of complete denture


- complete denture has 3 surfaces:
- 1- **The fitting surface (denture basal surface)** : is that portion of the denture surface which has its contour determined by the impression. It includes the borders of the denture and extends to the polished surface.



- **2- The occlusal surface** :- The portion of the denture surface that makes contact with its antagonist (opposing occlusion) include teeth.






- 
- 3- **The polished surface:** That portion of the denture surface which extends in an occlusal direction from the border of the denture and includes the palatal surface. Also it is called as that part of the denture base which is usually polished and includes the buccal and lingual surfaces of the teeth.

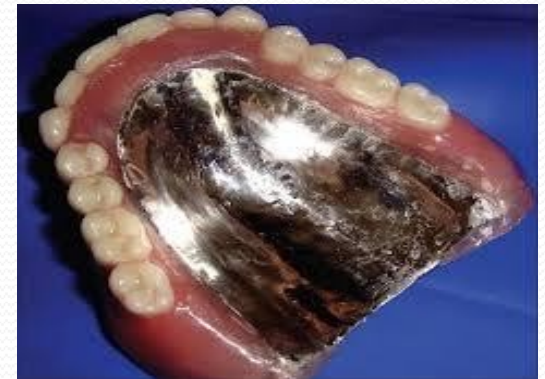# Functions of complete denture

- 1- **Appearance( Aesthetics)**: Is influenced by the shape of the jaws together with the position and occlusal relationship of the teeth.
- 2- **Mastication**:-Chewing food for swallowing and digestion .

- 
- 3- **Speech(Phonetics):-** the teeth either natural or artificial assist the tongue and lips to form sounds of speech .
  - 4- **Preservation** the health of the alveolar bone and temporo-mandibular joint.(TMJ) .

# The finished complete denture is composed of the following:

- **Acrylic resin**, which serves as the base of the complete denture, retains the denture teeth, and mimic the gingiva of supporting teeth.
- **Porcelain or acrylic denture teeth** to mimic natural teeth.
- **In some cases**, a cast metal base as part of a denture base



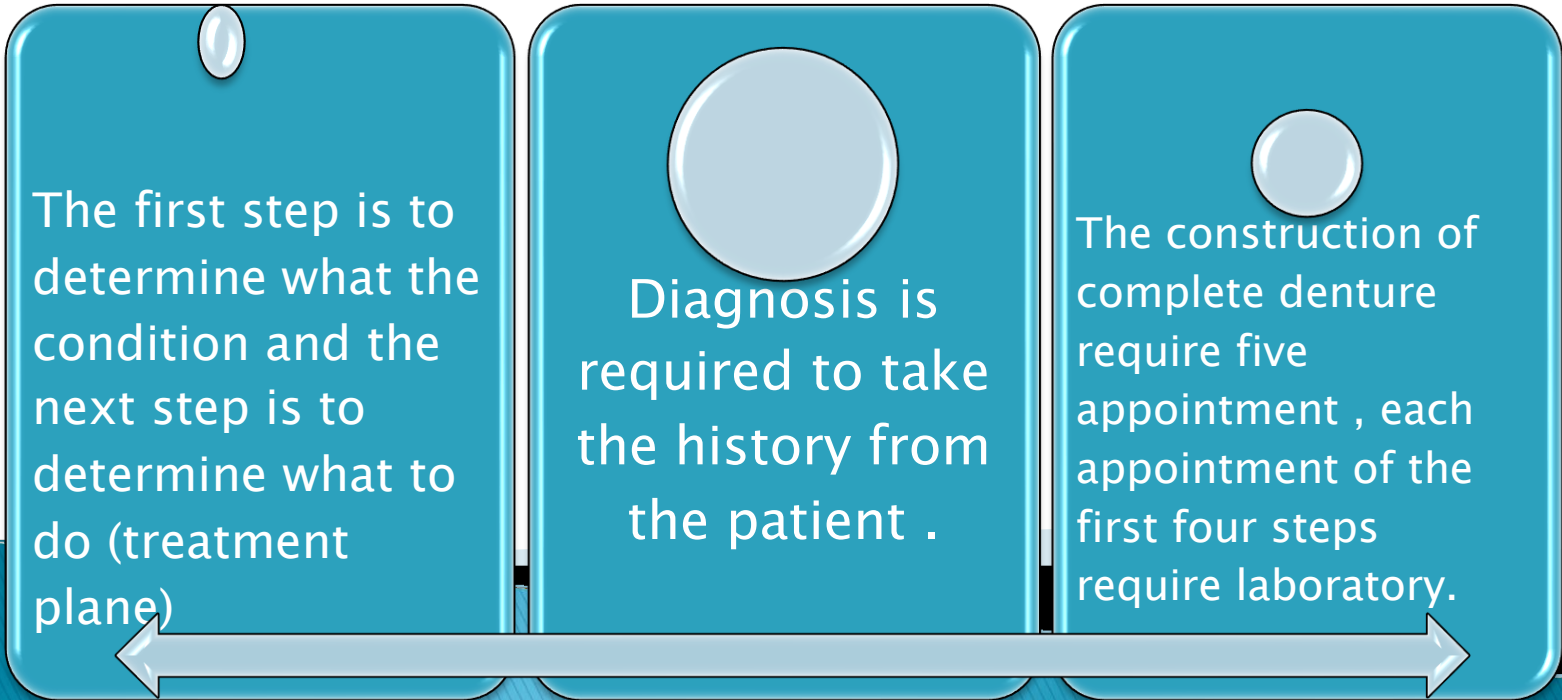


**The primary difference between a complete denture and a removable partial denture is the method by which the prosthesis gains support.**

**\*\* A complete denture** is supported by bone covered by soft tissue(mucosa).

**\*\* A removable partial** denture gains support from the bone covered the mucosa, and from the remaining teeth.

# Sequence of prosthodontic treatment of complete denture



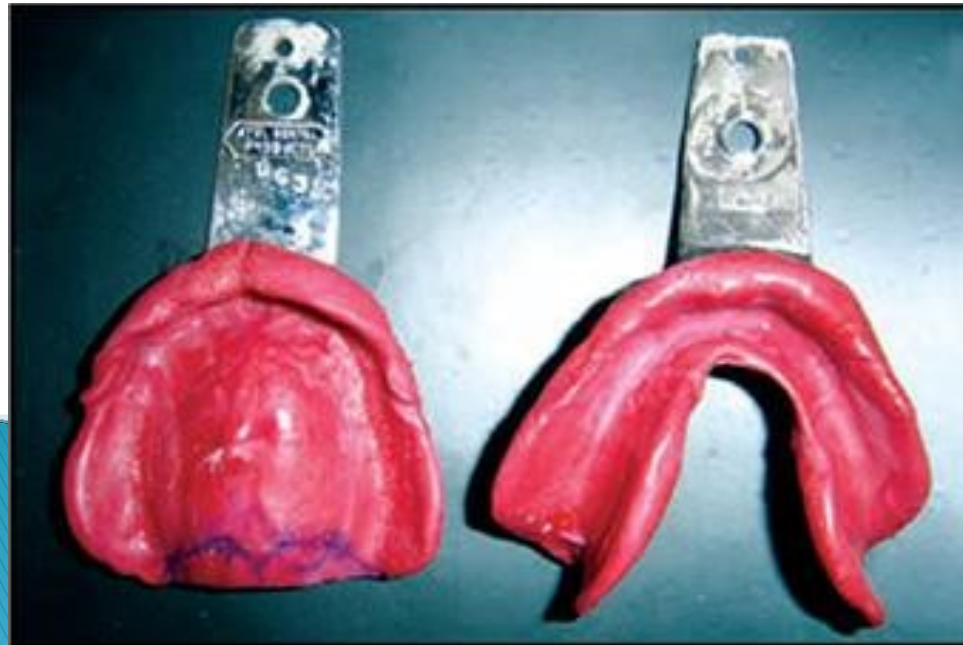The first step is to determine what the condition and the next step is to determine what to do (treatment plane)

Diagnosis is required to take the history from the patient .

The construction of complete denture require five appointment , each appointment of the first four steps require laboratory.

## A- First appointment :

- Clinical procedure** : primary impression (preliminary impression) are made with stock tray.
- Laboratory procedure**: the impression are poured with plaster to produce primary cast (preliminary cast) on which the special tray is constructed .

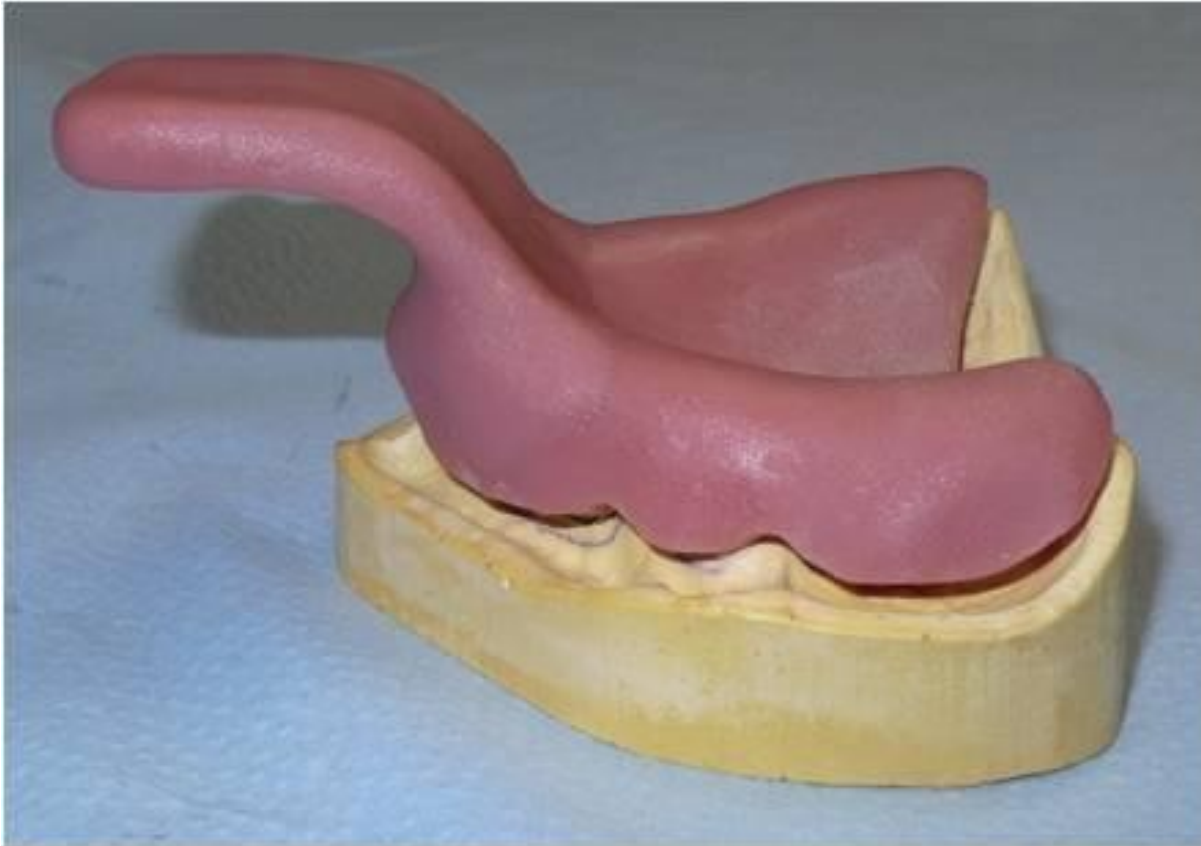

# Primary cast



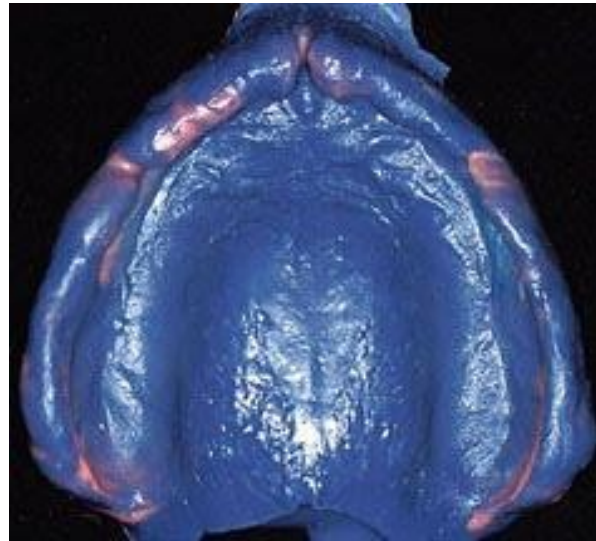


# Special tray

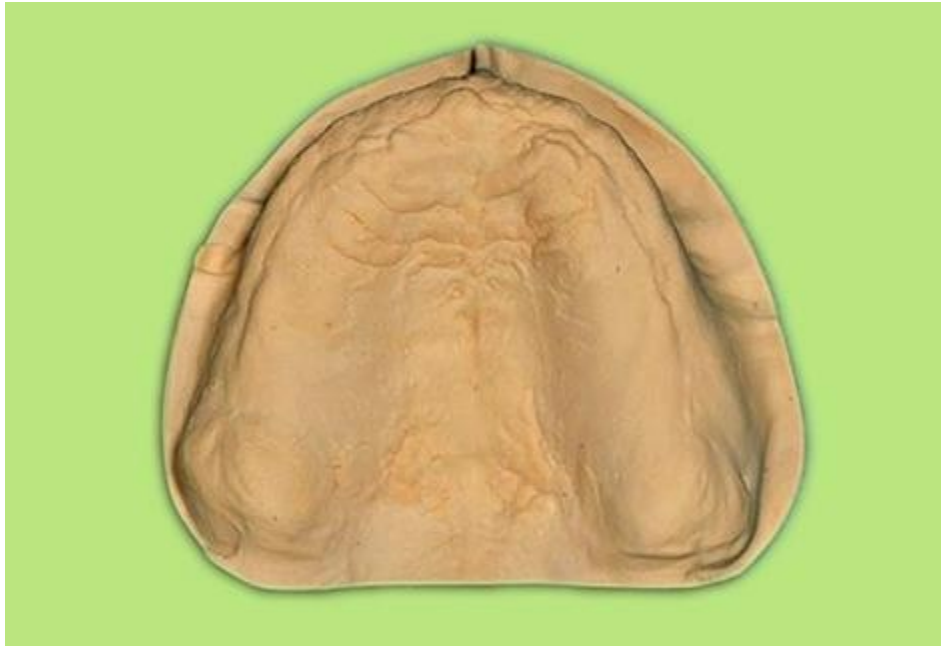

## B- Second appointment:

- Clinical procedure:** secondary or final impression are made .
- Laboratory procedure:** the final impression are poured, then base plate and occlusal rim are constructed .

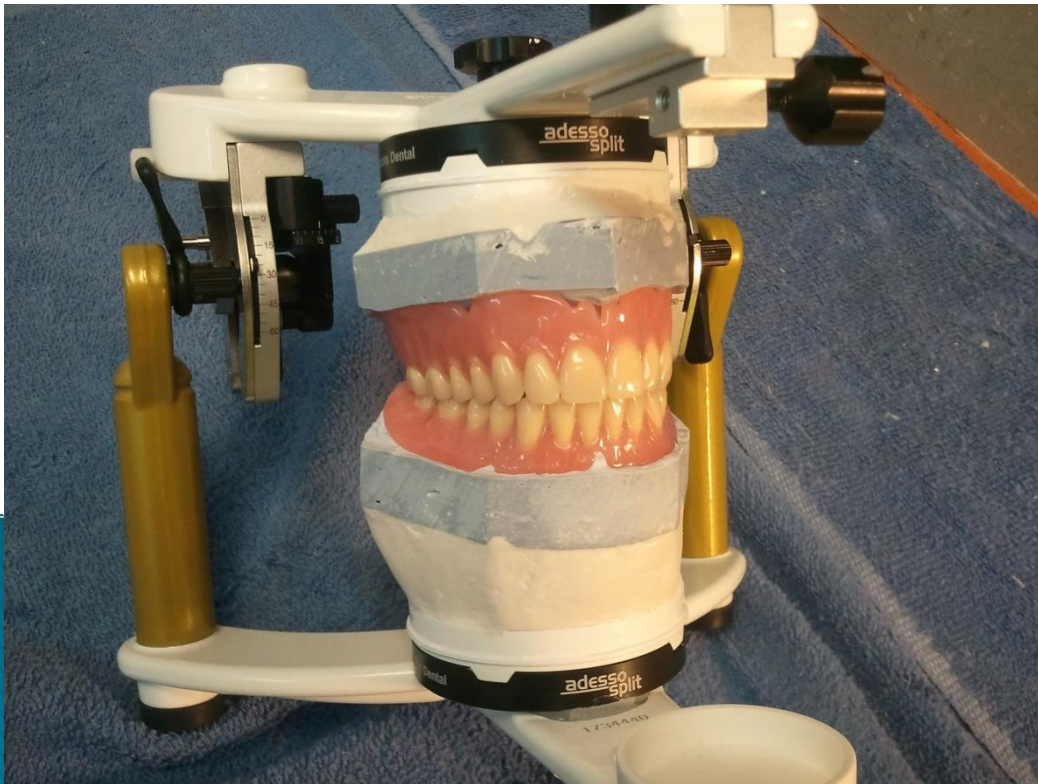

# Final cast




### C- Third appointment:

- Clinical procedure:** vertical dimension is determined and centric relation is taken.
- Laboratory procedure:** the cast are mounted on articulator and the tooth are arranged on the bite rim.





### **D- Fourth appointment:**

- Clinical procedure:** (trial stage) the dentist tries the denture and check for proper placement and arrangement of teeth, appearance and speech.
  - Laboratory procedure:** flasking, packing, finishing and polishing .
- 

E- Fifth appointment: the denture is delivered to the patient, it may require adjustment of the denture.



Any Question ? ●

# Primary Impression for complete denture

# Primary impression

- It is an impression made for the purpose of diagnosis, treatment planning and construction of special tray. It is the first impression made for the patient and from which the study cast was produced. These impressions are obtained by a stock tray.

- When the primary impression is made, the objectives are to record all areas to be covered by the impression surface of the denture and the adjacent landmarks with an impression material that is accurate.

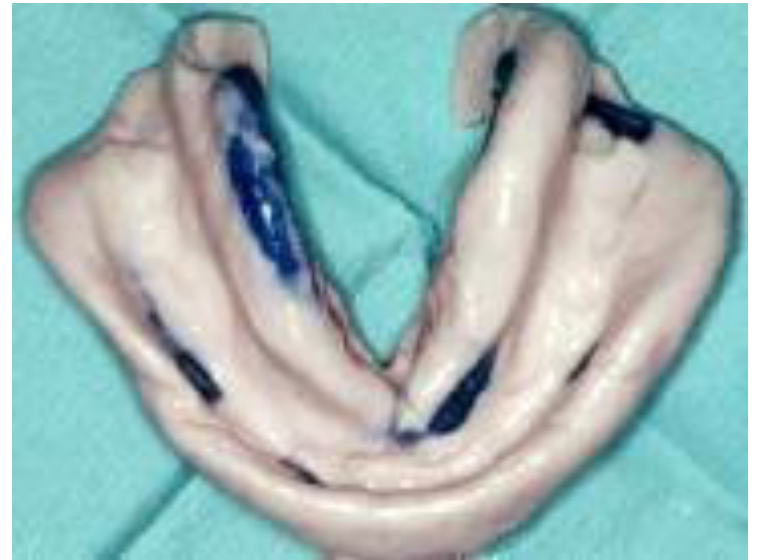
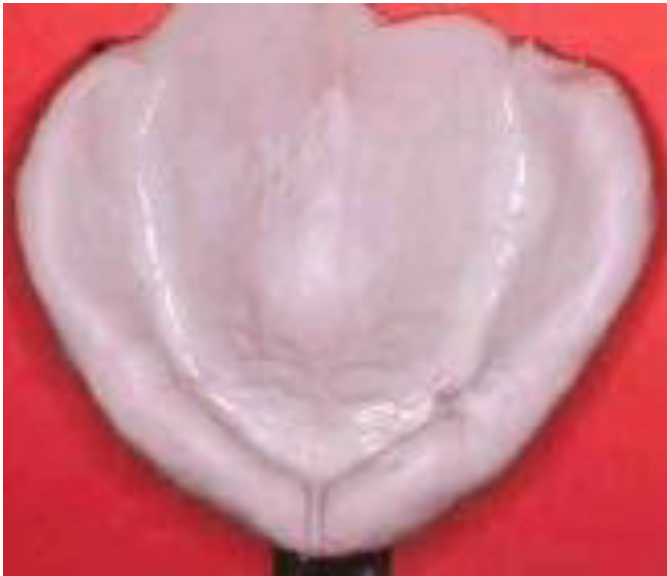- The maxillary impression should include the hamular notches, fovea palatina, frenum attachments, palate, and the entire labial and buccal vestibules.
- The mandibular impression should include the retromolar pad, the buccal shelf areas, the external oblique ridges, frenum attachments, sublingual space, retromylohyoid space, and the entire labial and buccal vestibules

# Materials used for primary impression

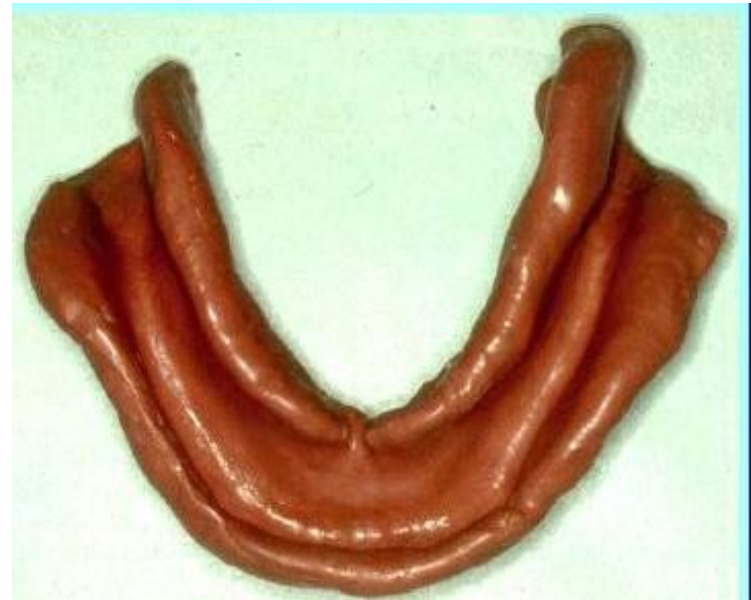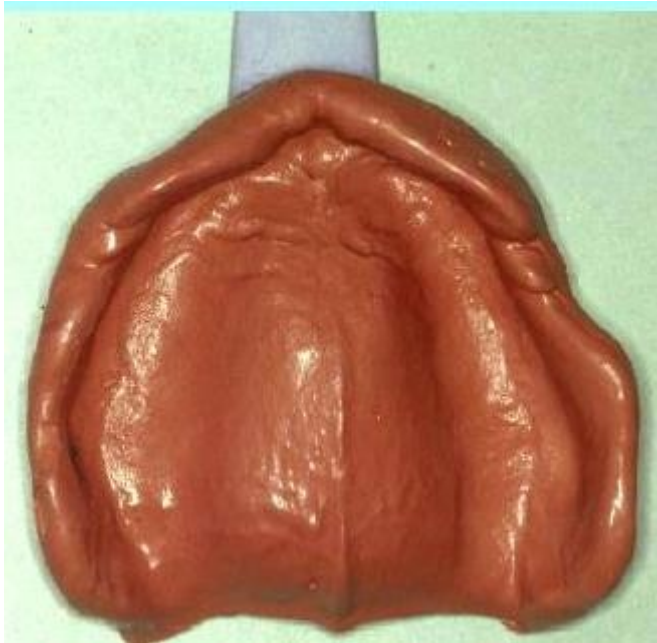- Impression compound
- Alginate
- Putty body



# alginate



# Impression compound



In complete denture prosthesis, we make two impressions for the patient:

- Primary impression
- Final impression

>>>>To make an impression we should have a suitable tray and impression material.

# Tray

- It is a device that is used to carry, confine and control the impression material while making an impression.
- Use of tray :
  - >>>>During the impression making, the tray facilitates insertion and removal of the impression material from the patient's mouth.

# Parts of the tray

- Body
- >>floor
- >>flange
- Handle



- There is upper tray and lower tray, the difference between them is that, in the upper tray, there is a palatal portion that called (**vault**), and in the lower tray, there is a (**lingual flange**).



# In general there are two types of tray

- Stock tray
- Special ( custom tray)

# Stock tray

- It is an impression tray serves to carry the impression material to the mouth and support it in the correct position while it is hardening. This type of trays can be used for making primary impression. It makes from different materials such as Aluminum, Tin, Brass or plastic, in variety of shapes, sizes to fit different mouth.





Types of stock tray:

1-stock tray for edentulous

2- stock tray for dentulous

There are Difference between them:

| Stock tray for edentulous 1. 2. 3 | Stock tray for dentulous |
|-----------------------------------|--------------------------|
| Short flanges                     | Long flanges. 1.         |
| Oval and narrow floor             | Flat and wide floor      |

# Stock tray edentulous stock trat dentulous



# Classification of stock tray according to material used:

- **Perforated stock tray:** used with alginate impression material
- **Non perforated stock tray:** used with sticky impression material like impression compound



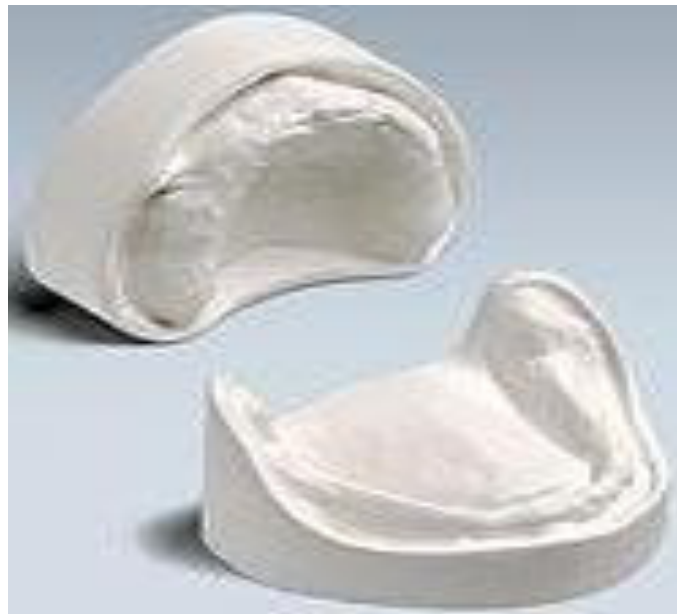# Factors affect selection of stock tray

- **Type of material used** : The type of material used in the primary impression procedure, like impression compound we used non-perforated tray, because it will be stick on the tray. And if we use alginate material we should use perforated stock tray for mechanical retention of impression material to the tray surface
- **Size of arch** : stock tray comes in different sizes.
- **Form of arch**: (ovoid, square, V-shaped).

- The stock tray must cover all the anatomical landmarks needed in complete denture and give a sufficient space (***4-5 mm***) ***for the impression material in all directions.***

# Primary cast

- The *primary cast is produced by pouring the primary impression with plaster which is the positive reproduction of the oral tissues.*



# Mtethod of mixing

- The plaster mixed with water by the saturation method in the rubber bowl and pour in the impression compound impression material after beading and boxing of the impression. When the plaster becomes hard, the cast is separated from the impression by the use of hot water (***55-60°C***).

- When using very hot water, the impression compound will be sticky and it will be difficult to remove from the cast. The special tray, which is used to make the final impression, will be constructed on the primary cast.



# Final Impression for complete denture

# Final impression

- It is an impression made for the purpose of fabrication of prosthesis. This impression is made with individual tray.
- Final impression must be poured with ***stone material to produce the master cast.***



# Materials used for final impression

- 1- Zinc Oxide Eugenol impression material.
- 2- Alginate impression material.
- 3- Elastomers impression materials (Rubber base).
- 4- Impression plaster.

- Irrespective of which material is selected, the optimum result will be achieved only if the custom tray has been constructed and refined correctly.

- After construction of the special tray, it is tried in the patient mouth and checked for proper extension and adaptation on the residual ridge, the special tray is a primary factor in obtaining a good working impression

# The technique used for taking final impression

- The basic differences in techniques for final impressions can be resolved as those that record the soft tissues in a:
- Functional position (Closed mouth technique, Pressure technique)
- Rest position

# Rest position

- Non pressure technique (Passive technique, Mucostatic technique).
- Selective pressure technique

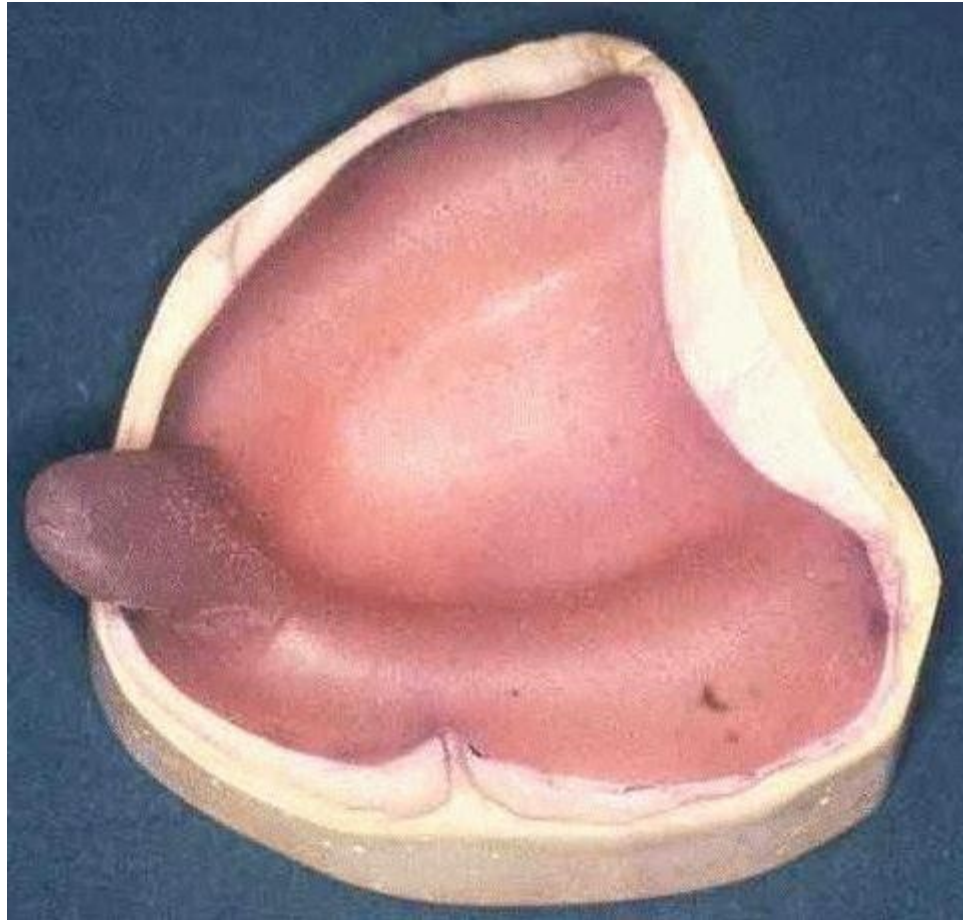


# Special tray (individual or custom tray)

- It is defined as a custom made device prepared for a particular patient which is used to confine and control an impression material making an impression. An individualized impression tray makes on the cast obtained from primary impression.

- It is used in making the final impression. On the primary cast (study cast), special tray is constructed because edentulous ridge shows variations in shape and size, some have flattened ridges and other have bulky ridge, and the stock tray can fit the ridge only in an arbitrary manner.

# Special tray




# Advantages of special tray

- Economy in impression material (less impression material required in special tray).
- More accurate impression.
- Special tray provides even thickness of impression material. This minimizes tissue displacement and dimensional changes of impression material

- The work with special tray is easier and quicker than modifying stock tray to provide accurate impression
- Special tray is more accurately adapted to the oral vestibules this helps in better retention of the denture.
- Special tray is less bulky than stock tray which is more comfortable for the patient

# Materials used for construction of special tray

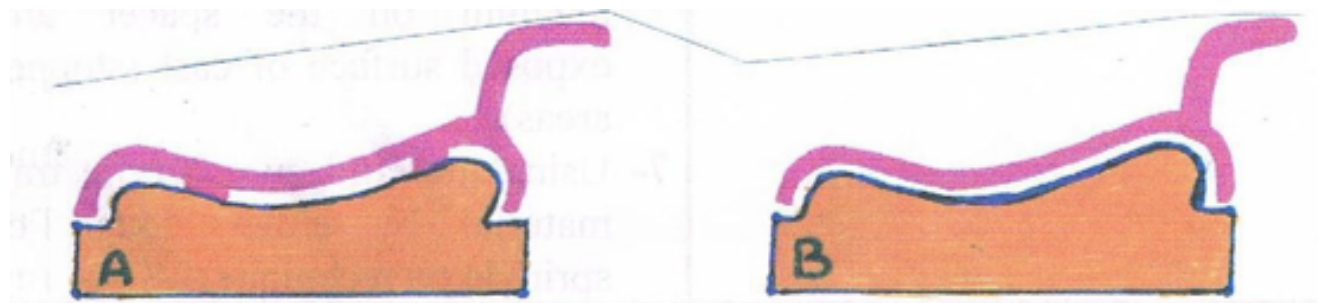
- Cold and heat cured acrylic.
- Light cured resin.
- Impression compound (higher fusing tray compound).



# Types of special tray


- *Spaced special tray (with or without stoppers).*
- *Closed fit special tray.*





*Figure (3-8): Spaced special tray. (A) With stopper. (B) Without stopper.*

*Figure (3-9): Closed fit special tray.*



# Fabrication of special tray

- The cast should be soaked in water.
- Severe undercuts should be blocked out using wax.
- The borders of the special tray and the relief areas should be marked.
- The borders of the tray marked on the cast are grooved deeper using a carver, this act as guide to trim the tray later.

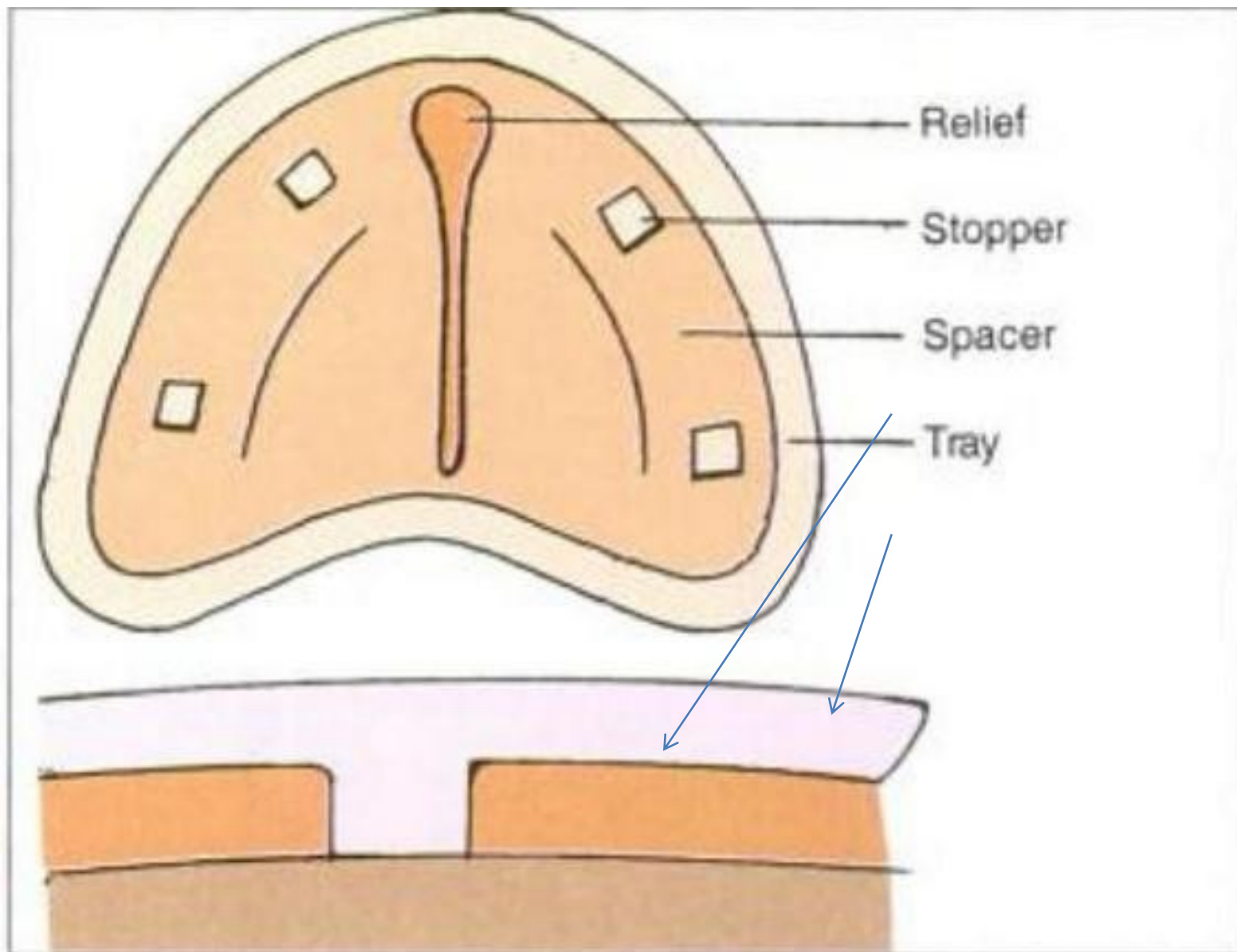
## For closed fit>>>>

- Application of separating medium on study cast.
- Using the cold cure acrylic tray material by dough technique

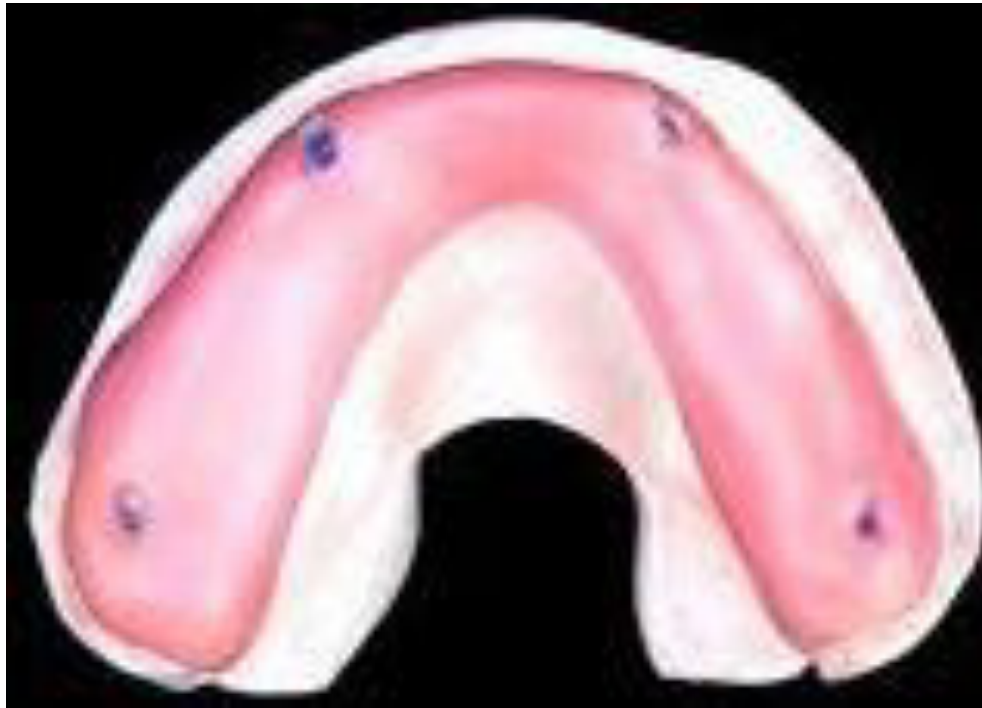# For spaced>>>

- Adapting the wax spacer, should be about 2 mm thick, the posterior palatal seal area on the cast is not covered with the wax spacer.
- Spacer should be cut out in 2-4 mm places so that the special tray touches the ridge in this area. This is done to stabilize the tray during impression making.
- The part of the special tray that extends into the cut out of the spacer is called stopper, usually 4 stoppers are placed, 2 on the canine eminence and 2 in molar region on either side.

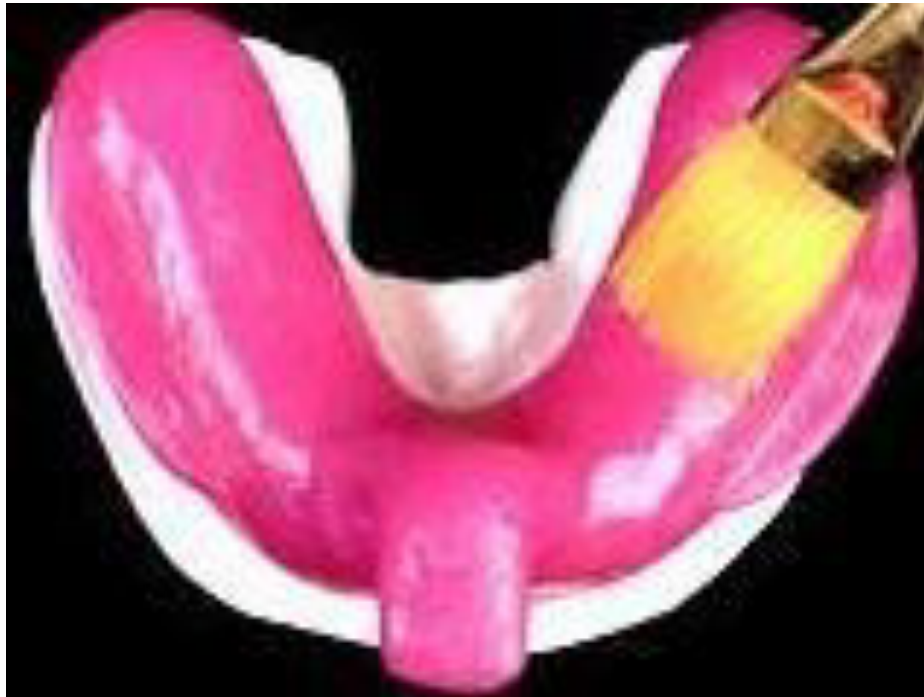- **Application of separating medium on the spacer and exposed surface of cast (stopper areas).**
- **Using the cold cure acrylic tray material by either dough or sprinkle on technique.**
- **When the special tray is removed from the cast, the wax spacer is left inside the tray to be properly positioned in the mouth during border molding procedure.**



# Wax spacer

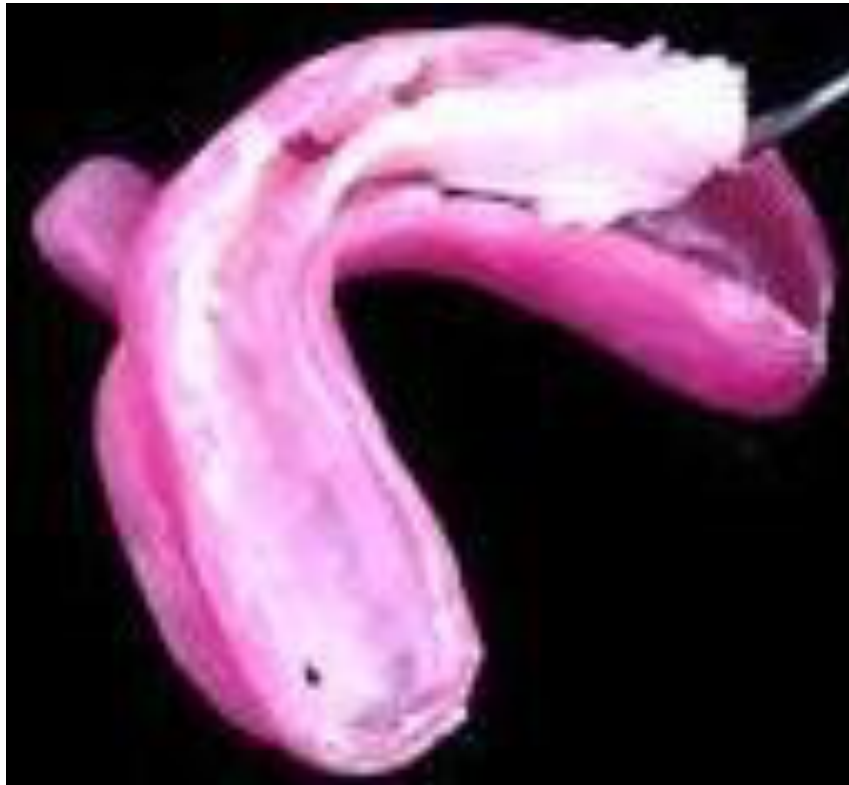

# Spacd special tray





# Removing of wax spacer



## construction Criteria for special tray

- The tray should be rigid and of sufficient even thickness that it will not fracture during its use.
- The special tray must not impinge upon movable structures.
- The borders must be (2 mm) under extended.

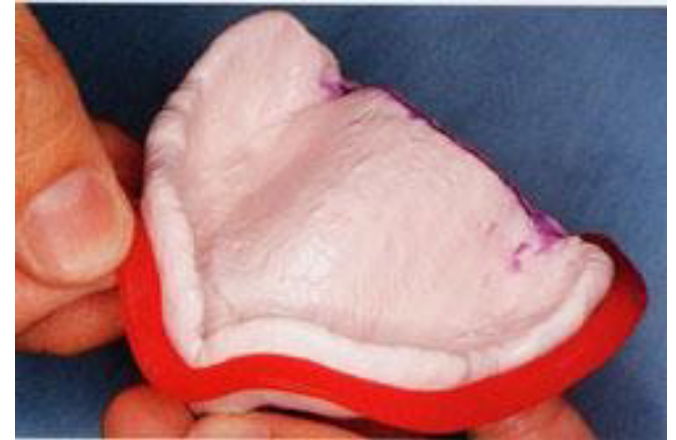- The posterior limits of the impression tray should be slightly over extended to ensure inclusion of the posterior detail for development of the post-dam area in upper tray.
- The tray must have a handle for manipulation, and the handle must not interfere with functional movement of the oral structures.

- The tray must be smooth on its exposed surfaces and should have no sharp corner or edges which would injury the patient.

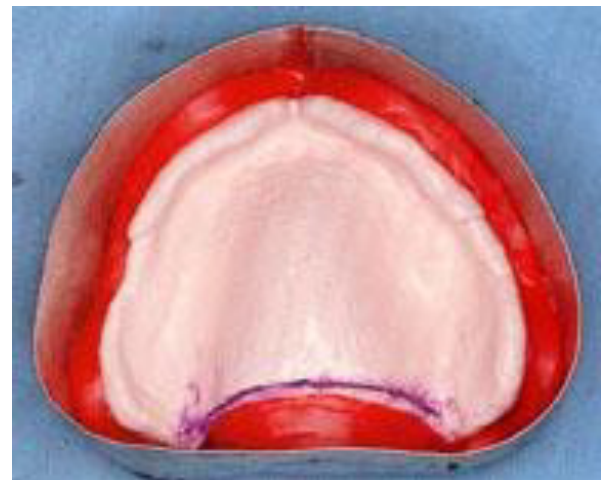
# Beading and boxing impression

Dr. Saraa Almallah

- Beading is done to preserve the width and height of the sulcus in a cast.



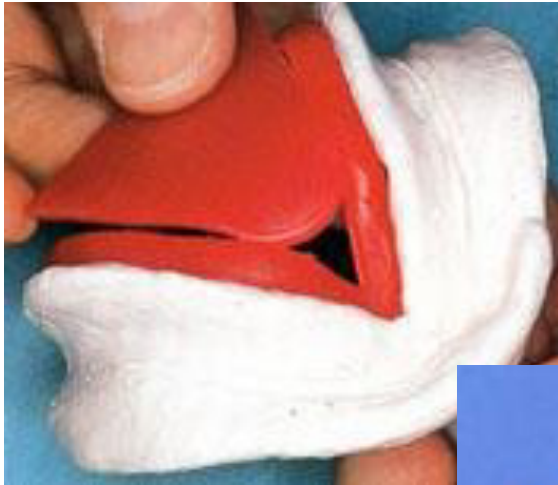Boxing is the enclosing of an impression with a beading wax to produce the desired size and form of the base of the cast.

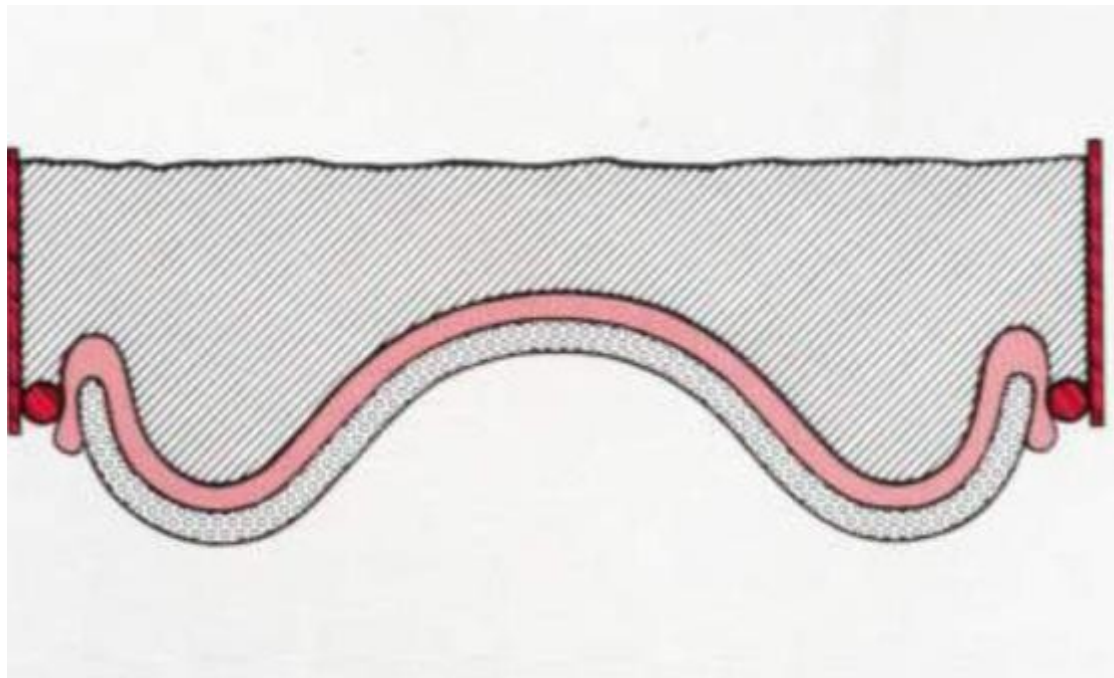


- Boxing impression can be used for primary and final impressions, this procedure cannot usually be used on impression made from hydrocolloid materials (*alginate*) ***because the boxing wax will not adhere to the*** impression material as well as the alginate can be easily distorted

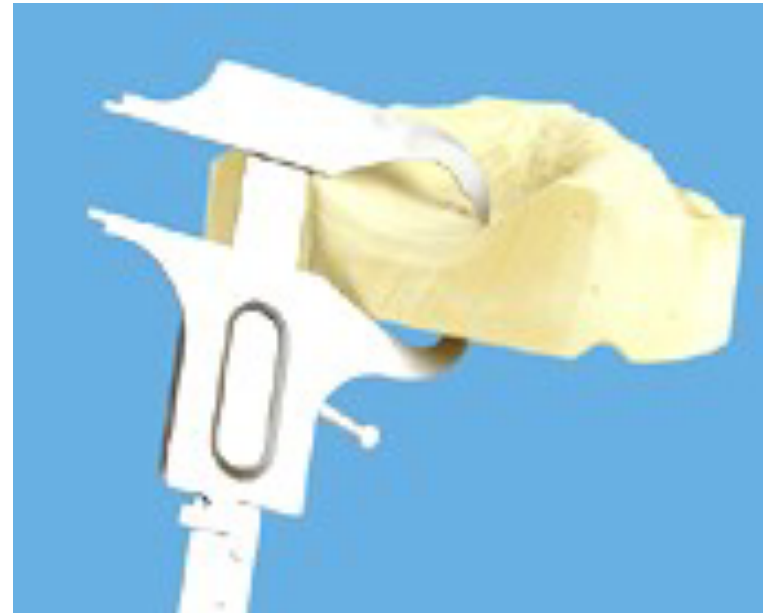
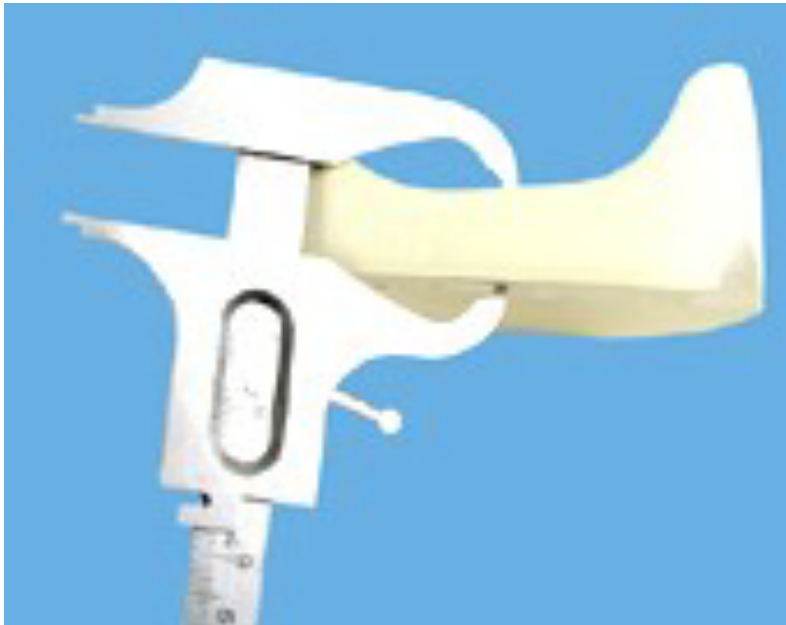
# Beading and boxing mandibular ZOE impression






Note>>>Minimum thickness for the  
base of the cast 11-15 mm



# Materials used for boxing impression

- **1- Beading wax:** a strip of wax is attached all the way around the outside of the impression approximately *(2-3 mm) below the border* and sealed to it with wax knife.



- **2- Boxing wax:** a sheet of wax is used to made the vertical walls of the box
- and it is attached around the outside of the beading wax strip so that it does not alter the borders of the impression, the width of the boxing wax is about ***9-15 mm***.



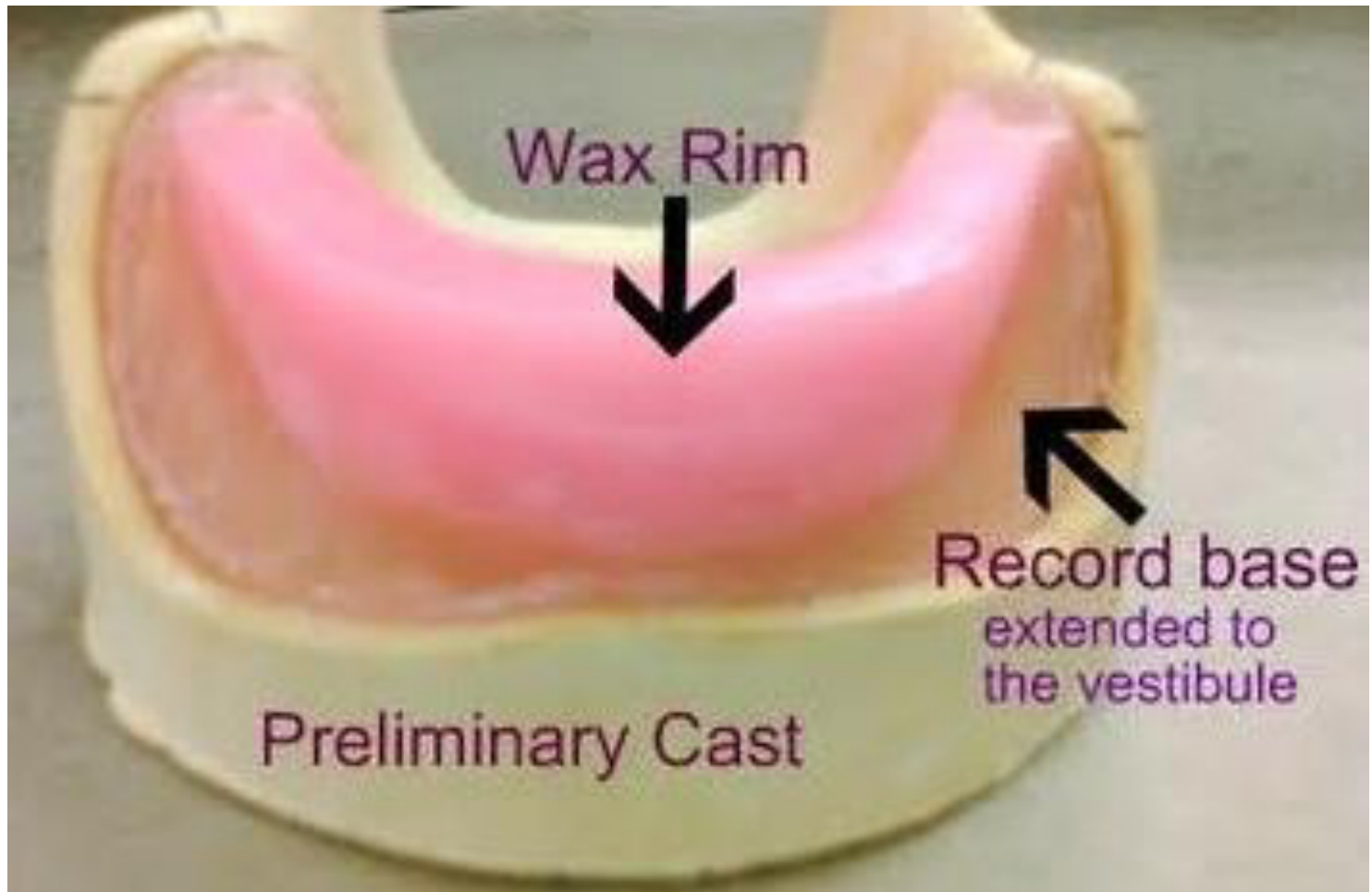
- **3- Base plate wax: a sheet of wax can be used to fill the tongue space in the mandibular impression that is sealed just below the lingual border of the impression.**



# Laboratory Procedures Prior to Jaw Relation Records

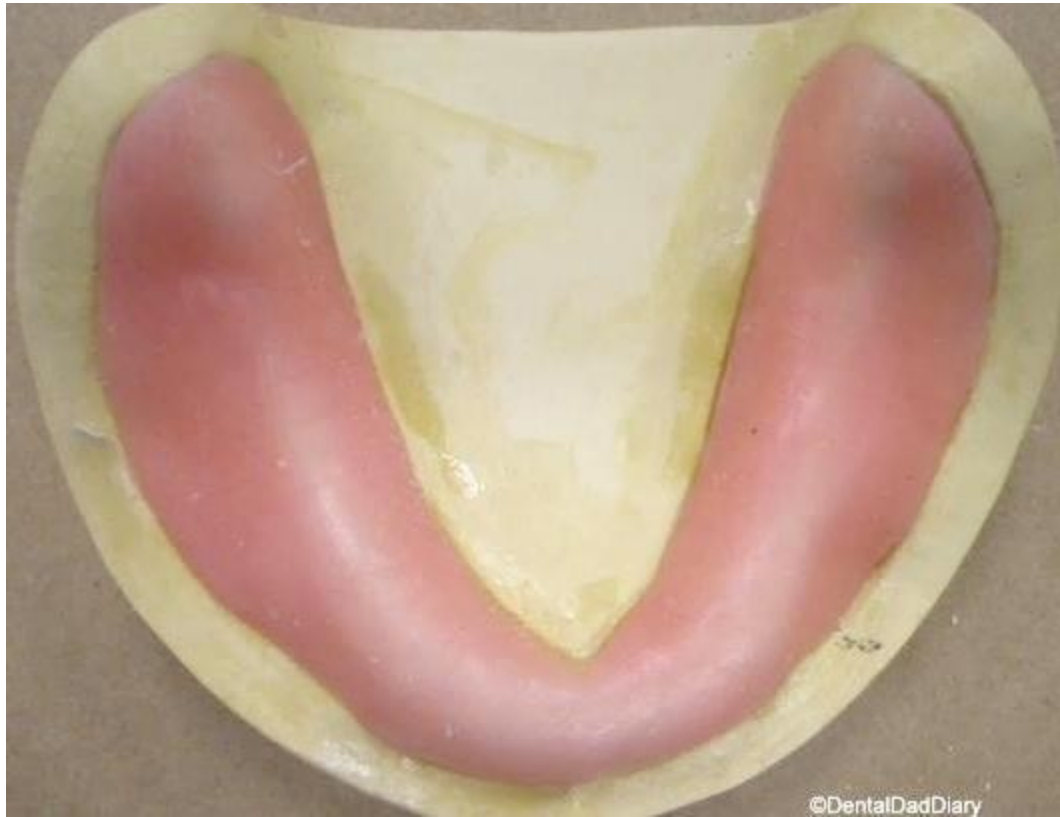## **RECORD BASE •**

- It is a temporary form representing the base of a denture. It is used for making maxillomandibular relation records and for arrangement of artificial teeth. It is also known as base plate, temporary base, trial base.





# Lower record base



# Requirements of record base

- 1-The record base must have rigidity to withstand occlusal loads.
- 2- The record base must have accuracy and stability.
- 3- The extent and the shape of the borders and fitness should resemble a finished denture.

# Requirements of record base

- 4- All surfaces that contact lips, cheek and tongue should be smooth, rounded and polished.
- 5- The crest, labial and/or buccal slopes should be thinned to provide space for teeth arrangement.

# Accuracy of maxilla mandibular relation record affected by:

- 1) Rrigidity.
- 2) Stability.
- 3) Movability of the record bases

# Materials used in construction of record base

- Materials used in construction of record base
  - 1. Shellac record base.
  - 2. Self-curing acrylic resin.
  - 3. Light curing acrylic resin.
  - 4. Thermoplastic resin.

# Methods of recording occlusal vertical dimension

Dr. Saraa Almallah

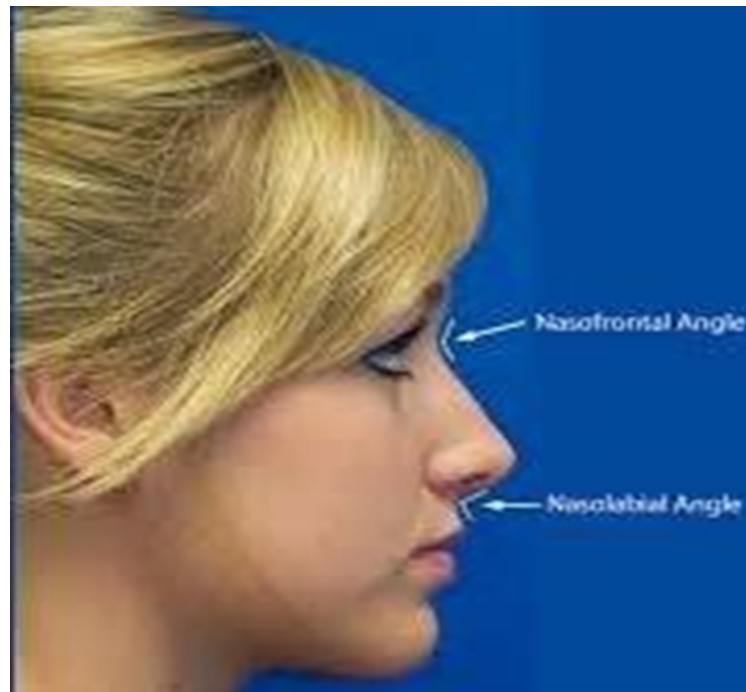# Methods of recording occlusal vertical dimension

- A) pre extraction records
- These records are made before the patient extracts all teeth and loses his occlusal vertical dimension; these records are:

# 1- Profile photographs

They are made and enlarged to life size.

Measurements of anatomic landmarks on the photograph are compared with measurements using the same anatomic landmarks on the face.





- These measurements can be compared when the records are made and again when the artificial teeth are tried in. The photographs should be made with the teeth in **maximum occlusion**, **as** this position can be maintained accurately for photographic procedures.

## 2- Profile silhouettes

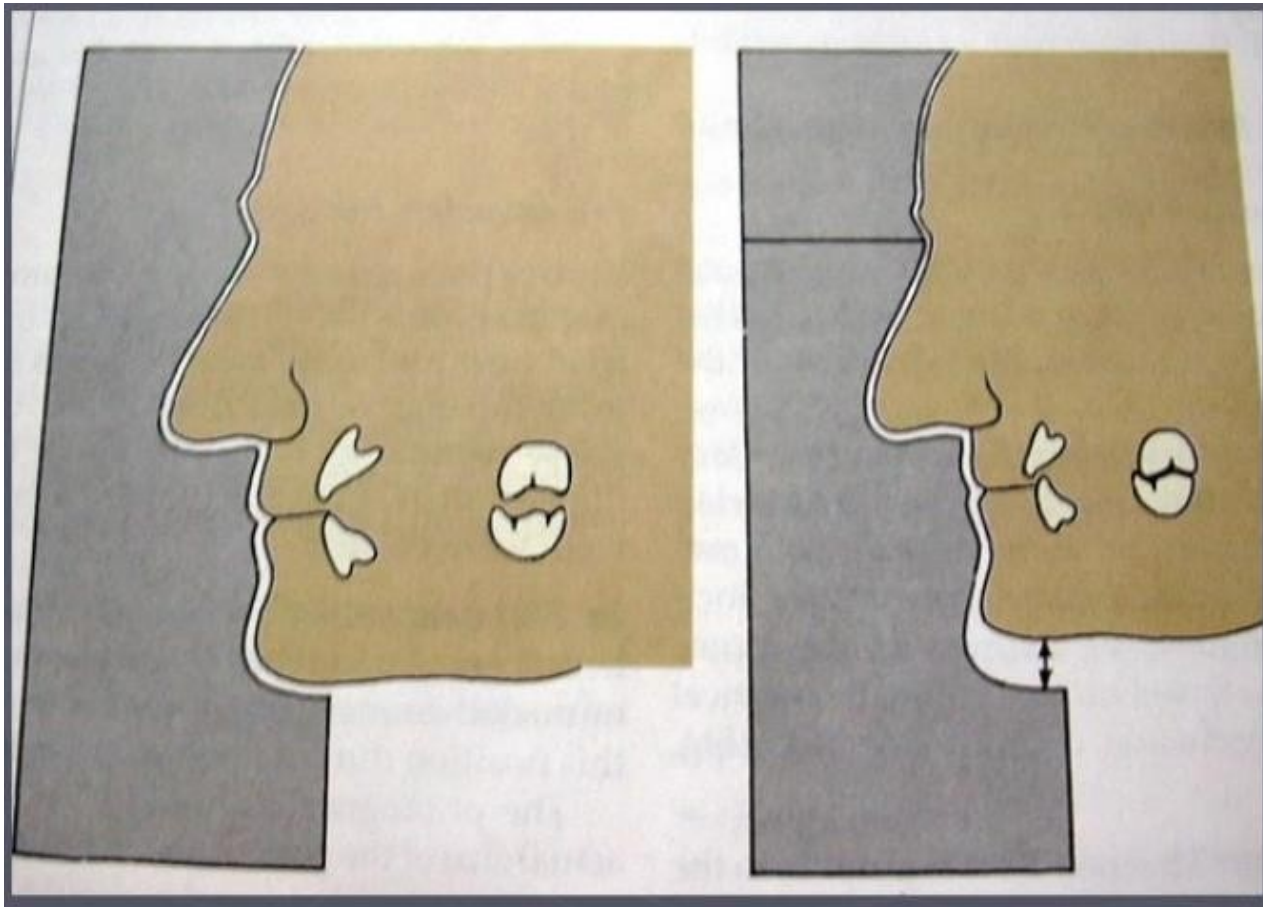
- An accurate reproduction of the profile silhouettes can be cut out in cardboard or contoured in wire. The silhouettes can be repositioned to the face after the vertical dimension has been established at the initial recording and/or when the artificial teeth are tried in.

# Profile silhouettes

**Profile silhouette:  
Cardboard (A); Wire (B).**



# Silhouette repositioned to the face



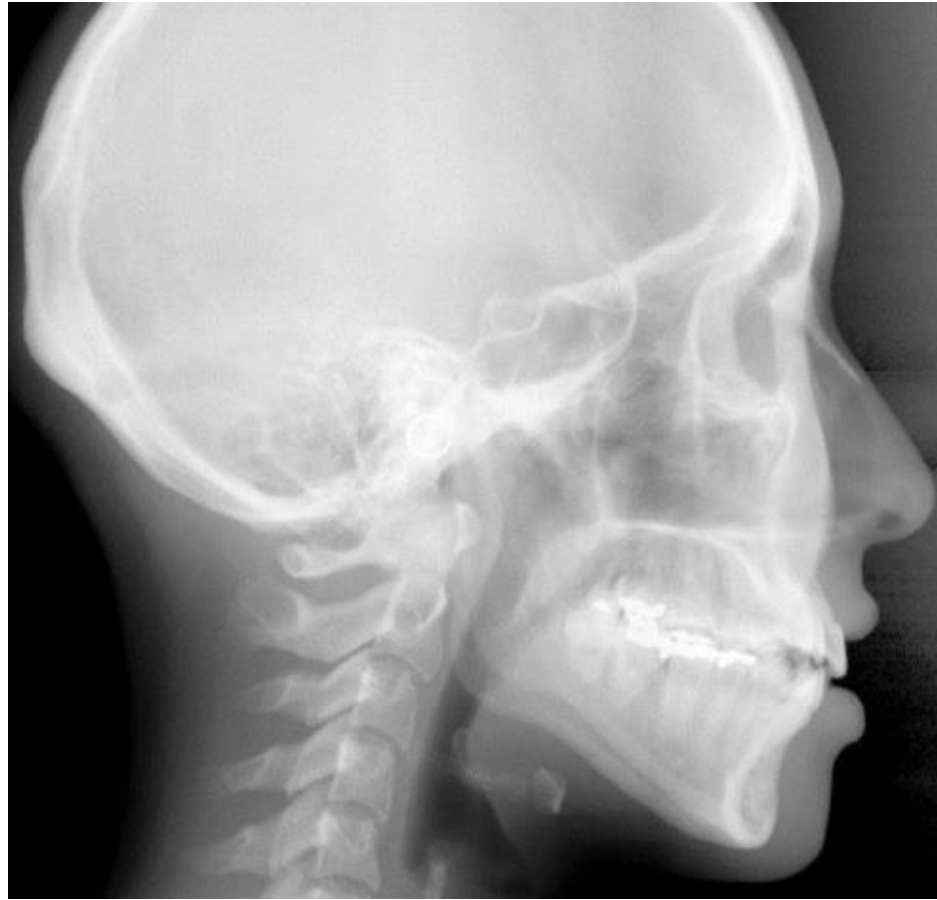### 3. Profile radiographs

- They have been much used in **researches** of vertical dimension of occlusion rather than routine clinical use in prosthodontic treatment for dentulous patients.

.The two types of radiographs advocated are the cephalometric profile radiograph and radiograph of the condyles in the fossae.

The inaccuracies that exist in either the technique or the method of comparing measurements make this method unreliable.

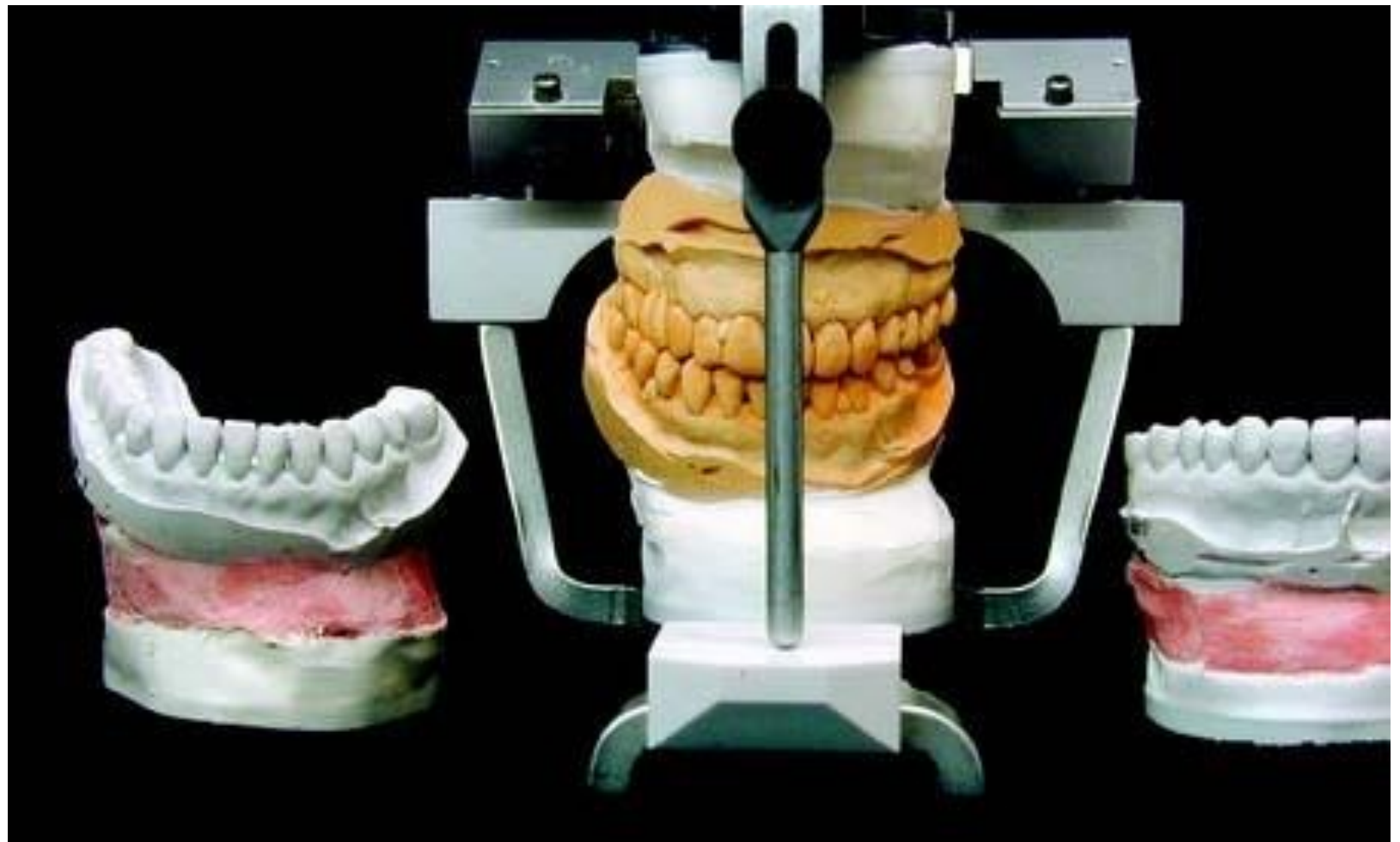
# cephalometric profile radiograph



## 4- Articulated casts

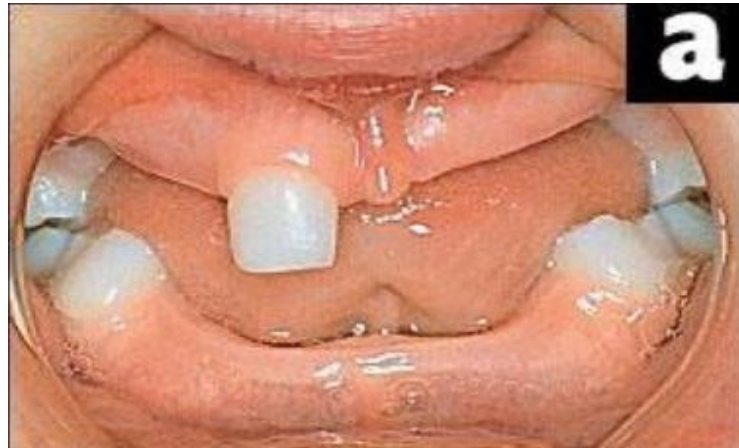- When the patient is dentulous, an accurate casts of the maxillary and mandibular arches have been made, the maxillary cast is related in its correct anatomic position on the articulator with a face-bow transfer.





- An occlusal record with the jaws in centric relation is used to mount the mandibular cast.
- After the teeth have been removed and edentulous casts have been mounted on the articulator, the interarch measurements are compared.
- Generally, the edentulous ridges will be parallel to one another at the correct vertical dimension of occlusion.

- This method is valuable with patients whose ridges are not sacrificed during the removal of the teeth or resorbed during a long waiting period for denture construction.

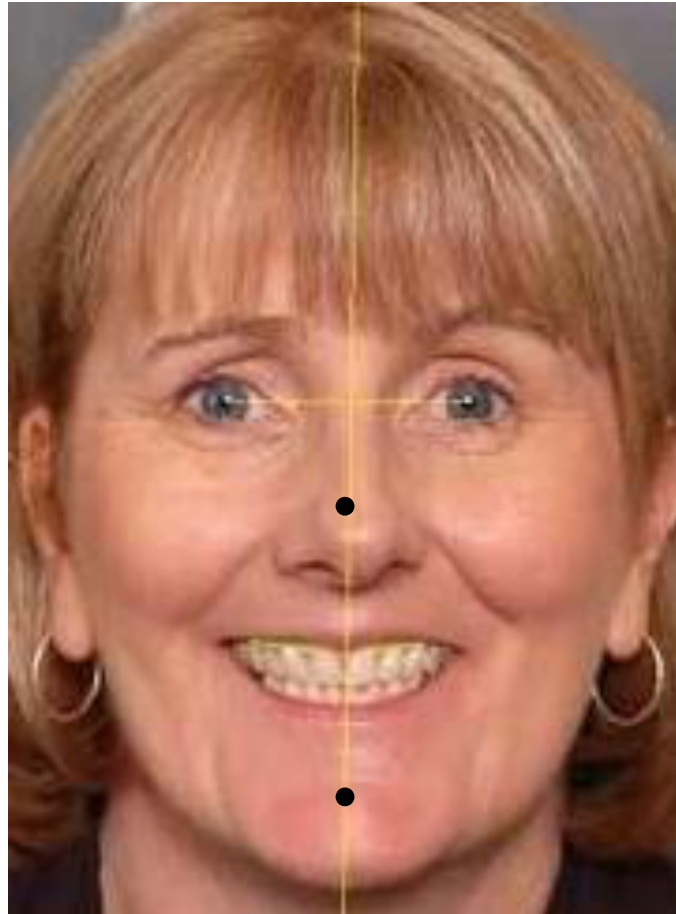

## 5. Facial measurements

- Before extraction, the patient is instructed to close the jaws into maximum occlusion, then two tattoo points have been marked, one on the upper half of the face and the other on the lower half.

- The distance is measured, after extraction these measurements are compared with measurements made between these points when the artificial teeth are tried in.

# *Facial measurements (tattoo).*

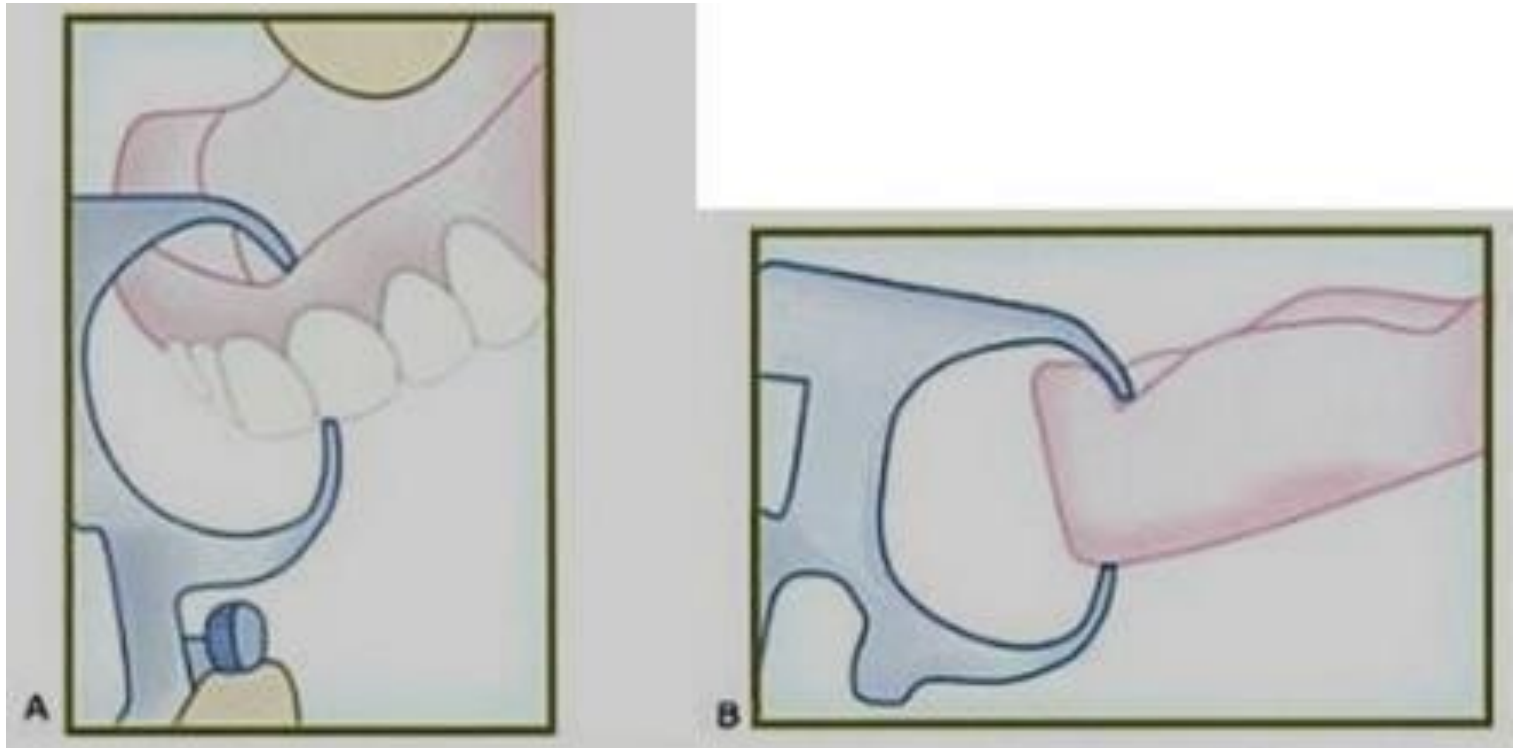


## Measurements from former dentures

- Dentures that the patient has been wearing can be measured, and measurements can be correlated with observations of the patient's face to determine the amount of change required. These measurements are made between the ridge crests in the maxillary and mandibular dentures with a *Boley gauge*.

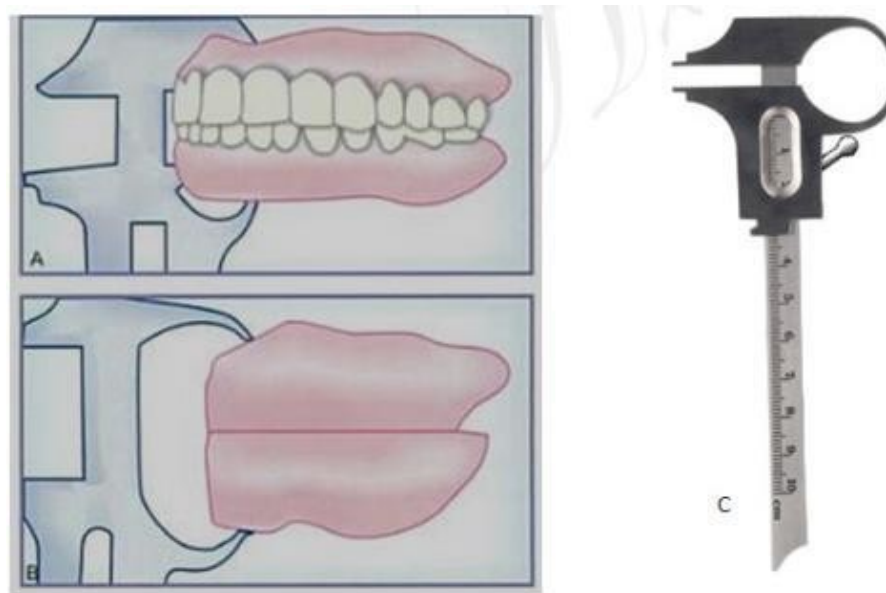
**Distance from the incisive papilla to the incisal edge is measured and compared to the maxillary occlusion rim**

**(A) Old denture (B) Occlusion rim.**





**Distance from the incisive papilla to the mandibular alveolar ridge is measured and compared to the vertical distance of that of the upper and lower occlusion rims (A) Old denture (B) Occlusion rim (C) Boley gauge.**



Vertical dimension

# Without pre extraction methods:

- **A - Direct methods to find occlusal vertical dimension**

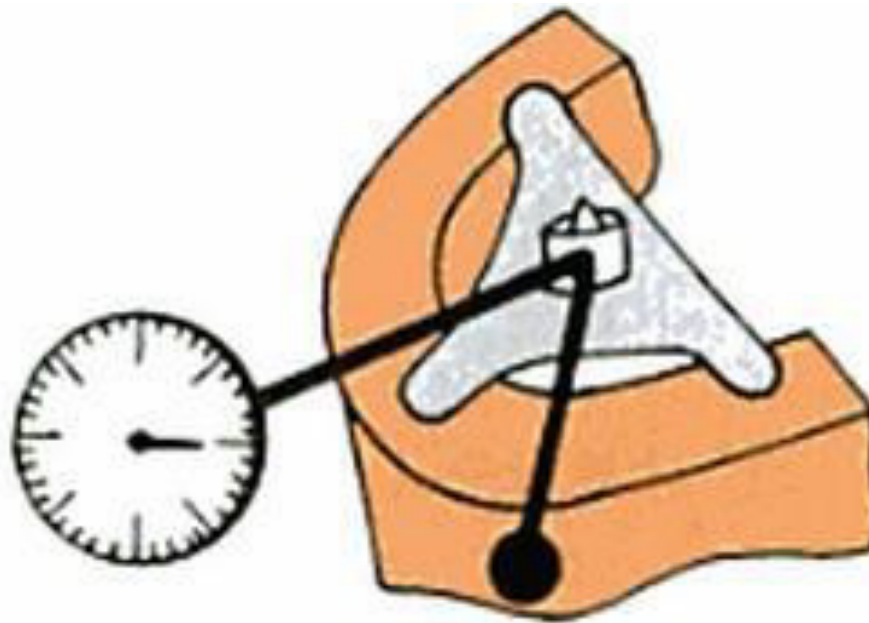# 1- Boos power point method

- A metal plate (*central bearing plate*) is attached to the maxillary record base. A bimeter (*an oral meter that measures pressure*) is attached to the mandibular record base.

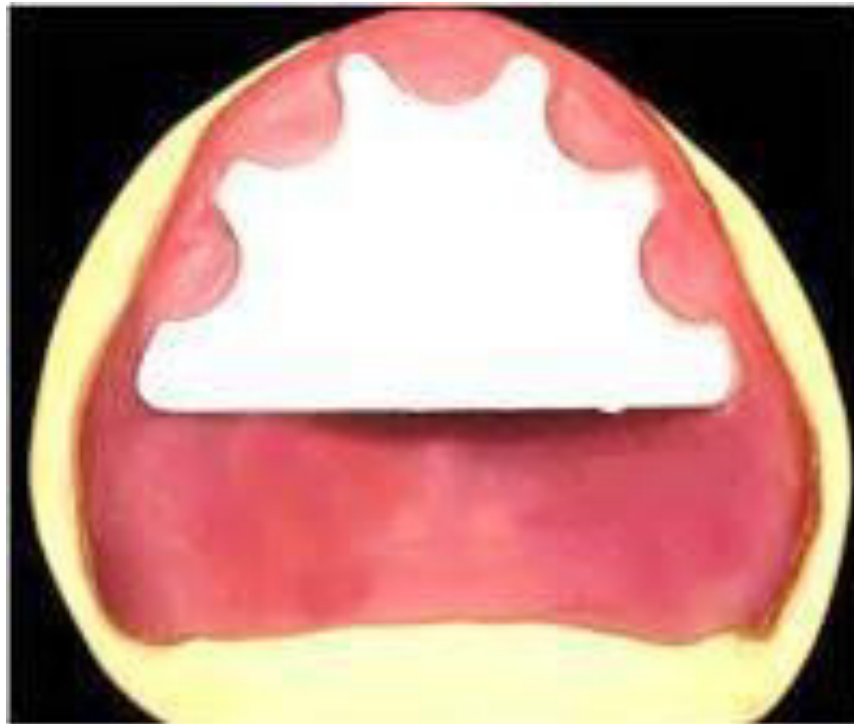
- This bimeter has a dial, which shows the amount of pressure acting on it. The record bases are inserted into the patient's mouth and the patient is asked to bite on the record bases at different degrees of jaw separation.

- The biting forces are transferred from the central bearing point to the bimeter. The highest value is called the power point which represents the occlusal vertical dimension.

# *Boos power point method*



# *Central bearing plate.*

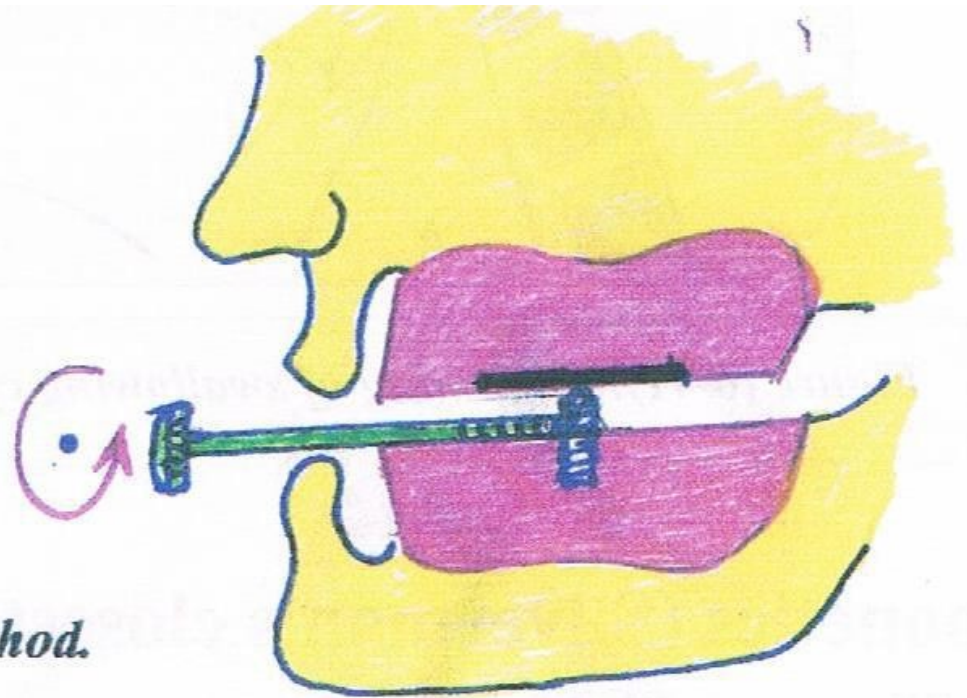




## 2-Tactile sense

- A central bearing screw/central bearing plate apparatus is used and attached to accurately adapt record bases permits the patient to experience through neuromuscular perception the different vertical relations.

- The central bearing screw is adjusted downward and upward until the height of contact feels right to the patient and this represents the occlusal vertical dimension.



*Figure (6-39): Tactile sense method.*

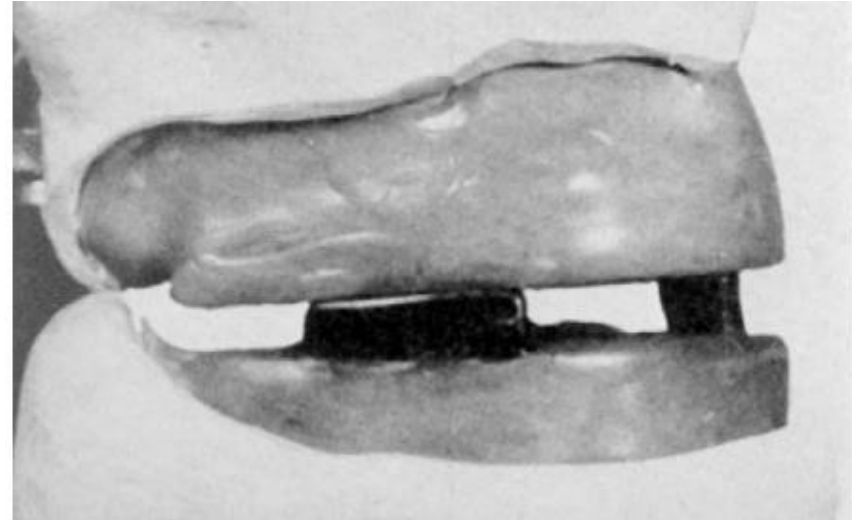

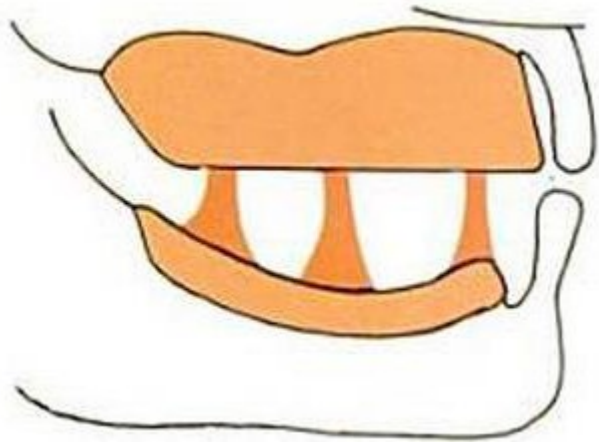
### 3- Swallowing threshold

- The theory behind this method is that at the beginning of swallowing cycle, the teeth of the upper and lower jaws almost come together with a very light contact. This factor can be used as a guide to determine the occlusal vertical dimension

- The technique involves fabrication of cones of soft wax on the mandibular record base. The maxillary and mandibular record bases are inserted in the patient mouth. Salivation is stimulated and the patient is asked to swallow.

- The repeated action of swallowing the saliva will gradually reduce the height of the wax cones to allow the mandible to reach the level of occlusal vertical dimension.

# Swallowing threshold



## 4- Phonetics

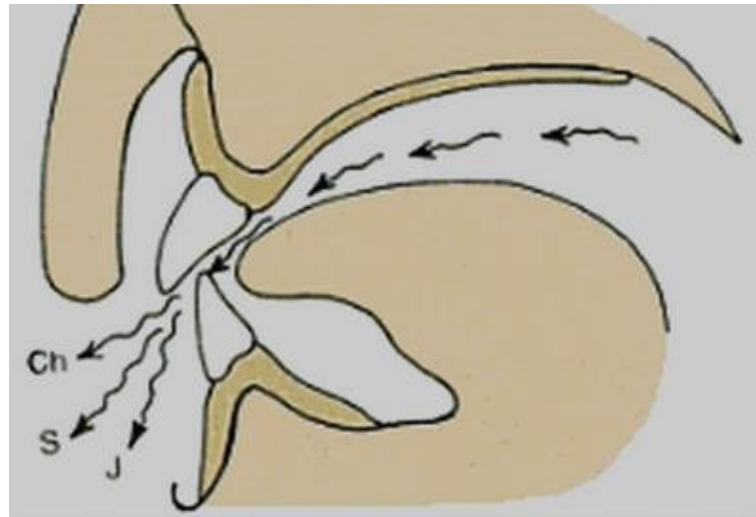
- *By: Silverman M. Meyer Silverman's closest speaking space:* It is the minimal amount of interocclusal space between the upper and lower teeth when sounds like *ch*, *s*, and *j* are pronounced. There is *1-2 mm* clearance between teeth when observed from the profile and frontal view.



- Phonetic tests of the vertical dimension include listening to speech sound production and observing the relationships of teeth during speech. The production of *ch*, *s*, and *j* sounds brings the anterior teeth closest together without contact.

- If the distance is too large, it means that too small a vertical dimension of occlusion may have been established.
- If the anterior teeth touch when these sounds are made, the vertical dimension is probably too great.

# *Silverman's closest speaking space.*



B-Indirect methods to find occlusal  
vertical dimension (methods of  
recording **rest** vertical dimension)

## 1- Facial measurements

- Instruct the patient to stand or sit comfortably upright with eyes looking straight ahead at some object which is on the same level. Insert the maxillary record base with the attached contoured occlusion rim.

- With an indelible marker, place a point of reference on the end of the patient's nose and another on the point of the chin. The patient is asked to perform functional movements like wetting his lips and swallowing, and to relax his shoulders (this is done to relax the supra- and infrahyoid muscles).


- When the mandible drops to the rest position, the distance between the points of reference is measured. Repeat this procedure until the measurements are consistent. Such measurements are helpful but cannot be considered as absolute.

## 2- Tactile sense

- Instruct the patient to stand or sit erect and open the jaws wide until strain is felt in the muscles. When this opening becomes uncomfortable, ask them to close slowly until the jaws reach a comfortable, relaxed position. Measure the distance between the points of reference.



# *Tactile sense.*




### 3- Phonetics

- Ask the patient to repeat pronounce the letter m a certain numbers of times, like repeat the name *Emma* until they are aware of the contacting of the lips as the first syllabus *em* is pronounced.

- When patient have rehearsed this procedure, ask that they stop all jaw movement when the lips touch. At this time measure between the two points of reference.


***/m/ sound***



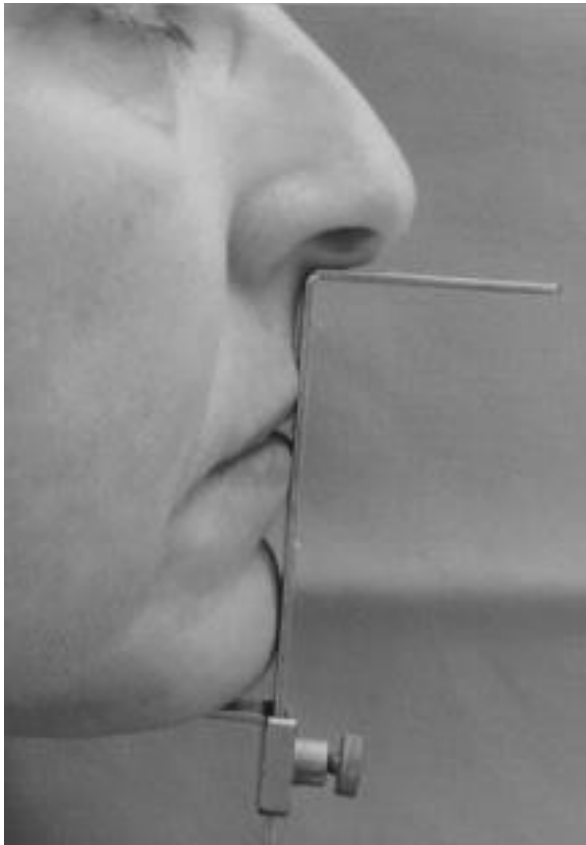
## 4- Anatomical landmarks (Willis method)

- The Willis guide is designed to measure the distance from the pupils of the eyes to the corner of the mouth and the distance from the anterior nasal spine to the lower border of the mandible. When these measurements are equal, the jaws are considered at rest. Its accuracy is questionable in patients with facial asymmetry.

# *Anatomical landmarks*



***Willis method and Boley gauge used  
to measure the distance recorded by  
Willis gauge.***

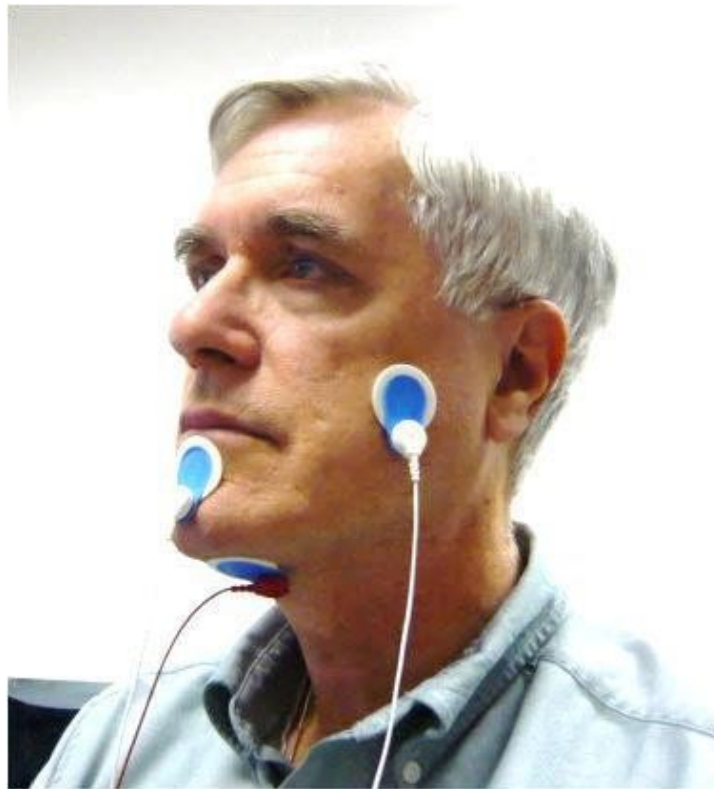

## 5- Electromyographic method (EMG)

- By using a special device that measures the tone of masticatory muscles, when the tone is at its least, this means these muscles are in rest position and the jaws are at rest position.



# ***EMG.***



# Centric Relation

**Dr. Saraa Almallah**

## Horizontal jaw relations:

- The relationship of mandible to maxilla in a horizontal plane (in anteroposterior and side to side direction).

# The horizontal relation include:

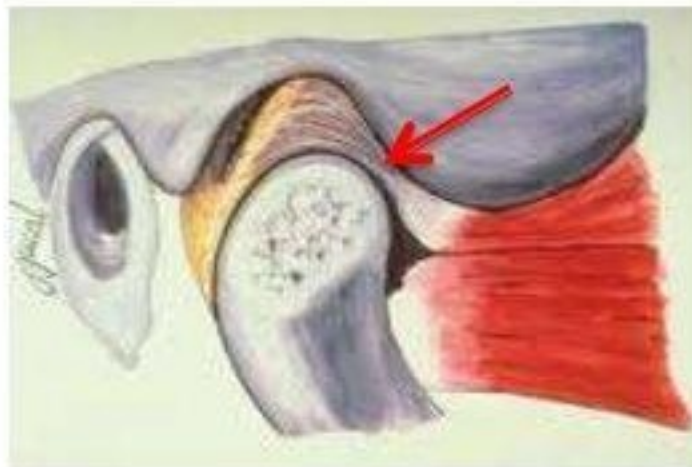
- Centric jaw relation
- Eccentric jaw relation:
  - **A Protruded or forward relation.**
  - **B Lateral relation (Left or right).**
  - **C Retruded positions.**

## Centric jaw relation:

- It is the maxillomandibular relationship in which the both condyles articulate with the thinnest avascular portion of their respective disks with the complex in the anterior-superior position against the shapes of the articular eminencies. This position is independent of tooth contact.
- *(it is bone-to-bone relationship).*

## ► Centric Relation

The **maxillomandibular relationship** in which the condyles articulate with the **thinnest avascular portion (non innervated)** of their respective disks with the complex in the **anterior-superior** position against the shapes of the articular eminencies. This position is independent of tooth contact. It is restricted to **a purely rotary movement** about the transverse horizontal axis



# Centric occlusion:

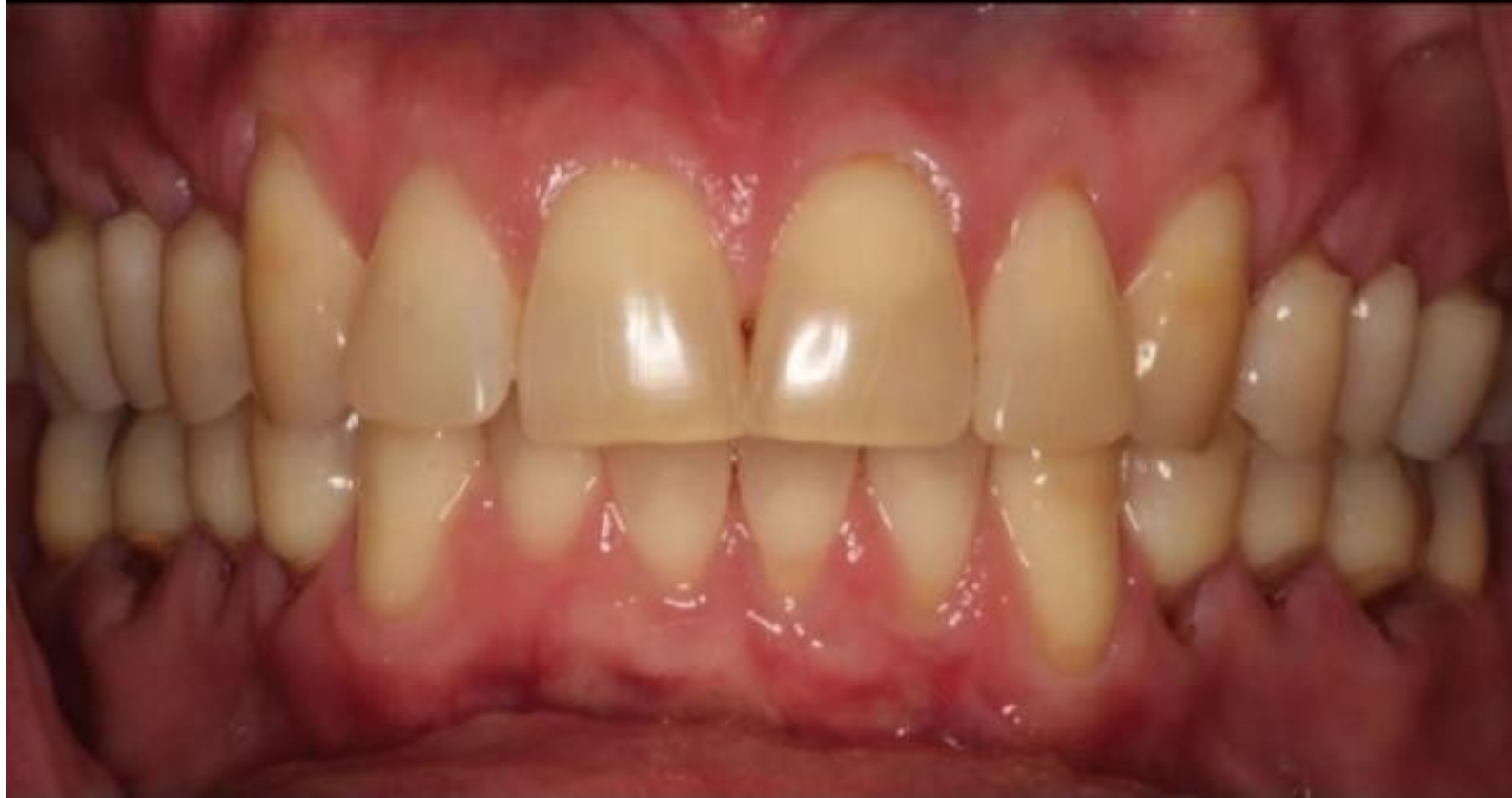- The occlusion of opposing teeth when the mandible is in centric relation. This may or may not coincide with the maximal intercuspal position (*it is tooth-to-tooth relationship dictated by bone to bone relationship*).

# Maximal intercuspal position:

- The most complete interdigitation of the teeth independent of condylar position. Hence maximal intercuspation is a maxillomandibular relationship determined by *tooth-to-tooth relationship*.



# Maximum Intercuspation



# Importance of centric jaw relation (Significance)

- It is learnable, repeatable, and recordable position which remains constant throughout life.
- It is a reference position from which the mandible can move to any eccentric position and return back involuntarily.

- It is the start point for developing occlusion
- Functional movements like chewing and swallowing are performed in this position, because it is the most unstrained position.
- It is a reliable jaw relation, because it is bone to bone relation.

# Methods of recording centric jaw relation

- 1. functional or chew in methods:
  - A. needles house method
  - B. Patterson method
- 2. graphic methods:
  - A. intraoral method
  - B. extraoral method

- 3 physiological methods
  - Tactile or inter- occlusal check record
- Method

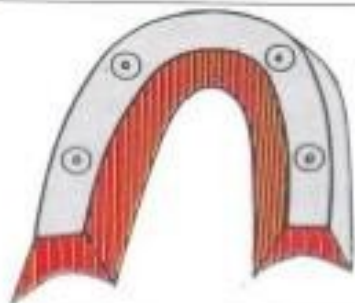
#### 4. Other methods

Swallowing method

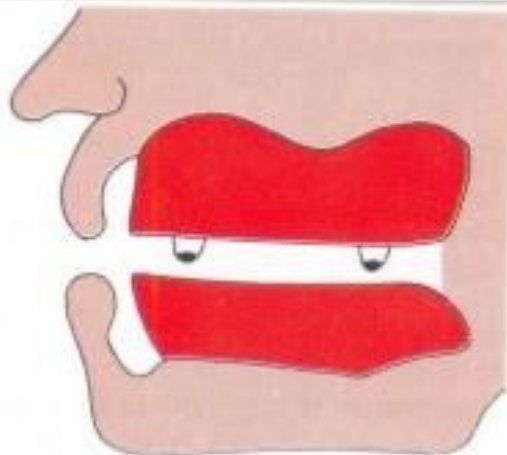
## Needles house method

- In this method used impression compound occlusion rims with four metal styli placed in the maxillary rim. When the patient moves his mandible, the styli on the maxillary rim will create a marking on the mandibular rim, after all mandibular movements are made, and a diamond-shaped pattern is formed. The anterior most point of this diamond pattern indicates the centric jaw relation.

# NEEDLES HOUSE METHOD

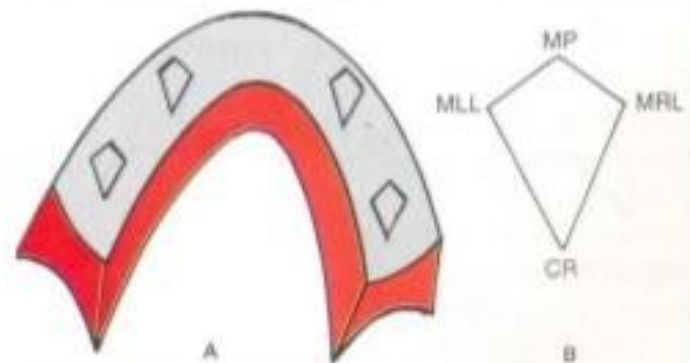


Maxillary occlusal rim made of impression compound with metal styli



Recording the mandibular movements

The posterior most point of this diamond pattern indicates the centric jaw relation.



Diamond-shaped markings made on the mandibular occlusal rim. (CR = Centric relation, MRL = maximum right lateral, MLL = Maximum left lateral)

## Tactile or inter- occlusal check record Method

- In this method the centric relation is recorded by placing a **record medium** between the record bases when the jaws positioned at centric relation. The patient closes into the recording medium with the lower jaw in its most retruded unstrained position and stops the closure at **predetermined vertical dimension**



- This method is **simple**, because mechanical devices are not used in the patient mouth and are not attached to the occlusion rims.

- This method is essential in making an accurate record, the visual acuity and the sense of touch of the dentist also inter in making of centric relation record, this phase is developed with experience and it is difficult to teach to another individual.

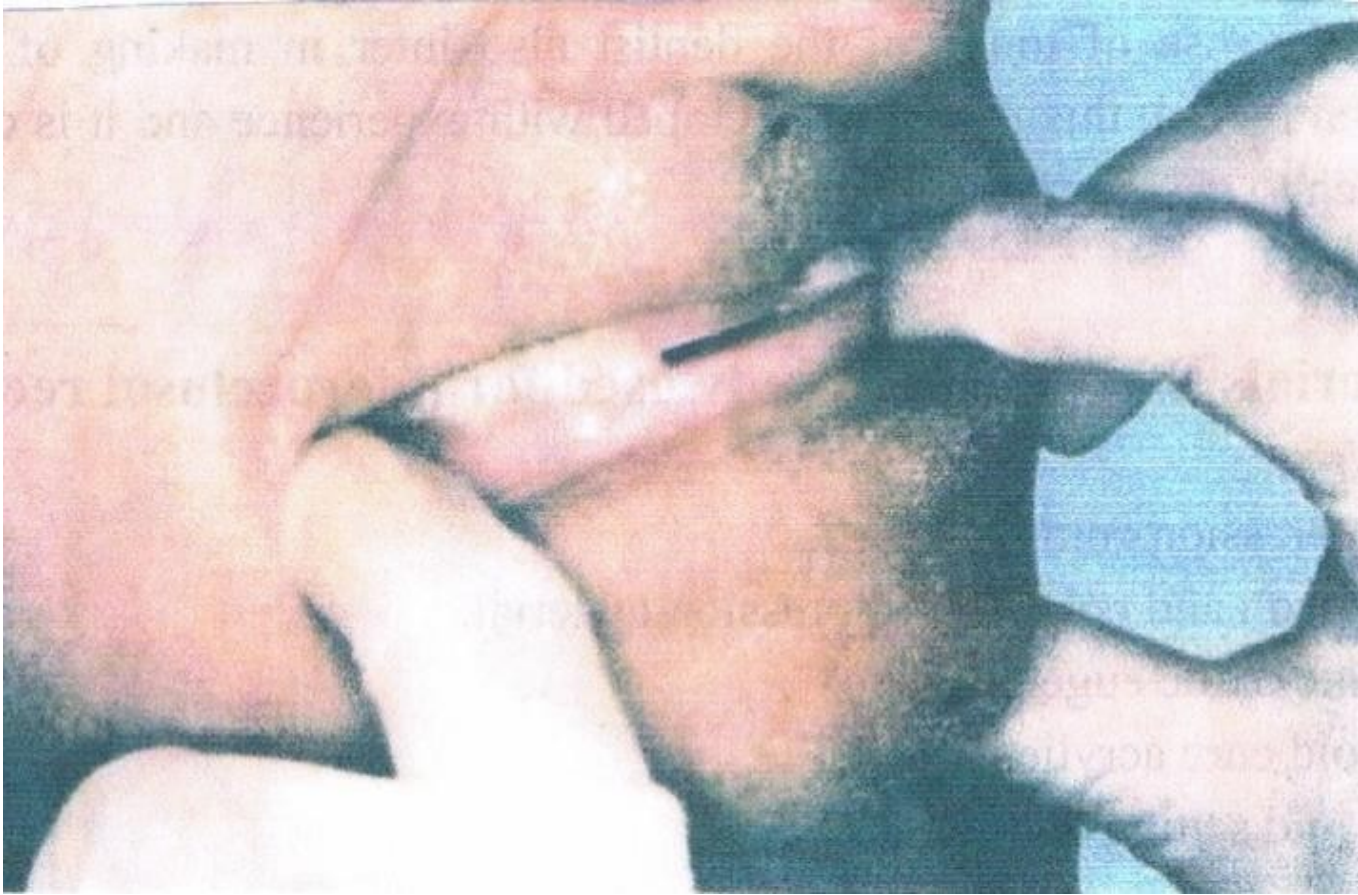
## **Materials that are commonly used for interocclusal record are**

- Wax.
- Impression compound.
- Silicon and polyether impression material.
- Zinc oxide eugenol paste.
- Cold cure acrylic.
- Rapid setting dental plaster

## Indication of Tactile or inter- occlusal check record Method

- Abnormally related jaws.
- Displaceable, flabby tissues.
- Large tongue.
- Uncontrollable mandibular movements.
- It can also be done for patient already using a complete denture.

# interocclusal record.

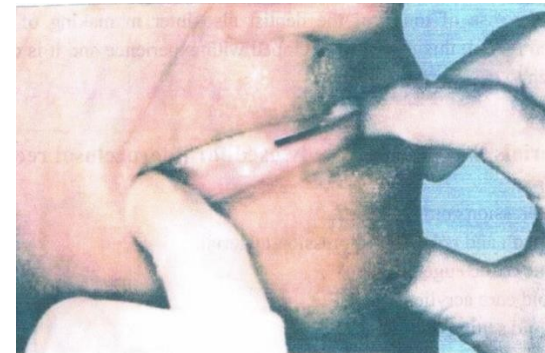

# Methods of assisting patient to move the mandible to the centric relation

- The dentist must guide the mandible of the patient to the centric relation, not force it !!
  1. The patient is instructed to let his jaw relax (palpate the temporalis and masseter muscles to relax them), pull it back and close slowly on the back teeth.

2. The patient is instructed to get the feeling of pushing his upper jaw out and then close the mouth with back teeth in contact.

- 3 .Assist the patient to protrude and retrude the mandible repeatedly with the operator holding the finger lightly against the chin.



- 4 -The patient is instructed to: **Boo's series of stretch exercise:** **a-** Open the mouth wide and relax.
- **b-** Move the jaw to the left and relax.
- **c-** Move the jaw to the right and relax.
- **d-** Move the jaw forward and relax, in series of movements.

The results to be expected are for the patient to be able to follow the dentist's directions in moving the jaw to centric relation and the desired eccentric positions



- 5. The patient can be instructed to turn the tongue towards the posterior border of the upper record base and close the rims together until they meet. The disadvantage with this method is the likelihood of displacing the mandibular record base by the action of the elevated tongue.

- 6 . Tilt the patient head back, the tension of muscles under chin make protrusion more difficult.
- 7. Exert pressure in molars in both sides and ask the patient to close (molar reflex method).

- 8. Celluloid strip is placed between the rims and pulled out. Ask the patient to restrain the strip from slipping away; the mandible involuntarily goes to centric relation.

# Swallowing method

- In this method, soft cones of wax are placed on the lower record base. The wax cones contact the upper occlusion rim when the patient swallows. This procedure is supposed to establish both proper vertical and horizontal relation of mandible to maxilla

# Occlusion rim

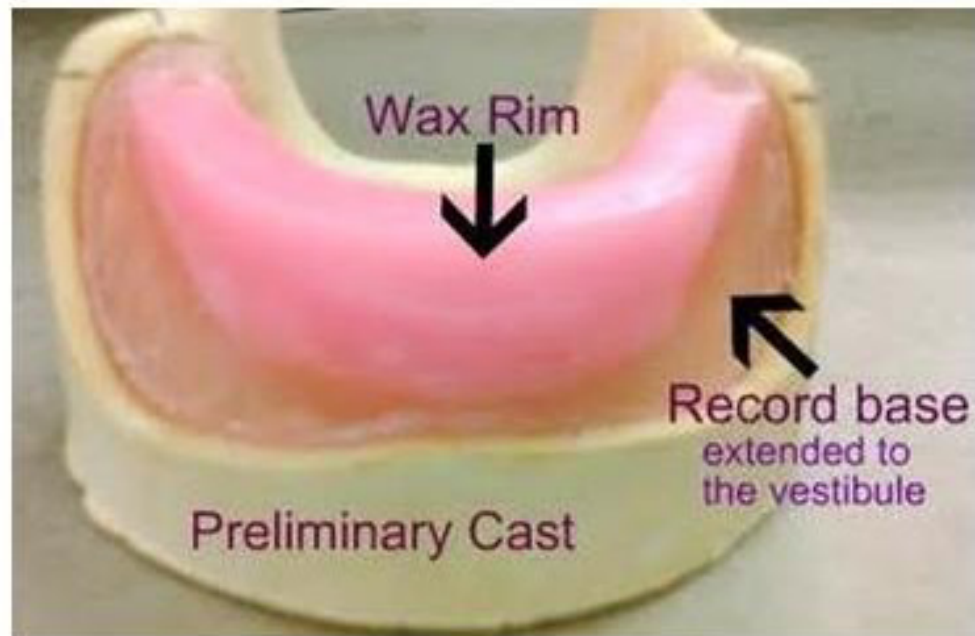
Dr. Saraa Almallah

# Occlusion rim

- Occlusion rim is occluding surfaces constructed on record bases for the purpose of making maxillomandibular relation records and for arranging artificial teeth. It is also called *bite rim and record rim*.

# Bite rim







- The borders of the record bases and the polished surfaces of the occlusion rims should be smooth and round; since smooth and round surfaces are conducive to patient comfort and relaxation.

# Materials used in construction of occlusion rims

- 1) Bite block wax.



- 2) Base plate wax.



- 3) Modeling compound



- ***Wax is used more frequently; since it is easier to manage in the*** registration and in arranging teeth.



# Uses of occlusion rim

- 1- Establishment of the arch form (neutral zone).

- 2- Support of the facial musculature.

The position of the lip and cheeks are important in the recording of maxillomandibular relations. The proper contouring of the occlusion rims for lip and cheek support allows the muscles of facial expression to act in a normal manner.

# Uses of occlusion rim

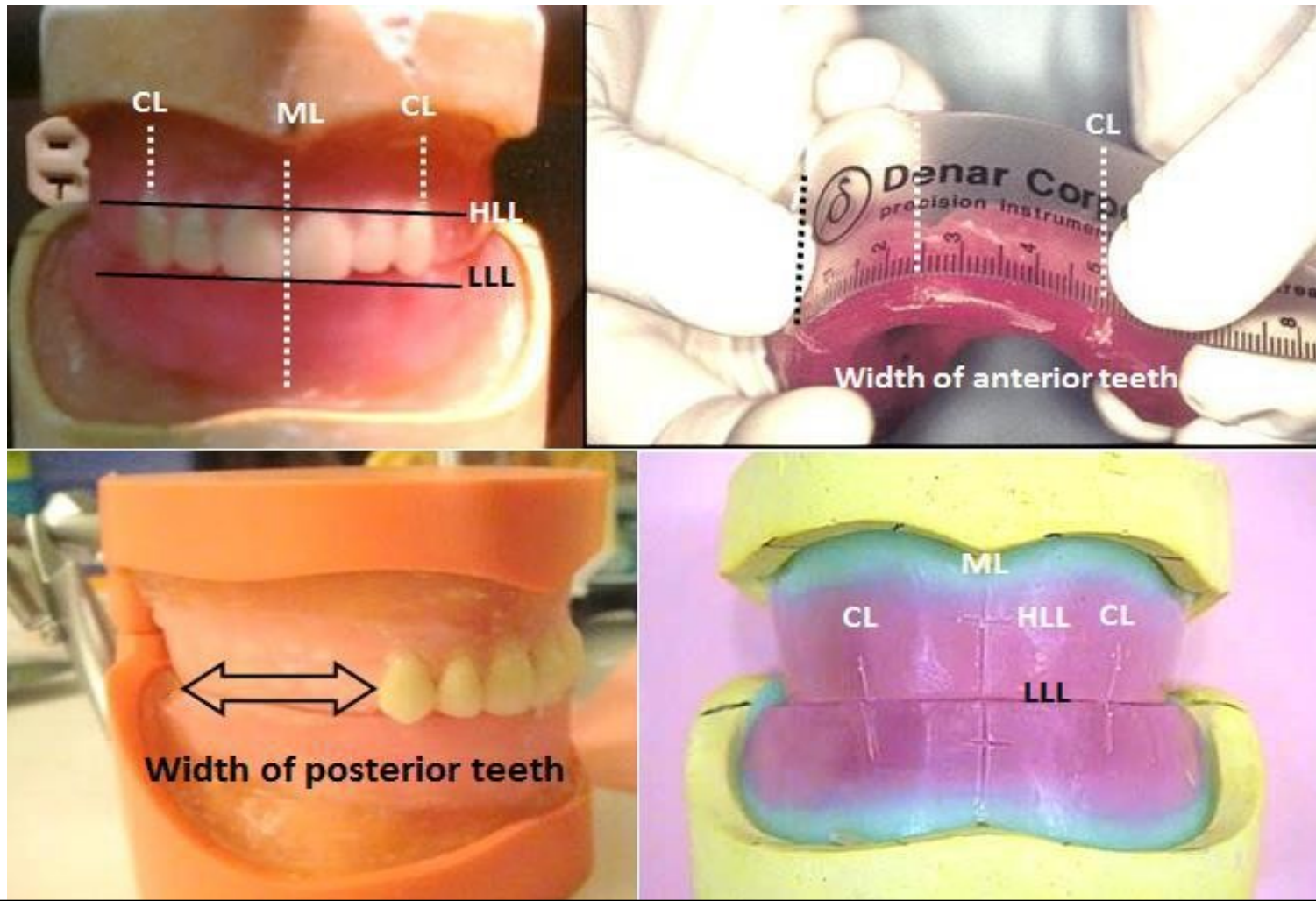
- 3- Establish the level/height of the occlusal plane.
- 4- In determining of jaw relation which include:
  - a) Determination of the vertical dimension. •
  - b) Determination of the horizontal (centric and eccentric jaw relations).

- 5- In selection of teeth:
- a) **The position of midline can be determine**
-

- **b) Canine lines (cuspid lines) are drawn at the corner of mouth on each side, width of 6 anterior teeth is equal to the distance between the two canine lines + 7 mm, the width of posterior teeth is equal to the distance between the canine line and the end of wax rim posteriorly**

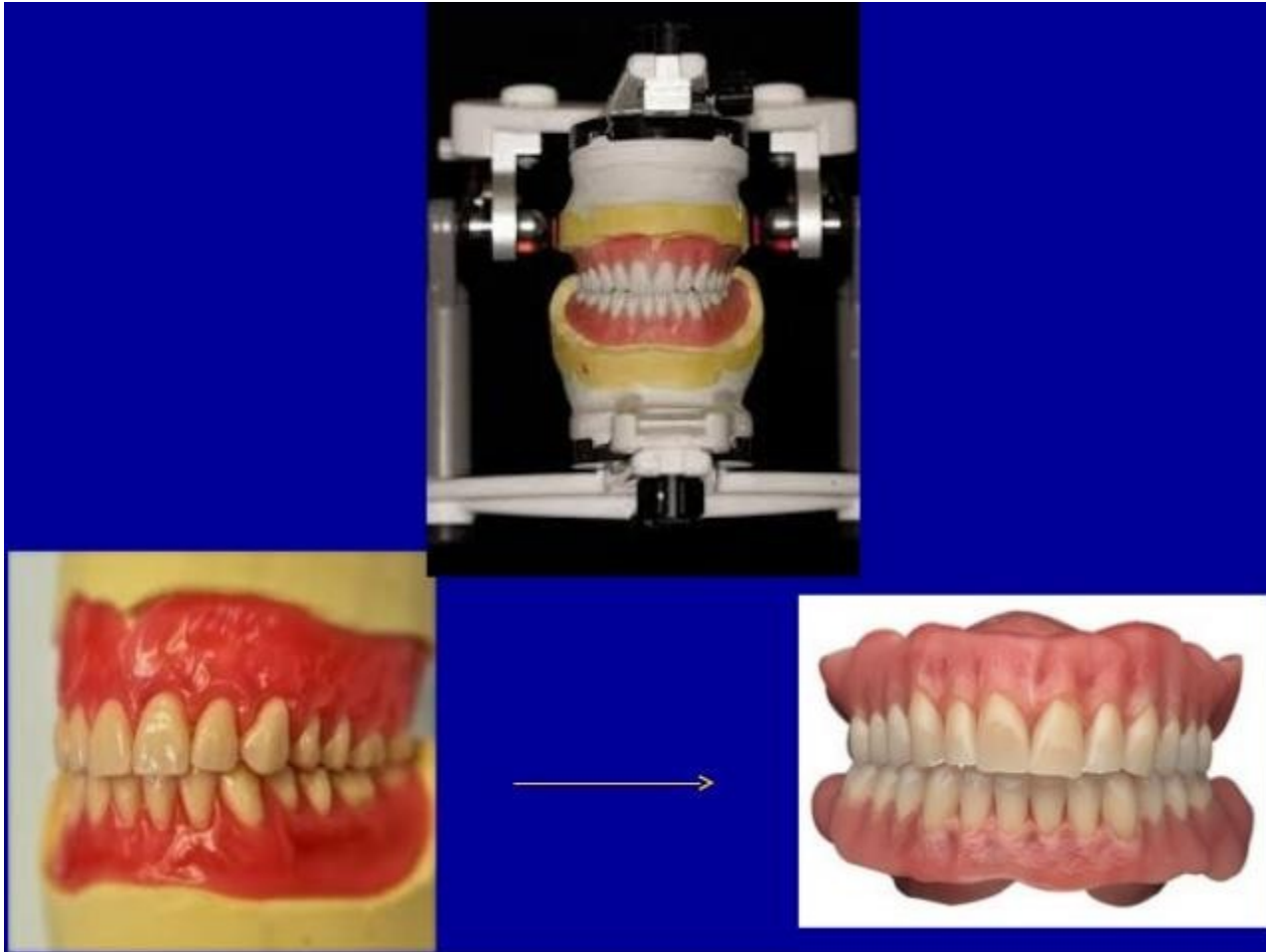

# *Midline (ML), canine line (CL), high lip line (HLL), low lip line (LLL), drawn in bit rim.*



- **c) The high length of anterior teeth is determined by drawing high lip line (gum line, smiling line) when patient smiling, the whole of anterior incisors should be seen.**

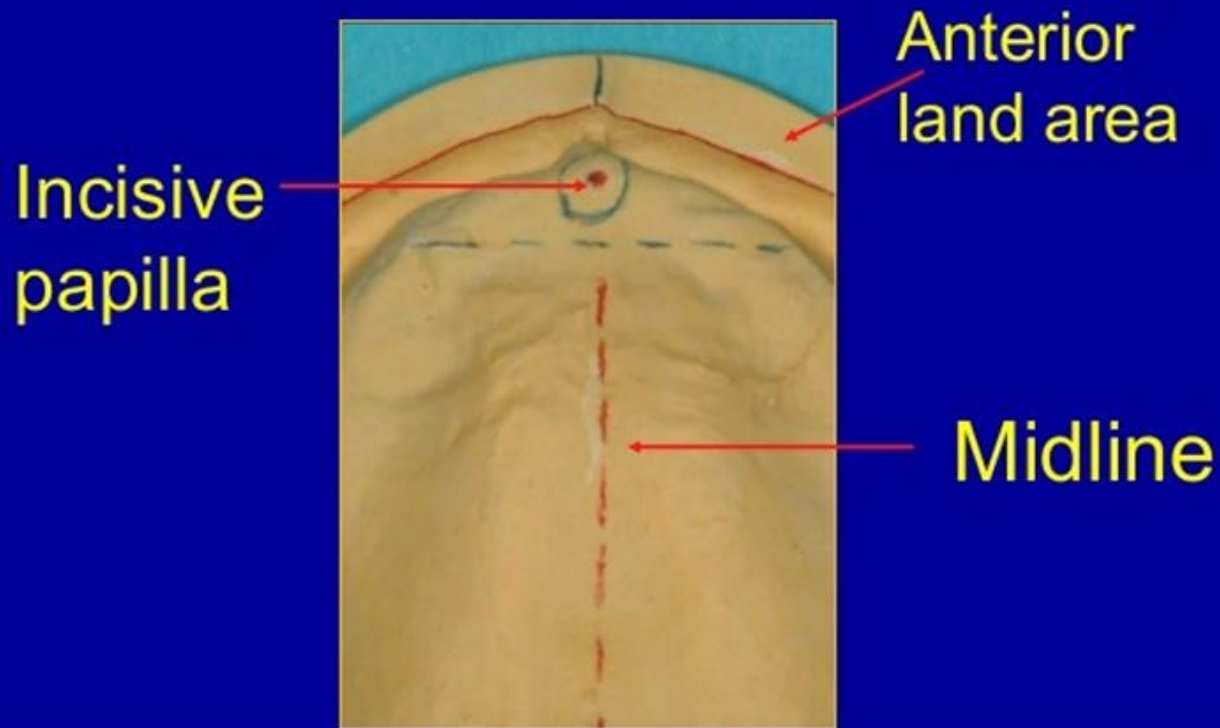
- **d) The low lip line (speaking line, relaxed lip line) is a line drawn on wax rim when lip is relax, in this case (*2 mm) of anterior teeth should be* seen.**
- 6) Setting up of teeth.



# Measurements of maxillary bite rim

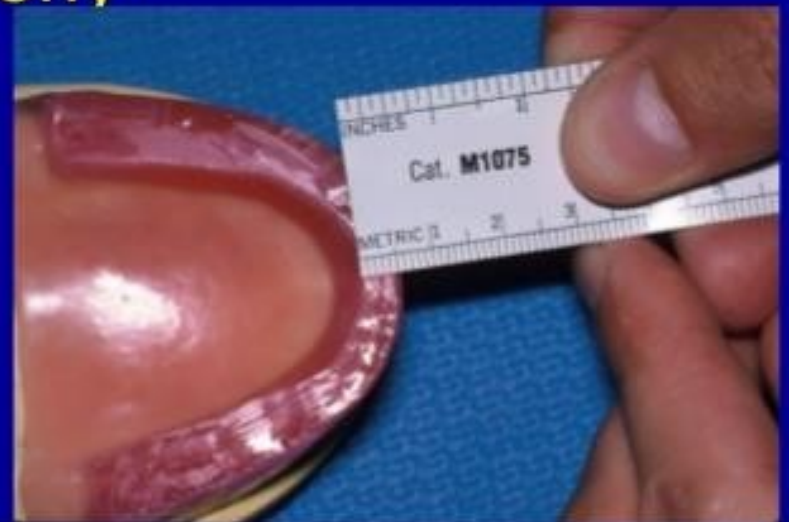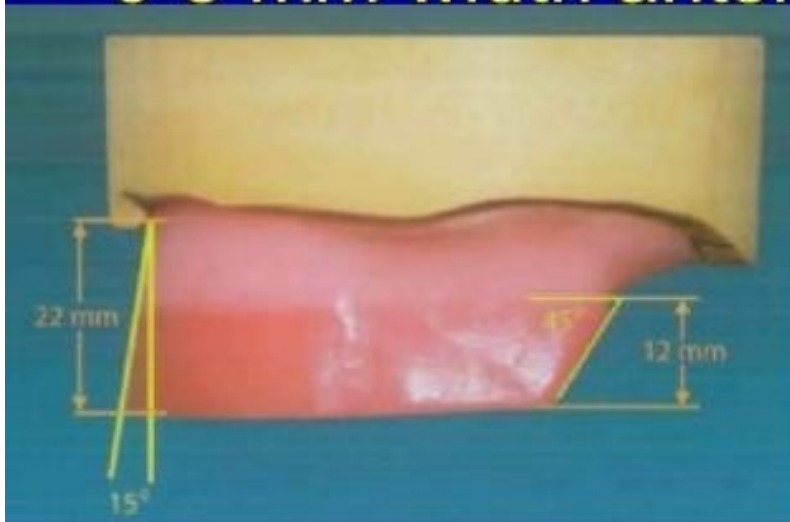
- It should be directly over the crest of the residual ridge.
- The anterior edge of the maxillary rim should have a slight labial inclination and the maxillary labial surface should be about (**8 mm**) anterior to the line bisecting the incisive papillae.

## Guidelines drawn on the master casts



# Maxillary occlusion rim

- 22 mm height from labial frenum,
- 12 mm height in the tuberosity from the record base
- 8-10 mm width posteriorly
- 6-8 mm width anteriorly



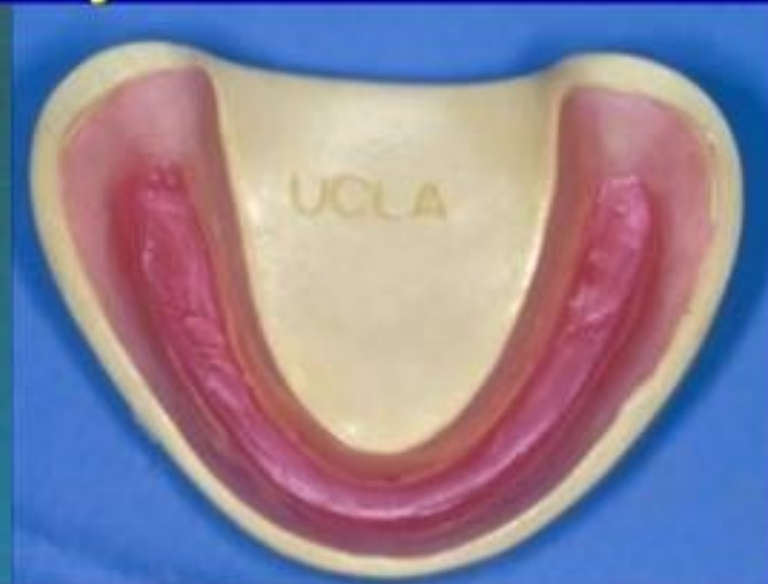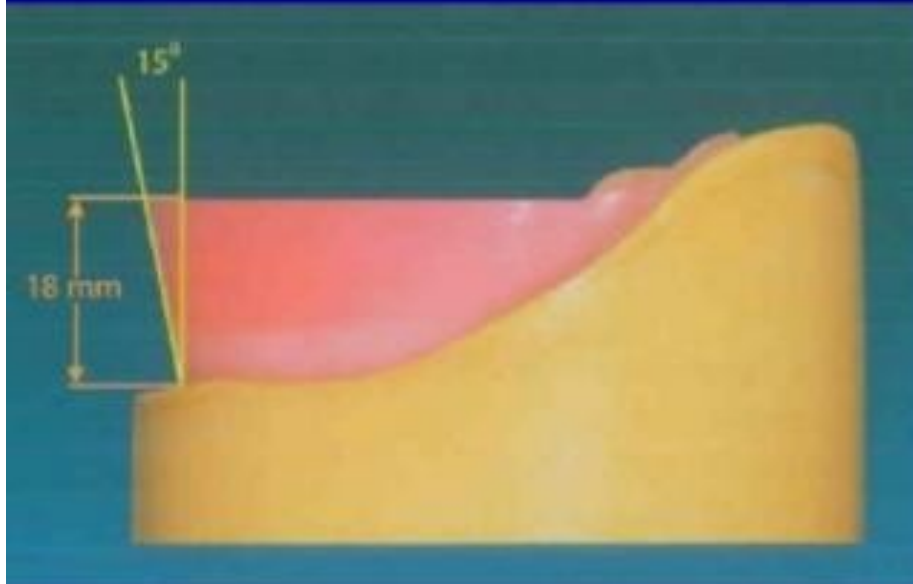
# Measurements of mandibular bite rim

- It should occupy the space over the crest of the residual ridge.
- Mandibular incisal edge should be at the level of the lower lip and about **(2 mm) behind the maxillary incisal edge.**



# Mandibular occlusion rim

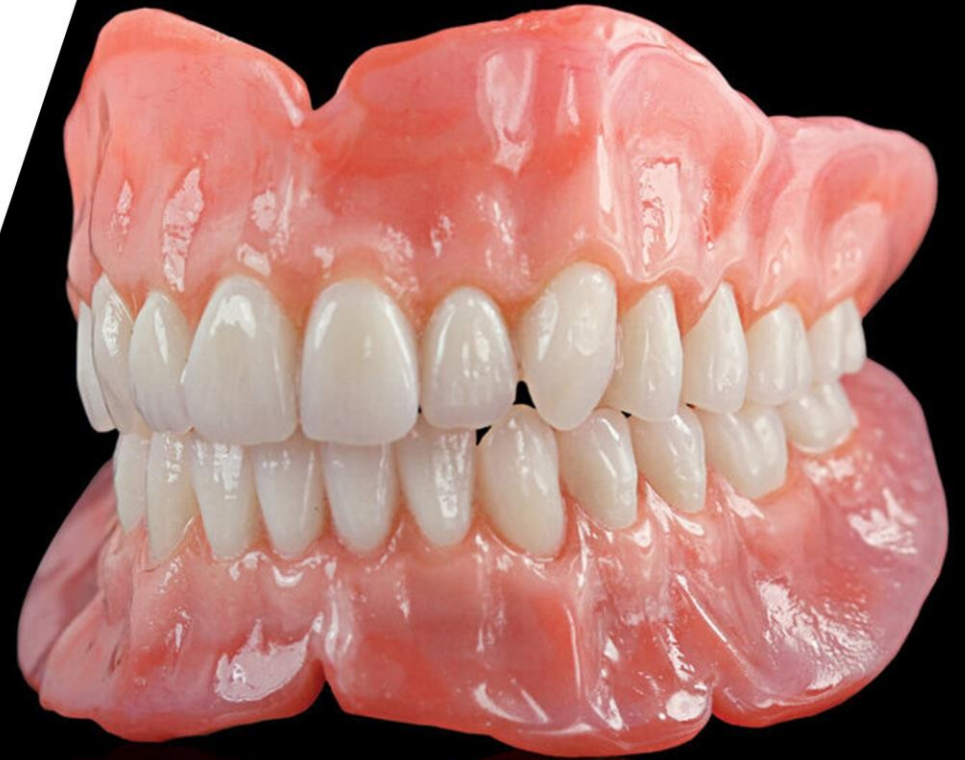- 18 mm height from labial frenum, midpoint or 2/3rds of retromolar pad posteriorly,
- 8-10 mm width posteriorly
- 6-8 mm width anteriorly

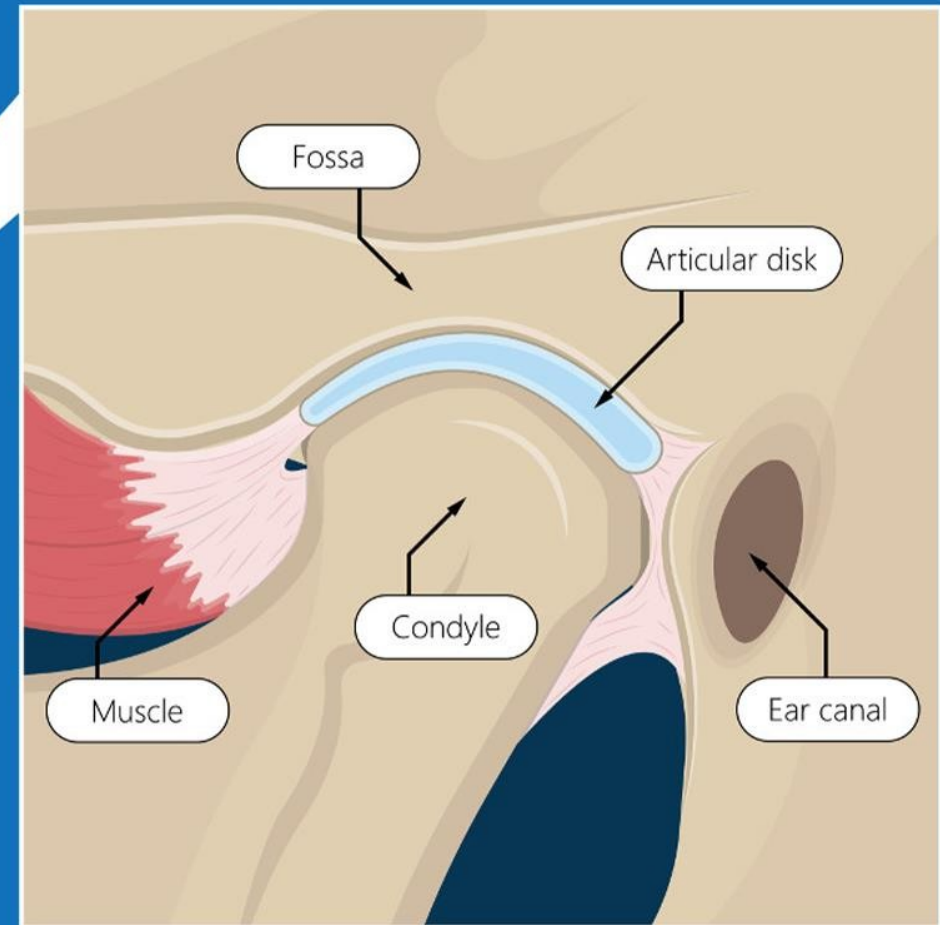
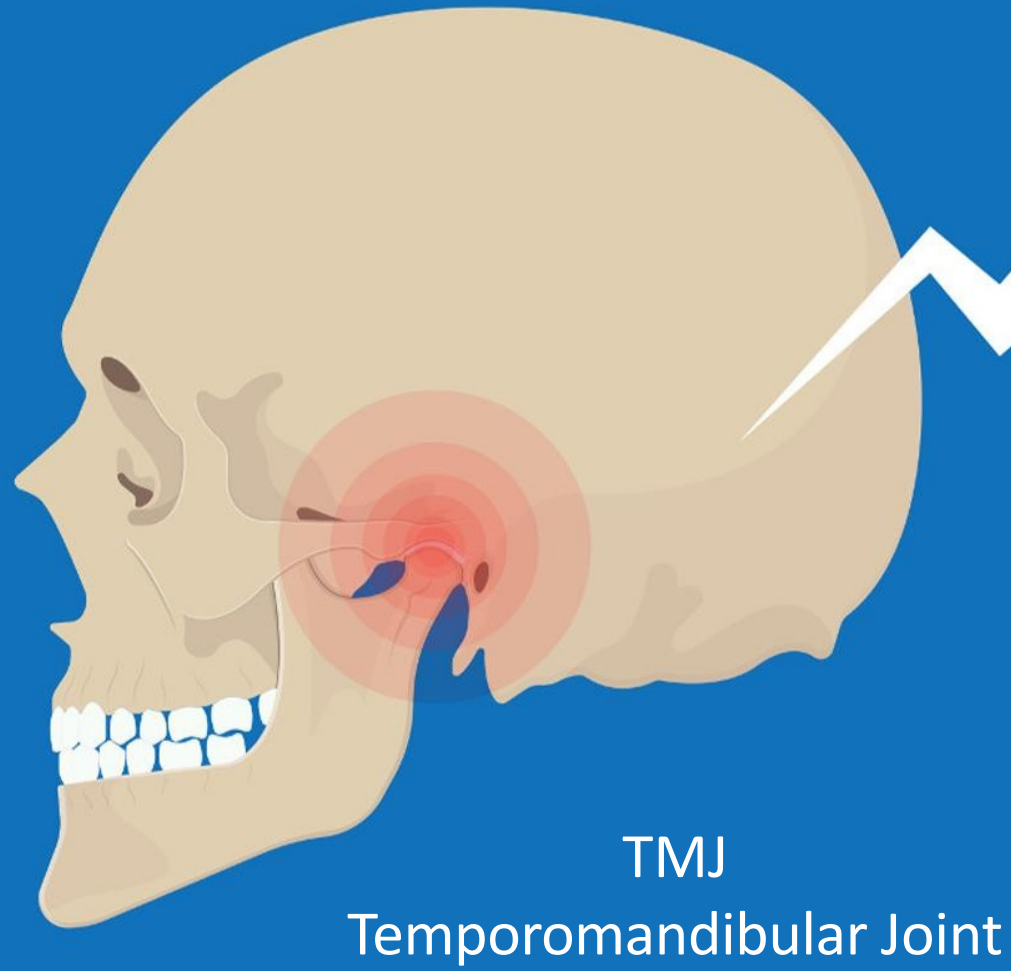




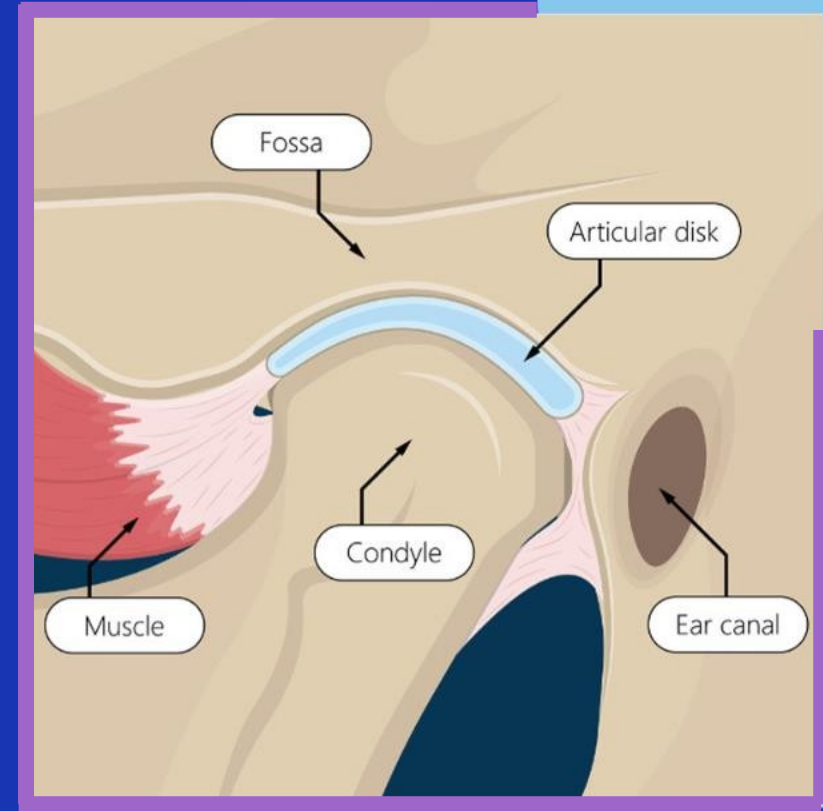
# PROSTHODONTICS

## ANATOMY AND PHYSIOLOGY OF TMJ





**Temporomandibular joint (TMJ):** Is the articulation of the condyloid process of the mandible and the inter-articular disk with the mandibular (glenoid fossa) of the temporal bone





# The TMJ Consists Of The Following Parts:

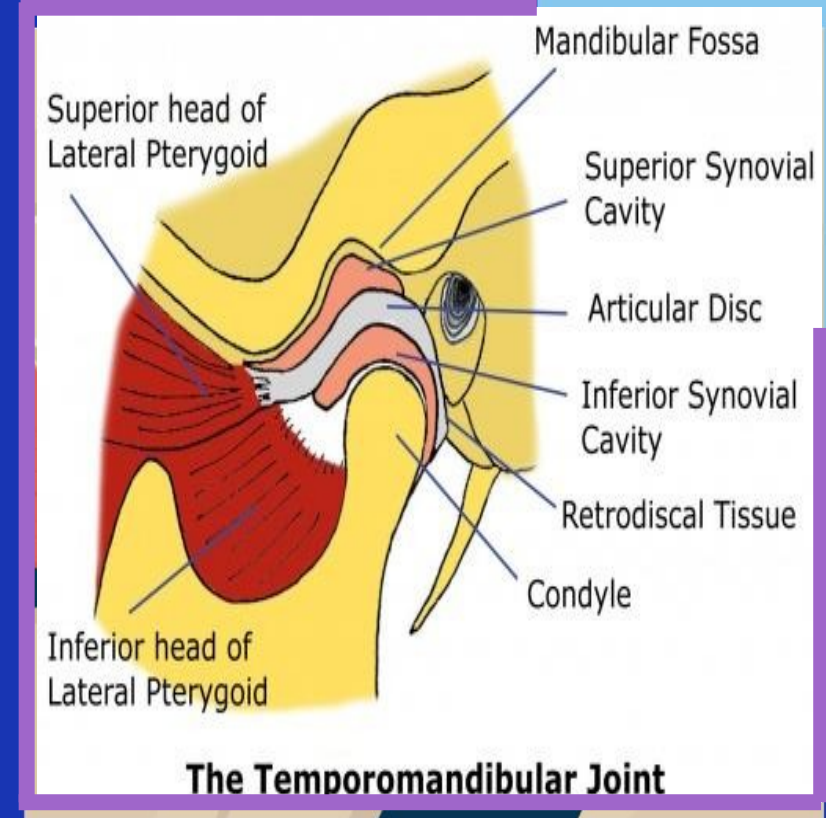
1) The mandibular or glenoid fossa.

2) The condyle or head of the mandible.

3) The articular disc or "**Meniscus**" which is found between the condyle and the glenoid fossa.

It divides the synovial joint or TMJ into upper (**superior**) and lower (**inferior**) compartments.

4) Synovial cavity.



# The differences between TMJ and other Joints in the body

1) TMJ has an **articular disc** which completely divides the joint spaces into **upper and lower** joint compartments.

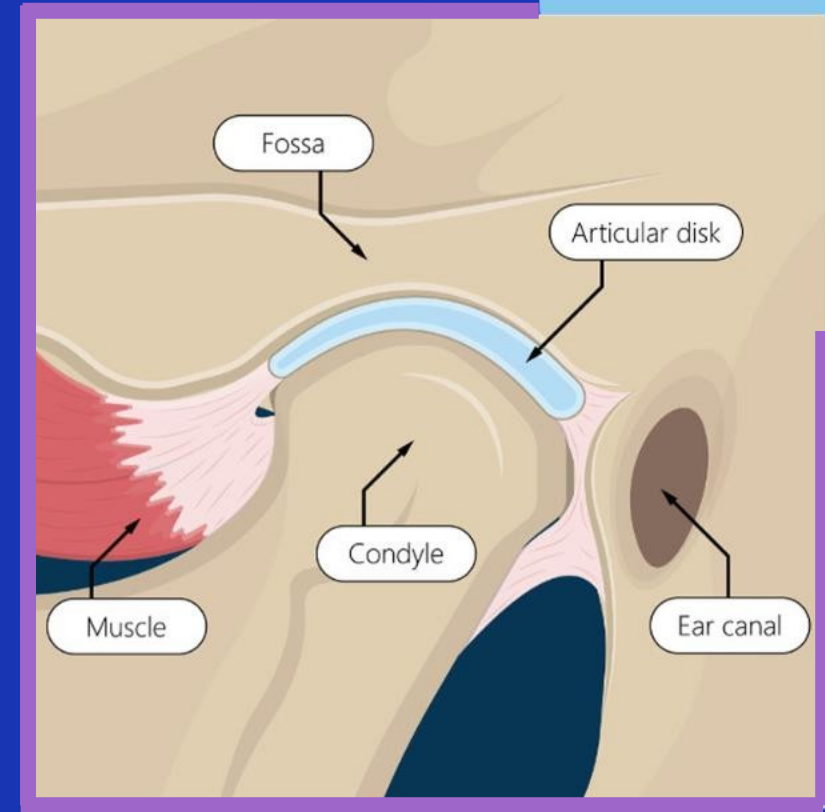
2) TMJ is **Ginglymoarthrodial** Joint.

a. Hinge action (**Rotation**)

b. Slide Action (**translation**)

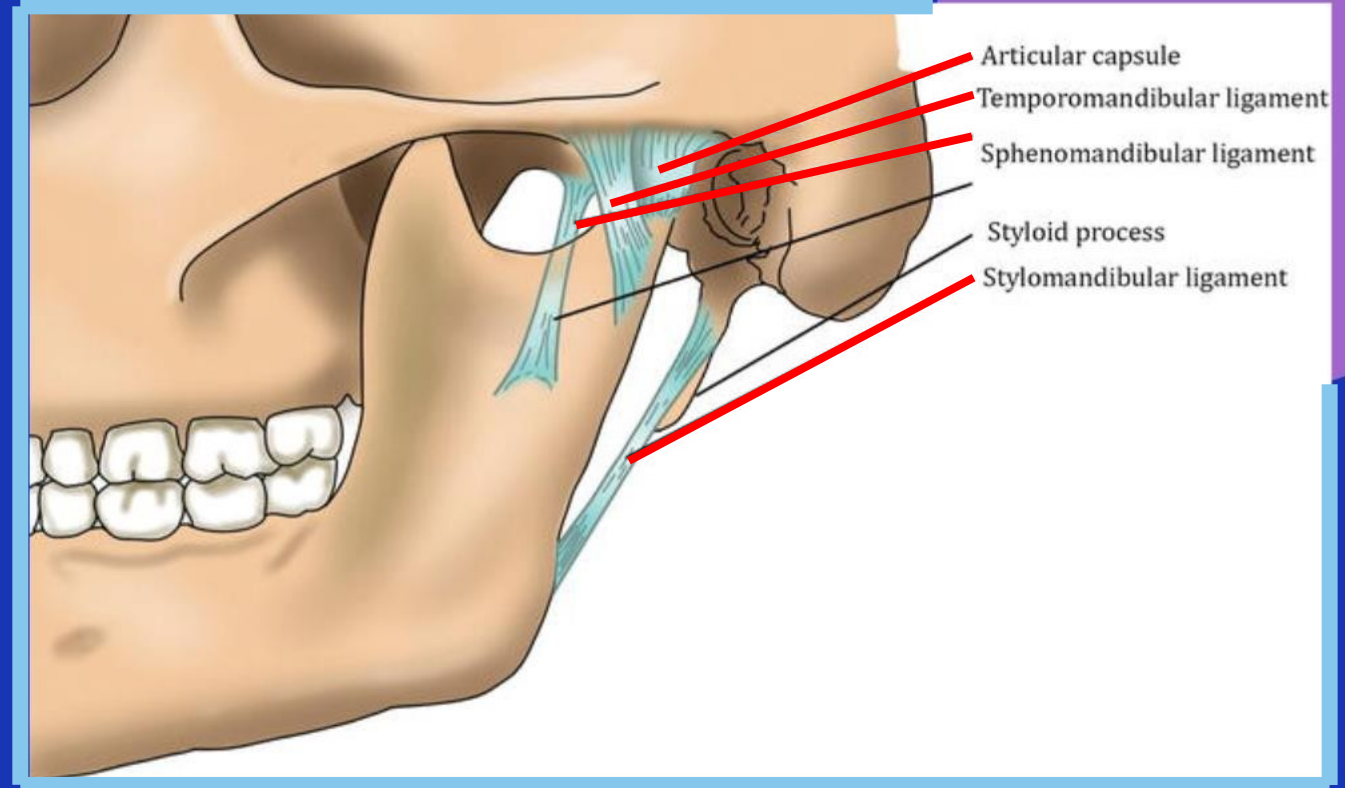
3) Relationship of **teeth affects** the relationship of the articulating components.

4) The mandible is the only bone in the body **hinged on both ends** that is not capable of independent movement at one ends.



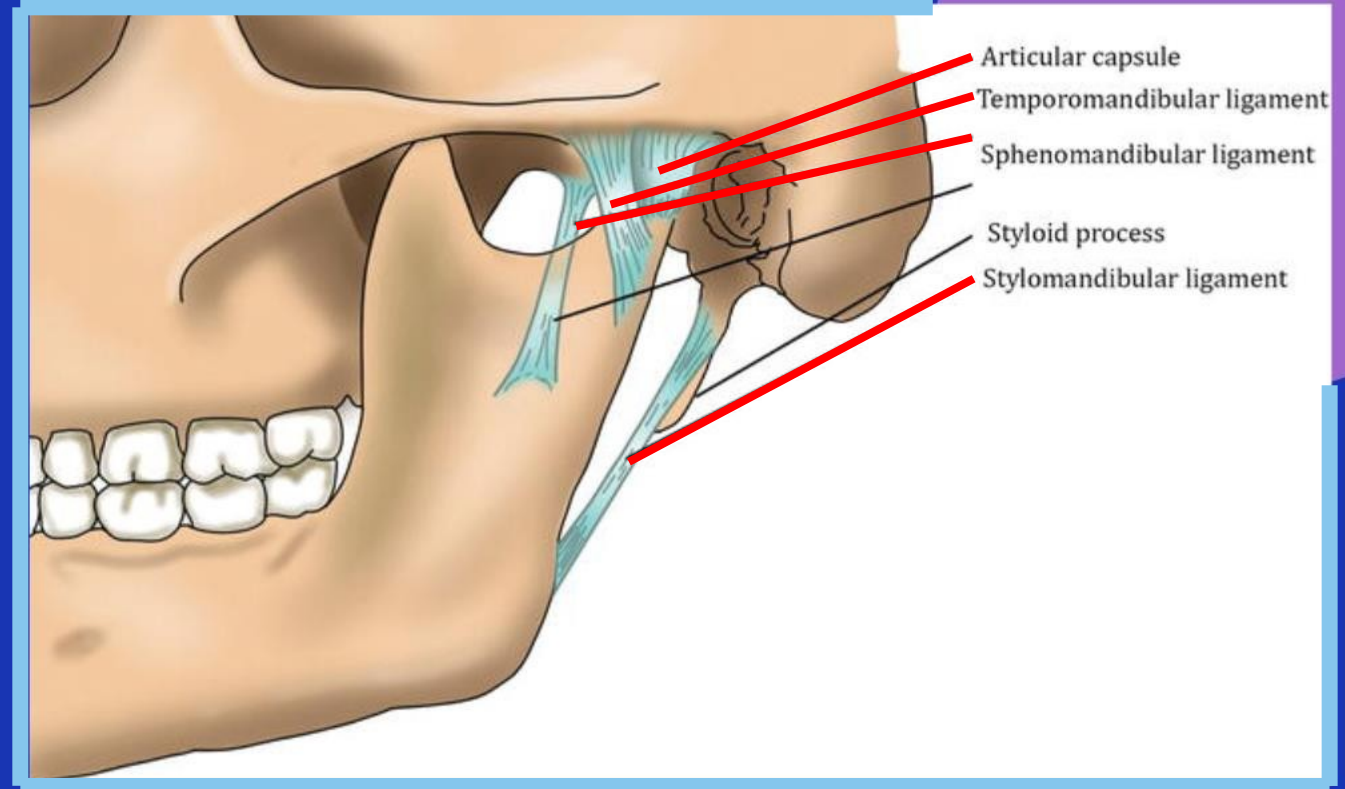
# The ligaments that affect the movement of the mandible consist of

1. Temporomandibular and capsular ligaments.
2. Spheno-mandibular ligament.
3. Stylo-mandibular ligament.



The mandibular bone has specific relationships to the bones of the cranium.

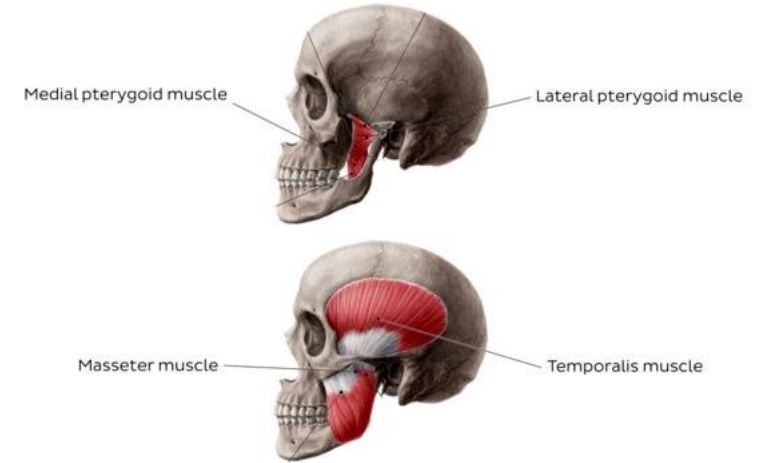
The mandible is connected to the cranium at the two TMJ by the temporomandibular and capsular ligaments. The sphenomandibular and Stylomandibular ligaments also connect the bones in such a way as to limit some motions of the mandible. The function of the ligaments is to stabilize the joints by limiting the movements, ligaments do not stretched but it could be elongated and the elongation of the ligament could compromise normal joint function.





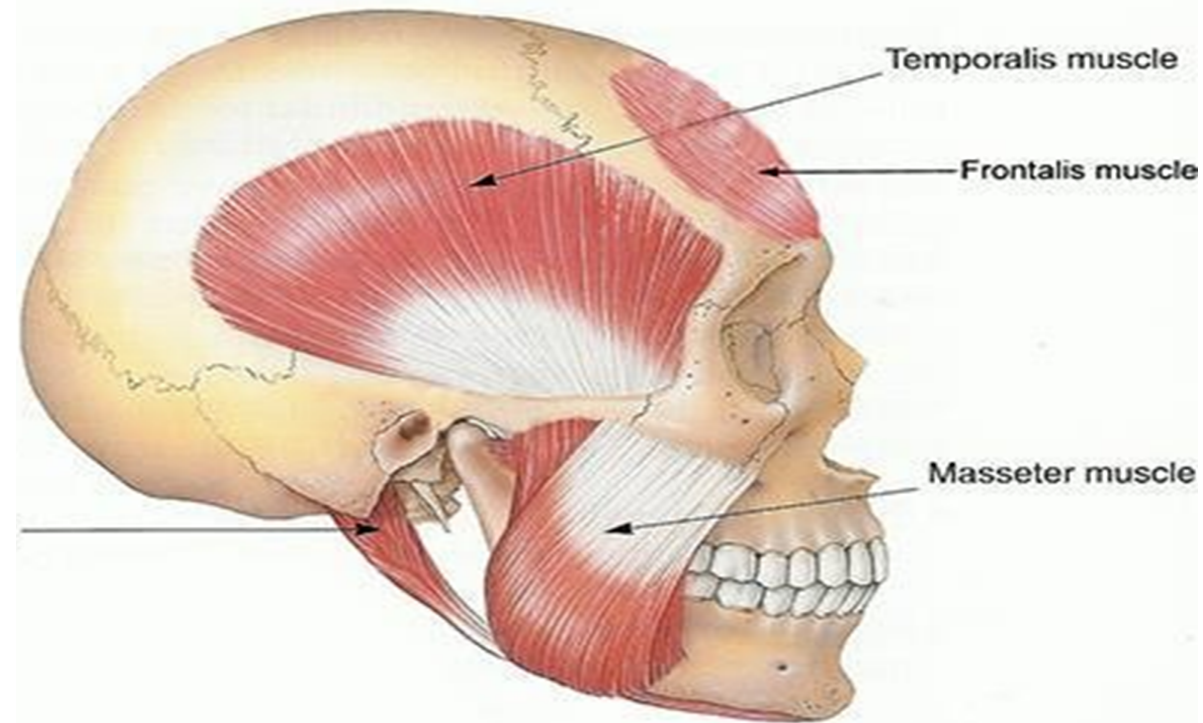
The muscles that control the movement of the mandible may be considered in 3 groups:

1. Closing muscles.
2. Gliding muscles.
3. Opening muscle.



# Closing muscles

The temporalis, masseter and medial pterygoid muscles supply the power for pulling the the mandible against the maxilla (elevating and closing the mandible).



# Gliding muscles

The lateral pterygoid muscle connects the mandible to the lateral pterygoid plate in such a way as to act as the steering mechanism for the mandible and act to protrude the jaw or to move it laterally.

# Opening muscles

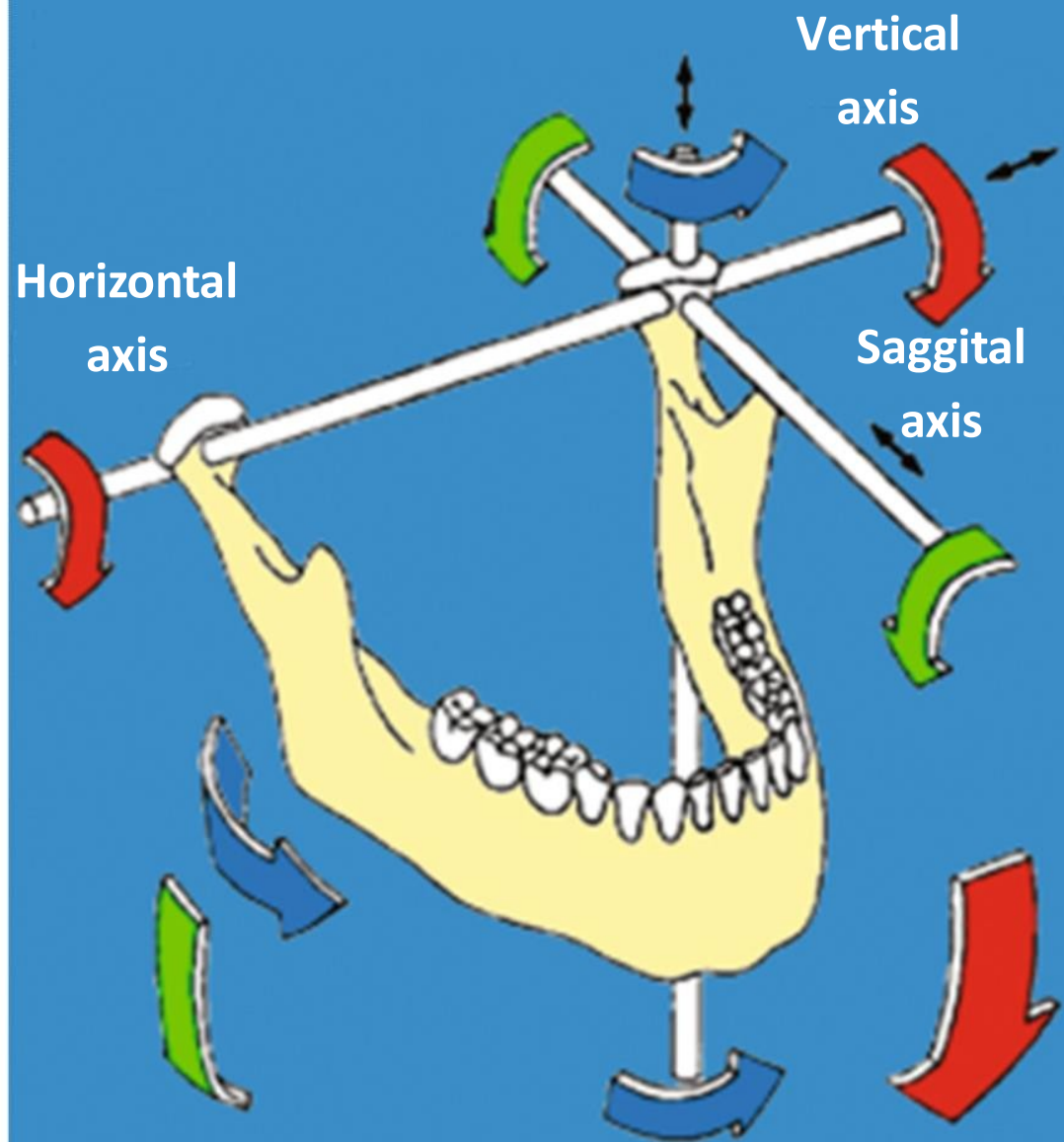
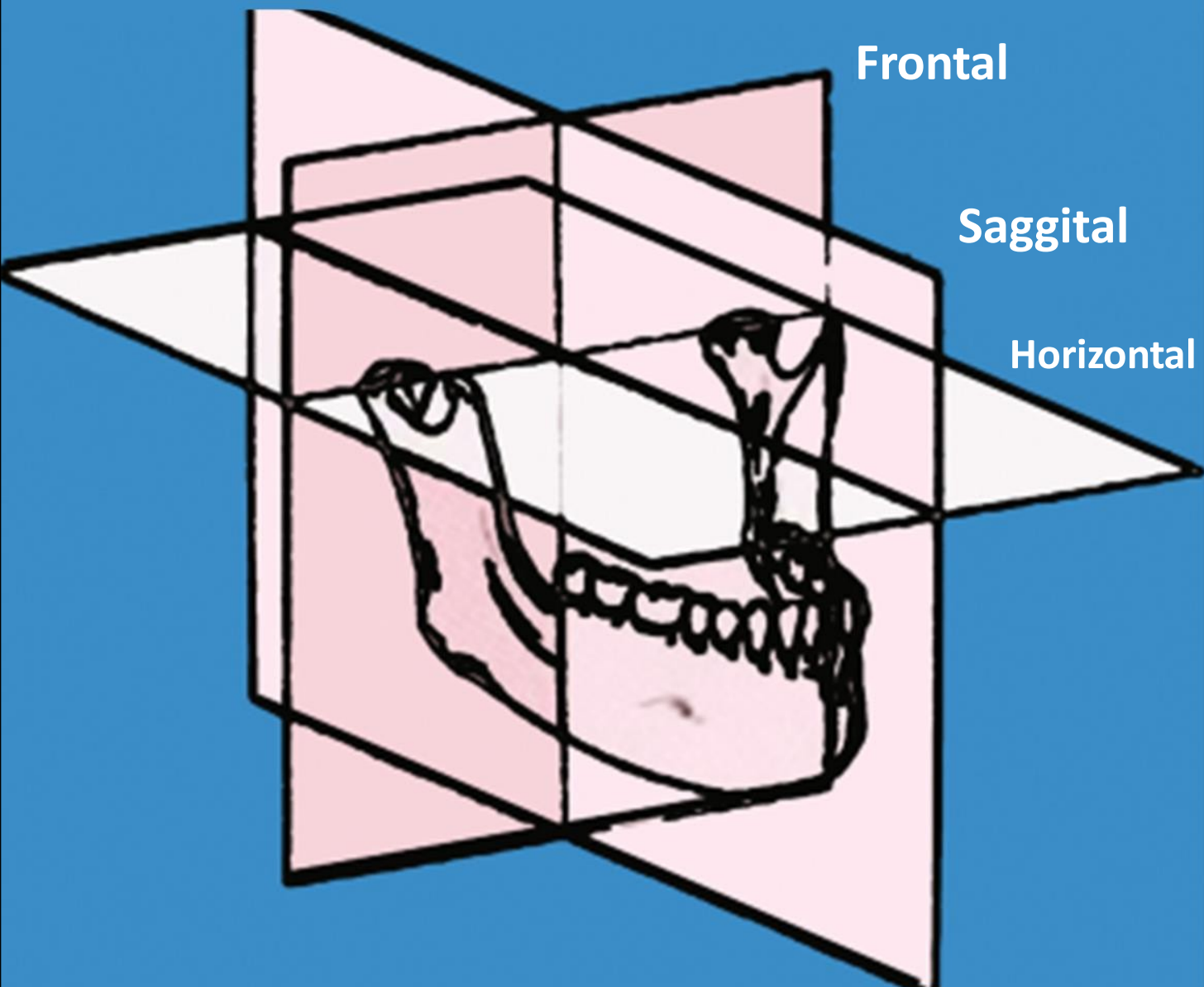
The muscles that depress (open) mandible consist of three groups, suprahyoid muscles, infrahyoid muscles, and platysma.

# Mandibular Axis And Mandibular Movements

Mandibular axis: There are three axis around which the mandibular movements take place in horizontal, sagittal and frontal planes.

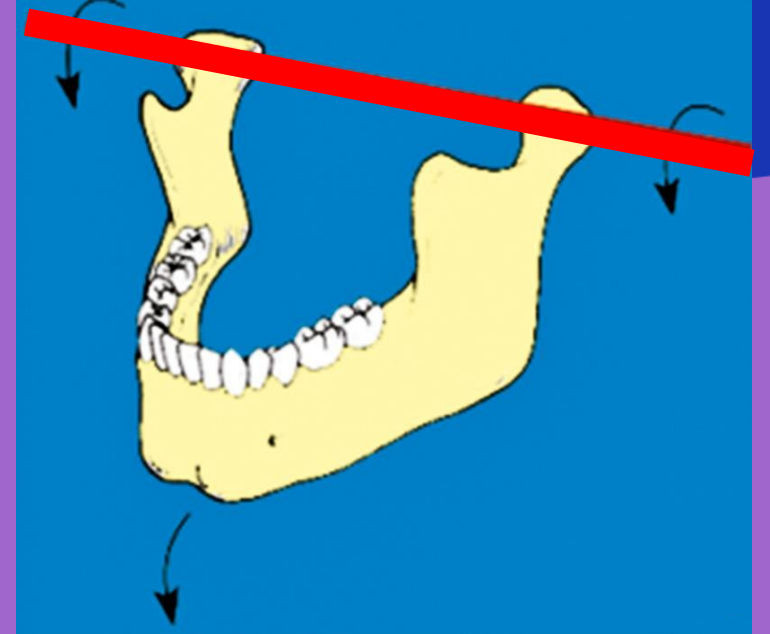
These axes include the followings:

1. Hinge axis or transverse horizontal axis
2. Sagittal axis of the mandible
3. Vertical axis of the mandible



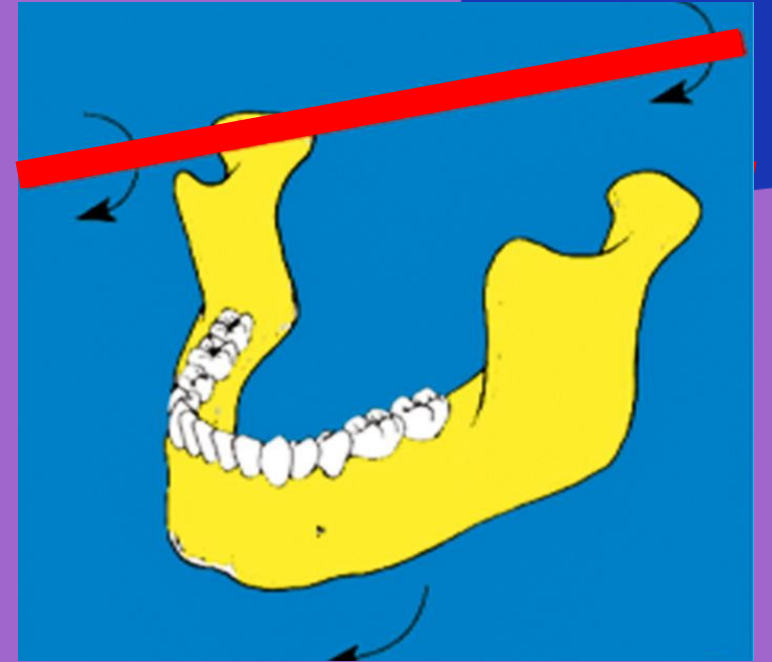
# Hinge axis or transverse horizontal axis

An imaginary **line** around which the mandible may rotate within the **sagittal plane**.  
(During the opening and closing movement).



# Sagittal axis of the mandible

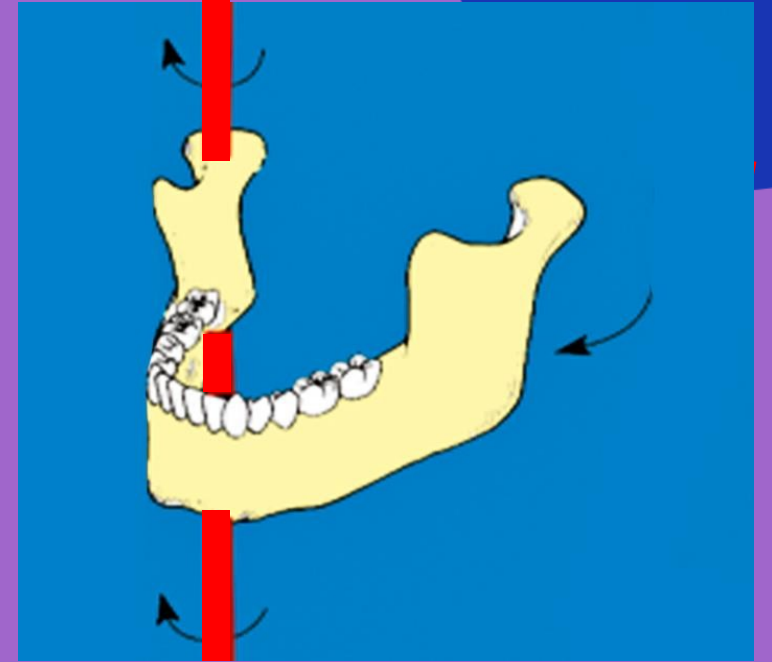
An imaginary anteroposterior **line** around which the mandible may rotate when view in the **frontal plane**.





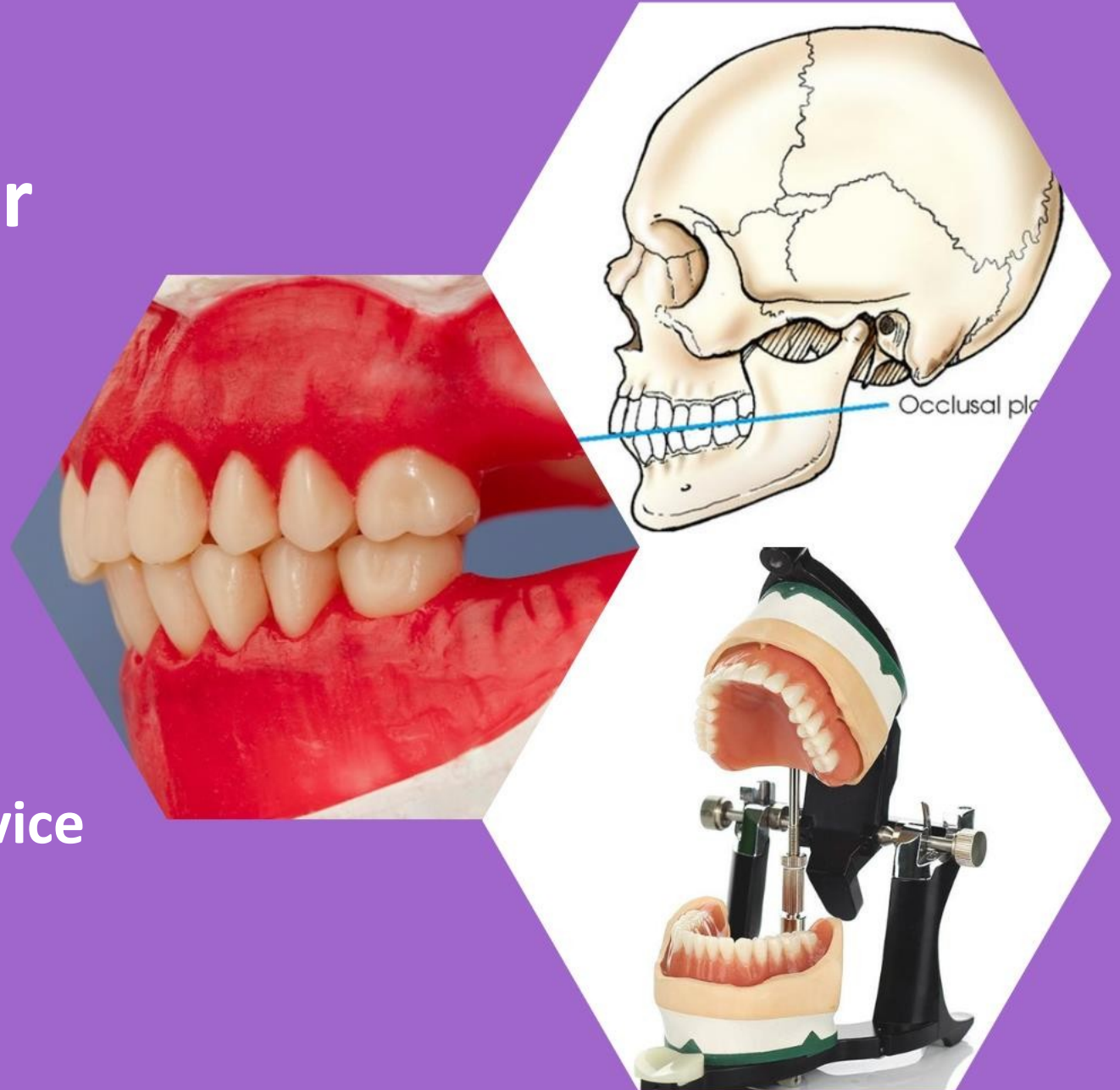
# Vertical axis of the mandible

An imaginary **line** around which the mandible may rotate through the **horizontal plane**.



# Knowledge of mandibular movements

1. To understand various **aspects** of **occlusion**
2. To **arrange** artificial teeth.
3. To select and adjust recording device **articulator**.

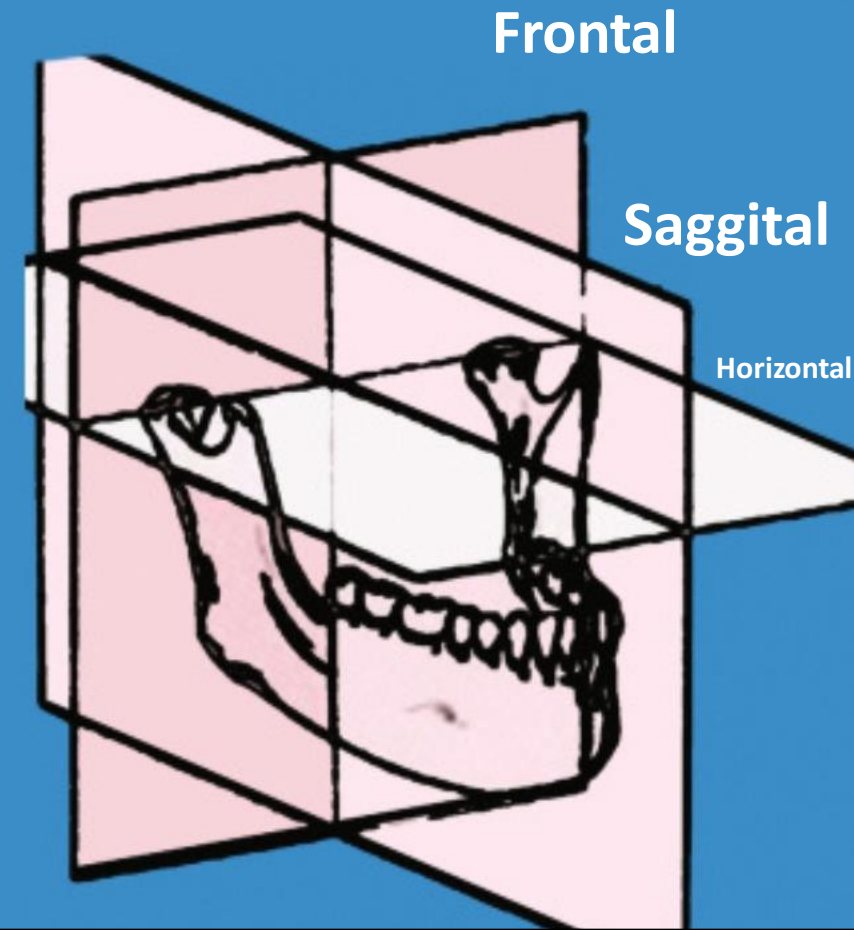


# Mandibular movements

## Classification of mandibular movement:

1. Based on the dimension involved in the movement.
2. Based on the type of movement

1) Based on dimension Mandibular movements are related to three planes of the skull the **horizontal**, **frontal** and **sagittal**. The mandible rotates in each of the three planes of space. The point of intersection of the three axes is called the **center of rotation**.

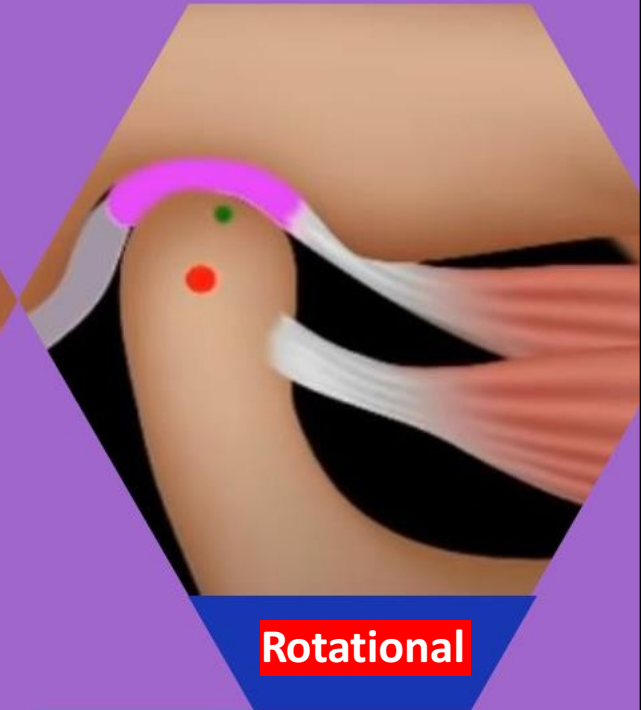
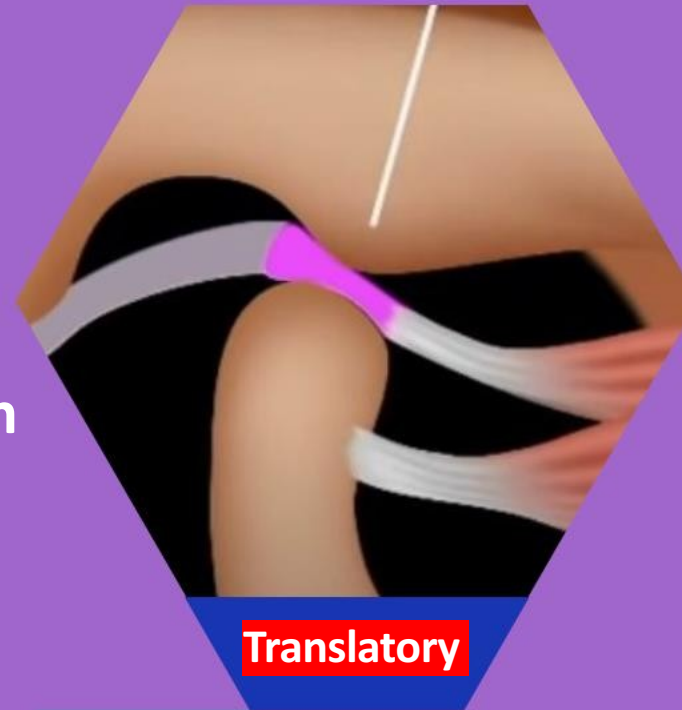


## 2) Based on the type of movement

**1- Basic Movement:** This movement occurs at the level of TMJ it may be divided into two types:

a- **Rotational movement:** The rotational movement occurs between the condyle and the inferior surface of the articular disk, i.e. in the lower compartment of the TMJ.

b- **Translatory or gliding movement:** It takes place in the upper compartment of the TMJ between the superior surface of the articular disk and the glenoid fossa.



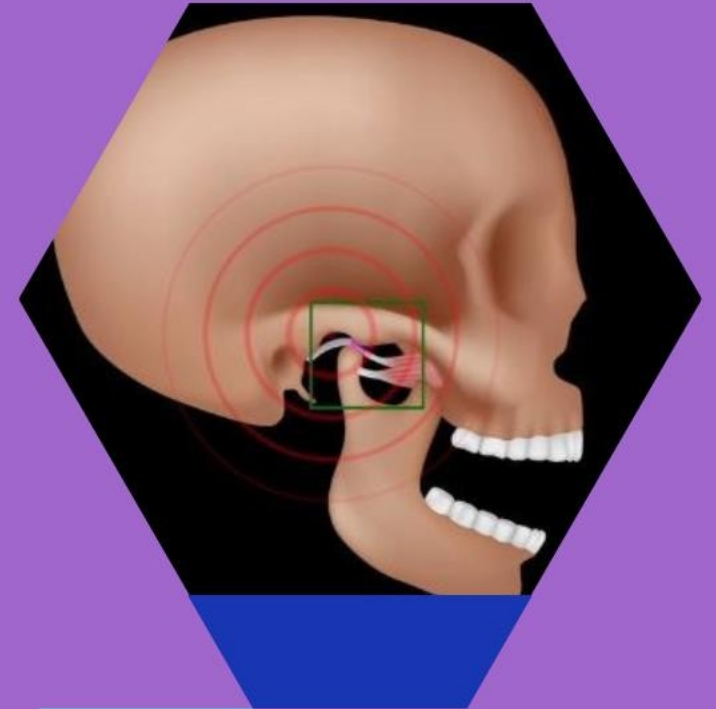
## 2) Based on the type of movement

### 2- Functional movement:

Opening and closing movements

Symmetrical forward and backward movements.

Asymmetrical side wise movement or lateral movement.



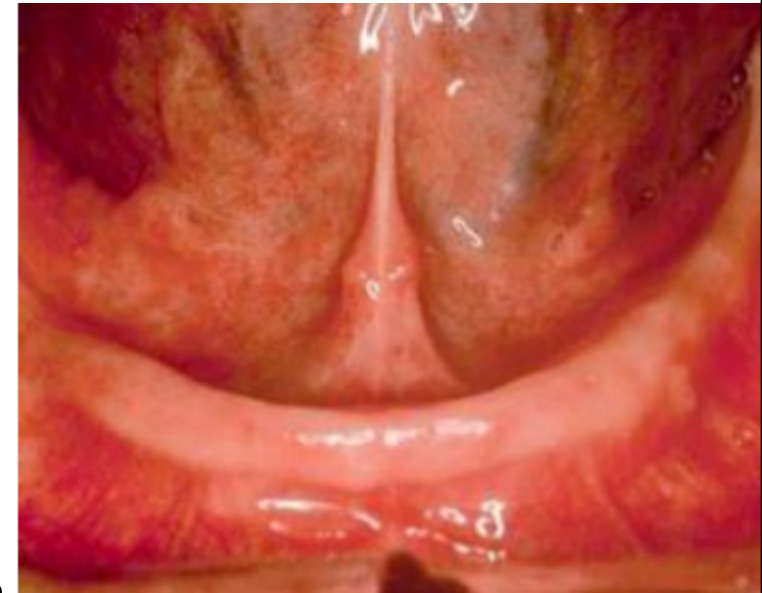
# Anatomical Landmarks – MANDIBULAR

Presented by:  
Dr. Saraa Almallah

# LIMITING STRUCTURES

## A) Labial, lingual & buccal frenum

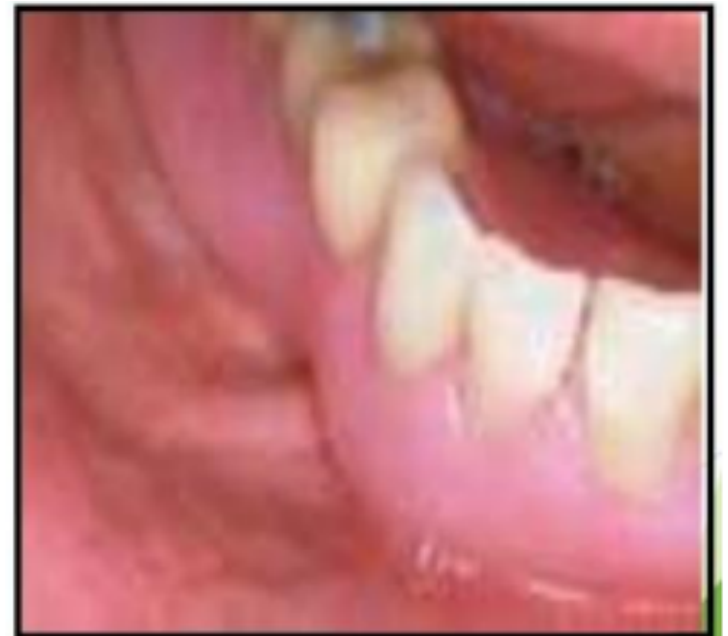It is fibrous band extending from the labial aspect of the residual alveolar ridge to the lip containing a band of the fibrous connective tissue That attachment of the orbicularis oris muscle.





It is quite sensitive hence the denture should have an appropriate labial notch.

**Buccal frenum:** It is either U-shaped or narrow V-shaped must have enough space in order to get proper denture seal

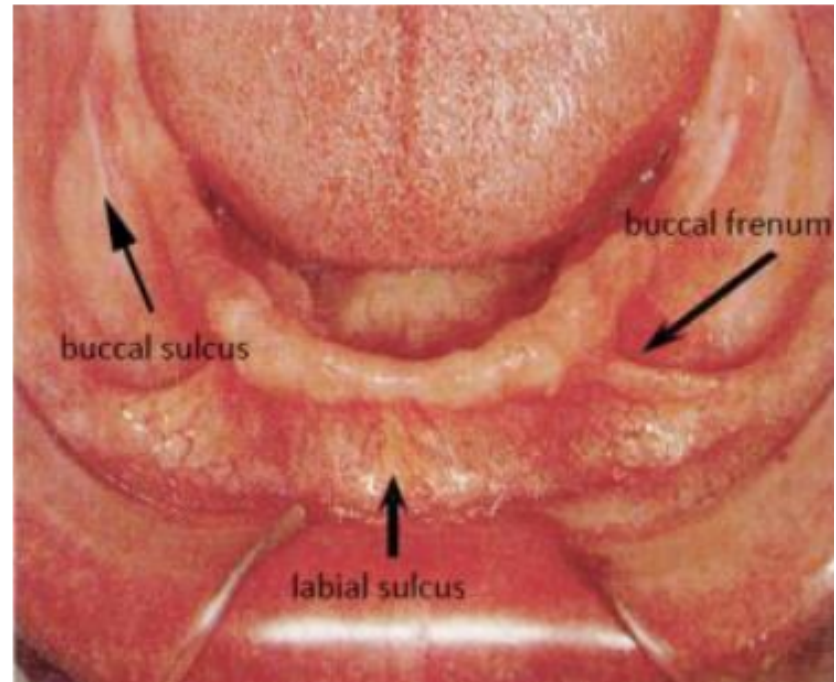




## B) Labial & buccal vestibule

The labial sulcus runs from the labial frenum to the buccal frenum on each side.

The buccal sulcus extends posteriorly from the buccal frenum to outside back corner of the retromolar region.

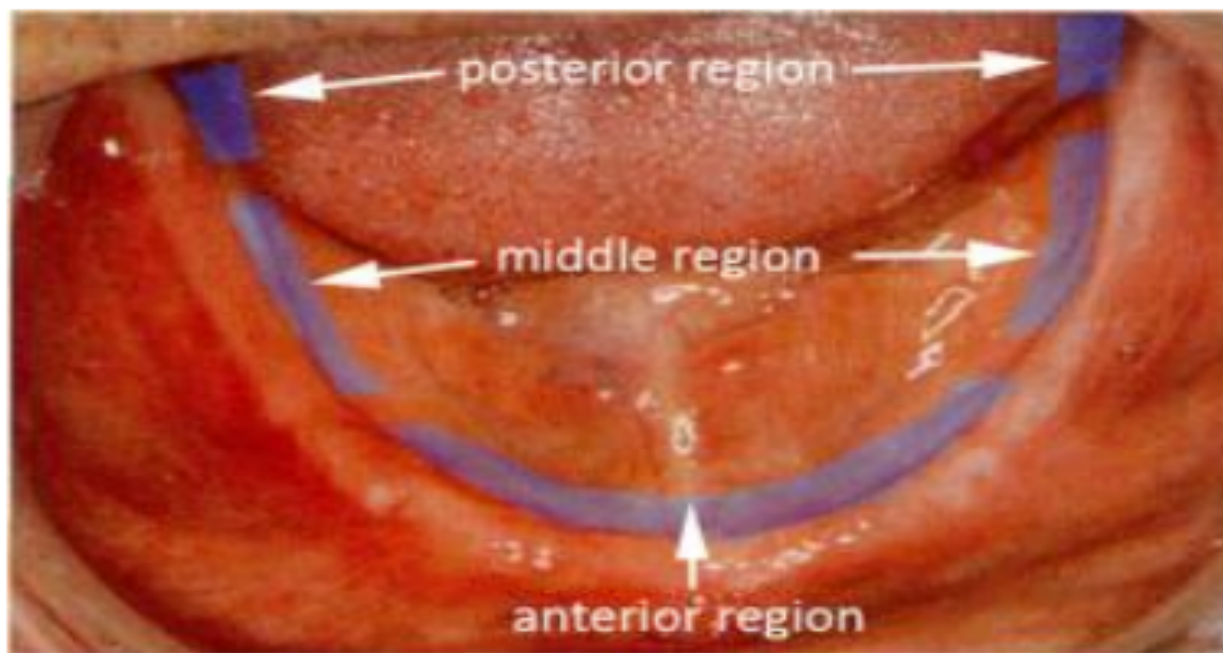


## C) Alveololingual sulcus

Between lingual frenum to retromylohyoid curtain.

Overextension causes soreness and instability.

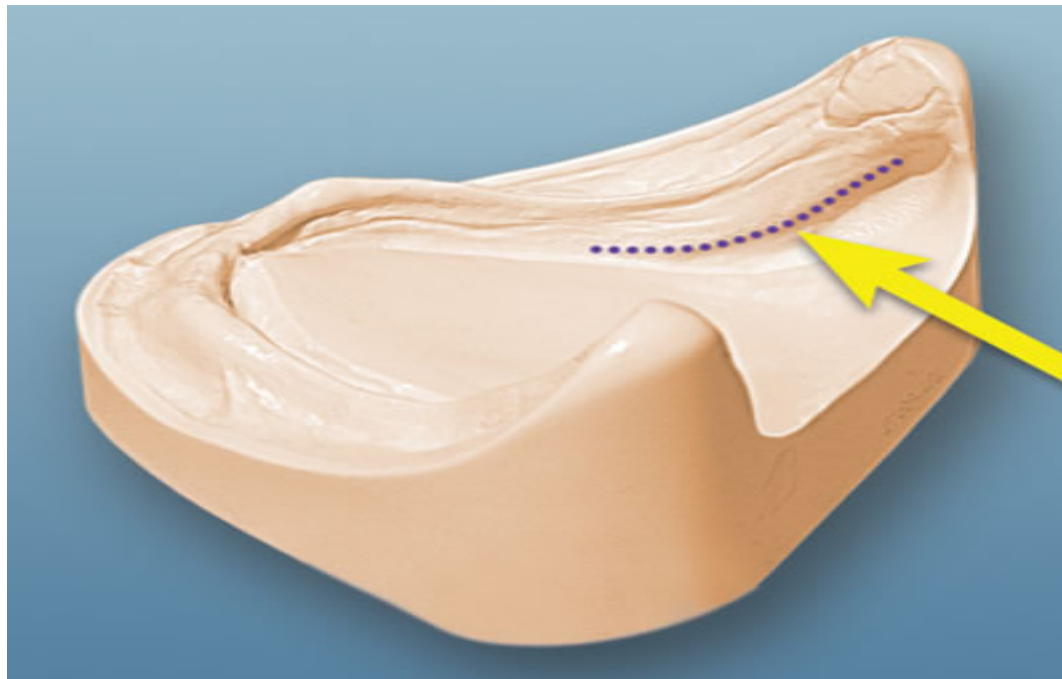
It can be divided into three parts:



## i) Anterior part :

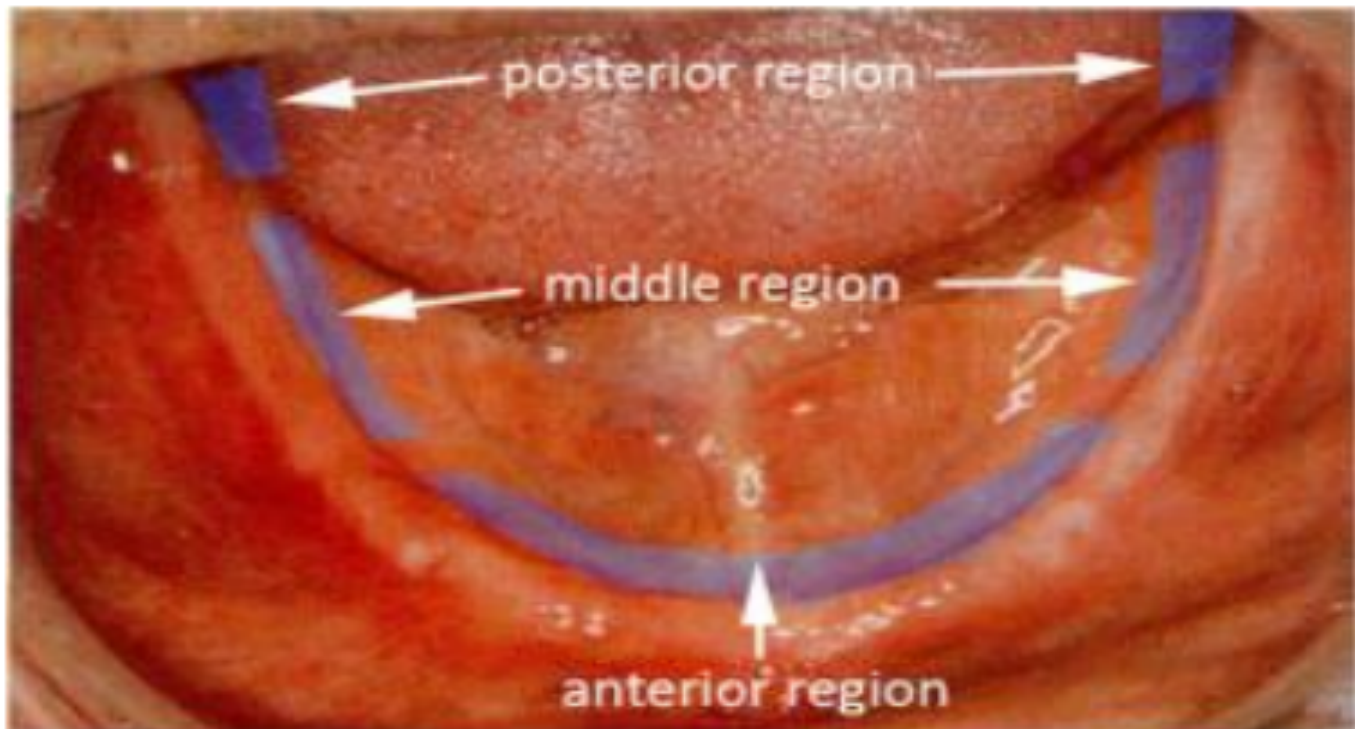
From lingual frenum to mylohyoid ridge

The shallowest portion(least height) of the lingual flange



## ii) Middle region :

From the premylohyoid fossa to the the distal end of the mylohyoid region



### iii) Posterior portion :

From the end of the mylohyoid ridge end to the retromylohyoid curtain

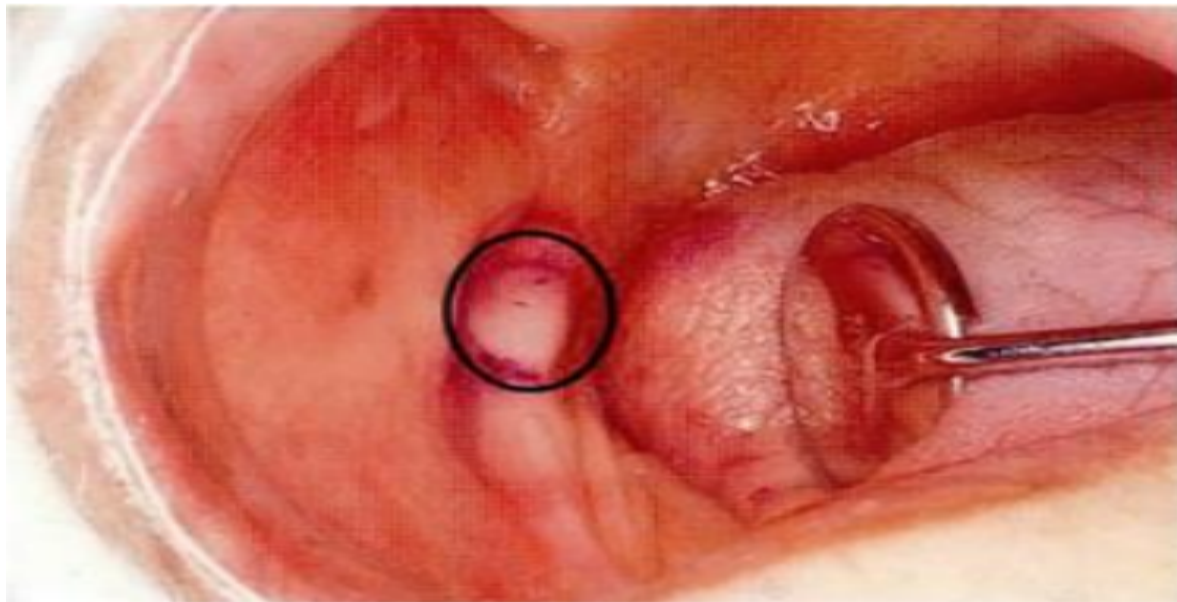Provides for a valuable undercut area so important retention

**Overextension** causes soreness and instability

## D) Retromolar pad

Pear-shaped triangular soft pad of tissue at the distal end of the lower ridge is referred to as the retromolar pad.

- **It is an important structure**, which forms the posterior seal of the mandibular denture.
- The denture base should **extend up to 2/3rd** of the retromolar pad triangle.



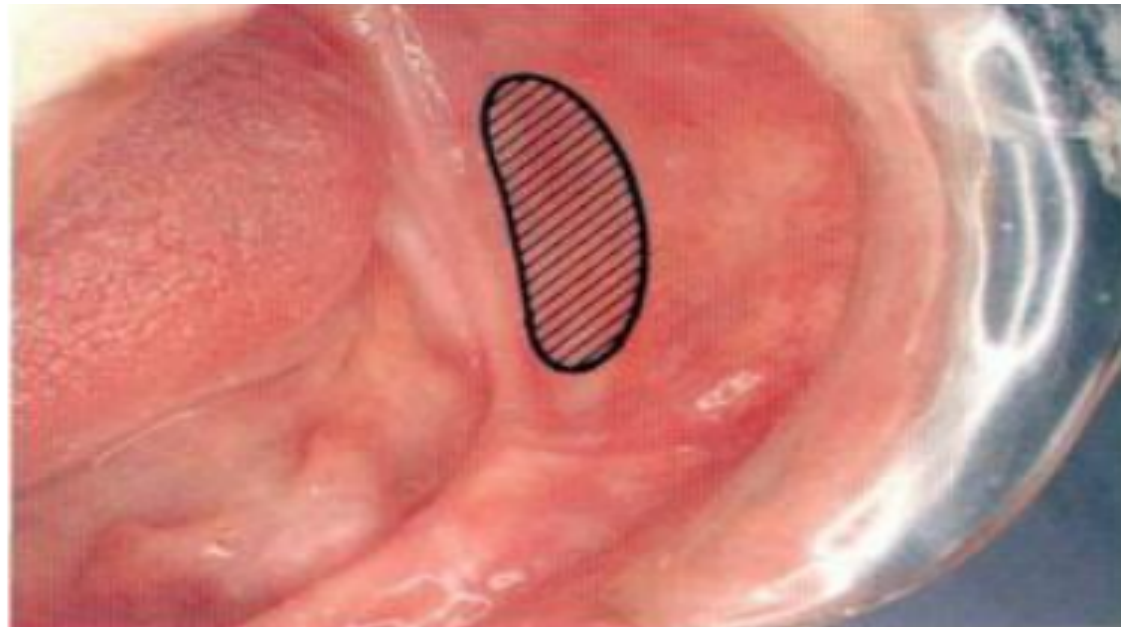
# SUPPORTING STRUCTURES



## A) Primary stress bearing area / Supporting area

### Buccal shelf area

- Extends from buccal frenum to retromolar pad.
- Between external oblique ridge and crest of alveolar ridge.

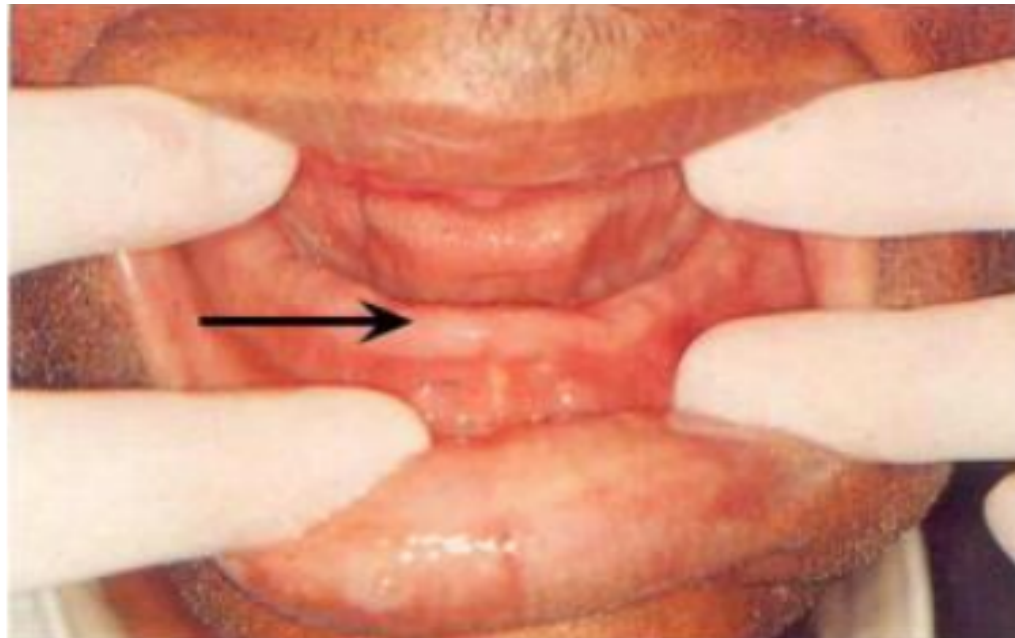



## B) Secondary stress bearing area / Supporting area

### Residual alveolar ridge

Buccal and lingual slopes are secondary stress bearing areas.



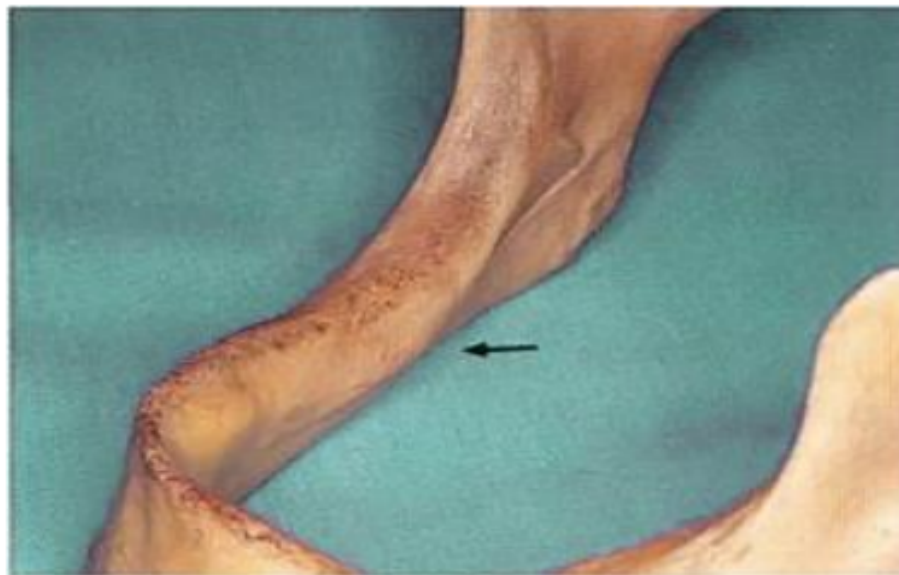
# RELIEF AREAS

## A) Mylohyoid ridge

Attachment for the mylohyoid muscle.

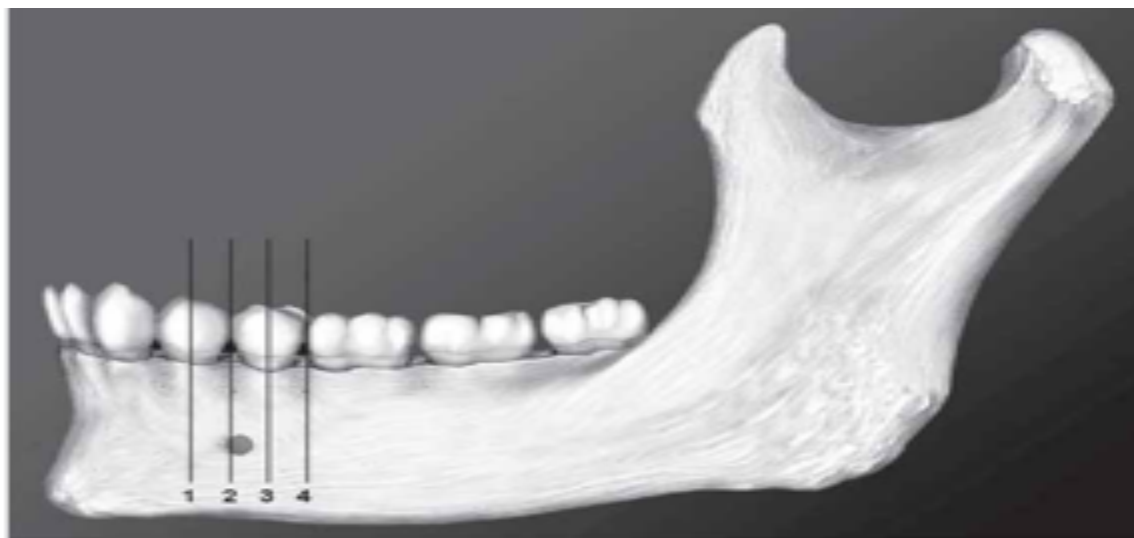
Running along the lingual surface of the mandible.

Covered by the thin mucosa which may be traumatized by denture base hence it should be relieved.



## B) Mental foramen

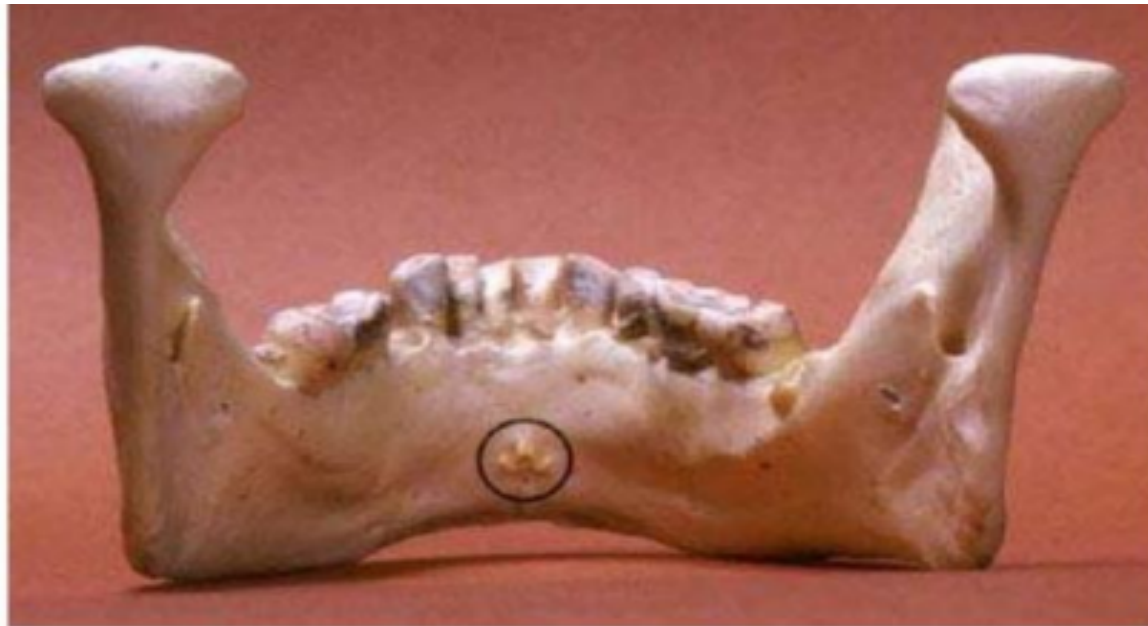- Lies on the external surface of the mandible in between the 1st and the 2<sup>nd</sup> premolar region.
- It should be relieved specially in case it lies close to the residual alveolar ridge due to ridge resorption to prevent parasthesia.



*Fig. 1. Position of the mental foramen in relation to mandibular*

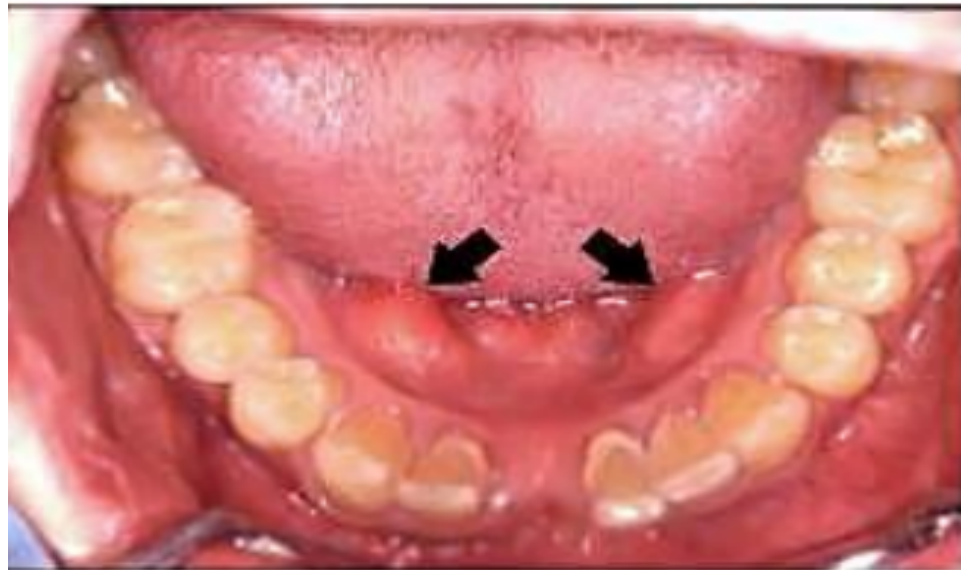## C) Genial tubercle

- pair of bony structures found anteriorly on the lingual side of mandible
- Area of muscle attachment (Genioglossus and Geniohyoid).
- Prominent in resorbed ridges therefore adequate relief to be provided



## D) Torus mandibularis

- Abnormal bony prominence.
- Bilaterally on the lingual side near the premolar area.
- Covered by thin mucosa so it should be relieved



# Impression for complete denture

Presented by:

Dr. Saraa Almallah

# Impression

It is the **negative replica** of the teeth and surrounding structure in the oral cavity, introduced as a gel form then becomes relatively hard or set while in contact with these tissues.



# Requirements for making impression

- Knowledge of Basic anatomy
- Knowledge of basic reliable technique
- Knowledge and understanding of impression materials
- Skill
- Patient management

Objectives for impression of complete denture; (importance is the sequence)

# 1) preservation

Preservation of the remaining residual ridges is one objective.

the effect of impression technique and impression material on denture base may have continued effect on health of both soft and hard tissue jaws

## 2) Support

It is the resistance to the force try to dislodge the denture in tissue ward direction .

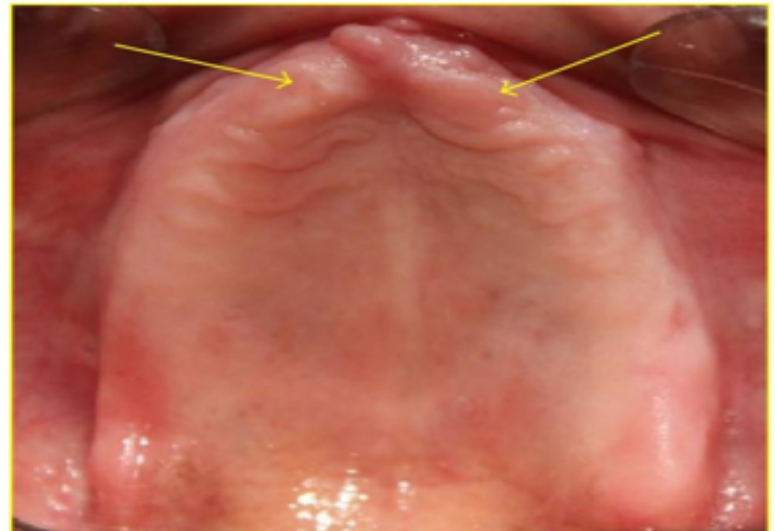
Maximum coverage provides distribution of applied forces over as wide an area as possible and this help in preservation, stability and retention.

### 3) Stability

Stability is resistance to **horizontal or rotational movement** which try to dislodge denture.

#### Stability decrease with the


1. Loss of vertical height of the ridge.
2. increase in movement of flabby movable tissue



## 4) Esthetics

Border thickness varies with the need of each patient in accordance with the extent of residual ridge loss.

**Esthetics depends on thickness of the border** so the vestibule should be filled, but not over filled to restore facial contour.



## 5) Retention

Retention is the resistance to the forces which tries to dislodge the denture in a direction **opposite to the path of insertion** (away from the tissue)

If the other objectives are achieved the retention will be adequate

# Factors affect retention

- a) Atmospheric pressure
- b) Adhesion
- c) Cohesion
- d) Mechanical interlock
- e) Muscle control.
- f) Patient tolerance



# Atmospheric pressure

Depend on peripheral seal, to ensure this seal the denture border should extend into but not to the extent to damage movable tissue.

# Adhesion

It is the attraction of unlike molecule.i.e: it is the attraction of saliva to denture.

# Cohesion

It is the attraction of molecules of saliva to each other.

# Muscle control and Patient tolerance

They are amazing influence. Dentures are often retained in the mouth and appear satisfactory, not because of the accuracy of conforming to the support but because of the adaptability of the muscle of the lip, tongue and cheek and patient tolerance.

# Classificaion of impression technique

# Depending on the theories of impression making

1. non-pressure technique(mucostatic)
2. Selective pressure techniques,
3. pressure techniques

# Non-pressure technique (mucostatic)

Attempts made to record the tissue at rest. It require minimal pressure be applied to the oral tissue during the seating of the impression tray and set of the impression material. it eliminate all distortion of the oral tissue and thus create a denture base that models the unloaded tissue.

# Pressure technique (Mucocompressive)

In this technique the impression is subjected to pressure during taking, this pressures either applied by dentist finger or by the teeth of the patient and in this case it is called **functional impression**



# Selective pressure techniques

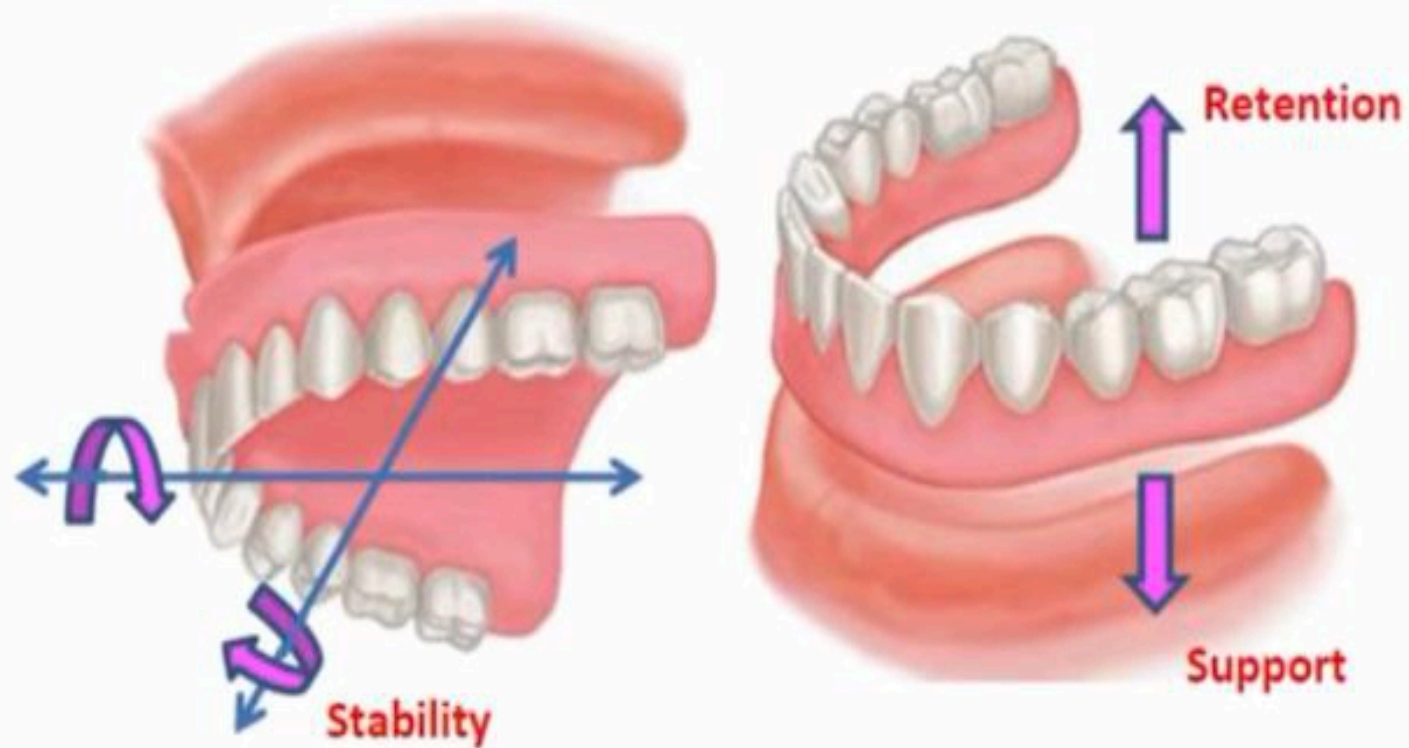Uses a custom tray constructed with less relief in the primary denture stress bearing area and greater relief in the non bearing areas.

Variation in relief result in theoretically in greater amount of pressure being applied directly to the primary bearing area ,which are biologically and biomechanically more capable of supporting and distributing the load.

This technique seeks to create a denture base that selecting loads the oral tissue during function of the prostheses, thus optimizing the stability and retention of the prostheses.

Impression can be classified depend on the sequence of the impression into:

1. Primary impression.
2. Secondary (final) impression).



*Figure (3-1): Retention, support, and stability.*