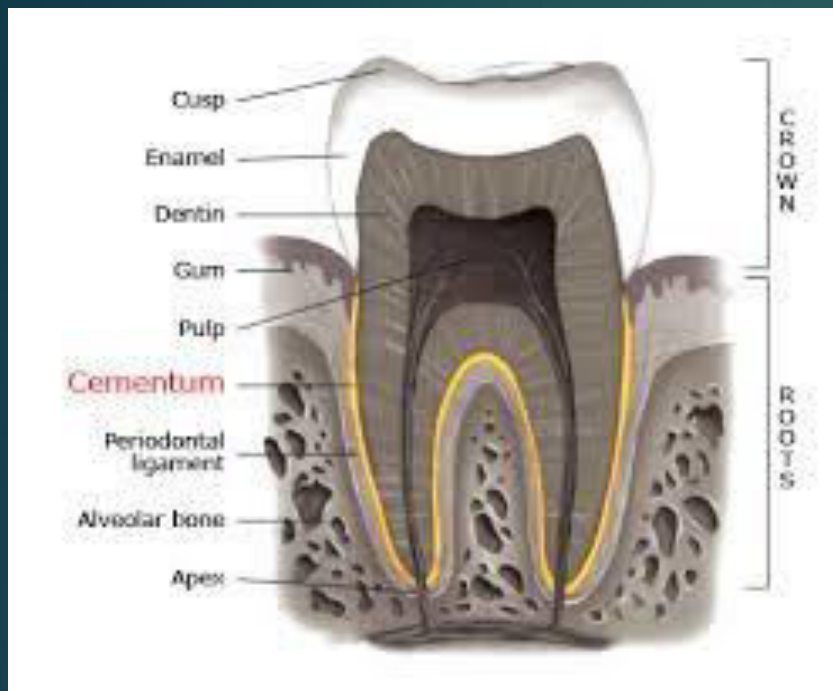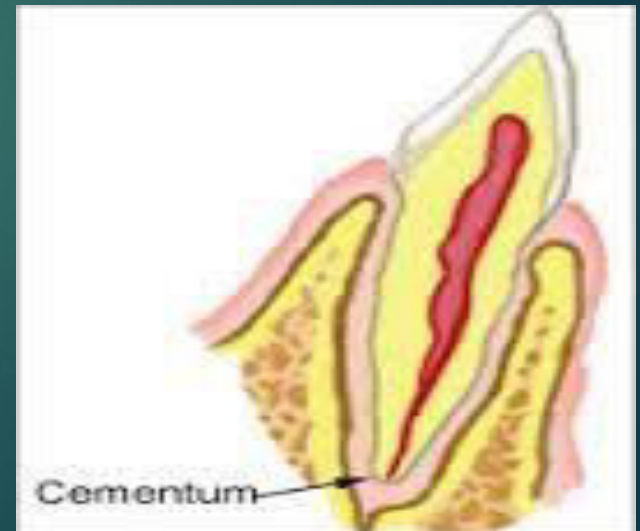




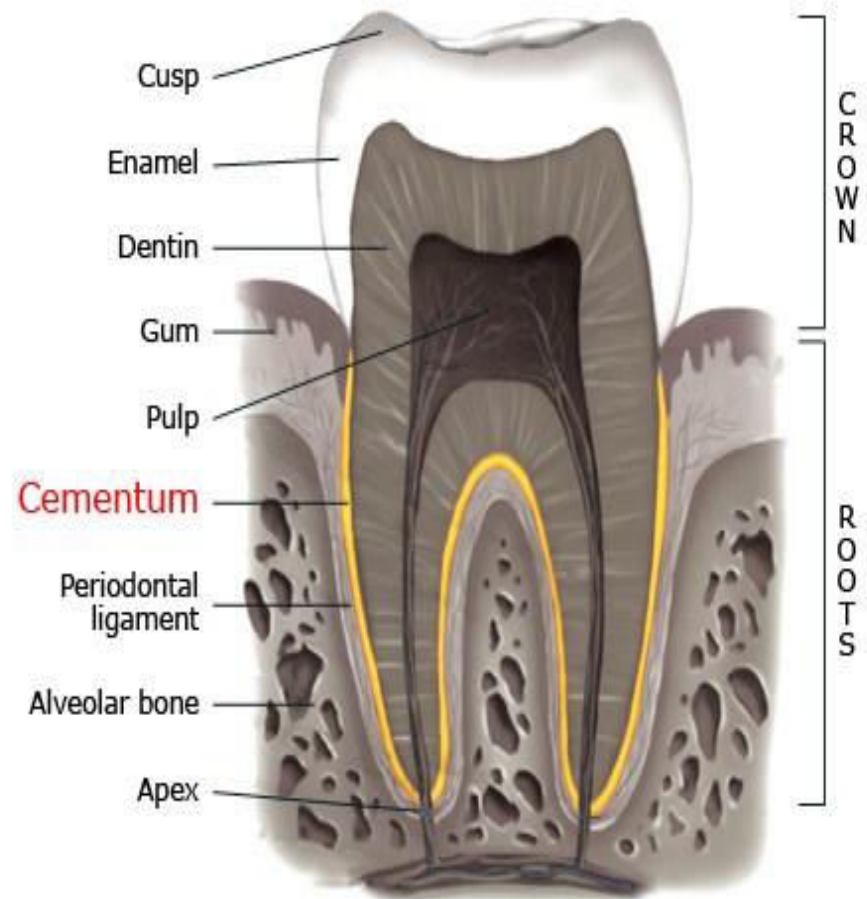
# Cementum

2023

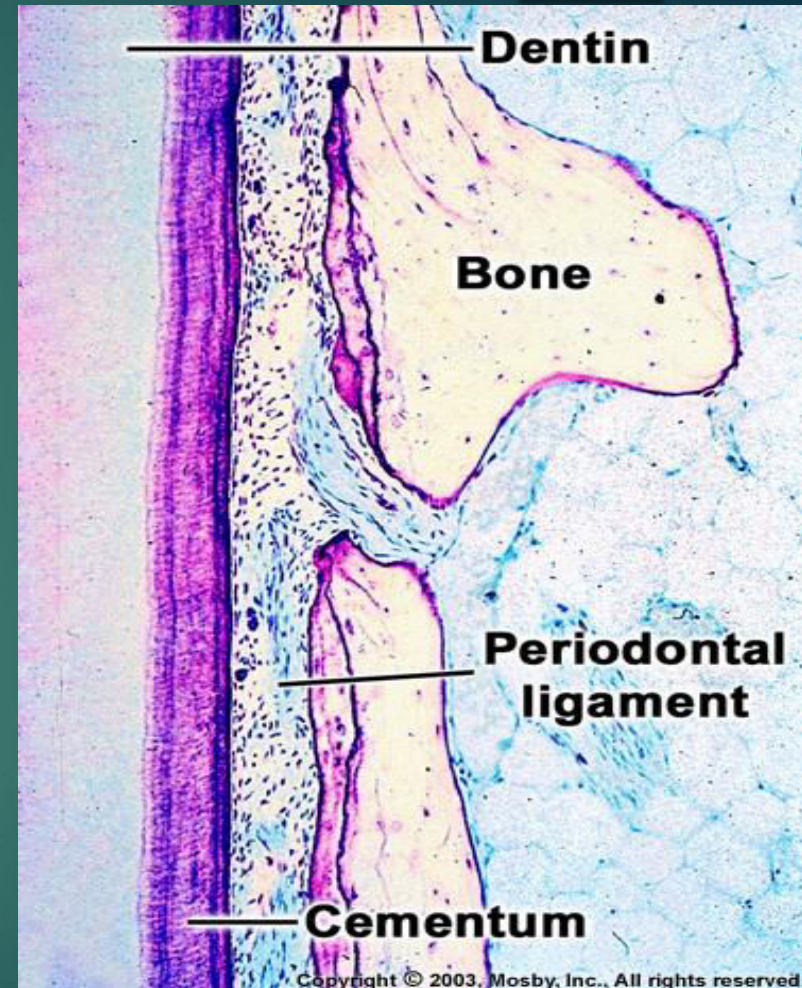


# Introduction

- Mineralized connective tissue covering the anatomic roots of human teeth.
- Begins at cervical portion at the CEJ & continues to the apex.



- ❑ Furnishes a medium for the attachment of collagen fibers that bind the tooth to surrounding structures.
- ❑ Makes functional adaptation of the teeth possible.
- ❑ Unlike bone, human cementum is avascular.



# Physical Characteristics

- ❑ Hardness: Cementum < Dentine
- ❑ Light yellow in color.
- ❑ Semi-permeable to a variety of materials.



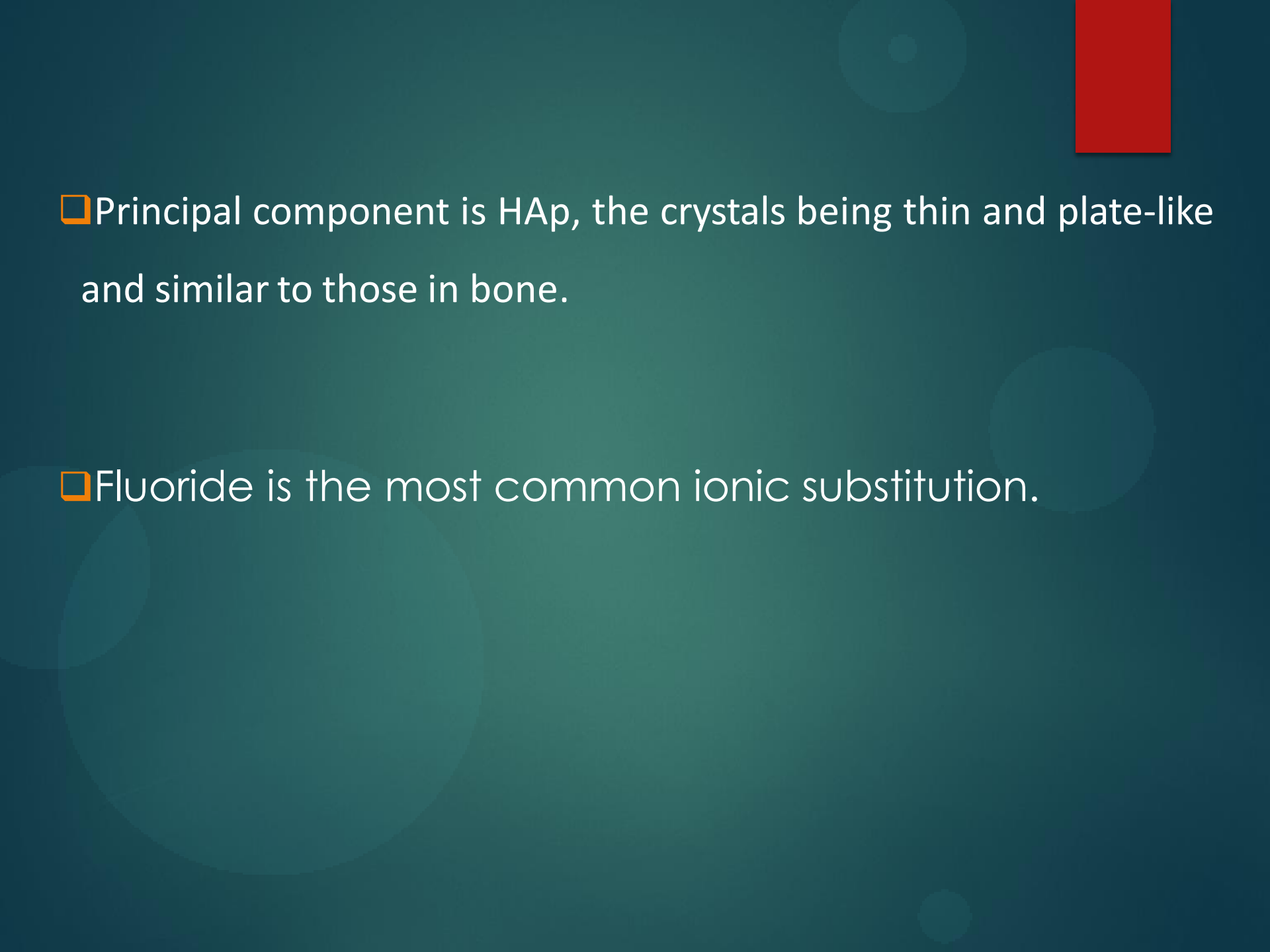
# Cementum Composition

```
graph LR; A[Cementum Composition] --- B[Inorganic Mineral 45-50%]; A --- C[Organic Matrix & Water 50-55%]
```

Inorganic Mineral 45-50%

Organic Matrix & Water  
50-55%


# Inorganic Mineral

- 
- ❑ Principal component is HAp, the crystals being thin and plate-like and similar to those in bone.
  - ❑ Fluoride is the most common ionic substitution.

# Organic Matrix

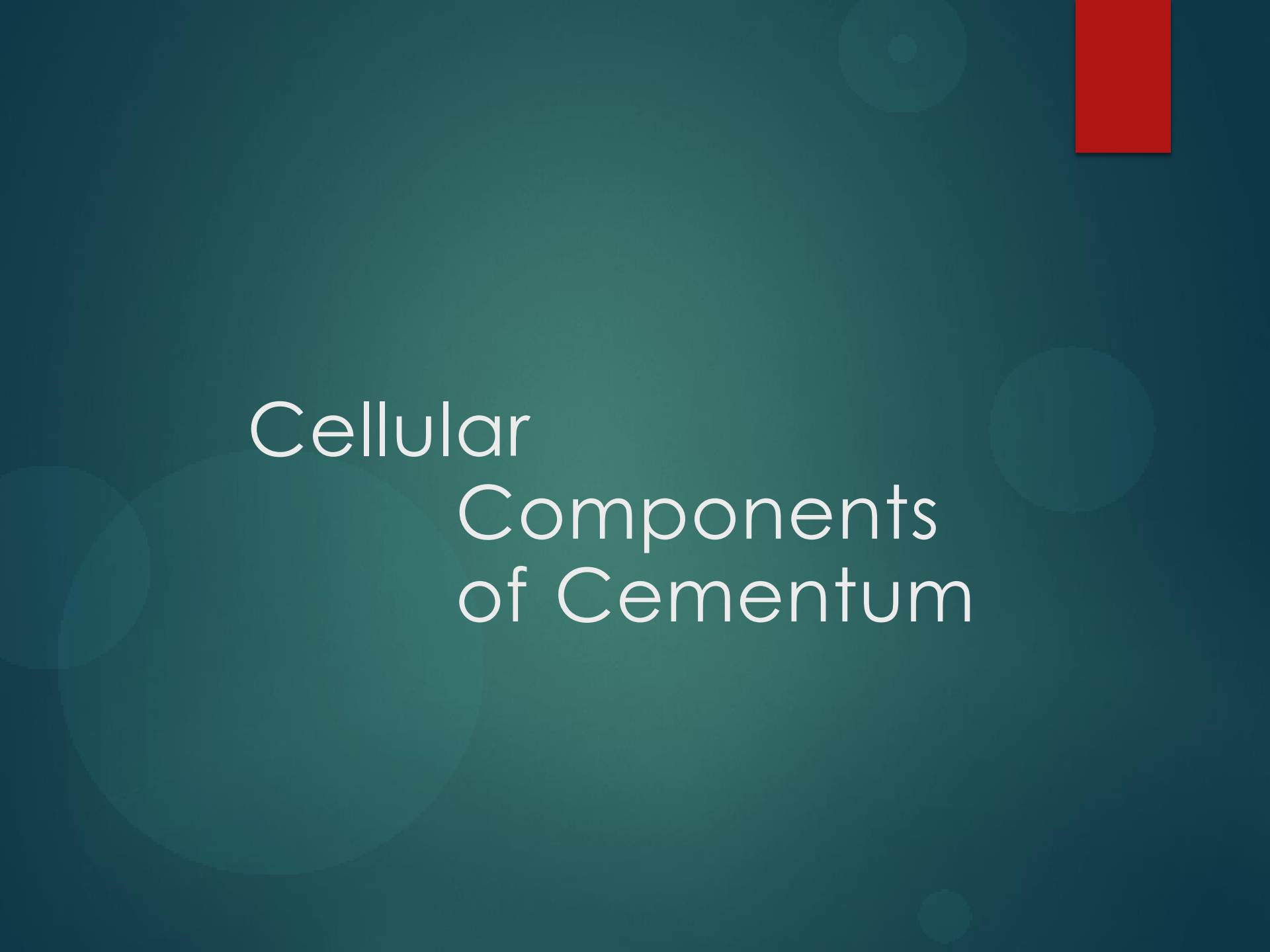
**Collagen (90%)**

**Non-Collagenous  
Proteins (10%)**

- 
- ❑ The organic matrix is collagen, with non-collagenous proteins being thought to be the same as in alveolar bone.
  - ❑ Collagen accounts 90% of the organic matrix, majority being type I collagen with some trace amounts of type III, mainly at the insertion points of the extrinsic Sharpey fibres.
  - ❑ Trace amounts of other types of collagen have also been reported.



- ❑ The non-collagenous matrix accounts 10% of the organic matrix.
- ❑ Important non-collagenous molecules found in cementum are the **proteoglycans and fibronectin**.
- ❑ There may be present a cementum-specific glycoprotein called ***Cementum Attachment Protein (CAP)*** that promotes the attachment of mesenchymal cells to the extracellular matrix.

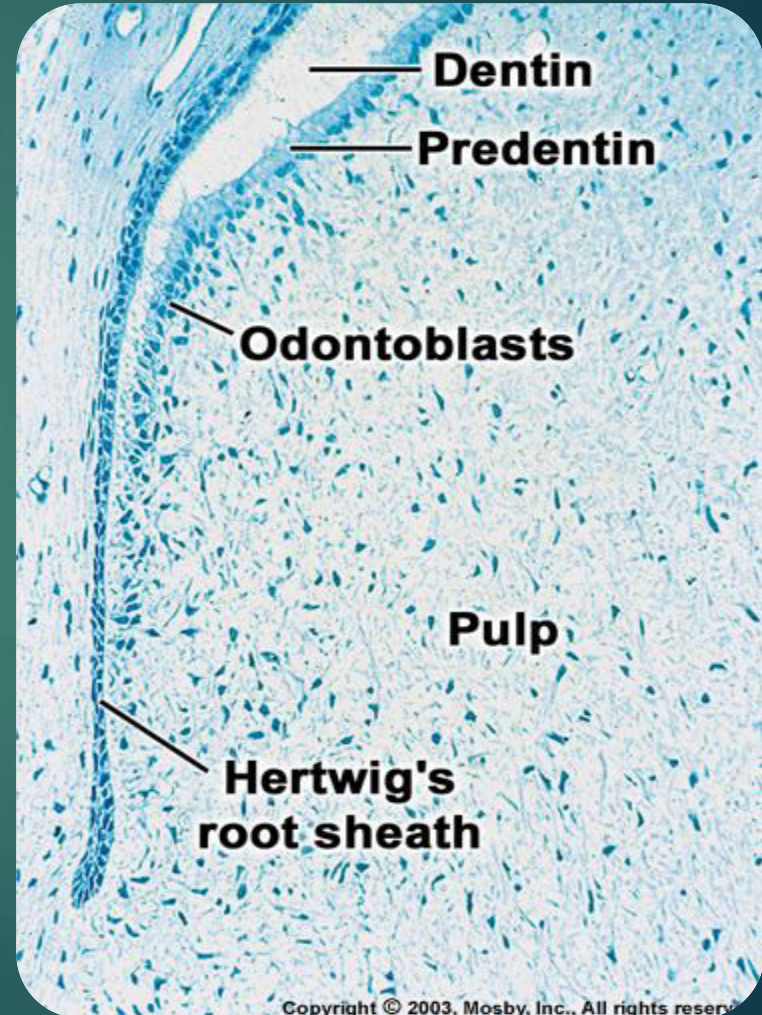
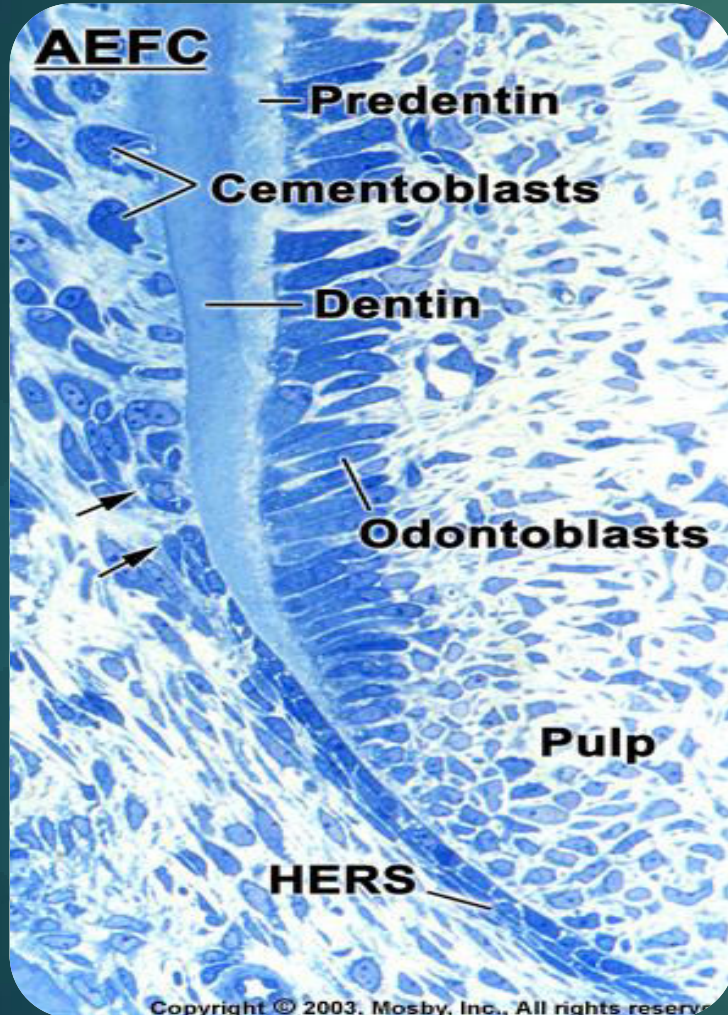
The background is a dark teal color with several lighter teal circles of varying sizes scattered across it. A solid red rectangle is positioned in the top right corner.

# Cellular Components of Cementum

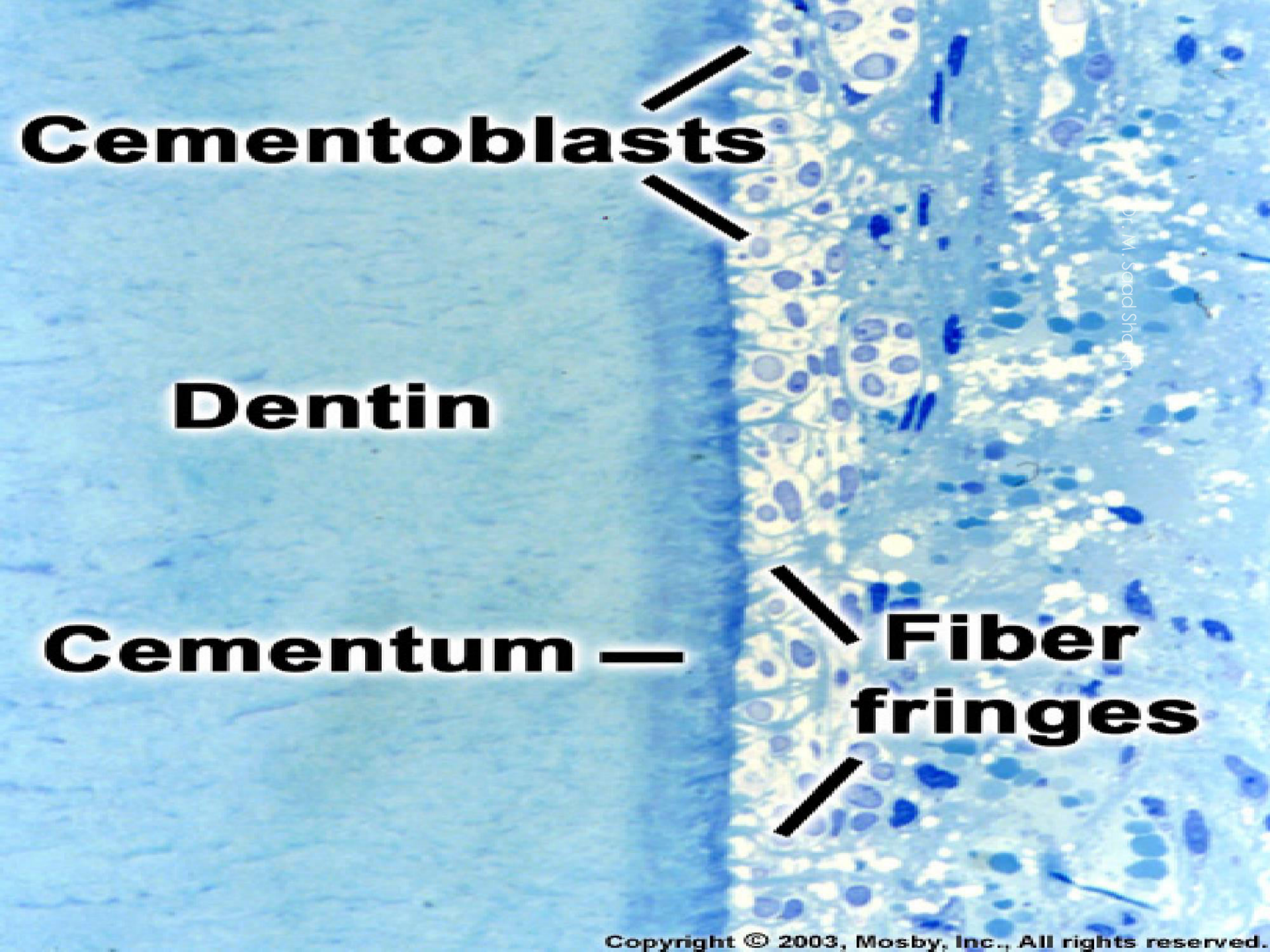
# Cementoblasts

- ❑ Following Hertwig's sheath fragmentation, *undifferentiated mesenchymal cells* from adjacent connective tissue differentiate into cementoblasts.
- ❑ Synthesize *collagen & protein polysaccharides* which makes up the cementum organic matrix.
- ❑ Have numerous mitochondria, a well-formed golgi apparatus, & large amounts of granular ER.

# CEMENTOGENESIS







Dr. M. Saad Shams

**Cementoblasts**

**Dentin**

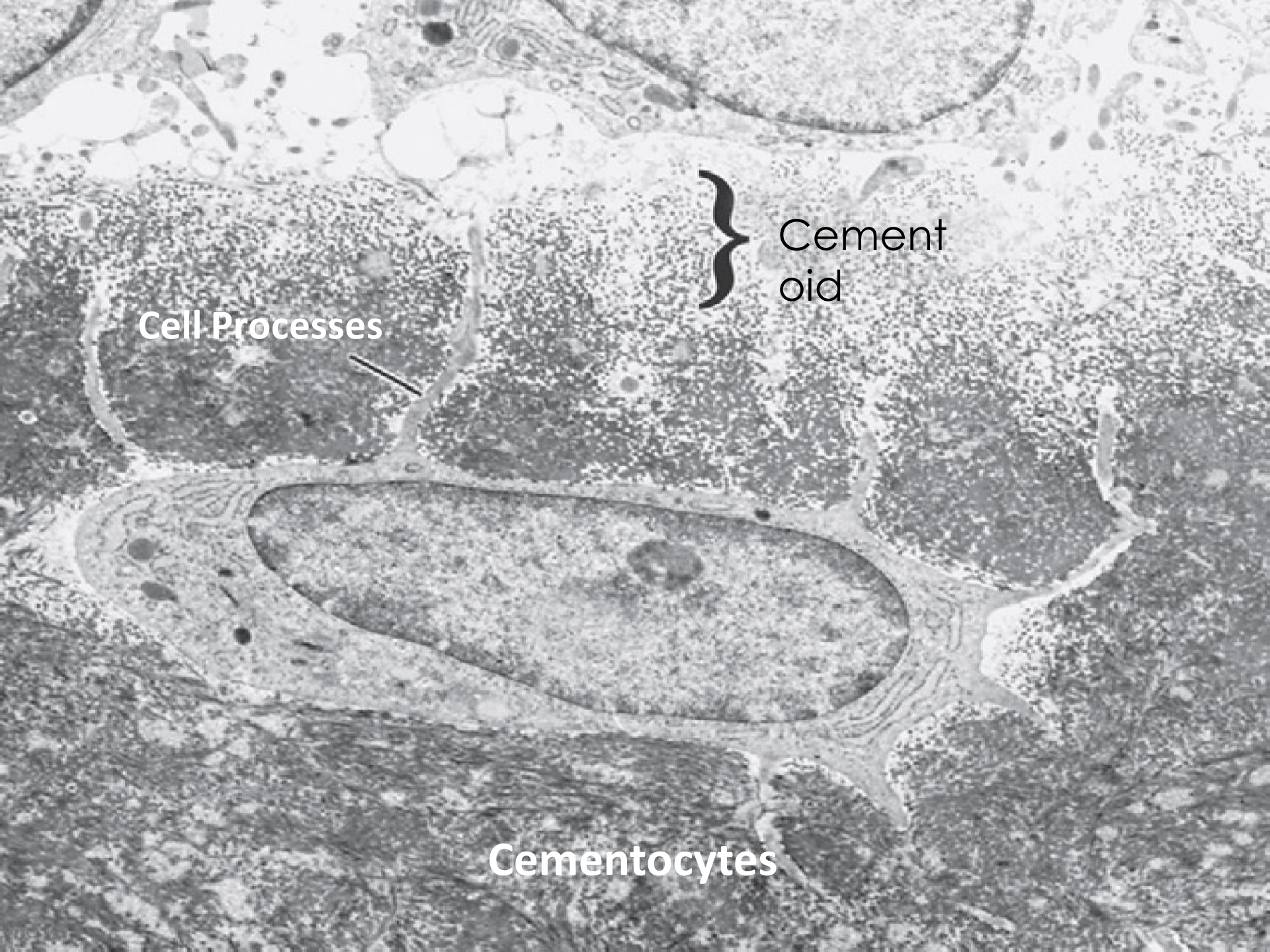
**Cementum —**

**Fiber  
fringes**



# Cementocytes

- ❑ Represents entrapped cementoblasts.
- ❑ Relatively inactive.
- ❑ Spaces that cementocytes occupy in cellular cementum → *Lacunae*.
- ❑ Channels that their processes extend along → *Canaliculi*.



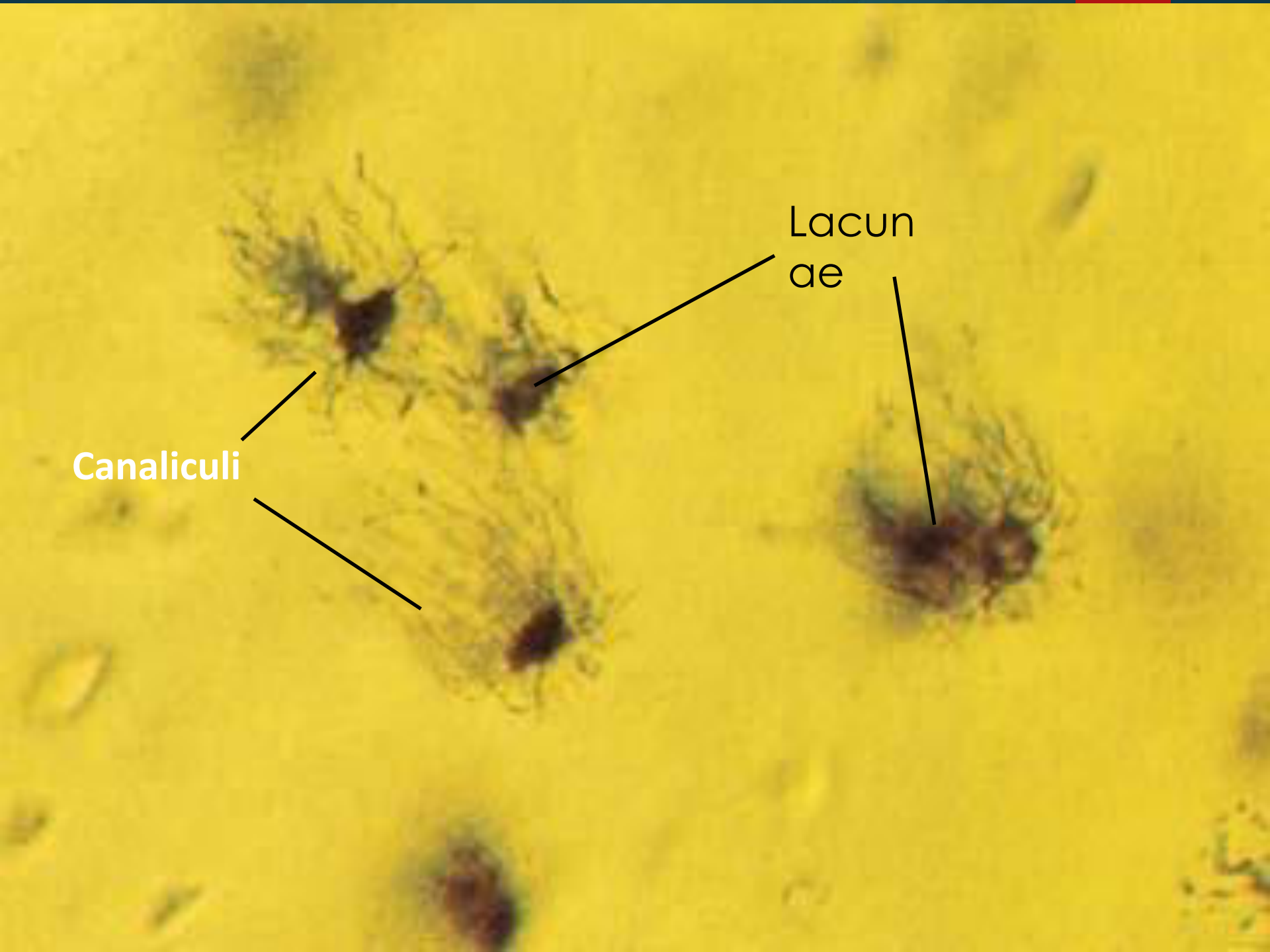
Cell Processes

Cement  
oid

Cementocytes

Canaliculi

Lacun  
ae



# Cementoid Tissue

- ❑ The **uncalcified matrix** is called cementoid.
- ❑ Mineralization of cementoid is a highly ordered event.
- ❑ Fibers are embedded in the cementum & serve to attach the tooth to surrounding bone. Their embedded portions are known as *Sharpey's fibers*.



**Periodontal  
ligament**

A histological section of a tooth root. The left side shows the dentin with a wavy, layered appearance. The middle section is the periodontal ligament, which contains a dense network of fibers. A prominent vertical line of Sharpey's fibers runs through the center of the ligament. The right side shows the bone, which has a more porous, trabecular structure. Labels with leader lines point to the periodontal ligament, Sharpey's fibers, and the bone.

**Bone**

**Sharpey's  
fibers**

**Dentin**



# Types of cementum :

1- Cementum containing cells :

- a. Cellular cementum
- b. Intermediate cementum

2- Acellular cementum

Based on fibrillar connotation :

# I) Based on cellular connotation

:

1- Cementum containing cells :

a. **Cellular cementum** is more frequently found on the

apical half of the root where cementum does contain

cementocytes in its matrix .

b. **Intermediate cementum**

Intermediate cementum is a thin, amorphous layer of hard tissue

approximately 10 micron thick.

it is found intermediate between cementum and dentin

## 2- Acellular cementum :


The matrix of this type of cementum does not involve cementocytes .

However, cementoblasts present on its outer surface and constitute an integral component of acellular cementum .

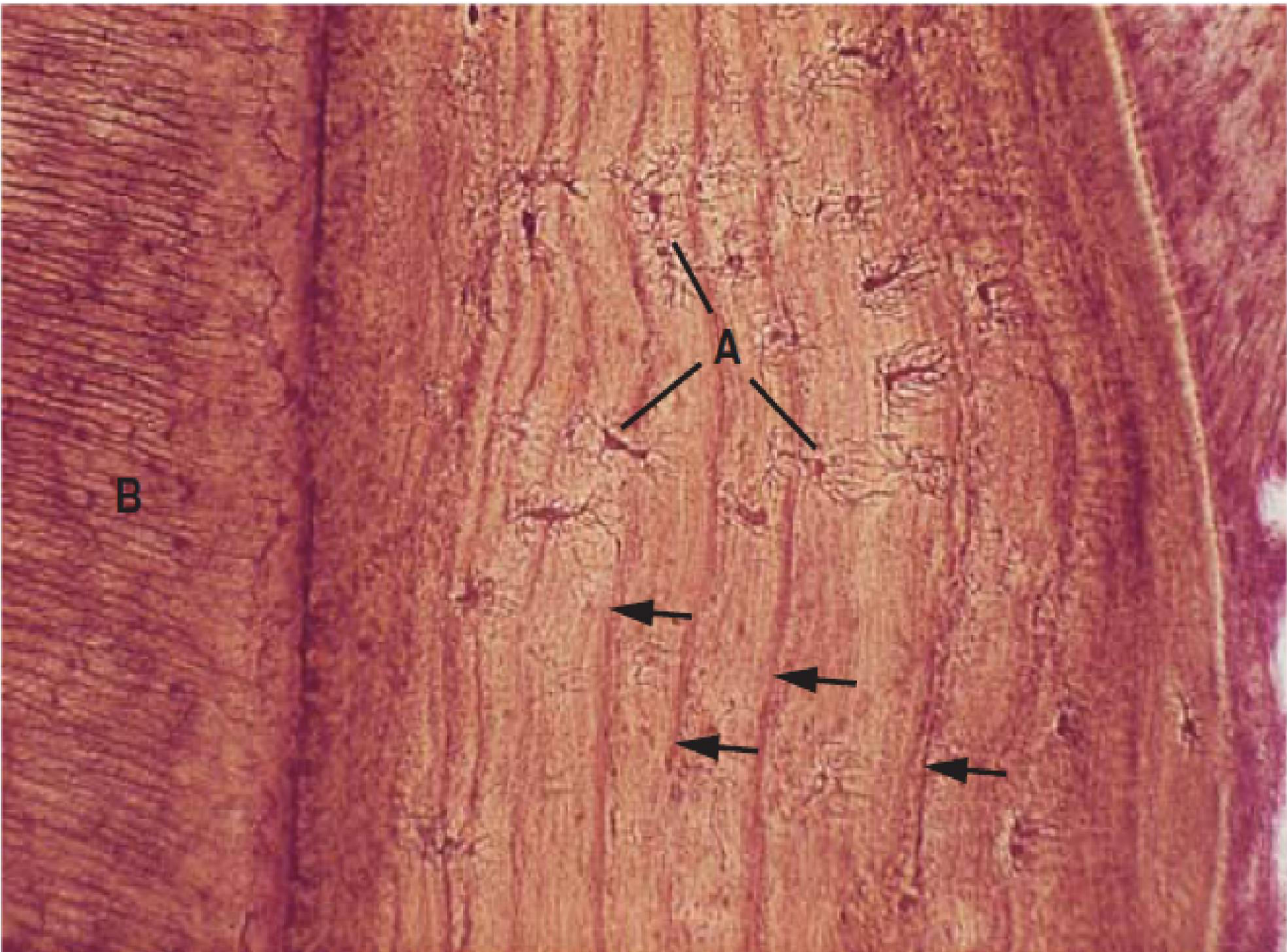# Incremental Lines

- ❑ Cementum is deposited rhythmically, resulting in unevenly spaced incremental lines (*of Salter*).
- ❑ In acellular cementum, incremental lines tends to be closer, thin and even.
- ❑ In the more rapidly formed cellular cementum, the line are further apart, thicker and more irregular.

# INCREMENTAL LINE OF SALTER



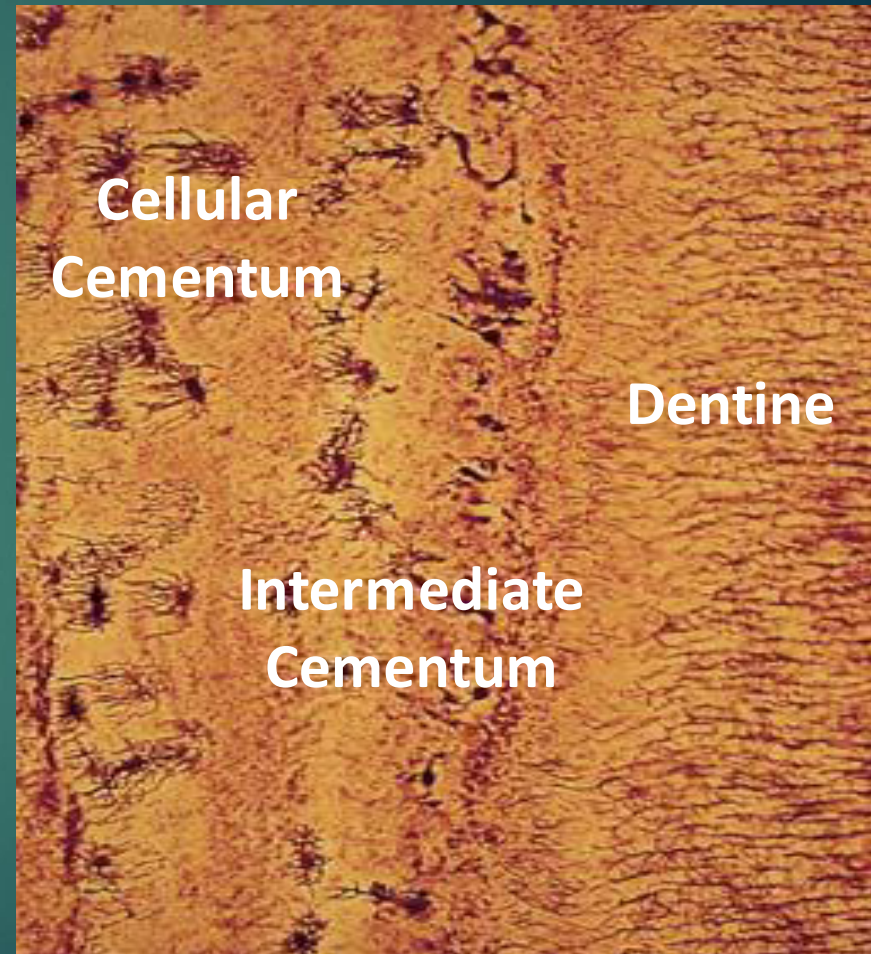






# Cemento-Dentinal Junction

- ❑ Smooth in permanent teeth.
- ❑ Scalloped in deciduous teeth.
- ❑ Dentin is separated from cementum by a layer termed *intermediate cementum*.
- ❑ Predominantly seen in apical 2/3<sup>rd</sup> of molars & premolars.



# Cemento-Enamel Junction

In 60% of the

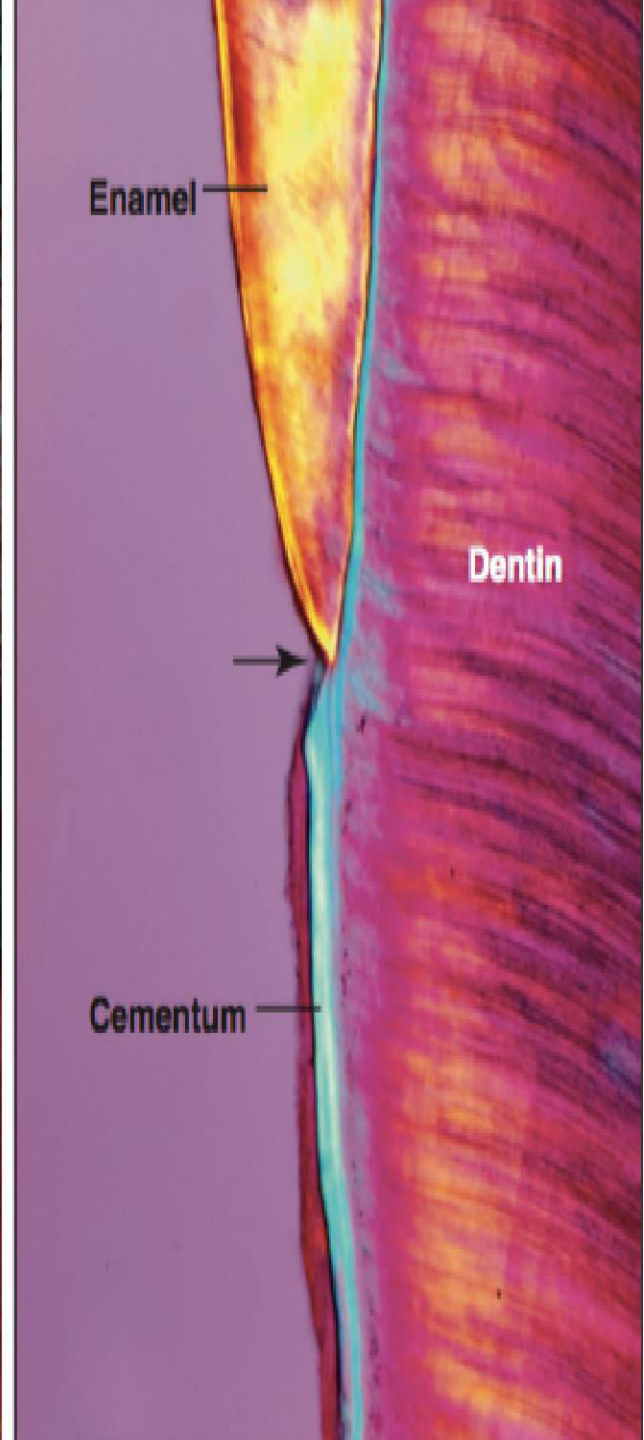
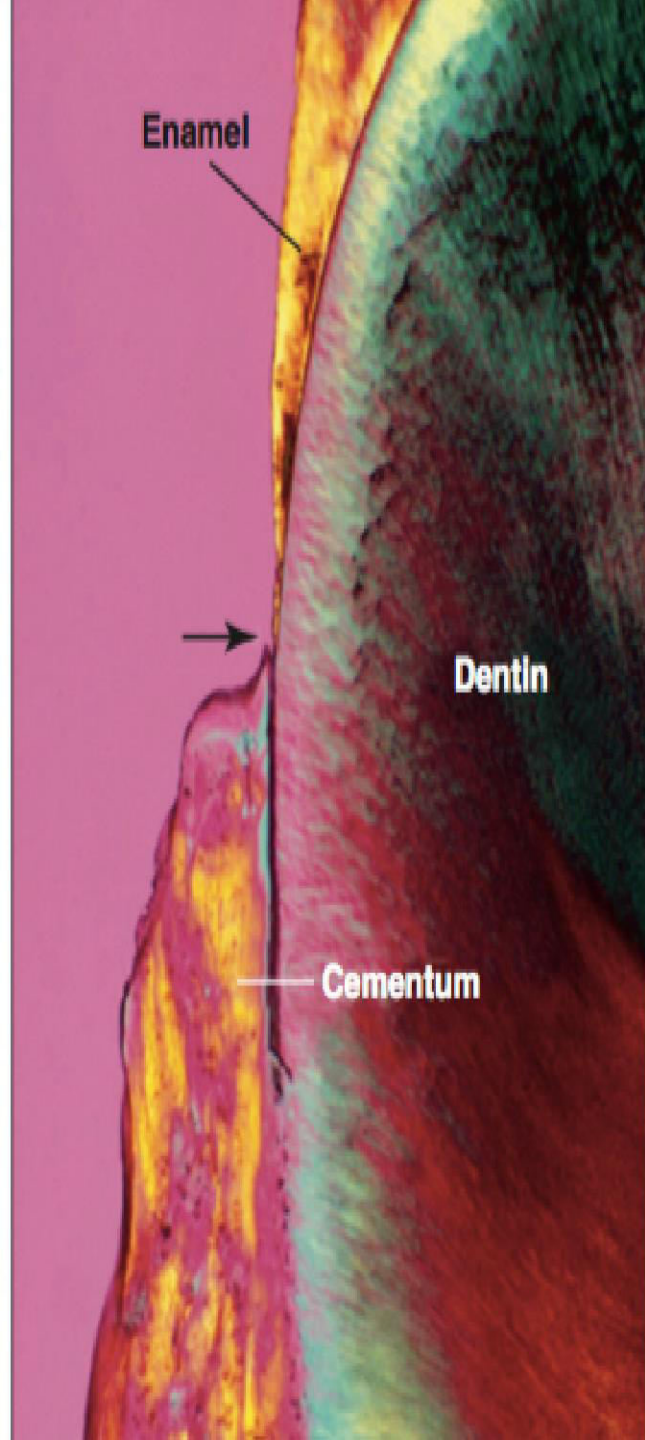
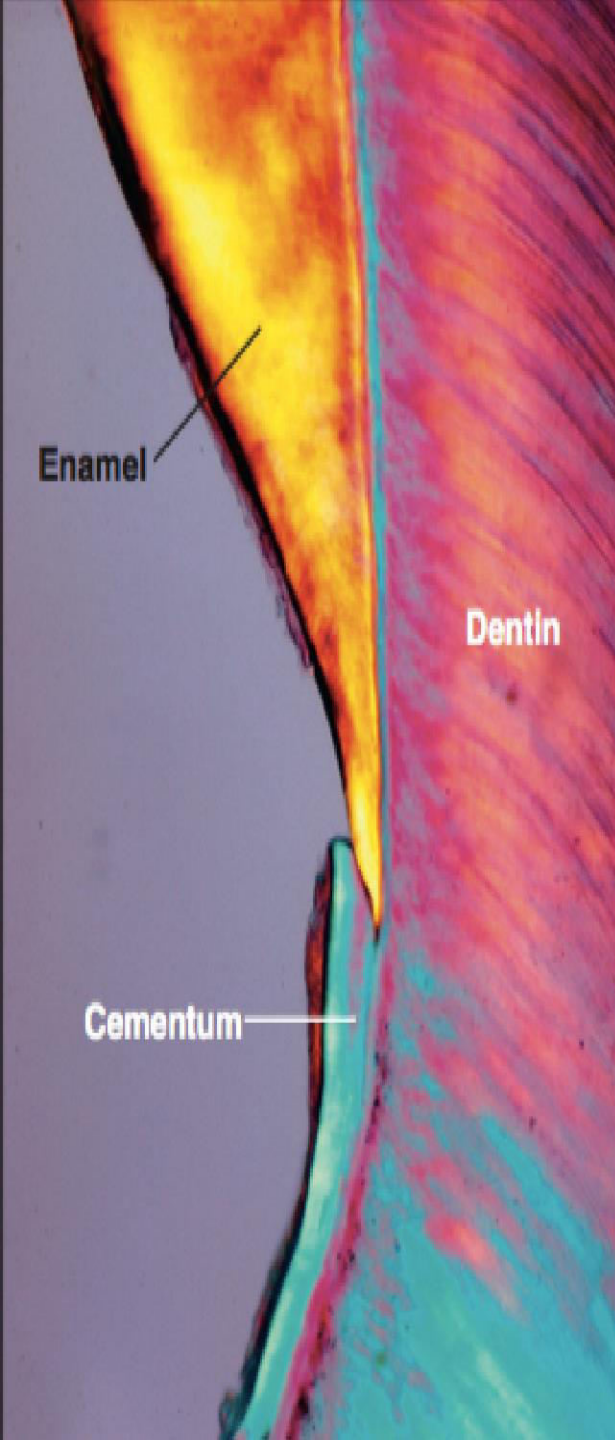
**Cementum overlaps the cervical end of enamel for a short distance.**

In 30% of the teeth

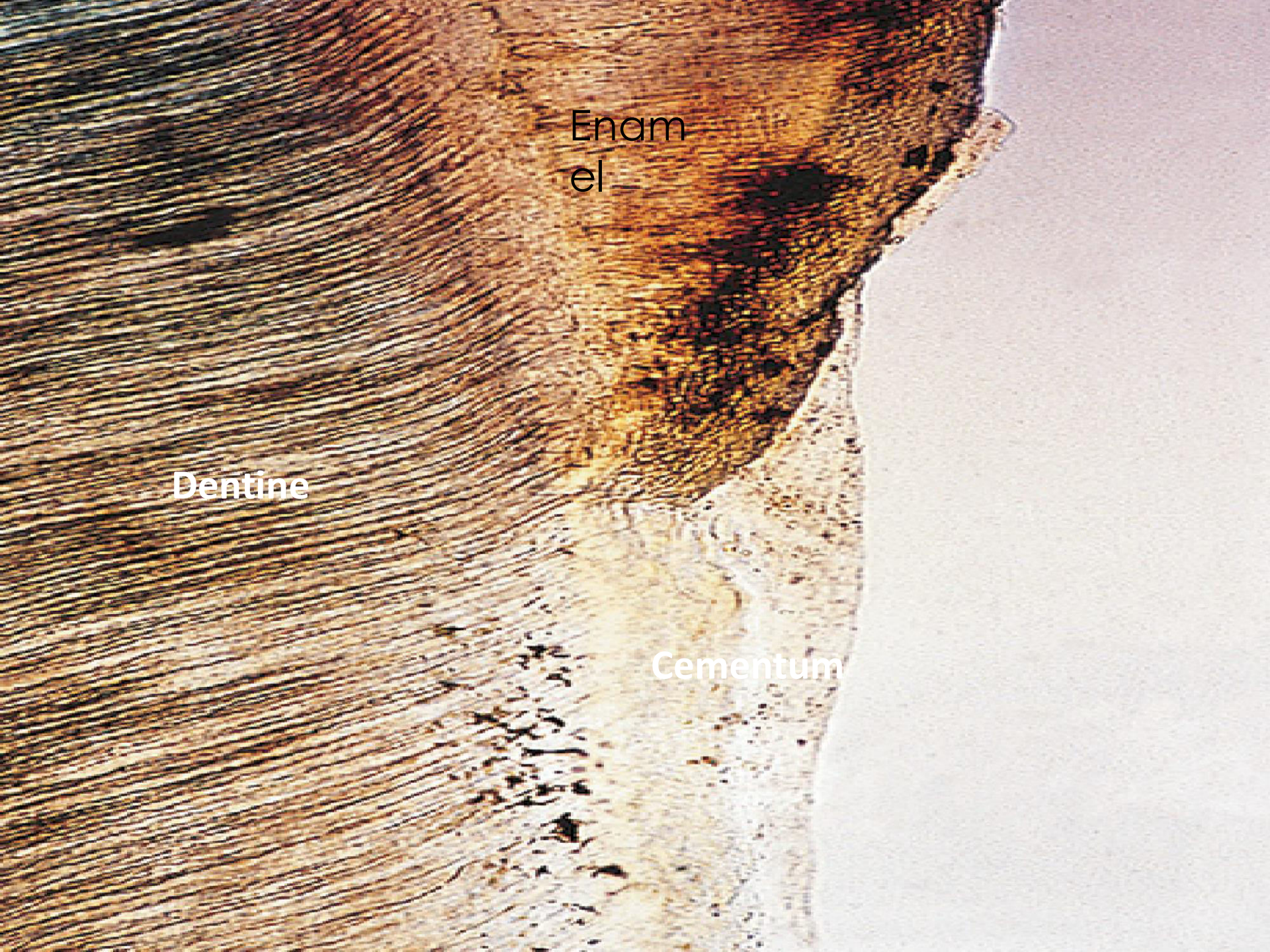
**Cementum meets the cervical end of enamel in a relatively sharp line.**

In 10% of the teeth

**Enamel and cementum do not meet.**







Enam  
el

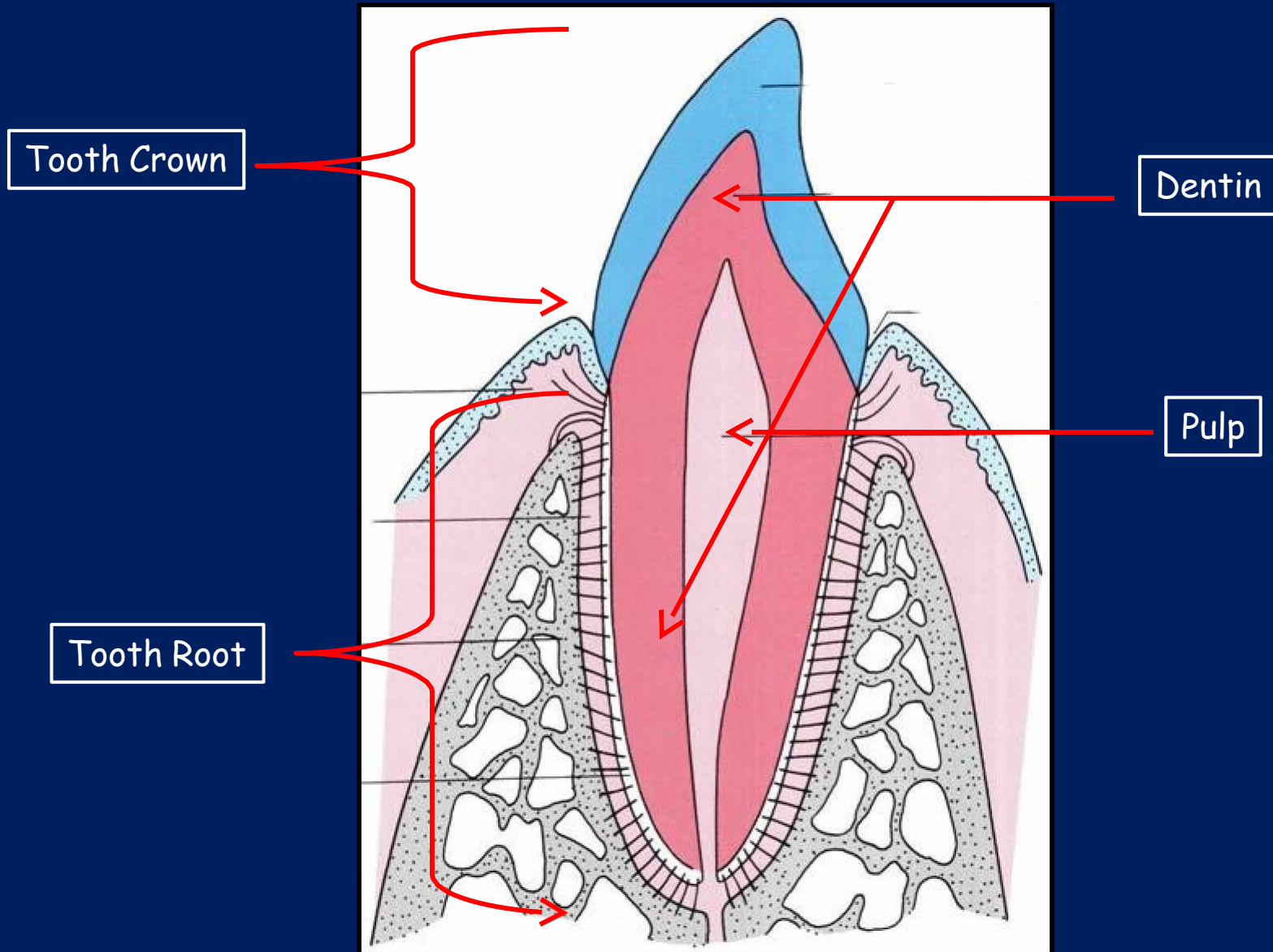
Dentine

Cementum



**DENTIN**

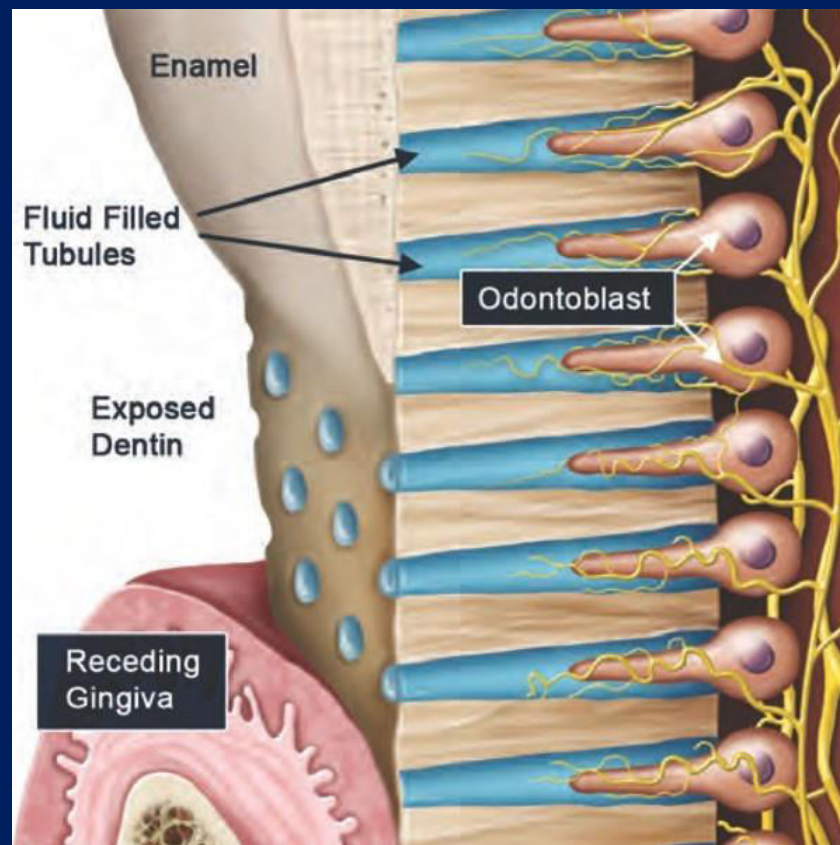
# Tooth



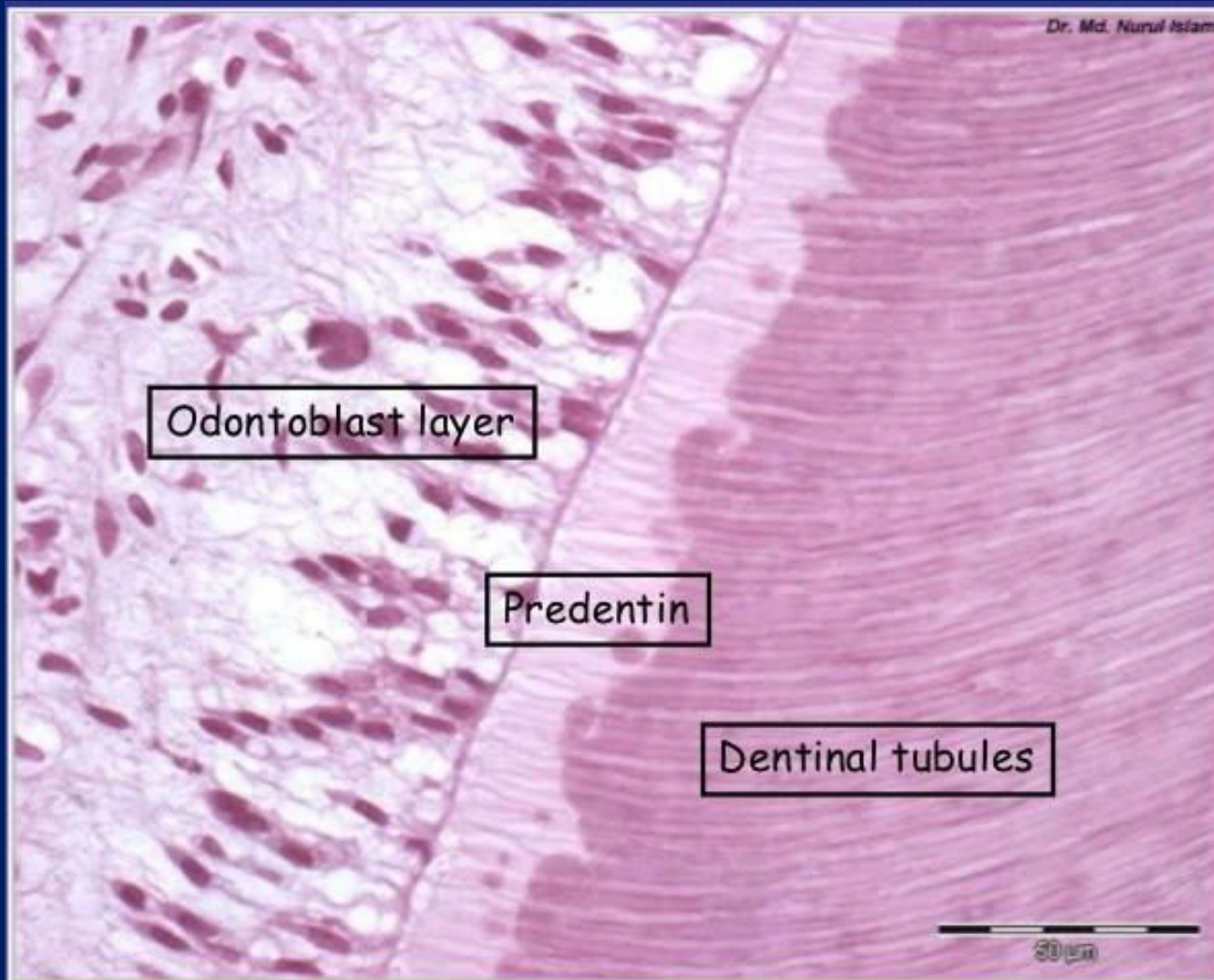


# STRUCTURE

- The bodies of the **odontoblasts** are arranged in a layer on the **pulpal surface** of the dentin, and only their **cytoplasmic processes** are included in the **tubules** in the mineralized matrix.

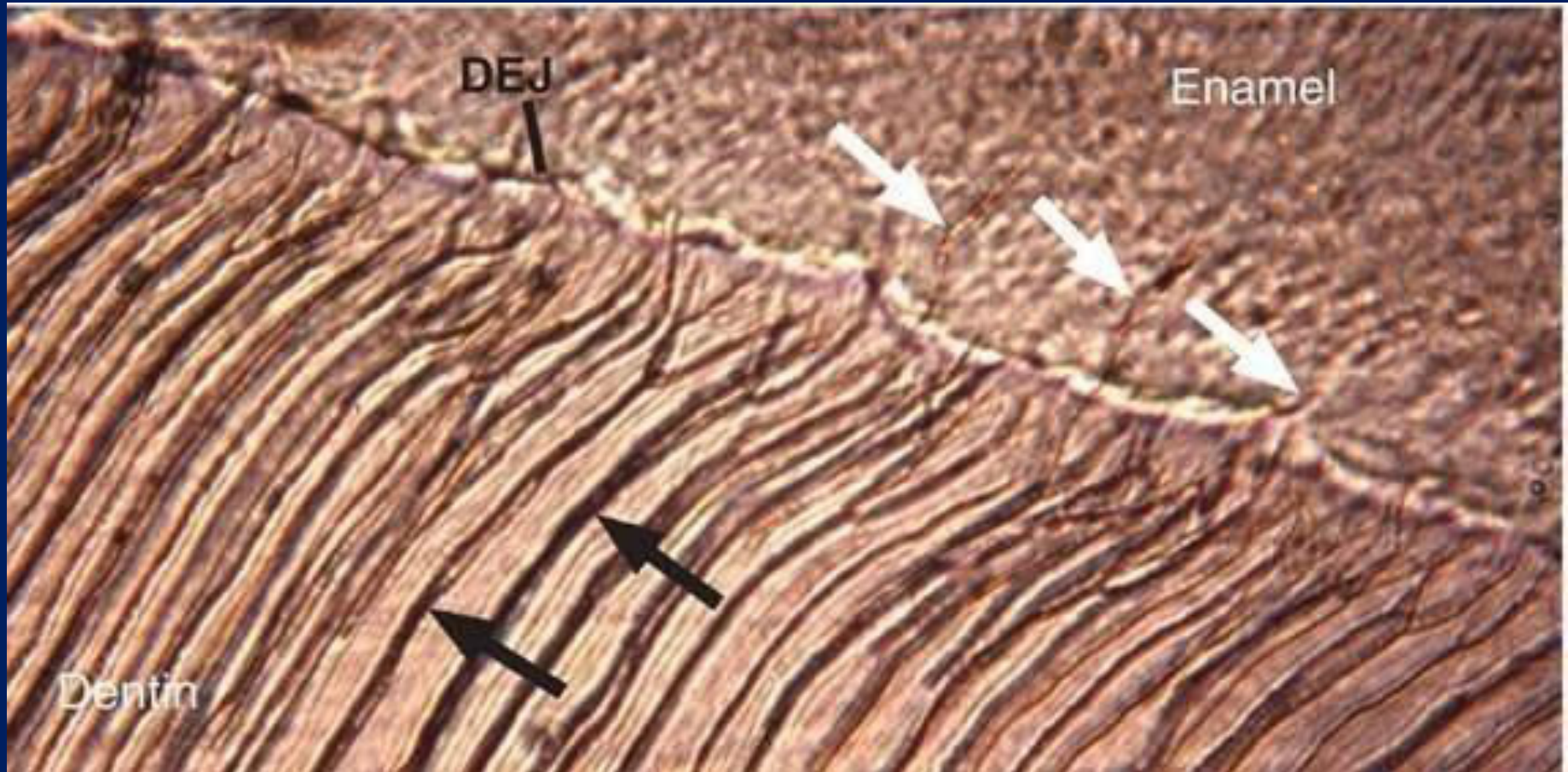


- Each cell gives rise to one process, which traverses the predentin & calcified dentin within one tubule.



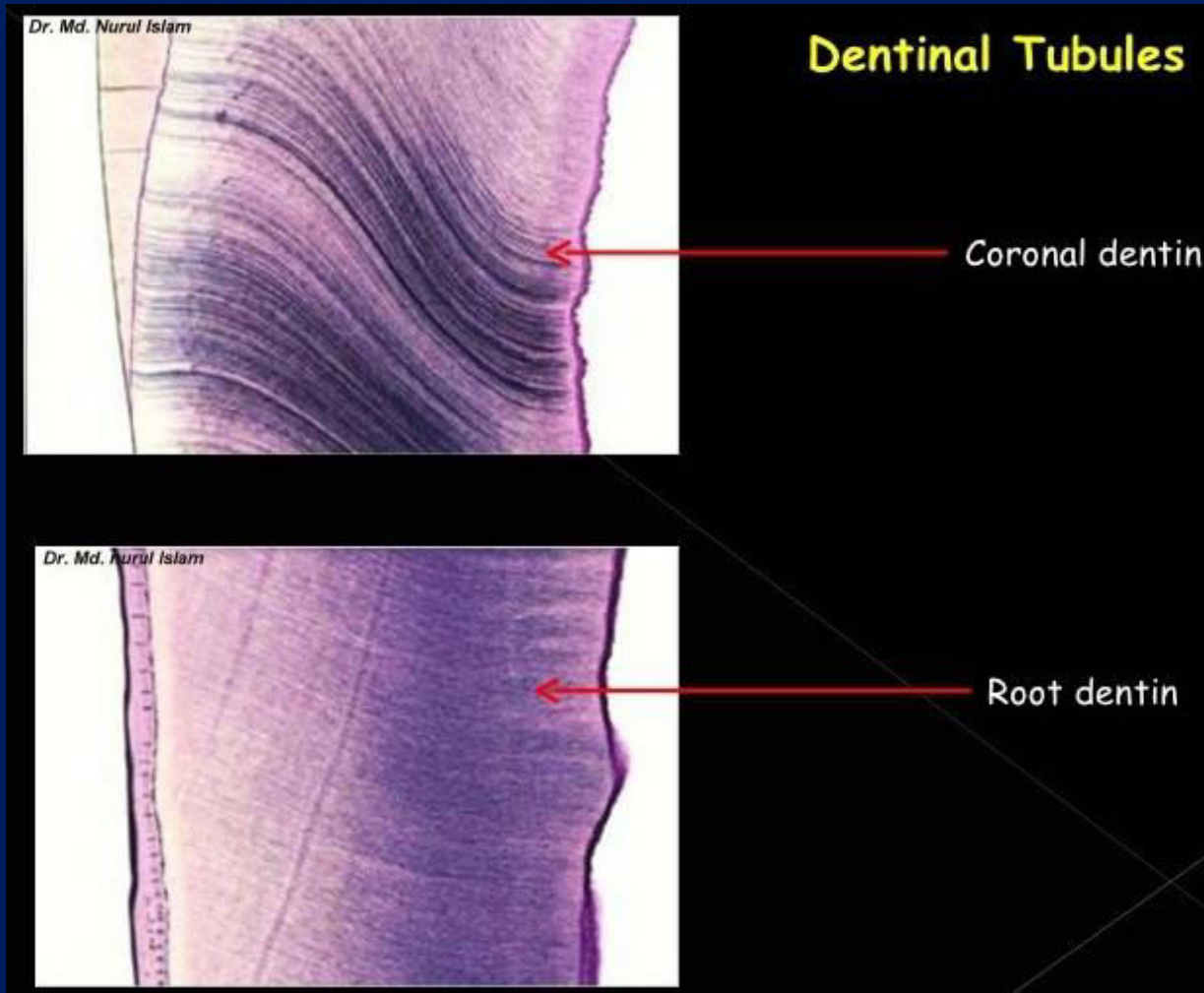


- Terminates in a **branching network** at the **junction** with **enamel** or **cementum**.
- Tubules are found throughout normal dentin & are therefore characteristic of it.



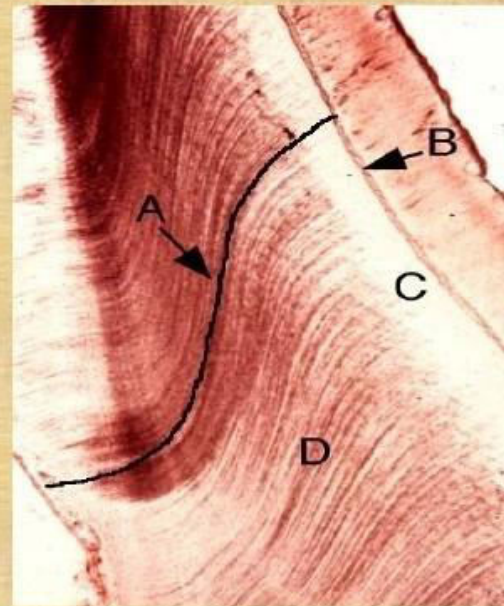
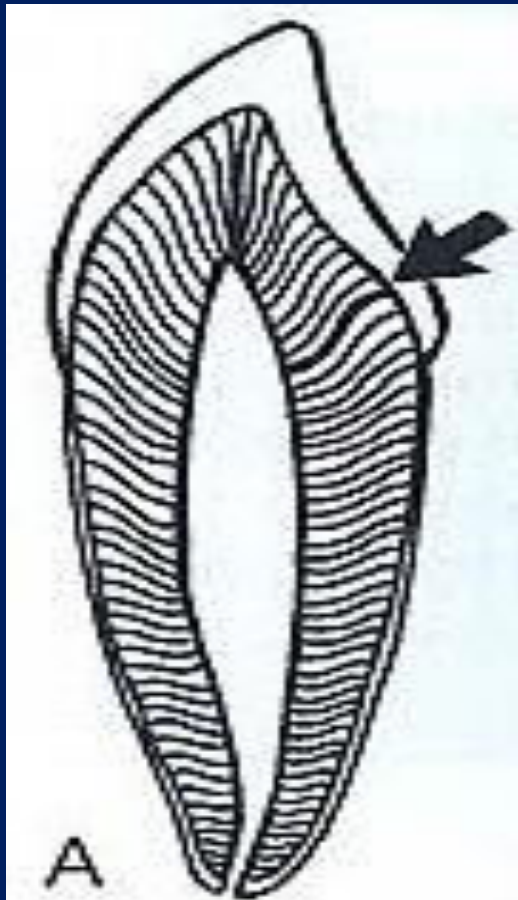# DENTINAL TUBULES

- The course follows a **gentle curve** in the crown, less so in the root, where it **resembles S** in shape.





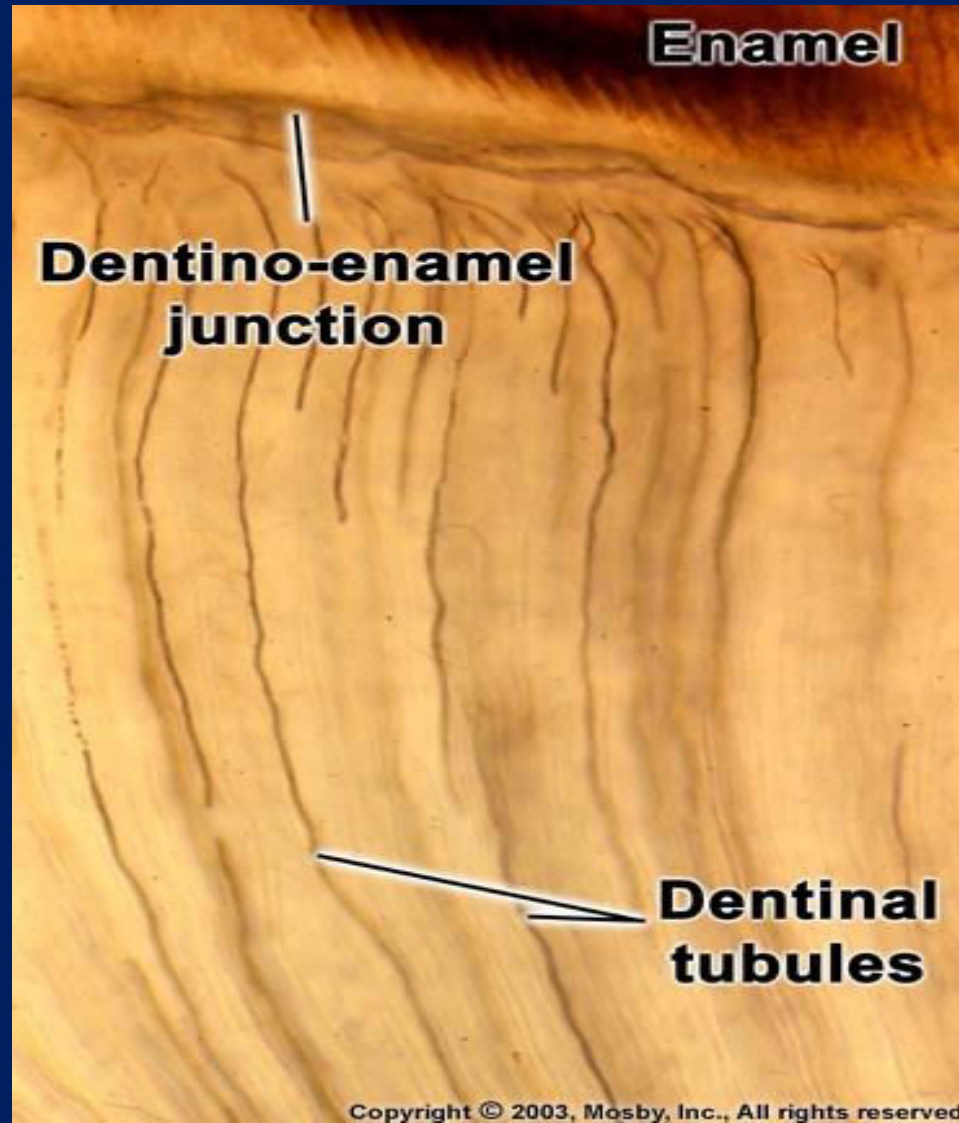
- Starting at **right angles** from the **pulpal surface**, the **first convexity** of this doubly curved course is directed toward the **apex of the tooth**.
- Near the **root tip** & along the **incisal edges** and **cusps** the tubules are almost **straight**.



A. PRIMARY CURVATURE OF  
DENTINAL TUBULES

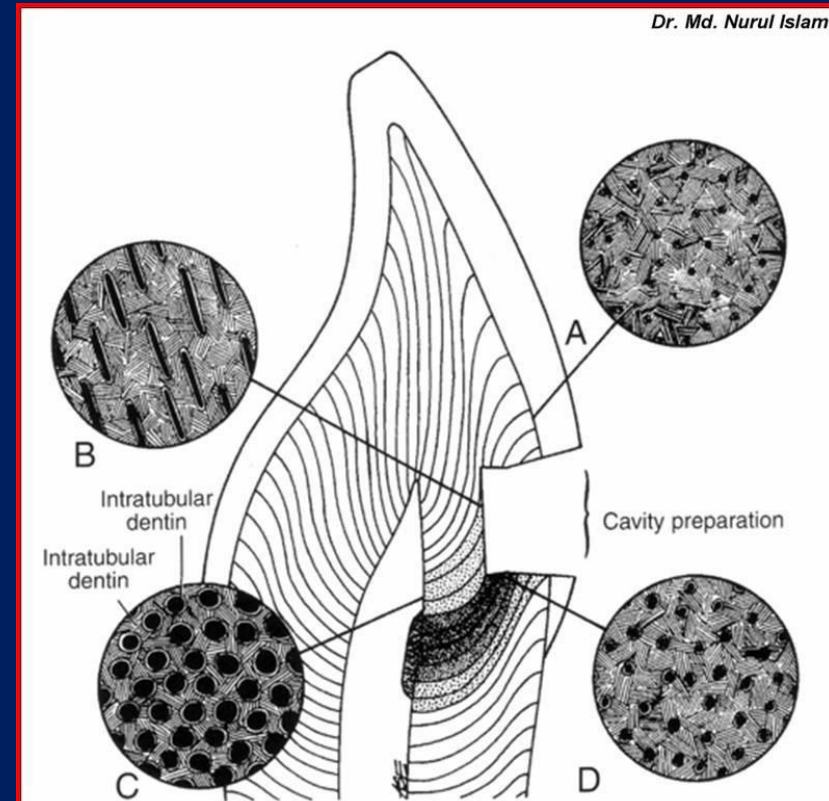
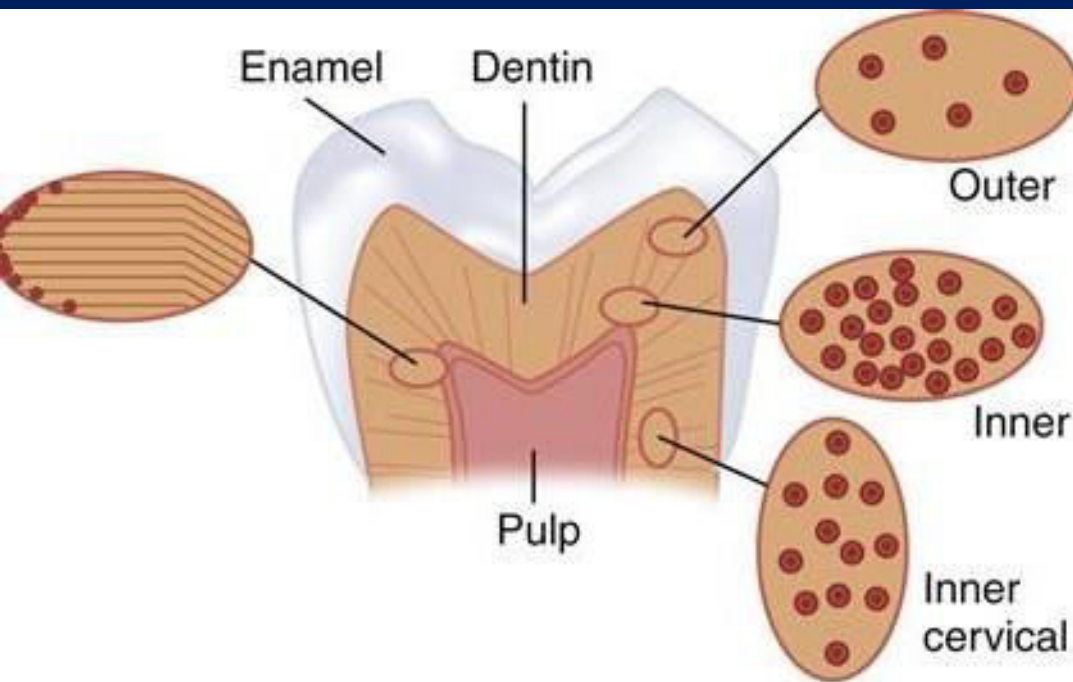
B. DENTINOENAMEL  
JUNCTION

- These tubules end **perpendicular** to the **dentinoenamel** and **dentinocementum junctions**.

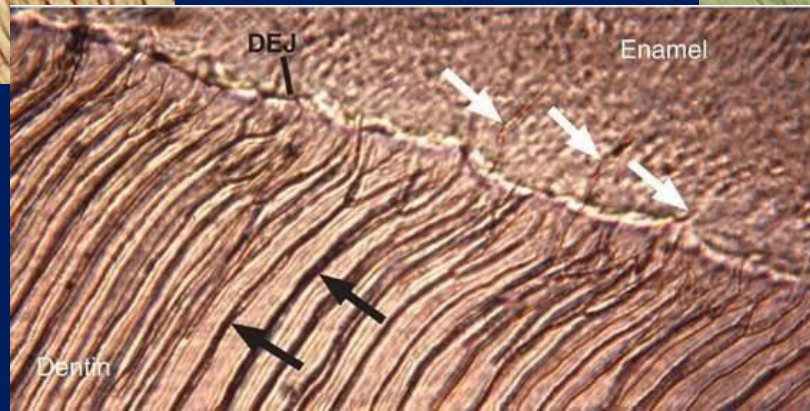
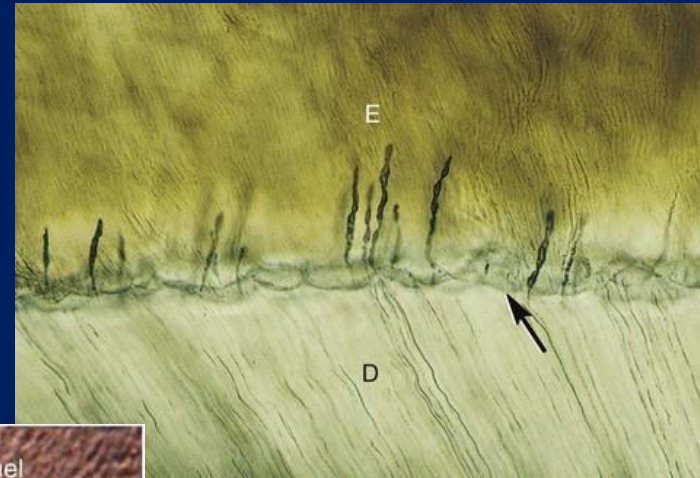
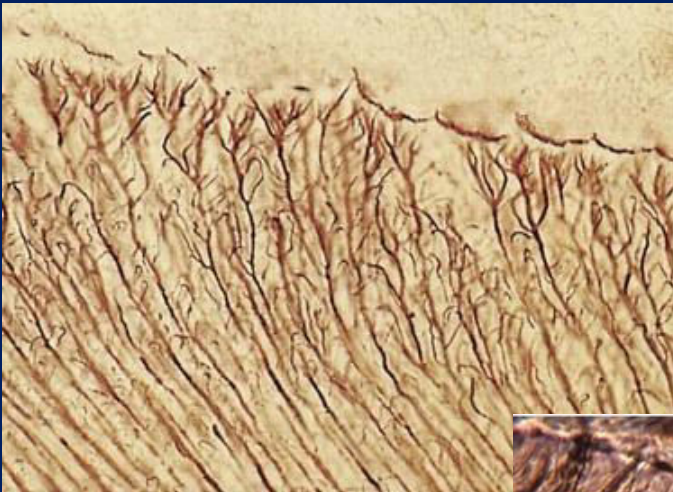


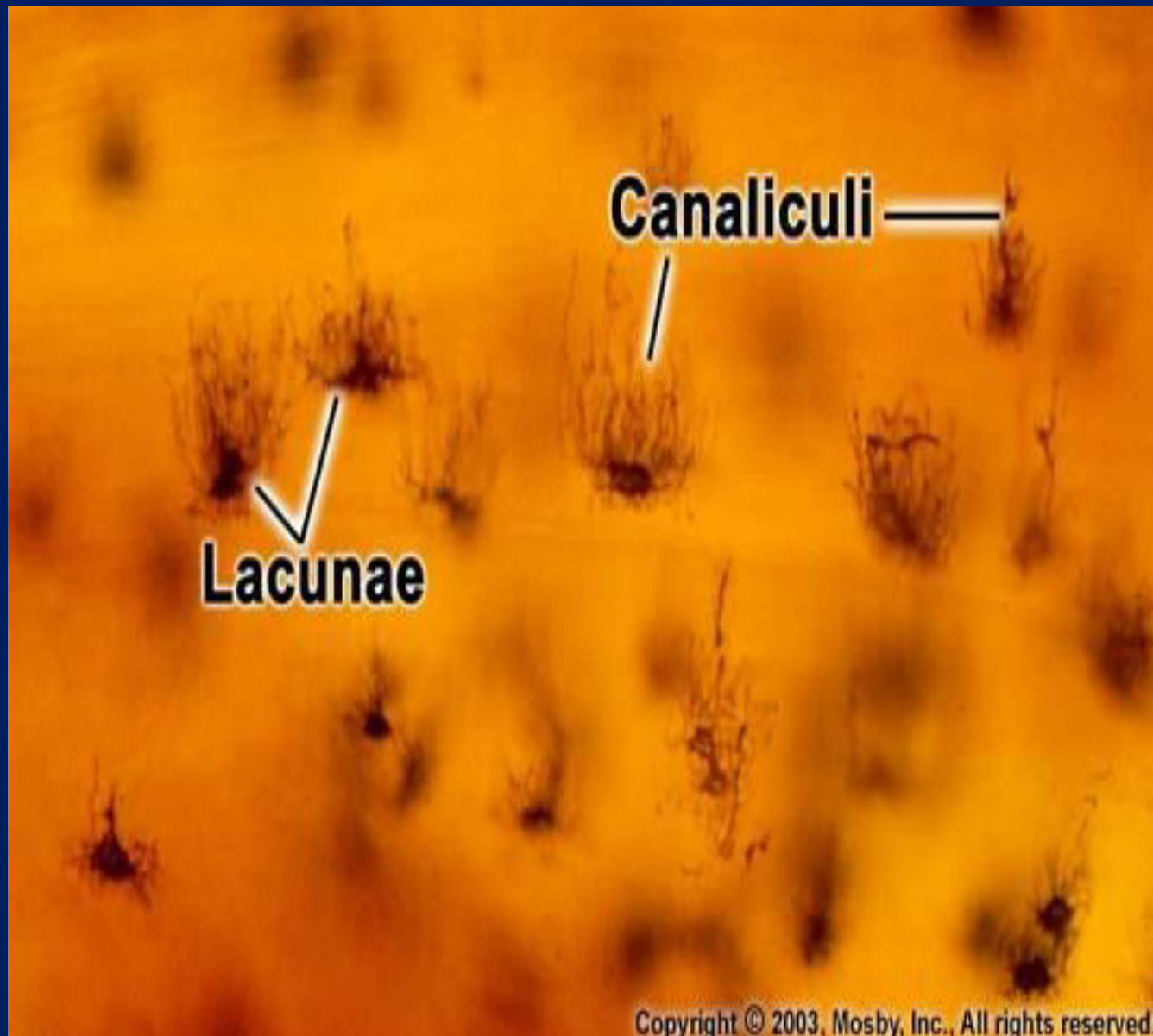


- The **ratio** between the **outer** and **inner surfaces** of dentin is about **5:1**.
- The **ratio** between the **numbers of tubules per unit area** on the **pulpal** and **outer surfaces** of dentin is about **4:1**.

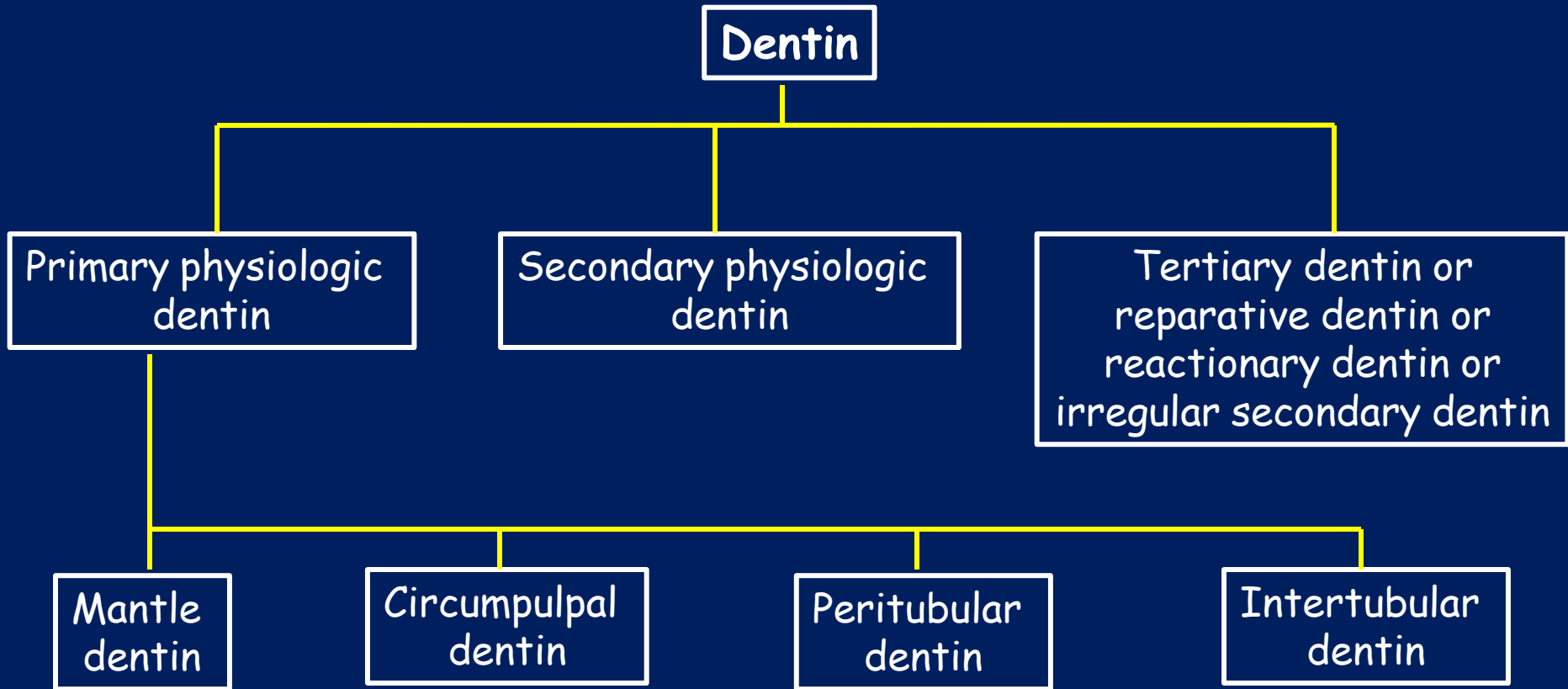


- There are **more tubules per unit area** in the **crown** than in the root.
- The dentinal tubules have **lateral branches** throughout dentin, which are termed **canaliculi** or **microtubules**.
- A few dentinal tubules **extend** through the **dentinoenamel junction** into the enamel. These are termed **enamel spindles**.

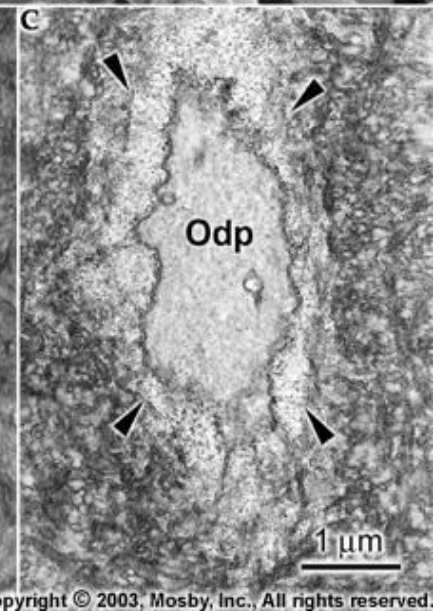

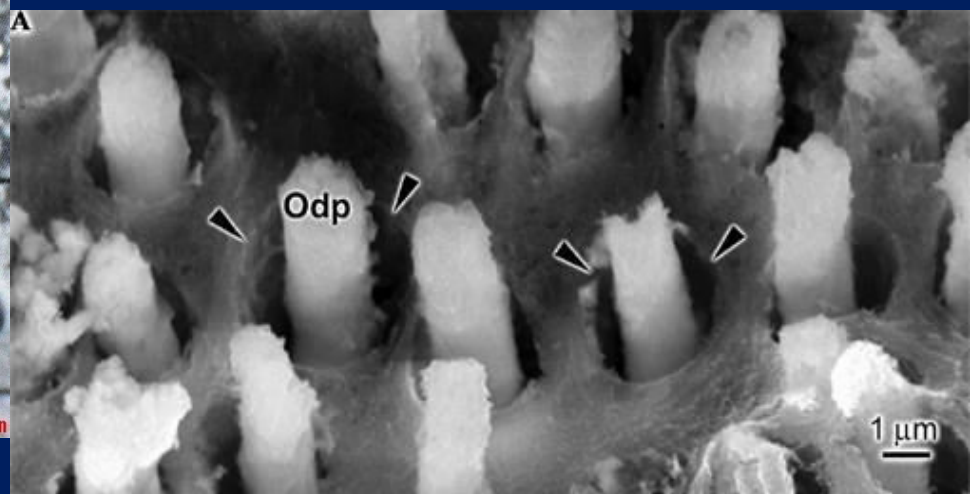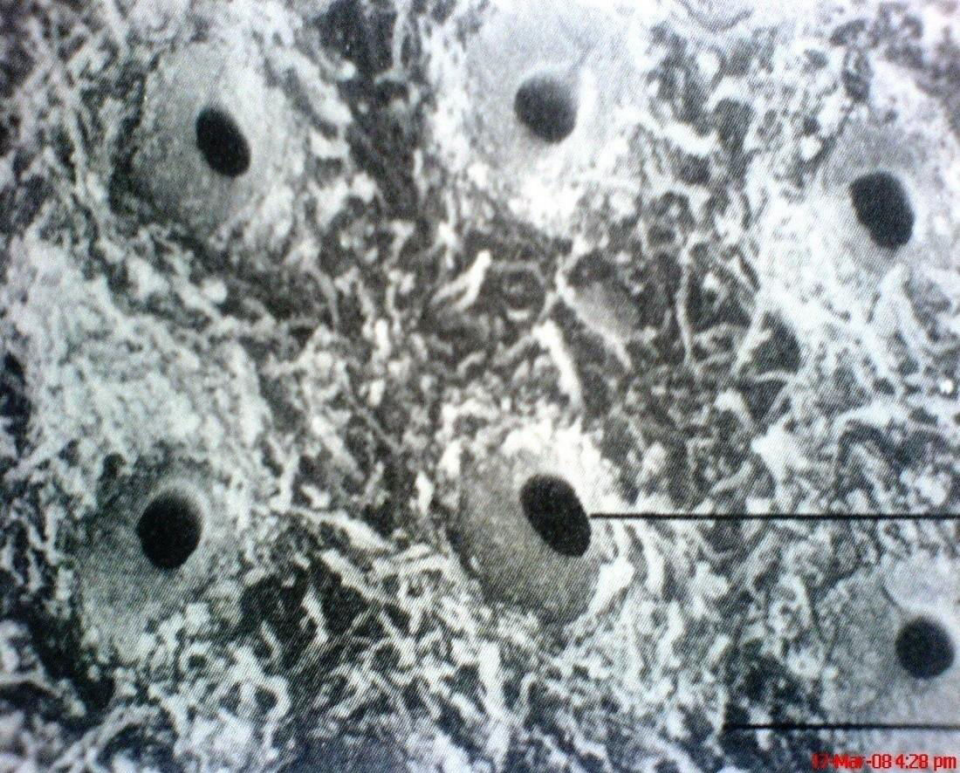




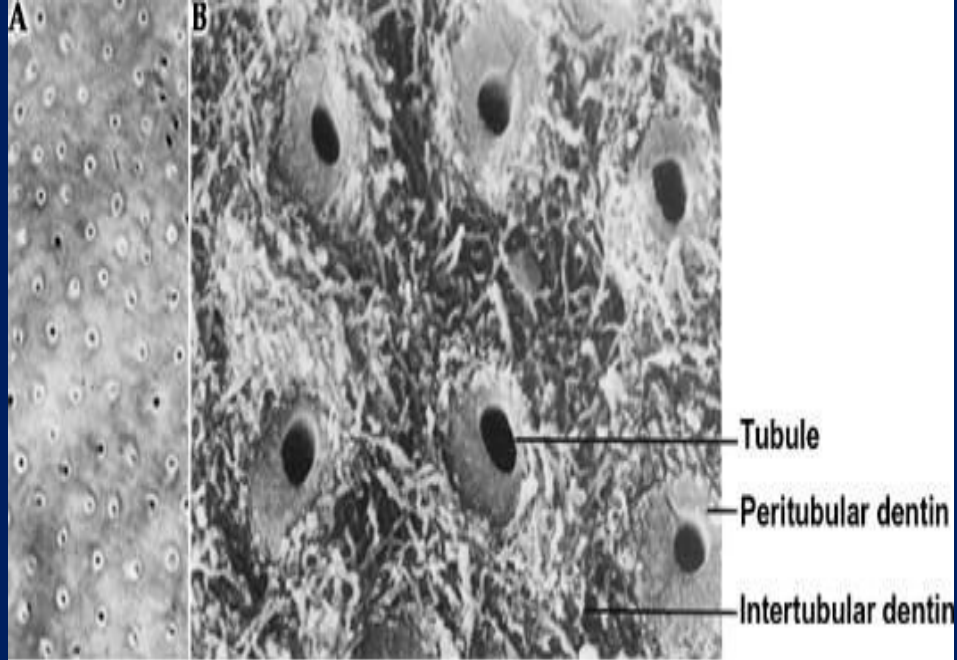
# Types of Dentin




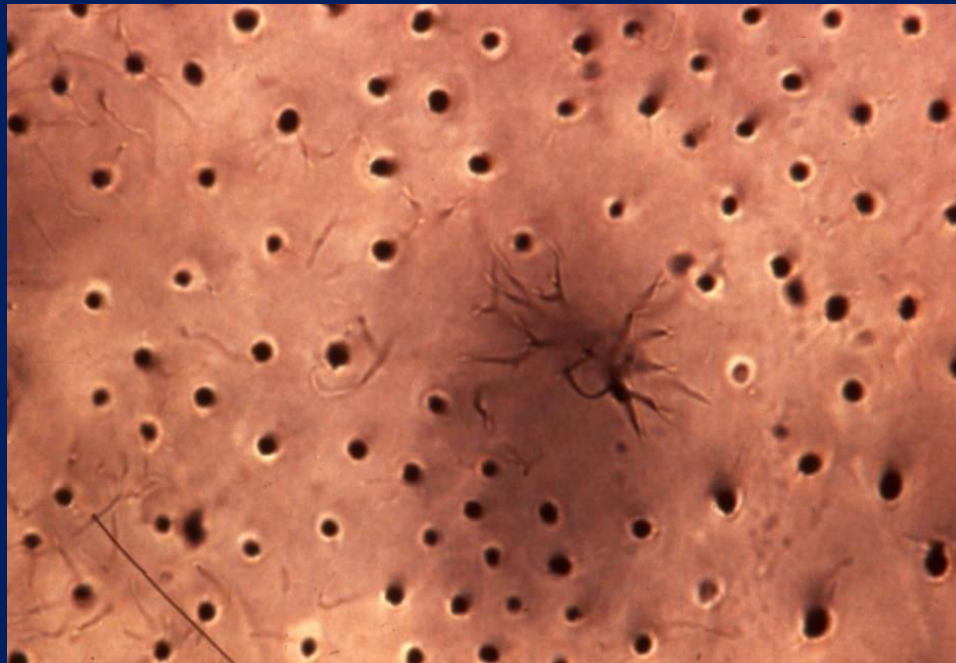








Copyright © 2003, Mosby, Inc., All rights reserved.



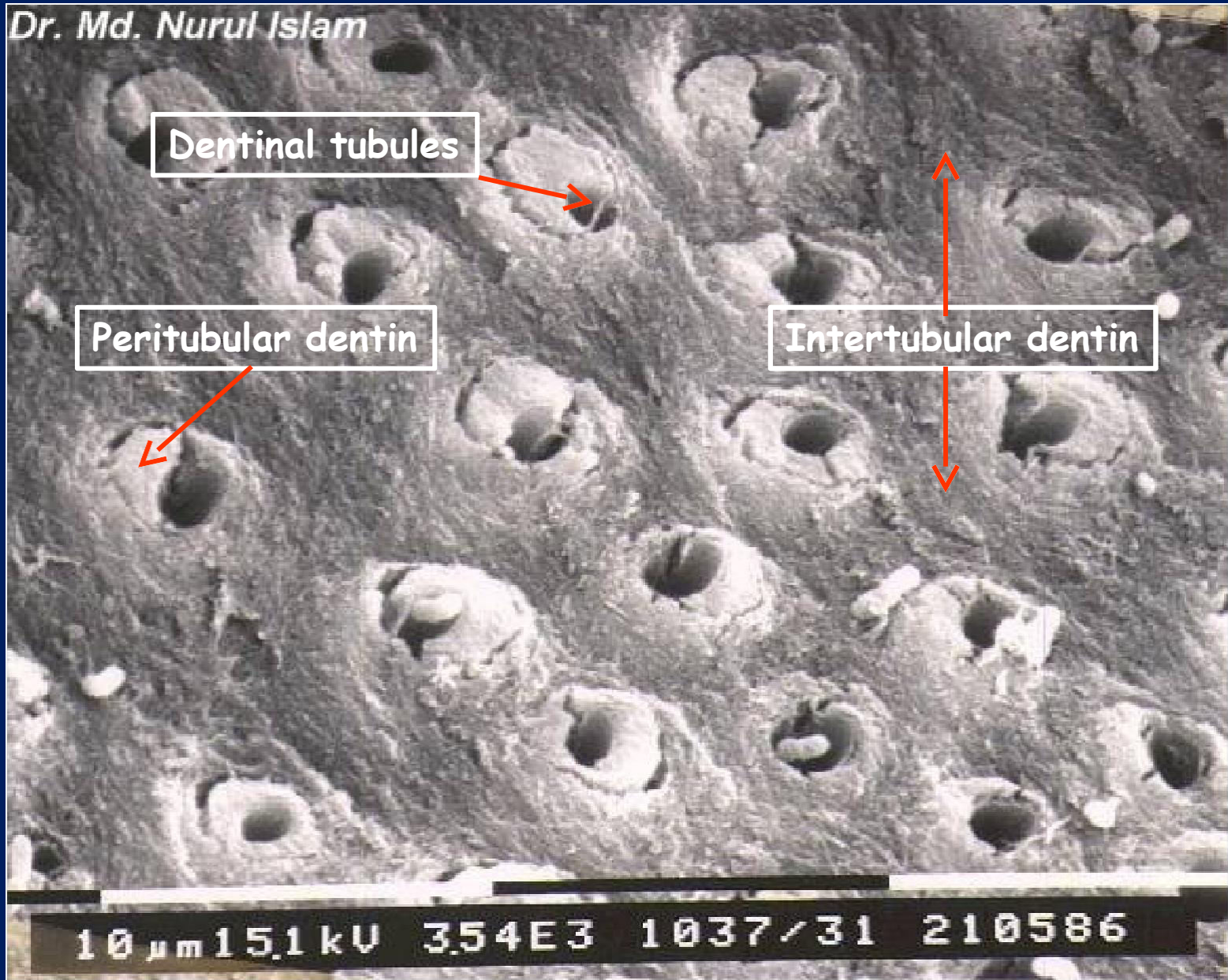
Dr. Md. Nurul Islam

Dentinal tubules

Peritubular dentin

Intertubular dentin

10  $\mu$ m 15.1kV 354E3 1037/31 210586





*Dr. Md. Nurul Islam*


Dentinal tubules

Peritubular dentin

Intertubular dentin

1  $\mu$ m 15.4 kV 1.04E4 0151/20 SE

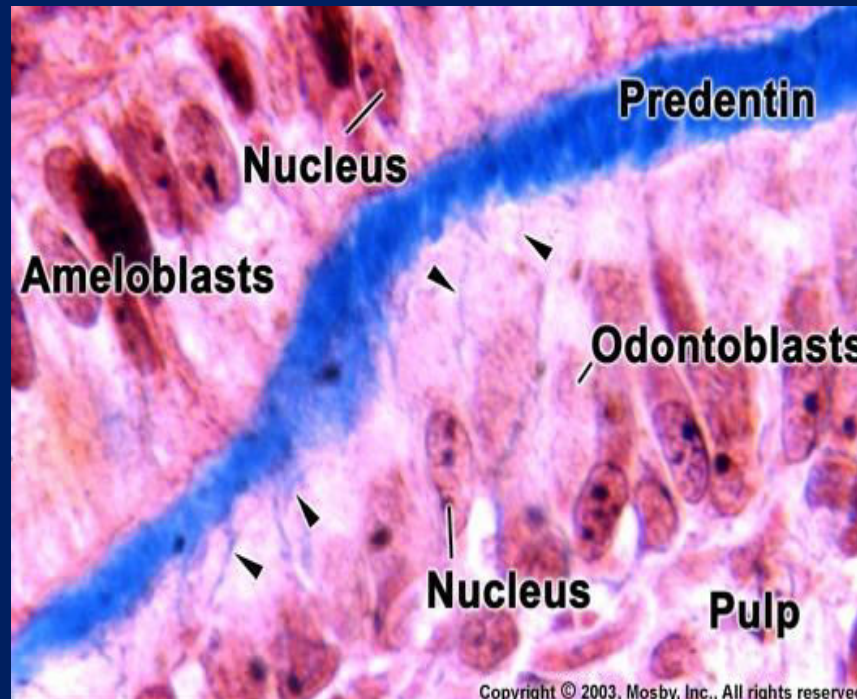
2  $\mu$ m





# PREDENTIN

- } Is located **adjacent** to the **pulp tissue**.
- } Is **2 to 6 um wide**, depending on the **activity** of the odontoblast.
- } It is the **first formed dentin** and is **not mineralized**.
- } As the collagen fibers undergo mineralization at the predentin- dentin front, the predentin then becomes dentin and a new layer of predentin forms circumpulpally.



# Odontoblasts and process

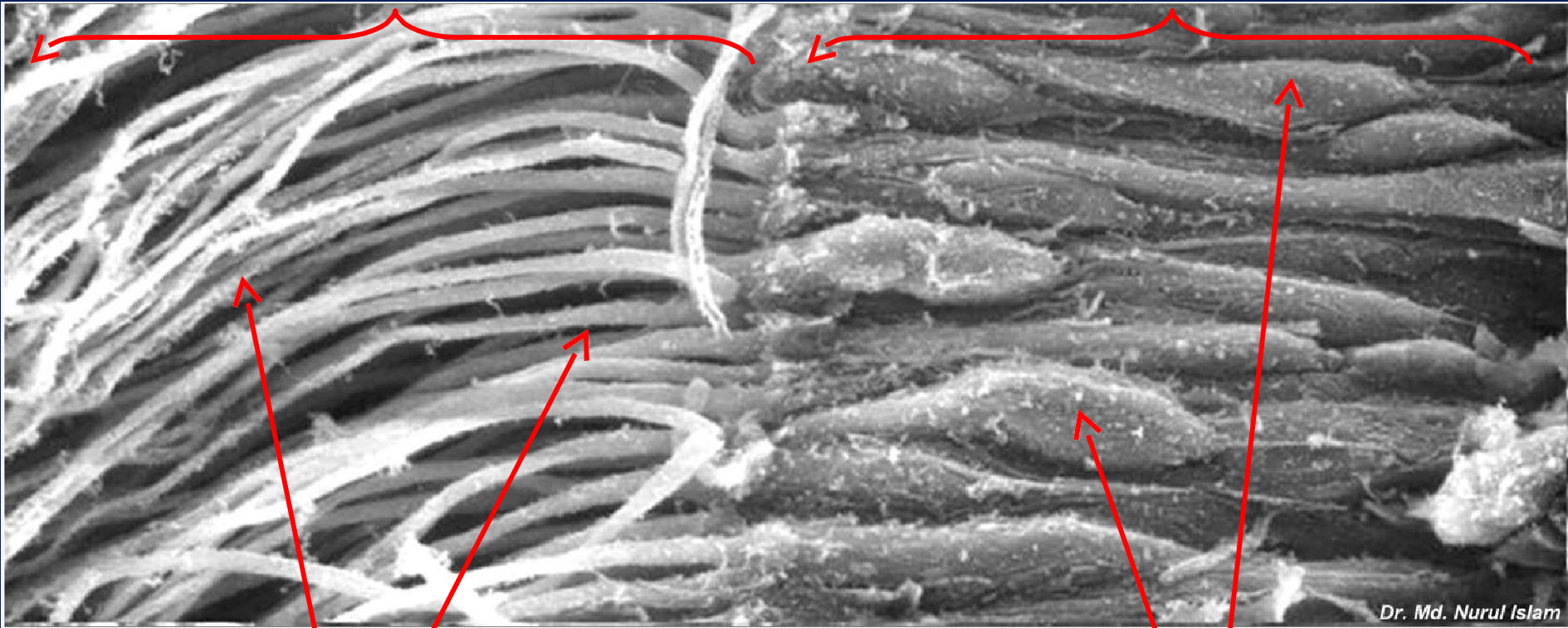
Dentin

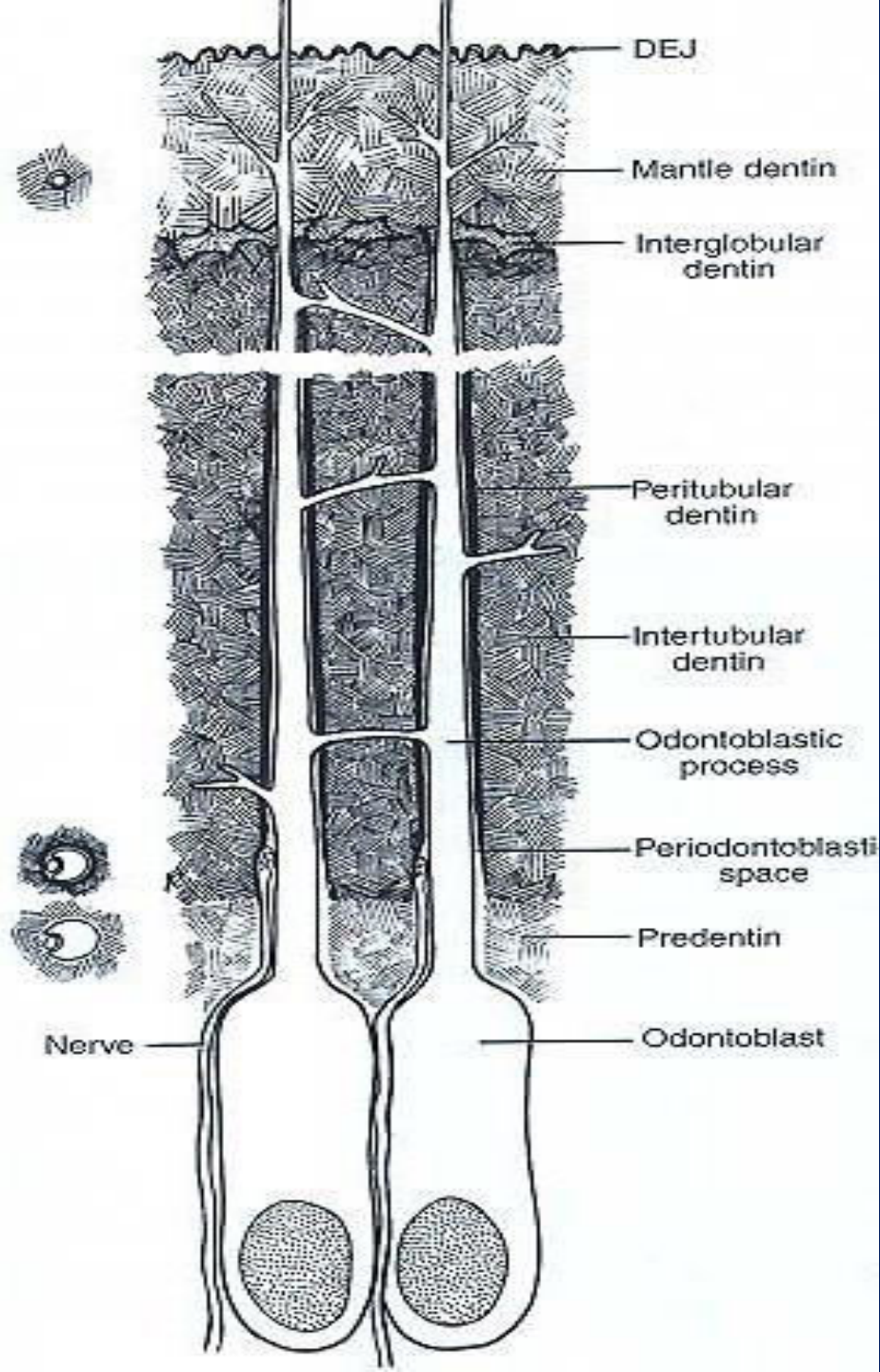
Pulp

Dr. Md. Nurul Islam

Odontoblast process

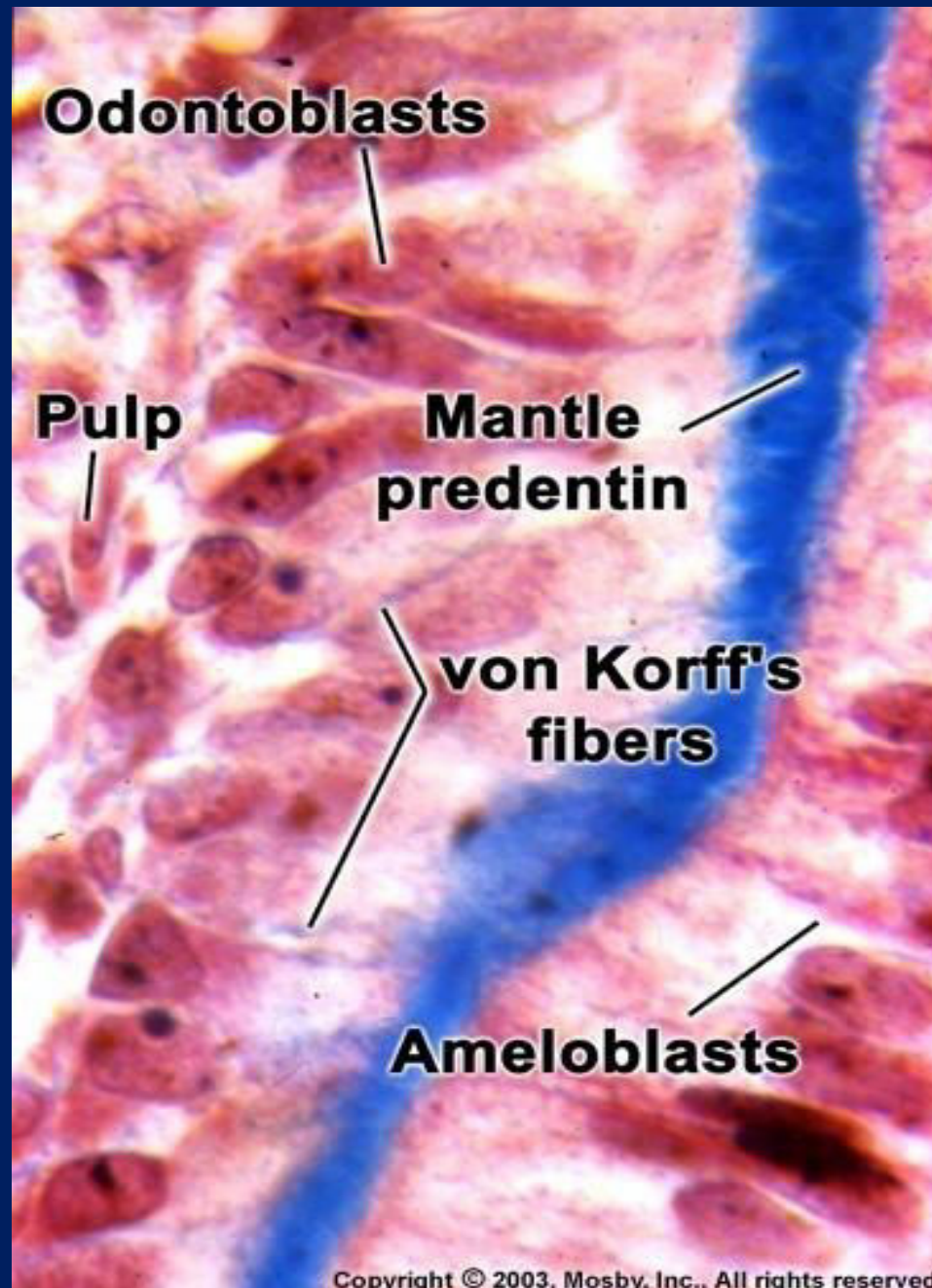
Odontoblast cells





## Relationship Between Odontoblastic Process And Dentinal Tubule



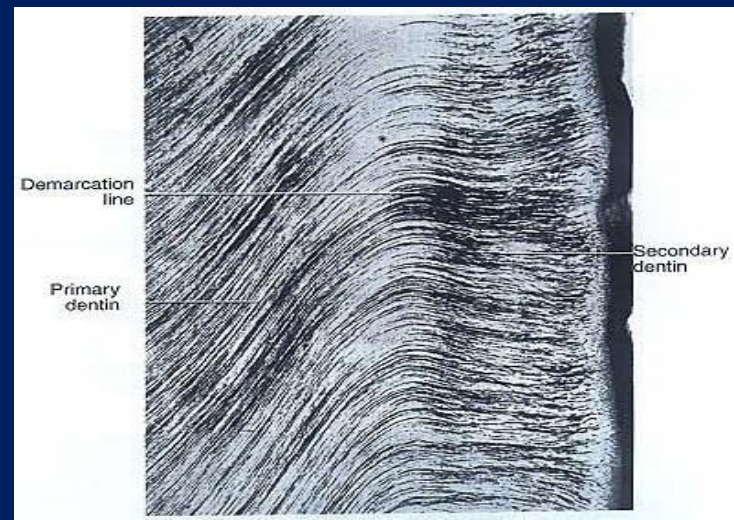


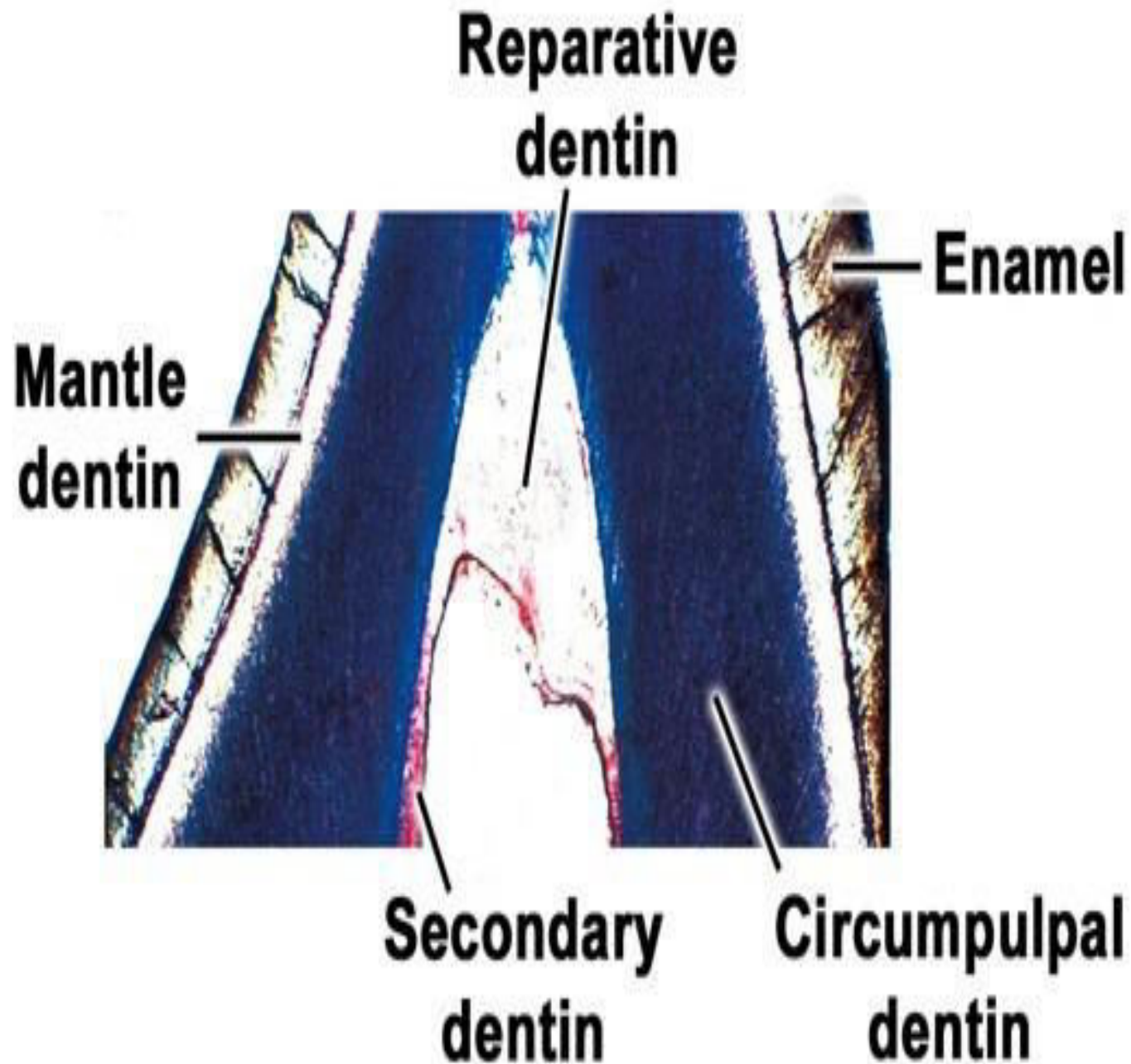


# SECONDARY DENTIN

- } A narrow band of dentin bordering the pulp and representing the **dentin formed after root completion**.
- } There is usually a bend in the tubules where primary and secondary dentin interface.

Some of the incremental lines are **accentuated** because of **disturbances in the matrix and mineralization process**. Such lines are known as **contour lines of Owen** between primary and secondary dentin.



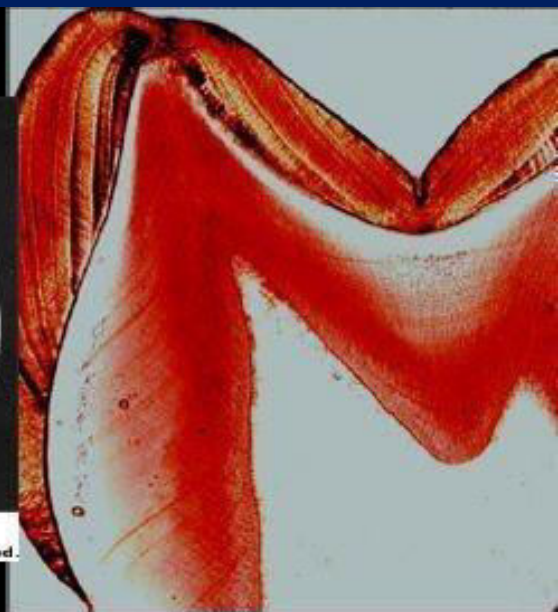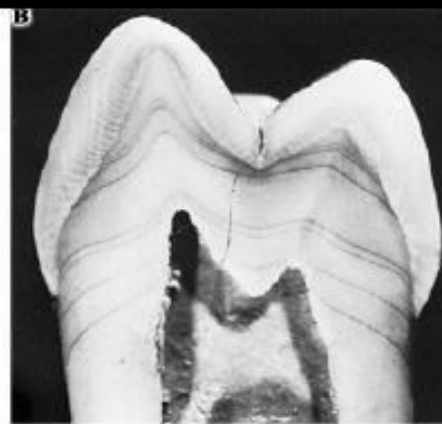
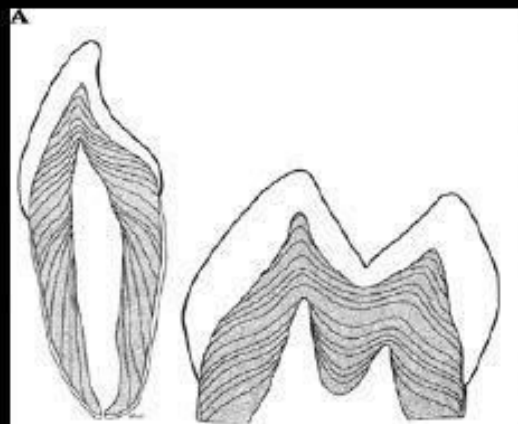
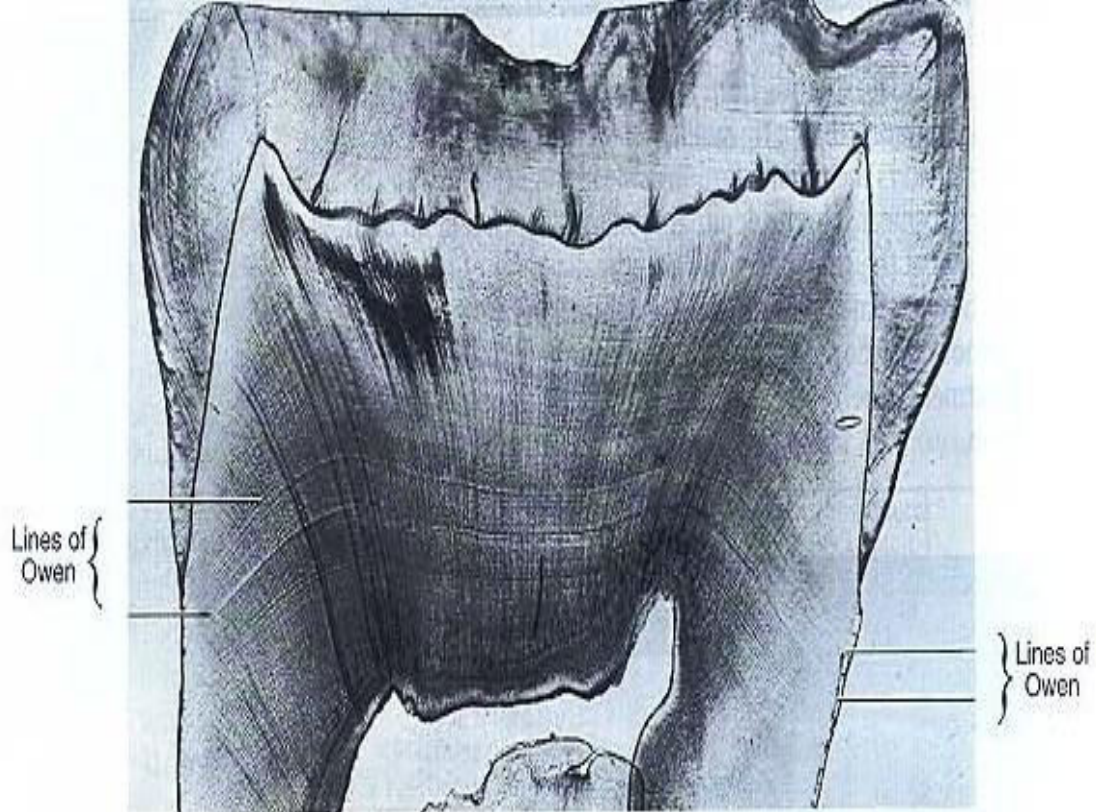




Incremental lines of Von Ebner

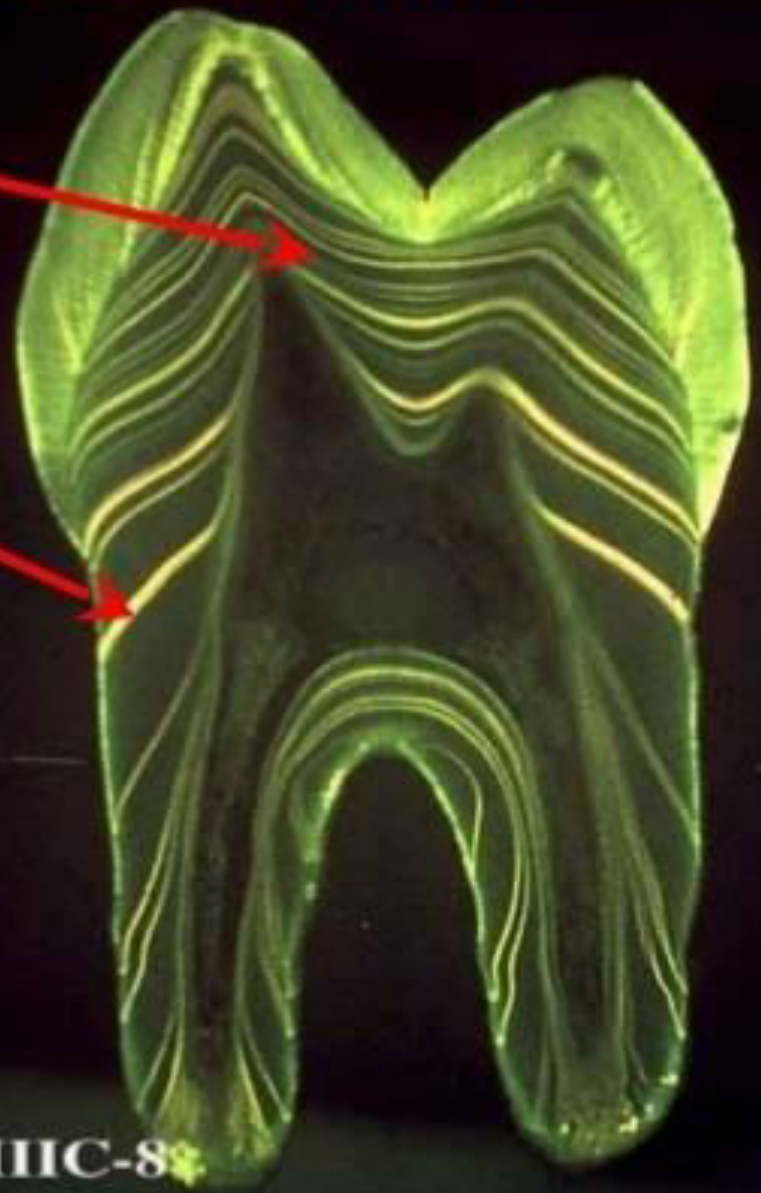






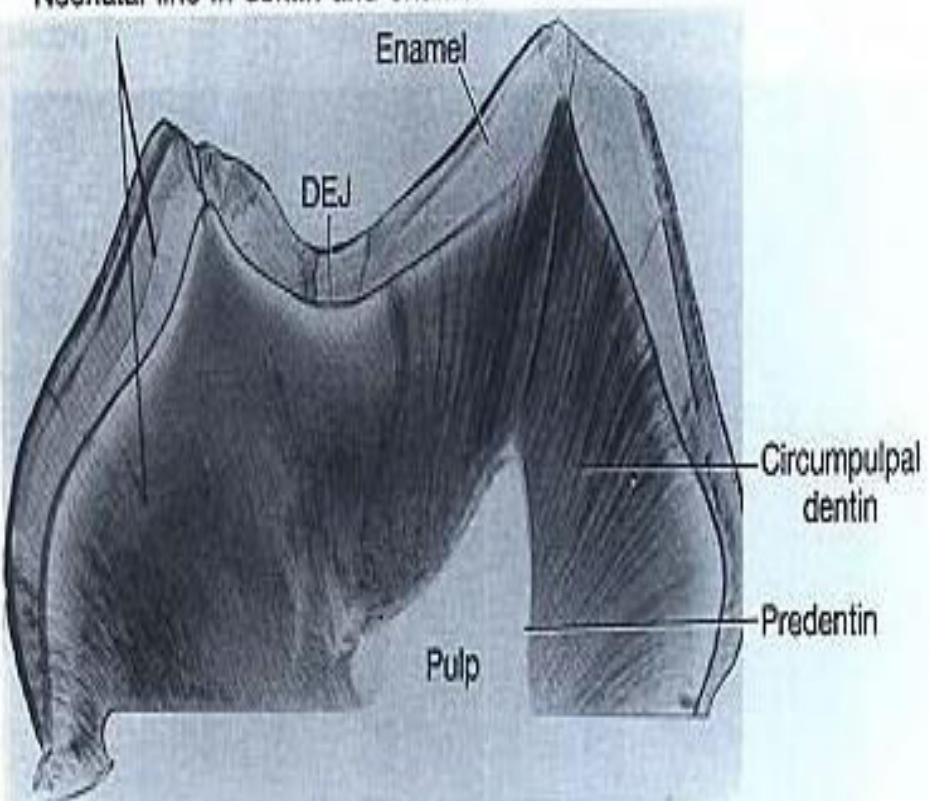
# Incremental lines of dentine

- 1-Incremental lines of von Ebner
- 2- contour line of Owen

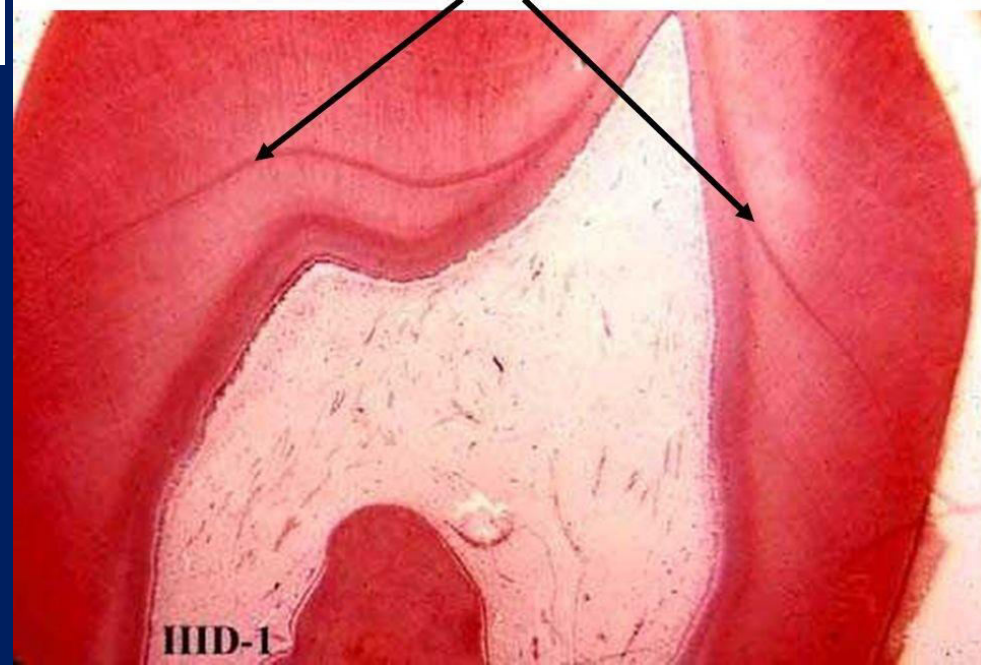




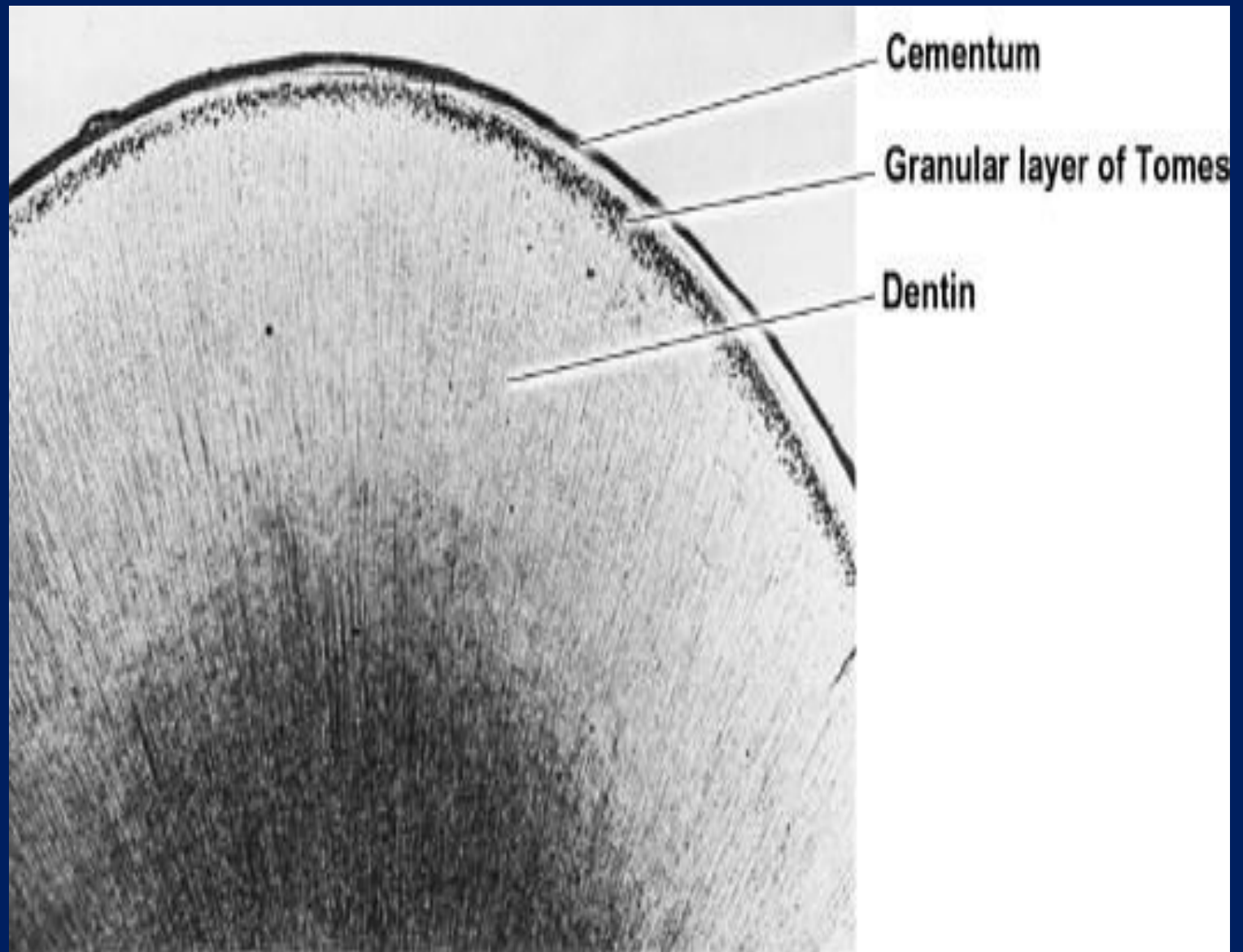
Neonatal line in dentin and enamel



neonatal line







**Granular layer  
of Tomes**

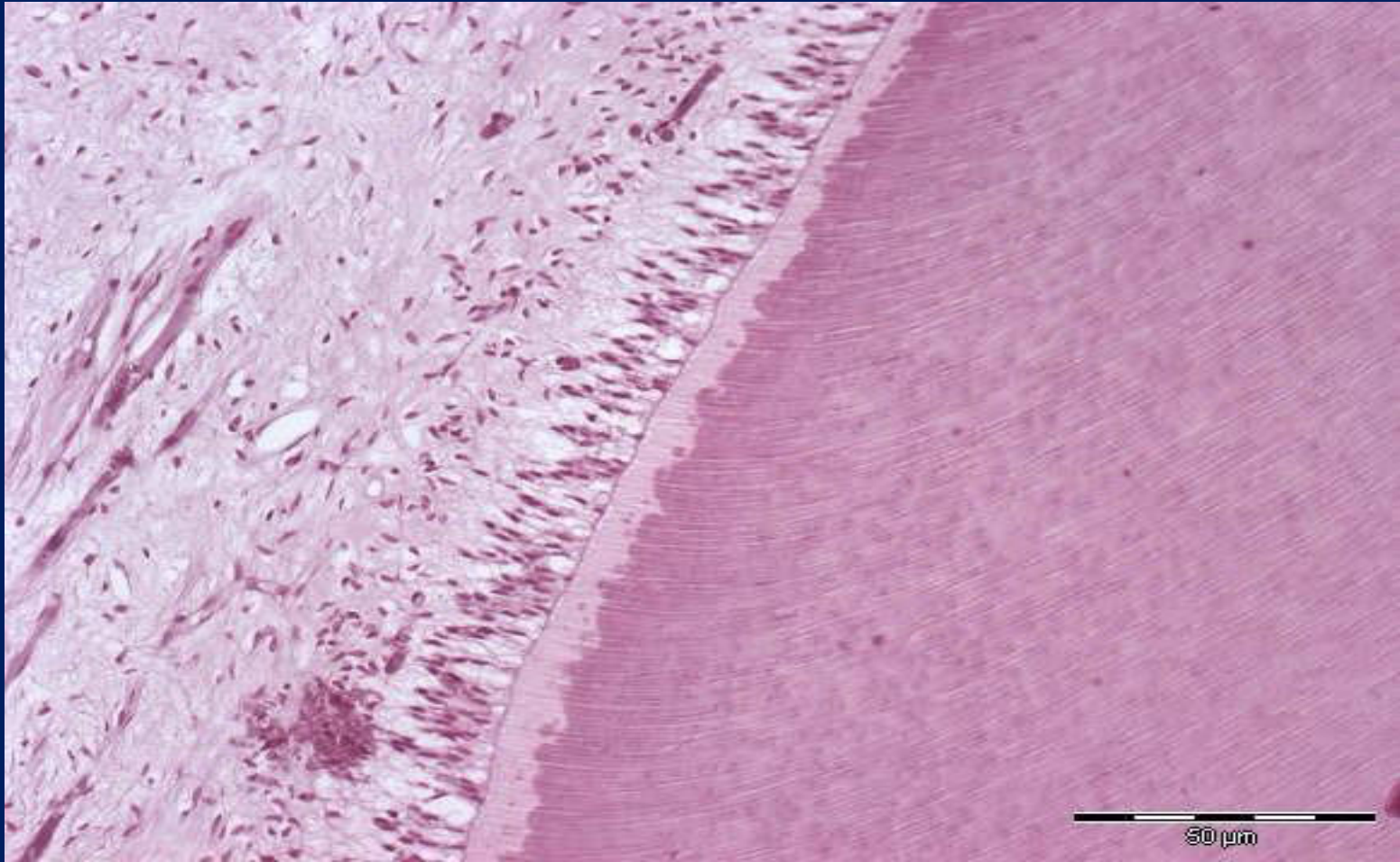
Copyright © 2003, Mosby, Inc., All rights reserved.

**Cementum**

**Dentin**



## 4- QUIESCENT STATE OF ODONTOBLASTS



**The odontoblasts decrease in size and form dentin in a slowly diminishing rate until stimulated to form reparative dentin.**

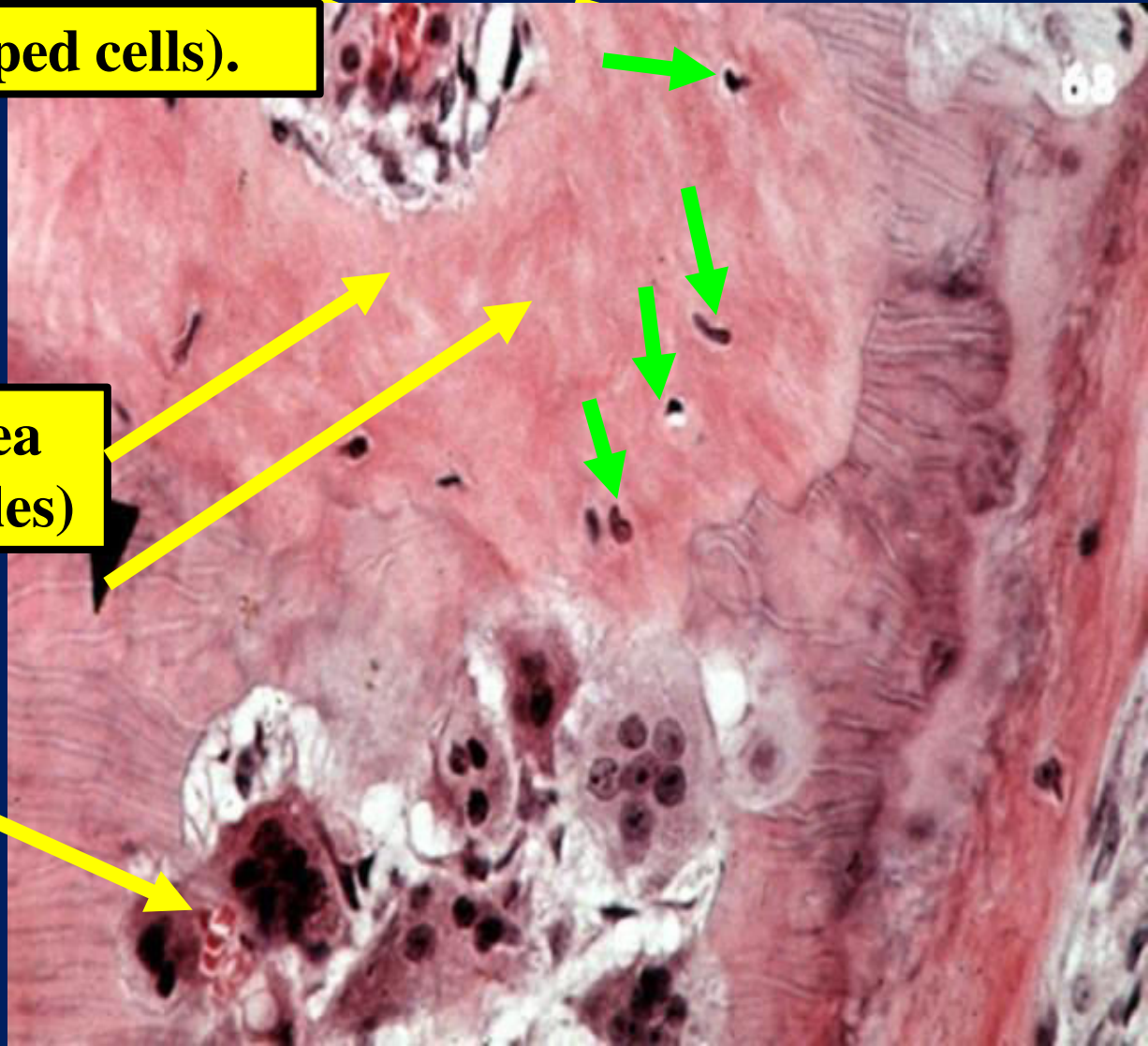


# TYPES OF REPARATIVE DENTIN

**Osteodentin (entrapped cells).**

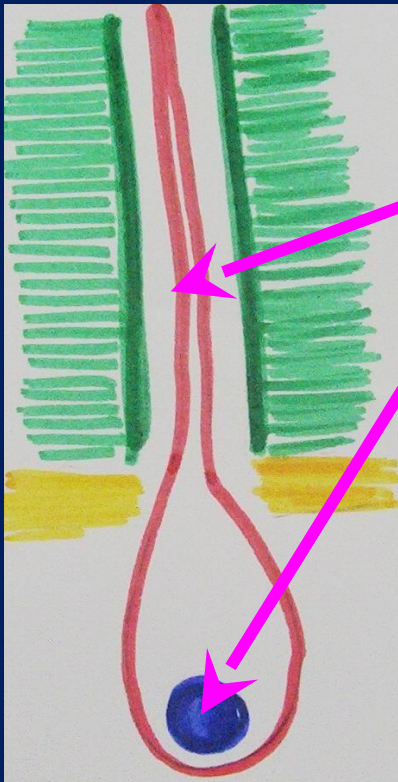
**Atubular dentin ( area  
without dentinal tubules)**

**Vasodentin  
(entrapped b.v.)**



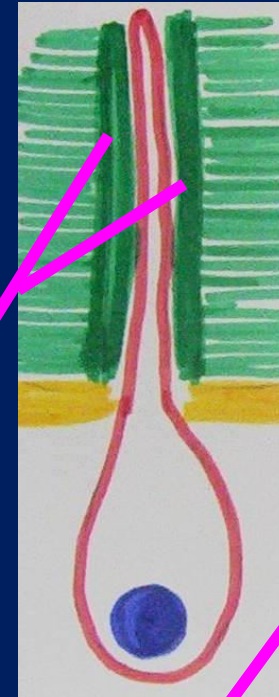
### 3- TRANSPARENT (SCLEROTIC DENTIN)

★Mild stimulus leads to changes in the dentin already present.




1- Odontoblast and its process undergo fatty degeneration.

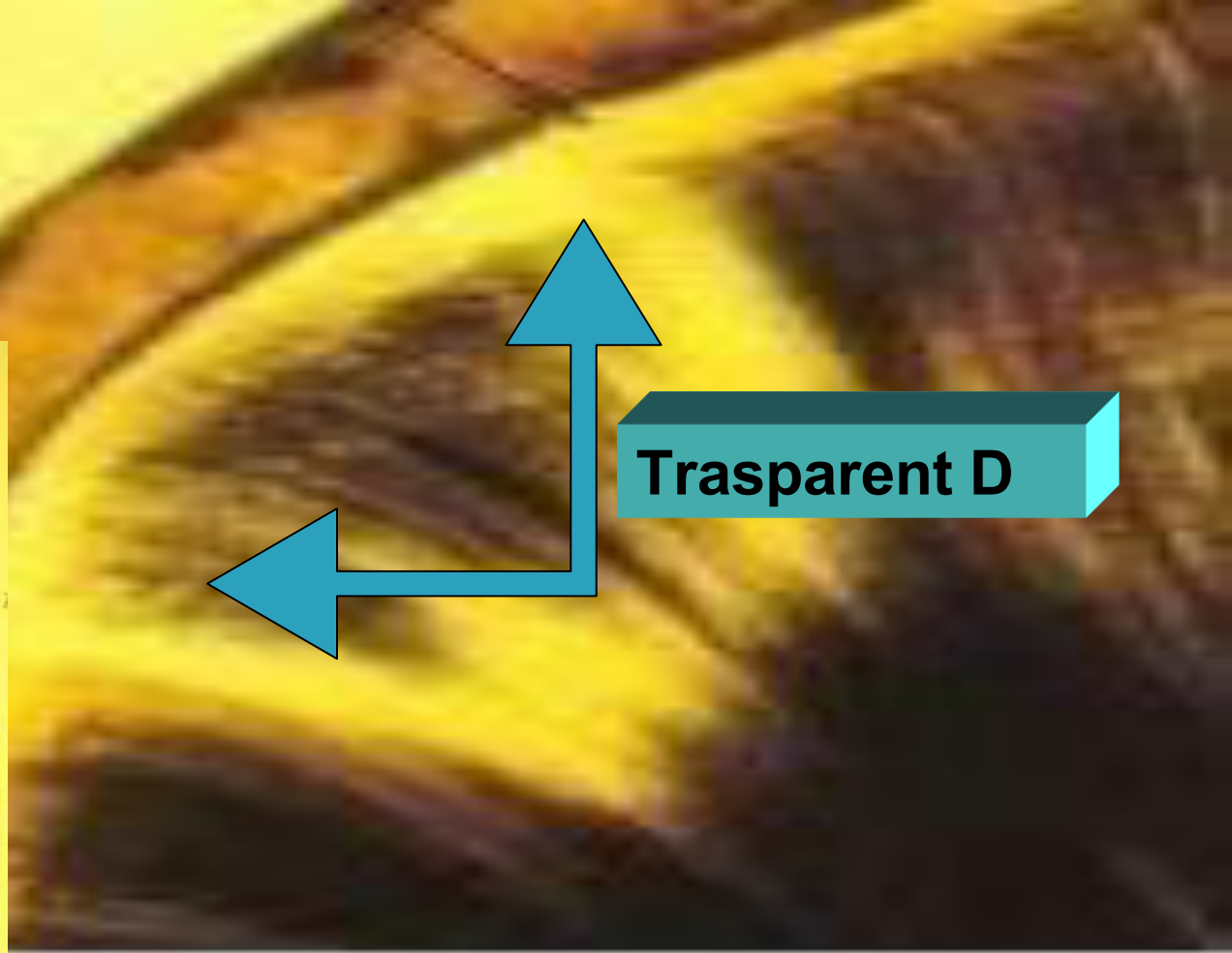
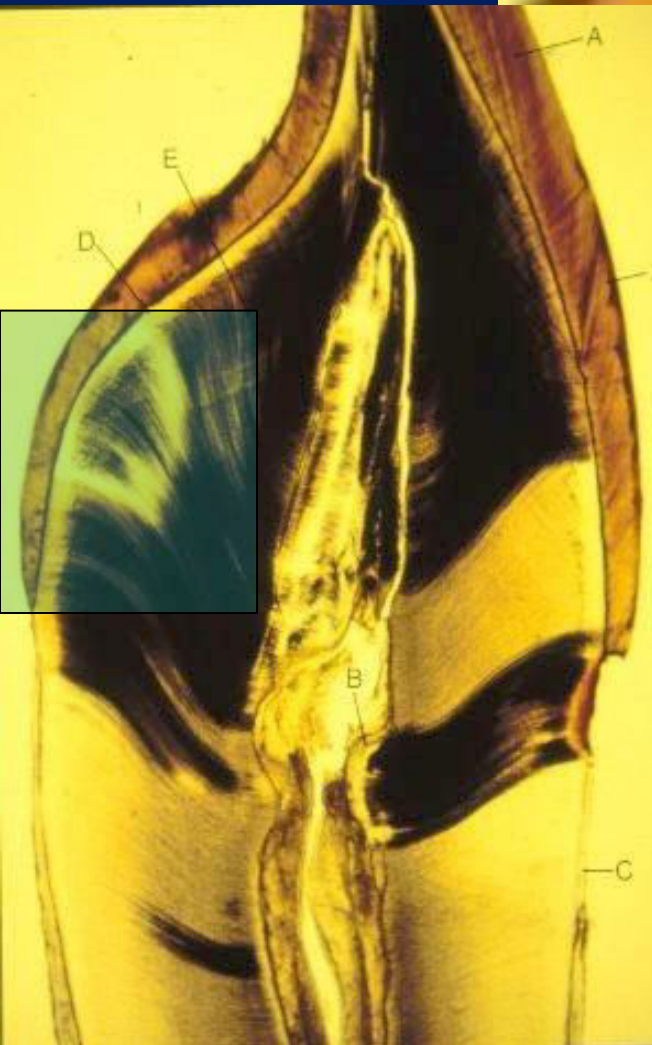2- Then there will be calcification of dentinal tubules. First become narrow by widening of the peritubular dentin.



3- Then the DT become obliterated.



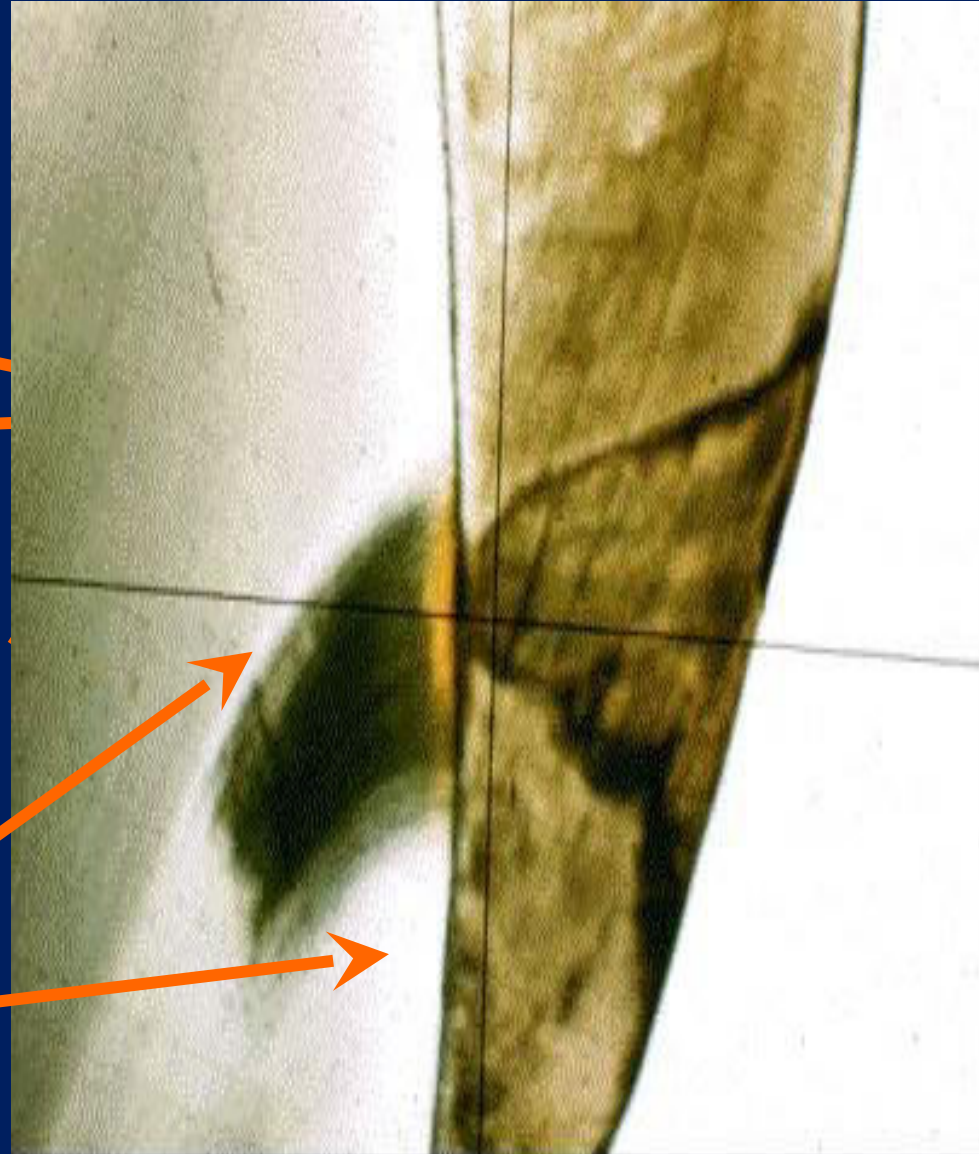
The affected area have occluded dentinal tubules, so the dentin have uniform refractive index. So this area of dentin appear translucent by transmitted light.





## 4-DEAD TRACTS

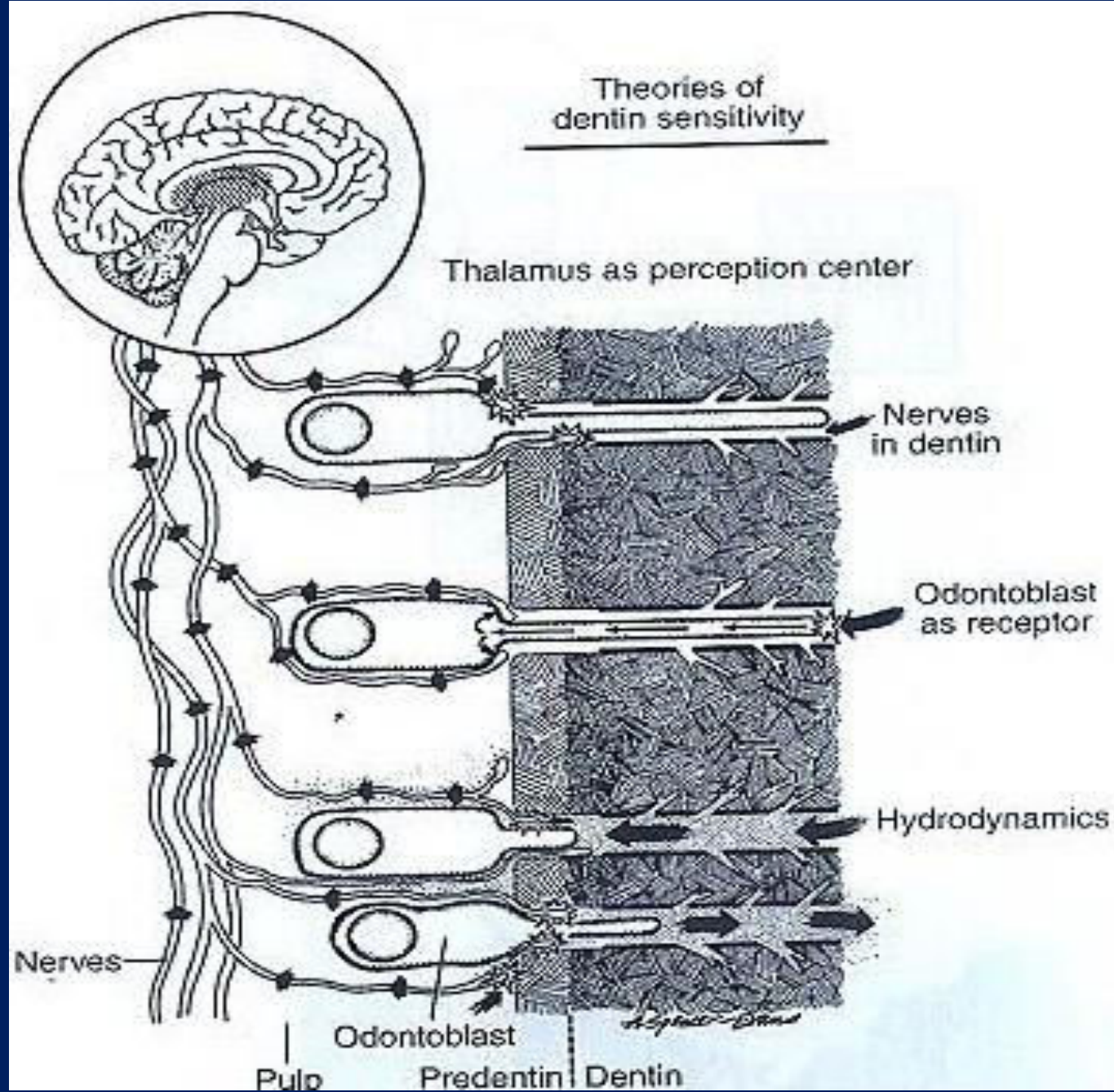
- } Severe stimulation to dentin leads to destruction of the odontoblastic process and odontoblasts. This leads to empty and wide dentinal tubules.
- } These areas appear black with transmitted light.
- } Under the dead tracts from the pulpal surface, reparative dentine will be formed.
- } The dead tract surrounded by sclerotic dentin.



# THEORIES OF PAIN TRANSMISSION THROUGH DENTIN

- **Direct conduction theory** in which stimuli directly effect the nerve endings in the tubules.
- **Transduction theory** in which the membrane of the odontoblast process conducts an impulse to the nerve endings in the predentin, odontoblast zone, and pulp.
- **Fluid or hydrodynamic theory** in which stimuli cause an inward or outward movement of fluid in the tubule, which in turn produces movement of the odontoblast and its processes.

# Theories of dentin sensitivity





THANK YOU

# Oral mucosa

DR. ABDUSATTAR SALIM



# ORAL MUCOSA

The oral cavity is lined with an uninterrupted mucous membrane, which is continuous with the skin near the vermillion border of the lips and with the pharyngeal mucosa in the region of the soft palate.

The epithelium of the oral mucosa originates partly from the ECTODERM (lips, vestibule, gingiva, cheeks, palate, floor of the mouth), and partly from the endoderm (tongue).



# MASTICATORY MUCOSA

- free and attached gingiva and hard palate comes in primary contact with food during mastication and is keratinized.

# LINING MUCOSA

- the lips cheeks, vestibule, floor of the mouth, interior surface of the tongue and soft palate. It does not function in mastication and therefore has little attrition. It is soft and non-keratinized.

# SPECIALIZED MUCOSA

- on the dorsal surface (dorsum) of the tongue. It is covered with cornified epithelial papillae

# **FUNCTION OF ORAL MUCOSA**



## Protection

- acts as major barrier to microorganisms

## Sensation

- receptors that respond to temperature, touch, pain, taste; initiates reflexes such as swallowing, gagging and salivation

## Secretion

- saliva, contributes to the maintenance of moist surface

## Permeability and Absorption

- thinnest epithelial regions, floor of the mouth, more permeable than other areas

## Thermal Regulation

- dogs, body heat is dissipated through the oral mucosa by panting



# **HISTOLOGICAL CHARACTERISTICS OF ORL MUCOSA**



# TWO MAIN TISSUE COMPONENTS:

**Oral  
epithelium**

- **stratified squamous epithelium**

**Lamina Propria**

- **underlying connective tissue layer**

The oral mucosa is attached to the underlying structures by a layer of loose fatty or granular connective tissue containing major blood vessels and nerves known as sub mucosa

## BASEMENT MEMBRANE

- **structureless layer about 1 – 2 micrometers thick; interface between epithelium and connective tissue**

## CONNECTIVE TISSUE PAPILLA

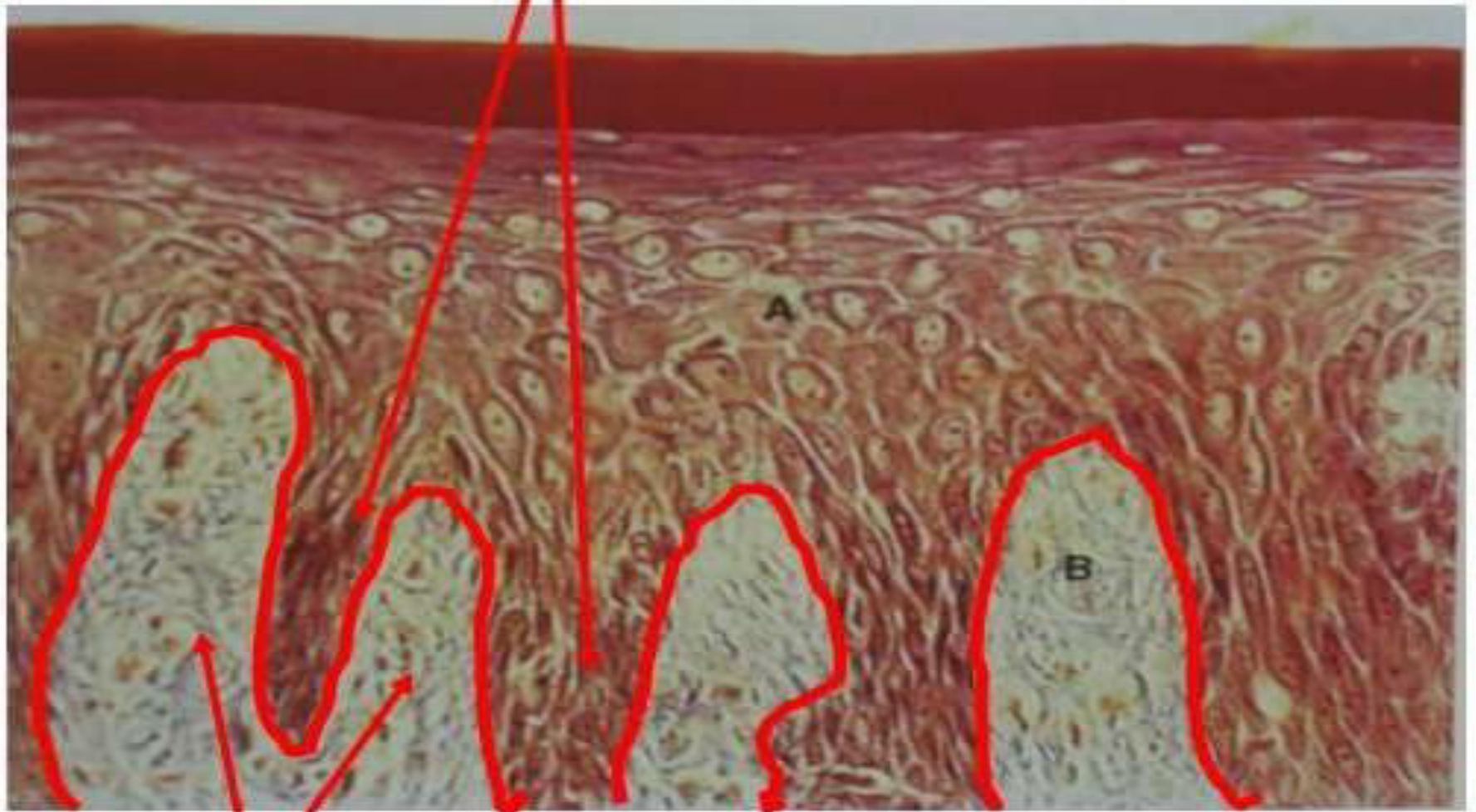
- **irregular and upward projections of connective tissue**

## EPITHELIAL RETE RIDGE

- **or rete pegs, epithelial ridges or pegs that interdigitate with the connective tissue papilla**



RETE RIDGES



CONNECTIVE  
TISSUE PAPILLA

BASEMENT LAMINA

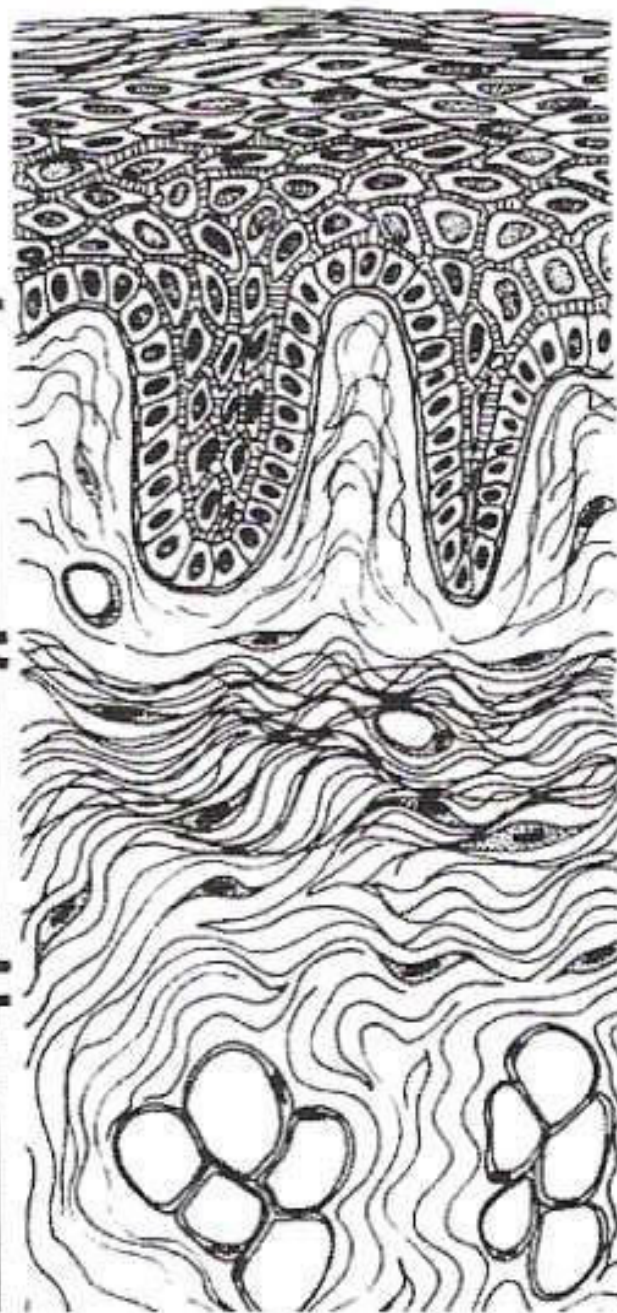
Papillary layer

Reticular layer

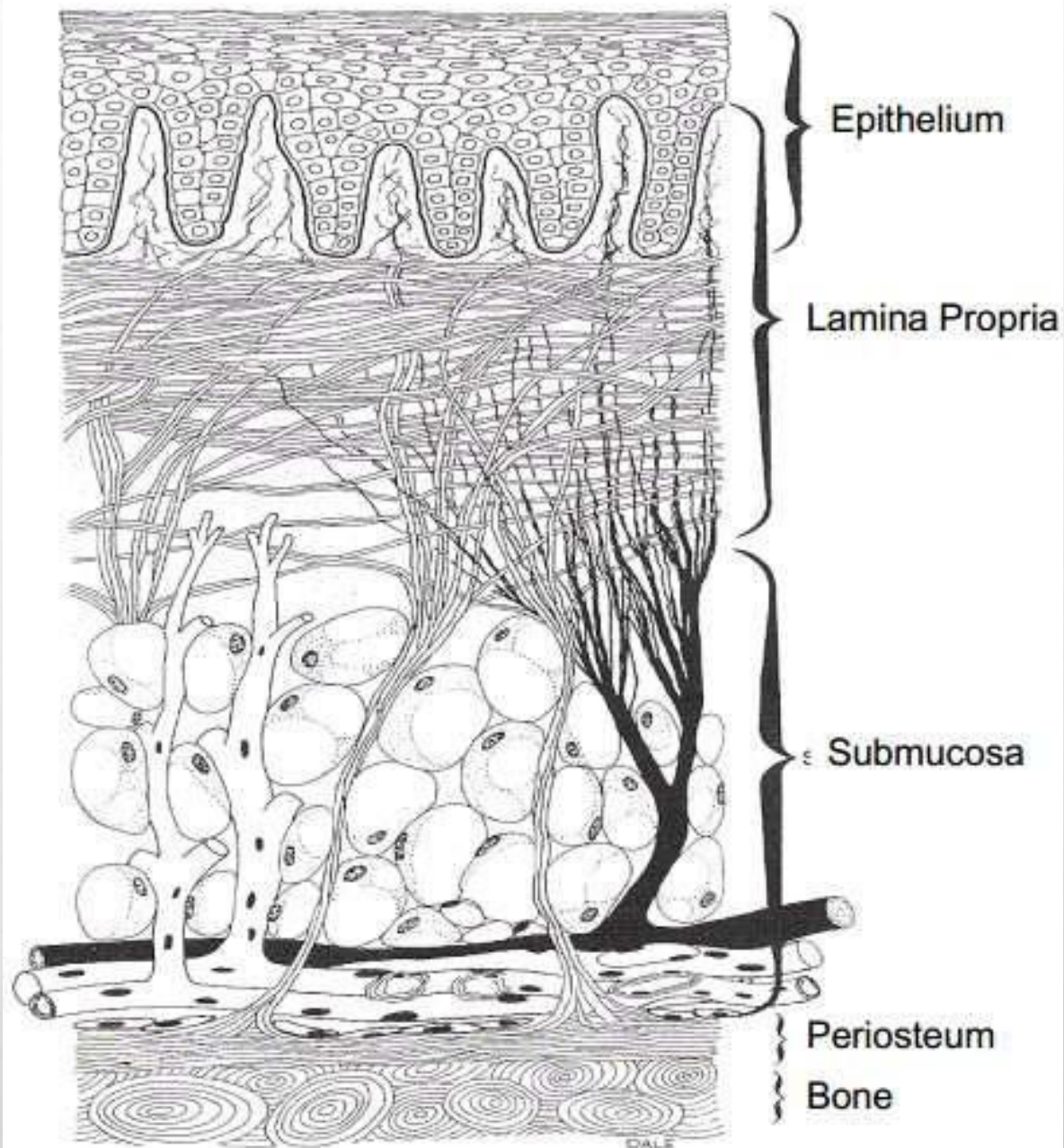
Submucosa

Lamina  
propria

Oral Mucous Membrane







Oral Mucous Membrane



# **SURFACE CHARACTERISTICS OF ORAL EPITHILUM**

# ORAL EPITHELIUM

**Oral epithelium forms the surface of the oral mucosa that forms a barrier between the oral environment and the deeper tissues**



**It is derived from the embryonic ectoderm.**



**It is stratified squamous epithelium and may or may not be keratinized.**



**Beneath the epithelium lies the connective tissue**

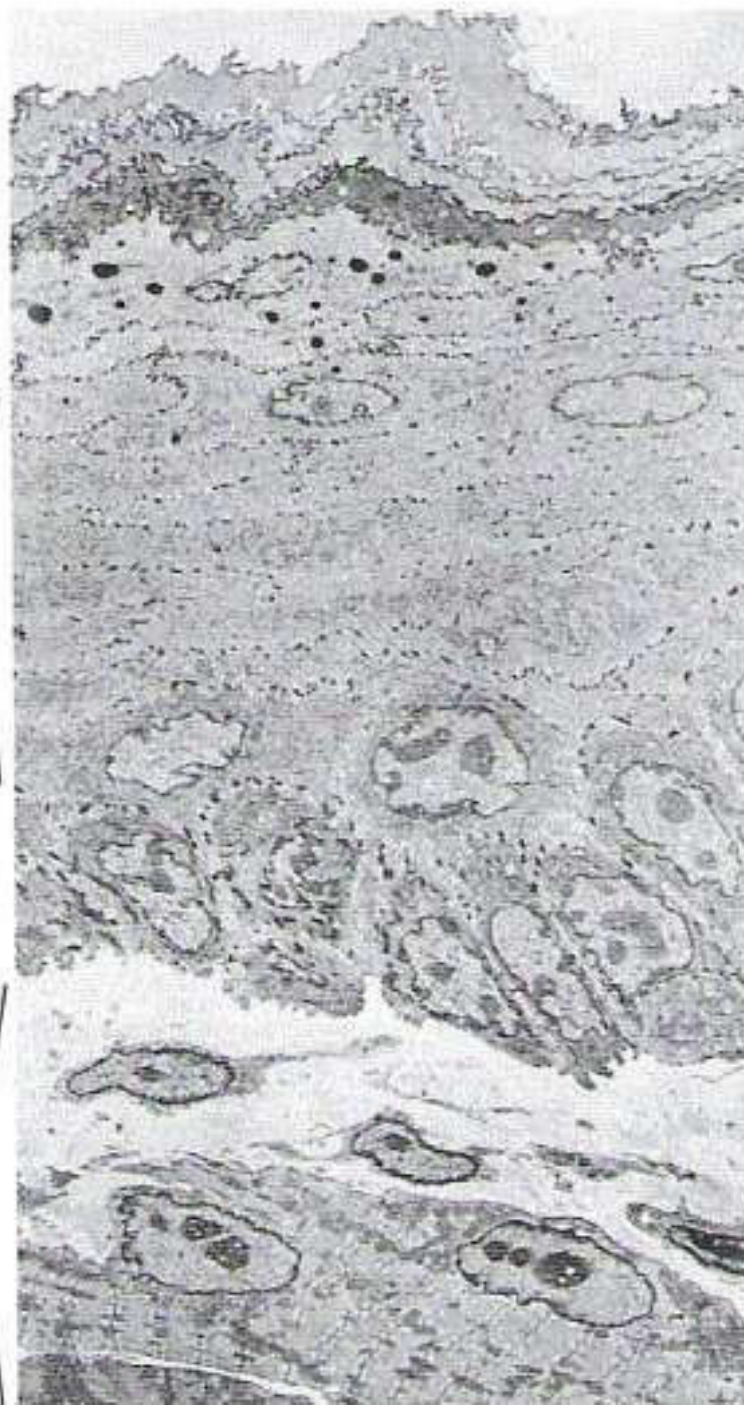
Stratum corneum

Stratum granulosum

Stratum spinosum

Stratum basale

Lamina propria



Oral Epithelium  
-Keratinized




# KERATINIZED ORAL EPITHELIUM

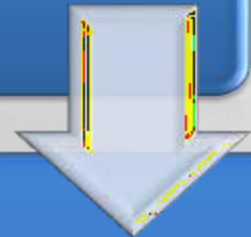
Most of the oral mucosal surface is

**lined by nonkeratinized stratified squamous epithelium except gingiva, hard palate and dorsal surface of the tongue where the epithelium is keratinized**

keratinized



**The keratinized cells have no nuclei and the cytoplasm is displaced by large numbers of keratin filaments**



**Keratinized epithelium is associated with masticatory function and have four layers of cells**

# LAYERS OF THE KERATINIZED SURFACE EPITHELIUM

**1.Stratum  
Basale**

**2.Stratum  
Spinosum**


**3.Stratum  
Granulosum**

**4.Stratum  
Corneum**

Stratum corneum {  
Stratum granulosum {

Stratum spinosum {

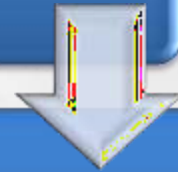
Stratum basale {



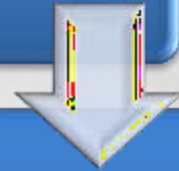
Cellular layers of oral epithelium - Keratinized

# STRATUM BASALE

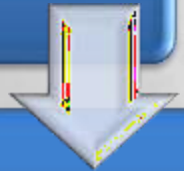**The cells of the stratum basale are cuboidal or low columnar and form a single layer resting on the basal lamina**



**The basal lamina is at the interface of the epithelium and lamina propria**



**Epithelial cells of the oral mucosa are in a constant state of renewal**

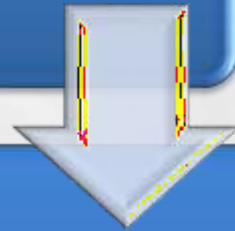


**The basal cells show the maximum mitotic activity**

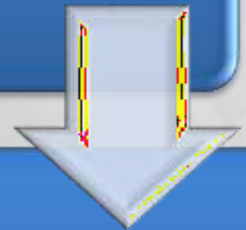


# STRATUM SPINOSUM

**Stratum spinosum is usually several cells thick**



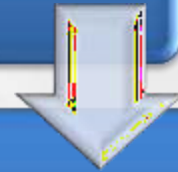
**They are shaped like polyhedron with short cytoplasmic processes**



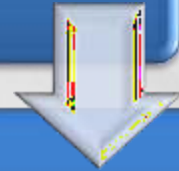
**The stratum basale and the first layers of stratum spinosum are referred to as **stratum germinativum** because these cells give rise to new epithelial cells**

# STRATUM GRANULOSUM

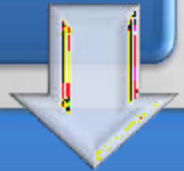**Cells of stratum granulosum are flat and are found in layers of three to five cells thick**



**This layer is prominent in keratinized epithelium (and absent in nonkeratinized epithelium)**



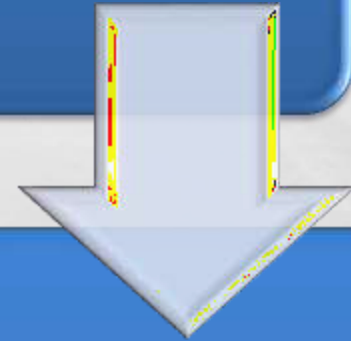**These cells have keratohyaline granules in their cytoplasm**



**Keratohyaline granules help to form the matrix of the keratin fibres found in the superficial layer**

# STRATUM CORNEUM

**Cells of stratum corneum are flat, devoid of nuclei and full of keratin filament surrounded by a matrix**



**These cells are continuously being sloughed and are replaced by epithelial cells that migrate from the underlying layers**





# ***TYPES OF KERATINIZATION***

## **Orthokeratinization**

**About 20-30% of gingiva, the stratum corneum homogenous and made up of flat, closely packed keratinized cells with out nuclei**

## **Parakeratinization**

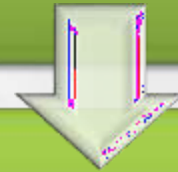
- Approximately 50-70% of the cases, the stratum corneum is homogeneous and consists of flat keratinized cells with pyknotic nuclei and remnants of cytoplasmic organelles**

## **Incomplete Keratinization**

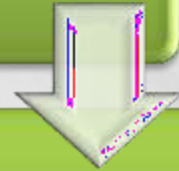
- Last common type, approximately 7-10% of cases and is seen only in the region of the marginal gingiva. Stratum corneum is homogenous and consists of 2 cell types, which occasionally form 2 superimposed layers: the first type of cell is the same as cornified cell of a parakeratinized stratum corneum; the 2nd type is different from keratinized cells and seems to reach the stratum corneum and its surface without being transformed into a keratinized cell.**

# **NONKERATINIZED ORAL EPITHELIUM**

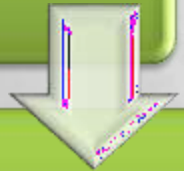
**NONKERATINIZED EPITHELIAL CELLS IN THE SUPERFICIAL LAYERS DO NOT HAVE KERATIN FILAMENTS IN THE CYTOPLASM**



**The surface cells also have nuclei**

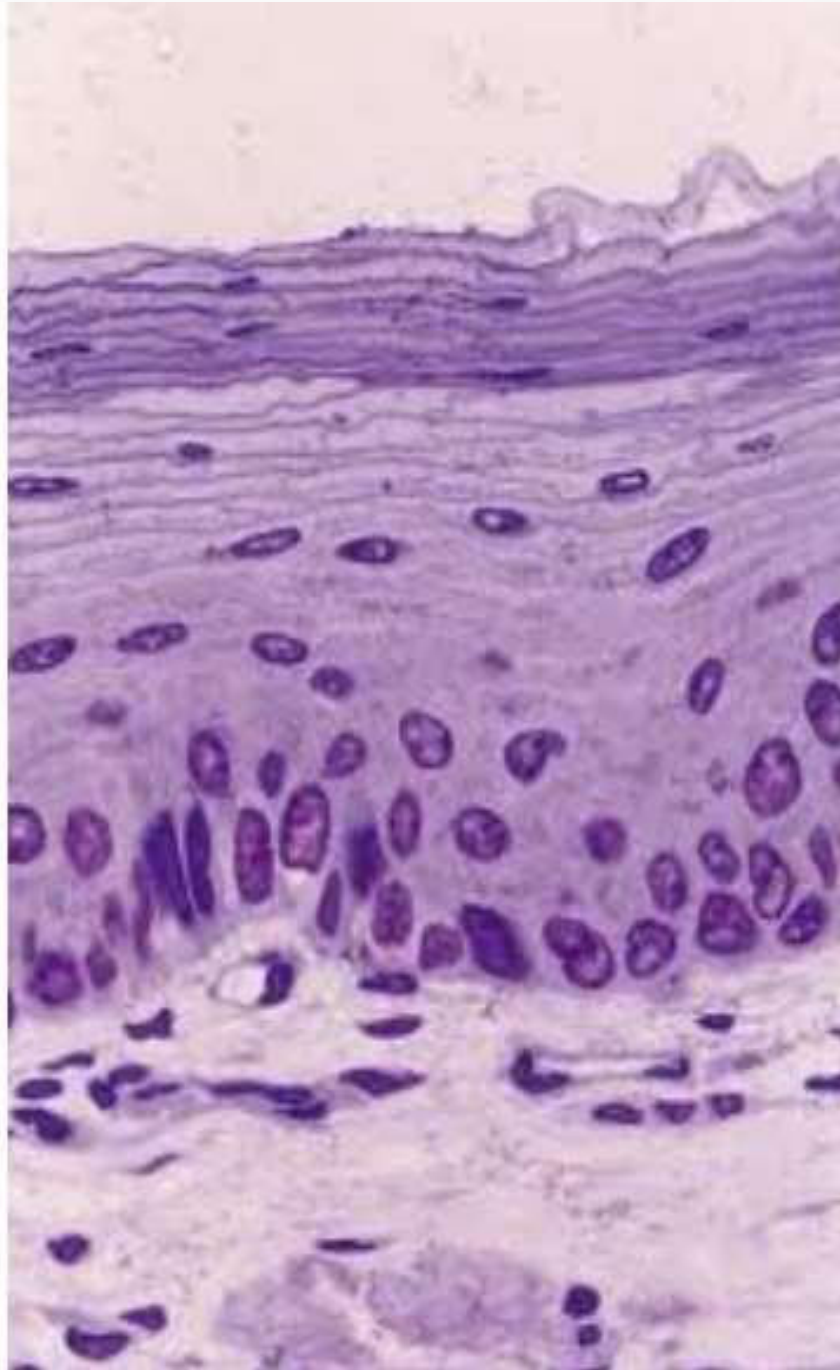


**The stratum corneum and stratum granulosum layers are absent**



**This epithelium is associated with lining of the oral cavity**





Non-keratinized  
squamous epithelium



# CONNECTIVE TISSUE

## Connective tissue can be differentiated as Lamina Propria and Submucosa

### Lamina propria

- Lamina propria is the connective tissue layer immediately below the epithelium

Lamina propria can be divided into:

1) papillary layer - prominent in masticatory mucosa  
2) reticular layer - prominent in lining mucosa

- Lamina propria consists of blood vessels and cells like fibroblasts, cells of blood vessels and lymphatics and nerves

- Epithelium is avascular, hence its metabolic needs come via the vessels of the lamina propria

# **SUBMUCOSA**

- **Submucosa lies below the lamina propria and serves as an attachment between lamina propria and bone or skeletal muscle**
- **It is found in the cheeks, lips and parts of the palate**
- **It consists of large blood vessels, nerves and lymphatics and its functions of mucosa are nutrition and defensive.**



# FUNCTIONAL TYPES OF ORAL MUCOSA

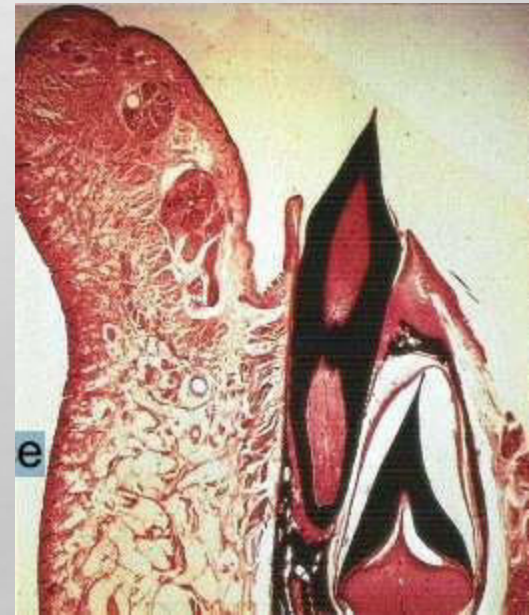## A) Lining mucosa

- Lining mucosa covers all soft tissues of the oral cavity except the gingiva, hard palate and the dorsal surface of the tongue

### *Lip*

**Lip is covered by lining mucosa**

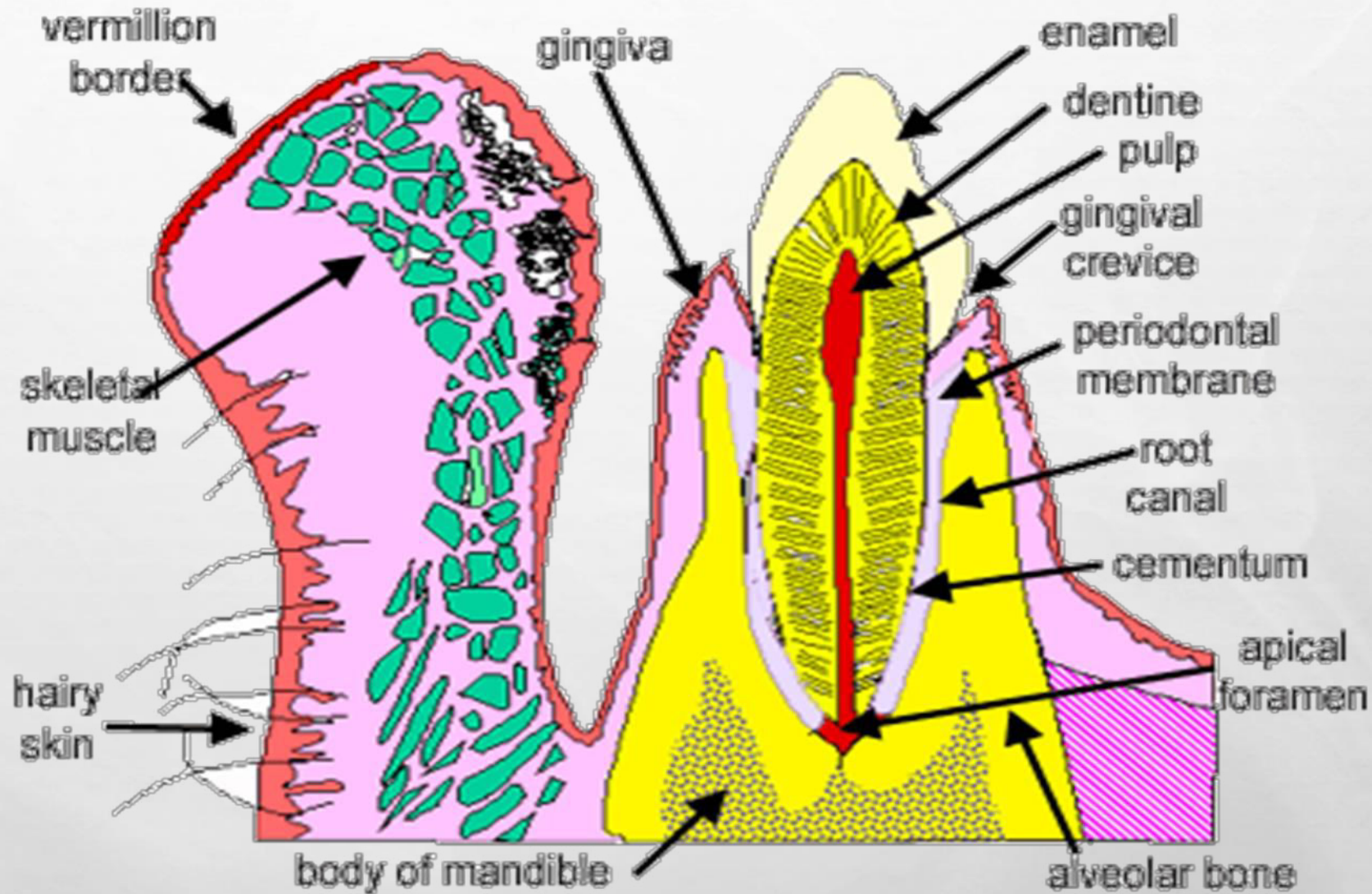
*Lip with skin on outer surface  
and lining mucosa on inner  
surface*



# Vermilion border



- THE JUNCTION BETWEEN THE SKIN AND MUCOUS MEMBRANE IS
- KNOWN AS THE VERMILION BORDER.
- HERE THE EPITHELIUM IS THIN THEREFORE, THE RED BLOOD CELLS IN THE
- CAPILLARIES SHOW THROUGH CONTRIBUTING TO THE VERMILION COLOUR

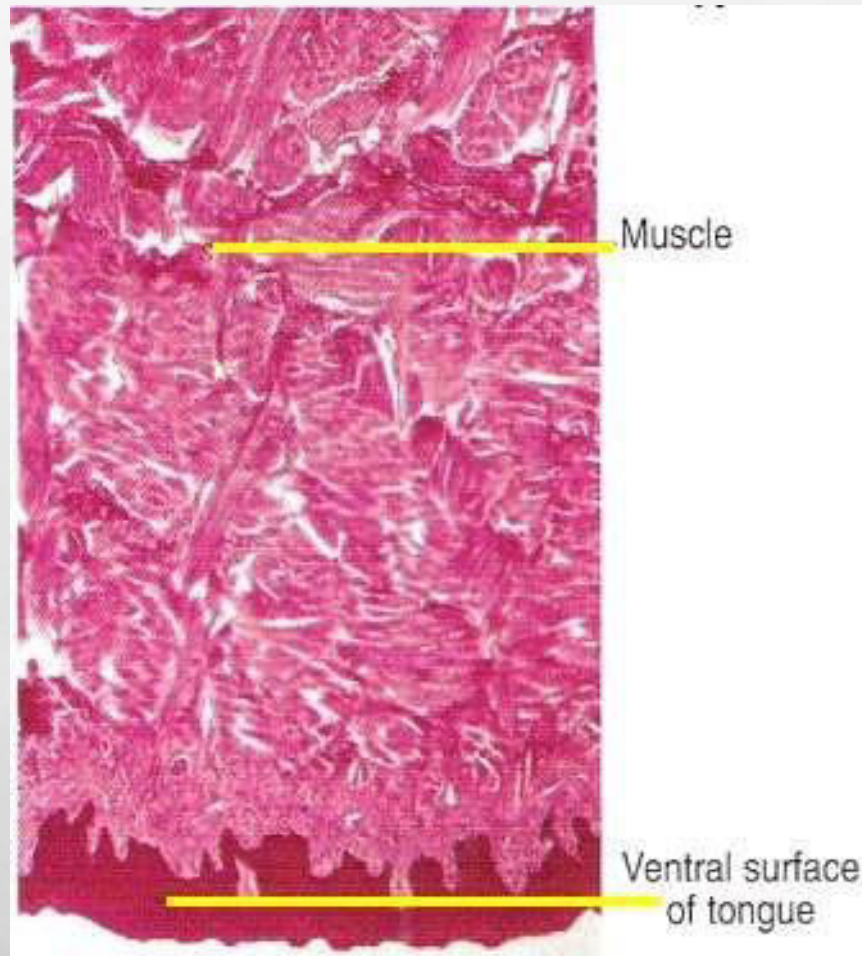




## ***Ventral surface of the tongue***

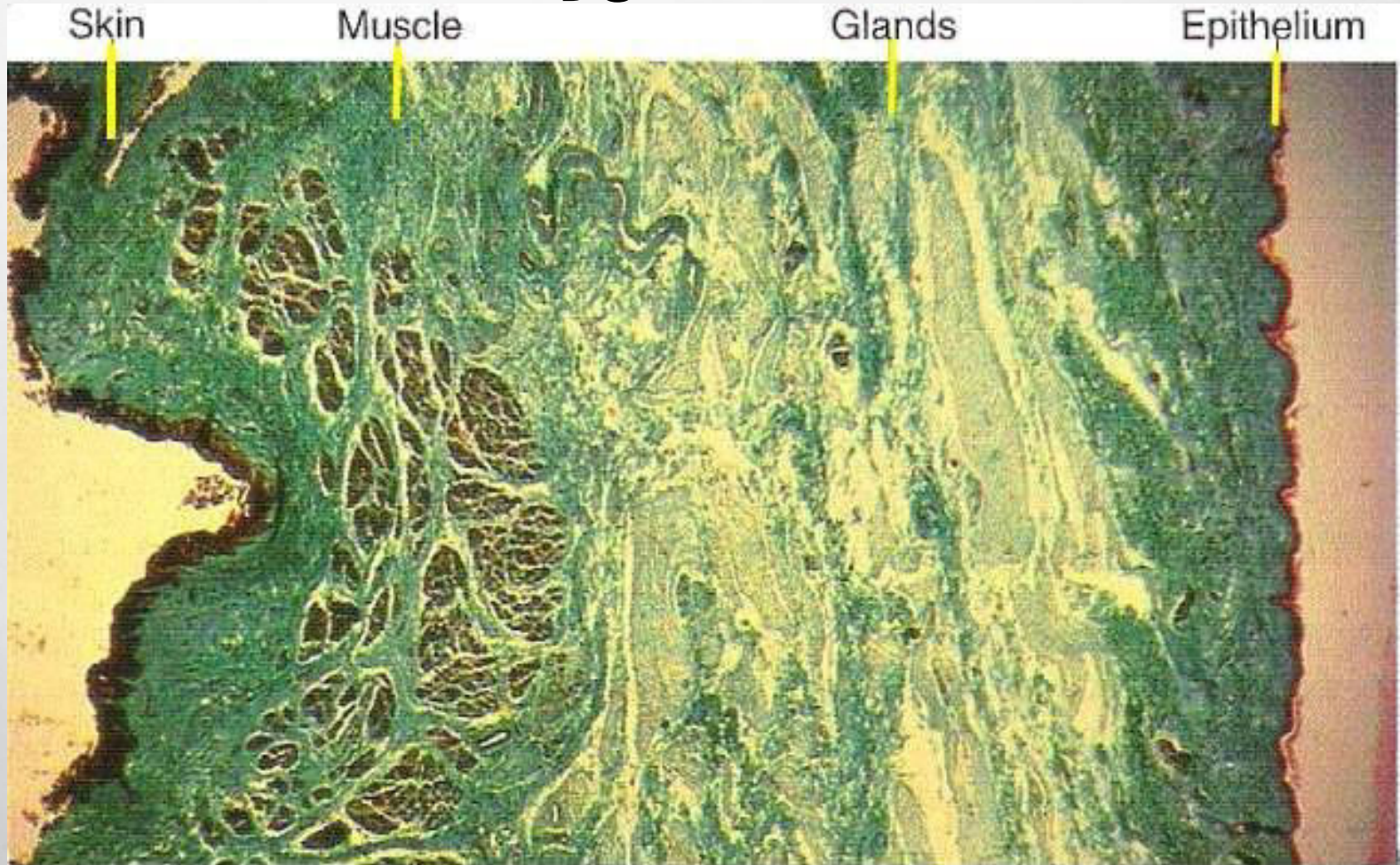
**The lining mucosa here contains both lamina propria and submucosa**

**The submucosa merges with the muscle bundles of the ventral surface of the tongue**



# ***Cheek***

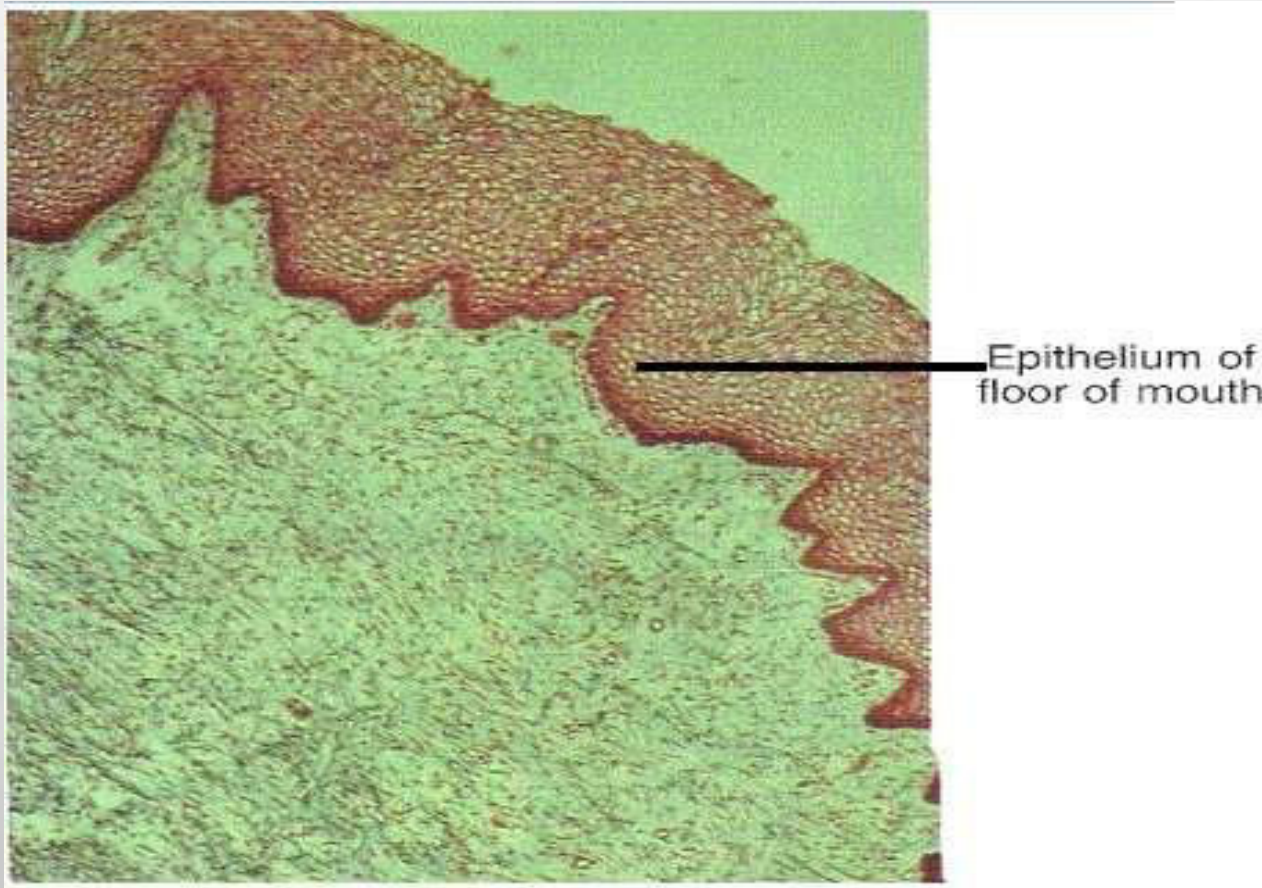
**In the cheek the underlying submucosa contains fat cells  
an small mixed salivary glands**





# **FLOOR OF THE MOUTH**

**THE MUCOUS MEMBRANE OF THE FLOOR OF THE MOUTH IS THIN AND LOOSELY ATTACHED TO THE UNDERLYING STRUCTURES**



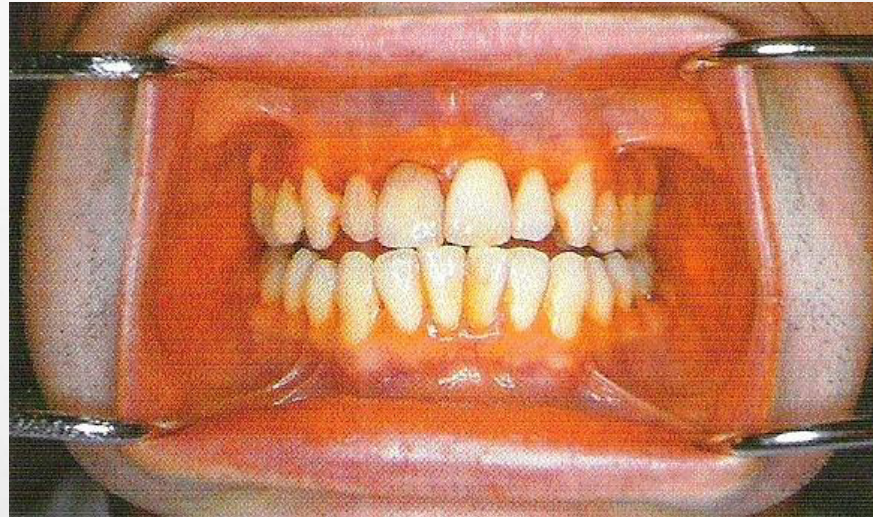

## **B) MASTICATORY MUCOSA**

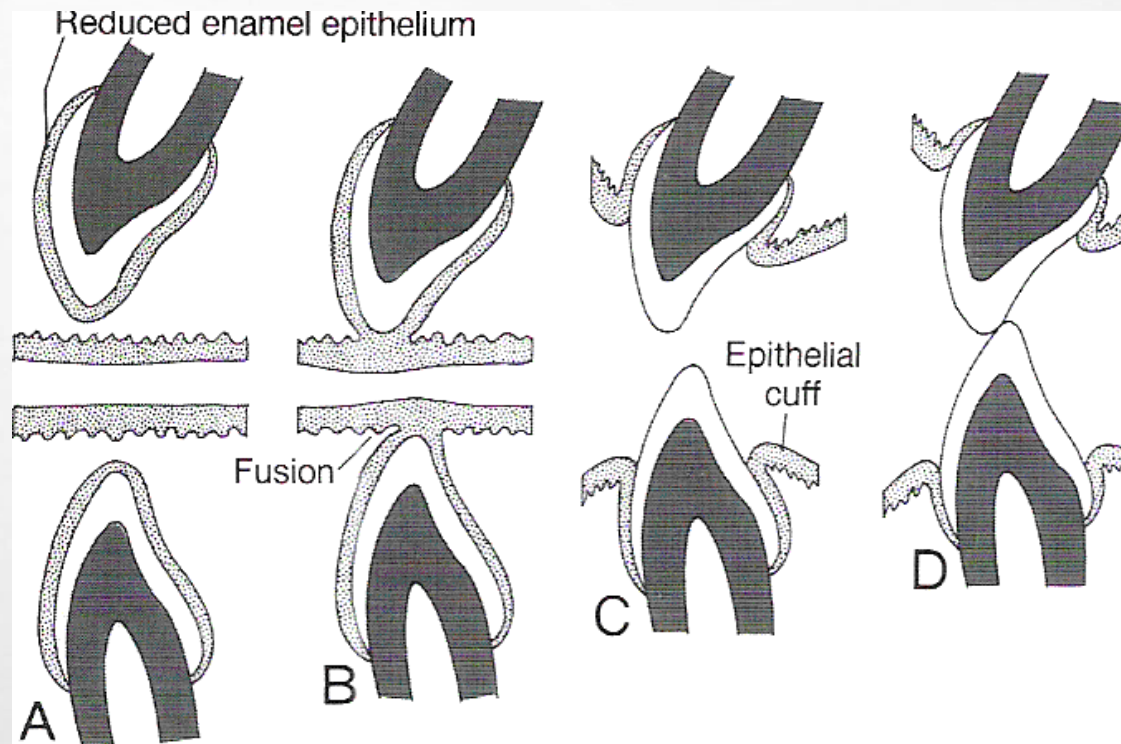
- **Masticatory mucosa covers the gingiva and hard palate and dorsal surface of tongue.**
- **In edentulous mouth, masticatory mucosa covers the chewing surface of the dental arches.**

### ***Gingiva***

- **Gingiva has keratinized or parakeratinized epithelium with no submucosal layer**
- **It develops from the union of oral epithelium and reduced enamel epithelium of the developing tooth**

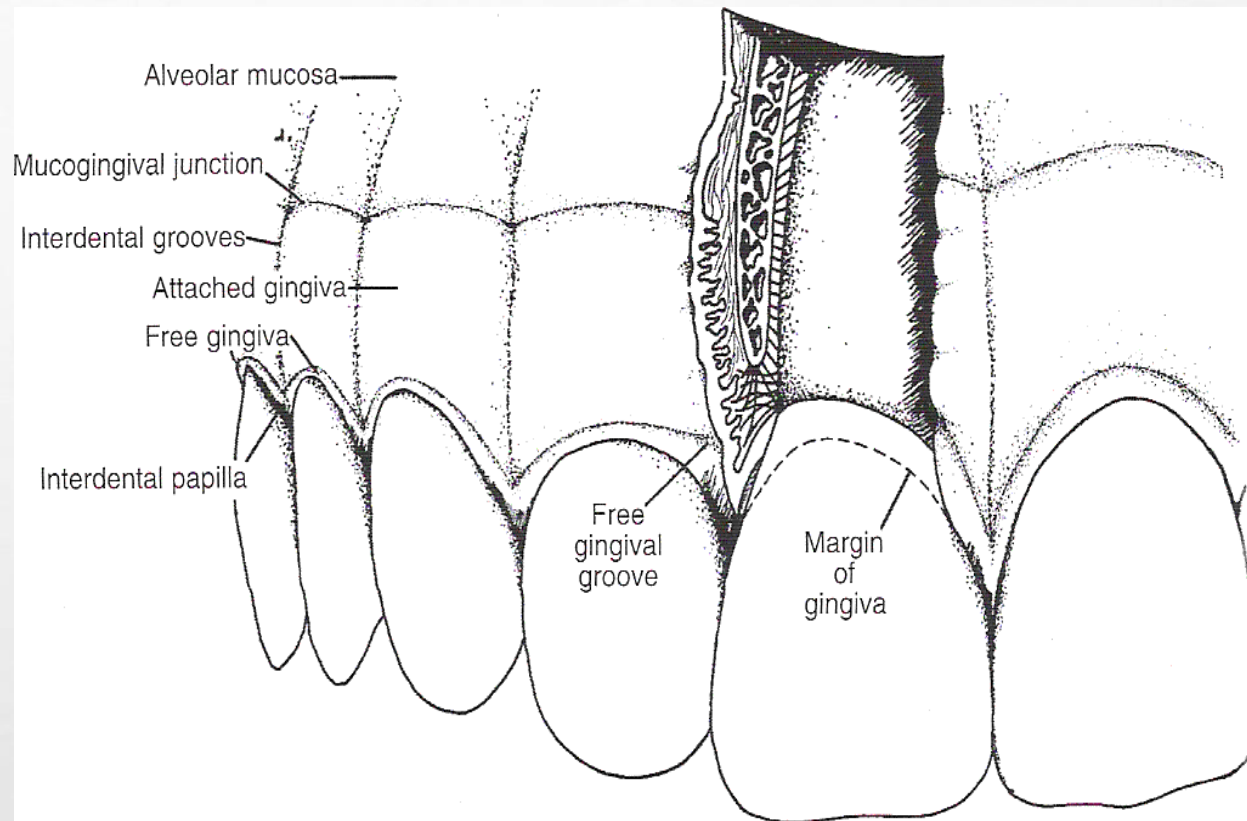


Normal Gingiva



Development of gingiva from oral epithelium and reduced enamel epithelium





Anatomy of gingiva

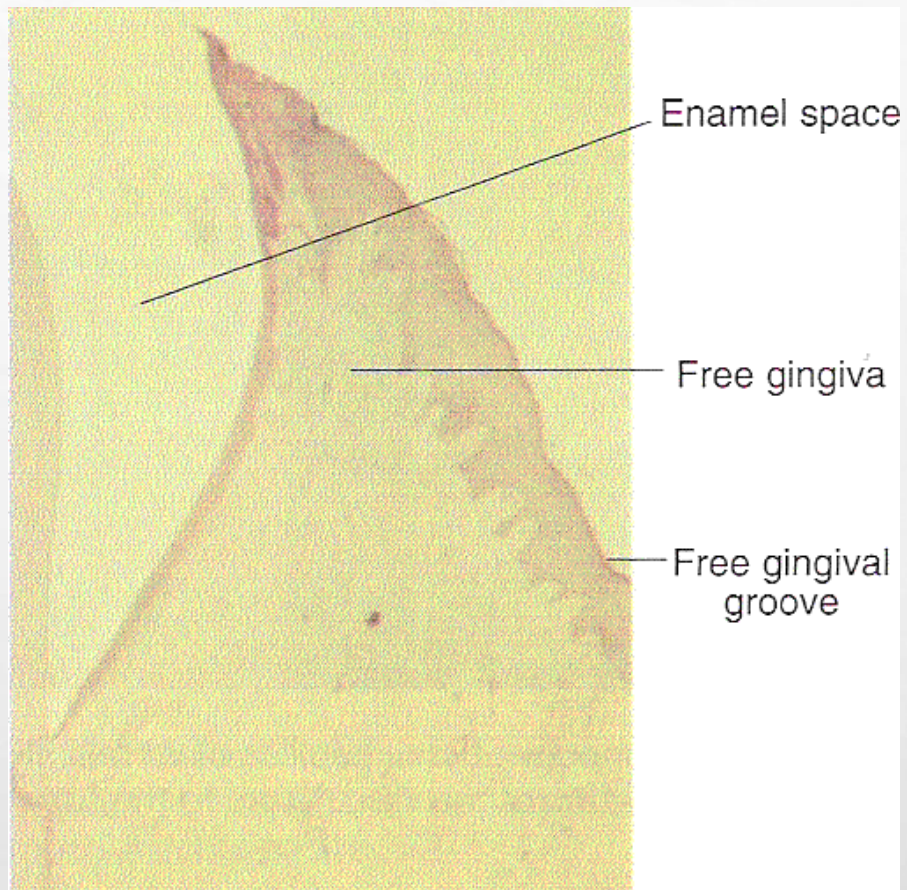
## Free gingiva (or marginal gingiva)

It is that part of the oral mucosa that surrounds the necks of the teeth and forms the free margin of the gingival tissue

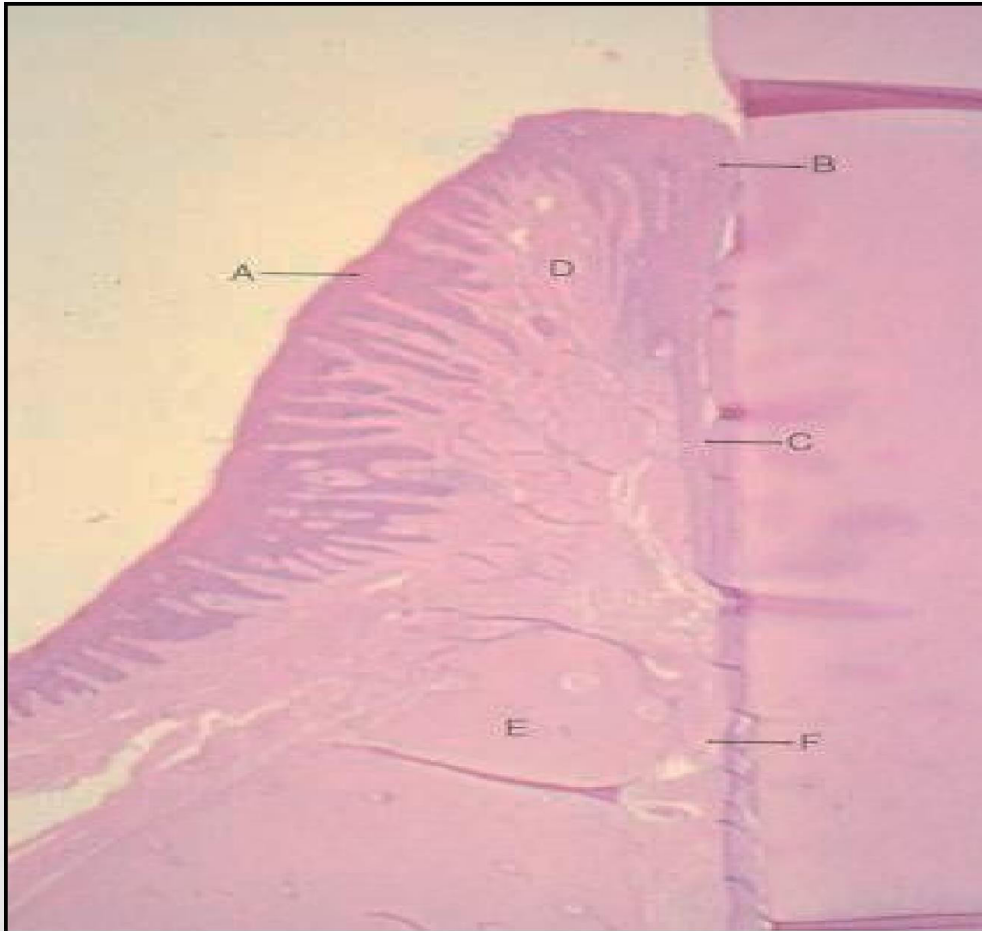
It is differentiated apically from the attached gingiva by the **free gingival groove**

The inner side of it forms the **gingival sulcus**

The free gingival mucosa is composed of stratified squamous epithelium that may be keratinized, parakeratinized or sometimes nonkeratinized



Free gingiva



**A- gingiva**

**B- sulcular  
epithelium**

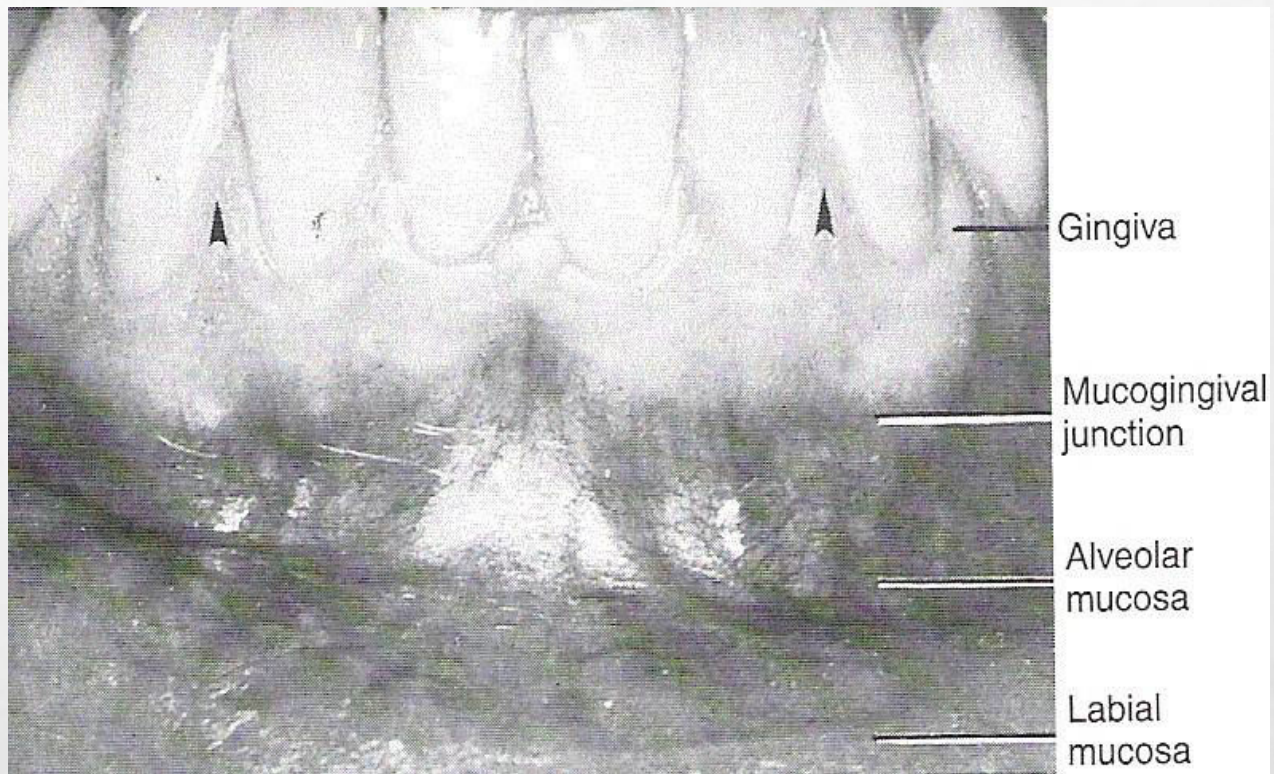**C- junctional  
epithelium**

**D- lamina  
propria  
(connective  
tissue)**

**E- alveolar  
process**

**F- PDL**





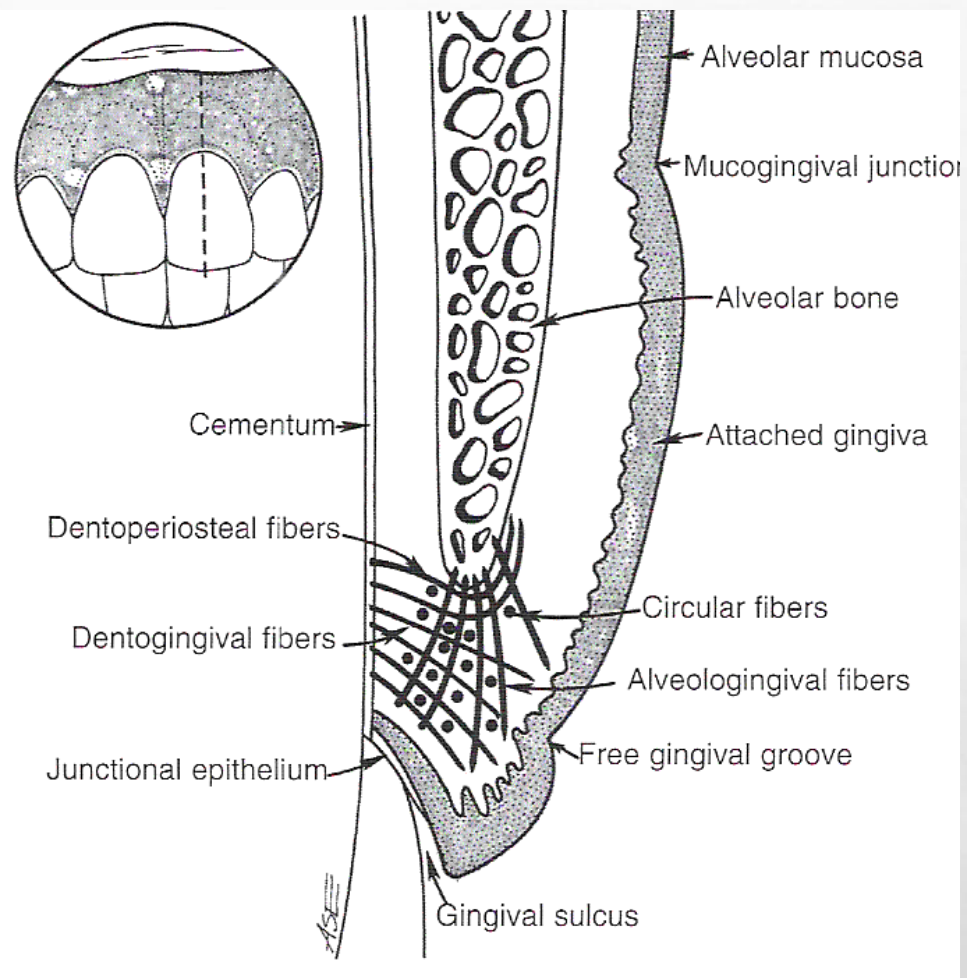
Alveolar Mucosa (Arrows - Interdental Papillae)

## Attached gingiva

The attached gingiva lies between the free gingival groove and the alveolar mucosa

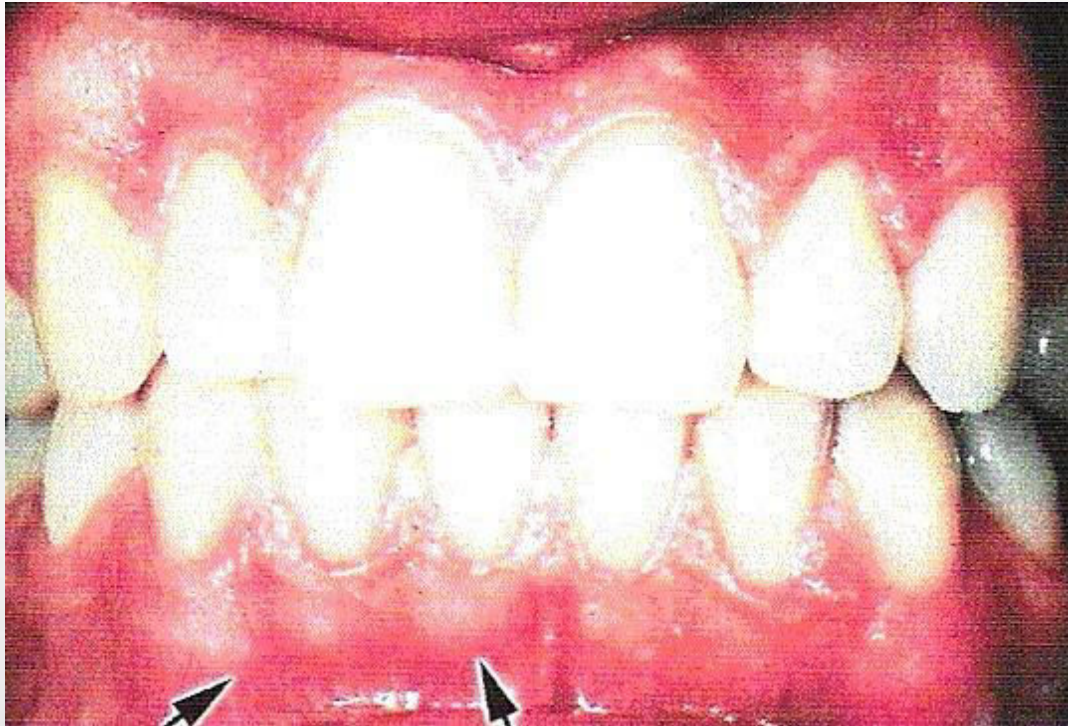The junction of the attached gingiva and the alveolar mucosa is called **mucogingival junction**

In healthy mouth attached gingiva shows stippling which is a characteristic of this type of mucosa

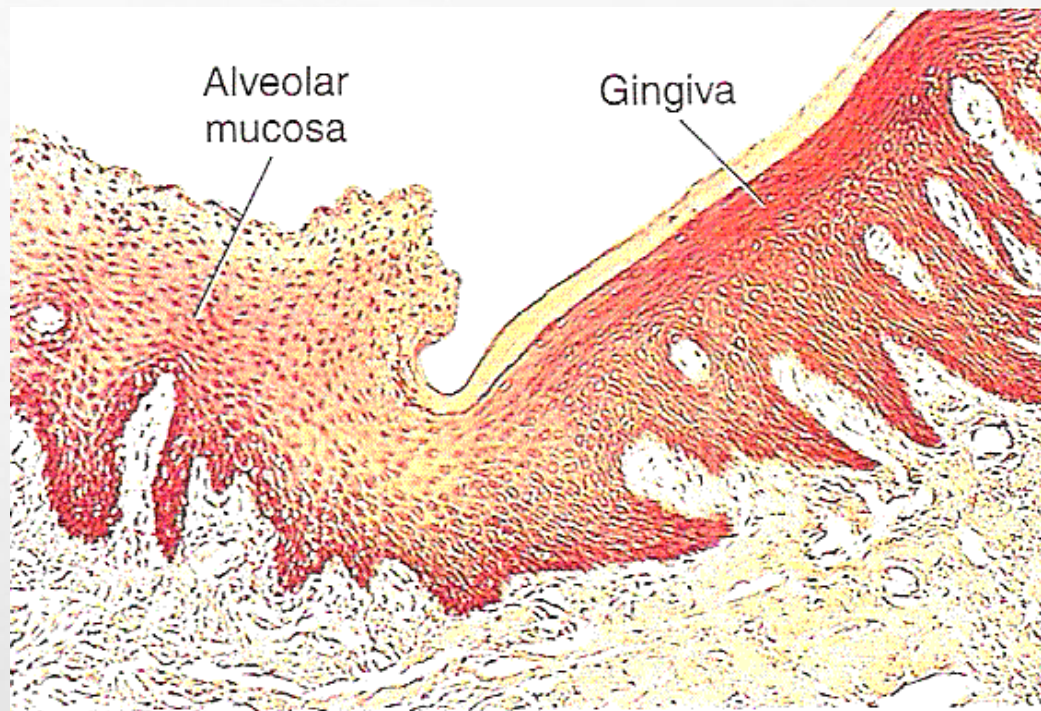


Histology of gingiva





Mucogingival junction (arrows)



Alveolar Mucosa

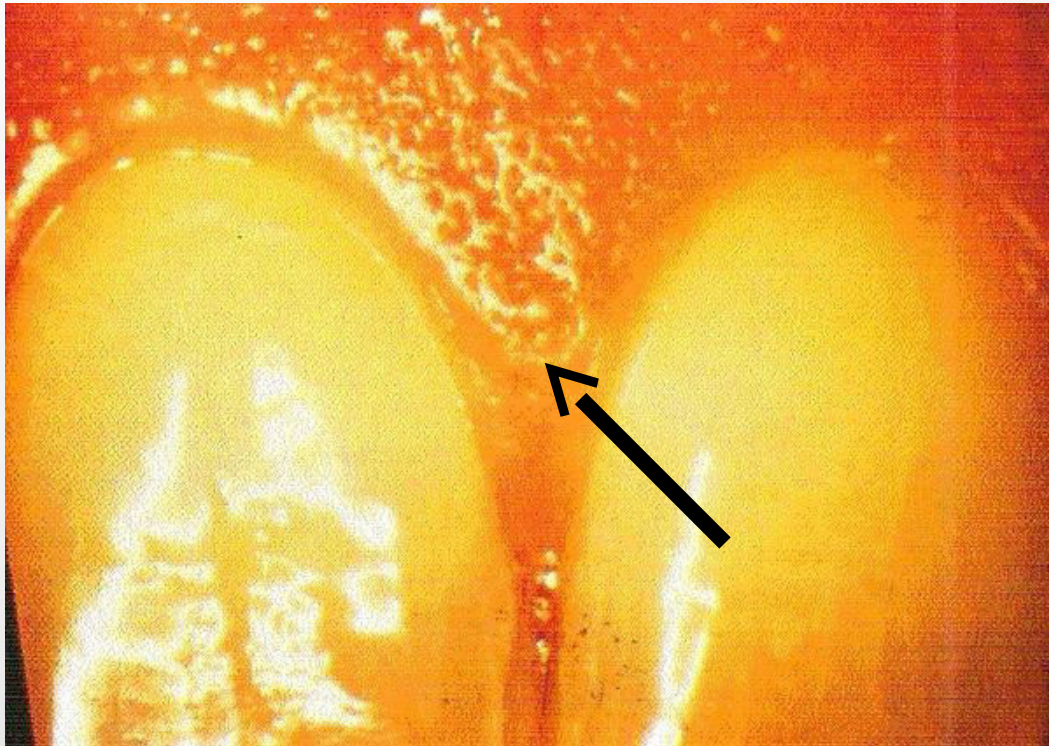
## Interdental papilla

Interdental papillae are those parts of gingival that appear in-between **teeth** apical to the contact points

Confirming to the shape of the interproximal contact area is a valley like depress in the interdental papilla called **Col.**

This depress lies in the facial and lingual plane





Interdental Papilla (arrow)

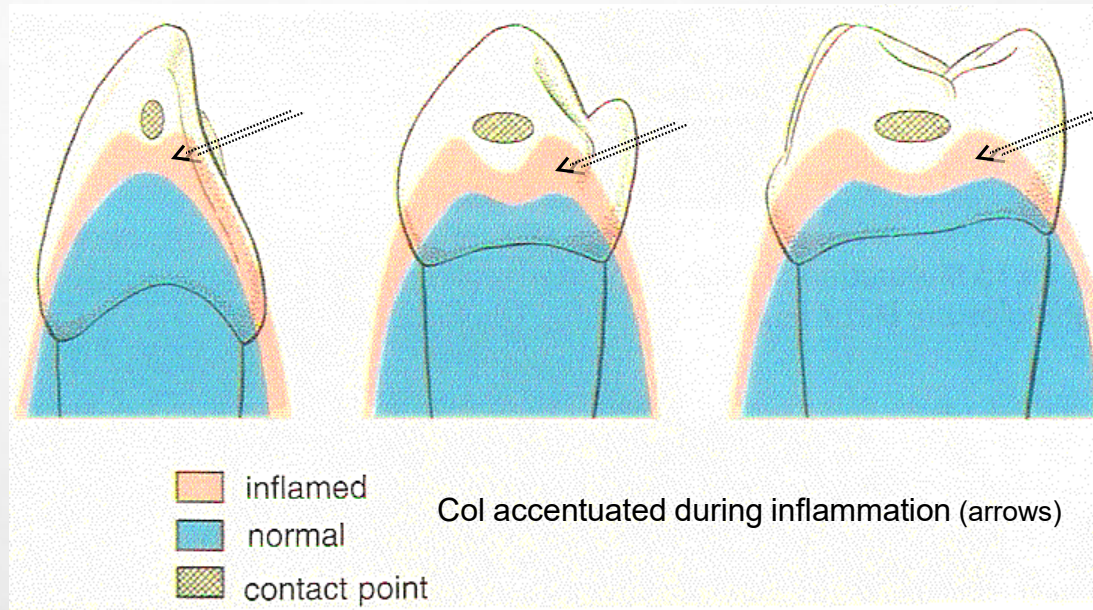


Diagram of positional relation of col in health and disease for canine, premolar and molar

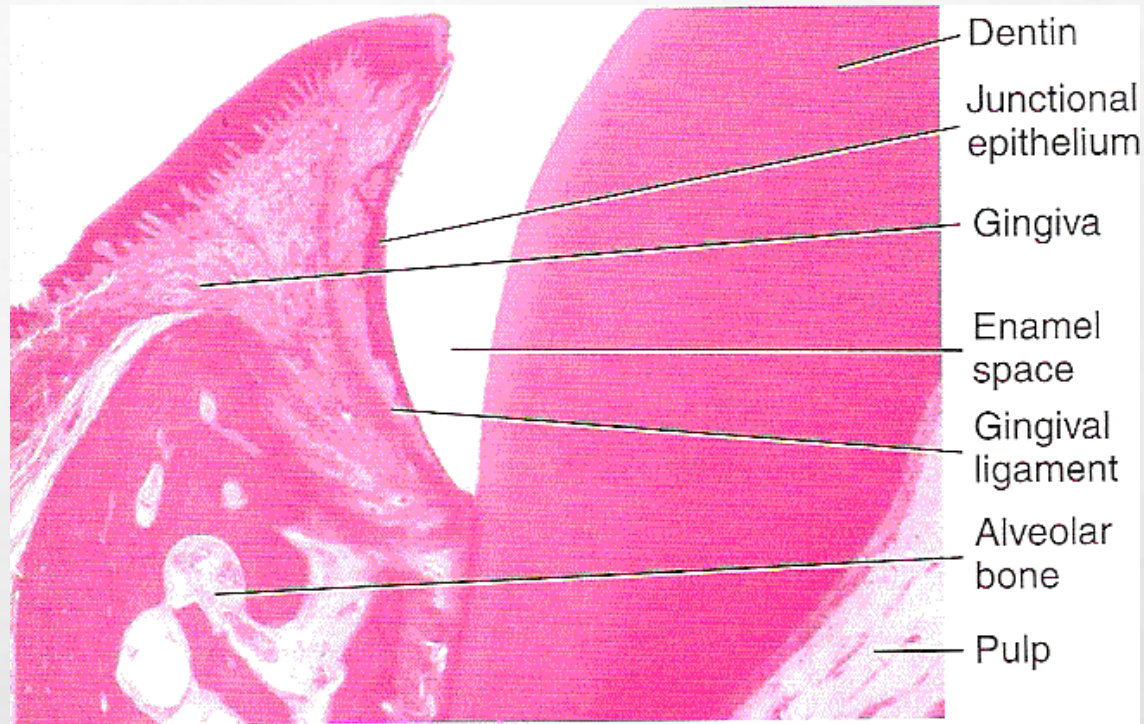
## Junctional epithelium

Junctional epithelium forms the seal of the gingival epithelium and the tooth

It forms the floor of the gingival sulcus and extends apically to the enamel of the tooth

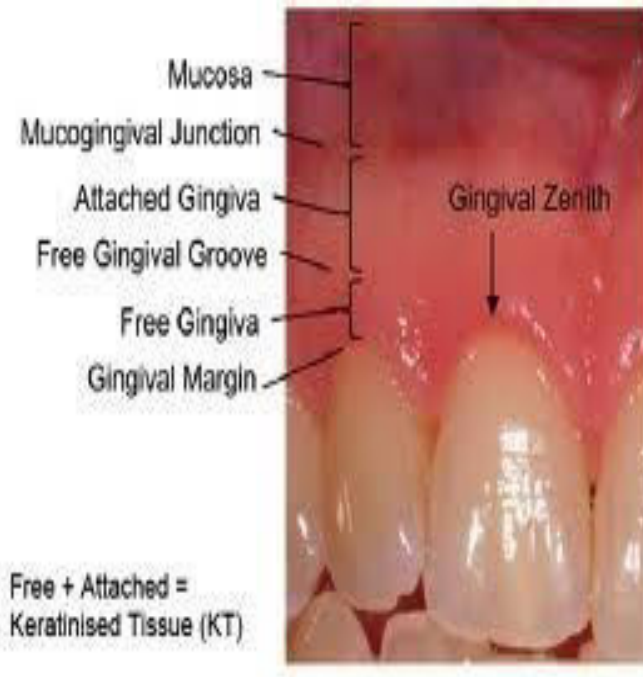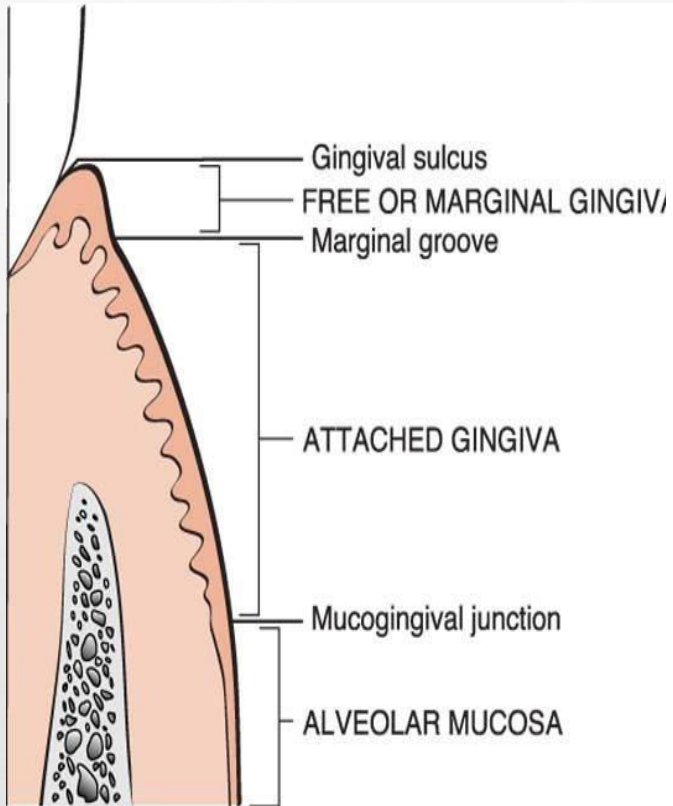
Disturbances of epithelial attachment results in deepening of the sulcus which is a sign of gingival/periodontal disease



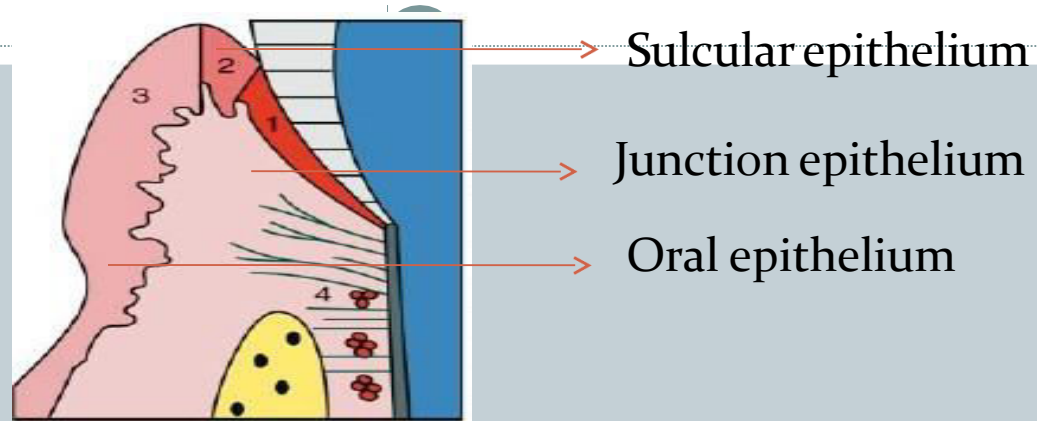


Histology of gingiva

# GINGIVA



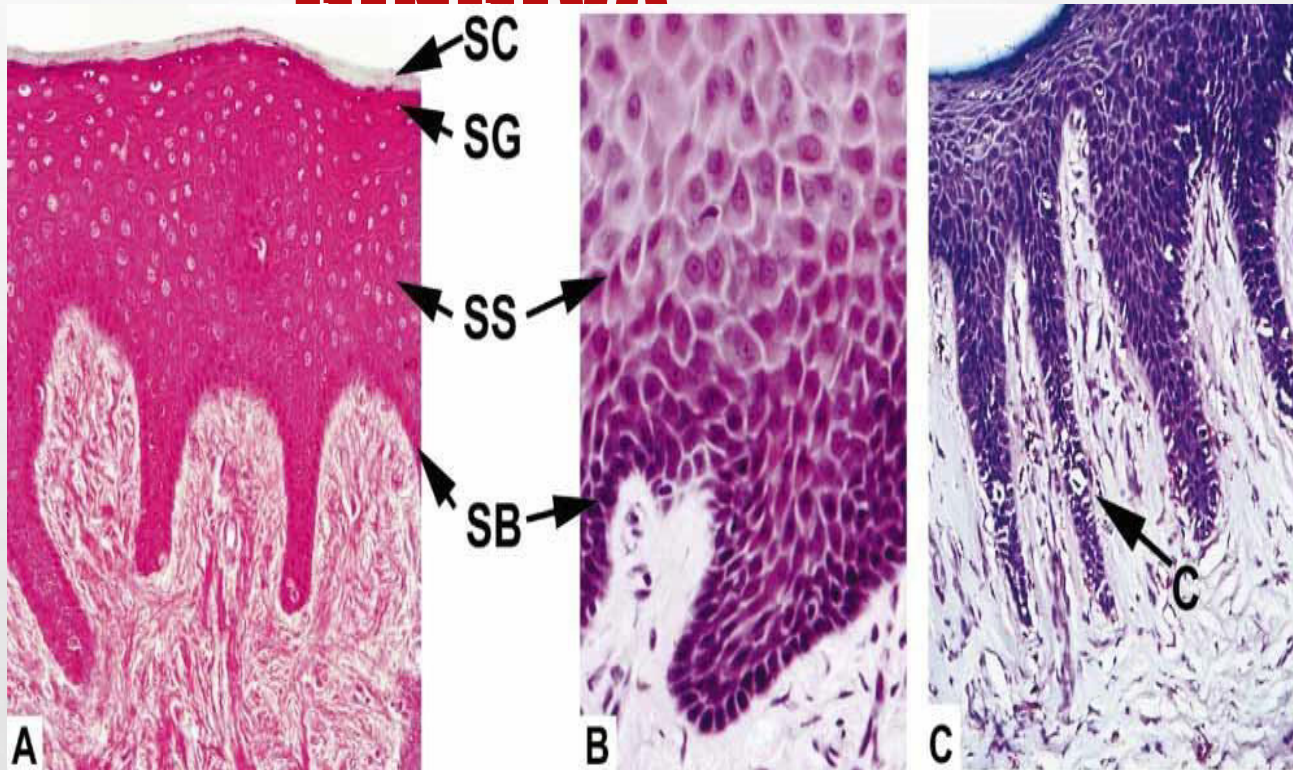
## ● TYPES OF EPIFHELIUM:



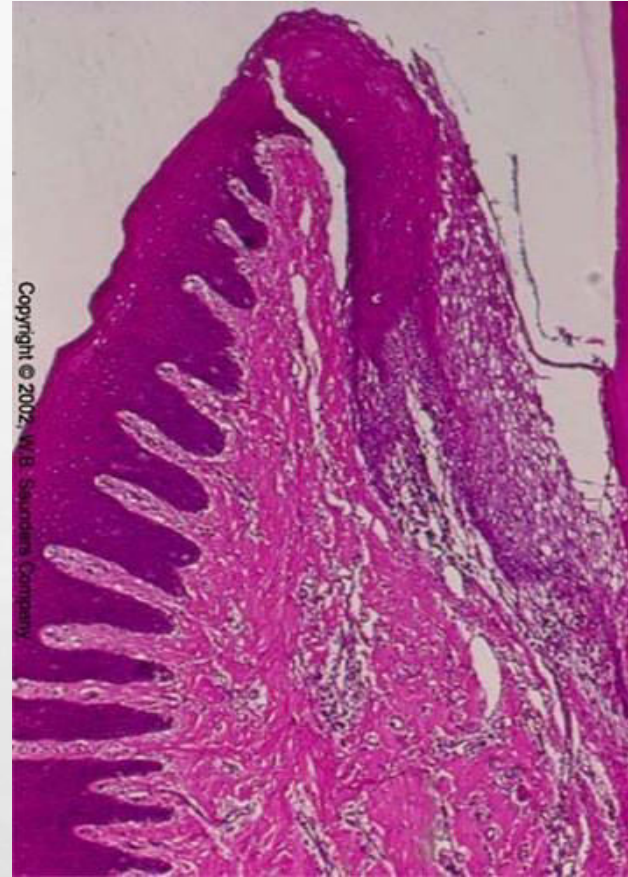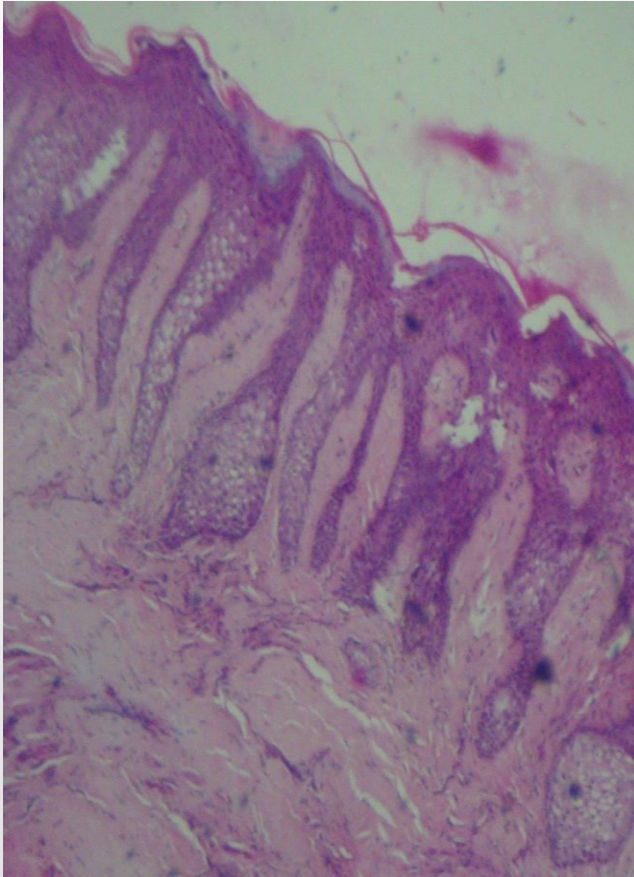
- Oral or outer epithelium
- sulcular epithelium
- Junctional epithelium



# HISTOLOGY OF CINCIVA



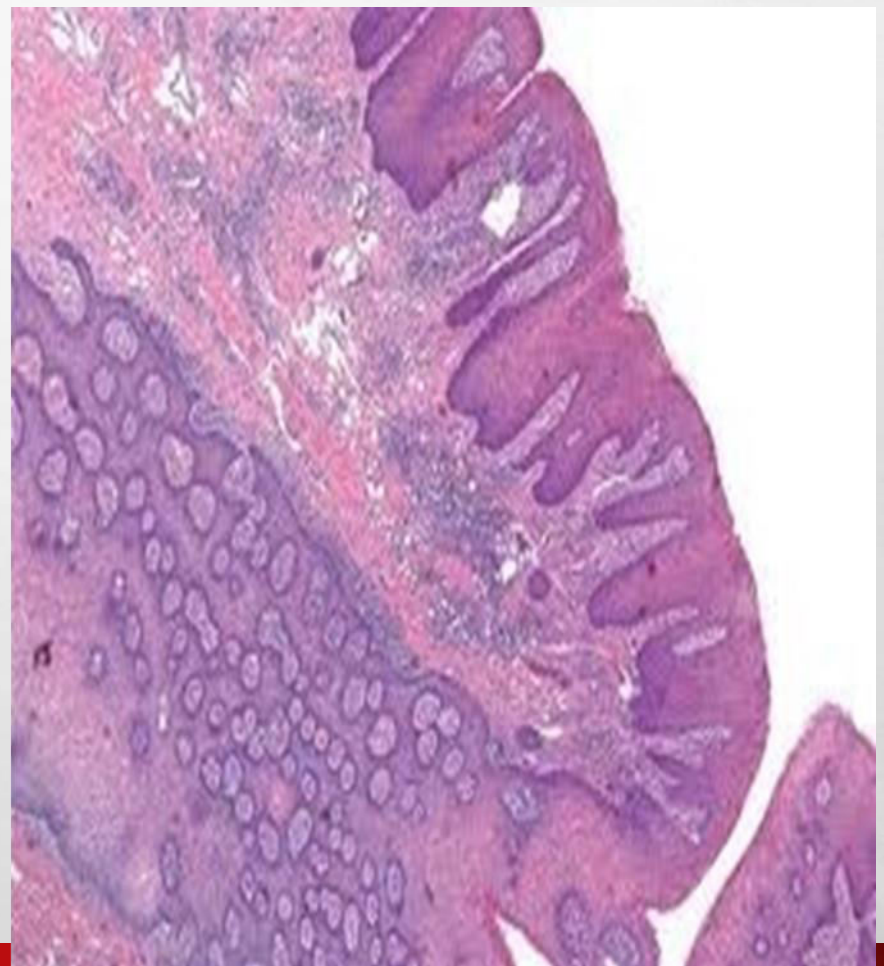
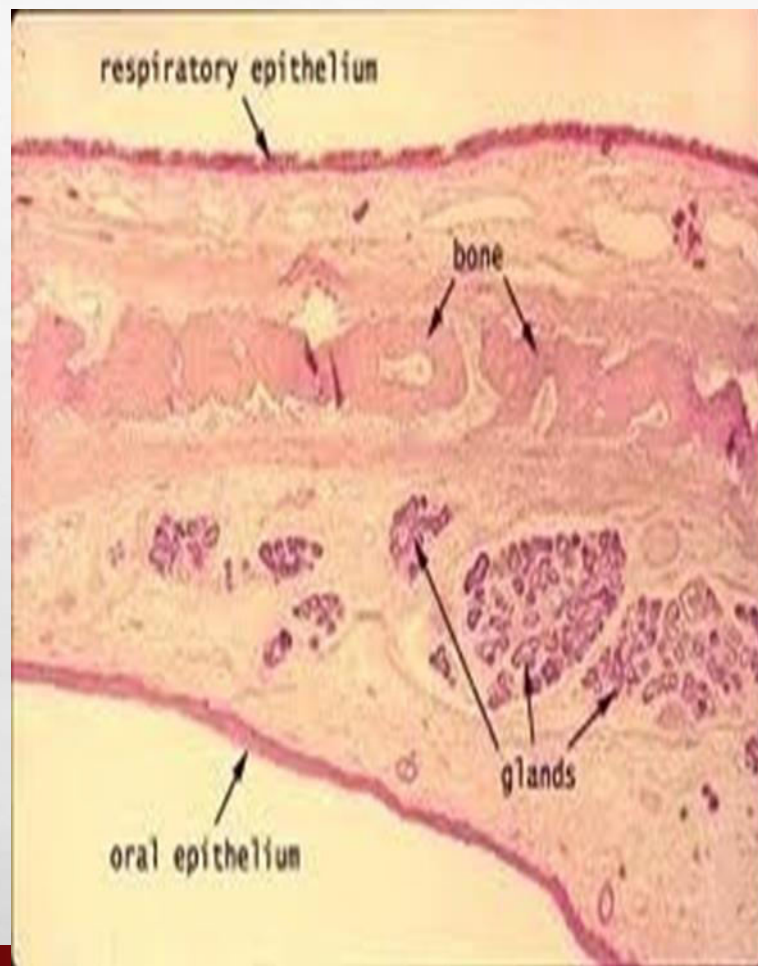
# GINGIVAL EPITHELIUM

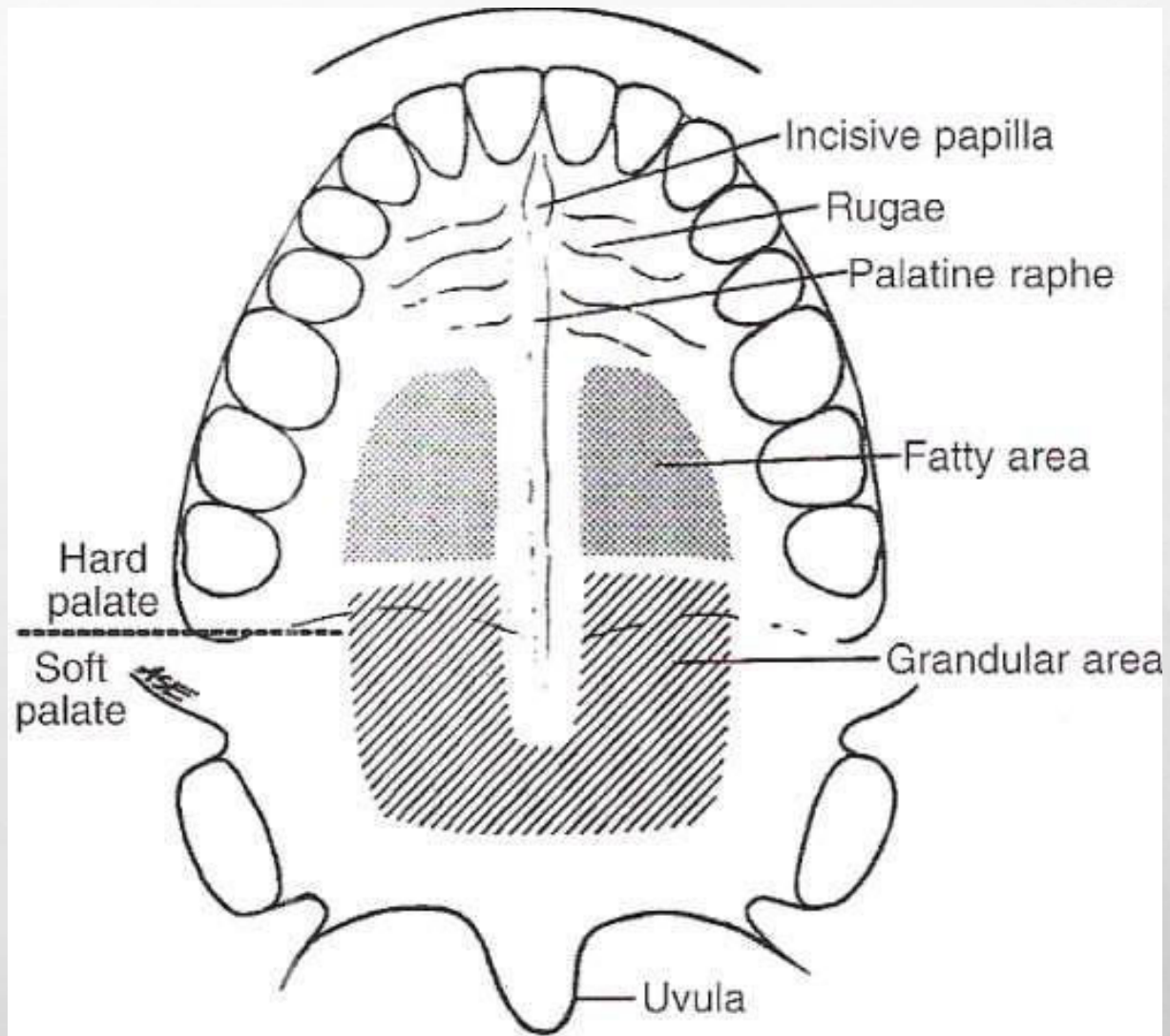


# HARD PALATE

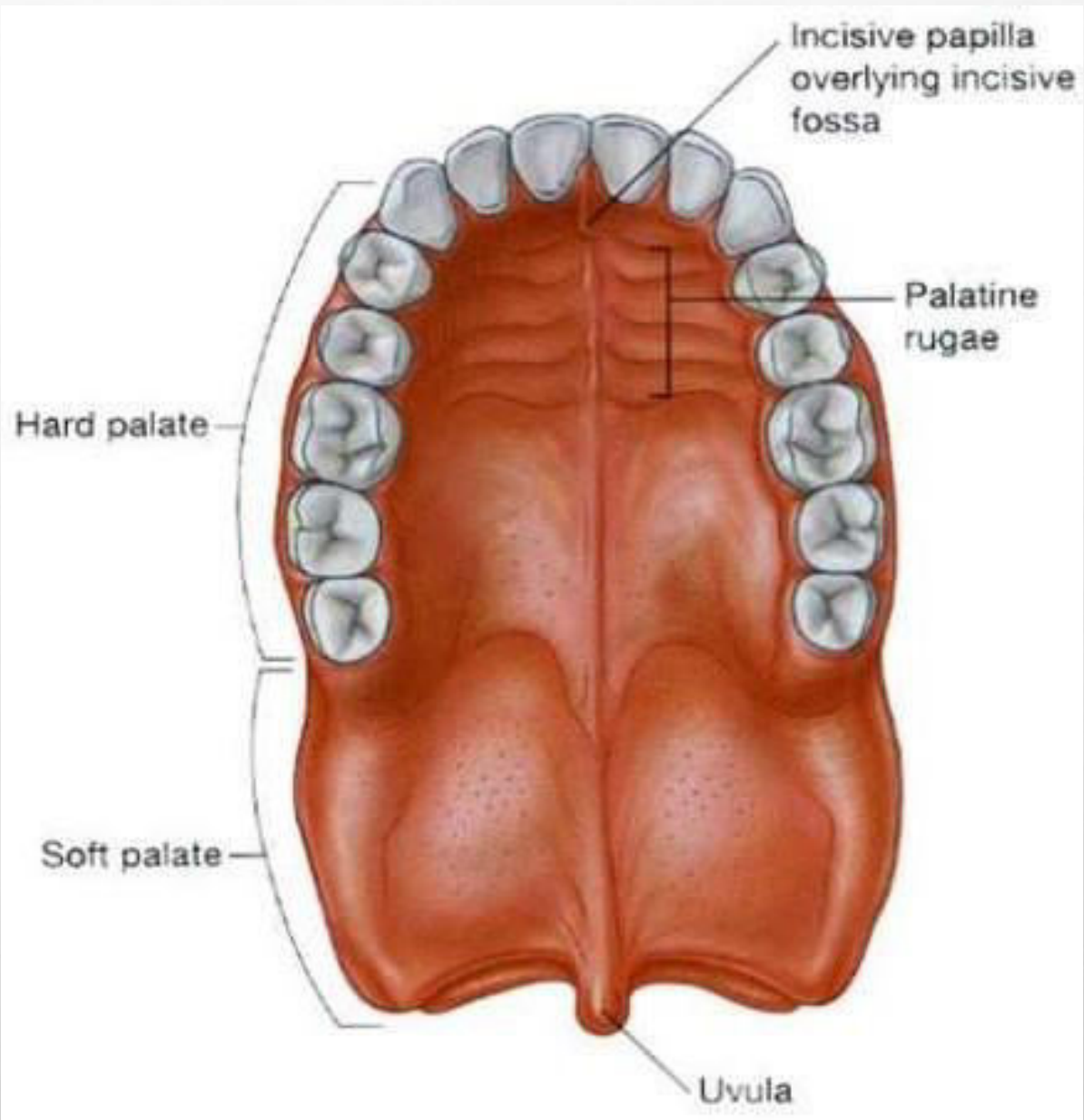
- The surface of the hard palate that is visible in the mouth is covered by masticatory mucosa
- The lateral regions of the posterior part contains *palatine glands*
- These glands are purely *mucous glands*
- The midline of the hard palate is called *median raphe*, where there is no submucosa
- A series of folds appear in the anterior part of the palate called *rugae*







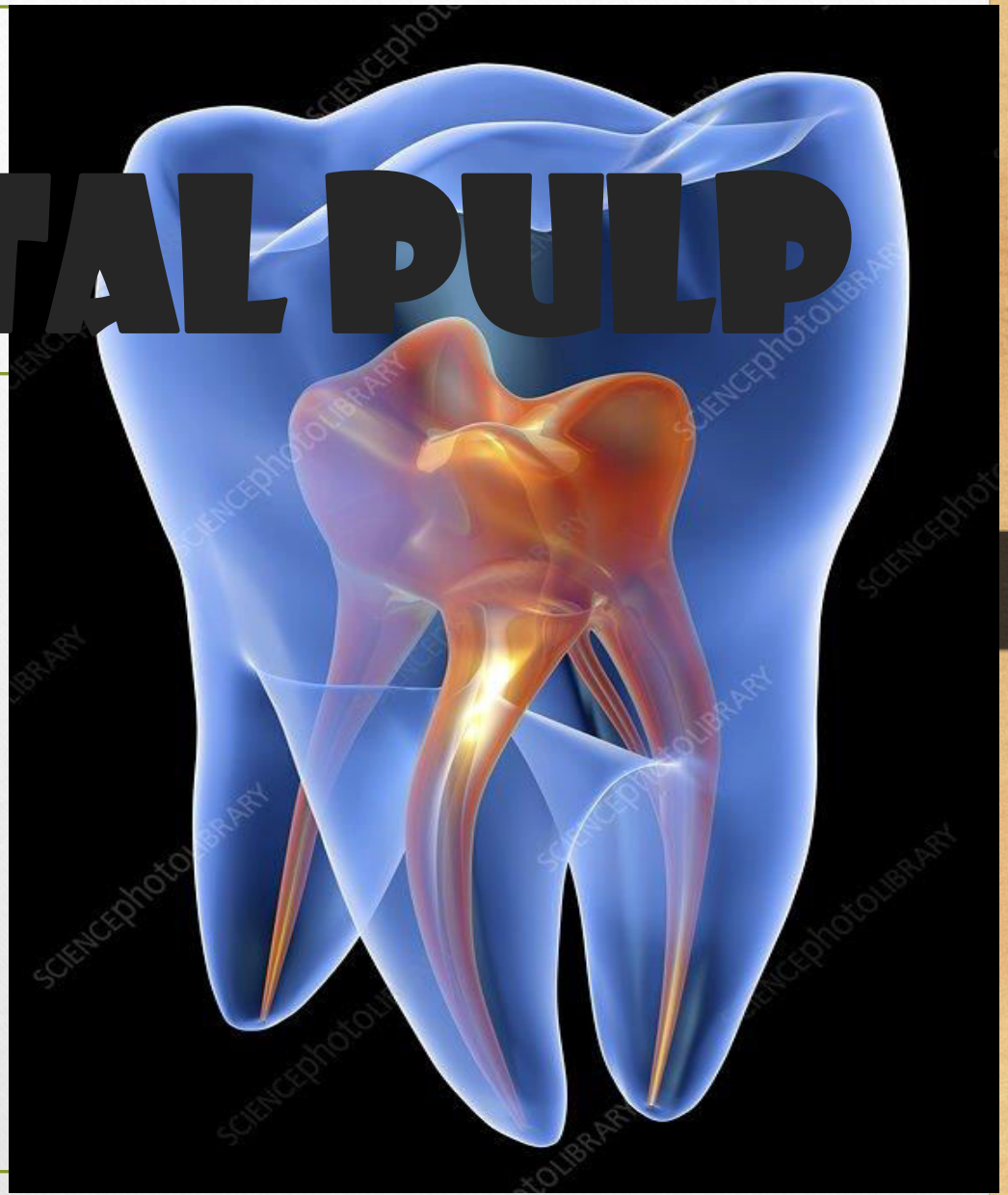
Hard Palate and Soft Palate





# DENTAL PULP

Dr. ABDULSATTAR SALIM  
PhD. Oral histology



# Contents

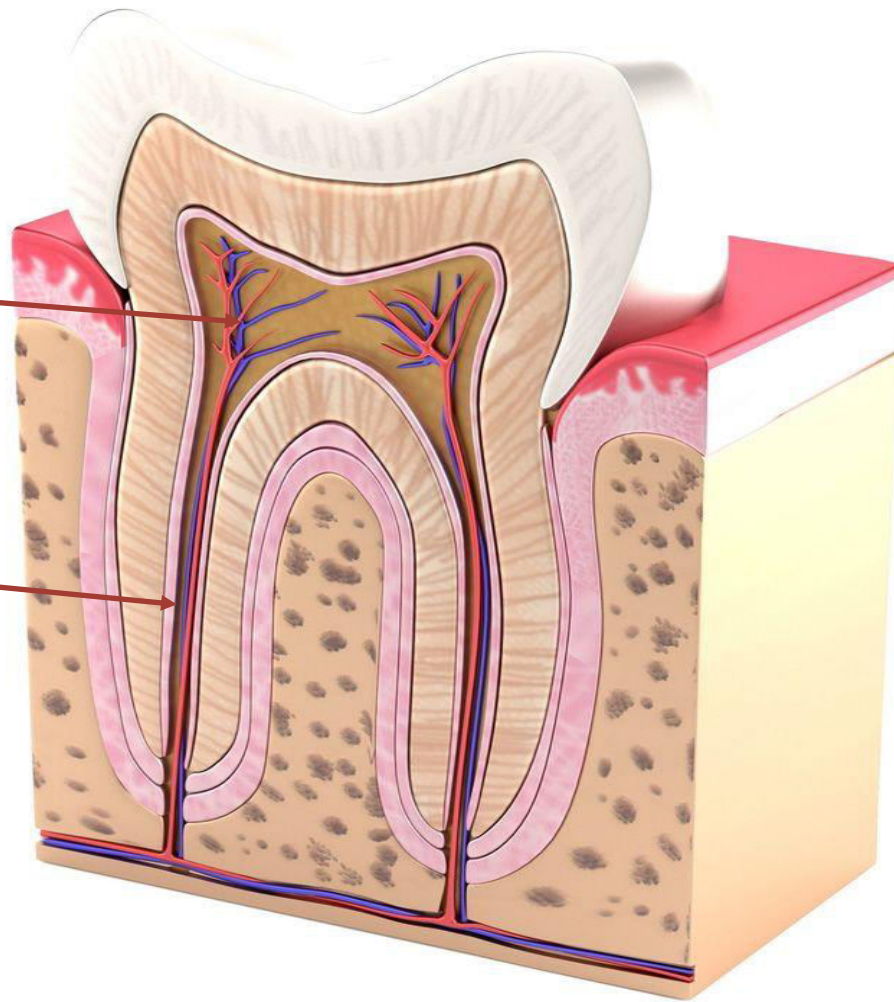
---

- 1 Development of Dental Pulp
2. Zones of Pulp
3. Cells of Pulp Tissue
4. Vessels and Nerves of Pulp
5. Pulp Stones



Coronal pulp

Radicular pulp





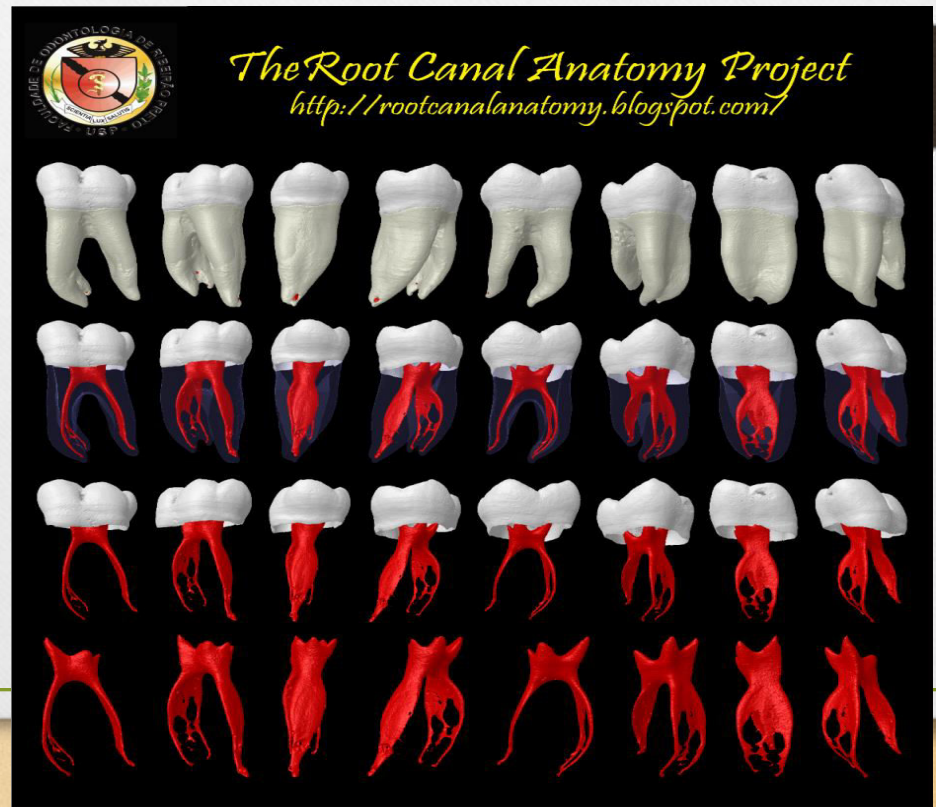# 1:Development of dental pulp

Dental pulp is soft connective tissue that is derived from the ectomesenchymal cells of the dental papilla

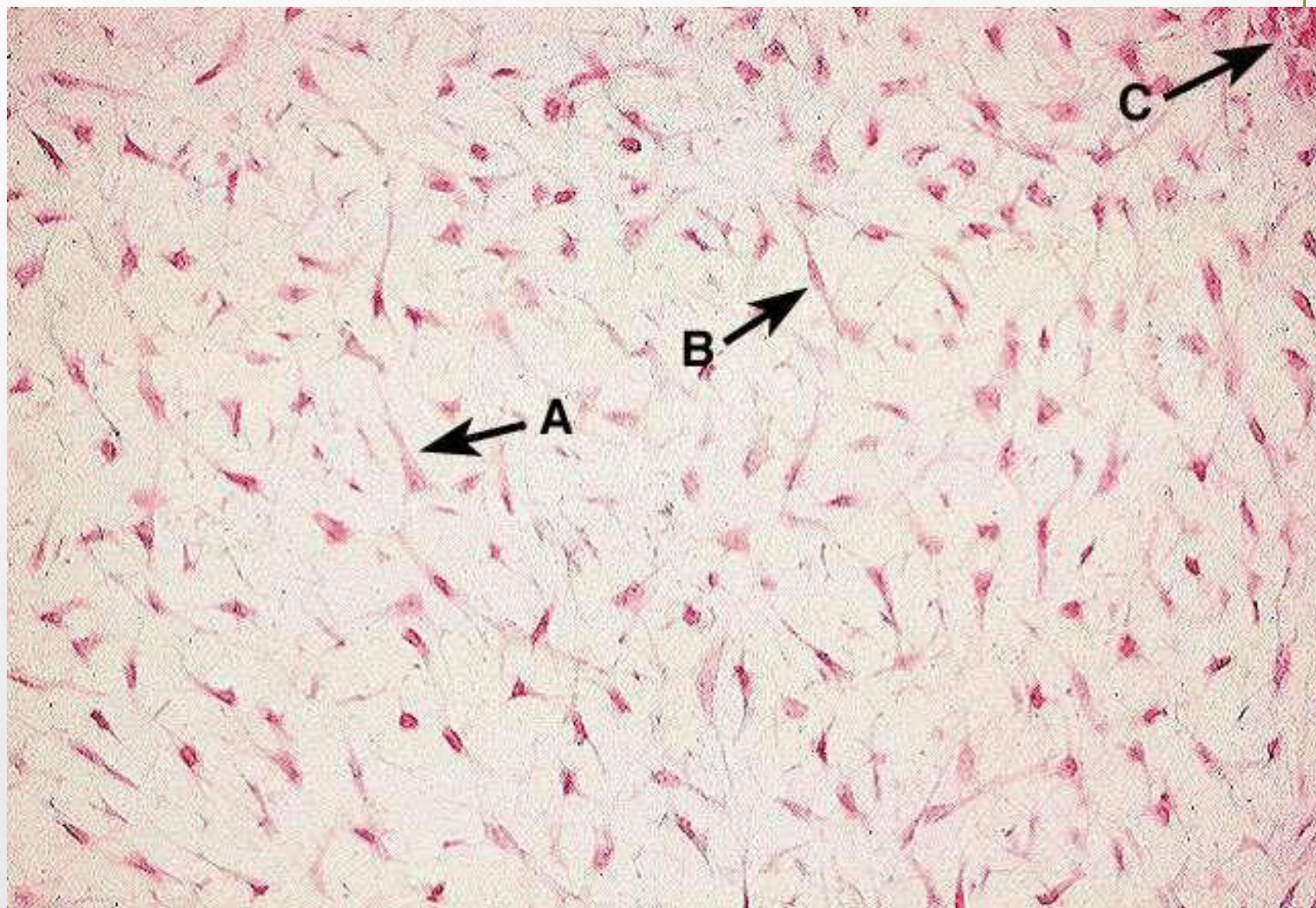
---

Pulp resides in the inner most part of the tooth and supports the dentine

pulp tissue

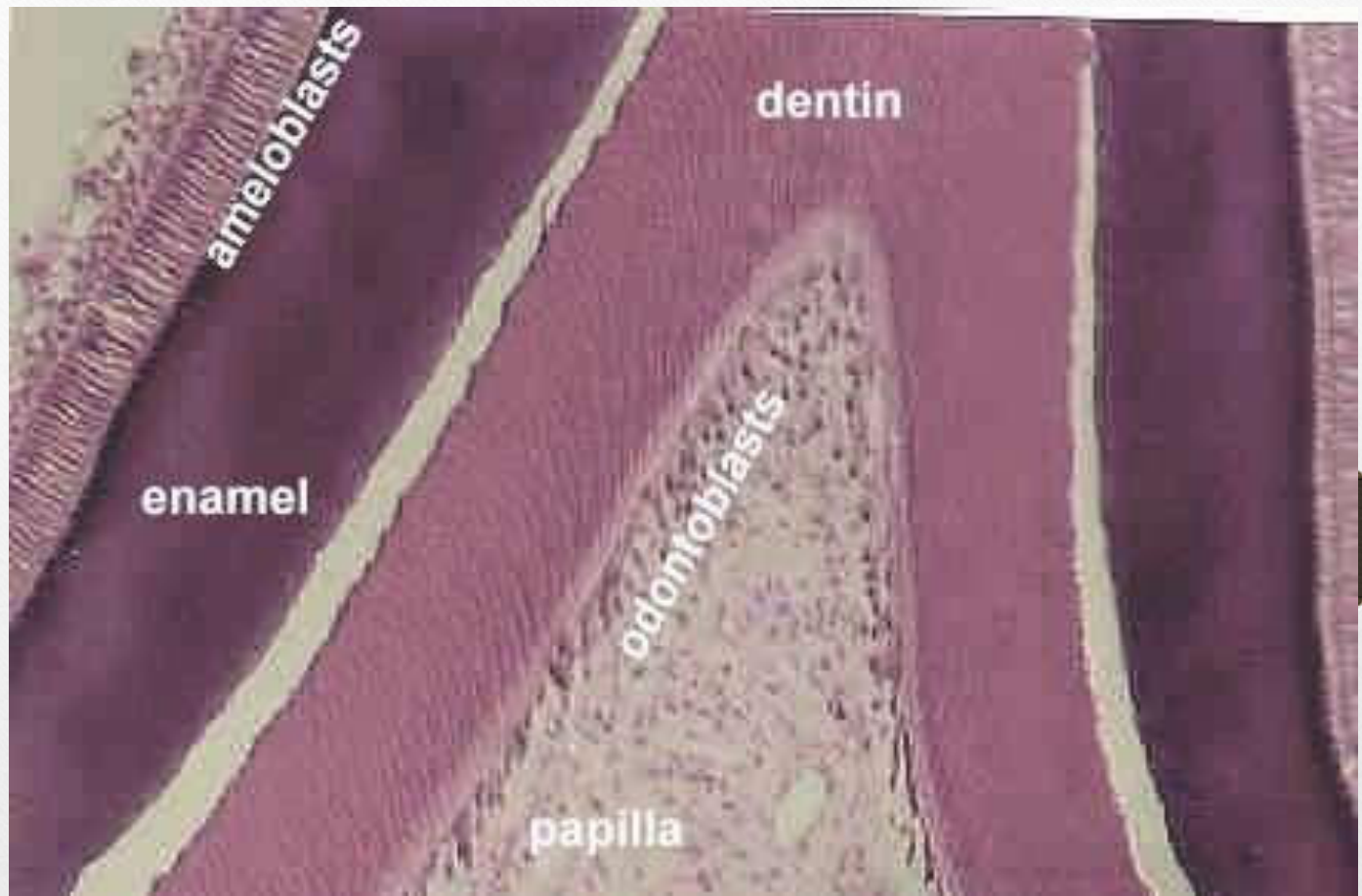






Dental Papilla





Developing pulp



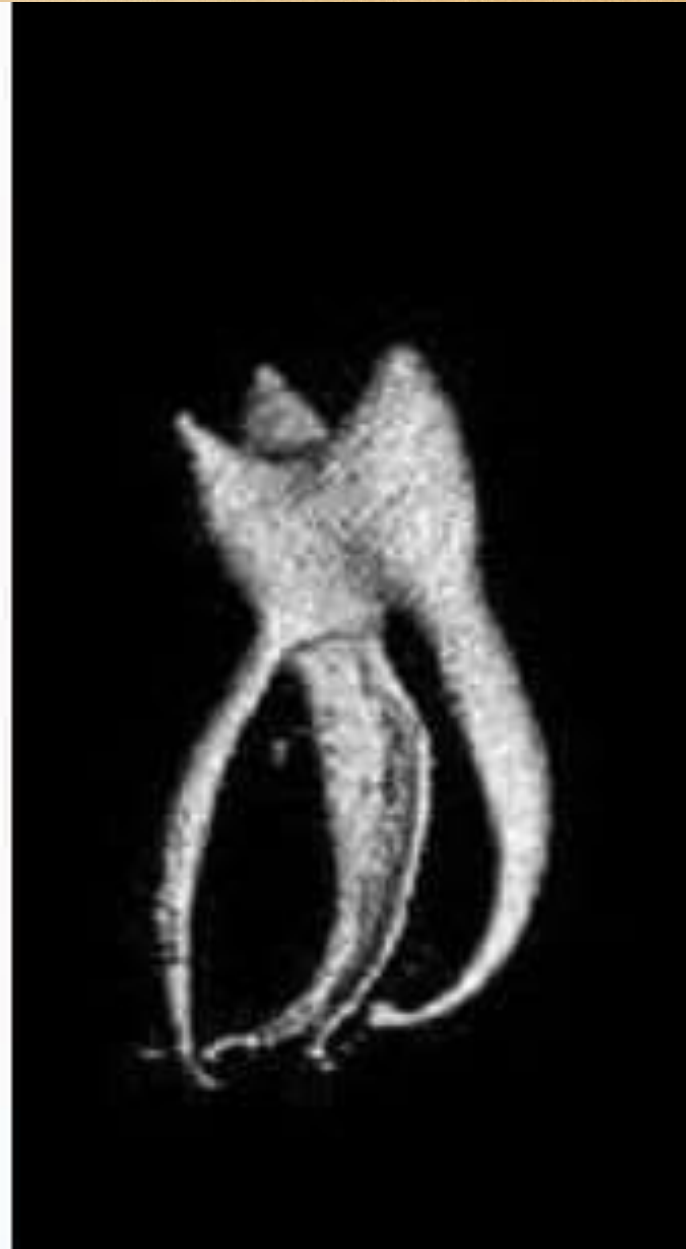During dentinogenesis the dental papilla gets surrounded by the newly formed dentine and it is then termed dental pulp

Pulp provides with odontogenic, nutritive, sensory, and defensive functions

The dental pulp and dentine are closely related to form the dentin-pulp complex

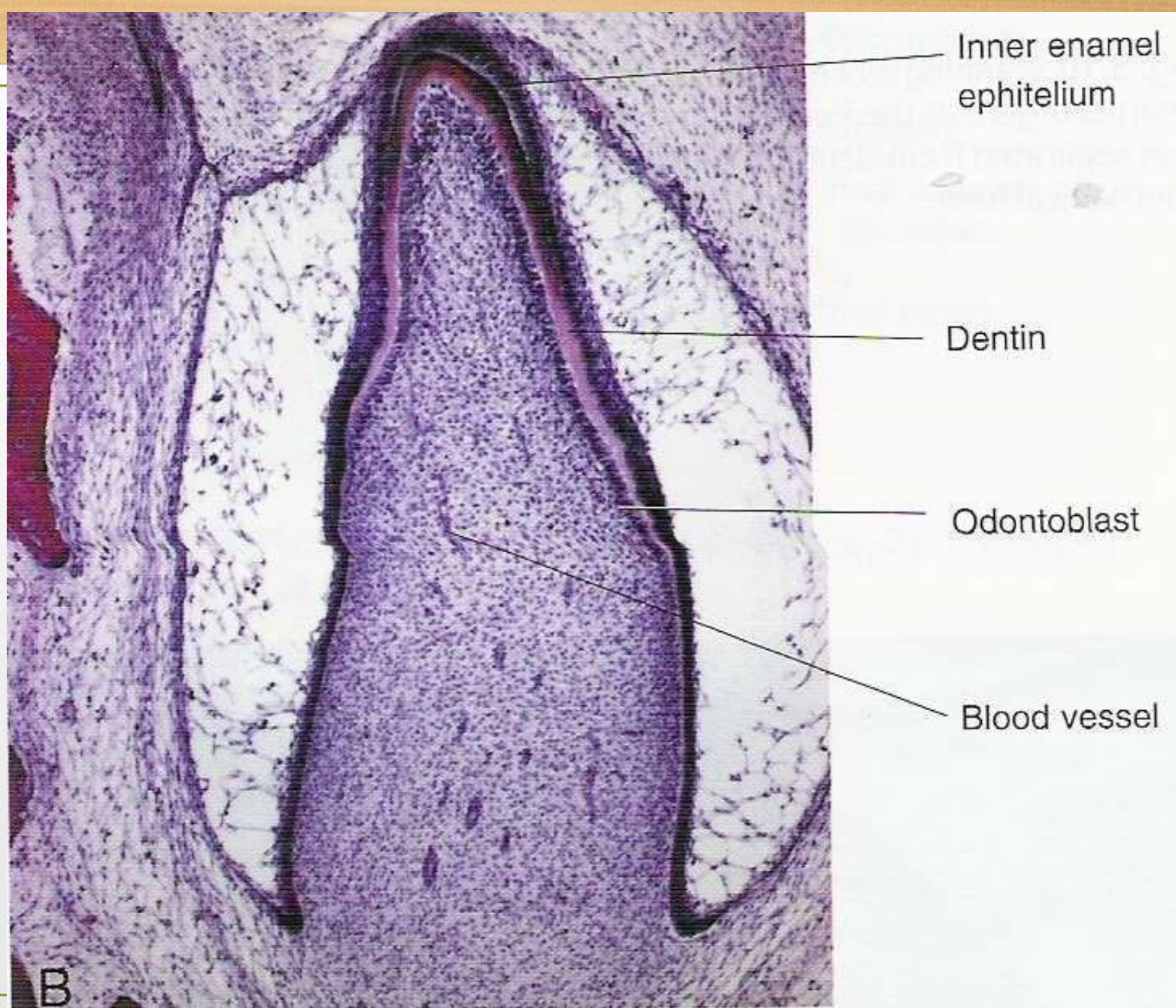


Radiographic appearance of pulp



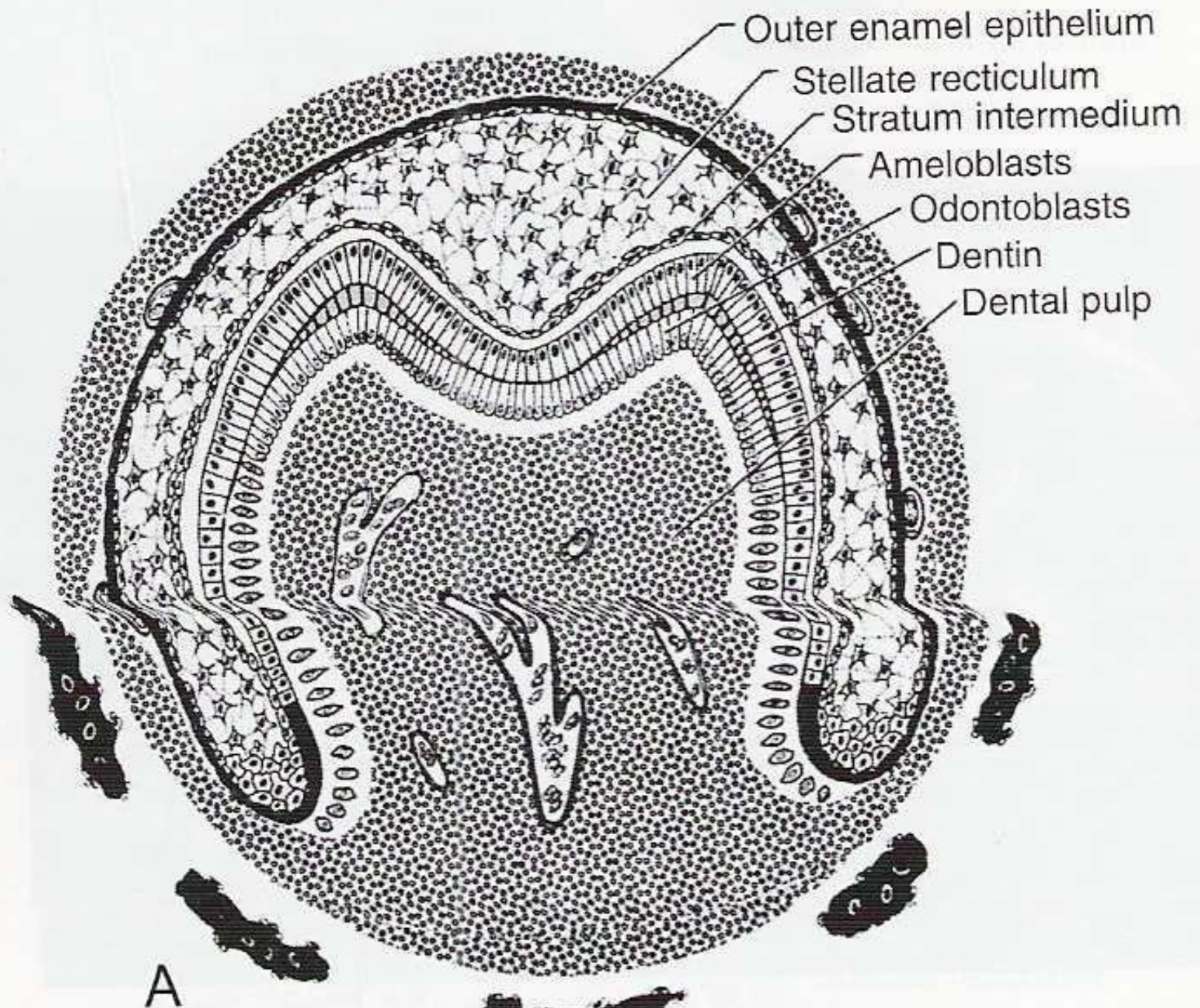
3D MRI of pulp





Developing pulp





Histology of pulp



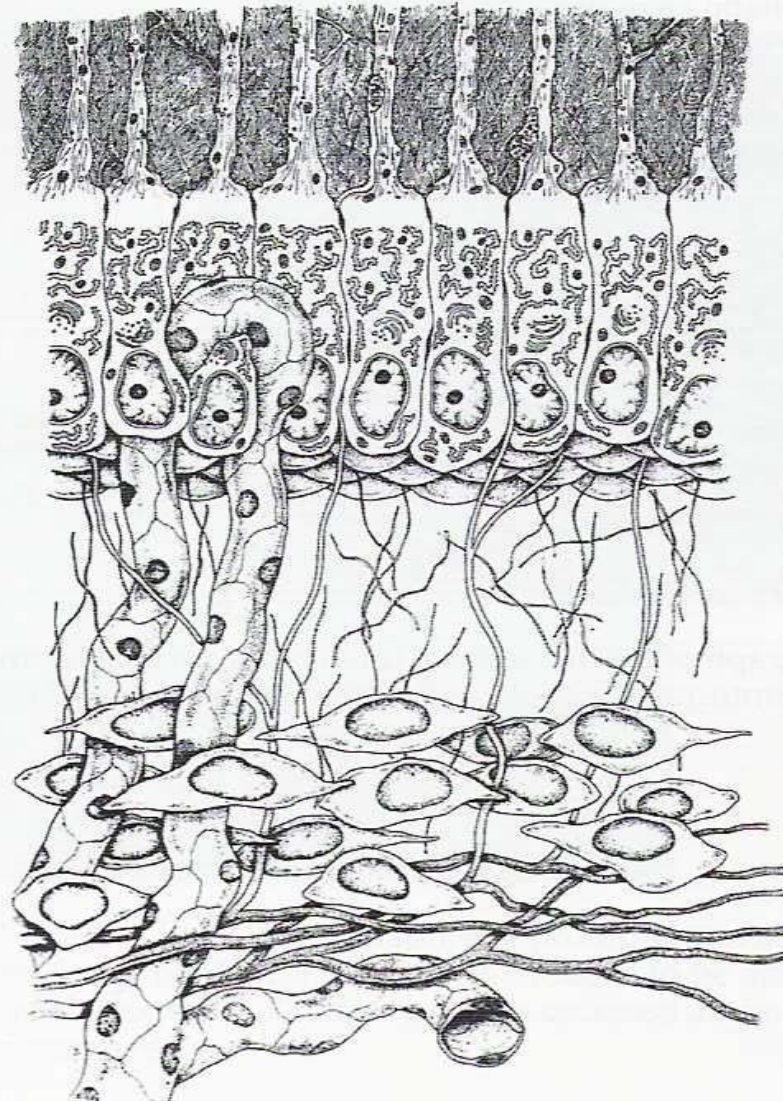
## 2: Zones of pulp tissue

When pulp is examined microscopically four distinct zones can be distinguished.

---

1. Odontoblastic zone
2. Cell free zone of Weil
3. Cell rich zone
4. Pulp core

## Zones of the pulp



Predentin

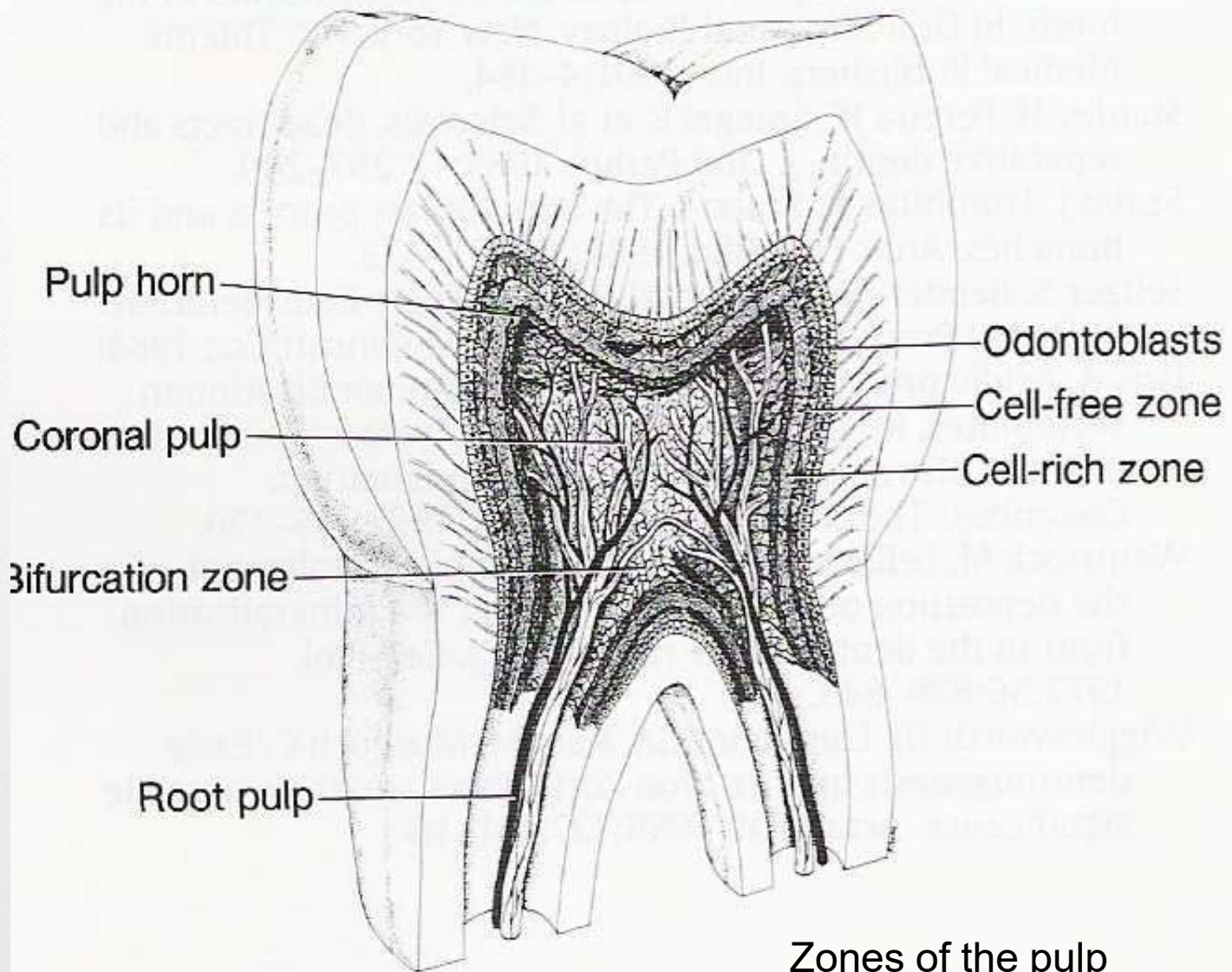
Odontoblasts

Cell-free zone

Cell-rich zone

Parietal neural  
plexus



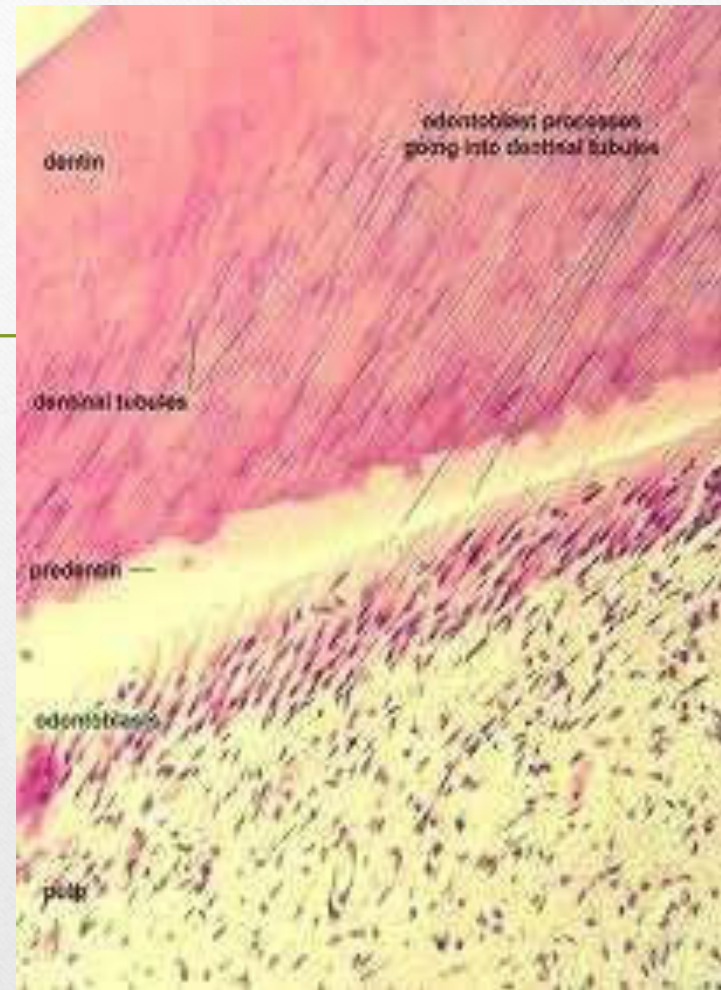

Zones of the pulp

## Odontoblastic zone

**Odontoblasts** are pulp cells that are found in the peripheral layer closely related to the predentine

The cells have a basally located nucleus with supraneuclear rough endoplasmic reticulum and golgi apparatus. Mitochondria and lysosomes are found throughout the cytoplasm

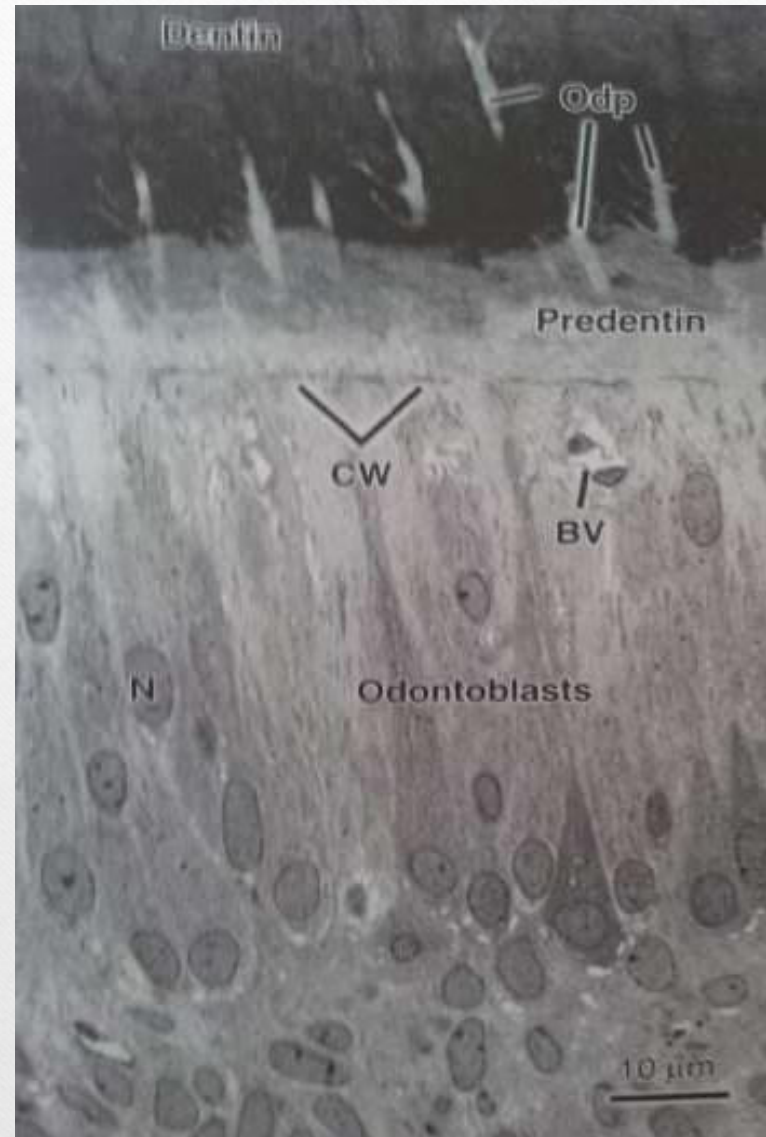


Dentin pulp complex



The major function of odontoblast is to produce and secrete extracellular matrix of the predentine and bio-mineralization of the dentine

They continue to produce predentine through out life but the rate of depositions reduces as age advances



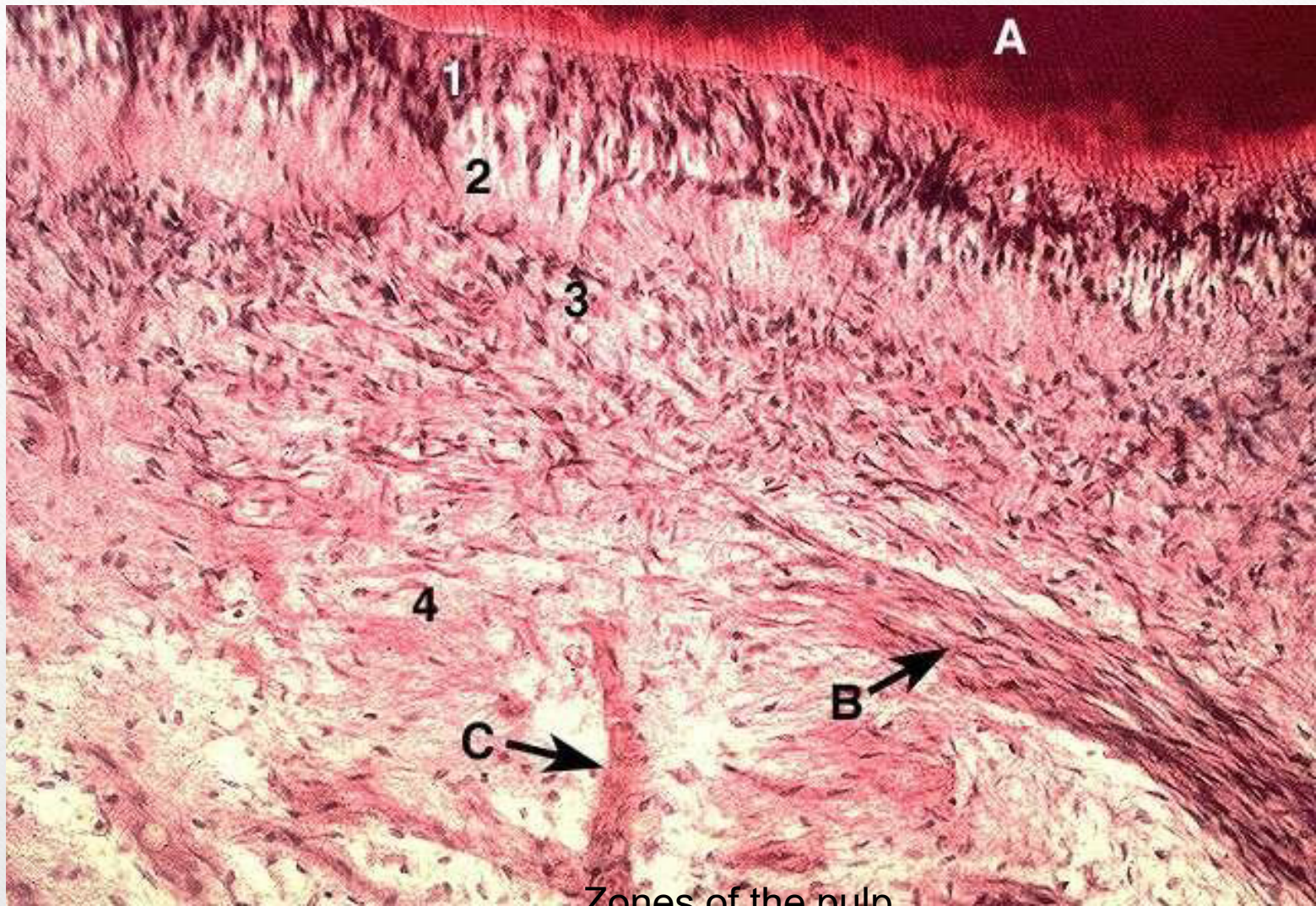


The major protein secreted by odontoblast is Type I Collagen

Odontoblasts have a process extending from the cell body up till the DEJ contained in a dentinal tubule, called the odontoblastic process

There are multiple lateral odontoblastic processes originating from the main process





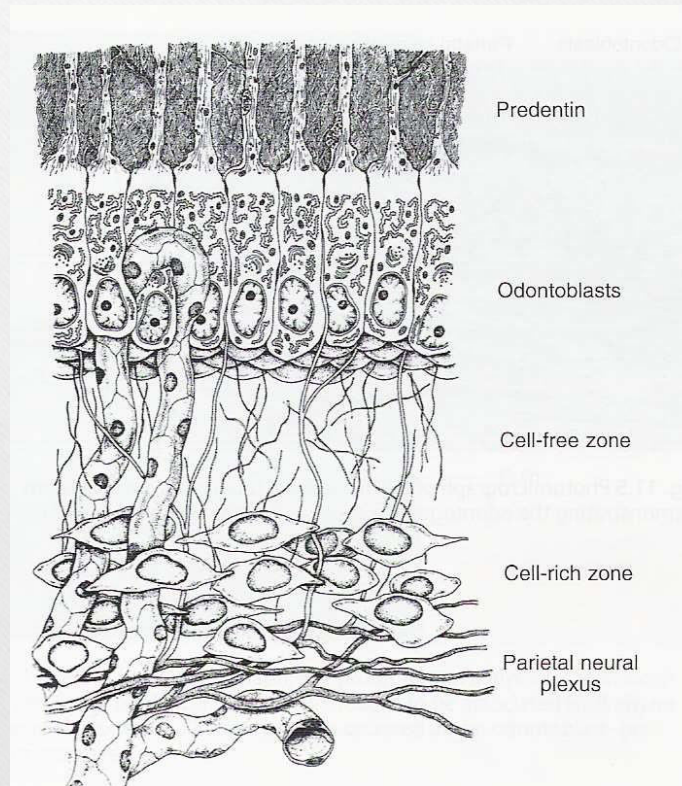
Zones of the pulp



## Cell free zone of Weil

- This zone lies below the odontoblast and is prominent in the coronal pulp
- As the name suggests this area of pulp is nearly devoid of any cells

Zones of the pulp





## Cell rich zone

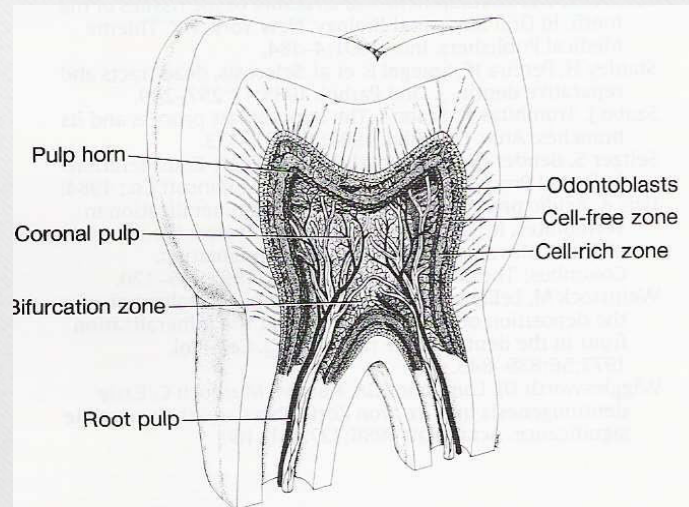
- This zone is beneath the cell free zone and the cell density is high

---

## Pulp core

- This area of pulp is characterized by the presence of major nerves and vessels of the pulp

## Zones of the pulp



### 3: Cells of pulp tissue

The principle cells of pulp are the odontoblasts, fibroblasts and undifferentiated mesenchymal cells

---

#### Odontoblasts

The major function of odontoblast is to produce and secrete extracellular matrix of the predentine and bio-mineralization of the dentine

They continue to produce predentine throughout life but the rate of depositions reduces as age advances



The major protein secreted by odontoblast is Type I Collagen

Odontoblasts have a process extending from the cell body up till the DEJ contained in a dentinal tubule, called the odontoblastic process

There are multiple lateral odontoblastic processes originating from the main process



## Fibroblasts

Fibroblasts are the most numerous cells found in the pulp

They are stellate shaped cells with long cytoplasmic extensions that contact adjacent fibroblasts or odontoblasts

Fibroblasts synthesise and secrete collagen and other extracellular components of pulp. They also play an important role in wound healing mechanism in pulp

## Undifferentiated mesenchymal cells

These cells represent the pool from which the cells of pulp arise

Depending on the stimulus they give rise to odontoblasts and fibroblasts

## Other cells

Other cells of pulp include macrophages, lymphocytes, perivascular cells, Schwann cells and endothelial cells



# 4 Vessels and nerves

## Vessels of pulp

Blood vessels enter and exit the pulp through the apical foramen

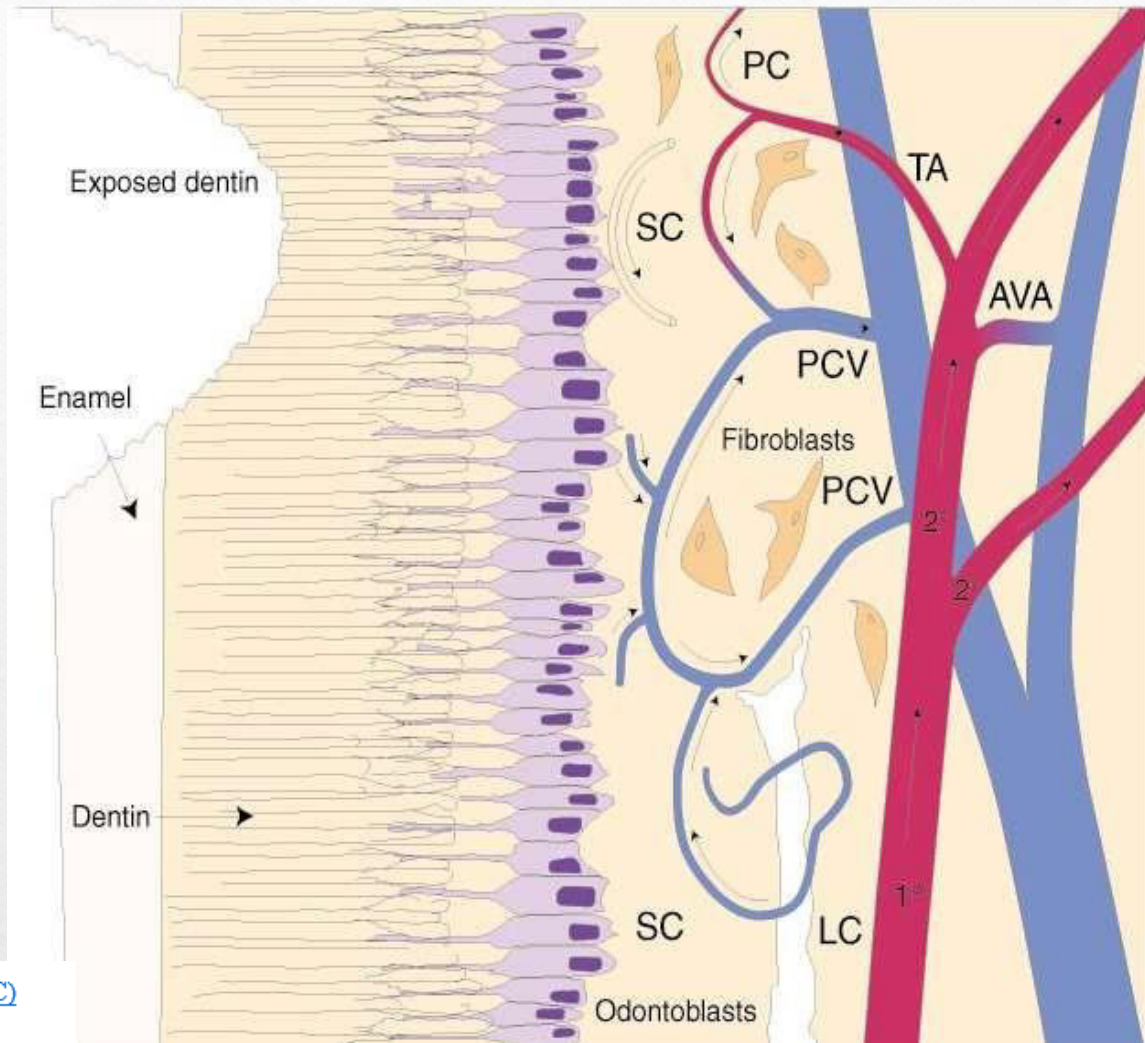
---

The vessels occupy a central position in the pulp and give out lateral branches that extend towards the subodontoblastic plexus

The provide nutrients and oxygen needed for cellular metabolism and remove the by-products of cellular metabolism

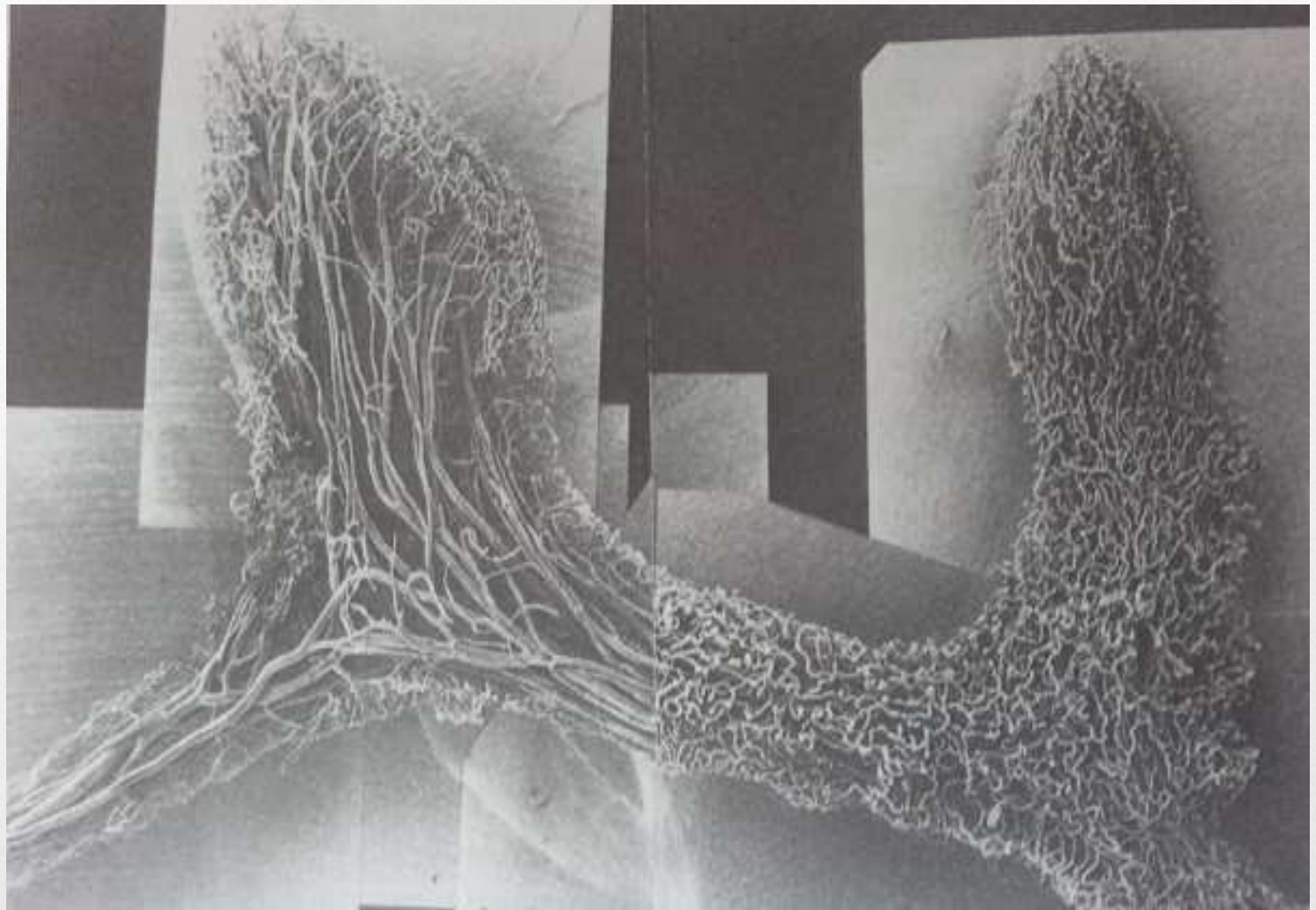
Lymphatic vessels are also located in the pulp





- Subodontoblastic capillaries ([SC](#))
- Terminal arterioles ([TA](#))
- Precapillary sphincters ([PC](#))
- Postcapillary venules ([PCV](#))
- Arteriovenous anastomosis ([AVA](#))
- Lymphatic channels ([LC](#))

Pulp vasculature





## Nerves

They enter the pulp through the apical foramen

Most of the never fibers end in subodontoblastic plexus known as the plexus of Raschkow

Some axons pass between the odontoblastic process and enter the dentinal tubule



## 5:Pulp Stones

Pulp stones are also called as denticles

---

They are calcified masses that have inorganic components comparable to dentin.

They are common in the orifice of the pulp chamber or in the root canal

## Types of Pulp stones

True pulp stones

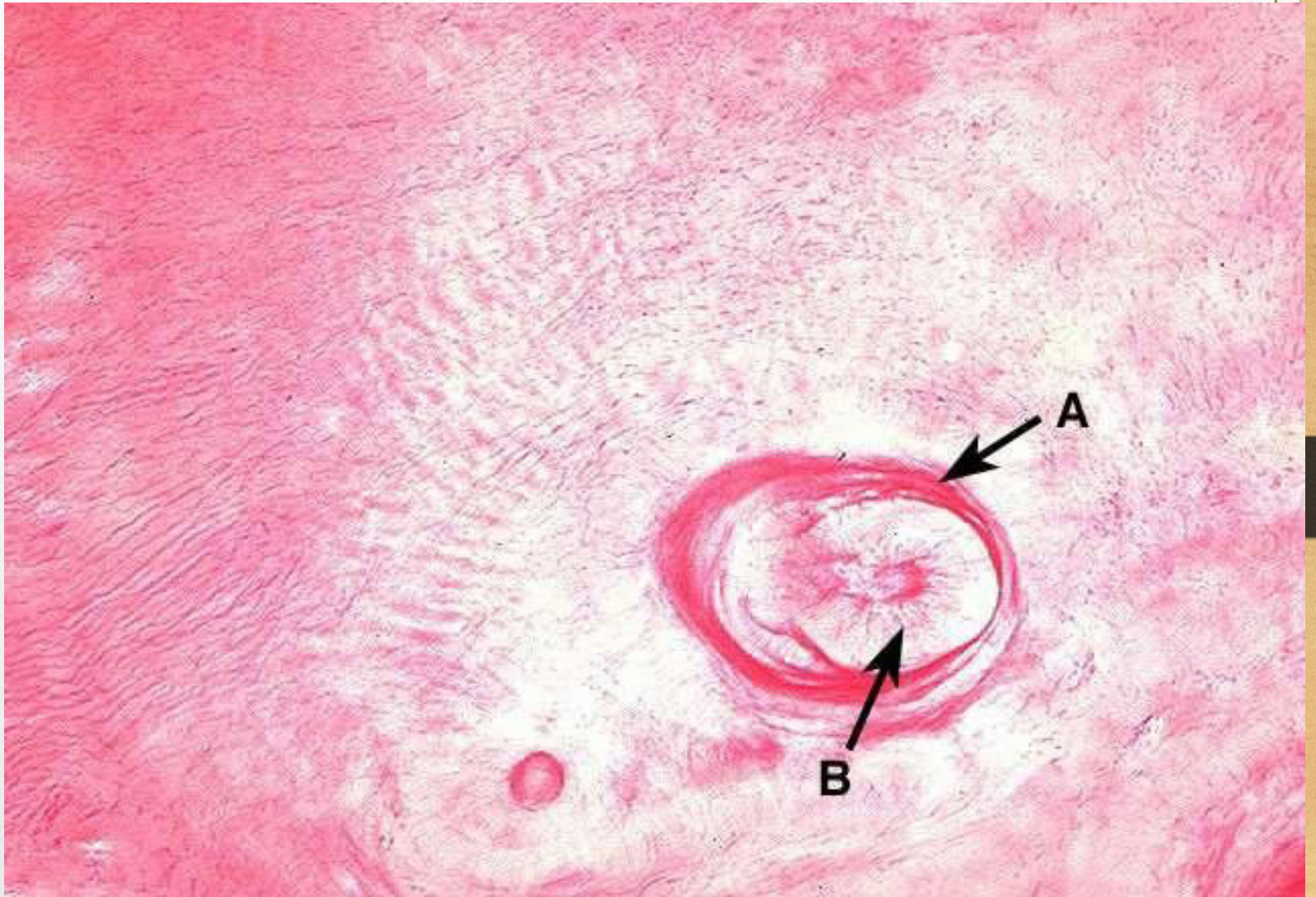
These pulp stone contain tubules and are surrounded by cells

False pulp stones

They do not have tubules like the dentin

They are not surrounded by cells





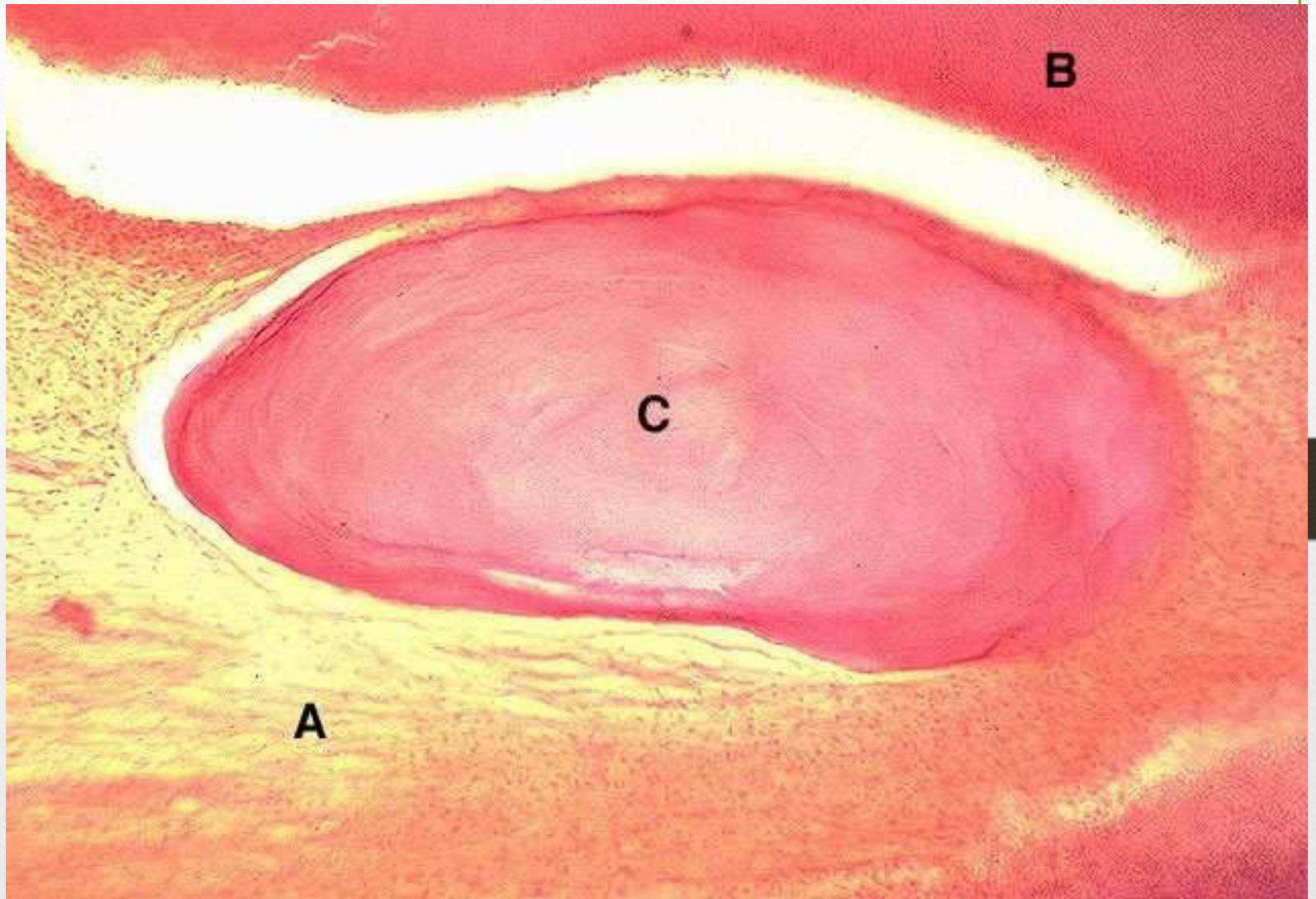
True pulp stone



## Types of Pulp stones

---

- Attached stone
- If the stone is attached to the dentinal wall it is called attached stone
- Free stone
- Such a stone is not attached to the dentinal wall, rather it is completely surrounded by soft tissue



Attached pulp stone



# DEVELOPMENT AND GROWTH Of TEETH

**Dr. ABDULSATTAR  
SALIM**





☐ **The development of the tooth involves many complex biological processes.**

☐ **The fundamental developmental processes is similar for all teeth.**



# STAGES OF TOOTH DEVELOPMENT AND GROWTH

STAGES OF TOOTH DEVELOPMENT MAY BE DESCRIBED ACCORDING TO :

1 Changes in the morphology of the developing tooth **(MORPHOLOGICAL STAGES)** .

2 Its physiological changes **(HISTOPHYSIOLOGICAL STAGES)**.

**Note:** both the *morphological* and the *histophysiological* changes are shearing in the different tooth development stages.

Stages of teeth development

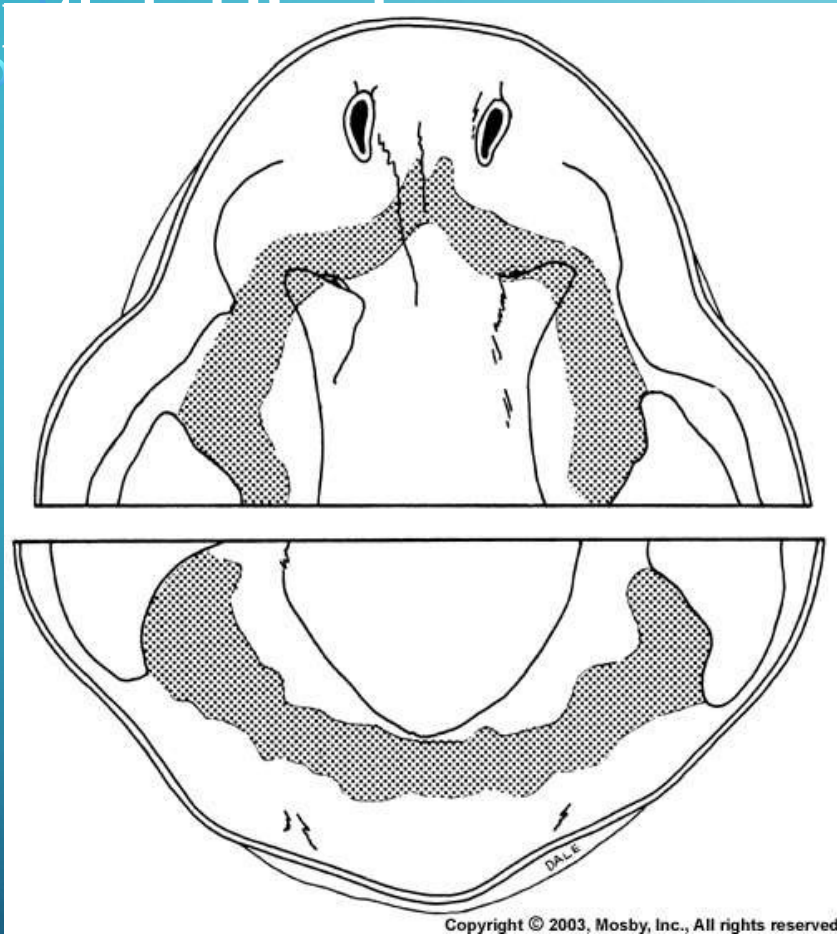
## MORPHOLOGICAL STAGES

1. Initiation stage
2. Bud stage
3. Cap stage
4. Bell stage ( early & advanced )
5. Root Stage



# 1: INITIATION OF TOOTH DEVELOPMENT

The initiation of tooth development begins at 37 days of development with formation of a continuous horseshoe-band of thickened epithelium in the location of upper and lower jaws – **Primary Ectodermal Ridge**



Each band of epithelium will give rise to 2 sub divisions:

1. Dental lamina and
2. Vestibular lamina

**PRIMARY  
EPITHELIAL  
BAND**



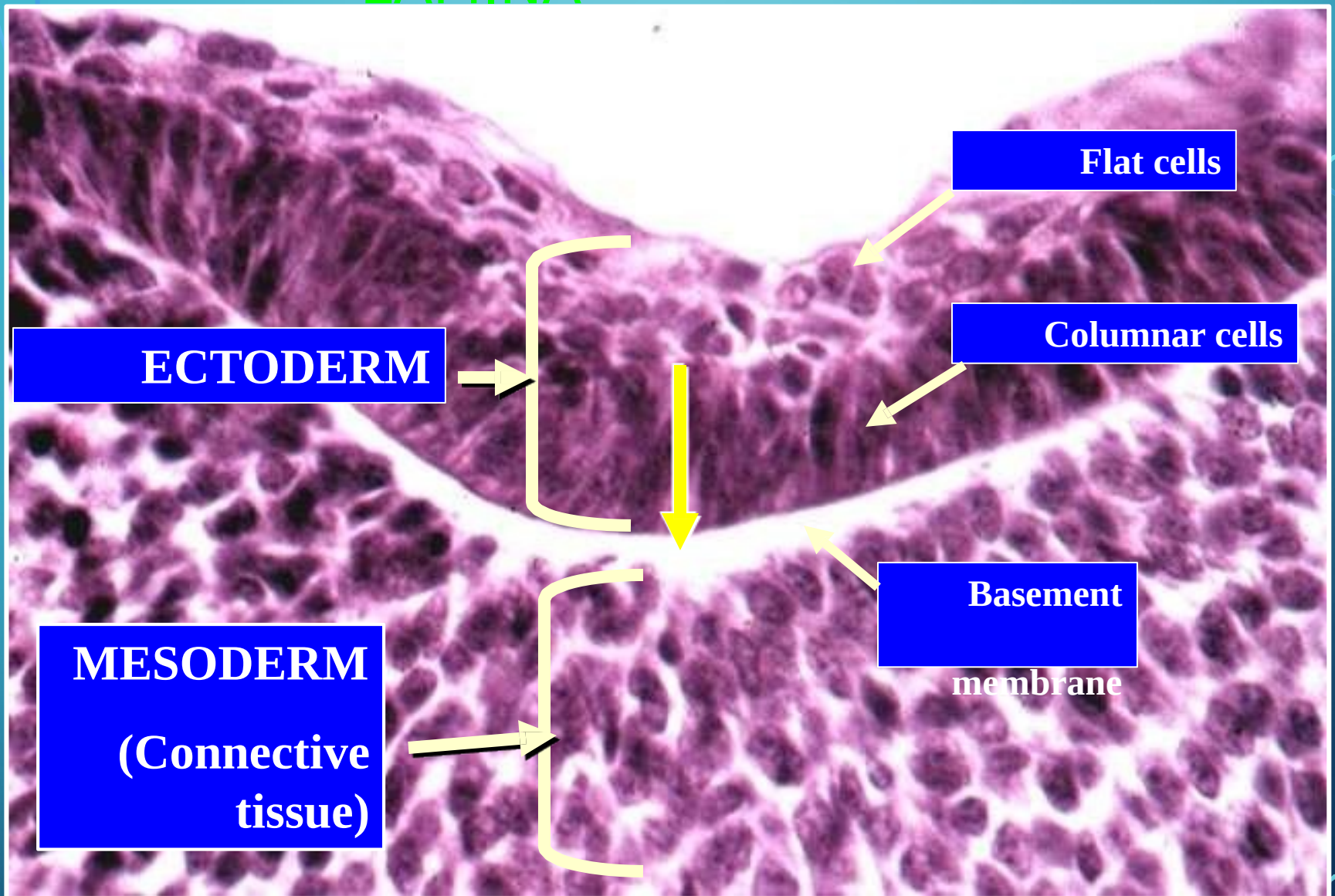
**Ectomesenchyme**

## VESTIBULAR LAMINA:-

It is a wedge of epithelial cells facial to dental lamina.  
It proliferates into ectomesenchyme. Then degenerates at the center to form cleft which becomes the oral vestibules.

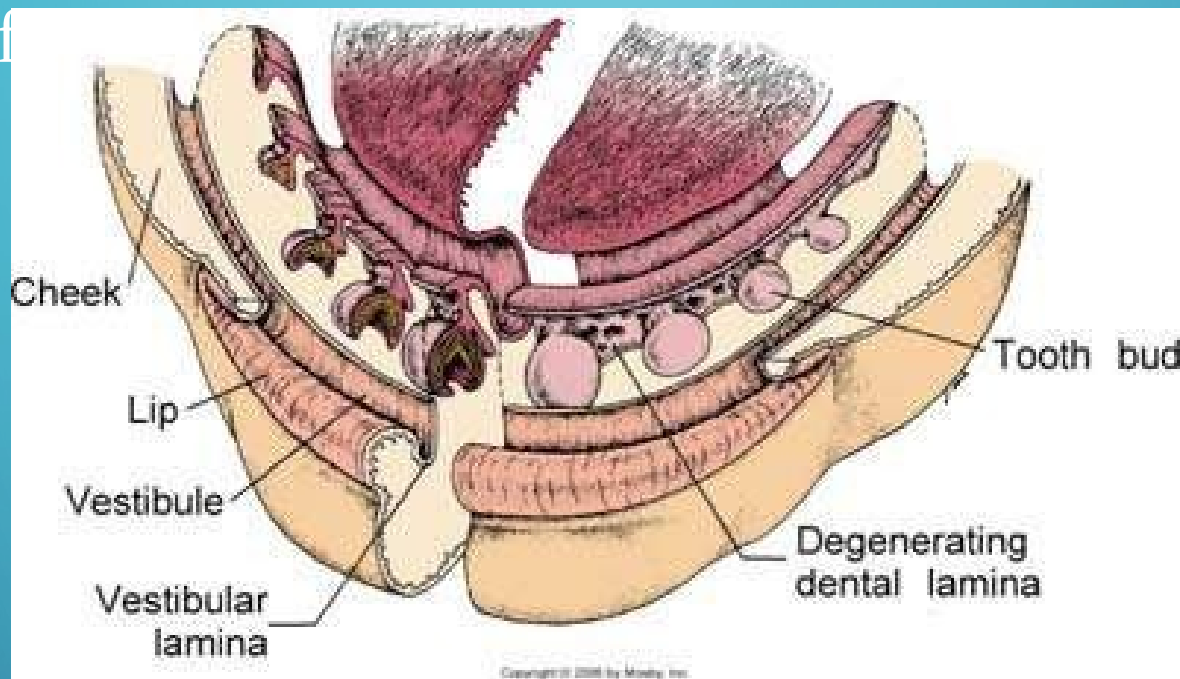


# THE DENTAL LAMINA



□ Dental lamina appears as a thickening of the oral epithelium adjacent to condensation of ectomesenchyme

- 20 areas of enlargement or knobs appear, which will form tooth buds



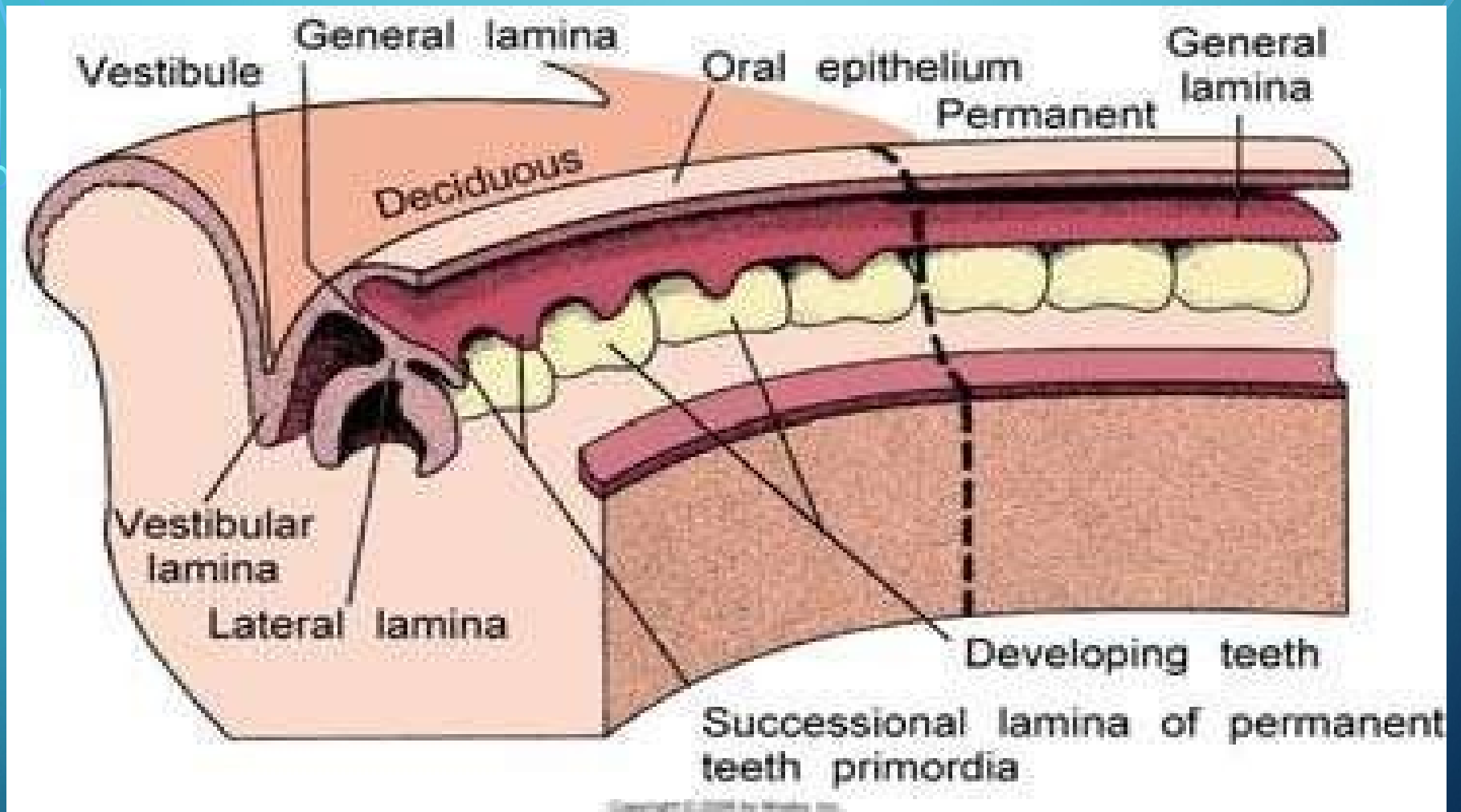
- Not all will appear at the same time . The first to develop are those of the anterior mandible region

• At this early stage the tooth buds have already determined their crown morphology .

❑ **Successional lamina** : lamina from which permanent teeth develop which replace the primary teeth except for the permanent molars.



## □ Dental lamina formation and development of tooth buds



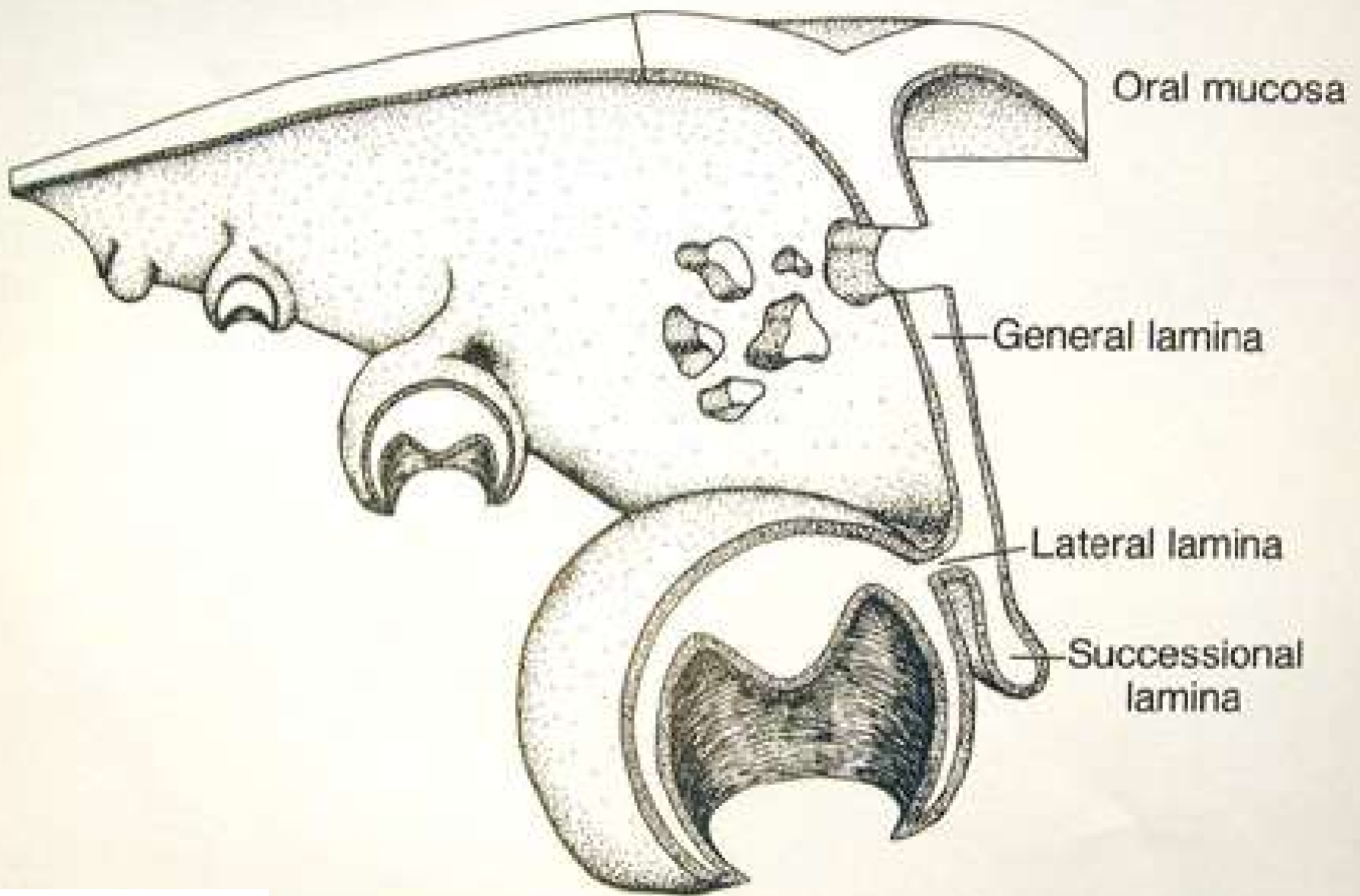
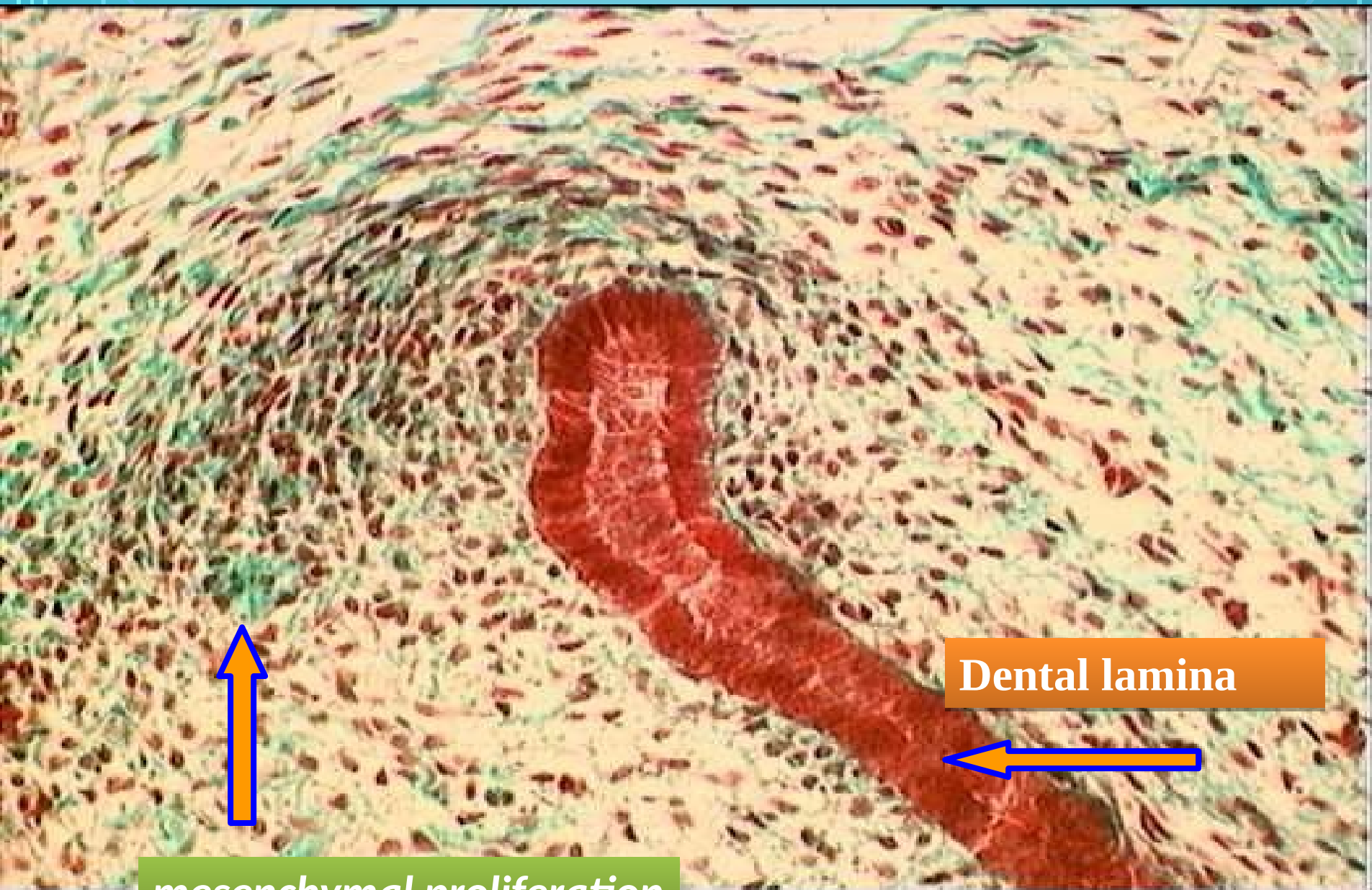

Diagram depicting the general and lateral lamina as well as the beginning of the dissolution of the dental lamina.



Dental lamina

*mesenchymal proliferation*



# FUNCTION OF THE DENTAL LAMINA

1. **Initiation of deciduous dentition.**
2. **Initiation of successors of deciduous dentition .** This is preceded by the growth of the terminal end of the dental lamina lingual to the deciduous enamel organ . ( 5 MIU. For central incisors, 10 M. of age for second premolars ) .
3. **Initiation of permanent molars .**

This is preceded by the extension of dental lamina distal to the enamel organ of the second deciduous molar to form the permanent molar tooth buds  
( first molar 4MIU. , second molar 1 year , third molar 4-5 years )


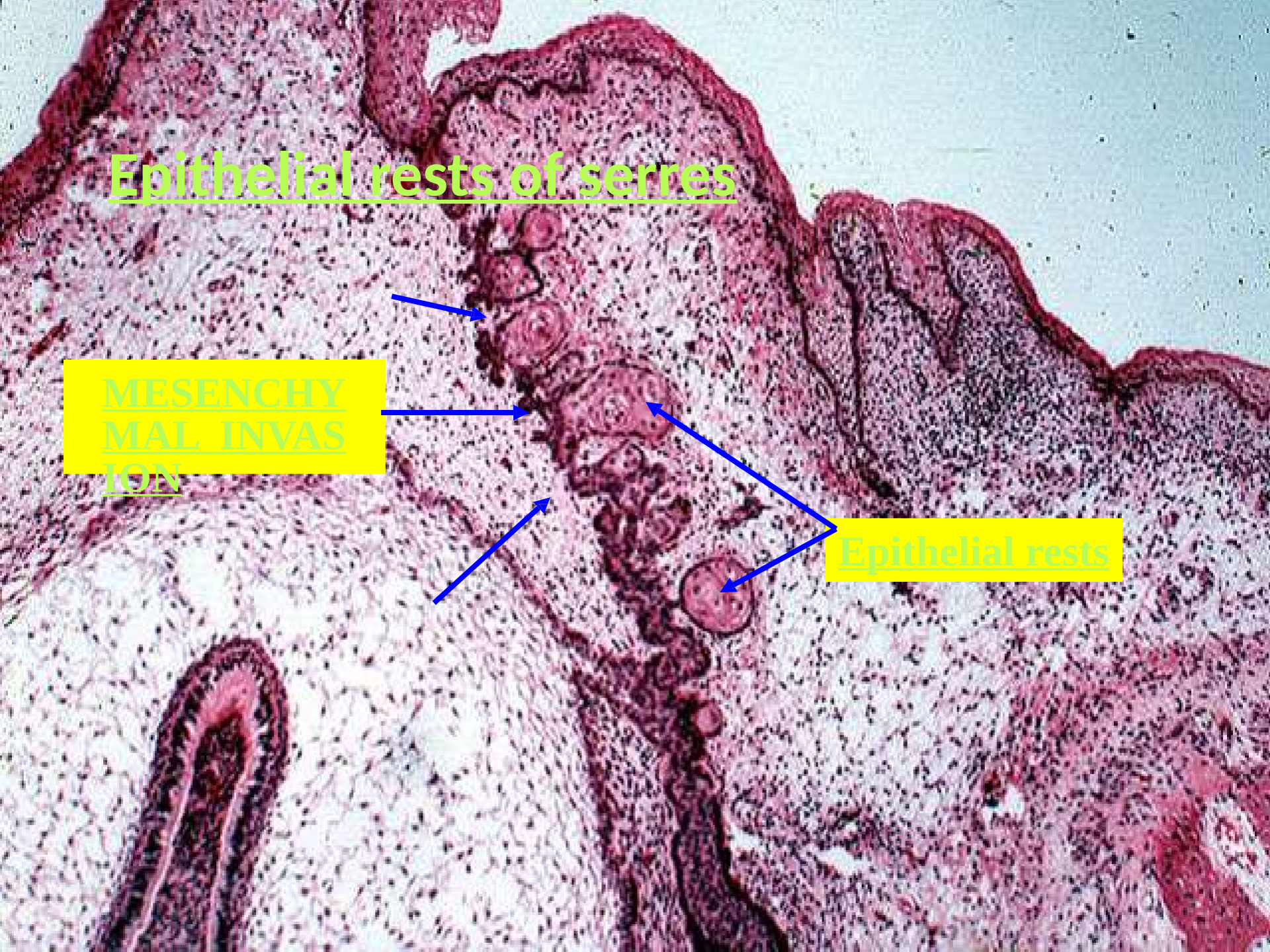
*epithelial rests of Serres*

4. It is thus evident that the activity of the dental lamina extends over a period of about five years and disintegrates completely or remains as *epithelial rests of Serres*.

Epithelial rests of serres

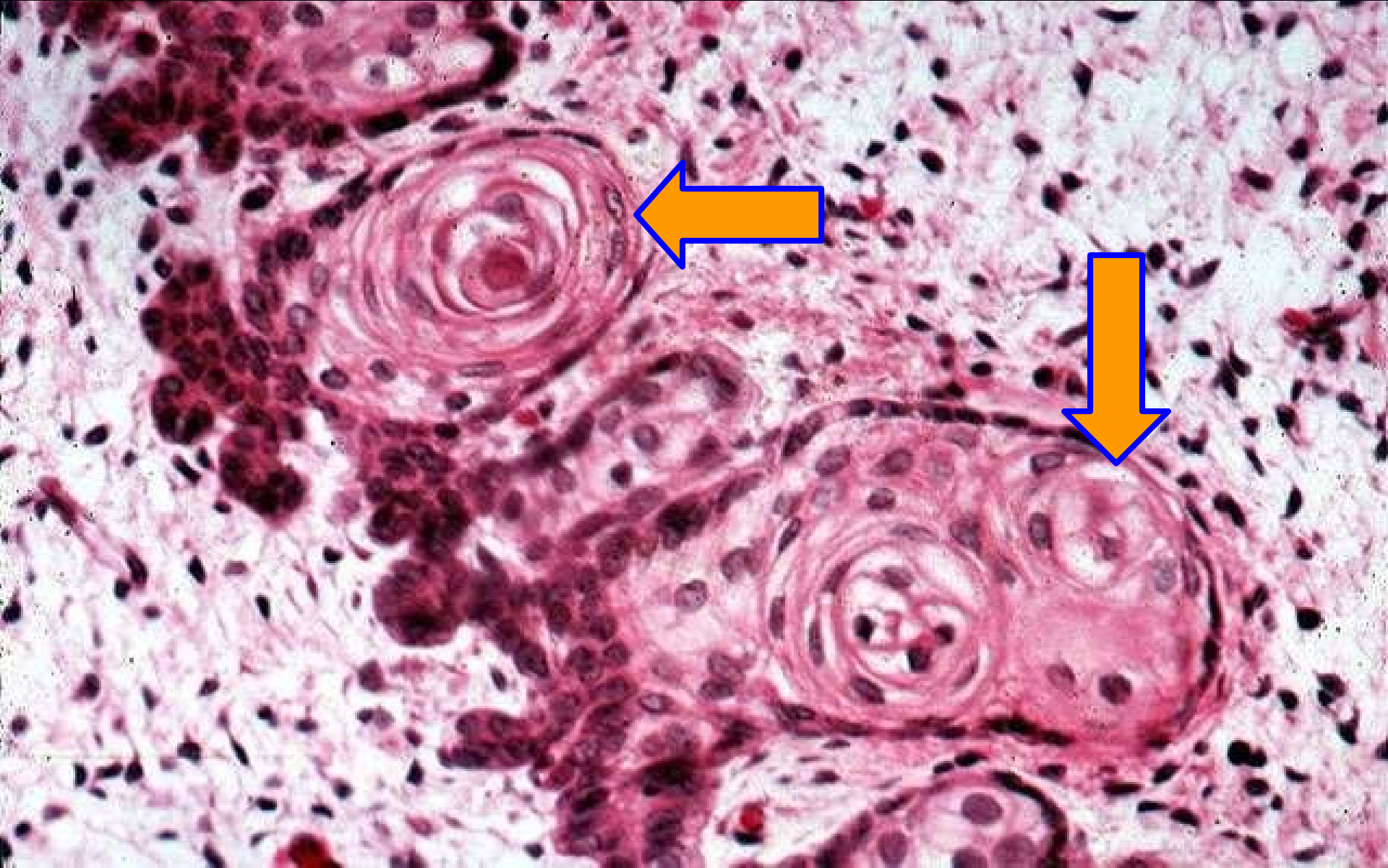
MESENCHY  
MAL INVAS  
ION

Epithelial rests





# EPITHELIAL RESTS OF SERRES

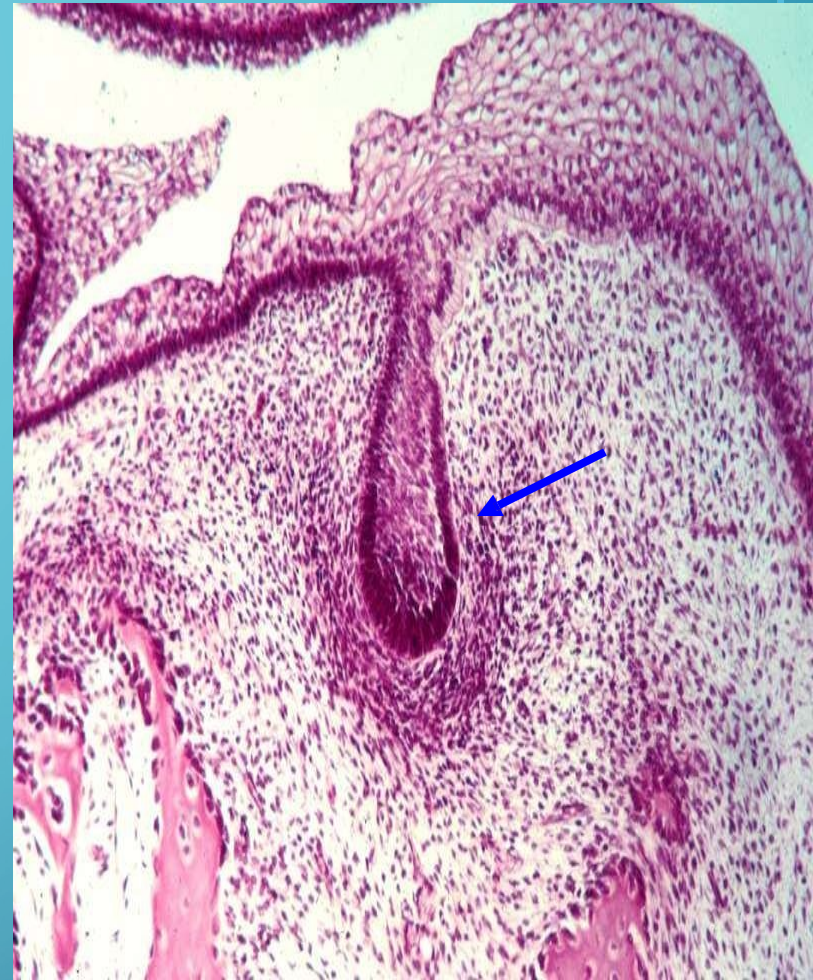



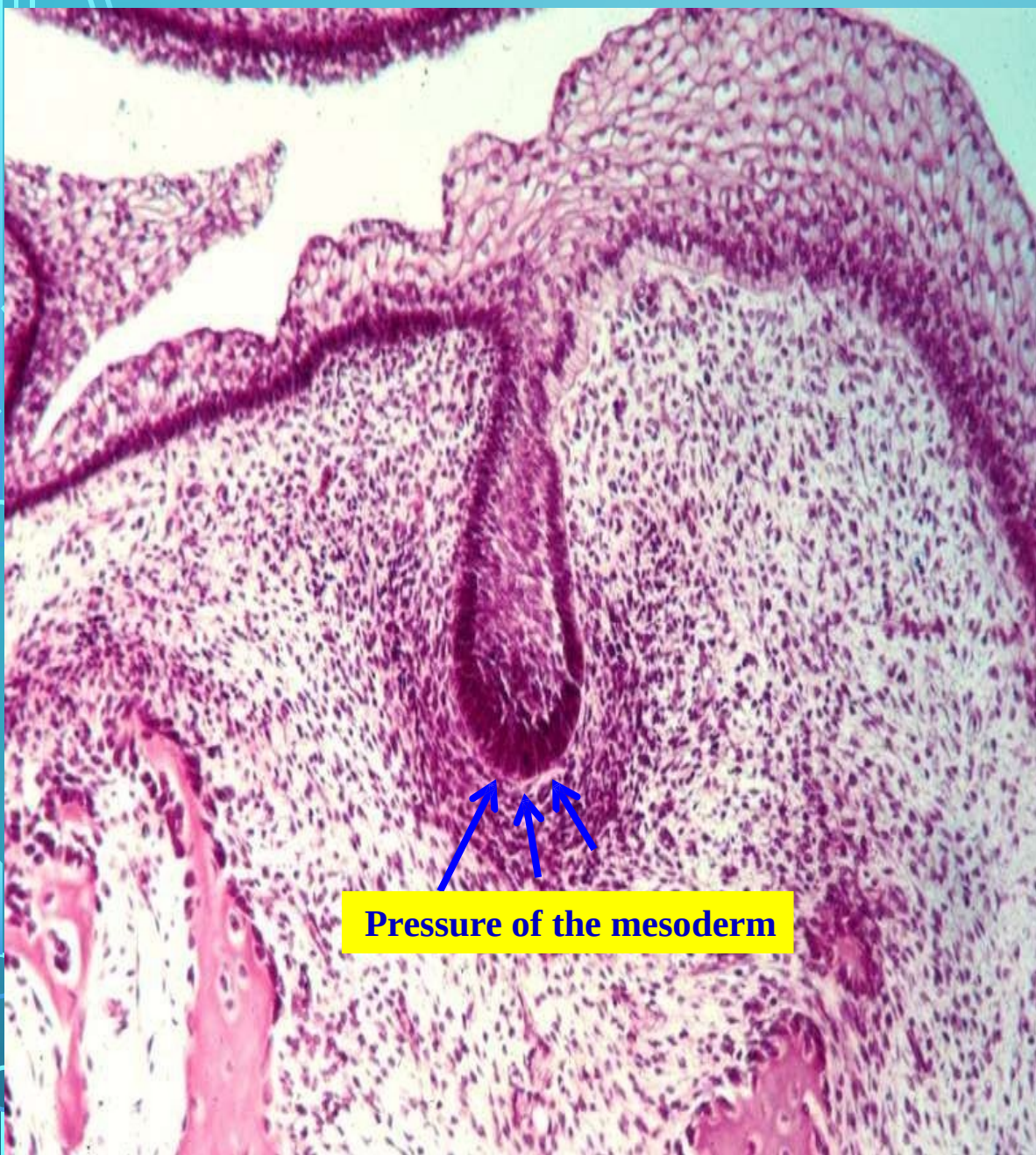
## 2: TOOTH BUD

### STAGE :

- At certain regions along the dental lamina , 10 rounded or ovoid localized growth of epithelium ( *Tooth bud* ) in each arch correspond to the primordia of the enamel organs of the deciduous teeth . These buds were surrounded by proliferating mesenchymal cells, which are packed closely beneath and around the epithelial buds



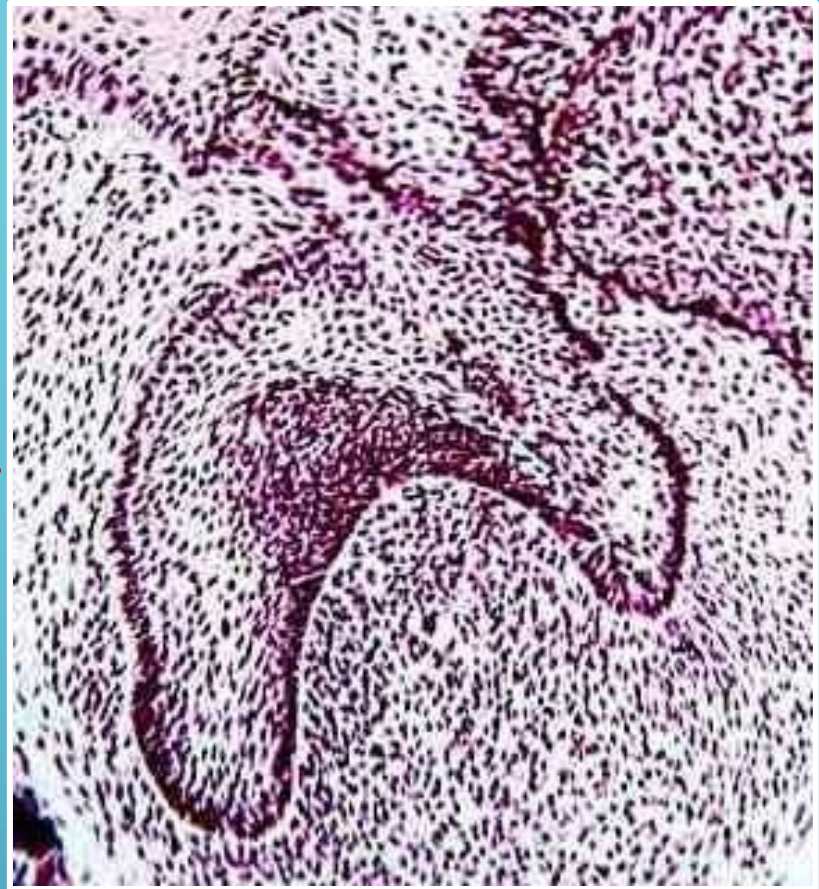
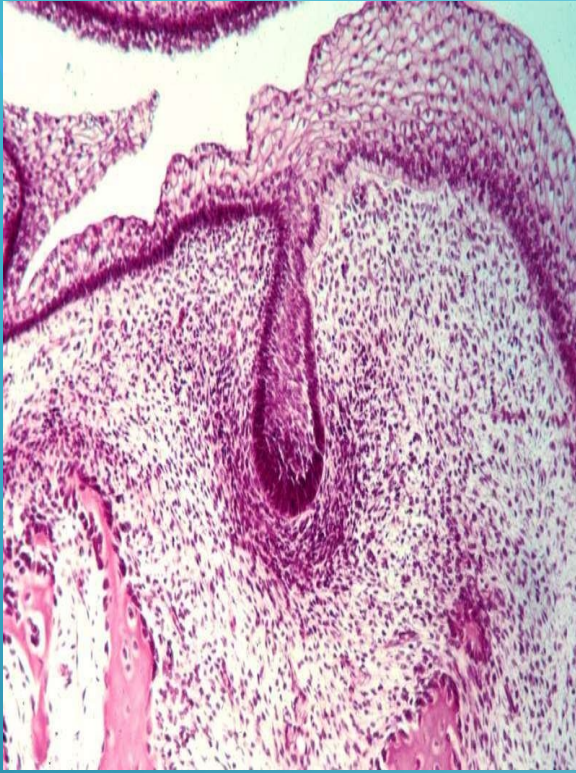



The mesoderm exerts a pressure at the base of tooth bud . The pressure of the mesoderm leads to invagination of the undersurface of the tooth bud , while the lower margin of the concavity proliferates downward to surround the actively growing mesoderm .



- As a result of this topographic alteration , the round shaped tooth bud is transformed to a cap shaped structure .



Later on , the cap shape structure can be distinguished into different cell layers , as follows :



### 3. A: EARLY CAP

#### STAGE:-

The inner cell become low columnar called inner enamel epithelium or inner dental epithelium.

**The outer cells become flat and called outer dental epithelium or outer enamel epithelium.**

The ectomesenchymal tissue becomes condensed in the concave surface and called dental papilla (much cells, low fibers).

Some ectomesenchymal fibers surround the cap called dental follicle (sac) (low cells, much fibers).

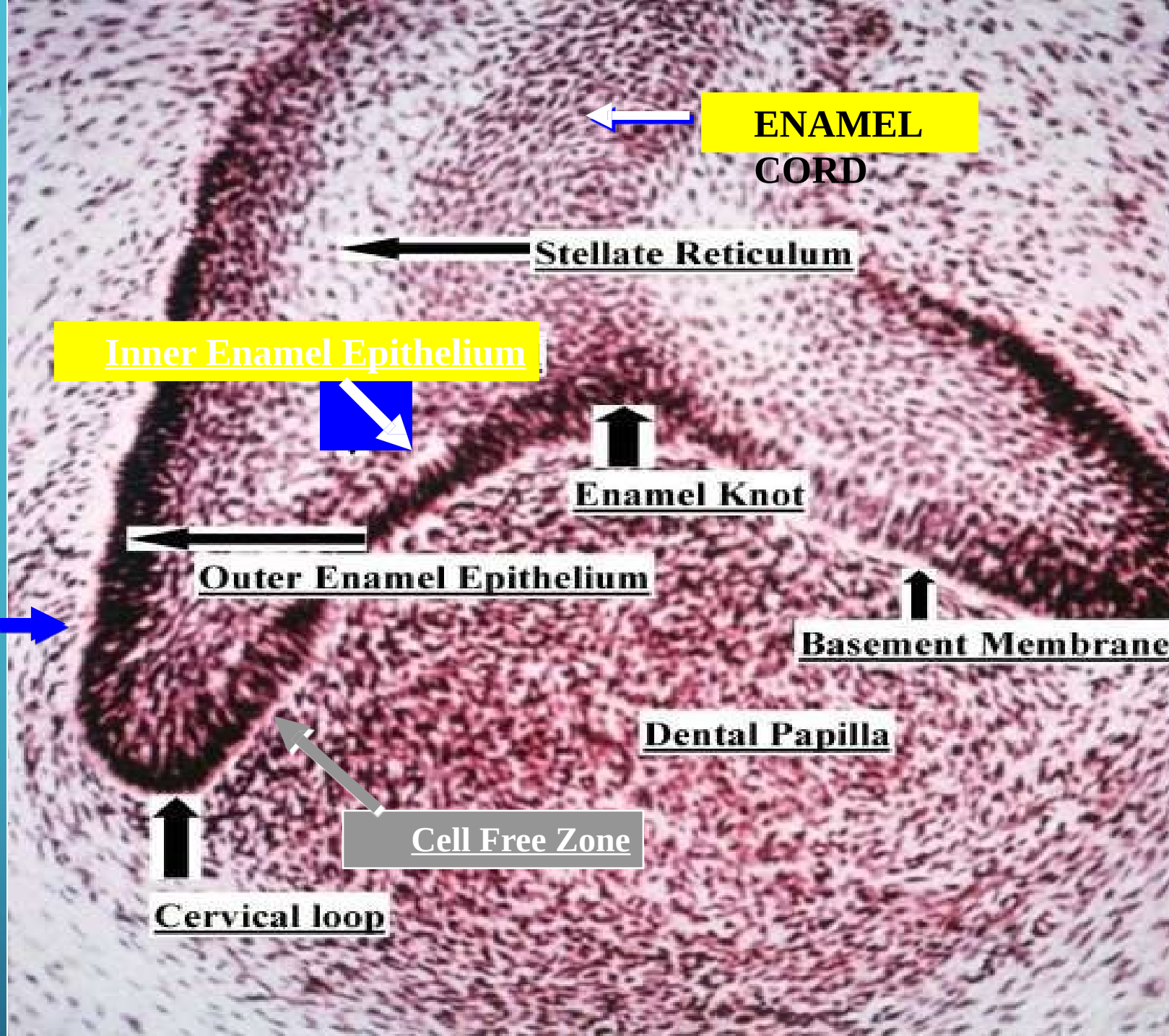
Enamel knot may be formed due to localized thickening at the inner dental epithelium at center.

Strands of epithelial cells also may be formed and called enamel cord .

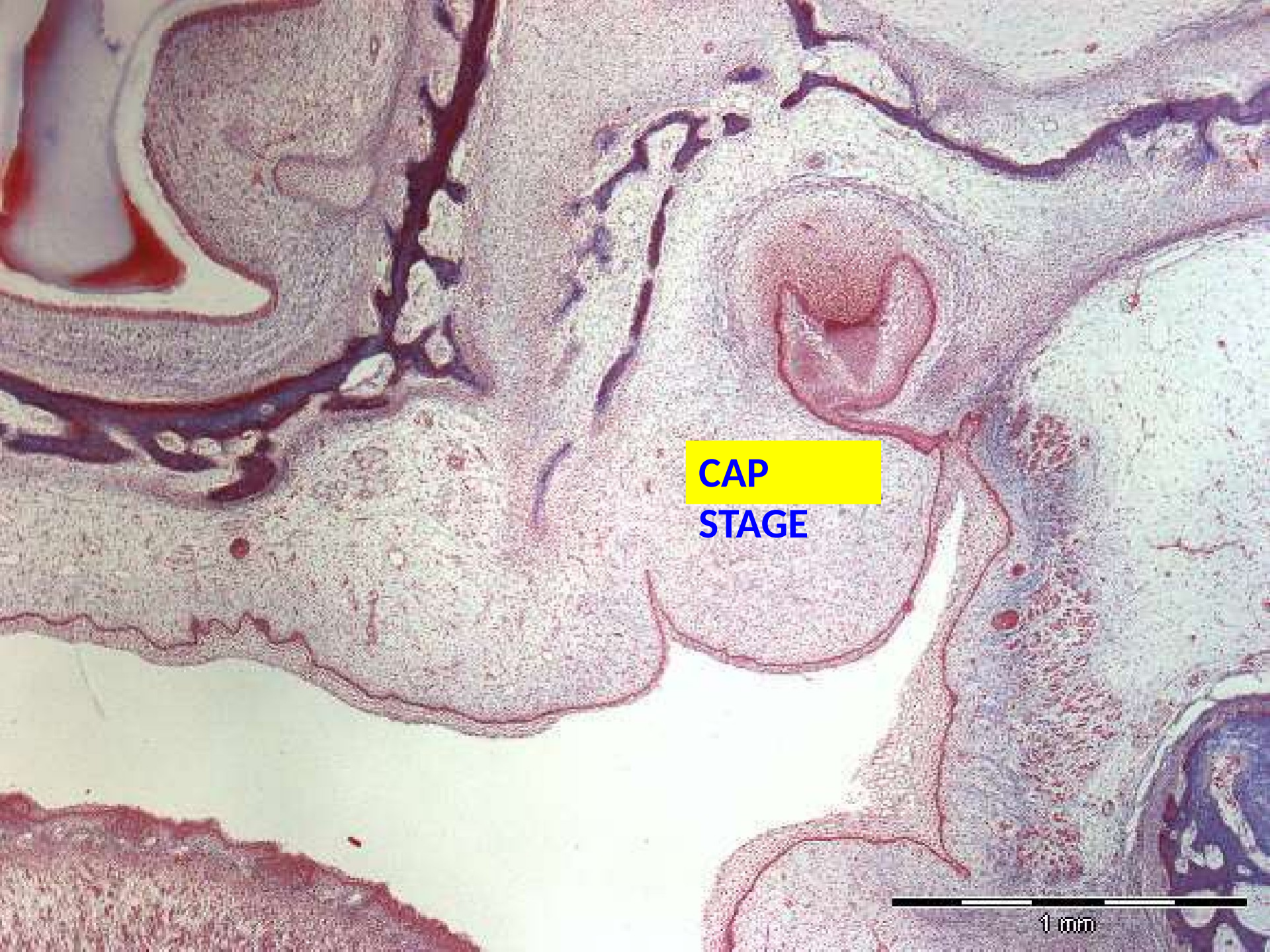
Between the outer and enamel epithelium there is a third layer known as stellate reticulum

# Cap stage

DENTAL  
(follicle)







CAP  
STAGE

1 mm



### 3.B: LATE CAP STAGE:-

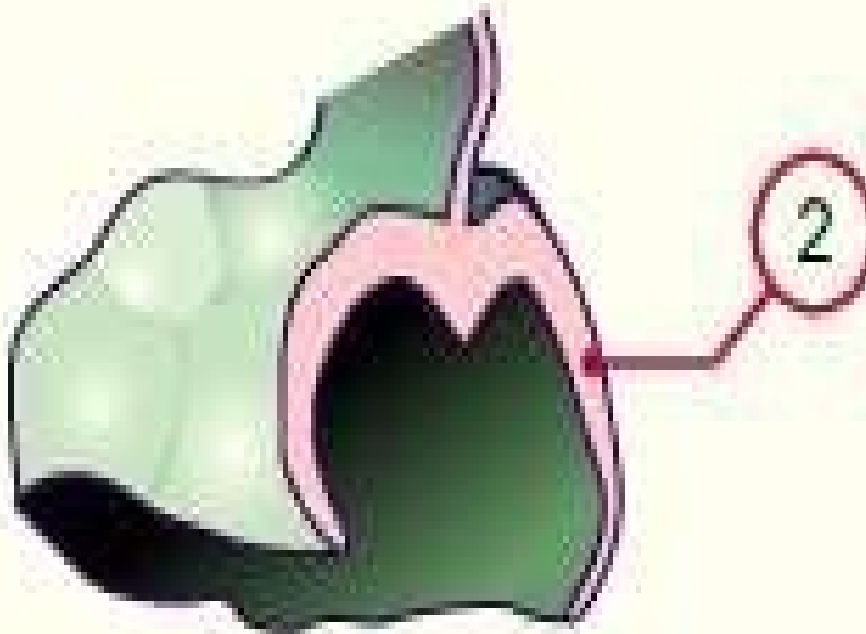

A FOURTH LAYER OF EPITHELIAL CELLS IS FORMED BETWEEN THE INNER DENTAL EPITHELIUM AND STELLATE RETICULUM CALLED STRATUM INTERMEDIUM. IT IS FORMED OF TWO LAYERS OF ROUNDED CELLS WHICH HAVE HIGH ACTIVITY OF ALKALINE PHOSPHATASE ENZYME THAT RESPONSIBLE FOR ENAMEL FORMATION.

#### Cervical loop:-

It is the most peripheral areas in both sides of cap (the proliferation zone) the outer and inner enamel epithelial cells come together with minimal inclusion of the stratum intermedium and stellate reticulum.

After crown formation cervical loop cells proliferate to form bilayer of cells (outer and inner enamel epithelium) called root sheath of Hertwig's

1- CAP-SHAPED  
STAGE 2- TOOTH  
BELL STAGE



# DEVELOPMENT AND GROWTH Of TEETH

## DEVELOPMENT AND GROWTH Of TEETH



## 4. Bell stage

```
graph TD; A[4. Bell stage] --> B[A. Early bell stage]; A --> C[B. Advanced bell stage];
```

A. Early bell stage

B. Advanced bell stage

# bell stage

## A . Early bell stage :

This stage is reached when the invagination of the dental organ is deepened and also the margin of the dental organ ( cervical loop ) grows deeper into the underlying mesenchyme .

1. Enamel organ tissues begin to differentiate.
2. Enamel organ begins to fold into shape of finished crown.
3. Dental papilla tissues begin to differentiate.

Associated with these changes , other changes occur in the dental organ as :

1. **Outer enamel epithelium** become cells transformed into folded layer instead of the previous smooth layer . The adjacent ectomesenchyme invade these folds.

The ectomesenchyme contain a rich capillary buds to provide nutrition for the highly and metabolically active dental organ .

2. ***inner enamel epithelium*** become tall columnar. these cells exert an inductive effect on the underlying ectomesenchymal cells found in the dental papilla resulting in there differentiation into odontoblasts .

3. ***Stellate reticulum*** The mucoid fluids in the intercellular spaces increases , thus the cells of the stellate reticulum appear star shaped .

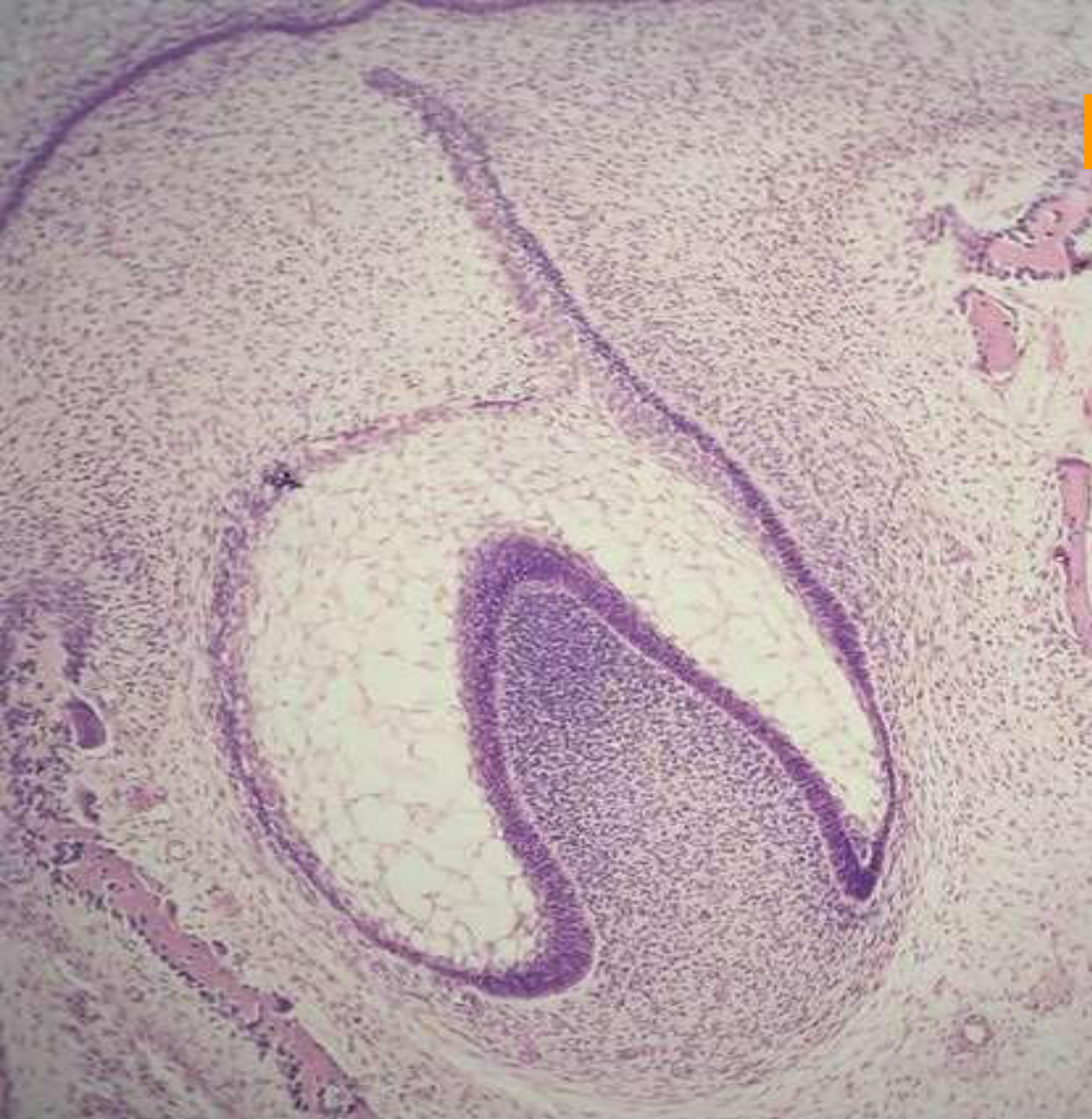4. ***stratum intermedium*** several squamous cells develop between the stellate reticulum and the inner enamel epithelium . these cells have a high degree of metabolic activity and appear to be essential for enamel formation .



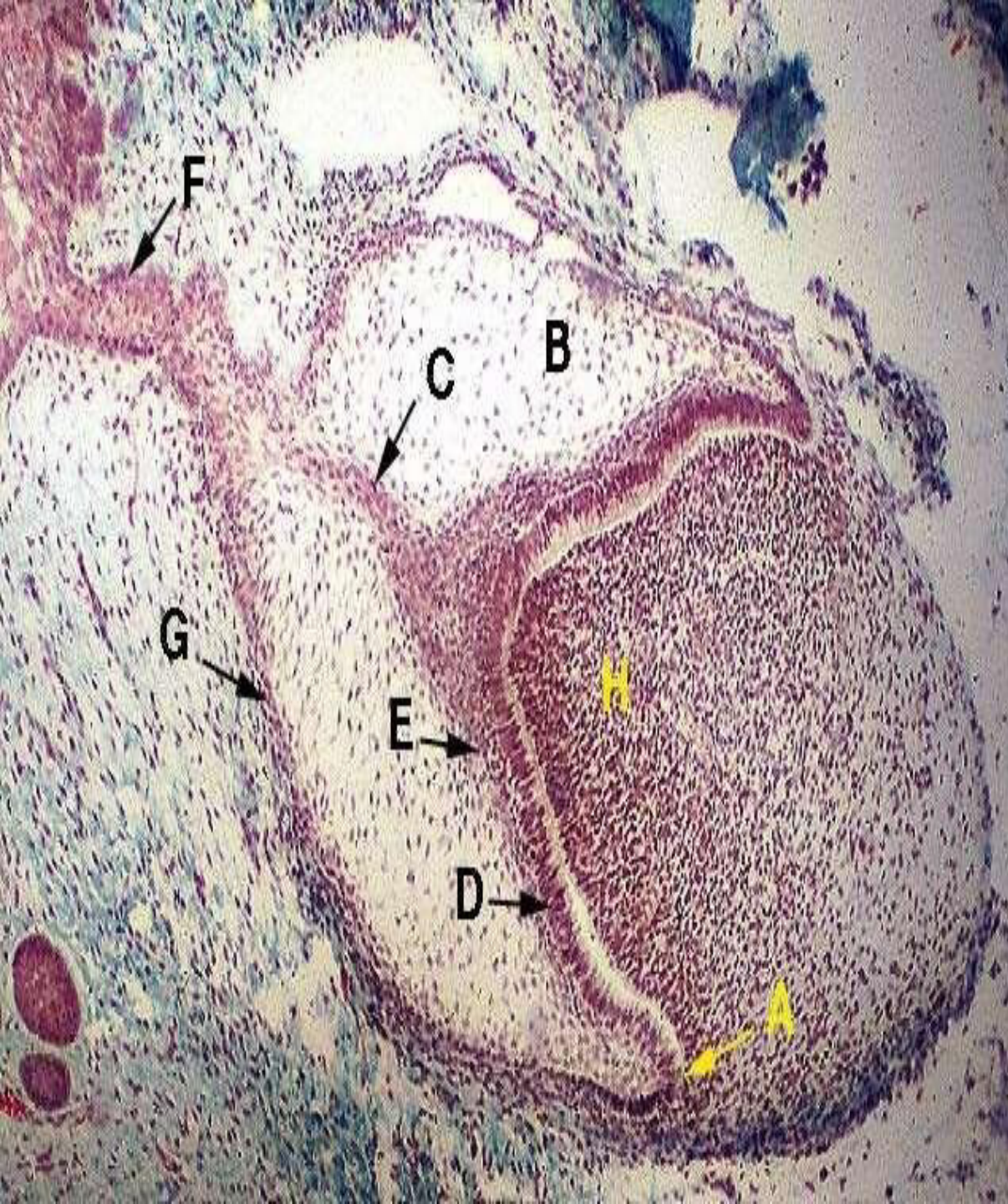
**4. Dental papilla** Before amelogenesis, the inductive effect exerted by the organized inner enamel epithelium ( tall columnar cells ), causes transformation of the peripheral ectomesenchymal cells of the dental papilla into odontoblasts and become potentially capable to form dentin .

**5. Dental sac** The fibrillar components of the dental sac arrange themselves in a circular pattern . As the root start to develop and cementum is being deposited on dentin surface, the fibers of the dental sac differentiate into periodontal fibers and become embedded into the developing cementum and alveolar bone .

**EARLY BELL  
STAGE**

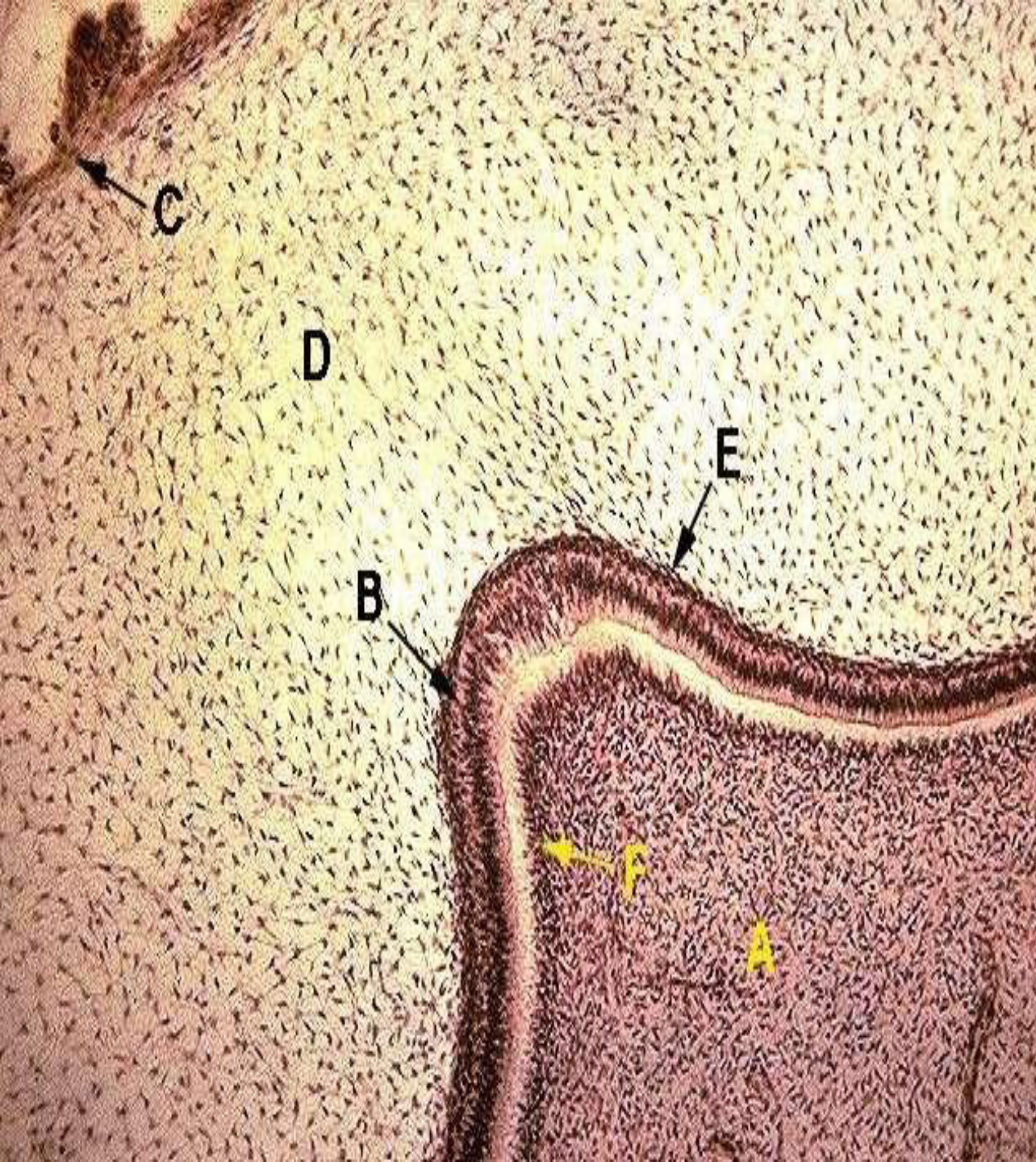






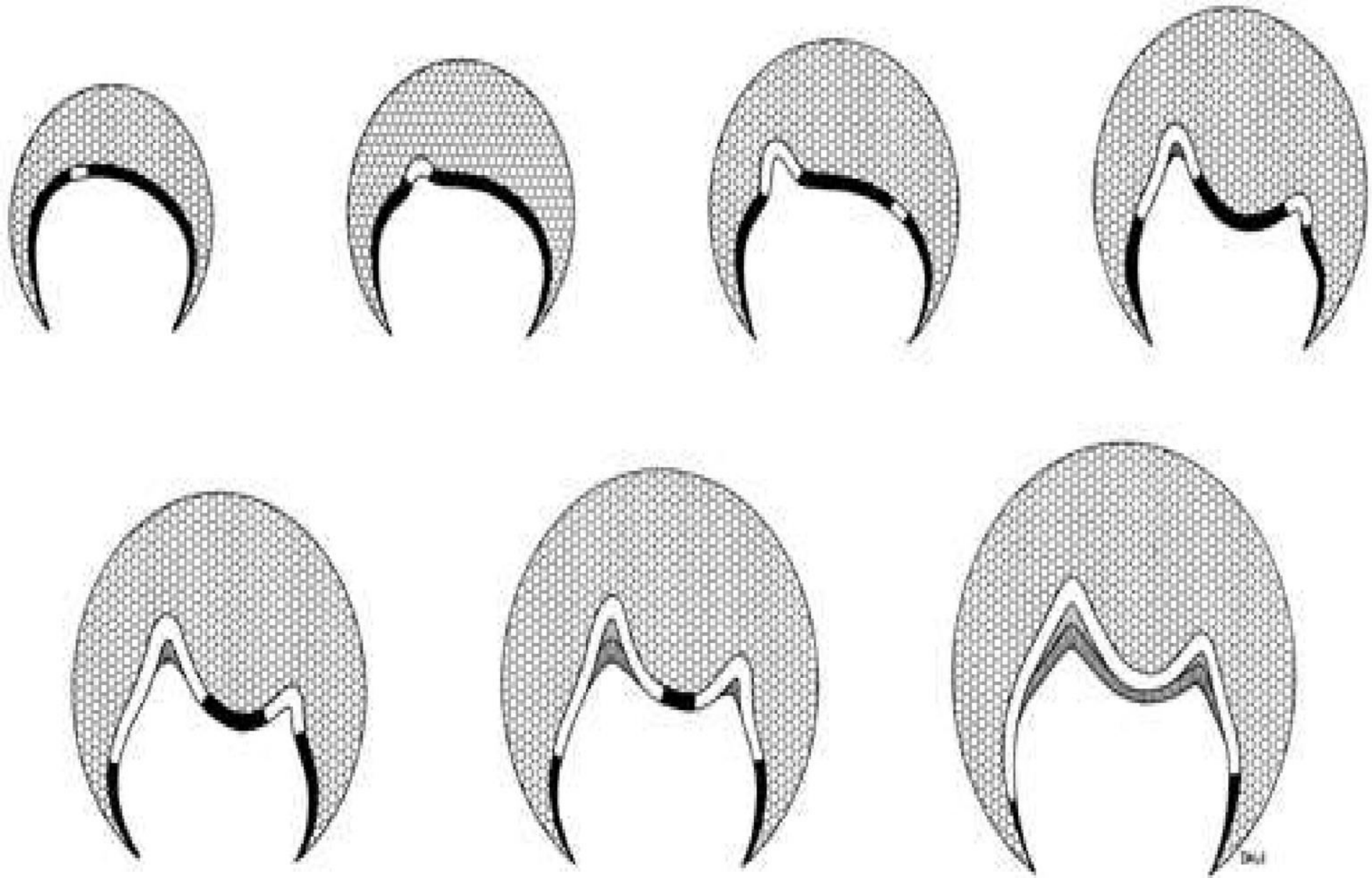
- A= cervical loop
- B= stellate reticulum
- C= enamel cord
- D= inner enamel epithelium
- E= stratum intermedium
- F= dental lamina
- G= outer enamel epithelium
- H= dental papilla





- A= dental papilla (a very condensed group of cells)
- B= ameloblast cell layer of the inner enamel epithelium cells are columnar
- C= outer enamel epithelium cells
- D= stellate reticulum
- E= stratum intermedium
- F= outer cells of dental papilla or differentiating odontoblasts





**FUTURE CROWN PATTERNING OCCURS IN THE BELL STAGE, BY FOLDING OF THE INNER DENTAL EPITHELIUM.**



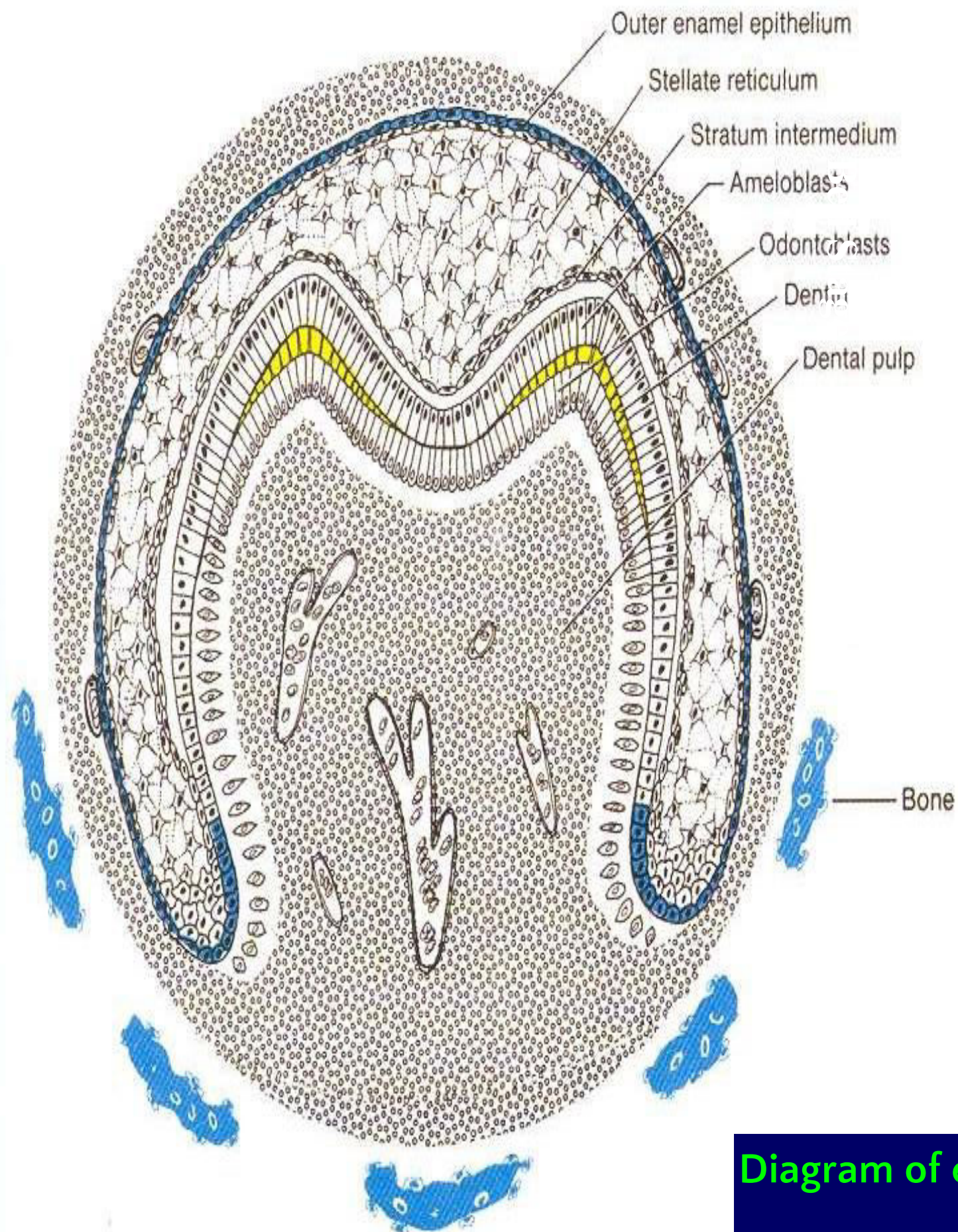
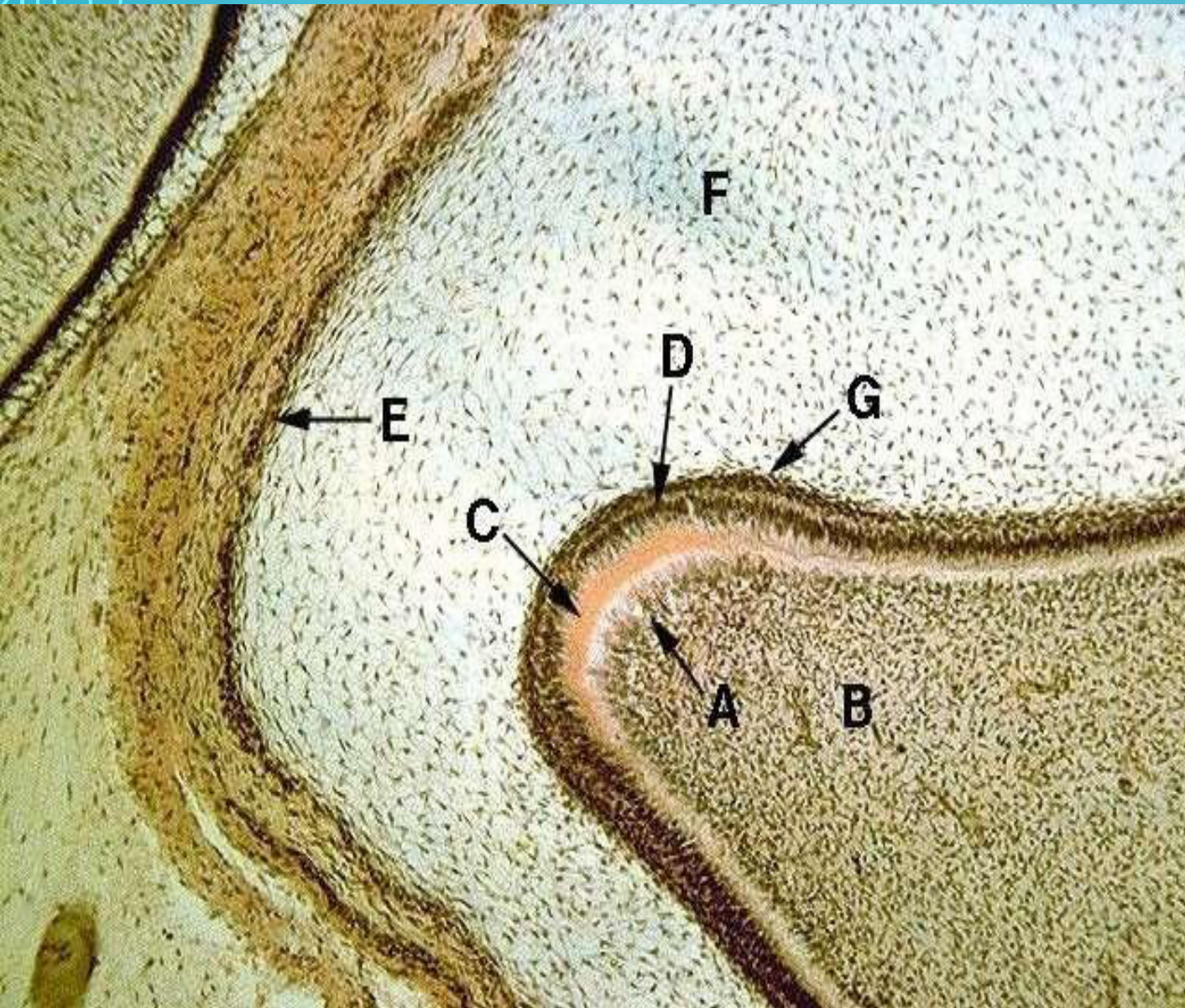


Diagram of early bell stage



## B. Advanced bell stage

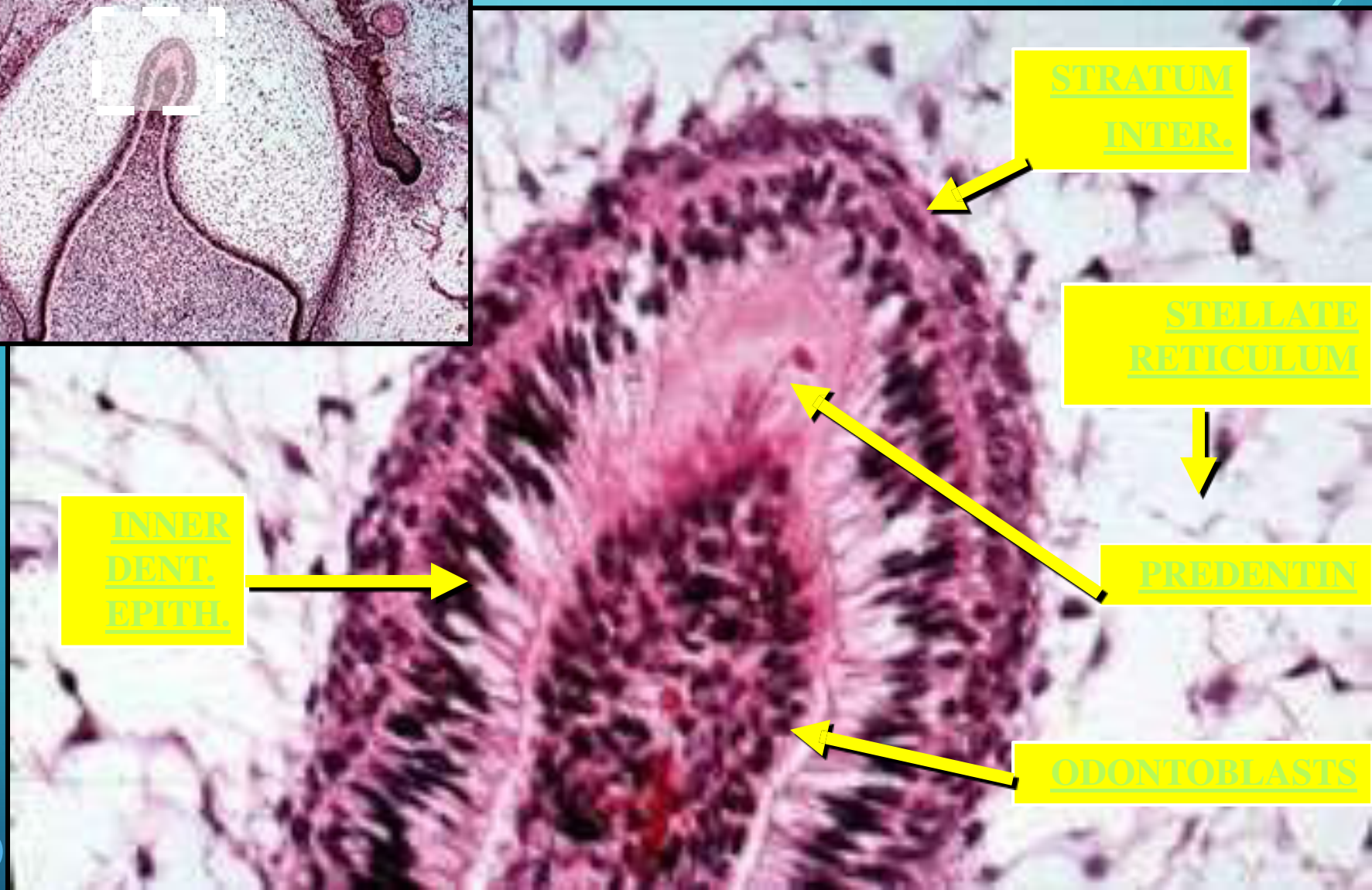
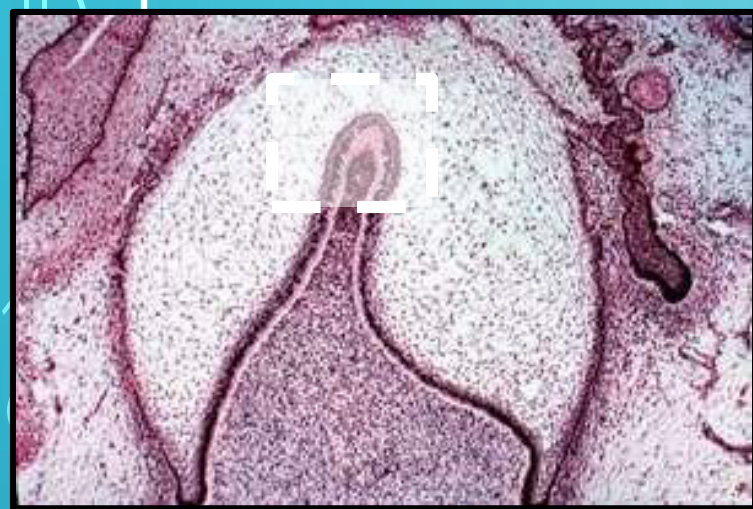### Formation of hard tissue structure



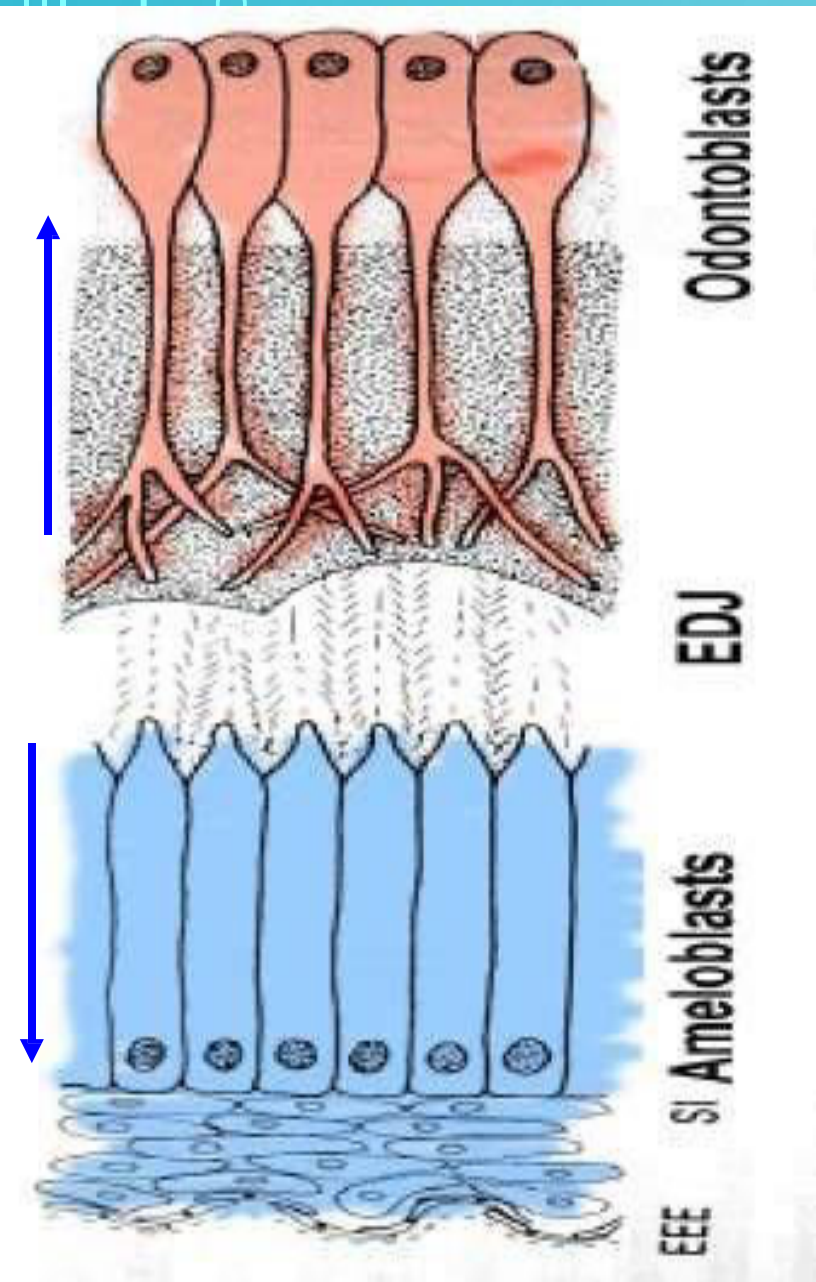
- A= odontoblasts
- B= dental papilla
- C= dentin
- D= organizing ameloblast layer of inner dental epithelium
- E= outer enamel epithelium
- F= stellate reticulum
- G = stratum intermedium



# Histological structure of the tooth germ during advanced bell stage

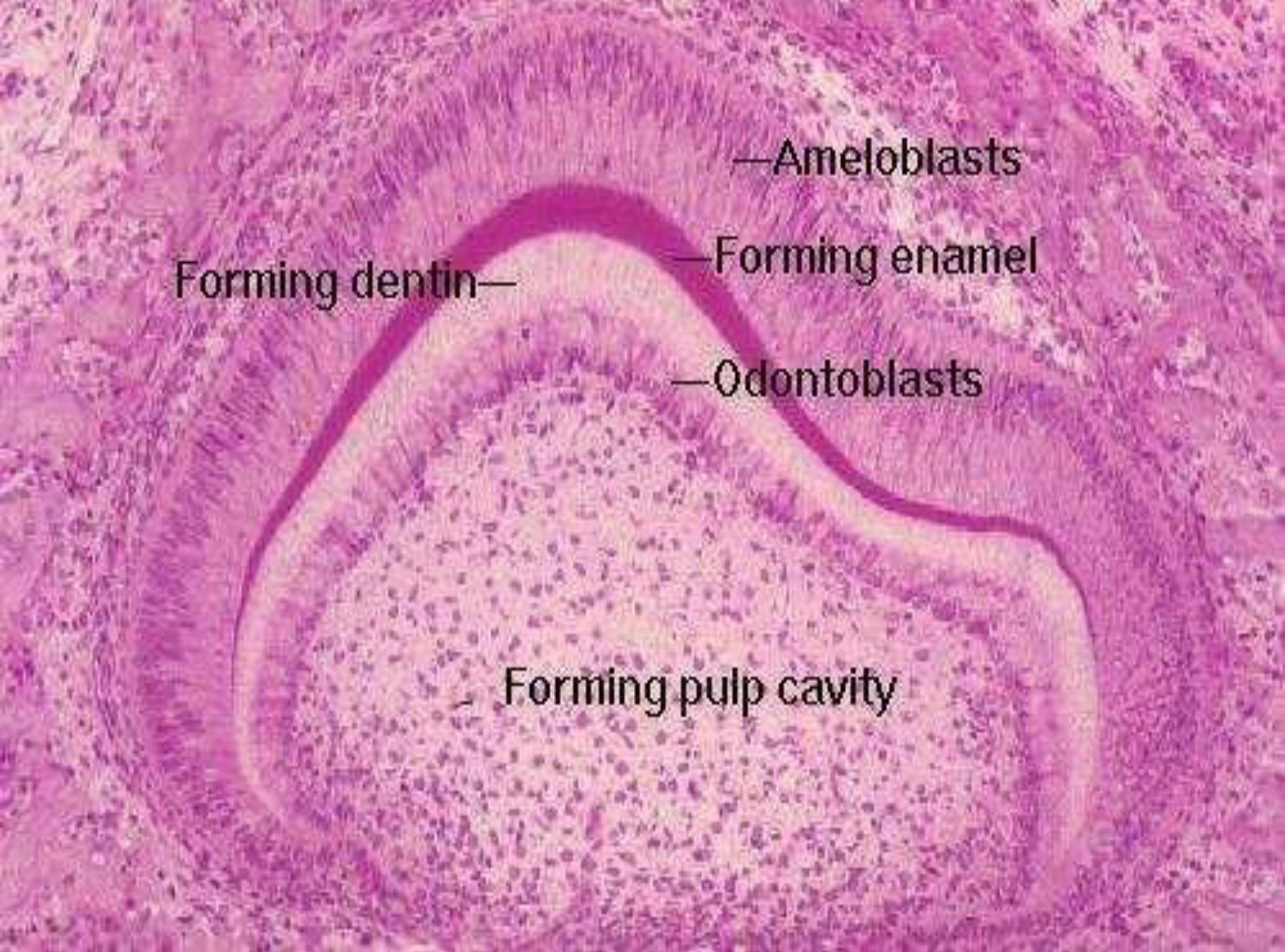


# Ameloblast & odontoblast



- Ameloblast and Odontoblast layers move apart, leaving enamel and dentine between them

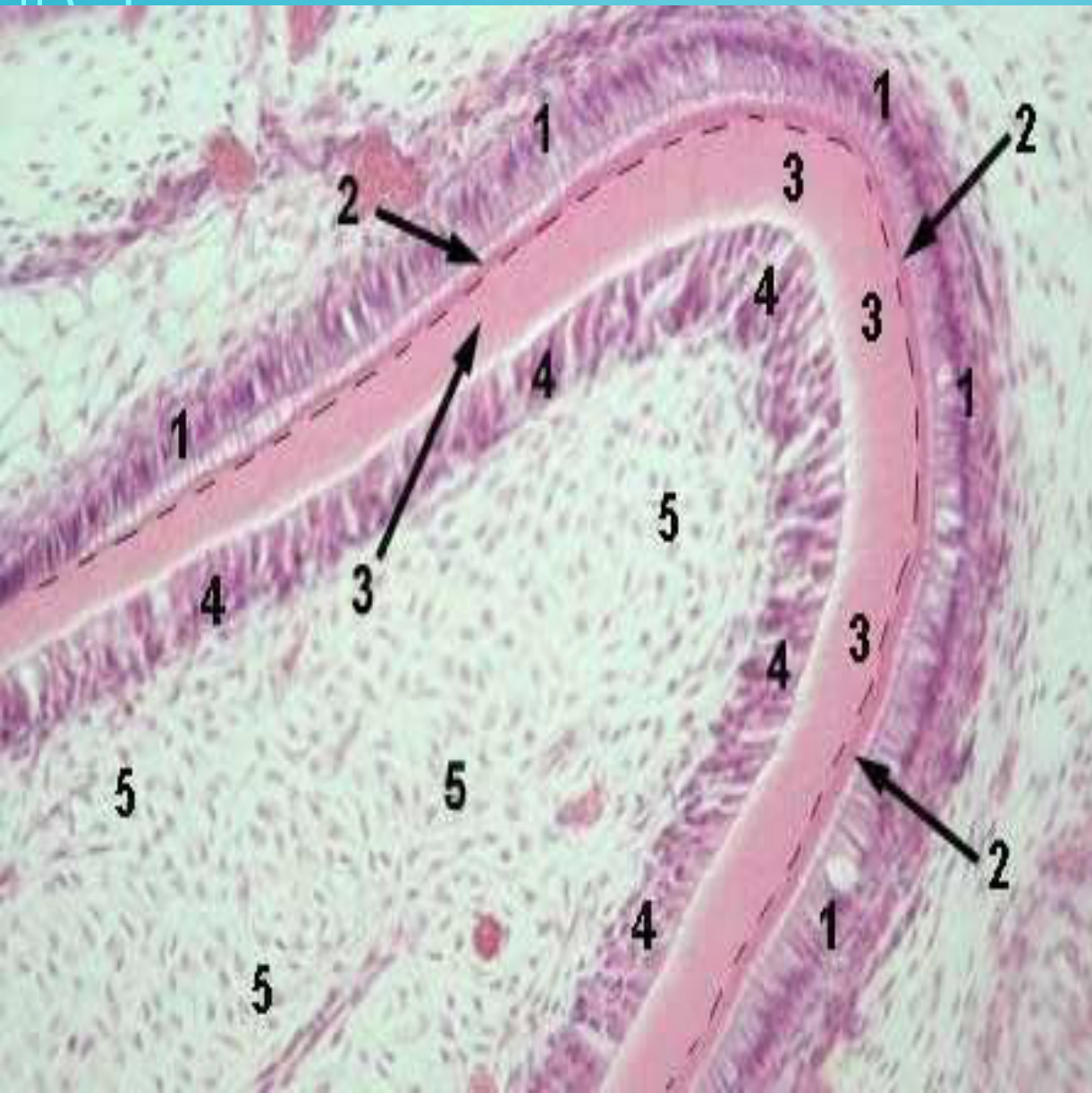




**ADVANCED BELL STAGE**



## Advanced bell stage



- 1 - ameloblasts
- 2 - enamel
- 3- dentine  
(predentine)
- 4- odontoblasts
- 5 - dental pulp



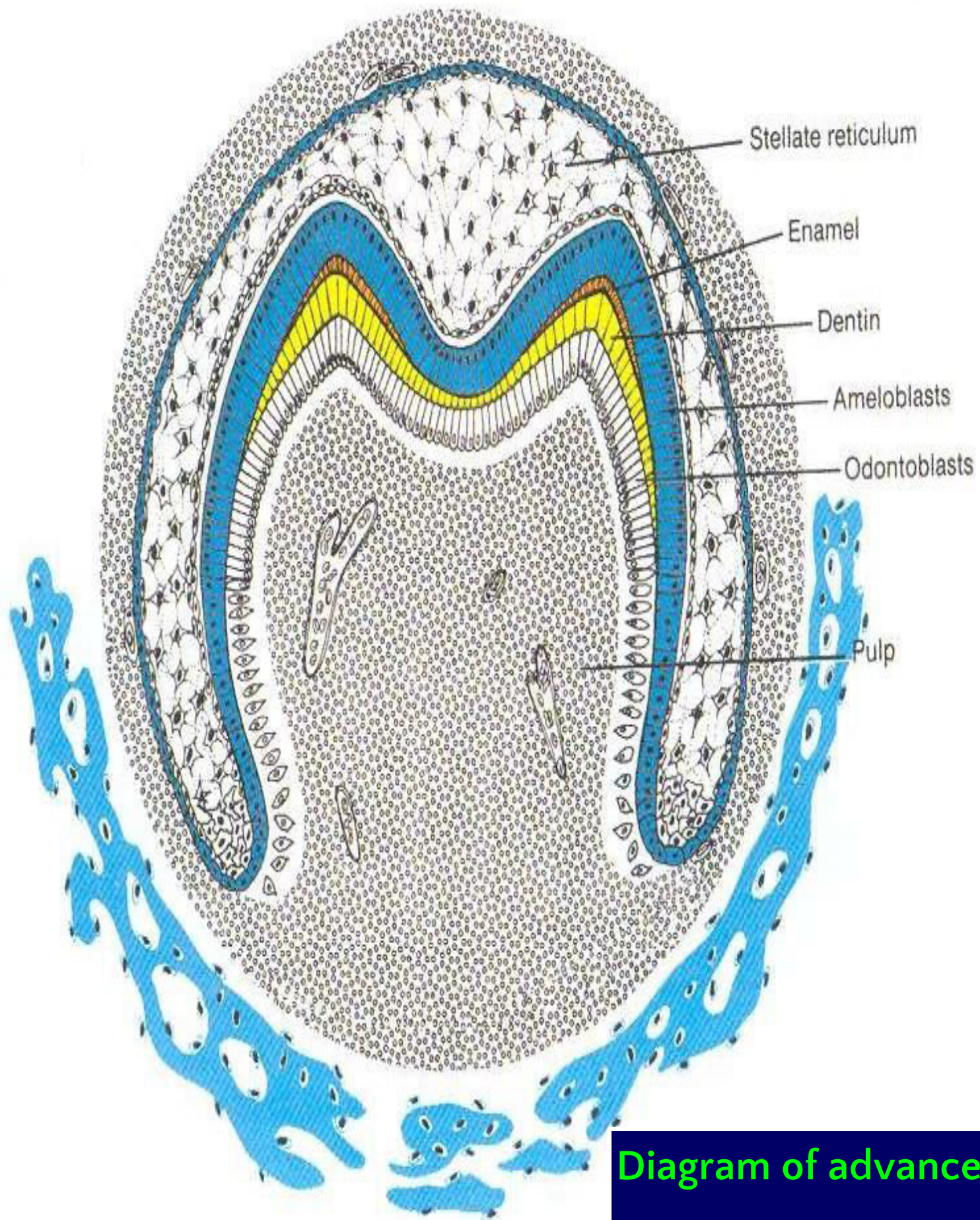


Diagram of advanced bell stage



# ROOT FORMATION

(Cervical loop forms the epithelial root sheath of Hertwig)

