

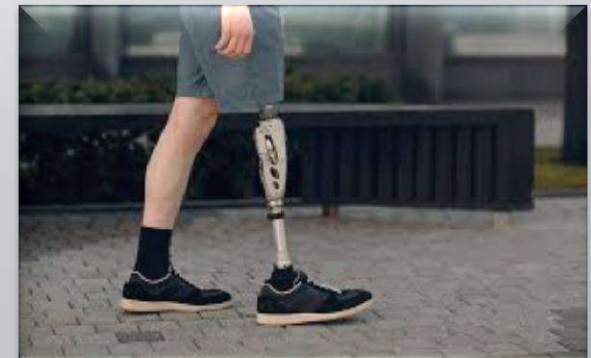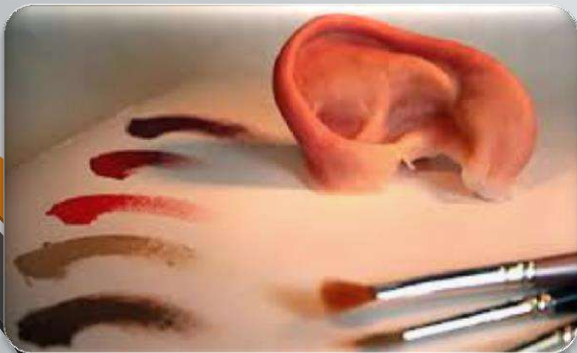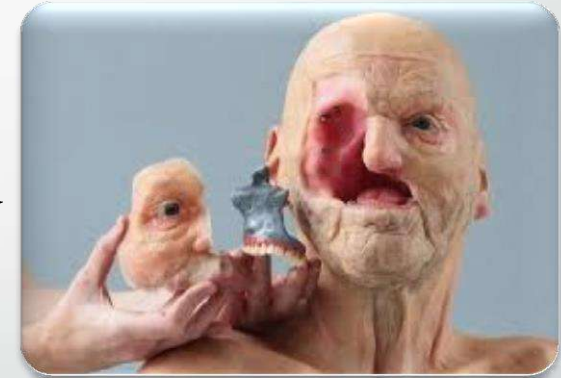
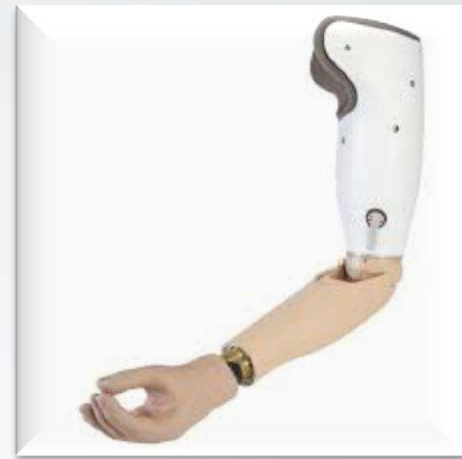# Maxillofacial prosthetic

**INTRODUCTION**

**LECT. HUSSEIN T. ABED**

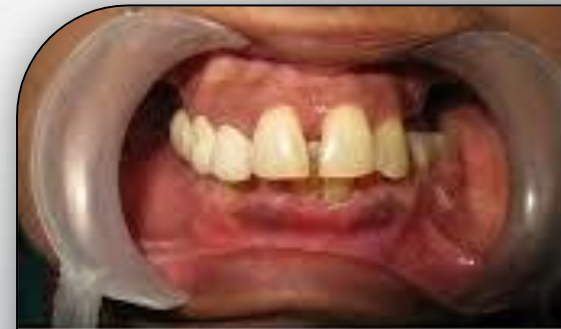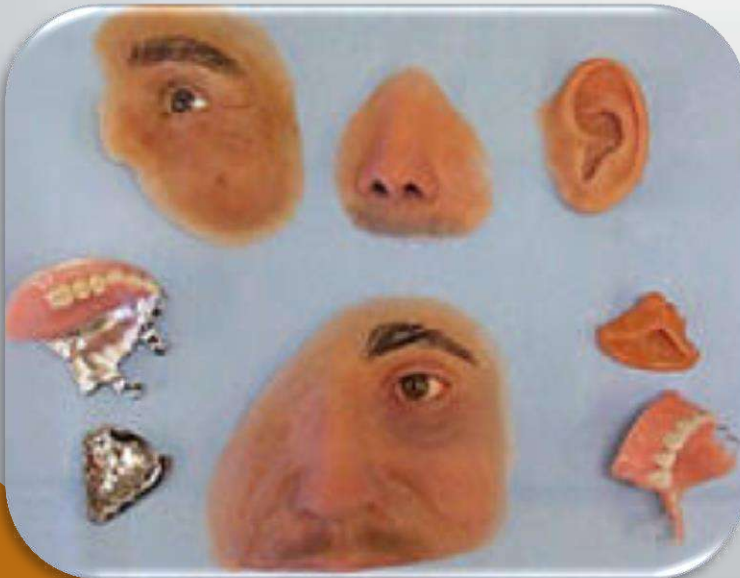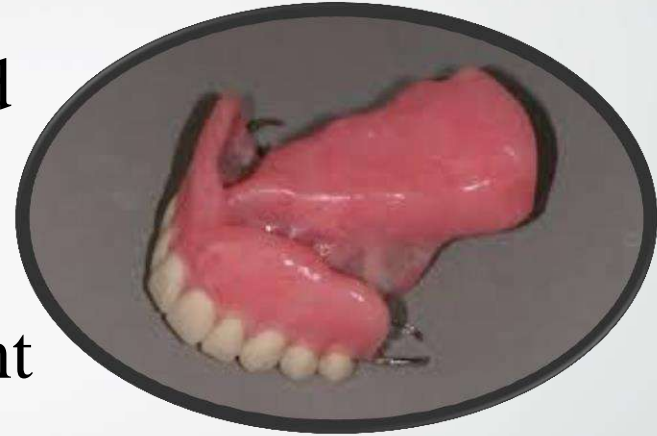# TERMINOLOGY

- **Prosthesis :**
- **maxillofacial prosthetics:** the branch of prosthodontics concerned with the restoration and/or replacement of stomatognathic and craniofacial structures with prostheses that may or may not be removed on a regular or elective basis.
- **Maxillofacial Prosthesis:** any prosthesis used to replace part or all of any stomatognathic and/or craniofacial structures.

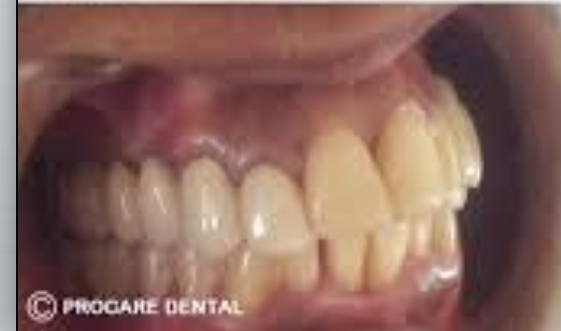

# TYPES OF MFP

- Prostheses which can be removed and replaced by the patient are called “removable prostheses,” while prostheses which the patient cannot remove or replace are called “fixed prostheses”



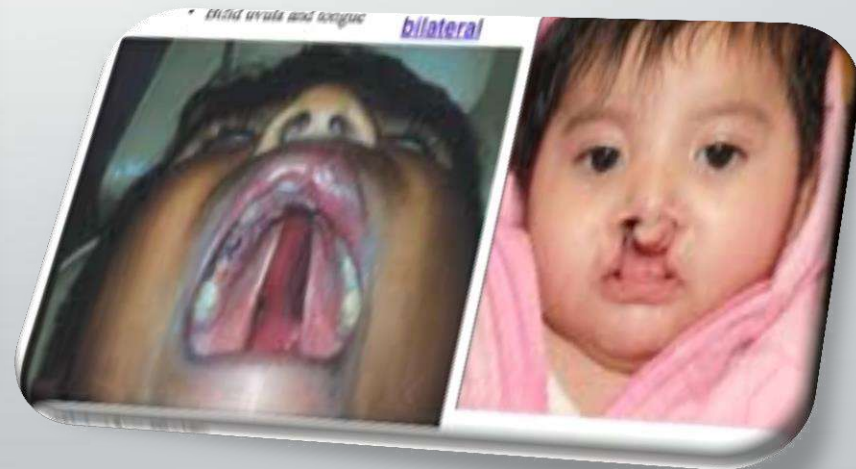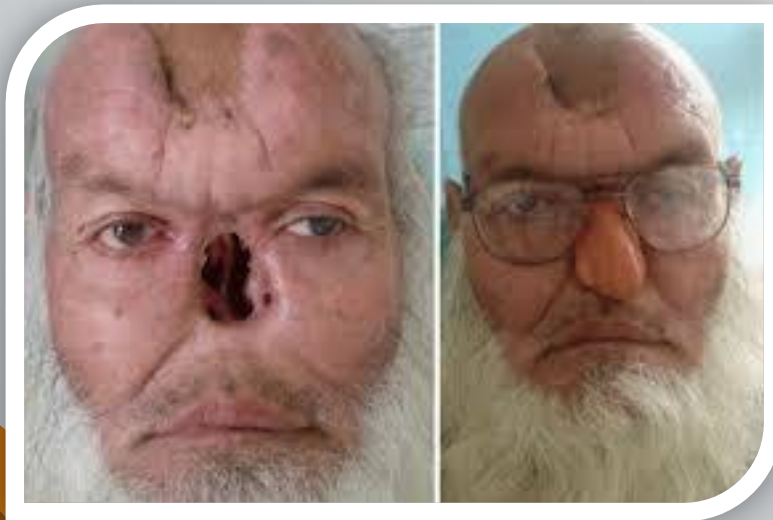BEFORE



AFTER



- large volume tissue losses are called “defects
- .” **Defects** are generally reconstructed by plastic reconstruction “reconstruction.” Some defects cannot be repaired with **operative methods**, rehabilitated by **prosthetic method**, rehabilitation aims to regain the lost abilities with artificial materials

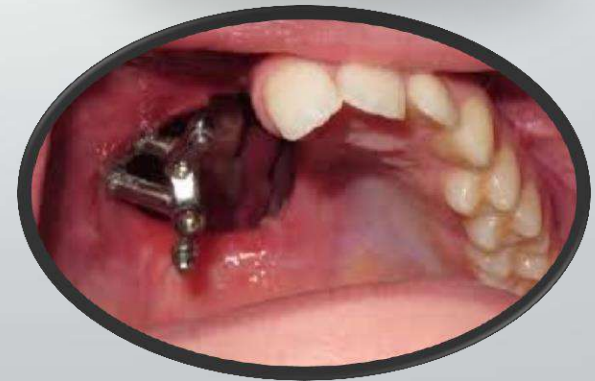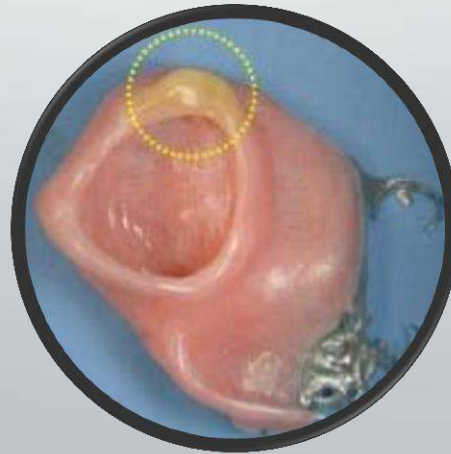
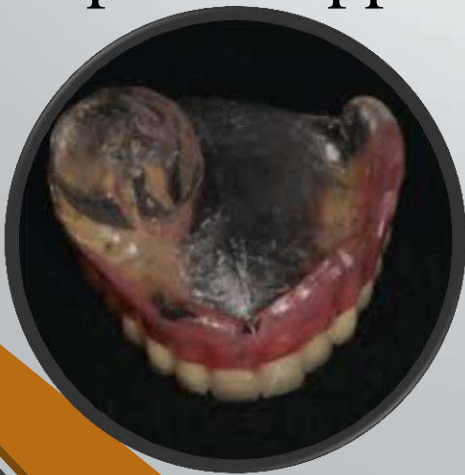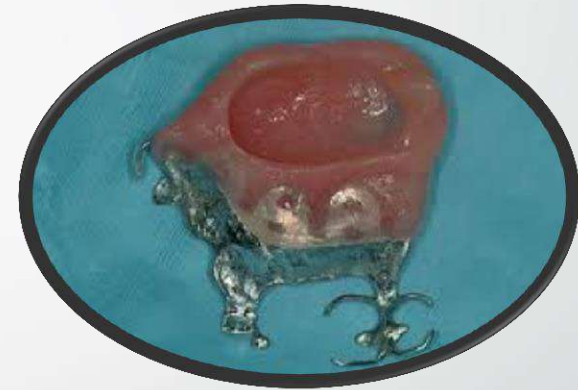




# CLASSIFICATIONS:

## A. ACCORDING TO THE SUPPORT

1. Teeth-supported prostheses:
2. Tissue-supported prostheses:
3. Teeth-and-tissue-supported prostheses:
4. Implant-supported prostheses:



# CLASSIFY THE DEFECTS ACCORDING TO THEIR ETIOLOGIES

## A. Congenital Defects

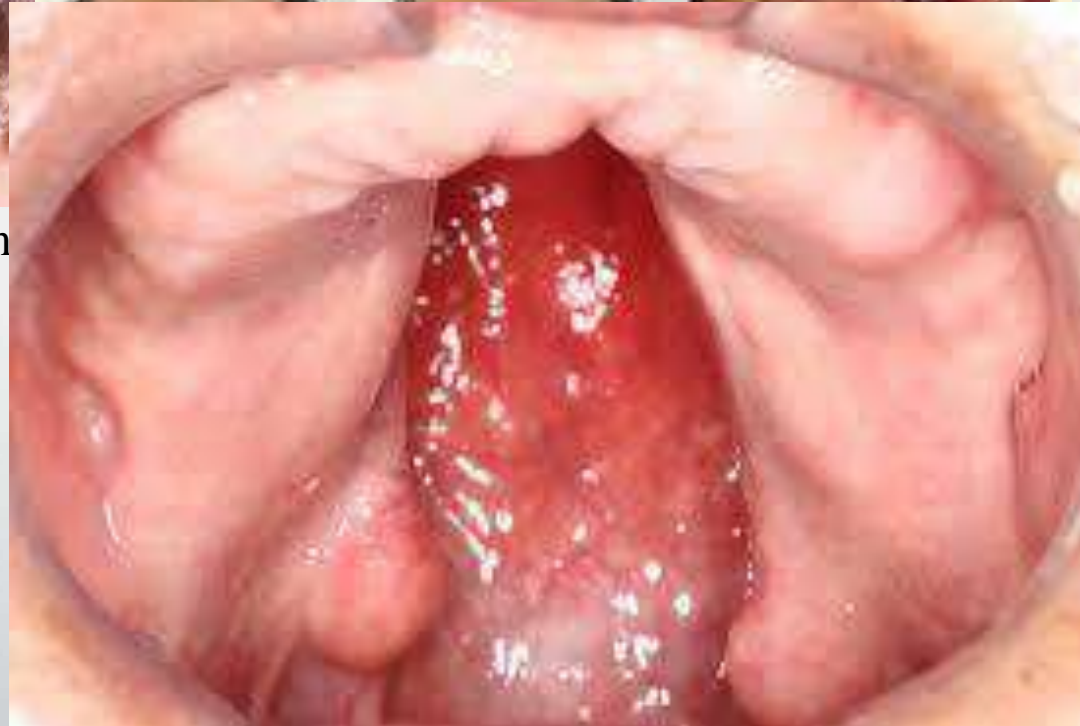1. Cleft lip and palate
2. Craniofacial cleft

## B. Developmental Defects :

1. Prognathism or retrognathism
2. Soft tissue anomalies
3. Chewing muscle anomalies
4. Skeletal anomalies

## C. Acquired Defects:

1. Intra-oral Defects
2. Extra-oral Defects
3. Combined Defects Basic Concepts



# OBJECTIVES OF MAXILLO-FACIAL PROSTHESES

- Restoration of esthetics or cosmetic appearance of the patient
- Restoration of function
- Protection of tissues
- Therapeutic or healing effect
- Psychologic therapy



# INDICATIONS FOR MAXILLOFACIAL PROSTHESES

- **post-operative** controls can be effectively established.
- In cases that received **radiotherapy**
- the defect **cannot be closed** with the patient's own tissues
- the **patient's age, health, or solvency** cannot withstand surgical reconstruction

# REQUIREMENTS OF MFP:

1. Should be easily placed and removed,
2. Should fix the lost function,
3. The appearance should be close to normal,
4. Should be easily cleaned,
5. Should be long lasting and resistant,
6. Should not have dimensional changes
7. Should be light and easy to make

# MATERIALS

Ideal **Requisites** Of Maxillofacial Materials.....

1. Biocompatibility
2. Flexibility
3. Color and translucency
4. Chemical and environmental stability
5. Thermal conductivity



# MATERIALS

Ideal **Requisites** Of Maxillofacial Materials.....

6. Ease of Processing

7. Strength –

8. Ease of duplication

9. Weight

10. Dimensional stability

# CRITERIA FOR MAXILLOFACIAL MATERIALS

## Processing Characteristics

1. Low Viscosity at ambient temperature
2. Intrinsic and extrinsic Coloration possible
3. Low Solubility parameter
4. Sufficient working time
5. Low curing temperature



THANK YOU



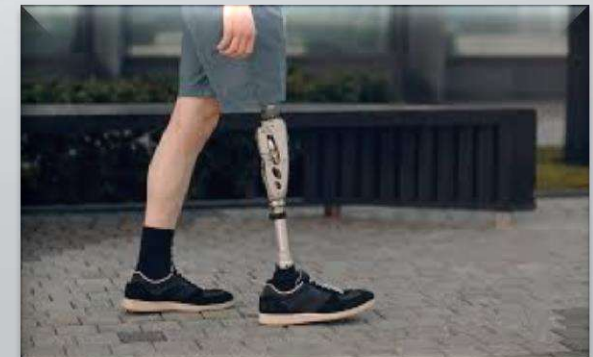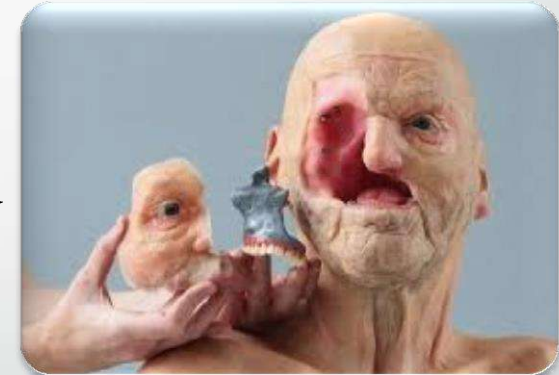
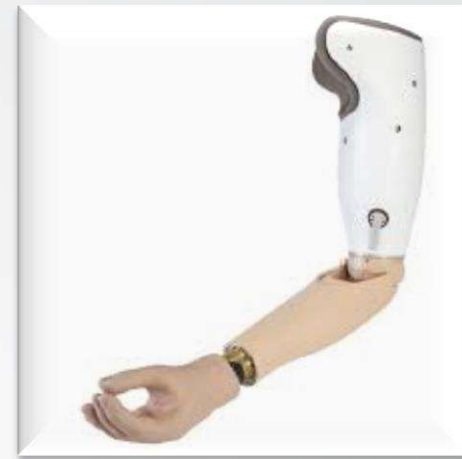# Maxillofacial prosthetic

**INTRODUCTION**

**LECT. HUSSEIN T. ABED**

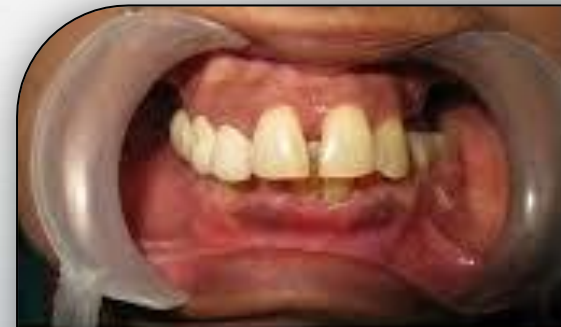# TERMINOLOGY

- **Prosthesis :**
- **maxillofacial prosthetics:** the branch of prosthodontics concerned with the restoration and/or replacement of stomatognathic and craniofacial structures with prostheses that may or may not be removed on a regular or elective basis.
- **Maxillofacial Prosthesis:** any prosthesis used to replace part or all of any stomatognathic and/or craniofacial structures.

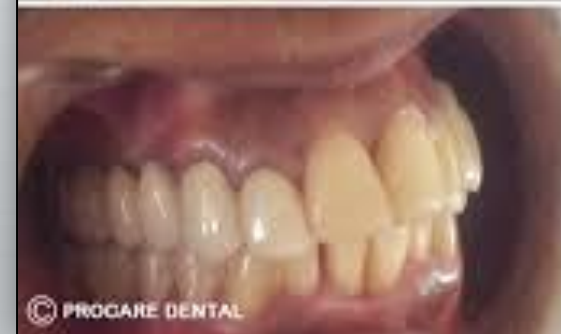

# TYPES OF MFP

- Prostheses which can be removed and replaced by the patient are called “removable prostheses,” while prostheses which the patient cannot remove or replace are called “fixed prostheses”



BEFORE



AFTER



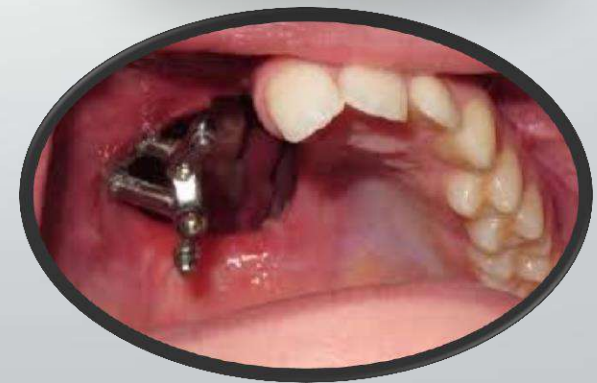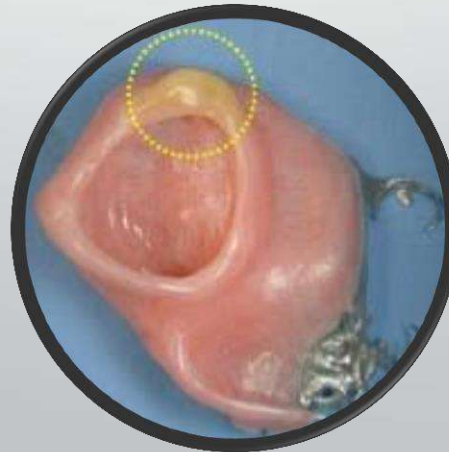
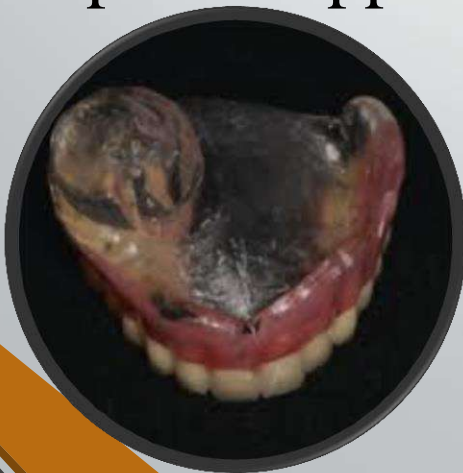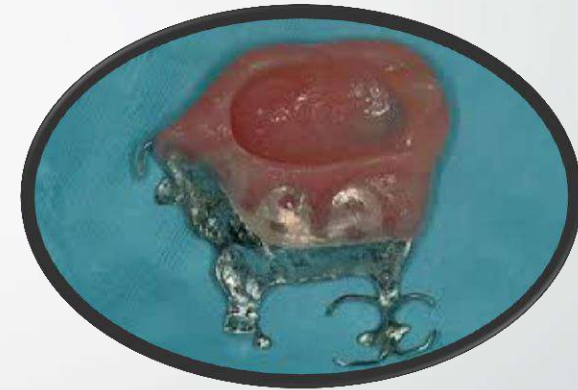
- large volume tissue losses are called “defects
- .” **Defects** are generally reconstructed by plastic reconstruction “reconstruction.” Some defects cannot be repaired with **operative methods**, rehabilitated by **prosthetic method**, rehabilitation aims to regain the lost abilities with artificial materials



# CLASSIFICATIONS:

## A. ACCORDING TO THE SUPPORT

1. Teeth-supported prostheses:
2. Tissue-supported prostheses:
3. Teeth-and-tissue-supported prostheses:
4. Implant-supported prostheses:



# CLASSIFY THE DEFECTS ACCORDING TO THEIR ETIOLOGIES

## A. Congenital Defects

1. Cleft lip and palate
2. Craniofacial cleft

## B. Developmental Defects :

1. Prognathism or retrognathism
2. Soft tissue anomalies
3. Chewing muscle anomalies
4. Skeletal anomalies

## C. Acquired Defects:

1. Intra-oral Defects
2. Extra-oral Defects
3. Combined Defects Basic Concepts



# OBJECTIVES OF MAXILLO-FACIAL PROSTHESES

- Restoration of esthetics or cosmetic appearance of the patient
- Restoration of function
- Protection of tissues
- Therapeutic or healing effect
- Psychologic therapy

# INDICATIONS FOR MAXILLOFACIAL PROSTHESES

- **post-operative** controls can be effectively established.
- In cases that received **radiotherapy**
- the defect **cannot be closed** with the patient's own tissues
- the **patient's age, health, or solvency** cannot withstand surgical reconstruction



# REQUIREMENTS OF MFP:

1. Should be easily placed and removed,
2. Should fix the lost function,
3. The appearance should be close to normal,
4. Should be easily cleaned,
5. Should be long lasting and resistant,
6. Should not have dimensional changes
7. Should be light and easy to make



# MATERIALS

Ideal **Requisites** Of Maxillofacial Materials.....

1. Biocompatibility
2. Flexibility
3. Color and translucency
4. Chemical and environmental stability
5. Thermal conductivity

# MATERIALS

Ideal **Requisites** Of Maxillofacial Materials.....

6. Ease of Processing

7. Strength –

8. Ease of duplication

9. Weight

10. Dimensional stability

# CRITERIA FOR MAXILLOFACIAL MATERIALS

## Processing Characteristics

1. Low Viscosity at ambient temperature
2. Intrinsic and extrinsic Coloration possible
3. Low Solubility parameter
4. Sufficient working time
5. Low curing temperature



THANK YOU

---

# Anatomy of face in relation to maxillofacial prosthesis

Lect. Hussein T.Abed

30\12\2020



---

The anatomy of the facial orifices has great relevance for the maxillofacial prosthodontist. It includes **bony orbit**, the **bony nasal opening** (piriform opening), the **oral opening** and maxillomandibular apparatus, and the **external auditory meatus**, as well as the collective and appended anatomy of these facial features.

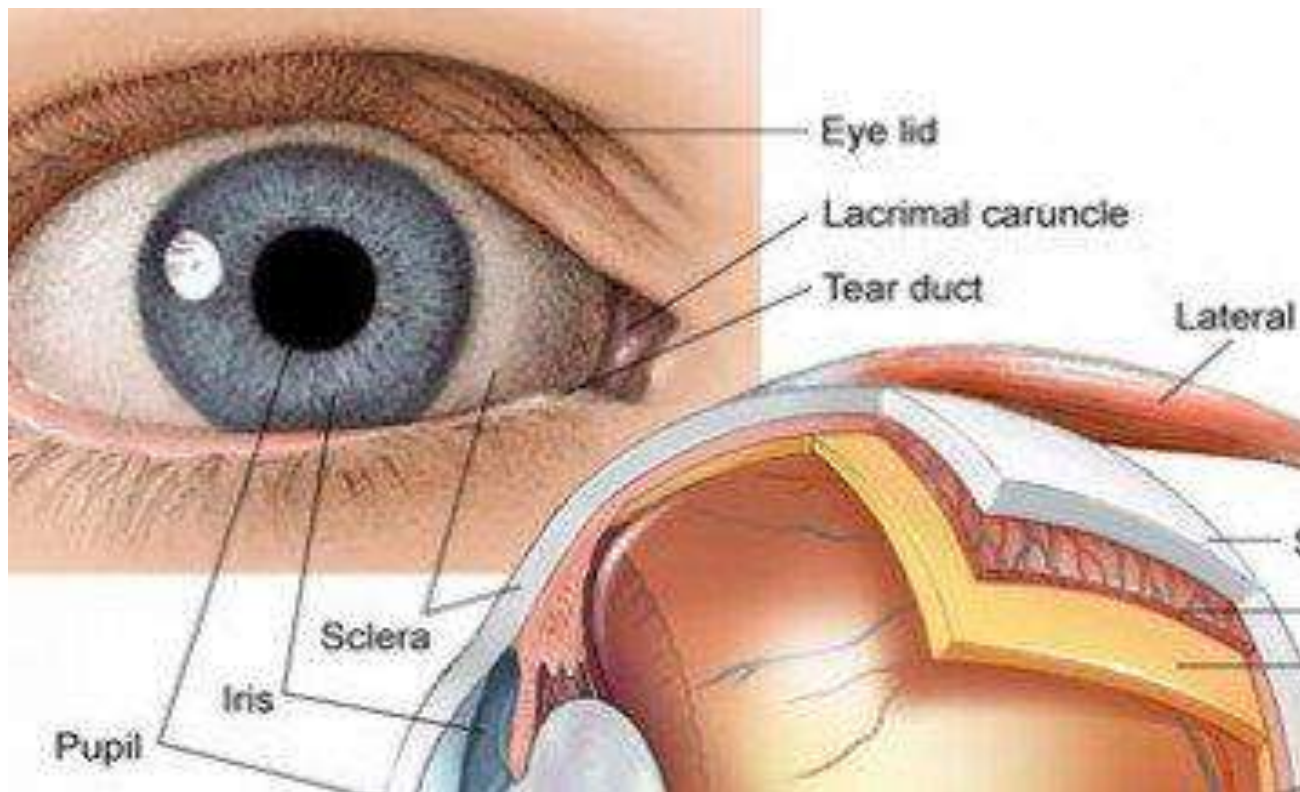
---

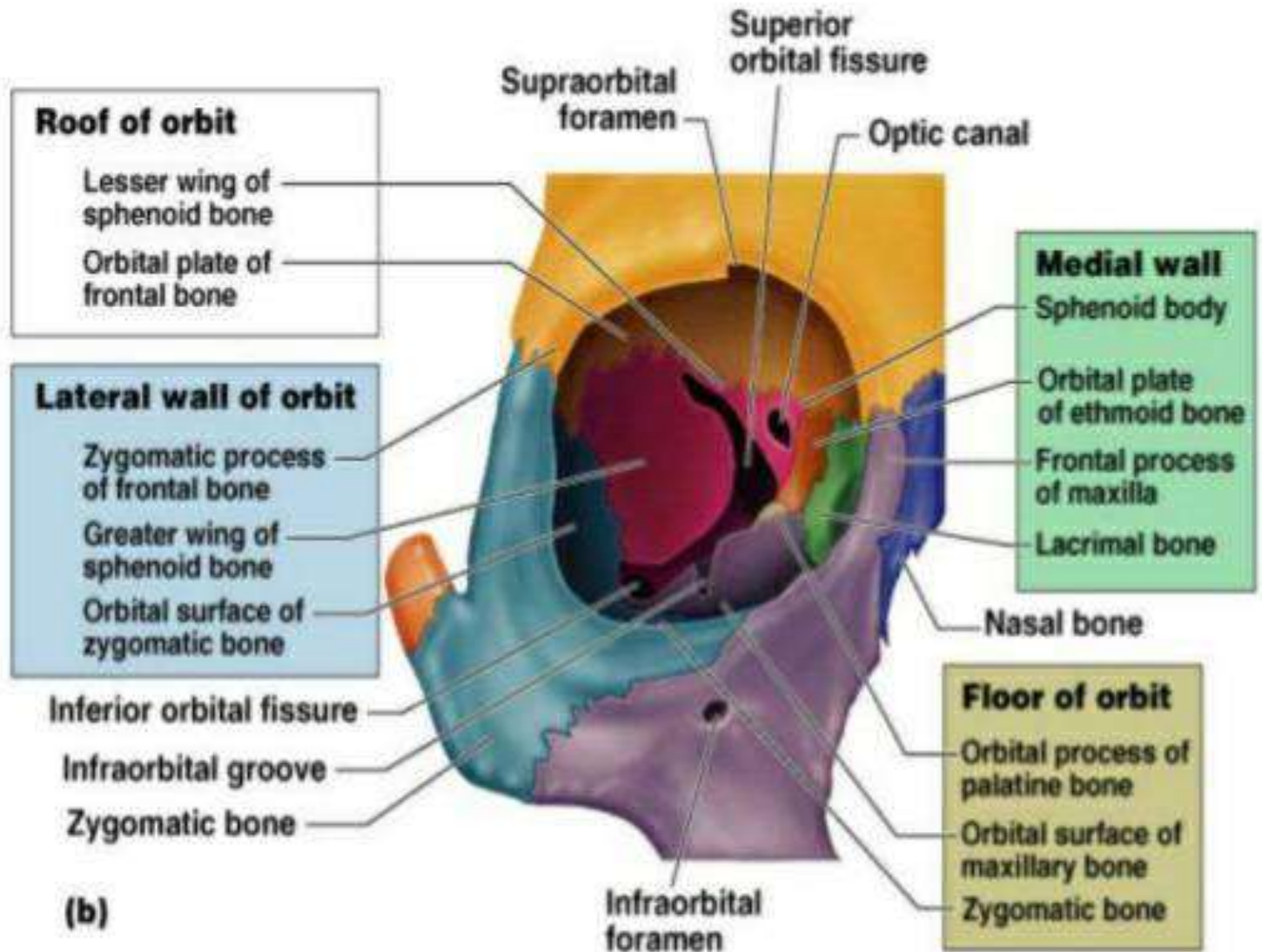
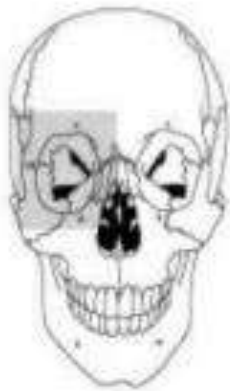

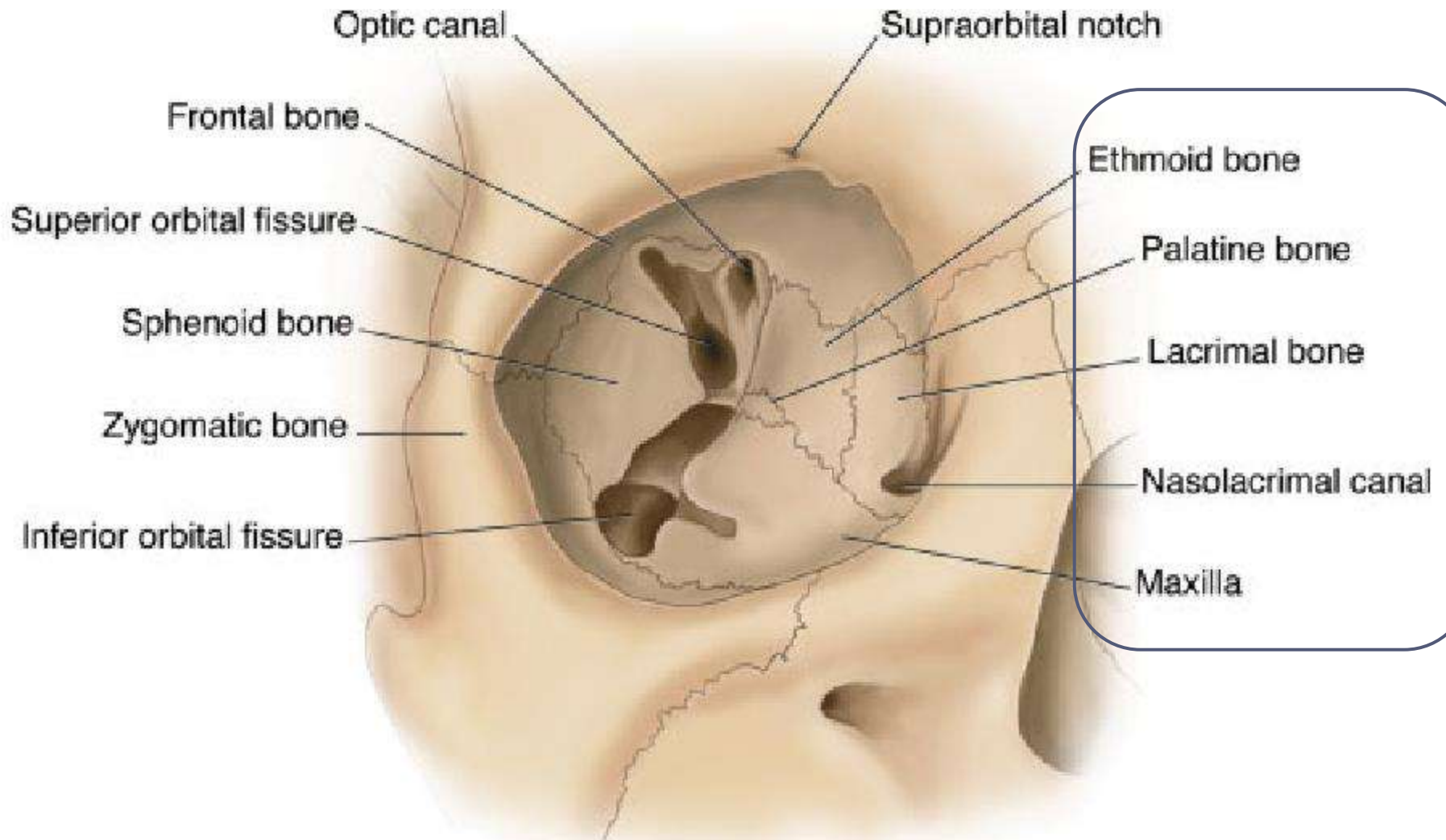


# Orbit and Contents

---



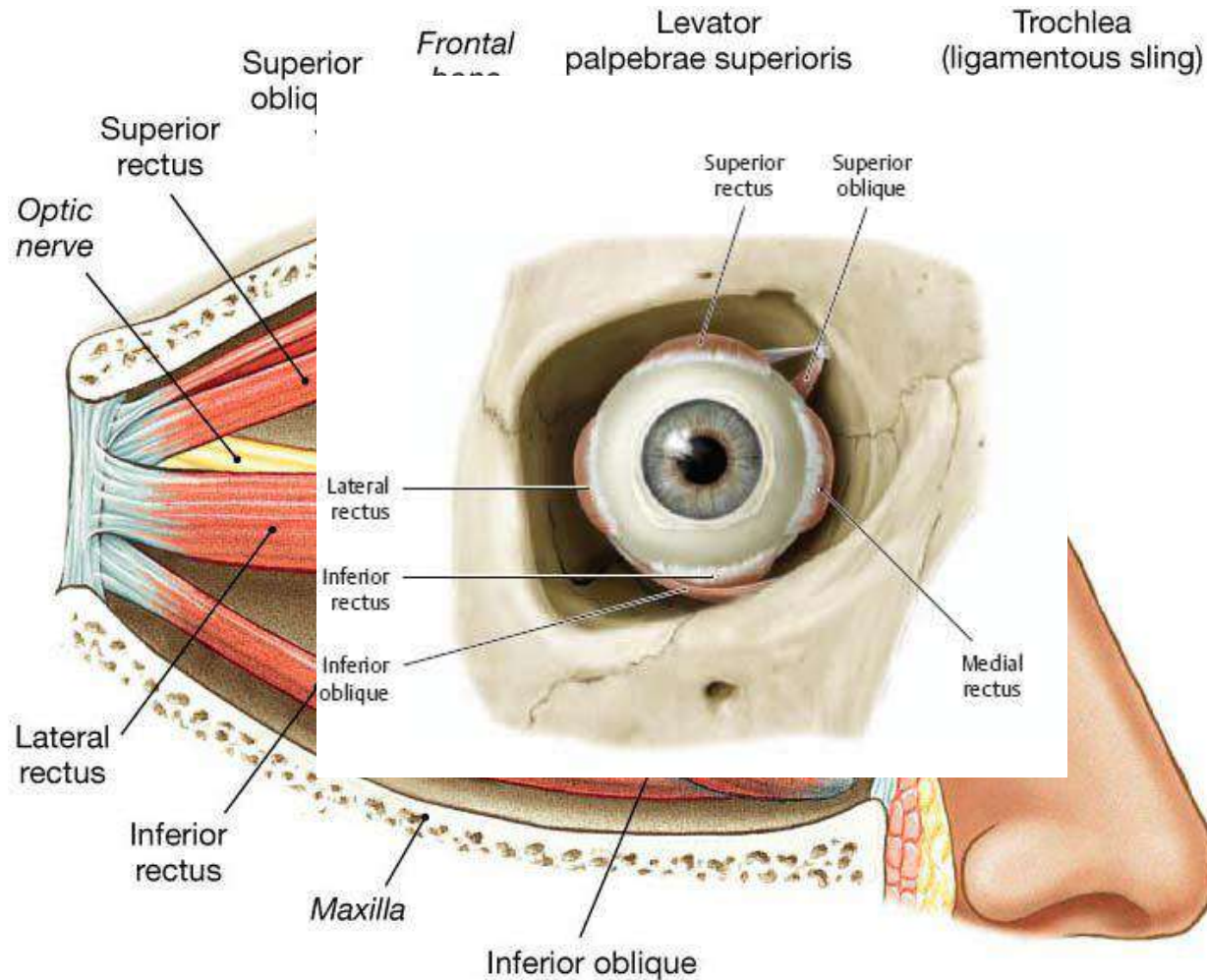




Ni-ka Ford ©2018 Mount Sinai Health System



# Extraocular muscles:

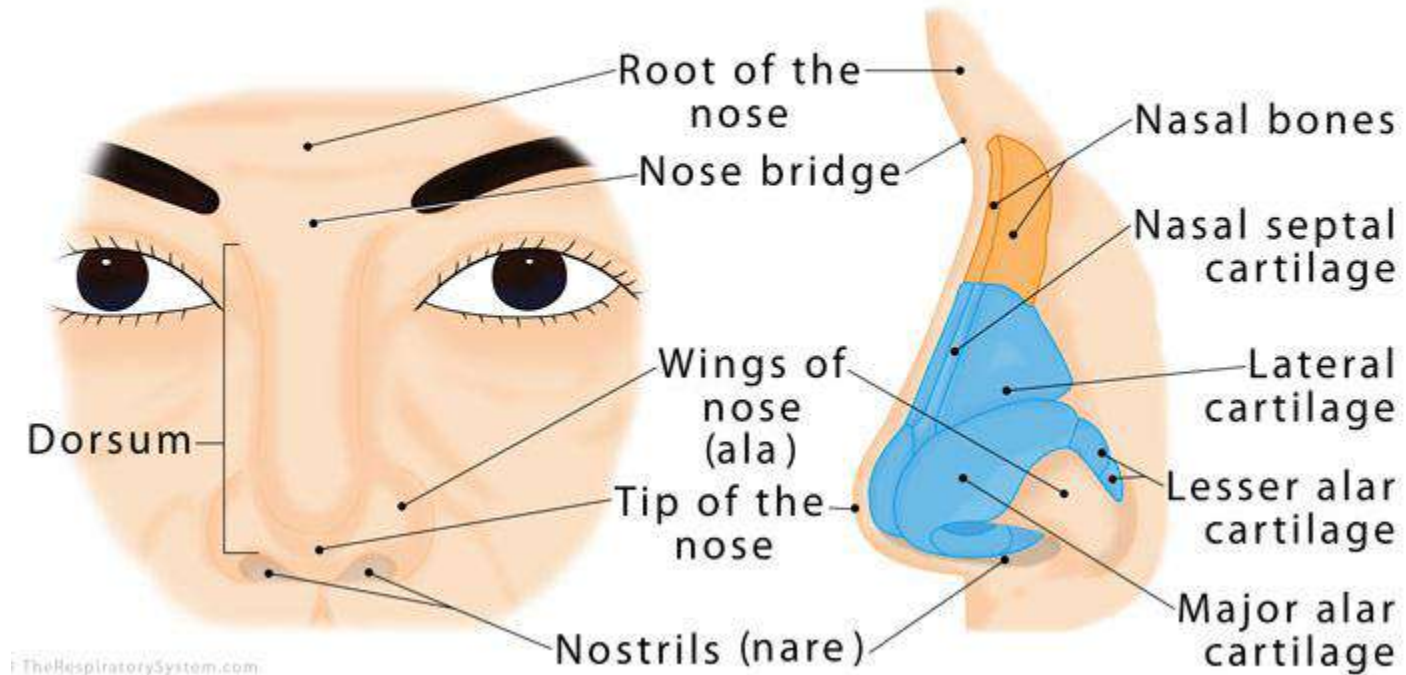


**(a) Lateral surface, right eye**

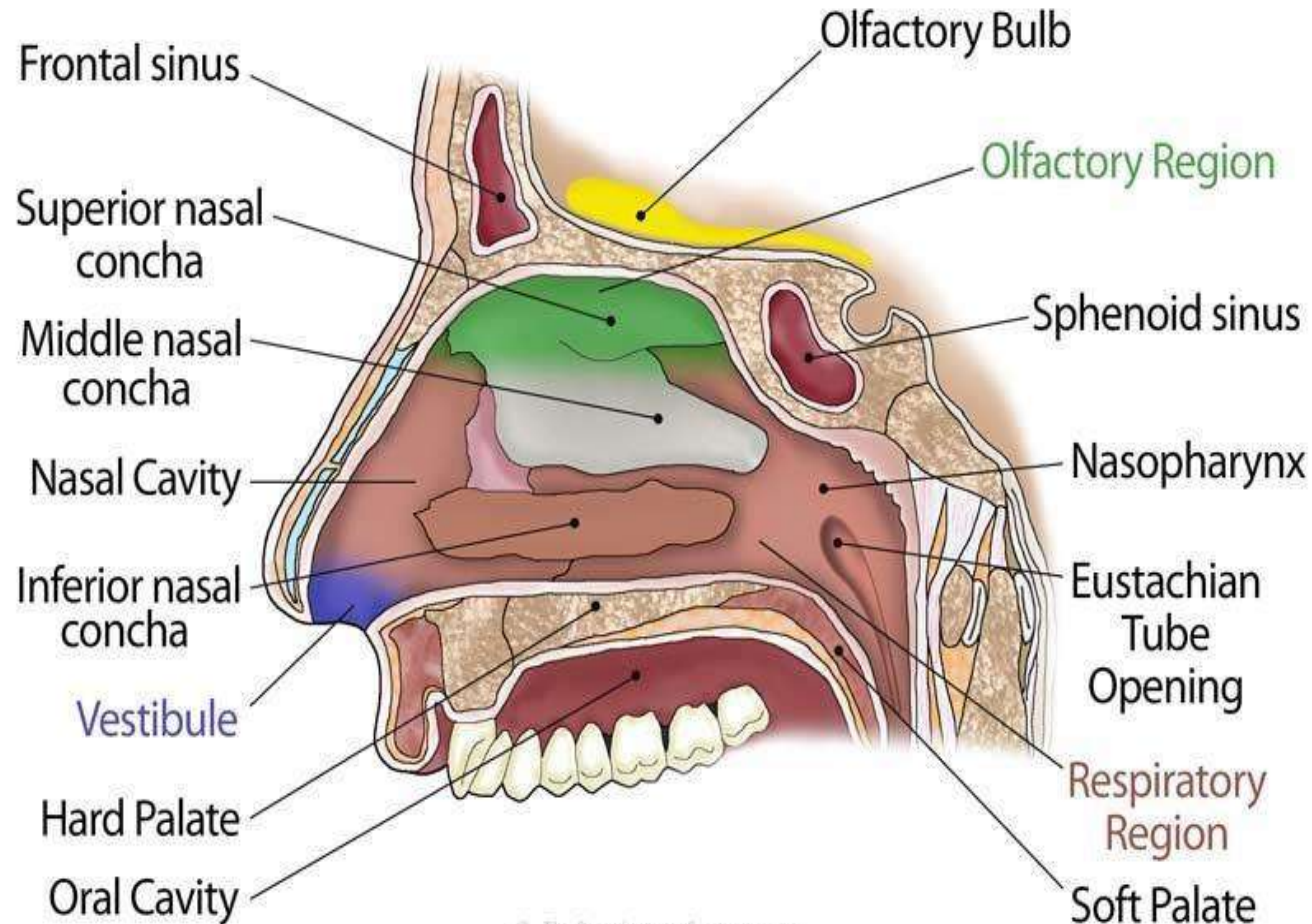
# Nose and Nasal Cavities

---

## External Nose



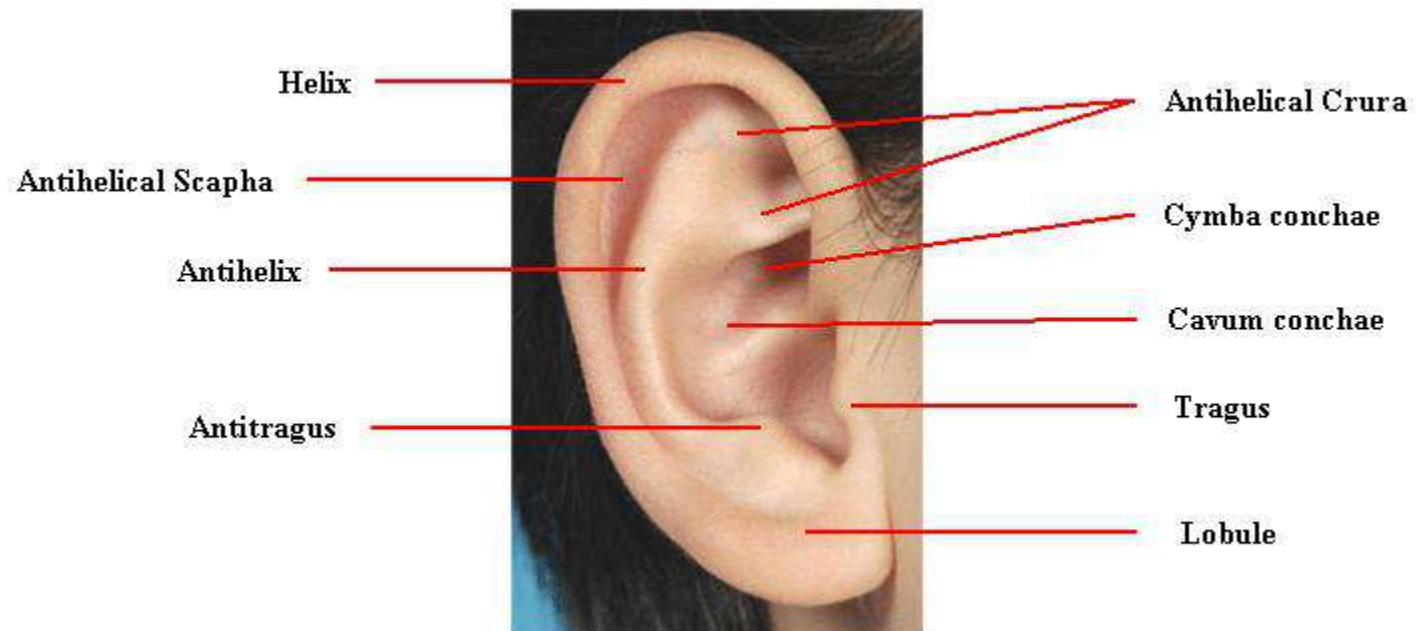
# Nasal Cavity





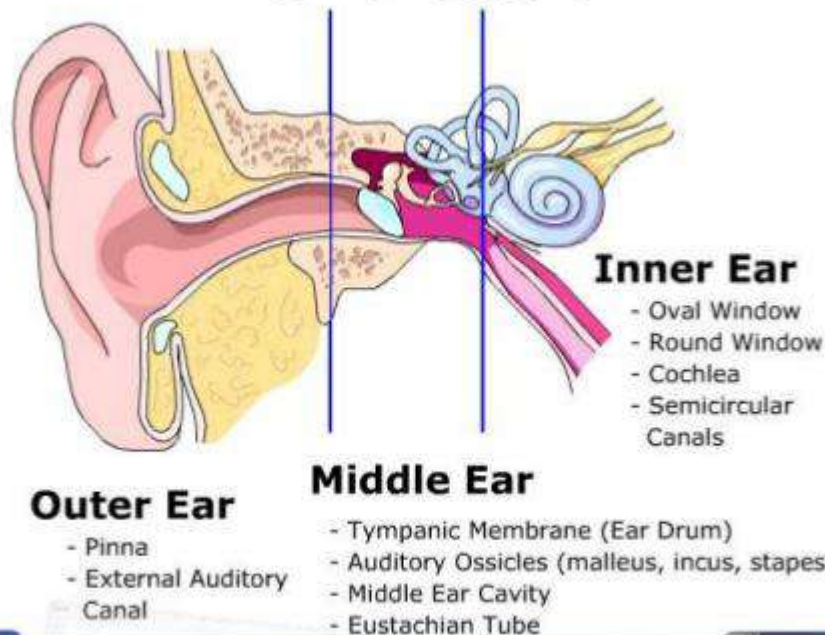
# The ear

---

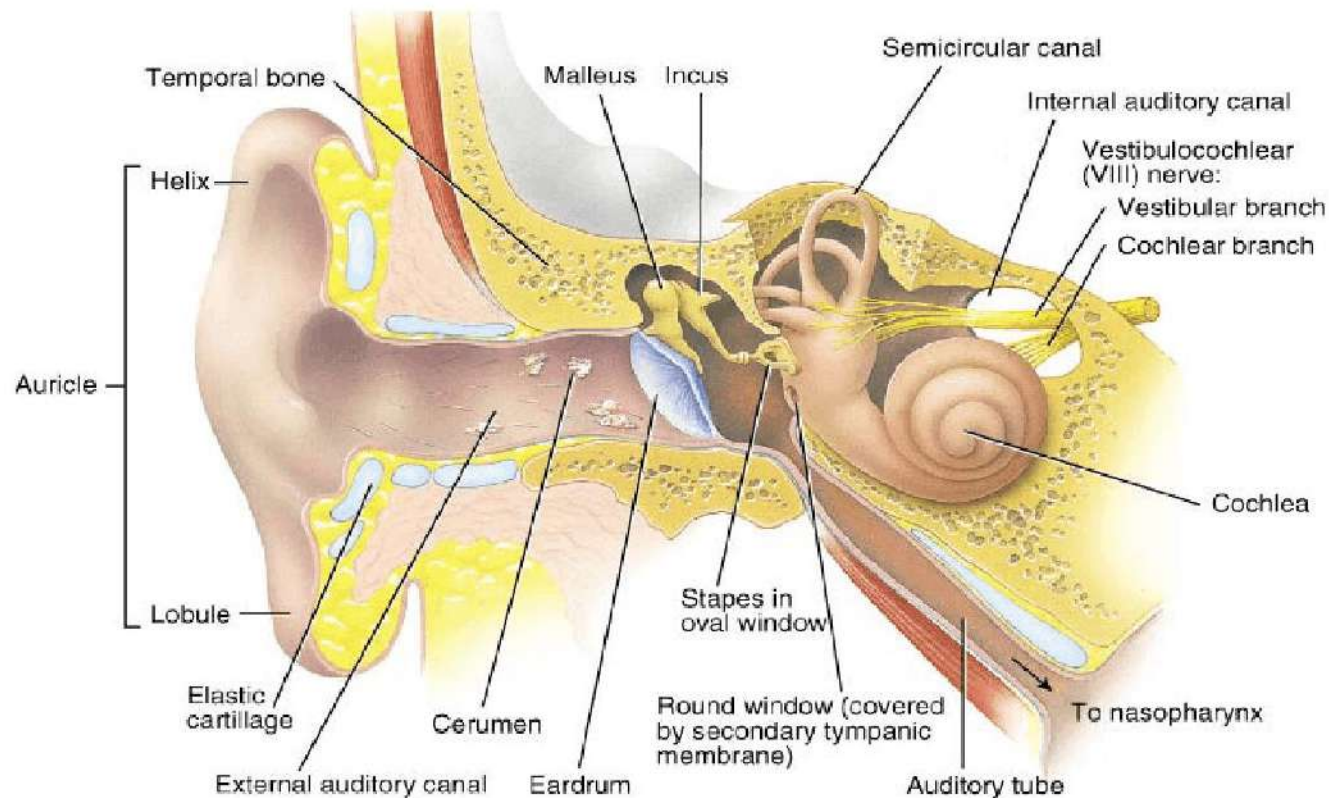


# Anatomy of the Ear

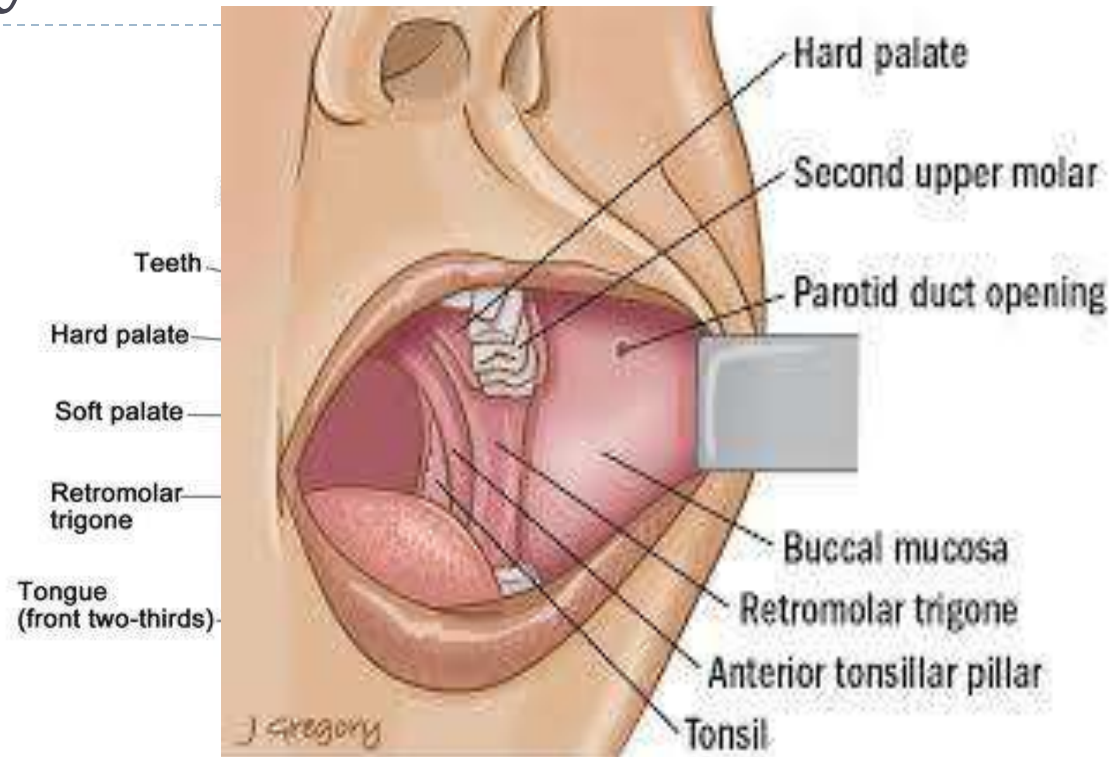
## Three Main Sections



# Anatomy of the Ear Region



# Oral cavity

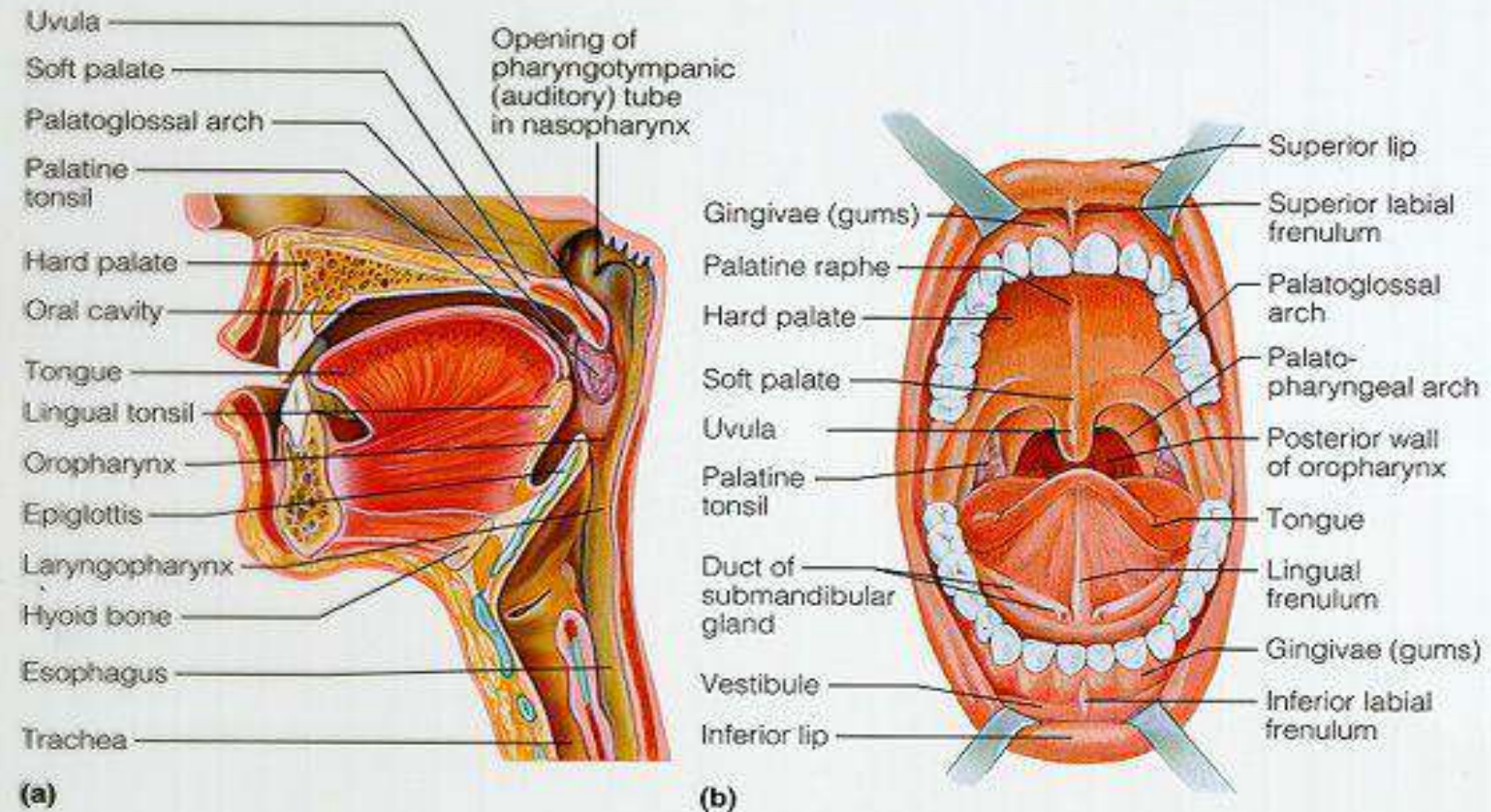


© 2012 Teresa Winslow LLC  
U.S. Govt. has certain rights

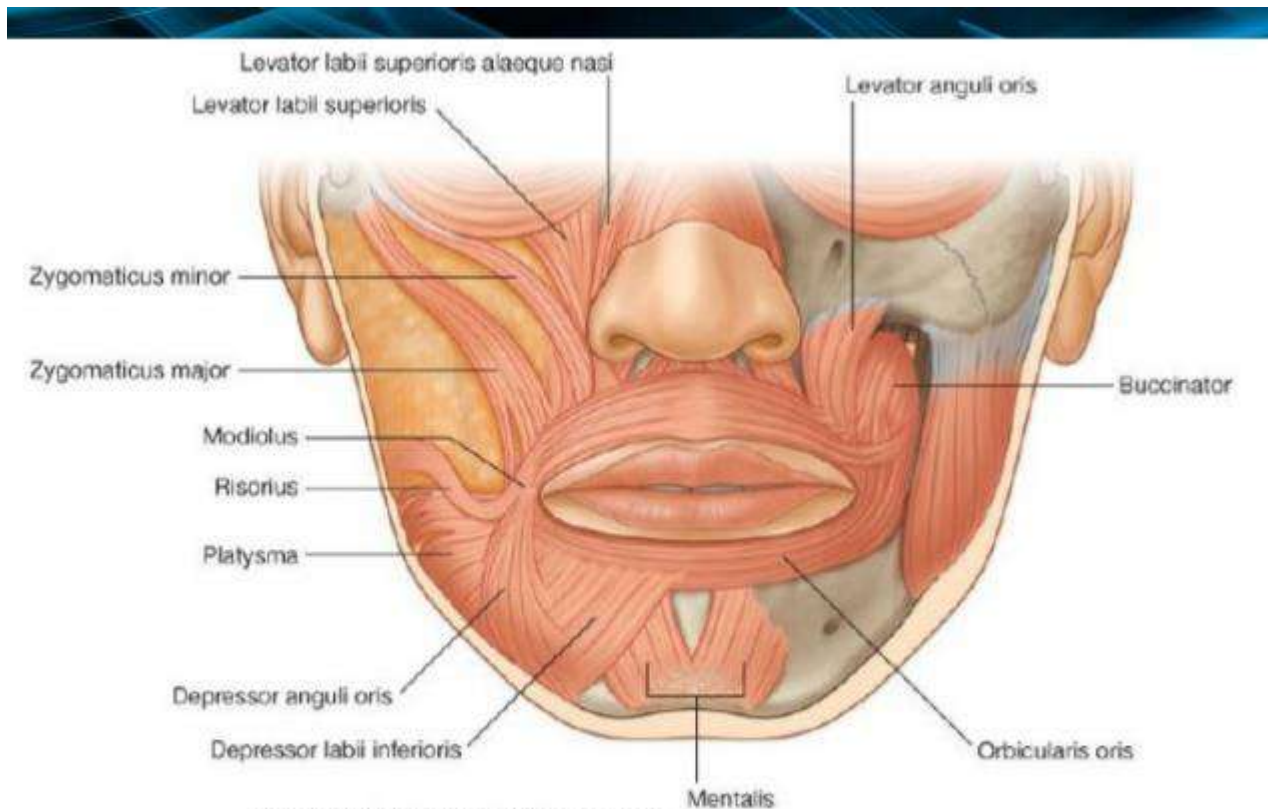


# Oral cavity

Anatomy of the oral cavity (mouth) (Figure 24.7)



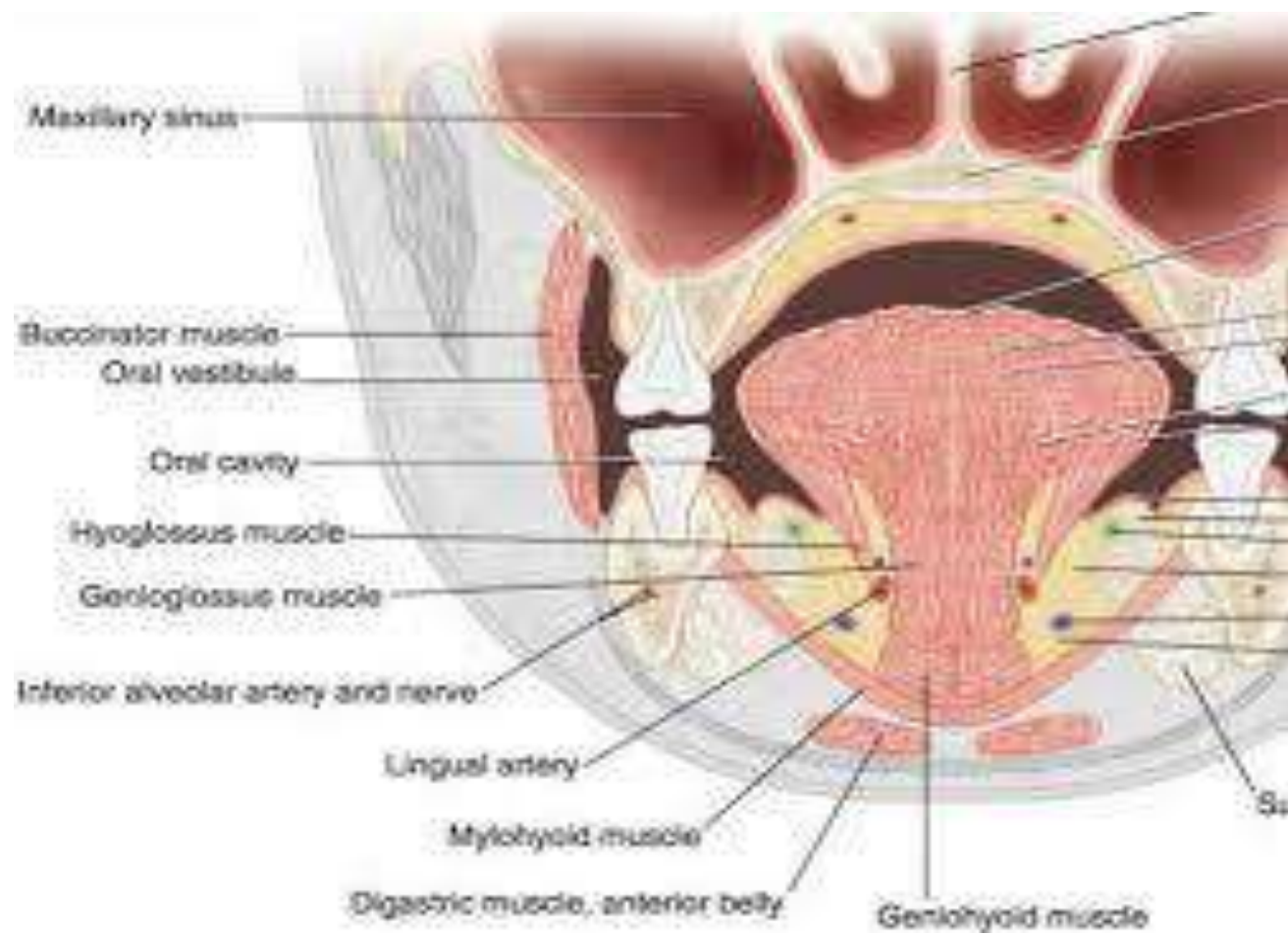




Drake: Gray's Anatomy for Students, 2nd Edition.

Copyright © 2009 by Churchill Livingstone, an imprint of Elsevier, Inc. All rights reserved.

Figure 8.53 Oral group of facial muscles.



---

## The action of the muscles of mastication:

- ✓ Temporalis, masseter, and medial pterygoid muscles.  
elevation of the mandible
- ✓ Depression, or jaw opening, involves the hyoid-fixated muscles, i.e., geniohyoid, mylohyoid, and anterior belly of the digastric, as well as the two-headed lateral pterygoid muscle.
- ✓ lateral pterygoid would deviate the lower jaw to the opposite side and forward, as well as depress it.



---

# Anatomy of face in relation to maxillofacial prosthesis

Lect. Hussein T.Abed

30\12\2020



---

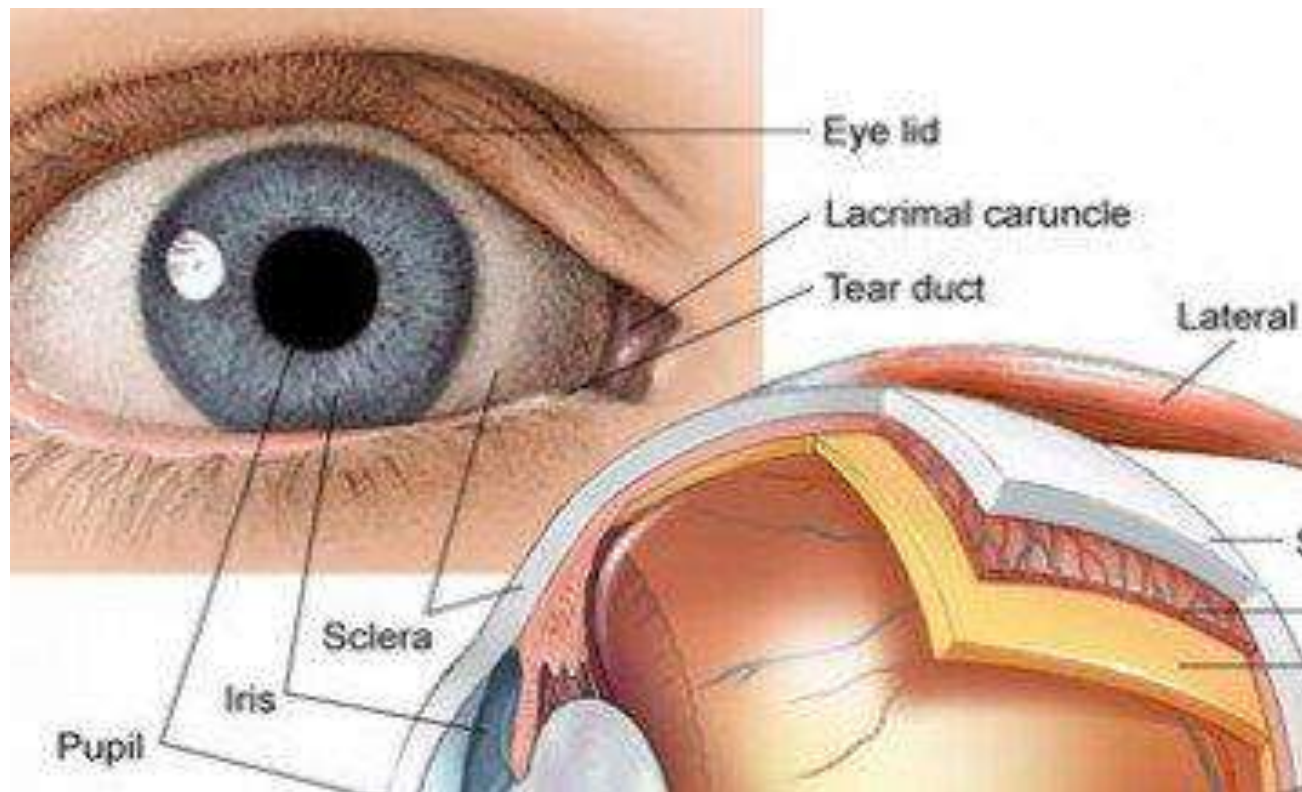
The anatomy of the facial orifices has great relevance for the maxillofacial prosthodontist. It includes **bony orbit**, the **bony nasal opening** (piriform opening), the **oral opening** and maxillomandibular apparatus, and the **external auditory meatus**, as well as the collective and appended anatomy of these facial features.

---

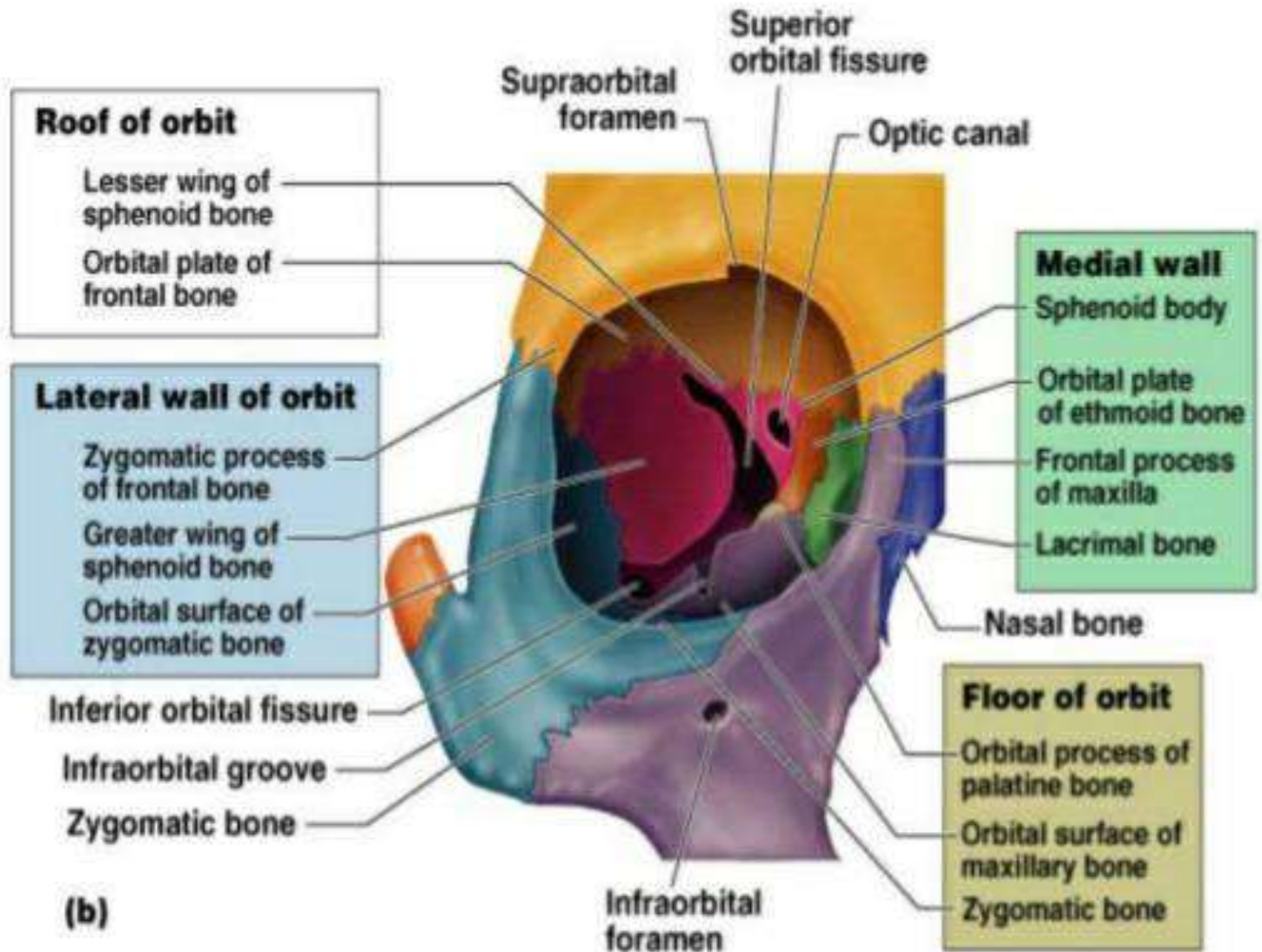


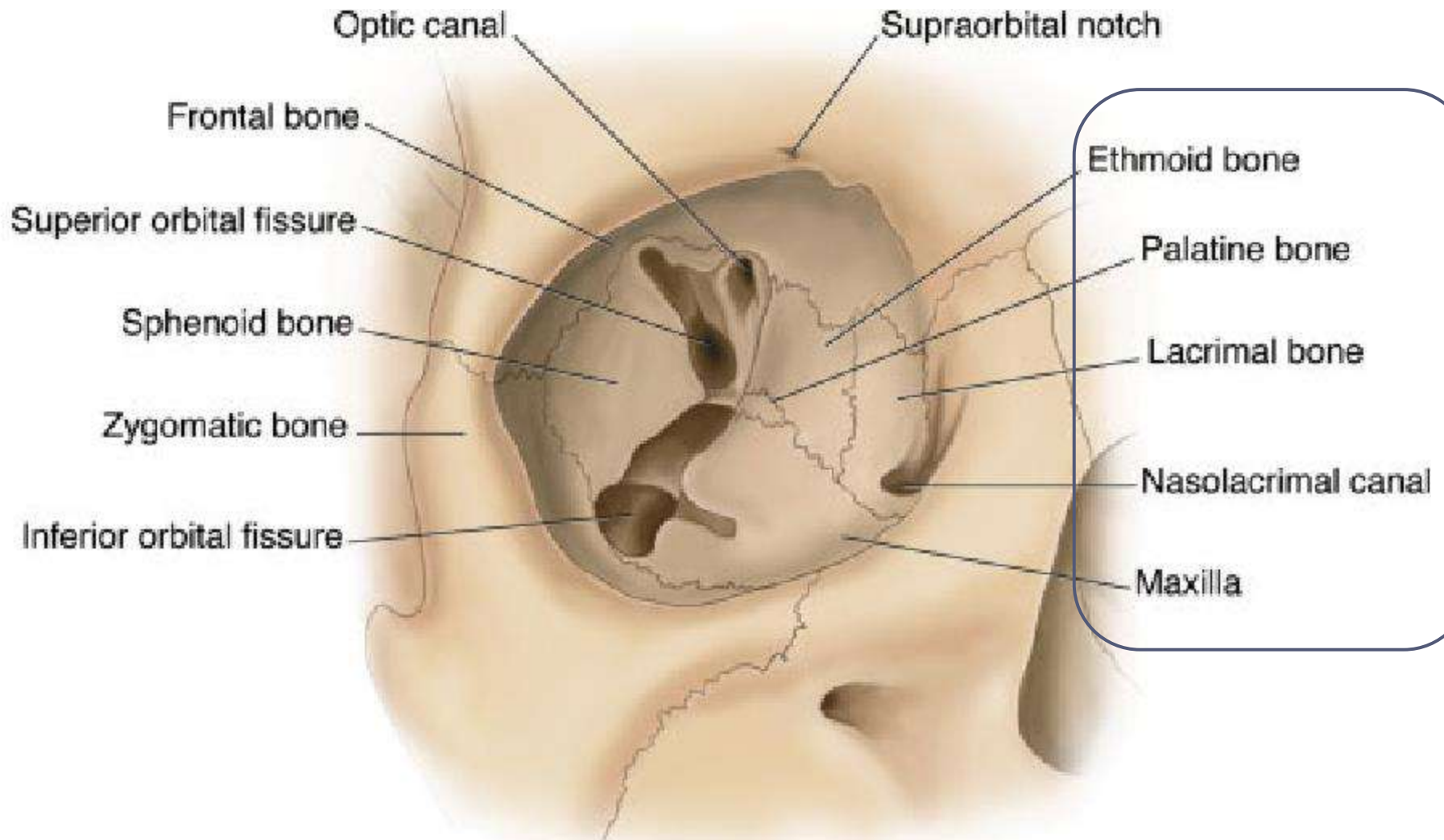
# Orbit and Contents

---



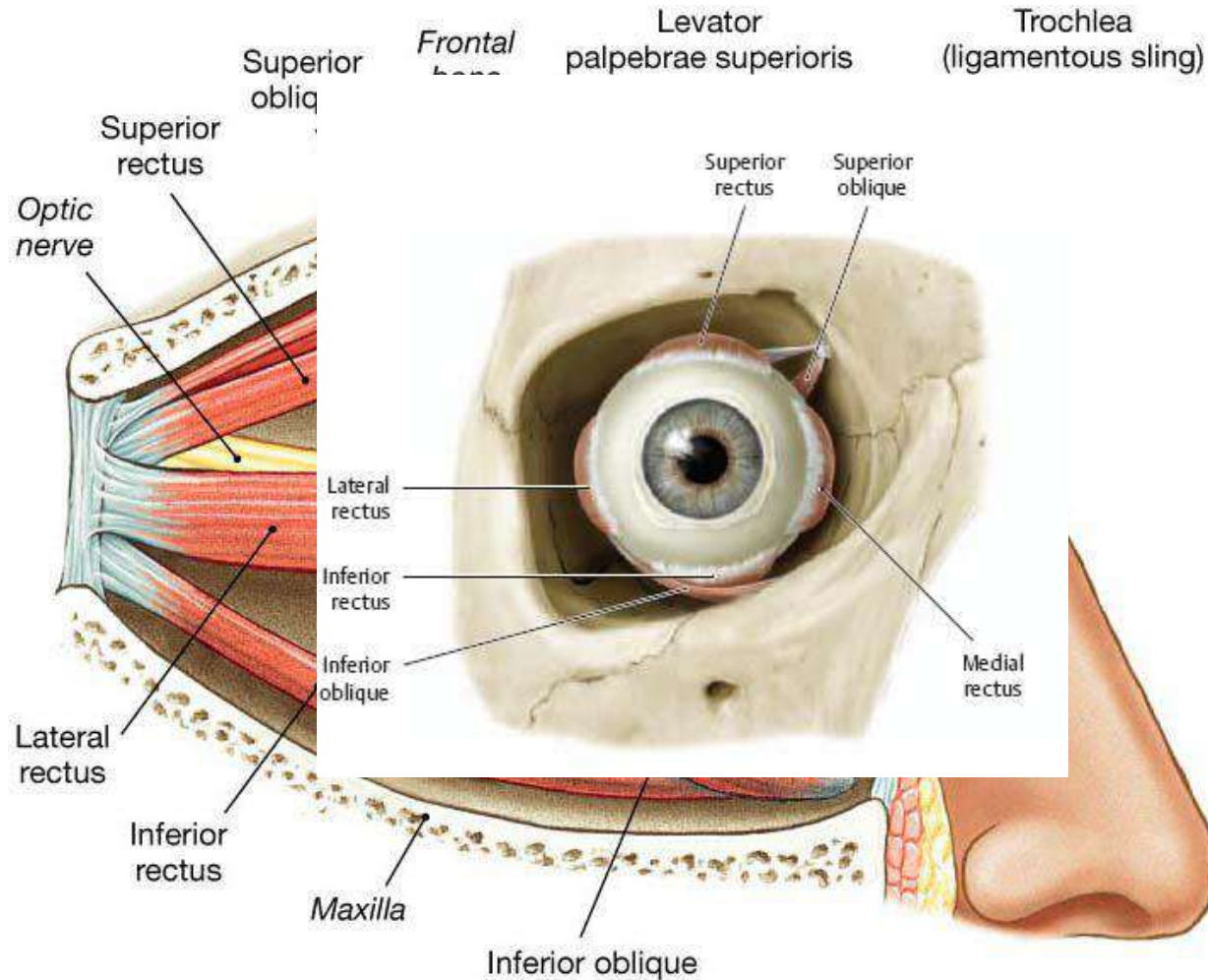






Ni-ka Ford ©2018 Mount Sinai Health System

# Extraocular muscles:

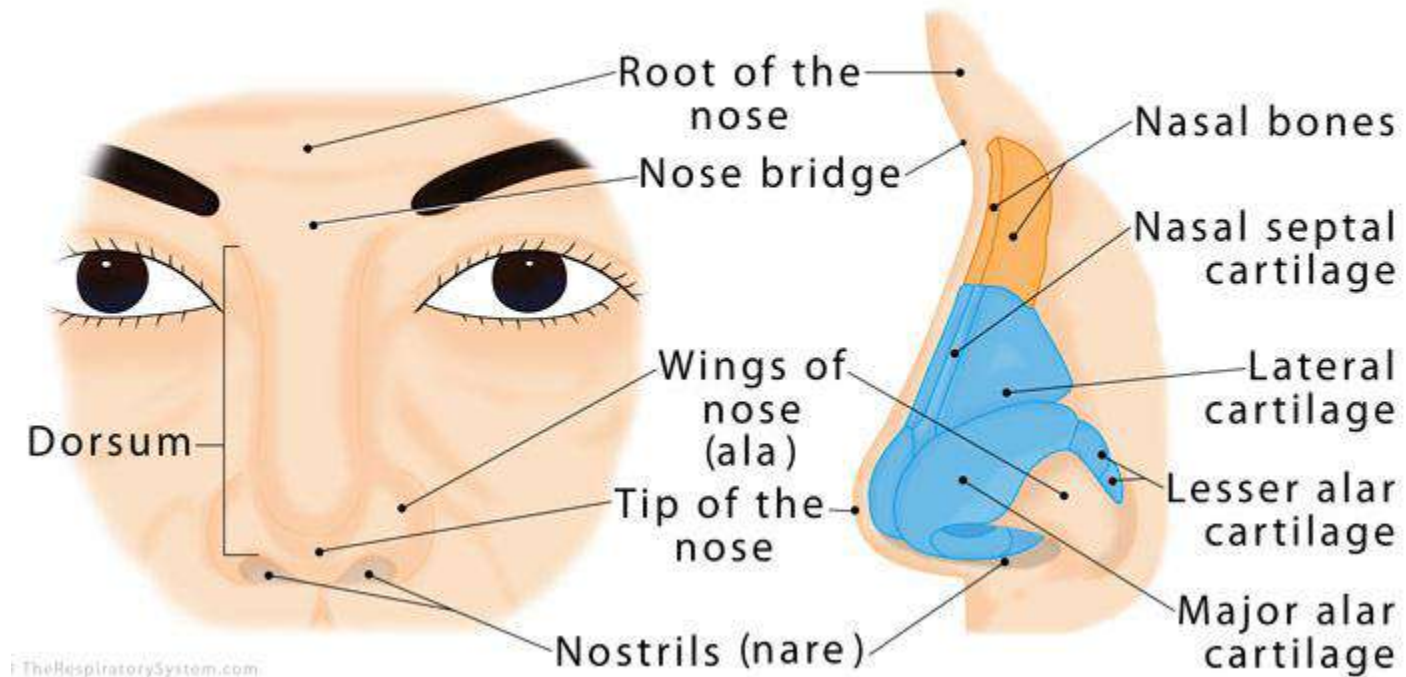


**(a) Lateral surface, right eye**

# Nose and Nasal Cavities

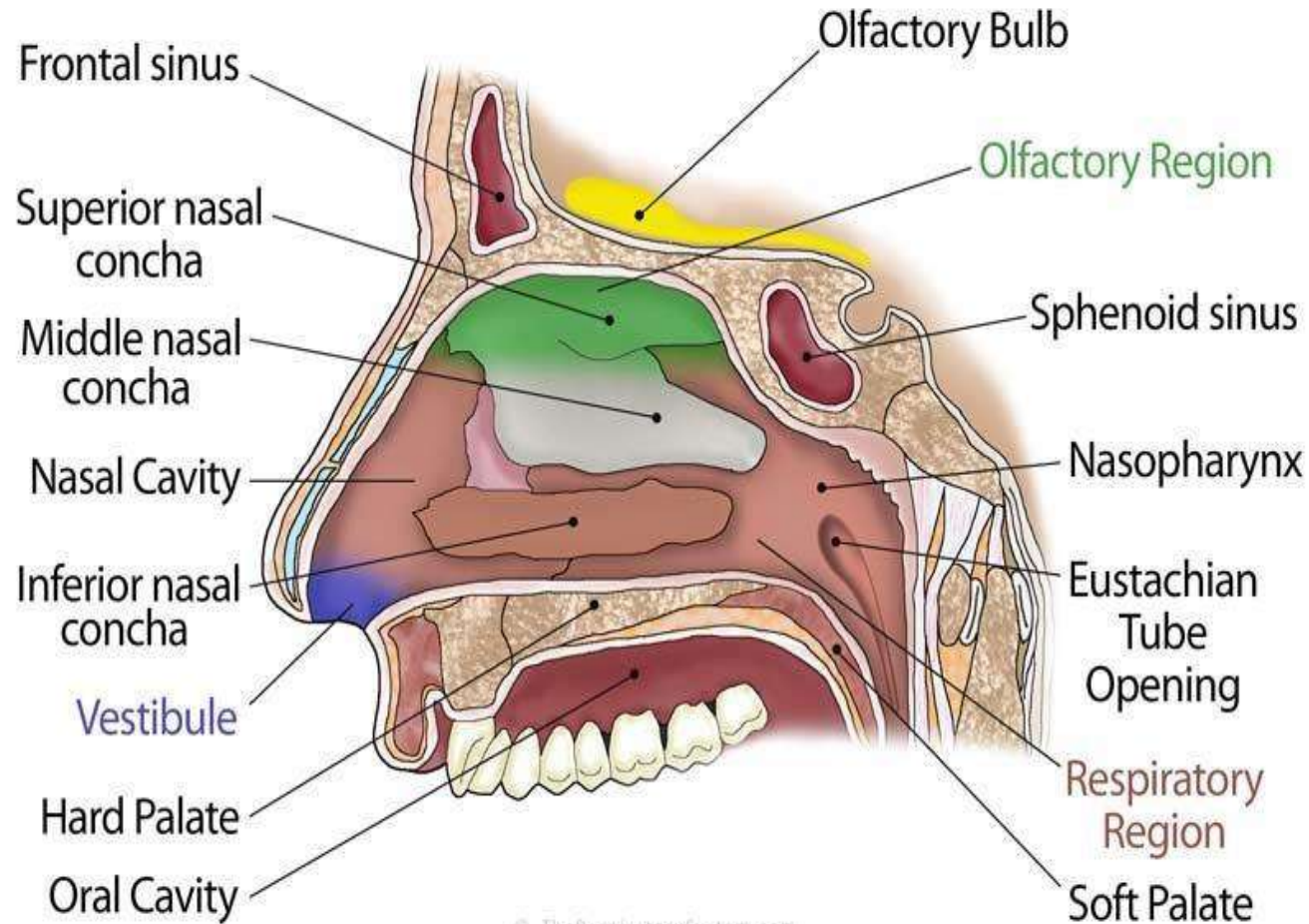
---

## External Nose





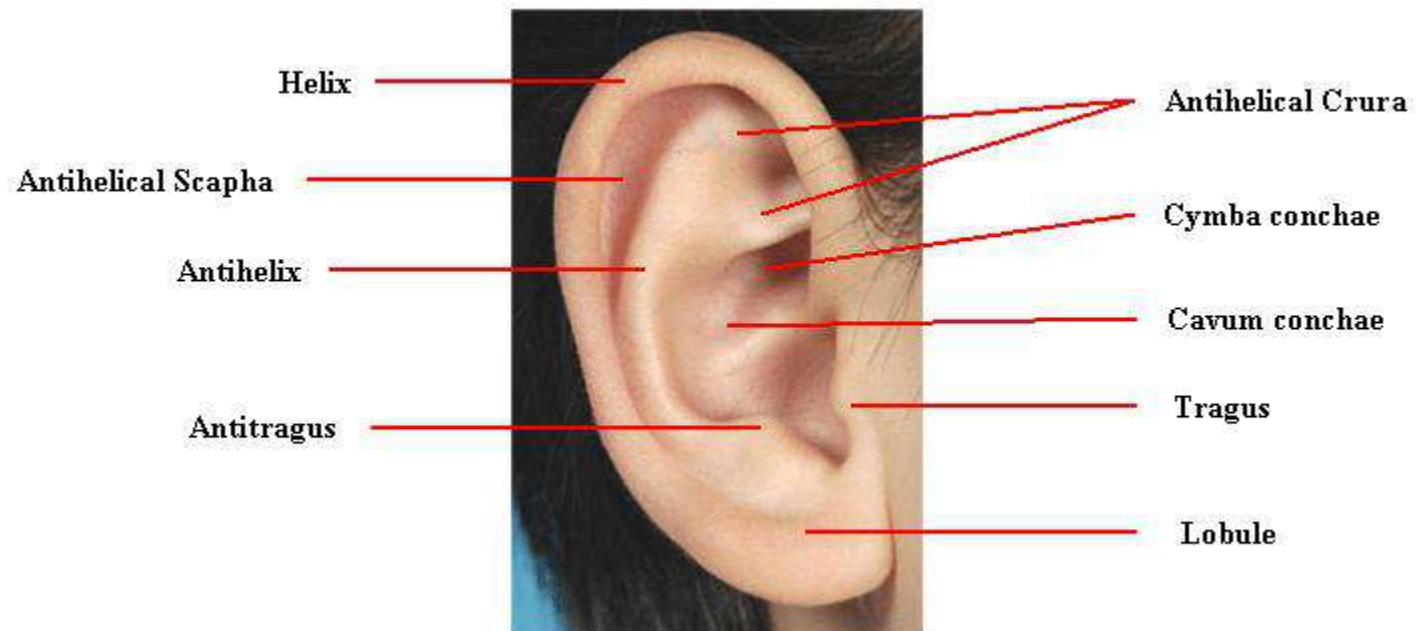
# Nasal Cavity





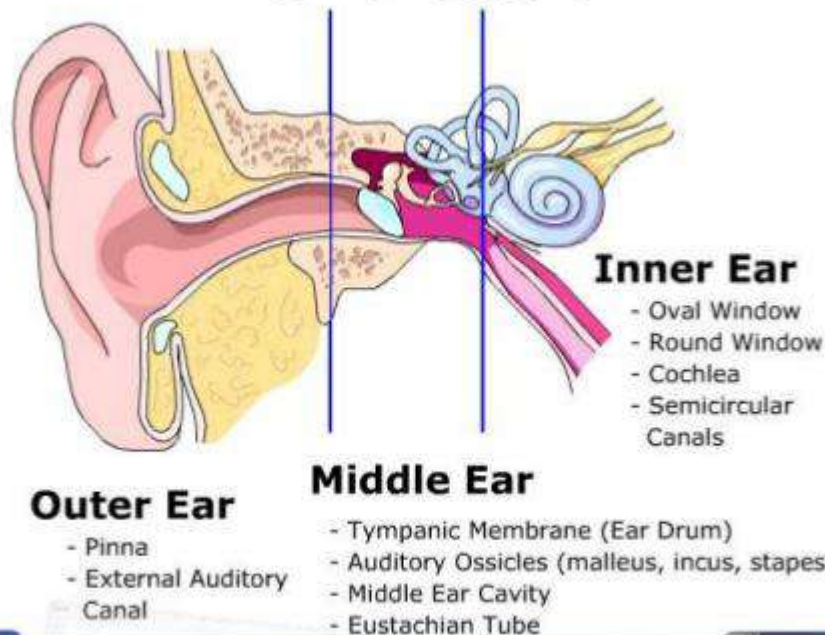
# The ear

---

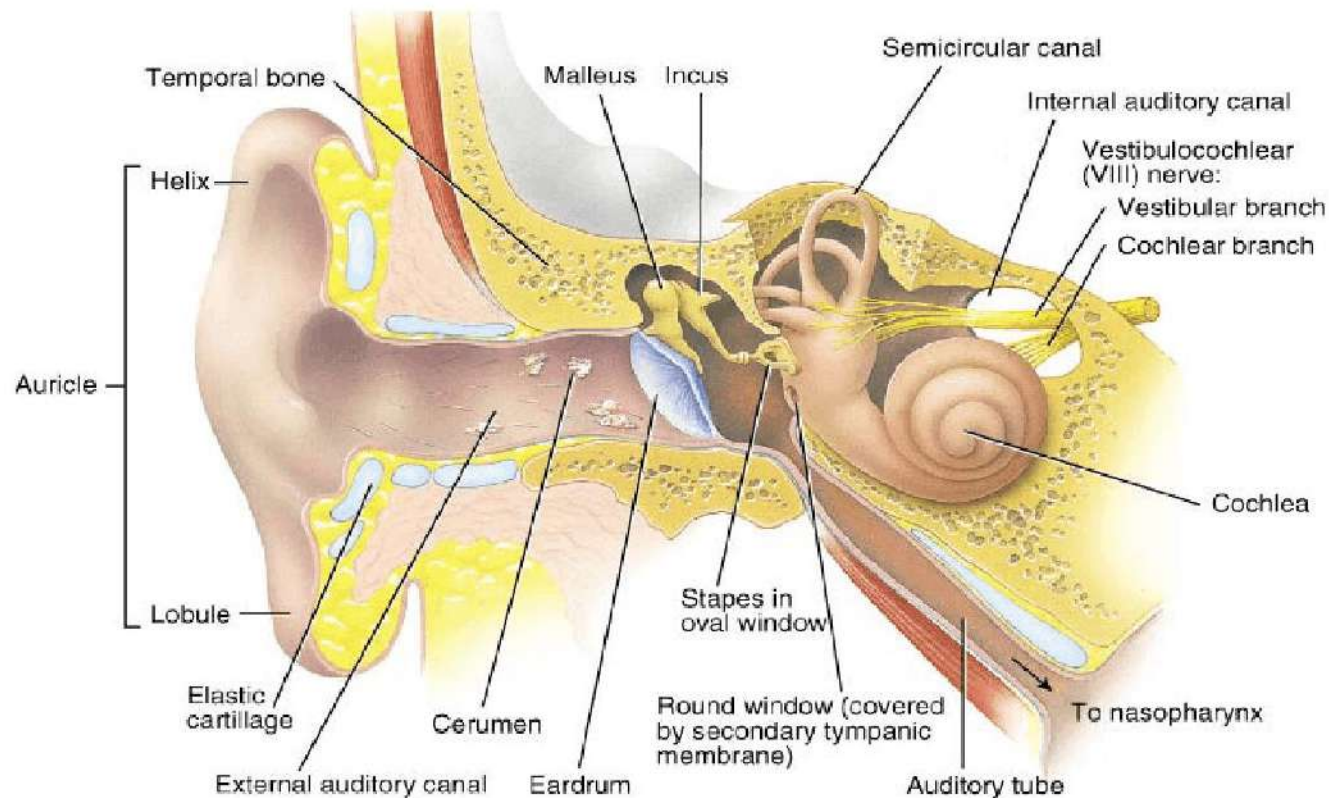


# Anatomy of the Ear

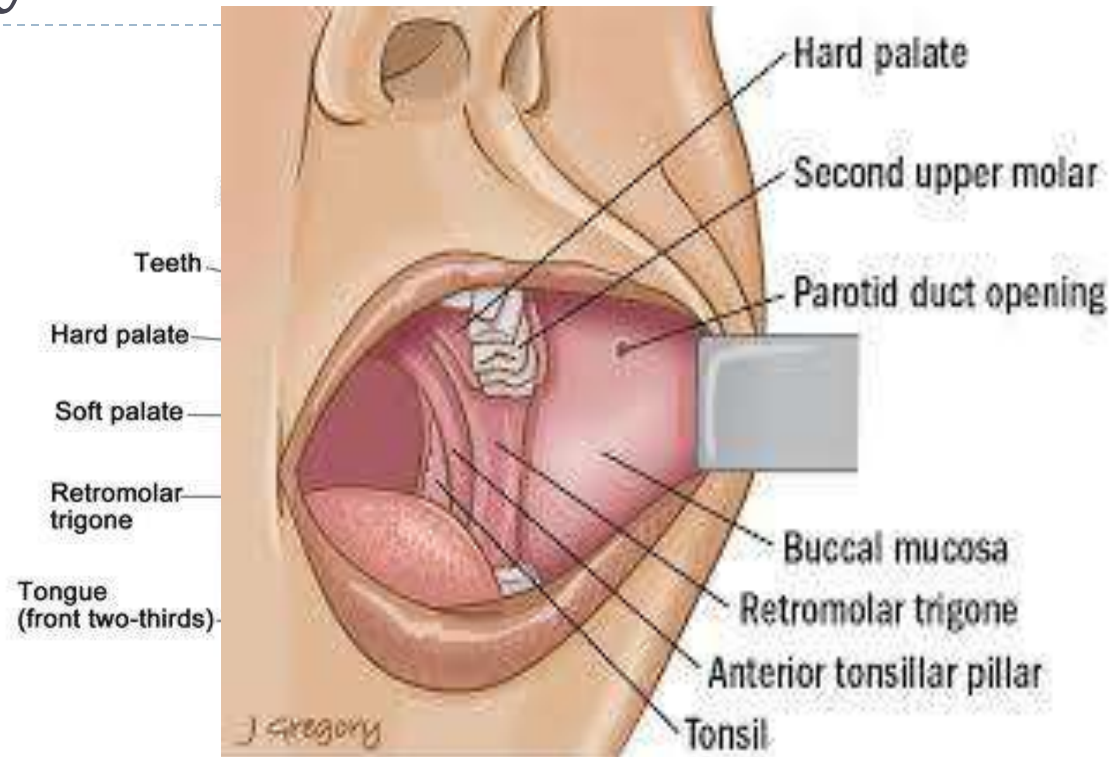
## Three Main Sections



# Anatomy of the Ear Region



# Oral cavity

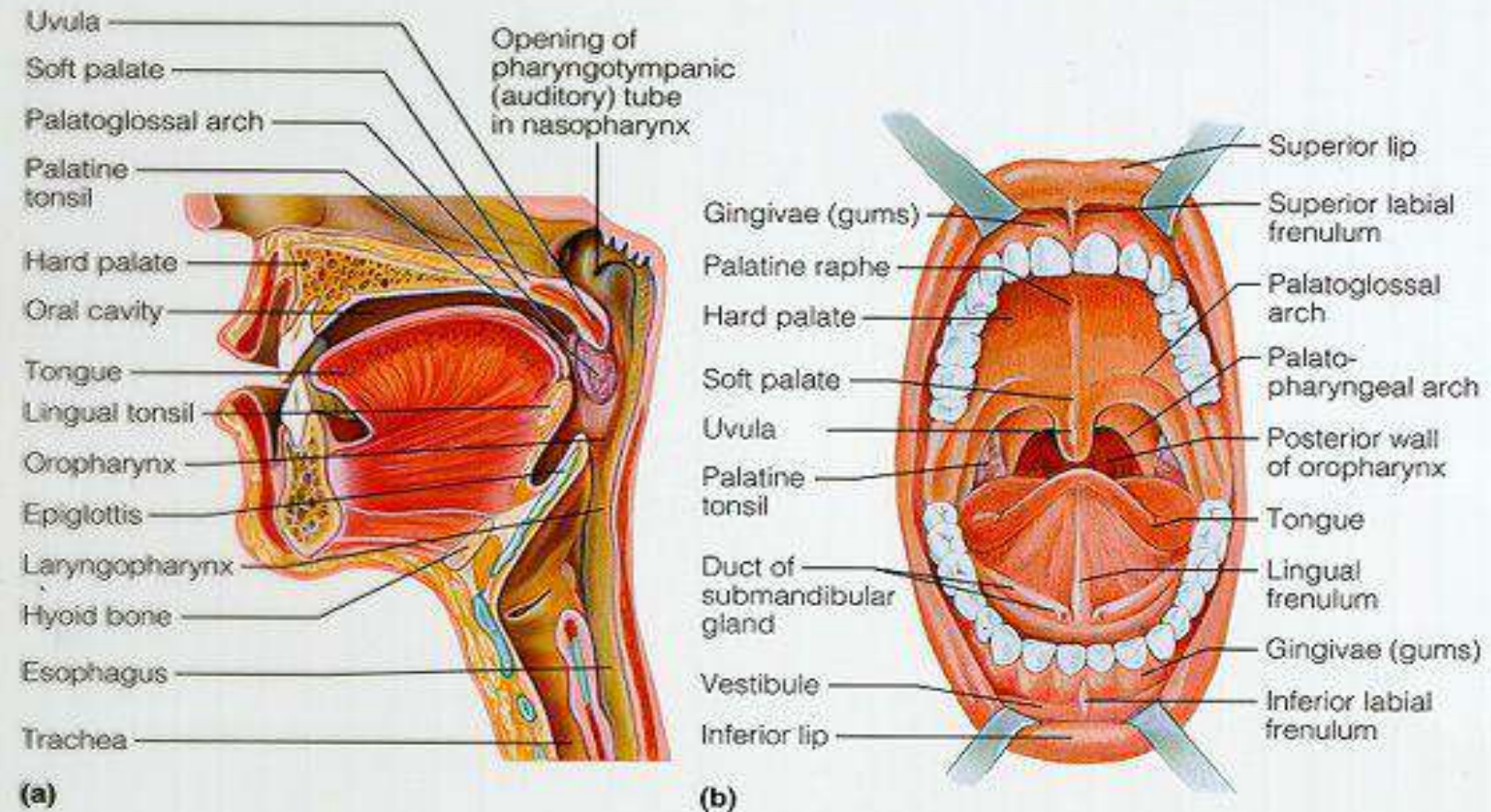


© 2012 Teresa Winslow LLC  
U.S. Govt. has certain rights

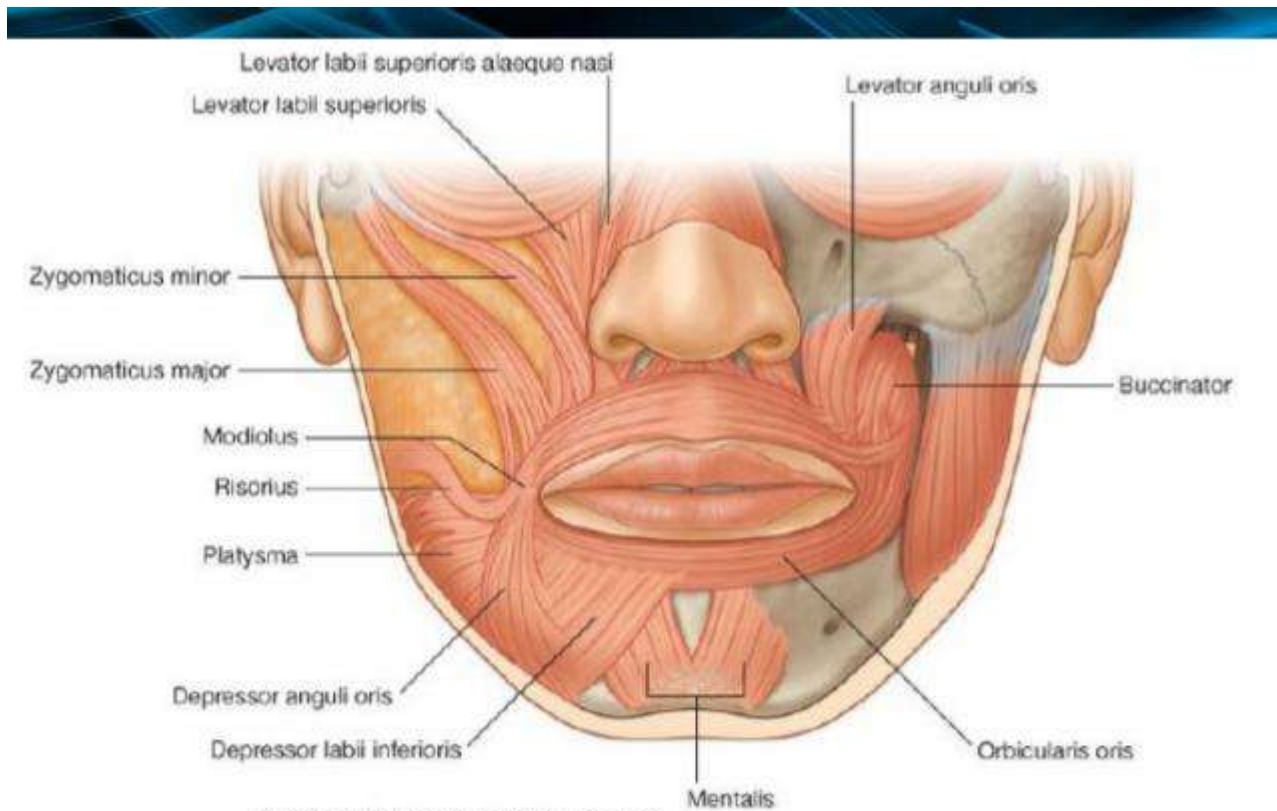


# Oral cavity

Anatomy of the oral cavity (mouth) (Figure 24.7)



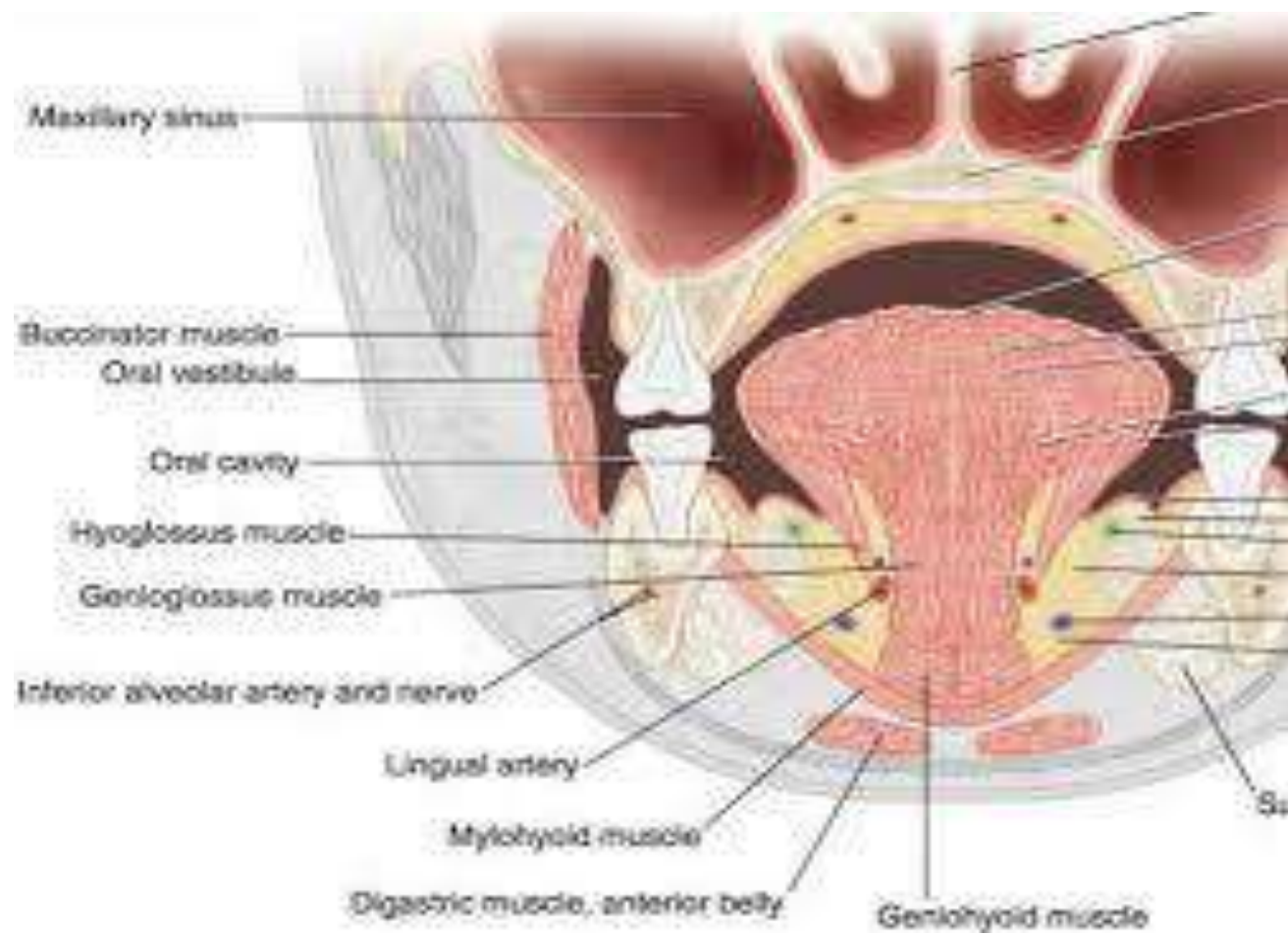




Drake: Gray's Anatomy for Students, 2nd Edition.

Copyright © 2009 by Churchill Livingstone, an imprint of Elsevier, Inc. All rights reserved.

Figure 8.53 Oral group of facial muscles.



---

## The action of the muscles of mastication:

- ✓ Temporalis, masseter, and medial pterygoid muscles.  
elevation of the mandible
- ✓ Depression, or jaw opening, involves the hyoid-fixated muscles, i.e., geniohyoid, mylohyoid, and anterior belly of the digastric, as well as the two-headed lateral pterygoid muscle.
- ✓ lateral pterygoid would deviate the lower jaw to the opposite side and forward, as well as depress it.





Lect. Hussein T. Abed

13.1.2021



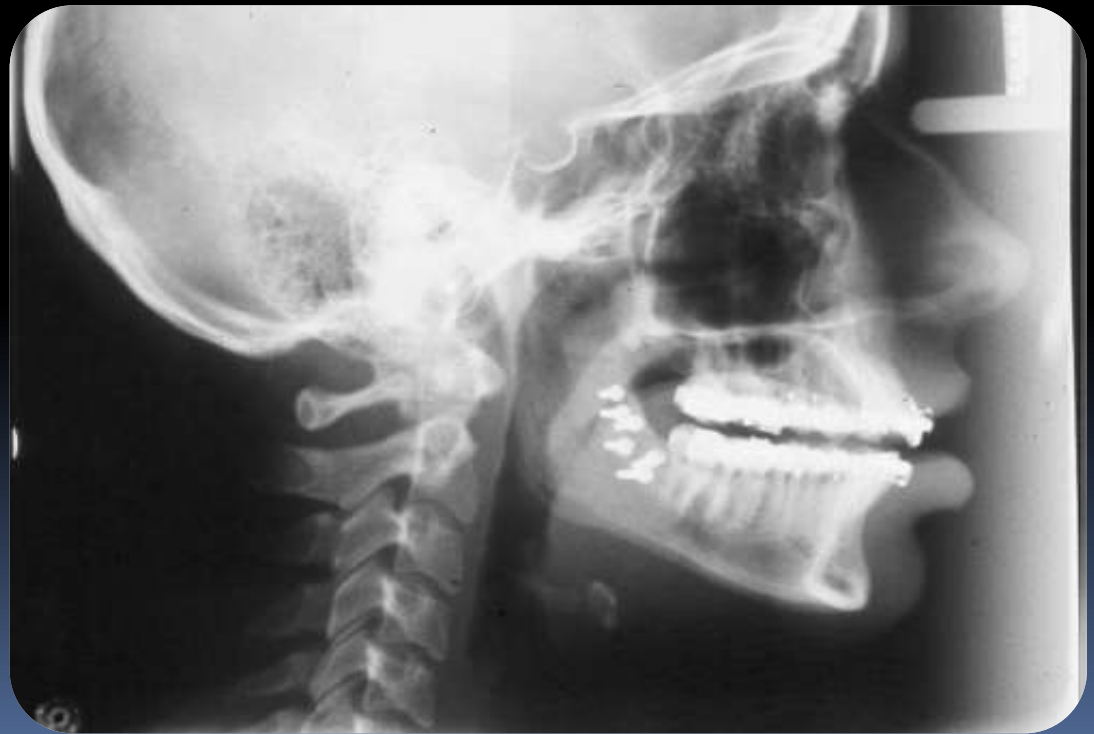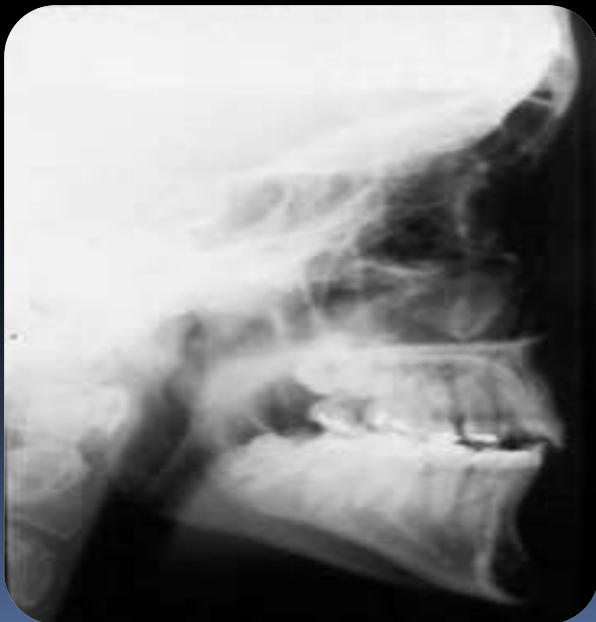# FACIAL MEASUREMENTS : X-RAY AND SLIDES

# How you evaluate a face

Soft tissue

Hard tissue

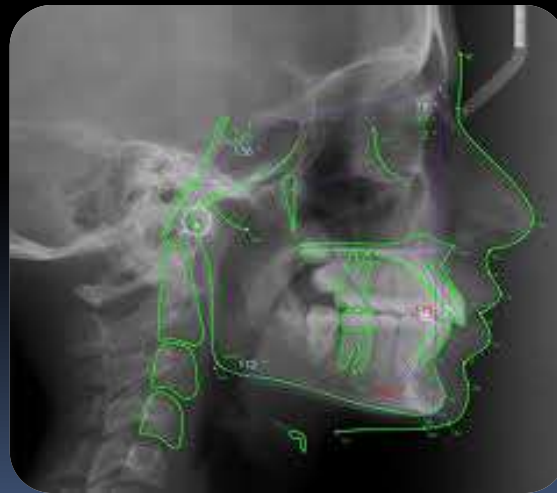
Dental tissue



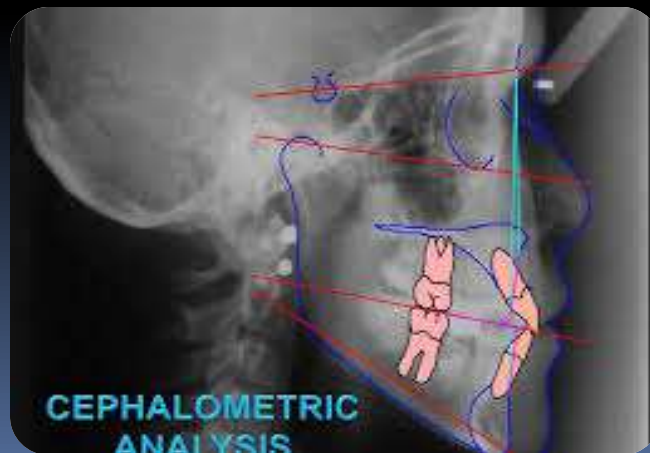


# Importance

Many of the difficulties experienced in the treatment can be attributed directly to the extent of the **excessive disharmony** of the skeletal pattern.



Simply calling a dimension 'large' or 'small' or 'good' or 'bad' does not mean the same to everyone. In order to be critical or descriptive it is more useful to express dimensions in terms of angles or linear measurements.

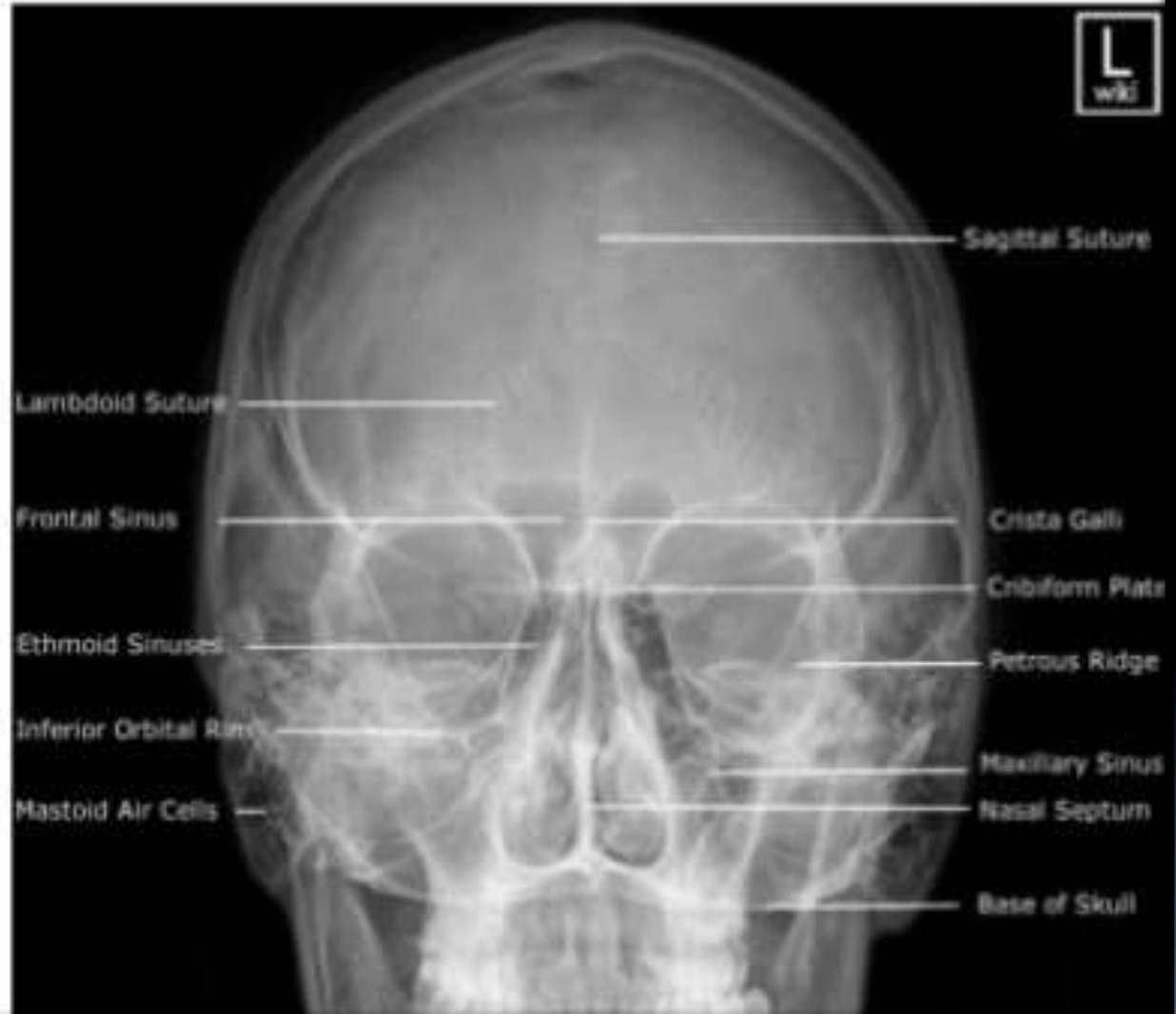



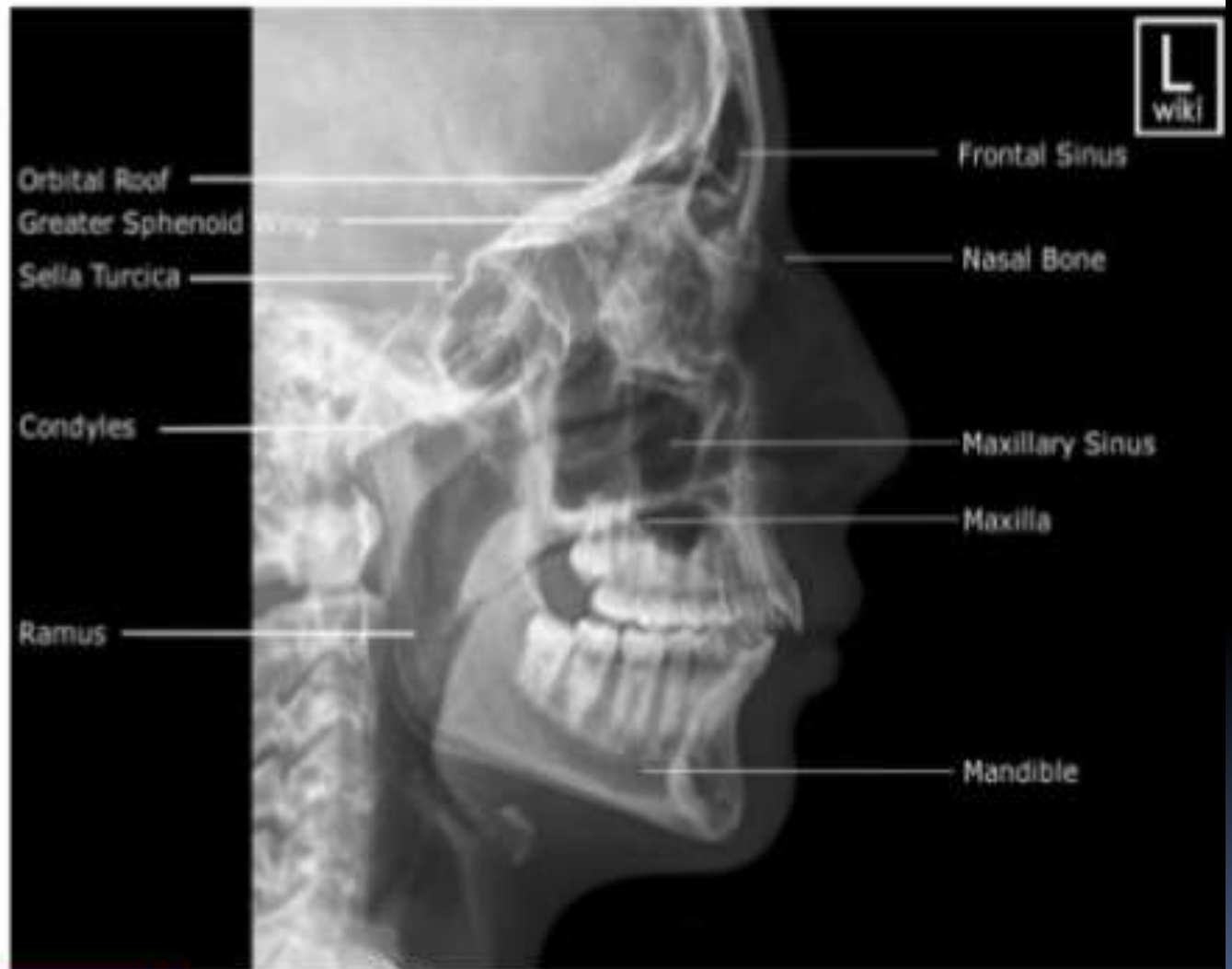
# Cephalometric Evaluation

- Identification of **anatomic landmarks**
- Landmarks: **stable** reference structures maxillary and mandibular skeletal and dental
- Graphically **relating** the dento-facial elements to these reference structures
- Angular and or linear **measurements**

## Adult Facial Bones - PA Caldwell

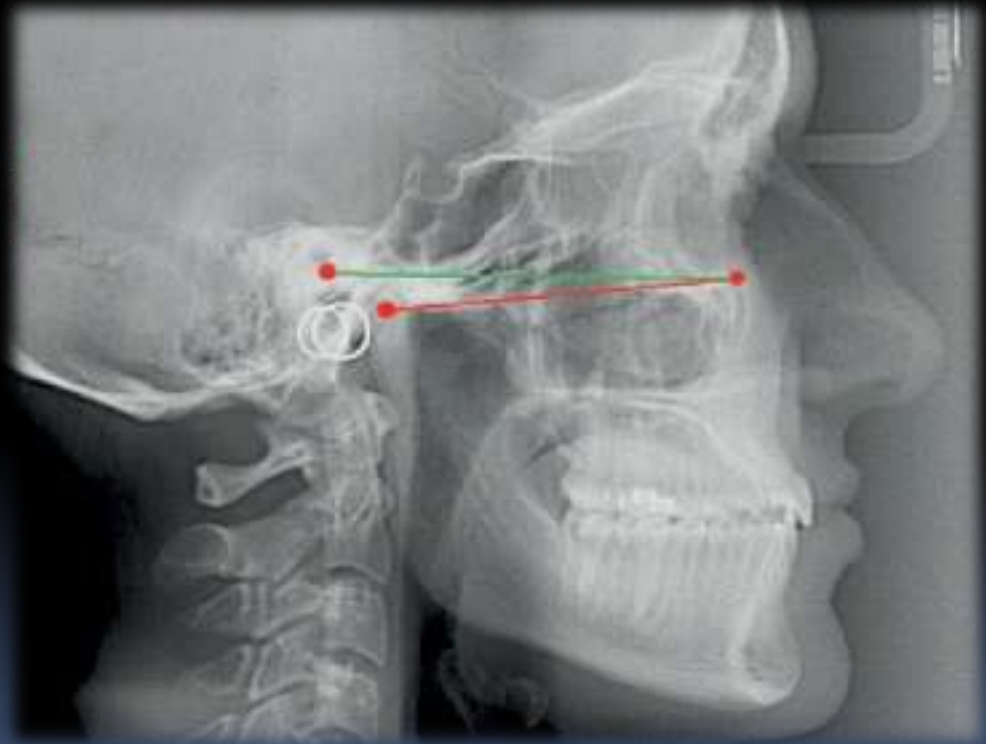
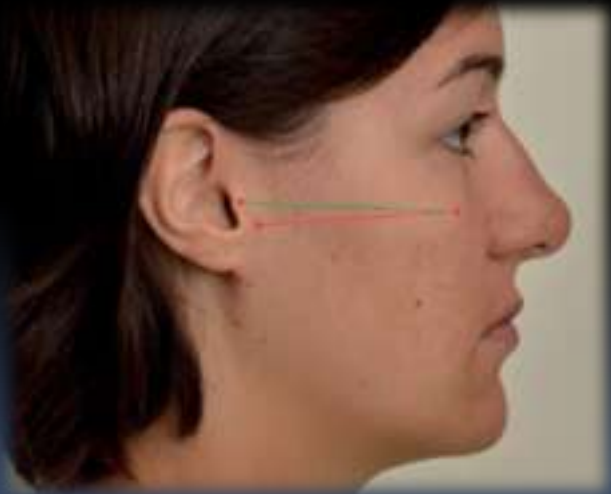


## Adult Facial Bones - Lateral View



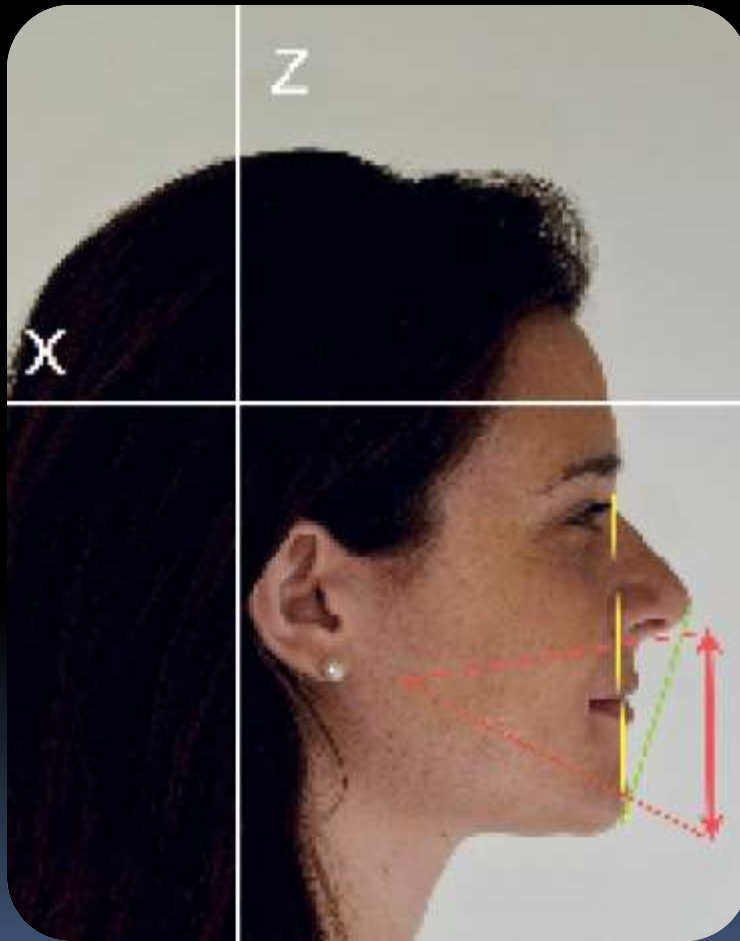


Lateral skull's x-ray: the **red line** indicates the arbitrary axis-orbital plane, whilst the **green line** shows the Frankfurt plane.

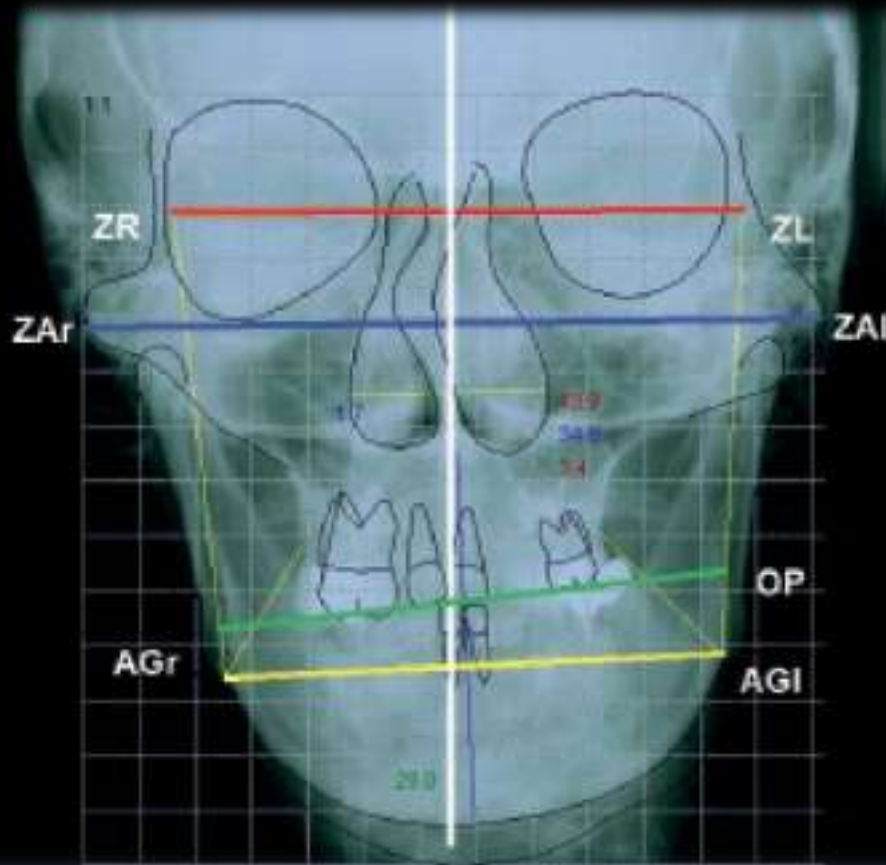




Plans and reference lines of the patient's face on the frontal plane: **Z-axis** that provides the vertical parameter, **Y-axis** that provides transversal parameter.




Maps and reference lines of the patient's face on the sagittal plane: X-axis that identifies the sagittal plane from the front to back (antero-posteriorly), Z-axis that provides the vertical parameter. The red triangle identifies the VD, the green line shows the profile evaluation according to Ricketts, the yellow line indicates the anterior-posterior position of the mandible.



Digital tracing run on  
the AP x-ray :  
red, zygomatic orbital  
line;  
blue, zygomatic line;  
green, occlusal plane;  
yellow, antegonial  
line.

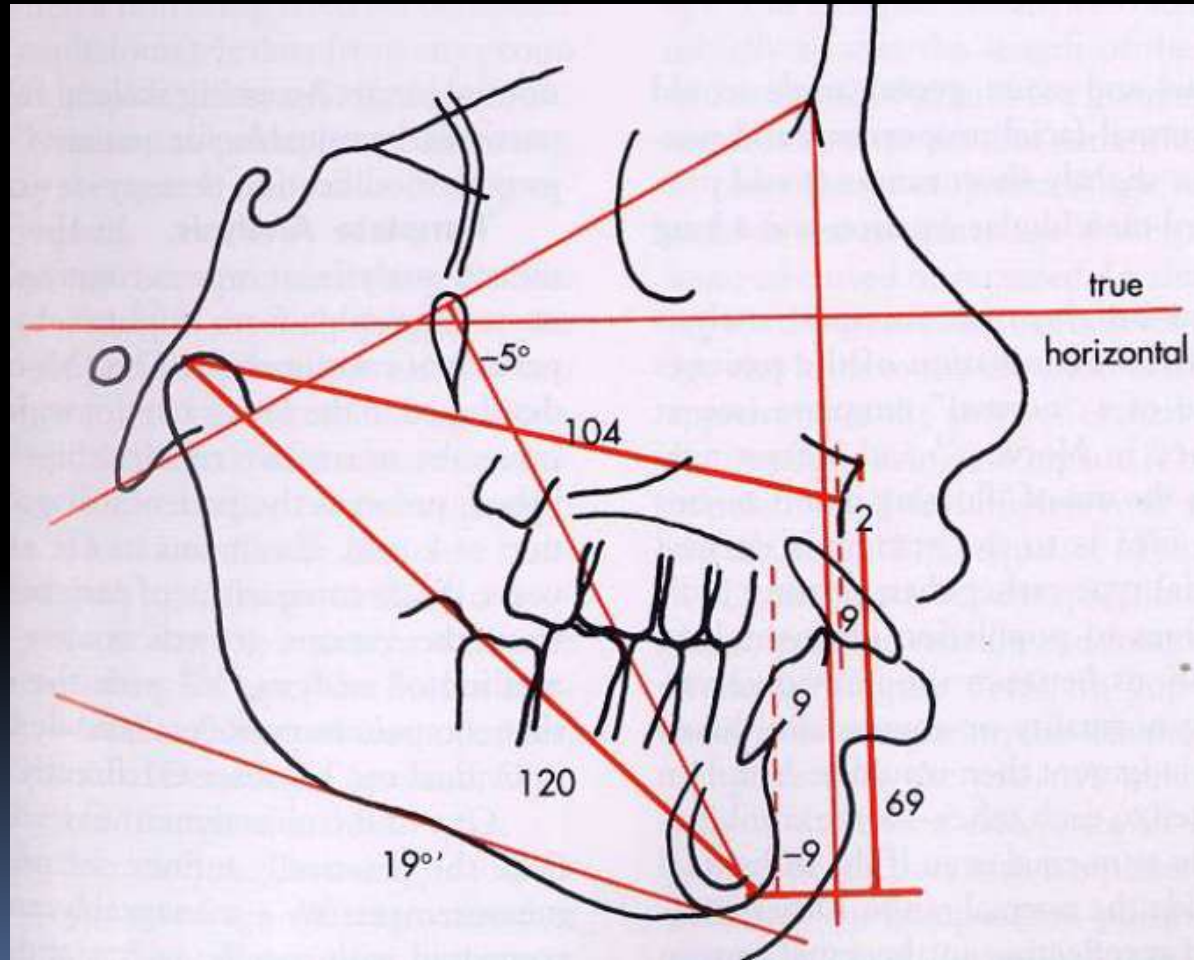


# METHODS OF CEPHALOMETRIC ANALYSIS

- **Metric approach** - use of selected linear and angular measures
  - **Graphic approach** - “overlay” of individual’s tracing on a reference template and visual inspection of degree of variation
    - **Digital approach.**
- 



# Metric Method - Use of selected linear and angular measures



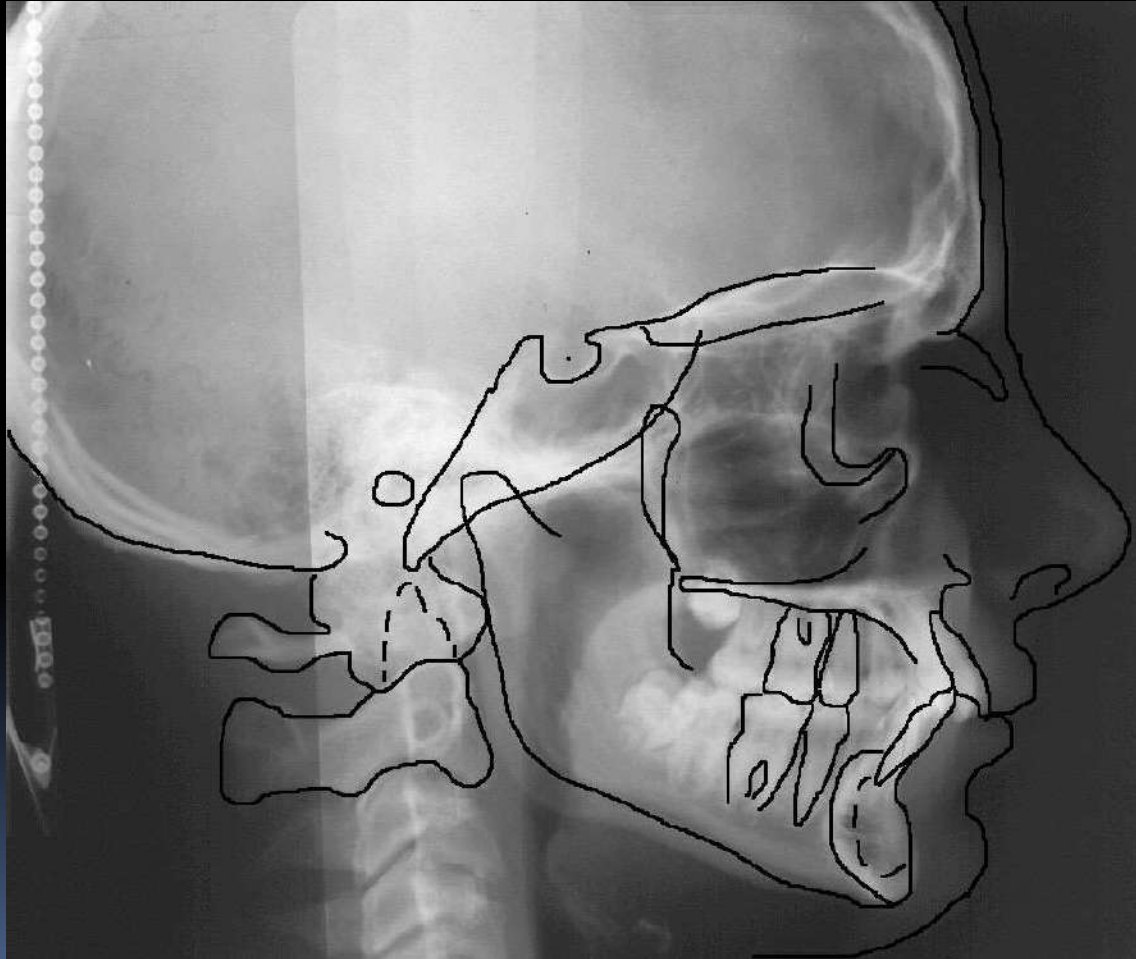


# Steps of tracing

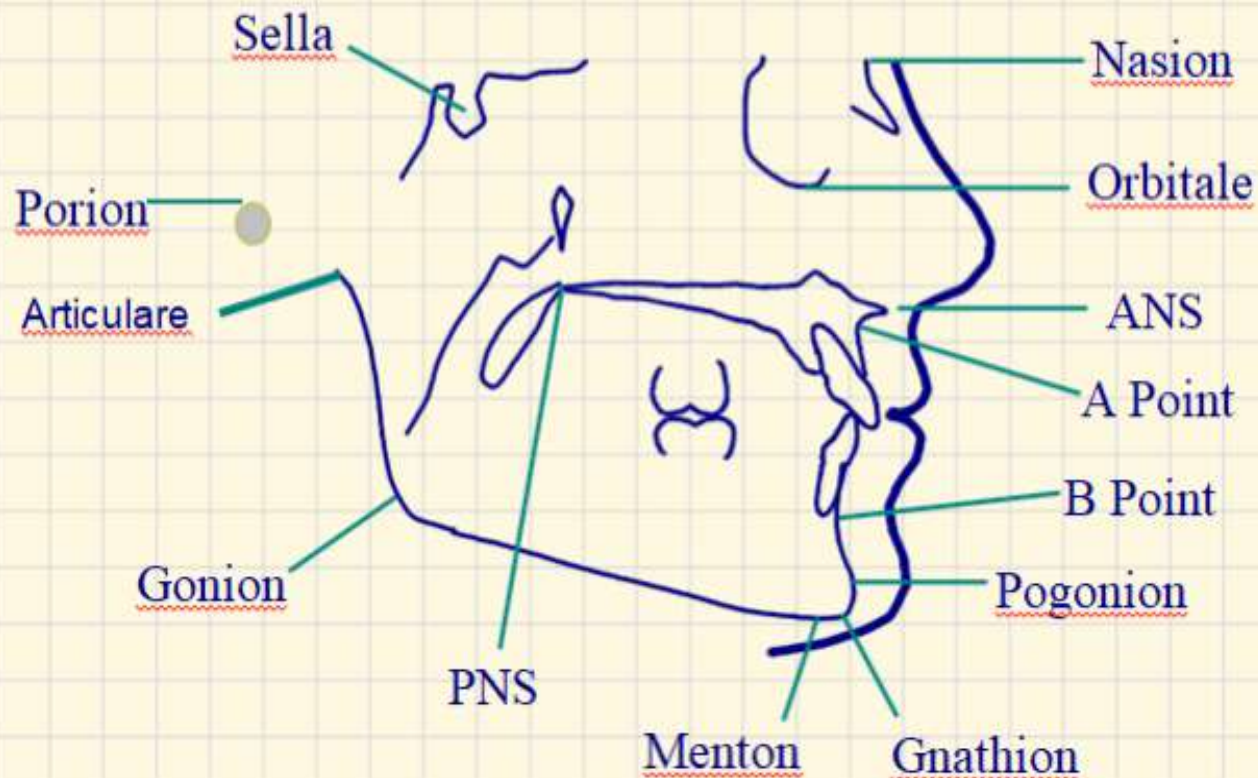
Draw soft tissue outline

- Cranial base
- Midface structures
- Maxillary dentition
- Mandibular structures
- Mandibular dentition

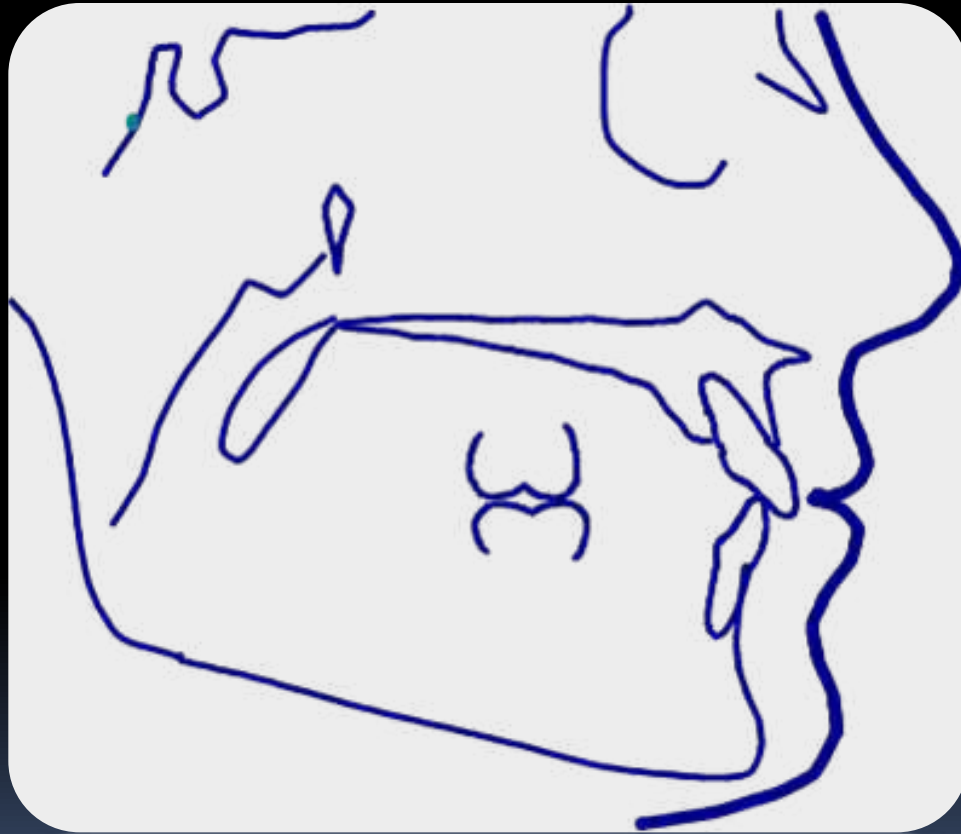# Tracing



# Standard Cephalometric Landmarks



# Structures to be Traced







# LANDMARKS

Sella: Centre of sella turcica

Nasion: Most anterior point on frontonasal suture

Orbitale: Lowest point on infraorbital margin

ANS: Tip of ant nasal spine



PNS: Tip post nasal spine


Point A: Deepest midline point b/w ANS and prosthion

Point B :Deepest point in the bony outline b/w infradentale and pogonion

Pogonion :Most ant point on bony chin

Gnathion :Most anterior and inferior on bony chin

Menton : Lowest point on the bony outline of the md symphysis



Gonion: Most lateral external point at the junction of horizontal and ascending rami of the mandible

Articulare: Intersection post border of md and temporal bone

Porion :Upper most point on the EAM

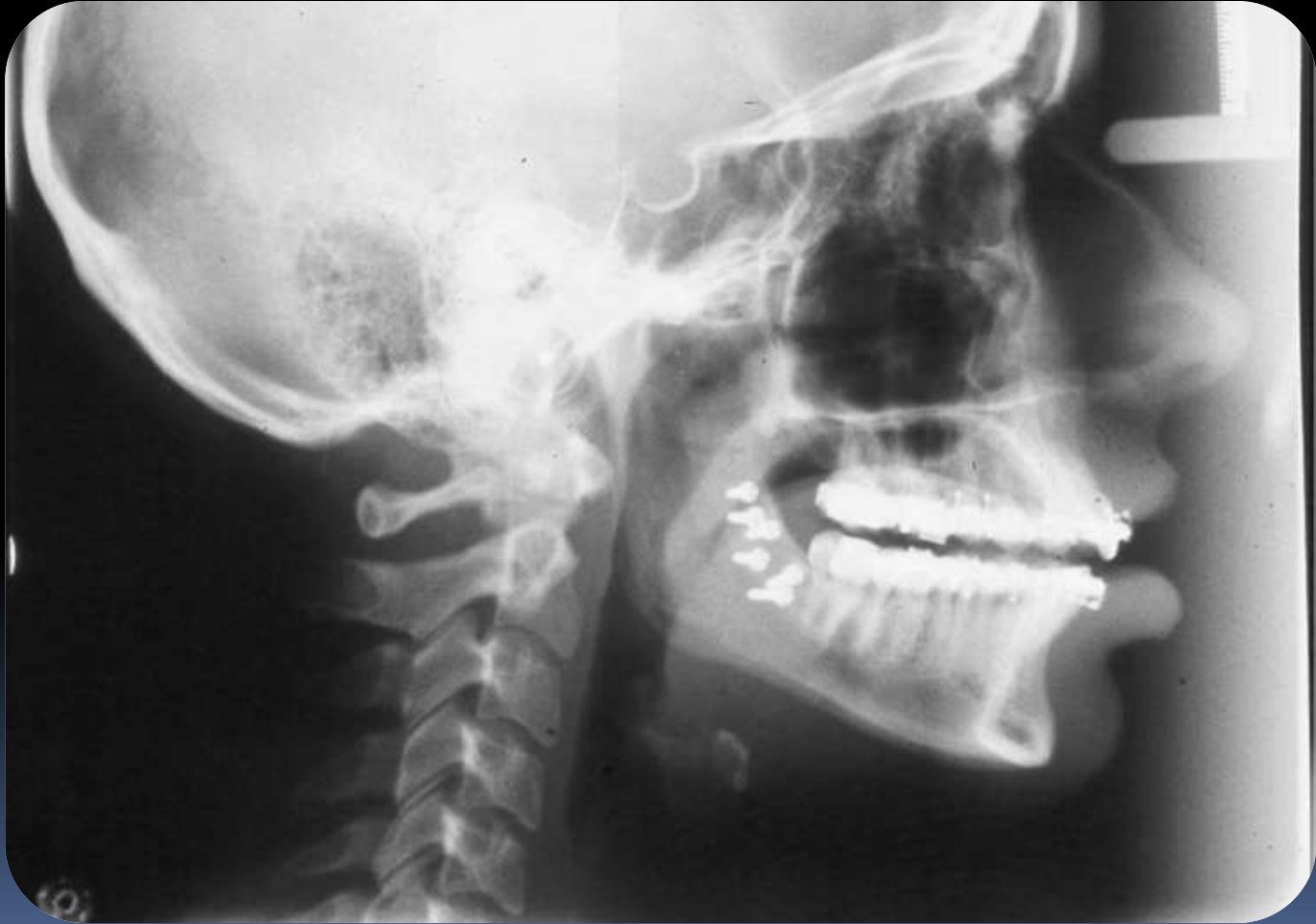

# GOALS OF CEPHALOMETRIC ANALYSIS

Evaluating relationships, both horizontal and vertical of 5 major functional components of the face:

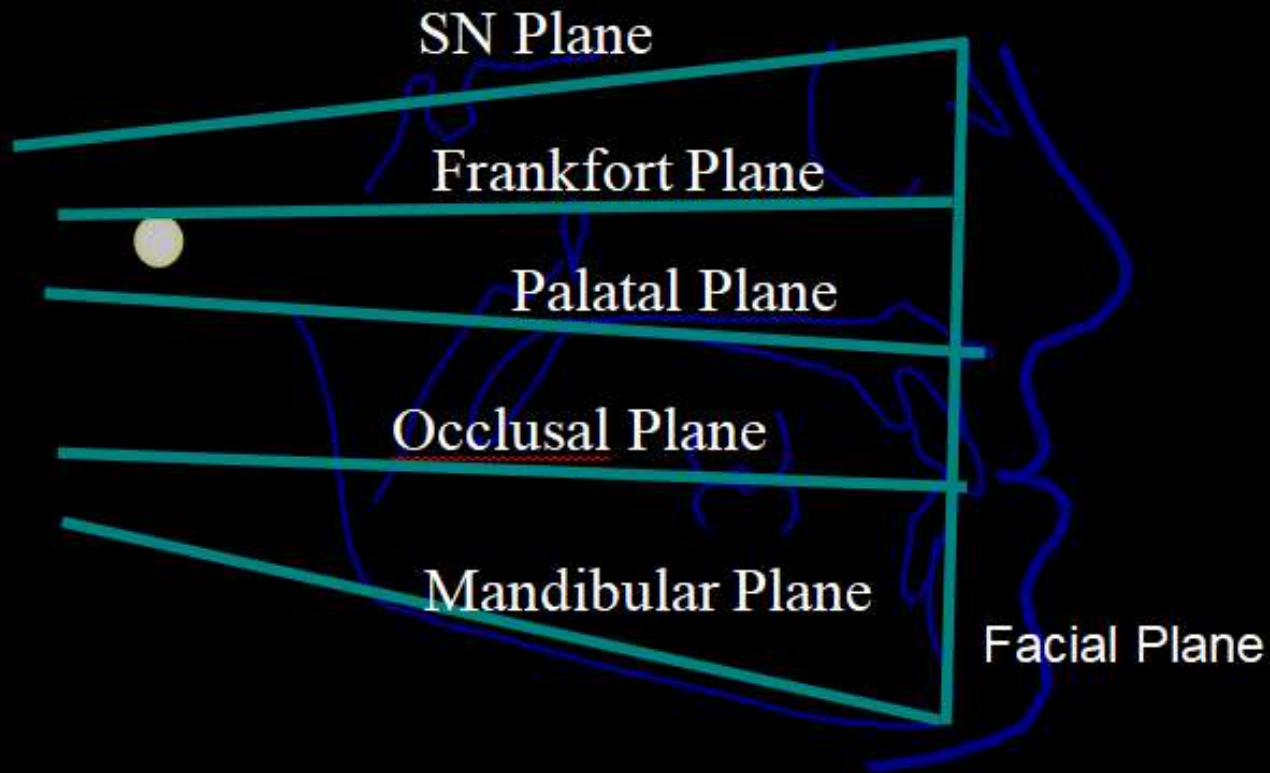
- The cranial base
- The maxilla
- The mandible
- The maxillary dento-alveolus
- The mandibular dento-alveolus

# Radiograph





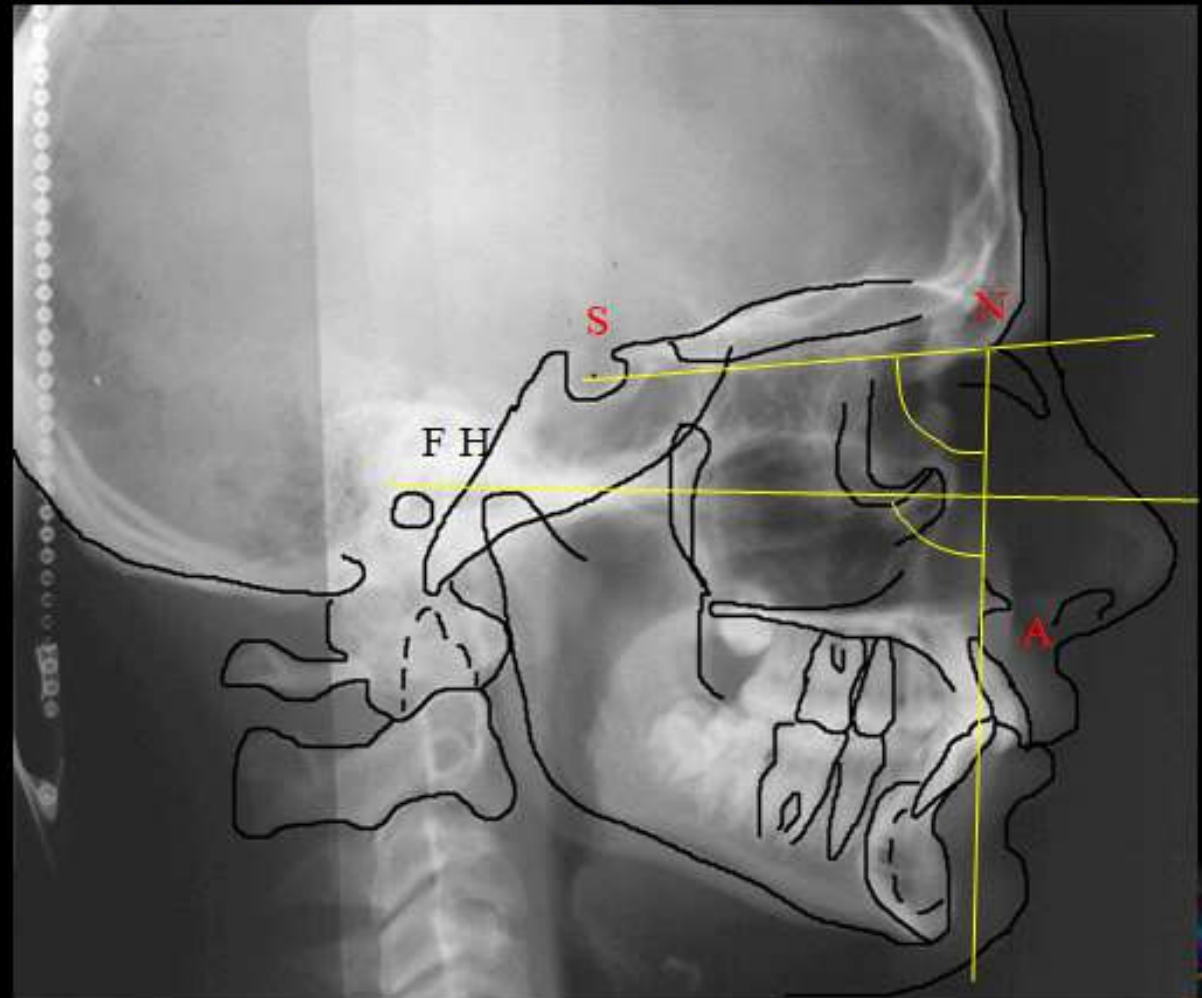
# Frequently Used Planes



NA TO FH  $90 \pm 3$  deg

# Sagittal Analysis

## Skeletal Horizontal - Maxilla



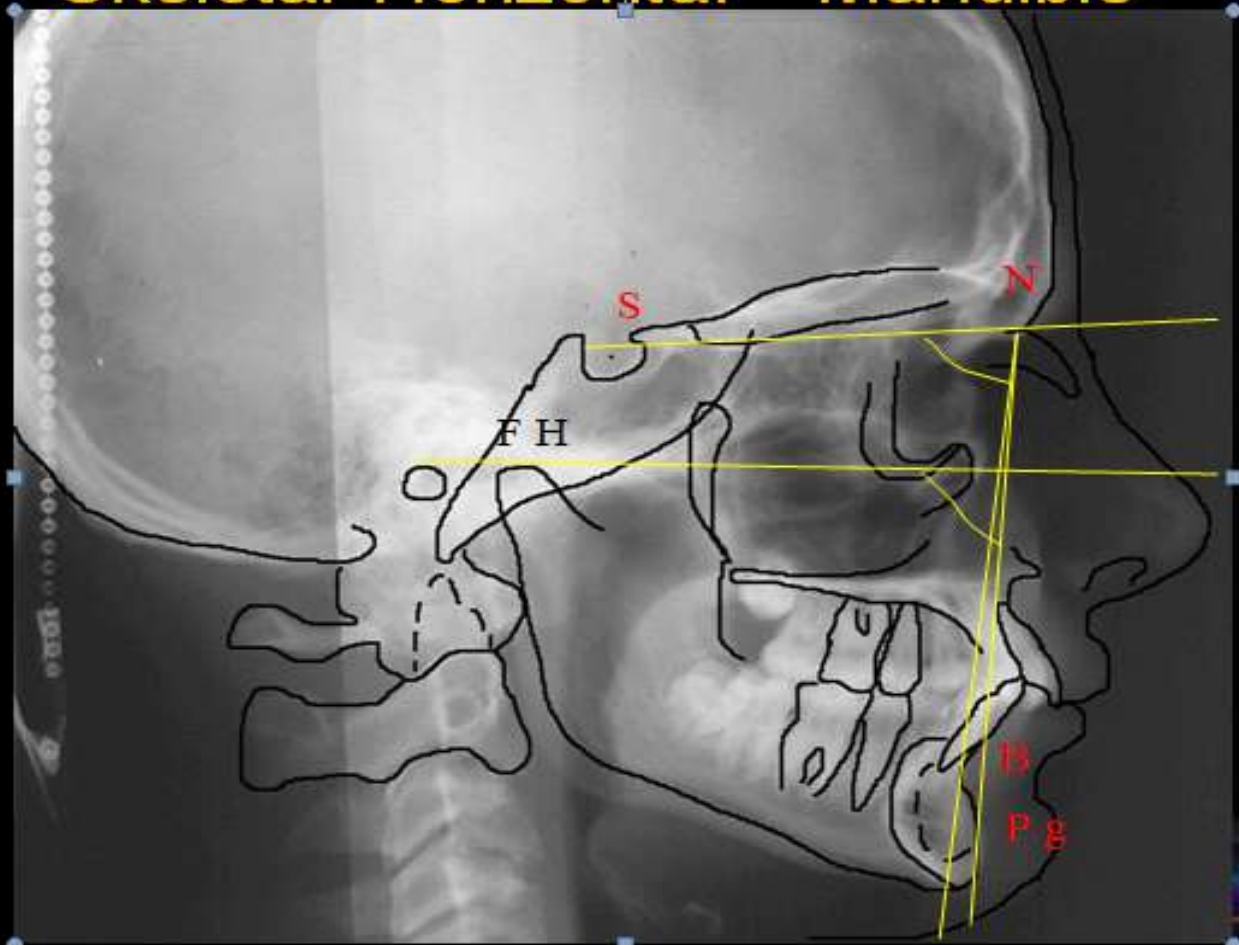
# SAGITTAL ANALYSIS

SNB  $80 \pm 2$  deg

N-PG TO FH  $87 \pm 4$  deg

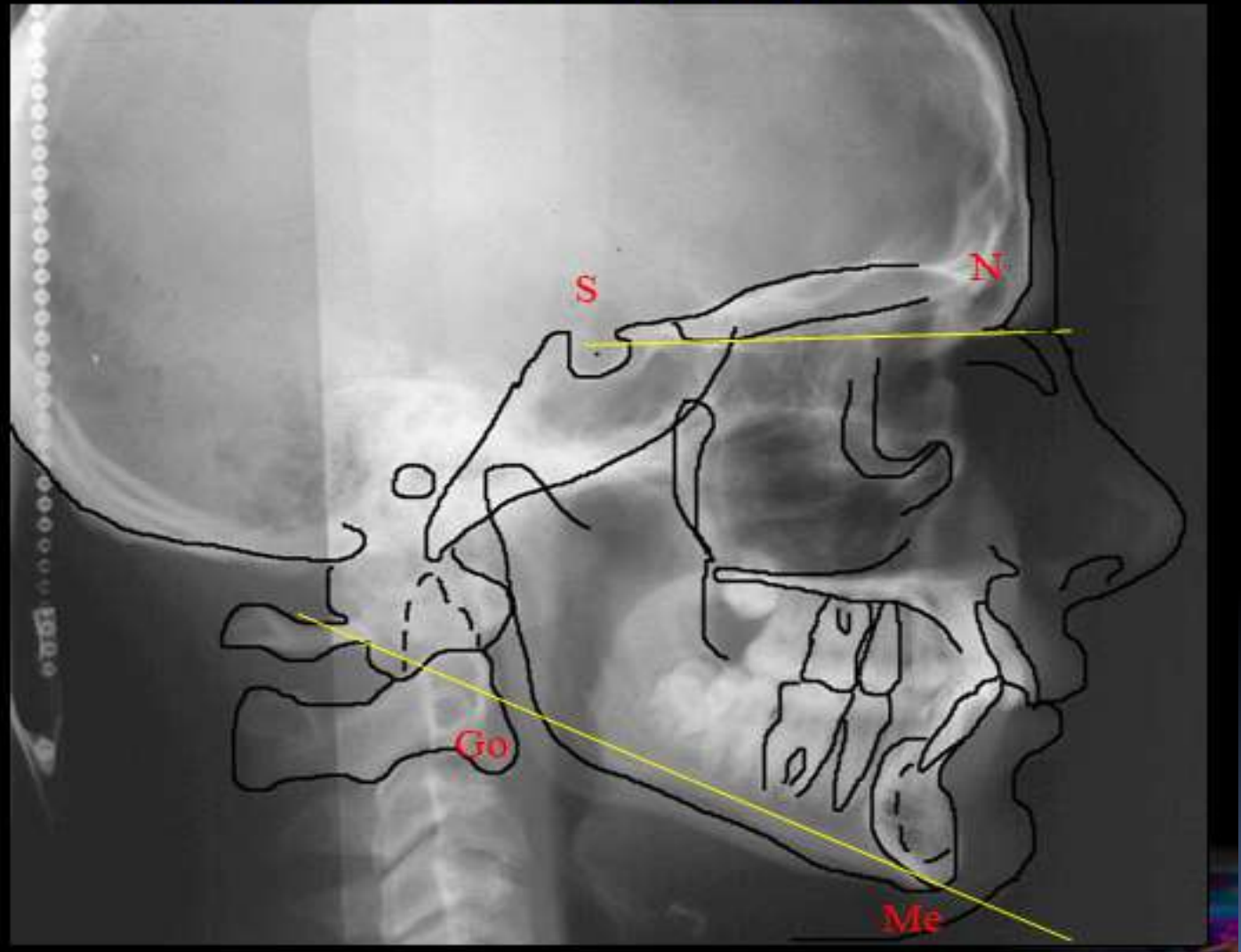
## Sagittal Analysis

### Skeletal Horizontal - Mandible



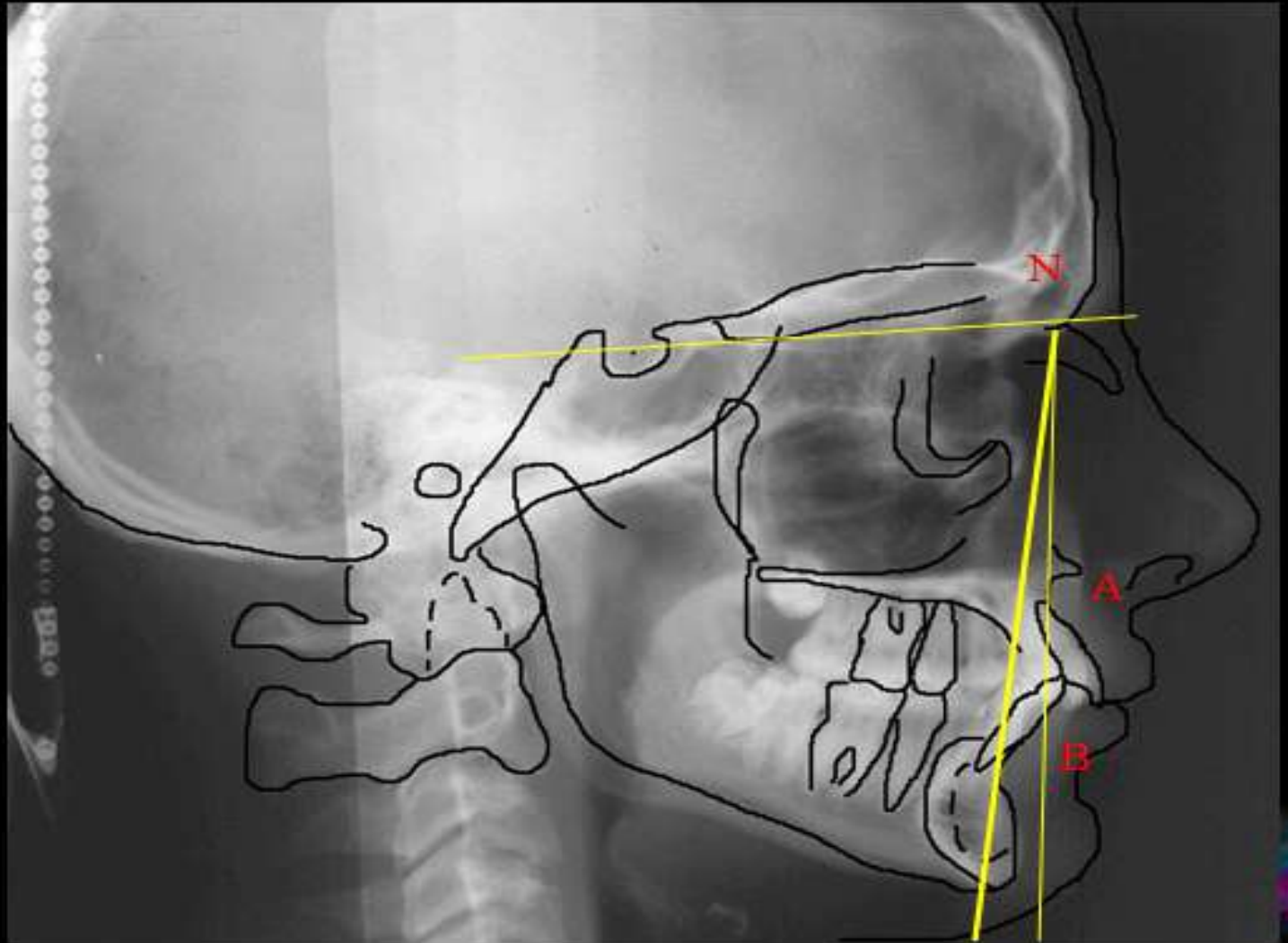
SN-Md Plane  $32 \pm 4$  deg

# SKELETAL VERTICAL



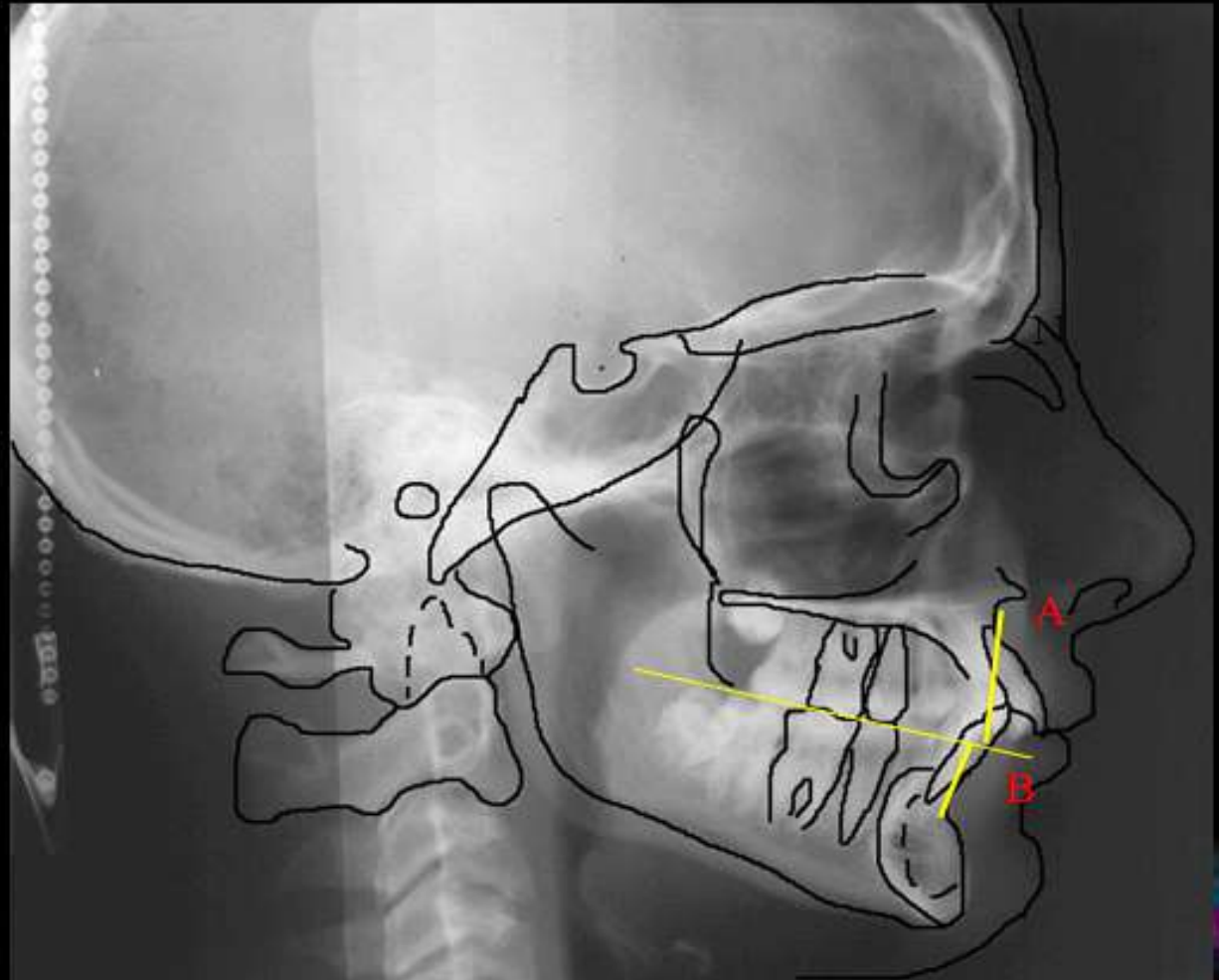
ANB  $2 \pm 2$  deg

# Sagittal Analysis Maxilla To Mandible





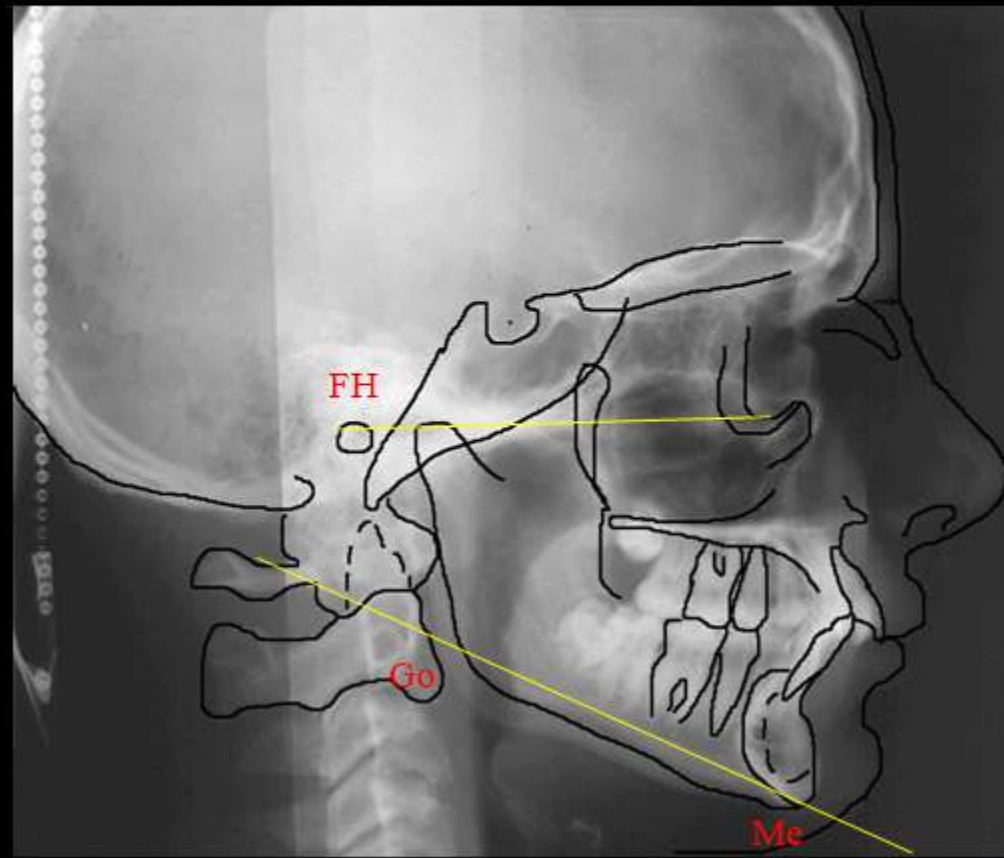
# Sagittal Analysis Maxilla and Mandible





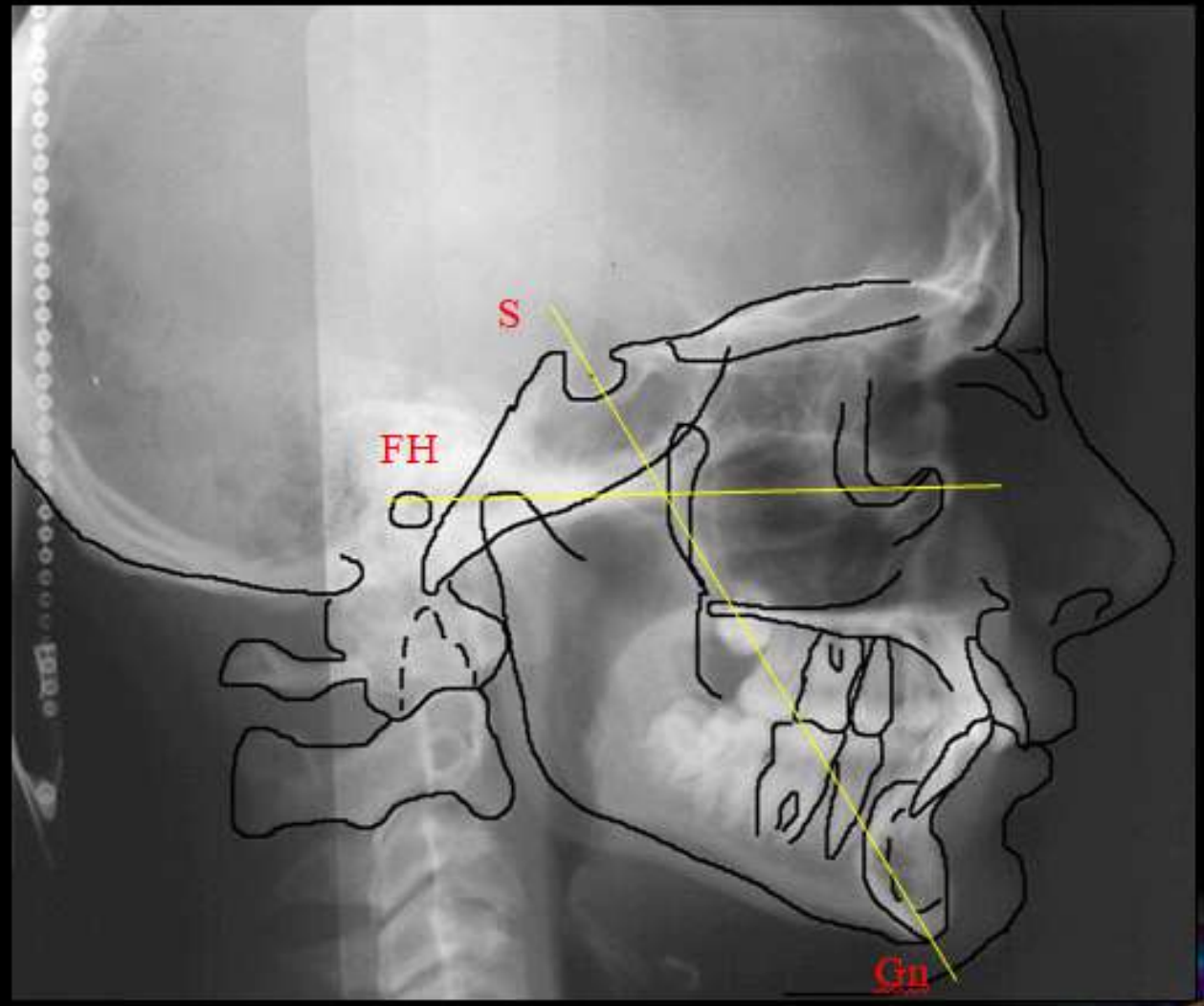
FH-Md Plane  $25 \pm 4$  deg

## SKELETAL VERTICAL



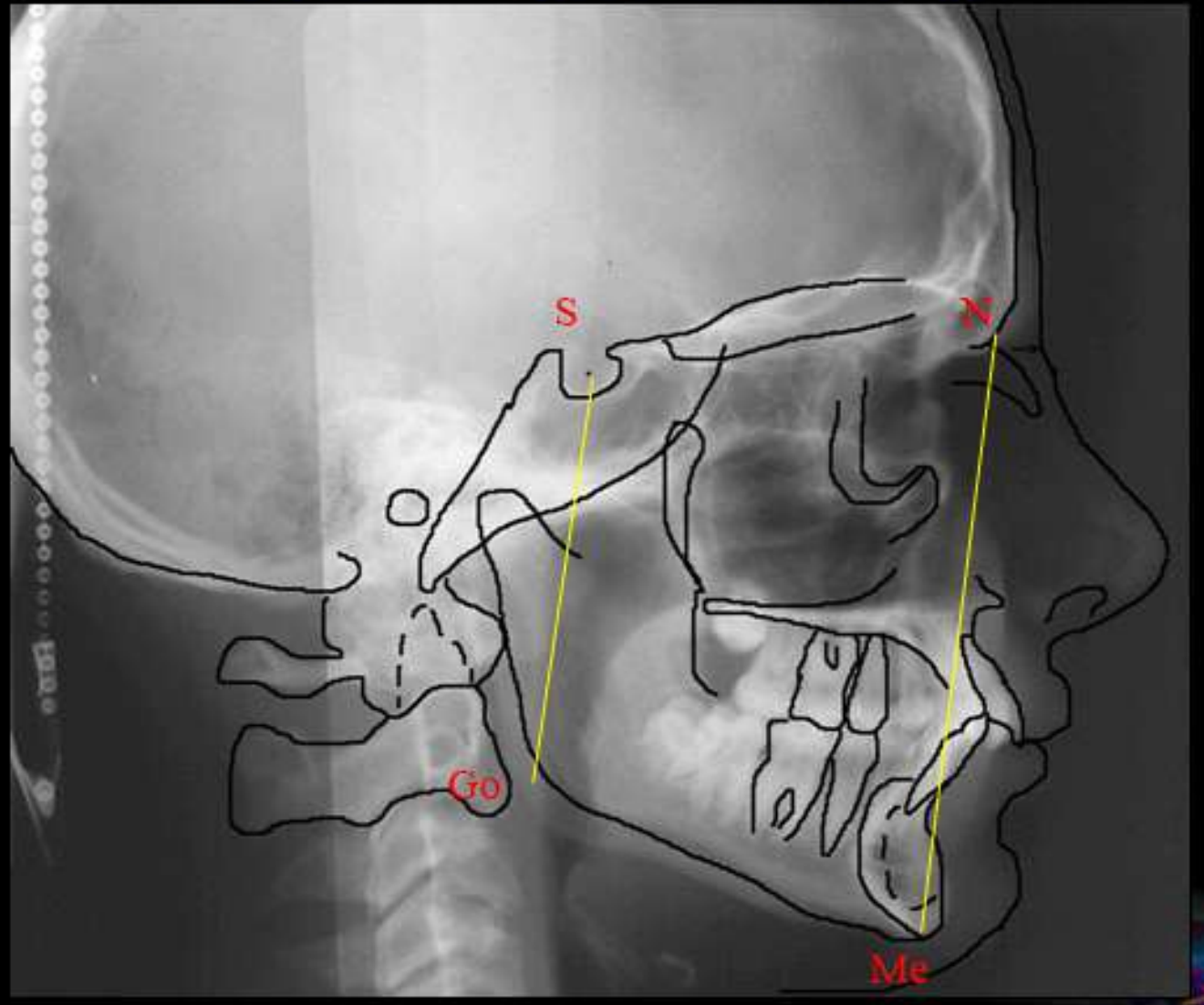
Y axis angle  $60 \pm 4$  deg

# SKELETAL VERTICAL



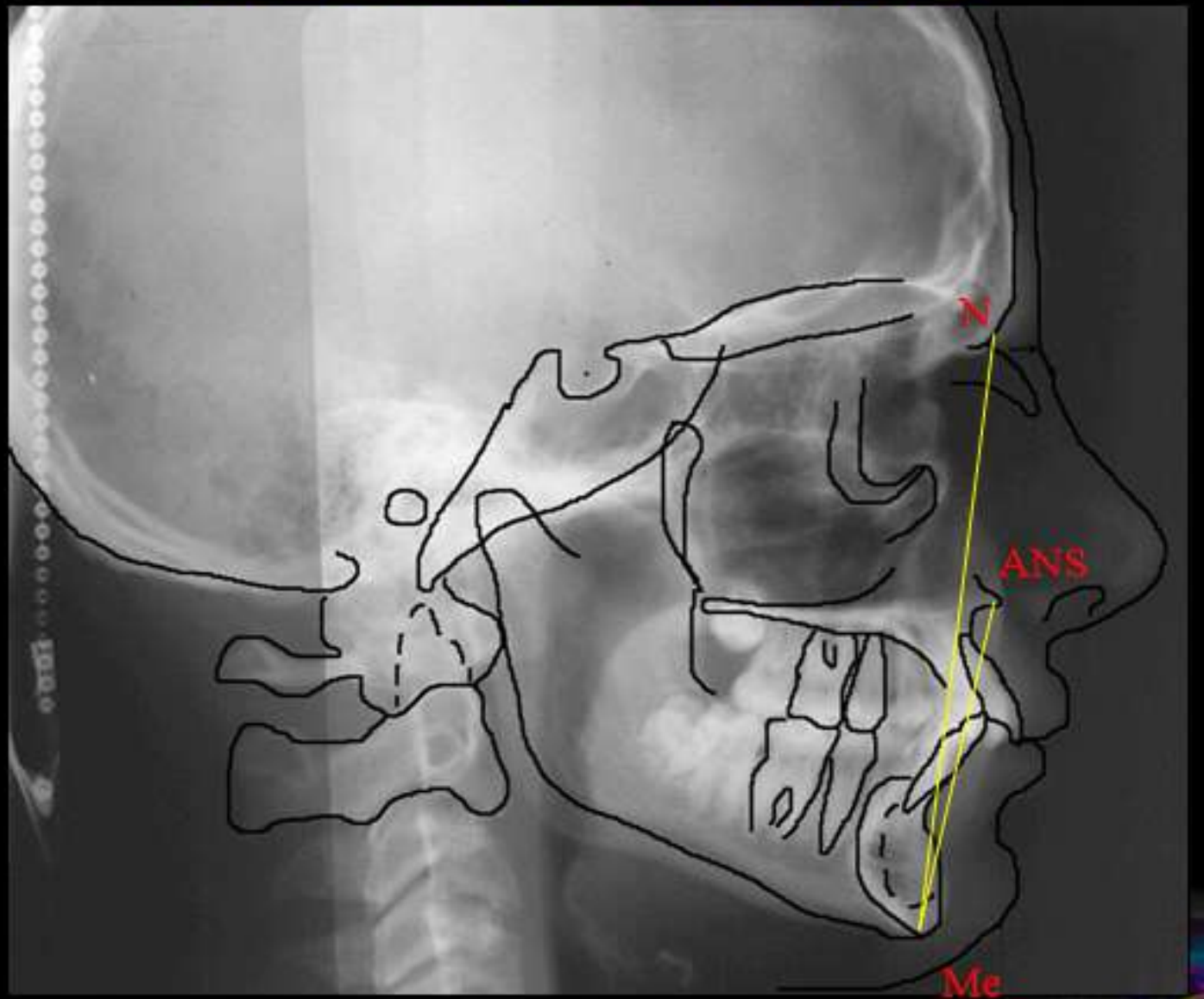
PFH/TAFH ratio 65 %

# SKELETAL VERTICAL

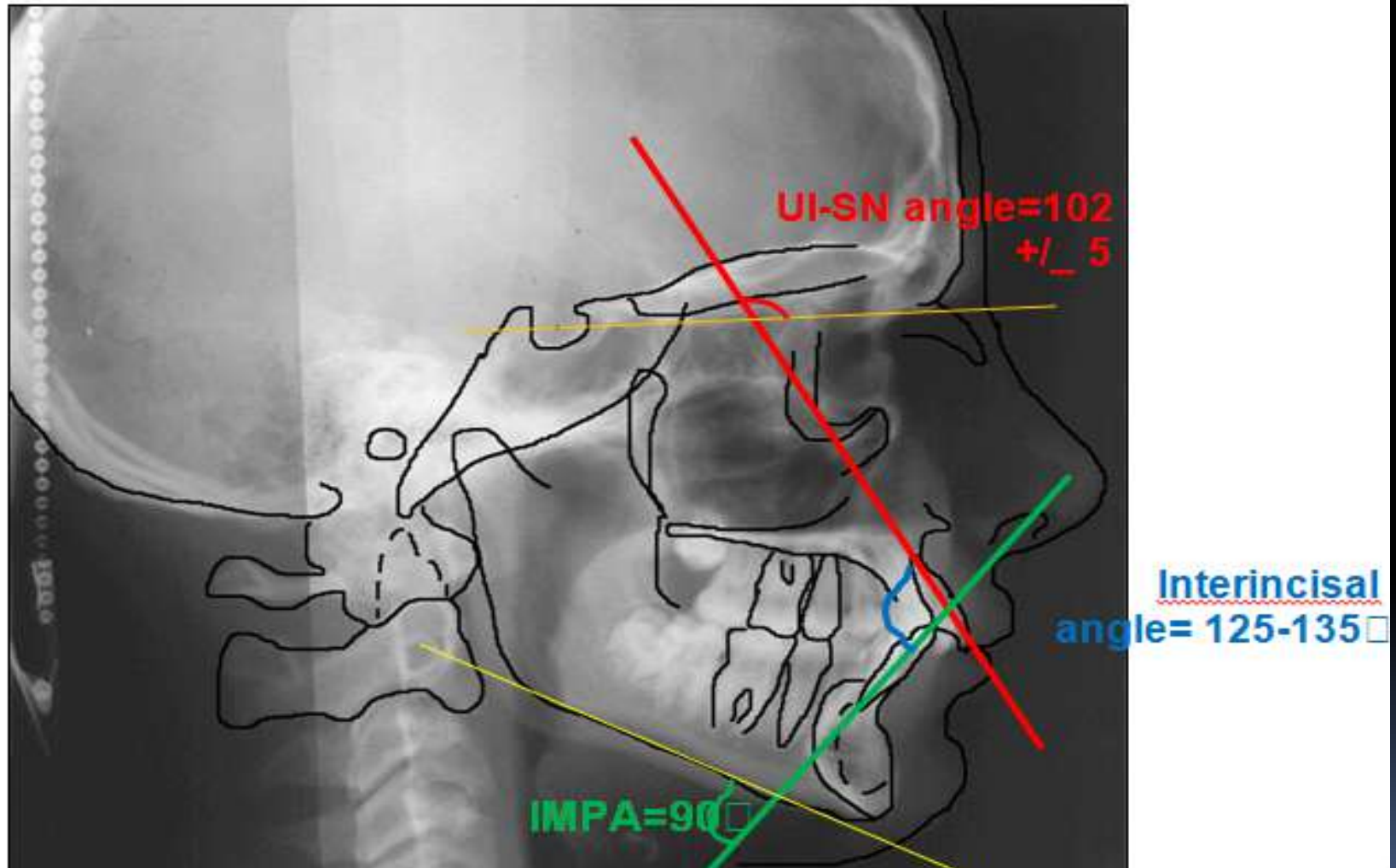


LFH/TAFH ratio 55 %

# SKELETAL VERTICAL

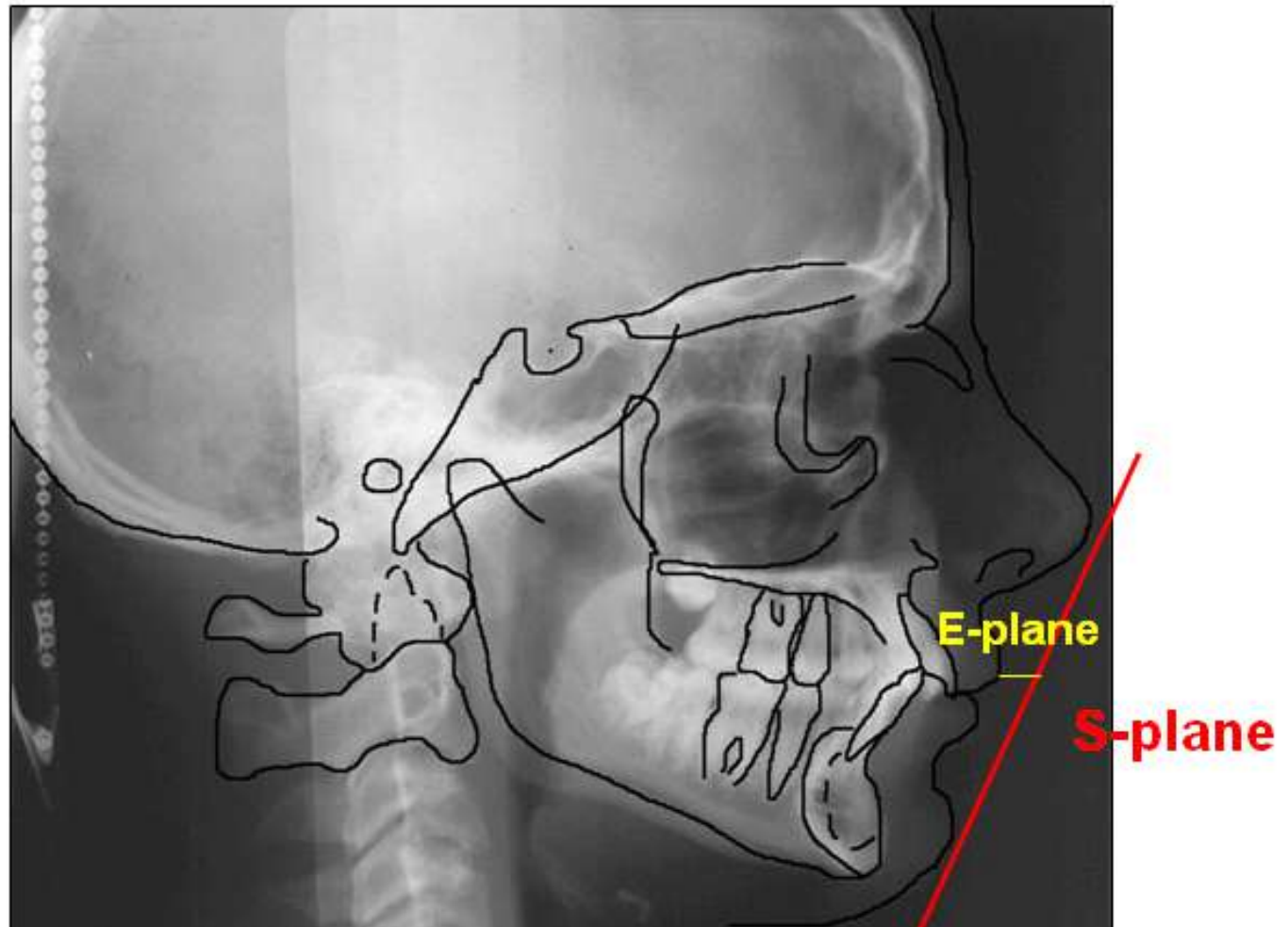


# Dental analysis

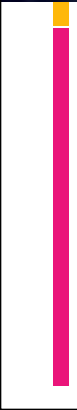
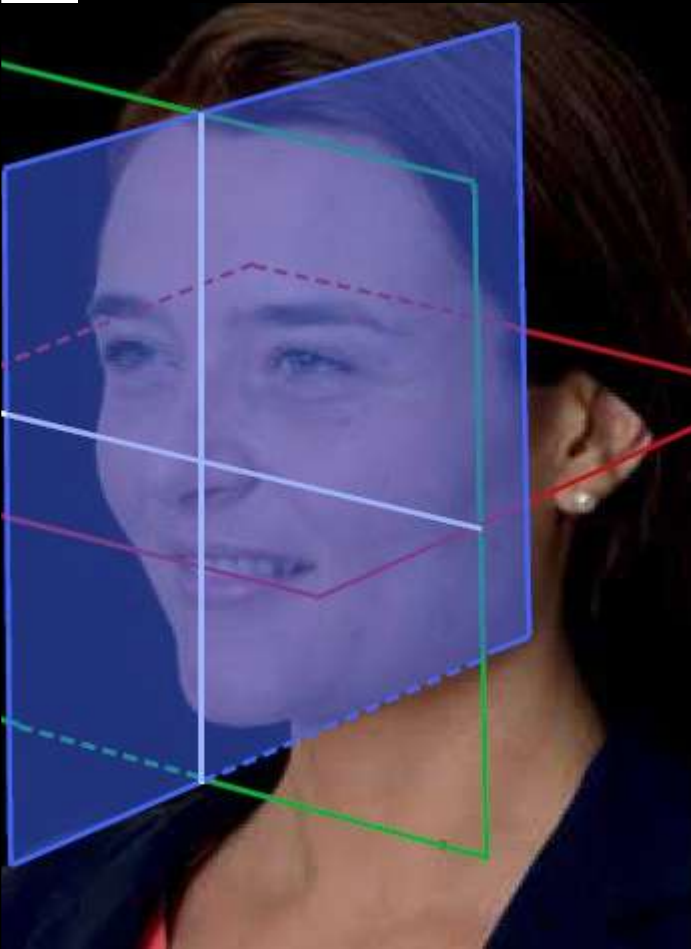




# Soft tissue analysis







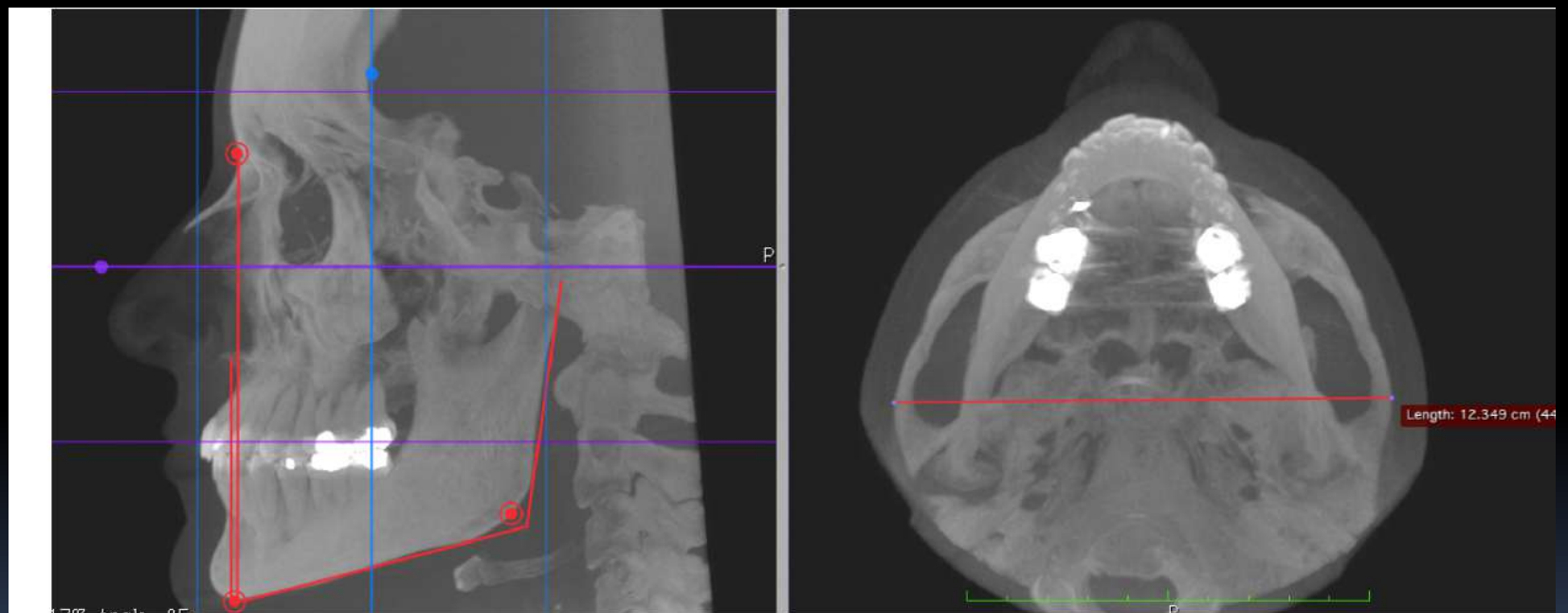
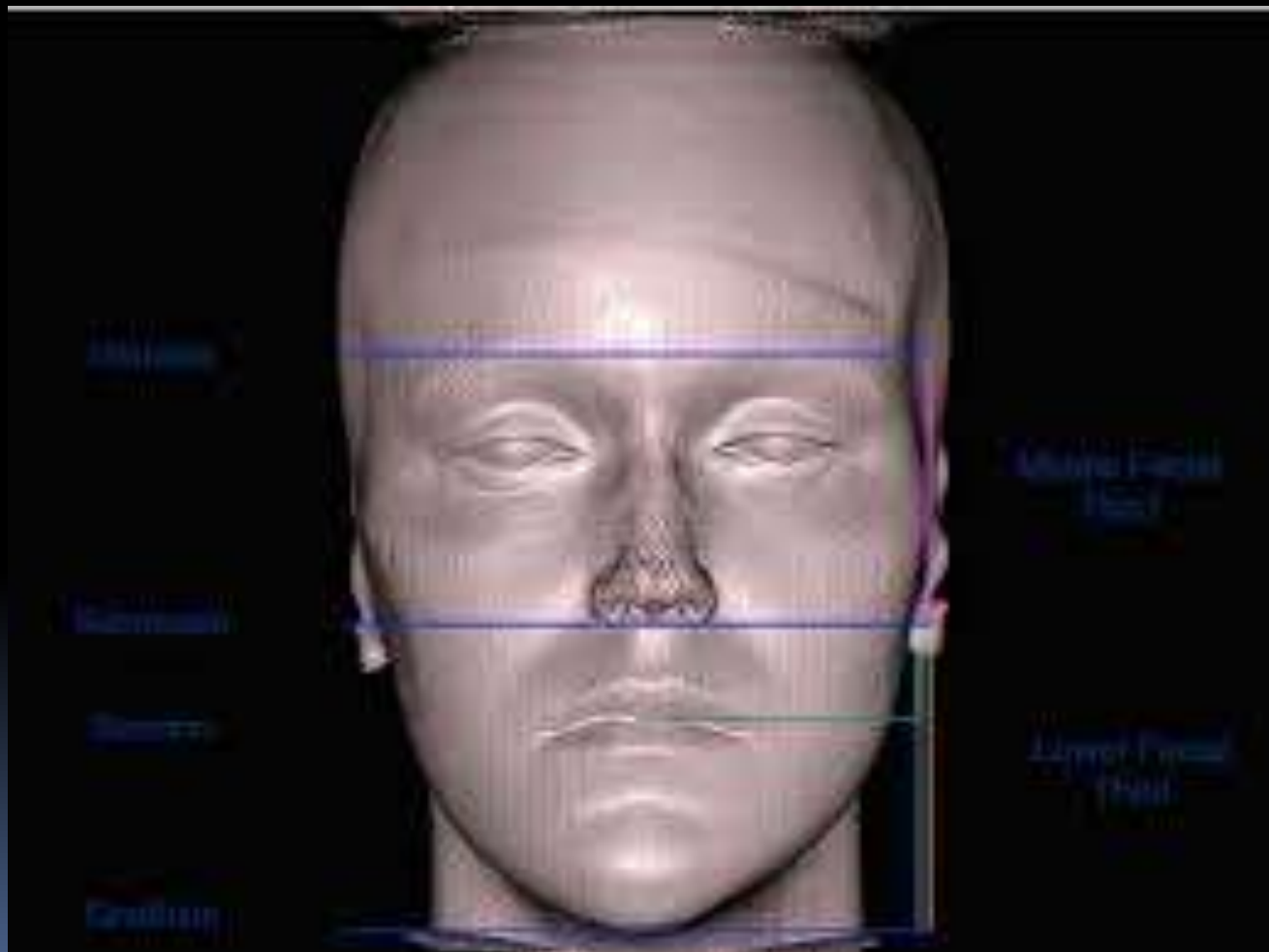


Figure 1. Facial pattern analysis in Computed tomography based on 3 facial features



A vertical bar on the left side of the slide, composed of several colored segments: a small pink square at the top, followed by a grey square, a yellow square, and a long pink rectangle at the bottom.

Thank you



Lect. Hussein T. Abed

13.1.2021

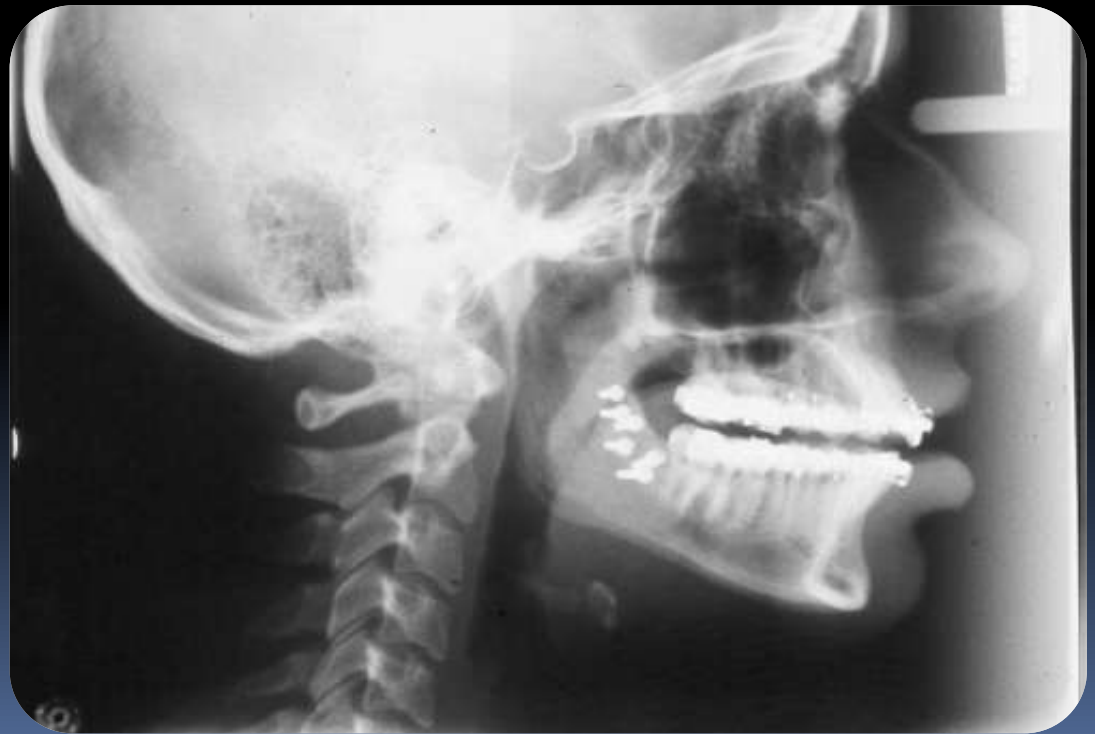# FACIAL MEASUREMENTS : X-RAY AND SLIDES

# How you evaluate a face

Soft tissue

Hard tissue

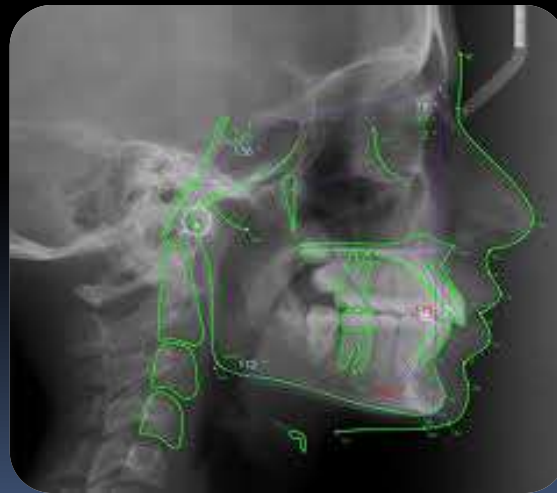
Dental tissue



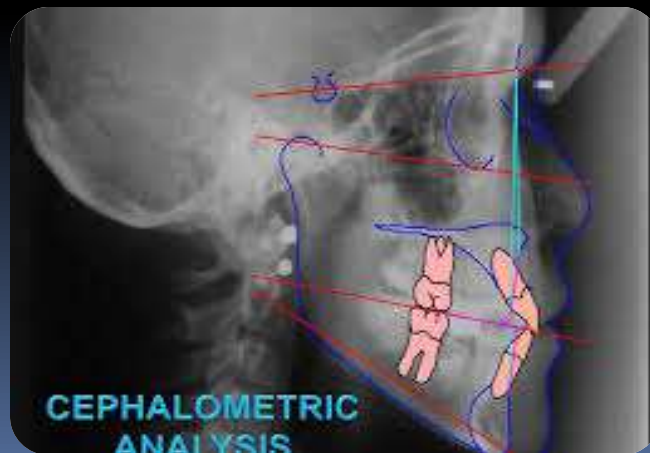


# Importance

Many of the difficulties experienced in the treatment can be attributed directly to the extent of the **excessive disharmony** of the skeletal pattern.



Simply calling a dimension 'large' or 'small' or 'good' or 'bad' does not mean the same to everyone. In order to be critical or descriptive it is more useful to express dimensions in terms of angles or linear measurements.





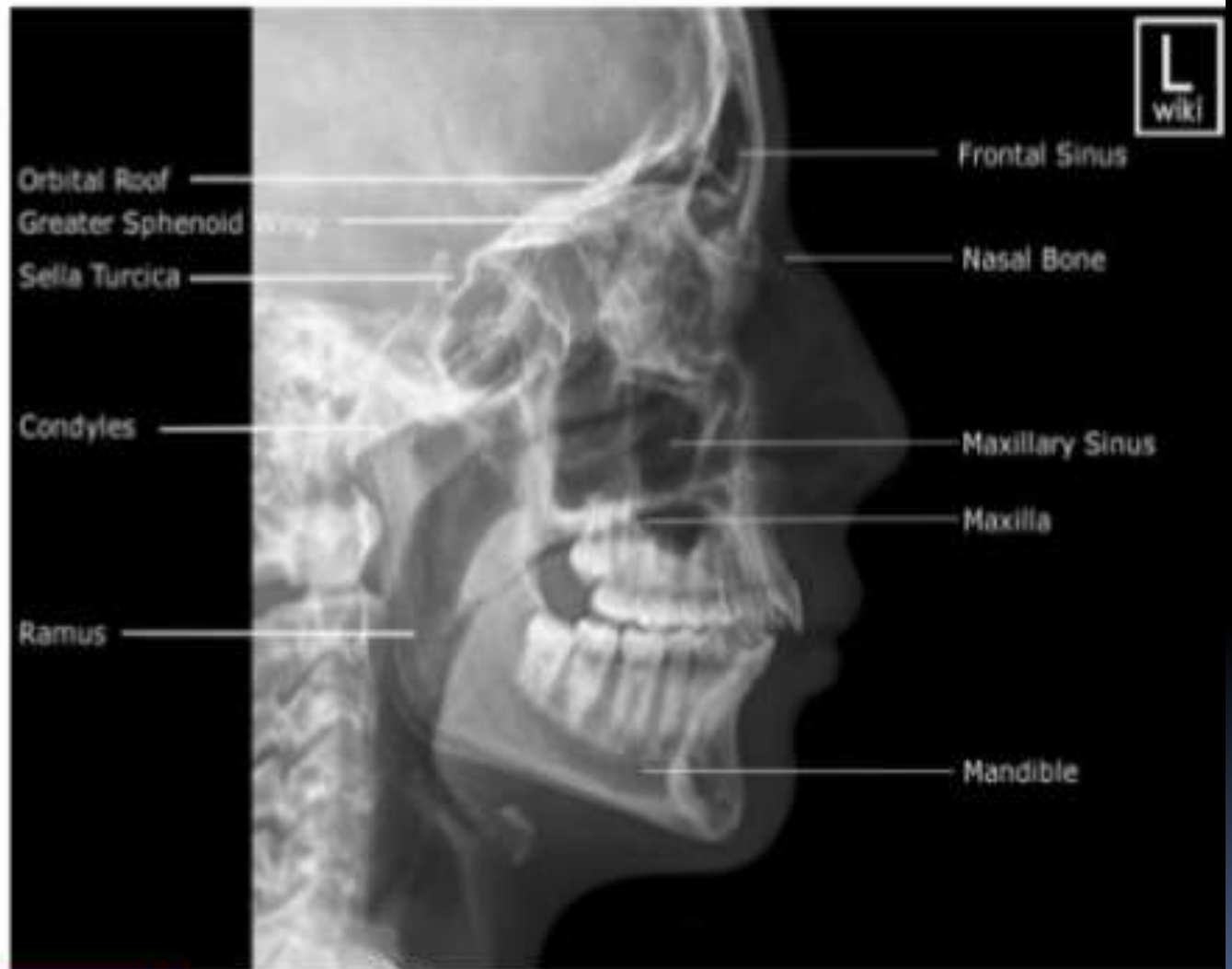
# Cephalometric Evaluation

- Identification of **anatomic landmarks**
- Landmarks: **stable** reference structures maxillary and mandibular skeletal and dental
- Graphically **relating** the dento-facial elements to these reference structures
- Angular and or linear **measurements**

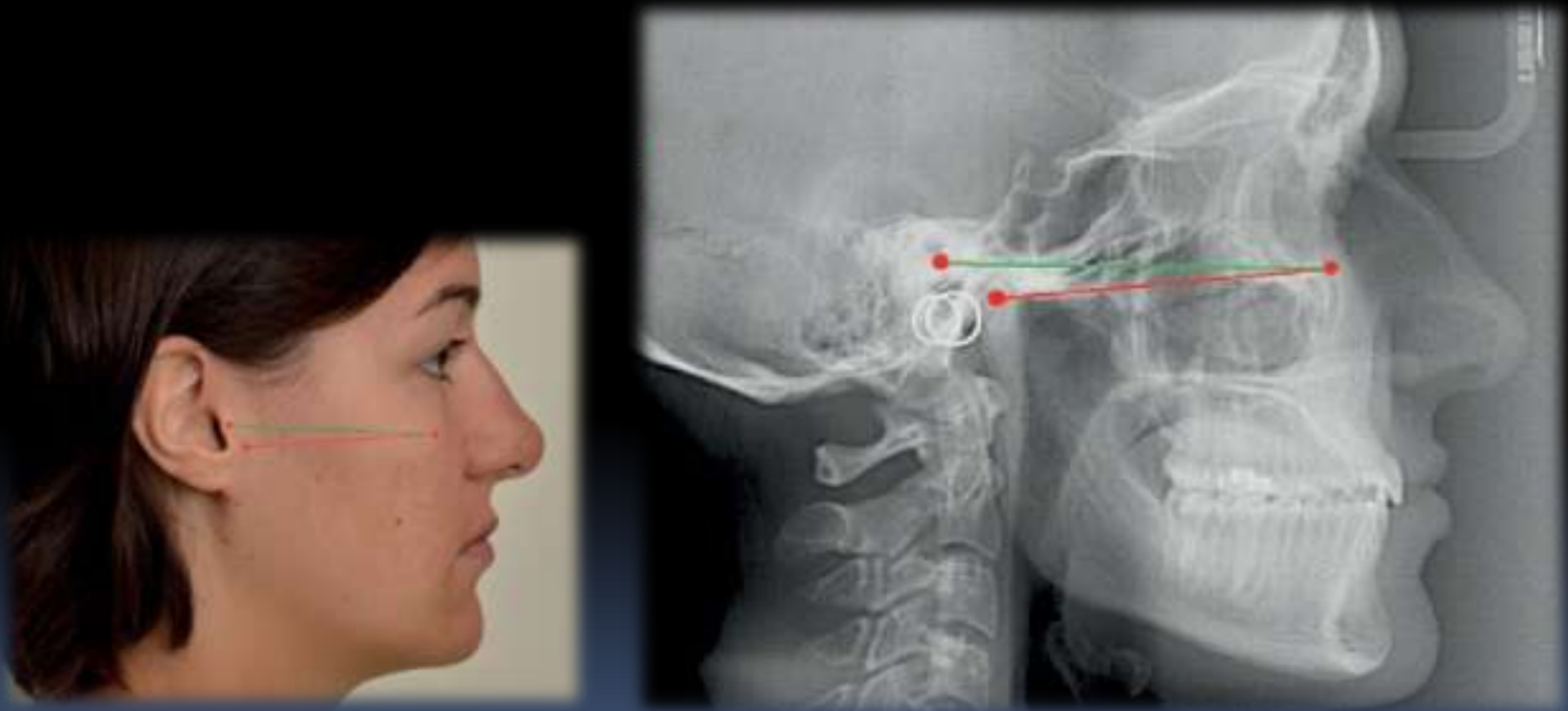
## Adult Facial Bones - PA Caldwell



## Adult Facial Bones - Lateral View



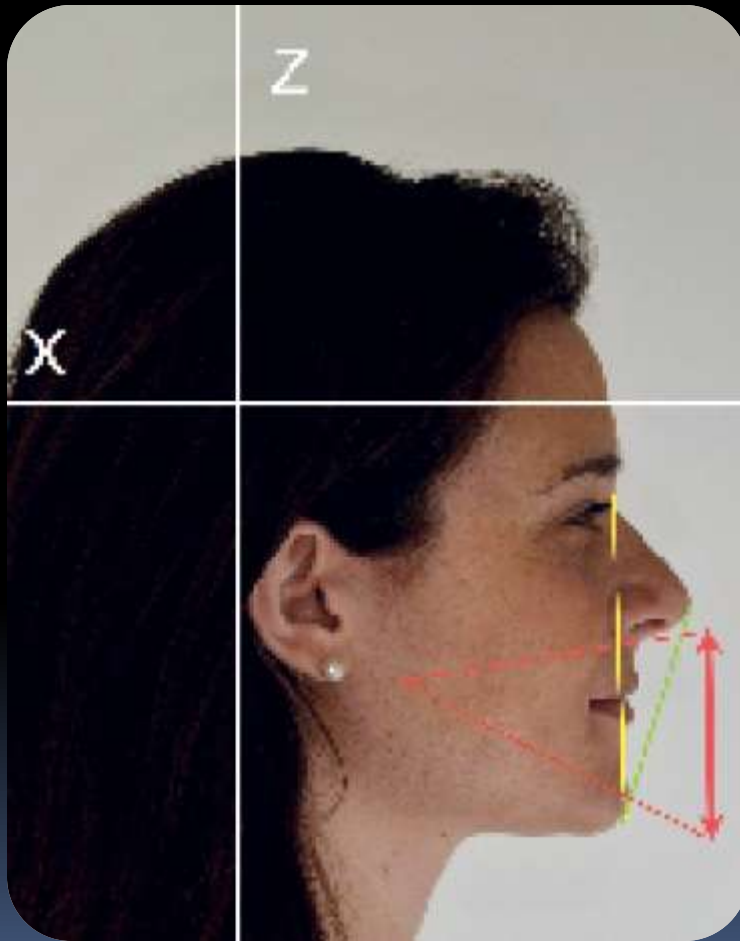
Lateral skull's x-ray: the **red line** indicates the arbitrary axis-orbital plane, whilst the **green line** shows the Frankfurt plane.



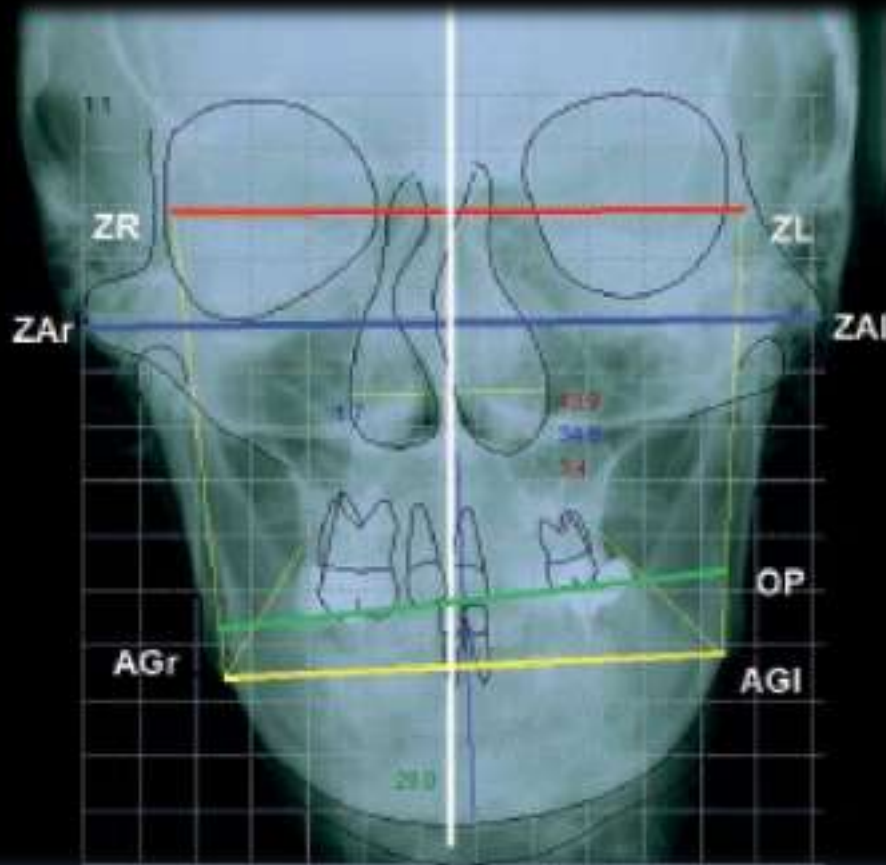




Plans and reference lines of the patient's face on the frontal plane: **Z-axis** that provides the vertical parameter, **Y-axis** that provides transversal parameter.




Maps and reference lines of the patient's face on the sagittal plane: X-axis that identifies the sagittal plane from the front to back (antero-posteriorly), Z-axis that provides the vertical parameter. The red triangle identifies the VD, the green line shows the profile evaluation according to Ricketts, the yellow line indicates the anterior-posterior position of the mandible.



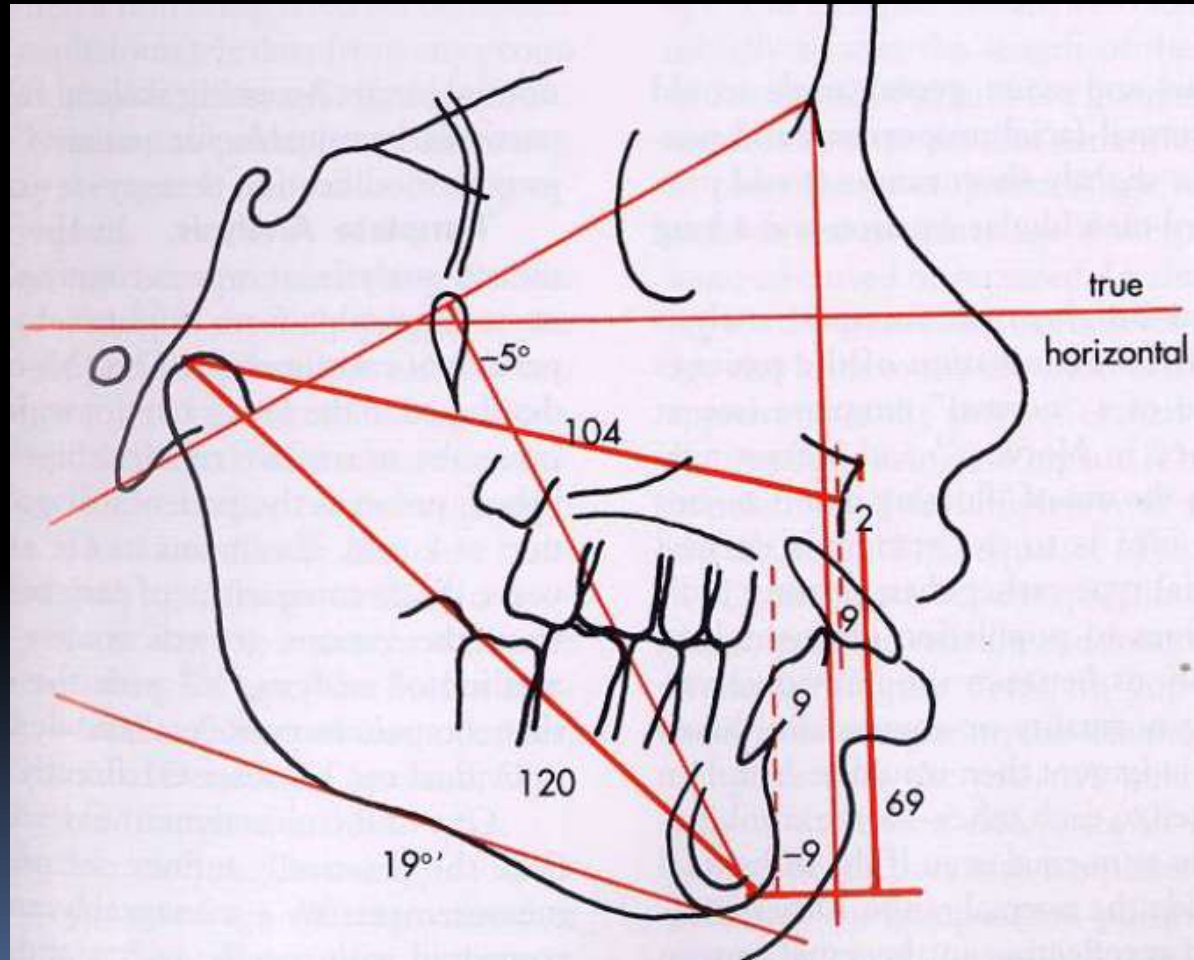
Digital tracing run on  
the AP x-ray :  
red, zygomatic orbital  
line;  
blue, zygomatic line;  
green, occlusal plane;  
yellow, antegonial  
line.



# METHODS OF CEPHALOMETRIC ANALYSIS

- **Metric approach** - use of selected linear and angular measures
  - **Graphic approach** - “overlay” of individual’s tracing on a reference template and visual inspection of degree of variation
    - **Digital approach.**
- 

# Metric Method - Use of selected linear and angular measures





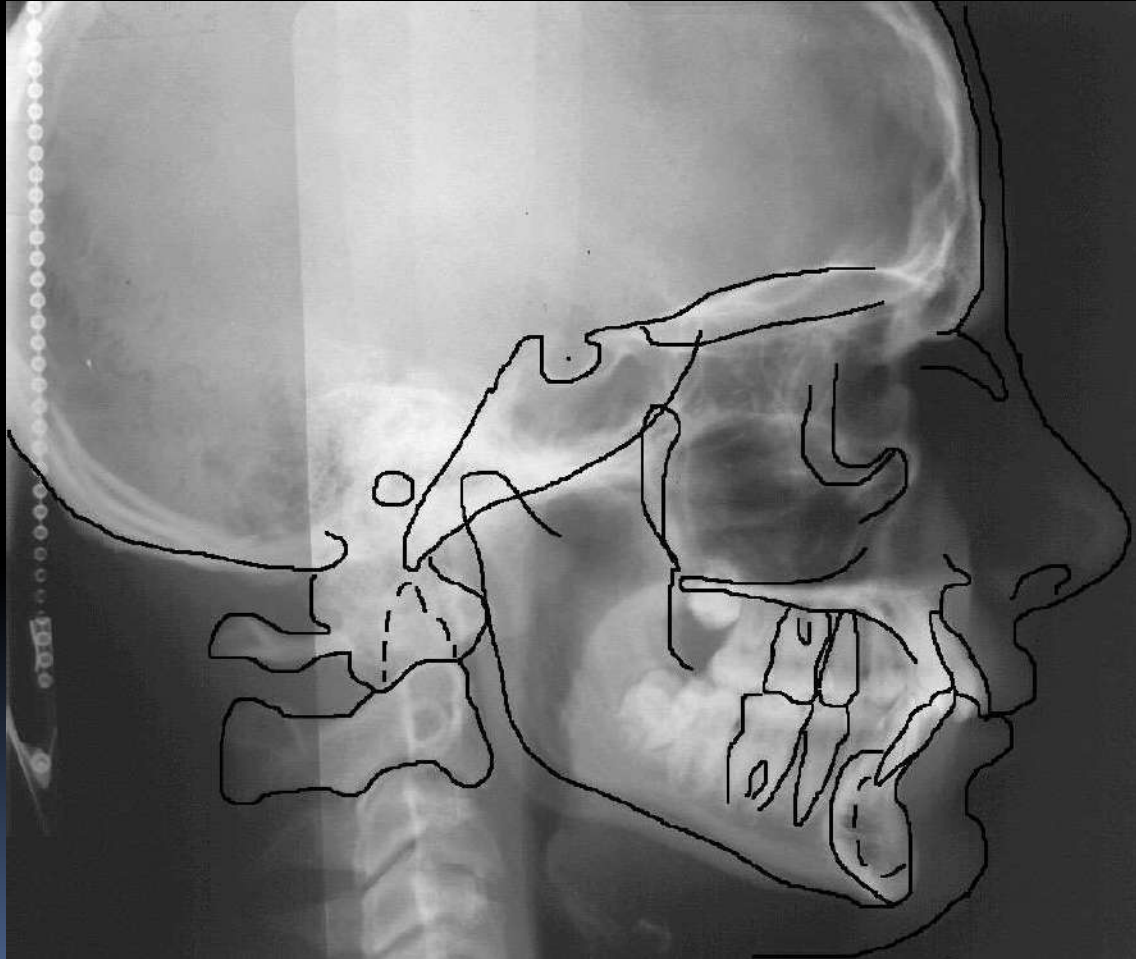
# Steps of tracing

Draw soft tissue outline

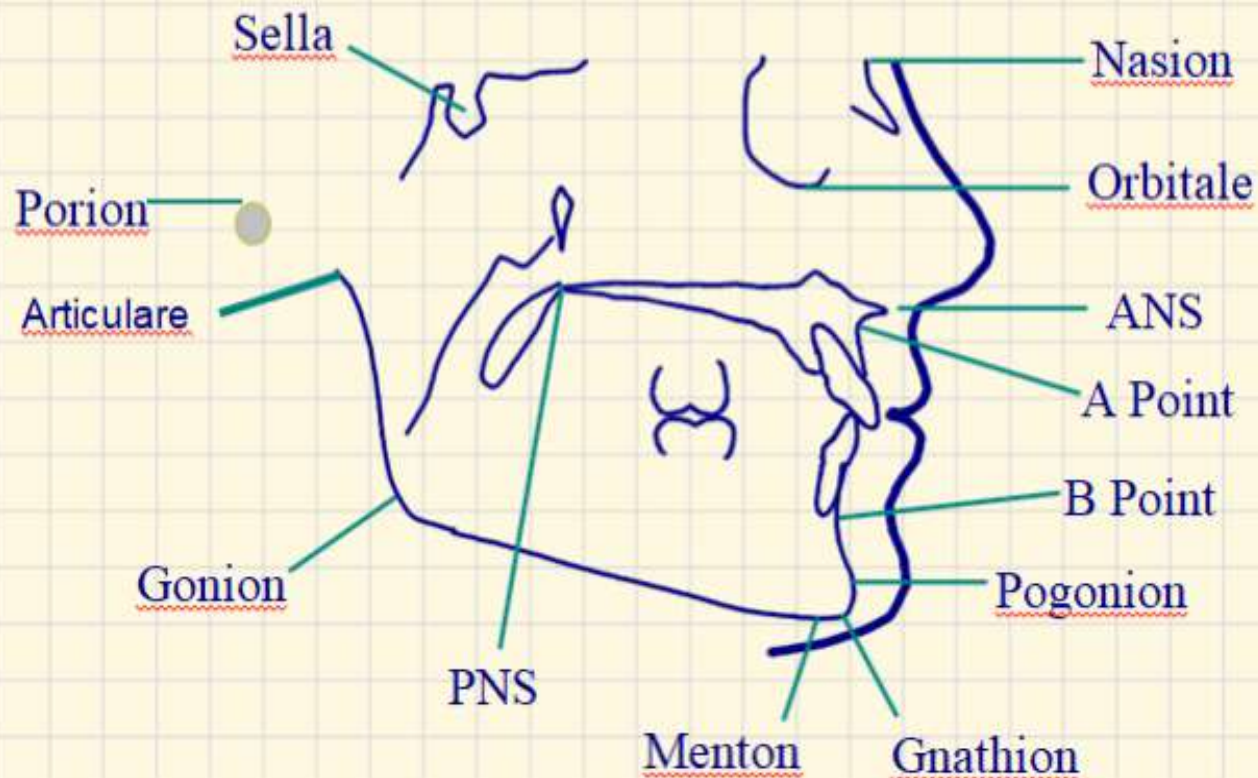
- Cranial base
- Midface structures
- Maxillary dentition
- Mandibular structures
- Mandibular dentition



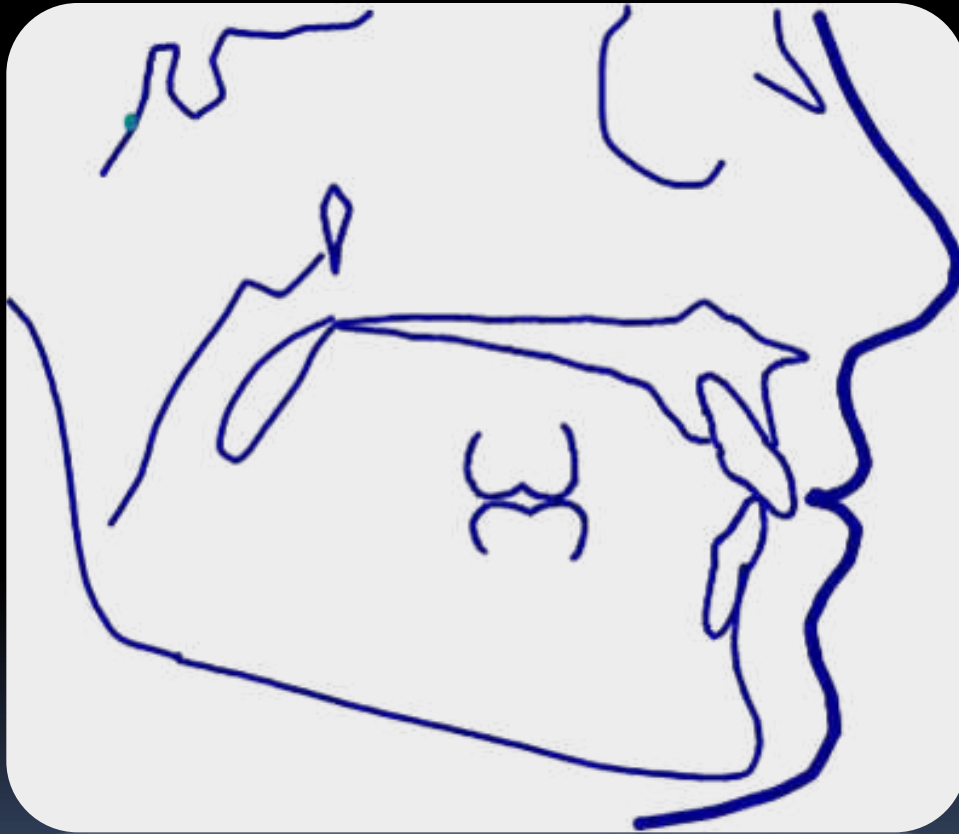# Tracing



# Standard Cephalometric Landmarks



# Structures to be Traced





# LANDMARKS

Sella: Centre of sella turcica

Nasion: Most anterior point on frontonasal suture

Orbitale: Lowest point on infraorbital margin

ANS: Tip of ant nasal spine



PNS: Tip post nasal spine


Point A: Deepest midline point b/w ANS and prosthion

Point B :Deepest point in the bony outline b/w infradentale and pogonion

Pogonion :Most ant point on bony chin

Gnathion :Most anterior and inferior on bony chin

Menton : Lowest point on the bony outline of the md symphysis



Gonion: Most lateral external point at the junction of horizontal and ascending rami of the mandible

Articulare: Intersection post border of md and temporal bone

Porion :Upper most point on the EAM





# GOALS OF CEPHALOMETRIC ANALYSIS

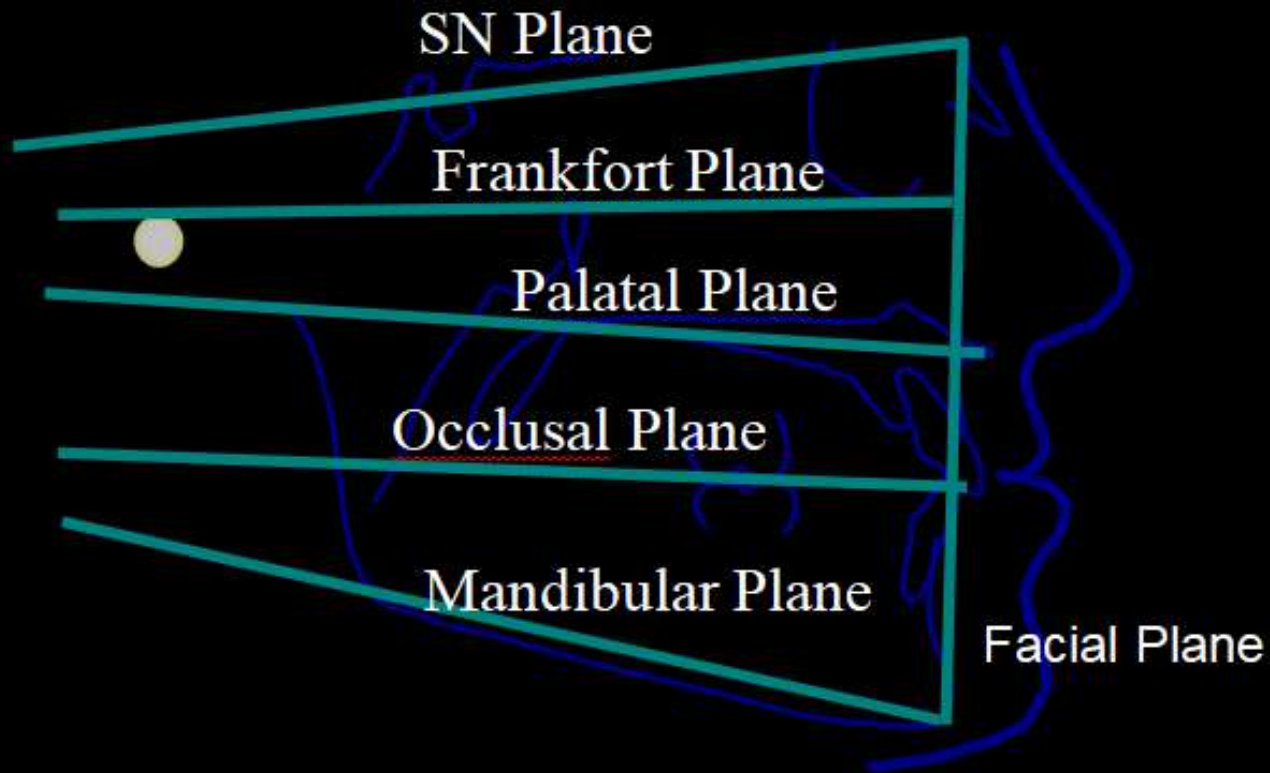
Evaluating relationships, both horizontal and vertical of 5 major functional components of the face:

- The cranial base
- The maxilla
- The mandible
- The maxillary dento-alveolus
- The mandibular dento-alveolus

# Radiograph



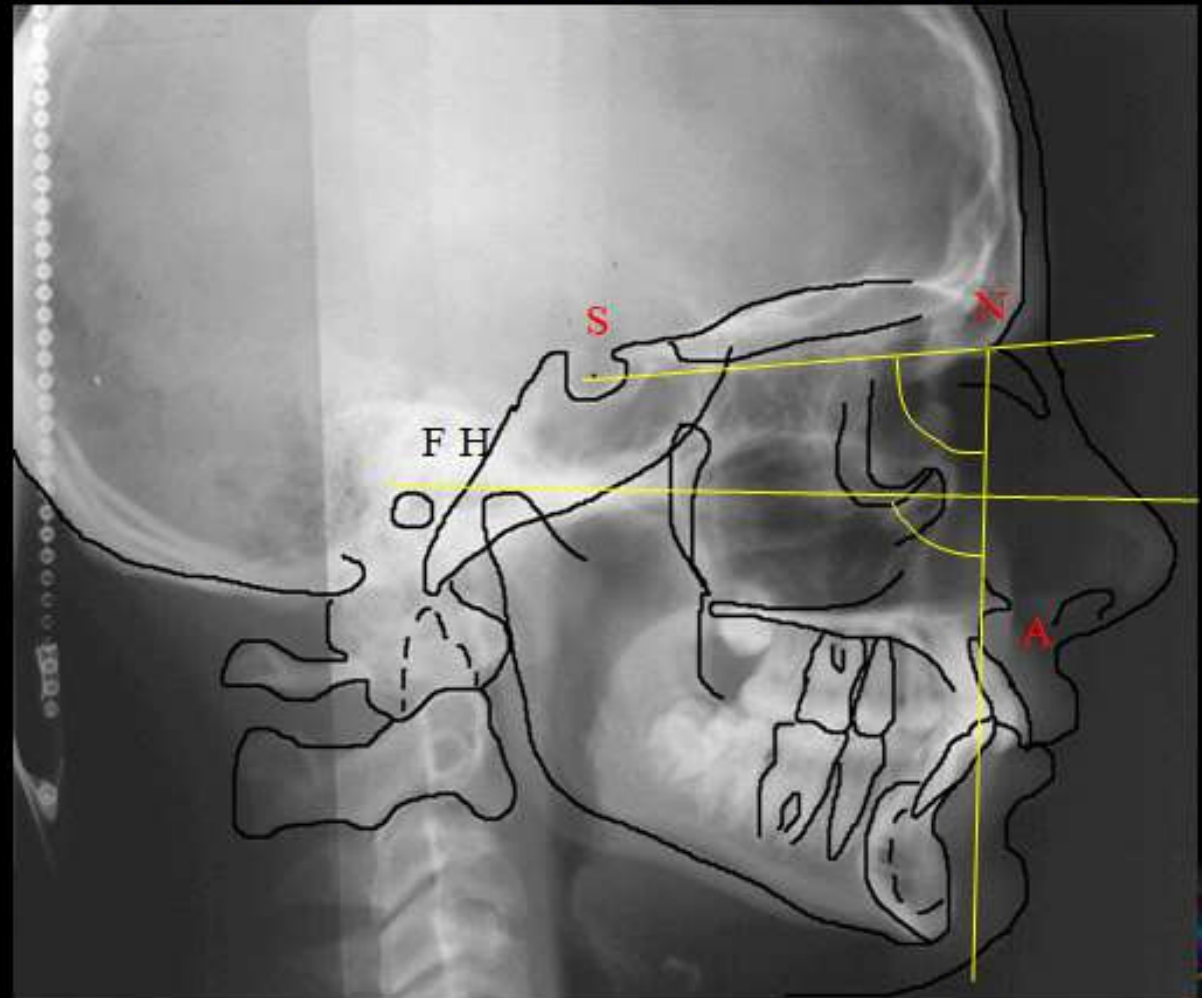
# Frequently Used Planes



NA TO FH  $90 \pm 3$  deg

# Sagittal Analysis

## Skeletal Horizontal - Maxilla



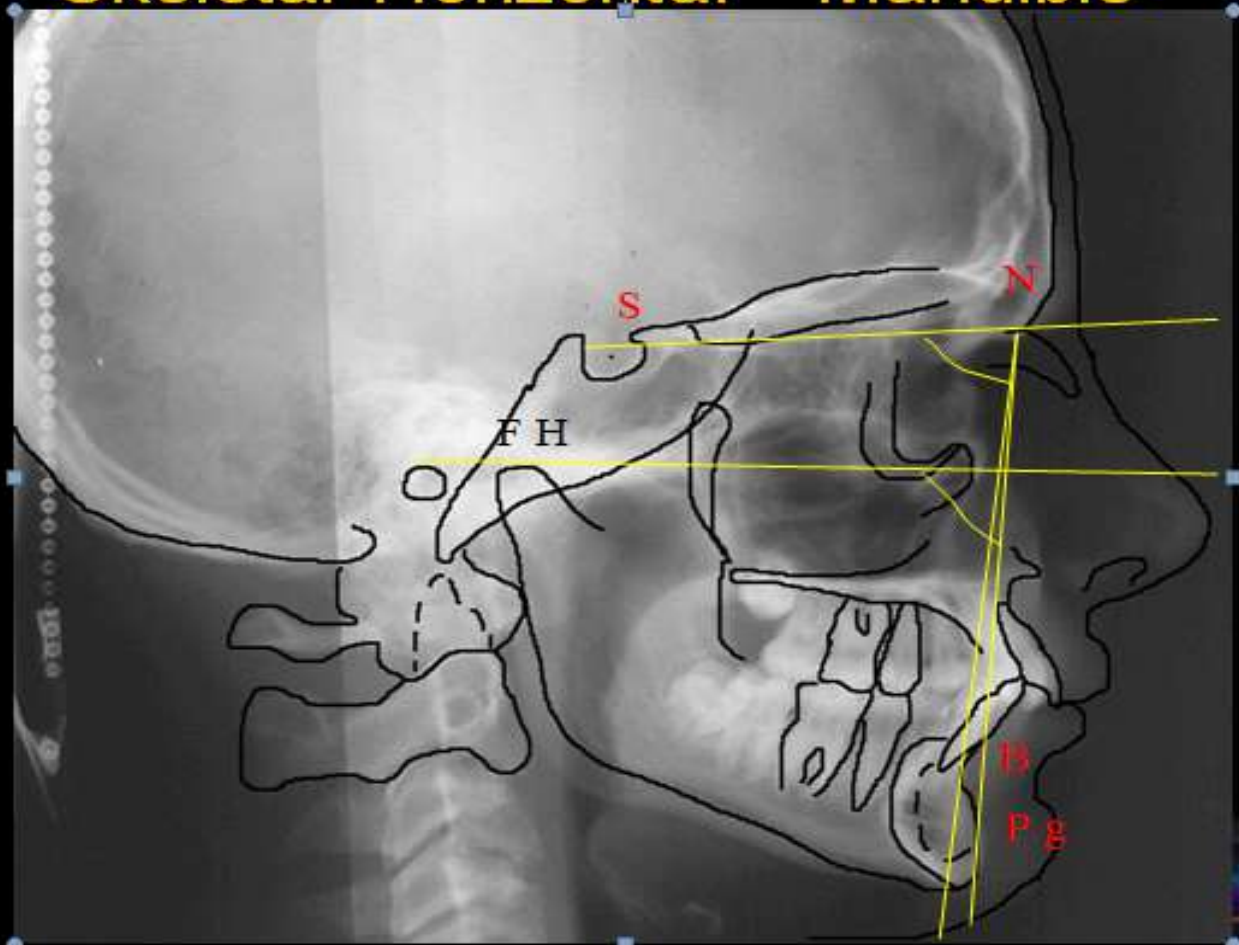
# SAGITTAL ANALYSIS

SNB  $80 \pm 2$  deg

N-PG TO FH  $87 \pm 4$  deg

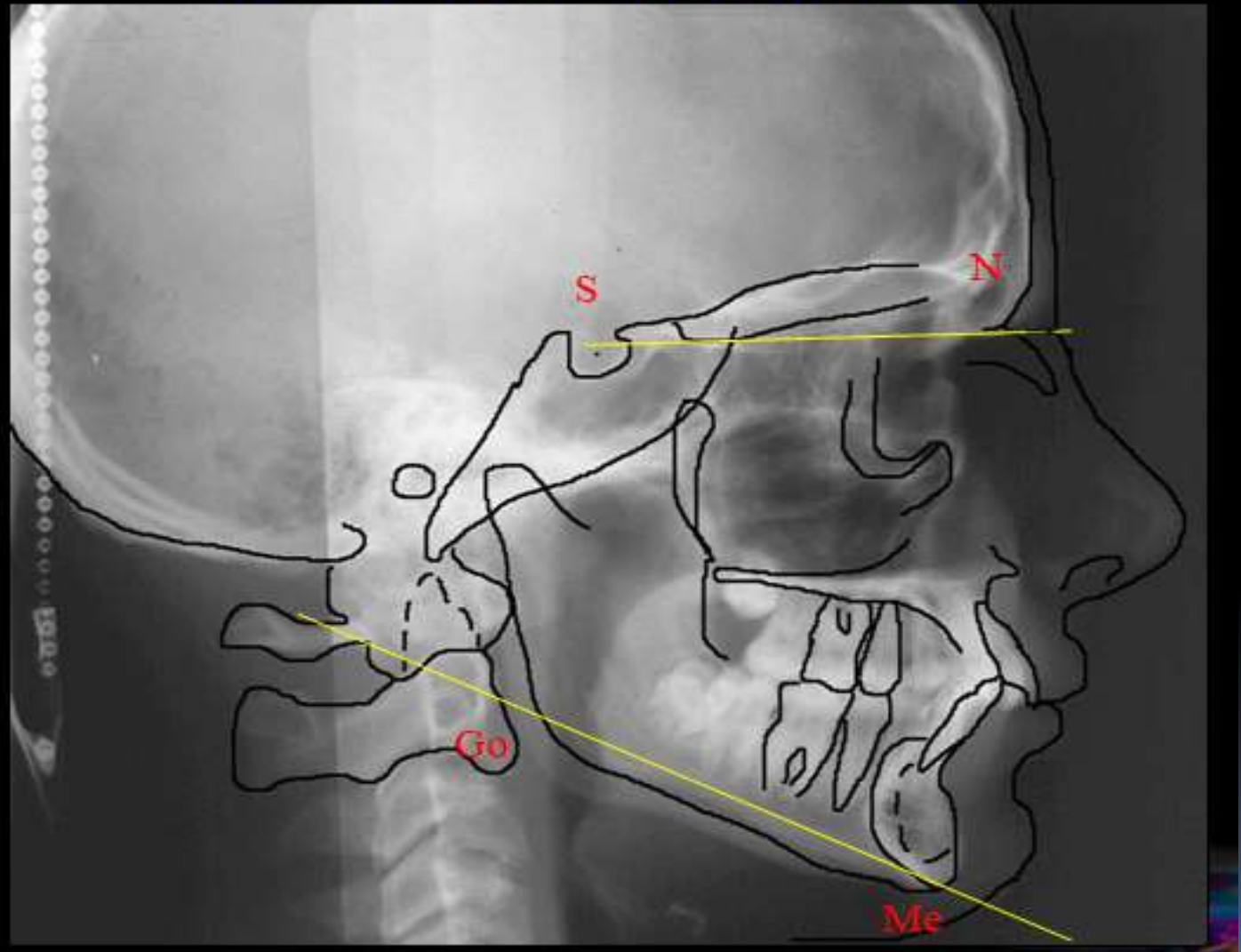
## Sagittal Analysis

### Skeletal Horizontal - Mandible



SN-Md Plane  $32 \pm 4$  deg

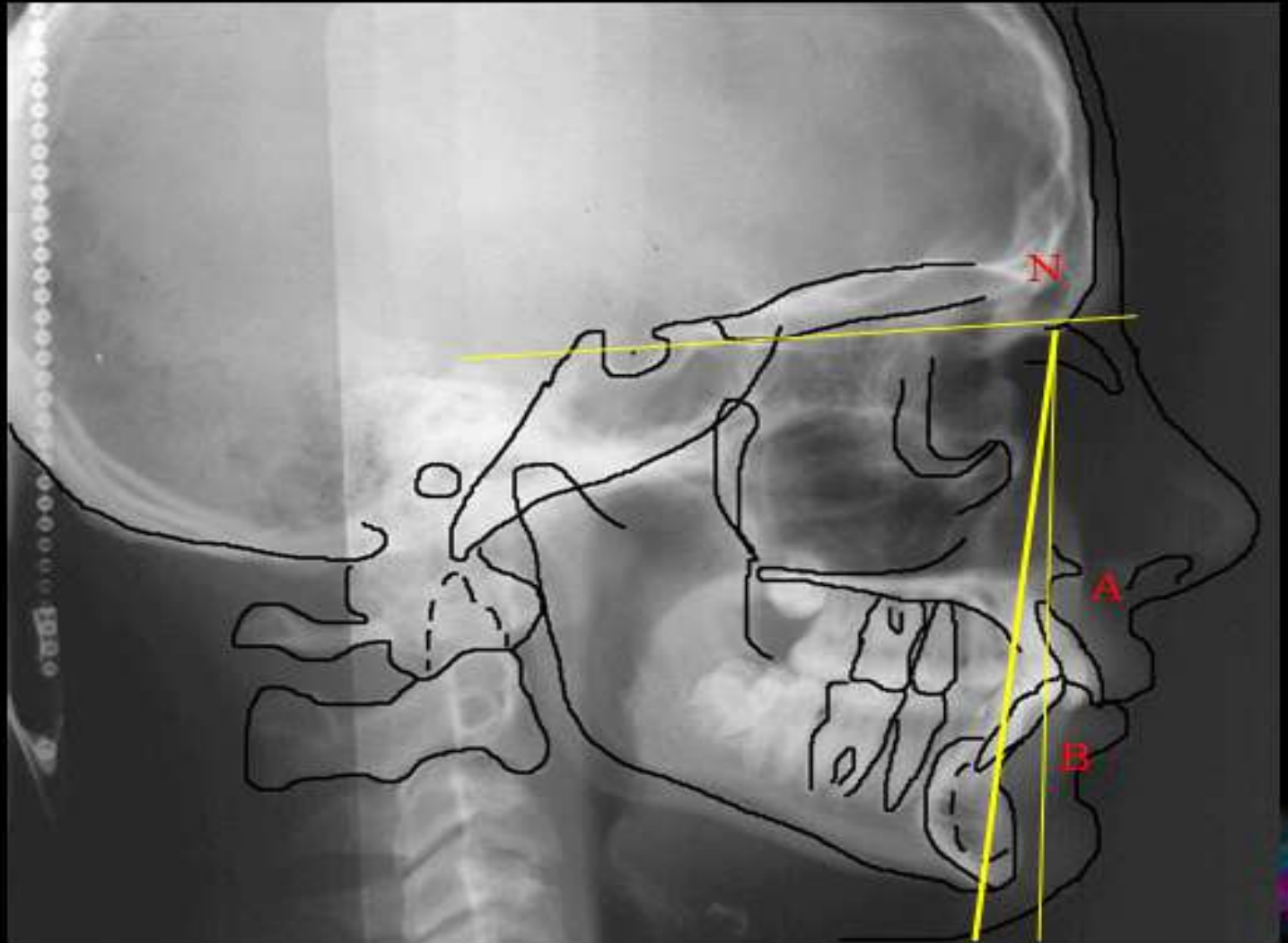
# SKELETAL VERTICAL



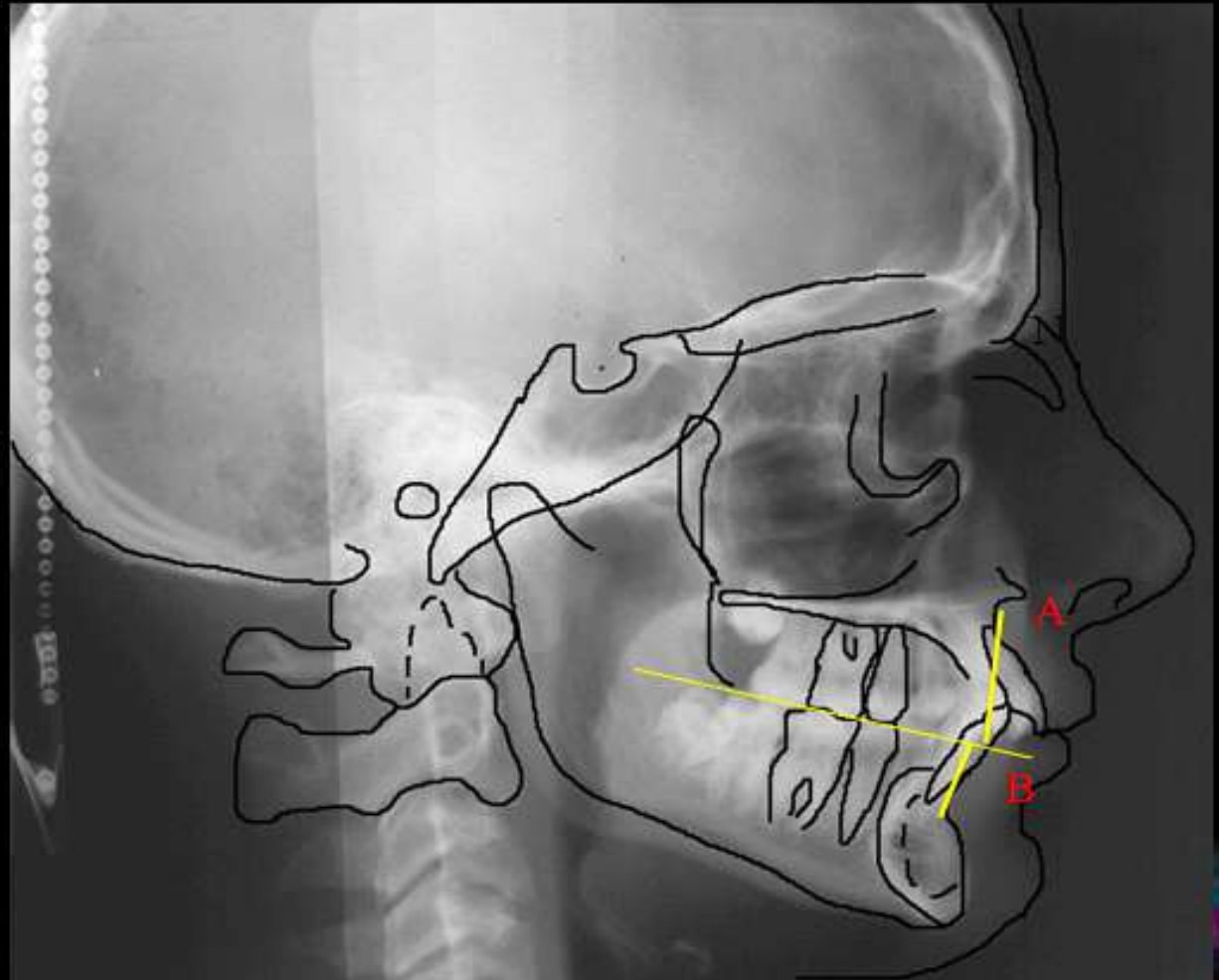


ANB  $2 \pm 2$  deg

# Sagittal Analysis Maxilla To Mandible

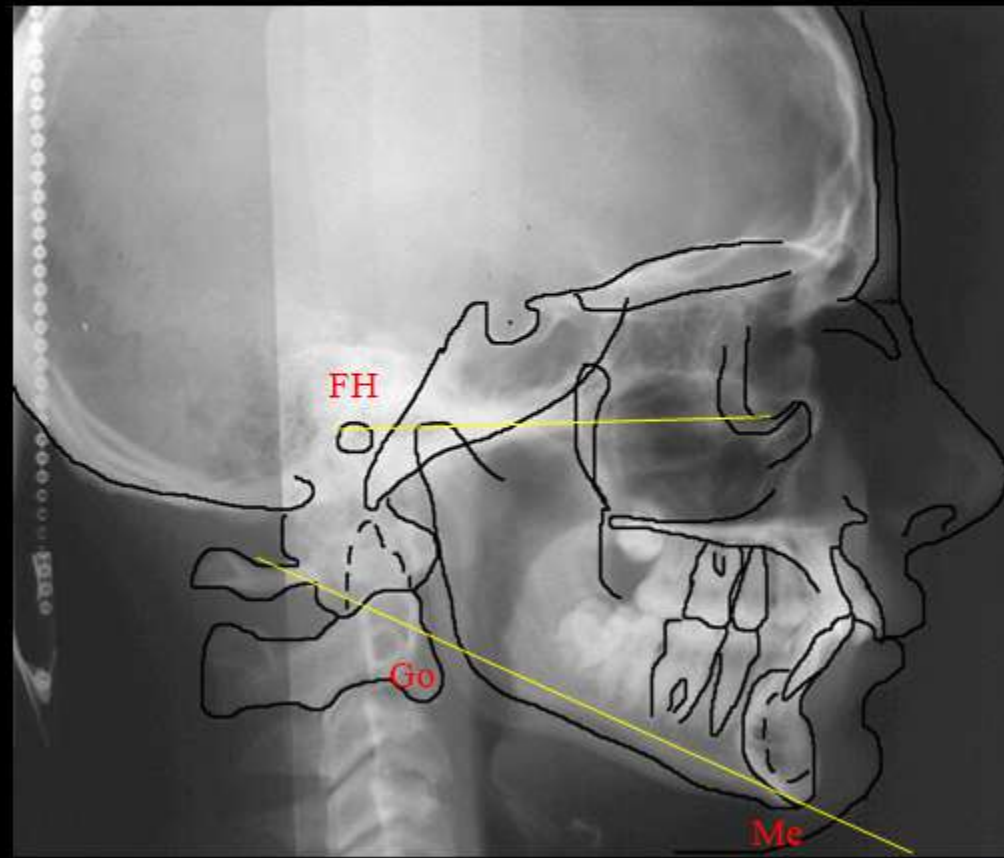


# Sagittal Analysis Maxilla and Mandible



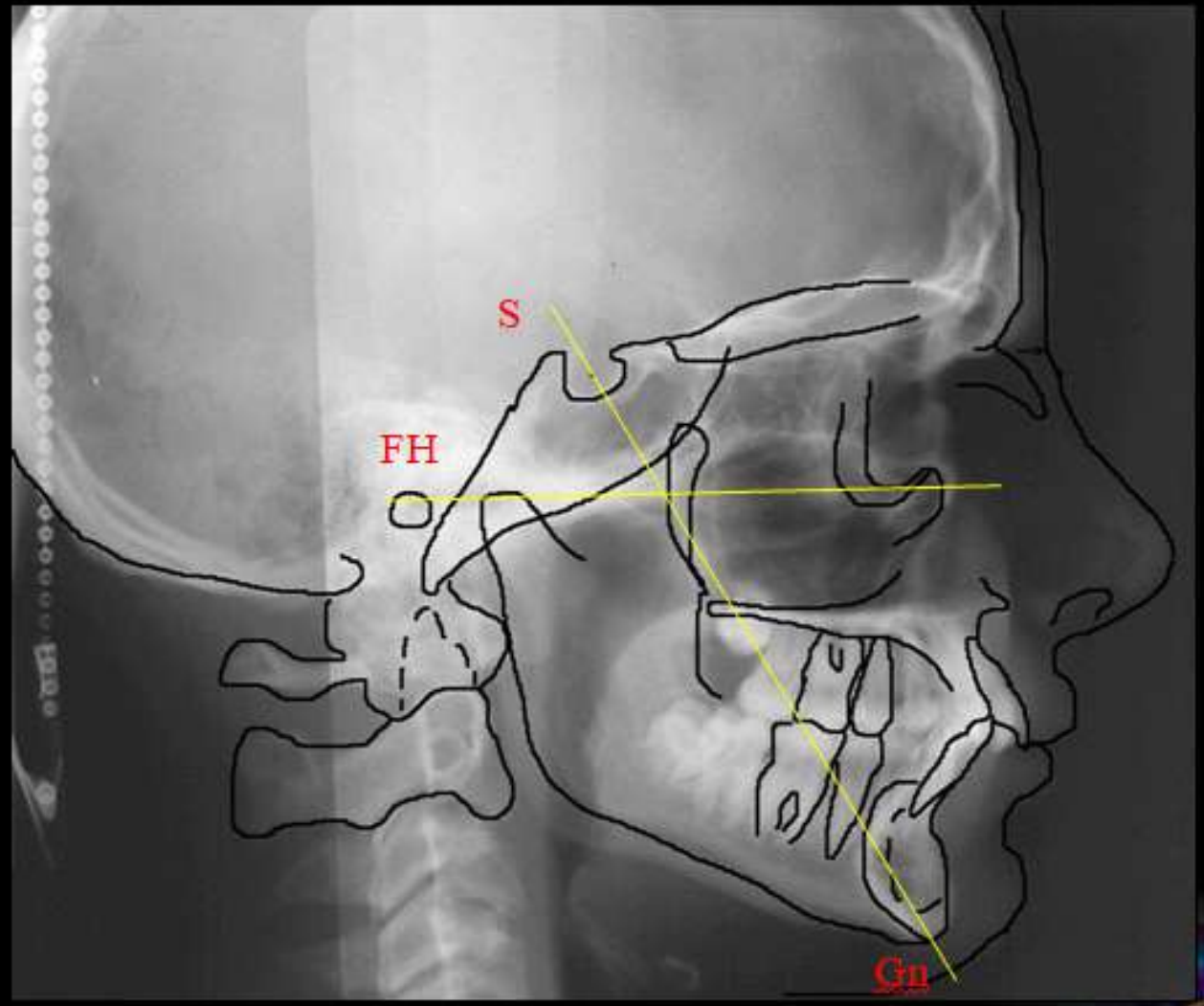
FH-Md Plane  $25 \pm 4$  deg

## SKELETAL VERTICAL



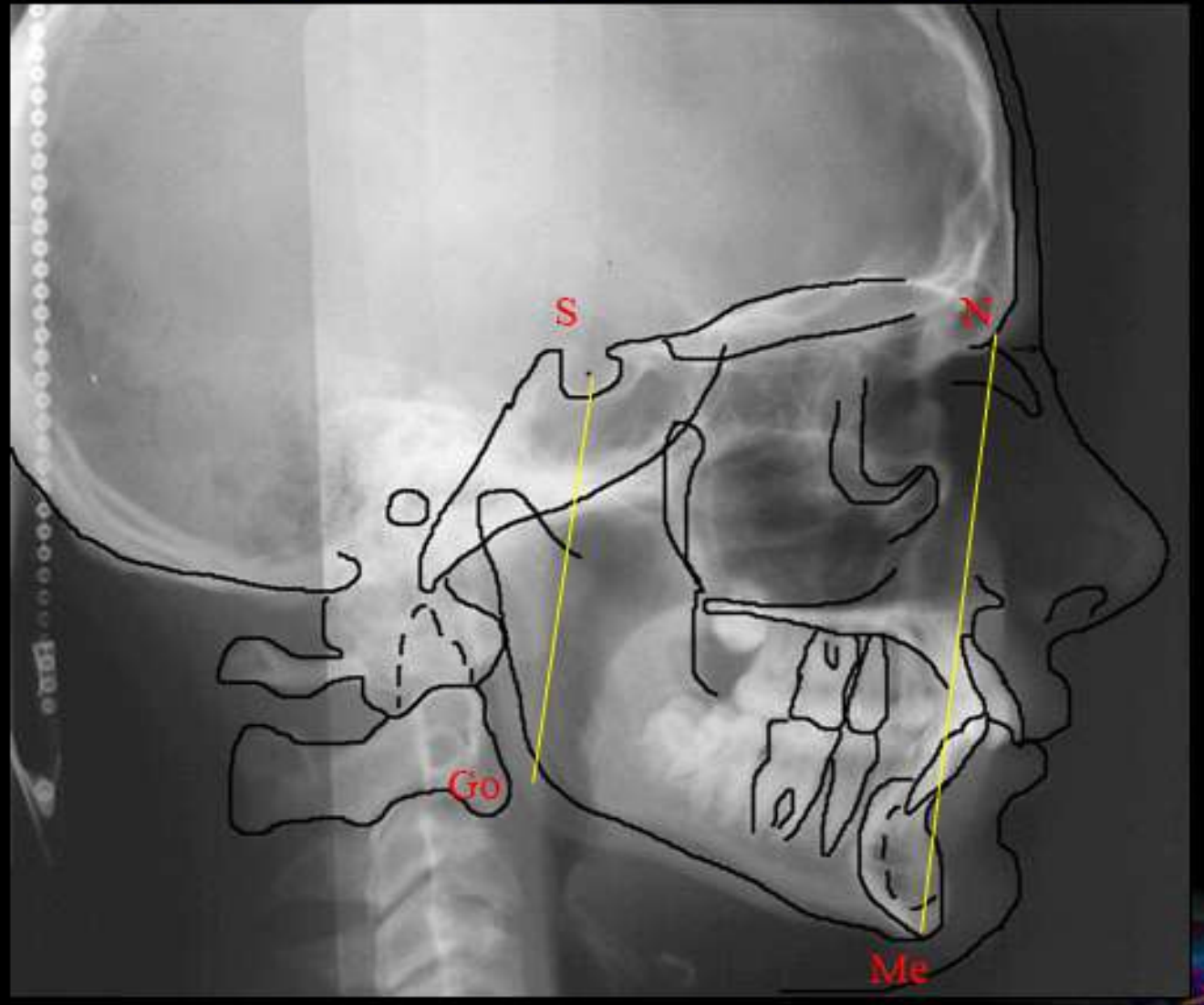
Y axis angle  $60 \pm 4$  deg

# SKELETAL VERTICAL



PFH/TAFH ratio 65 %

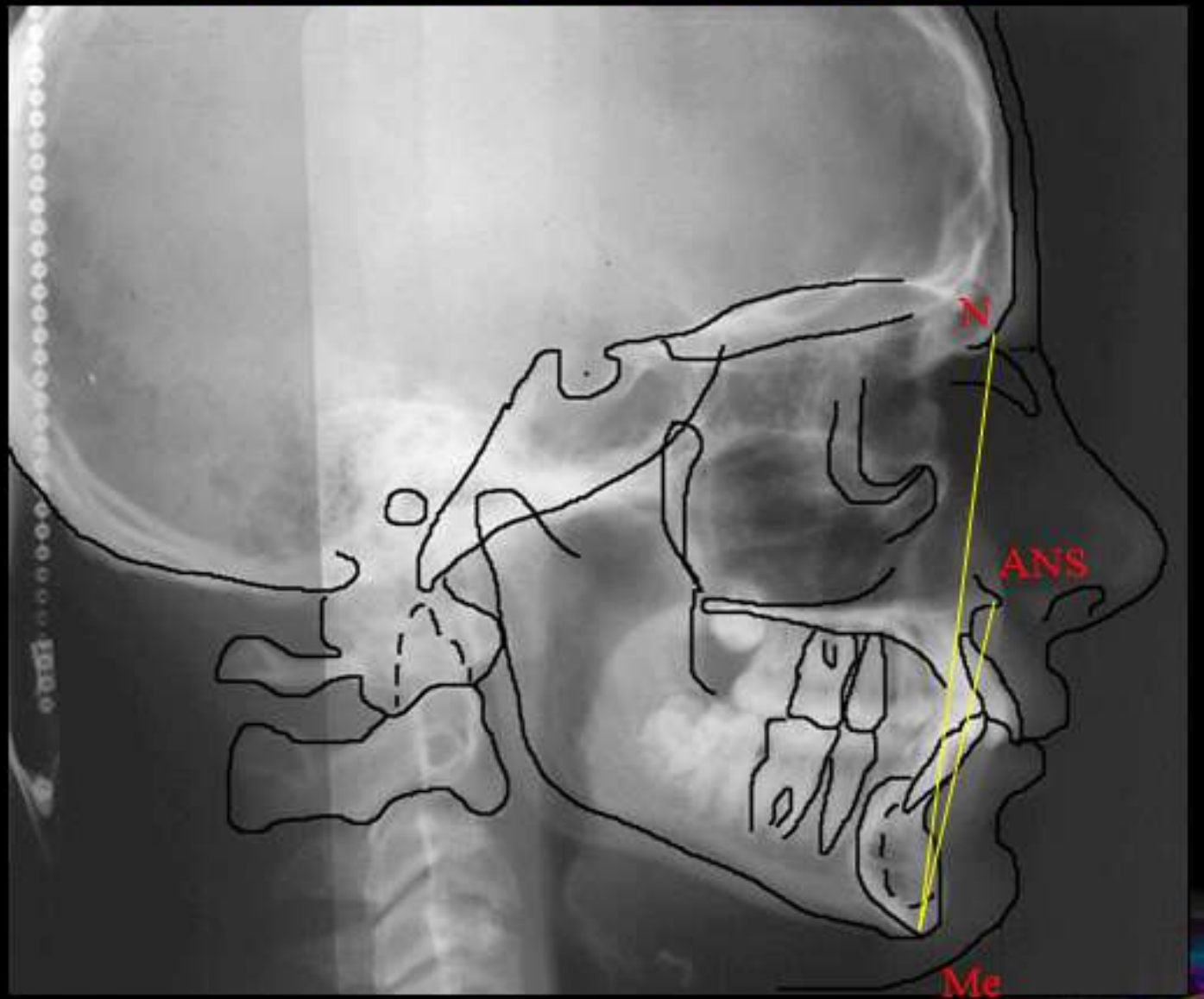
# SKELETAL VERTICAL





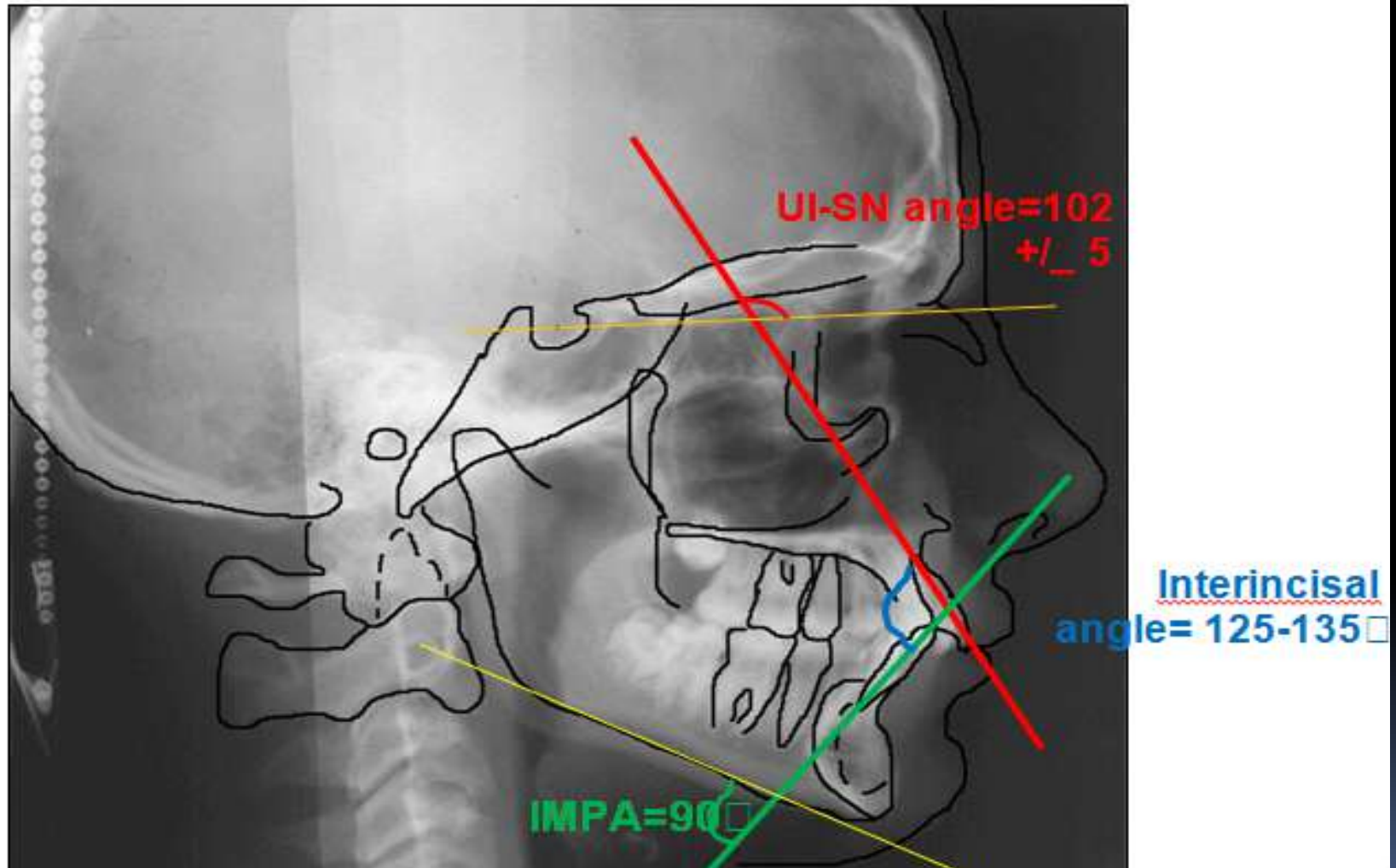
LFH/TAFH ratio 55 %

# SKELETAL VERTICAL

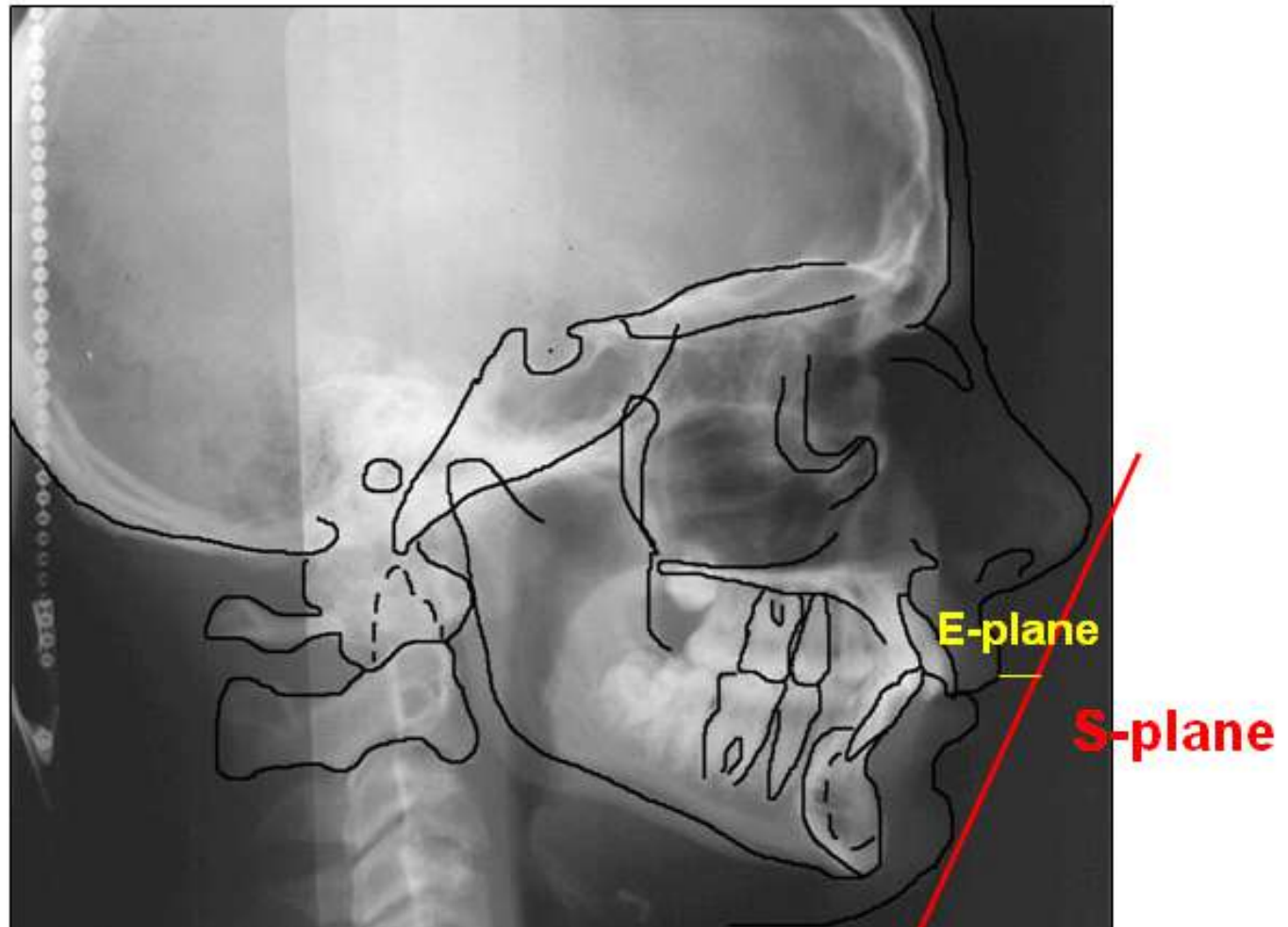



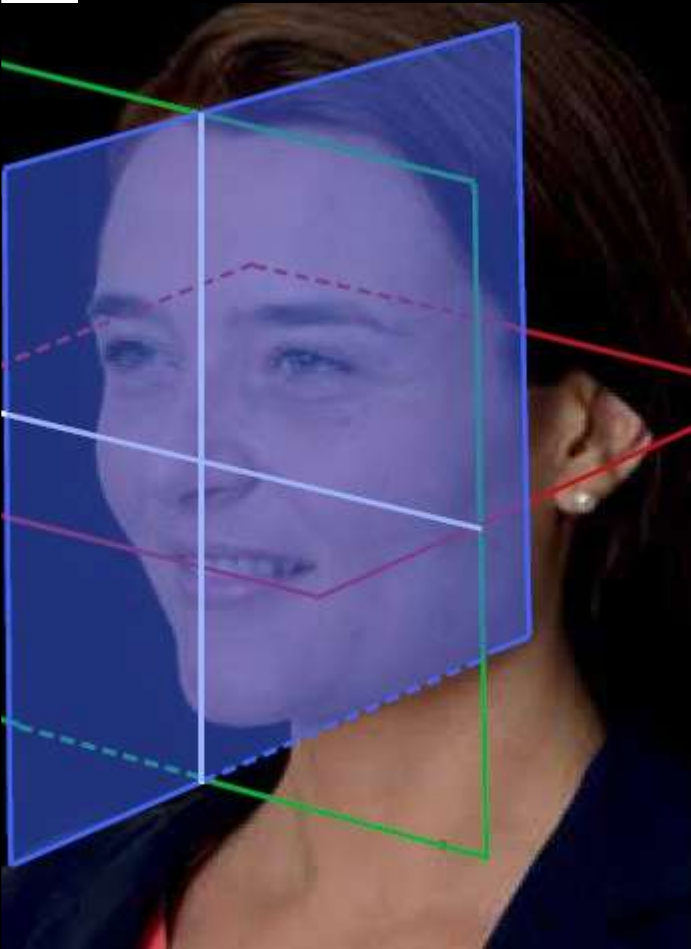


# Dental analysis



# Soft tissue analysis





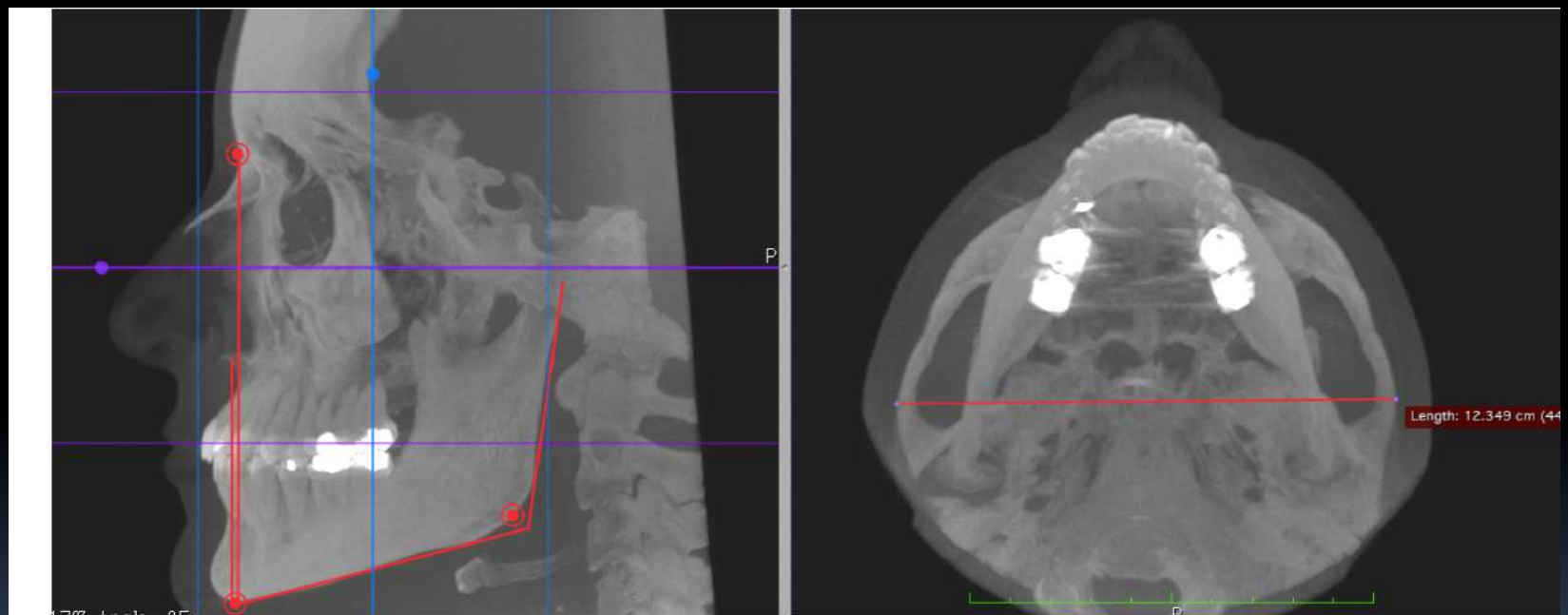
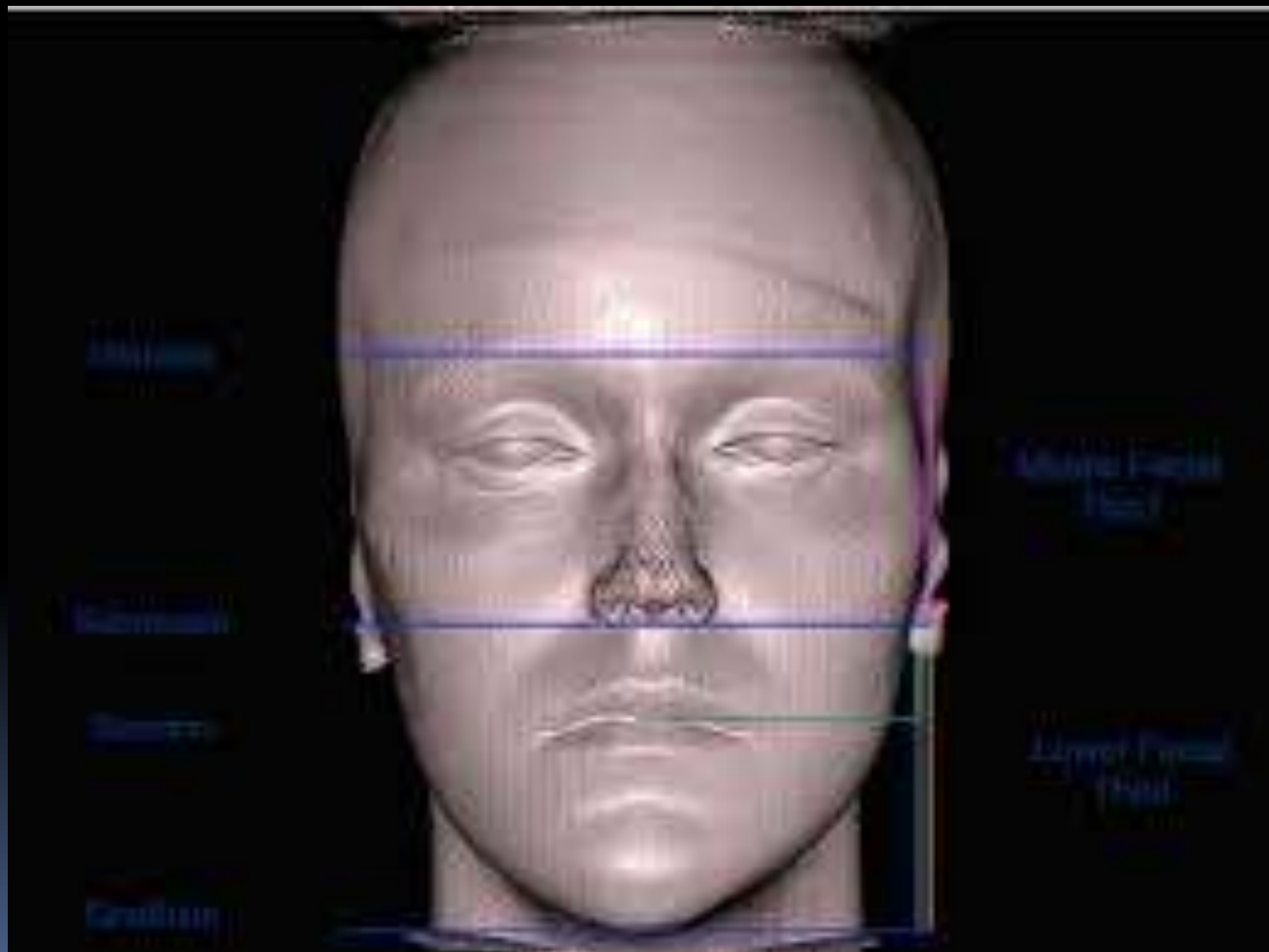


Figure 1. Facial pattern analysis in Computed tomography based on 3 facial features





Thank you





The background of the slide features a pattern of overlapping green hexagons of varying shades, creating a textured effect. A solid brown rectangle is positioned in the upper right corner. The main text area is white, with a thin green horizontal line at the bottom.

# Facial Aging, skin, muscles and bone

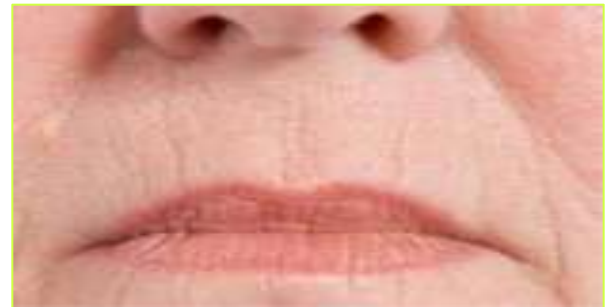Lect. Hussein T. Abed  
27\1\2021

# Facial aging

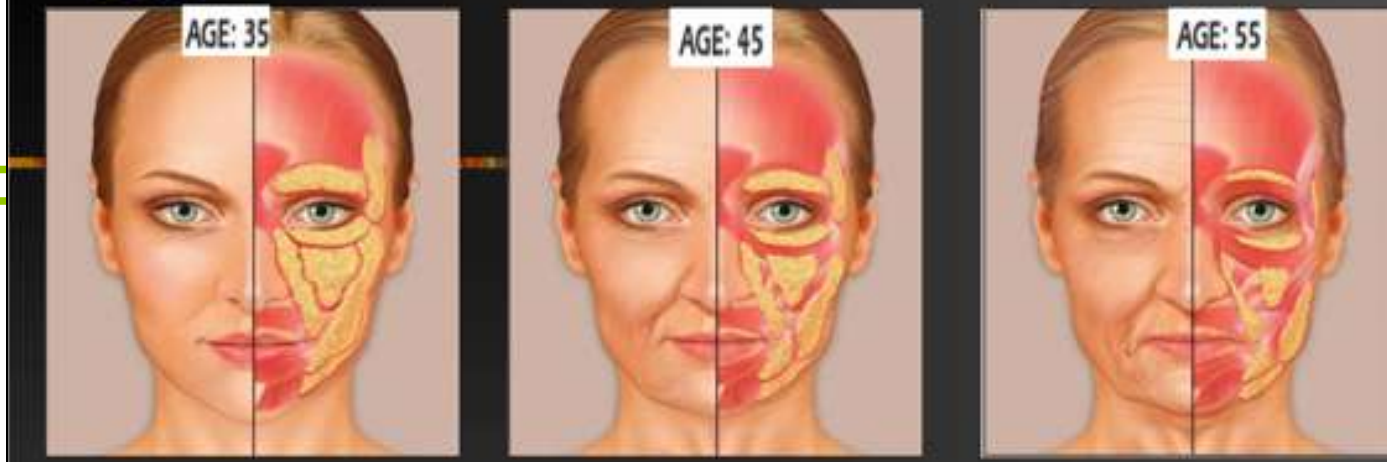- Begins with surface and subsurface structural changes in multiple facial tissue layers, including skin, fat, muscle and bone.
- Facial tissue layers age interdependently, contributing to overall facial appearance.
- Changes in one tissue layer have an effect on the other layers

# Skin

- With age, skin undergoes several changes.
  - More likely to wrinkle or sag
  - Reduction in collagen
  - Thinner
  - Drier
  - Less elastic



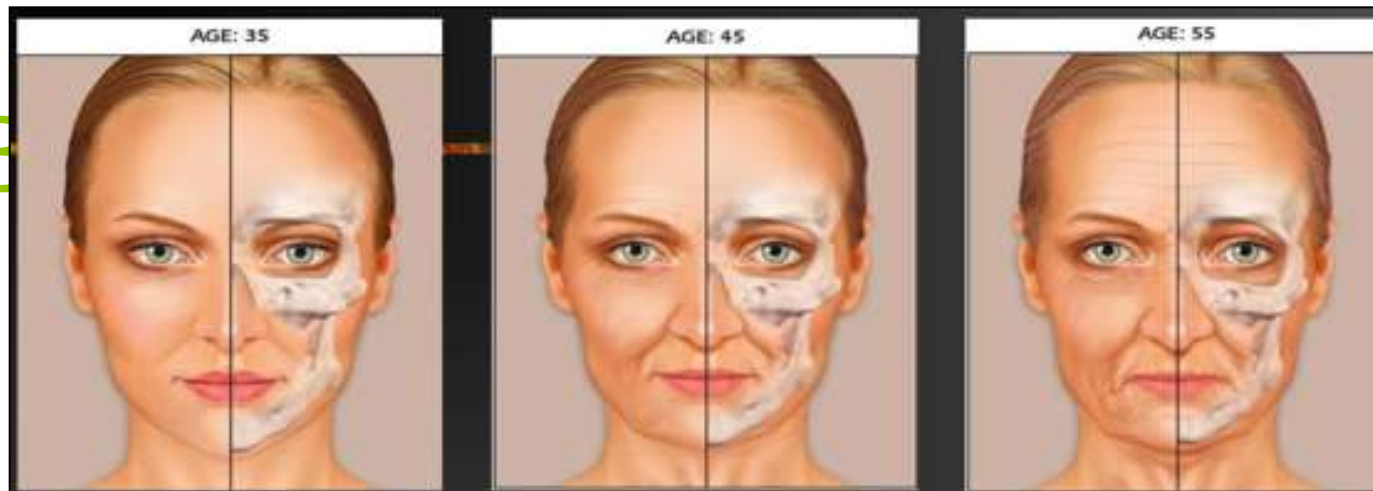## Fat



A youthful look depends on having the right amount of **facial fat** in right places.

**Redistribution, accumulation, and atrophy of fat lead to facial volume loss:**

- Some areas **lose fat** (forehead and cheeks).
- Other areas **gain fat** (mouth and jaw).
- Modification of the fat pads leads to contour deficiencies

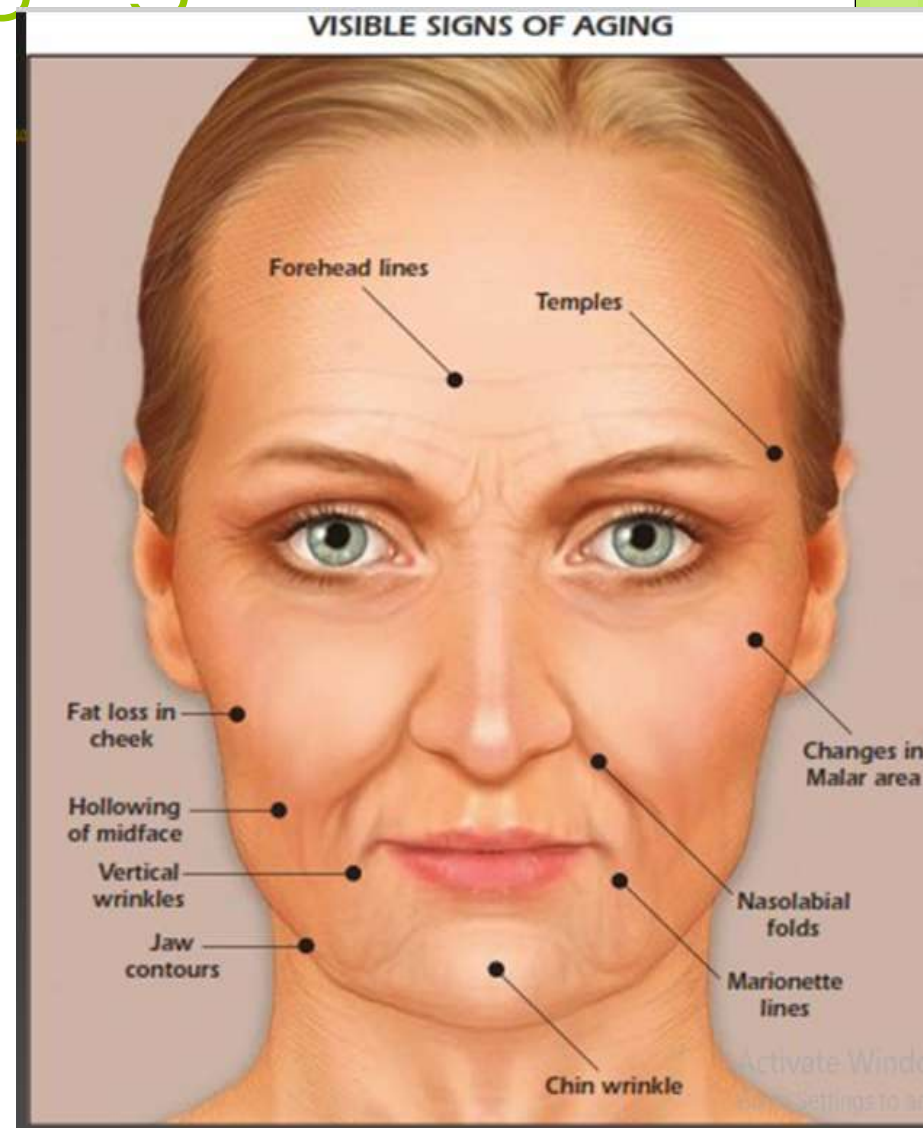


There is a significant loss of **facial bone** with age. Aging of the craniofacial skeleton may be due to changes in relative **dynamics** of bone expansion and bone resorption. Without the structural support of bone, there are noticeable changes in the other layers of overlying soft tissue and skin

# Signs of Facial Aging

Greater visibility of bony landmarks, lines and wrinkles

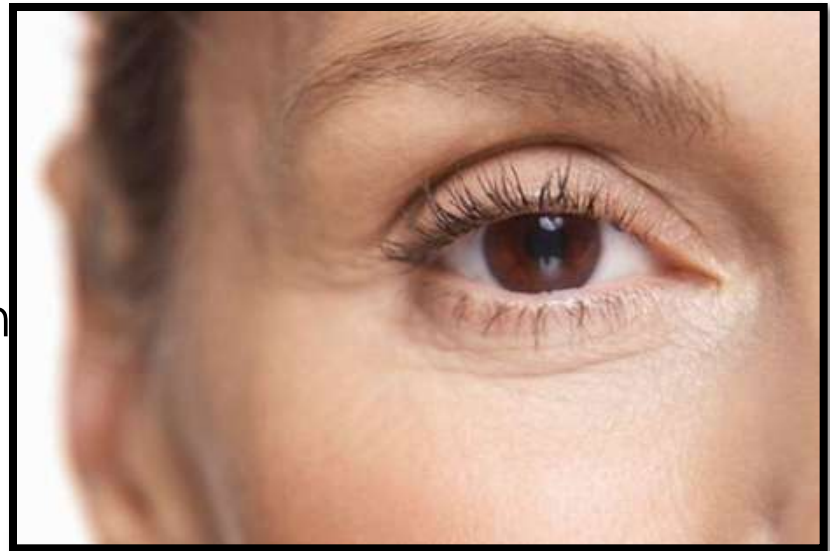- ✓ Prominence of transverse forehead lines
- ✓ Nasolabial folds become more prominent
- ✓ Hollowing of the mid-face (loose skin)
- ✓ Changes in area around the mouth (vertical wrinkles, lip thinning and flattening)
- ✓ Development of prejowl depression





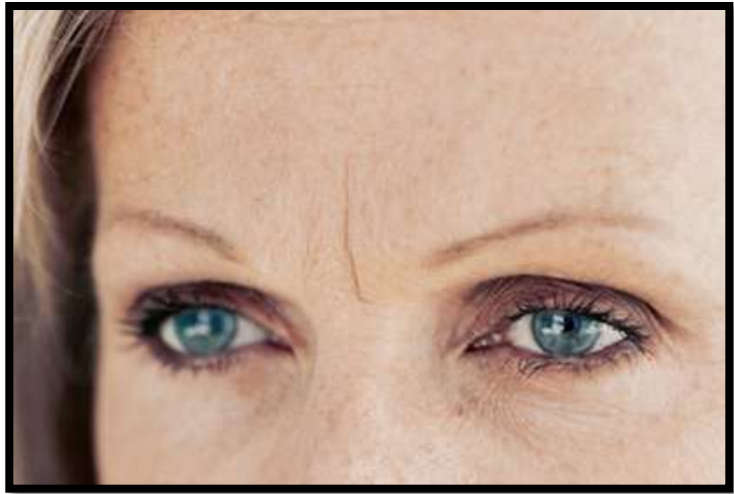# Fine lines around the eyes

are often the first visible sign of skin aging and are known as 'crow's feet' or 'laughter lines'. This is because the thinner skin in this area is more prone to developing lines than elsewhere on the face.



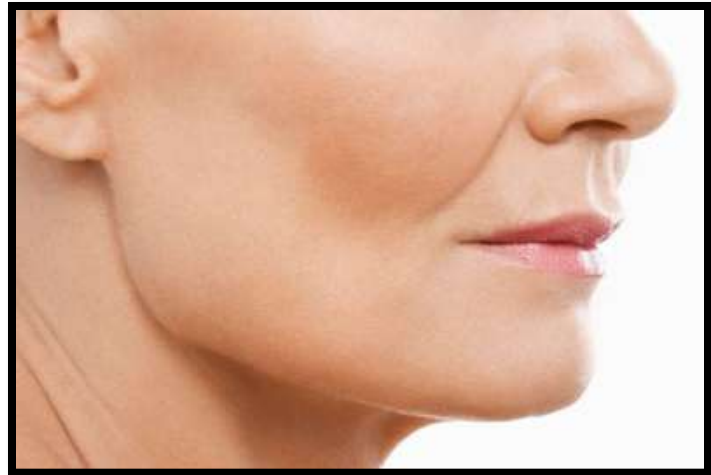# Wrinkles on the forehead

deepen over time  
horizontal lines and  
furrows between the  
brows. These start as  
'mimic wrinkles' and  
are partly caused by  
facial expressions.  
They deepen over  
time.



# nasolabial folds

These are known as nasolabial folds. The appearance of these wrinkles can be linked to a loss of volume as they are also a sign of sagging skin.



## Epidermis:

Stratum corneum

Stratum lucidum

Stratum granulosum

Stratum spinosum

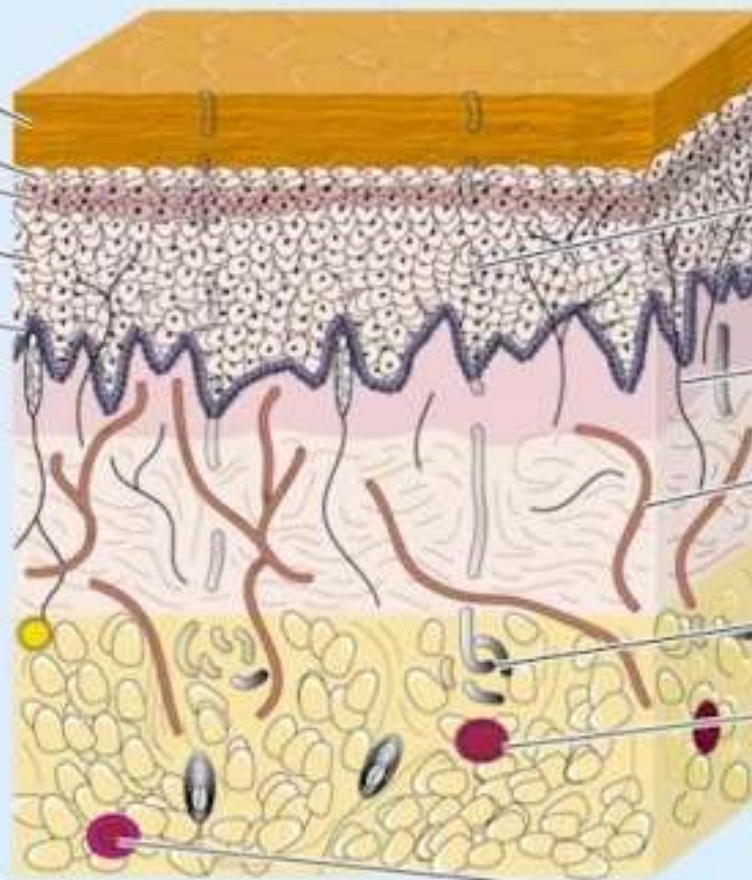Stratum basale

Papillary

## Dermis

Reticular

## Subcutaneous fatty tissue



Sweat duct

Nerve

Capillary

Sweat  
gland

Vein

Artery

# Aging

- ◉ **INTRINSIC SKIN AGING** (chronologic aging) or normal aging
- ◉ **EXTRINSIC AGING**



# INTRINSIC SKIN AGING

## (chronologic aging)

- **Inevitable** natural aging process that occurs in all people
- Occurs as part of a pre-programmed degeneration within cells and extracellular matrix in all skin layers.
- Although begin in 20's, visible signs are not apparent for many decades.
- Intrinsic aging proceeds at highly variable rates between different people



- Aged skin has increased rigidity
- Important in age related loss of elasticity of the skin.
- Older individuals are more susceptible to vitamin D3 deficiency in absence of regular sun exposure
- Decreased levels of estrogen are associated with loss of collagen and increased wrinkling

# INTRINSIC SKIN CHANGES

- **Epidermis**

- Keratinocytes demonstrate slower turnover.
- Keratin sloughs more slowly with thickening of keratin layer.
- Melanocytes decrease in number and produce less melanin.
- Uneven melanin pigment distribution.
- Flattening of the epidermis-dermis junction. Prone to blistering.

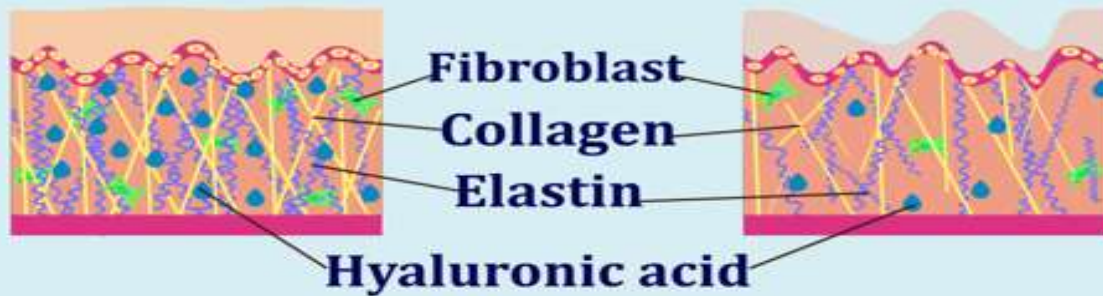# Dermis

- **Fibroblasts** – Decreased number and less collagen production.
- **Collagen** – Decreased quantity.  
Abnormal, weakened structure.
- **Elastin** – Thickened fibers with less elasticity.
- **Matrix** – Decreased quantity.
- **Blood vessels** – dilated, thinned and weakened walls, prone to rupture.

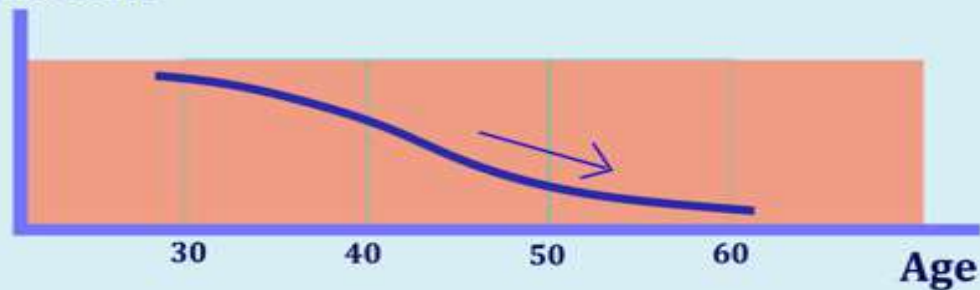
## Skin Changes with Aging

**Young skin**

**Aged skin**

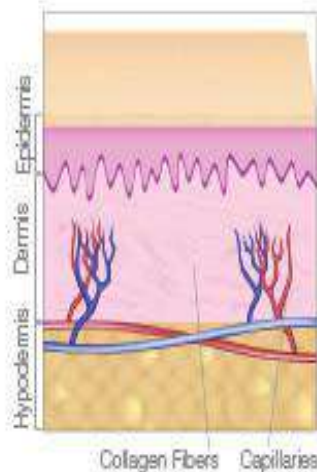


**Hyaluronic acid**  
**Collagen**  
**Elastin**



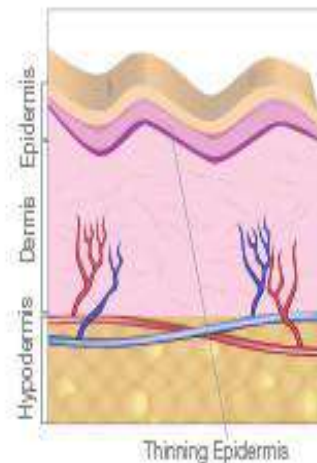
# Subcutaneous Layer

- ◉ Fat loss and thinning..
- ◉ Fewer blood vessels.
- ◉ Sweat glands - decreased.
- ◉ Sebaceous glands – Fewer with less sebum production.
- ◉ Hair shafts – fewer and thinner with less pigment.



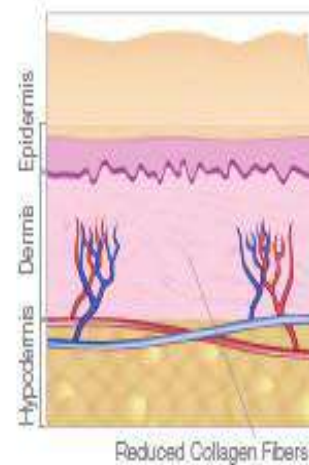
## 20s

Environmental damage and constant exposure to damaging UV rays begin to take their toll on skin. Free radicals attack the skin's structural integrity. Cell renewal and turnover rates begin to decline.



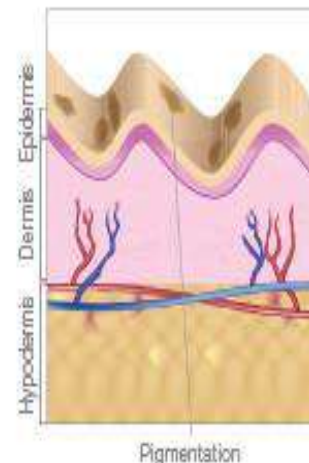
## 40s

By our 40s, the skin is thinner, barrier lipids are not as pronounced and dehydration can be an issue. More prominent signs of skin aging may also appear, such as dark spots and significant dullness.



## 30s

In our 30s, collagen and elastin degrade, resulting in our first wrinkles. Cell renewal and turnover continue to decline, leading to a duller complexion and uneven skin tone.



## 50s+

The protective barrier lipid layer lessens, leading to less efficiency in retaining moisture and more potential for sensitivity and dehydration. Skin shows wrinkles, fine lines and pigmentation.



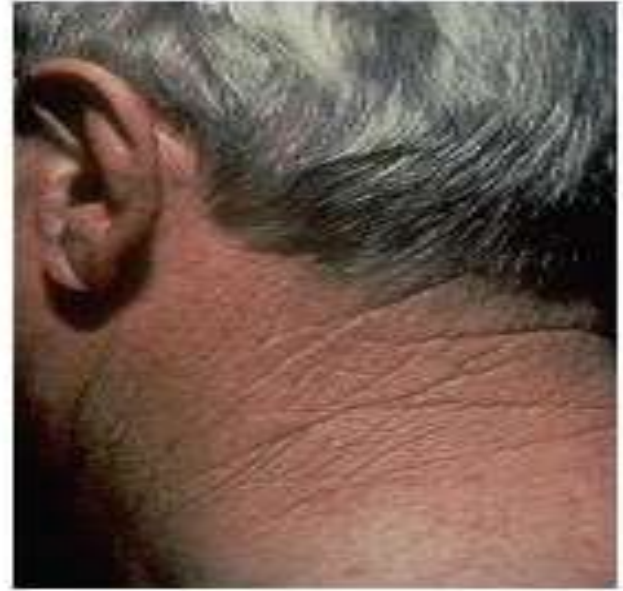# EXTRINSIC AGING

Outside factors that accelerate intrinsic aging.

- Photoaging
- Smoking
- Malnutrition
- Hormonal Disorders
- Chronic Disease States
- Repetitive facial expressions
- Gravity

# Photoaging

- Photoaged skin shows
- deep coarse wrinkling,
- excessive dryness,
- severe brown spots
- dry leathery texture when compared to intrinsically aged skin

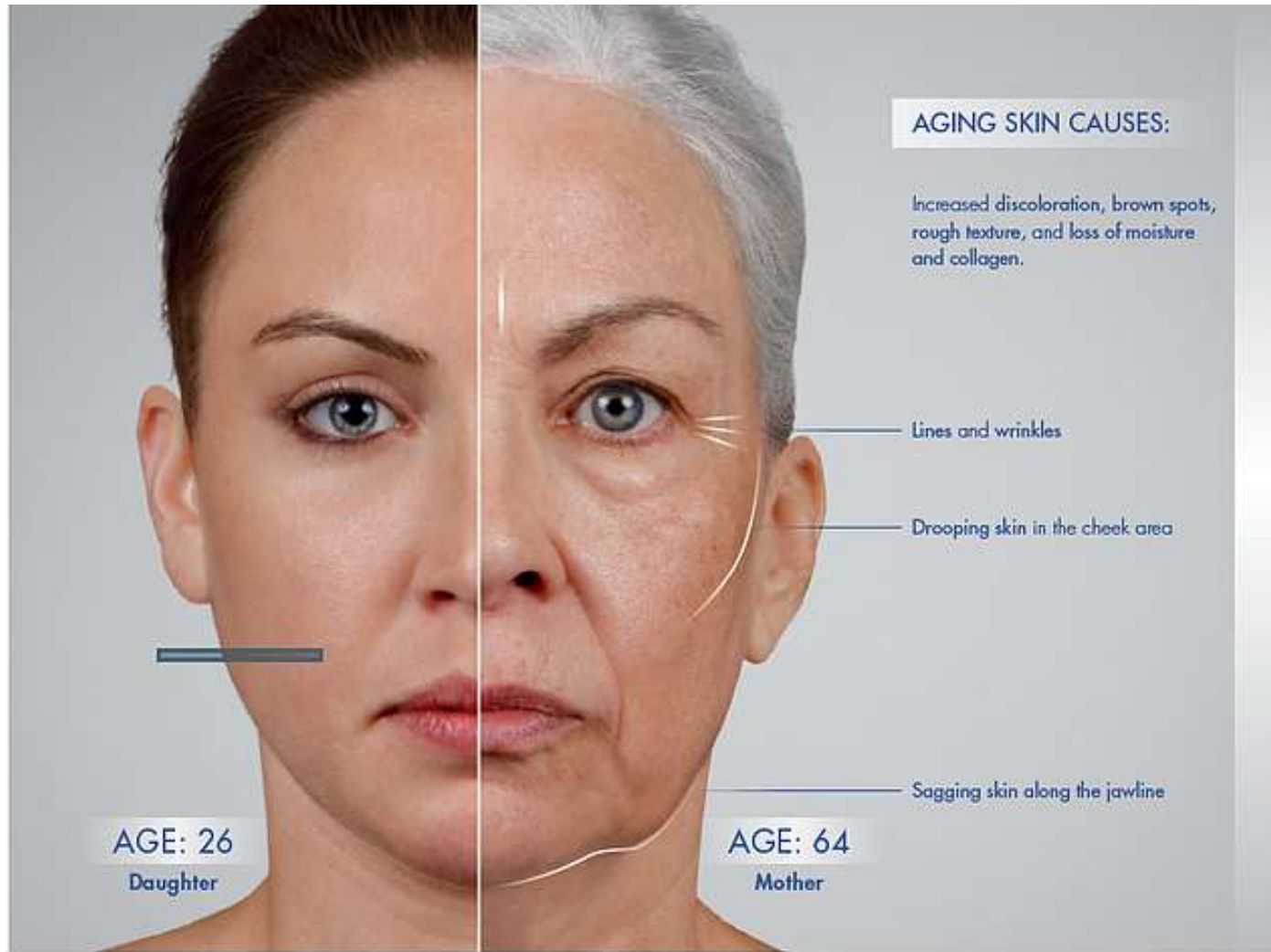

# Smoking

- Acts primarily **via vasoconstriction** of blood vessels going to and through skin layers.
- Decreased blood flow results in
  - decreased **nutrients**,
  - decreased **oxygen** supply
  - increased inflammatory **byproducts** (free radical oxidation byproducts).
- Net effect
  - decreased **collagen production** and turnover,
  - **poor quality** collagen and elastin,
  - decreased quantity of **matrix components** and less gland secretions.

# Gravity

- Constantly pulls on bodies.
- In 50s, when skin's elasticity declines dramatically, effects of gravity become evident.
- Causes tip of nose to droop, ears to elongate, eyelids to fall, jowls to form, and upper lip to disappear while lower lip becomes more pronounced



### AGING SKIN CAUSES:

Increased discoloration, brown spots, rough texture, and loss of moisture and collagen.

Lines and wrinkles

Drooping skin in the cheek area

Sagging skin along the jawline

AGE: 26  
Daughter

AGE: 64  
Mother









Thank you



The background of the slide features a pattern of overlapping green hexagons of varying shades, creating a textured effect. A solid brown rectangle is positioned in the upper right corner. The main text area is white, with a thin green horizontal line at the bottom.

# Facial Aging, skin, muscles and bone

Lect. Hussein T. Abed  
27\1\2021

# Facial aging

- Begins with surface and subsurface structural changes in multiple facial tissue layers, including skin, fat, muscle and bone.
- Facial tissue layers age interdependently, contributing to overall facial appearance.
- Changes in one tissue layer have an effect on the other layers

# Skin

- With age, skin undergoes several changes.
  - More likely to wrinkle or sag
  - Reduction in collagen
  - Thinner
  - Drier
  - Less elastic



## Fat



A youthful look depends on having the right amount of **facial fat** in right places.

**Redistribution, accumulation, and atrophy of fat lead to facial volume loss:**

- Some areas **lose fat** (forehead and cheeks).
- Other areas **gain fat** (mouth and jaw).
- Modification of the fat pads leads to contour deficiencies



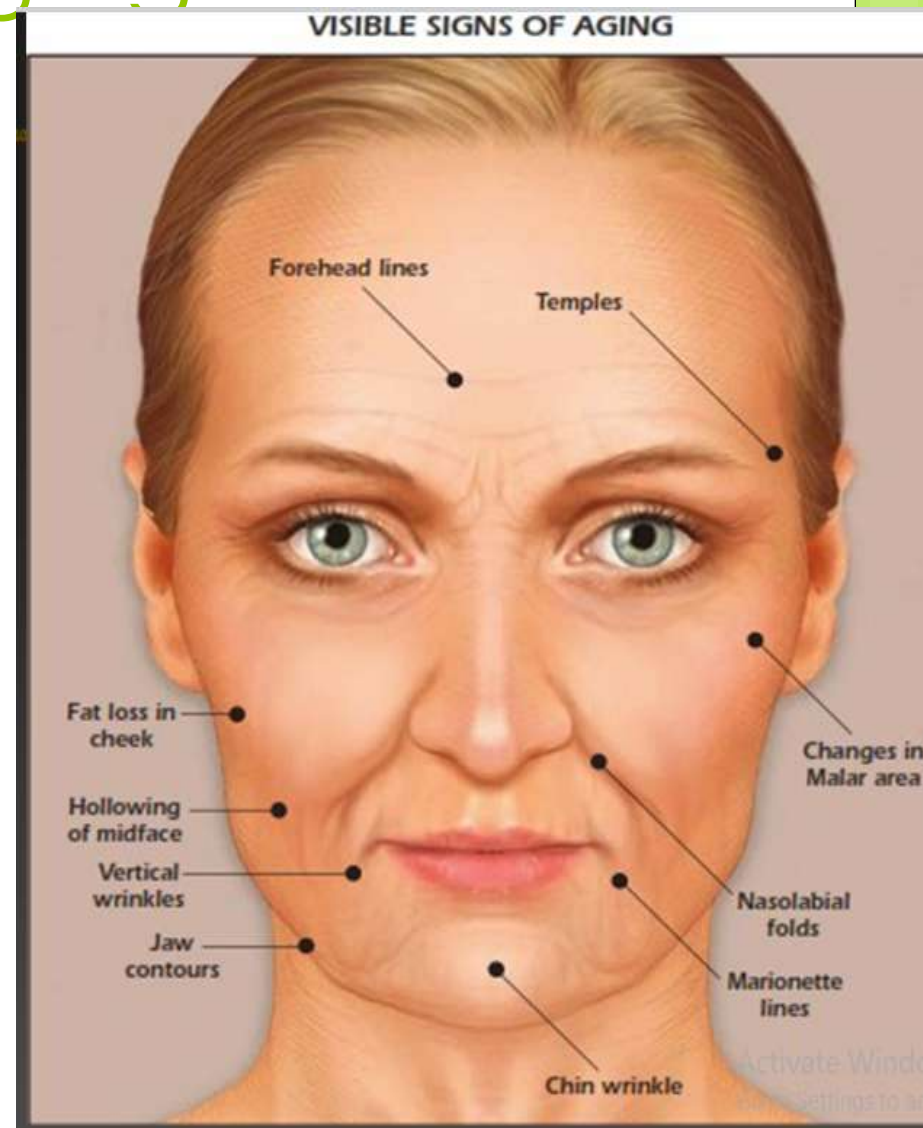


There is a significant loss of **facial bone** with age. Aging of the craniofacial skeleton may be due to changes in relative **dynamics** of bone expansion and bone resorption. Without the structural support of bone, there are noticeable changes in the other layers of overlying soft tissue and skin

# Signs of Facial Aging

Greater visibility of bony landmarks, lines and wrinkles

- ✓ Prominence of transverse forehead lines
- ✓ Nasolabial folds become more prominent
- ✓ Hollowing of the mid-face (loose skin)
- ✓ Changes in area around the mouth (vertical wrinkles, lip thinning and flattening)
- ✓ Development of prejowl depression



# Fine lines around the eyes

are often the first visible sign of skin aging and are known as 'crow's feet' or 'laughter lines'. This is because the thinner skin in this area is more prone to developing lines than elsewhere on the face.



# Wrinkles on the forehead

deepen over time  
horizontal lines and  
furrows between the  
brows. These start as  
'mimic wrinkles' and  
are partly caused by  
facial expressions.  
They deepen over  
time.



# nasolabial folds

These are known as nasolabial folds. The appearance of these wrinkles can be linked to a loss of volume as they are also a sign of sagging skin.





## Epidermis:

Stratum corneum

Stratum lucidum

Stratum granulosum

Stratum spinosum

Stratum basale

Papillary

## Dermis

Reticular

## Subcutaneous fatty tissue



Sweat duct

Nerve

Capillary

Sweat gland

Vein

Artery



# Aging

- ◉ **INTRINSIC SKIN AGING** (chronologic aging) or normal
- ◉ **EXTRINSIC AGING**



# INTRINSIC SKIN AGING

## (chronologic aging)

- **Inevitable** natural aging process that occurs in all people
- Occurs as part of a pre-programmed degeneration within cells and extracellular matrix in all skin layers.
- Although begin in 20's, visible signs are not apparent for many decades.
- Intrinsic aging proceeds at highly variable rates between different people

- Aged skin has increased rigidity
- Important in age related loss of elasticity of the skin.
- Older individuals are more susceptible to vitamin D3 deficiency in absence of regular sun exposure
- Decreased levels of estrogen are associated with loss of collagen and increased wrinkling

# INTRINSIC SKIN CHANGES

- **Epidermis**

- Keratinocytes demonstrate slower turnover.
- Keratin sloughs more slowly with thickening of keratin layer.
- Melanocytes decrease in number and produce less melanin.
- Uneven melanin pigment distribution.
- Flattening of the epidermis-dermis junction. Prone to blistering.

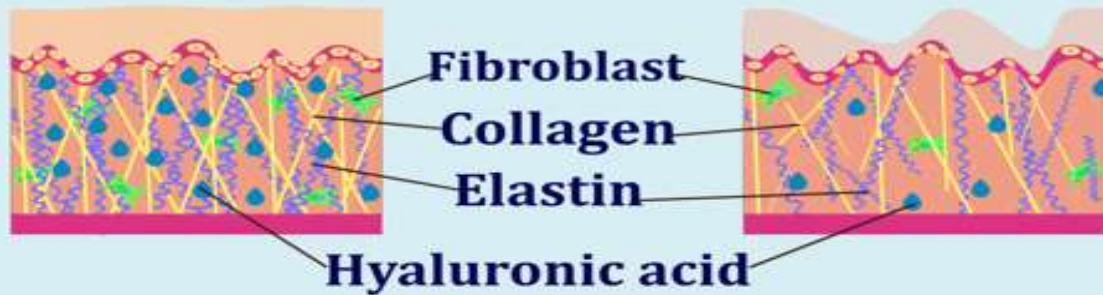# Dermis

- **Fibroblasts** – Decreased number and less collagen production.
- **Collagen** – Decreased quantity.  
Abnormal, weakened structure.
- **Elastin** – Thickened fibers with less elasticity.
- **Matrix** – Decreased quantity.
- **Blood vessels** – dilated, thinned and weakened walls, prone to rupture.

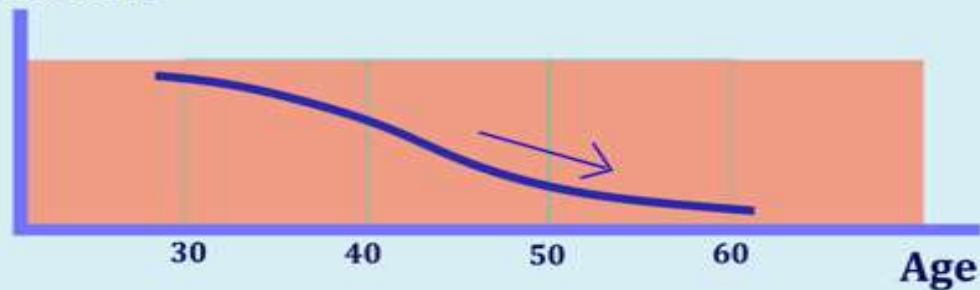
## Skin Changes with Aging

**Young skin**

**Aged skin**



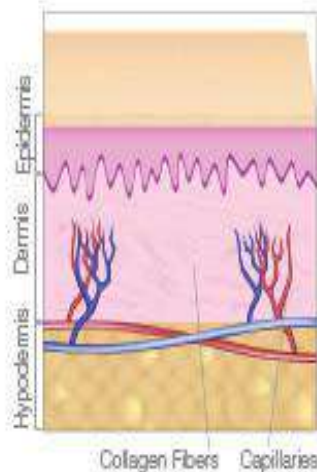
**Hyaluronic acid**  
**Collagen**  
**Elastin**





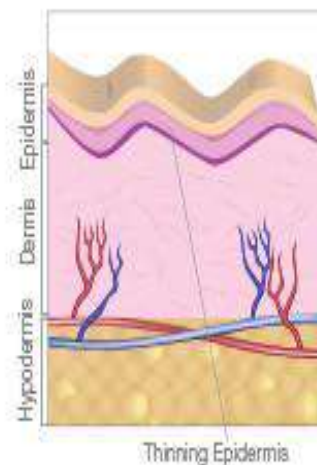
# Subcutaneous Layer

- ◉ Fat loss and thinning..
- ◉ Fewer blood vessels.
- ◉ Sweat glands - decreased.
- ◉ Sebaceous glands – Fewer with less sebum production.
- ◉ Hair shafts – fewer and thinner with less pigment.



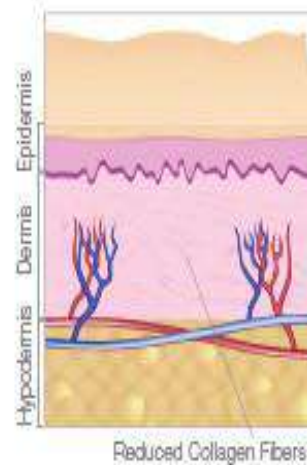
## 20s

Environmental damage and constant exposure to damaging UV rays begin to take their toll on skin. Free radicals attack the skin's structural integrity. Cell renewal and turnover rates begin to decline.



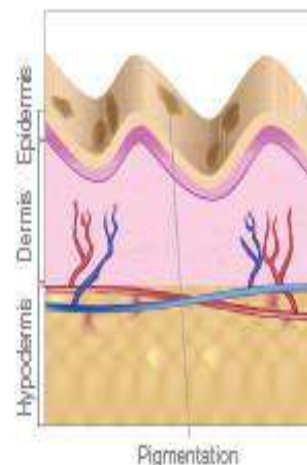
## 40s

By our 40s, the skin is thinner, barrier lipids are not as pronounced and dehydration can be an issue. More prominent signs of skin aging may also appear, such as dark spots and significant dullness.



## 30s

In our 30s, collagen and elastin degrade, resulting in our first wrinkles. Cell renewal and turnover continue to decline, leading to a duller complexion and uneven skin tone.



## 50s+

The protective barrier lipid layer lessens, leading to less efficiency in retaining moisture and more potential for sensitivity and dehydration. Skin shows wrinkles, fine lines and pigmentation.

# EXTRINSIC AGING

Outside factors that accelerate intrinsic aging.

- Photoaging
- Smoking
- Malnutrition
- Hormonal Disorders
- Chronic Disease States
- Repetitive facial expressions
- Gravity

# Photoaging

- Photoaged skin shows
- deep coarse wrinkling,
- excessive dryness,
- severe brown spots
- dry leathery texture when compared to intrinsically aged skin



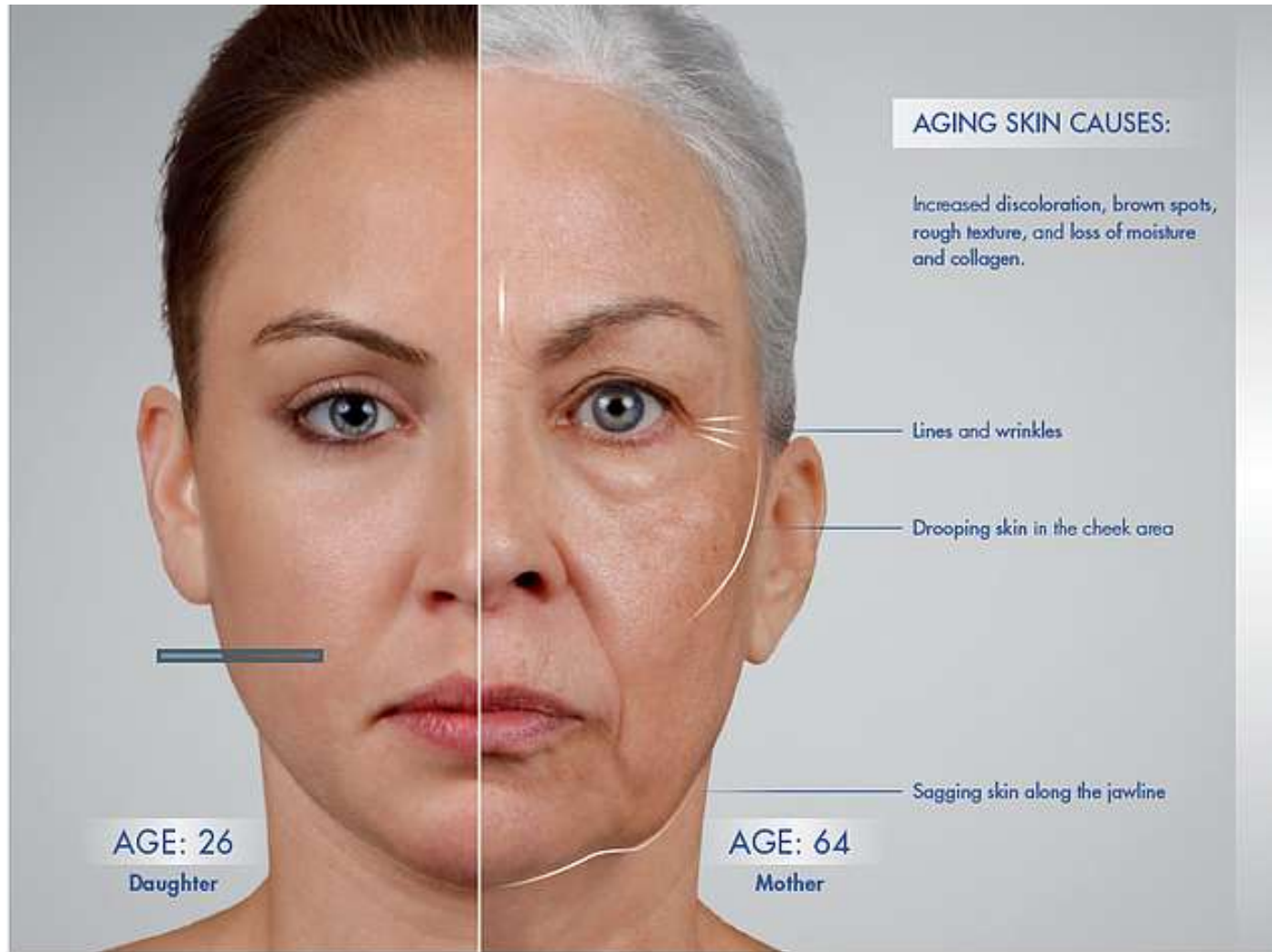# Smoking

- Acts primarily **via vasoconstriction** of blood vessels going to and through skin layers.
- Decreased blood flow results in
  - decreased **nutrients**,
  - decreased **oxygen** supply
  - increased inflammatory **byproducts** (free radical oxidation byproducts).
- Net effect
  - decreased **collagen production** and turnover,
  - **poor quality** collagen and elastin,
  - decreased quantity of **matrix components** and less gland secretions.

# Gravity

- Constantly pulls on bodies.
- In 50s, when skin's elasticity declines dramatically, effects of gravity become evident.
- Causes tip of nose to droop, ears to elongate, eyelids to fall, jowls to form, and upper lip to disappear while lower lip becomes more pronounced





### AGING SKIN CAUSES:

Increased discoloration, brown spots, rough texture, and loss of moisture and collagen.

Lines and wrinkles

Drooping skin in the cheek area

Sagging skin along the jawline

AGE: 26  
Daughter

AGE: 64  
Mother

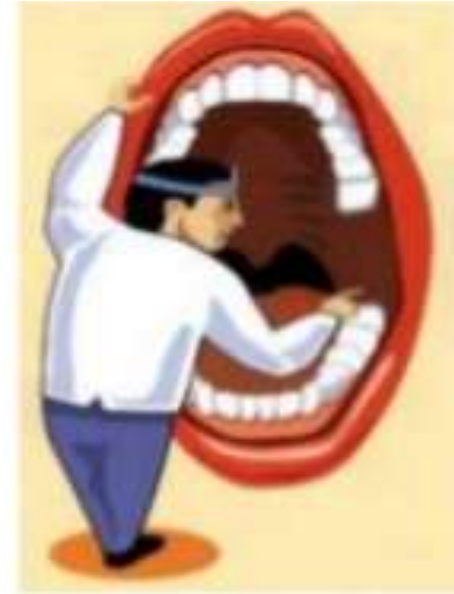





Thank you





# CLEFT PALATE NORMAL ANATOMY

Lect. Hussein T. Abed

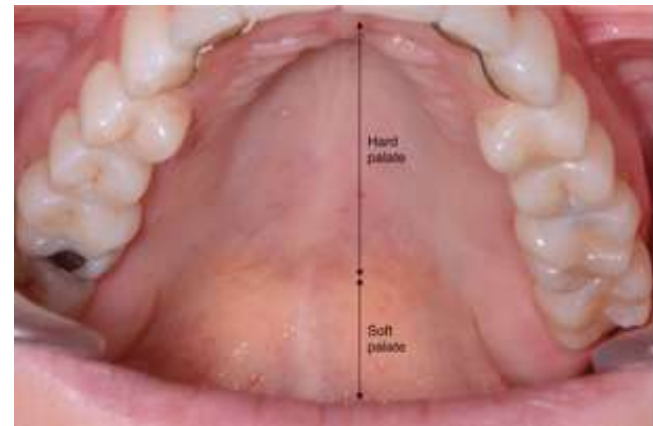
3\2\2021

# NORMAL ANATOMY:

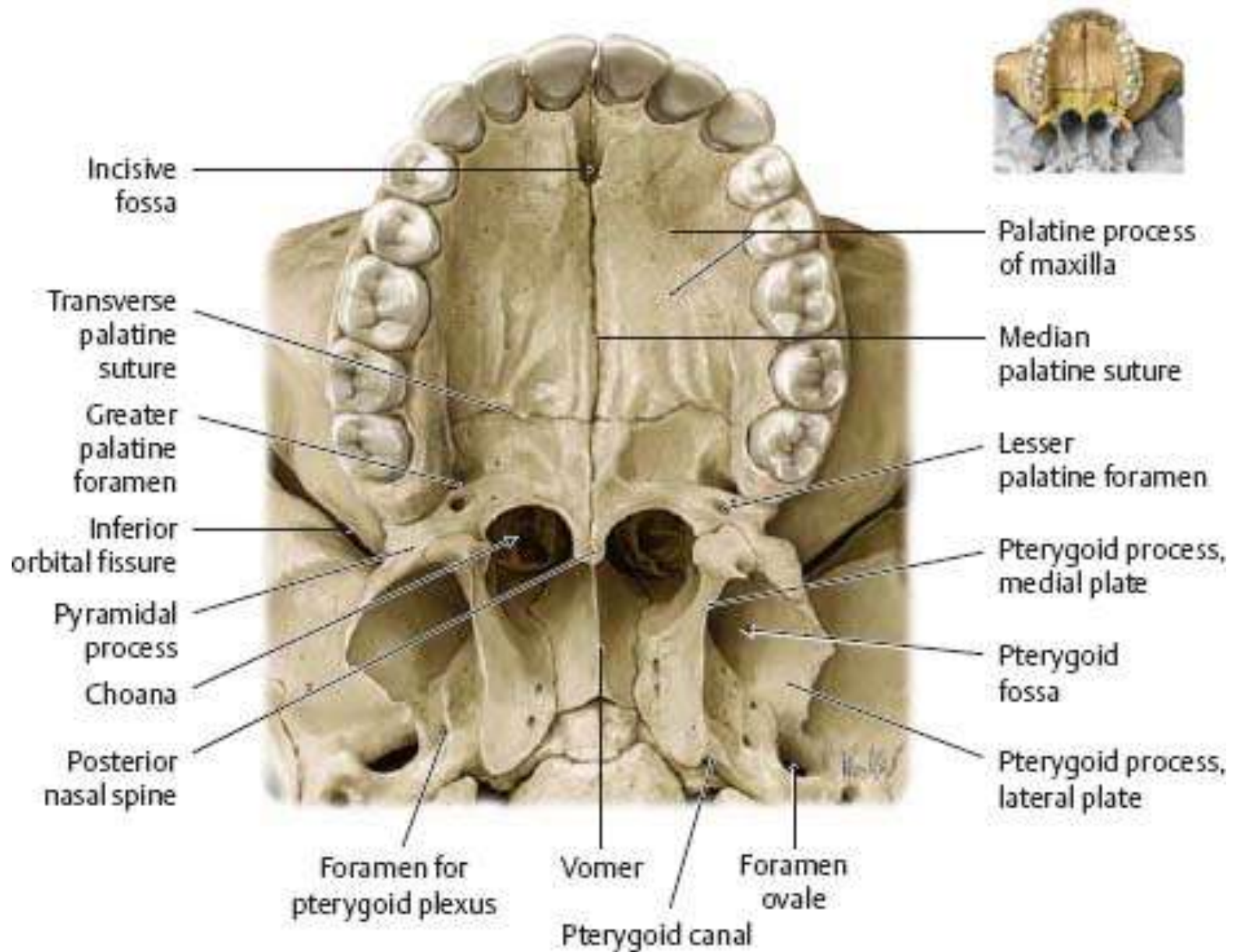
## A- MAXILLA

pyramidal-shaped bone. consists of a body ( mid face )and four processes (the frontal and zygomatic processes upwards and the alveolar and palatine processes downwards)

The palatine process forms the anterior two thirds of the hard palate..





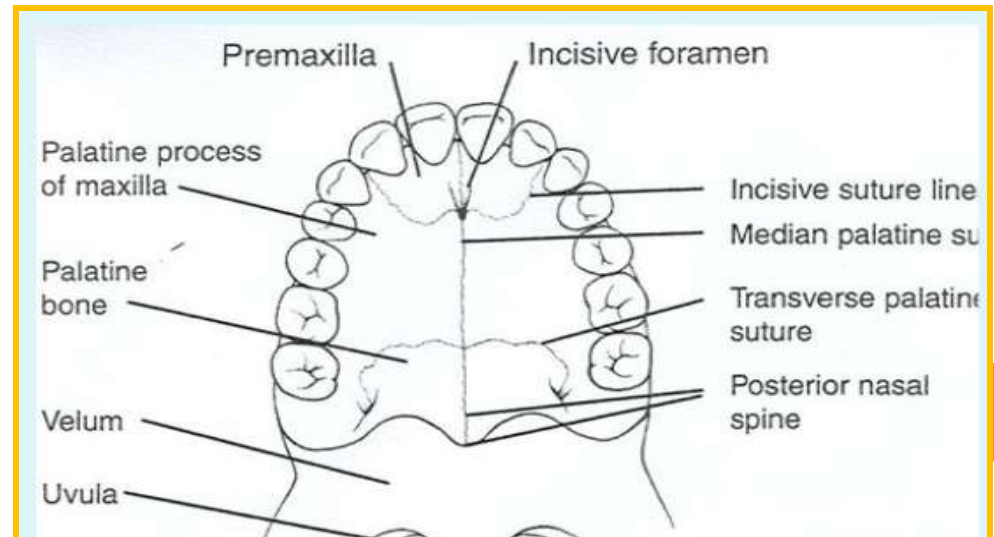


# NORMAL ANATOMY:

## A- MAXILLA

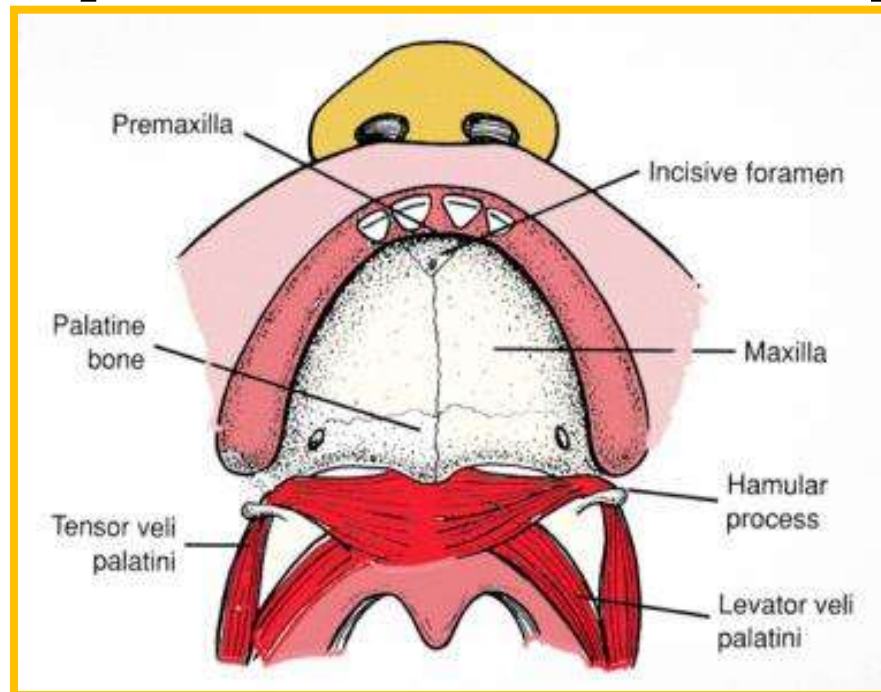
The **maxilla** has several distinct anatomical areas.

- The nasal spine is the anterior projection of the maxilla and alveolus.
- The alveolar process of the maxilla surrounds the palate and houses the teeth



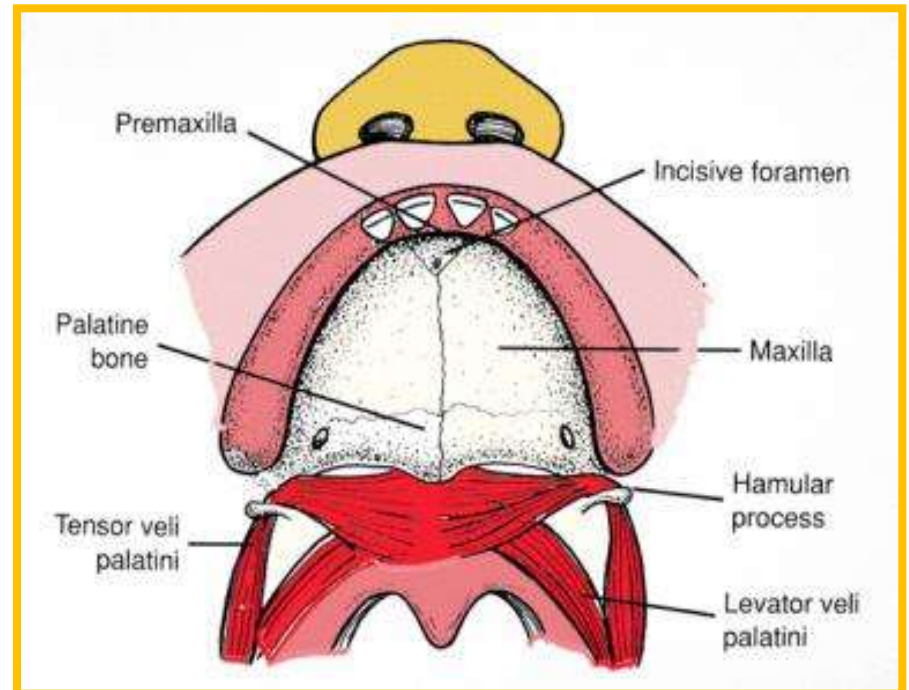
## B-THE PALATE

- is composed of the maxillary and palatine bony plates. The palatine process of maxillary bone forms the anterior two thirds of the palate and the horizontal maxillary plate of palatine bone constitutes the posterior third of the hard palate.



## B-THE PALATE

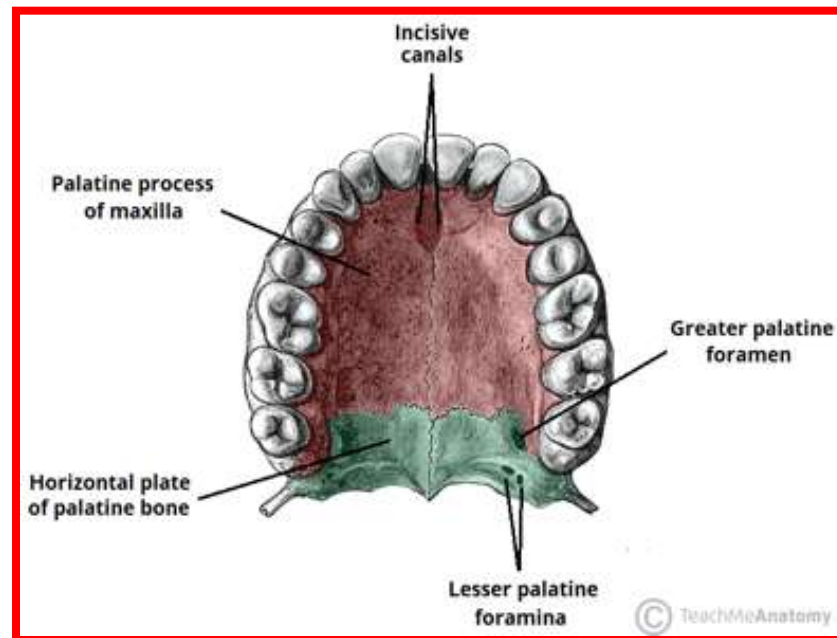
- They are both divided into right and left by a longitudinal midline suture.
- The anterior part of the palate is formed of the anterior alveolar process carrying the anterior teeth and the premaxilla.



## B-THE PALATE

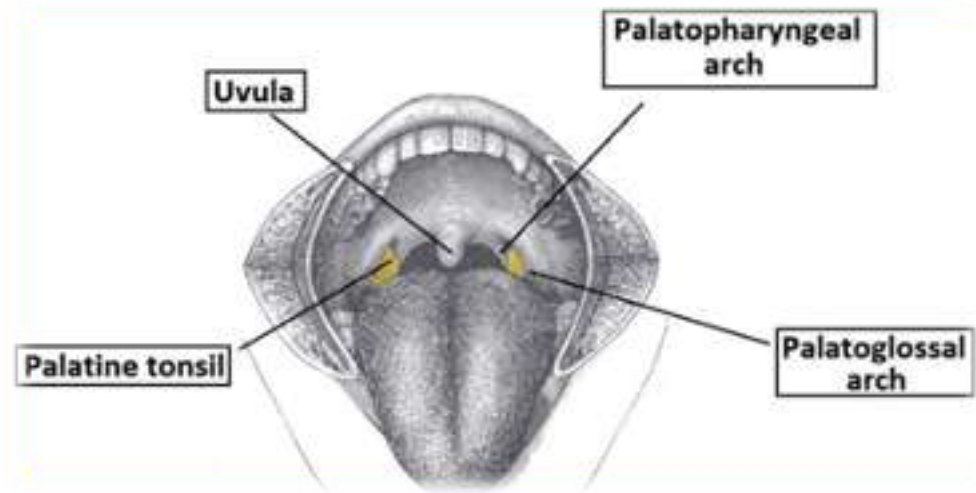
Blood vessels and nerves exit from the incisive foramen anteriorly and the greater and lesser palatine foramina postero-laterally.

The incisive canal is located posterior to the incisors, Posteriorly and laterally along the palate is the greater palatine foramina,



## C-THE SOFT PALATE

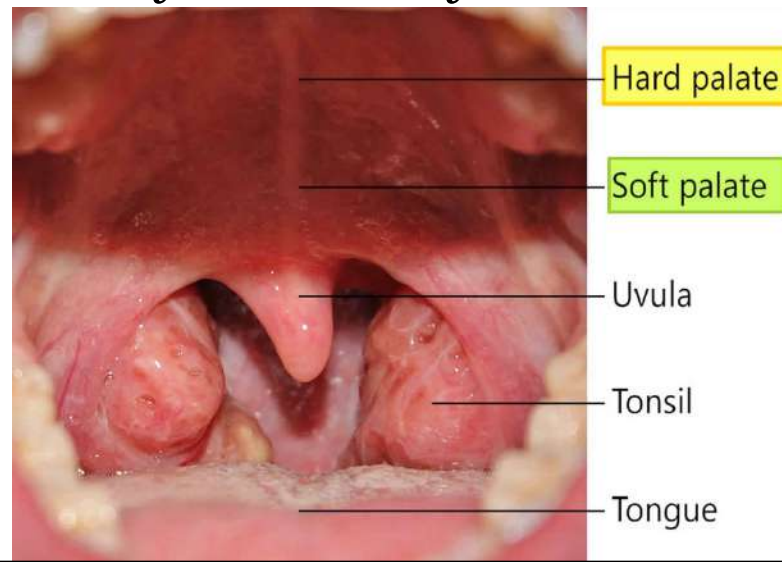
- is the unossified part of the palate. It attaches to the posterior rim of the hard palate.
- Medially, a posterior extension, the uvula or the velum extends downwards and acts as a valve for the pharyngeal cavity.





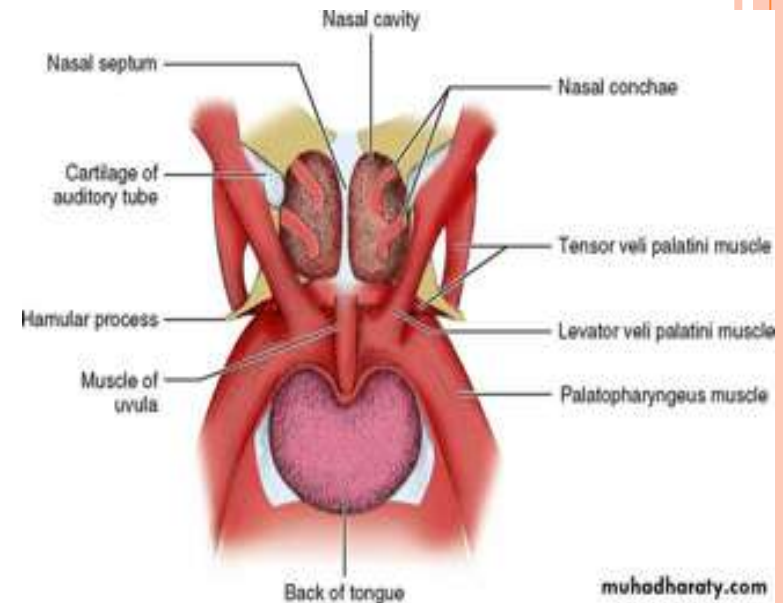
## C-THE SOFT PALATE

- The soft palate contains a series of muscles , numerous minor salivary glands and some lymphatic tissues and a dense network of elastic fibers which together with the muscles of the pharynx form a sphincter that opens and closes the orifice between the nasal cavities superiorly and the oro-pharyngeal cavity inferiorly.



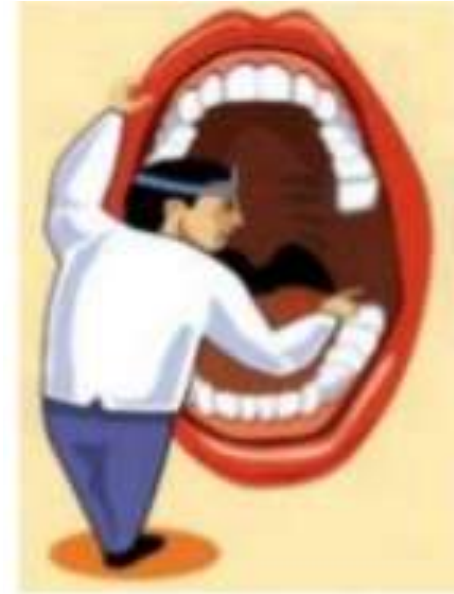
## C-THE SOFT PALATE

- The soft palate attaches to the posterior portion of the hard palate and interdigitates with the lateral pharyngeal wall via several muscular attachments. From the naso-pharyngeal to the oral cavity surface, the muscles of the soft palate consist of:
  - the palatopharyngeus
  - the levator and tensor palatini
  - the muscular uvula
  - the palatoglossus
  - the superior constrictor muscle.



Thank you





# CLEFT PALATE NORMAL ANATOMY

Lect. Hussein T. Abed

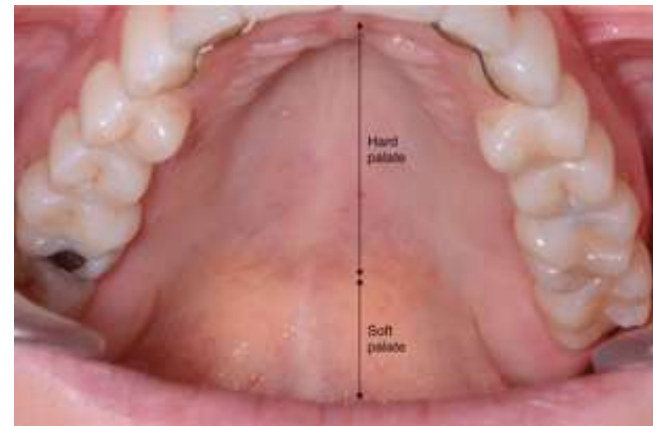
3\2\2021

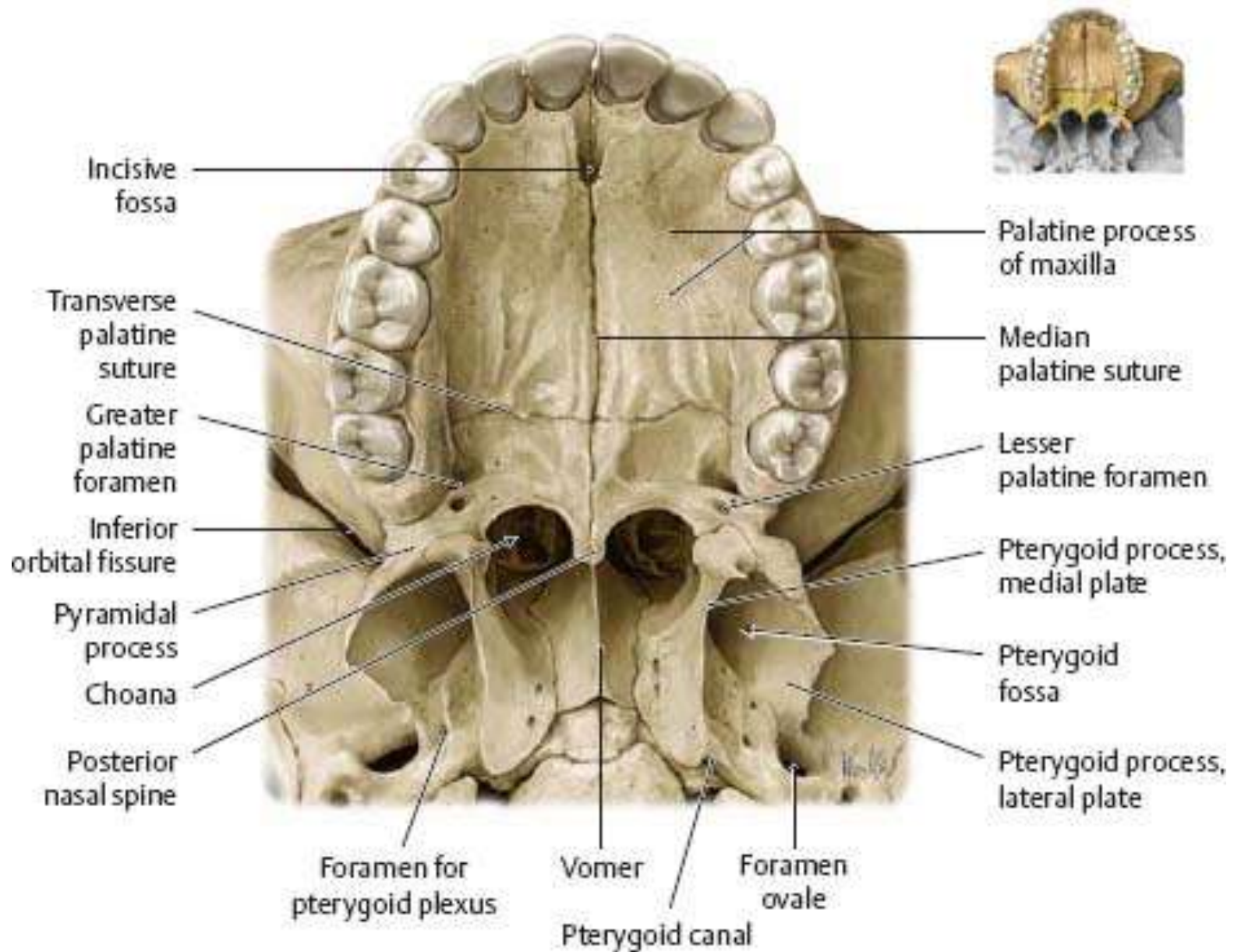
# NORMAL ANATOMY:

## A- MAXILLA

pyramidal-shaped bone. consists of a body ( mid face )and four processes (the frontal and zygomatic processes upwards and the alveolar and palatine processes downwards)

The palatine process forms the anterior two thirds of the hard palate..





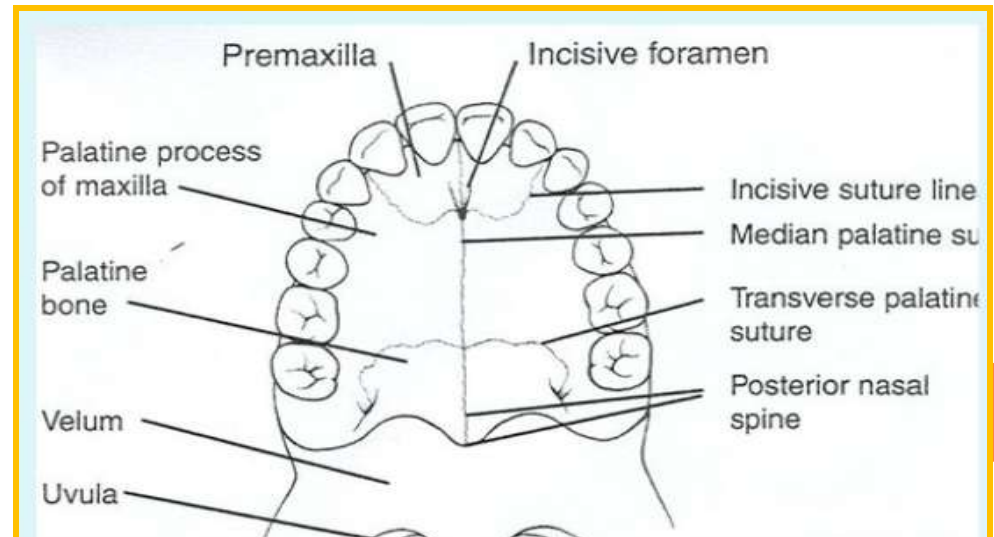


# NORMAL ANATOMY:

## A- MAXILLA

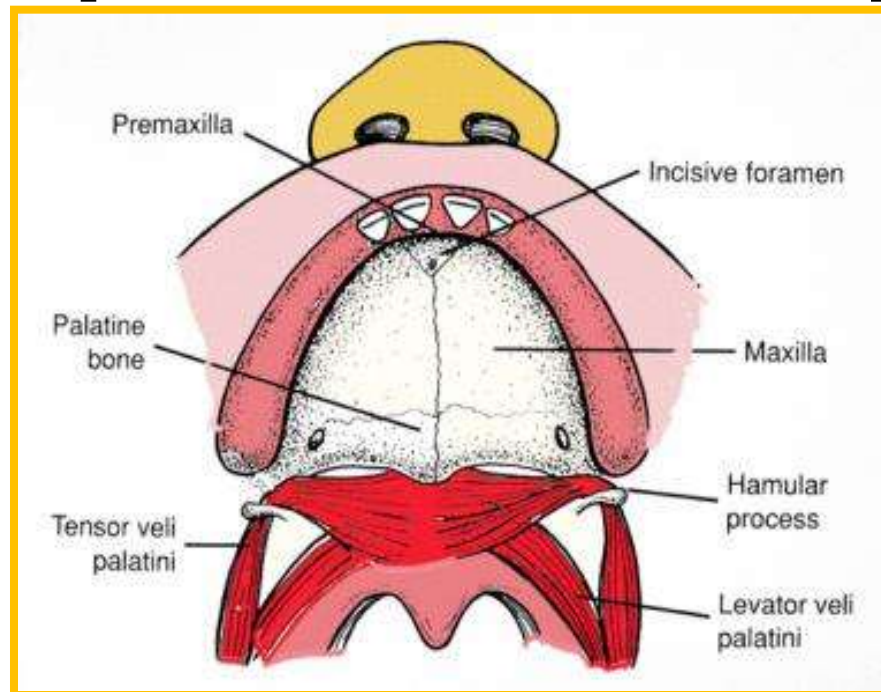
The **maxilla** has several distinct anatomical areas.

- The nasal spine is the anterior projection of the maxilla and alveolus.
- The alveolar process of the maxilla surrounds the palate and houses the teeth



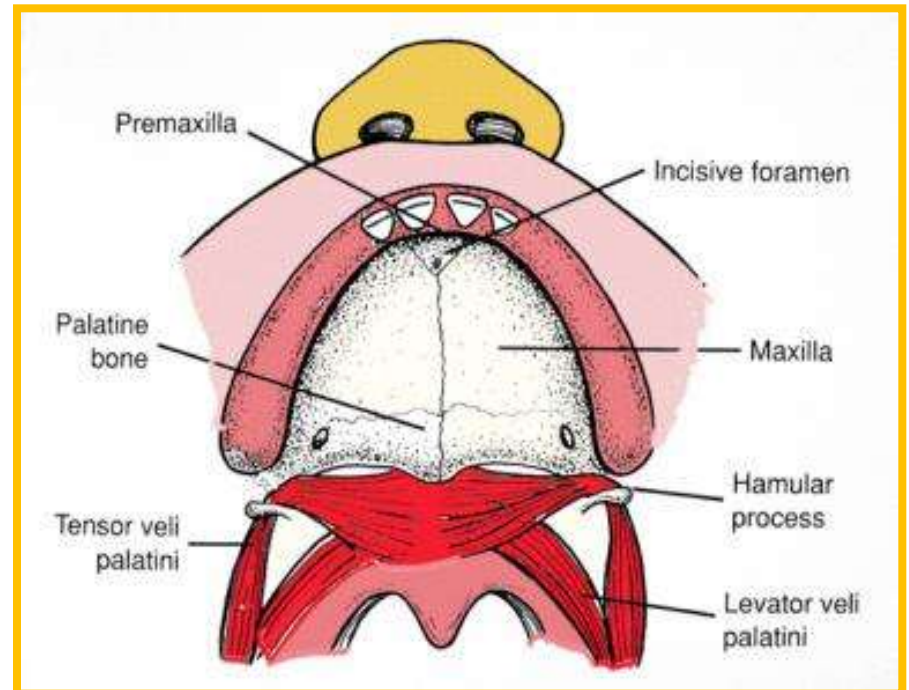
## B-THE PALATE

- is composed of the maxillary and palatine bony plates. The palatine process of maxillary bone forms the anterior two thirds of the palate and the horizontal maxillary plate of palatine bone constitutes the posterior third of the hard palate.



## B-THE PALATE

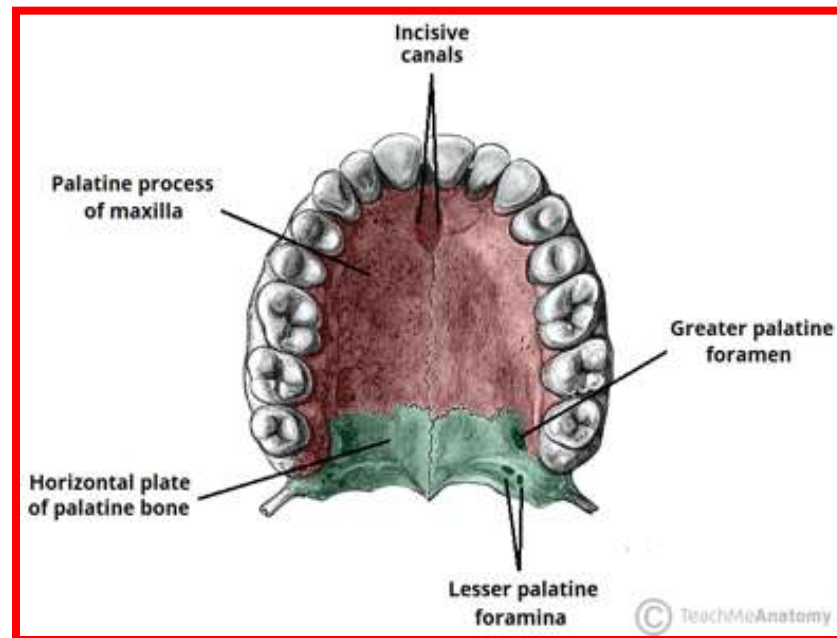
- They are both divided into right and left by a longitudinal midline suture.
- The anterior part of the palate is formed of the anterior alveolar process carrying the anterior teeth and the premaxilla.



## B-THE PALATE

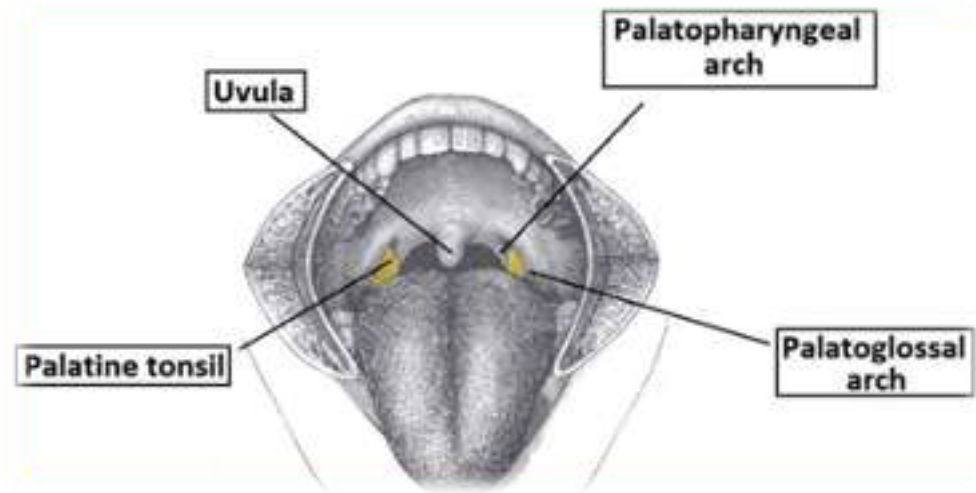
Blood vessels and nerves exit from the incisive foramen anteriorly and the greater and lesser palatine foramina postero-laterally.

The incisive canal is located posterior to the incisors, Posteriorly and laterally along the palate is the greater palatine foramina,



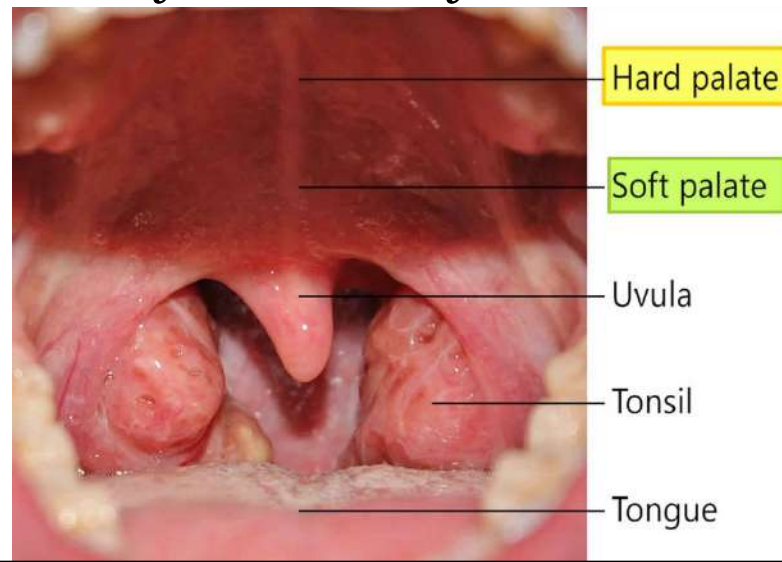
## C-THE SOFT PALATE

- is the unossified part of the palate. It attaches to the posterior rim of the hard palate.
- Medially, a posterior extension, the uvula or the velum extends downwards and acts as a valve for the pharyngeal cavity.



## C-THE SOFT PALATE

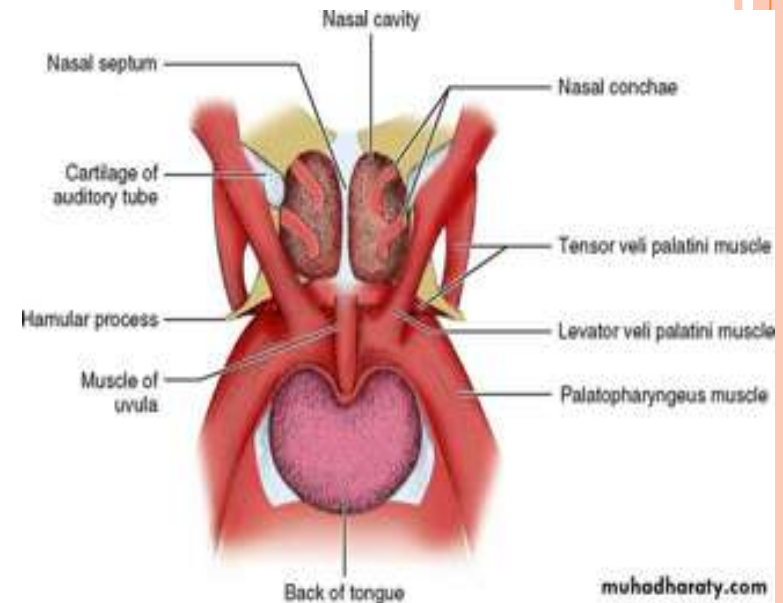
- The soft palate contains a series of muscles , numerous minor salivary glands and some lymphatic tissues and a dense network of elastic fibers which together with the muscles of the pharynx form a sphincter that opens and closes the orifice between the nasal cavities superiorly and the oro-pharyngeal cavity inferiorly.





## C-THE SOFT PALATE

- The soft palate attaches to the posterior portion of the hard palate and interdigitates with the lateral pharyngeal wall via several muscular attachments. From the naso-pharyngeal to the oral cavity surface, the muscles of the soft palate consist of:
  - the palatopharyngeus
  - the levator and tensor palatini
  - the muscular uvula
  - the palatoglossus
  - the superior constrictor muscle.



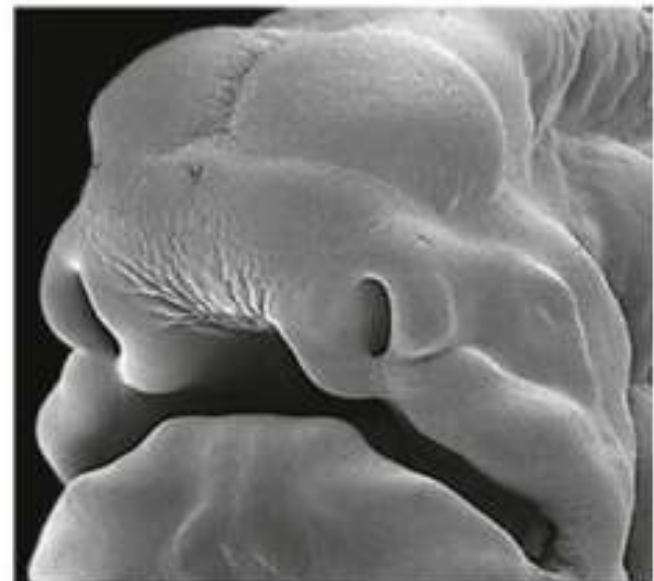
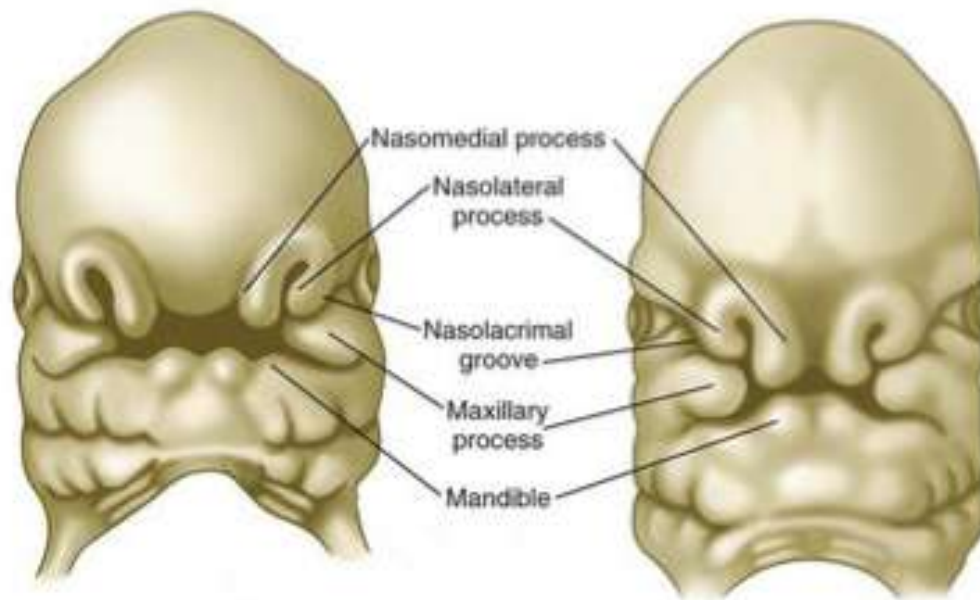
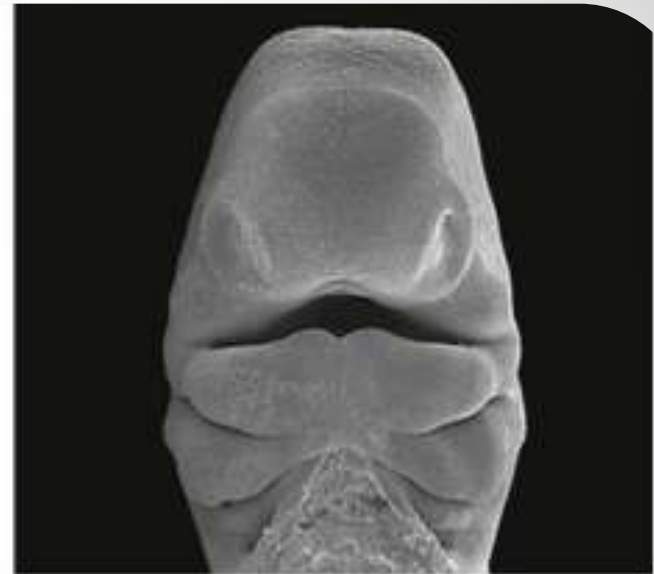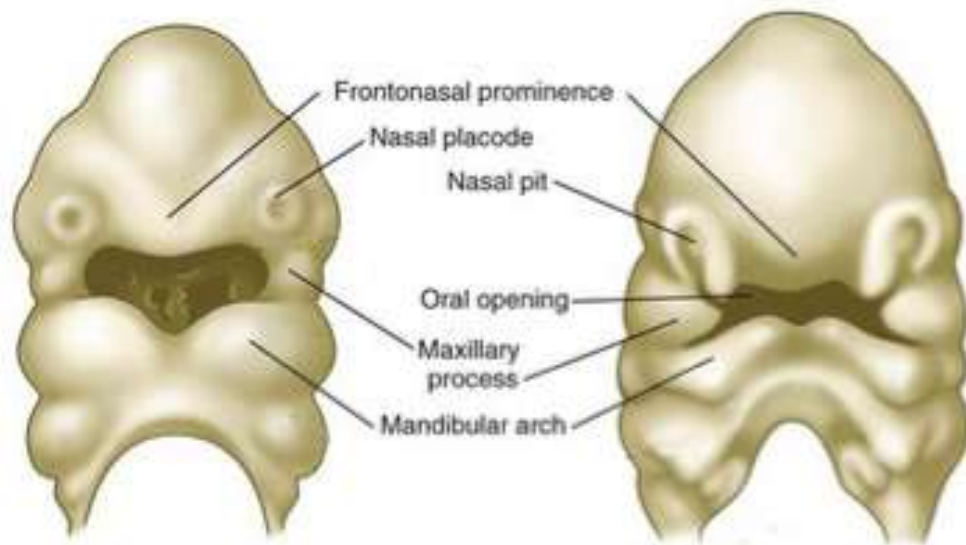
Thank you

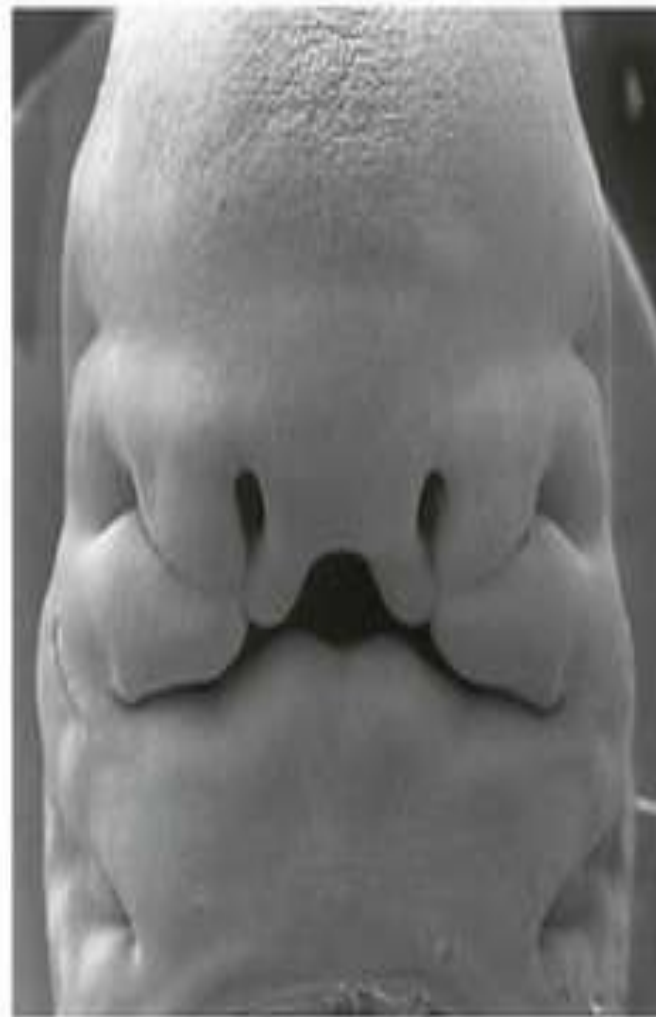
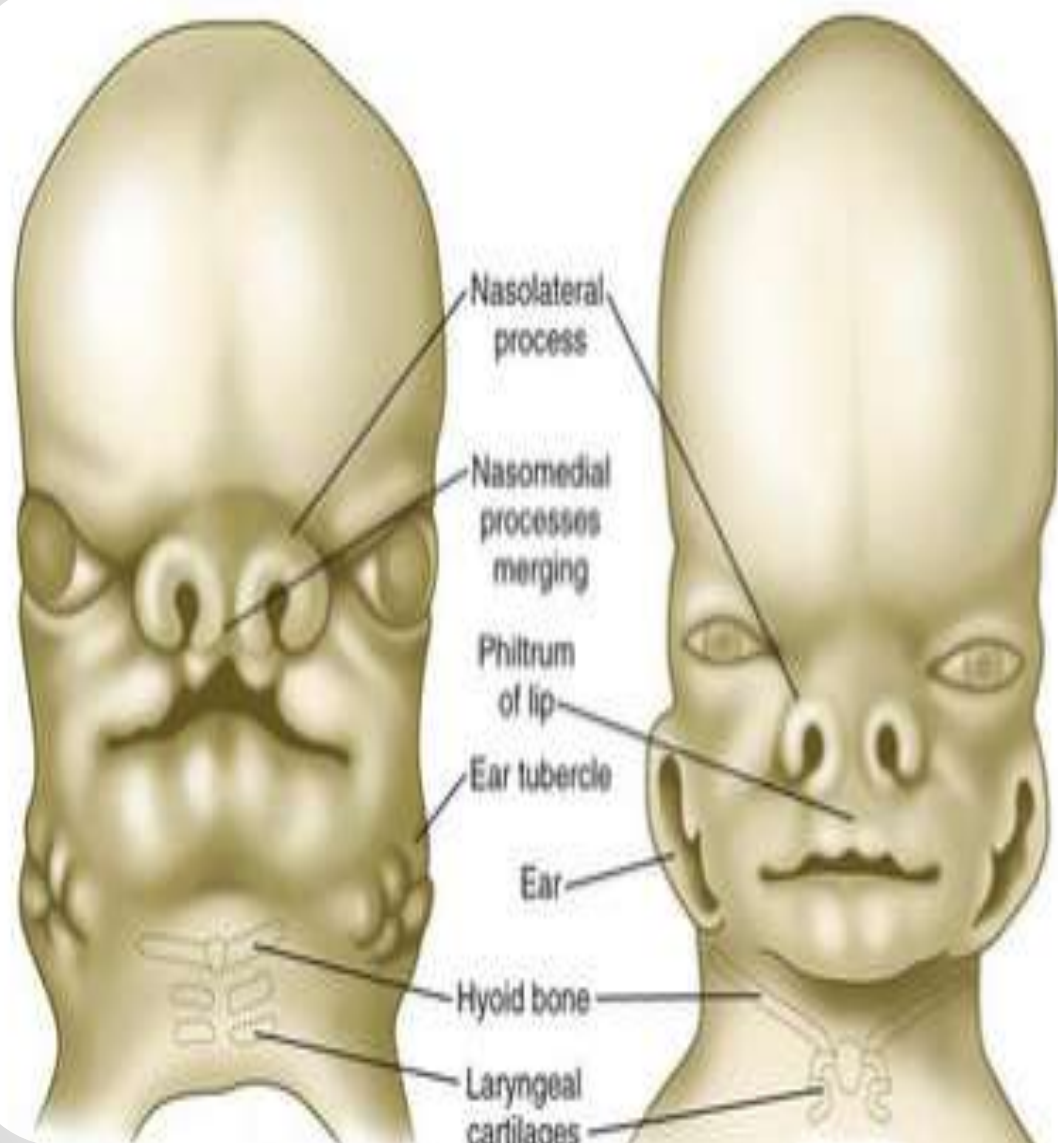


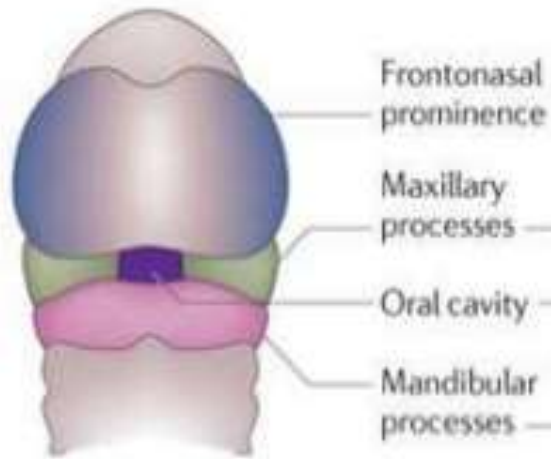
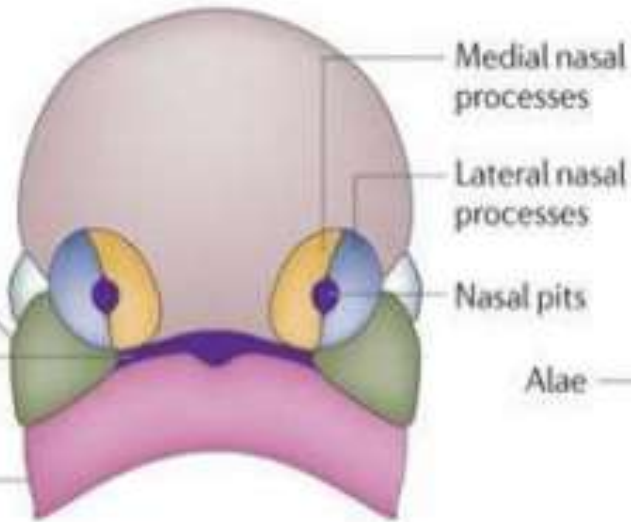
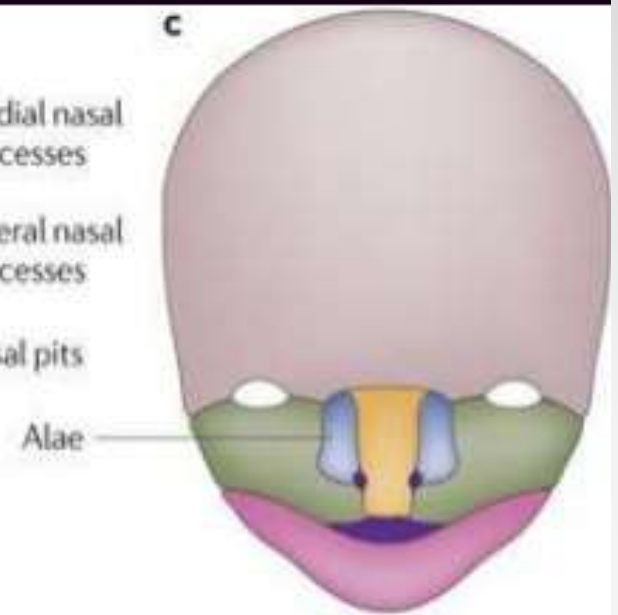
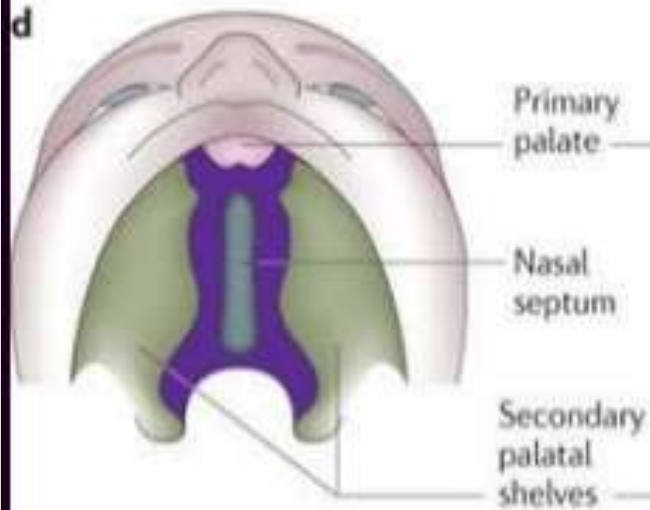
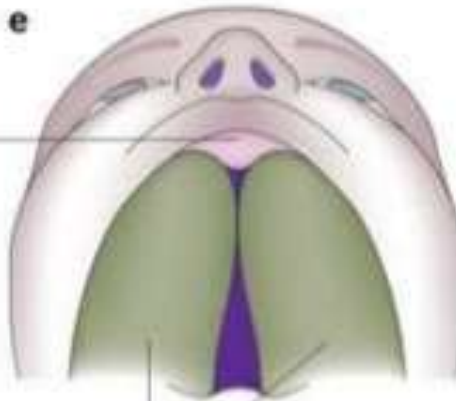
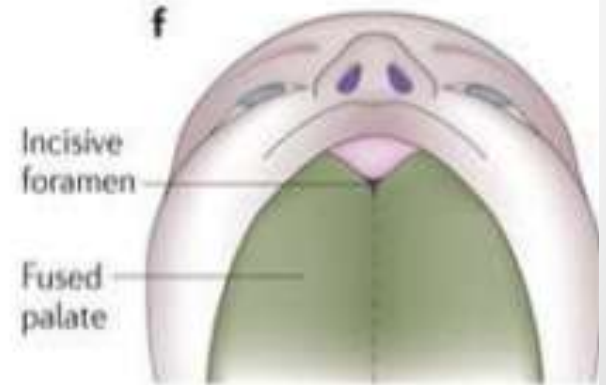
# Development of face, lip and palate

Lect. Hussein T. Abed

3\2\2021





**a****b****c****d****e****f**



**Nasal development** is instigated by the appearance of raised bumps called nasal placodes on both sides of the frontonasal prominence.

These then invaginate to form nasal pits, with medial and lateral nasal prominences on either side.

As the maxillary prominences expand medially, the nasal prominences are 'pushed' closer to the midline. The **maxillary prominences** then fuse with the nasal prominences – and soon after fuse in the midline to form a continuous central structure.

# Development of Palate

The development of the palate begins in the **fifth week and is completed in the twelfth week** intrauterine. It develops from:

**The primary palate** is derived from the median nasal process and gives rise to:

**a-The upper lip.**

**b-The premaxilla;** the part of the hard palate in front of the incisive foramen

c- **The anterior** part of the alveolar process and the incisors.

# Development of Palate

**The secondary palate:** is derived from **two horizontal lateral palatine** processes or palatine shelves. It gives rise to:

**a-Hard palate** posterior to the incisive foramen.

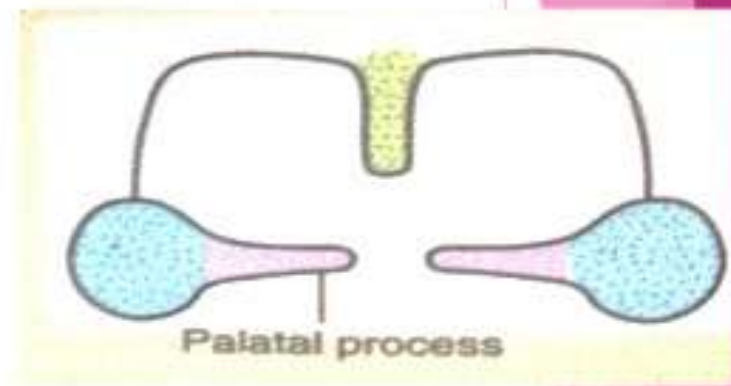
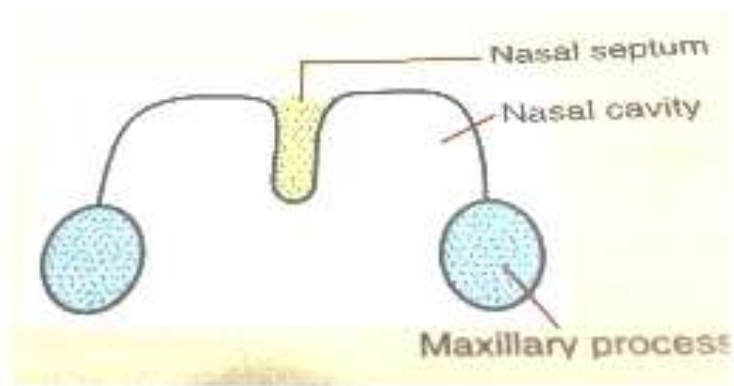
**b-Soft plate.**

At about the end of **the eighth gestational week**, the shelves elevate, make contact, and fuse with each other above the tongue.

Failure of union at any stage will result in a cleft palate and or lip.

# PALATE FORMATION

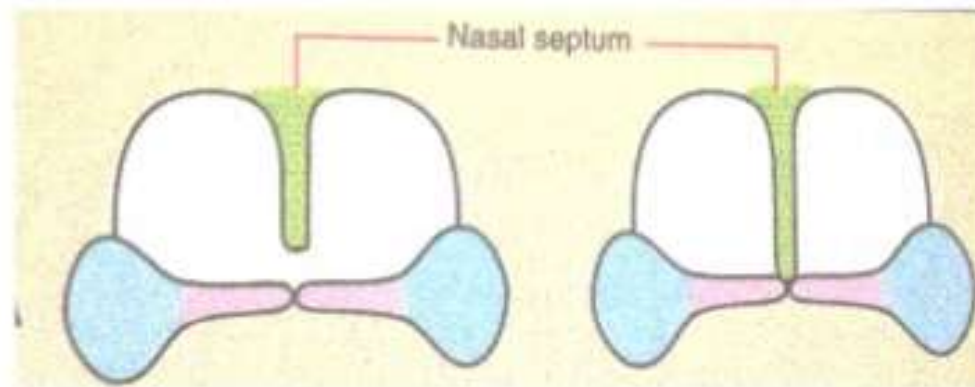
From each maxillary process 2 plate- like shelf grow medially called palatal process.



3 components contribute to the palate formation

- 2 palatal process
- primitive palate from the frontonasal process

Definitive palate is formed by fusion of these 3 parts.

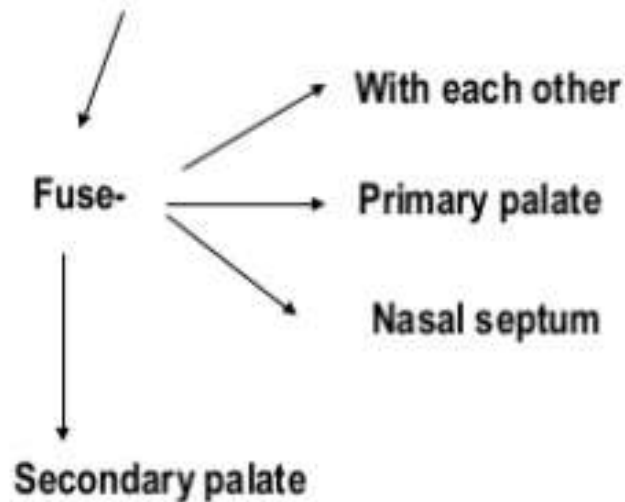


# Secondary palate

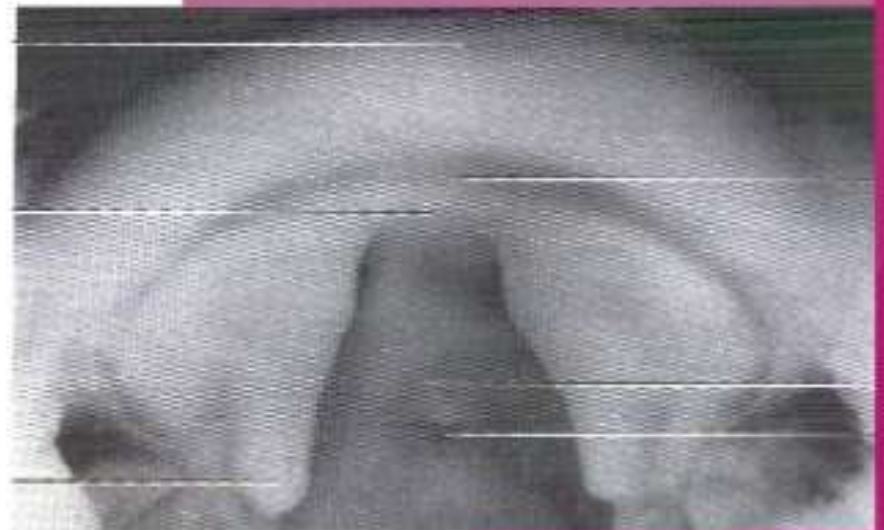Maxillary prominence

2 horizontal mesenchymal projections

Lateral palatine process

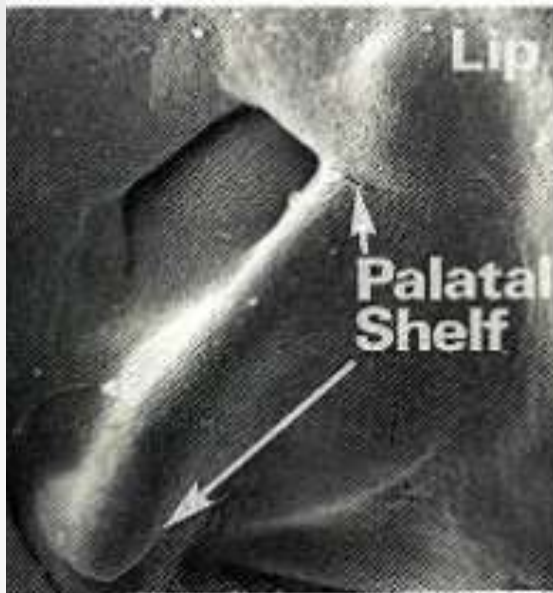


Intermaxillary Segment

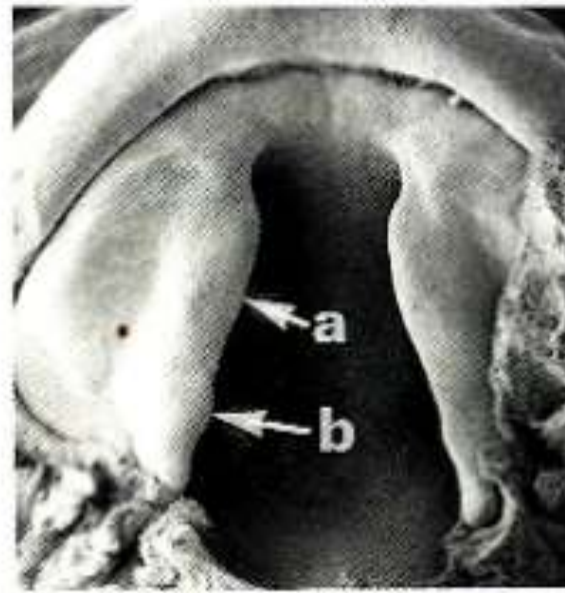




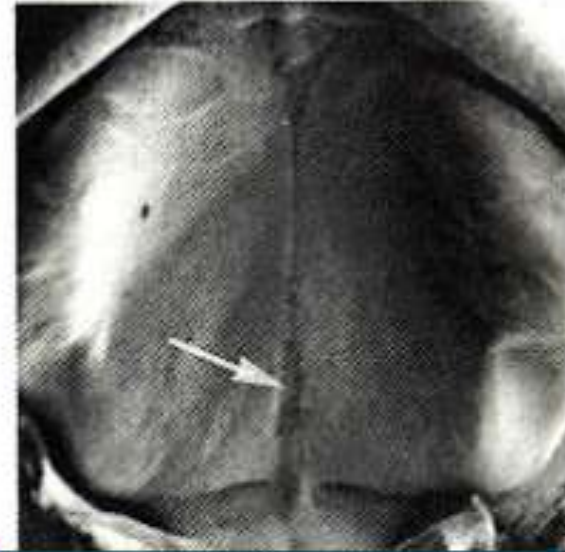
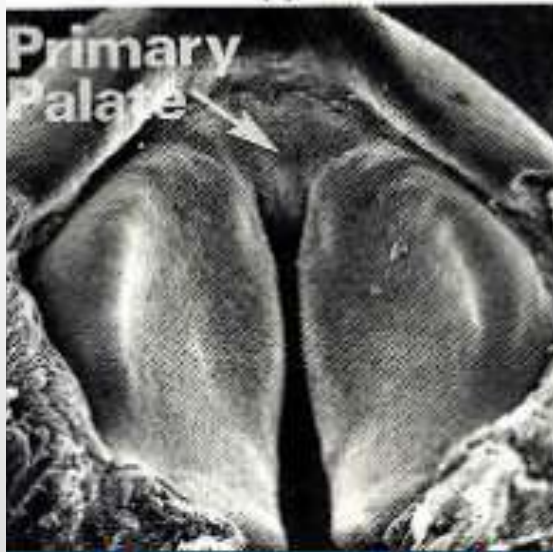
# FUSION OF PALATAL SHELVES



(a)



(b)



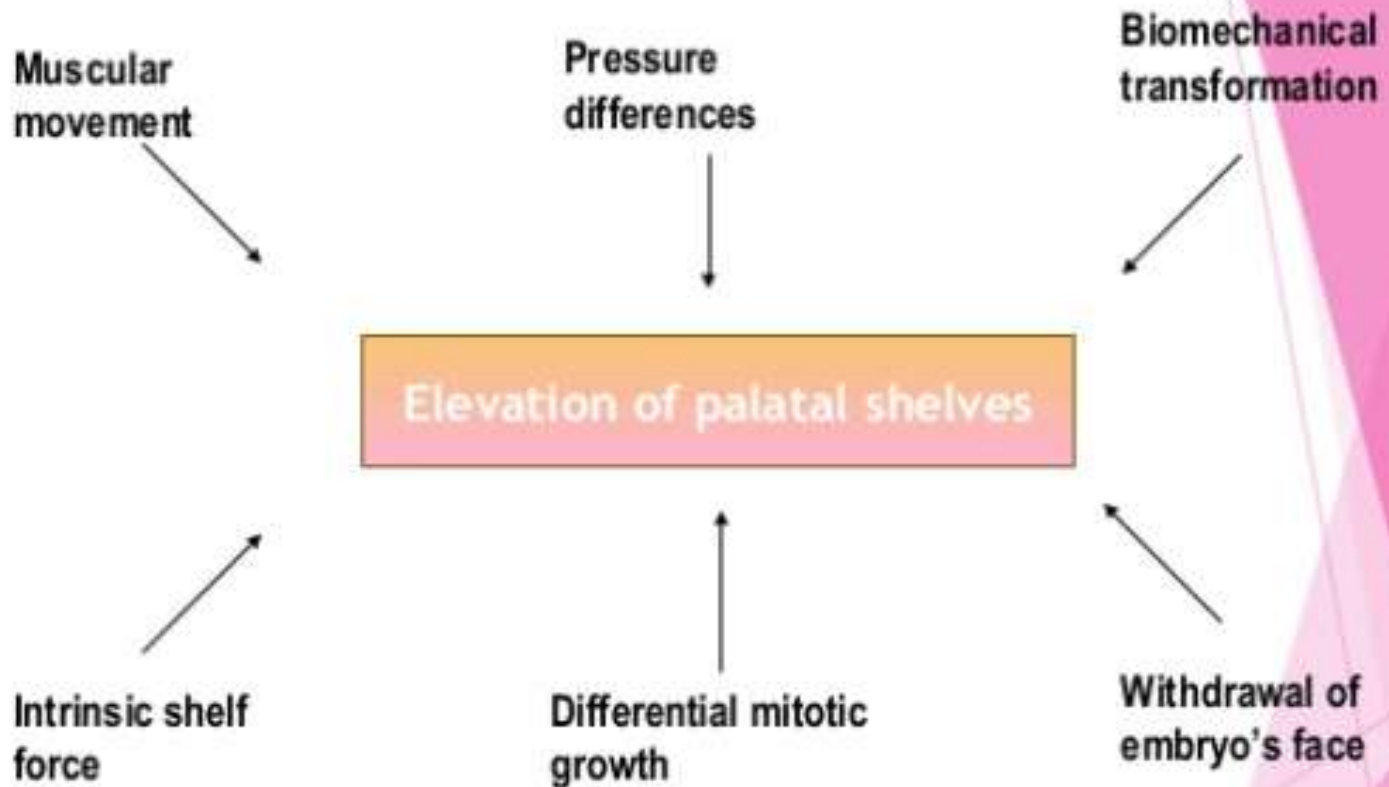
Entire palate does not fuse at the same time  
Initially contact occur  
In the central region  
of 2ndary palate post.  
to premaxilla.  
Extended anteriorly  
and posteriorly

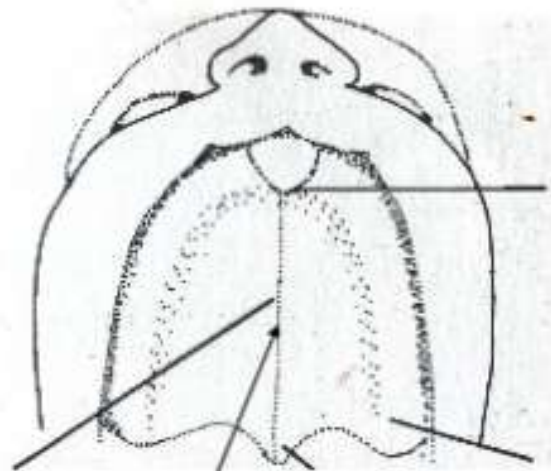
# ELEVATION OF PALATAL SHELVES

At 6 weeks

- Tongue (undifferentiated tissue)  
pushes dorsally
- Palatal shelves become vertical
- Elevation occurs from vertical to horizontal position

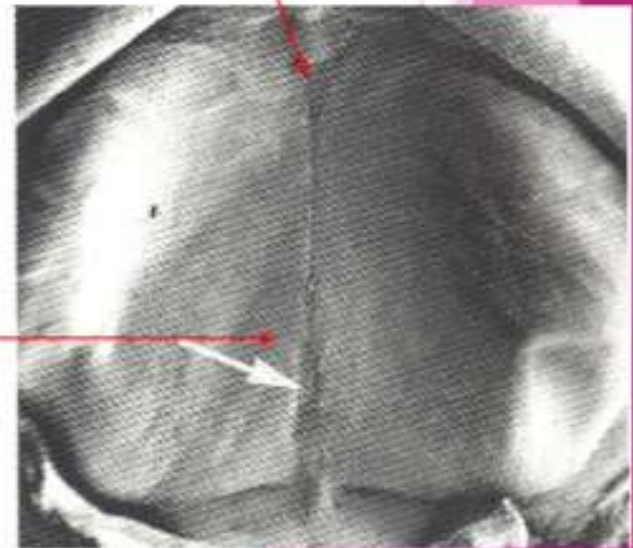
- **At 8 weeks**





**Incisive foramen**

**Mid palatine  
raphe**



# *Development of face and palate*

5 processes formed by proliferation of neural crest cells (ectoderm)

These cells migrate into arches

**1 frontonasal process –**

**2 maxillary processes –**

**2 mandibular processes –**



# *Development of face and palate*

## **1 FRONTAL NASAL PROCESS:**

2 nasal placodes develop

Each invaginated to form:

**Nasal pit** – forms nasal cavities – open in pharynx posteriorly

**Lateral nasal fold** – ala of nose

**Medial nasal fold** – fuse together to form:

**Surface**: middle part of nose, filtrum of upper lip

**Deep**: anterior upper jaw with Incisor teeth, primary palate with incisive fossa

Also forms nasal septum



# *Development of face and palate*

## **2 MAXILLARY PROCESSES:**

Grow medially

Fuse with medial nasal fold – form upper lip

Fuse with lateral nasal fold – form nasolacrimal duct

Fuse with mandibular process – forms cheeks

Forms palatine shelves

# *Development of face and palate*

## **2 MANDIBULAR PROCESSES:**

Fuse with each other medially – form lower lip and chin

fuse with maxillary process – forms cheeks

NB: Degree of fusion of max. and mand. processes determine width of mouth

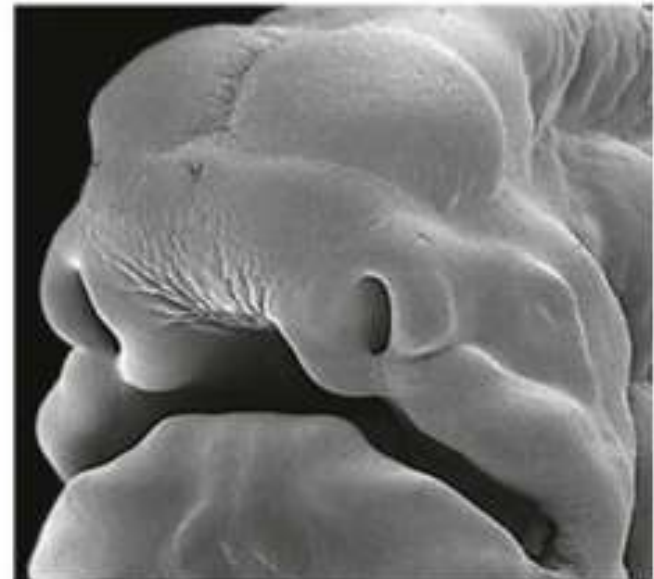
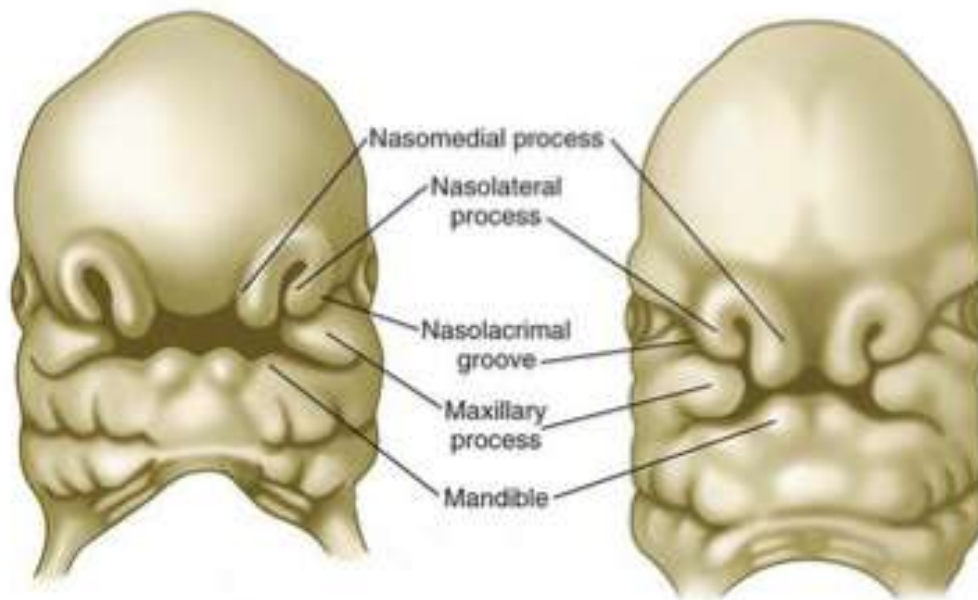
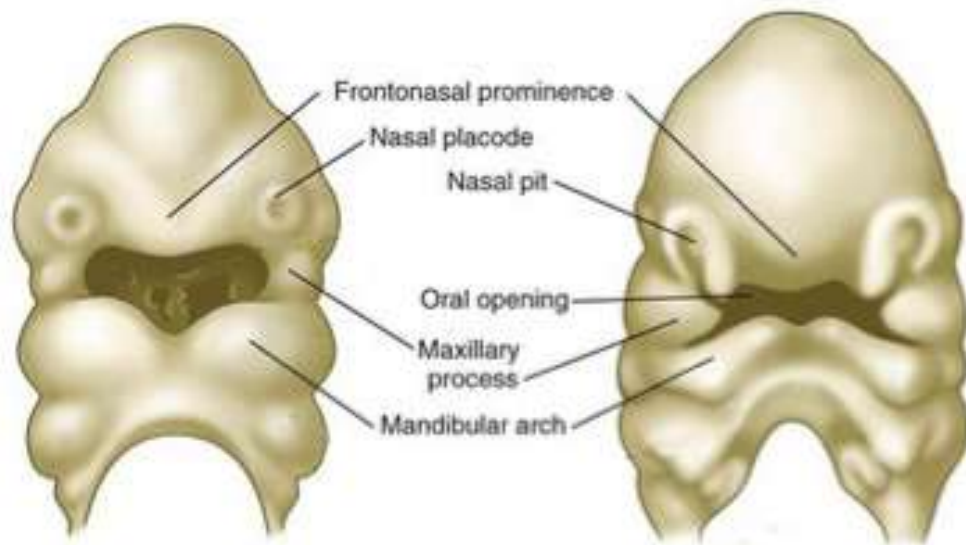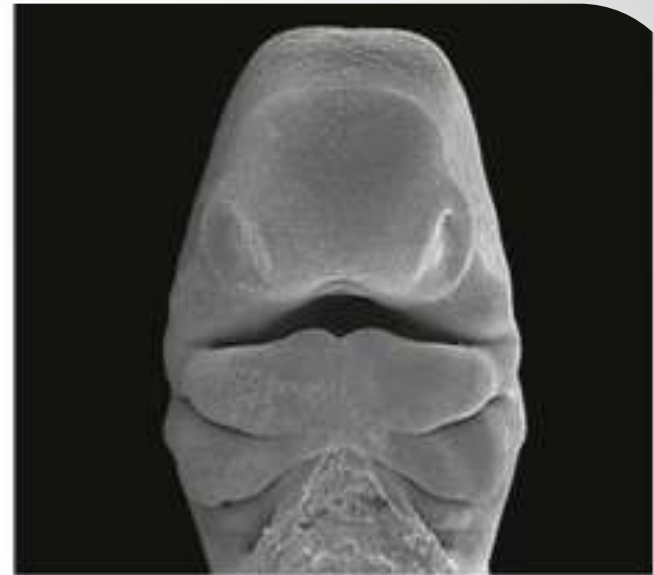
Prominence	Derivatives
Frontonasal	Forehead, bridge of nose, medial and lateral nasal prominences
Medial nasal	Philtrum, primary palate, upper 4 incisors and associated jaw
Lateral nasal	Sides of the nose
Maxillary (1st pharyngeal arch)	Cheeks, lateral upper lip, secondary palate, lateral upper jaw
Mandibular (1st pharyngeal arch)	Lower lip and jaw

Thank you

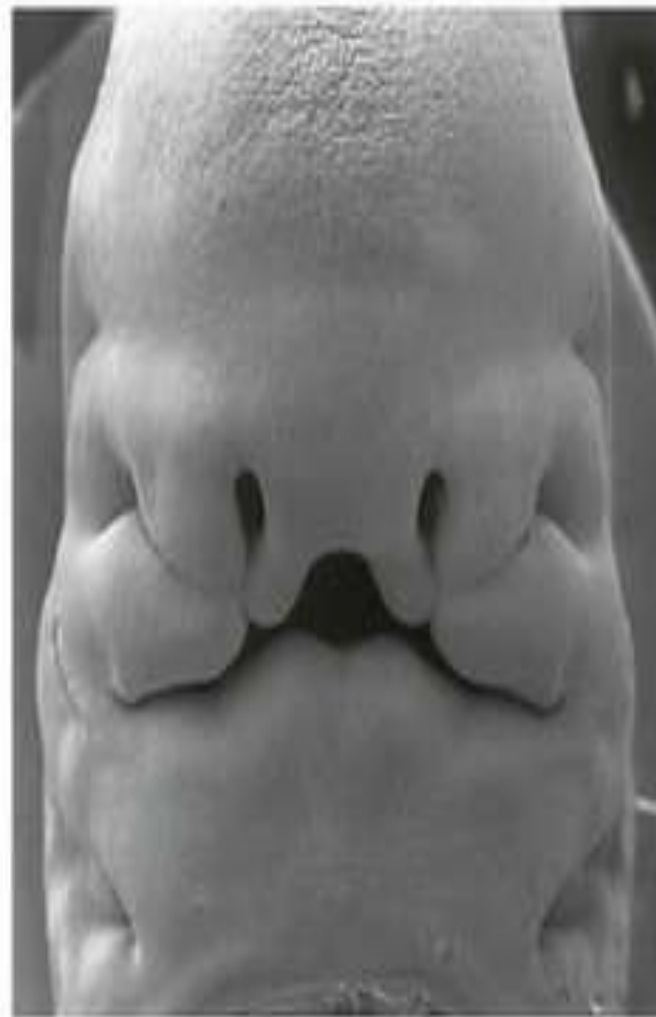
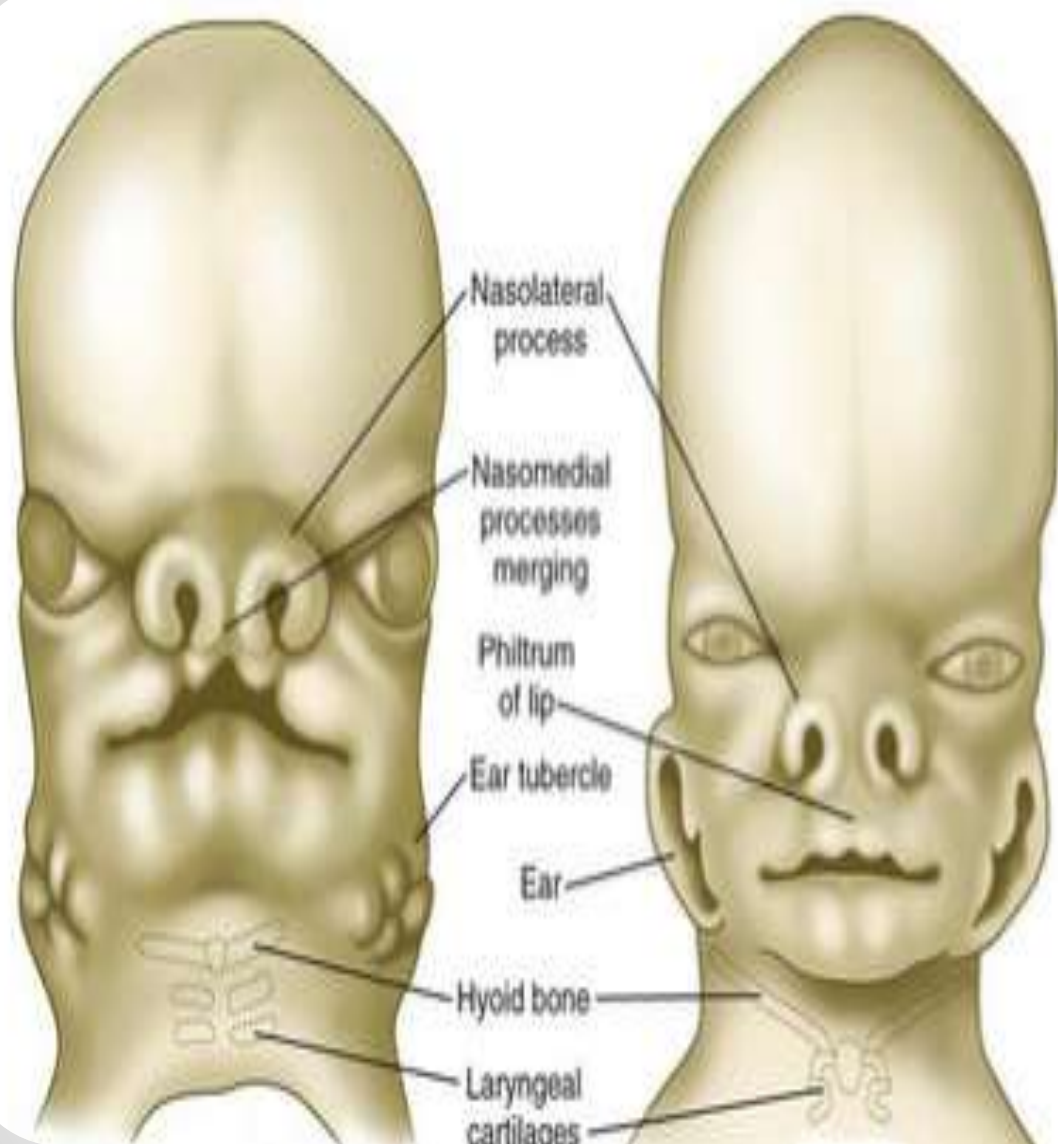
# Development of face, lip and palate

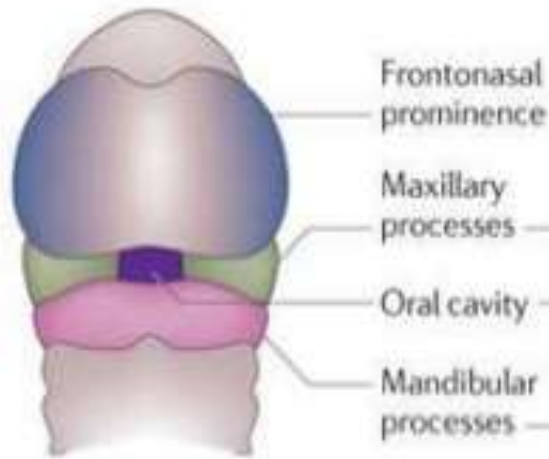
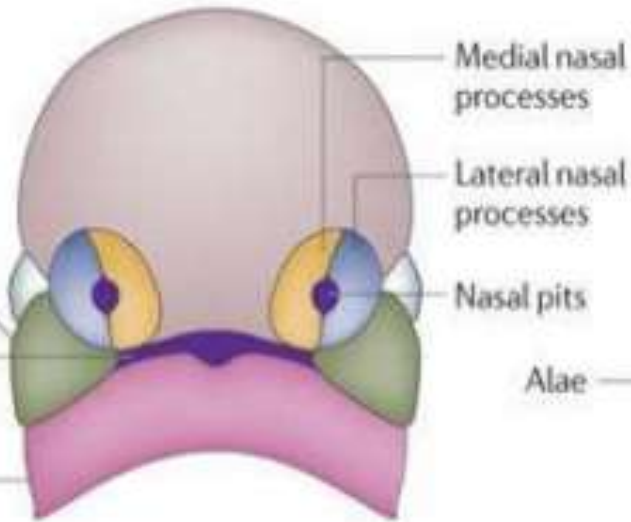
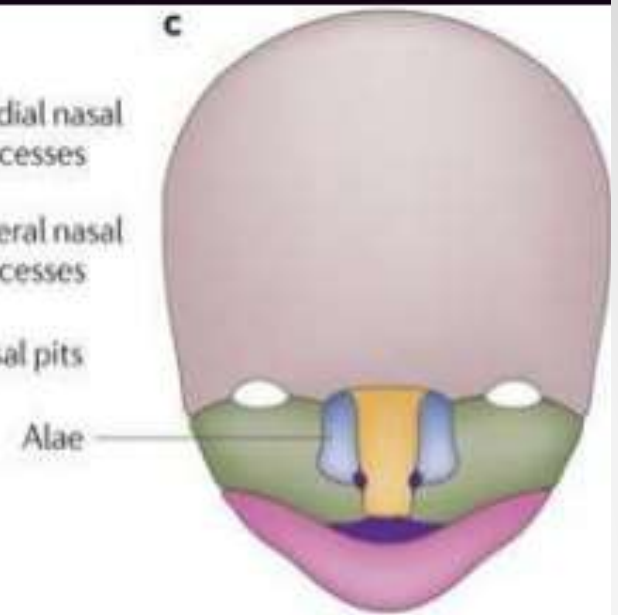
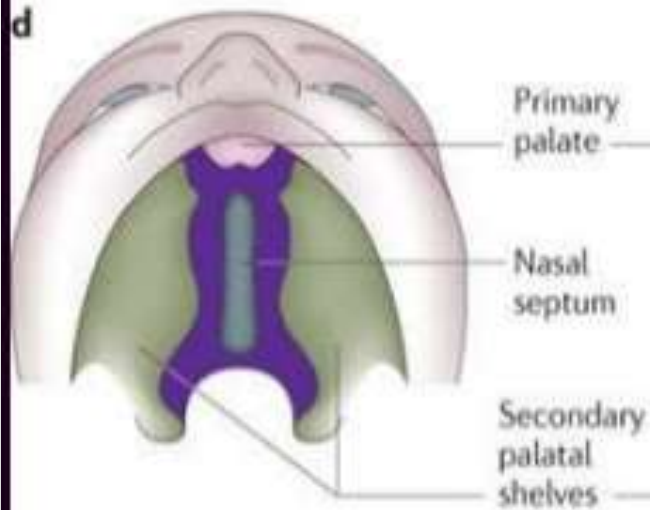
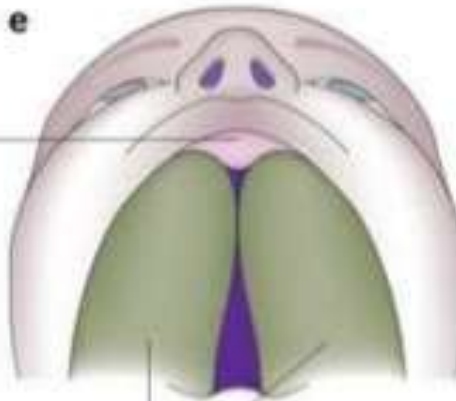
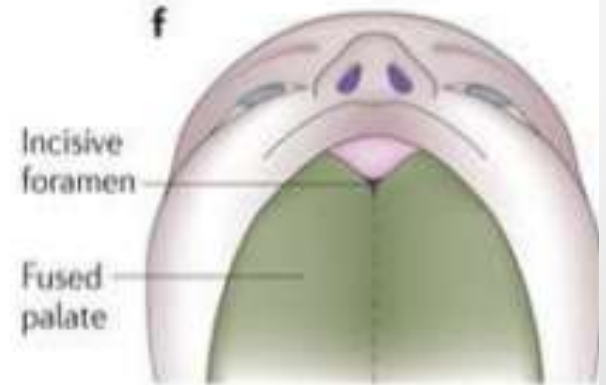
Lect. Hussein T. Abed

3\2\2021







**a****b****c****d****e****f**

**Nasal development** is instigated by the appearance of raised bumps called nasal placodes on both sides of the frontonasal prominence.

These then invaginate to form nasal pits, with medial and lateral nasal prominences on either side.

As the maxillary prominences expand medially, the nasal prominences are 'pushed' closer to the midline. The **maxillary prominences** then fuse with the nasal prominences – and soon after fuse in the midline to form a continuous central structure.

# Development of Palate

The development of the palate begins in the **fifth week and is completed in the twelfth week** intrauterine. It develops from:

**The primary palate** is derived from the median nasal process and gives rise to:

**a-The upper lip.**

**b-The premaxilla;** the part of the hard palate in front of the incisive foramen

c- **The anterior** part of the alveolar process and the incisors.

# Development of Palate

**The secondary palate:** is derived from **two horizontal lateral palatine** processes or palatine shelves. It gives rise to:

**a-Hard palate** posterior to the incisive foramen.

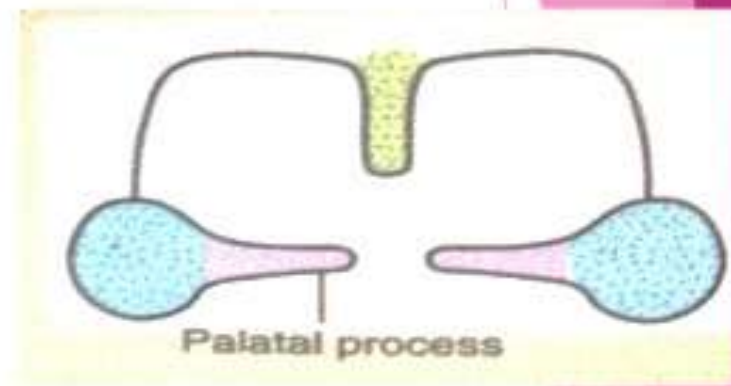
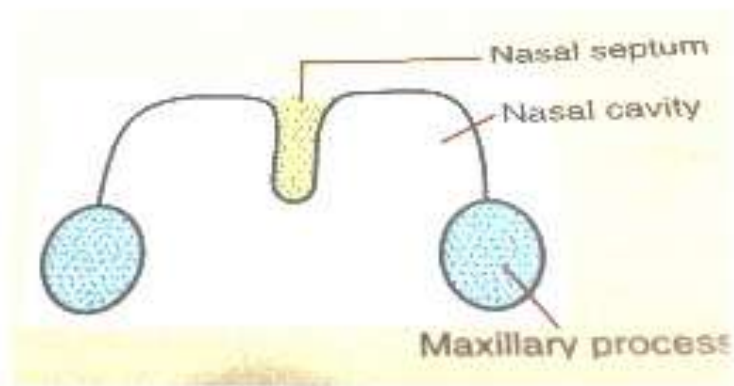
**b-Soft plate.**

At about the end of **the eighth gestational week**, the shelves elevate, make contact, and fuse with each other above the tongue.

Failure of union at any stage will result in a cleft palate and or lip.

# PALATE FORMATION

From each maxillary process 2 plate- like shelf grow medially called palatal process.

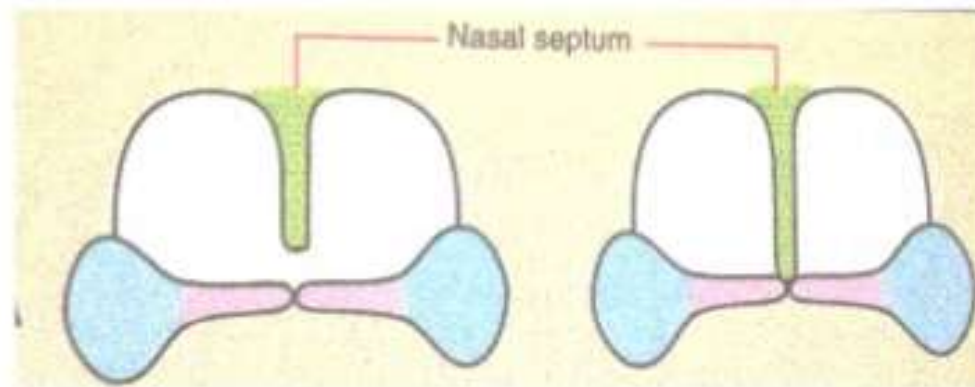


3 components contribute to the palate formation

- 2 palatal process
- primitive palate from the frontonasal process



Definitive palate is formed by fusion of these 3 parts.



# Secondary palate

Maxillary prominence

2 horizontal mesenchymal projections

Lateral palatine process

Fuse-

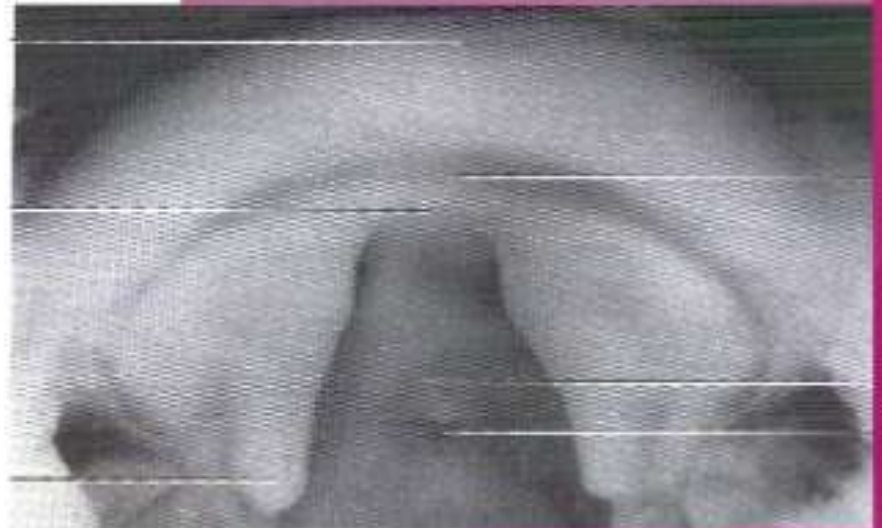With each other

Primary palate

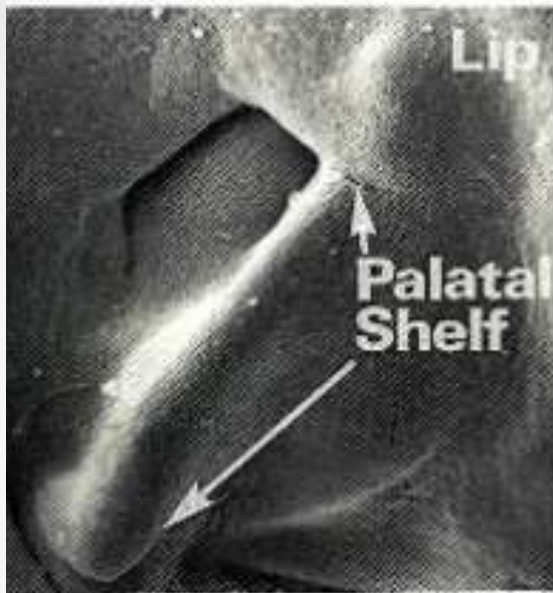
Nasal septum

Secondary palate

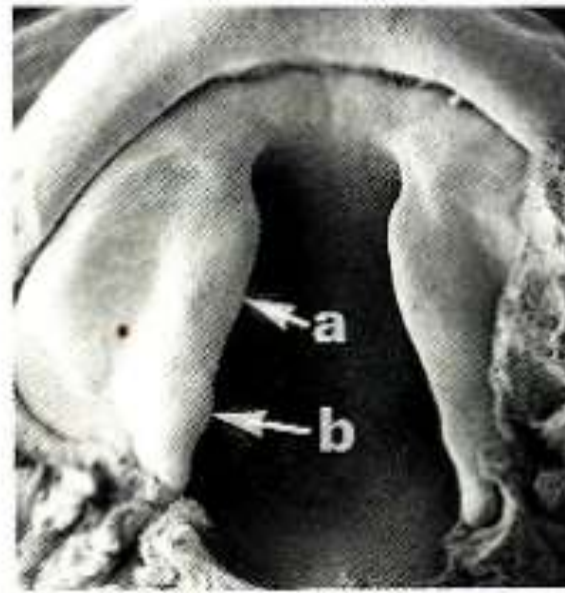
Intermaxillary Segment



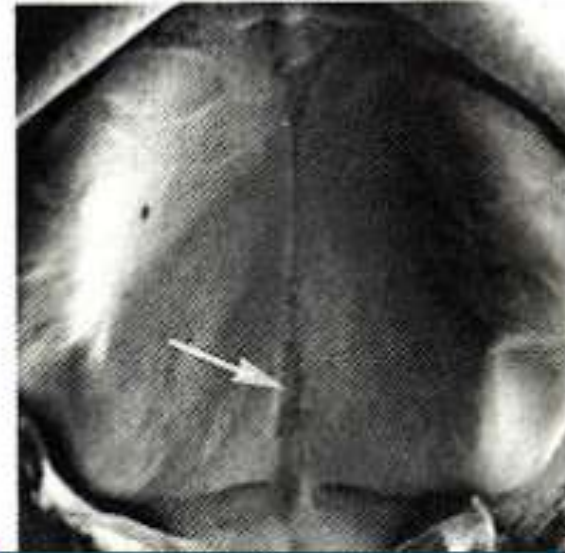
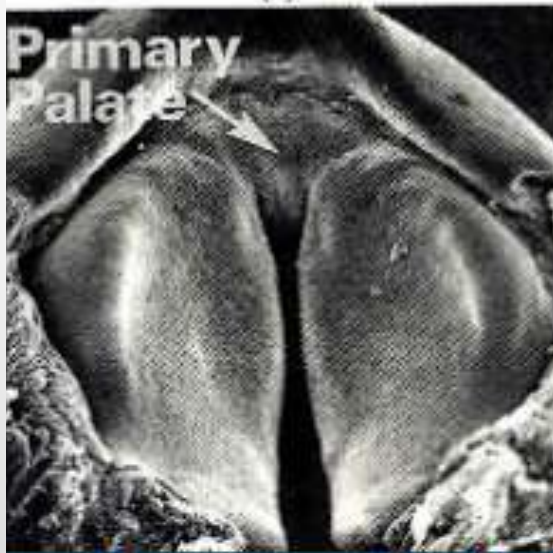
# FUSION OF PALATAL SHELVES



(a)



(b)



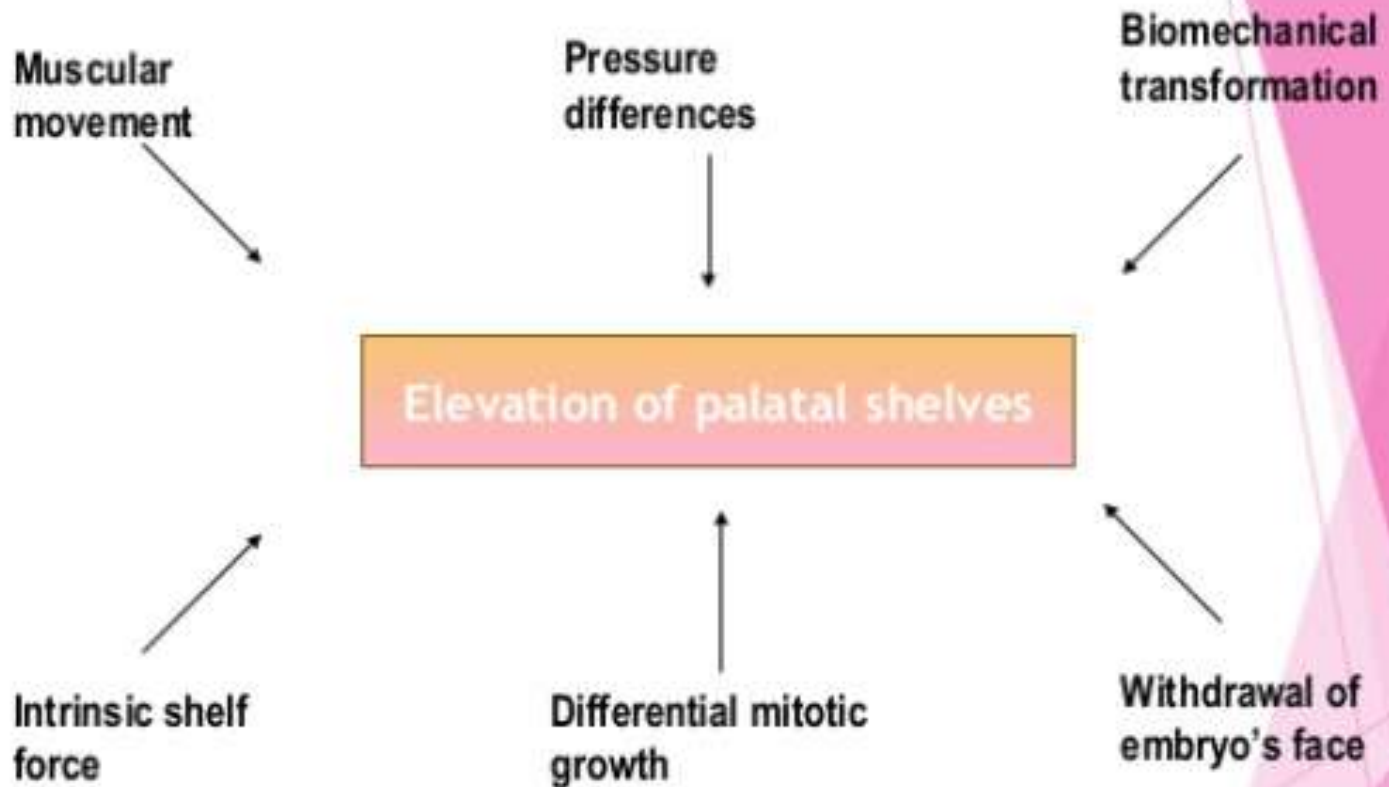
Entire palate does not fuse at the same time  
Initially contact occur  
In the central region  
of 2ndary palate post.  
to premaxilla.  
Extended anteriorly  
and posteriorly

# ELEVATION OF PALATAL SHELVES

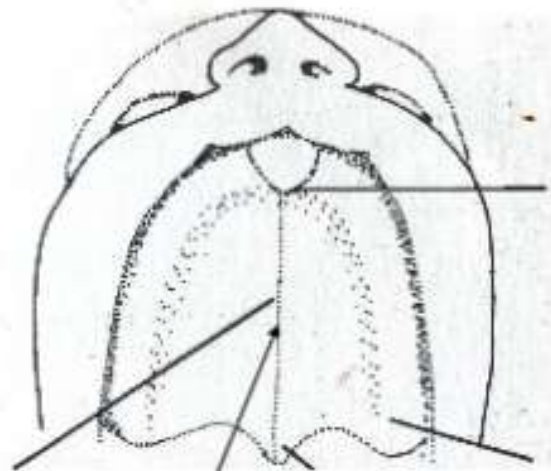
At 6 weeks

- Tongue (undifferentiated tissue)  
pushes dorsally
- Palatal shelves become vertical
- Elevation occurs from vertical to horizontal position

- **At 8 weeks**

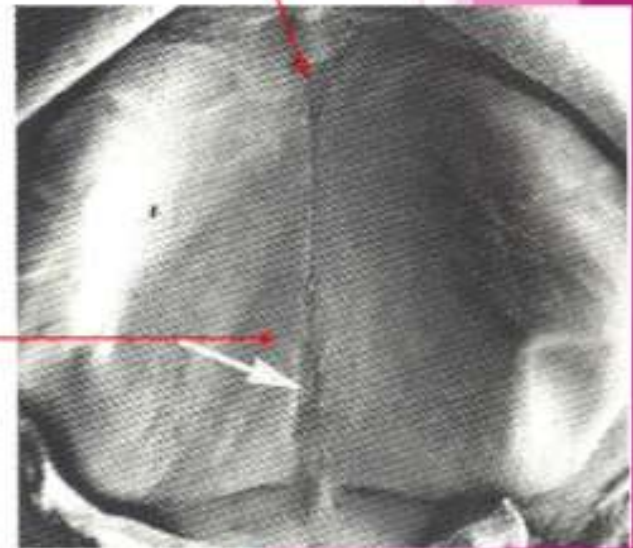






**Incisive foramen**

**Mid palatine  
raphe**





# *Development of face and palate*

5 processes formed by proliferation of neural crest cells (ectoderm)

These cells migrate into arches

**1 frontonasal process –**

**2 maxillary processes –**

**2 mandibular processes –**

# *Development of face and palate*

## **1 FRONTAL NASAL PROCESS:**

2 nasal placodes develop

Each invaginated to form:

**Nasal pit** – forms nasal cavities – open in pharynx posteriorly

**Lateral nasal fold** – ala of nose

**Medial nasal fold** – fuse together to form:

**Surface**: middle part of nose, filtrum of upper lip

**Deep**: anterior upper jaw with Incisor teeth, primary palate with incisive fossa

Also forms nasal septum

# *Development of face and palate*

## **2 MAXILLARY PROCESSES:**

Grow medially

Fuse with medial nasal fold – form upper lip

Fuse with lateral nasal fold – form nasolacrimal duct

Fuse with mandibular process – forms cheeks

Forms palatine shelves

# *Development of face and palate*

## **2 MANDIBULAR PROCESSES:**

Fuse with each other medially – form lower lip and chin

fuse with maxillary process – forms cheeks

NB: Degree of fusion of max. and mand. processes determine width of mouth

Prominence	Derivatives
Frontonasal	Forehead, bridge of nose, medial and lateral nasal prominences
Medial nasal	Philtrum, primary palate, upper 4 incisors and associated jaw
Lateral nasal	Sides of the nose
Maxillary (1st pharyngeal arch)	Cheeks, lateral upper lip, secondary palate, lateral upper jaw
Mandibular (1st pharyngeal arch)	Lower lip and jaw

Thank you



# Classification of cleft lip and palate

Lect. Hussein T. Abed

10\2\2021

# Clefts are described

Based on

A) structures involved:

Lip

Alveolas

Hard palate

Soft palate

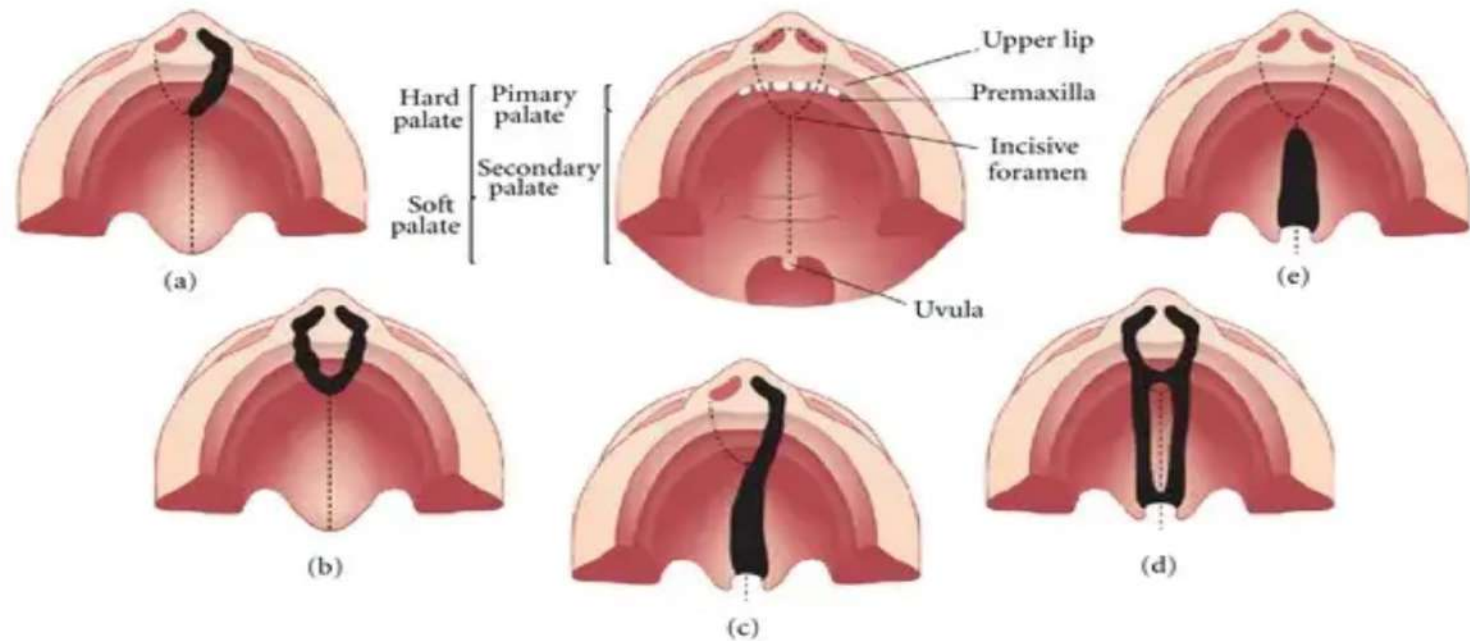
B) Laterality:

Unilateral left

Unilateral Right

Bilateral

C) Severity: Width & Extent of structures involved



- a) Uni Cleft L & Alv involved
- b) Bi Cleft L & Alv involved
- c) Uni Cleft L & P
- d) Bi Cleft L & P
- e) Cleft P only

# Clefts can be

**Isolated (Cleft lip or palate only,  
combination)**

**Unilateral or Bilateral**

**Complete or Incomplete**

# *Victor Veau' s classification*

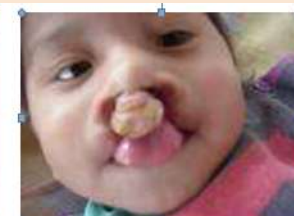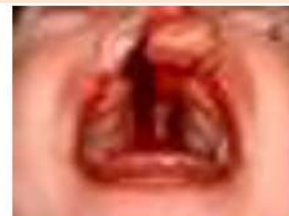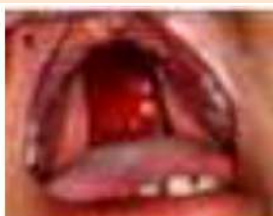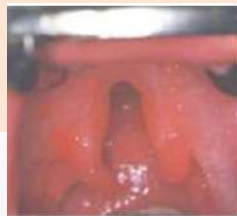## **B) CLEFT PALATE.**

Class I. Clefts involving soft palate only.

Class II. Clefts involving soft and hard palates up to incisive foramen.

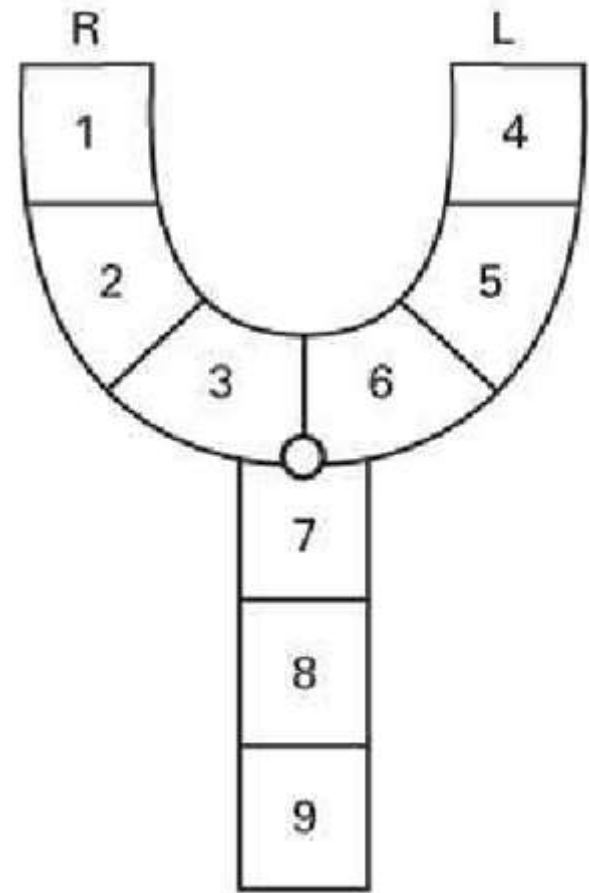
Class III. Clefts of soft and hard palates, right forwards through alveolar ridge and continues into lip on one side.

Class IV. Same as Class III only associated with bilateral harelip.



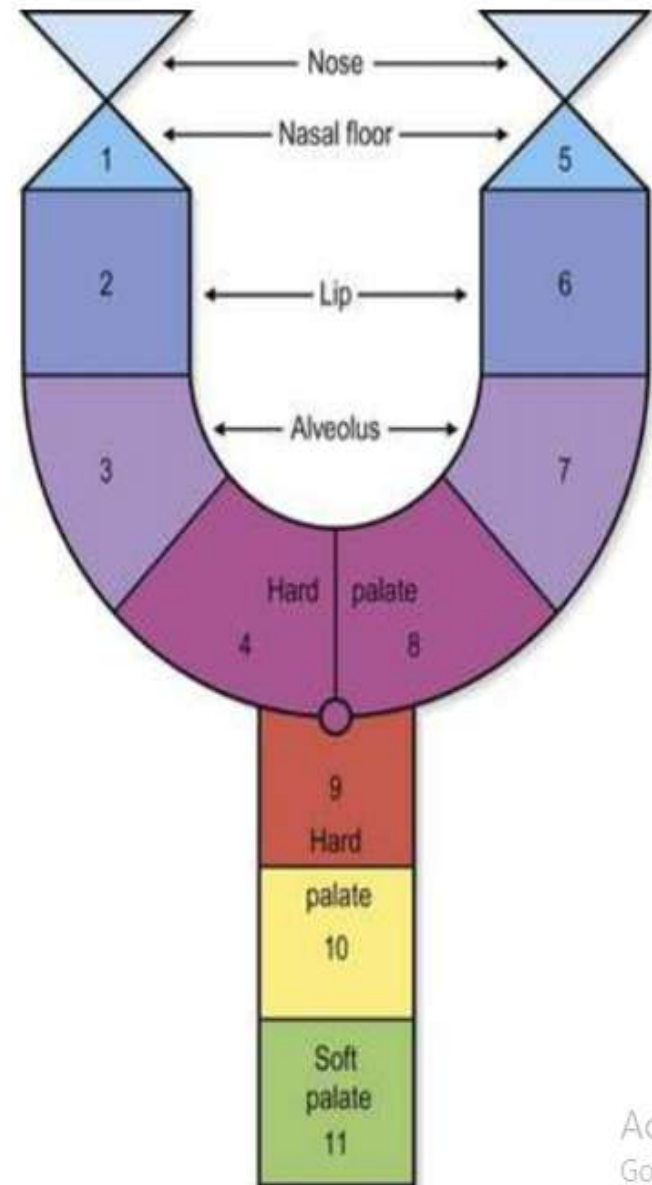
# stripped Y classification (1971)

- 1 R lip
- 2 R alveolus
- 3 R palate anterior to the incisive foramen
- 4 L lip
- 5 L alveolus
- 6 L palate anterior to the incisive foramen
- 7 anterior hard palate
- 8 posterior hard palate
- 9 soft palate

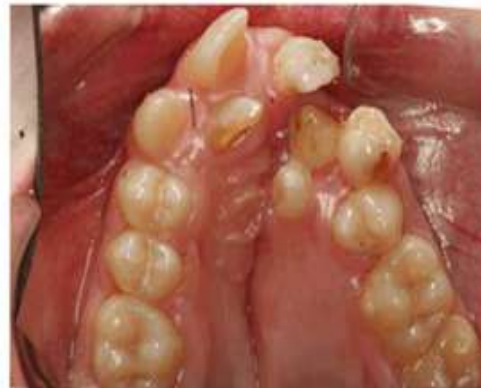
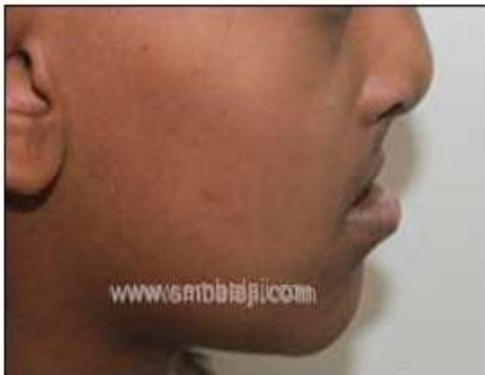



**Kernahan and Stark's  
stripped-Y:  
Modification by Ehlsaky  
(1973) and Millard  
(1976)**



# PROBLEMS ASSOCIATED WITH CLEFT LIP & PALATE



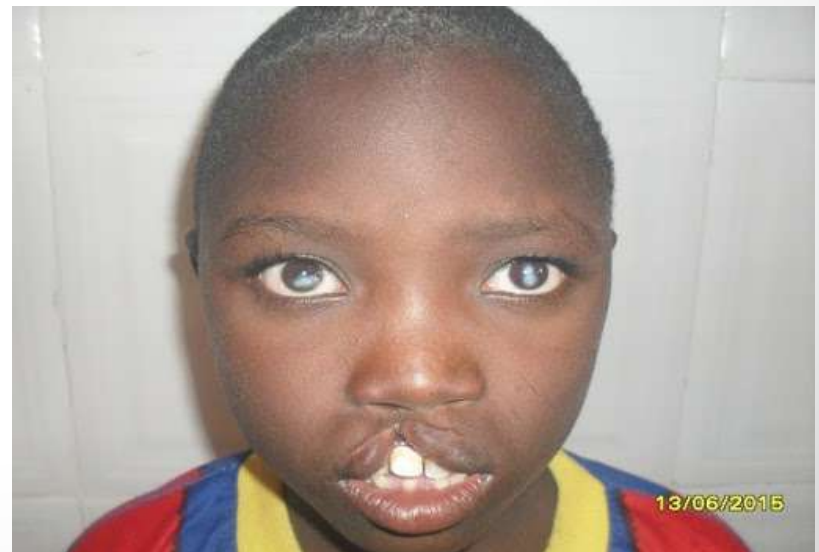
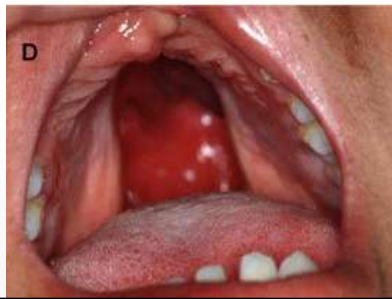
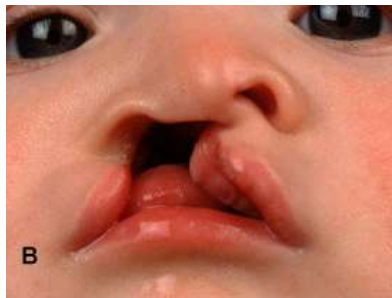
Activate

# Disabilities associated by the presence of cleft palate

1. **Esthetic problem:** due to - Basic anatomic deformity  
- Deficient facial growth

2. **Improper mastication:** The masticatory function is impaired because babies cannot feed due to lack of negative pressure, food escape through the nasal cavity and the presence of missing teeth and malocclusion.



# 3. Feeding problems

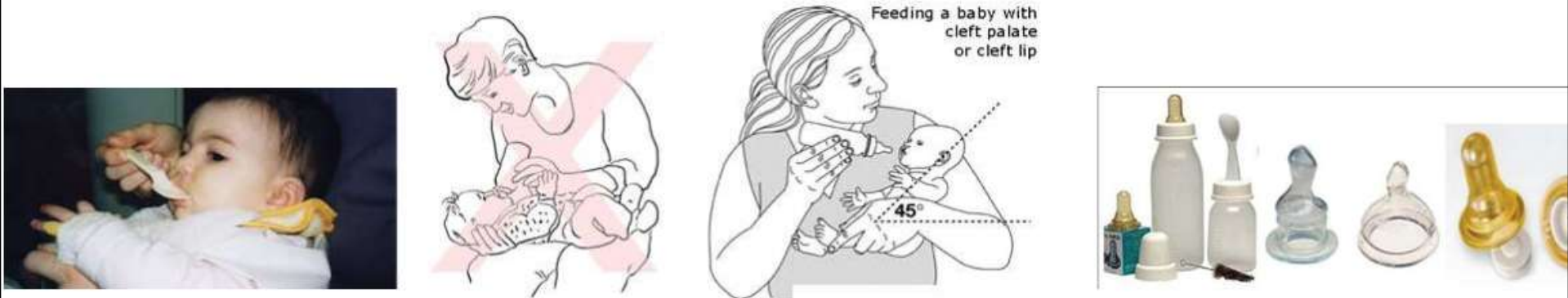
Swallowing is impaired when cleft occurs in both hard and soft palate. The baby should be placed in upright position and a special nipple is used during feeding.

presence of Oronasal fistulas

Draining of oral fluids in nasal cavity and vice versa

Bottle, cup and spoon, tube feeding

Infant held at 30-45 angle to aid swallowing





## 4. Dental problems

Missing, malformed, and supernumerary teeth, Malocclusion

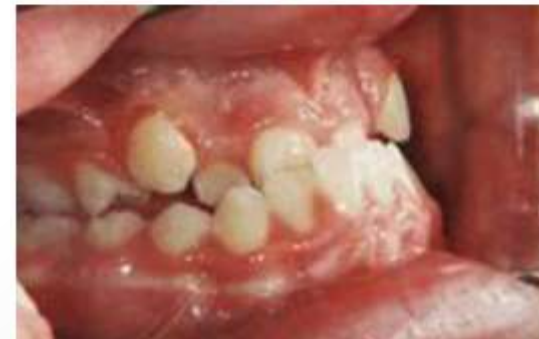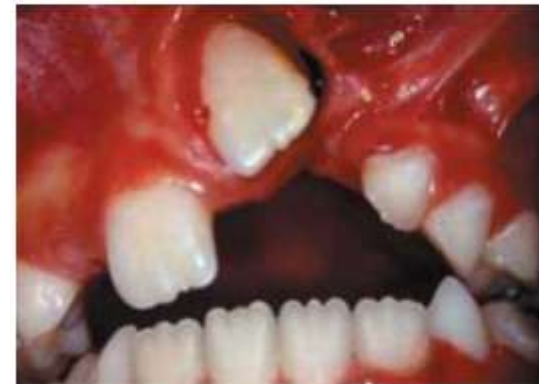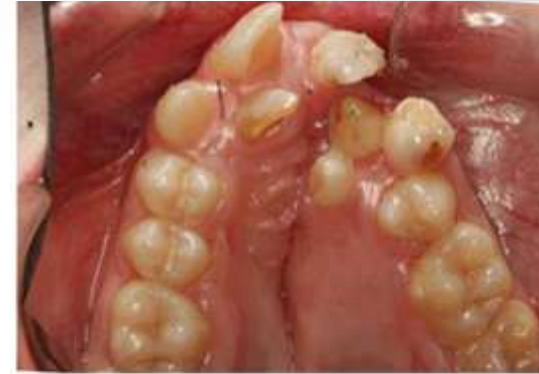Tooth agenesis, hypodontia (most common) Supernumerary teeth (2<sup>nd</sup> most common)

Enamel hypoplasia

(CI iii) Crossbites

Ectopic eruption, transposition

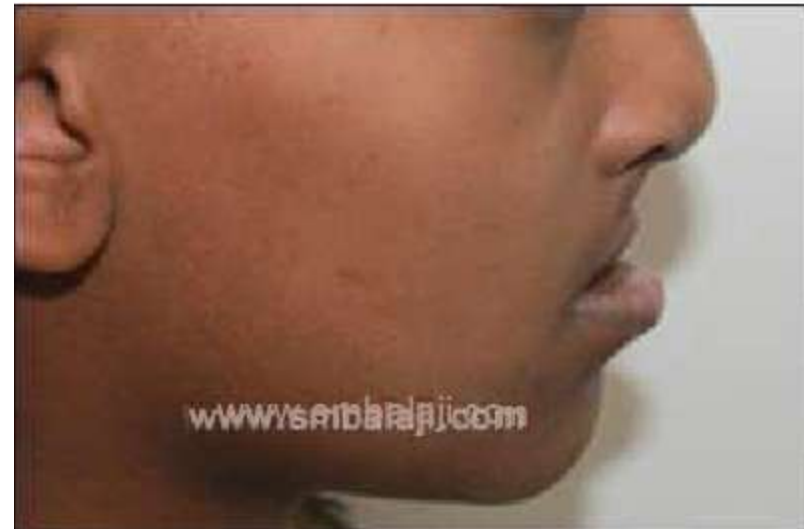Taurodontism, dilacerations





# 5. skeletal problems

- Maxillary deficiency
- Mandibular prognathism
- Class III malocclusion
- Concave profile



**6. Speech problems** (see speech & Palato (velo) pharyngeal mechanism)

- Velopharyngeal incompetence
- Secondary articulation disorders

**7. Otologic problems**

Eustachian tube dysfunction

Chronic ear disease

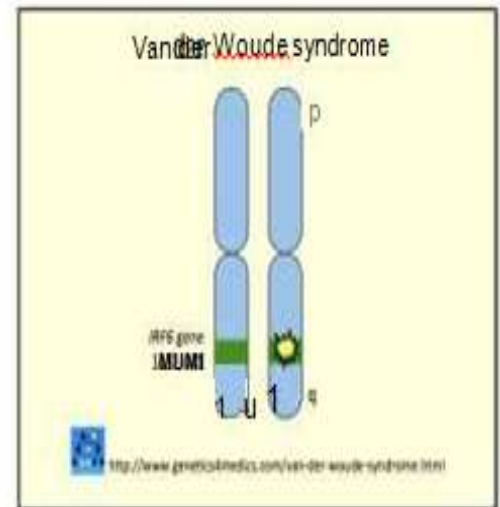
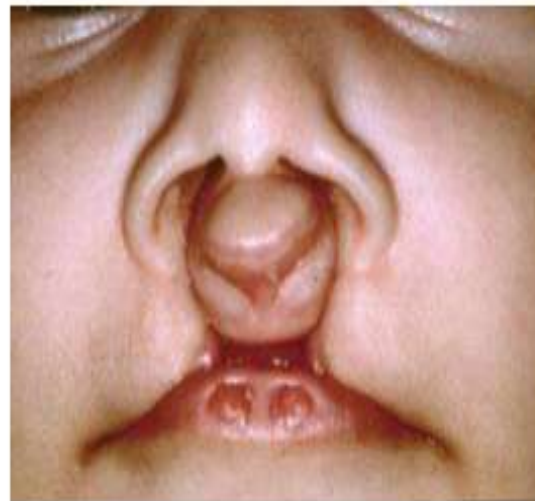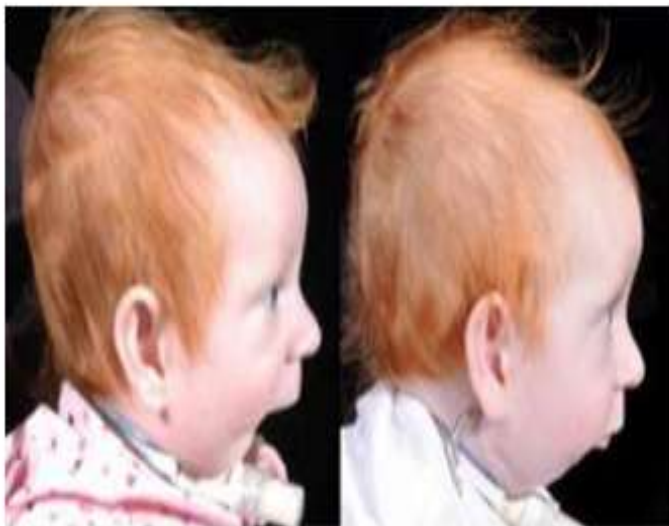Hearing loss

**8. General health:** The general health of the child is affected due to inadequate nutrition and mouth breathing.

**9. Psychological problems:** Children with clefts have difficulty in adjusting with society. They may withdraw or turn aggressive.

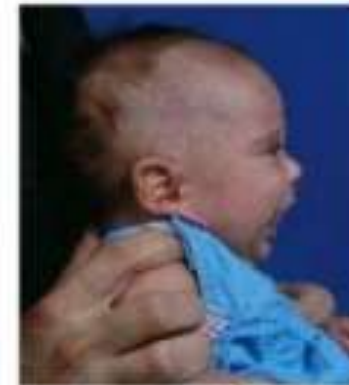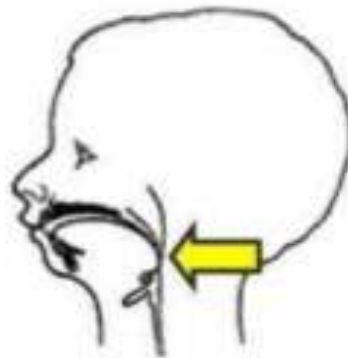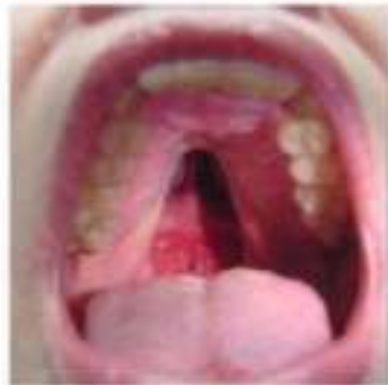**10. Additional congenital anomalies.**

# SYNDROMES ASSOCIATED WITH CLEFT LIP & PALATE

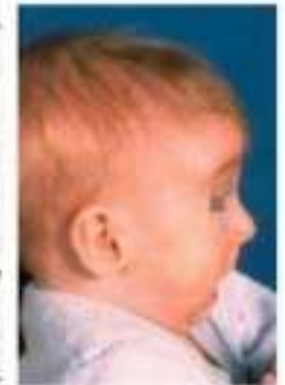

# Pierre Robin Syndrome

## Features



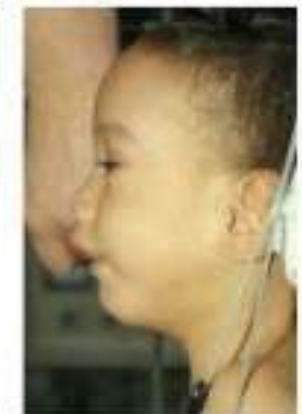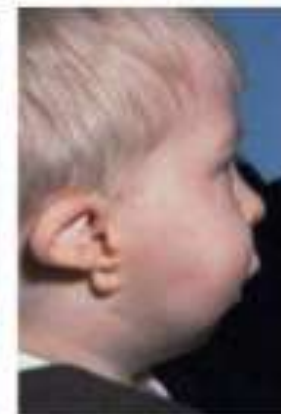(courtesy of Dr. Hutchinson)



- Cleft palate
- Retrognathia
- Macroglossia and ankloglossia uncommon

■ Glossoptosis

■ Micrognathia

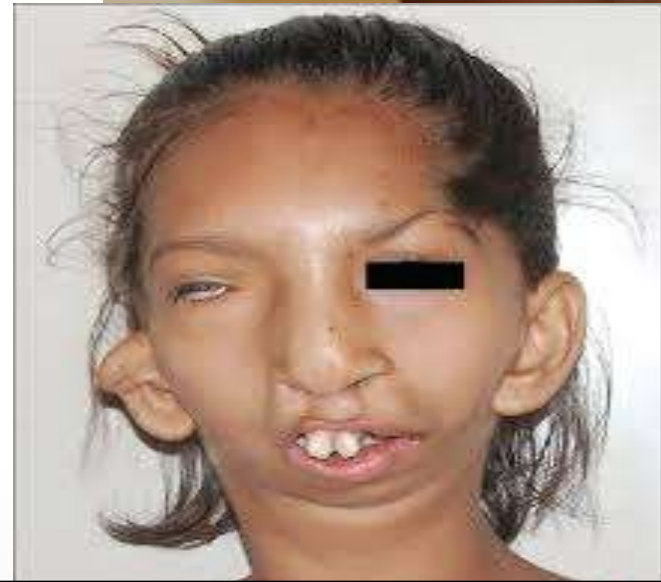
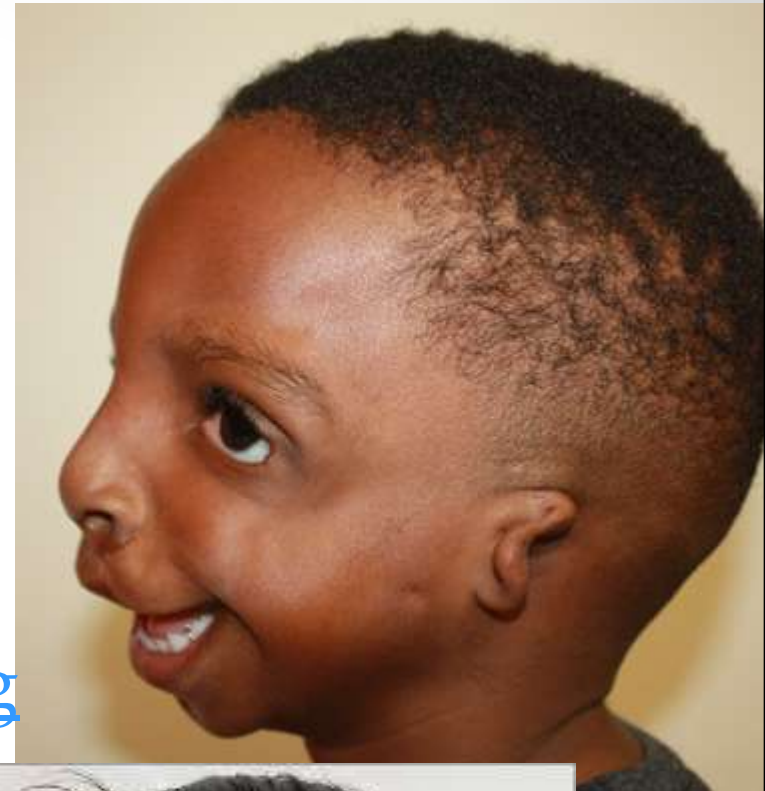
(courtesy of Dr. Hutchinson)

(Jackson, 2009)

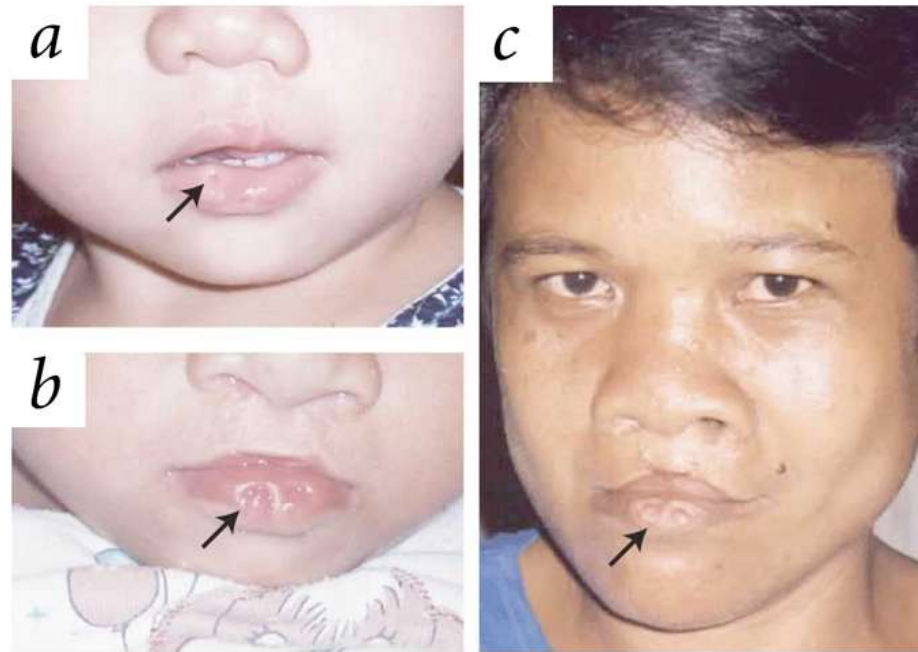
**Treacher Collins syndrome (TCS)** is a [genetic disorder](#) characterized by deformities of the ears, eyes, cheekbones, and chin.

Complications may include breathing problems, problems seeing, [cleft palate](#), and [hearing loss](#).





# Van de Wroude (AD) syndrom



is a genetic disorder characterized by the combination of lower lip pits, cleft lip with or without cleft palate (CL/P), and cleft palate only (CPO).

Thank you

# Classification of cleft lip and palate

Lect. Hussein T. Abed

10\2\2021

# Clefts are described

Based on

A) structures involved:

Lip

Alveolas

Hard palate

Soft palate

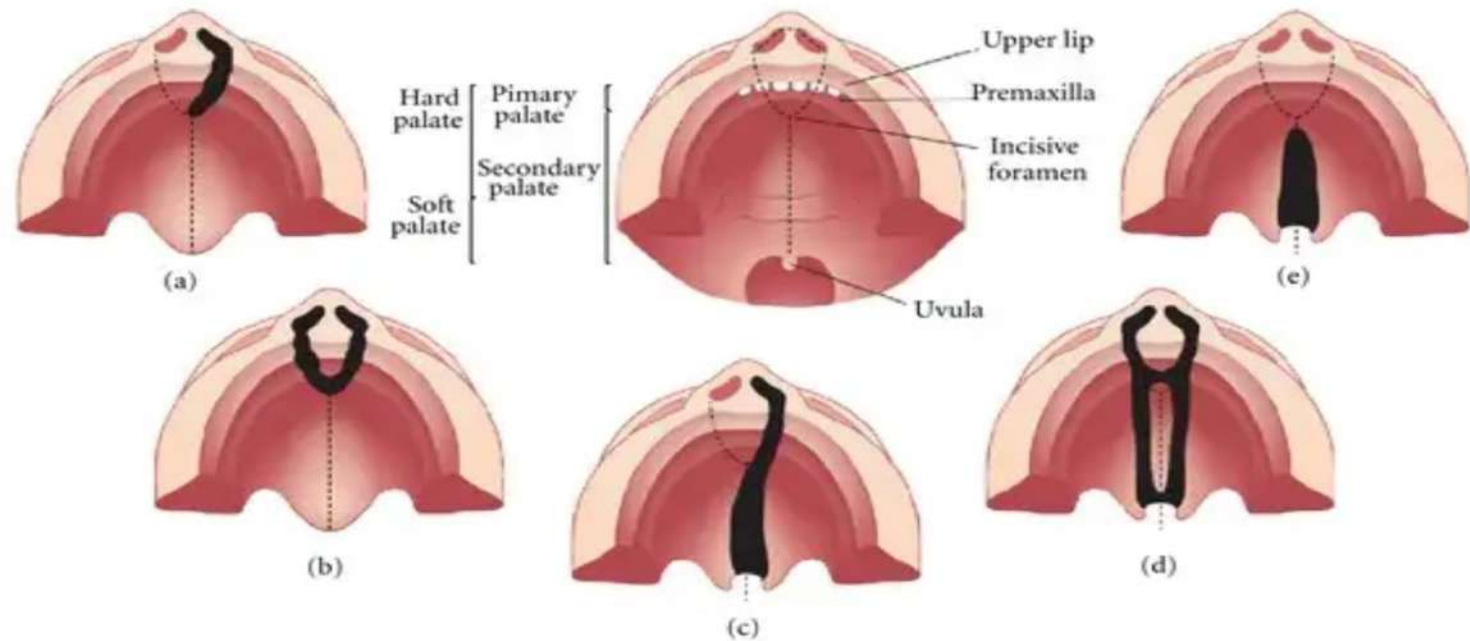
B) Laterality:

Unilateral left

Unilateral Right

Bilateral

C) Severity: Width & Extent of structures involved



- a) Uni Cleft L & Alv involved
- b) Bi Cleft L & Alv involved
- c) Uni Cleft L & P
- d) Bi Cleft L & P
- e) Cleft P only

# Clefts can be

**Isolated (Cleft lip or palate only,  
combination)**

**Unilateral or Bilateral**

**Complete or Incomplete**



# *Victor Veau' s classification*

## **B) CLEFT PALATE.**

Class I. Clefts involving soft palate only.

Class II. Clefts involving soft and hard palates up to incisive foramen.

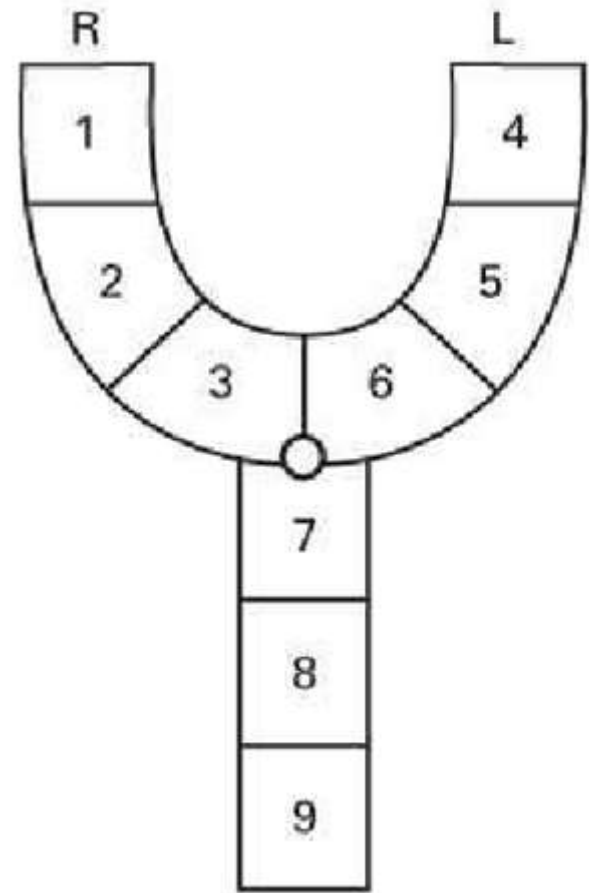
Class III. Clefts of soft and hard palates, right forwards through alveolar ridge and continues into lip on one side.

Class IV. Same as Class III only associated with bilateral harelip.

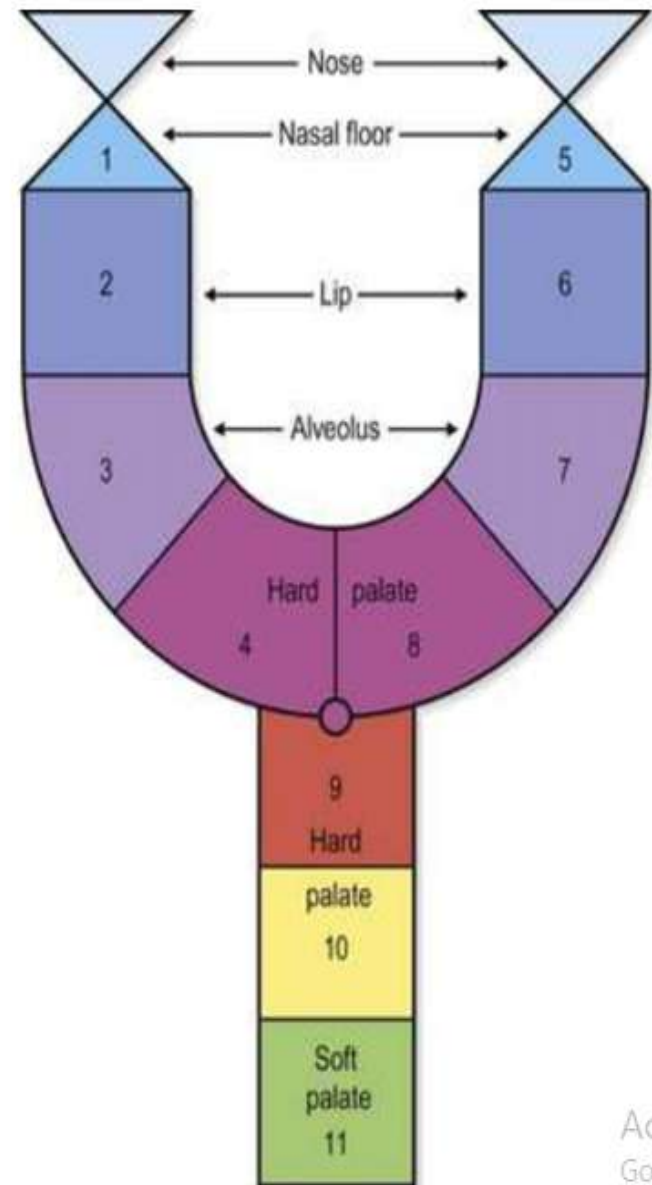


# stripped Y classification (1971)

- 1 R lip
- 2 R alveolus
- 3 R palate anterior to the incisive foramen
- 4 L lip
- 5 L alveolus
- 6 L palate anterior to the incisive foramen
- 7 anterior hard palate
- 8 posterior hard palate
- 9 soft palate




**Kernahan and Stark's  
stripped-Y:  
Modification by Ehlsaky  
(1973) and Millard  
(1976)**



# PROBLEMS ASSOCIATED WITH CLEFT LIP & PALATE



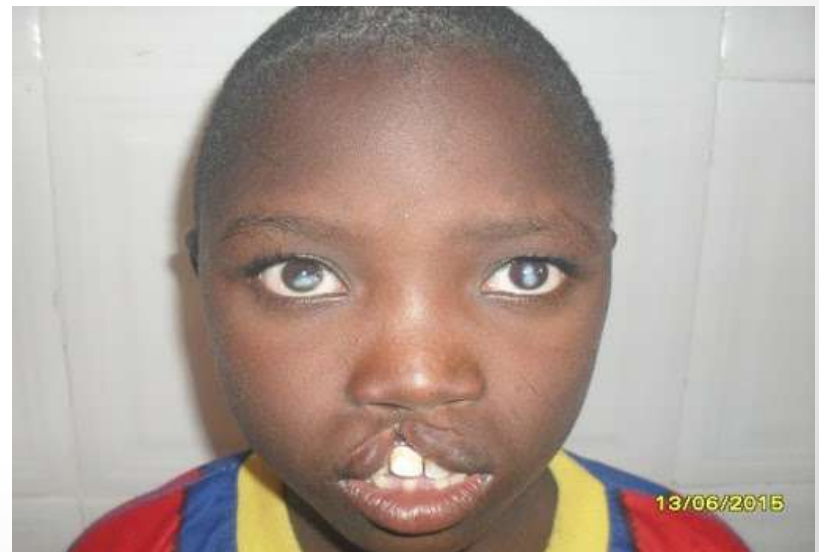


Activate

# Disabilities associated by the presence of cleft palate

1. **Esthetic problem:** due to - Basic anatomic deformity  
- Deficient facial growth

2. **Improper mastication:** The masticatory function is impaired because babies cannot feed due to lack of negative pressure, food escape through the nasal cavity and the presence of missing teeth and malocclusion.





# 3. Feeding problems

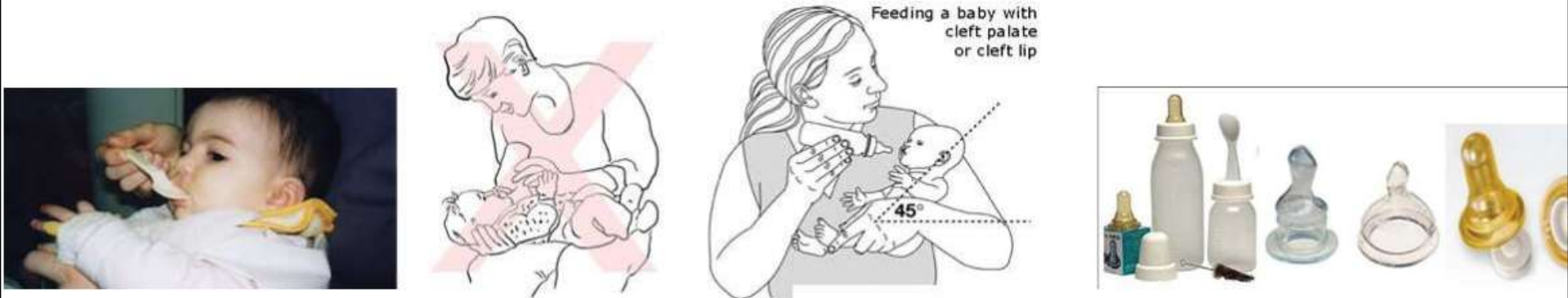
Swallowing is impaired when cleft occurs in both hard and soft palate. The baby should be placed in upright position and a special nipple is used during feeding.

presence of Oronasal fistulas

Draining of oral fluids in nasal cavity and vice versa

Bottle, cup and spoon, tube feeding

Infant held at 30-45 angle to aid swallowing



## 4. Dental problems

Missing, malformed, and supernumerary teeth, Malocclusion

Tooth agenesis, hypodontia (most common) Supernumerary teeth (2<sup>nd</sup> most common)

Enamel hypoplasia

(CI iii) Crossbites

Ectopic eruption, transposition

Taurodontism, dilacerations



# 5. skeletal problems

- Maxillary deficiency
- Mandibular prognathism
- Class III malocclusion
- Concave profile



**6. Speech problems** (see speech & Palato (velo) pharyngeal mechanism)

- Velopharyngeal incompetence
- Secondary articulation disorders

**7. Otologic problems**

Eustachian tube dysfunction

Chronic ear disease

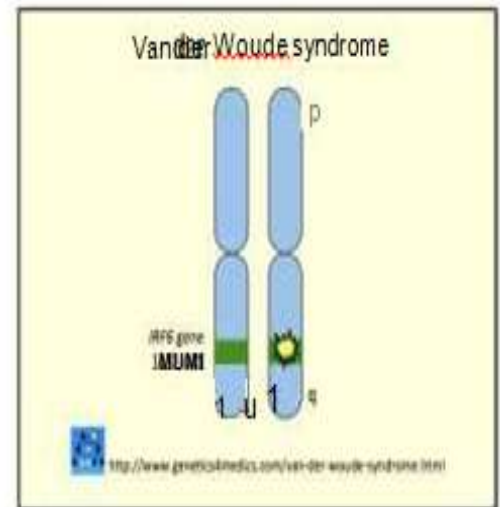
Hearing loss

**8. General health:** The general health of the child is affected due to inadequate nutrition and mouth breathing.

**9. Psychological problems:** Children with clefts have difficulty in adjusting with society. They may withdraw or turn aggressive.

**10. Additional congenital anomalies.**

# SYNDROMES ASSOCIATED WITH CLEFT LIP & PALATE





# Pierre Robin Syndrome

## Features



(courtesy of Dr. Hutchinson)



- Cleft palate
- Retrognathia
- Macroglossia and ankloglossia uncommon

■ Glossoptosis

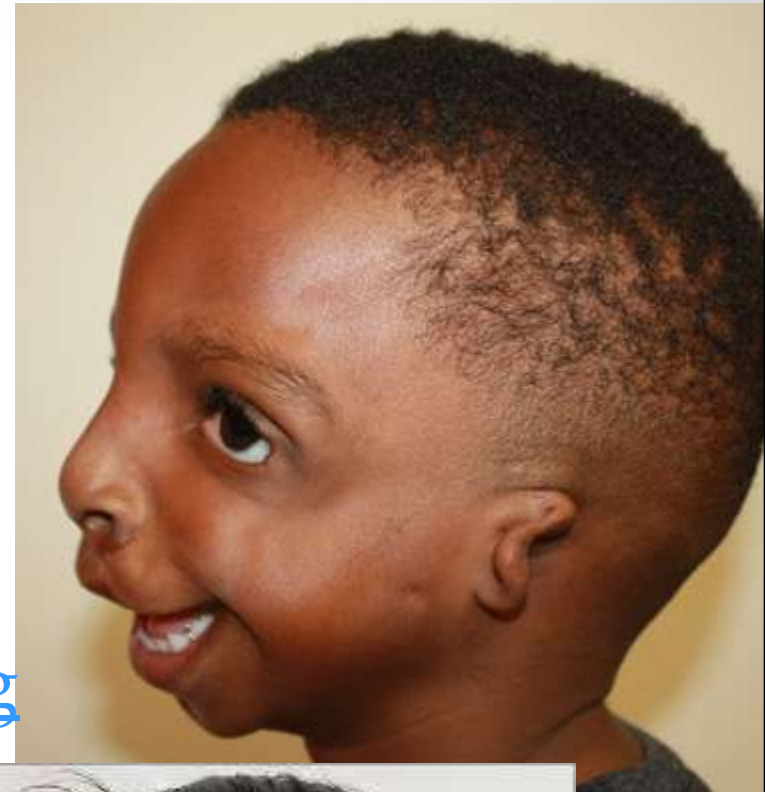■ Micrognathia



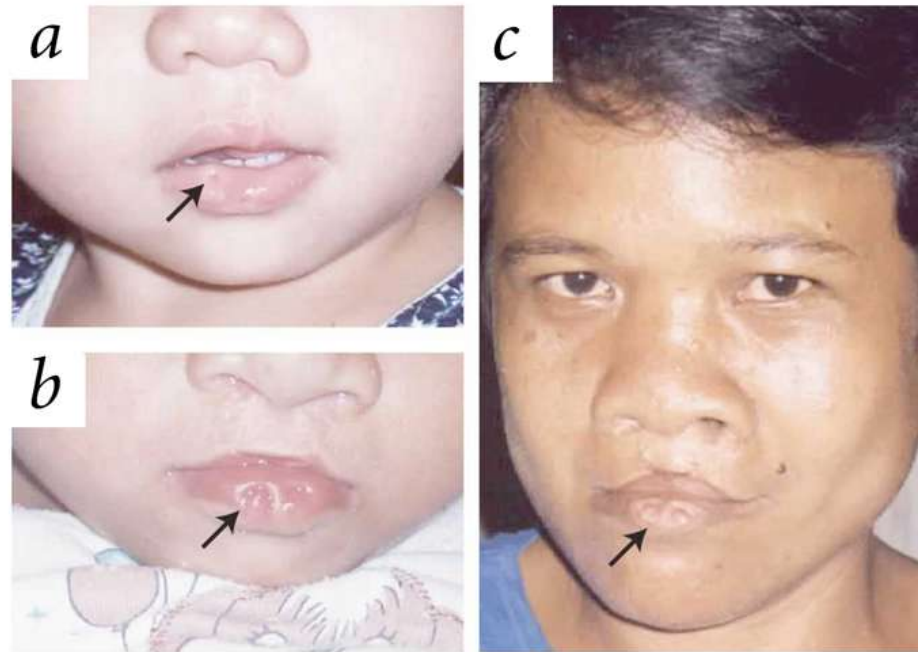
(courtesy of Dr. Hutchinson)

(Jackson, 2009)

**Treacher Collins syndrome (TCS)** is a [genetic disorder](#) characterized by deformities of the ears, eyes, cheekbones, and chin. Complications may include breathing problems, problems seeing, [cleft palate](#), and [hearing loss](#).



# Van de Wroude (AD) syndrom



is a genetic disorder characterized by the combination of lower lip pits, cleft lip with or without cleft palate (CL/P), and cleft palate only (CPO).

Thank you

# Maxillary obturator: lab technique

Lect Hussein T. Abed

2.6.2021

# Techniques:

Several techniques are used for the fabrication of hollow bulb obturator .

The commonly used ones are:

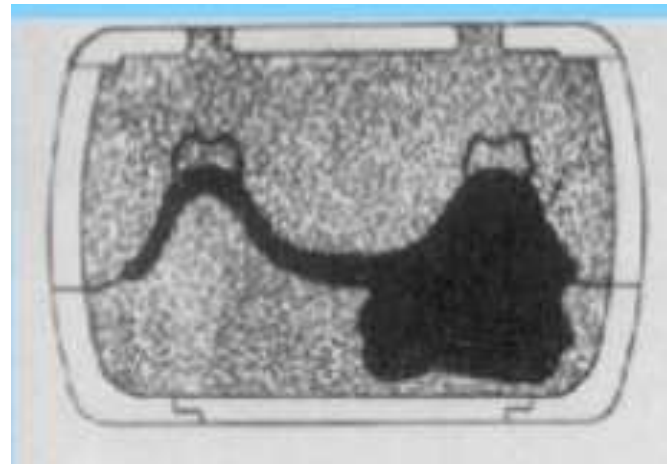
- 1.two piece hollow obturator
- 2.one piece hollow obturator




# FABRICATION OF ONE PIECE HOLLOW BULB OBTURATOR

(According to Challan and Barnett) Procedure:

1. Try the trial denture in the mouth and make necessary modifications.
2. Waxup the denture after the try in.
3. Invest the denture in the flask in the usual manner.




4. Boil out the wax in the conventional manner.
5. Block out the undercut area in the cast of the defect

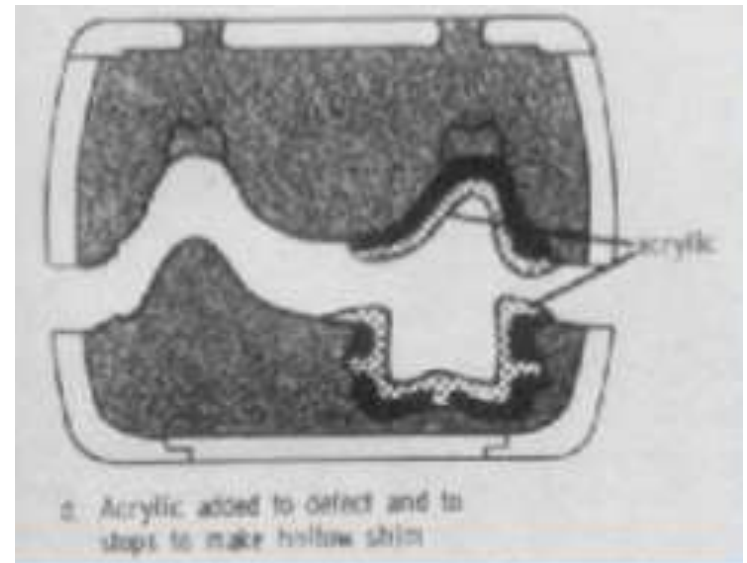


# Construction of autopolymerizing acrylic resin shim

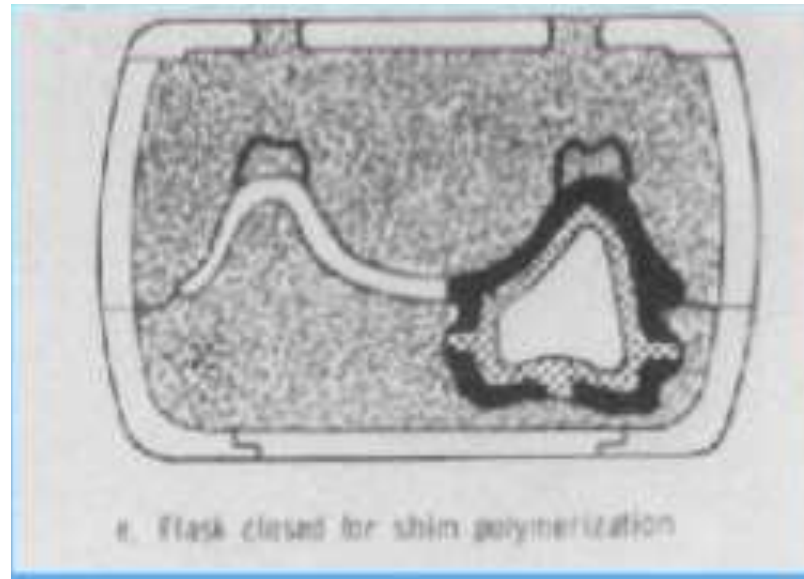
- Relieve the entire defect area with one thickness of base plate
- Place three steps deep enough to be deep enough to cast. of the master
- Place one in the top half of the flange area to form the top wall of the shim. This will provide space for heat cure acrylic resin on the palatal side of the denture.



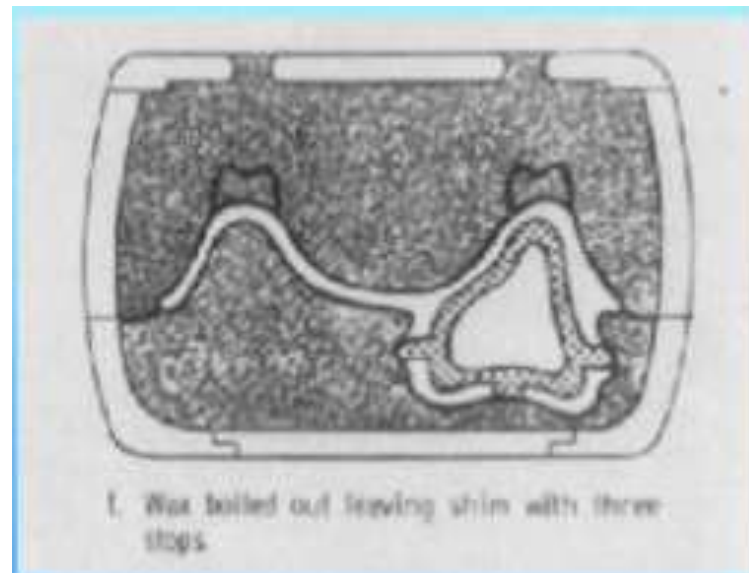
- Make the autopolymerizing acrylic resin and allow it to come to a dough consistency.
- Contour a layer of dough consistency acrylic resin over the wax relief.



- Close the flask, Allow the resin to cure for 15 min.

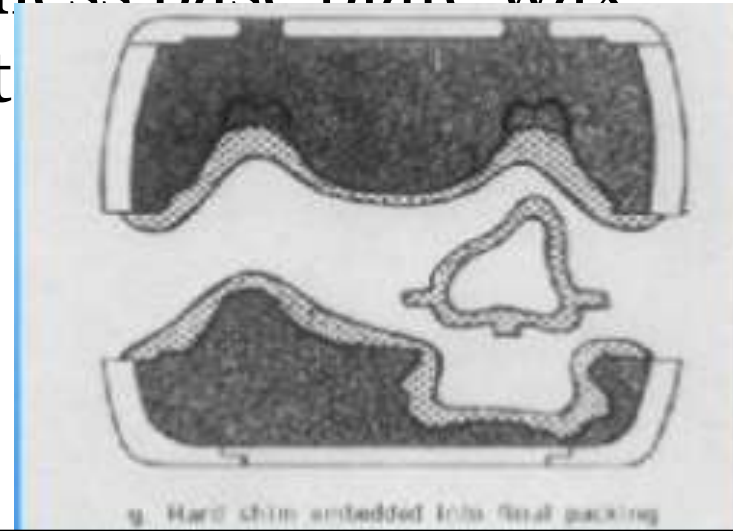

- Flush the wax from the acrylic resin shim with a steam of boiled water



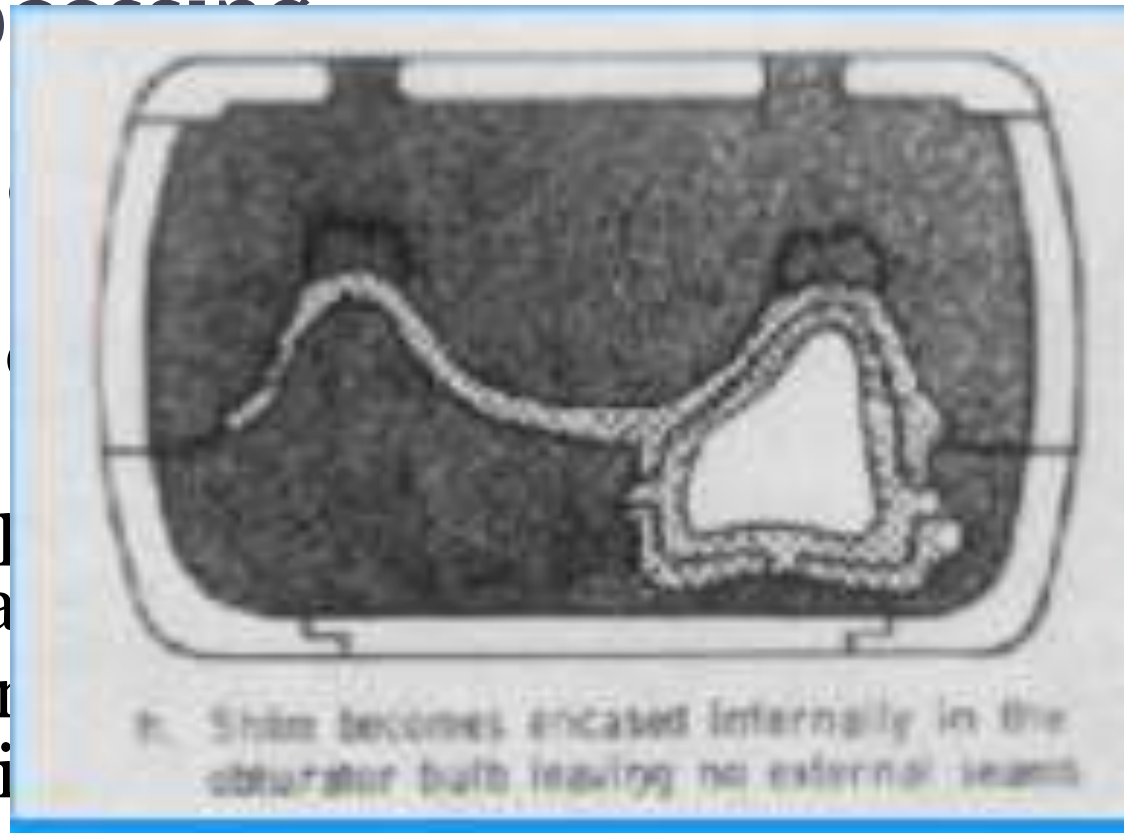


- Trim all the excess of acrylic resin from the shim.
- Replace the heat cure acrylic resin shim using 3 stops for correct positioning. At this stage see that there is at least one thickness base plate wax between the shim and the cast



# Placement of acrylic resin shim and denture processing

- Mix the heat in the usual manner.
- Place a layer of acrylic resin over the defect.
- Reinsert the plaster mold and the still soft acrylic resin.
- Add more acrylic resin and packing in the usual manner.
- Cure the resin in the usual manner.
- Deflask it and trim and polish in usual manner

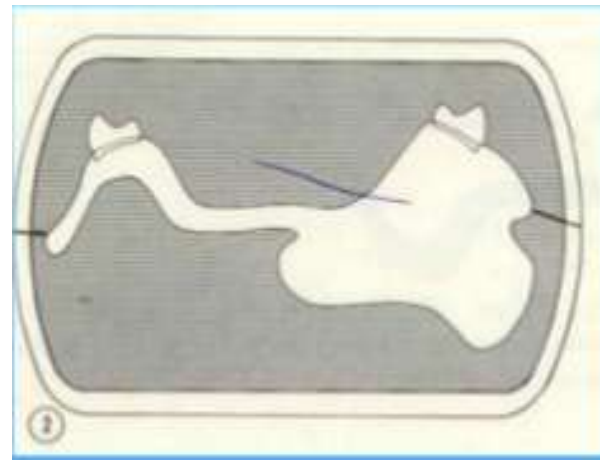


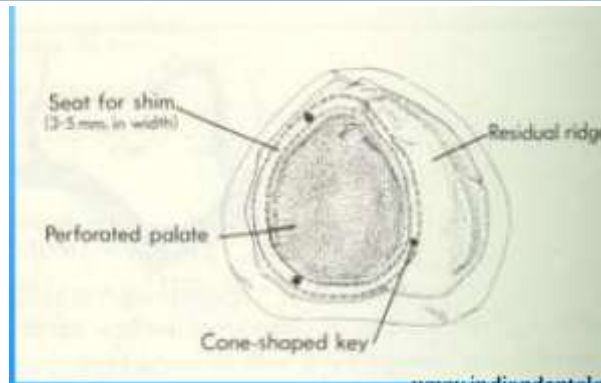
- Maxillary obturator with silicone-lined hollow extension (Takashi Ohyama, and Gold 1975)

The hollow extension consists of two layers of different materials. The **exterior** of the hollow extension, which is in apposition with the defect, is coated with a soft, **resilient silicone**. The **interior** of the hollow extension is fabricated of hard **self-curing acrylic resin**. The resiliency of the outer surface of the hollow extension facilitates insertion of the prosthesis into deep undercuts, providing for improved retention while minimizing the tissue irritation.

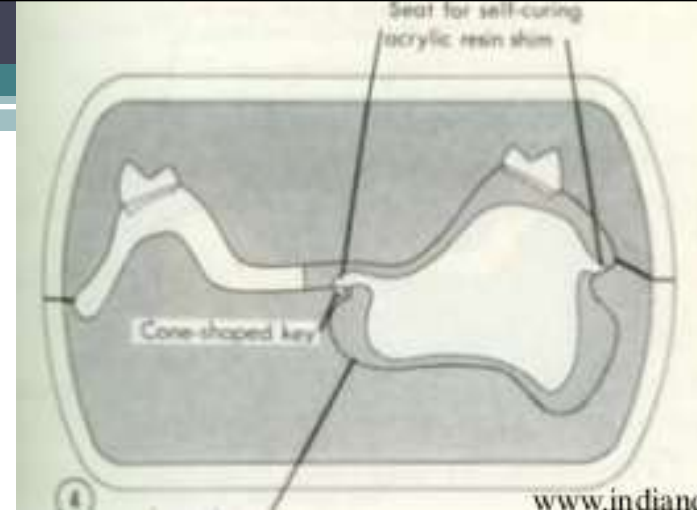
# Fabrication:-

- Step 1. Investing the obturator. Invest the wax dentur-obturator in a flask, and boil out the wax in the conventional manner.





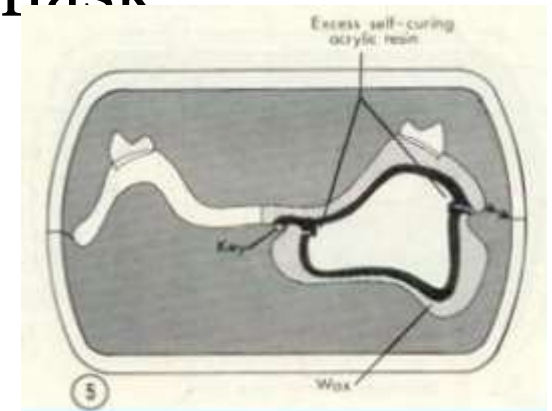
- Making the shim in self curing acrylic resin:-
- -Outline the seat, cut keys for the shim in the stone of the bottom half of the flask. The seat should encircle perforated palate, measuring about 3-5mm in width and extending laterally 1-2mm.
- To **maintain the relationship** of the shim to the cast, 3 cone shaped keys should be cut within the stone of the seat of the shim. The cone shaped keys relate the shim to its proper seat.



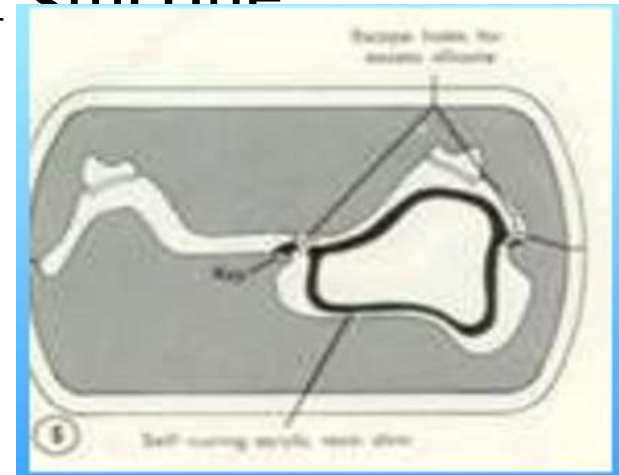
- Place **2 sheets** of base plate wax over the mould of the defect in the flask to **provide space for the silicone** between shim and the defect. Fill all remaining undercuts with wax so that the shim, made from self-curing acrylic resin, can be removed.
- For **relief**, place one thickness of baseplate wax over the teeth and palatal part of the mold on the side of the palatal defect in the top half of the flask. This wax will **provide space for a thickness** of heat- curing acrylic resin over the oral aspect of the prosthesis.



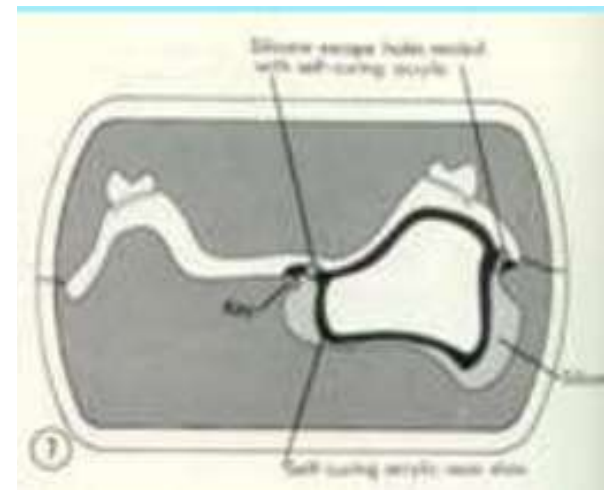
- Paint a layer of **thin foil** substitute on the wax relief and keyed seat for the shim. Put a mixture self-curing acrylic resin into the top and bottom halves of flask on the relief wax, and spread the resin evenly to approximate one or two thickness of baseplate wax. Then, close the flask



- Completely flush the wax away from the cured resin shim.
- Drill holes with a No.3 round bur at 1/2 inch intervals through the tip of the shim which communicates with the space for silicone

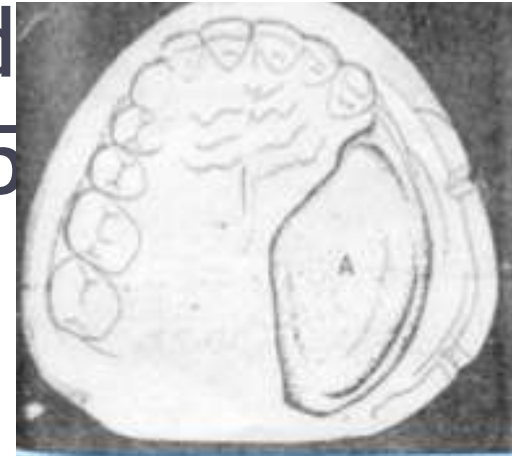

- Before packing the heat cure acrylic resin the silicone escape holes in the shim are cleaned out and closed by adding self-curing acrylic resin.



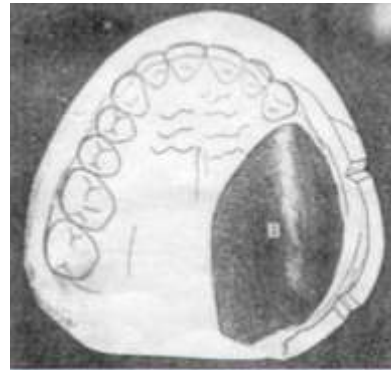
- ✓ Premade shim is then pressed into position over the silicone.
- ✓ Packing is done.
- ✓ Place the flask in a 165°F water bath for 9 hours.
- ✓ Trim and polish the acrylic resin parts of the obturator, trim the silicone flash with scissors, a sharp blade, or abrasive finishing wheels.

# FABRICATION OF TWO PIECE HOLLOW BULB OBTURATOR (According to Palmer and Coffey in 1985)



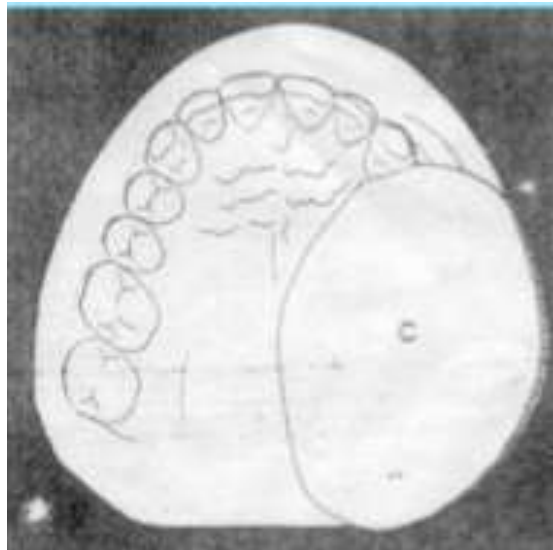
- **Method:**
- **1.** Make an impression that includes the palatal defect to be obturated.
- **2.** Pour a stone cast, separate, and key at the border of the cast

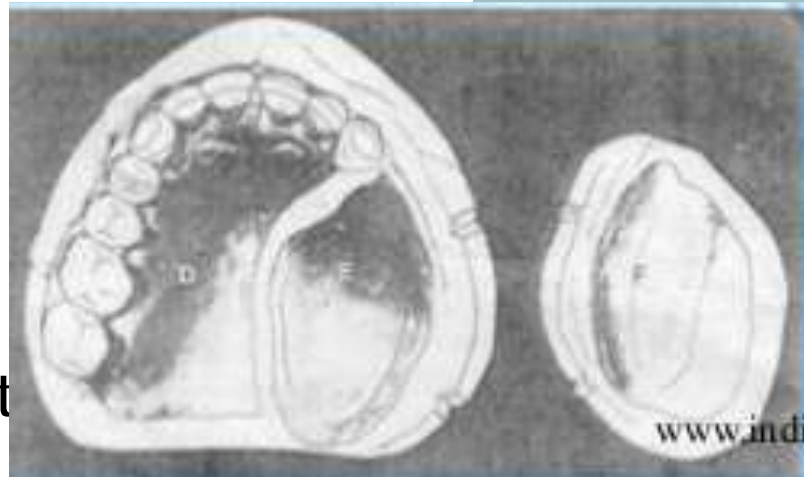
- Apply a suitable separating media to the stone surface
- Clay is sculpted to the palatal defect and missing alveolus





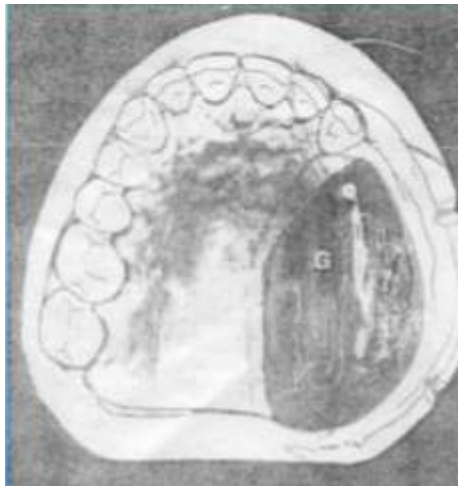- Pour a plaster (plaster cap) over the clay, including the keys in the master cast.





- Remove the plaster cap and discard it.
- Coat the tissue side of the plastic cap with a suitable separating media.
- Apply thin layer of self cure acrylic resin to the defect (E) and tissue surface of the plaster cap(F). - Soft acrylic resin is added into the border of E and F and into the border of D adjacent to E.
- Invert the plastic cap and F into the master cast. Be sure the acrylic resin is kept moist with monomer before closure.
- Check the key for the proper fit and allow the acrylic resin to cure.

- Remove and finish the bulb in usual manner



# Simplified method of making a hollow obturator (Victor Matalon in 1986)

- Method:-
- Invest the impression for obturator in a flask in the normal manner
- Remove the impression material.
- Place separating medium on the investment surface
- Roll out heat-curing acrylic resin to an approximate 2 mm thickness when it is in the doughy stage.
- Pack the periphery of the obturator with rolled out heat cure acrylic resin.
- Fill the center of the concavity created in the previous step with granulated sugar to within approximately 2 mm of the top.

- Pack the mould with rolled out heat-curing resing in the usual manner.
- process the acrylic resin according to manufacturer's specifications.
- Deflask the prosthesis.
- Using a No.8 bur, drill a hole in the superior surface of the obturator.
- Pour out the sugar.
- Use autopolymerizing acrylic resin to seal the hole made by the bur.
- Finish the restoration in the customary maner.

# Aaron Schneider in 1978

- described another method of fabrication of hollow bulb obturator where the defect cavity is filled with **crushed ice of filled with water and freezed overnight**. After processing two halves are drilled to remove the water and the holes are closed with autopolymerizing resin.





Thank you

# Maxillary obturator: lab technique

Lect Hussein T. Abed

2.6.2021

# Techniques:

Several techniques are used for the fabrication of hollow bulb obturator .

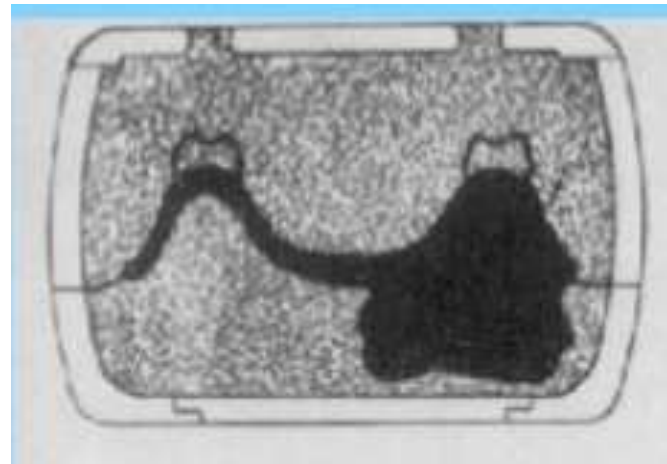
The commonly used ones are:

- 1.two piece hollow obturator
- 2.one piece hollow obturator

# FABRICATION OF ONE PIECE HOLLOW BULB OBTURATOR

(According to Challan and Barnett) Procedure:

1. Try the trial denture in the mouth and make necessary modifications.
2. Waxup the denture after the try in.
3. Invest the denture in the flask in the usual manner.




4. Boil out the wax in the conventional manner.
5. Block out the undercut area in the cast of the defect

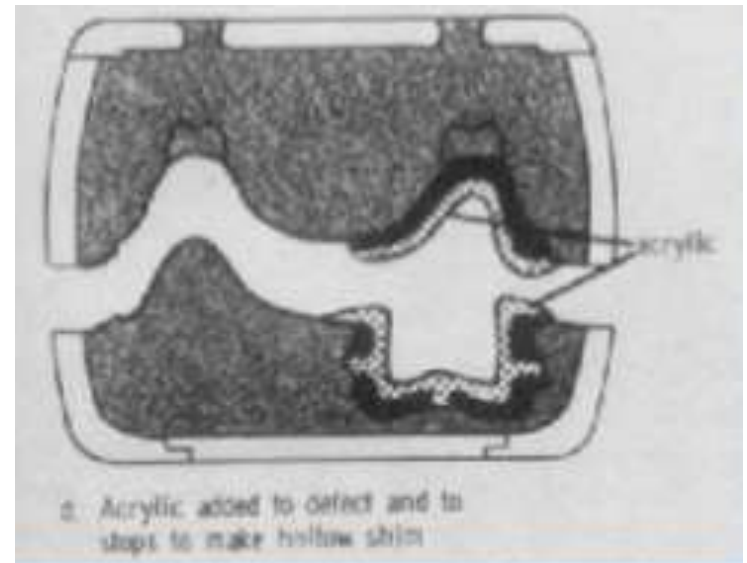


# Construction of autopolymerizing acrylic resin shim

- Relieve the entire defect area with one thickness of base plate
- Place three steps deep enough to be deep enough to cast. of the master
- Place one in the top half of the flange area to form the top wall of the shim. This will provide space for heat cure acrylic resin on the palatal side of the denture.

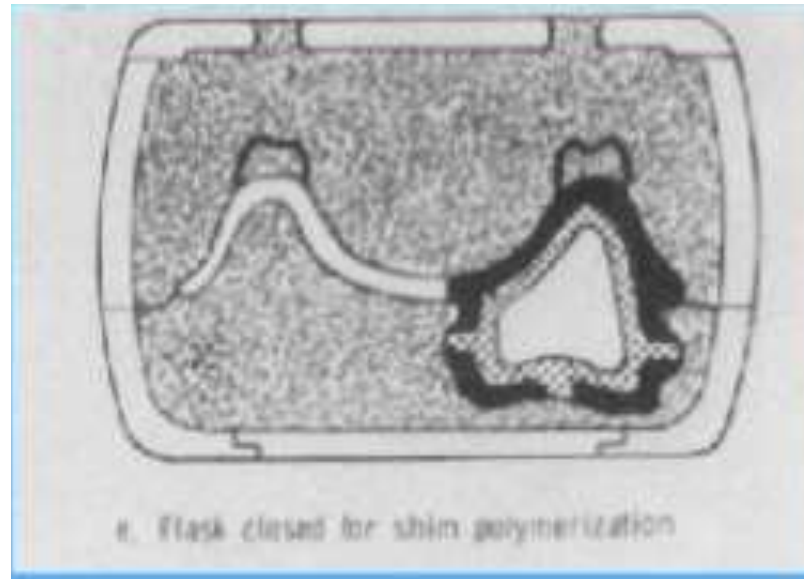


- Make the autopolymerizing acrylic resin and allow it to come to a dough consistency.
- Contour a layer of dough consistency acrylic resin over the wax relief.

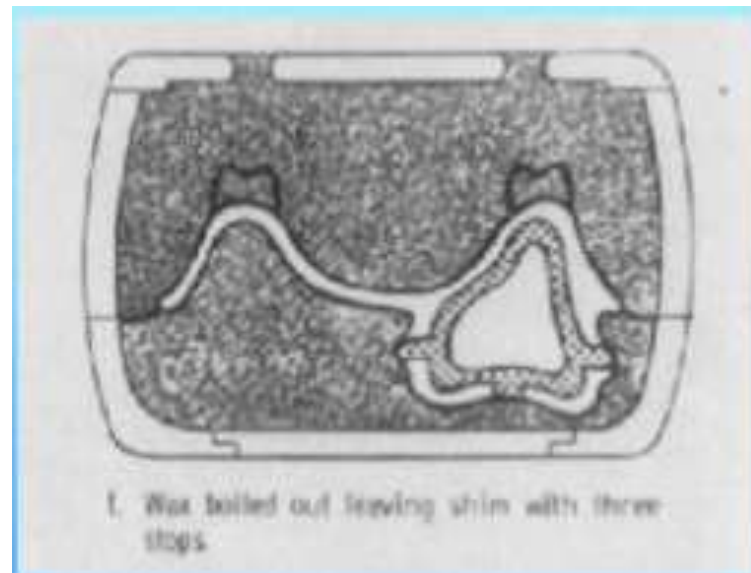




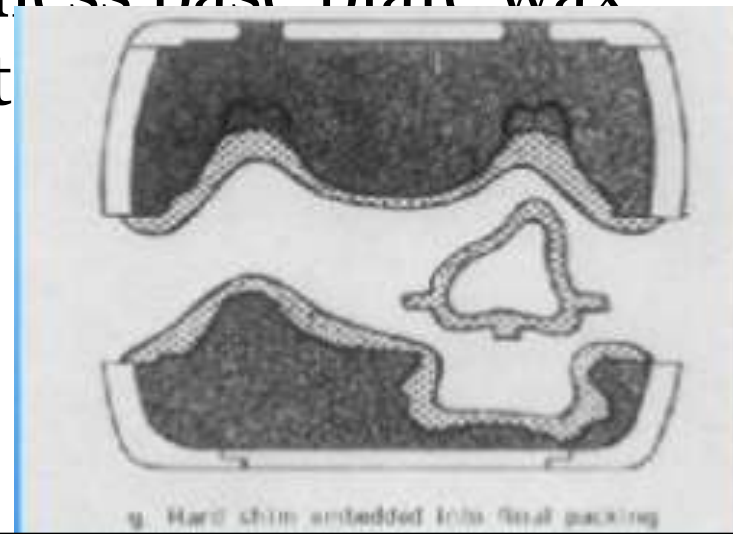- Close the flask, Allow the resin to cure for 15 min.



- Flush the wax from the acrylic resin shim with a steam of boiled water

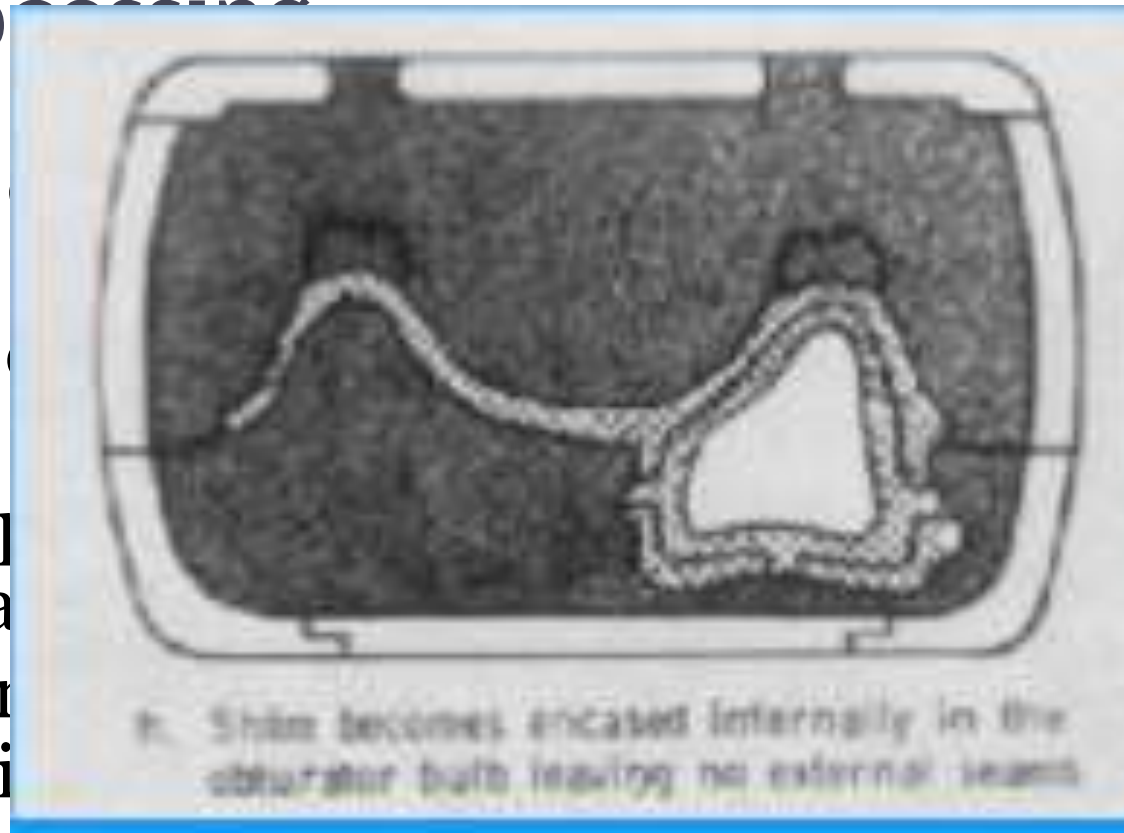


- Trim all the excess of acrylic resin from the shim.
- Replace the heat cure acrylic resin shim using 3 stops for correct positioning. At this stage see that there is at least one thickness base plate wax between the shim and the cast



# Placement of acrylic resin shim and denture processing

- Mix the heat in the usual manner.
- Place a layer of acrylic resin over the defect.
- Reinsert the plaster mold and the still soft acrylic resin.
- Add more acrylic resin and packing in the usual manner.
- Cure the resin in the usual manner.
- Deflask it and trim and polish in usual manner




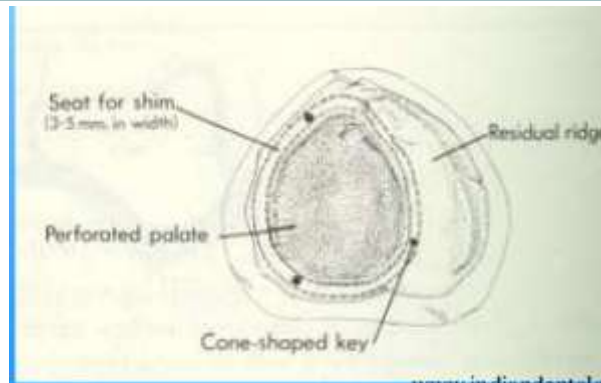
- Maxillary obturator with silicone-lined hollow extension (Takashi Ohyama, and Gold 1975)

The hollow extension consists of two layers of different materials. The **exterior** of the hollow extension, which is in apposition with the defect, is coated with a soft, **resilient silicone**. The **interior** of the hollow extension is fabricated of hard **self-curing acrylic resin**. The resiliency of the outer surface of the hollow extension facilitates insertion of the prosthesis into deep undercuts, providing for improved retention while minimizing the tissue irritation.

# Fabrication:-

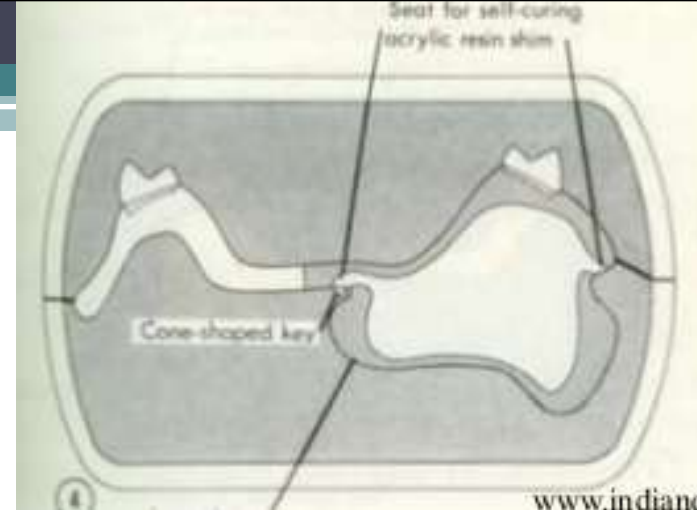
- Step 1. Investing the obturator. Invest the wax dentur-obturator in a flask, and boil out the wax in the conventional manner.





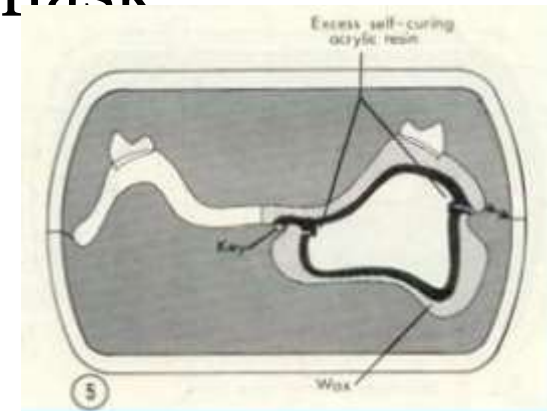
- Making the shim in self curing acrylic resin:-
- -Outline the seat, cut keys for the shim in the stone of the bottom half of the flask. The seat should encircle perforated palate, measuring about 3-5mm in width and extending laterally 1-2mm.
- To **maintain the relationship** of the shim to the cast, 3 cone shaped keys should be cut within the stone of the seat of the shim. The cone shaped keys relate the shim to its proper seat.



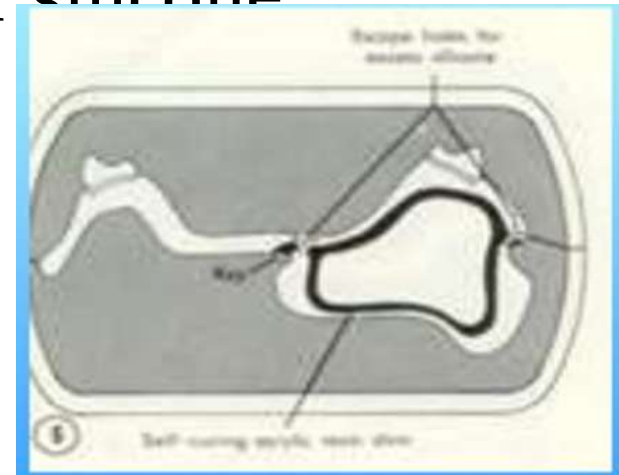


- Place **2 sheets** of base plate wax over the mould of the defect in the flask to **provide space for the silicone** between shim and the defect. Fill all remaining undercuts with wax so that the shim, made from self-curing acrylic resin, can be removed.
- For **relief**, place one thickness of baseplate wax over the teeth and palatal part of the mold on the side of the palatal defect in the top half of the flask. This wax will **provide space for a thickness** of heat- curing acrylic resin over the oral aspect of the prosthesis.

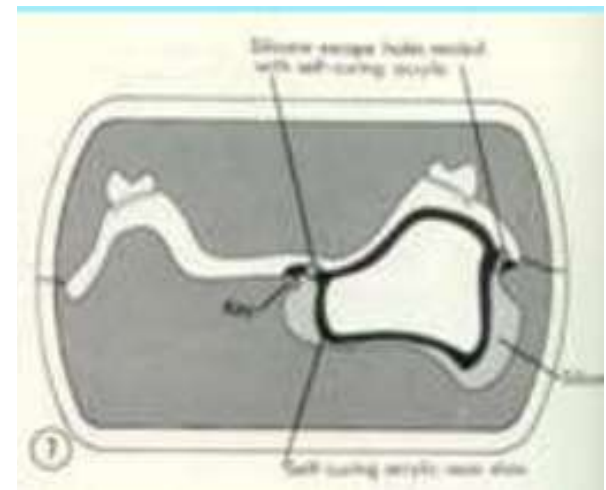
- Paint a layer of **thin foil** substitute on the wax relief and keyed seat for the shim. Put a mixture self-curing acrylic resin into the top and bottom halves of flask on the relief wax, and spread the resin evenly to approximate one or two thickness of baseplate wax. Then, close the flask



- Completely flush the wax away from the cured resin shim.
- Drill holes with a No.3 round bur at 1/2 inch intervals through the tip of the shim which communicates with the space for silicone



- Before packing the heat cure acrylic resin the silicone escape holes in the shim are cleaned out and closed by adding self-curing acrylic resin.



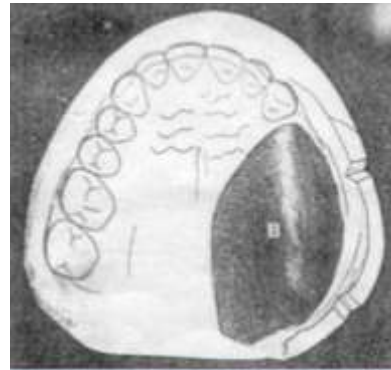
- ✓ Premade shim is then pressed into position over the silicone.
- ✓ Packing is done.
- ✓ Place the flask in a 165°F water bath for 9 hours.
- ✓ Trim and polish the acrylic resin parts of the obturator, trim the silicone flash with scissors, a sharp blade, or abrasive finishing wheels.

# FABRICATION OF TWO PIECE HOLLOW BULB OBTURATOR (According to Palmer and Coffey in 1985)



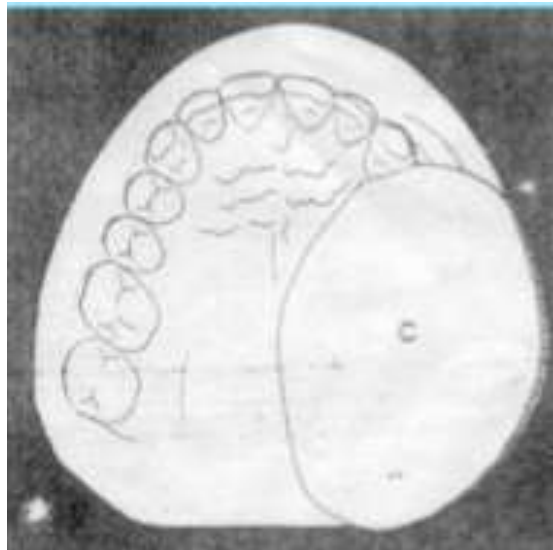
- **Method:**
- **1.** Make an impression that includes the palatal defect to be obturated.
- **2.** Pour a stone cast, separate, and key at the border of the cast

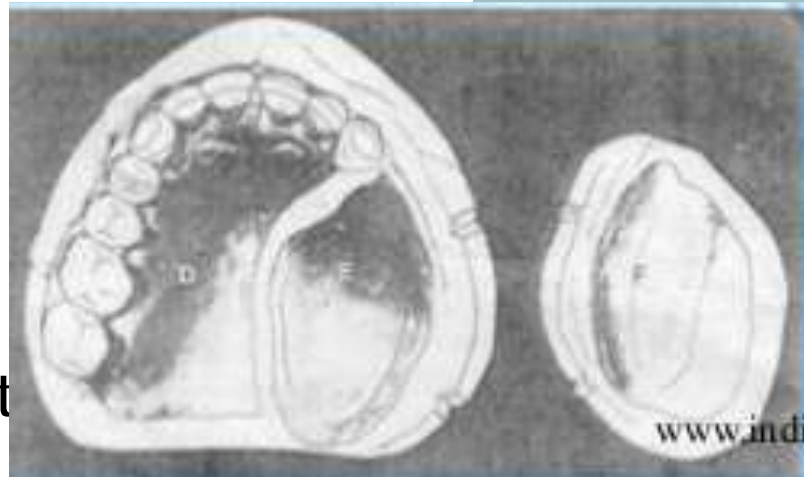
- Apply a suitable separating media to the stone surface
- Clay is sculpted to the palatal defect and missing alveolus





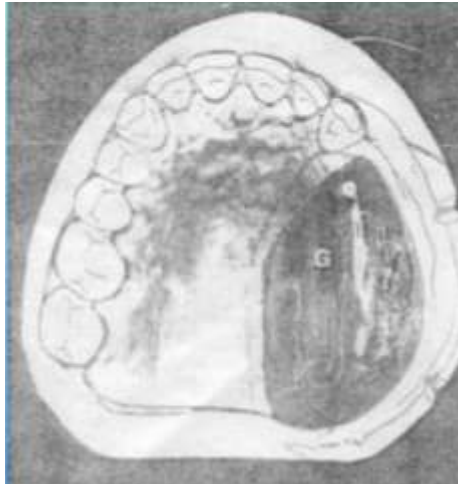- Pour a plaster (plaster cap) over the clay, including the keys in the master cast.





- Remove the plaster cap and discard it.
- Coat the tissue side of the plastic cap with a suitable separating media.
- Apply thin layer of self cure acrylic resin to the defect (E) and tissue surface of the plaster cap(F). - Soft acrylic resin is added into the border of E and F and into the border of D adjacent to E.
- Invert the plastic cap and F into the master cast. Be sure the acrylic resin is kept moist with monomer before closure.
- Check the key for the proper fit and allow the acrylic resin to cure.

- Remove and finish the bulb in usual manner



# Simplified method of making a hollow obturator (Victor Matalon in 1986)

- Method:-
- Invest the impression for obturator in a flask in the normal manner
- Remove the impression material.
- Place separating medium on the investment surface
- Roll out heat-curing acrylic resin to an approximate 2 mm thickness when it is in the doughy stage.
- Pack the periphery of the obturator with rolled out heat cure acrylic resin.
- Fill the center of the concavity created in the previous step with granulated sugar to within approximately 2 mm of the top.

- Pack the mould with rolled out heat-curing resing in the usual manner.
- process the acrylic resin according to manufacturer's specifications.
- Deflask the prosthesis.
- Using a No.8 bur, drill a hole in the superior surface of the obturator.
- Pour out the sugar.
- Use autopolymerizing acrylic resin to seal the hole made by the bur.
- Finish the restoration in the customary maner.

# Aaron Schneider in 1978

- described another method of fabrication of hollow bulb obturator where the defect cavity is filled with **crushed ice of filled with water and freezed overnight**. After processing two halves are drilled to remove the water and the holes are closed with autopolymerizing resin.



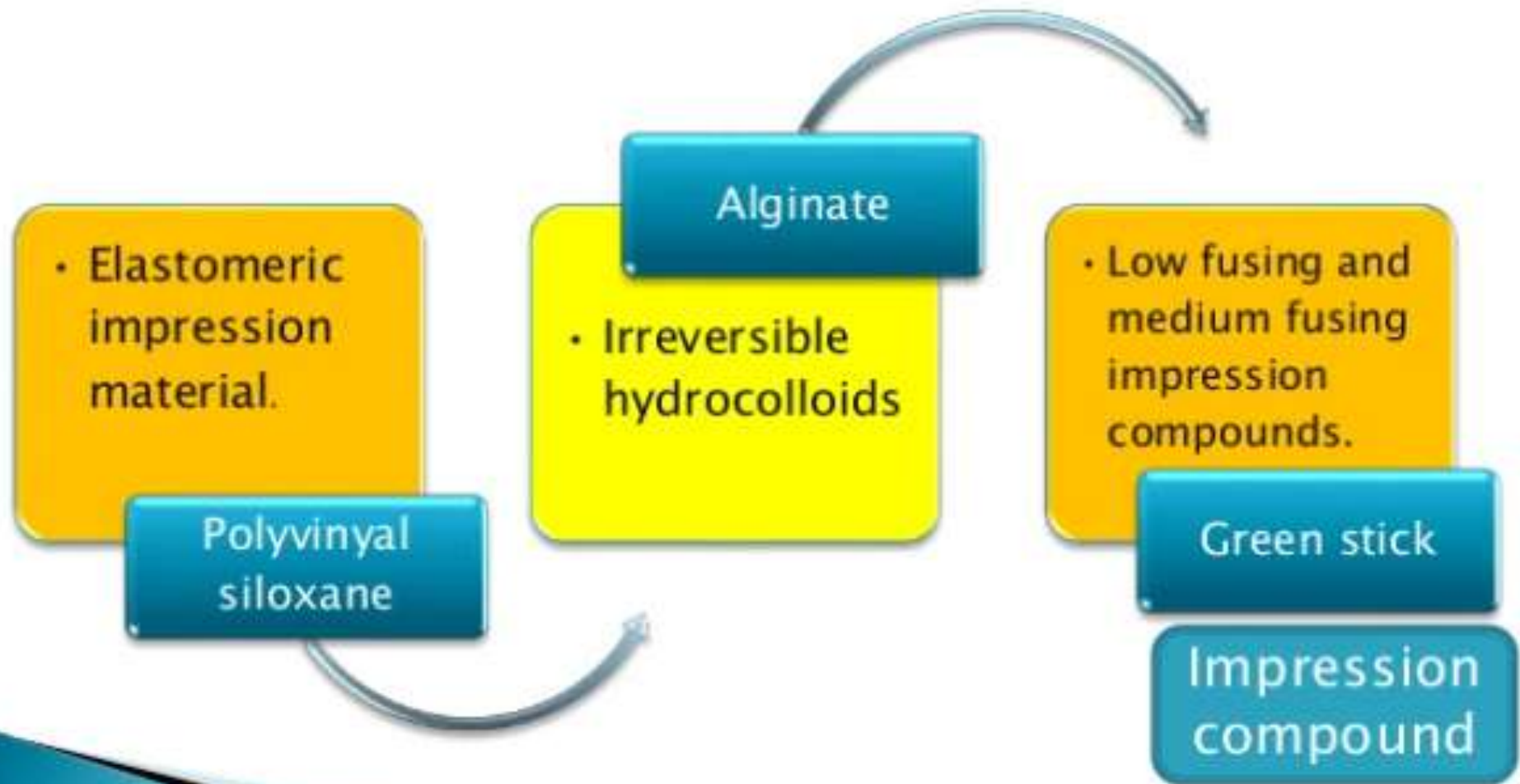
Thank you



# Cleft lip & palate: impression technique

Hussein T. Abed 17\2\2021

# Impression materials



# Impression compound

- ❖ It is a thermoplastic impression material and used for impressions of infant with oral clefts.

## Advantages

- *Easy removal*
- *Better resistance*

## Disadvantages

- *Scalding or burn*

# Low fusing impression compound

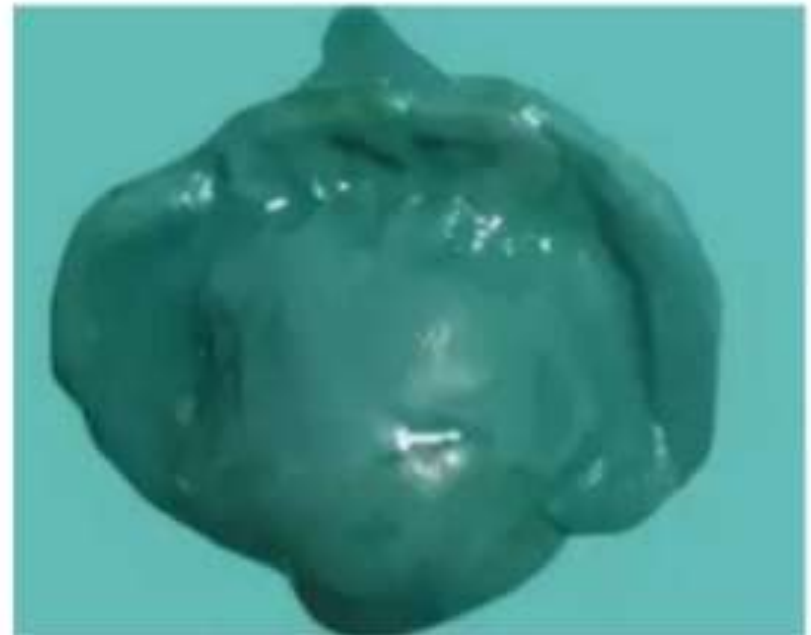
- ▶ *Green stick compound* is a low fusing impression compound.

## Advantage

- ▶ Softened easily and quite Hard on setting

## Disadvantage

- ▶ Can cause burn





# Irreversible hydrocolloids

## ❖ Alginate

### Advantage

- ▶ Ease of mixing and manipulation
- ▶ Economical
- ▶ Pleasant color and taste

### Disadvantage

- ▶ Poor tear strength



- ❖ Use of Fast setting color timed alginate has been suggested in cleft infants , which has advantages to record the details even in presence of saliva.

### Advantage

- ▶ Comfortable to patient
- ▶ Easy to manipulate
- ▶ Relatively inexpensive
- ▶ Prevents respiratory arrest

# Elastomeric impression material

❑ *Elastomeric impression materials* are better suited in making of cleft impression and they don't lead to any complications.

## Advantage

- good elastic behaviour
- high tear strength
- accurate reproduction of surface detail
- long term dimensional stability



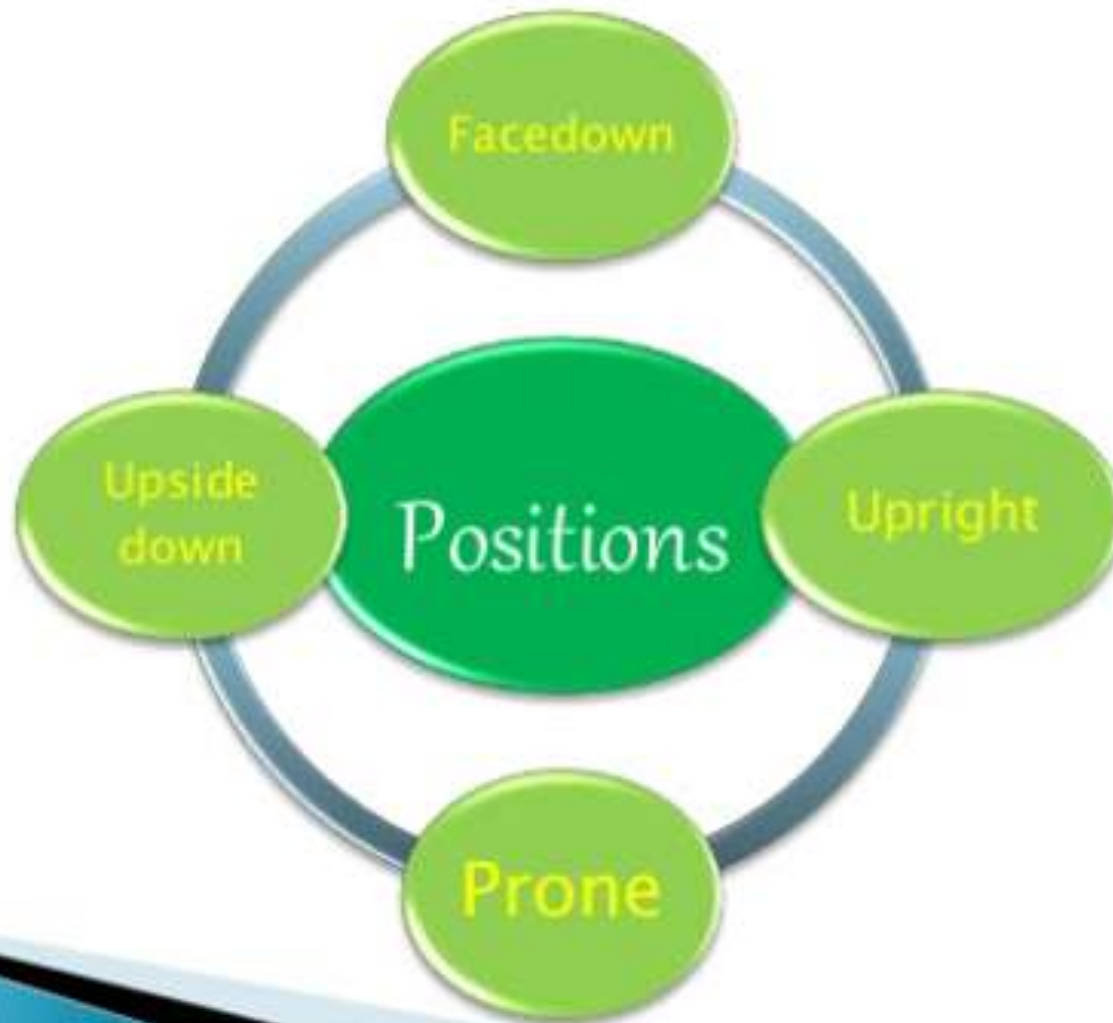

# Impression position

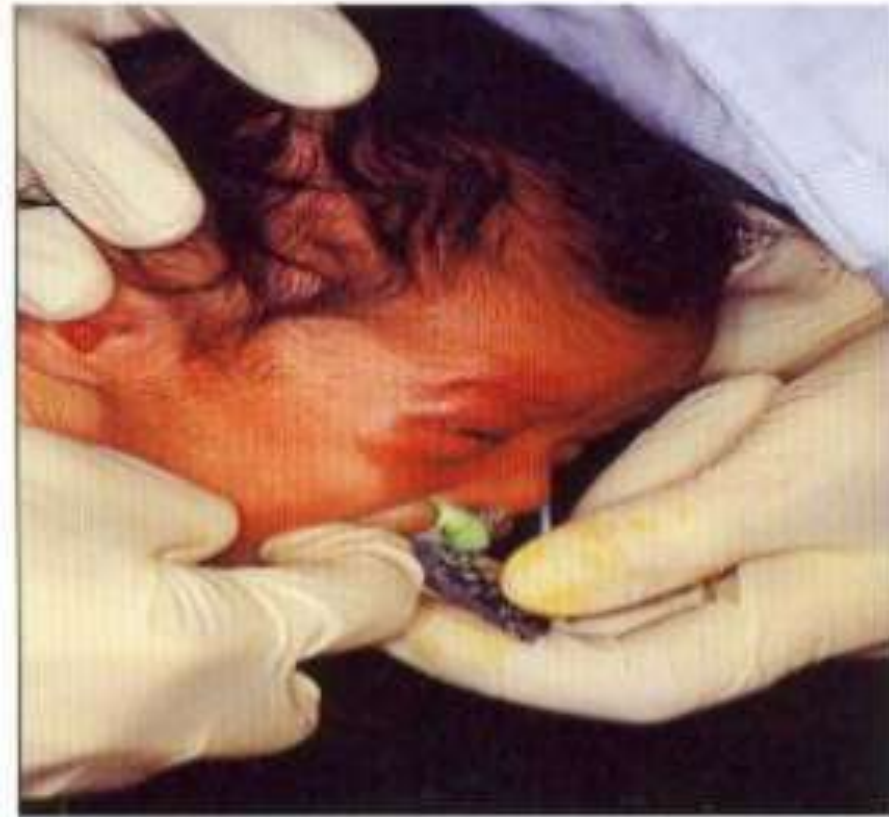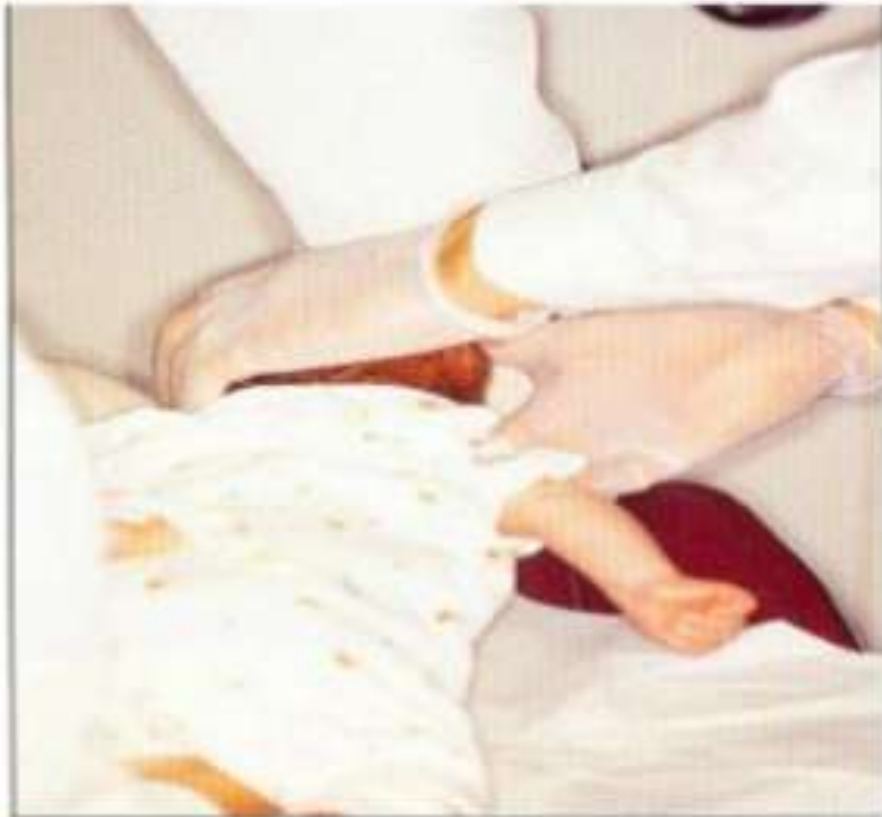## *In Infants*

- ▶ The most important part of the oral rehabilitation of a patient with cleft lip and cleft palate is the impression making procedure.
- ▶ The making of the impression in an infant with a cleft palate is a critical procedure.
- ▶ For an accurate and safe impression procedure, a proper patient and dentist position are vital.

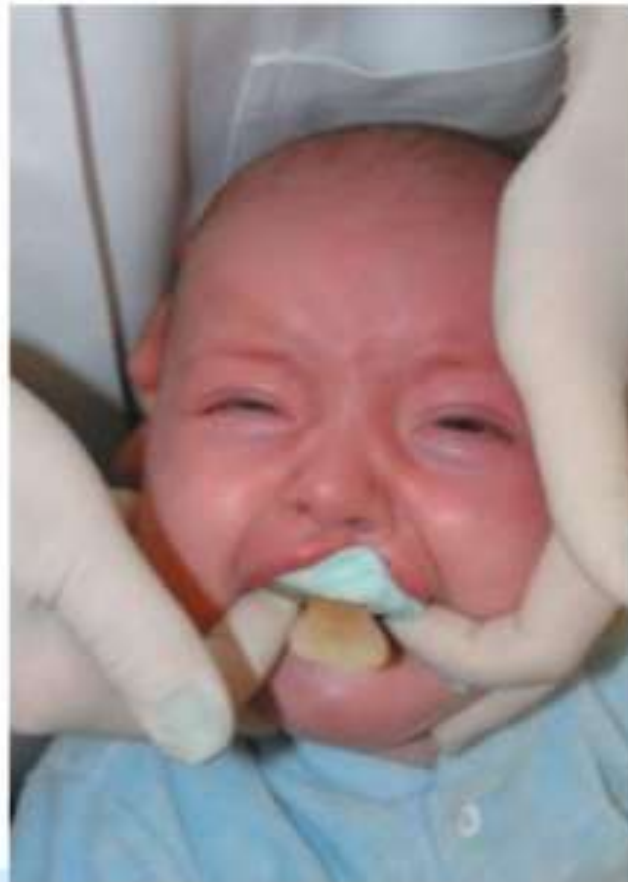- ❖ A no. of **impression positions** have been adopted for cleft palate in infants are --



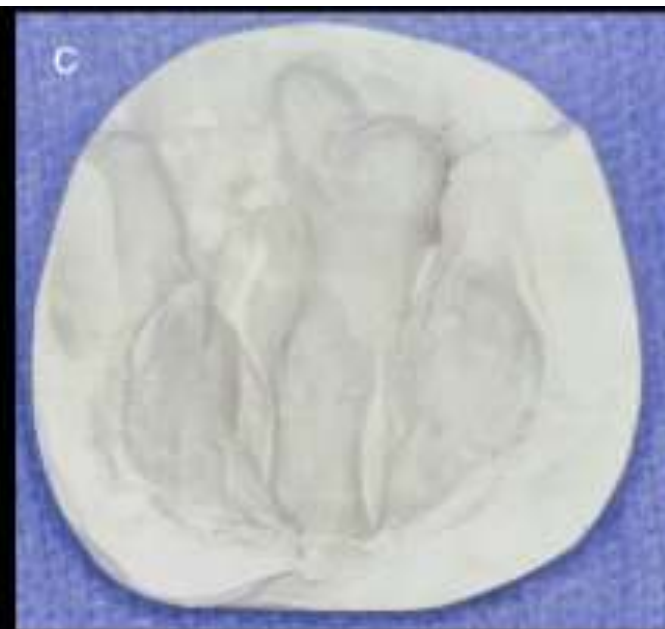
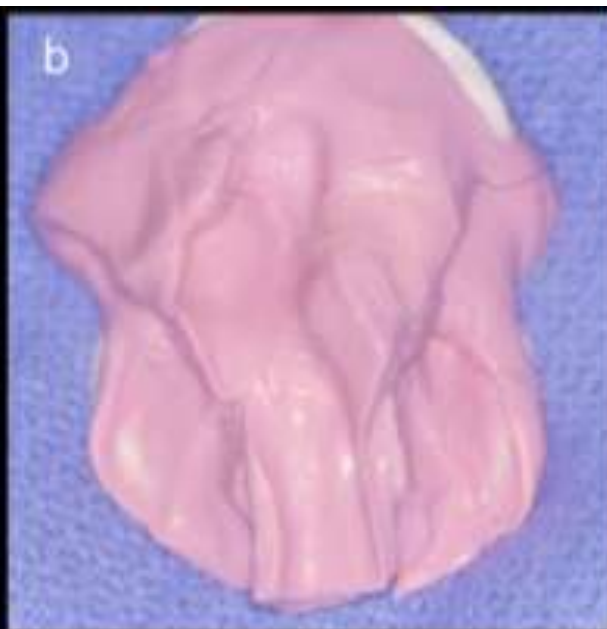
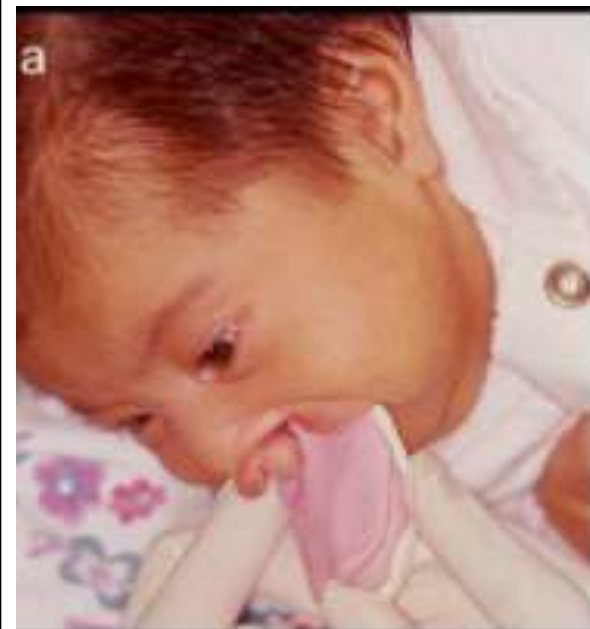## Facedown position



Upright position

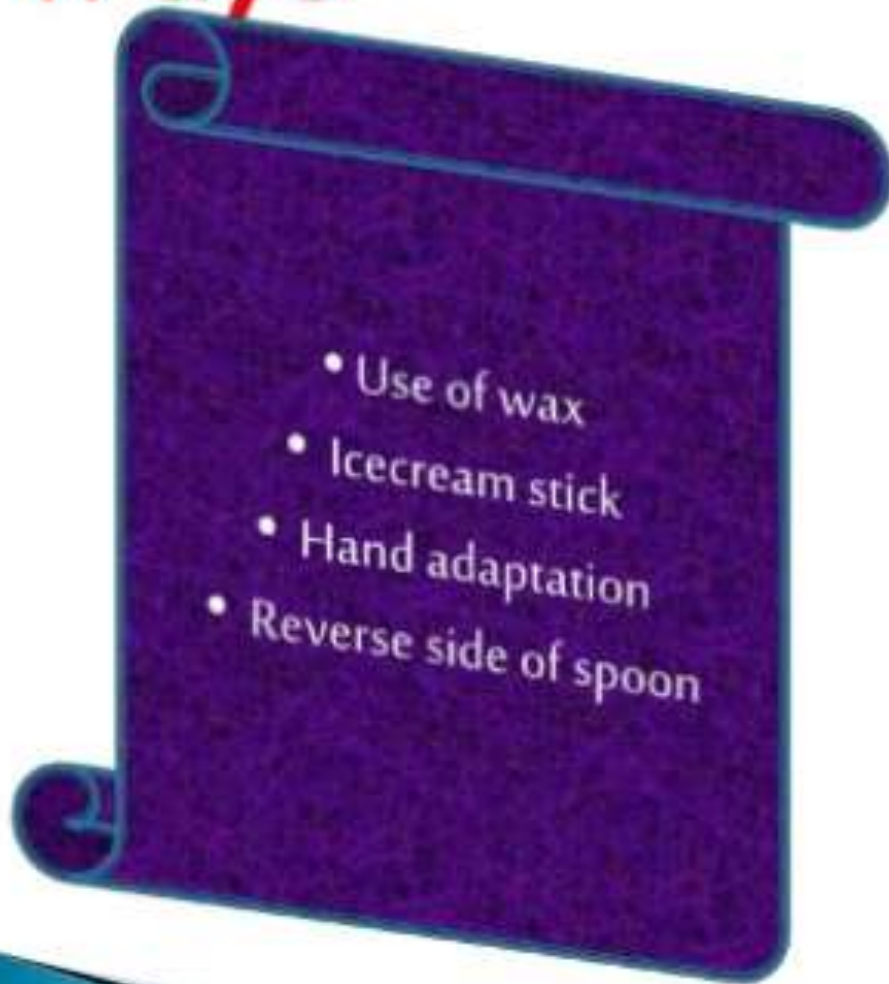




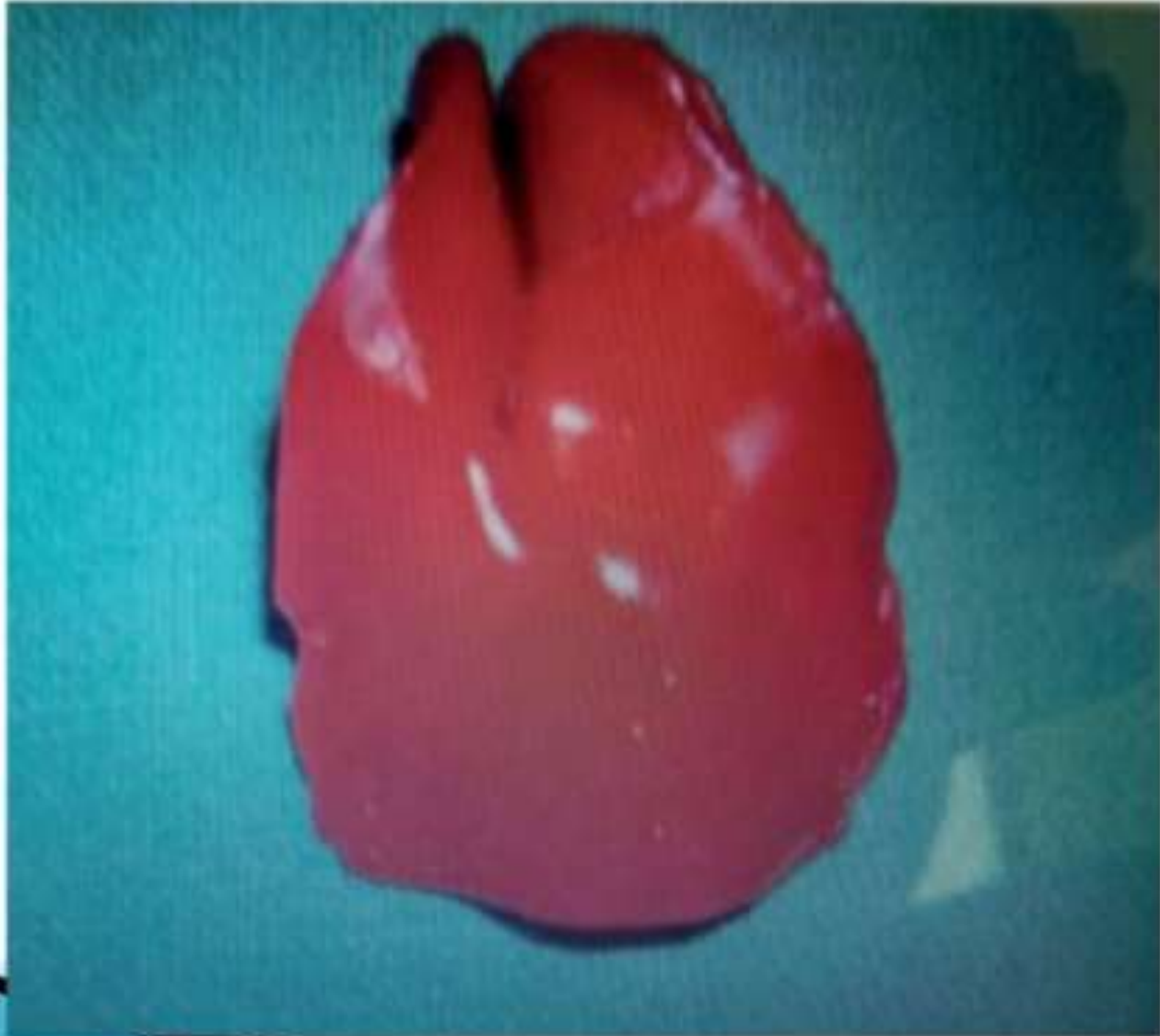
a. During impression, infant's head must be in an upright position and well supported. b. Impression of silicone putty. c. Master cast.


# Selection of Impression trays



# Use of wax



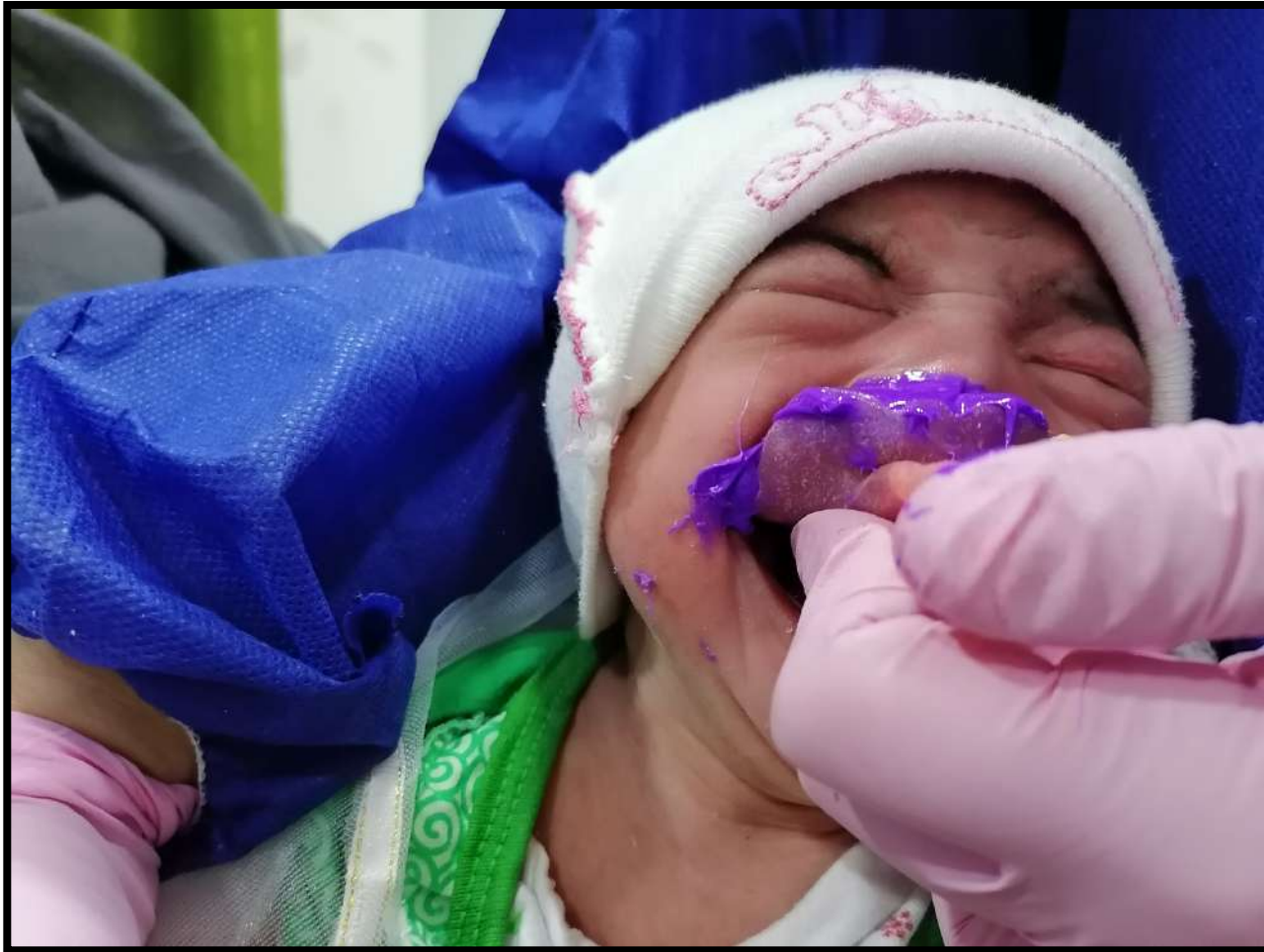

- Prefabricated trays that are commercially available (Coe Laboratory, Chicago) for cleft palate impressions in infants.
  - Shatkin and Stark described the use of a wax as impression trays in cleft lip and palate patients.
  - Ice cream sticks can also be used to carry materials for infant impressions.
- 

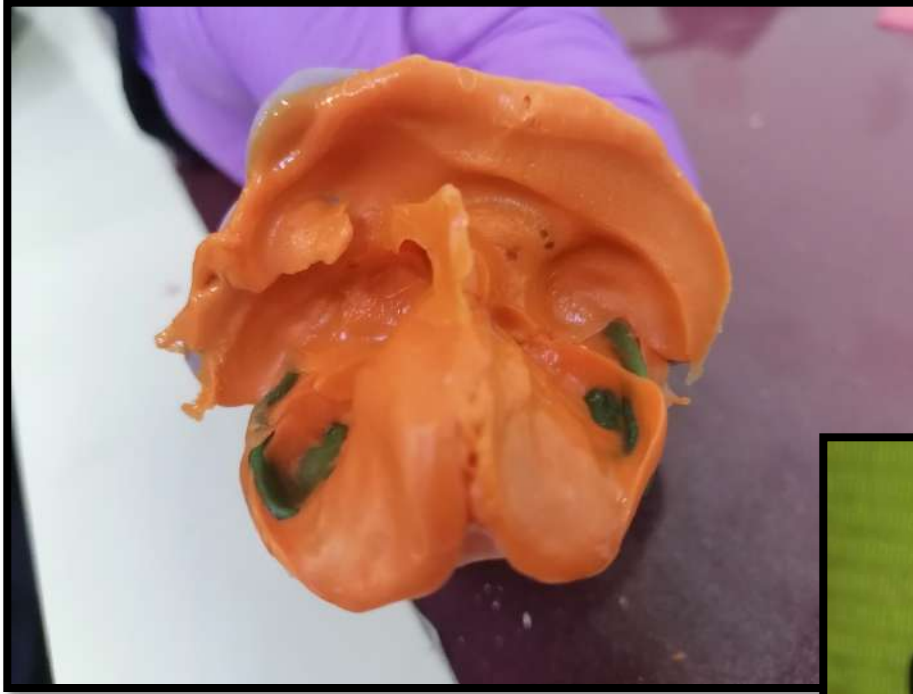# Primary impression silicon impression material



# Final impression \ light body

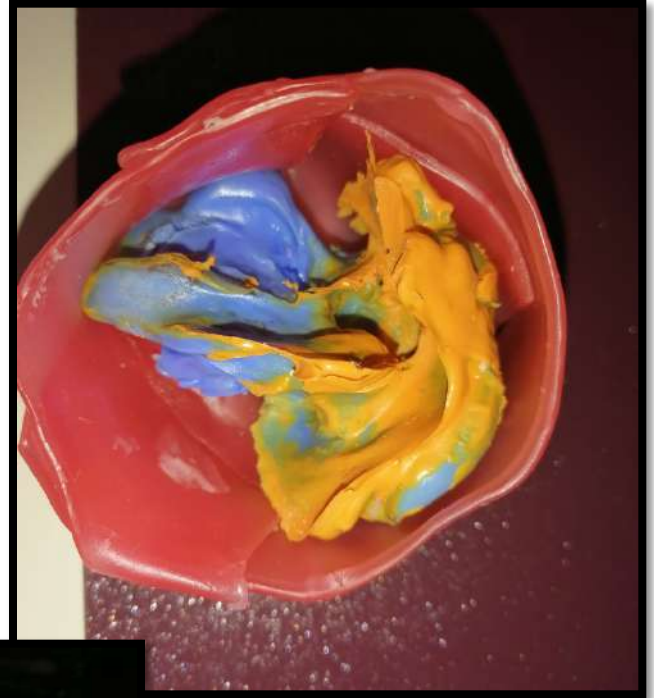
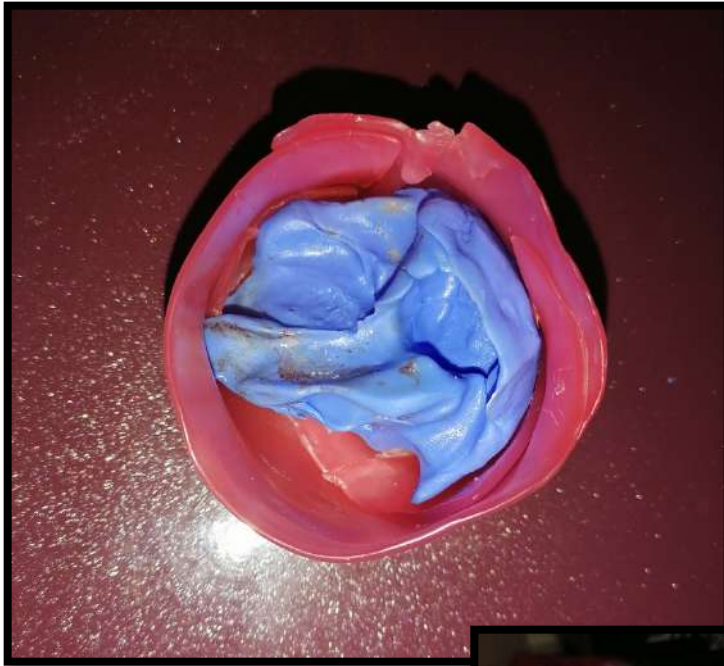


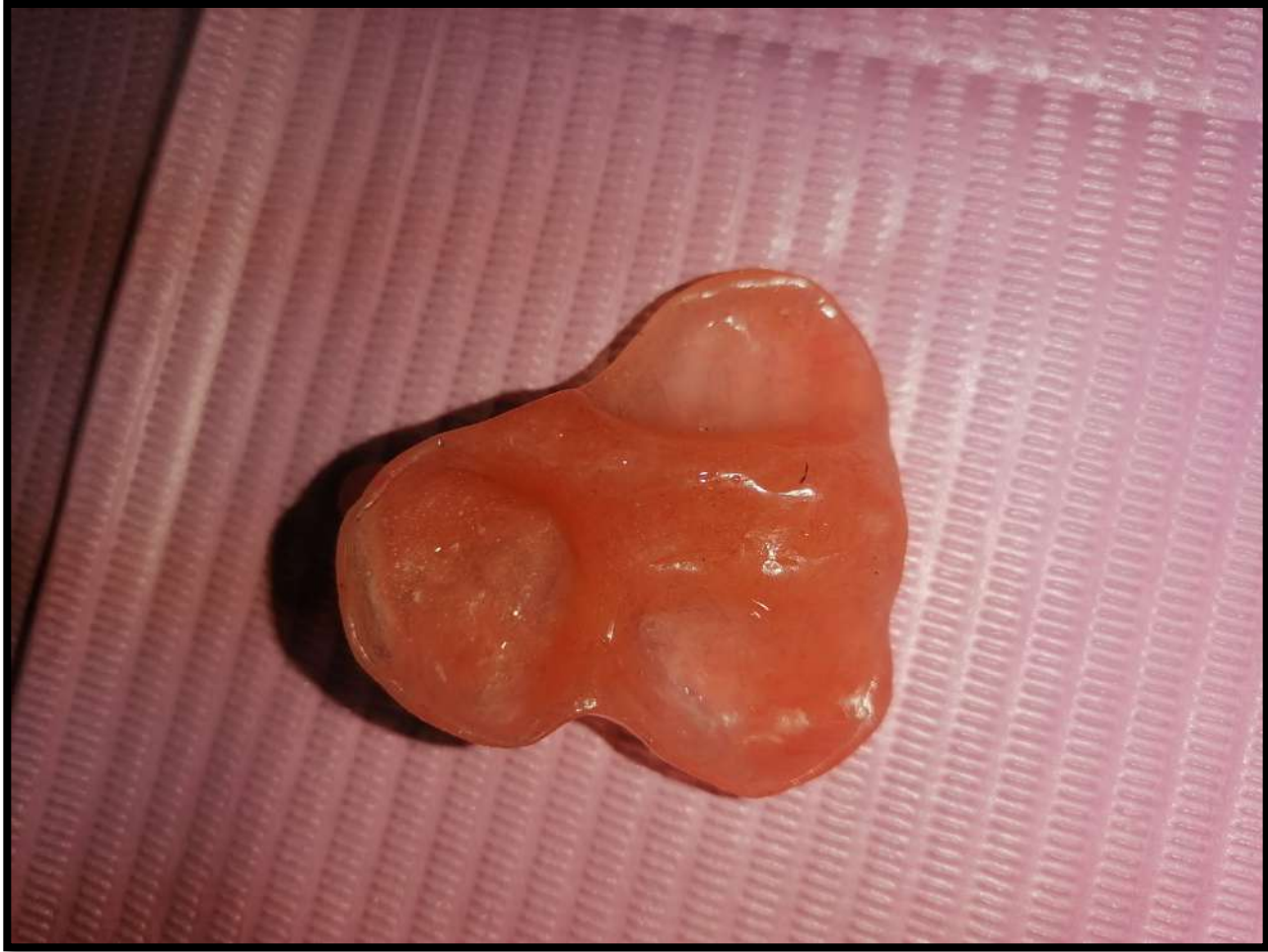# Final impression





# Pouring the impression





Thank you

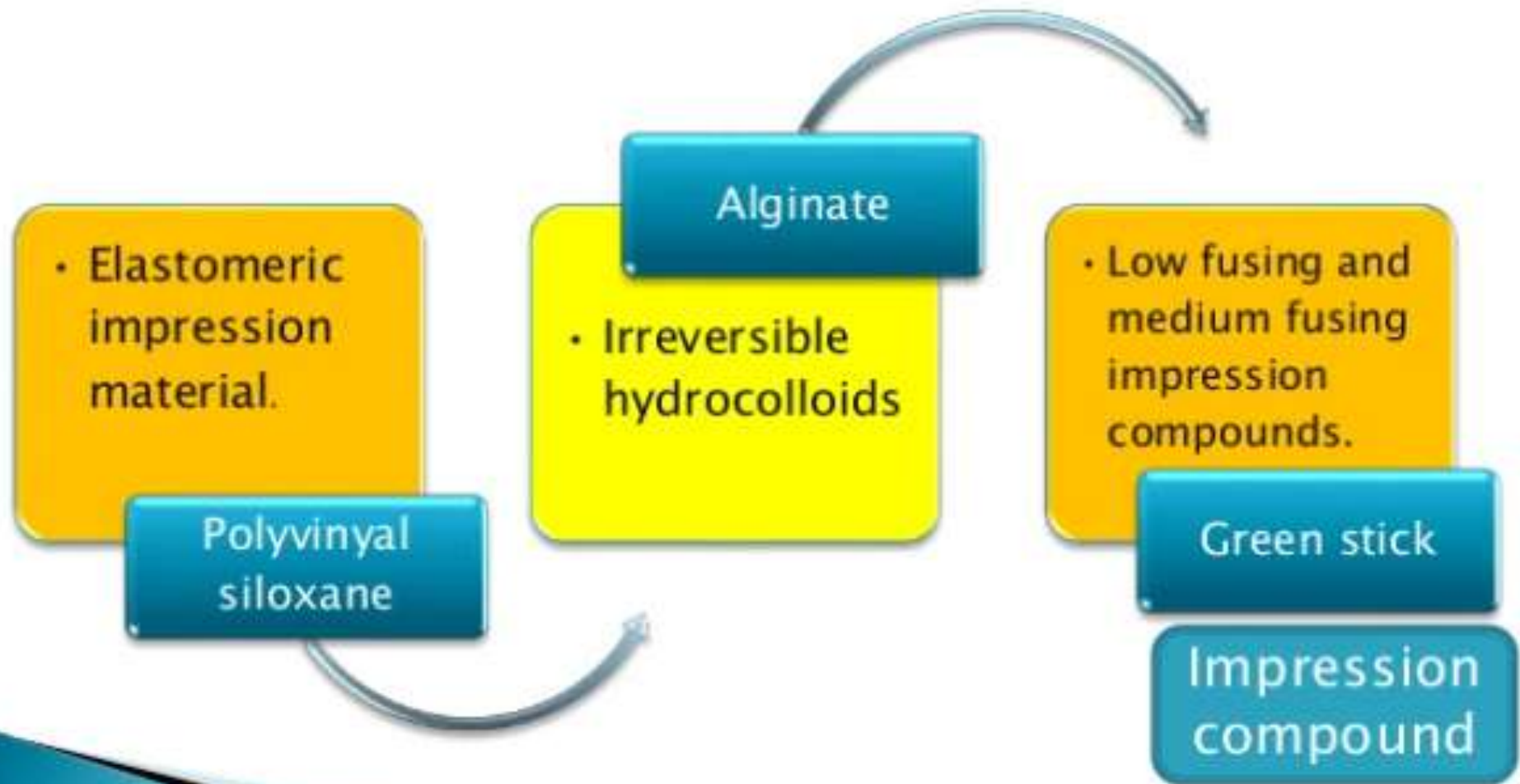




# Cleft lip & palate: impression technique

Hussein T. Abed 17\2\2021

# Impression materials



# Impression compound

- ❖ It is a thermoplastic impression material and used for impressions of infant with oral clefts.

## Advantages

- *Easy removal*
- *Better resistance*

## Disadvantages

- *Scalding or burn*

# Low fusing impression compound

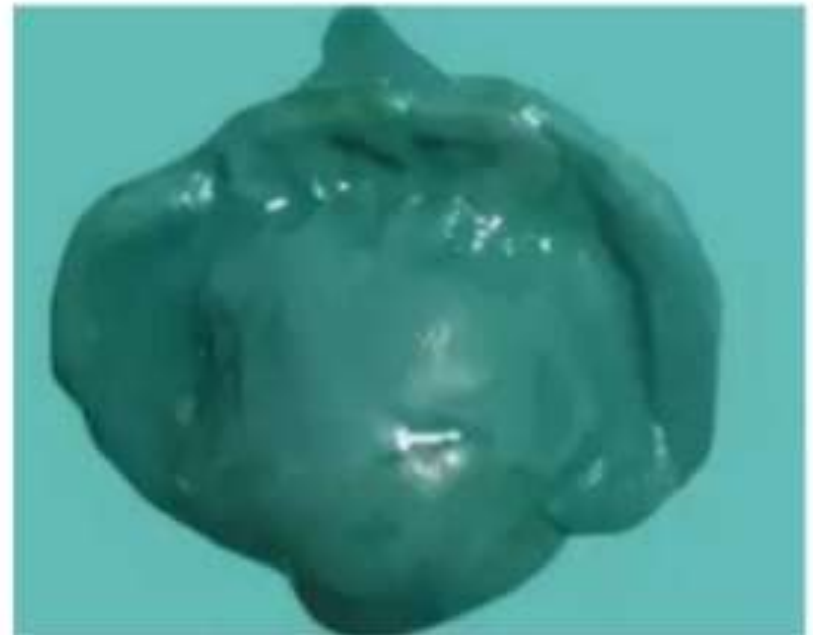- ▶ *Green stick compound* is a low fusing impression compound.

## Advantage

- ▶ Softened easily and quite Hard on setting

## Disadvantage

- ▶ Can cause burn





# Irreversible hydrocolloids

## ❖ Alginate

### Advantage

- ▶ Ease of mixing and manipulation
- ▶ Economical
- ▶ Pleasant color and taste

### Disadvantage

- ▶ Poor tear strength



- ❖ Use of Fast setting color timed alginate has been suggested in cleft infants , which has advantages to record the details even in presence of saliva.

### Advantage

- ▶ Comfortable to patient
- ▶ Easy to manipulate
- ▶ Relatively inexpensive
- ▶ Prevents respiratory arrest

# Elastomeric impression material

❑ *Elastomeric impression materials* are better suited in making of cleft impression and they don't lead to any complications.

## Advantage

- good elastic behaviour
- high tear strength
- accurate reproduction of surface detail
- long term dimensional stability





# Impression position

## *In Infants*

- ▶ The most important part of the oral rehabilitation of a patient with cleft lip and cleft palate is the impression making procedure.
- ▶ The making of the impression in an infant with a cleft palate is a critical procedure.
- ▶ For an accurate and safe impression procedure, a proper patient and dentist position are vital.

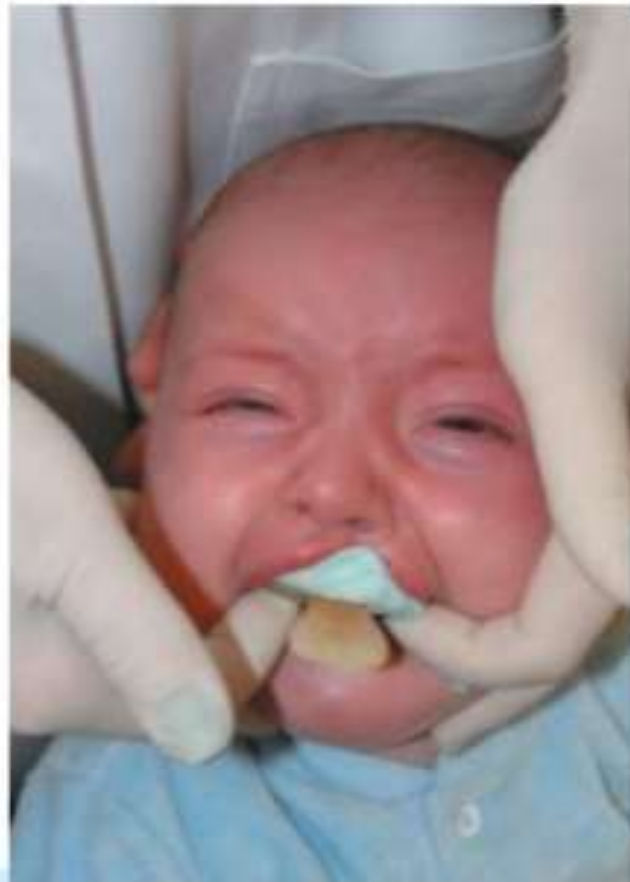
- ❖ A no. of **impression positions** have been adopted for cleft palate in infants are --



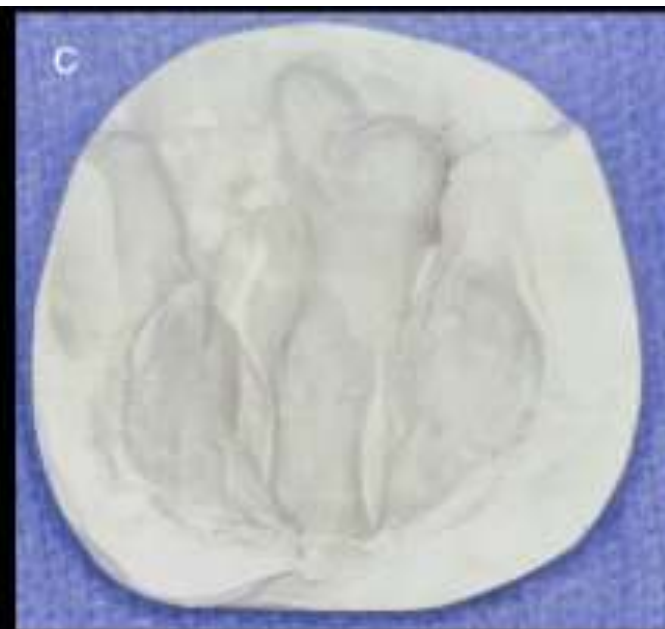
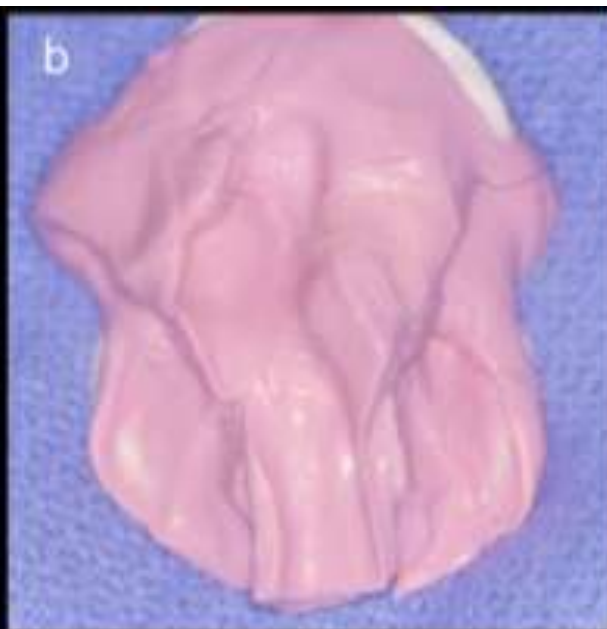
## Facedown position



Upright position







a. During impression, infant's head must be in an upright position and well supported. b. Impression of silicone putty. c. Master cast.


# Selection of Impression trays



# Use of wax





- Prefabricated trays that are commercially available (Coe Laboratory, Chicago) for cleft palate impressions in infants.
  - Shatkin and Stark described the use of a wax as impression trays in cleft lip and palate patients.
  - Ice cream sticks can also be used to carry materials for infant impressions.
- 

# Primary impression silicon impression material



# Final impression \ light body

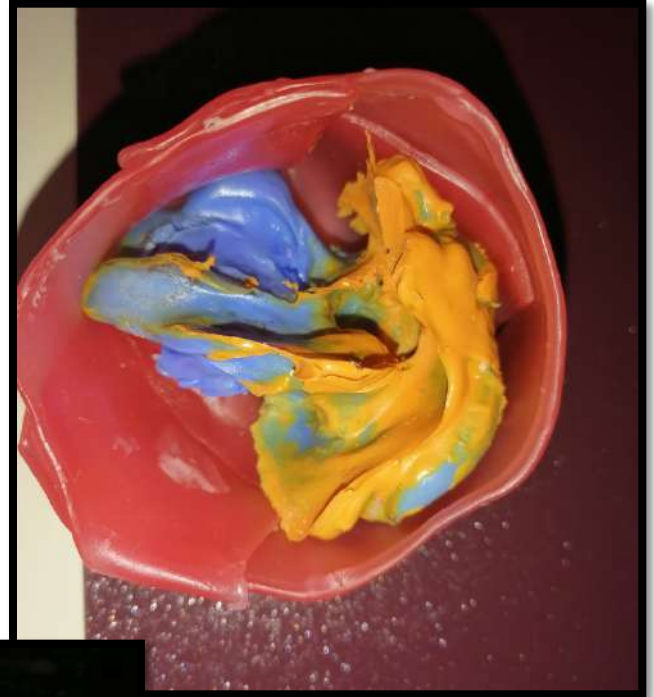
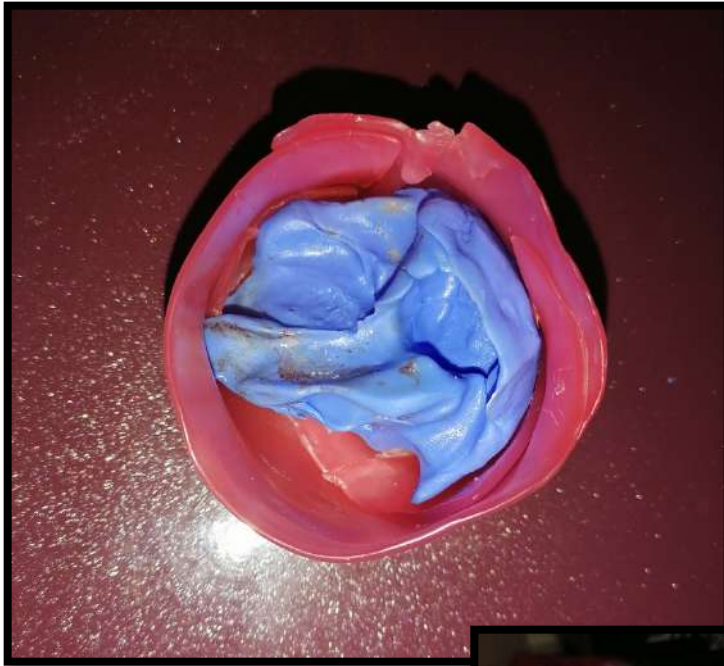


# Final impression





# Pouring the impression





Thank you





# Cleft palate: Pharynx anatomy & problems

Hussein T. Abed 17\2\2021

# The pharynx

is a simple, funnel shaped tube wide at the head and narrow at esophageal end. The pharynx has three muscles:

superior, middle and inferior constrictors.

# The pharynx

The action of the pharynx is :

1. it contracts from side to side and its posterior surface moves forwards.
2. it is capable of local contractions at various levels, which are mainly used in speech, and swallowing.

## Divisions

- 1) NASOPHARYNX
- 2) OROPHARYNX
- 3) LARYNGOPHARYNX (HYPOPHARYNX)

Nasal cavity

Soft palate


Hard  
palate

Tongue

Epiglottis

Larynx  
(voice box)

Trachea



Nasopharynx

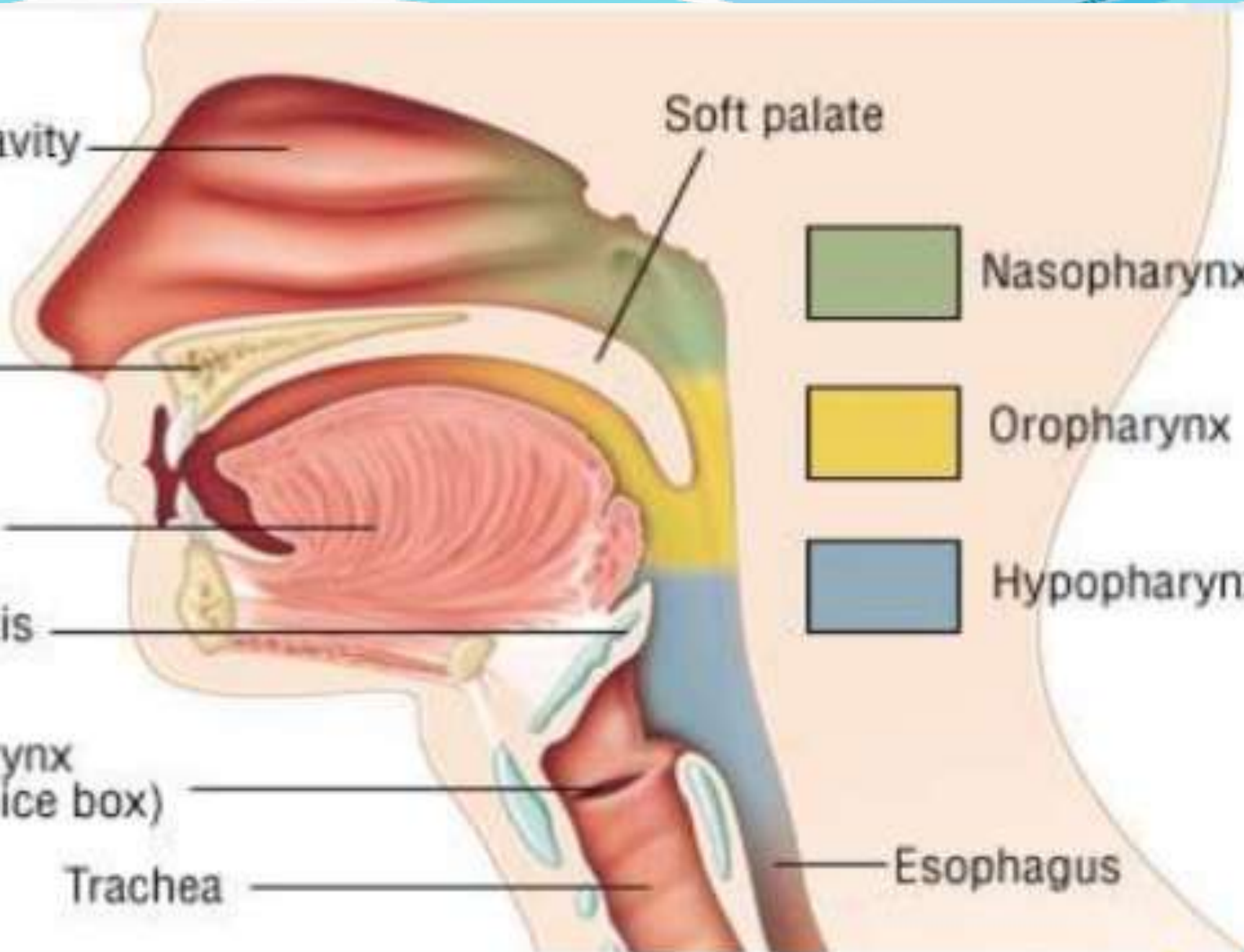


Oropharynx



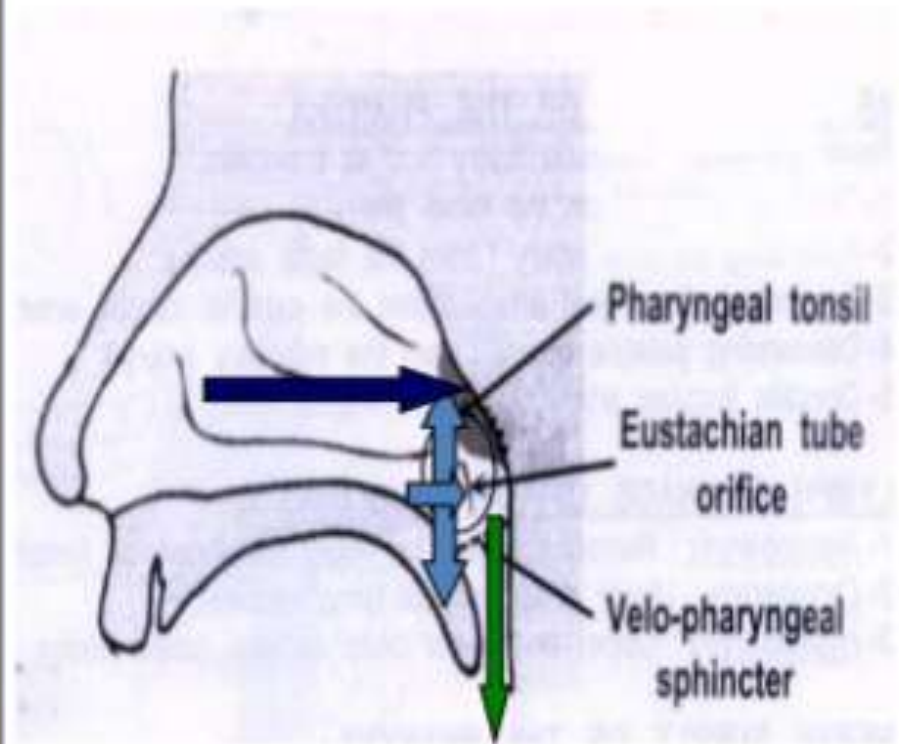
Hypopharynx

Esophagus

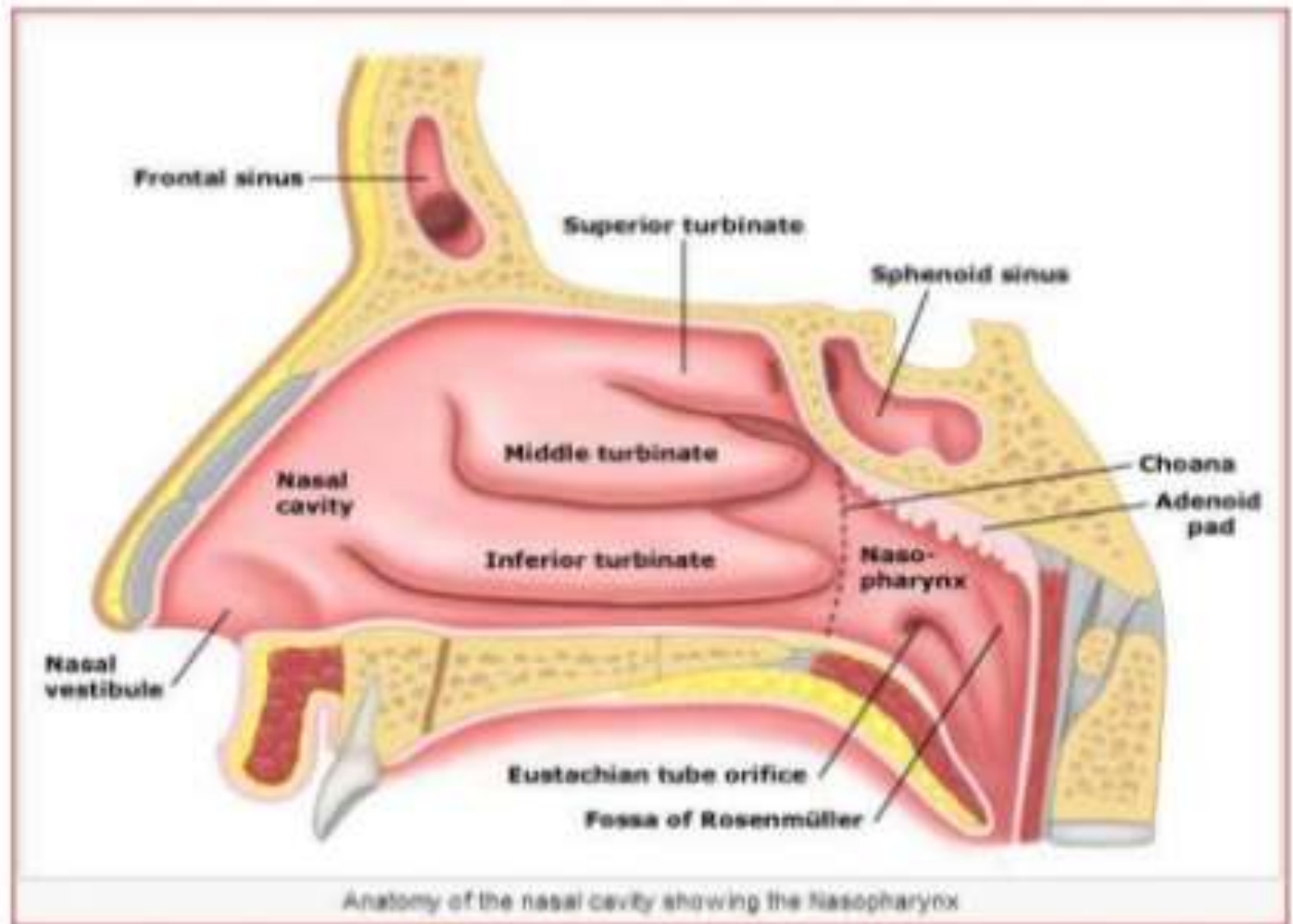


# Nasopharynx

- Behind the nasal cavity
- Extends from skull  
Base superiorly to the soft palate inferiorly
- **Communicates inferiorly with the oropharynx through the velo-pharyngeal sphincter**
- **The nasopharyngeal tonsil lies in the roof**
- The pharyngeal opening of ET lies in the lateral wall







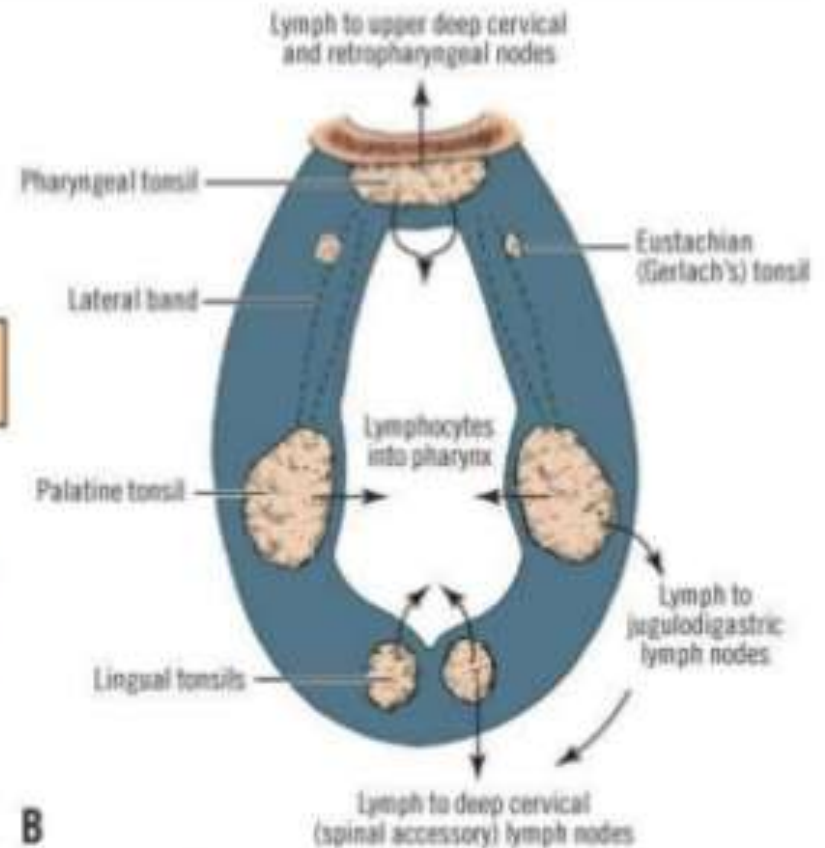
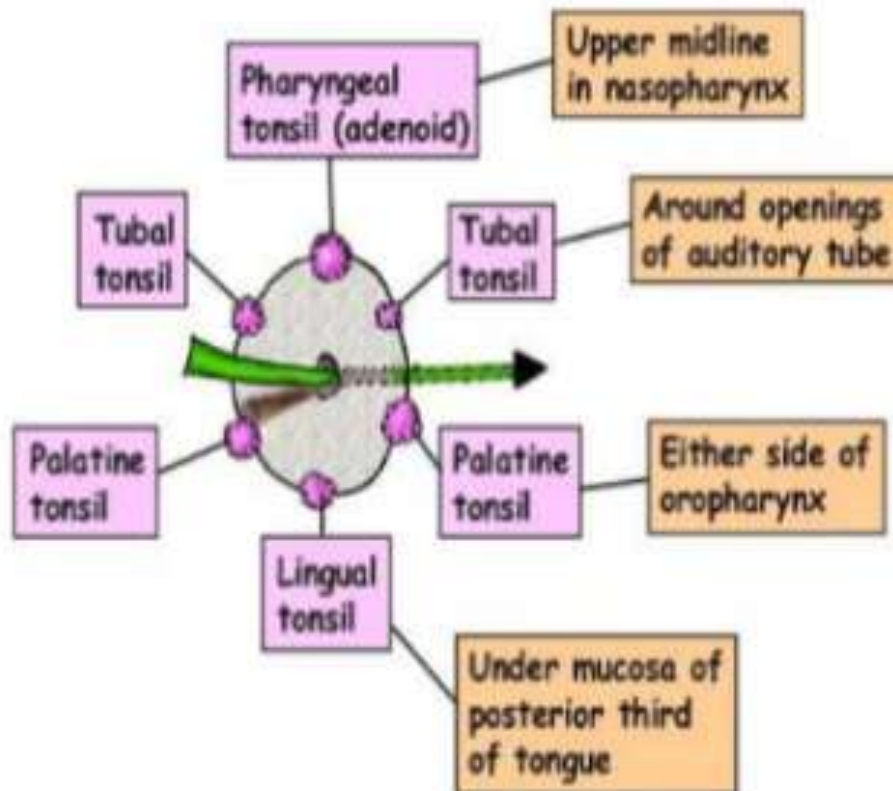


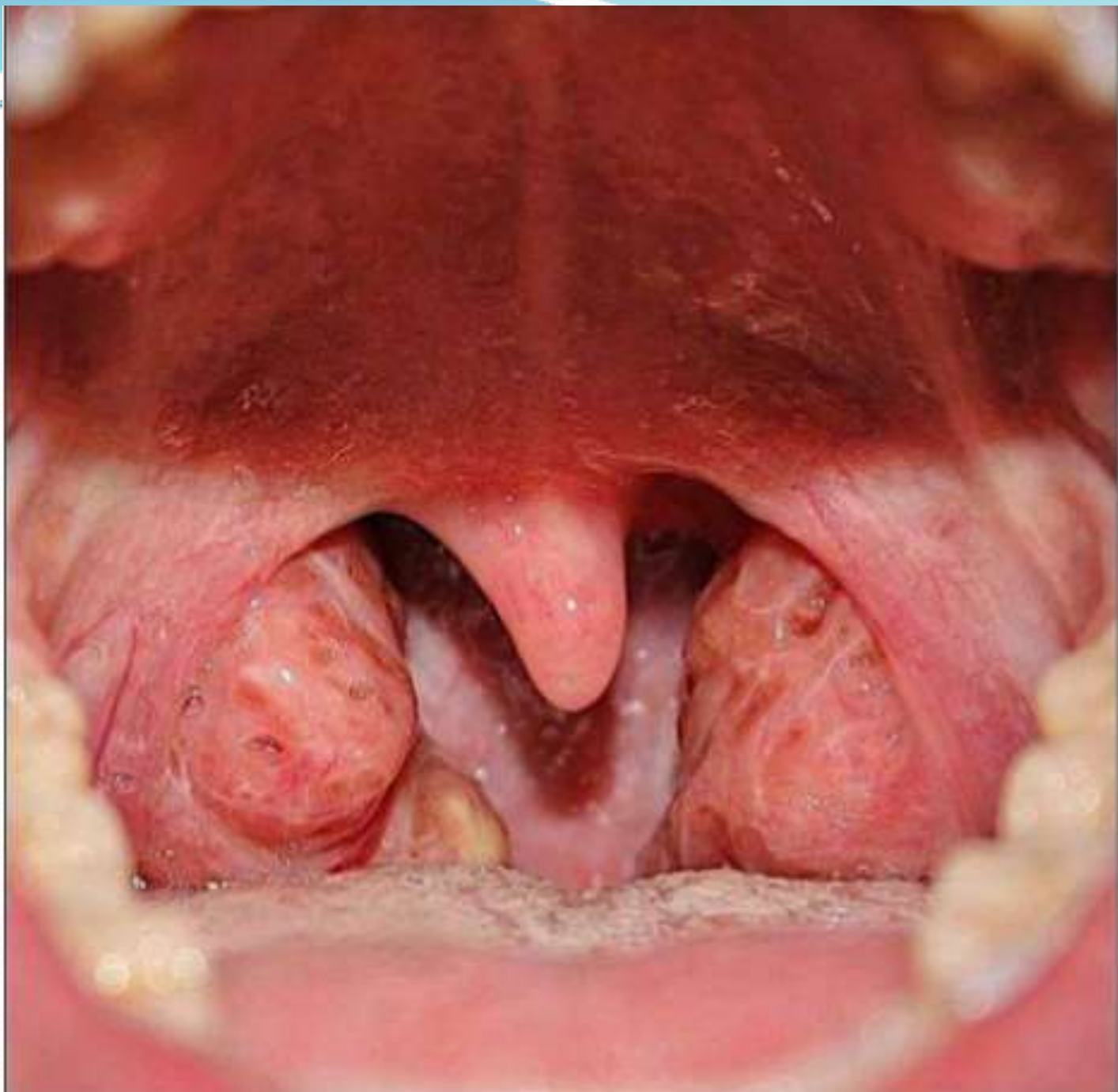
# Tonsils

- **Pharyngeal** tonsil (adenoids): midline on the roof of the nasopharynx;
- **Palatine** tonsils: on each side of the oropharynx between the palatoglossal and palatopharyngeal arches
- **Lingual** tonsil : posterior one-third of the tongue.
- **Tubal** tonsil: pharyngotympanic tube near its opening into the nasopharynx, and on the upper surface of the soft palate.

# What is Waldeyer's ring?

An interrupted circle of protective lymphoid tissue at the upper ends of the respiratory and alimentary tracts



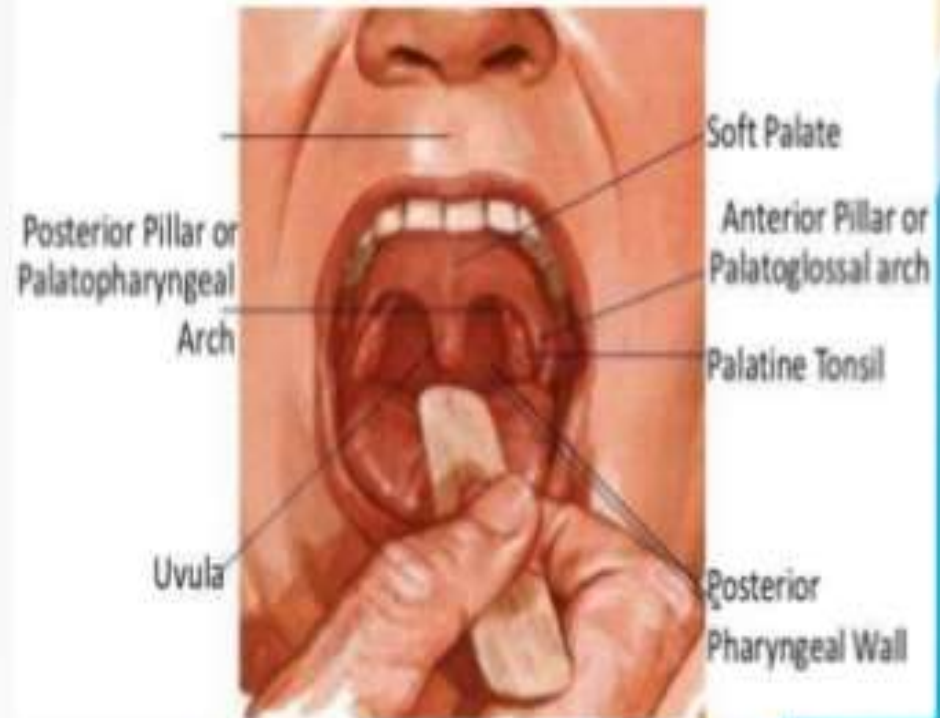

## 2. OROPHARYNX

- Middle part
- Above -Nasopharynx
- Front- oral cavity
- Below-Laryngopharynx
- Supported by C2&C3
- Lateral -Palatine Tonsils

### OROPHARYNX

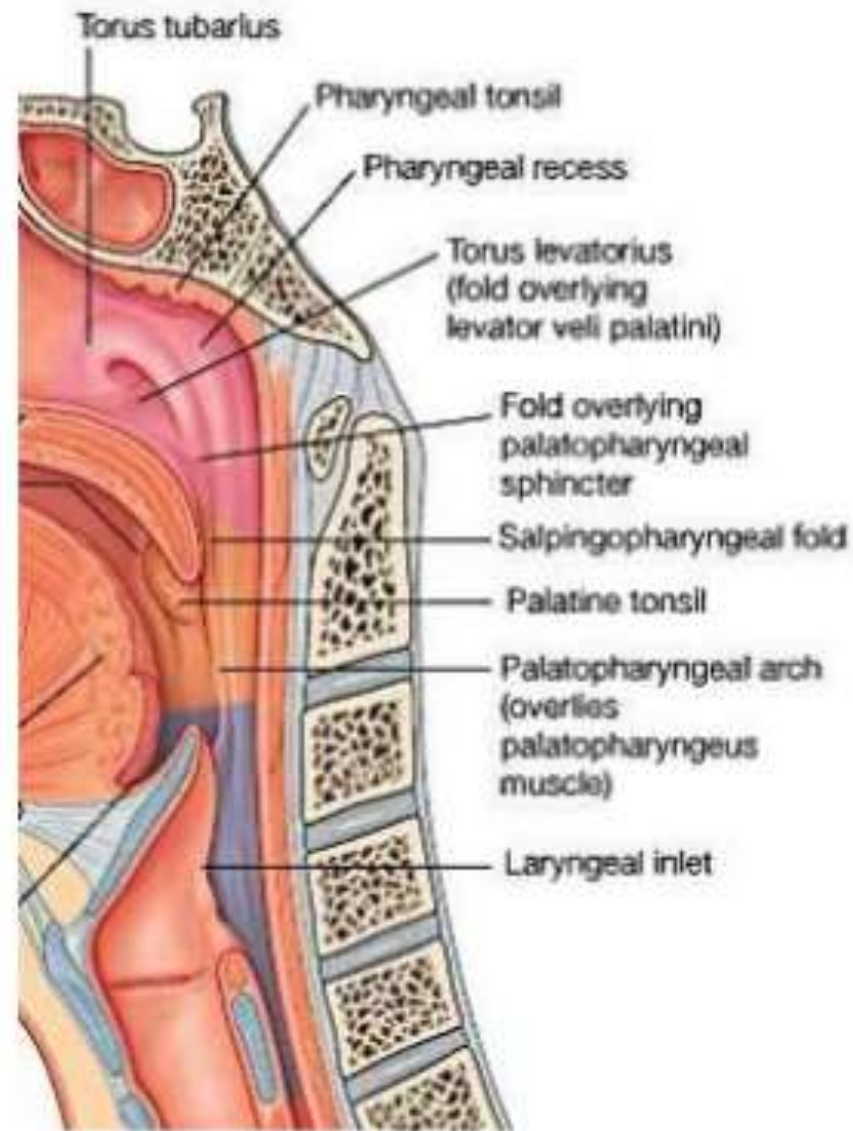
It is the middle part of the pharynx situated behind the oral cavity.





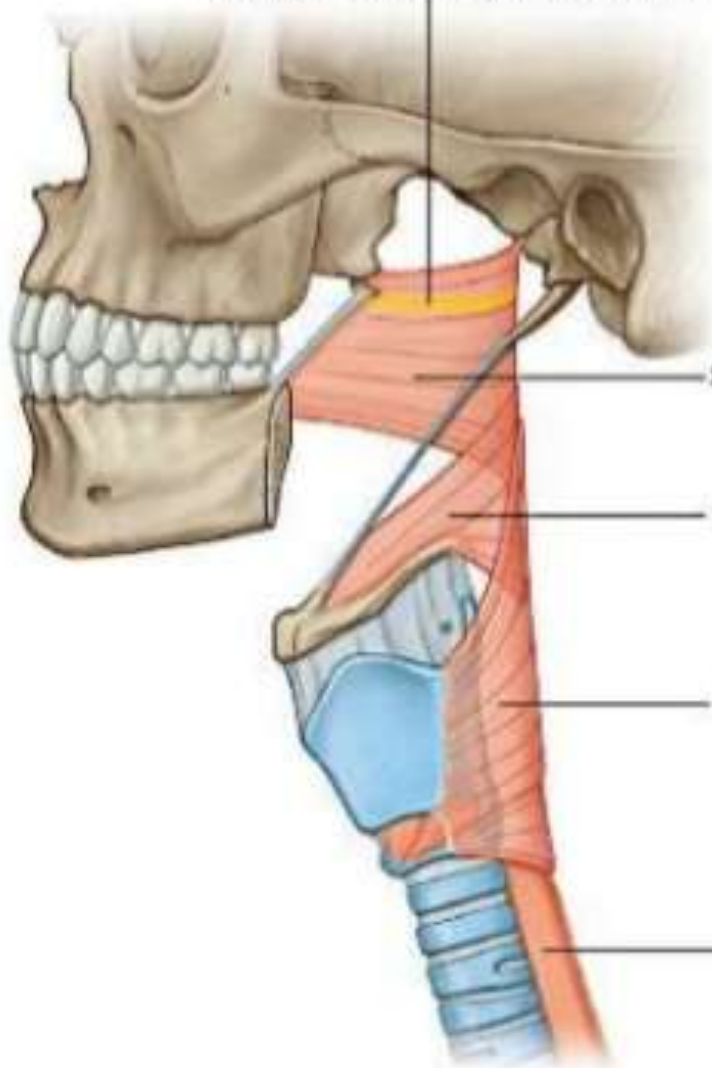
# OROPHARYNX

- Behind mouth and tongue.
- common to both respiratory and digestive systems
- Oropharyngeal isthmus
- Posterior wall is smooth
- Lateral walls shows **palatine tonsils** between palatoglossal and palatopharyngeal arches.



**A**

Position of palatopharyngeal sphincter  
on deep surface of superior constrictor



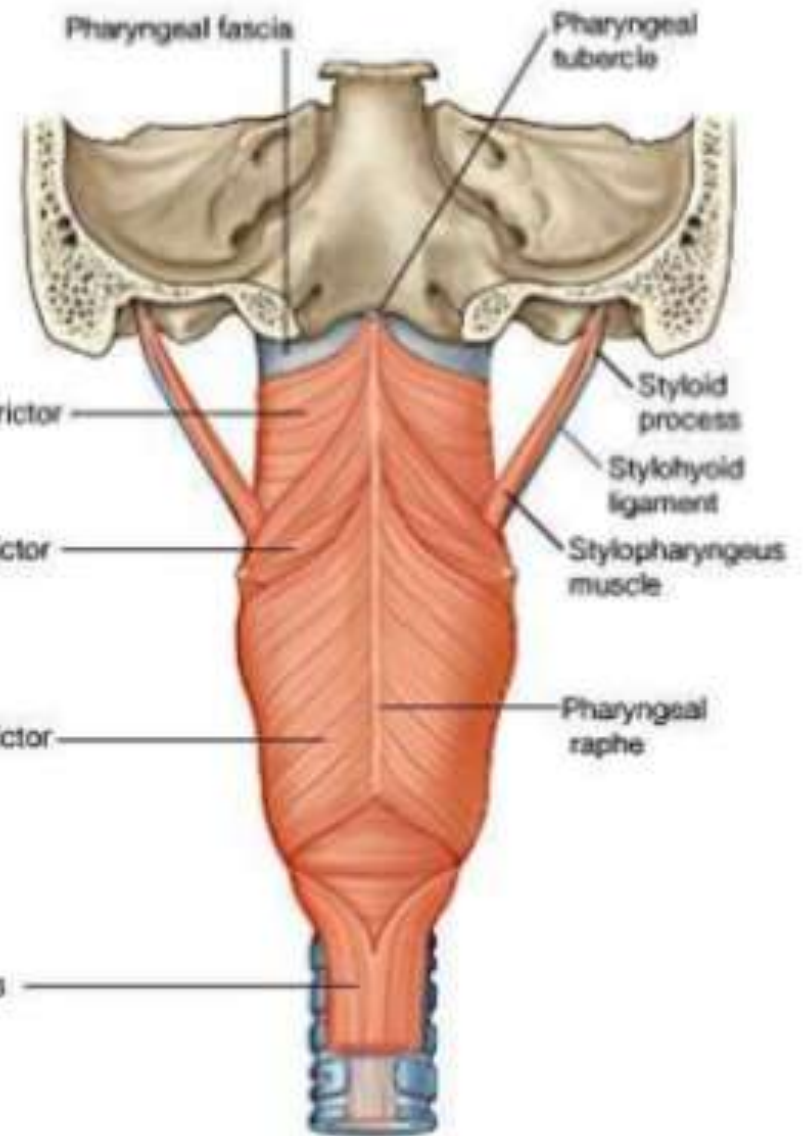
Superior constrictor

Middle constrictor

Inferior constrictor

Esophagus

**B**



Pharyngeal fascia

Pharyngeal  
tubercle

Styloid  
process

Stylohyoid  
ligament

Stylopharyngeus  
muscle

Pharyngeal  
raphe

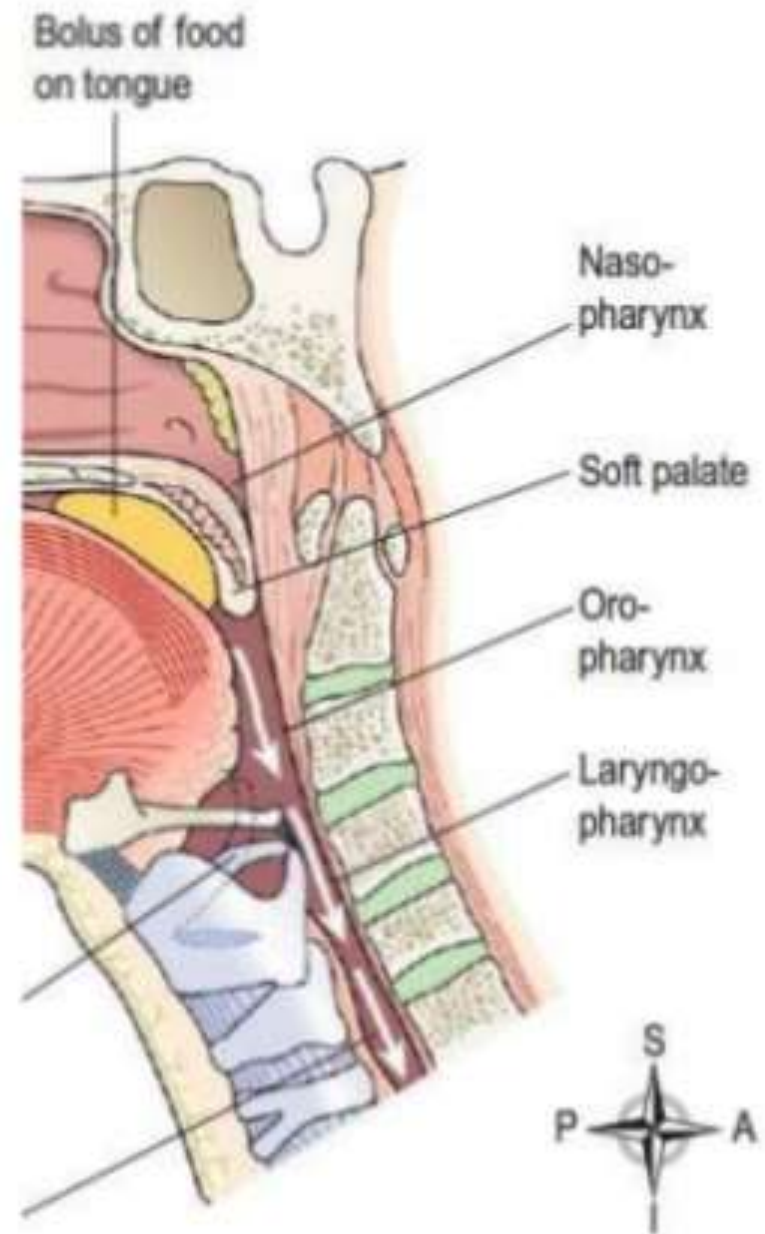
### **3.Laryngopharynx**

- Lower part of pharynx.
- behind the Larynx.
- Upper border of epiglottis to lower border of Cricoid Cartilage



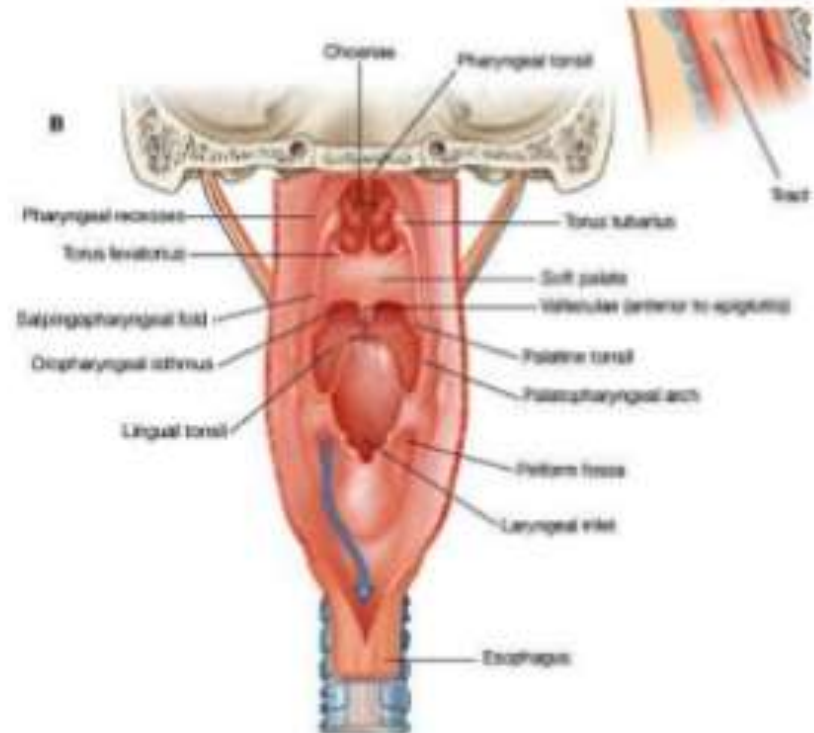
# LARYNGOPHARYNX

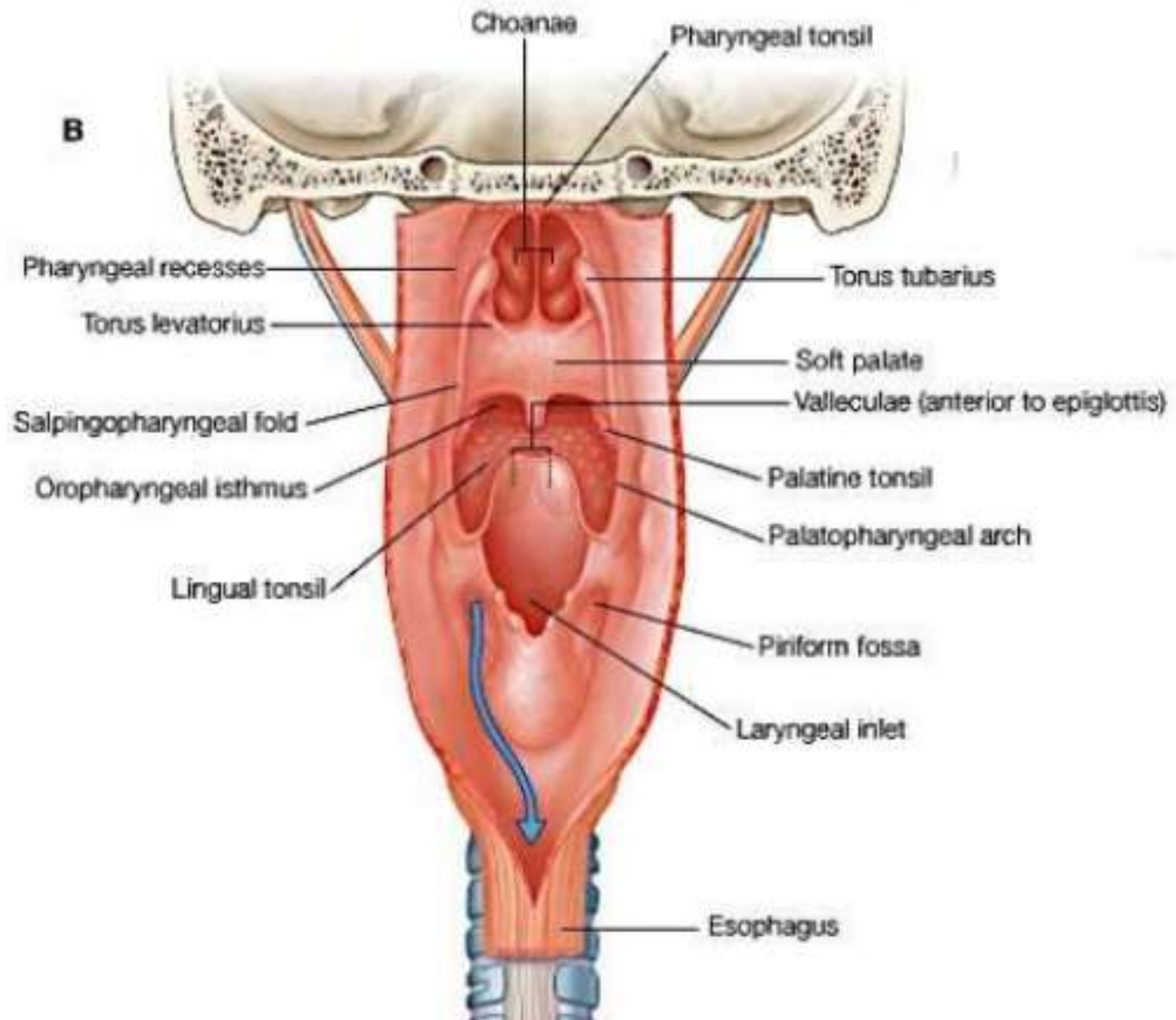
- Behind larynx
- upper part - common to digestive & respi tracts
- lower part continues with esophagus
- Anterior & posterior walls approximated except when food is passing



# LARYNGOPHARYNX

- Posterior wall and side - walls are smooth.
- Anterior wall from above downwards presents
  - epiglottis
  - aryepiglottic folds
  - Arytenoids & cricoid
  - inlet of larynx
  - piriform fossa
- Anterior wall - back of larynx.





# Functions of Pharynx

- Deglutition
- Respiration
- Vocal resonance
- Secretion of mucus by mucous membrane to lubricate the pharynx
- Provides drainage to nose, oral cavity, middle ear



# Functions of Nasopharynx

- Airway for passage of air into larynx, trachea and lungs
- Hearing – middle ear ventilation, maintains air pressure
- Resonance for voice production
- Drainage for nasal and nasopharyngeal secretions
- Prevents aspiration (Nasopharyngeal isthmus closes during, swallowing, vomiting, speech..)

# Functions of Oropharynx

- Common conduit for air and food
- Deglutition
- Vocal resonance
- Taste sensation (tongue base, soft palate, anterior pillar, posterior pharyngeal wall)
- Local defence and immunity (Waldeyer's ring)



# Functions of Laryngopharynx

- Common conduit for air and food
- Voice resonance
- Deglutition

# Palato (velo) pharyngeal mechanism

The velopharyngeal mechanism **is** a coordinated valve formed by the muscles of the soft palate and pharynx.


# Muscles forming the velopharyngeal sphincter

*Muscles forming the palate, these are:*

- Levator veli palatini muscle
- Tensor veli palatini muscle
- Palato glossus muscle
- Palato pharyngus muscle
- Uvula muscle, which is the intrinsic muscle of the velum

*Muscles forming the pharynx, these are:*

- Superior constrictor muscle
- Salpingo pharynges muscle
- Palato pharyngus muscle which has two portions, the pharyngo palatal portion and the thyro-palatal portion

- 
- The levator veli palatini muscle and the superior constrictor muscles play the dominant role in velopharyngeal mechanism especially during closure of the nasal cavity. The levator veli palatini muscle is a long muscle and provides a wide range of movement necessary in moving the velum from the relaxed rest position to a fully elevated position



**pharynx** shares in palato pharyngeal mechanism by:

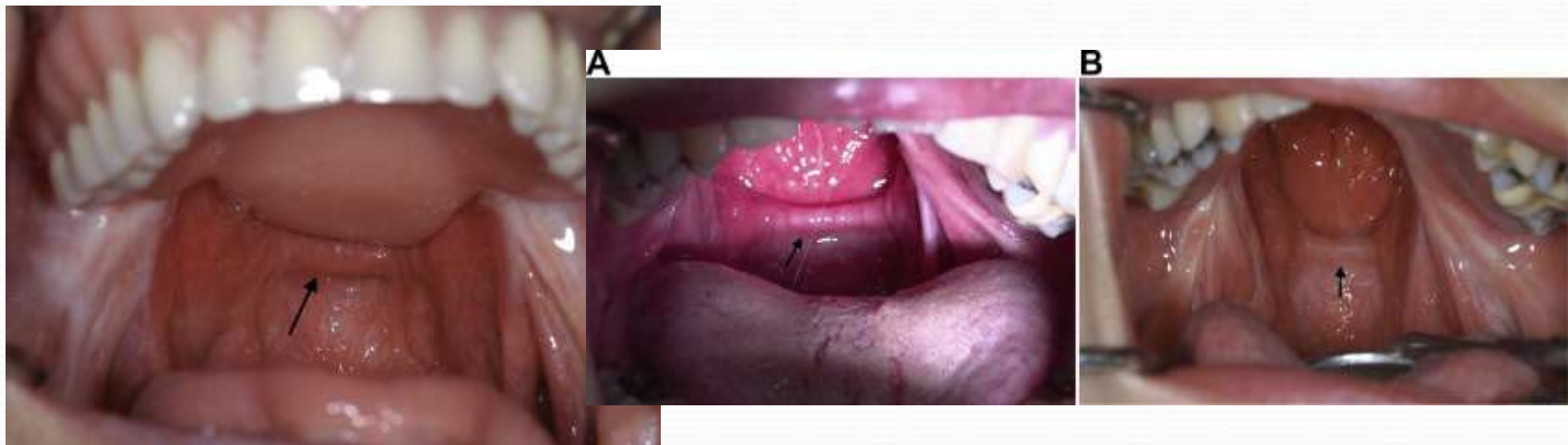
- \*Movement of the posterior wall of the pharynx forwards. This is done by the action of the superior constrictor muscle aided by the pharyngo palatal portion of the palato pharyngus muscle.

- \*Movement of the lateral walls of the pharynx medially to close the last gap between the lateral aspect of soft palate and lateral walls of pharynx. This is done by the action of the salpingo pharynges muscle.

- \*The posterior pharyngeal muscles contracts strongly and produces a bunch-up forming a prominent ridge or pad called “Ridge of Passavant”. This helps to approximate the soft palate and pharynx,

# Ridge of Passavant

The ridge of Passavant is a horizontal roll of muscles on the posterior wall of the pharynx forming a bunching-up of the posterior pharyngeal wall. It is present at the level of the palate which corresponds to the level of the atlas vertebra. It is usually more evident in patients with soft palate defects as a compensating mechanism to aid in speech and swallowing. It also serves as a guide for placement of soft palate prostheses



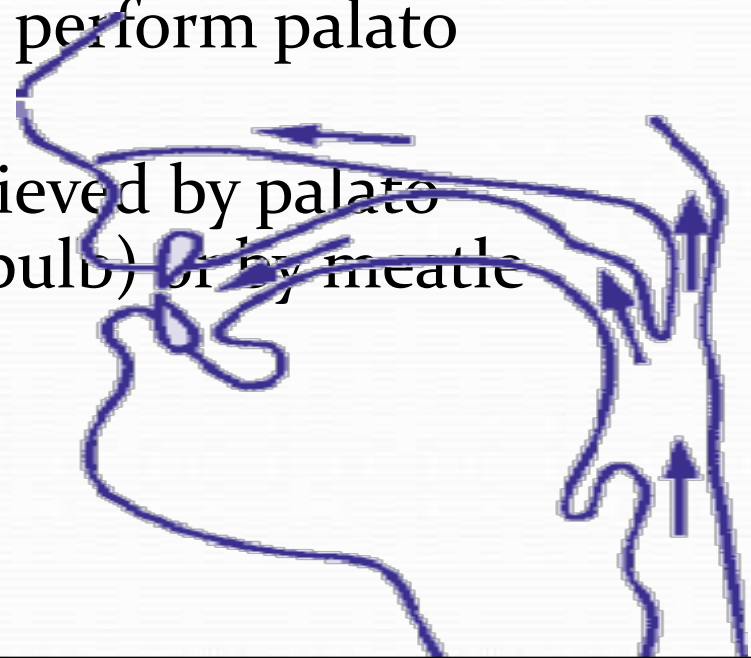


# Velopharyngeal insufficiency:

Palato pharyngeal insufficiency is a condition characterized by abnormal anatomy of the palate in the form of absence, short length or cleft in the tissues of the soft palate.

This could be congenital, or due to acquired causes as resection of soft palate or lateral pharyngeal wall. This condition results in inability to perform palato pharyngeal mechanism.

Prosthetic rehabilitation is achieved by palato pharyngeal obturator (speech bulb) or by meatal obturator.



# complications

- **feeding difficulties**

Feeding difficulties occur more with cleft palate abnormalities. The infant may be unable to suck properly because the roof of the mouth is not formed completely.

- **ear infections and hearing loss**

Ear infections are often due to a dysfunction of the tube that connects the middle ear and the throat. Recurrent infections can then lead to hearing loss.

Cont...

- **speech and language delay**

Due to the opening of the roof of the mouth and the lip, muscle function may be decreased, which can lead to a delay in speech or abnormal speech. (*hypernasal speech*) due to Velopharyngeal incompetence.

- **dental problems**

As a result of the abnormalities, teeth may not erupt normally and orthodontic treatment is usually required

# Cont...

## ■ Airway :

- Major respiratory obstruction is uncommon
- Hypoxic episodes during sleep and feeding are life threatening
- intermittent airway obstruction is more frequent and managed by nursing the baby prone



Thank you

# Cleft palate: Pharynx anatomy & problems

Hussein T. Abed 17\2\2021



# The pharynx

is a simple, funnel shaped tube wide at the head and narrow at esophageal end. The pharynx has three muscles:

superior, middle and inferior constrictors.

# The pharynx

The action of the pharynx is :

1. it contracts from side to side and its posterior surface moves forwards.
2. it is capable of local contractions at various levels, which are mainly used in speech, and swallowing.

## Divisions

- 1) NASOPHARYNX
- 2) OROPHARYNX
- 3) LARYNGOPHARYNX (HYPOPHARYNX)

Nasal cavity

Soft palate


Hard  
palate

Tongue

Epiglottis

Larynx  
(voice box)

Trachea



Nasopharynx

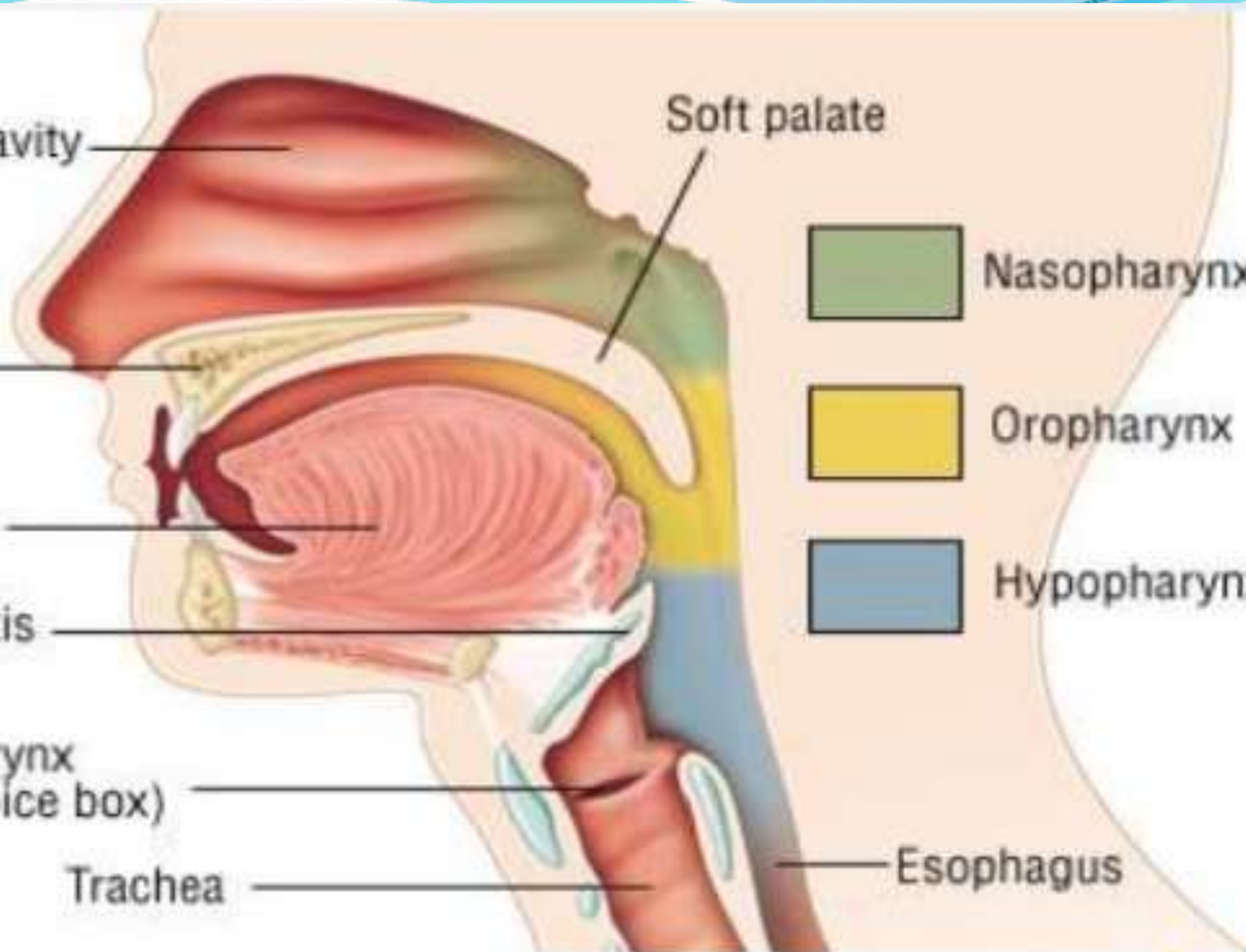


Oropharynx



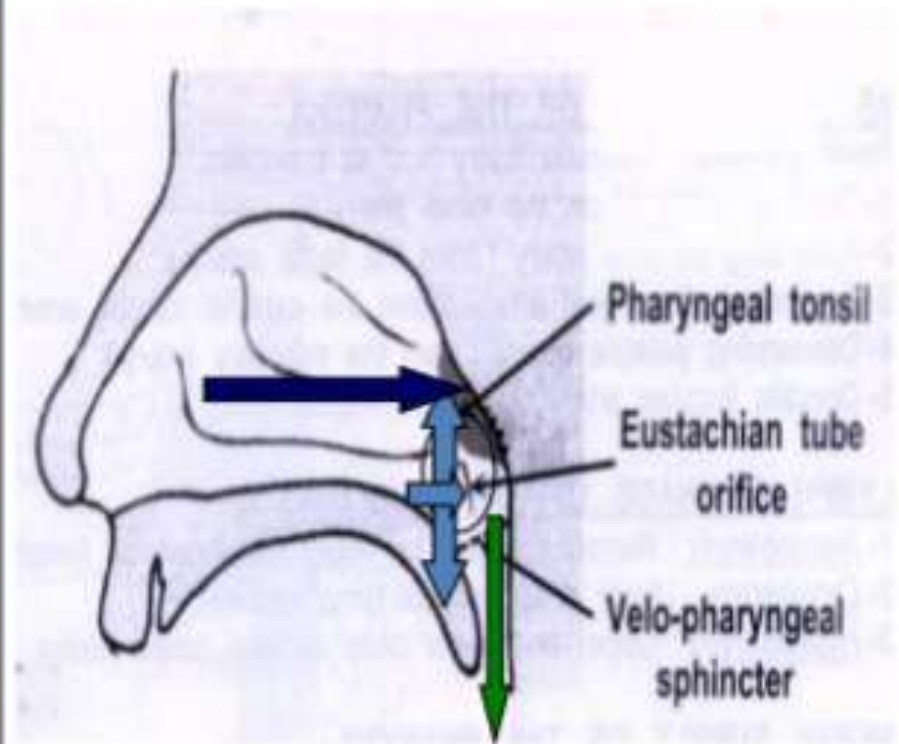
Hypopharynx

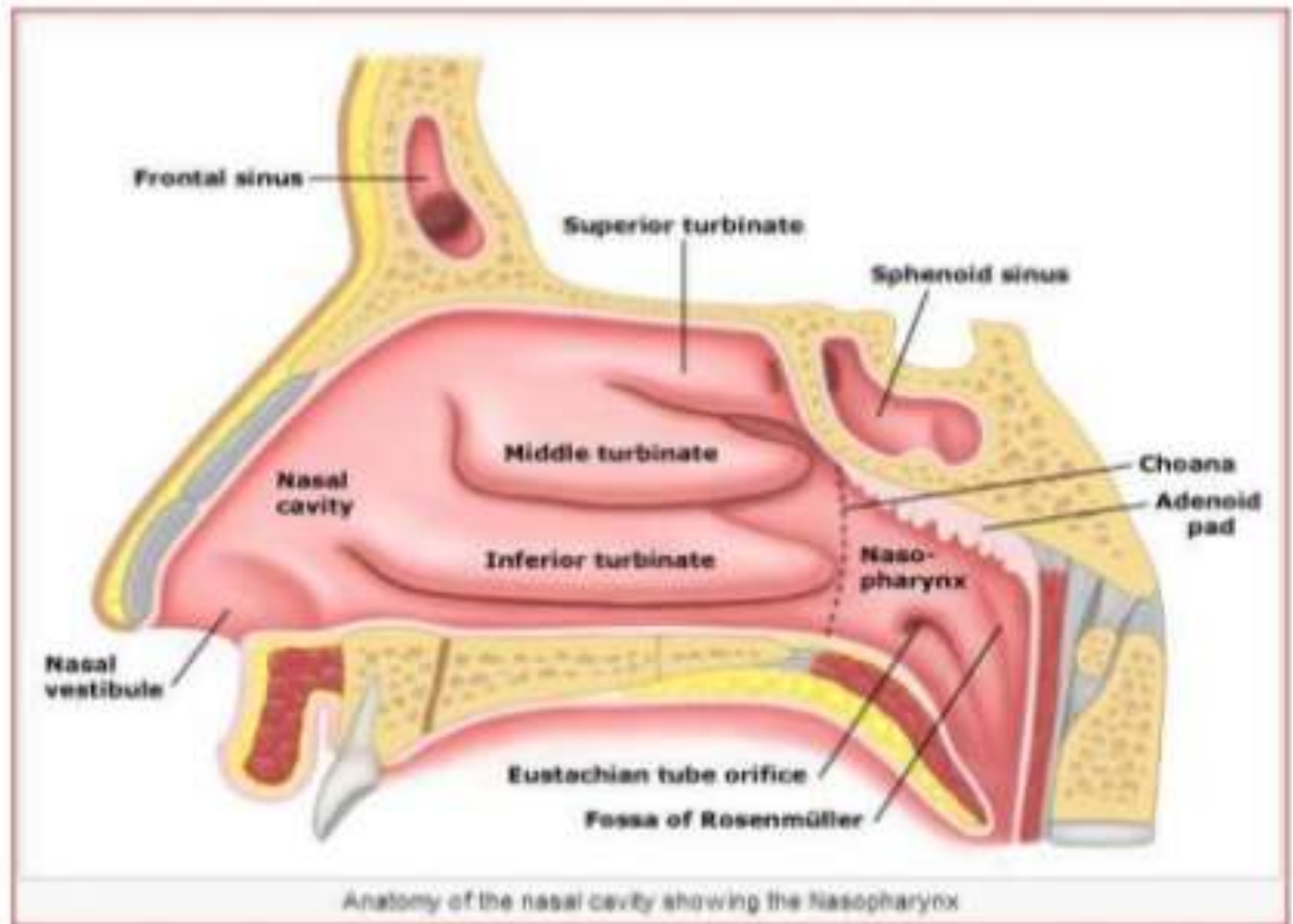
Esophagus



# Nasopharynx

- Behind the nasal cavity
- Extends from skull  
Base superiorly to the soft palate inferiorly
- **Communicates inferiorly with the oropharynx through the velo-pharyngeal sphincter**
- **The nasopharyngeal tonsil lies in the roof**
- The pharyngeal opening of ET lies in the lateral wall





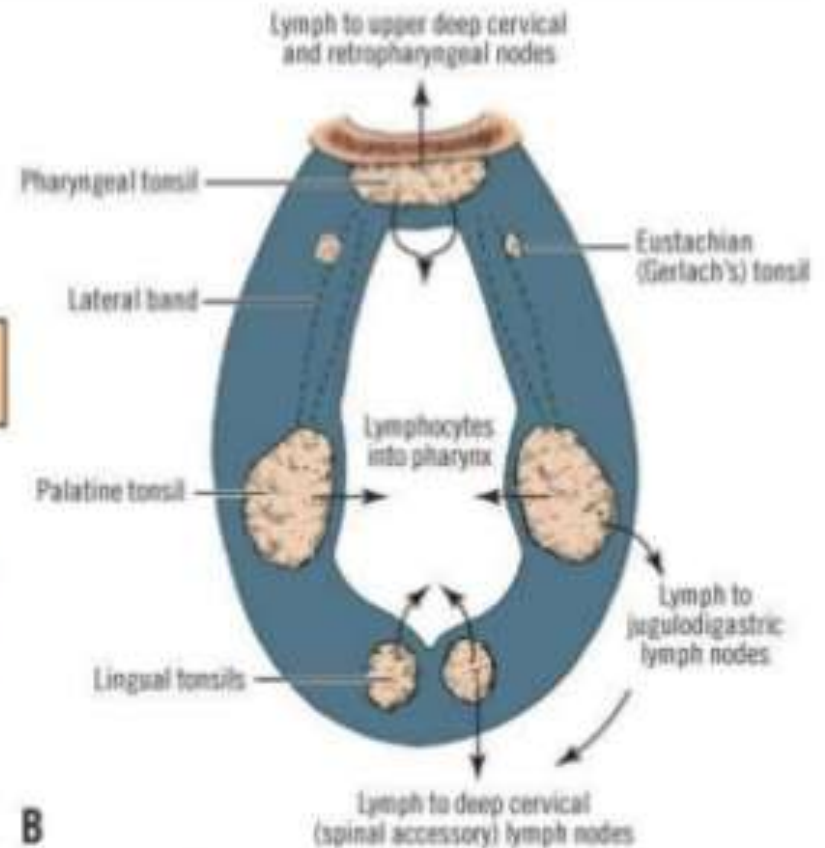
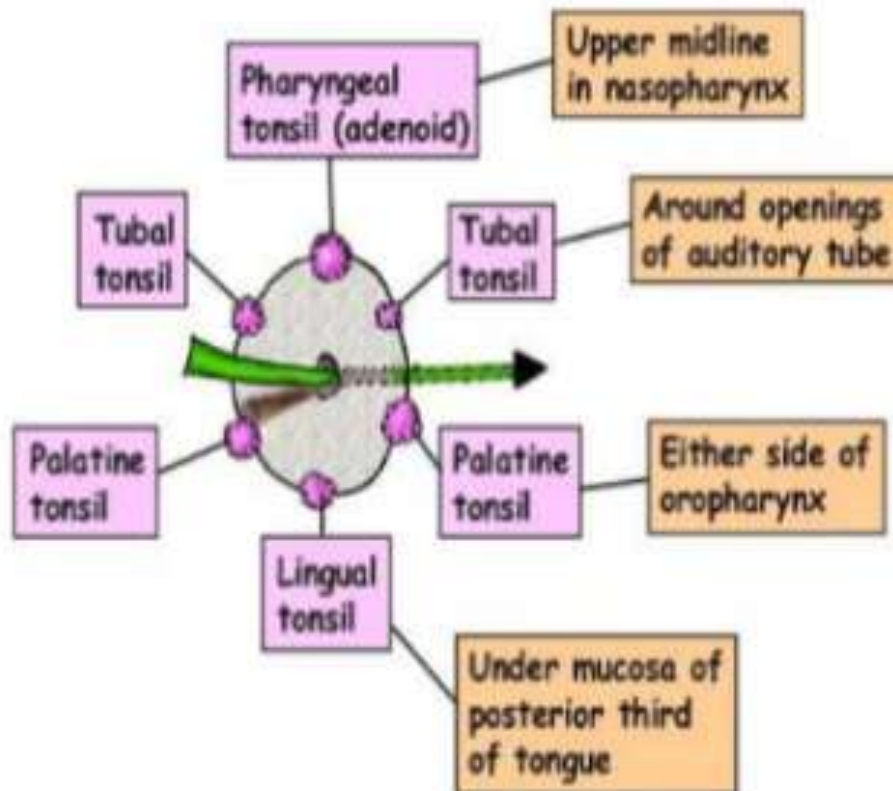


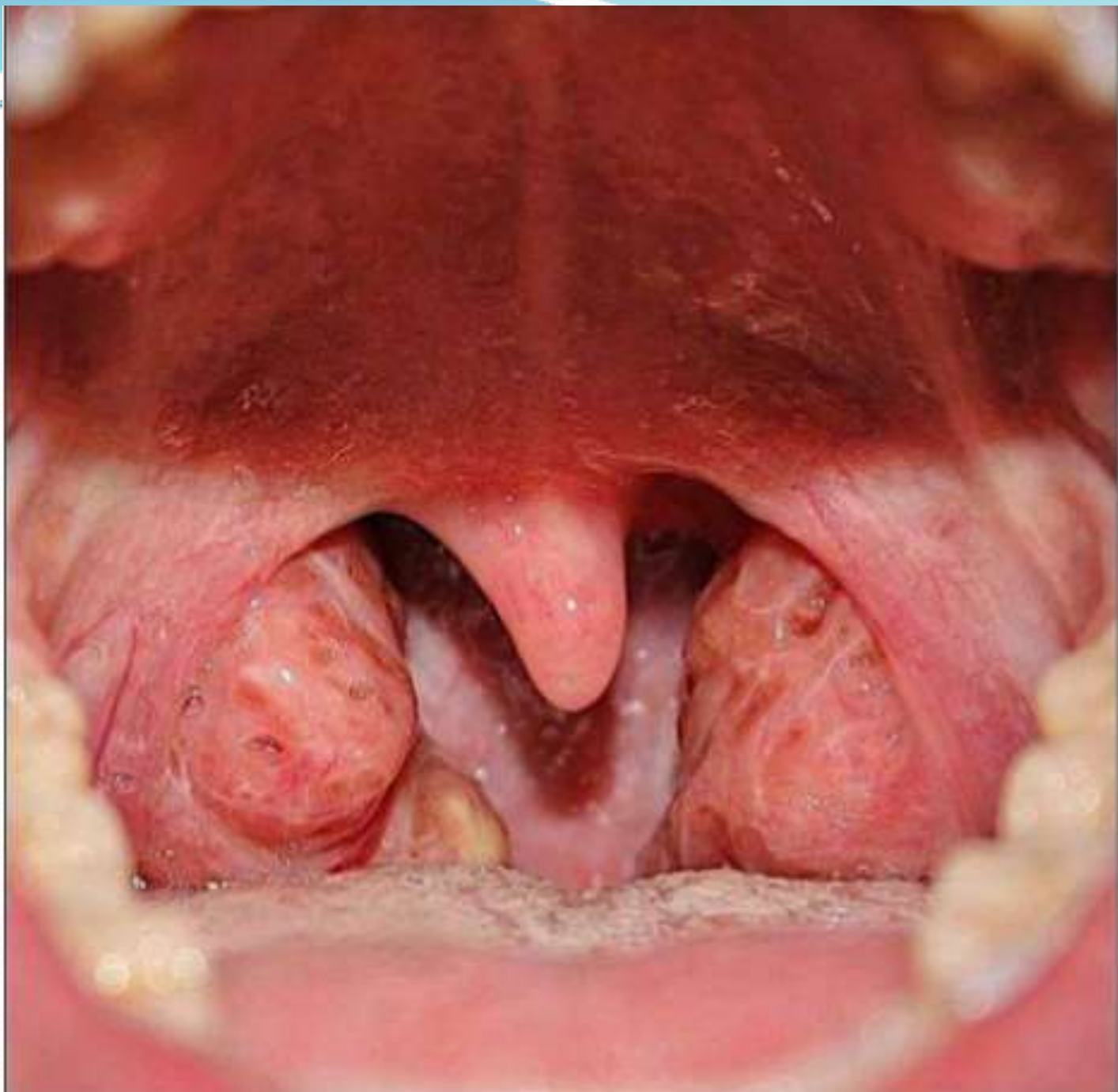
# Tonsils

- **Pharyngeal** tonsil (adenoids): midline on the roof of the nasopharynx;
- **Palatine** tonsils: on each side of the oropharynx between the palatoglossal and palatopharyngeal arches
- **Lingual** tonsil : posterior one-third of the tongue.
- **Tubal** tonsil: pharyngotympanic tube near its opening into the nasopharynx, and on the upper surface of the soft palate.

# What is Waldeyer's ring?

An interrupted circle of protective lymphoid tissue at the upper ends of the respiratory and alimentary tracts





## 2. OROPHARYNX

- Middle part
- Above -Nasopharynx
- Front- oral cavity
- Below-Laryngopharynx
- Supported by C2&C3
- Lateral -Palatine Tonsils

### OROPHARYNX

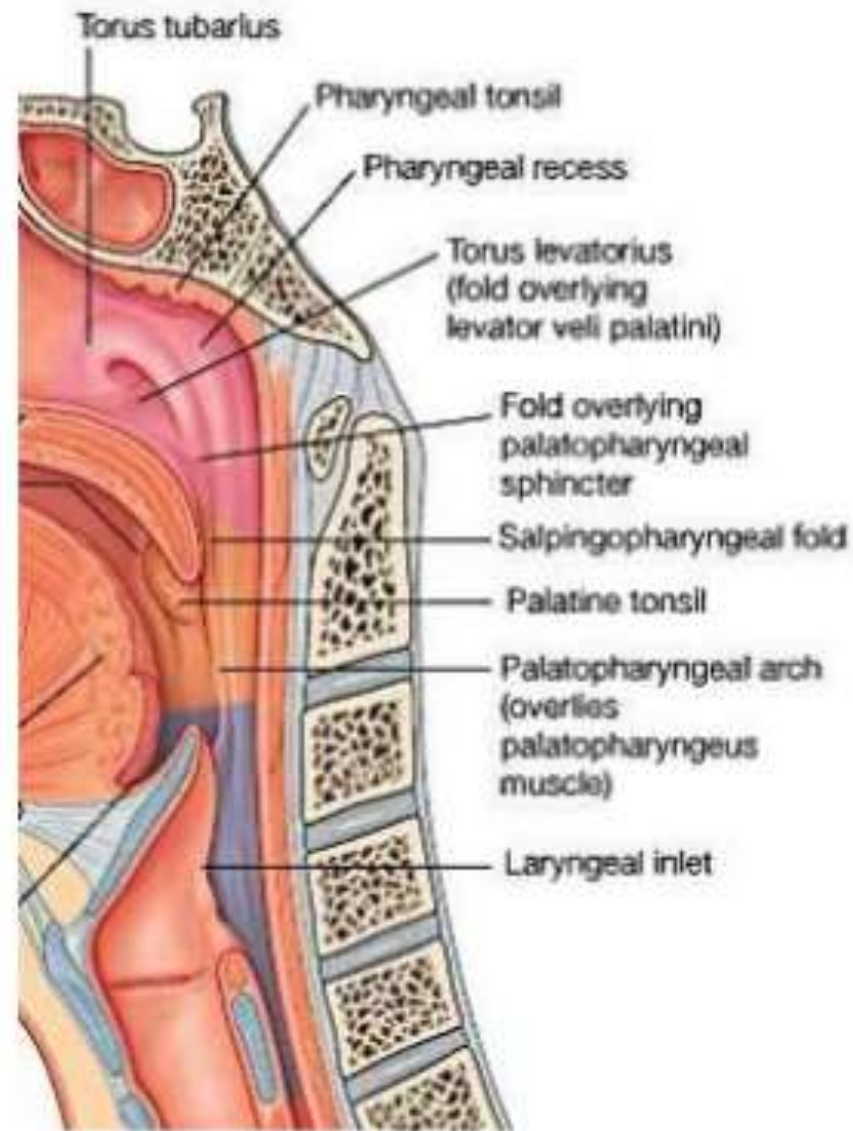
It is the middle part of the pharynx situated behind the oral cavity.





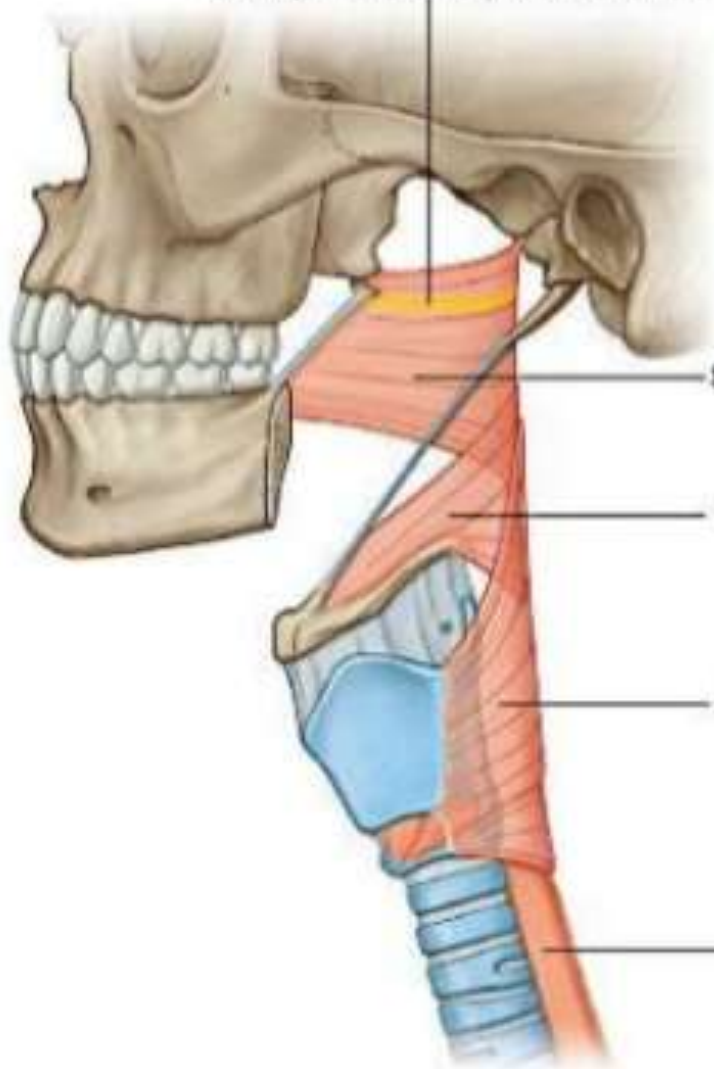
# OROPHARYNX

- Behind mouth and tongue.
- common to both respiratory and digestive systems
- Oropharyngeal isthmus
- Posterior wall is smooth
- Lateral walls shows **palatine tonsils** between palatoglossal and palatopharyngeal arches.



**A**

Position of palatopharyngeal sphincter  
on deep surface of superior constrictor



Superior constrictor

Middle constrictor

Inferior constrictor

Esophagus

**B**

Pharyngeal fascia

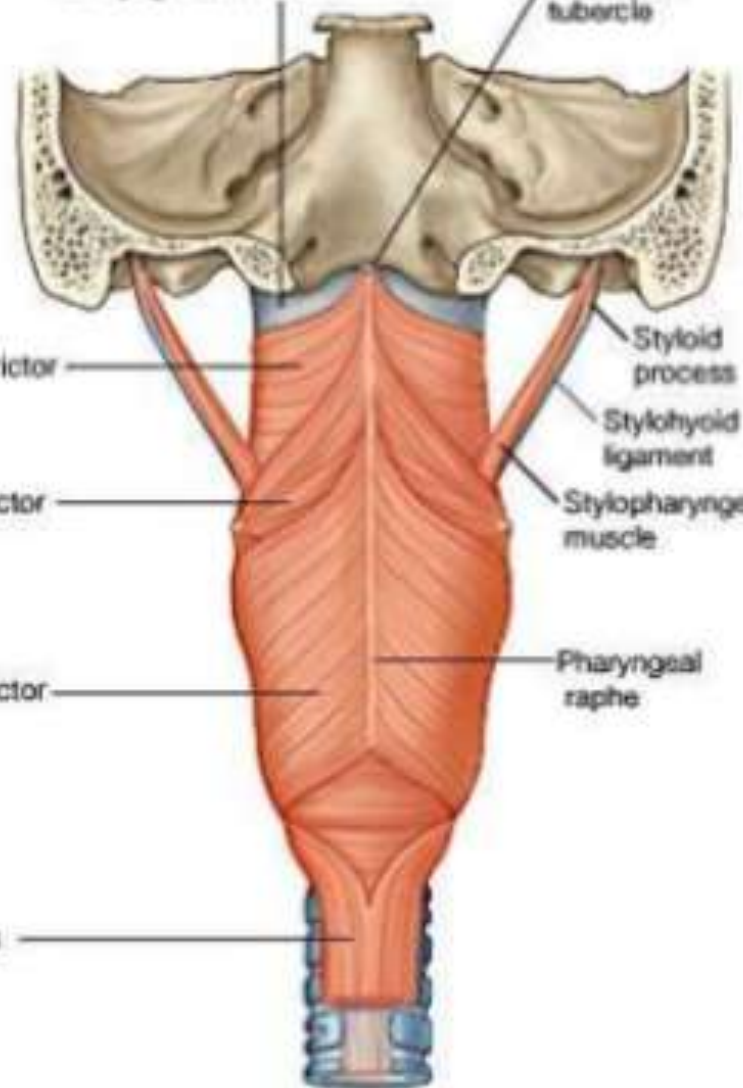
Pharyngeal  
tubercle

Styloid  
process

Stylohyoid  
ligament

Stylopharyngeus  
muscle

Pharyngeal  
raphe



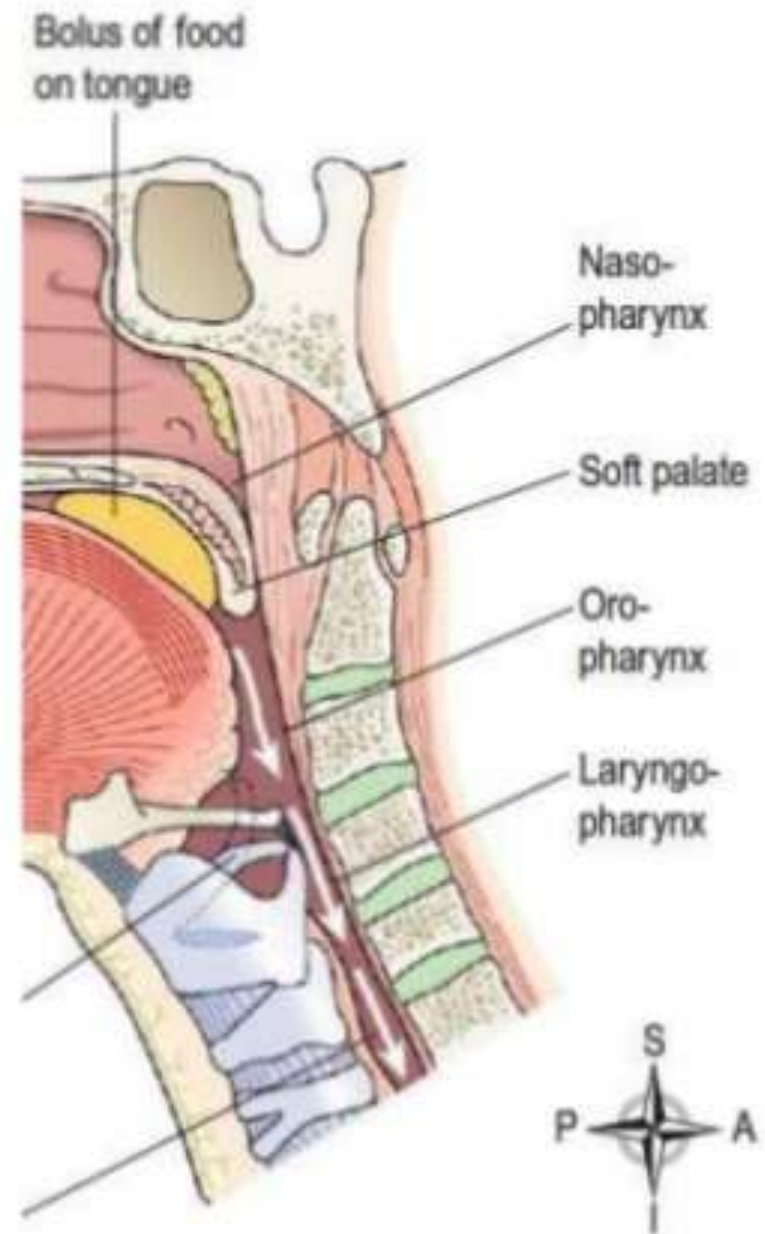


### **3.Laryngopharynx**

- Lower part of pharynx.
- behind the Larynx.
- Upper border of epiglottis to lower border of Cricoid Cartilage

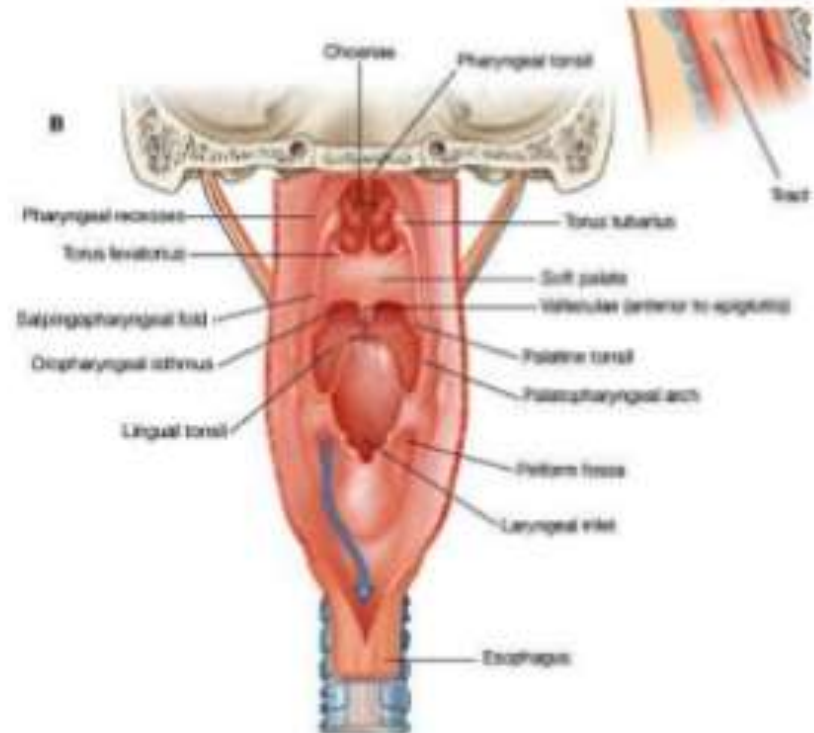
# LARYNGOPHARYNX

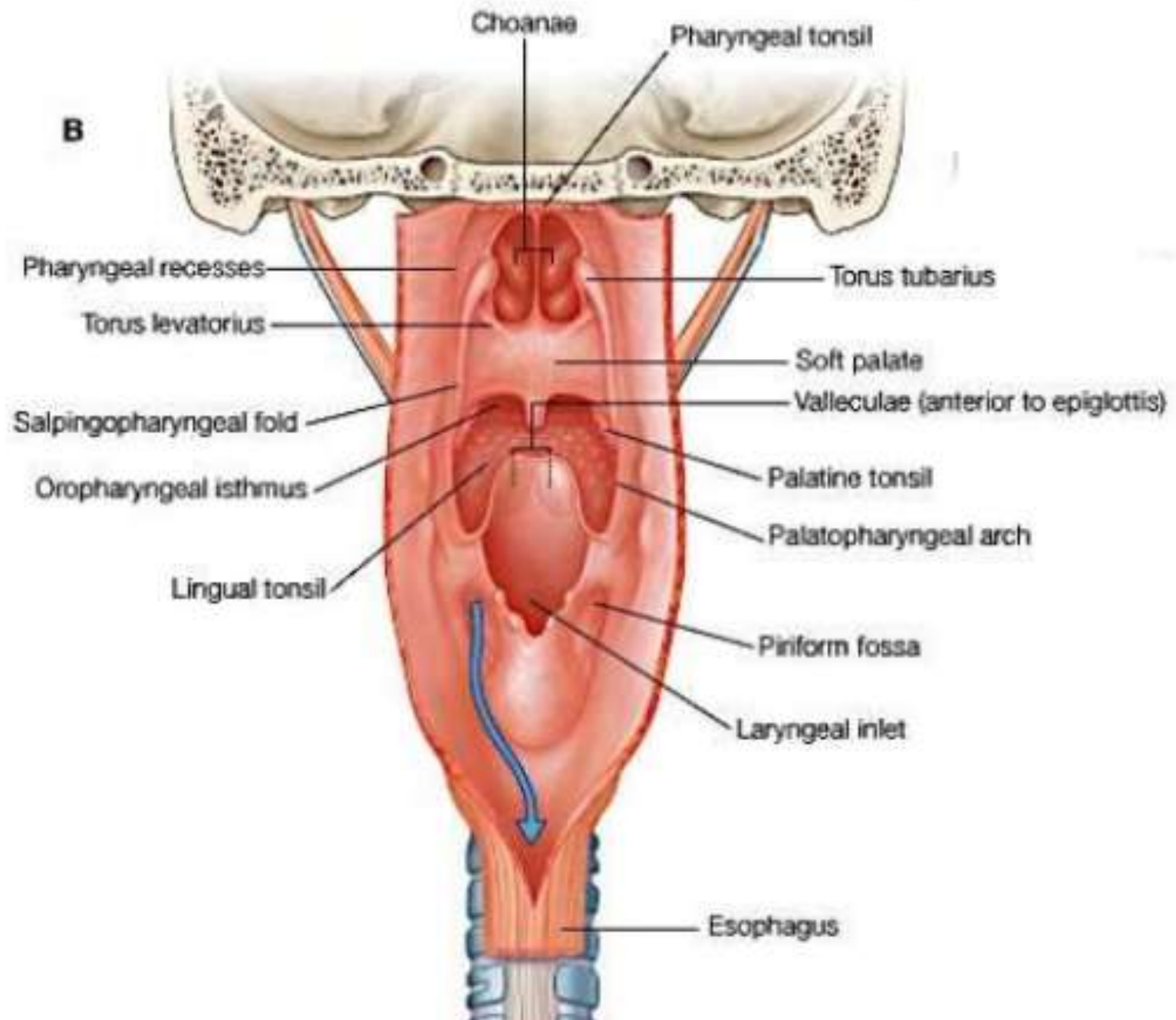
- Behind larynx
- upper part - common to digestive & respi tracts
- lower part continues with esophagus
- Anterior & posterior walls approximated except when food is passing



# LARYNGOPHARYNX

- Posterior wall and side - walls are smooth.
- Anterior wall from above downwards presents
  - epiglottis
  - aryepiglottic folds
  - Arytenoids & cricoid
  - inlet of larynx
  - piriform fossa
- Anterior wall - back of larynx.





# Functions of Pharynx

- Deglutition
- Respiration
- Vocal resonance
- Secretion of mucus by mucous membrane to lubricate the pharynx
- Provides drainage to nose, oral cavity, middle ear



# Functions of Nasopharynx

- Airway for passage of air into larynx, trachea and lungs
- Hearing – middle ear ventilation, maintains air pressure
- Resonance for voice production
- Drainage for nasal and nasopharyngeal secretions
- Prevents aspiration (Nasopharyngeal isthmus closes during, swallowing, vomiting, speech..)



# Functions of Oropharynx

- Common conduit for air and food
- Deglutition
- Vocal resonance
- Taste sensation (tongue base, soft palate, anterior pillar, posterior pharyngeal wall)
- Local defence and immunity (Waldeyer's ring)

# Functions of Laryngopharynx

- Common conduit for air and food
- Voice resonance
- Deglutition

# Palato (velo) pharyngeal mechanism

The velopharyngeal mechanism **is** a coordinated valve formed by the muscles of the soft palate and pharynx.


# Muscles forming the velopharyngeal sphincter

*Muscles forming the palate, these are:*

- Levator veli palatini muscle
- Tensor veli palatini muscle
- Palato glossus muscle
- Palato pharyngus muscle
- Uvula muscle, which is the intrinsic muscle of the velum

*Muscles forming the pharynx, these are:*

- Superior constrictor muscle
- Salpingo pharynges muscle
- Palato pharyngus muscle which has two portions, the pharyngo palatal portion and the thyro-palatal portion

- 
- The levator veli palatini muscle and the superior constrictor muscles play the dominant role in velopharyngeal mechanism especially during closure of the nasal cavity. The levator veli palatini muscle is a long muscle and provides a wide range of movement necessary in moving the velum from the relaxed rest position to a fully elevated position



**pharynx** shares in palato pharyngeal mechanism by:

- \*Movement of the posterior wall of the pharynx forwards. This is done by the action of the superior constrictor muscle aided by the pharyngo palatal portion of the palato pharyngus muscle.

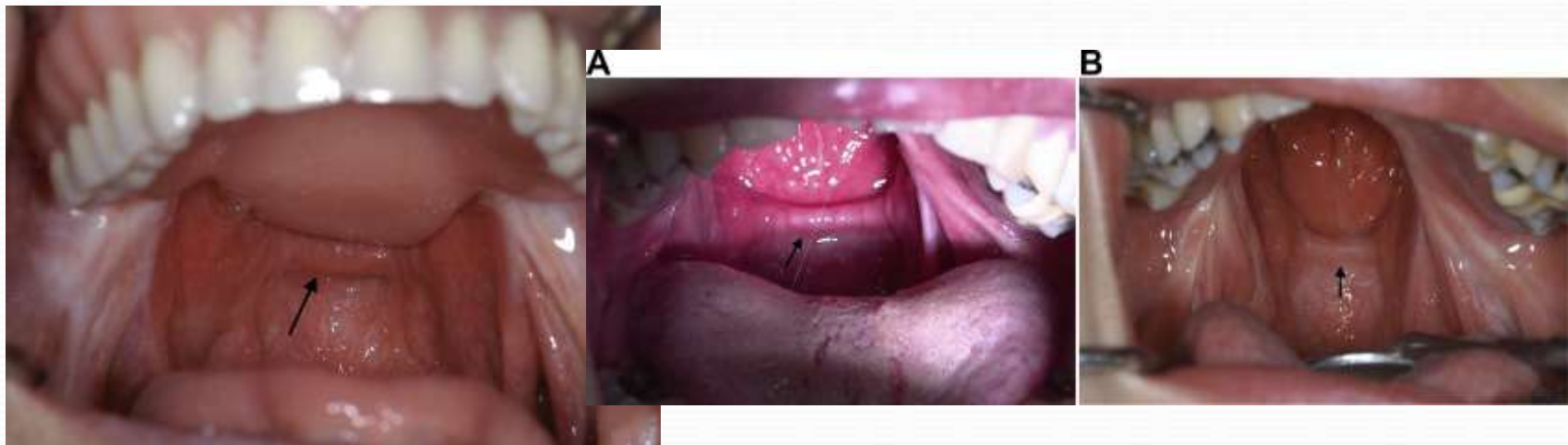
- \*Movement of the lateral walls of the pharynx medially to close the last gap between the lateral aspect of soft palate and lateral walls of pharynx. This is done by the action of the salpingo pharynges muscle.

- \*The posterior pharyngeal muscles contracts strongly and produces a bunch-up forming a prominent ridge or pad called “Ridge of Passavant”. This helps to approximate the soft palate and pharynx,



# Ridge of Passavant

The ridge of Passavant is a horizontal roll of muscles on the posterior wall of the pharynx forming a bunching-up of the posterior pharyngeal wall. It is present at the level of the palate which corresponds to the level of the atlas vertebra. It is usually more evident in patients with soft palate defects as a compensating mechanism to aid in speech and swallowing. It also serves as a guide for placement of soft palate prostheses

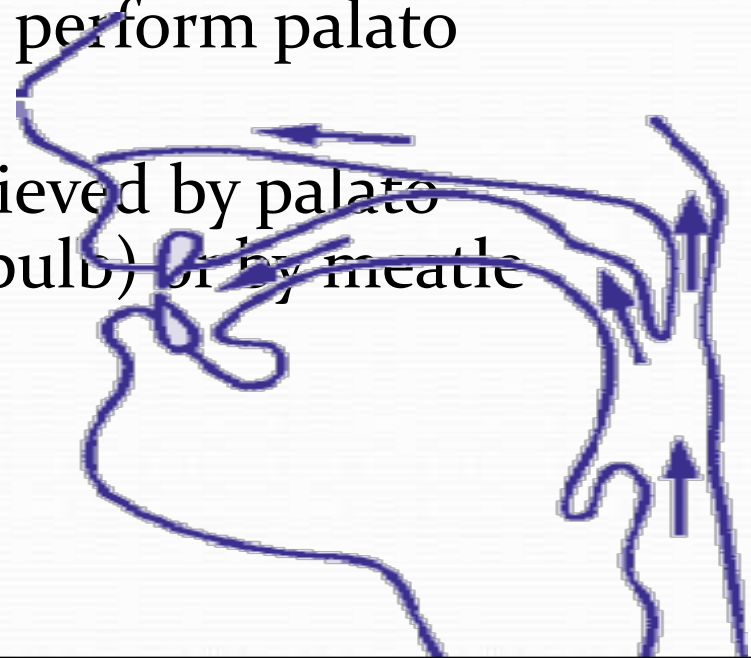


# Velopharyngeal insufficiency:

Palato pharyngeal insufficiency is a condition characterized by abnormal anatomy of the palate in the form of absence, short length or cleft in the tissues of the soft palate.

This could be congenital, or due to acquired causes as resection of soft palate or lateral pharyngeal wall. This condition results in inability to perform palato pharyngeal mechanism.

Prosthetic rehabilitation is achieved by palato pharyngeal obturator (speech bulb) or by meatal obturator.



# complications

- **feeding difficulties**

Feeding difficulties occur more with cleft palate abnormalities. The infant may be unable to suck properly because the roof of the mouth is not formed completely.

- **ear infections and hearing loss**

Ear infections are often due to a dysfunction of the tube that connects the middle ear and the throat. Recurrent infections can then lead to hearing loss.

## Cont...

- **speech and language delay**

Due to the opening of the roof of the mouth and the lip, muscle function may be decreased, which can lead to a delay in speech or abnormal speech. (*hypernasal speech*) due to Velopharyngeal incompetence.

- **dental problems**

As a result of the abnormalities, teeth may not erupt normally and orthodontic treatment is usually required



# Cont...

## ■ Airway :

- Major respiratory obstruction is uncommon
- Hypoxic episodes during sleep and feeding are life threatening
- intermittent airway obstruction is more frequent and managed by nursing the baby prone



Thank you



# Cleft palate: Pharynx anatomy & problems

Hussein T. Abed 17\2\2021

# The pharynx

is a simple, funnel shaped tube wide at the head and narrow at esophageal end. The pharynx has three muscles:

superior, middle and inferior constrictors.

# The pharynx

The action of the pharynx is :

1. it contracts from side to side and its posterior surface moves forwards.
2. it is capable of local contractions at various levels, which are mainly used in speech, and swallowing.

## Divisions

1) NASOPHARYNX

2) OROPHARYNX

3) LARYNGOPHARYNX (HYPOPHARYNX)

Nasal cavity

Soft palate

Hard  
palate

Tongue

Epiglottis

Larynx  
(voice box)

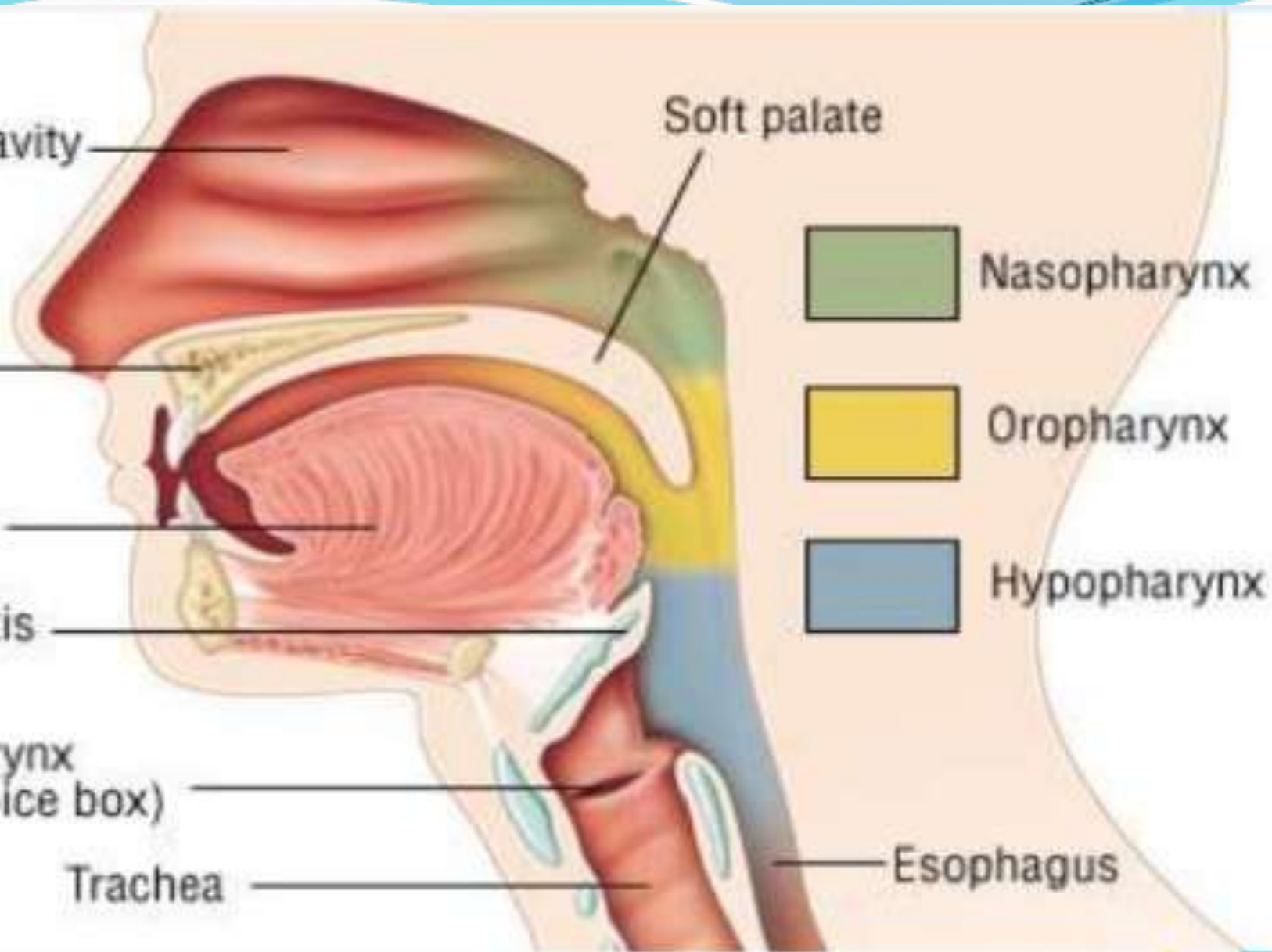
Trachea

Nasopharynx

Oropharynx

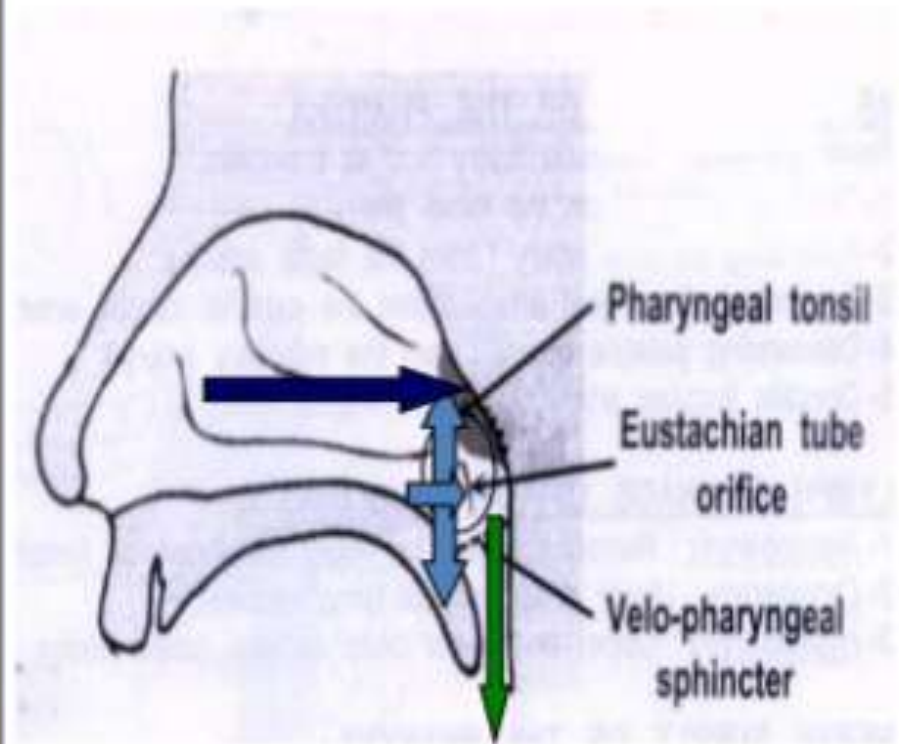
Hypopharynx

Esophagus

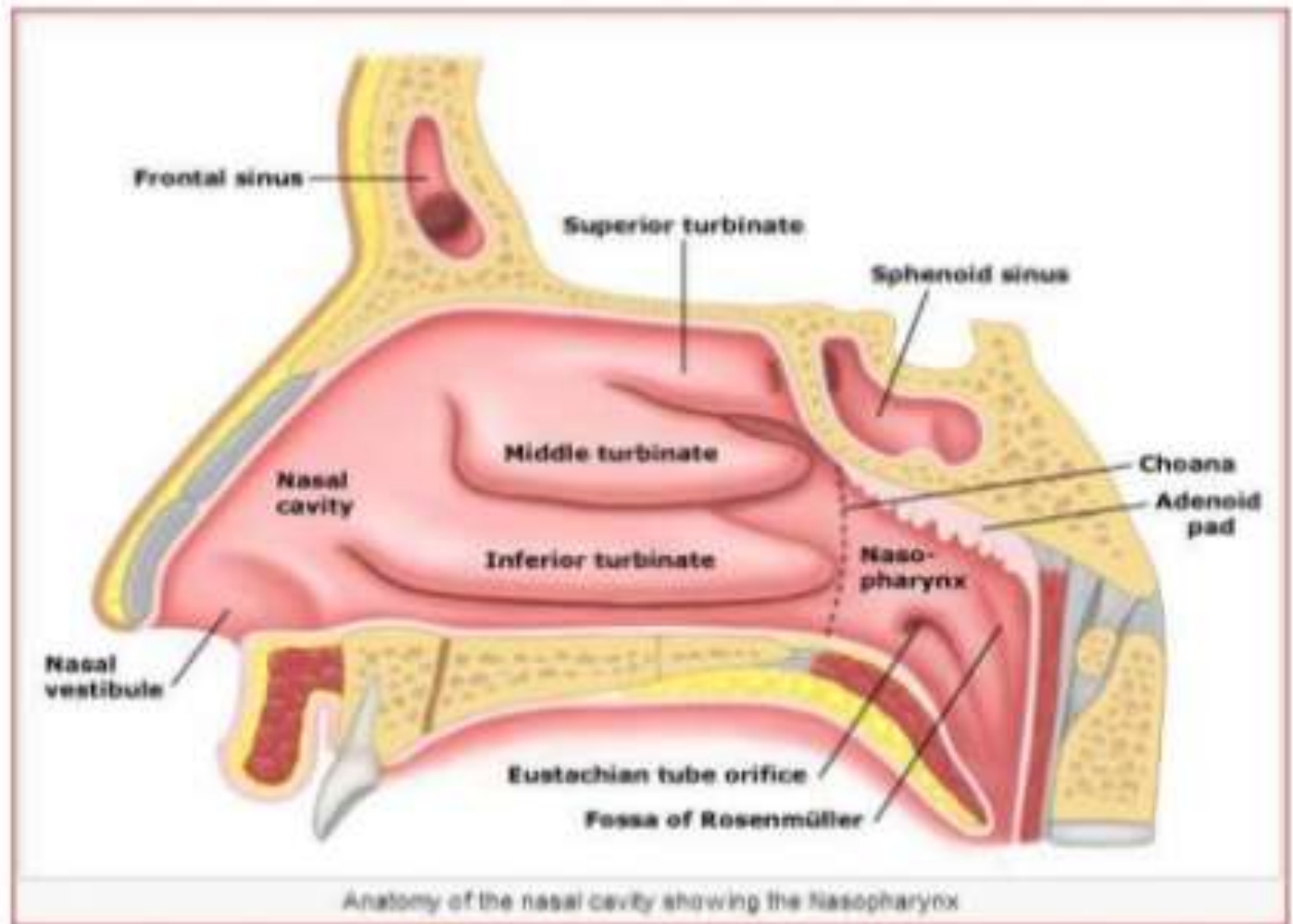


# Nasopharynx

- Behind the nasal cavity
- Extends from skull  
Base superiorly to the soft palate inferiorly
- **Communicates inferiorly with the oropharynx through the velo-pharyngeal sphincter**
- **The nasopharyngeal tonsil lies in the roof**
- The pharyngeal opening of ET lies in the lateral wall





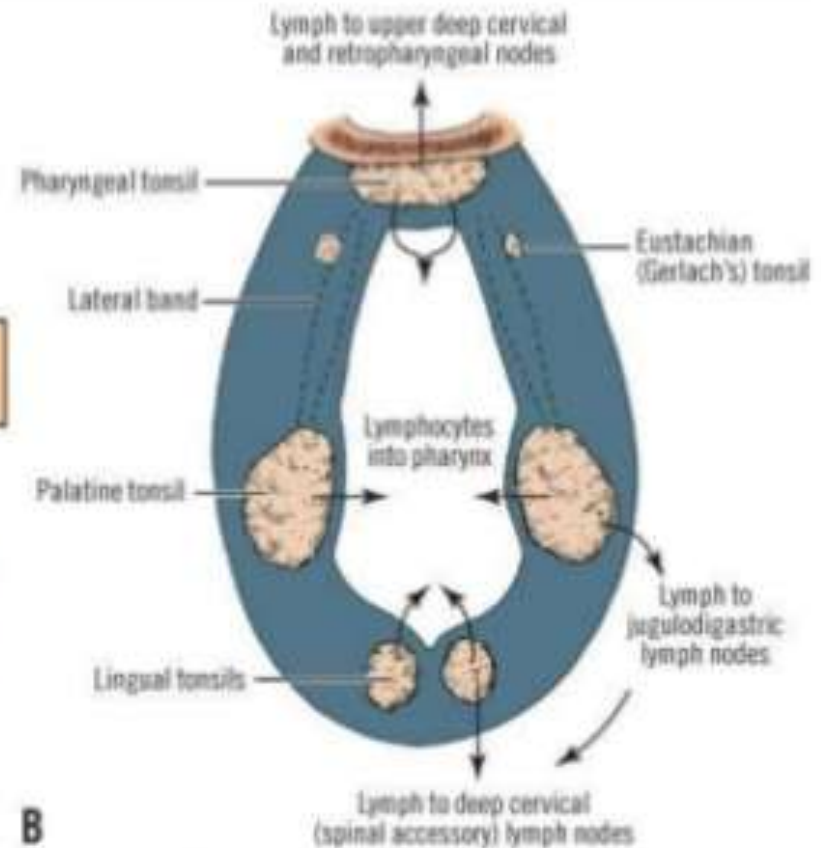
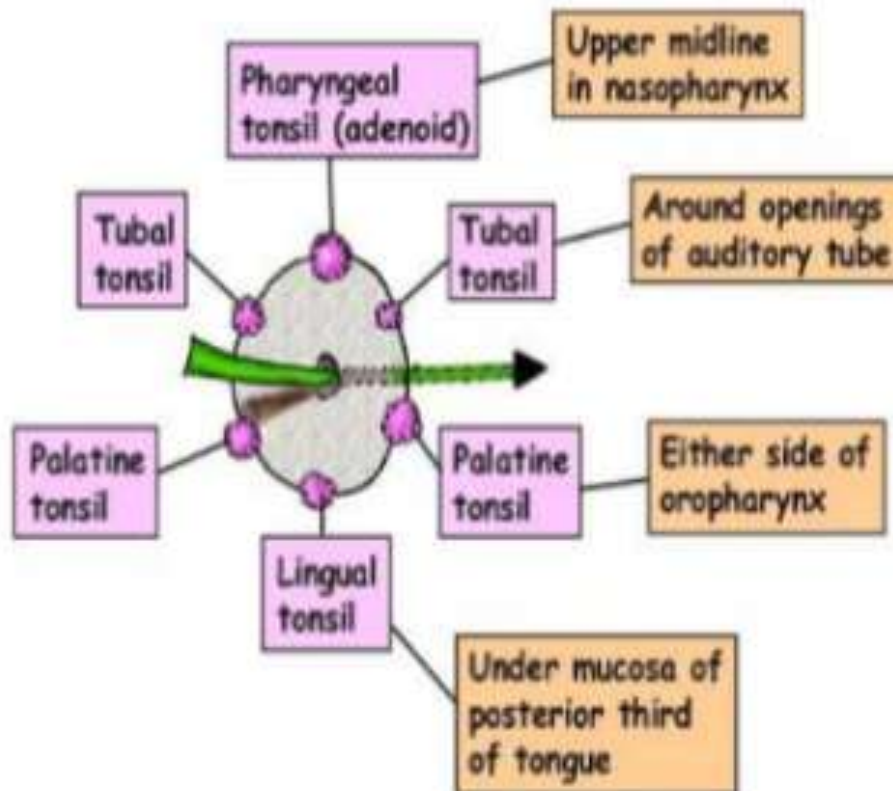


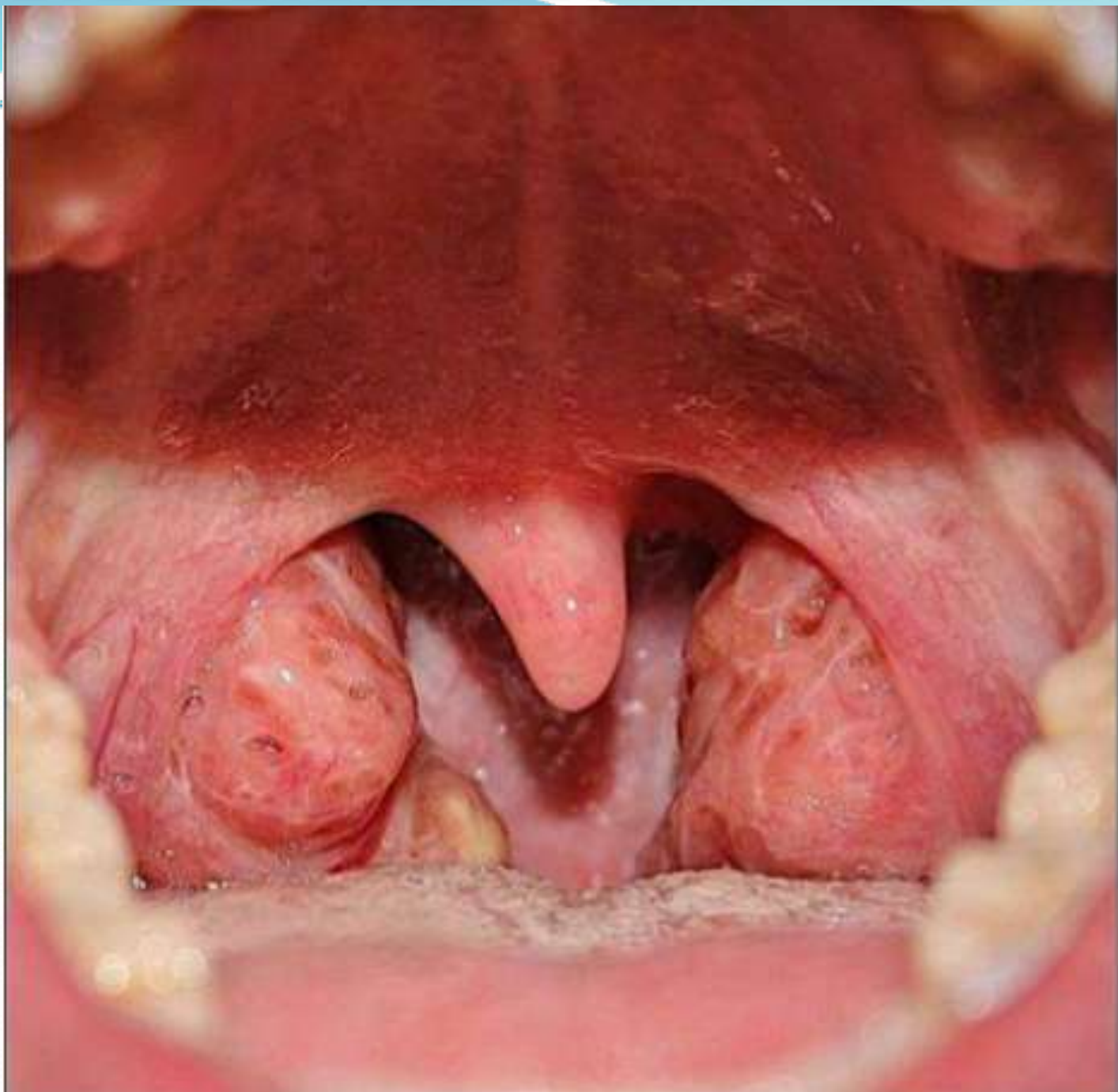
# Tonsils

- **Pharyngeal** tonsil (adenoids): midline on the roof of the nasopharynx;
- **Palatine** tonsils: on each side of the oropharynx between the palatoglossal and palatopharyngeal arches
- **Lingual** tonsil : posterior one-third of the tongue.
- **Tubal** tonsil: pharyngotympanic tube near its opening into the nasopharynx, and on the upper surface of the soft palate.

# What is Waldeyer's ring?

An interrupted circle of protective lymphoid tissue at the upper ends of the respiratory and alimentary tracts







## 2. OROPHARYNX

- Middle part
- Above -Nasopharynx
- Front- oral cavity
- Below-Laryngopharynx
- Supported by C2&C3
- Lateral -Palatine Tonsils

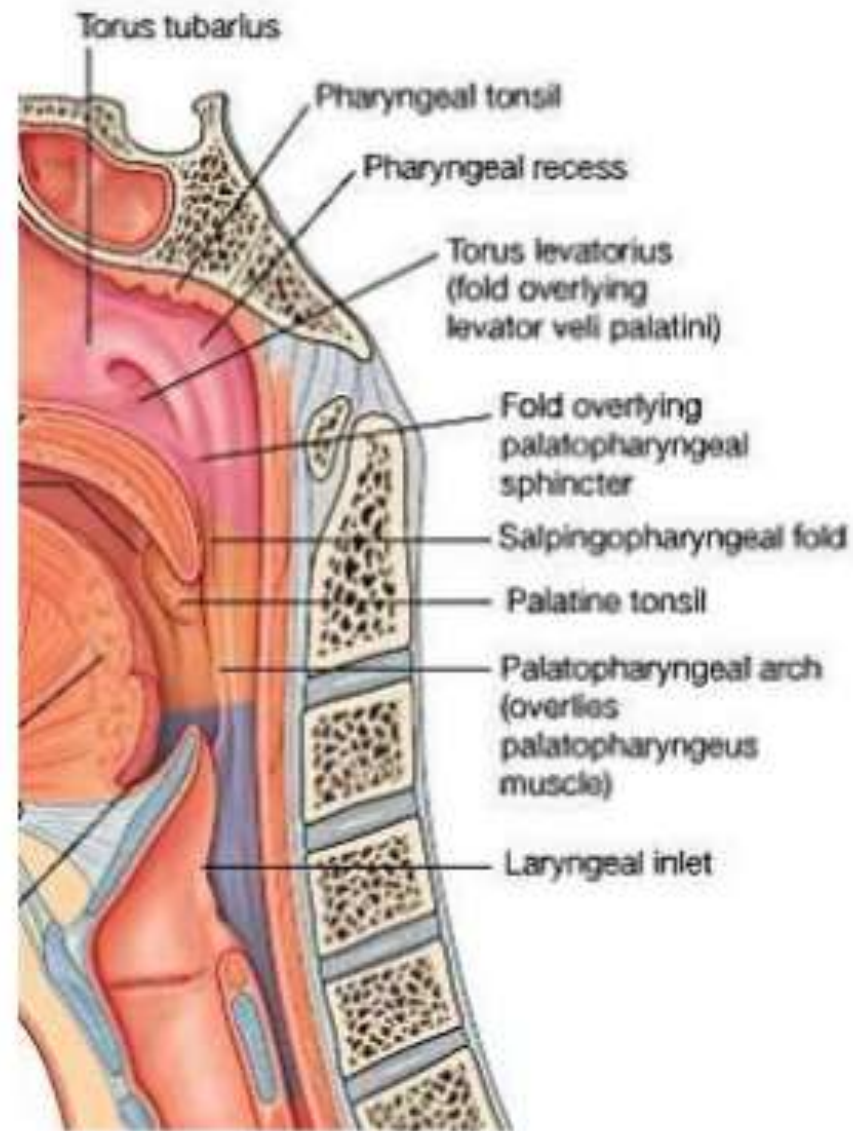
### OROPHARYNX

It is the middle part of the pharynx situated behind the oral cavity.



# OROPHARYNX

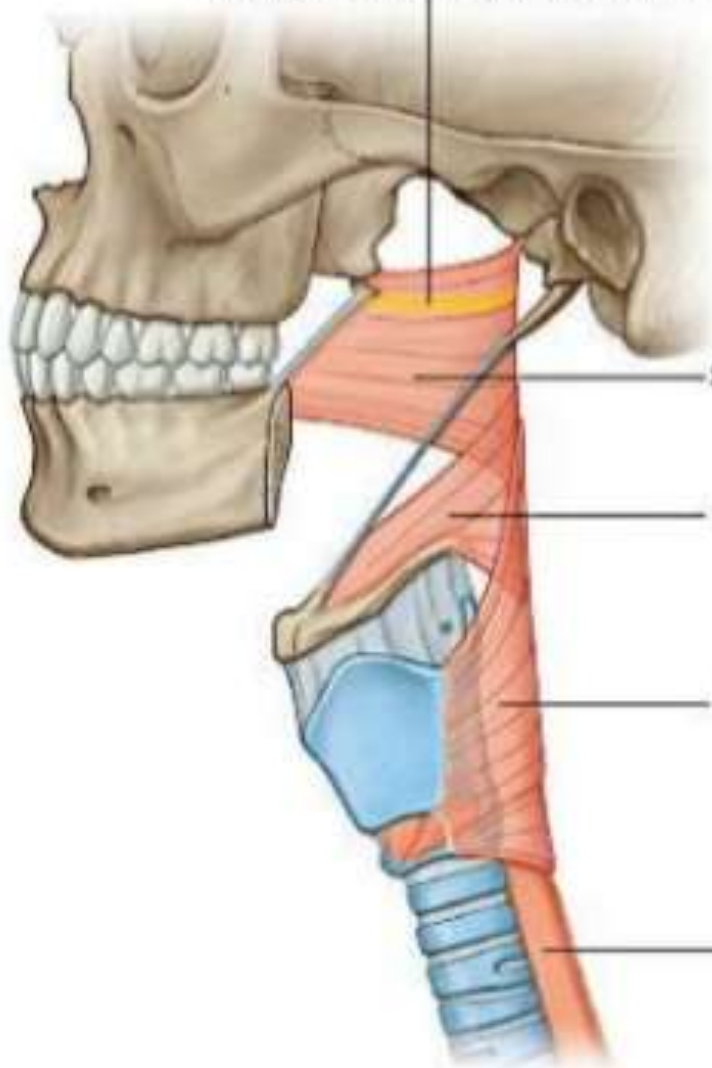
- Behind mouth and tongue.
- common to both respiratory and digestive systems
- Oropharyngeal isthmus
- Posterior wall is smooth
- Lateral walls shows **palatine tonsils** between palatoglossal and palatopharyngeal arches.





**A**

Position of palatopharyngeal sphincter  
on deep surface of superior constrictor

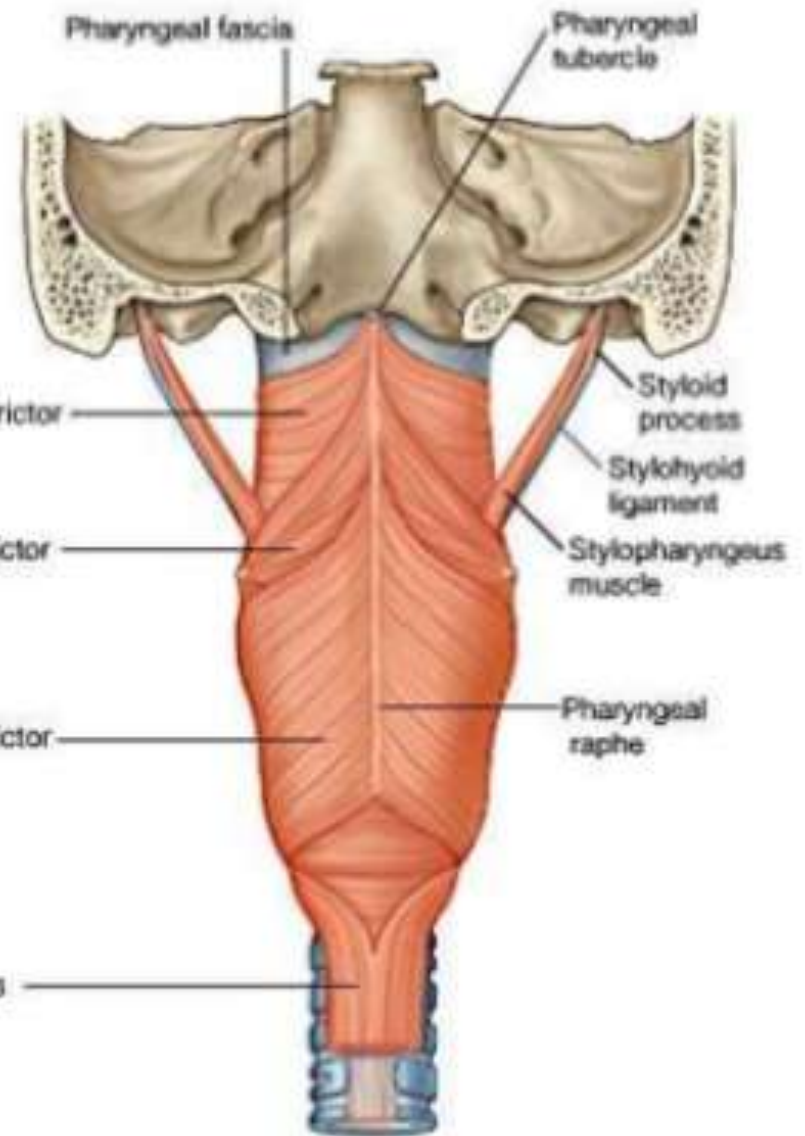


Superior constrictor

Middle constrictor

Inferior constrictor

Esophagus

**B**

Pharyngeal fascia

Pharyngeal  
tubercle

Styloid  
process

Stylohyoid  
ligament

Stylopharyngeus  
muscle

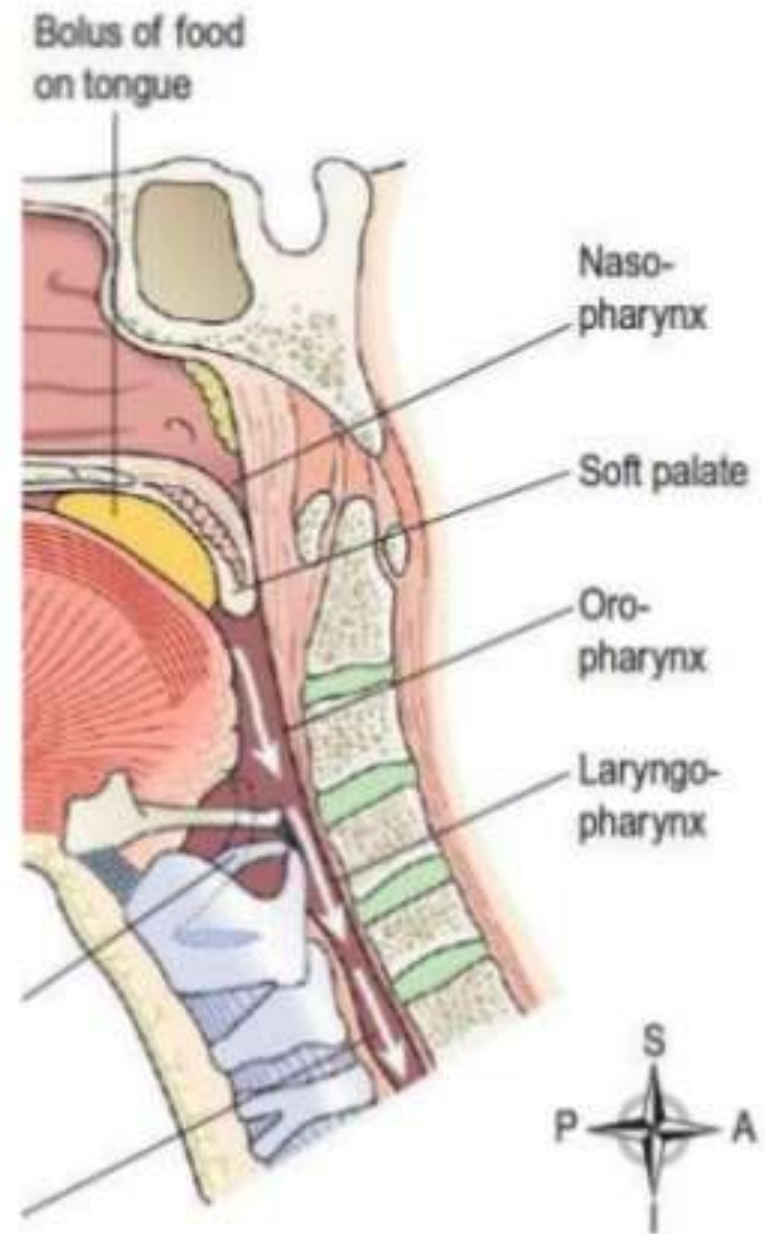
Pharyngeal  
raphe

### **3.Laryngopharynx**

- Lower part of pharynx.
- behind the Larynx.
- Upper border of epiglottis to lower border of Cricoid Cartilage

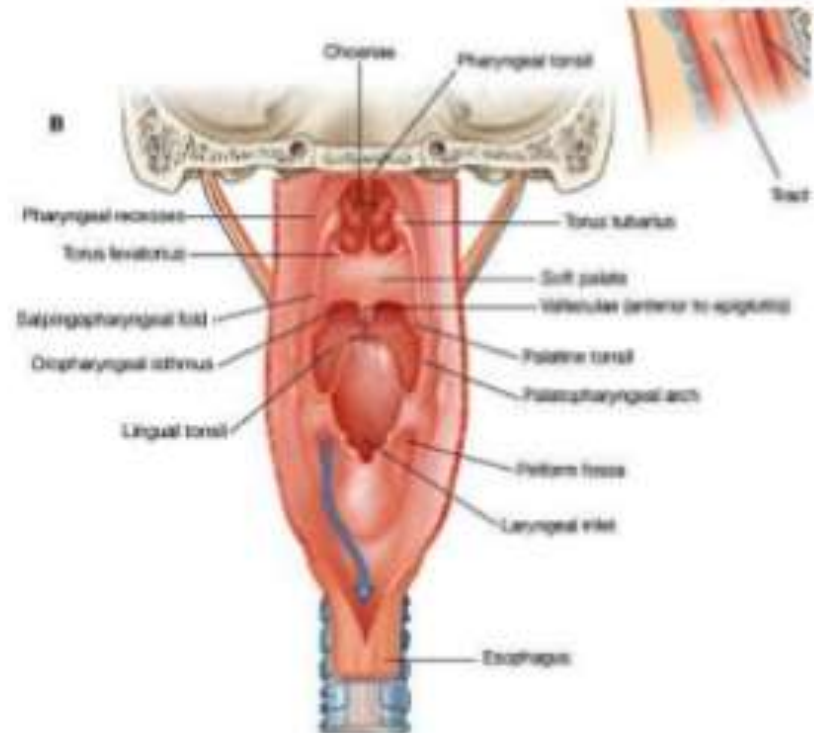
# LARYNGOPHARYNX

- Behind larynx
- upper part - common to digestive & respi tracts
- lower part continues with esophagus
- Anterior & posterior walls approximated except when food is passing

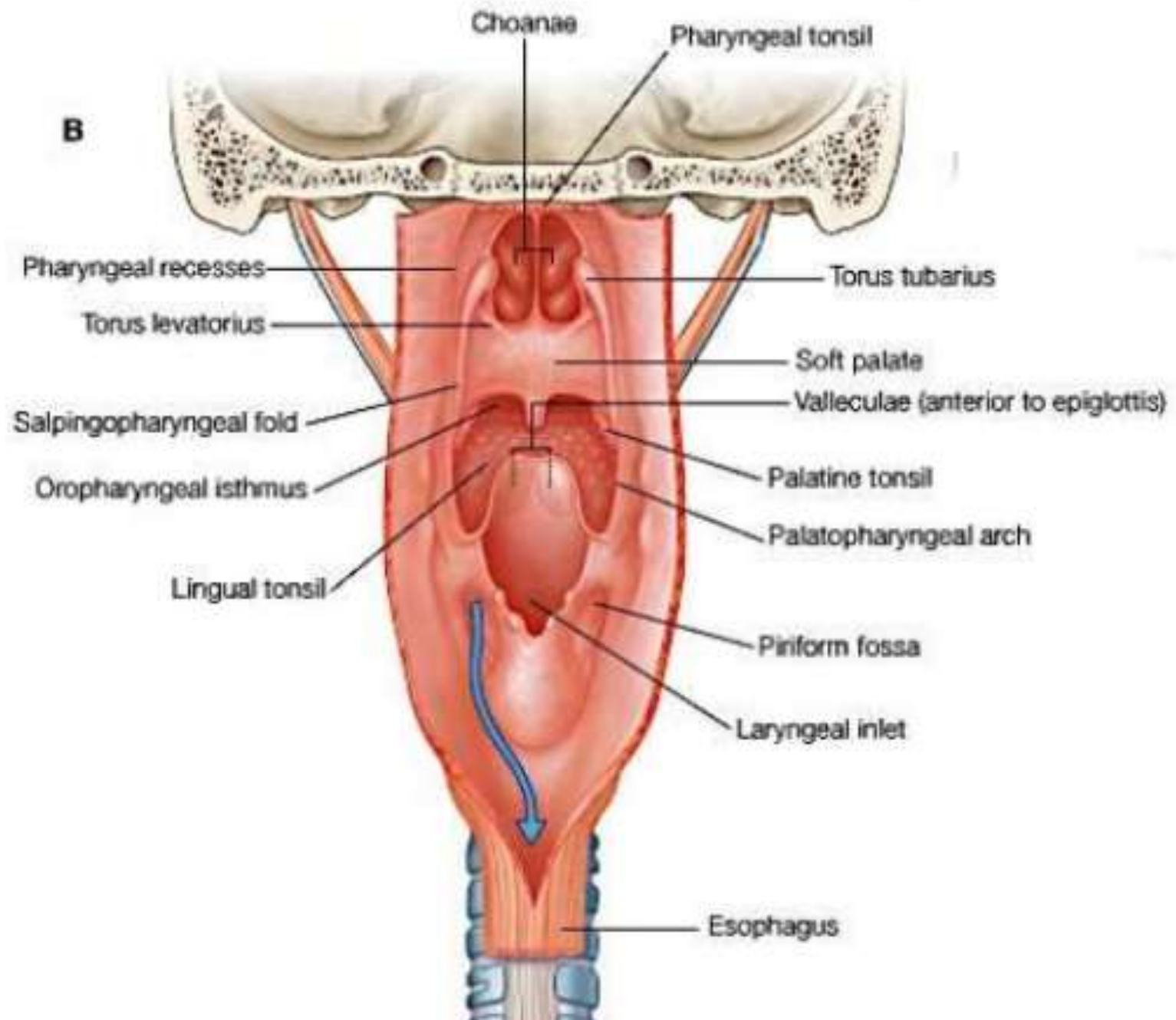


# LARYNGOPHARYNX

- Posterior wall and side - walls are smooth.
- Anterior wall from above downwards presents
  - epiglottis
  - aryepiglottic folds
  - Arytenoids & cricoid
  - inlet of larynx
  - piriform fossa
- Anterior wall - back of larynx.







# Functions of Pharynx

- Deglutition
- Respiration
- Vocal resonance
- Secretion of mucus by mucous membrane to lubricate the pharynx
- Provides drainage to nose, oral cavity, middle ear



# Functions of Nasopharynx

- Airway for passage of air into larynx, trachea and lungs
- Hearing – middle ear ventilation, maintains air pressure
- Resonance for voice production
- Drainage for nasal and nasopharyngeal secretions
- Prevents aspiration (Nasopharyngeal isthmus closes during, swallowing, vomiting, speech..)

# Functions of Oropharynx

- Common conduit for air and food
- Deglutition
- Vocal resonance
- Taste sensation (tongue base, soft palate, anterior pillar, posterior pharyngeal wall)
- Local defence and immunity (Waldeyer's ring)

# Functions of Laryngopharynx

- Common conduit for air and food
- Voice resonance
- Deglutition

# Palato (velo) pharyngeal mechanism

The velopharyngeal mechanism **is** a coordinated valve formed by the muscles of the soft palate and pharynx.


# Muscles forming the velo-pharyngeal sphincter

*Muscles forming the palate, these are:*

- Levator veli palatini muscle
- Tensor veli palatini muscle
- Palato glossus muscle
- Palato pharyngus muscle
- Uvula muscle, which is the intrinsic muscle of the velum

*Muscles forming the pharynx, these are:*

- Superior constrictor muscle
- Salpingo pharynges muscle
- Palato pharyngus muscle which has two portions, the pharyngo palatal portion and the thyro-palatal portion

- 
- The levator veli palatini muscle and the superior constrictor muscles play the dominant role in velopharyngeal mechanism especially during closure of the nasal cavity. The levator veli palatini muscle is a long muscle and provides a wide range of movement necessary in moving the velum from the relaxed rest position to a fully elevated position





**pharynx** shares in palato pharyngeal mechanism by:

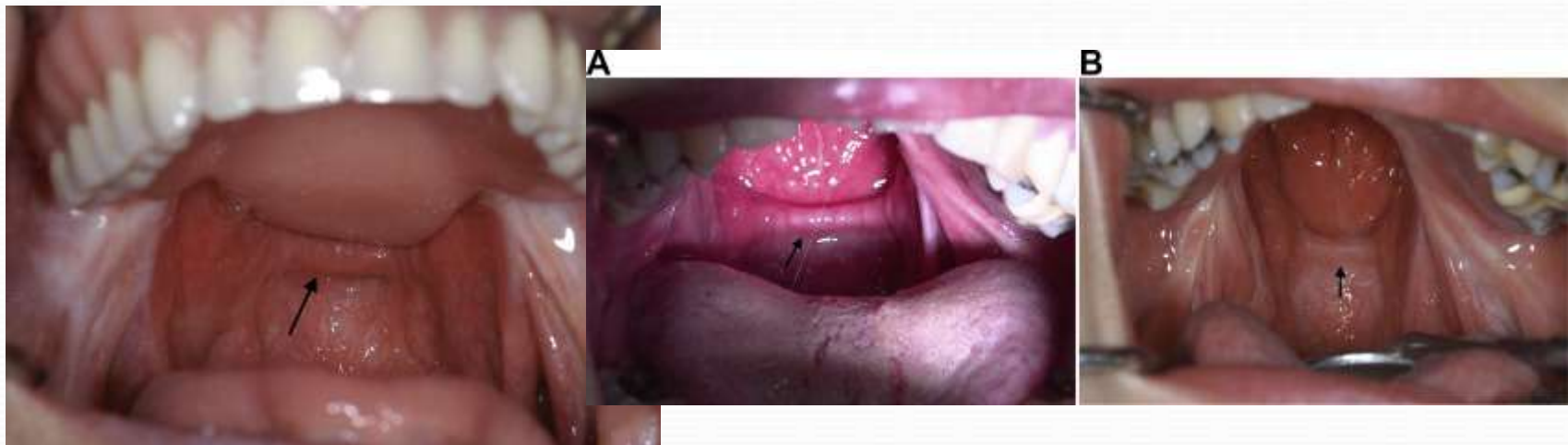
- \*Movement of the posterior wall of the pharynx forwards. This is done by the action of the superior constrictor muscle aided by the pharyngo palatal portion of the palato pharyngus muscle.

- \*Movement of the lateral walls of the pharynx medially to close the last gap between the lateral aspect of soft palate and lateral walls of pharynx. This is done by the action of the salpingo pharynges muscle.

- \*The posterior pharyngeal muscles contracts strongly and produces a bunch-up forming a prominent ridge or pad called “Ridge of Passavant”. This helps to approximate the soft palate and pharynx,

# Ridge of Passavant

The ridge of Passavant is a horizontal roll of muscles on the posterior wall of the pharynx forming a bunching-up of the posterior pharyngeal wall. It is present at the level of the palate which corresponds to the level of the atlas vertebra. It is usually more evident in patients with soft palate defects as a compensating mechanism to aid in speech and swallowing. It also serves as a guide for placement of soft palate prostheses

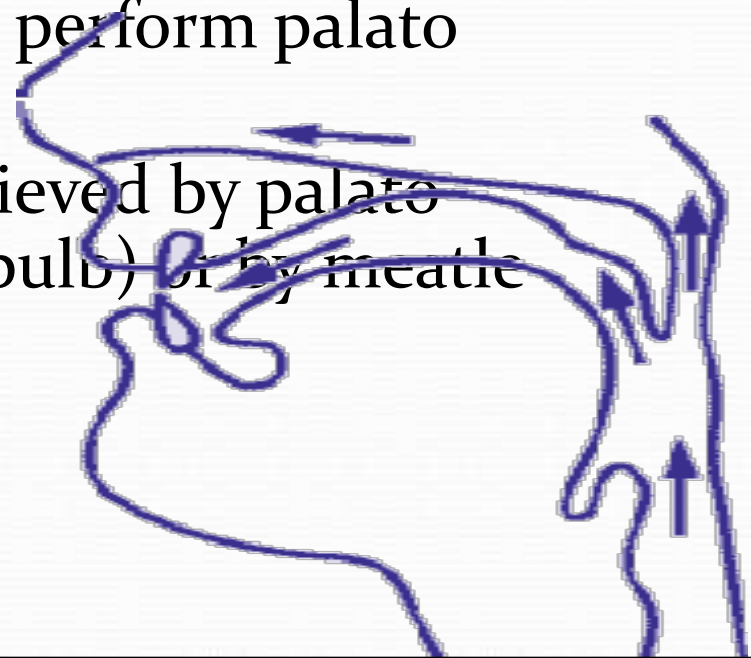


# Velopharyngeal insufficiency:

Palato pharyngeal insufficiency is a condition characterized by abnormal anatomy of the palate in the form of absence, short length or cleft in the tissues of the soft palate.

This could be congenital, or due to acquired causes as resection of soft palate or lateral pharyngeal wall. This condition results in inability to perform palato pharyngeal mechanism.

Prosthetic rehabilitation is achieved by palato pharyngeal obturator (speech bulb) or by meatal obturator.



# complications

- **feeding difficulties**

Feeding difficulties occur more with cleft palate abnormalities. The infant may be unable to suck properly because the roof of the mouth is not formed completely.

- **ear infections and hearing loss**

Ear infections are often due to a dysfunction of the tube that connects the middle ear and the throat. Recurrent infections can then lead to hearing loss.



Cont...

- **speech and language delay**

Due to the opening of the roof of the mouth and the lip, muscle function may be decreased, which can lead to a delay in speech or abnormal speech. (*hypernasal speech*) due to Velopharyngeal incompetence.

- **dental problems**

As a result of the abnormalities, teeth may not erupt normally and orthodontic treatment is usually required

# Cont...

## ■ Airway :

- Major respiratory obstruction is uncommon
- Hypoxic episodes during sleep and feeding are life threatening
- intermittent airway obstruction is more frequent and managed by nursing the baby prone





Thank you

# Cleft palate: treatment soft palate obturator prosthesis

{Hussein T. Abed  
{24\2\2021

1- Restoration of **masticatory apparatus**.

2- Restoration of **speech**.

3- Prevent foods from **enter the nose** and prevent nasal secretion from enter the mouth.

4- Improve the **esthetics** of the patient by restoring the missing part of ridge and teeth.

5- Improve **psychological** condition of the patient.

## Objectives of cleft palate prosthesis:

### *A-In unoperated cases:*

1. A wide cleft with a deficient soft palate that cannot function properly after surgery.
2. A wide bilateral hard palate cleft.
3. Partial or complete paralysis of the soft palate remnants
4. In patients with neuromuscular disease affecting the soft palate and pharynx resulting in velopharyngeal incompetence.

### **Indication of maxillofacial prosthesis:**

### *A-In unoperated cases:*

5. Absence of the premaxilla.
6. Patients with poor general health.
7. The cleft palate may be temporarily closed with speech aid, when surgery is delayed.
8. When orthodontic appliance (e.g. expansion appliance or appliance to correct teeth position) is indicated.

## **Indication of maxillofacial prosthesis:**

1. Failure of surgery to close the defect completely.
2. When the soft palate movement is inactive or completely absent or the soft palate is short causing incompetent palatopharyngeal closure.
3. A transitional prosthesis to provide certain function, e.g. feeding appliance or appliance to activate the soft tissues of the pharynx for function.

*B- In operated cases:*



1. Easability of surgical repair
2. Uncooperative patient and parents.
3. Uncontrolled dental caries as rampant caries.
4. Mentally retarded patient.
5. Lack of dentist who has had training in cleft palate prosthodontics.

## **Contra-indications for maxillofacial prosthesis**

# Prosthetic devices used in management of congenital cleft palate

An **obturator** is an appliance, which corrects openings in the hard palate, soft palate or both. The prosthetic treatment consists of the construction of an obturator or an artificial palate for closing the cleft and restoring the function of speech and swallowing.

# 1. Obturators

The orthopedic appliances are of two types:

a-The passive or holding type.

b- The active or expansion type.

## 2. Orthopedic treatment

- ⌘ The *palatal portion* composed of two separate lateral sections covering the hard palate and united by expansion device. In the pre-eruptal eruption period. The prosthesis covers the alveolar ridge and extends to the mucobuccal fold. When the teeth are erupted the prosthesis is extended to the lingual surface of the teeth and retained by wire clasps.
- ⌘ The *pharyngeal portion* may be constructed in some cases to improve the speech and deglutition

The expansion prosthesis consists of palatal portion and pharyngeal portion.

In case of malposed teeth an orthodontic appliance may be combined with a prosthesis to move malposed teeth into a more favorable alignment. A speech appliance prosthesis could be designed for patient receiving full band orthodontic treatment.

### **3. Combined prosthesis and orthodontic appliance**



1. Preoperative devices for children:
  1. Feeding devices
  2. Expansion prosthesis.
2. Cleft palate prosthesis for adolescent: Fixed pharyngeal obturator.
3. Cleft palate prosthesis for adult (definitive obturator)

## **Obturators used for treatment of congenital cleft palate**

## The importance of feeding appliances:

Most infants with cleft lip and palate are unable to nurse from the breast or bottle. Since normal feeding is impossible, a more upright position of the baby, and a bottle with large hole nipple may compensate for the slow flow of milk or fluid associated with defective feeding. Sometimes Nasogastric tube is used for feeding.

The repeated pressure of the tongue on the nipple forces it upwards against the edges of the cleft and tends to increase the width of the cleft.

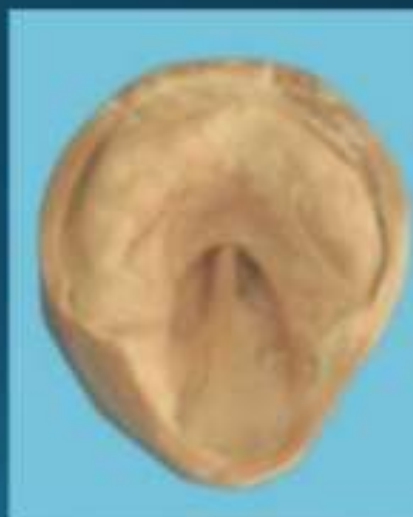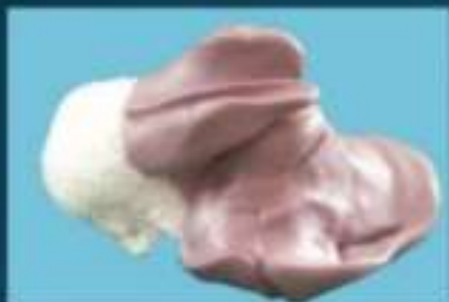## **Prosthetic rehabilitation of congenital cleft palate (in children)**

### **Feeding device**<sub>s</sub>:

All these difficult conditions make the construction of the feeding device essential **to separate the oral cavity** from the nasal cavity and thus , **facilitate** food intake and **reduce irritation** prior to surgical closure.

- ⌘ The feeding devices consists of an acrylic plate, constructed from a low fusing compound impression.
- ⌘ A mass of **softened compound** is placed on suitable tray or on the convex surface of the spatula and mould it to the shape of block of the needed size. Then compound is inserted into the baby' s mouth to the back of the pharynx and with light upward and forward movement, so that the edges of the cleft leaves their marks on the block.
- ⌘ The compound impression is taken out by moving the spatula from the front to back and then downward and forward. The impression is poured in stone and allowed to set before separation. A plate of softened wax is adapted on the lingopalatine surface of the model formed the palatine wings of the obturator. The wax is replaced by acrylic resin using the routine method of flasking, then finishing and polishing are done.

## *Construction:*





The expansion prosthesis may be constructed with pharyngeal portion to improve the speech and deglutition.

## *2. Expansion prosthesis*



## 1-Fixed pharyngeal obturator (speech aid)

The fixed pharyngeal obturator is an extension of a denture projecting into the pharynx to the level of the anterior arch of the atlas bone or Passavant's ridge.

They are temporary appliances usually constructed for adolescents (between 11-20 years) till they reach complete growth.

Normal lateral growth of the palatal bones necessitates replacement of this prosthesis occasionally. Intermittent revisions of the obturator section can assist in maintenance of palatopharyngeal closure.

Appliances for habilitation of congenital cleft palate (for adolescents):

1. Socially acceptable speech.
2. Restoration of masticating apparatus.
3. Prevent the seepage of nasal secretion into the oral cavity.
- 4-Facial esthetics and dental harmony.
- 5-Improve psychological condition of the patient.

*Objectives:*

1. The prosthesis must be designed to suit the patient regarding his oral and facial condition, masticatory function, and speech.
2. The prosthesis must preserve the remaining structures
3. The prosthesis requires greater retention and support..
4. Closed vertical dimension in more suitable in the cleft palate patients.
5. Minimum weight should be kept. The material used should be easily repaired and altered.
6. Soft tissue pressure in the velar and naso–pharyngeal areas by the appliance must be avoided.
7. The prosthesis must not be displaced by velum, lateral and posterior pharyngeal wall muscle activities or tongue movement during swallowing and speech production.
8. Pharyngeal section should be properly placed. The superior surface of the pharyngeal section must be at the level of the palatal plane.

## **Fixed pharyngeal obturator requirements:**

The speech aid consists of three sections; palatomaxillary section, palatovelar section and pharyngeal section.

a-The **palatomaxillary section**:It covers the cleft of the hard palate, and may be constructed in the form of partial or complete denture.

B- The **palatovelar section** or tailpiece: It supplements the palatal cleft and must remain in lateral contact with the soft palatal muscles during function or rest.

c. The **pharyngeal section** (speech bulb): It extends posteriorly into the pharyngeal cavity to be surrounded by the sphincteric action of the pharyngeal muscles during swallowing and speech.

## Sections of speech aid





### *1. Preliminary impression:*

Prior to taking the impression the undercuts in the palatal cleft is packed with vaseline gauze. An alginate impression is taken in a suitable stock tray and cast is poured.

### *2. Final impression:*

An acrylic special tray is constructed and the final impression is taken with rubber base or alginate impression material. The deep undercuts in the hard palatal cleft should be packed with vaseline gauze prior to taking impression.

## **Construction:**

- ⌘ If the patient is edentulous the upper denture should have an upward extension that engages undercuts in the cleft to help retention.
- ⌘ If the patient is dentulous the working model is surveyed and the cleft in the hard palate filled in with plaster of paris to reproduce the contour of a normal palate. On this prepared model a record block is constructed. Jaw relation is recorded in the usual manner and the casts are articulated.

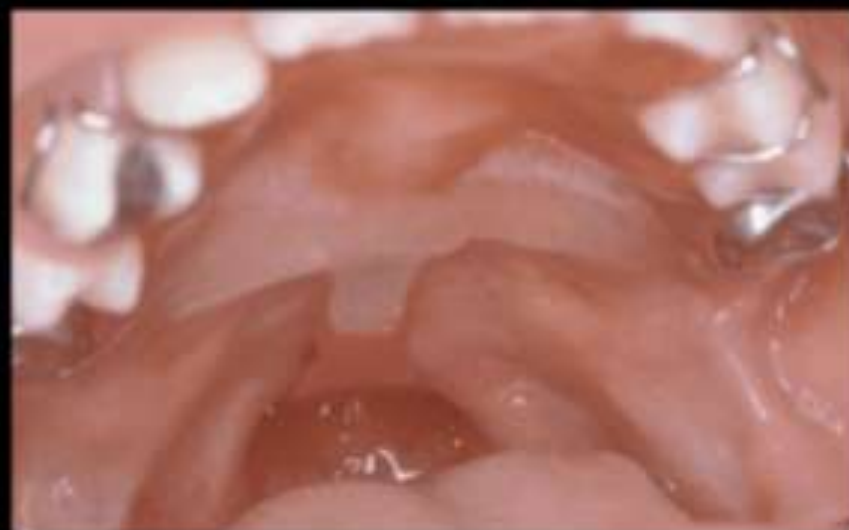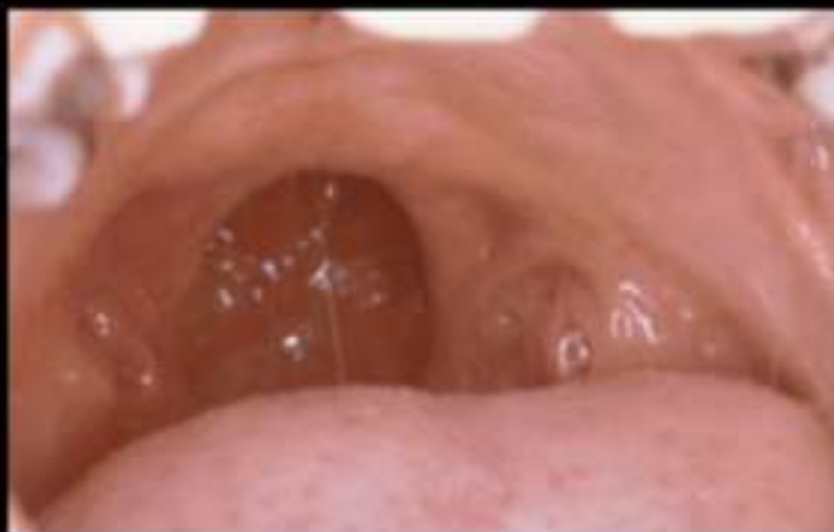### *3. Recording jaw relation:*



- ⌘ The artificial teeth are set in positions demanded by appearance and occlusion.
- ⌘ At the try-in the usual points are checked and a wire loop made of German silver or stainless steel is bent and attached with sticky wax to the base of the trial denture. This loop should be adjusted by bending and altering its position in the wax until it lie along the center of the cleft of the soft palate, without contact with its remnants or with the posterior pharyngeal wall when a prolonged “ah” is sounded.

# Interim Speech Aids

Soft palate obturators are fabricated in the usual fashion  
(see “Restoration of Soft Palate Defects” FFOFR.org)



- ❖ Fabricate palatal stent with adequate retention.
- ❖ Gradually develop the pharyngeal extension.
- ❖ When the child has accommodated to the pharyngeal extension, develop the obturator portion.

⌘ In some cases where difficulty to the wearing of the denture is anticipated it is desirable to leave the wire loop off the denture and allowing the patient to wear the denture for few weeks until it is quite comfortable. The wire loop may then be added to the denture with cold cure resin to avoid the induce of extra strains in the acrylic by a second processing





⌘ After the denture has been completed and fitted, a tailpiece must be made and attached to the back edge of the denture and positioned at a level just below the soft palate when assumes fully relaxation. If the tailpiece is positioned at higher level, discomfort and pressure sores will occure when the soft palate relaxes. If on the other hand the level of the tailpiece is much below that assumed by the relaxed soft palate, then it will cause discomfort by obstructing the movements of the tongue.

⌘ A piece of soft modeling compound is added on the wire loop that attached to the end of the velar section. The denture with the soft compound is inserted into the mouth and the patient is requested to swallow, say “ah” move his head up and down and then from side to side while the compound is still soft. A drink of warm water or hot tea will facilitate swallowing. The denture is removed, cleaned, dried and the compound is inspected and reheated then reinserted in the mouth and the patient is asked to do the same previously described movements using stick compound to correct the impression section by section .

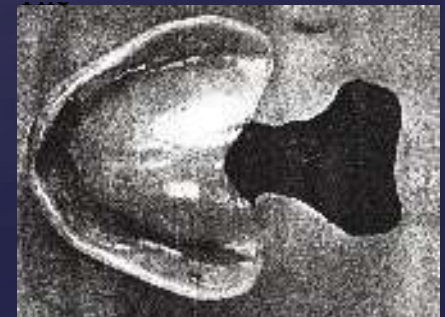## *Construction of speech bulb*

⌘ Impression wax softened in water bath maintained at 51 - 64 C painted over the green compound with a brush. The denture carrying the compound and wax is inserted to the patient's mouth and the same previously described movements are performed. The prosthesis is removed and reinserted several times with gradual adjustment to the speech bulb until a satisfactory functional impression is made. The impression wax has the advantage that it can stay soft in the mouth for relatively long period for better registration of the functional movement



⌘ The size of the bulb should be adjusted until the patient can breath clearly through the nose and produce acceptable nasal sounds. If the patient is sensitive enough to produce a gag reflex, the speech bulb should be made underextended using self curing resin, allowing the patient to wear the denture for few weeks until he is accustomed to the underextended bulb, then the final impression of the speech bulb is taken.

- ⌘ The black gutta-percha can also be used to make impression for the speech bulb. This material can be fully adjusted to fit the movements of the pharynx and palatal remnants before being processed in acrylic resin.
- ⌘ The black gutta-percha has the advantage of remaining soft enough to be moulded by the pharyngeal musculature for about 5 minutes after each heating, while at the same time remaining sufficiently viscous to support its own weight. It is therefore deformed by muscular pressure and then retains the shape impressed on it by that pressure. The final details should be register by zinc oxide paste.



- ⌘ A special large flask is used for curing the tailpiece into clear acrylic resin.
- ⌘ If the speech bulb is not too large and the denture is well retained, the speech bulb can be made of solid acrylic. If however, the speech bulb is large ,or if the denture is poorly retained due to there being only a few nature teeth present in the upper jaw or if it is a full upper denture, then the speech bulb should be made hollow to reduce the weight of the appliance.

- ⌘ when the palate is cleft a **problem of how a fixed obturator** which can fit the cleft in both the functions of speaking and swallowing will developed.
- ⌘ The solution of this problem may include the following. In relation to the function of an obturator it is suggested that the patient must learn new speech habits.

- ⌘ The gripping of the bulb during swallowing is a basic principle which must be mastered
- ⌘ The action in producing the palatal consonants is horizontal instead of vertical and involves the gripping of the pulb as in swallowing.
- ⌘ The plane of location of the obturator must be in the plane of action of the palatopharyngeal sphincter or bulge of passavant so the individual can gripping it with his ring or sphincter mechanism and squeezing the remnants of the soft palate against it.



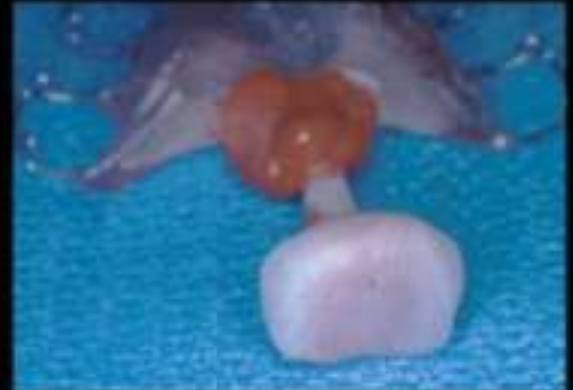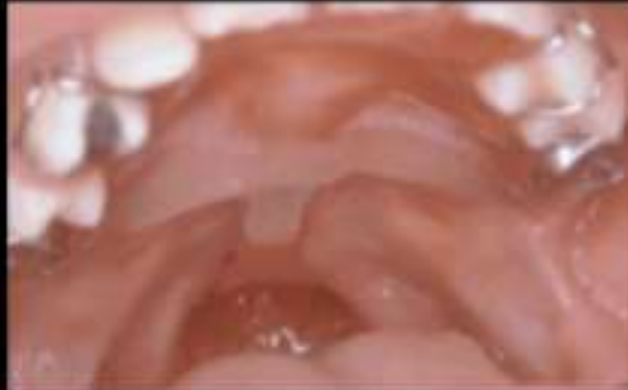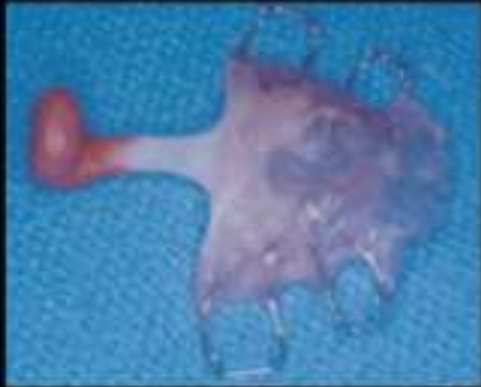
⌘ In practice an obturator is shaped by luting a piece of softened gutta-percha to a wire loop or tail piece extending from the posterior border of the denture along the midline of the cleft into the pharynx. The gutta-percha is then shaped by the muscles as they function.



# Part 2

# Interim Speech Aids

The bulb is molded with compound and thermoplastic wax.

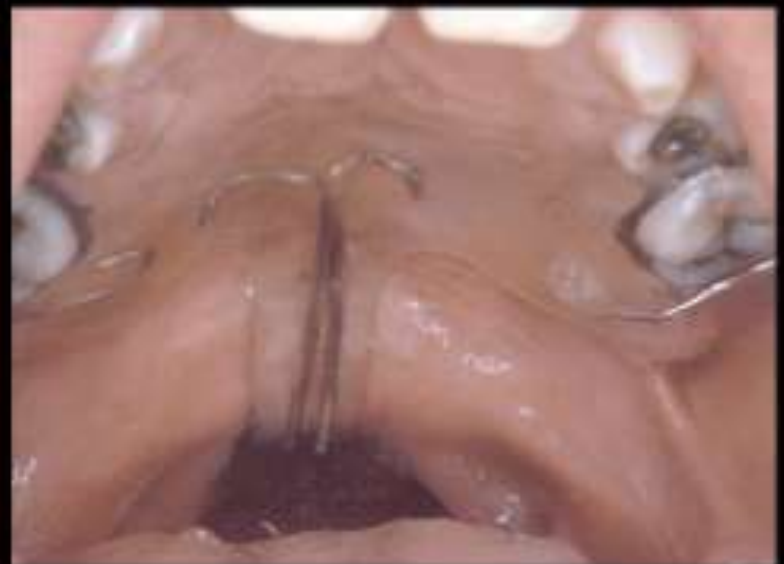
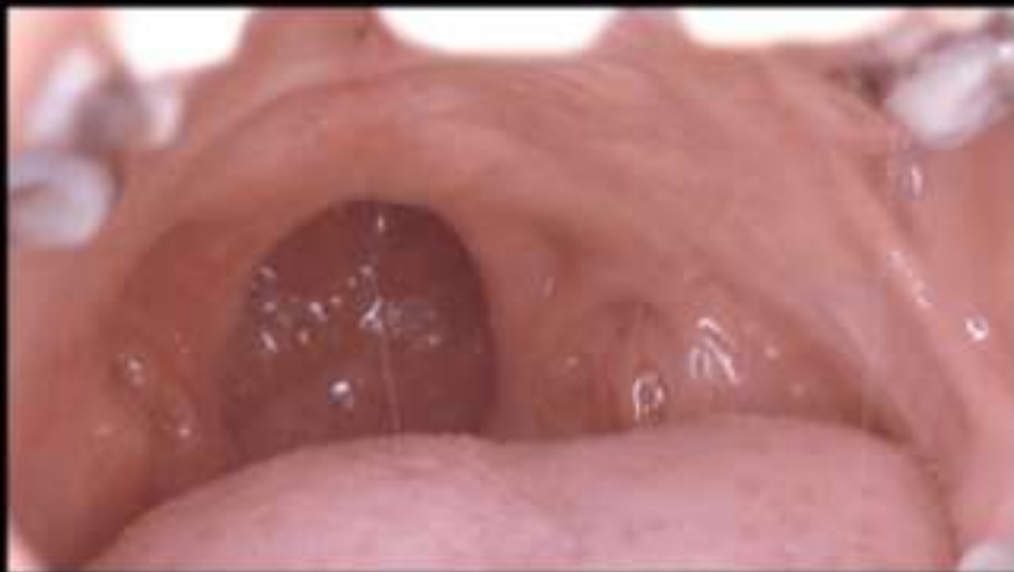
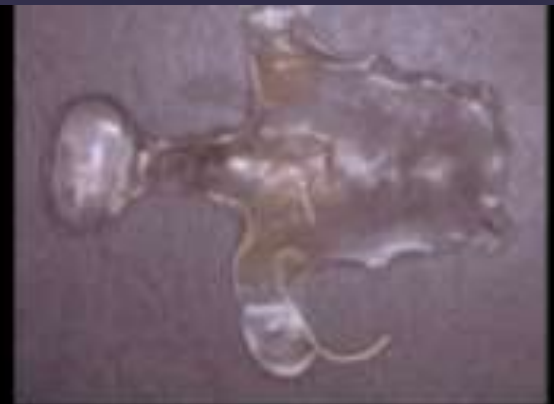- ❖ The extensions of the prosthesis are developed with dental compound and a thermoplastic wax
- ❖ Following processing the contours and extensions are verified with pressure indicating paste and/or



# Interim Speech Aids

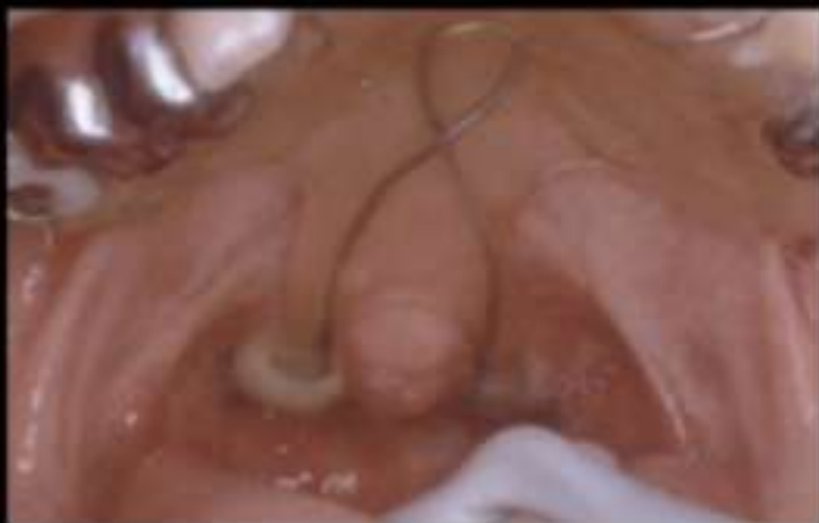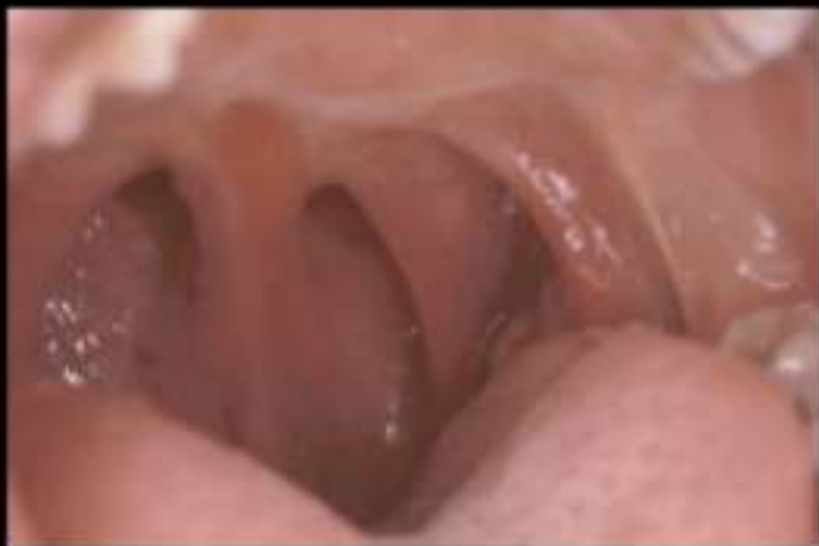A completed speech bulb



Obturator prostheses restore velopharyngeal function very effectively and are well tolerated by the patient. They need to be remade periodically to account for growth and eruption of the permanent dentition.



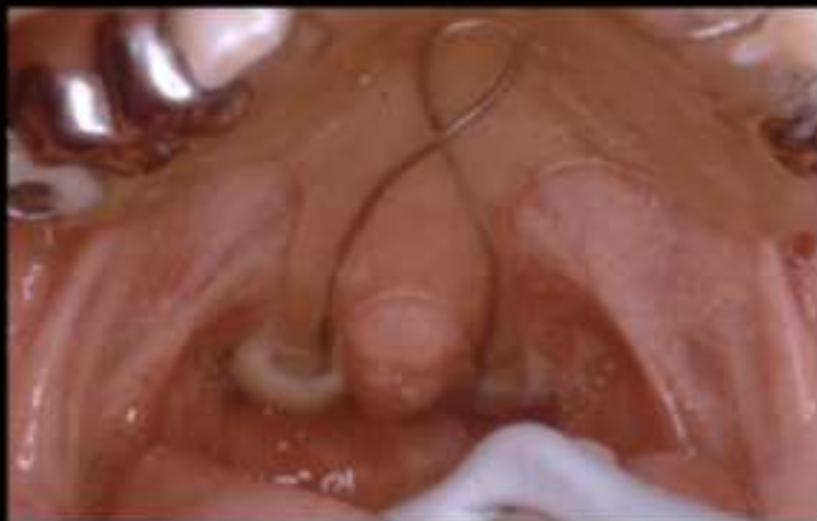# Obturator prosthesis for failed pharyngeal flaps



Obturator for failed pharyngeal flaps are rarely successful because it is difficult to extend the prosthesis superiorly to engage the movable lateral pharyngeal walls.

## Obturator prosthesis for failed pharyngeal flaps

In this patient, the bulb resulted in constant contact with non-mobile pharyngeal tissues, resulting in hyponasal speech. The bulb was discarded and the flap removed.

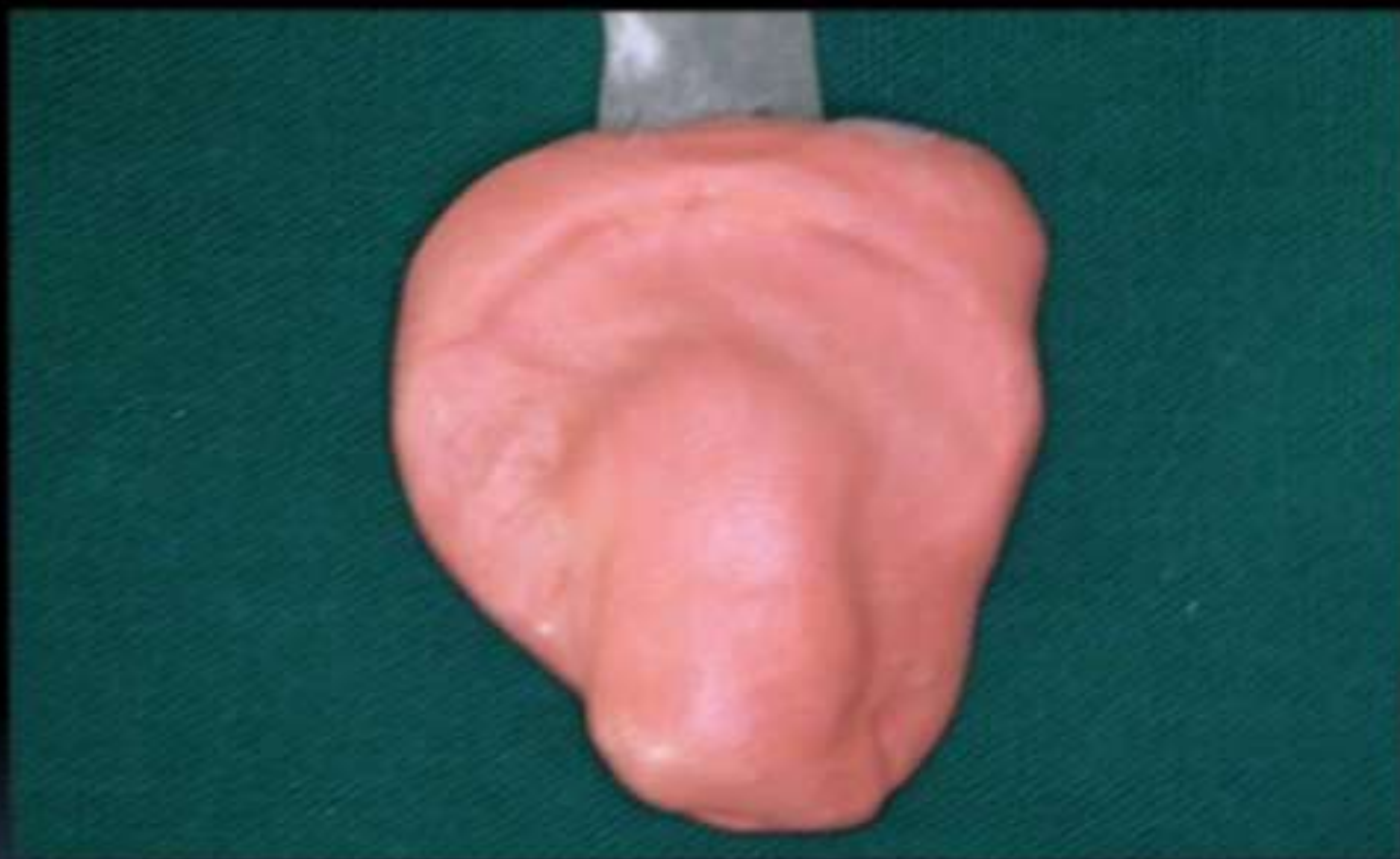

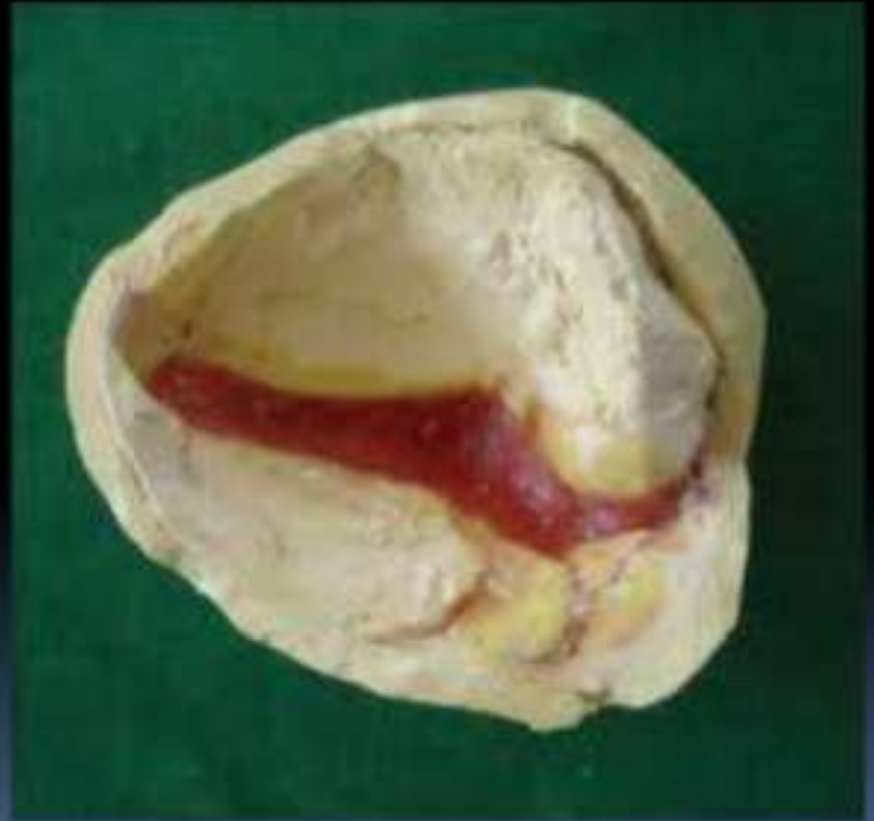Velopharyngeal function and normal speech was eventually restored with a new obturator prosthesis after the flap had been removed.

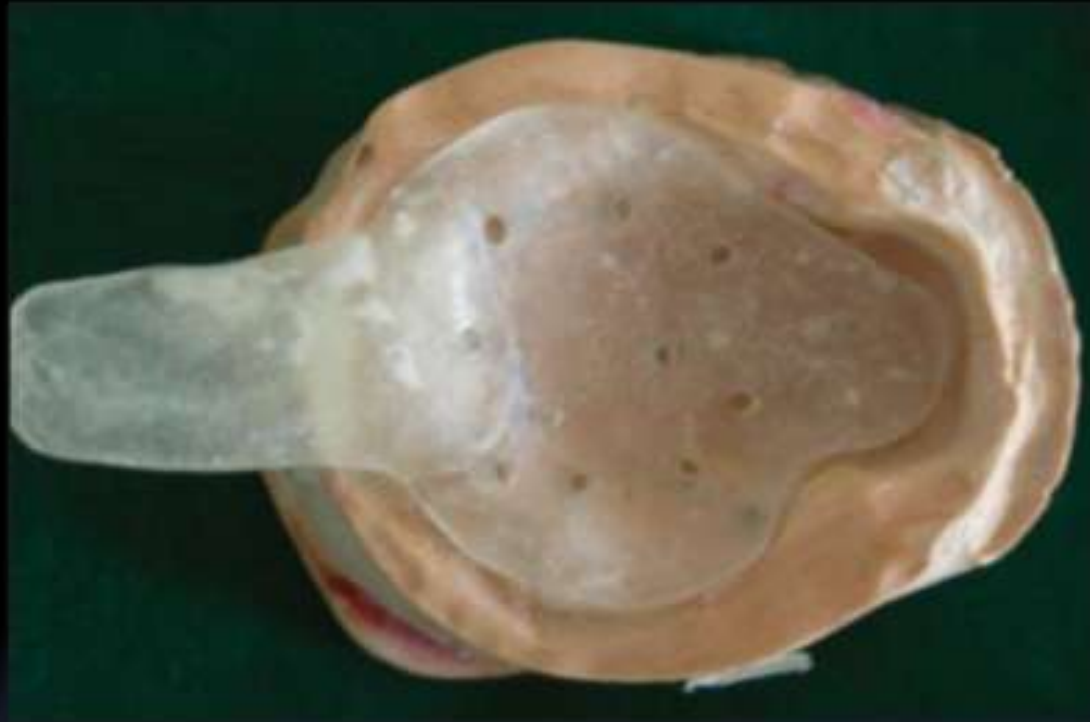# IMPRESSION MAKING Procedure

- Upper and lower perforated stock trays were selected. Upper tray was modified with wax extension into the defect to record the defect.
- Then upper and lower preliminary impressions were made with irreversible hydrocolloid. The upper impression also records the defect.
- Impressions were poured with dental stone to make diagnostic casts.







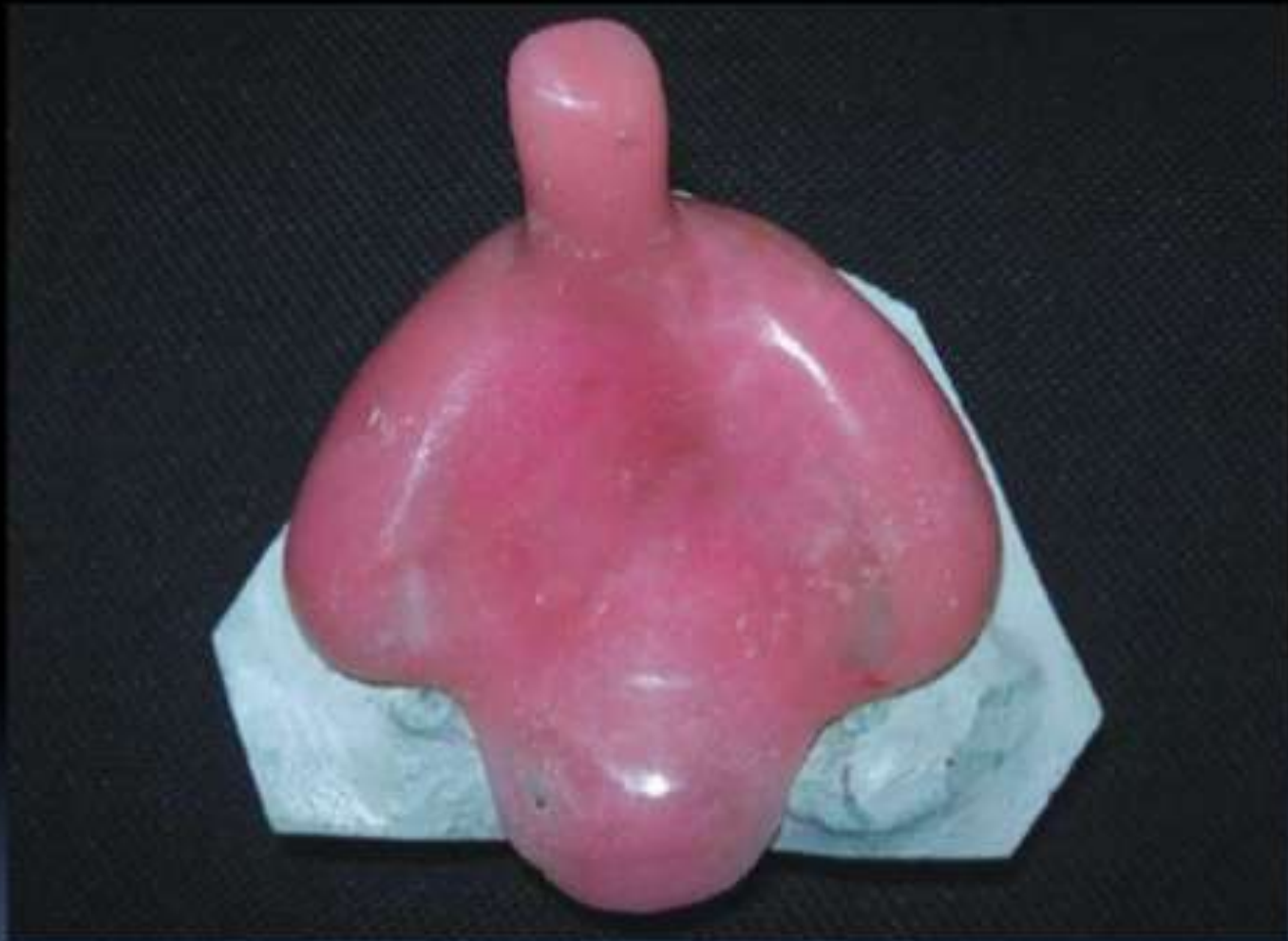

- Lower special tray is fabricated in conventional manner using autopolymerising acrylic resin.

But during the fabrication of upper tray following factors were kept in mind.

- There should be a 5 mm gap between the bulb and posterior pharyngeal wall.
- Angle of the bulb should be approximately  $20^{\circ}$  relative to the palatal plane.
- Keeping in mind all these criteria upper special tray was fabricated with autopolymerising acrylic resin having pharyngeal extension.

Impression of the defect area was made with modeling plastic wax.

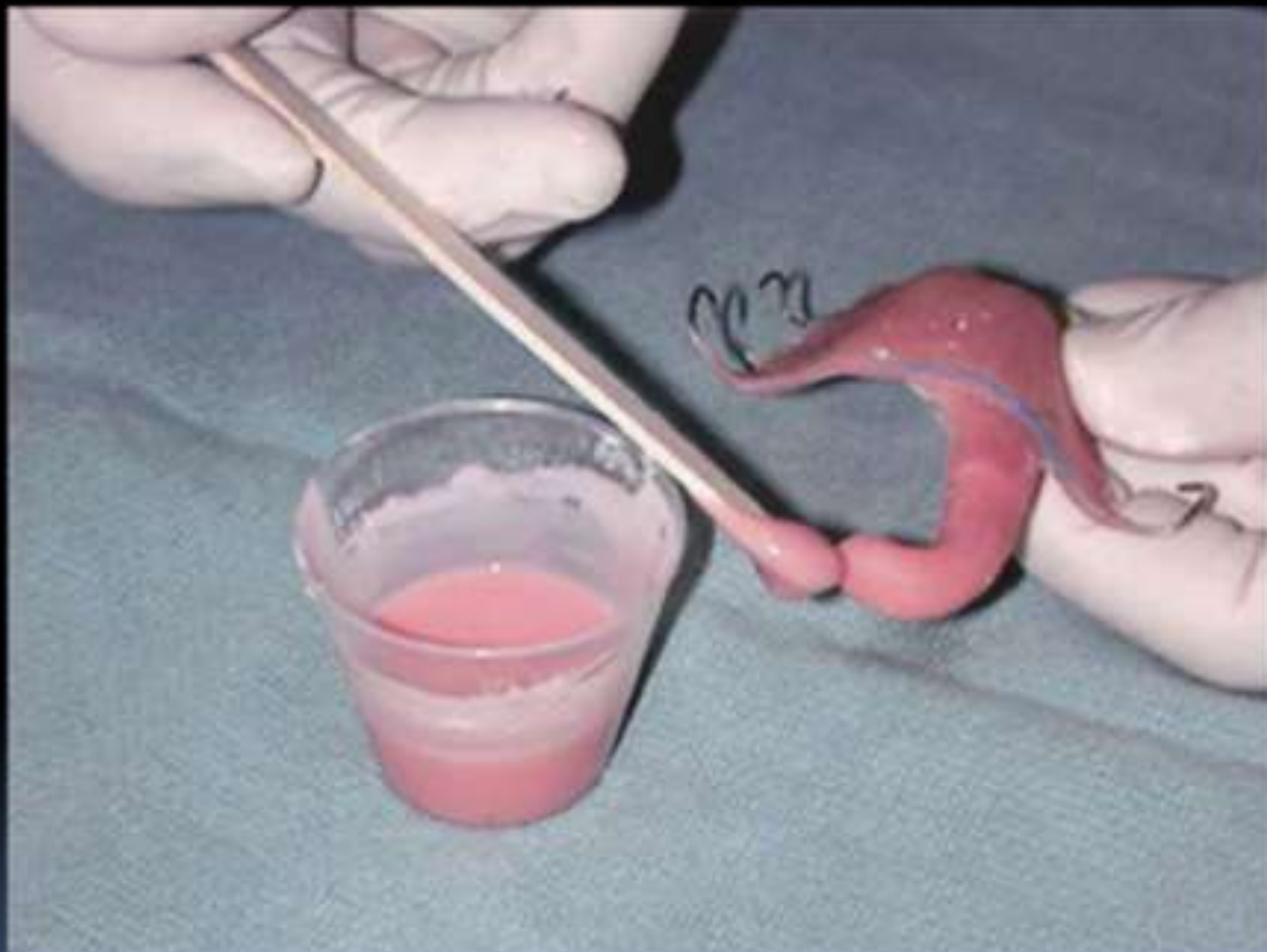



- Border molding was accomplished by recording all the functional movements of the soft palate, i.e., by asking the patient to tilt her head side-to-side and front-back when sitting upright.
- the patient is instructed to flex the neck fully to achieve contact of the chin to the chest. This movement will establish contact of the middle third of the soft palate with the soft tissue covering the dorsal tubercle of the atlas.
- Lateral aspects of the lift are formed by rotation and flexion of the neck to achieve chin contact with the right and left shoulder respectively.

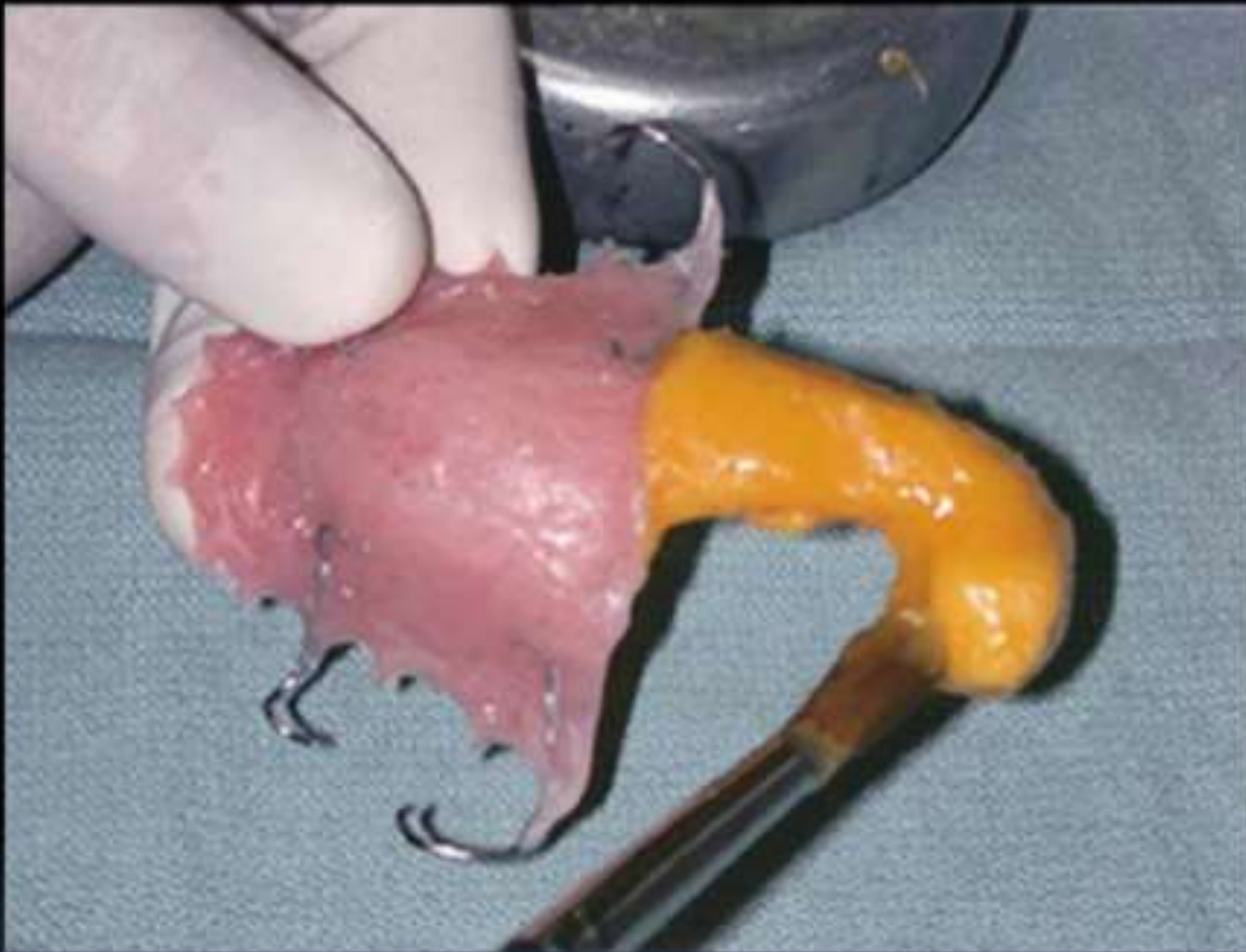


- Check indentation made by the ant. And posterior tonsillar pillars, the tori tubari, Passavant's pad, and the anterior tubercle of the atlas.
- Shiny area will indicate the lack of tissue contact.
- Activated pharyngeal musculature will displace the excess modeling plastic superiorly and inferiorly and these excesses should be trimmed.



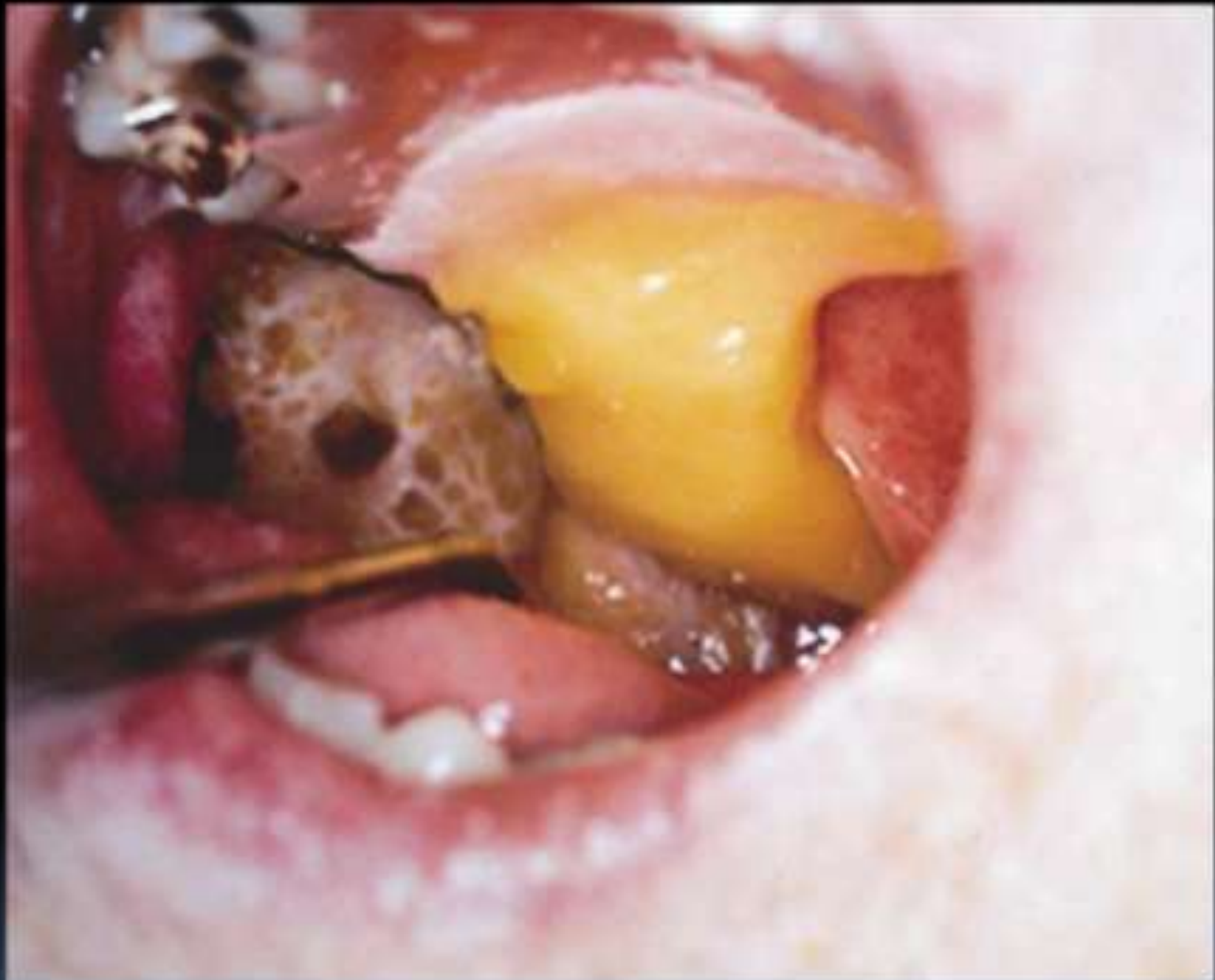- If the position and contours of the obturators are satisfactory , reduced all extension approximately by 1mm.
- Add thermoplastic wax because this will ensure the overextension of obturator.
- Contour modification are done if required.

- Oral surface should be concave to provide space for tongue.
- Superior surface should be convex and well polished to facilitate the deflection of nasal secretion into oropharynx.
- Area of excessive pressure are relieved using pressure indicating paste on lateral and posterior wall.

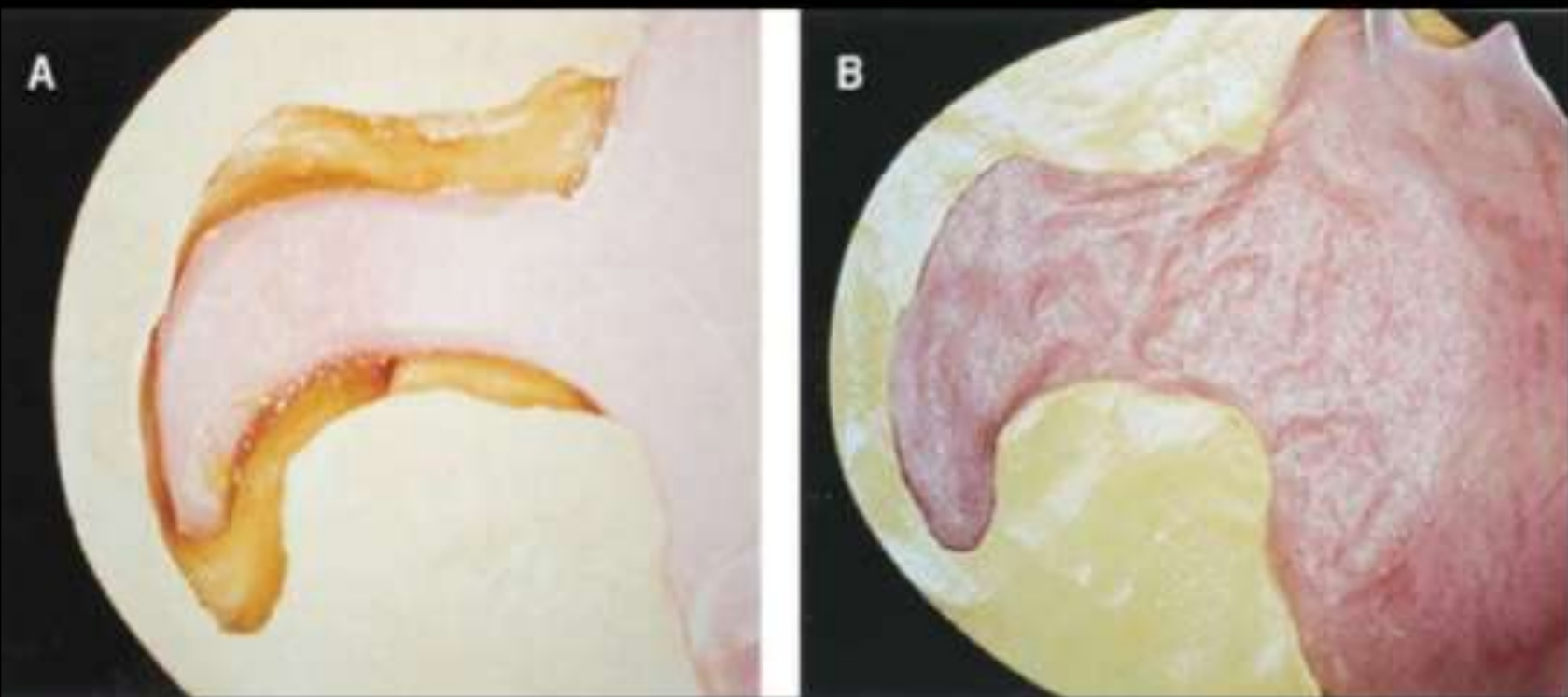


Placement of thermoplastic corrective wax onto oropharyngeal extension.









A. Thermoplastic corrective wax removed from base.

B, Autopolymerizing resin added to space provided by thermoplastic corrective wax.

If hyponasal voice is still evident ..then postero-lateral dimensions of the obturator is reduced judiciously.

## *Size and position of obturator....factors to be consider*

- 1.The closure of soft palate against the posterior pharyngeal wall extends approximately 5-7mm in vertical height with closure at o above the level of the palatal plane.
- 2.At pharyngeal wall activity ( middle position of obturator) the speech is is best for patients.

- Lower Border molding was done in conventional manner.
- Boxing was done and impressions were poured with die stone to fabricate master casts.

# Procedure for edentulous patient

- Autopolymerising acrylic resin record bases were made. In case of upper record base did not include the pharyngeal extension.
- Jaw relations and try in was done in accordance with for conventional complete denture fabrication procedures.
- After try in was over, all the undercuts of the defect area were blocked with wax.
- Flasking and dewaxing was done. Then dentures were processed with heat cure acrylic resin.
- Lid for the bulb was processed separately with heat curing acrylic resin and was attached to the completed denture with autopolymerising acrylic resin.



- Patient found drastic improvement in speech and nasal regurgitation was reduced. Patient was advised to continue her referral to speech therapist.
- . Once surgical care and speech therapy have been completed, the need for follow-up care is needed unless specific problems manifest. Preventive care is imperative if long-term preservation of the supporting structures is desired.



This obturator aids in closing the remaining fistula and is used when no further surgical procedures are planned.

It must be frequently revised.

# Limitations of Prosthetic Devices

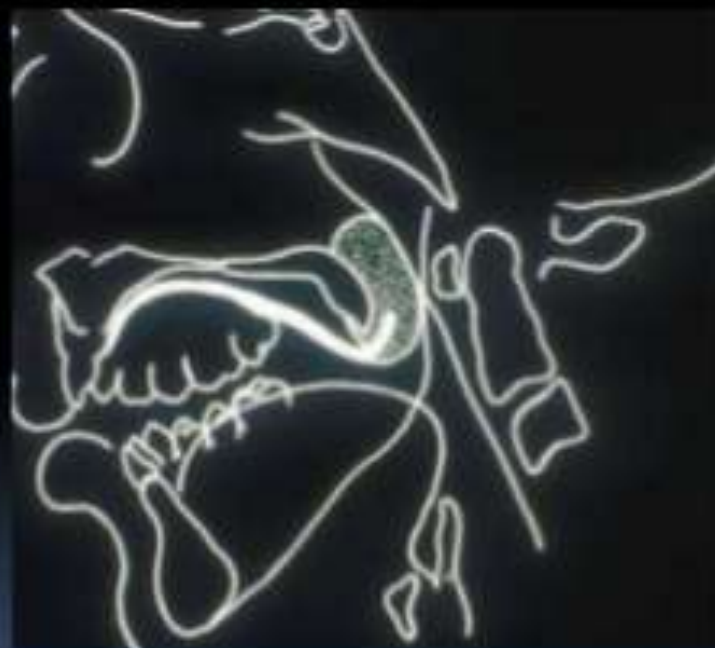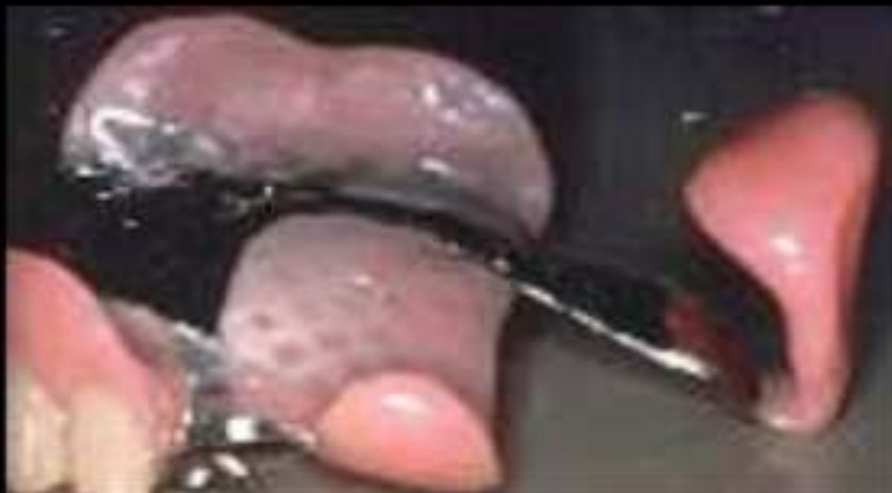- Require insertion and removal
  - Have to redo periodically due to growth
  - Can be lost or damaged
  - May be very uncomfortable
  - Compliance is often poor
  - Don't permanently correct the problem
  - Many centers use only if surgery is not possible

# ***Speech Bulb***



# Speech Bulb

- Occludes nasopharynx when the velum is short (velopharyngeal insufficiency)
- Aids in velopharyngeal closure
- Contains pharyngeal section, goes behind soft palate
- Can be combined with an obturator



Thank you

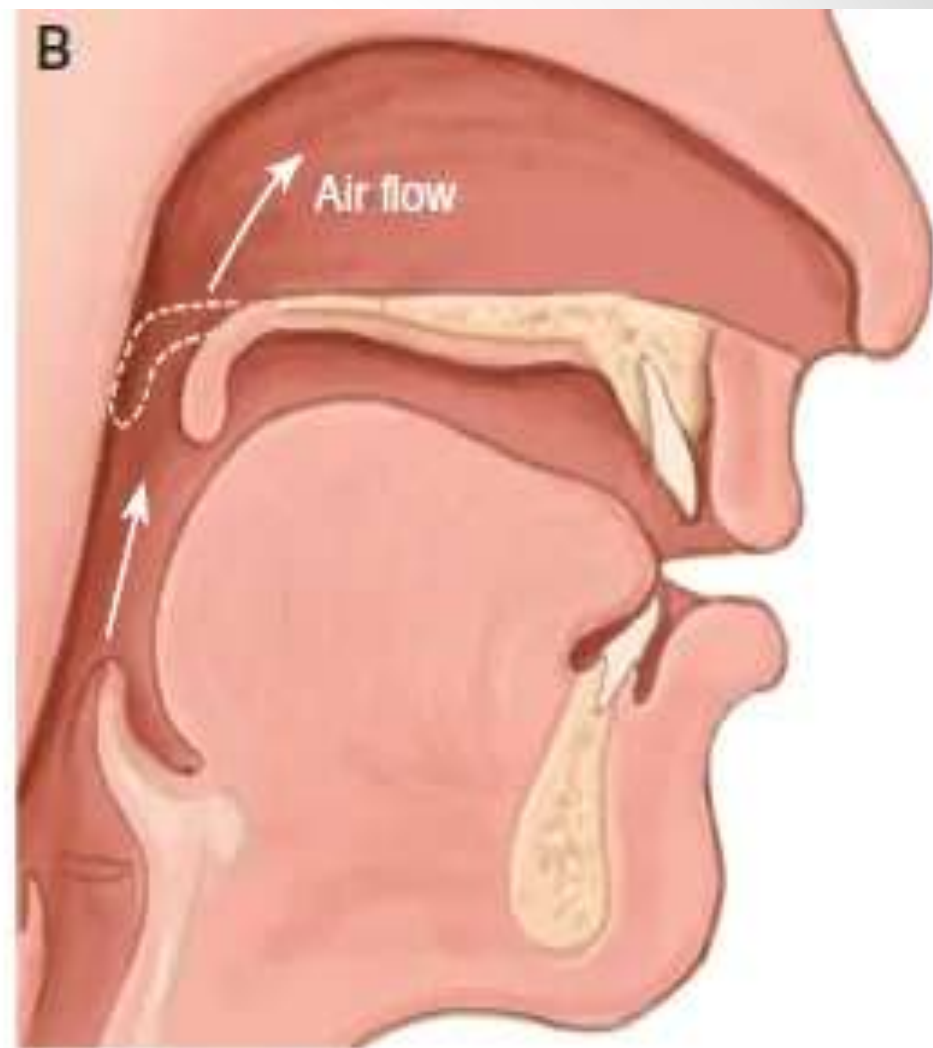
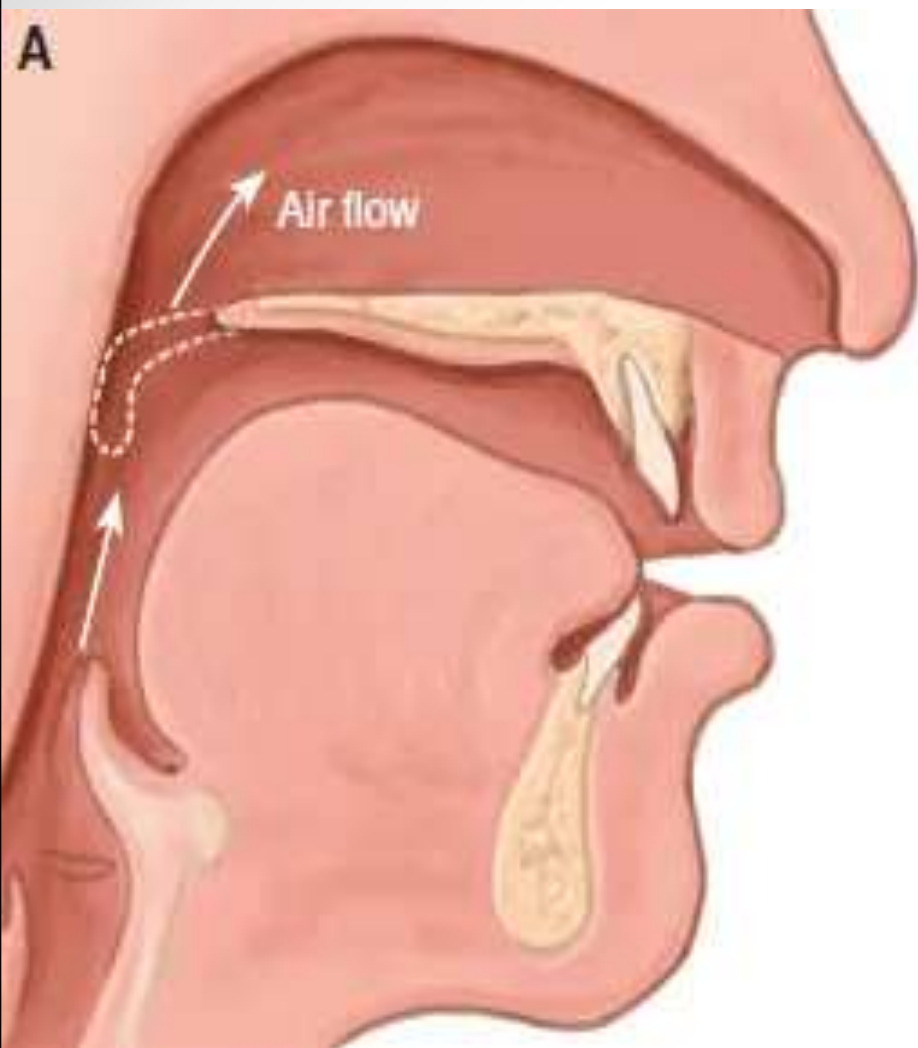

# Palatal lift prosthesis

Hussein T. Abed3\3\2021

# The Palatal Lift Prosthesis

- This type of prosthesis is designed to displace the soft palate superiorly and posteriorly to assist the soft palate to close with the peripheral pharyngeal tissues.



# *Indications*

- a-Neurologic diseases as myasthenia gravis, cerebrovascular accidents, traumatic brain injuries, and bulbar poliomyelitis.
- B-Injuries to the soft palate as following adenoidectomy, tonsillectomy, or maxillary resections.
- C-Postsurgical cleft palate with insufficient length and movement.

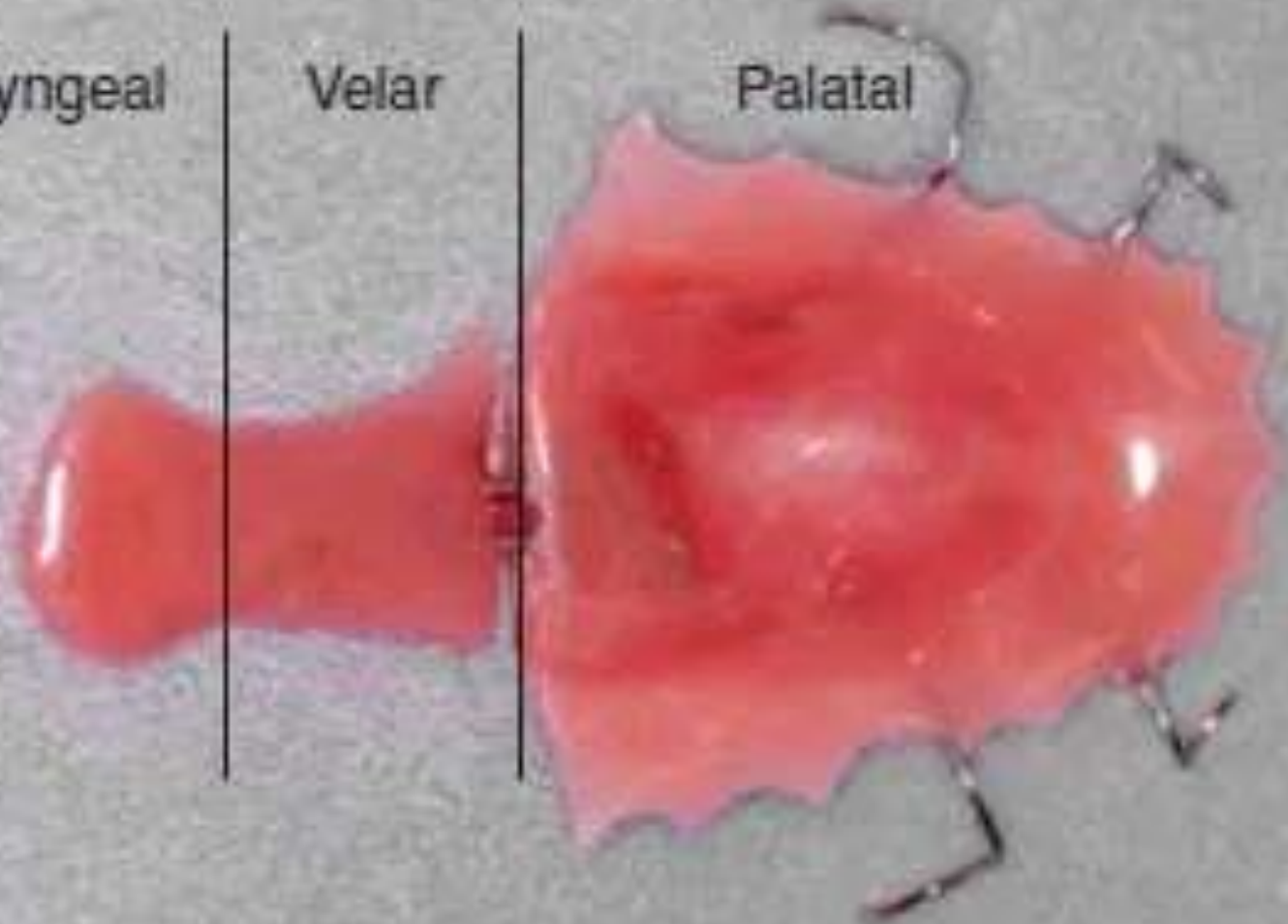
# *Contraindications*

- 1- If adequate retention is not available.
- 2- If the palate is not displaceable.
- 3- Uncooperative patients.

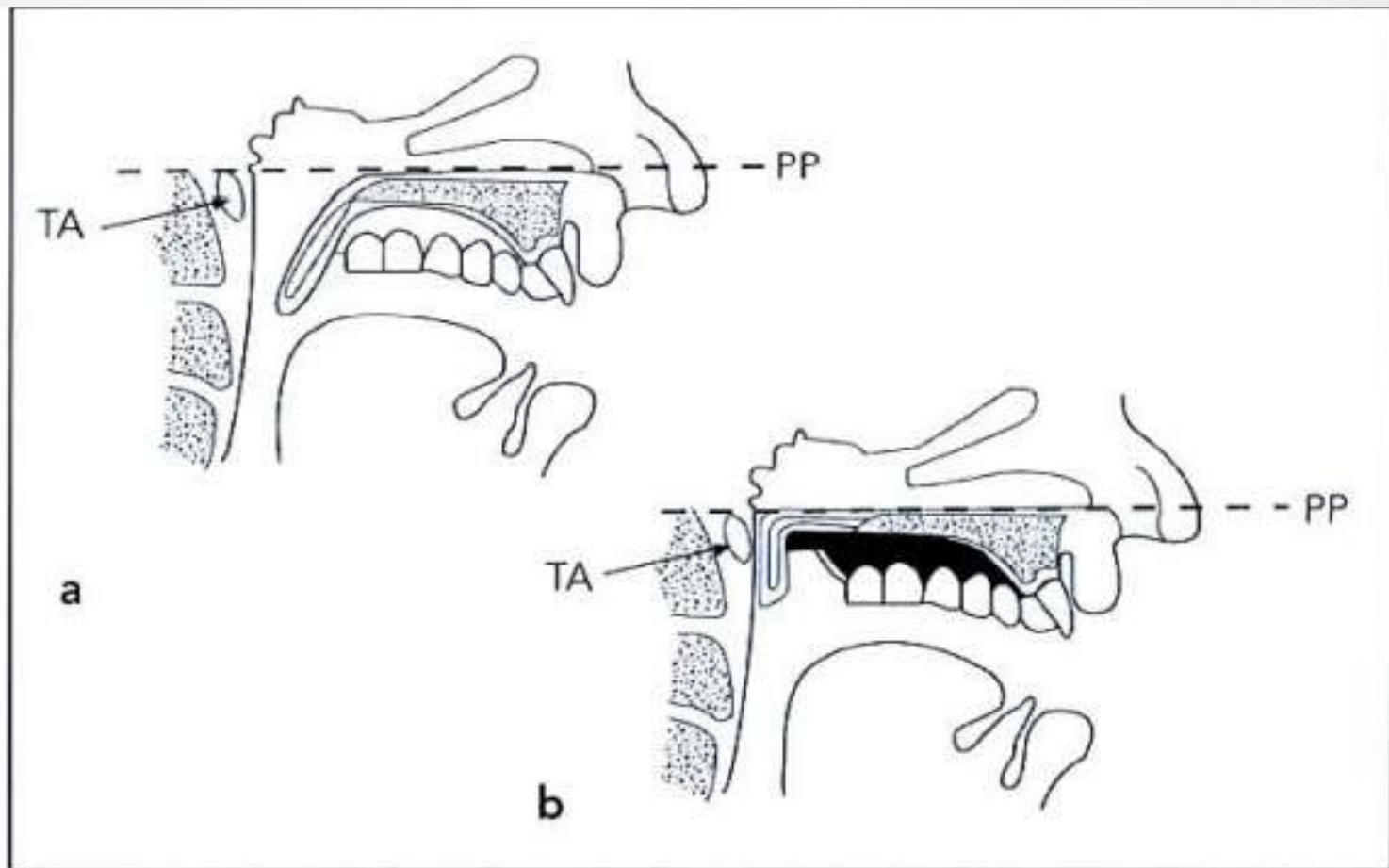
Pharyngeal

Velar

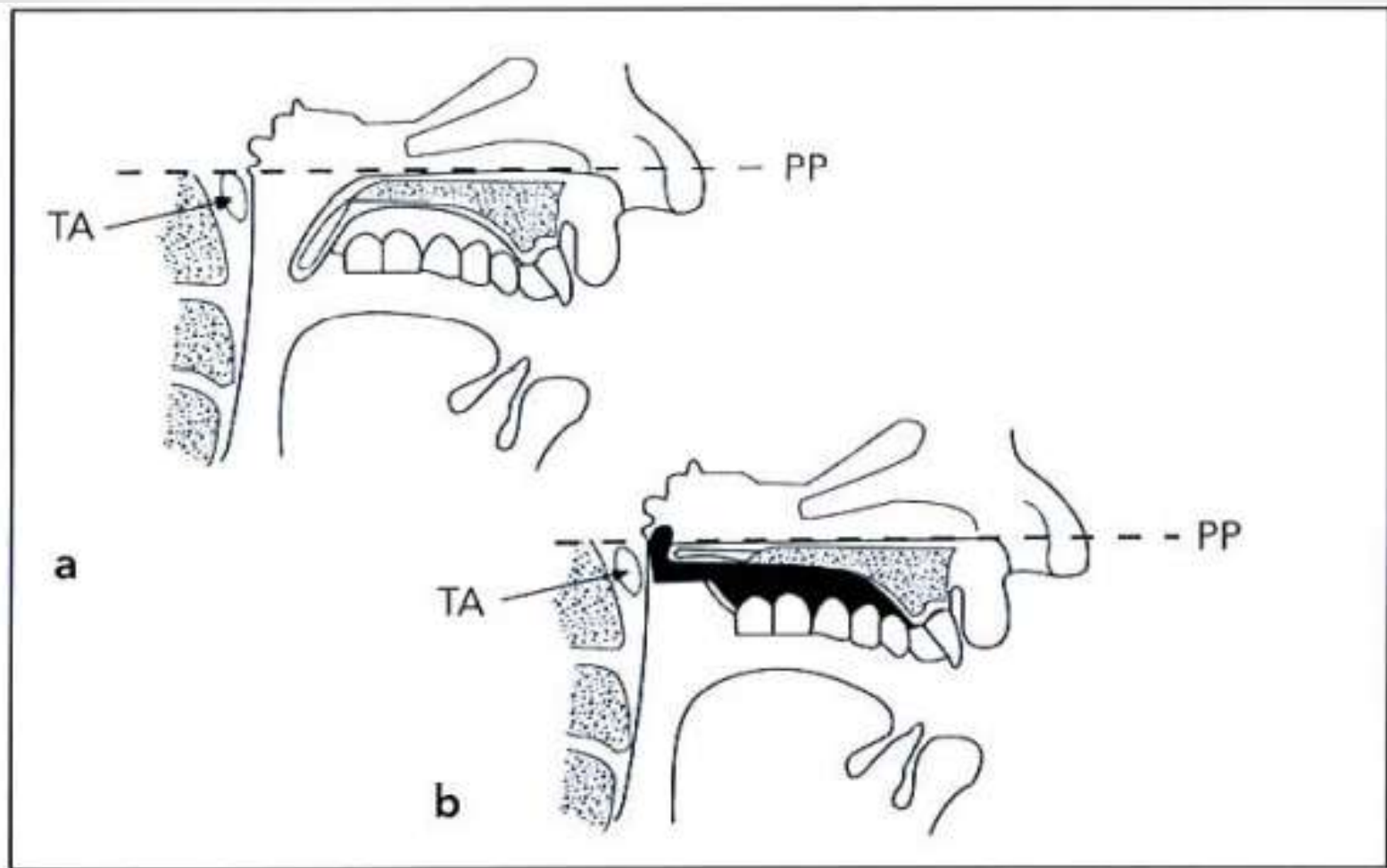
Palatal







**Fig 4-36** (a) Anatomically normal but paralyzed soft palate. (b) Palatal lift prosthesis in position, elevating the soft palate to produce velopharyngeal closure. PP—palatal plane; TA—median tubercle of the atlas. (Adapted from Gonzalez and Aronson<sup>264</sup> with permission.)



**Fig 4-37** (a) Congenital anatomical insufficiency of velopharyngeal region. (b) Palatal lift plus obturator in position elevating the soft palate and obturating the velopharyngeal space. PP—palatal plane; TA—median tubercle of the atlas.

# *The objective of the palatal lift prosthesis*

- -To displace the soft palate to the level of normal palatal elevation enabling closure by pharyngeal wall action
- -In cases where the length of the soft palate is insufficient to effect closure after maximal displacement, the addition of an obturator behind the displaced soft palate may be necessary. This prosthesis may be used as a diagnostic aid to assess the possible improvement in speech. Some clinicians believe that the use of a palatal lift on an interim basis may stimulate flaccid soft palate to increase functional activity.

# *The advantages of palatal lift prosthesis*

- a-The gag response is minimized (because of the superior position and the sustained pressure of the lift portion against the soft palate.
- b-The tongue is not changed (because of the superior position of the palatal extension.
- c- The access to the nasopharynx for the obturator (if necessary) becomes easier.
- d-The lift portion of the prosthesis may be extended gradually to help patient adaptation.
- e-Useful treatment for surgically risky patients.

# *Construction*

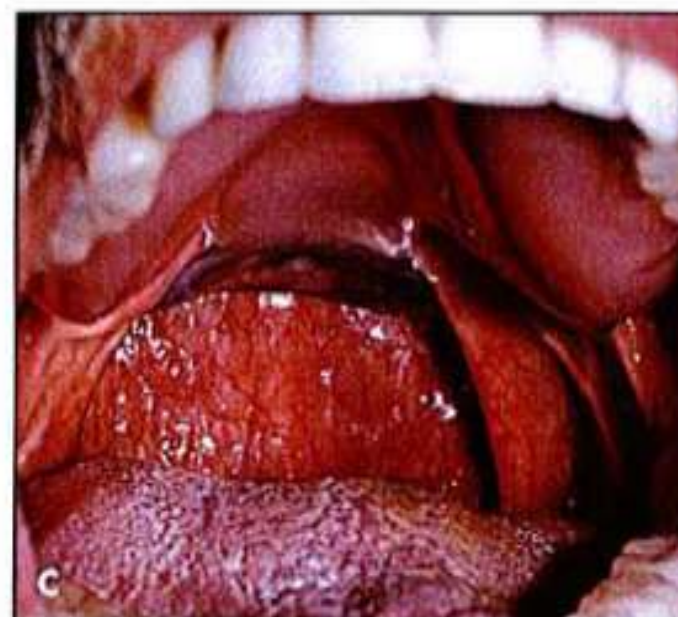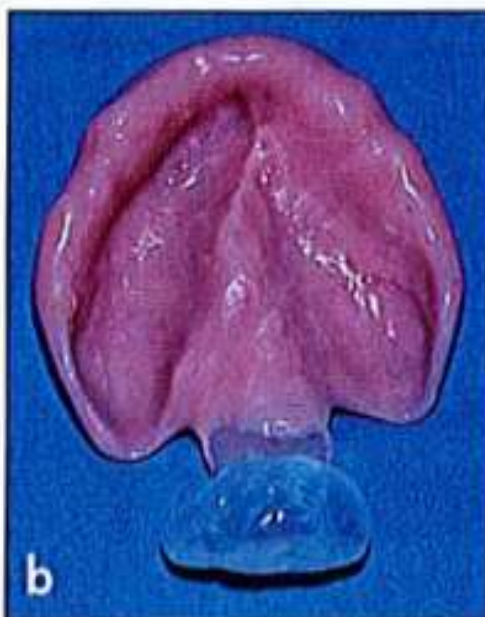
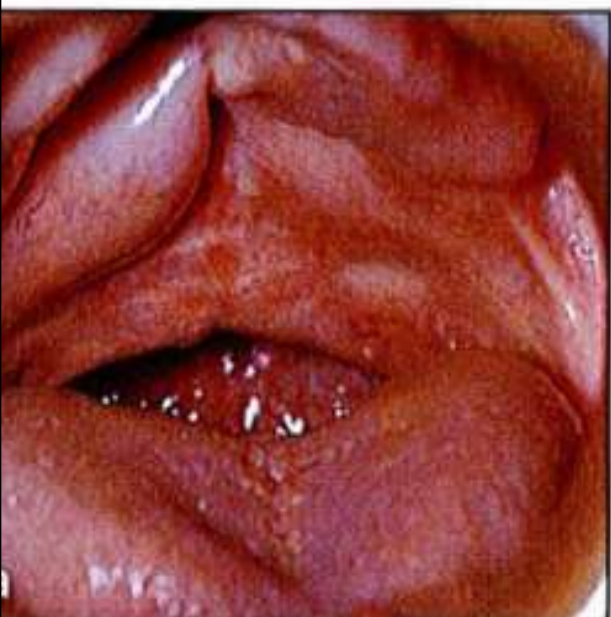
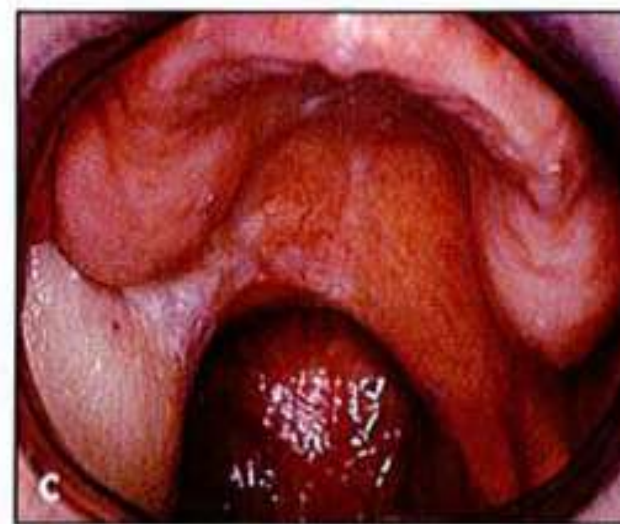
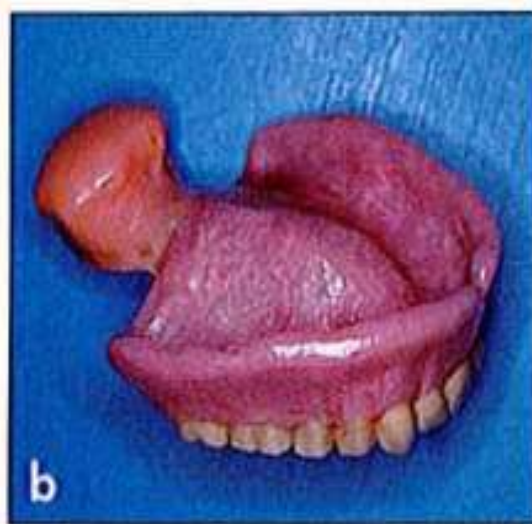
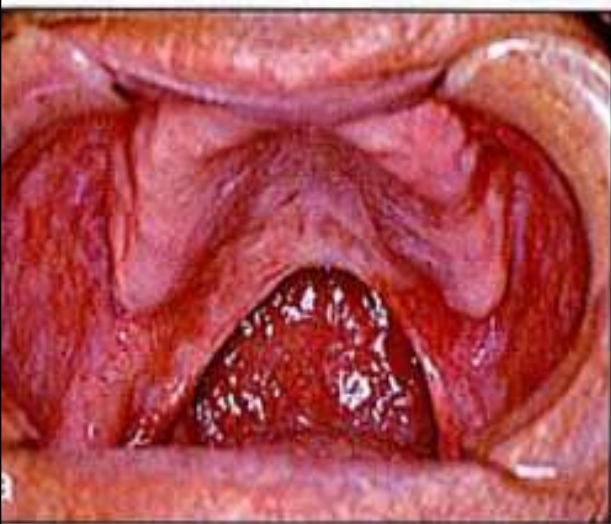- The impression is taken using custom tray that extended with baseplate wax to record and displace the soft palate superiorly. A suitable partial denture framework is fabricated and verified.

# *Construction*

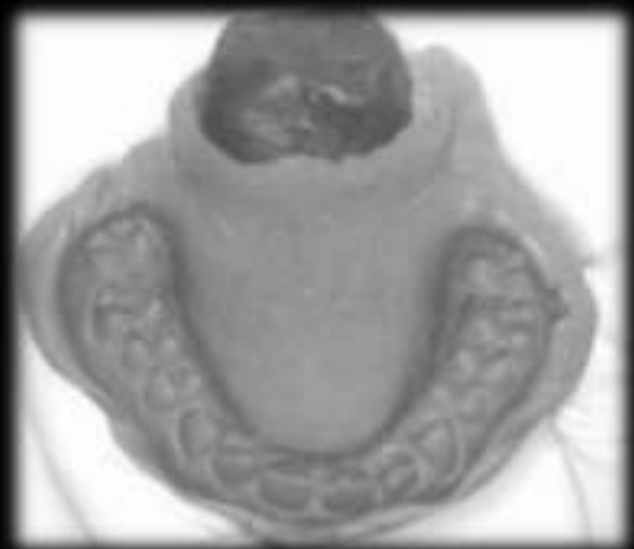
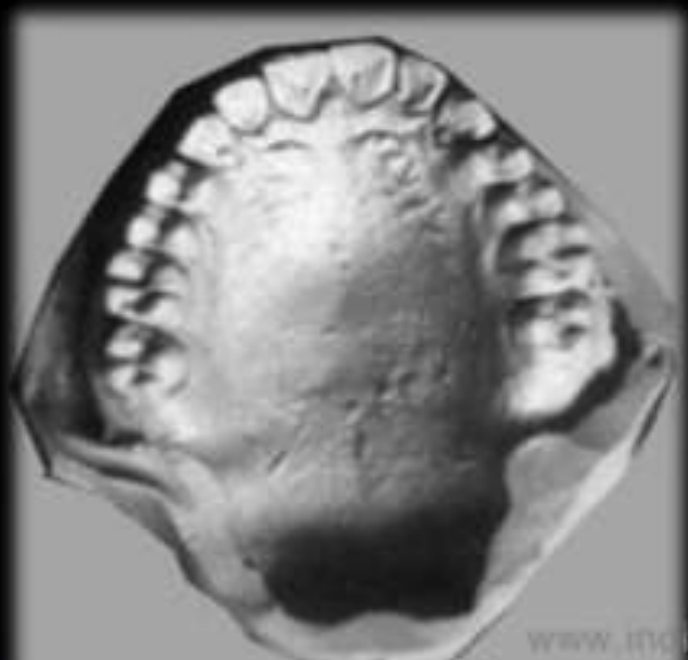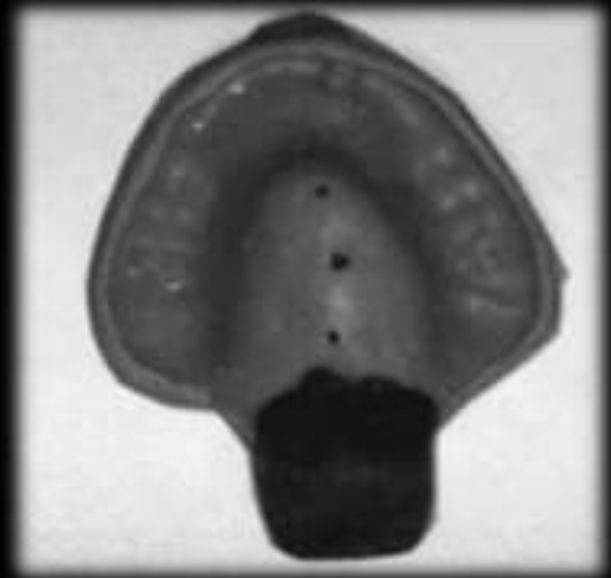
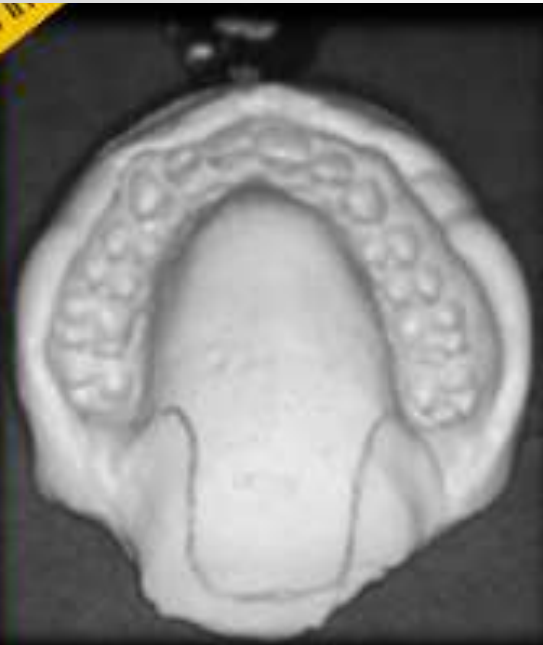
- The retentive meshwork or wire loop is extended to cover the anterior two thirds of the soft palate. Modeling plastic is added to the retentive meshwork until the appropriate displacement of the soft palate is achieved. Then a thermoplastic wax is used to record tissue detail. If displacement of the soft palate does not achieve adequate obturation the obturator can be extended behind the deficient soft palate.

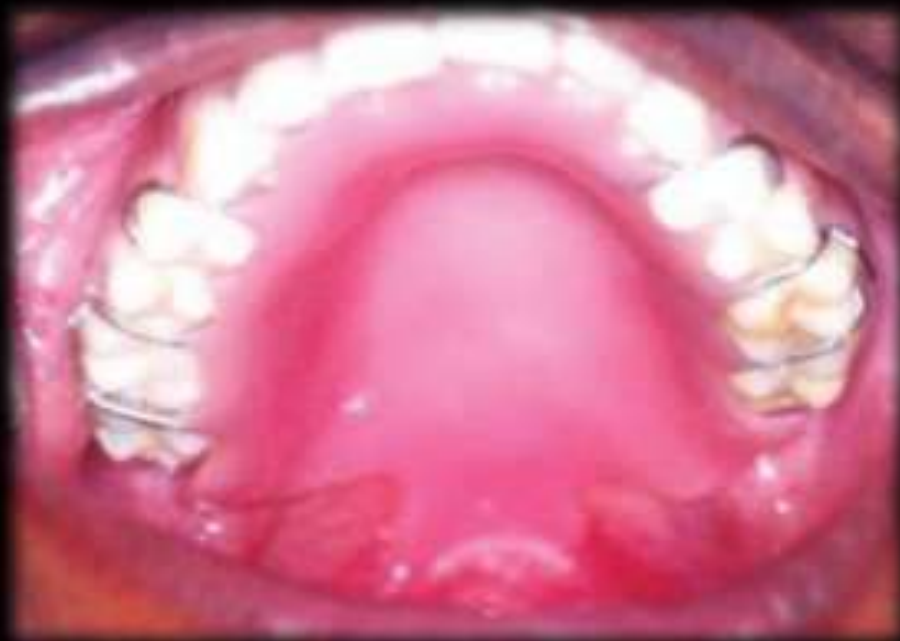
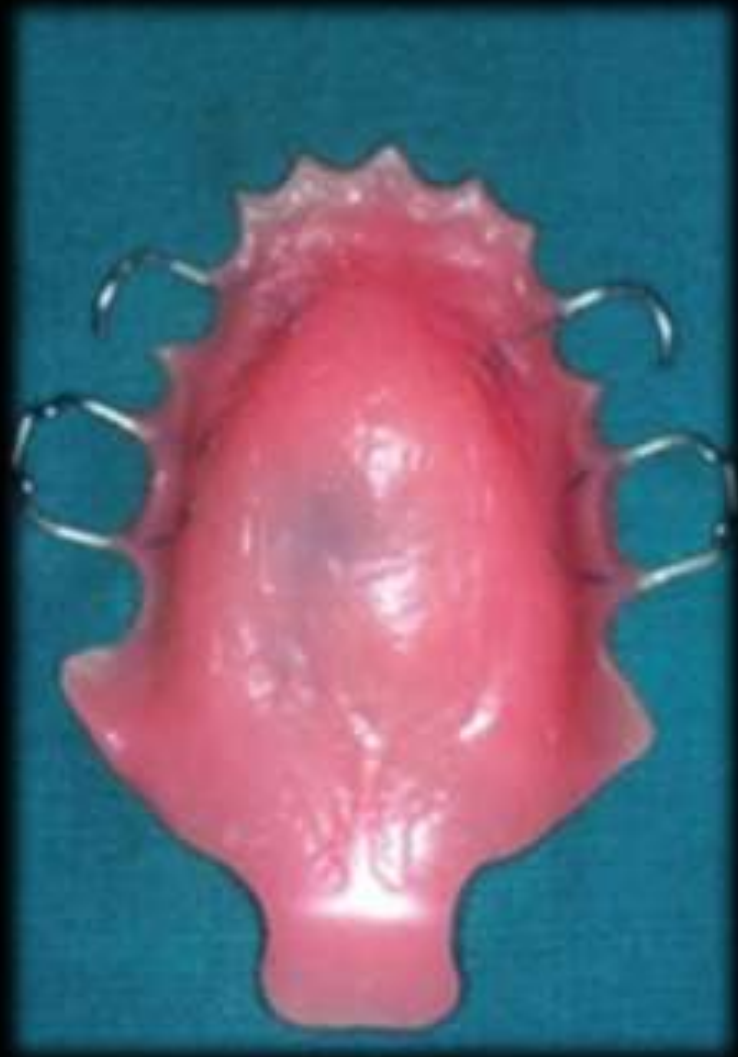
- It is important to insure that the lifting force does not create soreness and the force of displacement does not have an adverse effect on the supporting dentition.



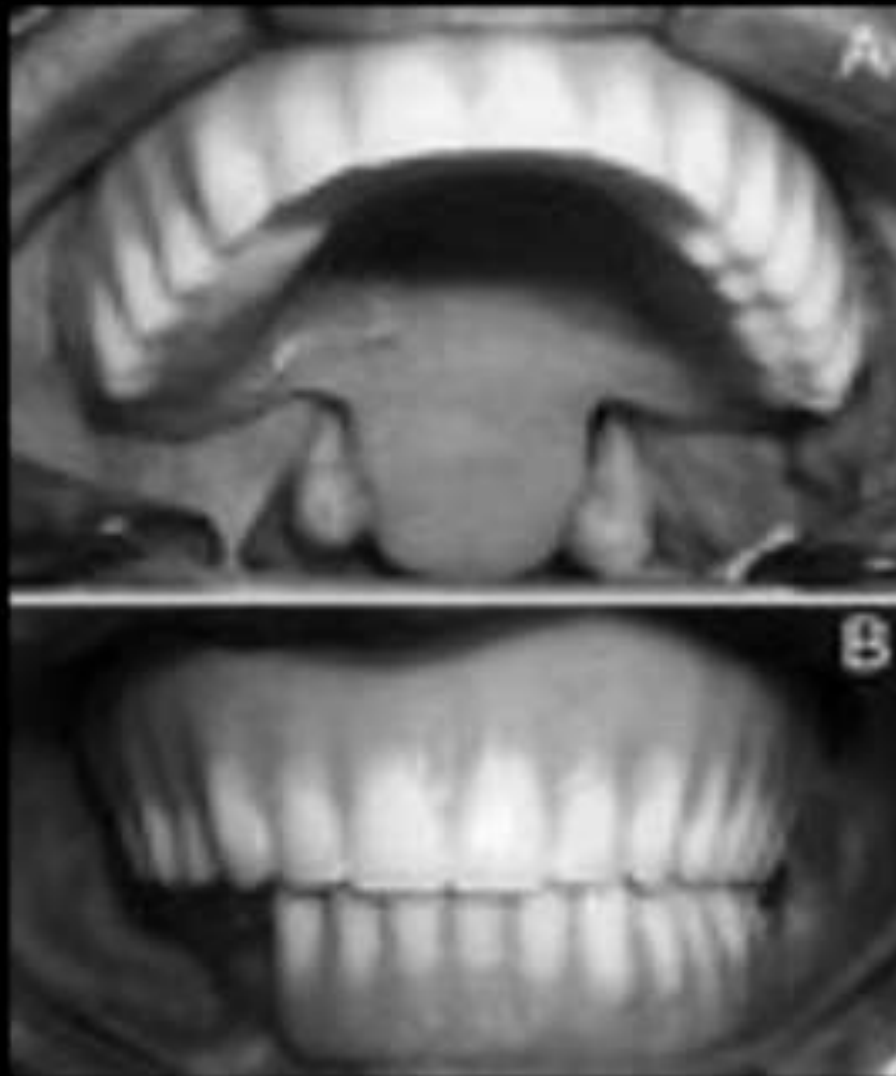
# FABRICATION

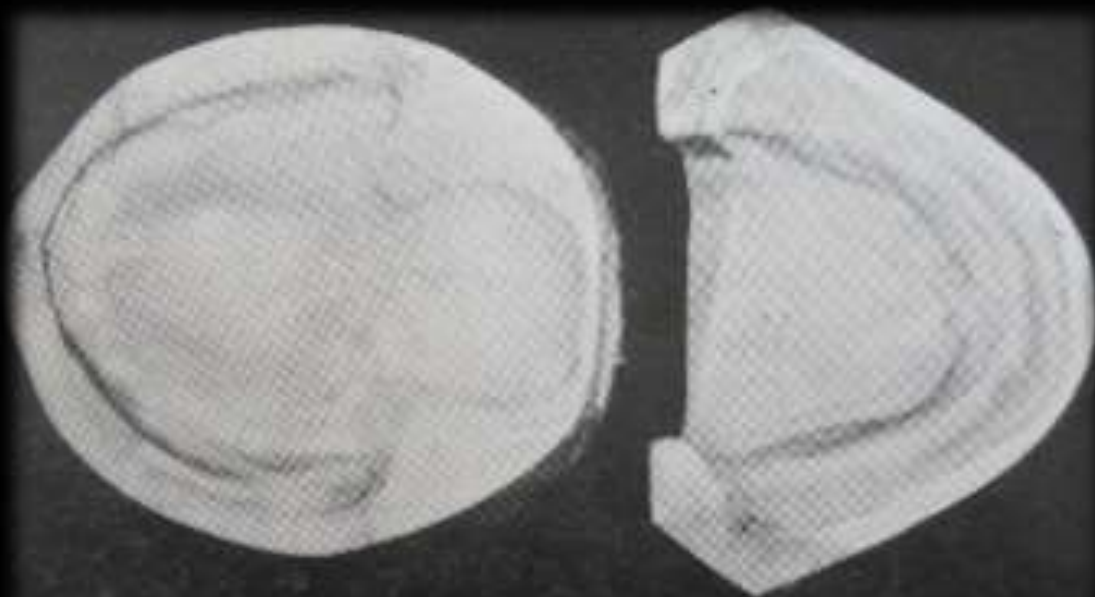
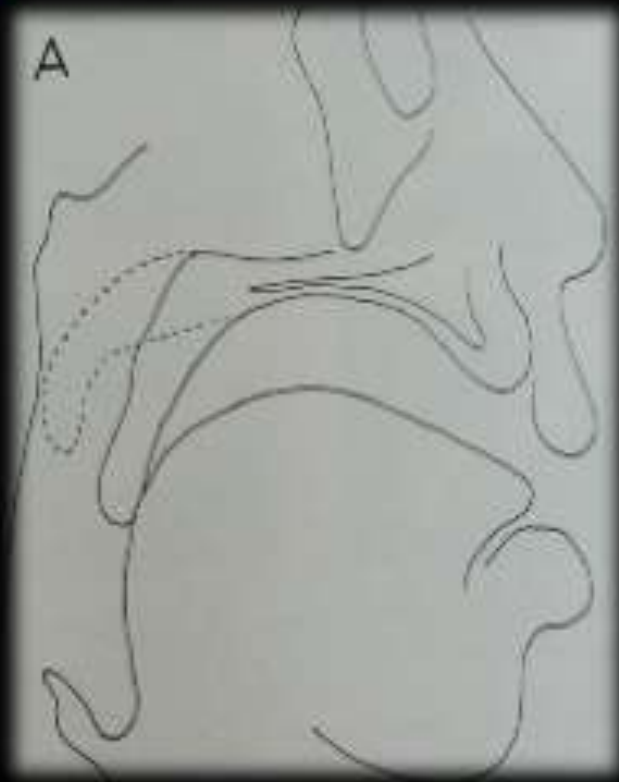





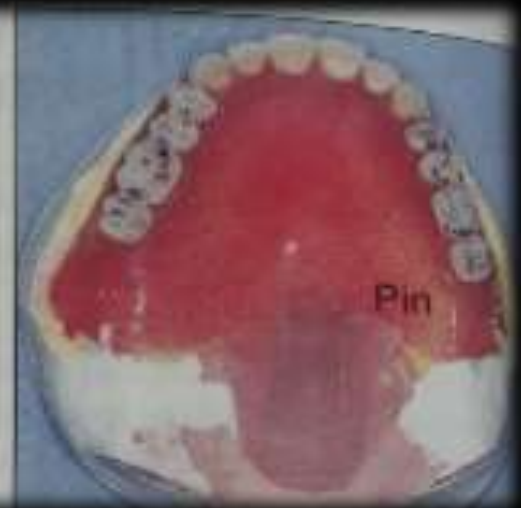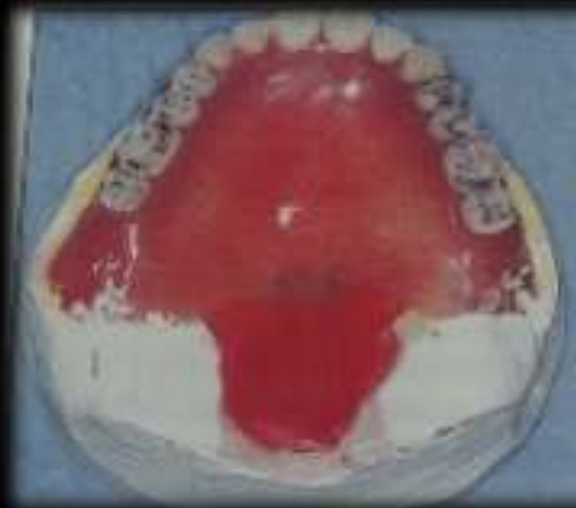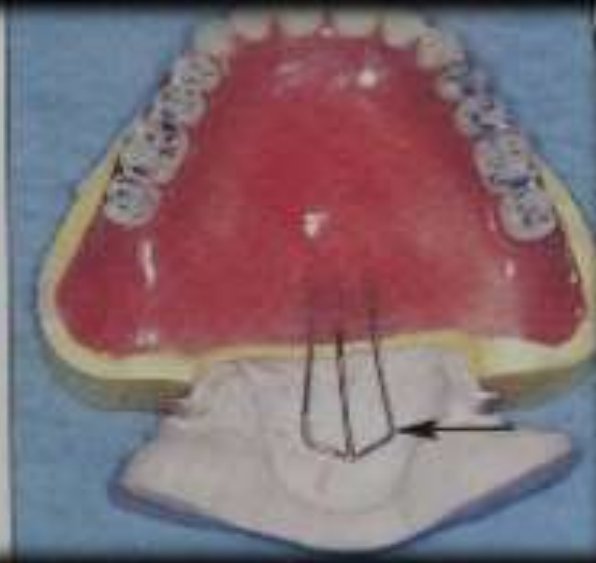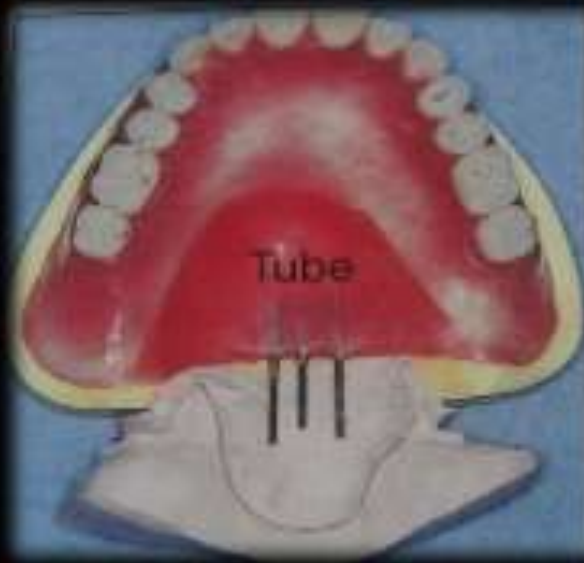# Palatal lift prosthesis in edentulous patients

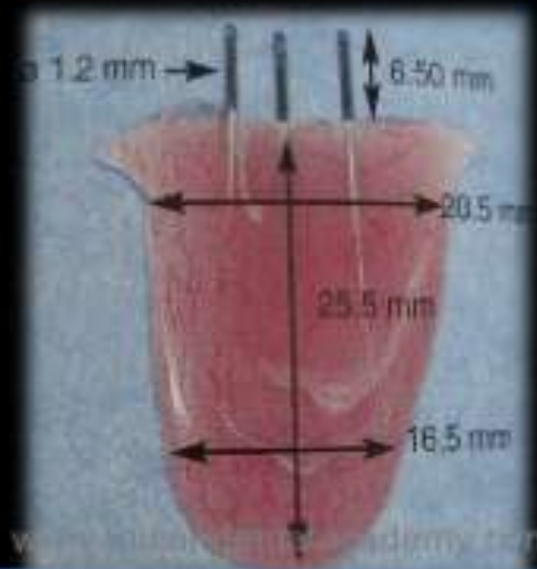
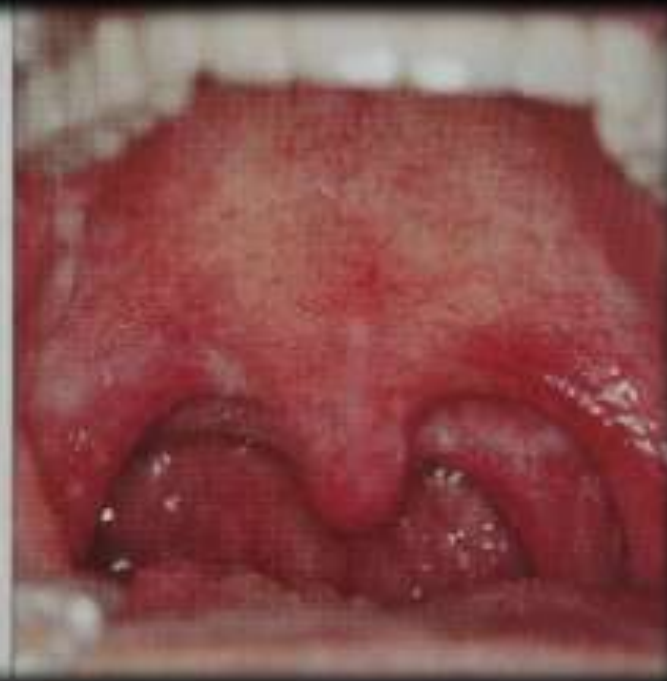
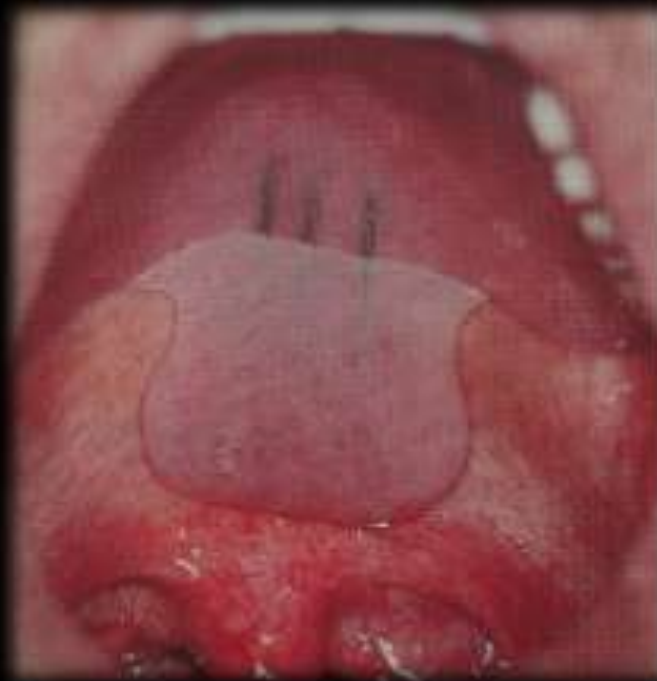
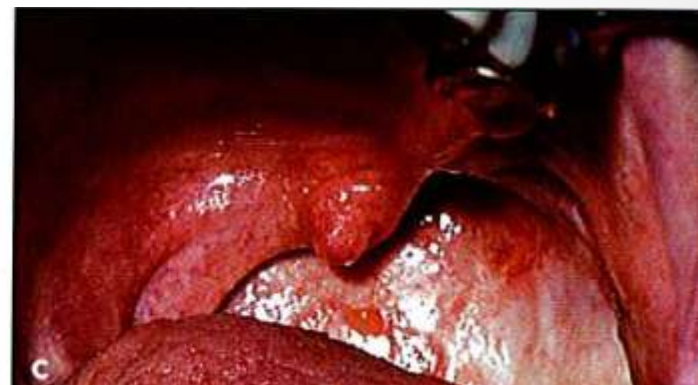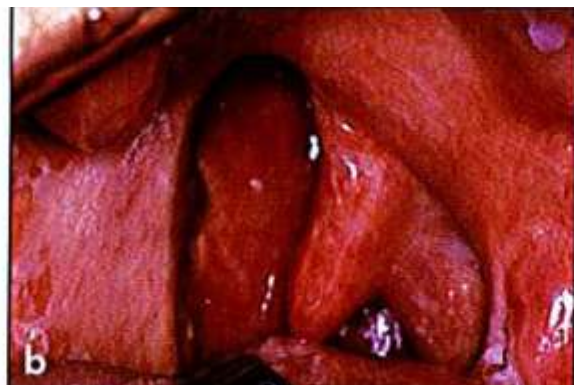
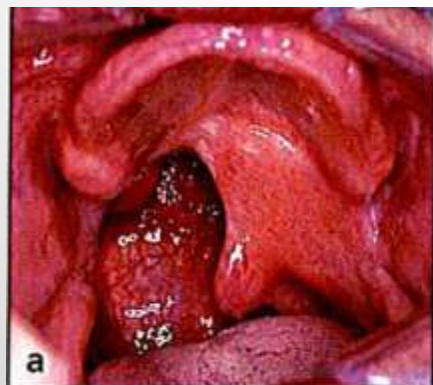
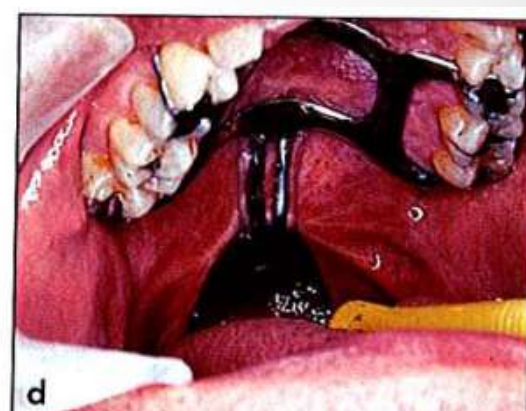
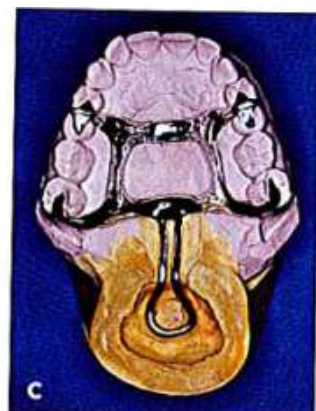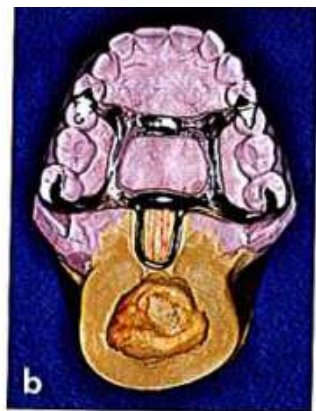




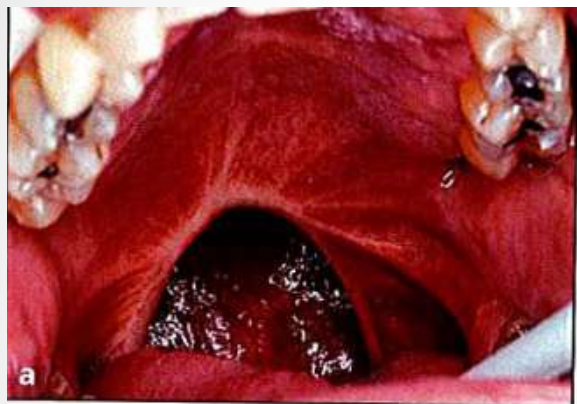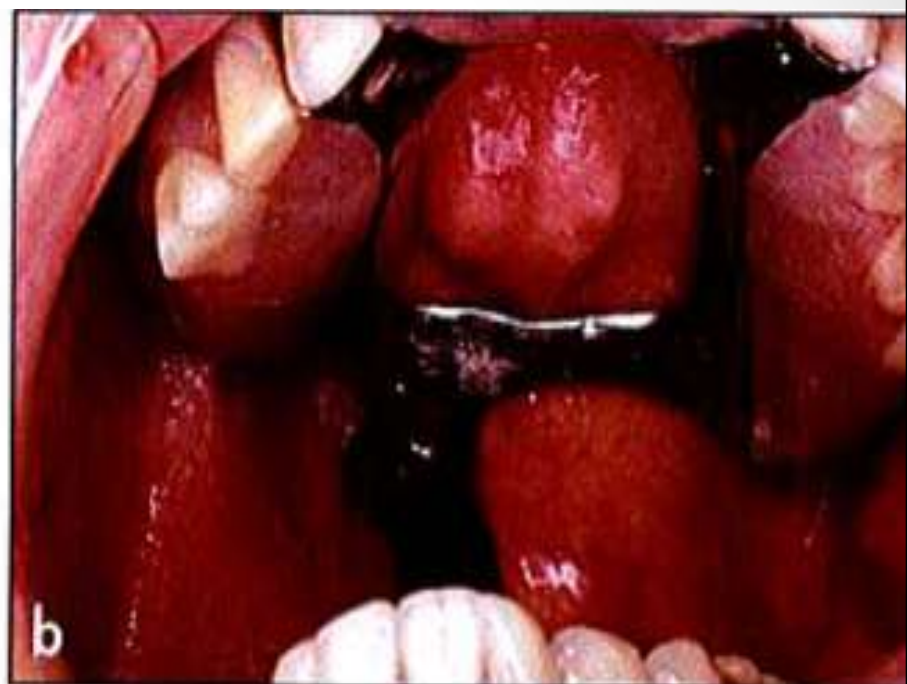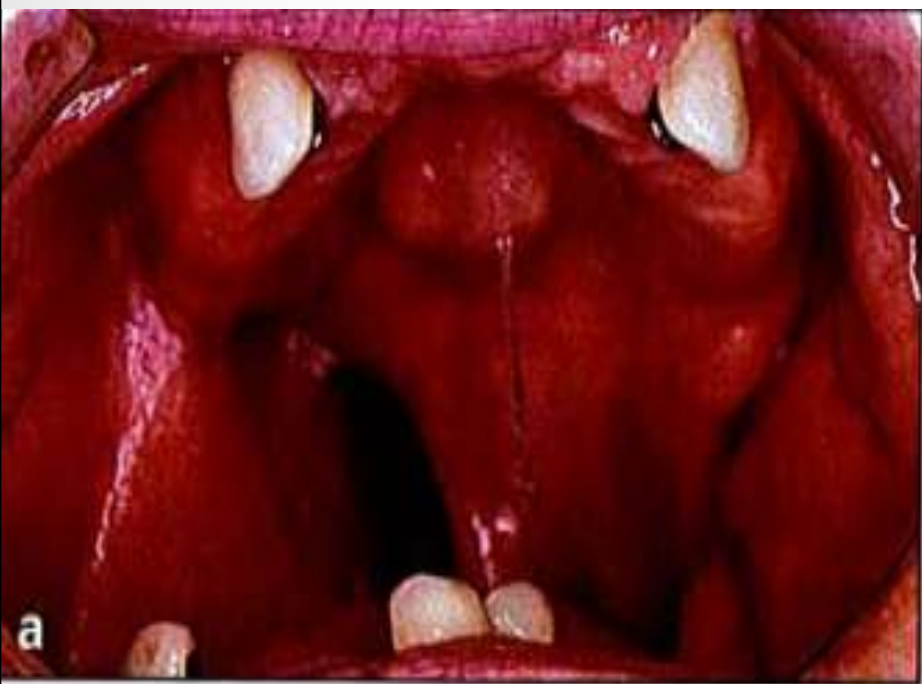# Removable palatal lift prosthesis











Thank you

# Feeding obturator

Lect. Hussein T. Abed

10\3\2021



Cleft lip  
and  
palate

```
graph TD; A[Cleft lip and palate] --> B[Syndrome]; A --> C[non-syndromic]
```

Syndrome

non-  
syndromic

# Cleft patients problems:

1. feeding difficulties,
2. facial growth deficiency,
3. dental, esthetic, psychological problems,
4. velopharyngeal incompetence,
5. otologic problems like middle ear infection, Eustachian tube dysfunction
6. delayed speech.
7. immediate concern for a newborn is feeding difficulty.

- Feeding problems occurs because child is not able to create sufficient negative intraoral pressure during feeding.
- It also affects bolus organization, bolus retention before swallowing, and also initiation of swallowing itself
- Feeding is further complicated by, nasal regurgitation, excessive air intake, and burping, coughing, choking and prolonged feeding causing fatigue

## neonatal intervention include:

modified bottles and nipples,  
feeding plates,  
and particular feeding techniques.

If defect is large. Early surgical repair of the palate is a viable option. But usually it needs to be postponed until certain age and weight gain of the infant. Orogastric or nasogastric tube can be used but for limited time. In such patients, feeding obturator is a ray of hope

# Benefits of feeding obturator:

1. Create rigid platform against which baby can press the nipple and extract milk.
2. Help in creating negative pressure thus reducing regurgitation, choking and thus reduces time of feeding also.
3. Help in proper tongue position thus preventing its interface in growth of palatal shelves and allowing functional development of jaw.
4. Contribute to speech development.
5. Reduces nasopharyngeal infection preventing food regurgitation in nasopharynx.

## DIFFERENT DESIGNS POSSIBLE ARE

### Based on material used

1. Heat cure resin
2. Autopolymerising resin
3. Visible light cure resin
4. Clear autopolymerising resin
5. Flexible plates

### Based on age of the patient

#### Days and months:

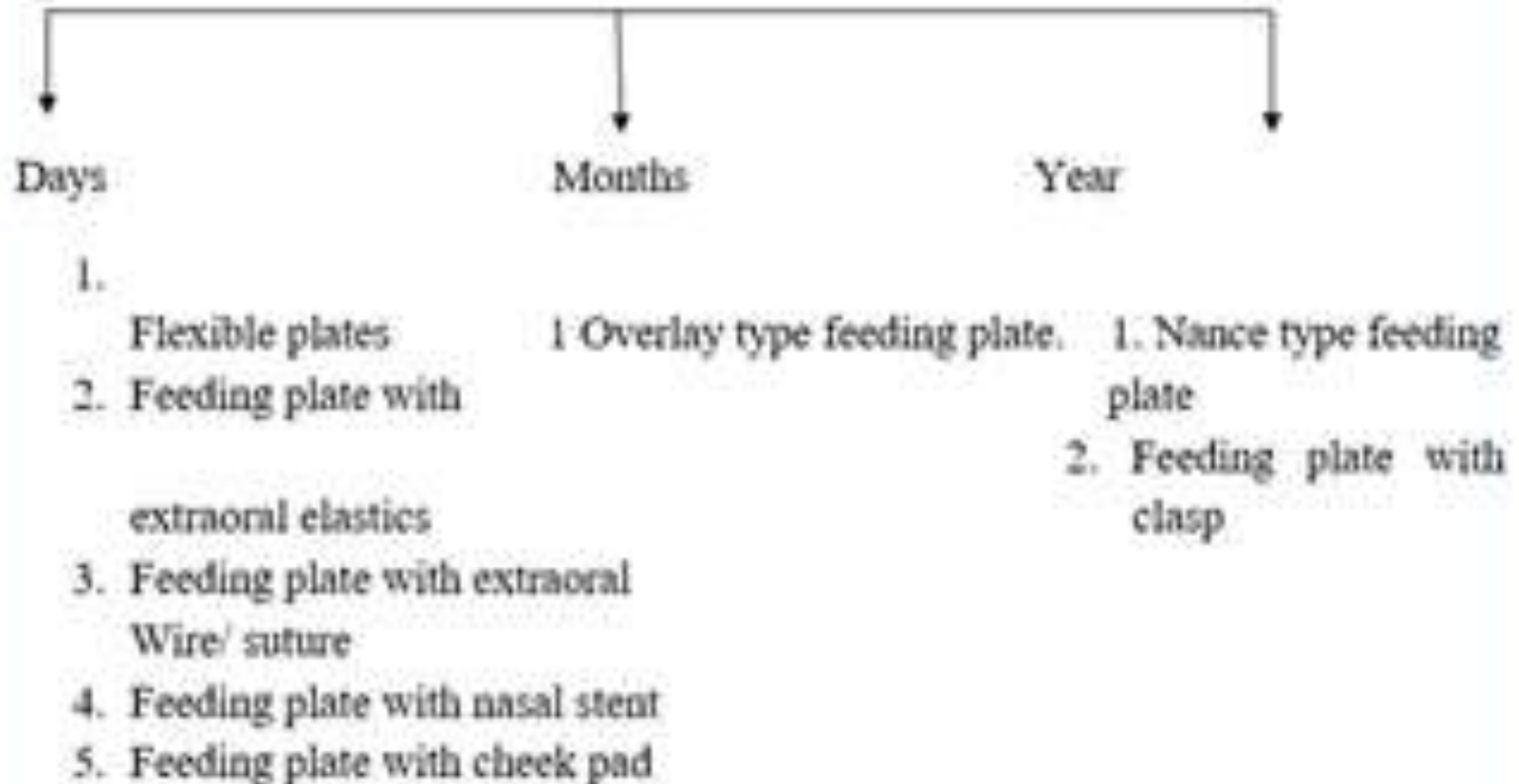
1. Flexible plates
2. Feeding plate with extraoral elastics
3. Feeding plate with extraoral wire/suture
4. Feeding plate with added nasal stent
5. Feeding plate with cheek pad
6. Overlay type feeding plate

#### Years:

1. Nance type feeding plate
2. Feeding plate with Jackson's clasp



## Clinical Implications:

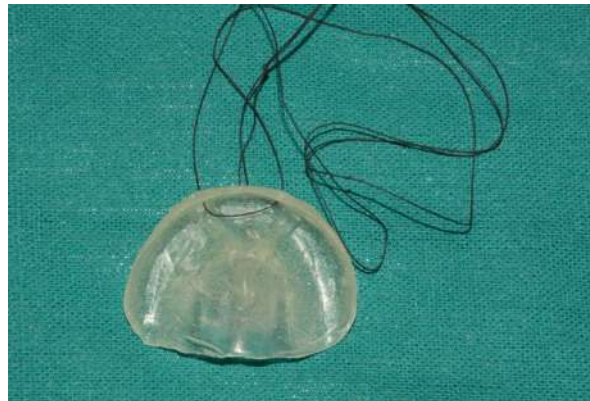

# Passive plates

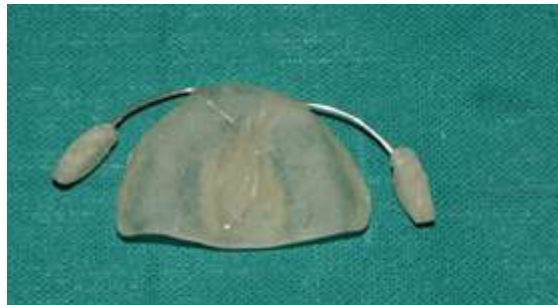

- The passive plates do not apply any force, they serve to:
  1. provide an artificial palate for the infant and permit functions like swallowing and feeding in a more normal manner.
  2. They also serve to prevent the widening of the cleft due to the activity of the tongue.

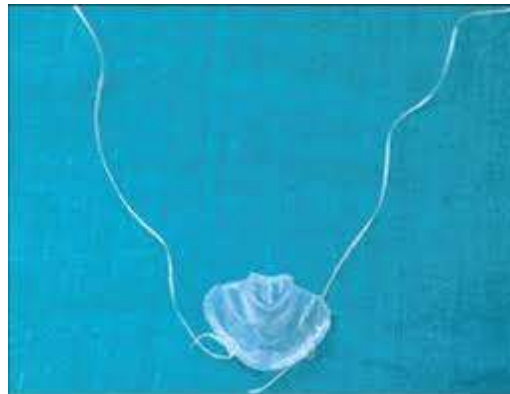
- Construction of feeding obturator in a day using autopolymerising resin and incorporation of dental floss to avoid gagging and accidental swallowing.



- Fabrication of feeding obturator in a day using autopolymerising resin attaching two 18G orthodontic wire that extend out of mouth to avoid accidental ingestion or aspiration of obturator. Application of some acrylic resin at sharp end of wire to avoid injury to both child and parent



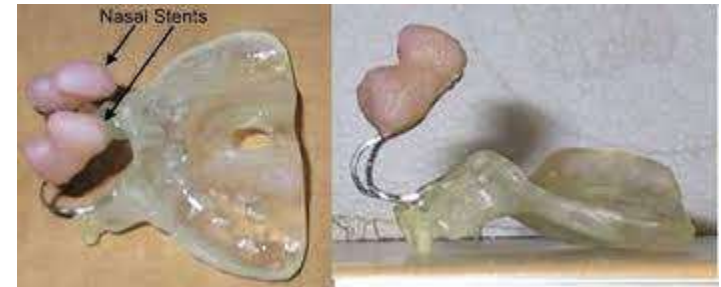- Vacuum tray fabrication because of its added advantage over acrylic obturator of being mouldable and soft texture with less possibility of soft tissue injury, good fit to ridges and palate and light in weight. But these are not economical, and can cause irritation to palate



- Fabrication of pre alveolar nasal molding plate (PNAM) with heat cure clear acrylic resin with retentive acrylic button at 45 degree to occlusal plane in upward direction incorporation of stretchable extra oral elastic in retentive button in a hole that can be retained extraorally.



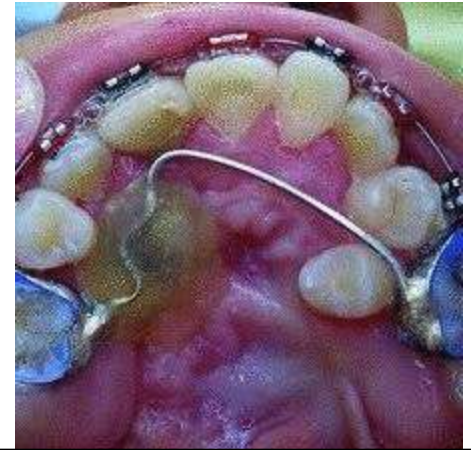
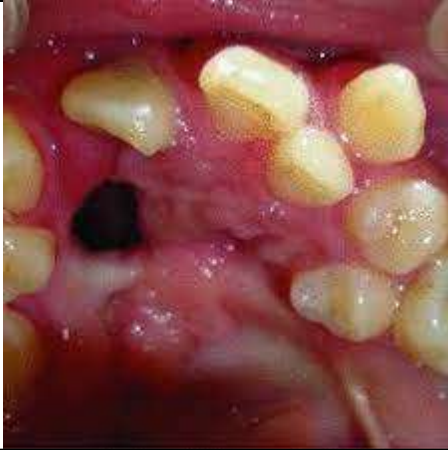


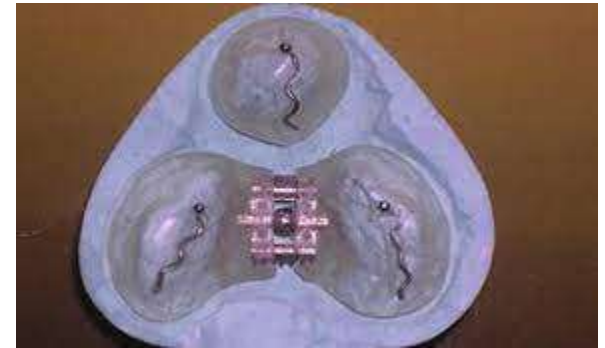
- Fabrication of pre naso alveolar molding plate with nasal stent using clear heat polymerized resin with a extraoral retentive button positioned at 45 degree to occlusal plane on labial flange facing downward. A wire added to upper end of button end of wire coated with permasoft to avoid injury to nasal soft tissue. Nasal cartilage molding is done by applying gentle pressure by activating wire loop.

# Nance obturator

- can be used when it is not feasible to close fistula in palate surgically, and removable appliance is also not possible. It is a modified Nance space maintainer with a acrylic plate covering the defect. Advantage is it also acts as space maintainer and we need not to remake it with growth of maxilla.

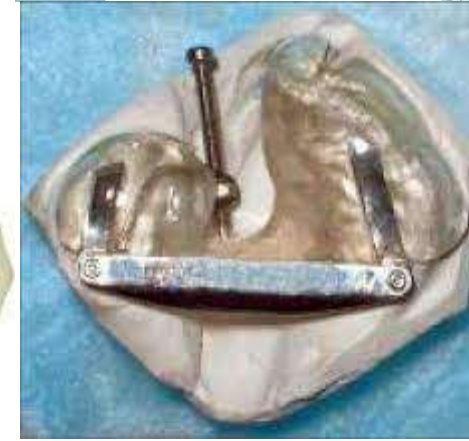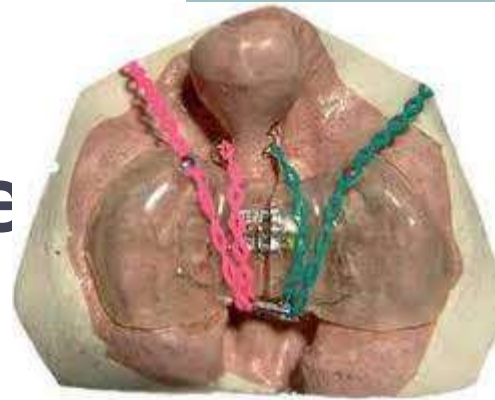


# Active appliances

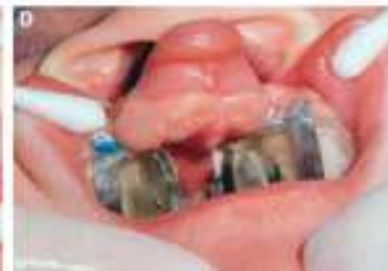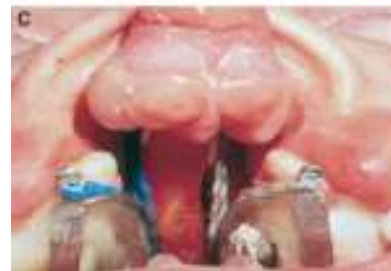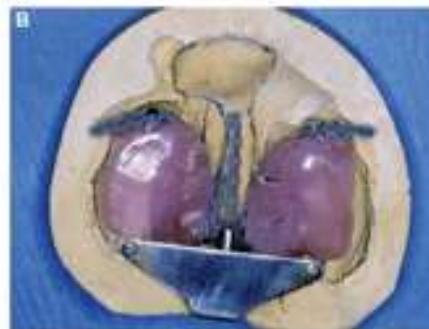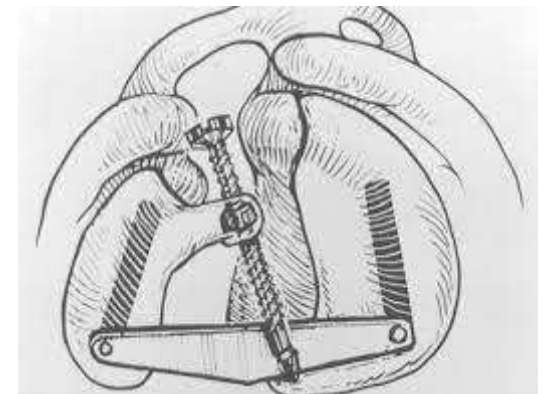
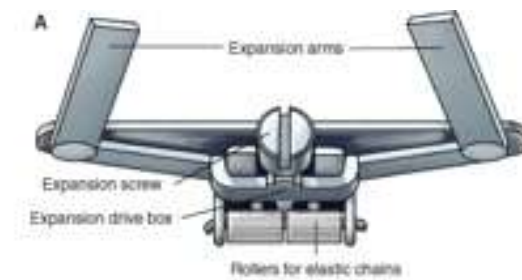


- **Latham's appliance:** It is a fixed appliance. It consists of two acrylic plates surgically fitted to palate under general anesthesia that are connected with a hinged bar posteriorly. Manipulation is done by rotating the hinged bar. In the area of the cleft a screw is present. The screw is turned  $\frac{3}{4}$ th of a turn over 3 - 4 week period, every day until it is tight.

# Latham's appliance



- It helps in repositioning of protruding premaxilla in bilateral cleft lip and palate patients, along with expansion of lateral maxillary segments. The advantage of this device is that it allows narrowing of defect by manipulating the palatal segments to desired location and thus make repair of cleft lip easy. Disadvantage is it does not cover the defect.





# JackscREW appliance

- This consists of two acrylic plates fitted over the alveolar segments and attached by single or multiple jackscrews. By adjusting the jackscrew the palatal segments can be manipulated to desired location. And jackscrew also prevents the interference of tongue in cleft closure.

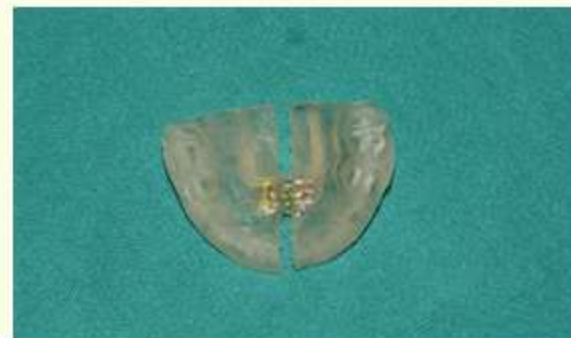
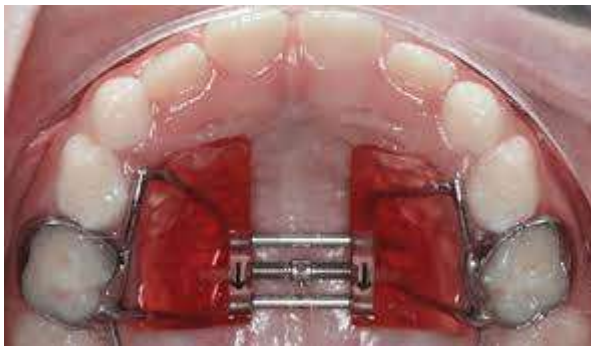
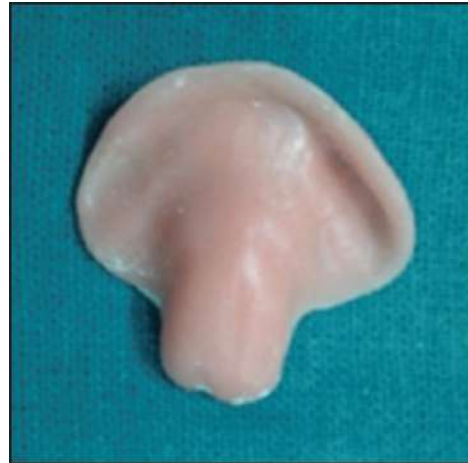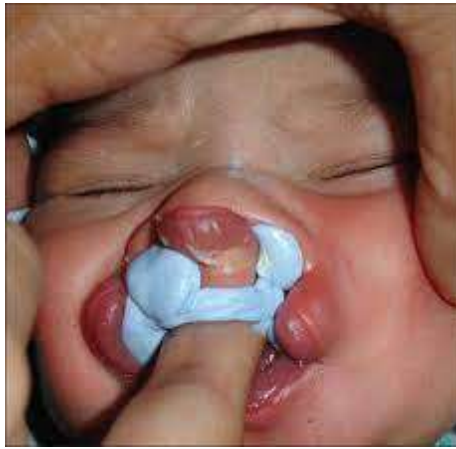Figure 8



# Steps to be followed in fabrication of feeding

- **plates Step 1:**
- Selection of the impression tray: size of impression tray should be enough to include maxillary segments laterally, cover up maxillary tuberosities posteriorly.
- Prefabricated trays also are also available commercially (Coe laboratories, Chicago) for cleft lip and palate infants



**Step 2:**

Making Primary impression. The making of the impression in an infant with a cleft palate is a critical procedure.

**Step 3:**

Primary cast was fabricated with type III gypsum product (dental stone).

**Step 4:**

Custom tray fabrication with autopolymerising resin.

**Step 5:**

Final impression made with rubber base impression materials to record precise details.

### **Step 6:**

Master cast fabrication and excessive undercut blocking with modeling wax.

### **Step 7:**

Wax pattern adaption on master cast.

### **Step 8:**

Flasking, dewaxing procedure and feeding plate fabrication with heat cure acrylic resin.

### **Step 9:**

Eyelets created on feeding plate to allow silk suture to pass through.

Various techniques are used to enhance retention of plate.

# Complication encountered while making impression are:

- Engagement of impression in undercuts and its fragmentation during withdrawal causing respiratory obstruction/asphyxiation.

# Precautions taken to avoid complications are:

- Impression should be made when the infant is fully awake
- Impression should be made in proper hospital setting with a surgeon present all the time to handle airway emergency.
- Maintaining airway patency by depressing tongue with mouth mirror.
- Clean remnants of impression material after the procedure.


# Precautions taken to avoid complications are:

- Infant has not had food for at least two hour before procedure. High volume suction should be ready at all times, in case of aspiration of gastric content.
- Maintain a proper patient and dentist position. A number of positions including prone, face down, upright, and even up- side down have been adopted.





Thank you

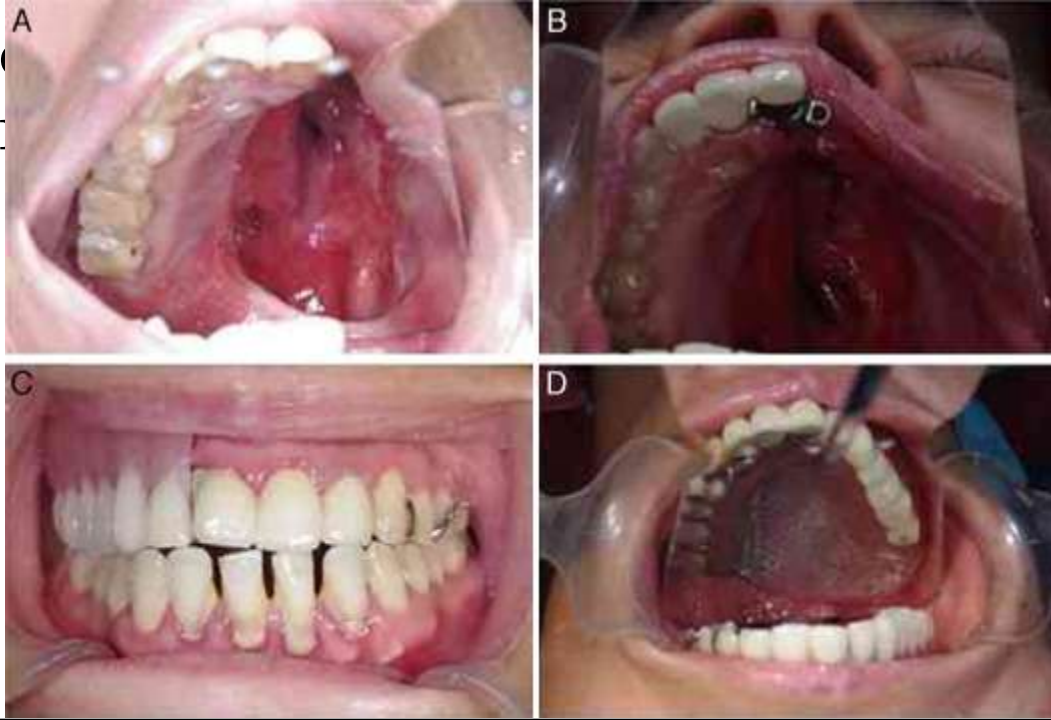


# **MAXILLARY OBTURATOR PROSTHESIS : INDICATIONS AND TREATMENT PLANE**

**Lect. Hussein T. Abed**

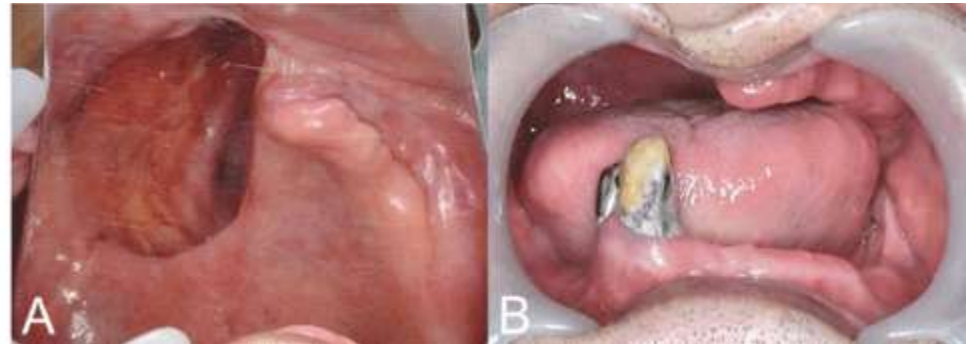
**19\5\2021**

- Definition : Obturator is a prosthesis used to close a congenital or acquired tissue opening, primarily of the hard palate &/or contiguous alveolar structures. Prosthetic restoration of defect often includes use of a surgical obturator.



# PROBLEMS ASSOCIATED WITH DEFECTED MAXILLA

1. Reduced bony support
2. Increased inter arch
3. Lack of adequate der
4. Inadequate retention due to ineffective posterior palatal seal due to scar issue if surgery was previously performed.
5. Scarring of lip tissues which may affect anterior border seal and exerts a backward push on the denture, thus affecting denture retention.



# INDICATIONS:

1. to act as a framework over which tissues may be shaped by the surgeon;
2. to serve as a temporary prosthesis during the period of surgical correction ;
3. to restore a patient's cosmetic appearance rapidly for social contacts ;
4. to provide for an inability to meet the expenses of surgery ;



# INDICATIONS:

- 5. when the patient's age contraindicates surgery ;
- 6. when the size and extent of the deformity contraindicates surgery ;
- 7. when the local avascular condition of the tissues contraindicates surgery ; and,
- 8. when the patient is susceptible to recurrence of the original lesion which produced the deformity.





# USES OF OBTURATORS

- Provides a stable matrix for surgical packing
- Reduces oral contamination
- Speech is effective post-operatively
- Permits deglutition
- Reduces the psychological impact of surgery
- Reduce the period of hospitalization



# TYPES OF OBTURATORS

Based on phase of treatment :-

- Surgical obturators (immediate surgical obturators & delayed surgical obturators)
- Interim obturators
- Definitive obturators

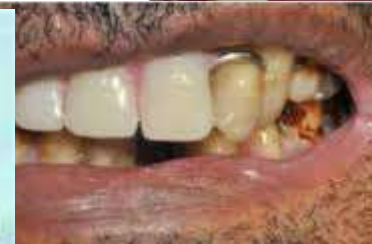
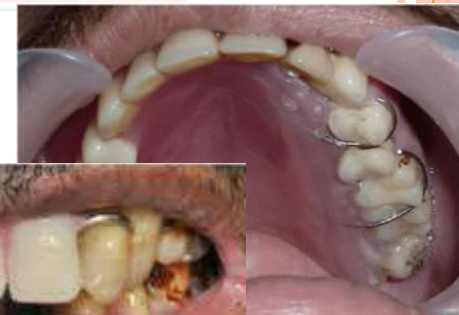
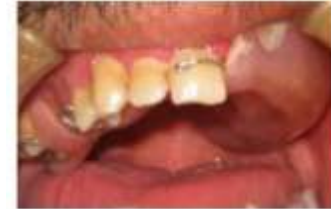Figure 1: A red, anatomical model of a surgical obturator appliance.

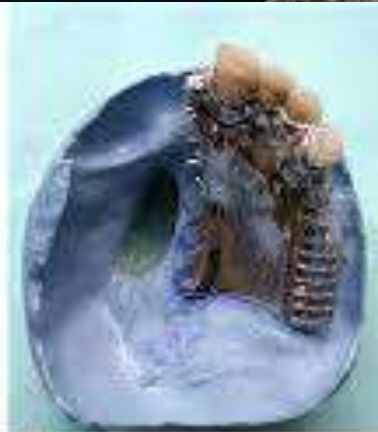

Figure 2: A blue, anatomical model of a surgical obturator appliance.

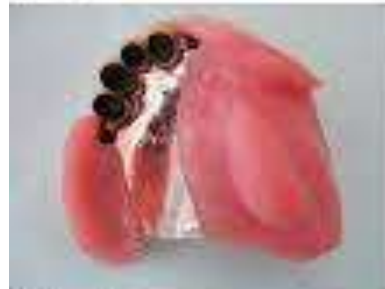

Figure 3: A red, anatomical model of a surgical obturator appliance.

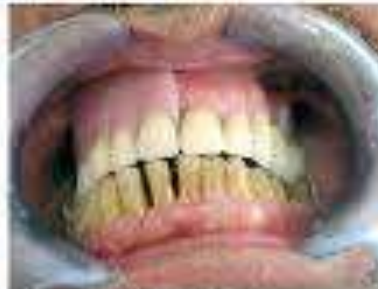
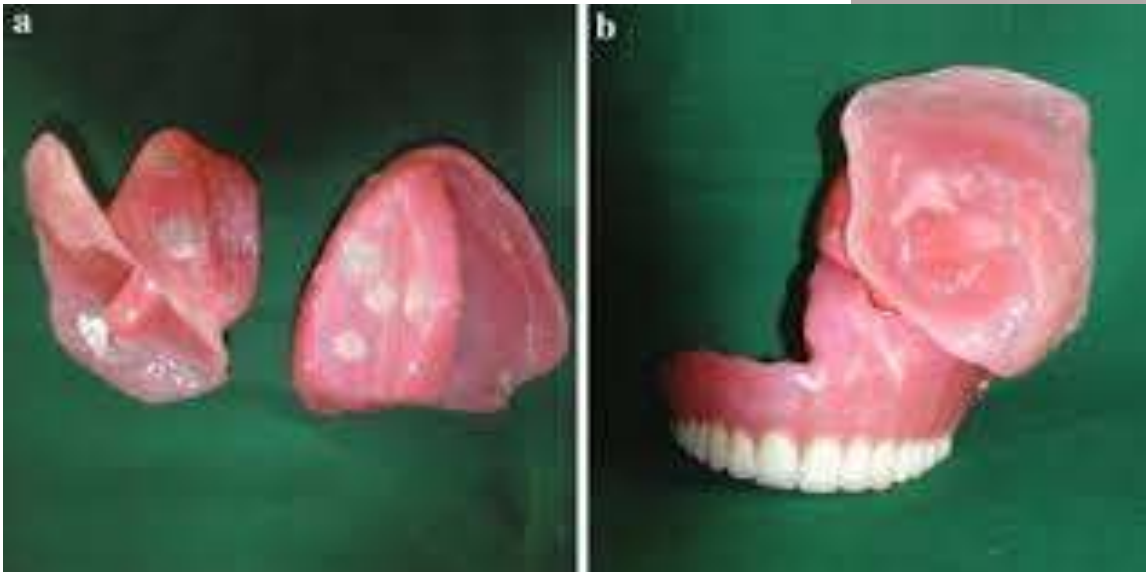
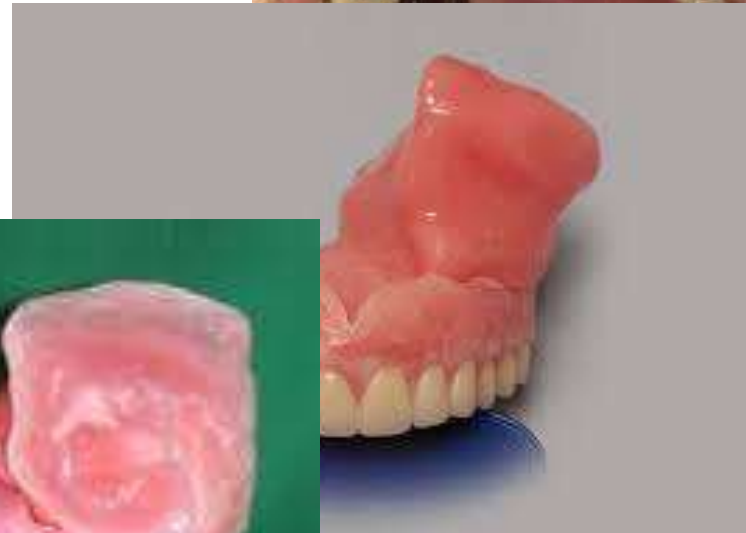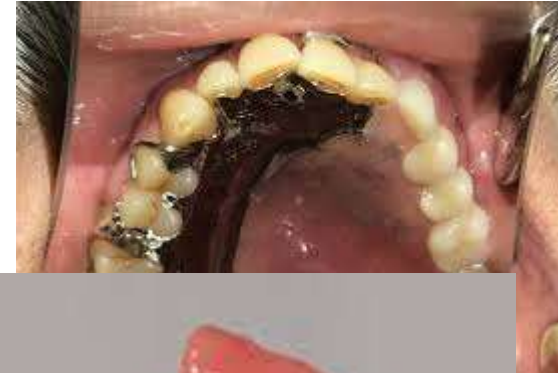Figure 4: A clinical photograph of a patient's teeth showing a surgical obturator appliance in place.



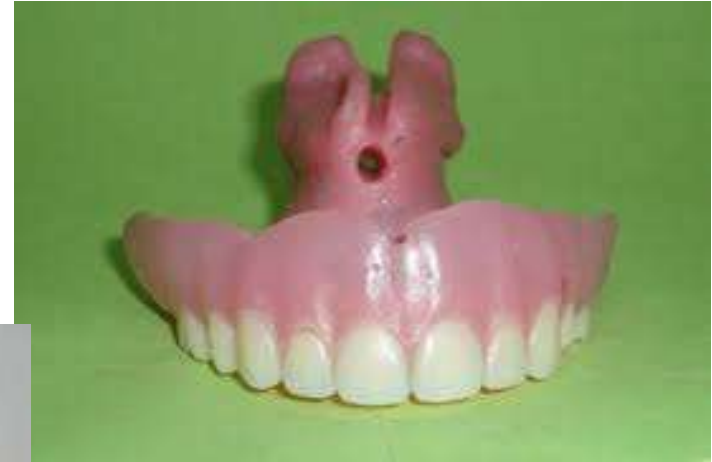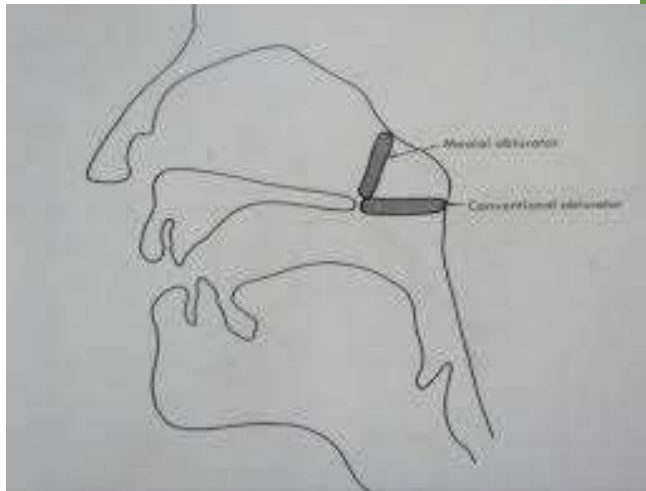
# BASED ON THE MATERIAL USED :-

- Metal obturators
- Resin obturators
- Silicone obturators



# BASED ON AREA OF RESTORATION :-

- Palatal obturator
- Meatal obturators



# SURGICAL OBTURATOR

- A temporary prosthesis used to restore the continuity of hard palate immediately after surgery or traumatic loss of a portion or all of the hard palate &/or contiguous alveolar structures like gingival tissue,teeth.

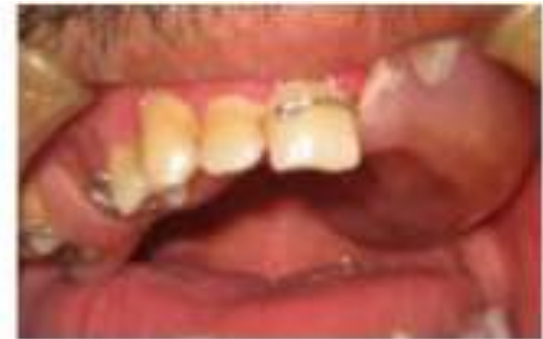
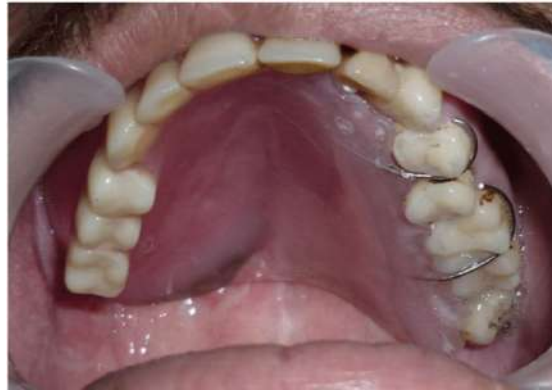
# SURGICAL OBTURATOR

It is of two types :-

Immediate surgical obturator :- It is inserted at time of surgery.

Delayed surgical obturator :- It is inserted 7-10 after surgery





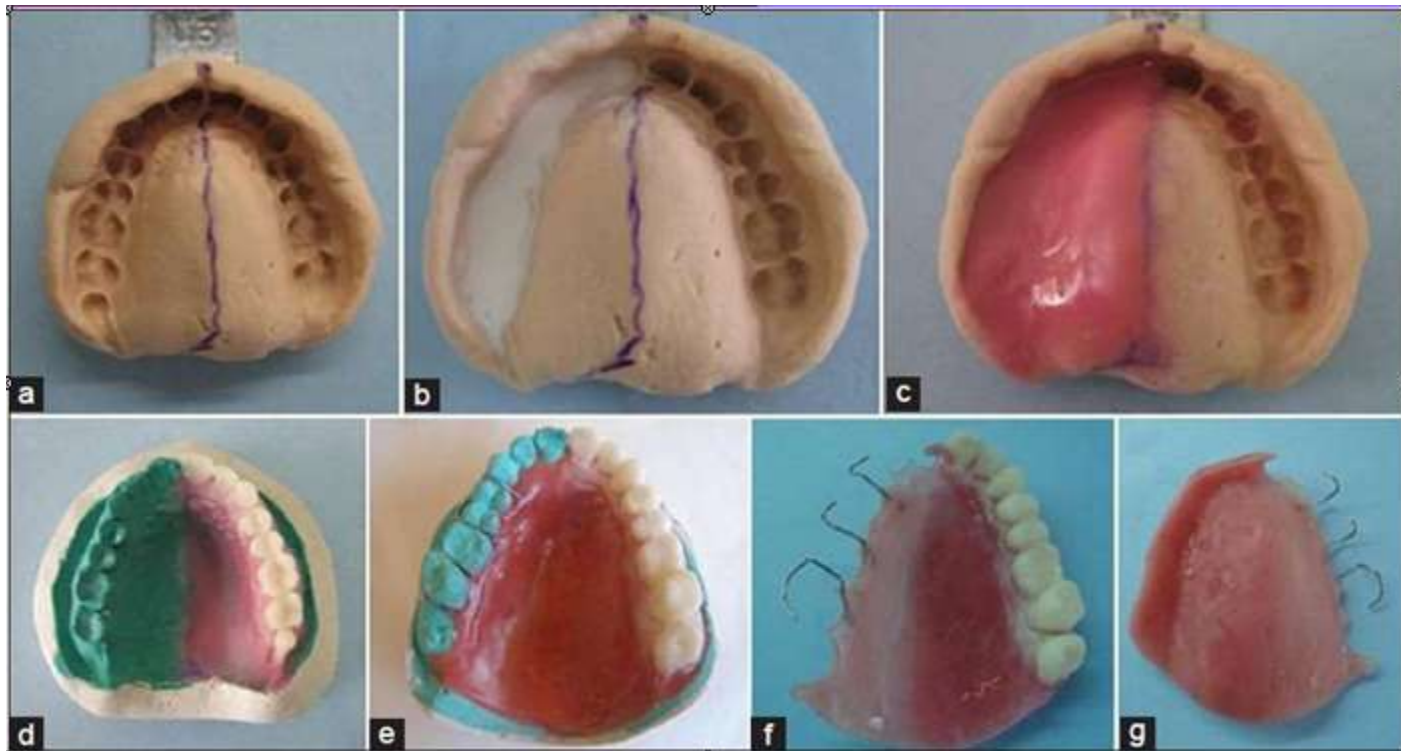
# CLINICAL CONSIDERATIONS

- ✓ Surgical obturator is inserted on the day of surgery.
- ✓ A preliminary cast is obtained before surgery on which a mock surgery is performed.
- ✓ A clear acrylic plate is fabricated & inserted after surgery.
- ✓ If patient is dentulous, retention is obtained with simple clasps.



- ✓ If the patient is edentulous, the obturator is wired into alveolar ridge & zygomatic arch.
- ✓ The obturator is retained for 3-4 months post surgically.
- ✓ It is replaced with an interim or definitive obturator after complete healing of the surgical wound.





# PRINCIPALS RELATIVE TO THE DESIGN OF IMMEDIATE SURGICAL OBTURATORS

1. If it is possible the surgeon should leave the posterior edge of the hard palate & tuberosity. Otherwise the soft palate will be flabby and often drop inferiorly.
2. The obturator should **terminate short of the skin graft-mucosal junction**. As soon as the surgical packing is removed., extension into the defect may be accomplished with tissue conditioning or interim soft lining materials.
3. The prosthesis should **be simple and light** in weight.
4. The prosthesis for dentulous patients should be **perforated at the interproximal extension** to allow the prosthesis to be wired to the teeth at the time of surgery.



5. **Normal palatal contours** should be reproduced to facilitate postoperative speech and deglutition.
6. A couple of **wire loops** is attached to the fitting surface in cases of big tumor.
7. Posterior **occlusion** should not be established on the defect side until the surgical wound is well organized. If the three maxillary anterior teeth included in the resection, they may be added to the prosthesis to improve esthetics.
8. The **existing complete or partial denture** may be modified for use as an immediate surgical obturator. The flange at the defect should be reduced and the posterior teeth removed prior to surgery. Tissue conditioning material may be used to improve adaptation at the time of surgery.



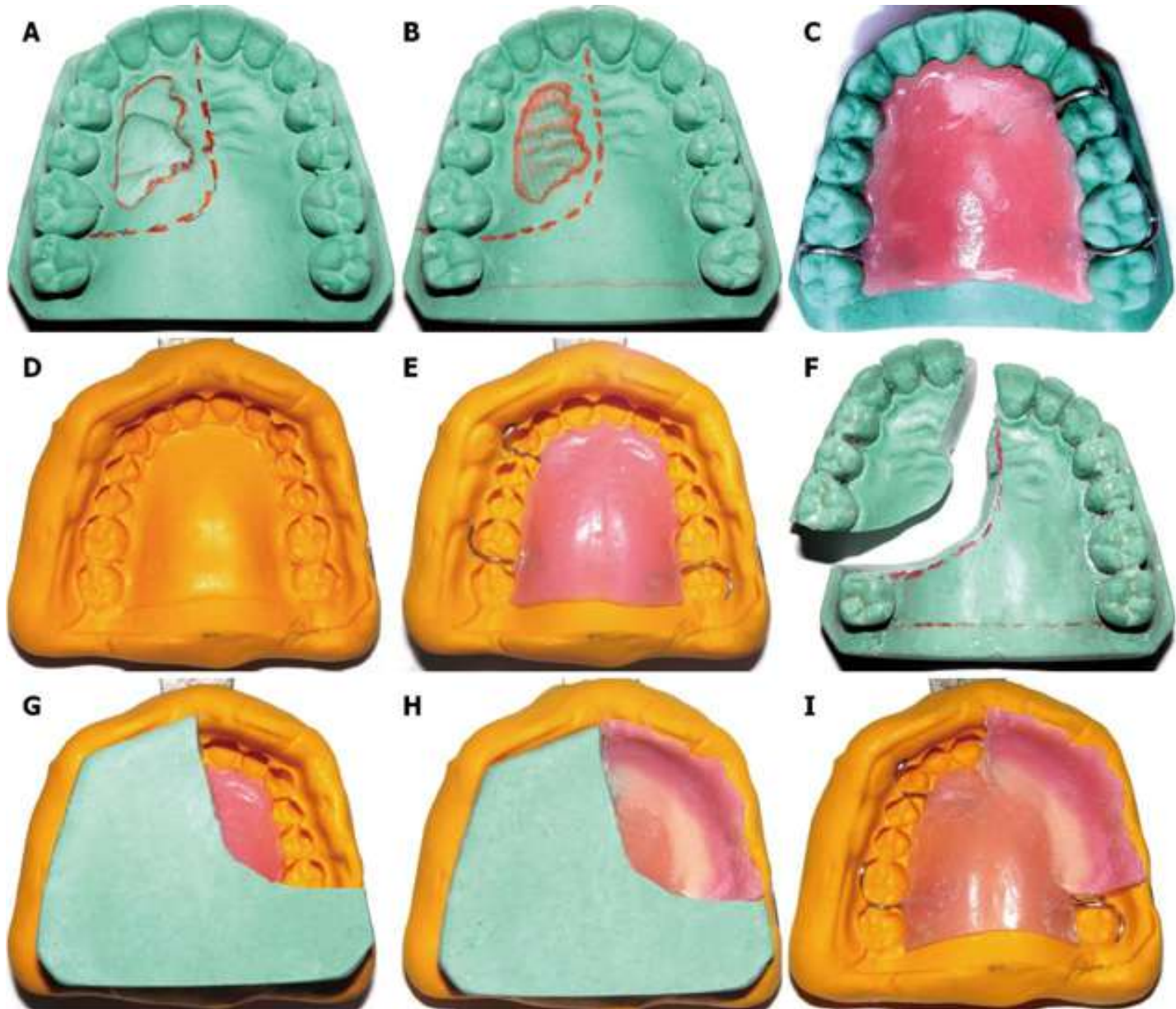
# THE TECHNIQUE OF CONSTRUCTION

- It is important to make an accurate impression of the vestibular depth .on the resected side so that the approximate position of the skin graft mucosal junction can be determined.
- The upper and lower impressions are **poured in stone** and the maxillary cast is duplicated for future reference. The casts are mounted on a suitable articulator with the aid of a jaw relation record.





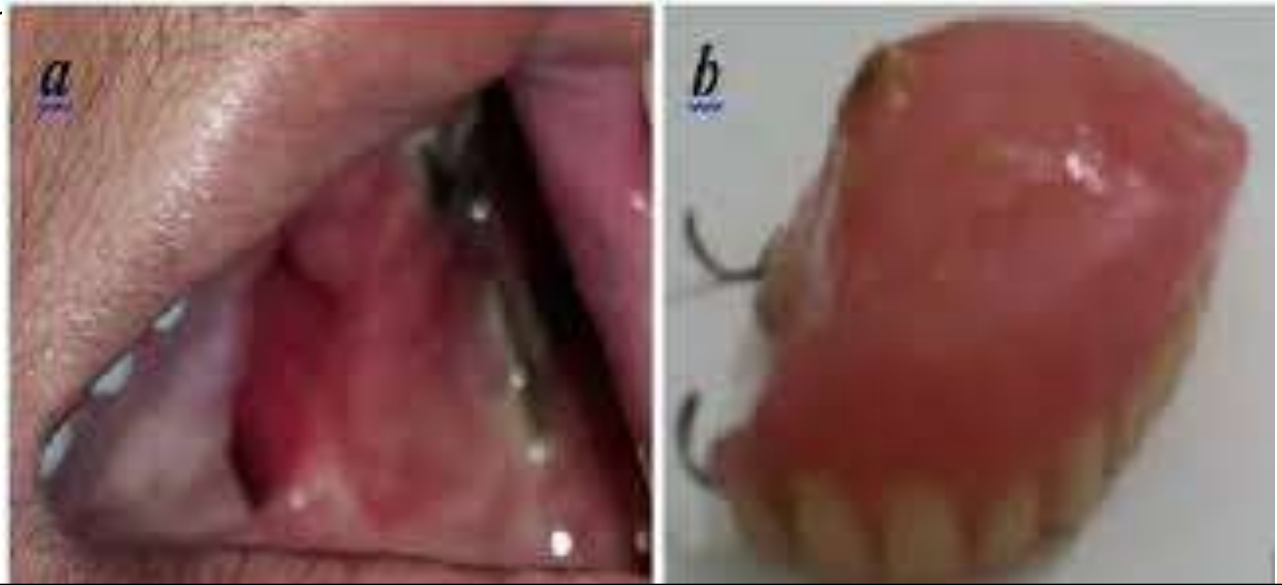# THE TECHNIQUE OF CONSTRUCTION



- The **maxillary cast is altered** to conform to the proposed surgical resection. Teeth on the area involved are cut away from the cast, but alveolar height is maintained. Any elevation on the cast representing the palatal swelling should be removed to give a normal palatal contour. The residual alveolar ridge is trimmed moderately on the labial and buccal surface to reduce the stress on the soft tissue closure.



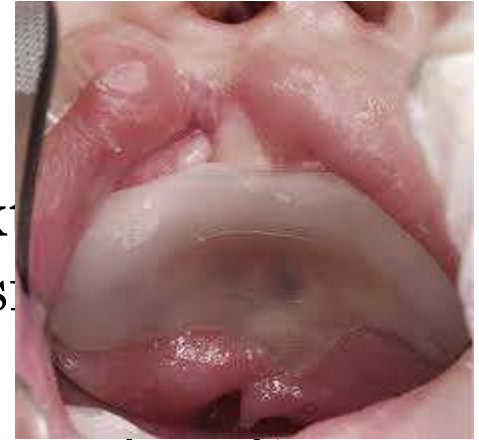- If the pterygoid hamulus is removed during the maxillectomy procedure, the attachment and/or function of the tensor veli palatine, buccinator, and superior constrictor muscles can be compromised due to the medial collapse of the distolateral portion of the defect. In this case the cast should be reduced 2 to 3 mm medially.



- The wire retainers are adapted and the **prosthesis is waxed**, invested and processed in clear acrylic resin , then finished and polished in the normal manner.
- A couple of wire loops is added at the fitting surface to hold the lining material.

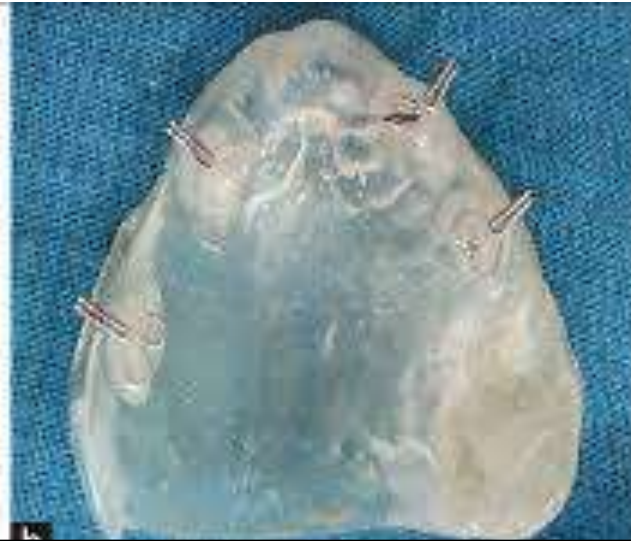
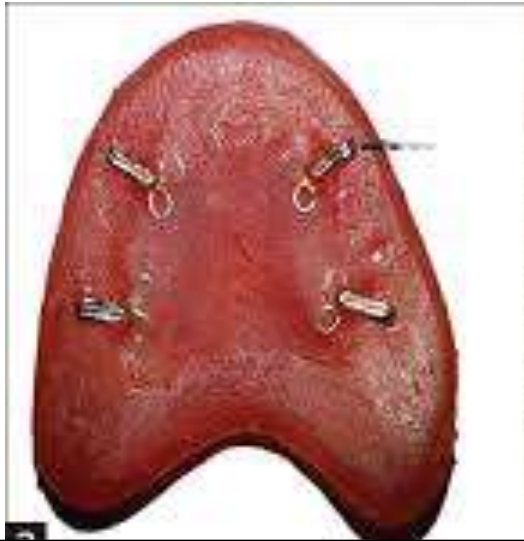
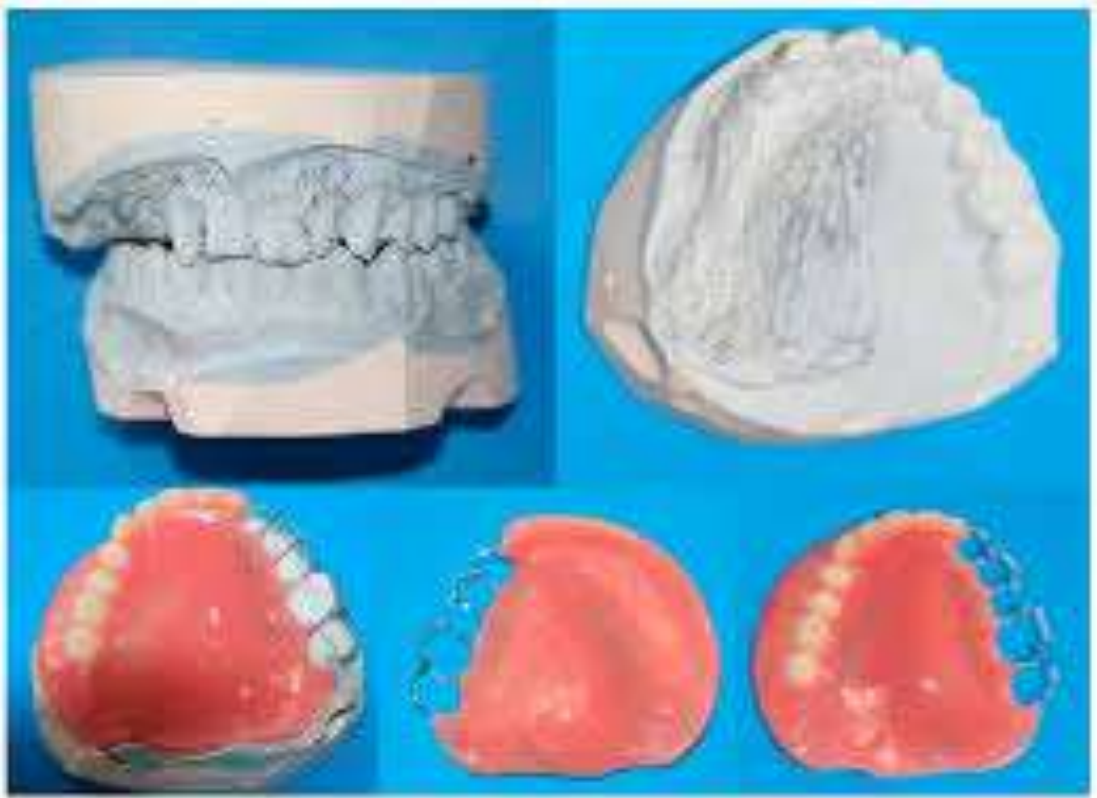- Clear resin is preferred because the extent and possible pressure areas can be easily assessed prior to surgery.
- **Holes are drilled** in the buccal flanges when it is supposed to wire the obturator to the zygomatic arches and/or anterior nasal spine.
- Prior to surgery the obturator is **immersed in a disinfectant** solution, the required instruments are autoclaved, and the dental material are sterilized with gas.





- **Retention** can be achieved in edentulous patients by wiring teeth. In edentulous patients, the denture is wired or pinned to the zygomatic arches and the maxilla and mandible.



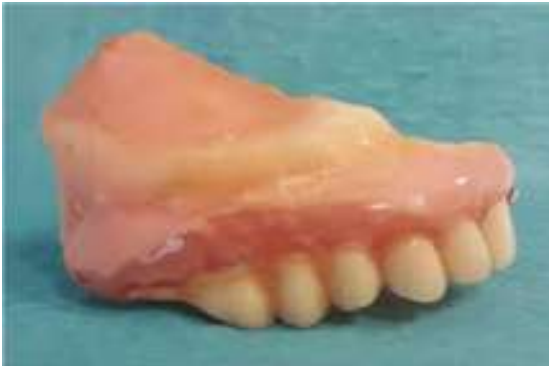

## AFTER 7 TO 10 DAYS POSTSURGICALLY

- The prosthesis and packing are removed. The obturator is cleansed; the wire retainers and minor occlusal discrepancies are adjusted.
- A new application of tissue conditioning material may be made to improve adaptation , seal and comfort.
- The patient is dismissed for one week with the instruction regarding the irrigation and cleaning of the surgical defect properly.



- Usually the patient is **seen every 2 weeks** and the tissue conditioning material changed to suite for tissue contracture. It is better to remove and change all of the lining material to reduce bacterial contamination and mucosal irritation.



Thank you ○



# INTRIEM AND DEFINITIVE OBTURATOR

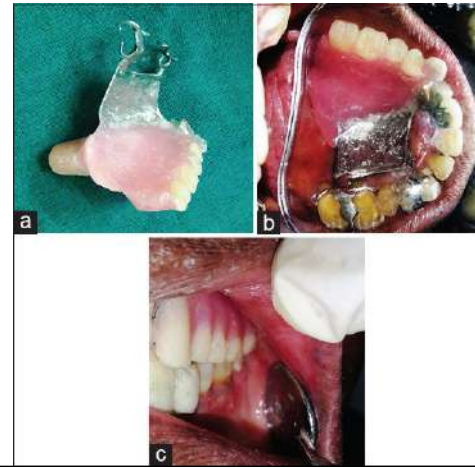
Lect. Hussein T. Abed

26\5\2021

# INTERIM OBTURATOR

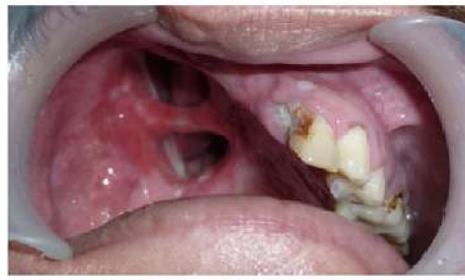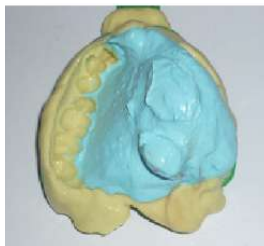A prosthesis that is made several weeks or months following surgical resection of a portion of one or both maxillae. It frequently includes replacement of teeth in defect area.

This prosthesis when used, replaces the surgical obturator that is placed immediately following the resection & may be subsequently replaced with a definitive obturator.



The defect is packed with gauze **dipped in Vaseline** to the level of the remaining tissue, then impression is taken with modified stock tray using elastic impression material.

The steps of construction are the same as in immediate obturator.



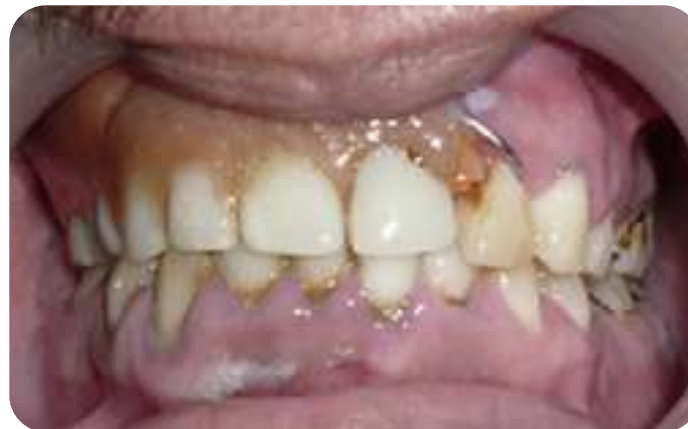

# FUNCTION: HELPS IN RESTORING

1. Speech.
2. Feeding.
3. Esthetics.
4. Prevent wound contamination.

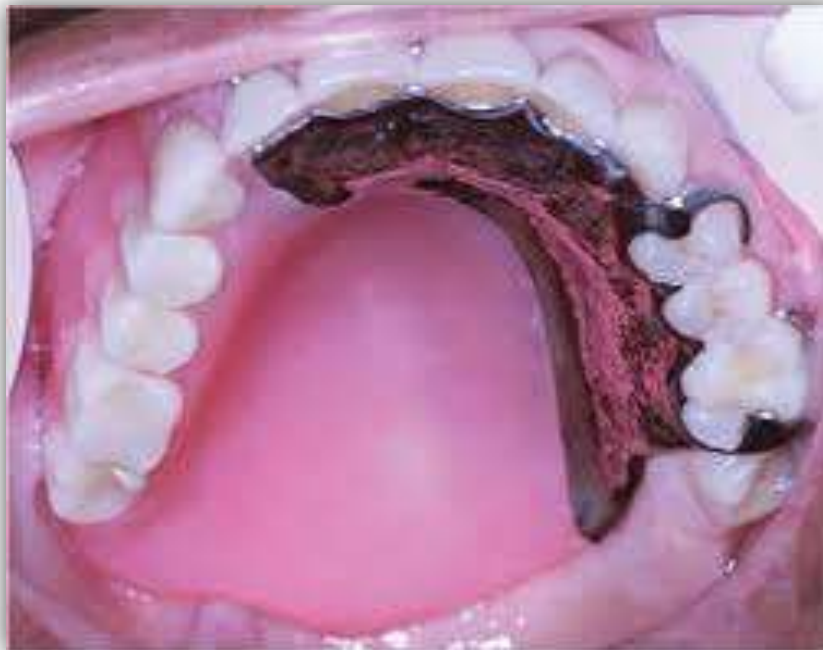## Preparation of the mouth for obturator:

- ◉ Extract hopeless teeth.
- ◉ Periodontal therapy.
- ◉ Restore carious teeth.



# Definitive Obturators

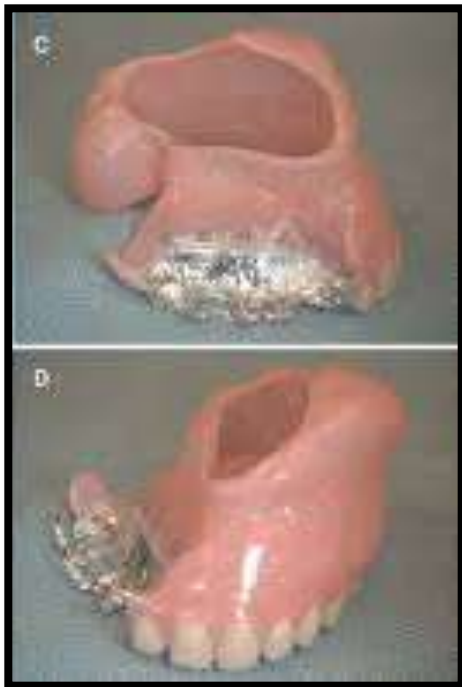
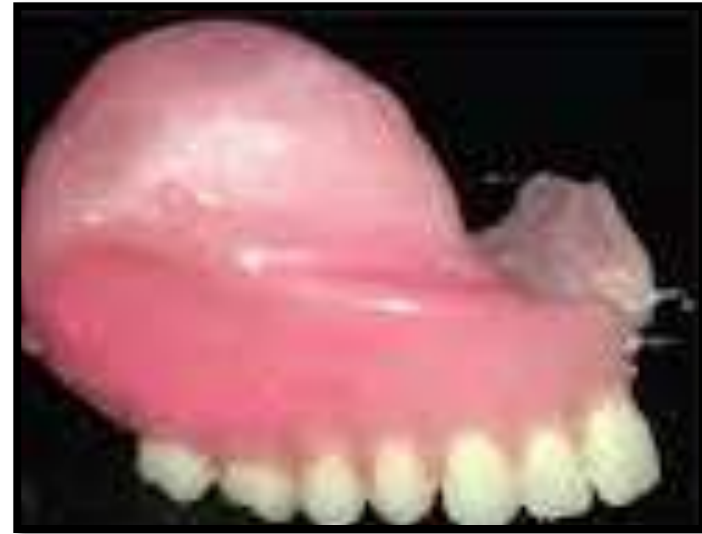1. A prosthesis that artificially replaces part or all of the maxilla & the associated teeth lost due to surgery or trauma



# Definitive Obturators

Types of obturators:

- Hollow bulb (Closed).
- Roofless (Open bulb).



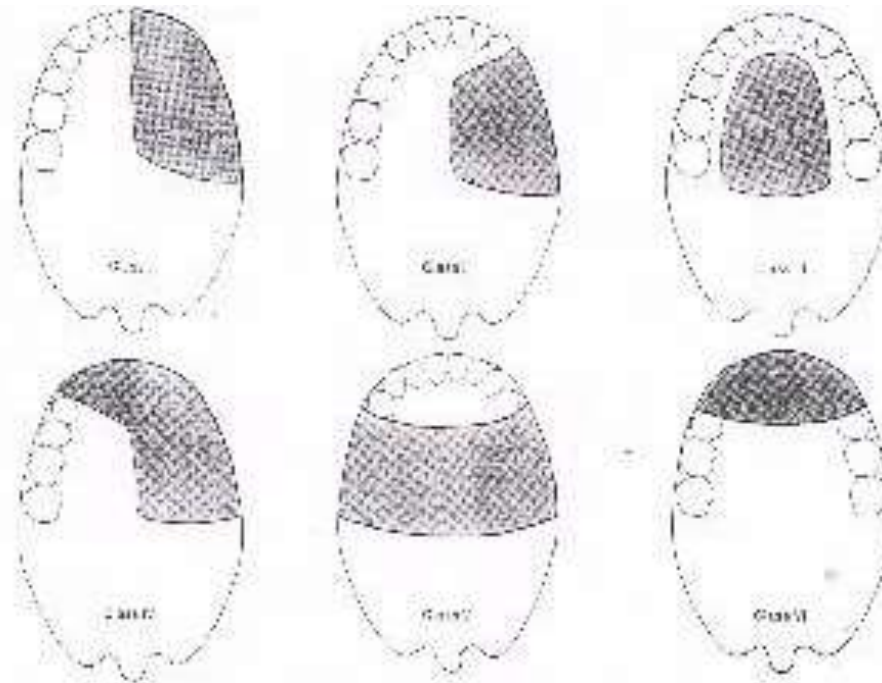
# Definitive obturator:

It is constructed **3-4 months** after surgery. The timing will very depending on many factors:

1. The size of the defect.
2. The progress of healing.
3. The prognosis for the tumor.
4. The effectiveness of the present obturator.
5. The presence or absence of teeth

# The prognosis of definitive obturator depends on (Treatment concepts):

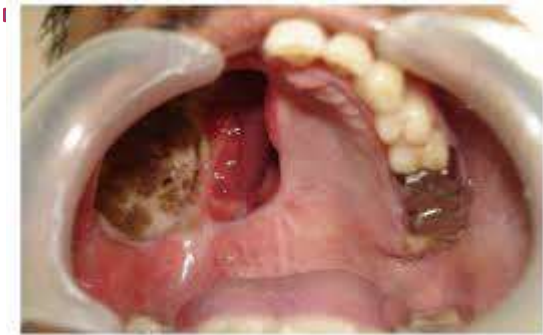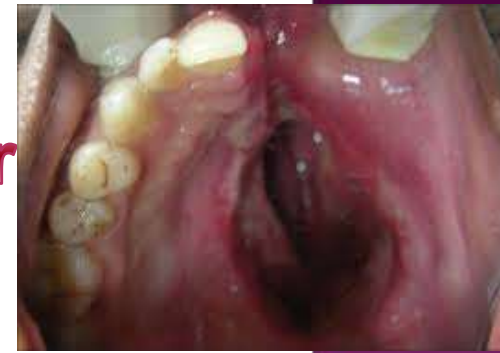**1. Defects classification** : Maxillary defects have been conveniently classified according to the defect location and its relation to the remaining teeth by Aramany, 1978.



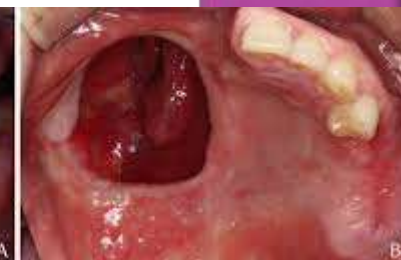
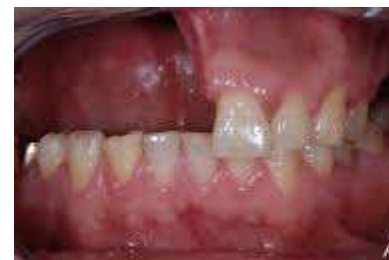
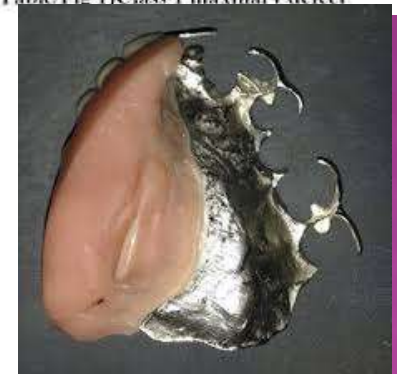**The prognosis of definitive obturator depends on (Treatment concepts):**

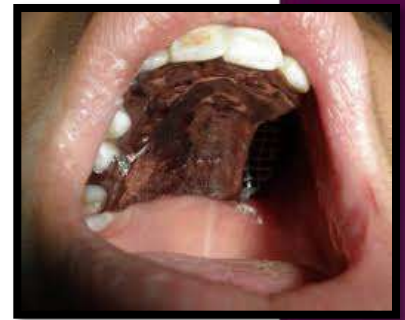- 2. Movement of the prosthesis.**
- 3. Tissue changes.**
- 4. Extension into the defect.**
- 5. Length of the lever arm**
- 6. Arch form**
- 7. The weight of the prosthesis.**
- 8. The presence of teeth.**
- 9. Covering prostheses**



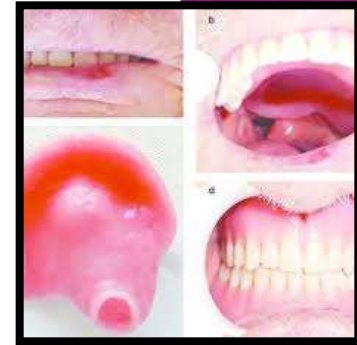(Table/Fig 1) Class I maxillary defect



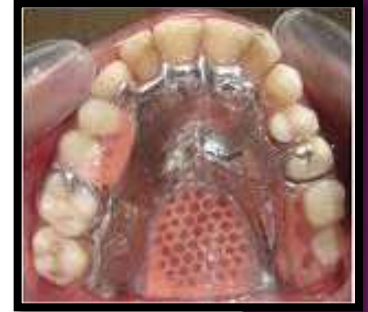# Guide lines for location of the obturator



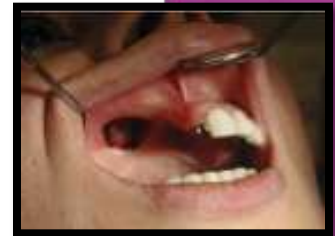- 1- The obturator should be located in the **nasopharynx** at the level of normal palatal closure.
- 2- The inferior margin of the obturator should be placed at the level of **greatest muscular activity** exhibited by the residual palatopharyngeal complex.
- 3- The inferior extension of the obturator will usually be an extension of the **palatal plane** as extended to the posterior pharyngeal wall.



# Methods of construction:

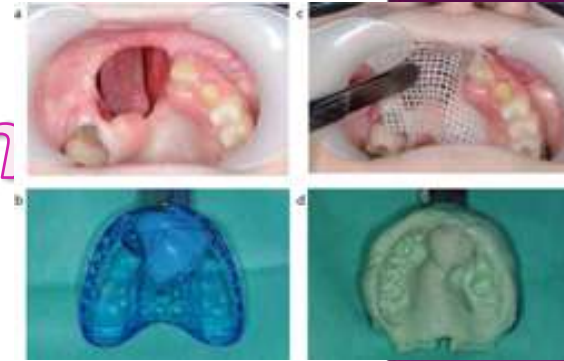


- ✓ Impressions .
- ✓ Multiple occlusal rests on either sides of the fulcrum line will increase stability and resist the downward displacement of the obturator.
- ✓ Multiple retainers should be used with the retentive arms engaging distal undercuts.
- ✓ If the patients has an anterior edentulous area, crown should be placed on the adjacent abutment teeth with the attachment of an anterior bar



# *Technique of construction*

## *Impression technique:*

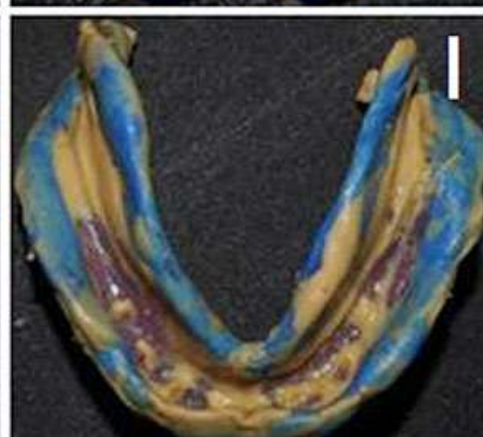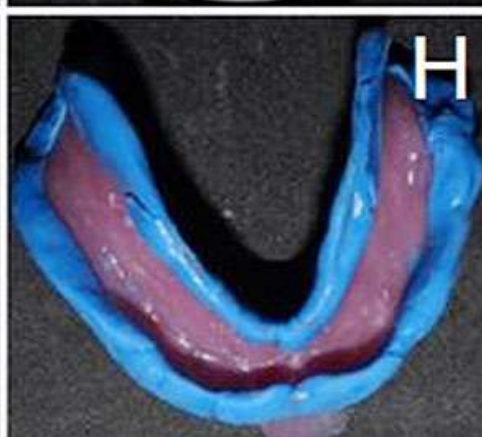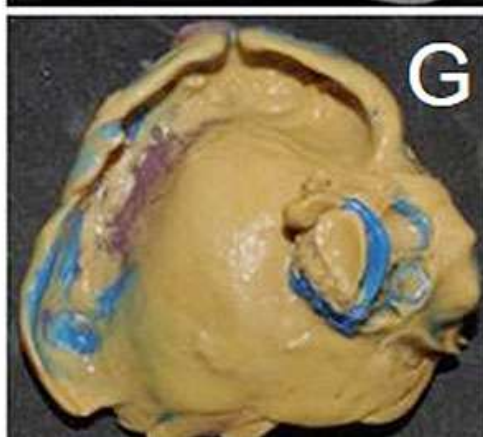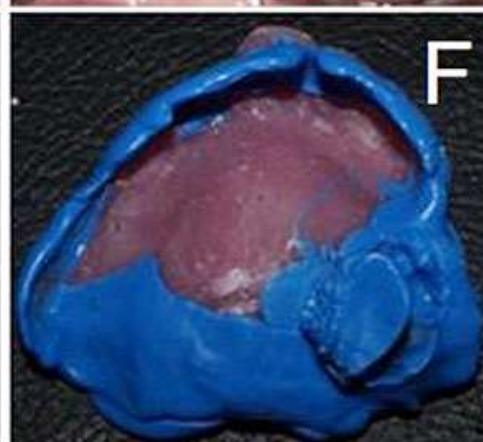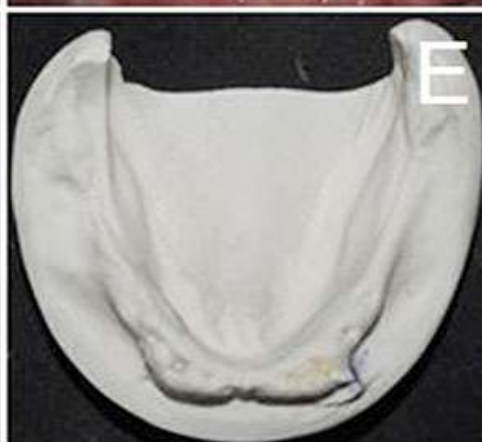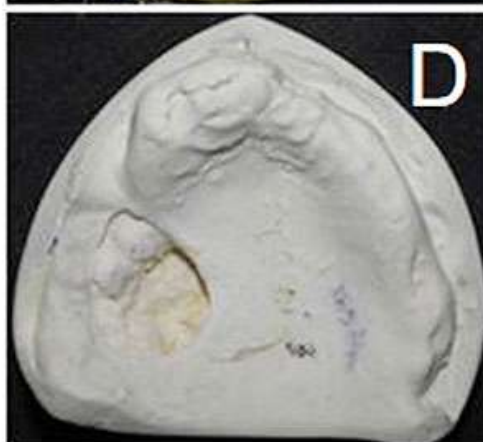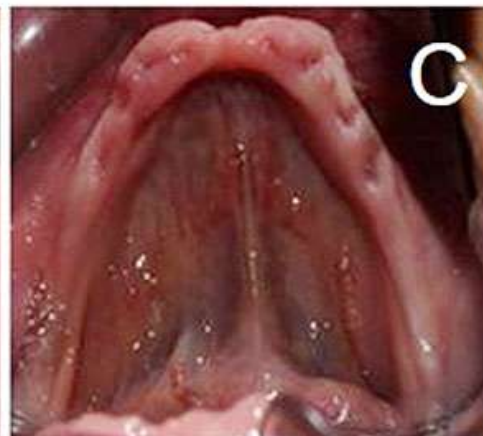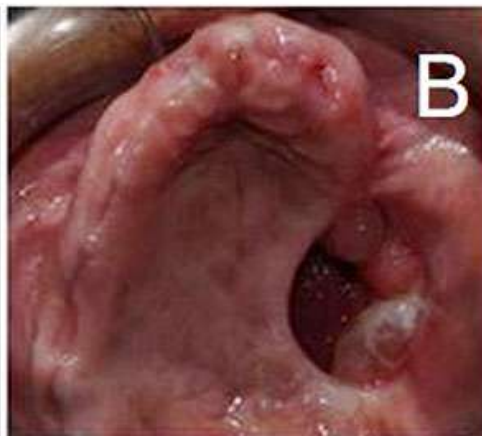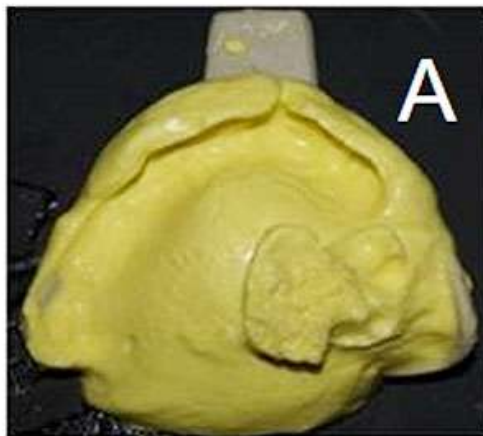


- An edentulous suitable **metal tray** is selected and altered. The medial and anterior undercuts are blocked out with vaselineated gauze.
- **Adhesive** is applied to the tray and alginate is mixed and loaded in the tray. Prior to seating the tray, impression material is wiped or injected into posterior and lateral undercuts.
- Cast is poured, and the undesirable undercuts are blocked out with wax.



- Elastomeric impression material is prepared and injected into desirable undercut areas and the loaded tray is seated into position. The lips and cheek are manipulated and the patient is instructed to perform eccentric mandibular movements to account for the movement of the anterior border of the ramus and the coronoid process of the mandible. After the material has set, the impression is removed with a gentle teasing action.

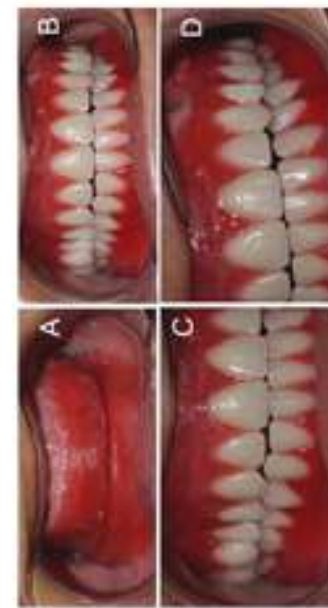





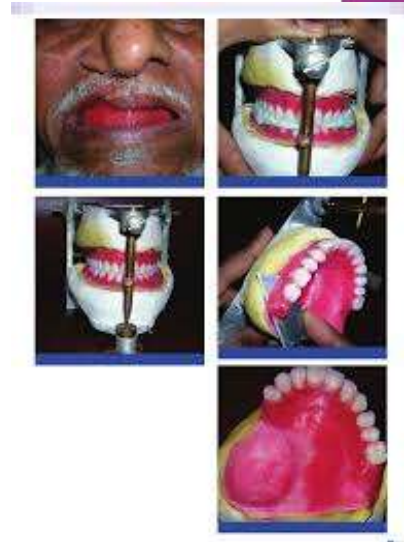
# Recording of jaw relationship

- If the defect **is large** and stability and support are difficult to obtain with a conventional record base, the *definitive base is fabricated from the master cast*. This base is used in recording jaw relation and at a later time the denture teeth are added with self curing acrylic resin.
- If **stability and support are adequate**, a conventional self curing acrylic base is constructed after blocking of all undercuts and the rugae area to protect the master cast.
- The vertical dimension of occlusion is determined in the usual manner using wax rims on the record bases.

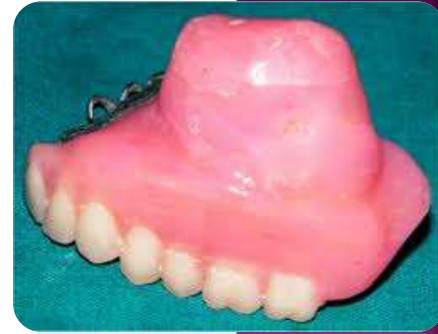

**Nonanatomic posterior** teeth are preferred and adjusted to eliminate lateral deflective occlusal contact.

The **trial denture** are tried in the mouth and changes are made to accommodate the esthetic desires of the patient and the prosthodontist.

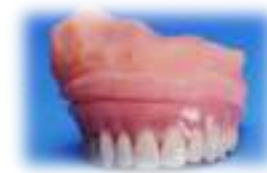

## *Processing, delivery and follow up:*



- ◉ The obturator with the denture are processed in *heat-cured acrylic resin*.
- ◉ The superior surface of the obturator should be slightly convex and well polished. Any sharp projection on the lateral surface of the obturator should be rounded and polished with pumice. Polishing improve **cleansibility** and **reduce the friction** between the prosthesis and soft tissue during functional movements.

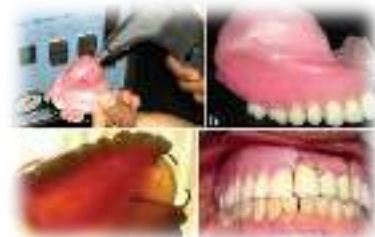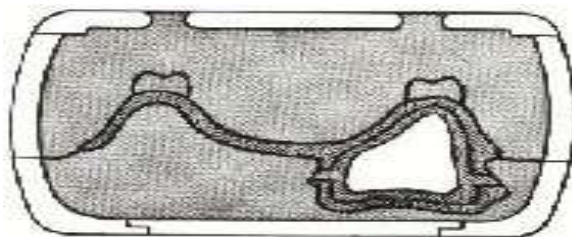
- ◉ If more retention is necessary, **soft silicon material** is used for the obturator segment to engage undercuts more profoundly.



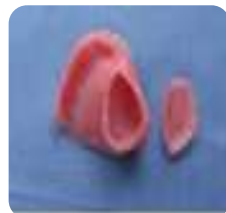- ◉ Home care instructions are reviewed and recall appointments are arranged. Most maxillary obturator will require **rebasing** within the first year because of dimensional changes of the defect.

## To obtain hollow bulb:

- Bulky areas should be hollowed to reduce weight to avoid unnecessary stress to the teeth and supporting tissues. The hollowing is done **during packing** the acrylic resin, by **placing a sand bag** between the acrylic resin in the middle of the defect. After curing a small hole is made on the fitting surface to empty the obturator from the sand. Then the hole is closed with **self cure acrylic resin**.



- ◉ The superior surface may be closed to avoid accumulation of the nasal secretions leading to odor and added weight, or left open to decrease the weight and is easier to adjust. In the open type if secretions do tend to accumulate, a small diagonal opening may be made between the inferior-lateral floors of the obturator through to the cheek surface for drainage.



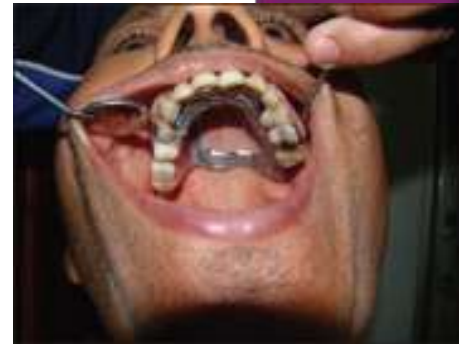

# Advantages of hollow bulb:

- ◉ The **weight** of the prosthesis is reduced, more comfortable and efficient.
- ◉ The lightness of the prosthesis **increases retention** & physiologic function.
- ◉ The **decrease in pressure** to the surrounding tissues aids in deglutition and encourages the regeneration of tissue.
- ◉ The light weight of the hollow bulb obturator does **not add to the self-** consciousness of wearing a denture.
- ◉ The lightness of the prosthesis **does not cause** excessive atrophy and physiologic changes in muscle balance.

# General principles for the design of obturator

1. The need for a **rigid major** connector;
2. **Guide planes** and other and other components that facilitate stability and bracing;
3. A design that **maximizes support**;
4. **Rests** that place supporting forces along the long axis of the abutment tooth;
5. **Direct retainers** that are passive at rest and provide adequate resistance to dislodgment without overloading the abutment teeth; and
6. Control of the that opposes the defect, especially when it involves natural teeth.

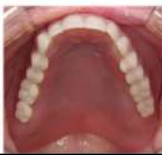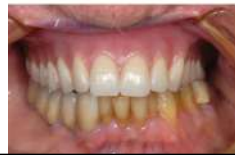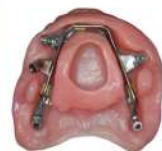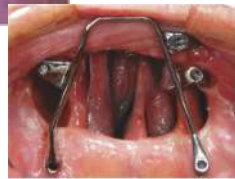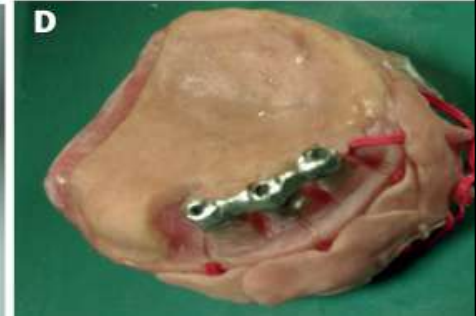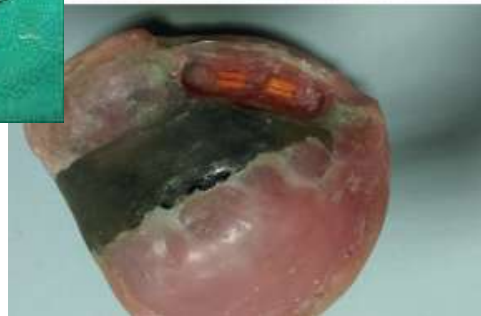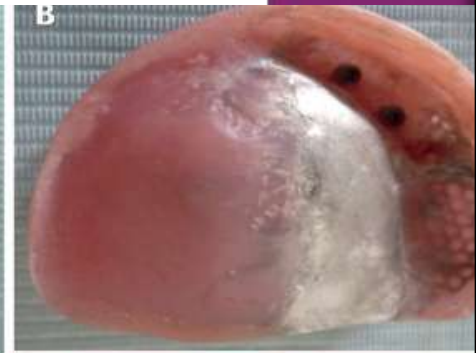
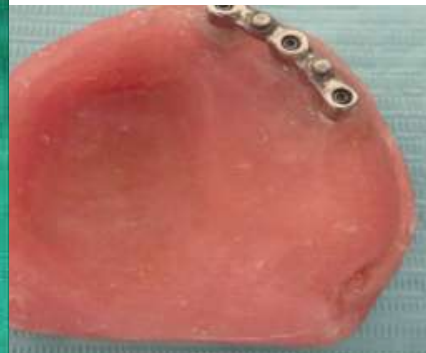
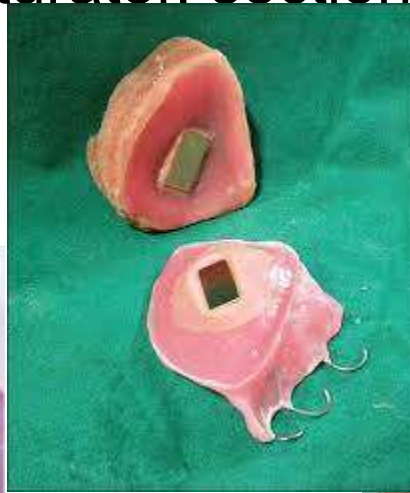


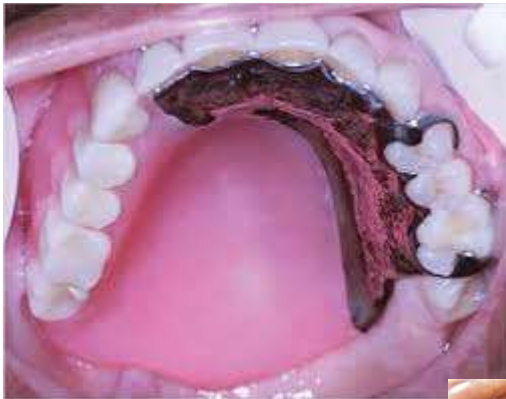# Methods to Improve Retention of Acquired Obturators

1. Engagement of the scar band .
2. Extension of the obturator against the lateral wall of the defect .
3. Resilient lining material.
4. Hollowing the obturator portion.
5. Refitting the base.

# Methods to Improve Retention of Acquired Obturators

6. Osseointegrated dental implants
7. Two piece obturator. sectional obturator.
8. Magnets.
9. Clasping.



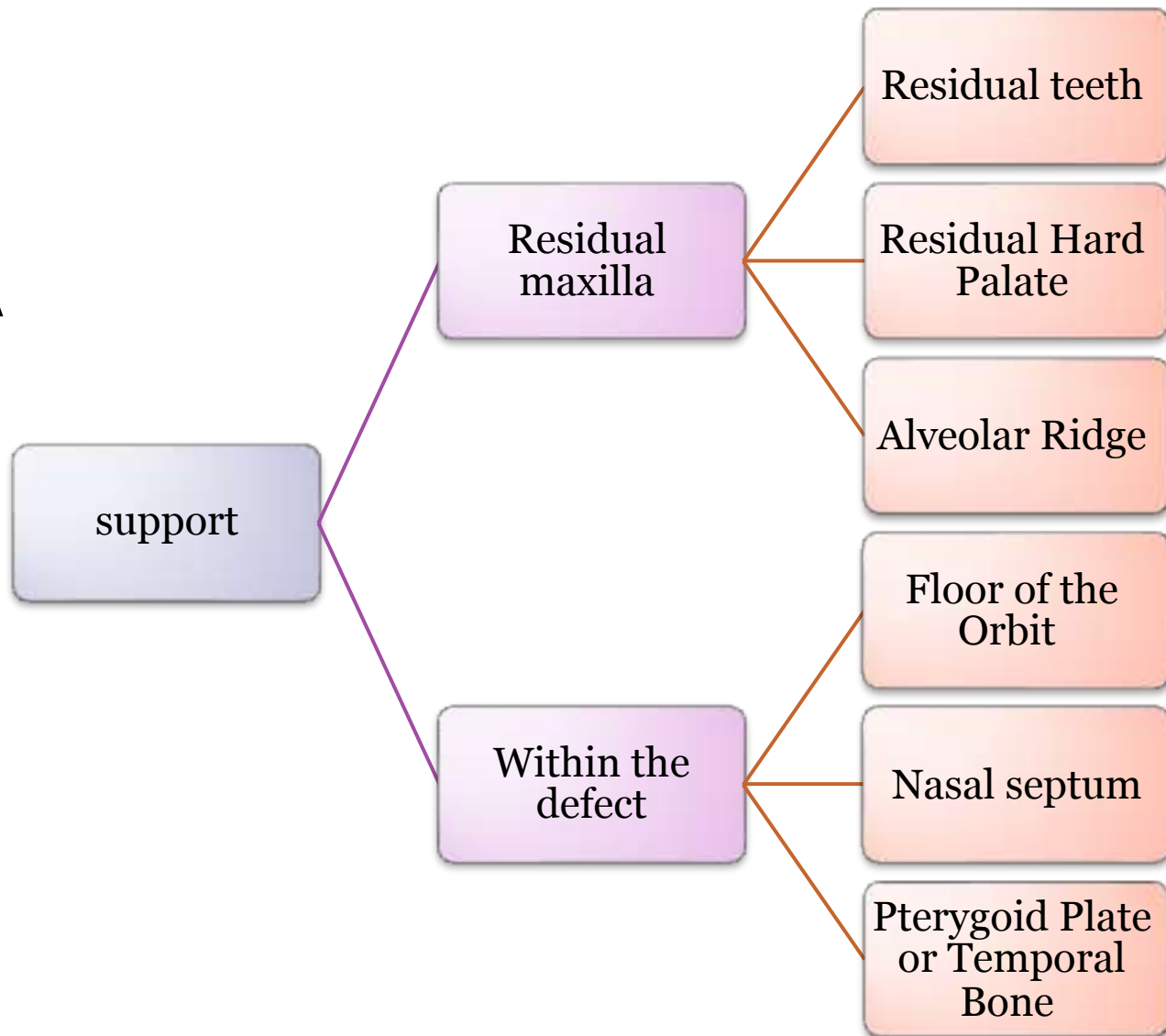
Thank you

# Maxillary obturator: complications

Lect Hussein T. Abed

2.6.2021





# RETENTION

Within the residual  
maxilla

Teeth

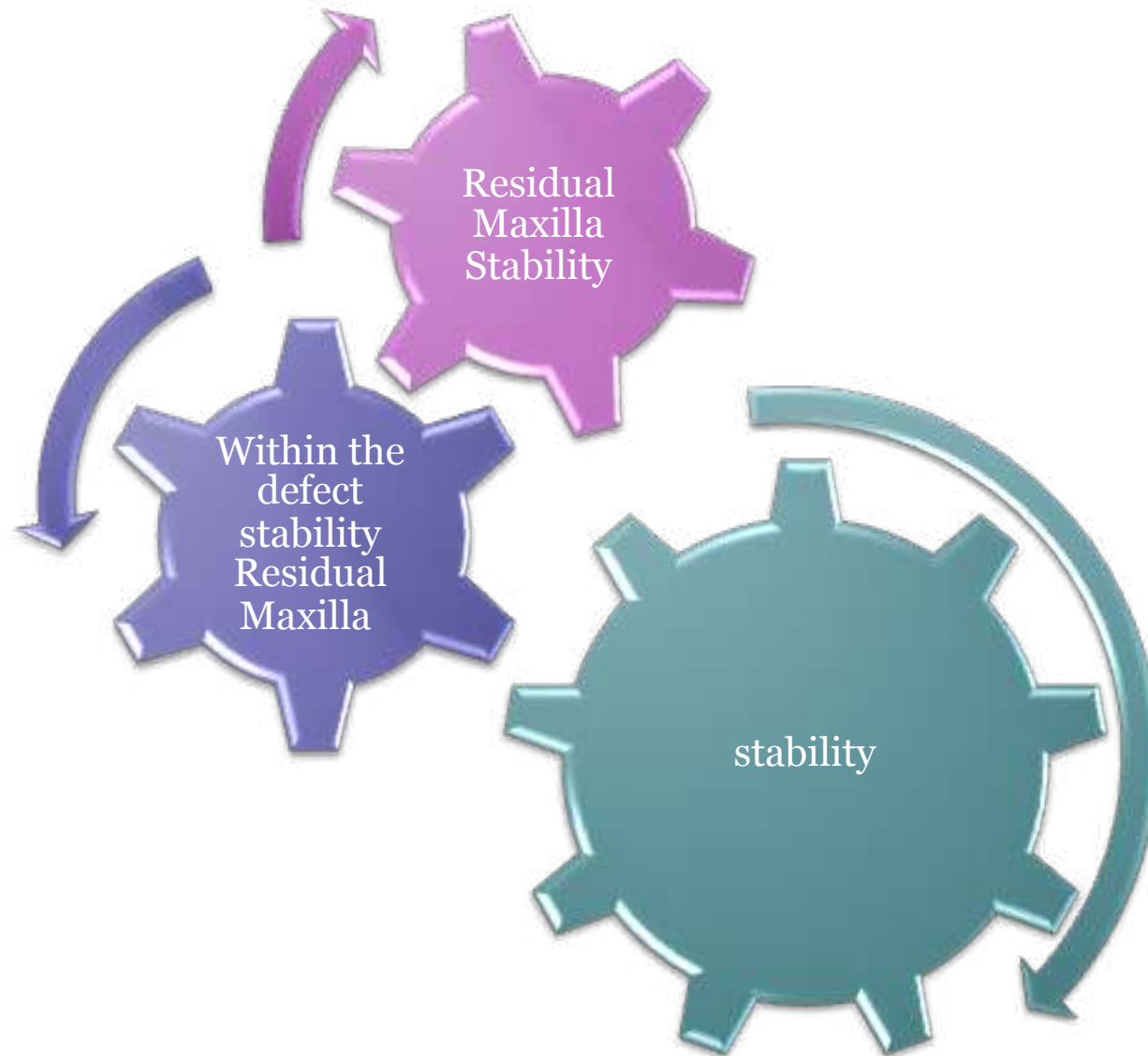
Height  
of  
lateral  
wall

Lateral  
Scar  
Band

Alveolar Ridge

Residual  
Hard  
Palate

Residual  
soft  
palate



# Trouble shooting of obturator

- 1. **nasal reflux and hypernasal speech** caused by escape of air. This is mainly due to continued fibrosis of the tissues bordering the prosthesis. Leakage into the nose
- The prosthesis should be disclosed with a tissue-conditioning material, and the patient should perform functional movements. If swallowing and speech improve, the disclosing material should be evaluated for the area where the tissue conditioner is thickest.

- The speech can be tested by evaluating the “m” and “b” sounds and the word beat.
- The thickness of the material can be checked with an explorer. Most areas will be very thin, while other areas will be 2–3 mm or thicker. These thicker areas should be targeted for the reline procedure. This reline can be accomplished chair side with an autopolymerizing or composite acrylic resin (Triad). This procedure satisfies the patient’s chief complaint and requires minimal time.

## 2. Hypernasal speech

Disclosure of the bulb with a tissue conditioning material often reveals that the surface contact is adequate. In this situation, the prosthesis is adequately closed at the periphery, but the patient's soft palate and pharyngeal closure mechanism are not functional. This condition is seen frequently when a portion of the soft palate was also resected due to a lesion located at the hard palate-soft palate junction. Relining of the prosthesis periphery will not alter the hypernasal speech.



Lect. Hussein T. Abed

16/6/2021

# NASAL DEFECT: ANATOMY AND IMPRESSION

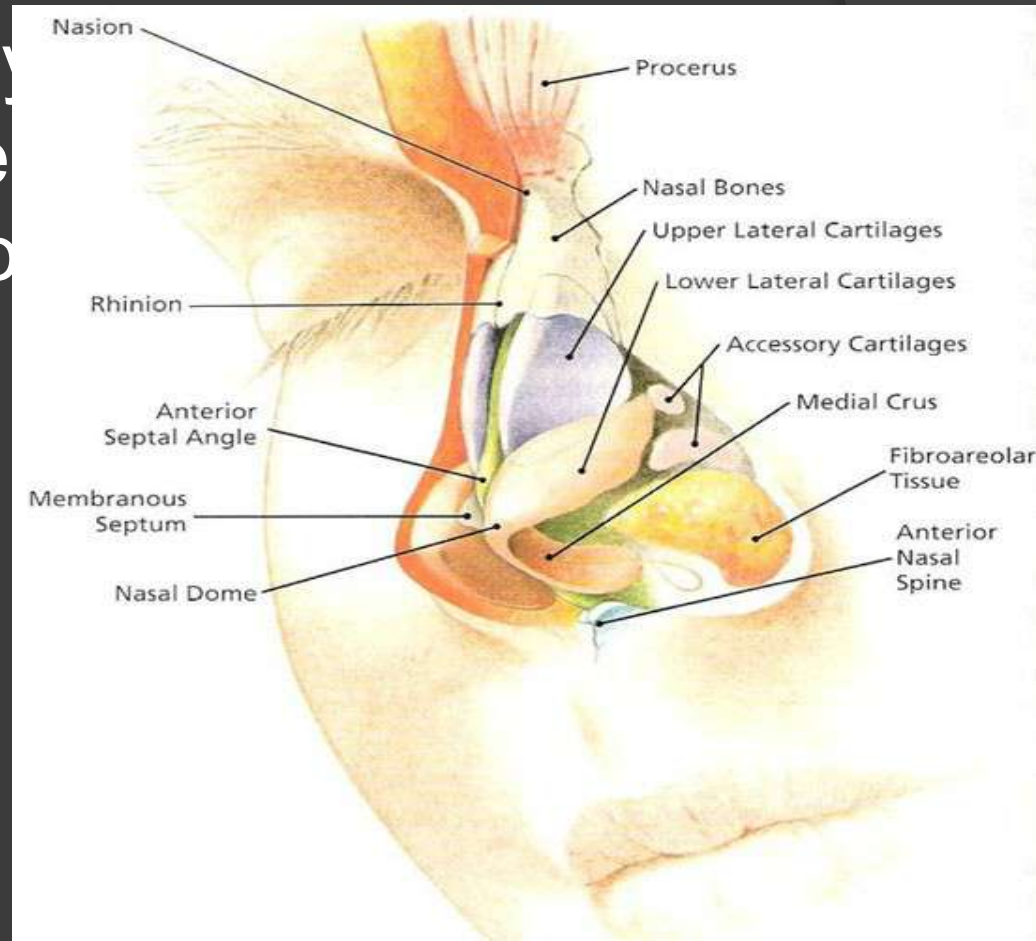
# Rehabilitation of facial defects

Surgical reconstruction verses prosthetic restoration: It depends on :

- 1-the size of the defect.
- 2-the etiology of the defect.
- 3-the age of the patient.

# Anatomy of the nose

- The nose is a highly pyramidal structure on the face and it is composed of:
- Skin
- Mucosa
- Bone
- Cartilage
- Supporting tissue



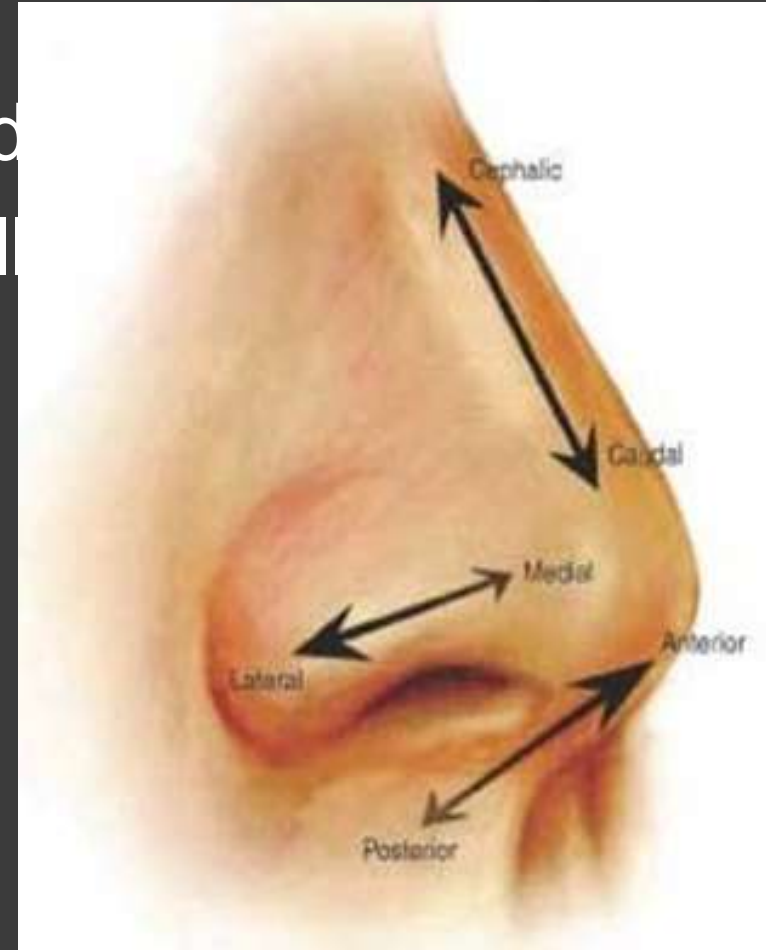
# Topographic analysis



# Anatomy of the nose The nose is formed of:

**A-external structures:** it includes

- 1-The tip of the nose(columella)
- 2-The dorsum of the nose.
- 3-The bridge of the nose.
- 4-ala of the nose.
- 5-The nares.
- 6-The nosolabial folds.

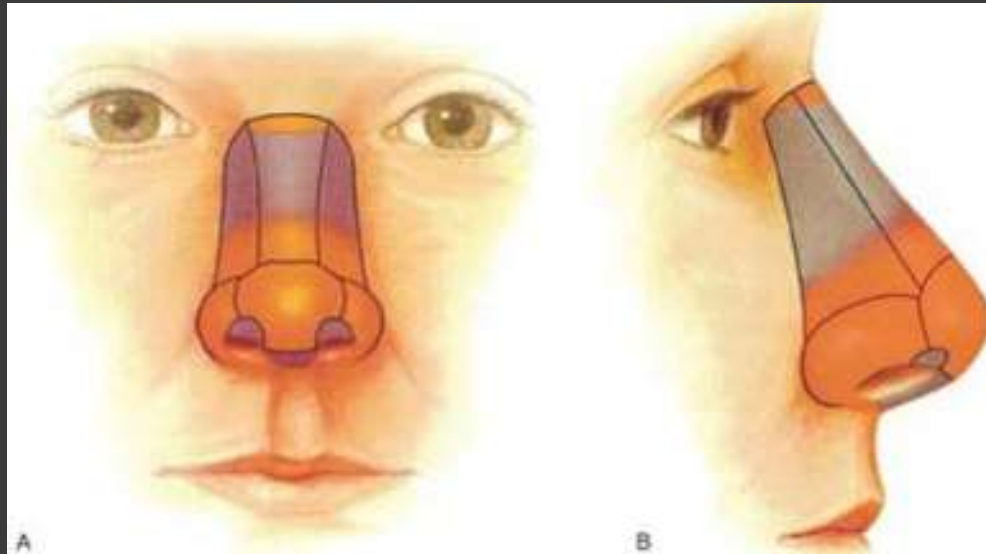


# Thicker

Dorsum  
Nostril margins  
**Columella**

# Thinner

Radix  
**Nasal tip**  
Alae





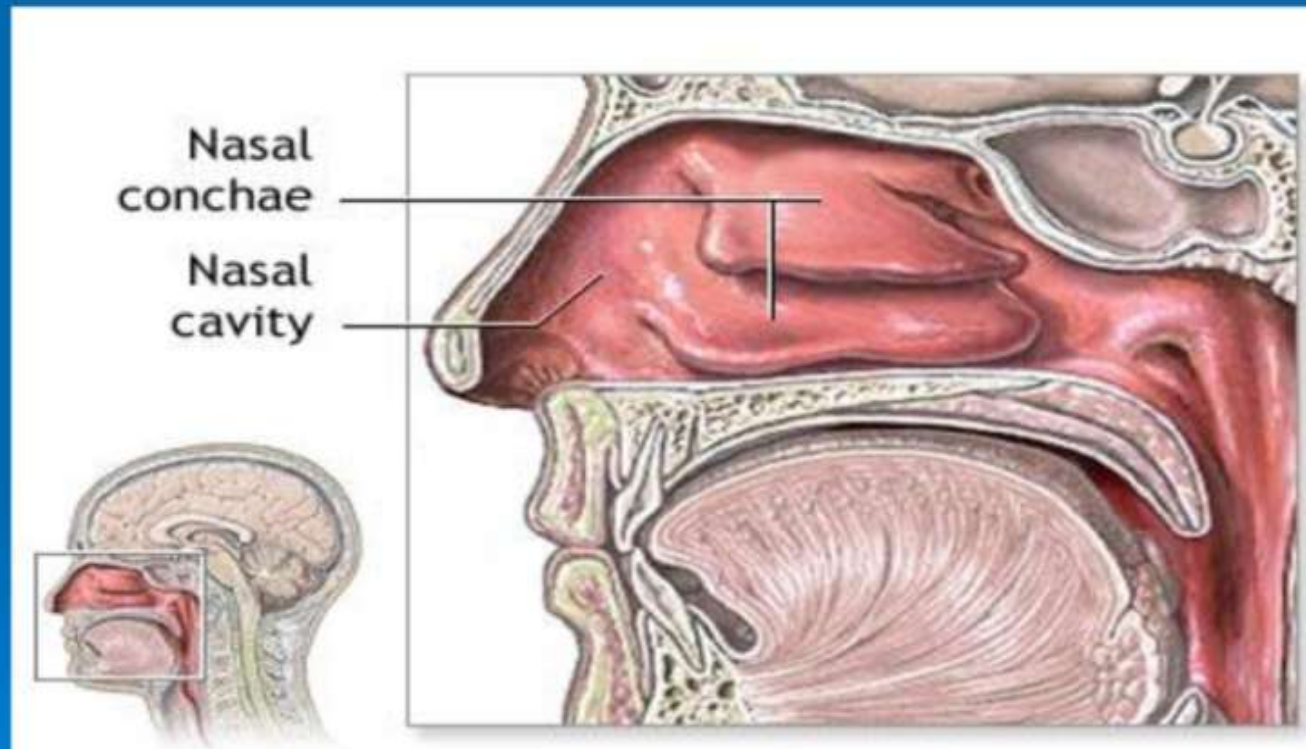
# B.Internal nasal anatomy

it includes

1-Nasal

2-Nasal  
posterior

## Anatomy of the nose



# Surgical reconstruction of defects

For reconstructing of the nose four basics should be followed:

- 1-Adequate flap length.
- 2-Avoiding tension.
- 3-Providing a base for the new nose.
- 4-Establishing one-piece reconstruction

# Prosthetic restoration of nasal defects

The majority of nasal defects are secondary to treatment of neoplasm.

Most partial nasal defects are restored with **surgery** while total nasal defects are restored **prosthetically**

# Materials used for facial prosthesis

1-Acrylic resins (not use now).

2-Acrylic copolymers.

3-Vinyle polymers & copolymers(Mediplast

4-Polyurethane elastomers. (Epithane-3)

5-Silicone elastomers: it is available in two forms:

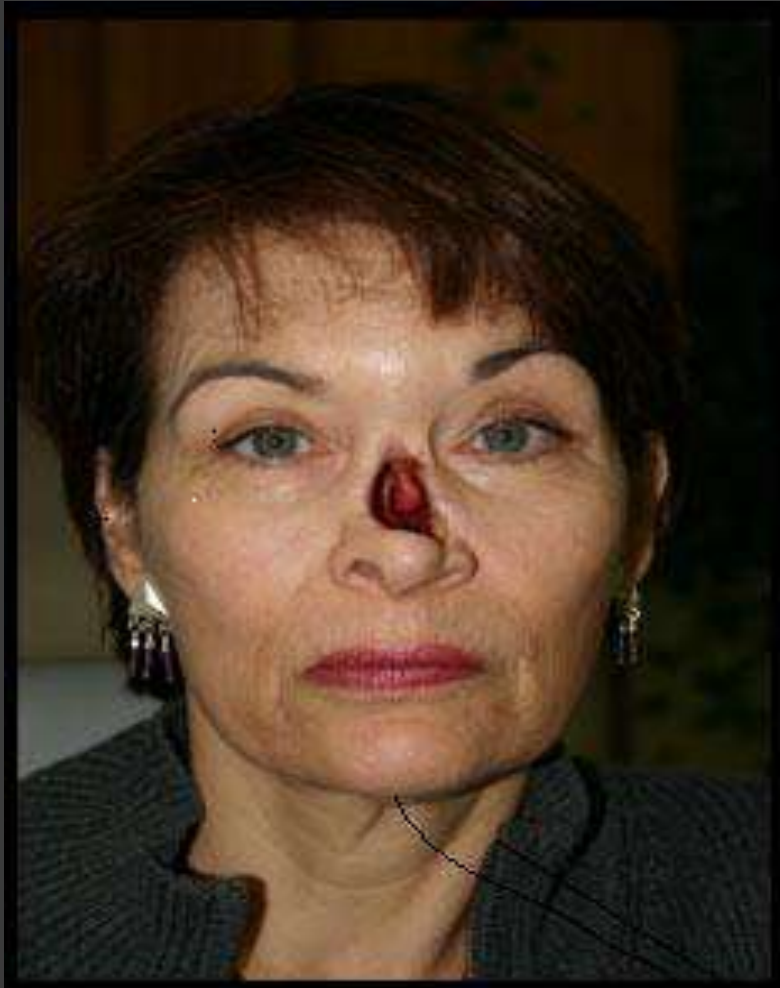- HTV.

- RTV.

Most commonly used materials for facial restoration



# Before and after surgical reconstruction





# Before & after surgical reconstruction



# Pre-prosthetic consideration

- 1- the surgeon should **remove the nasal bone** as well as the rest of the nose.
- 2-the wound should **not be closed** primarily.
- 3-The placement of split thickness skin over exposed tissue bed areas is **preferable**.
- 4-Prior to surgery ,**facial impressions** & photographs should be obtained.
- 5-**Psychological** evaluations & consultations should begin prior to the resection

# Main problems of nasal prosthesis

1-**Retention** of large nasal restoration.

2-**Esthetic** of the prosthesis.

3-**Color** matching.

There are intrinsic & extrinsic coloration.

The **intrinsic** coloration are more stable while **extrinsic** coloration wear rapidly because of ultraviolet rays & surface oxidation.

# Impressions

Prior to surgery ,facial impressions are preferred because they provide useful information for clinician.

Steps:

- 1-The pt is in **upright position**.
- 2-**Elastic** impression materials is used as Irreversible hydrocolloid.
- 3-The nasal passage should **be blocked** out with gauze.

# Impressions

The gauze used to cover the **middle nasal conchea** because it contains ridges & part of impression materials may cut inside it and act as foreign body.

Prosthodontist prefer irreversible hydrocolloid because it has low tear strength & high flow.

Facial impression is carried out for the pt.

# Steps of impressions

4-Using the preliminary cast ,master impression tray is fabricated confined to the defect area.

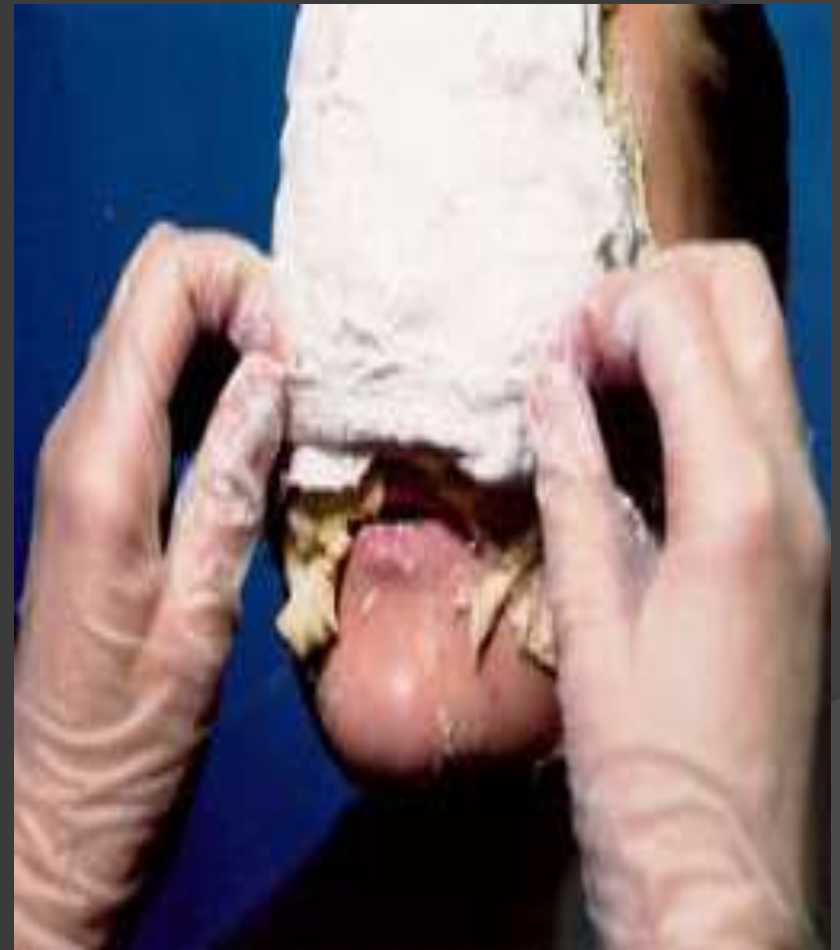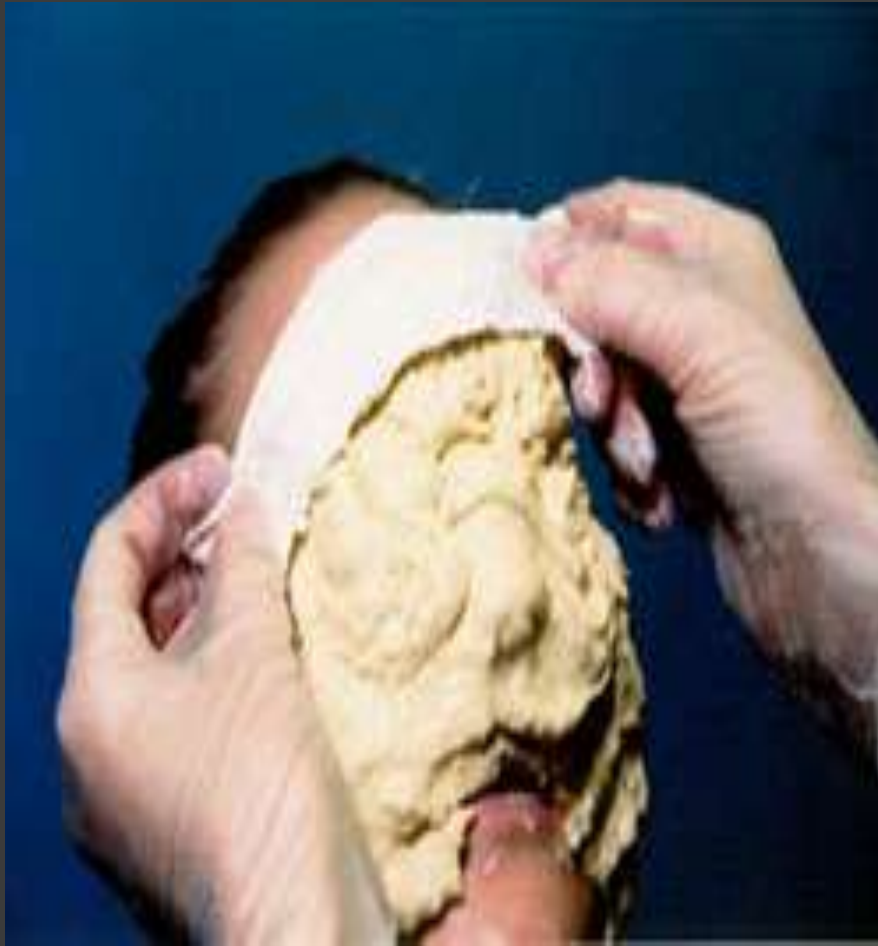5-A syringe is used to inject impression material to areas of difficult access.

6-Taking care not to compress the tissue bed.

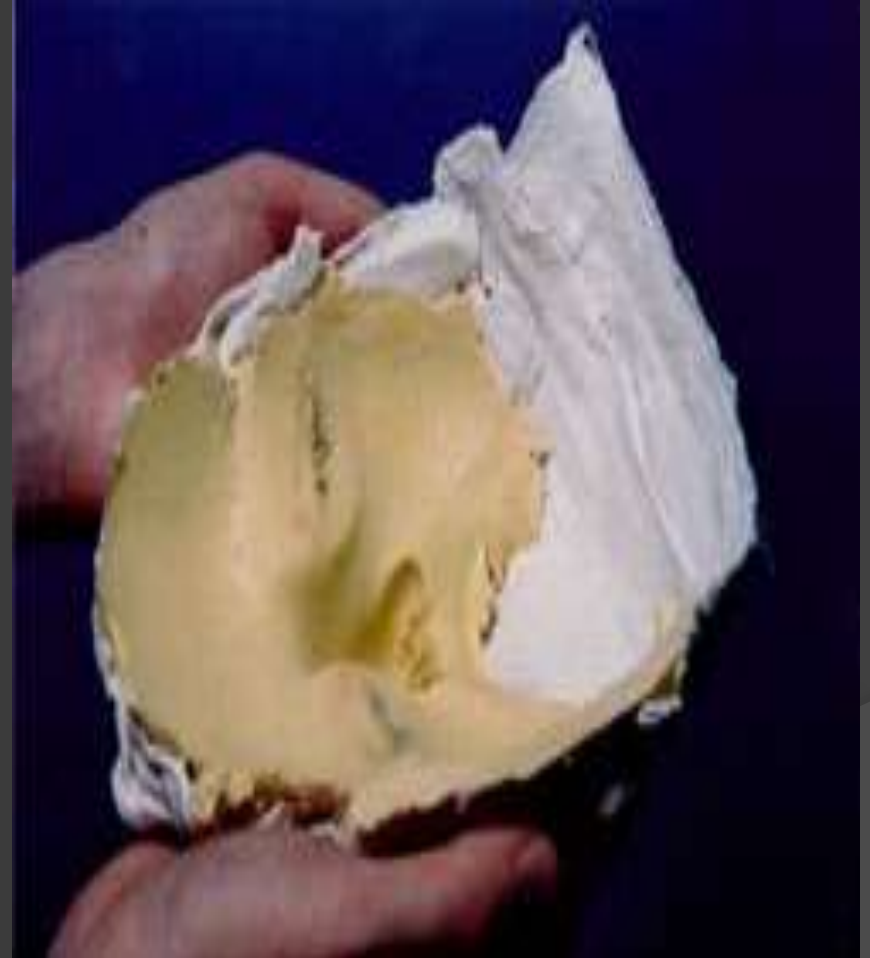6-After setting of the impression, a master cast of dental stone is prepared.



# Steps of impressions



# Steps of impressions



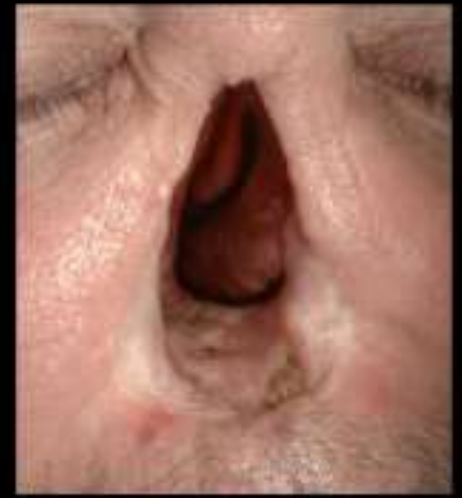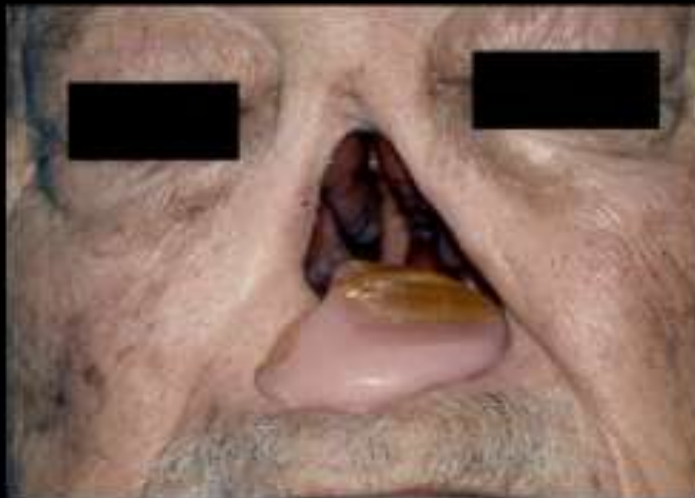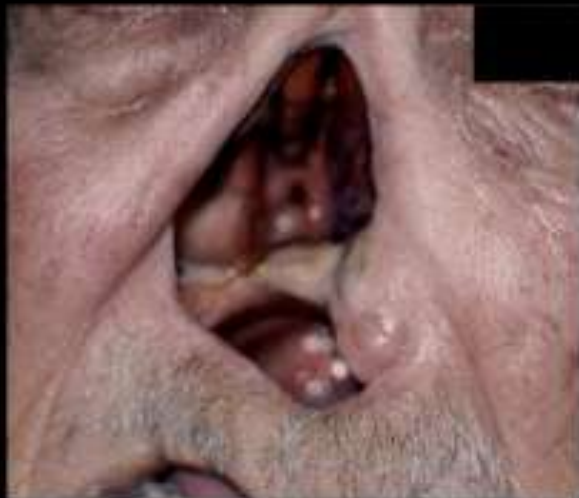# Steps of impressions



# Impressions

Evaluate the defect to determine the extension of the prosthesis

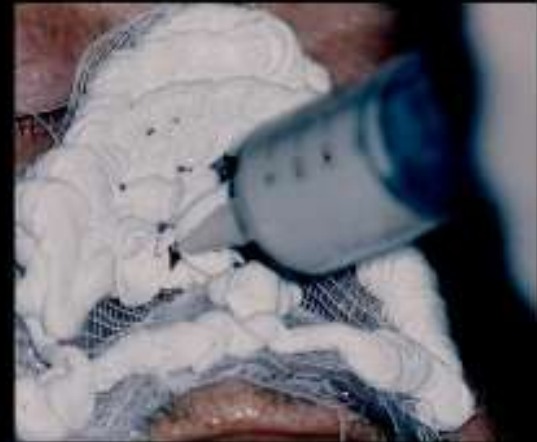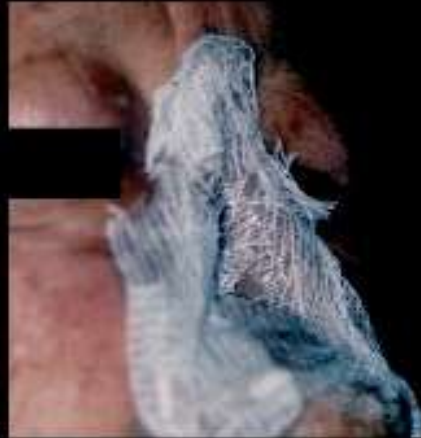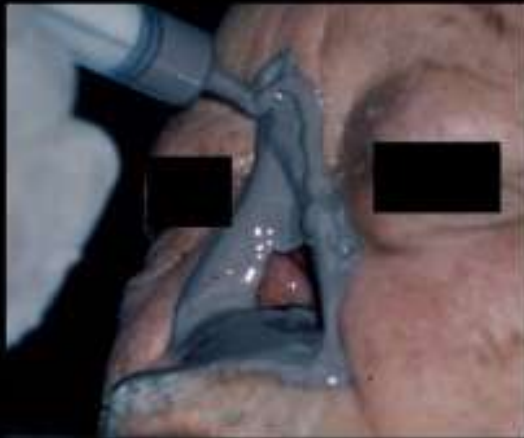- ❖ Can the floor of the nose be engaged for support
- ❖ Can undercuts in the defect be used to enhance retention and stability
- ❖ Does the lip require support from an oral prosthesis





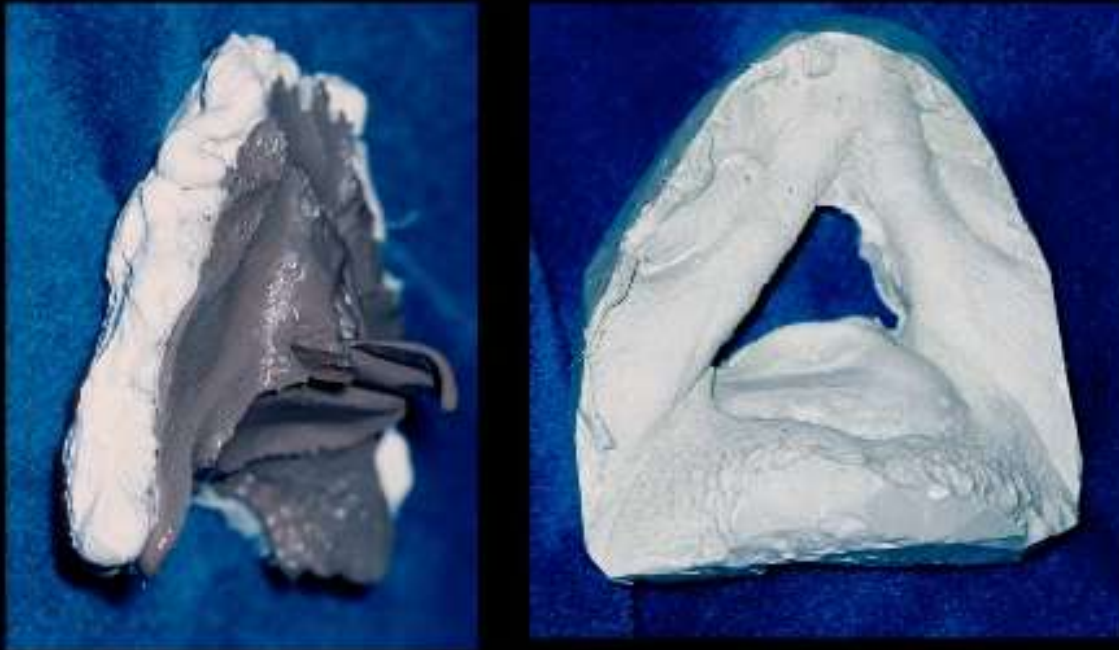# Impressions

**Challenge: Make impressions that do not distort the soft tissues**



- 1) Apply a thin layer of light body rubber base
- 2) Apply a layer of gauze to the rubber base as the material begins to polymerize
- 3) Apply succeeding layers of quick setting plaster to the polysulfide to provide the support for the elastic material. The initial layer must be thinned and partially set before succeeding layers of plaster are

# Master Cast



Master cast is made of green die stone.



# Types of nasal prosthesis

1-Temporary nasal prosthesis.

2- Definitive nasal prosthesis.

# Temporary nasal prosthesis

- Approximately 3-4 weeks following surgery.
- Heat polymerizing methyl methacrylate is preferred because it can be relined with a temporary denture reliner.
- Retention of the prosthesis is accomplished with medical grade skin adhesive.

# Definitive nasal prosthesis

- After 3-4 months fabrication of definitive prosthesis is carried out.
- Flate defects in which the nasolabial folds remain are the easiest to restore prosthetically.
- In most pts the residual tissue bed is highly mobile therefore prosthesis of highly flexible materials are advised.

# Classification of nasal restoration

It can be classified according to the means of retention into:

**1-Adhesives:** medical grade adhesive

Disadvantages :

a- Applied periodically.

b- sometimes allergic.

c- difficult to clean the skin & prosthesis

# Classification

2- Eye glass frame.

3- Implant :

Bone in and around facial defects into which osseointegrated fixtures can be placed depends on the size, location of the defect and integrity of the residual structures.

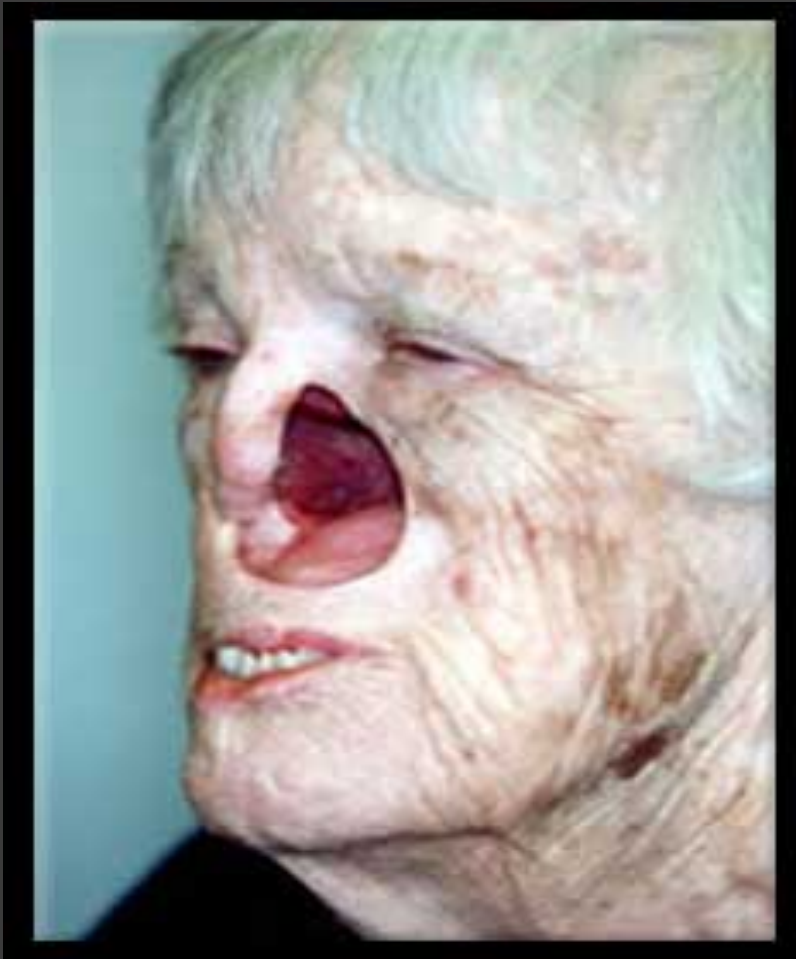a-The piriform area of the floor of the nose.

# Classification

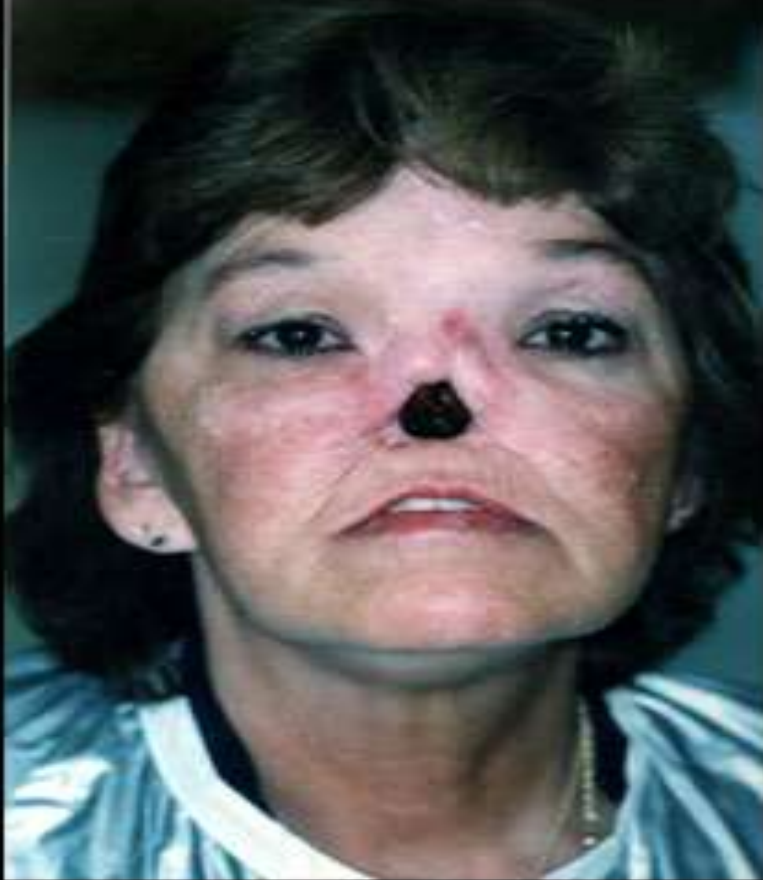b- The superior surface of the maxilla offer sufficient bone to place fixtures.



# Before & after prosthetic restoration



# Before & after prosthetic restoration





# Thank you



Lect. Hussein T. Abed

23\6\2021

# NASAL SCULPTING AND COLARATION



# Sculpting

## ❖ Contours

- ❖ Must be compatible with the facial form of the patient

## ❖ Surface texture

- ❖ Stipple, lines and grooves must be slightly more prominent than those on the adjacent skin

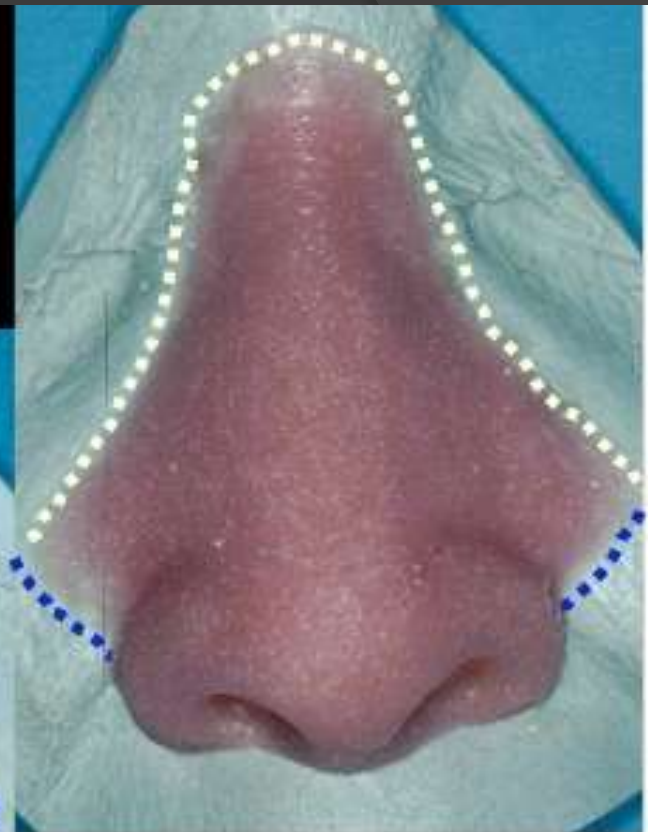
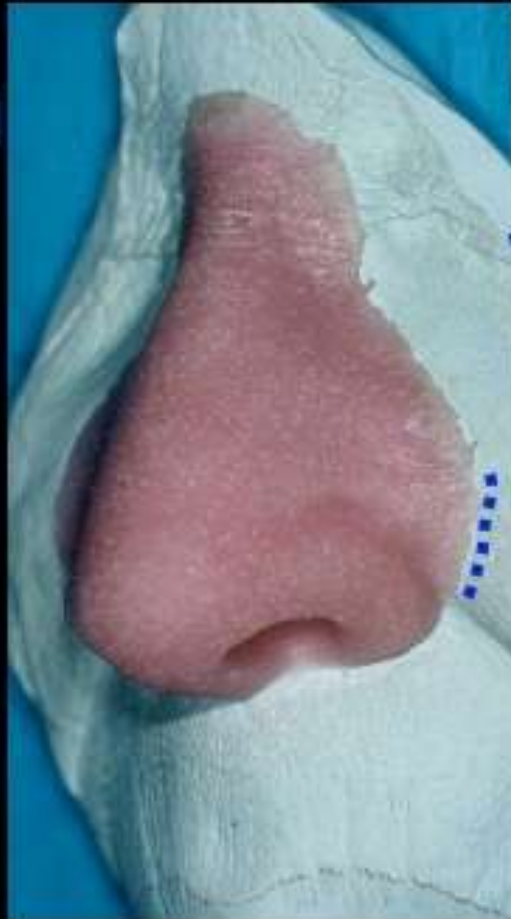## ❖ Margin placement

- ❖ The superior margin and the upper portions of the lateral margins should be positioned beneath the eyeglass frames
- ❖ The lower portion of the lateral margin should be carefully thinned and blended in with the adjacent skin
- ❖ The alae must be tucked in so that only the height of contour is seen from the anterior view
- ❖ The columella must be tucked up underneath the tip of the nose so that this margin cannot be seen from the anterior view

# Sculpting Favorable Defects

## Margin placement

- ❖ Superior and upper portions of the lateral margins should be positioned beneath the glass frames
- ❖ The lower portion of the lateral margin should be carefully thinned and blended in with the adjacent skin



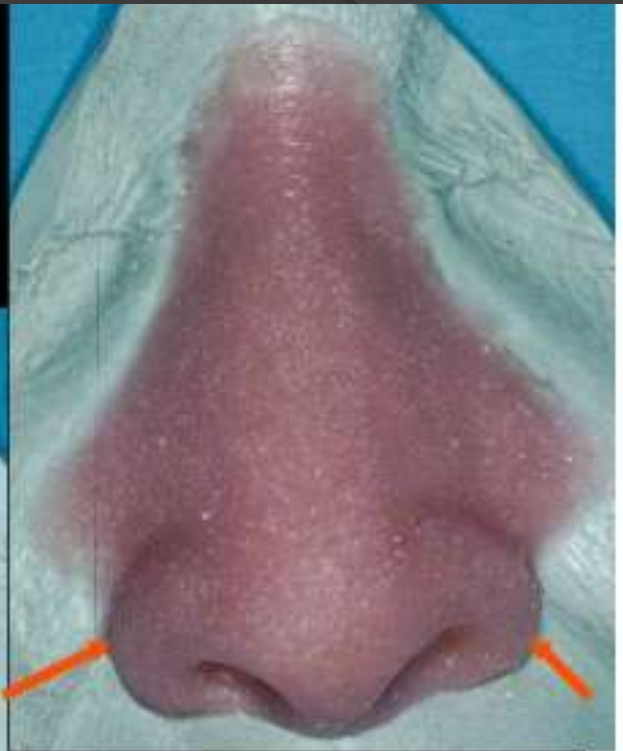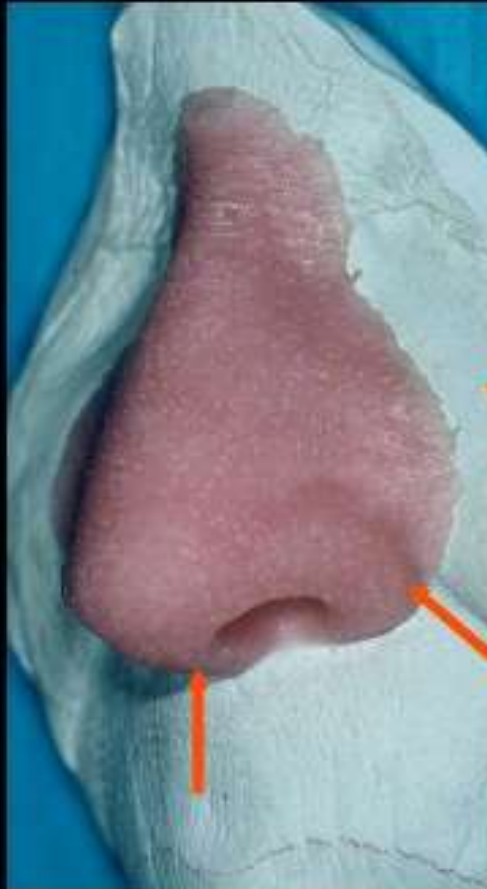


# Sculpting

## Favorable Defects

### Margin placement

- ❖ The nostrils must be tucked into the nasolabial groove so that only their height of contour is seen from the anterior view
- ❖ The columella must be tucked underneath the nasal tip so that this margin cannot be seen from the anterior view

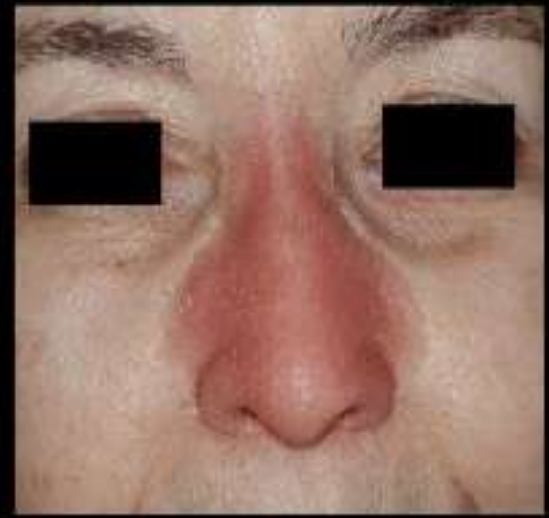
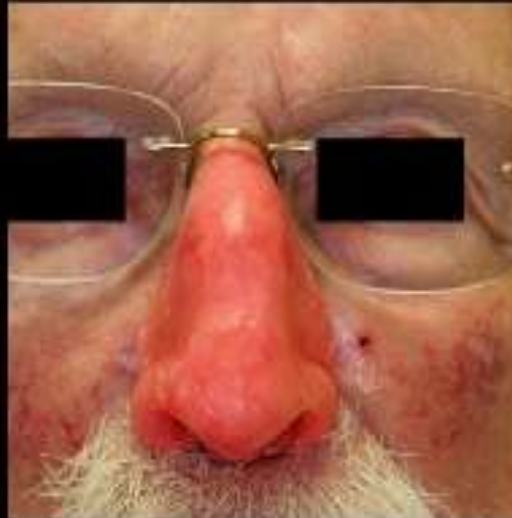
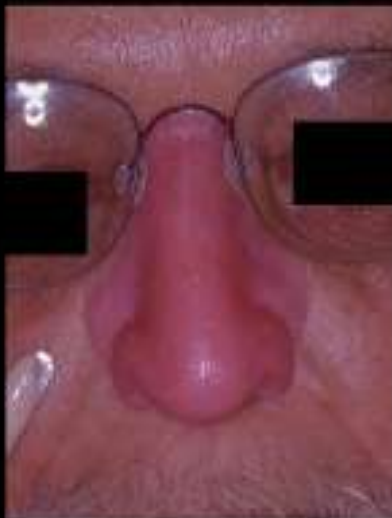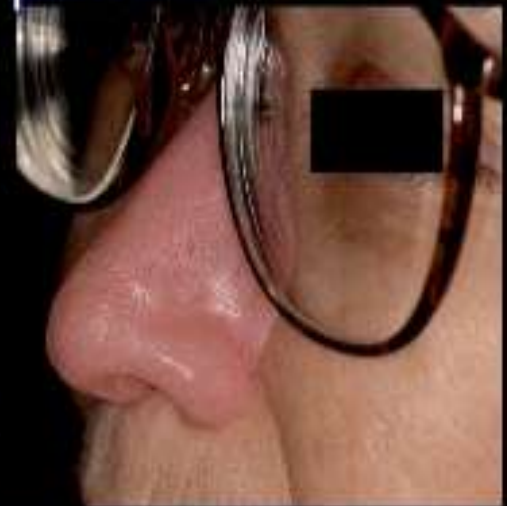# Favorable Defects

Verify the margin placement, contours and surface texture of the wax pattern on the patient

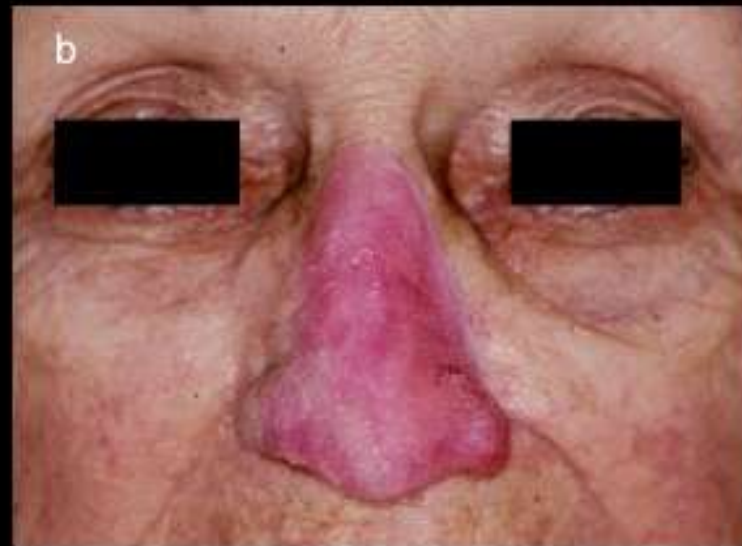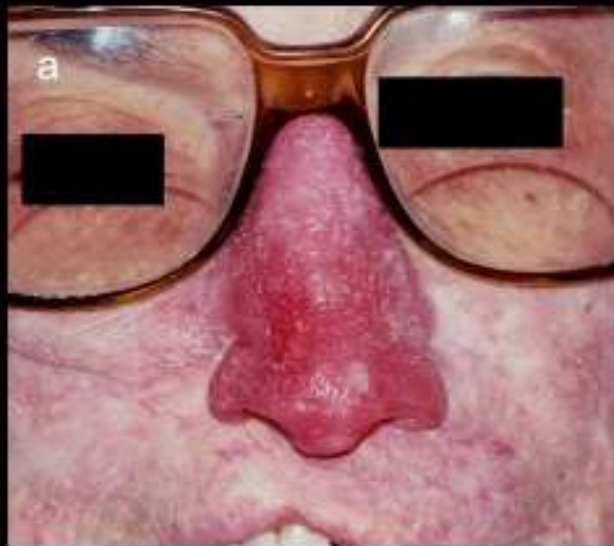## Check list:

- ❖ Size and contour
- ❖ Alar contours and margins
- ❖ Lateral and superior margin placement
- ❖ Surface texture
- ❖ Columella margin placement and contour





## Unfavorable Defects

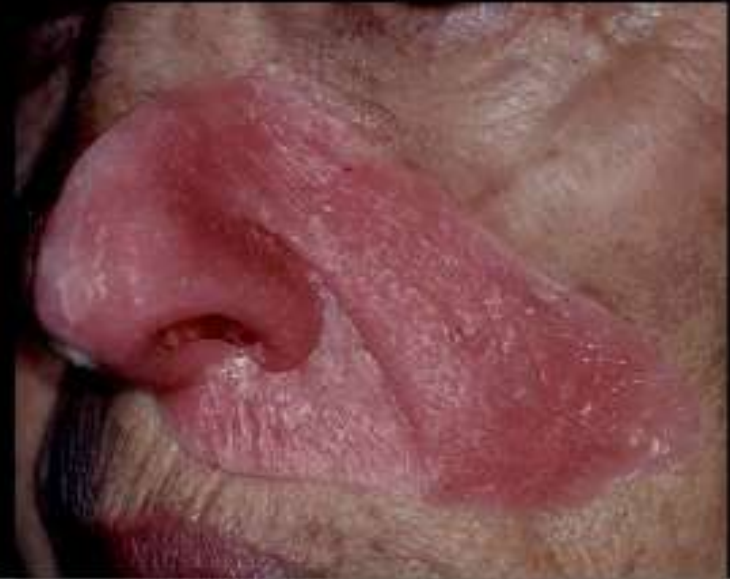
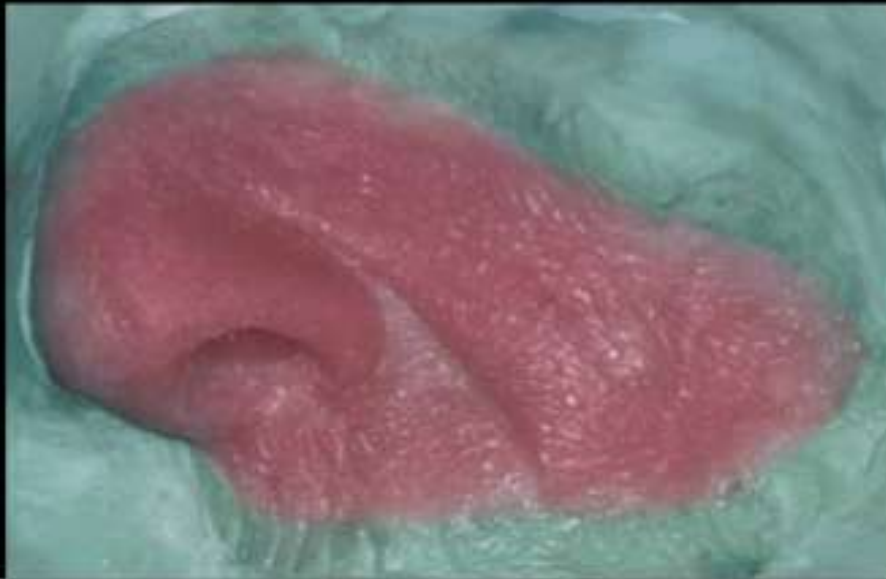
Note the deviations from normal in both these sculptures

- ❖ In both patients the right nostril is elevated and smaller than the left nostril because of elevation of the lip in "a" and the distortion of the nasolabial fold in "b".

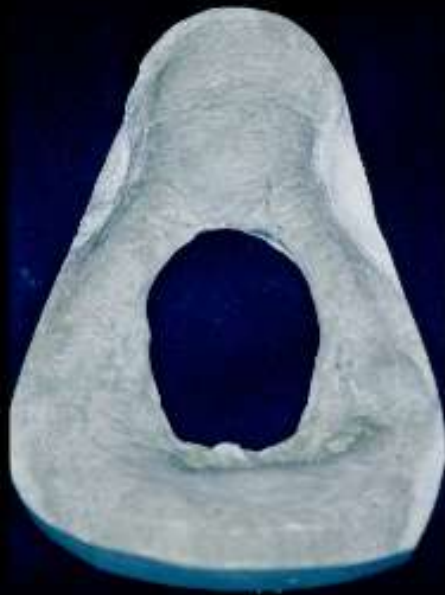# Surface texture

- ❖ Stipple, lines and grooves must be slightly more prominent than those on the adjacent skin. Why?
  - ❖ Some of the surface detail is lost during flasking, processing and the application of extrinsic colorants.
- ❖ In some instances the stipple can be created with a brush but in most this results in a stipple that is insufficiently prominent
- ❖ In this sculpting the surface texture was created with a wax carving instrument

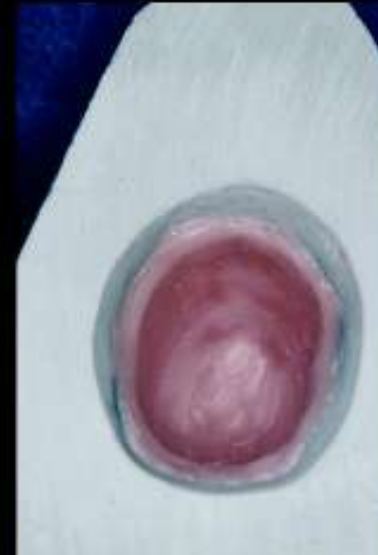
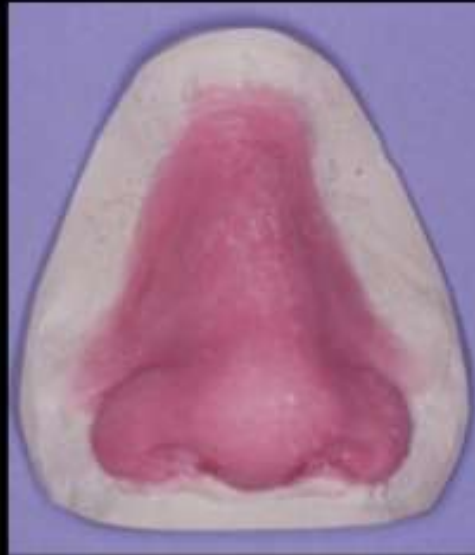

# Processing

## Flasking – Sealing the pattern to the cast



Hole is placed through the cast as shown.

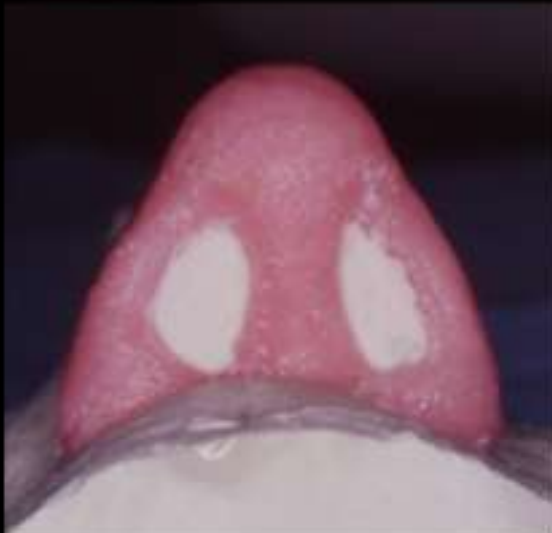
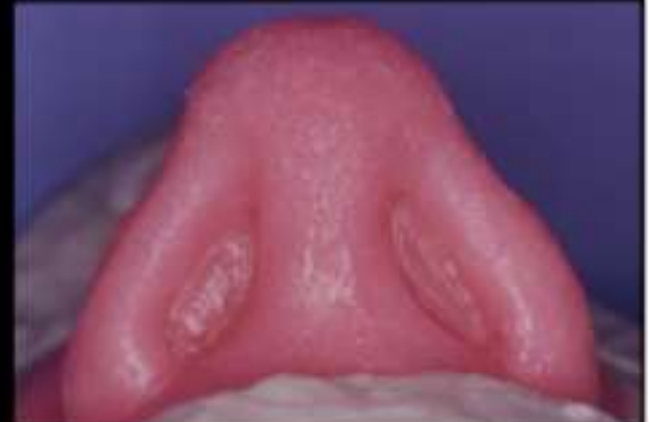
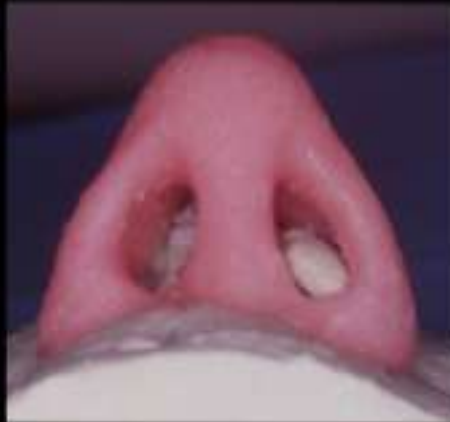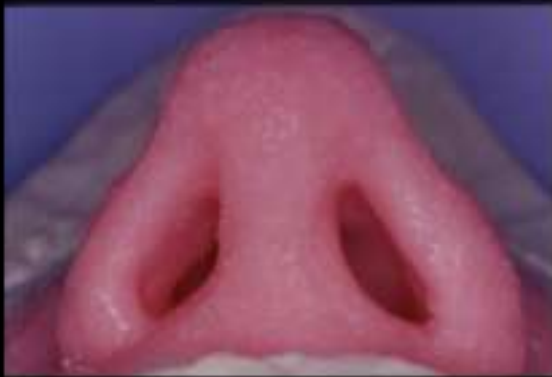Wax sculpture is luted to the cast externally and also from the back to insure the engagement of the usable undercuts and proper extension onto the floor of the nose.



# Processing

## Flasking – Sealing the pattern to the cast



❖ The nostrils are sealed as shown



# Developing shade guides



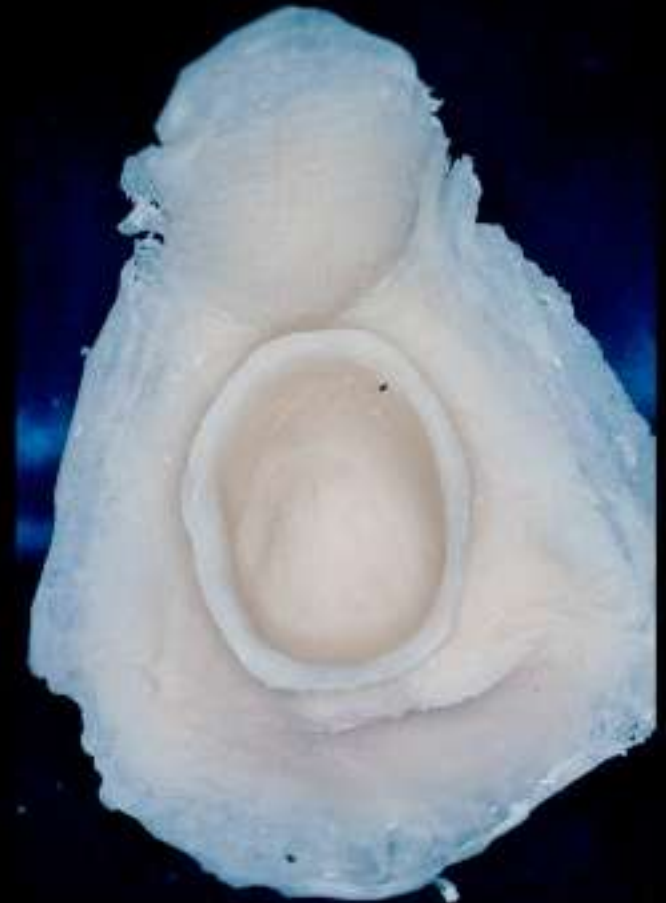The shade selected should be slightly lighter than the lightest skin tone of the patient

# Processing

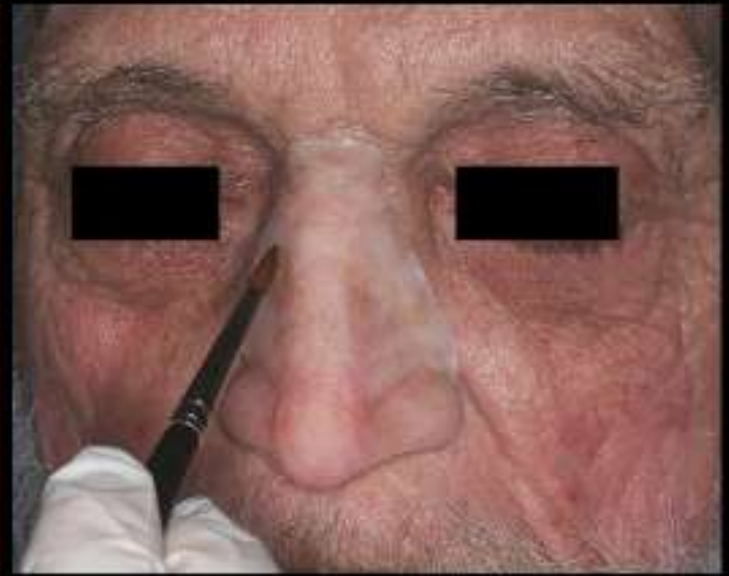
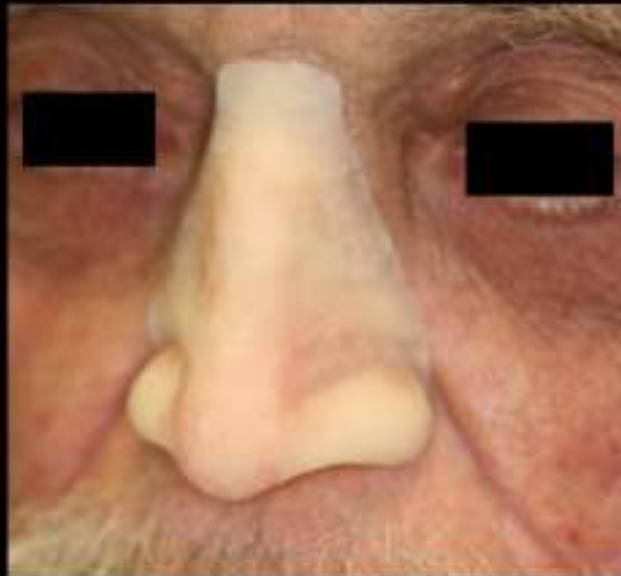
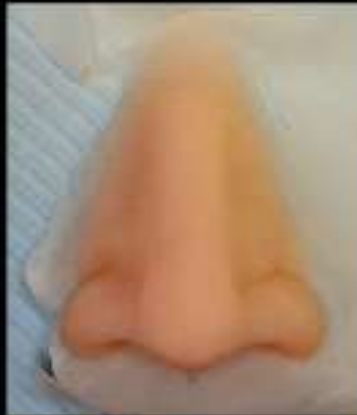Polymerized silicone casting is thin, flexible and light weight



Stone is vibrated through opening in back of the cast



# Extrinsic coloration



Colors are applied slowly and carefully

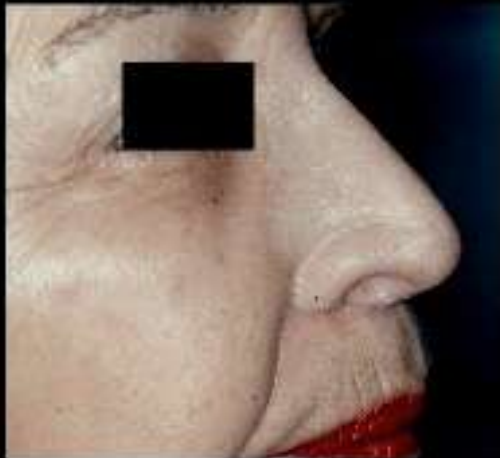- ❖ Browns are applied first
- ❖ Red and blue highlights next
- ❖ Dark browns and grays are applied to the lines and grooves to simulate shadowing in these areas



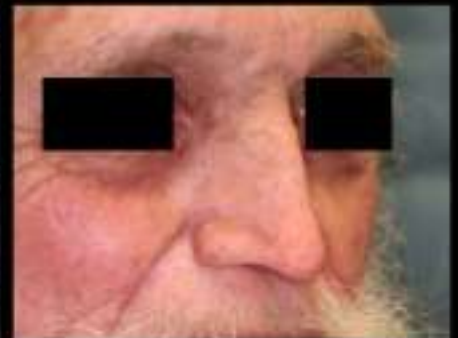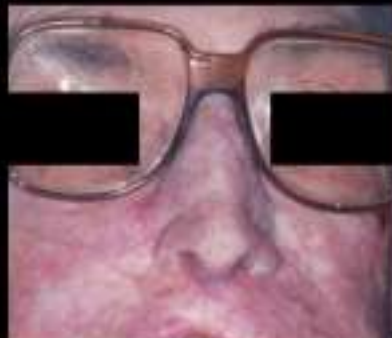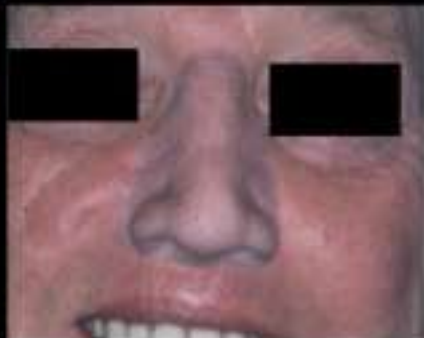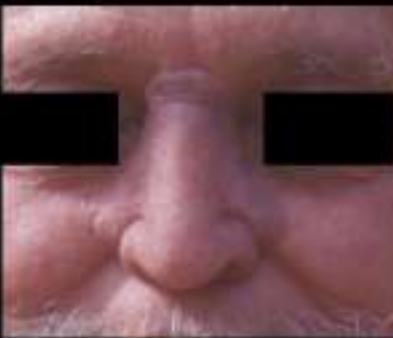
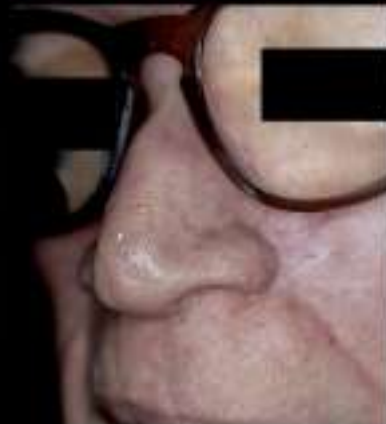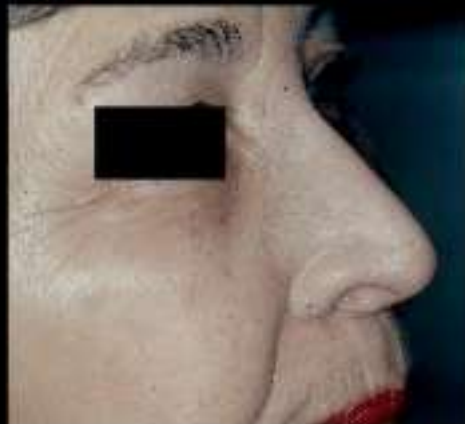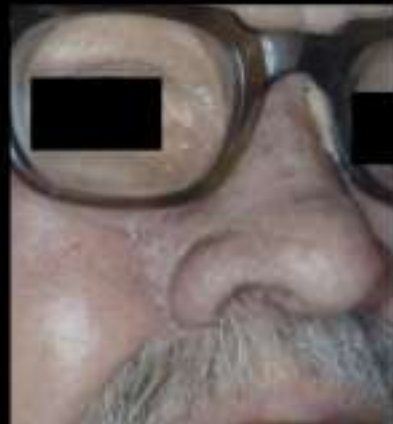# Completed prosthesis

## Note the following

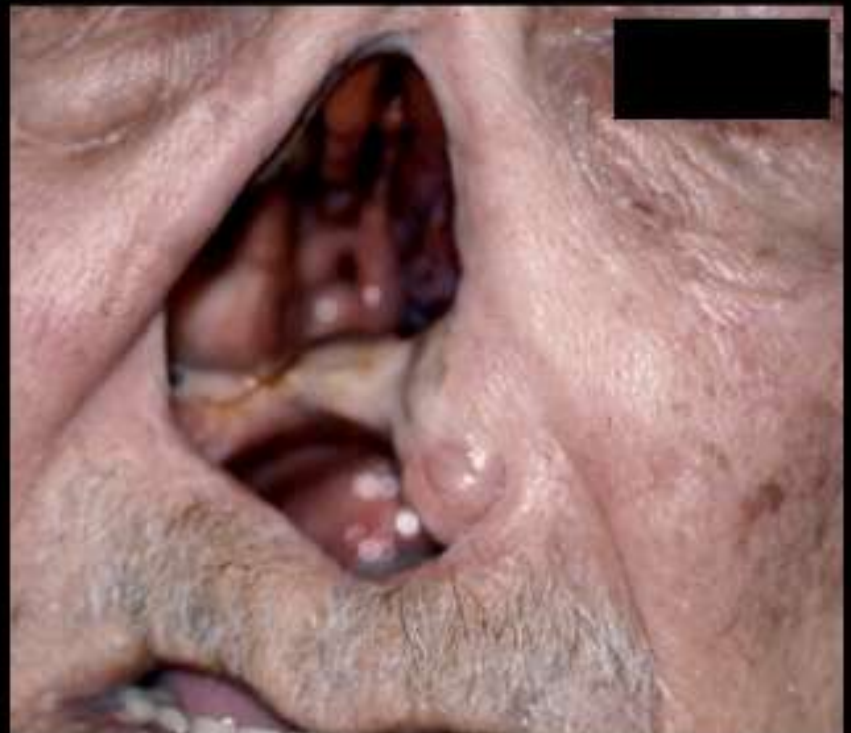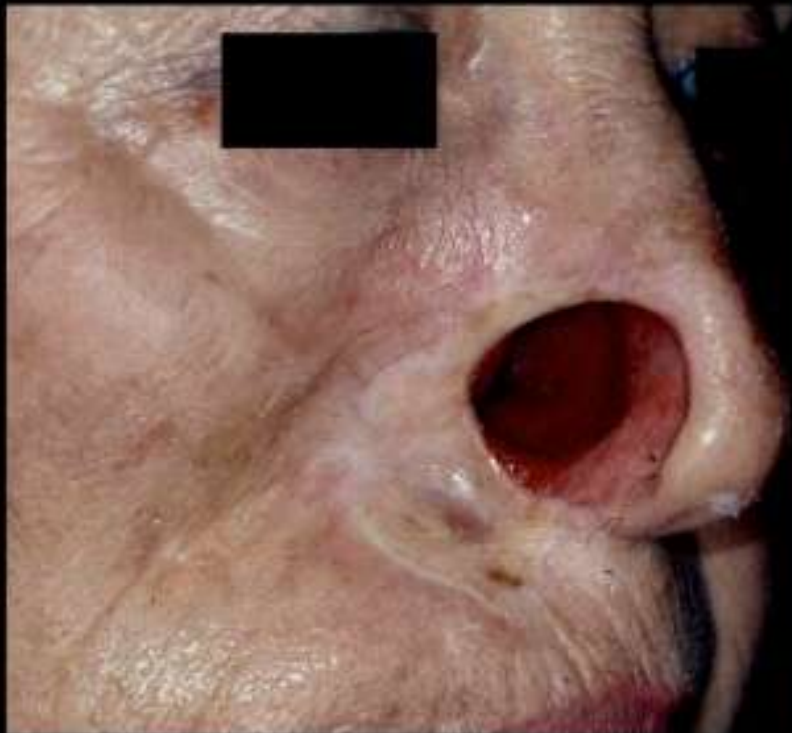- ❖ The lateral and superior margins are positioned beneath the eyeglass frames
- ❖ The margins from the bottom of the eyeglass frames to the alar groove are thinned and carefully blended in the adjacent skin
- ❖ The inferior surface of the columella is rounded and this margin is tucked in beneath the nasal tip
- ❖ The nostrils are blended in with the nasal labial folds



**Contours - Nasal contours must be consistent with the facial form of the patient**

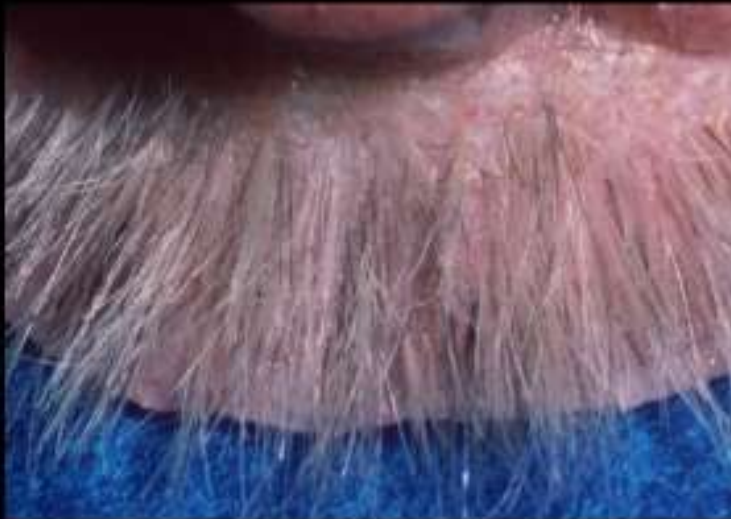

## Nasal defects extending onto the upper lip





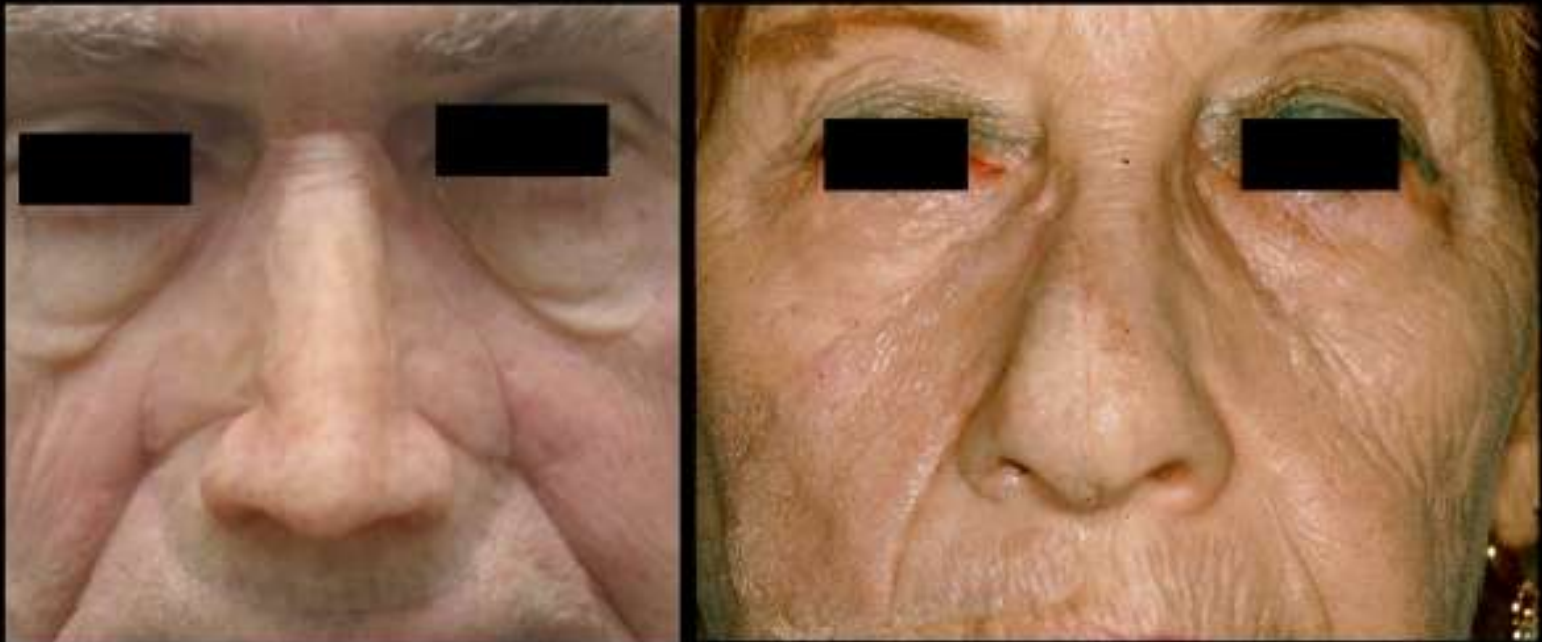## Nasal defects extending onto the upper lip



Mustache is woven into the upper lip extension on the prosthesis and blended in the existing mustache.

## Nasal defects extending onto the upper lip

If a moustache is not used the the lip and cheek margins must be carefully blended with the adjacent skin.



The patient must be warned that lip margin will open upon movement of the upper lip. Slight positive pressure in this region will minimize the opening somewhat.

● Thank you

# Nasal prosthesis: retention

Lect. Hussein T. Abed

30/6/2021

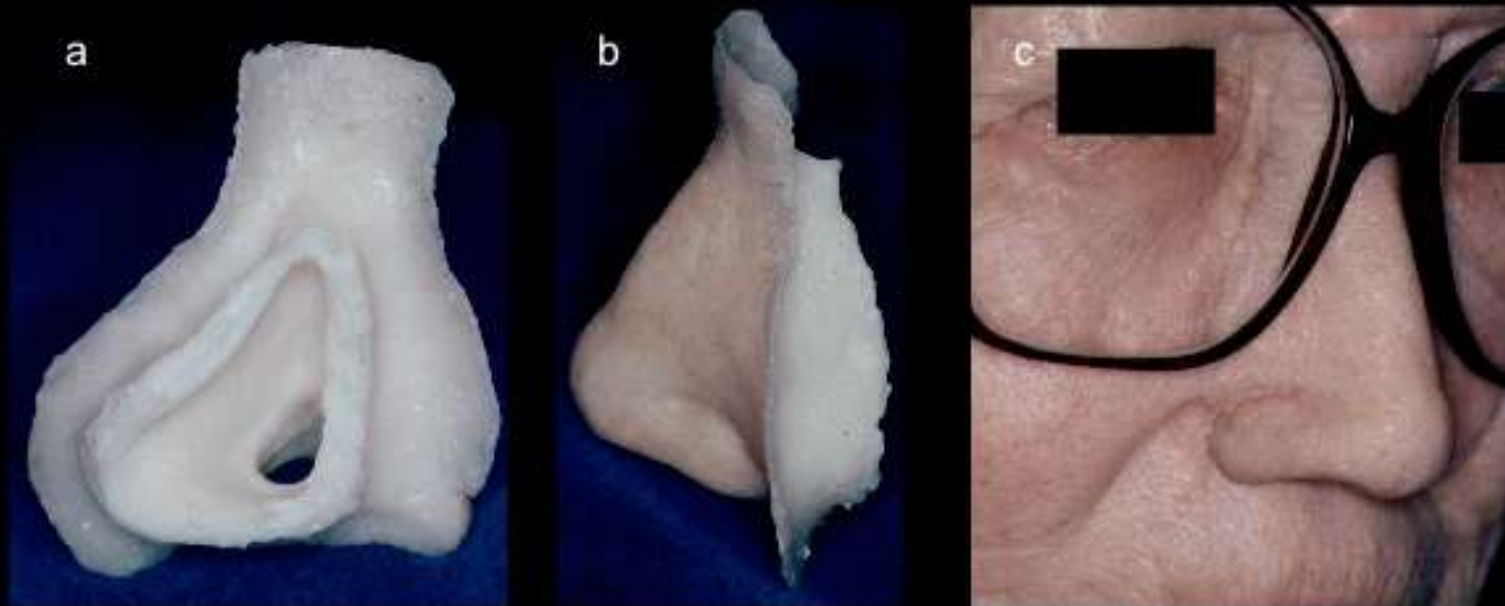
# Methods of retention

- ❖ Skin adhesives only
- ❖ Engagement of undercuts plus skin adhesives
- ❖ Osseointegrated implants



# Methods of retention

## Engagement of undercuts



Retention was achieved by engagement of undercuts in the nasal cavity. a and b: Nasal prosthesis. Note posterior portion is hollow to reduce weight and improve flexibility. c: Prosthesis in position. Adhesive was not necessary.



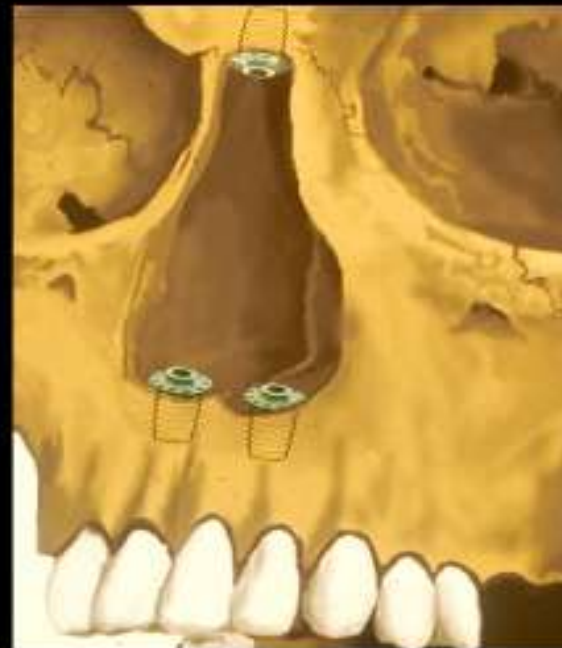# Craniofacial Implants

## Sites

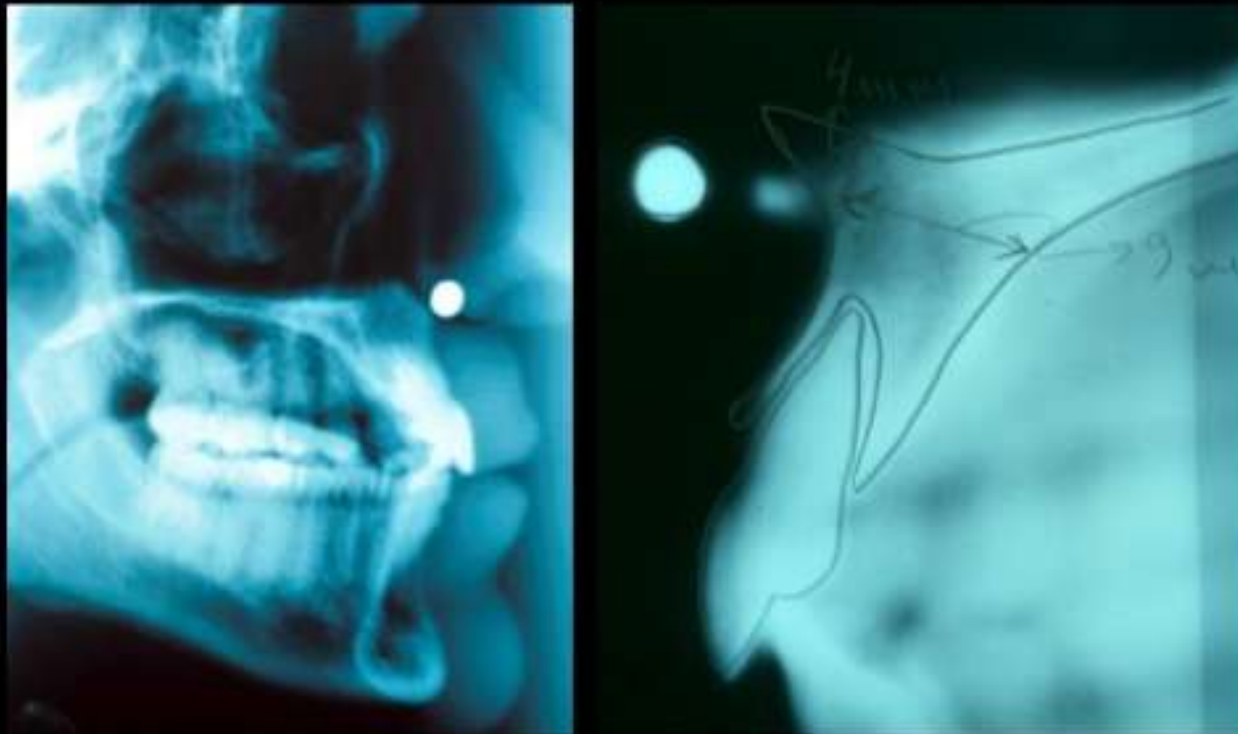
Craniofacial Implants -  
Lengths 4 mm and 5 mm



- Floor of the nose
  - This site is favored
- Glabella

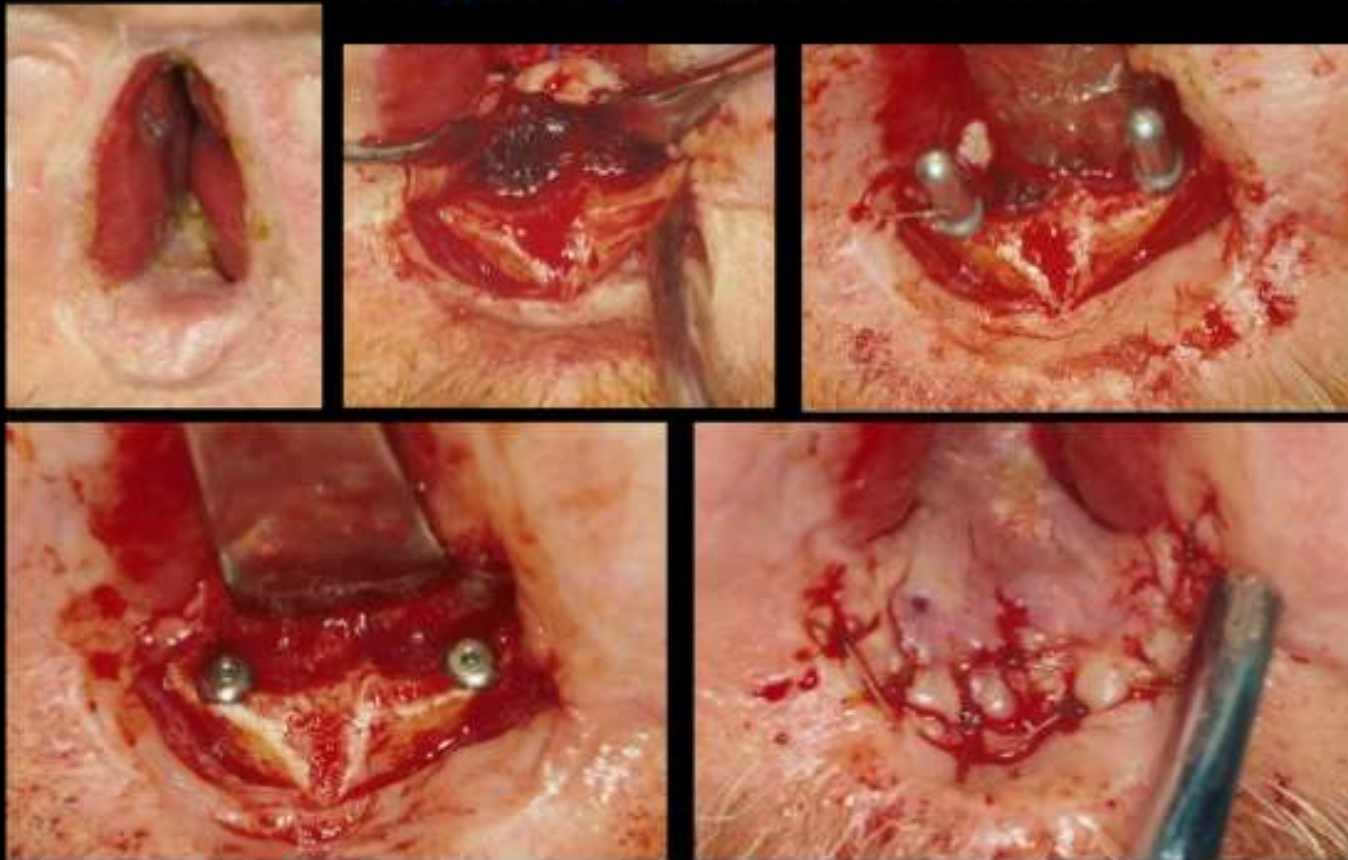


# Nasal Implants-Radiographic Evaluation



Beware of the roots of the anterior teeth.

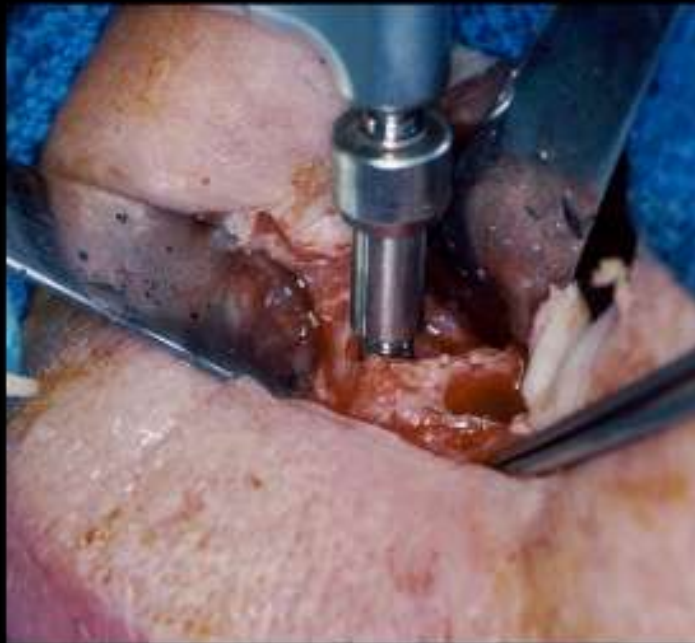
# Implant Placement



- ❖ Implants should be 10-15 mm apart to ensure appropriate hygiene access

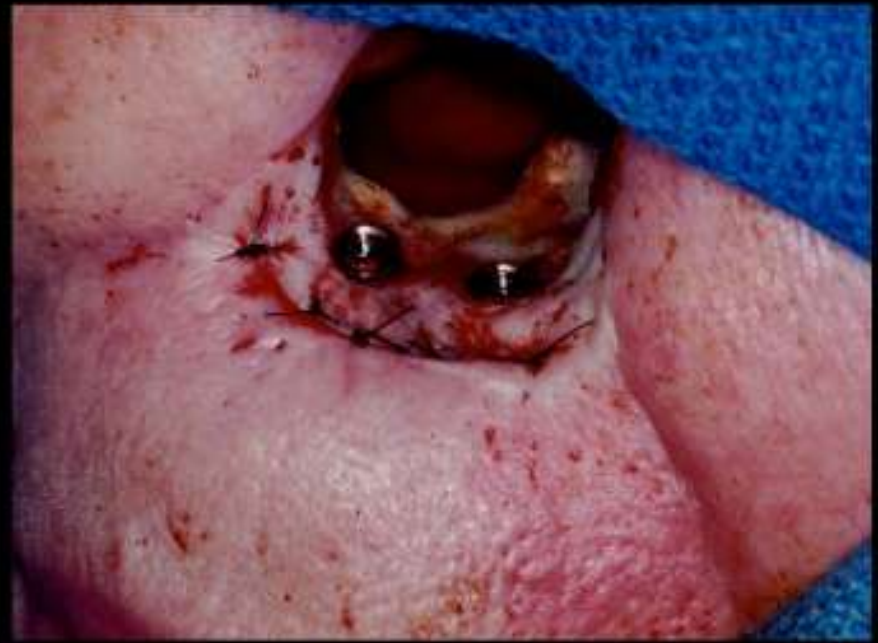

## Site preparation and position



### Implant position

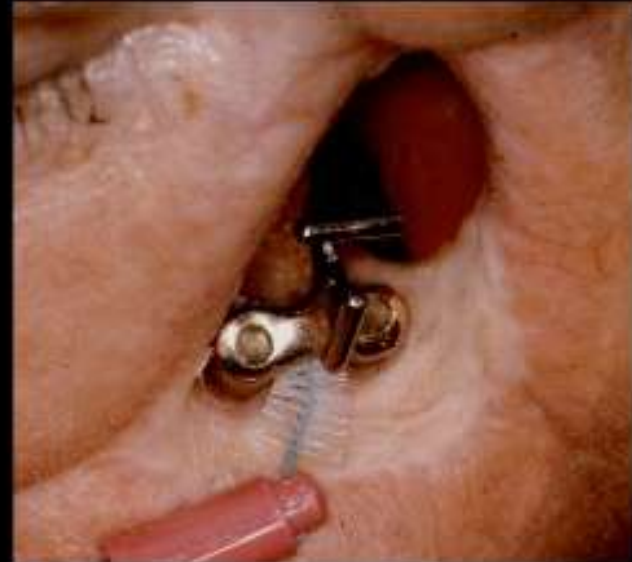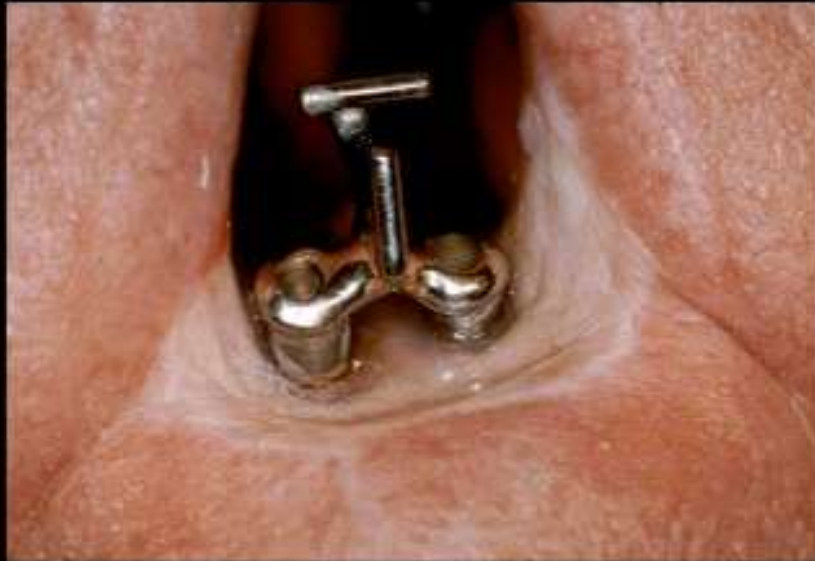- ❖ 10-15 mm apart
- ❖ Exit attached  
immobile tissues



### Ideal implant position permits

- ❖ Easy fabrication of retention bar
- ❖ Easy hygiene access

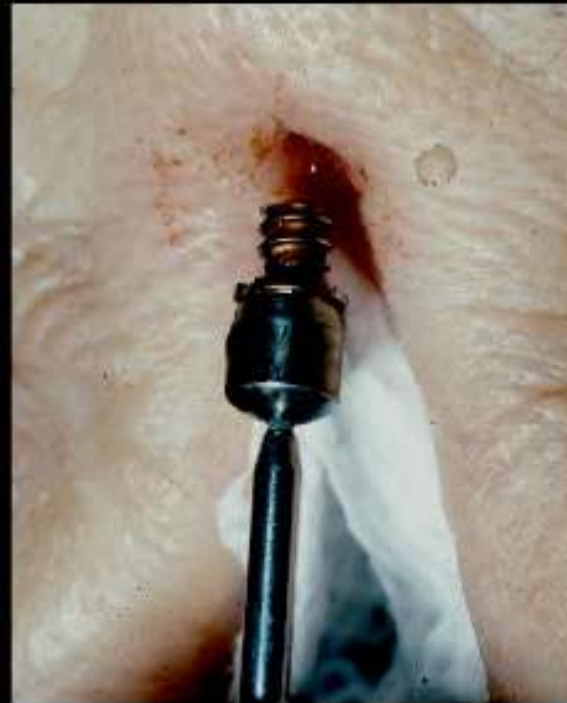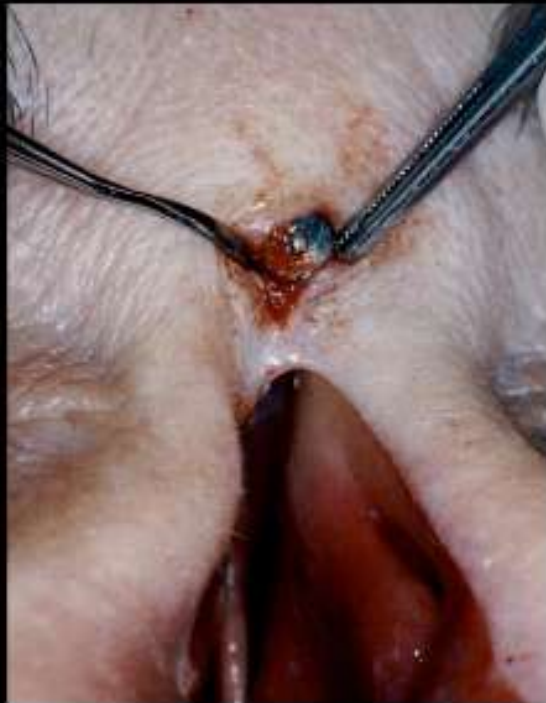## Site selection and position



### Ideal implant position permits

- ❖ Easy fabrication of retention bar
- ❖ Easy hygiene access for the patient

## Nasal defects – Craniofacial implants



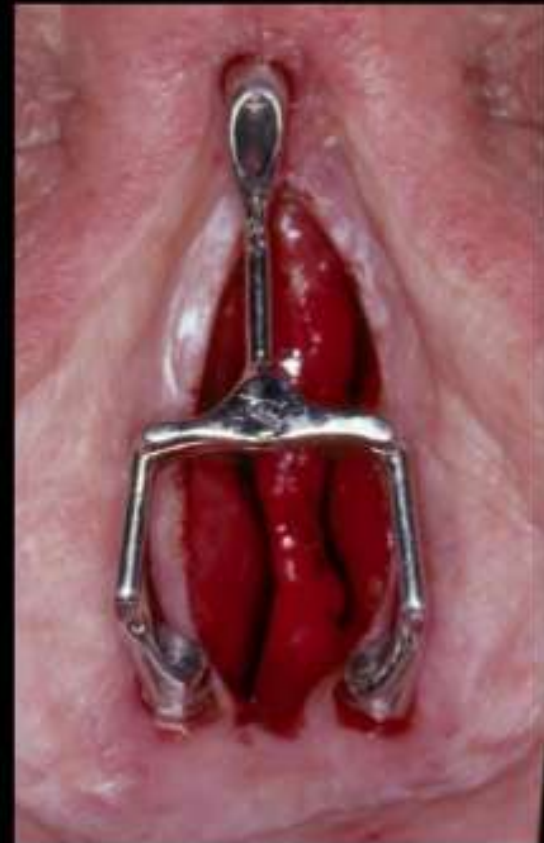Craniofacial implants placed in the glabella have a lower success rate. If implants are planned for this site oral lengths (7-10mm) are recommended.



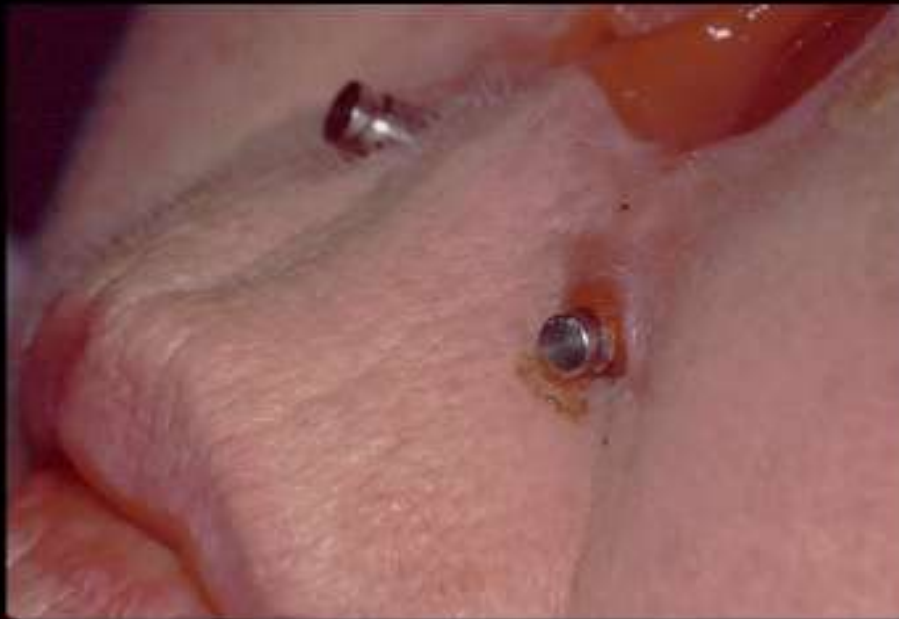# Nasal Implants – Glabella

## Possible Alternatives

- ❖ Us implants of conventional length
  - ❖ 7mm and 10 mm
- ❖ Splint the glabella implants to the implants in the floor of the nose

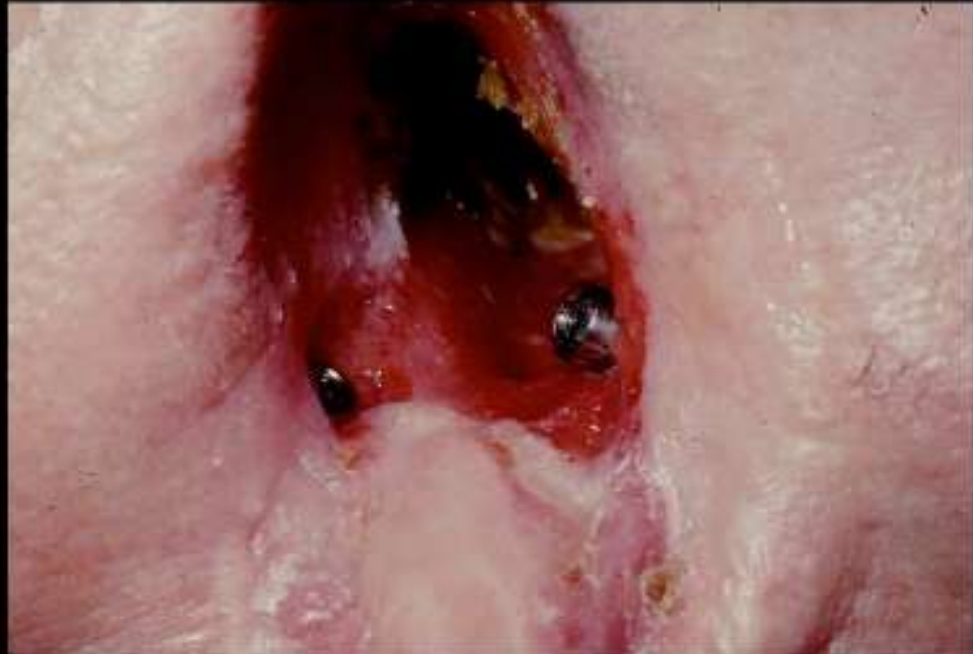
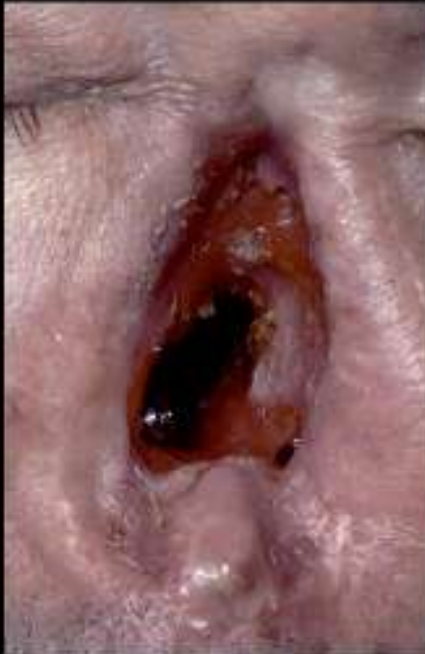
## Improper implant position



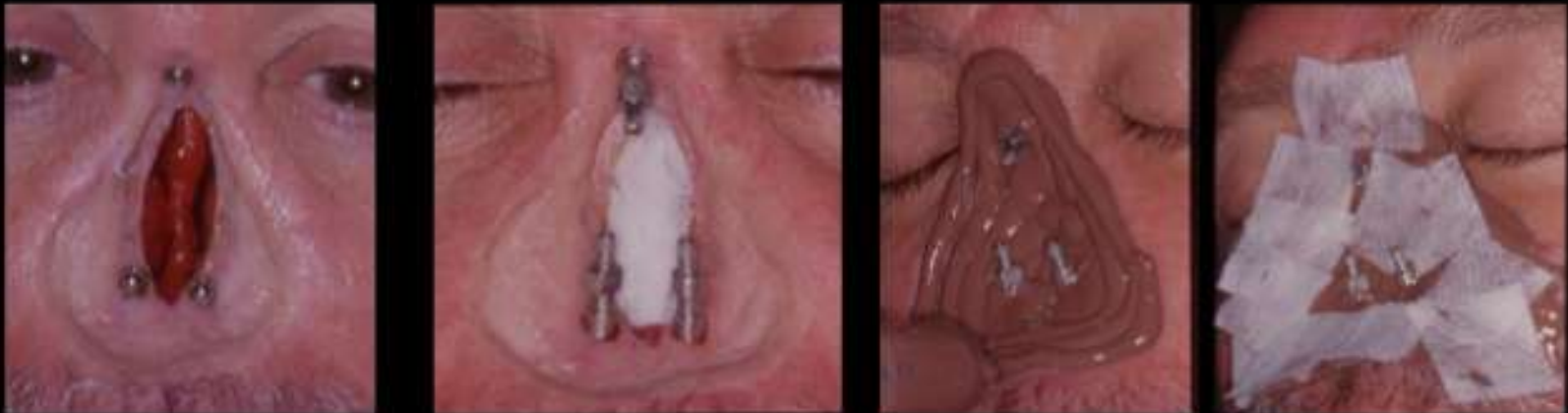
Implants should not exit through the mobile tissues of the lip. Otherwise chronic tissue irritation will lead to formation of granulation tissues around the implants.

## Improper implant position



These implants are positioned too far posteriorly making hygiene difficult for the patient.

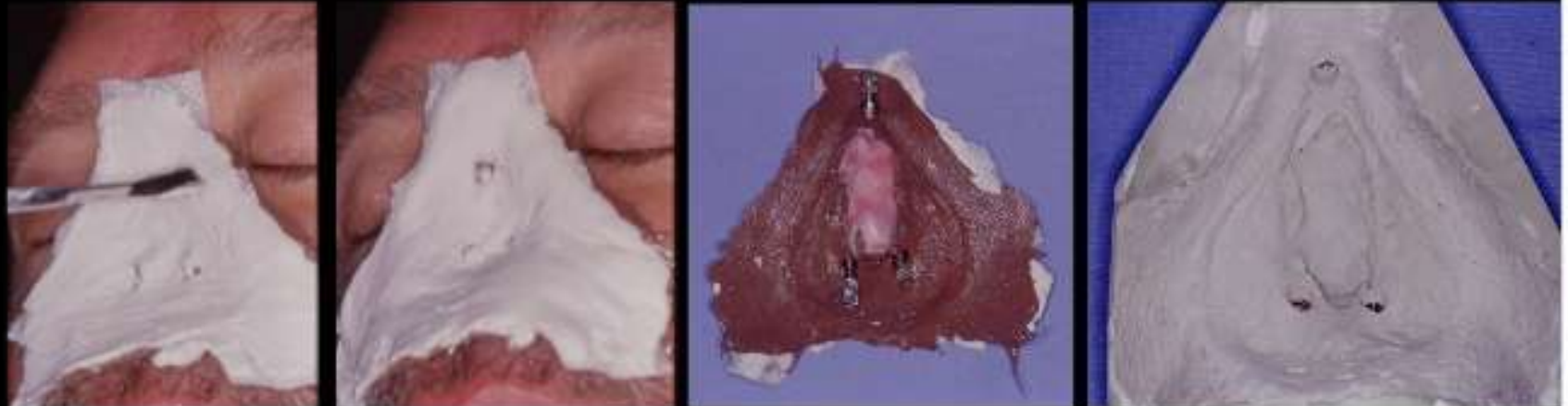# Impressions



- ❖ Impression copings are attached to the implant fixtures
- ❖ Light body rubber base is applied with a syringe and thinned with a cement spatula taking care to avoid displacing tissues of the lip and cheek.
- ❖ A thin layer of adhesive is applied to the polymerizing polysulfide and gauze strips are adhered to the adhesive.

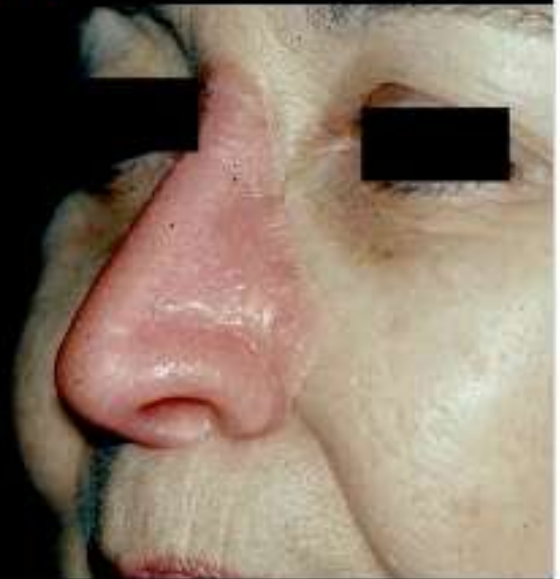
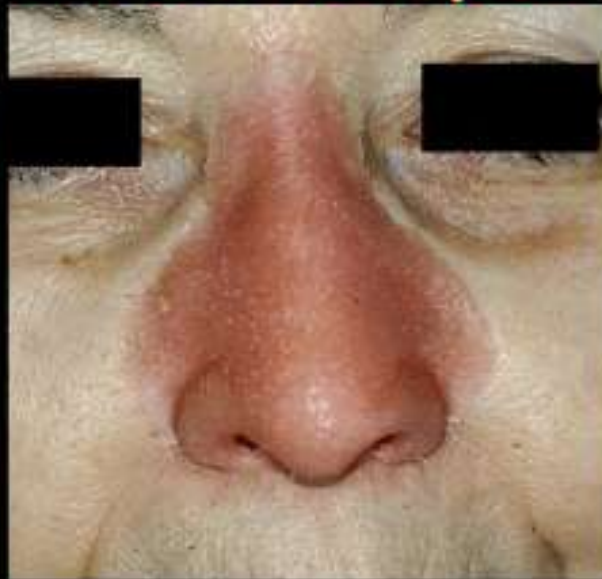
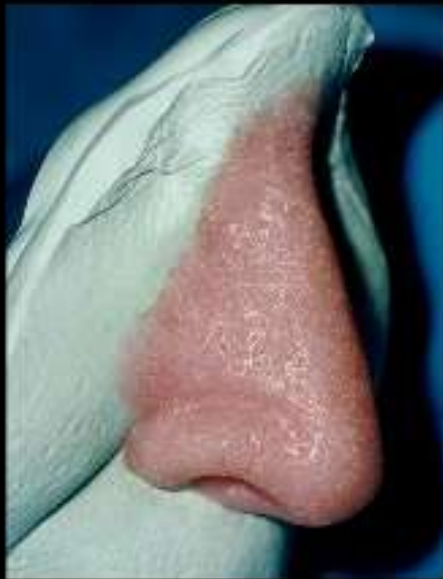# Impressions



- ❖ Succeeding layers of quick set impression plaster are applied. The first layer must be very thin and be allowed to set before the succeeding layers are applied.
- ❖ The screws securing the impression copings to the implant fixtures must not be covered with plaster.
- ❖ When the impression plaster has set these screws are loosened and the impression removed. Fixture analogues are then attached to the impression copings.
- ❖ The master cast is made in the usual manner.

## Trial wax pattern

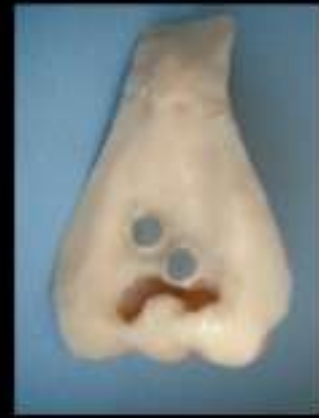
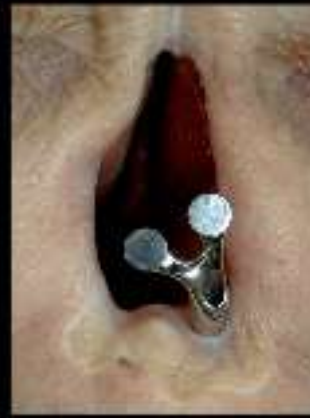
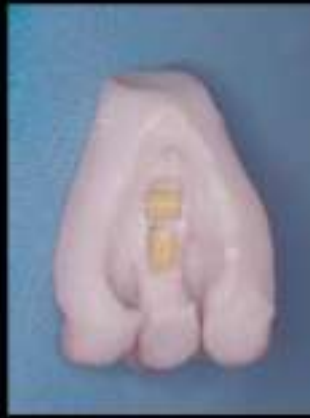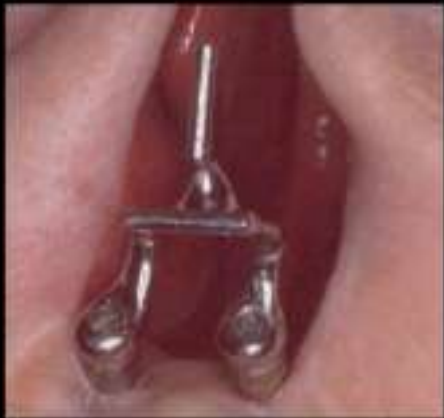Before the tissue bar is designed and fabricated a trial wax sculpting of the prosthesis must be completed and verified on the patient.



# Tissue bar designs

## Magnetic attachments vs Bar-Clip retained prostheses

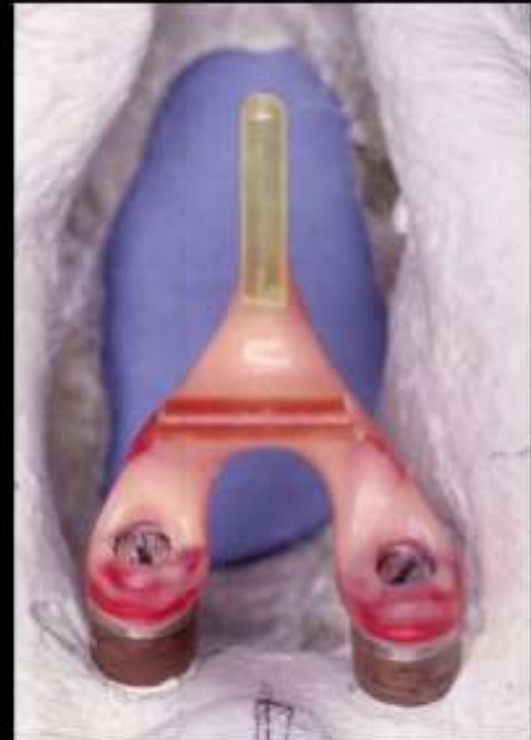
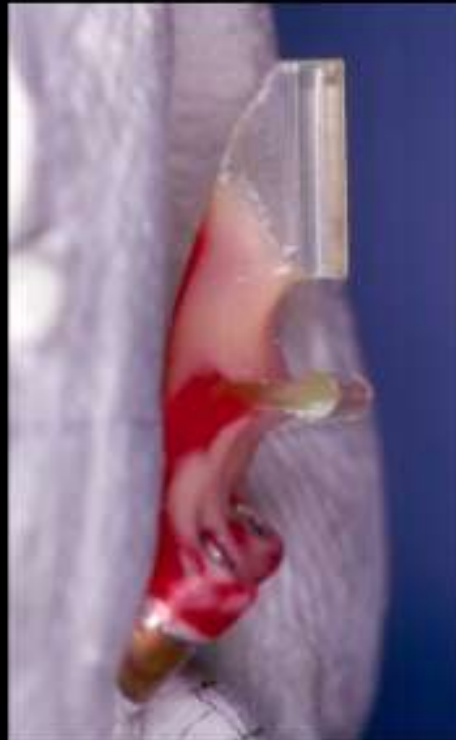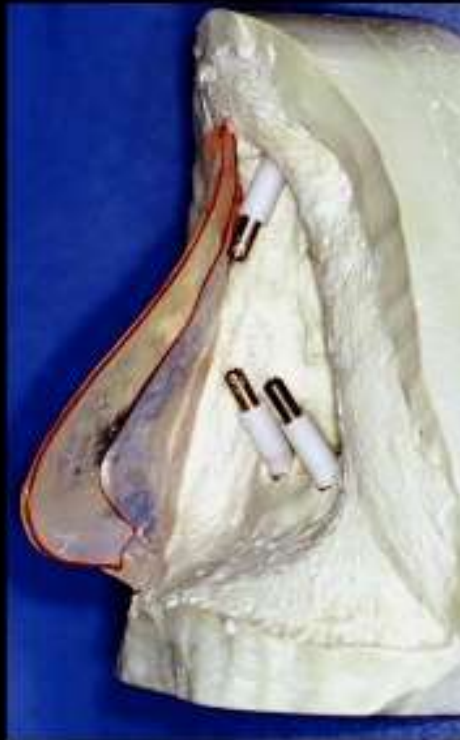


Clip retained prostheses are preferred

- a) Better retention
- b) Magnetic attachments tend to corrode

Magnetic attachments deliver less stress to the anchoring bone and are recommended when used when only a solitary implant is available.

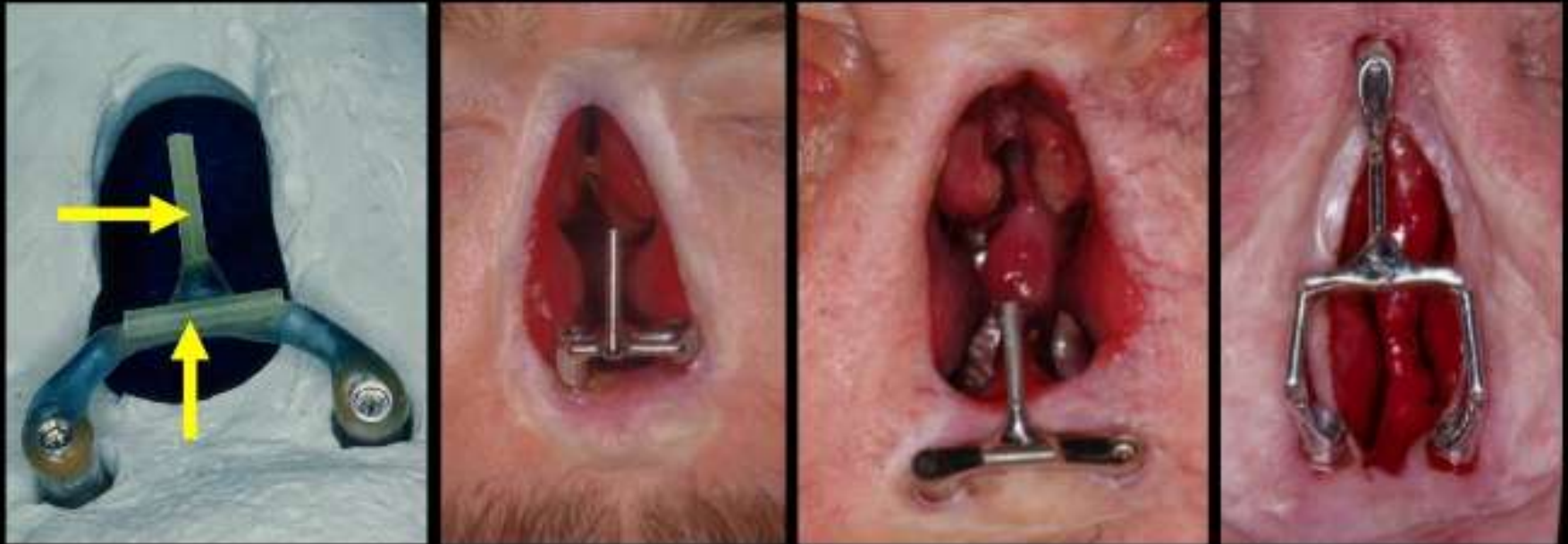## Bar Clip Designs -Tissue Bar Fabrication:



### UCLA abutment

- ❖ Versatile
- ❖ Cost effective

## Bar Clip Tissue bar designs

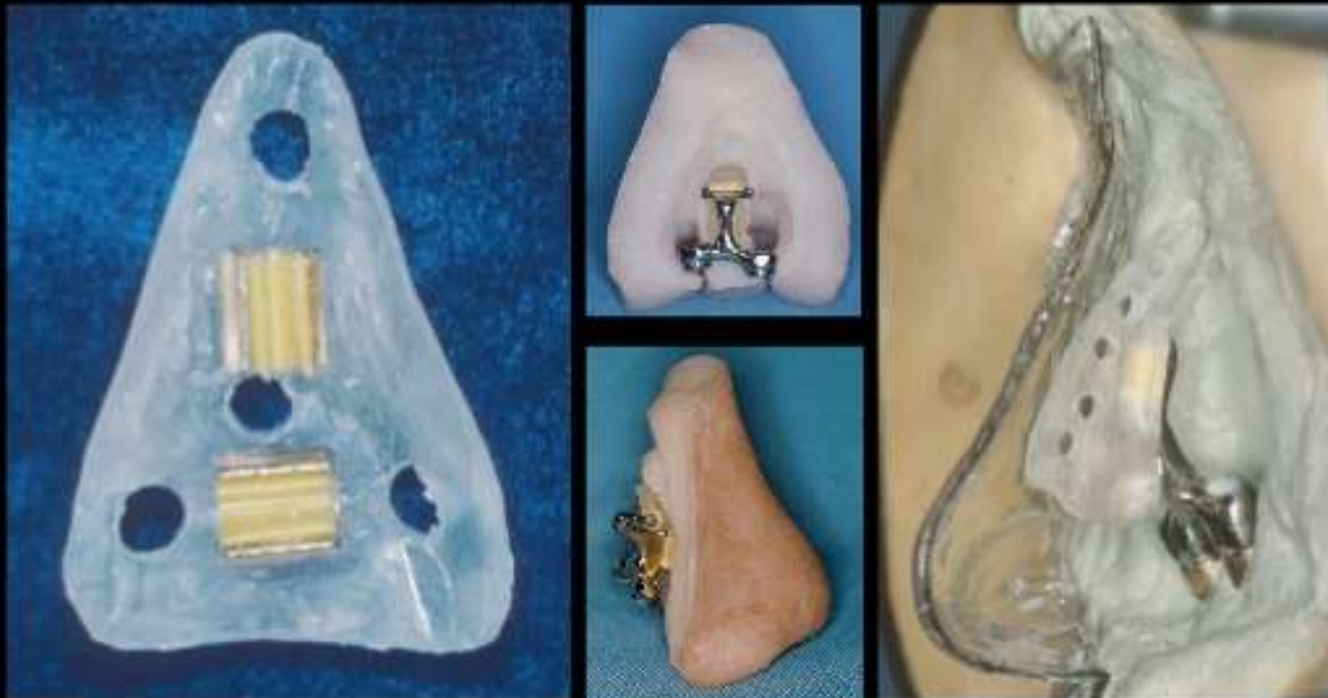

Best results achieved when vertical and horizontal components are incorporated within the tissue bar (arrows)



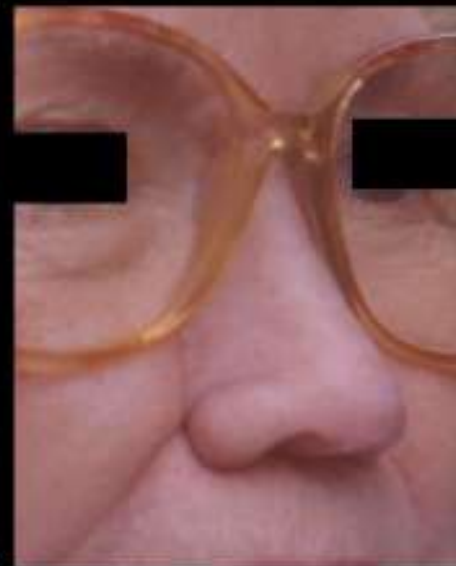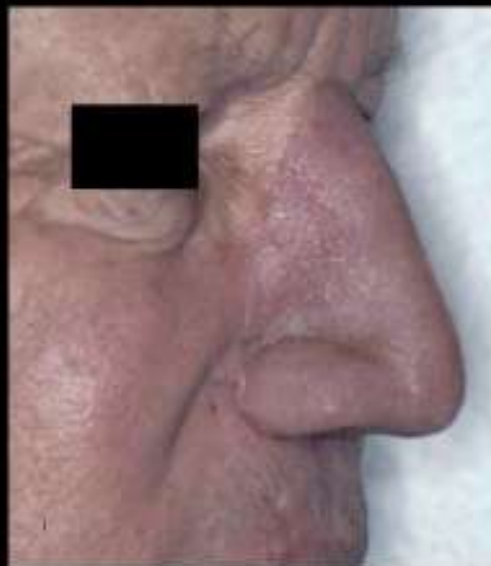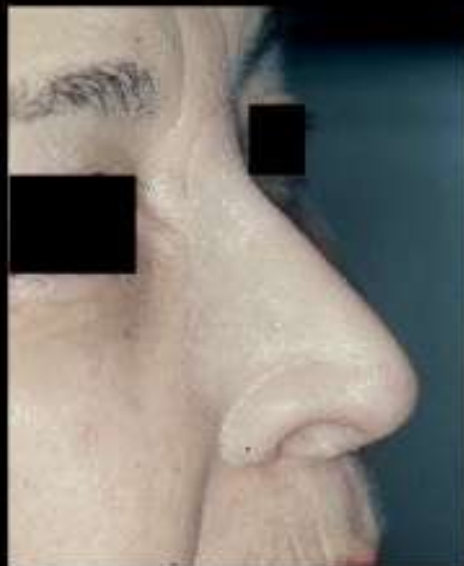## Acrylic resin substructure

- ❖ Contains the retentive elements
- ❖ Must fit within the confines of the nasal prosthesis
- ❖ Must have sufficient surface area so that the bond between resin and silicone doesn't fail.

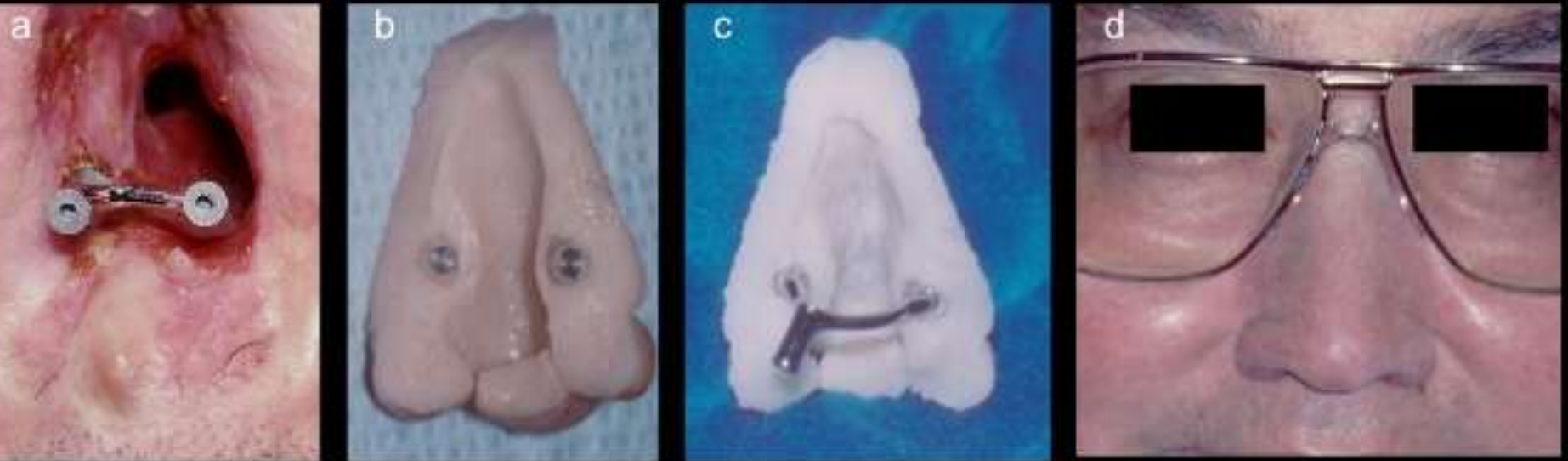


## Nasal defects – Craniofacial implants

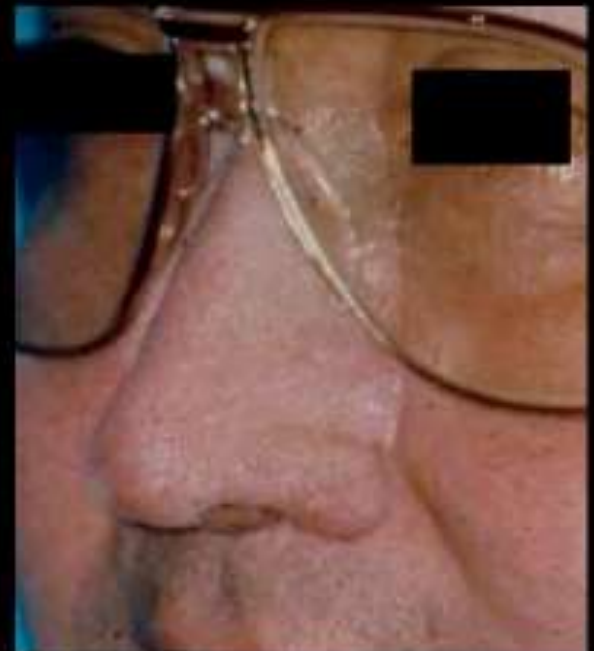Completed prosthesis provides patient with an esthetic, well retained restoration



# Magnetic retention

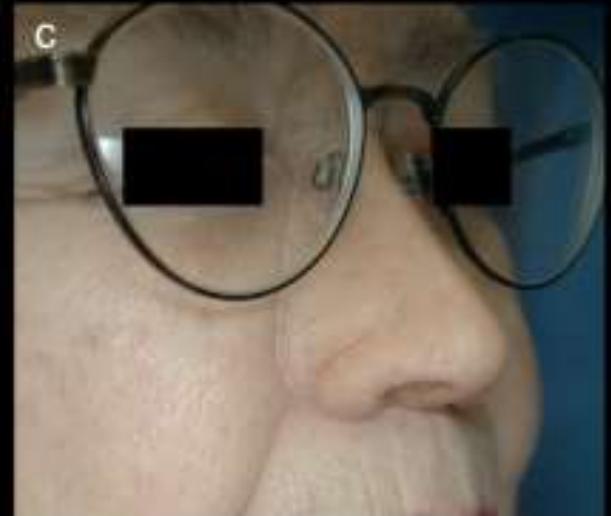
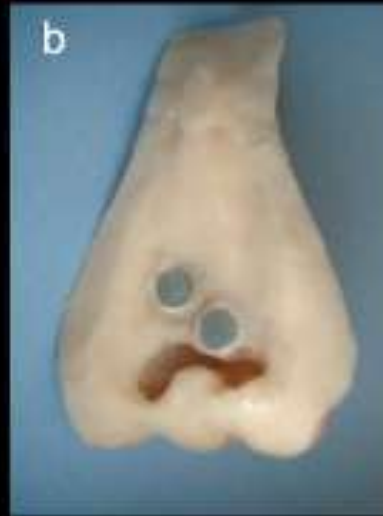
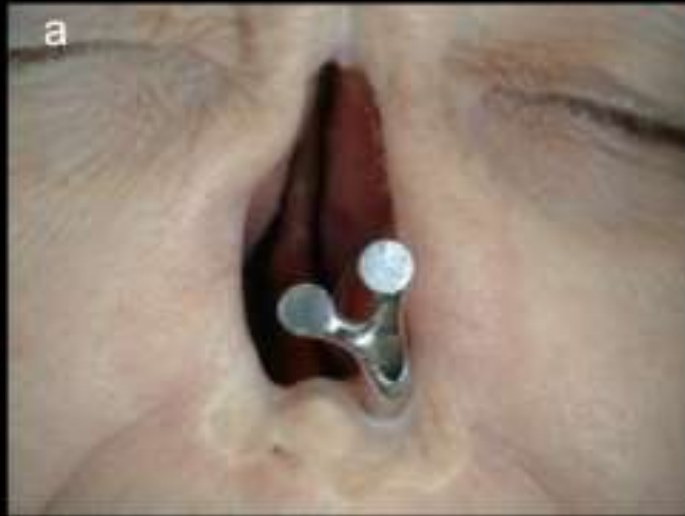- ❖ This patient received in excess of 65 Gy post operatively. One implant failed immediately and only one remained (a). Bar engaged hex atop implant fixture to prevent rotation of bar and loosening of screw.
- ❖ Posterior surface of nasal prosthesis. Note magnetic attachments (b).
- ❖ Bar engaging prosthesis (c).
- ❖ Prosthesis in position (d).





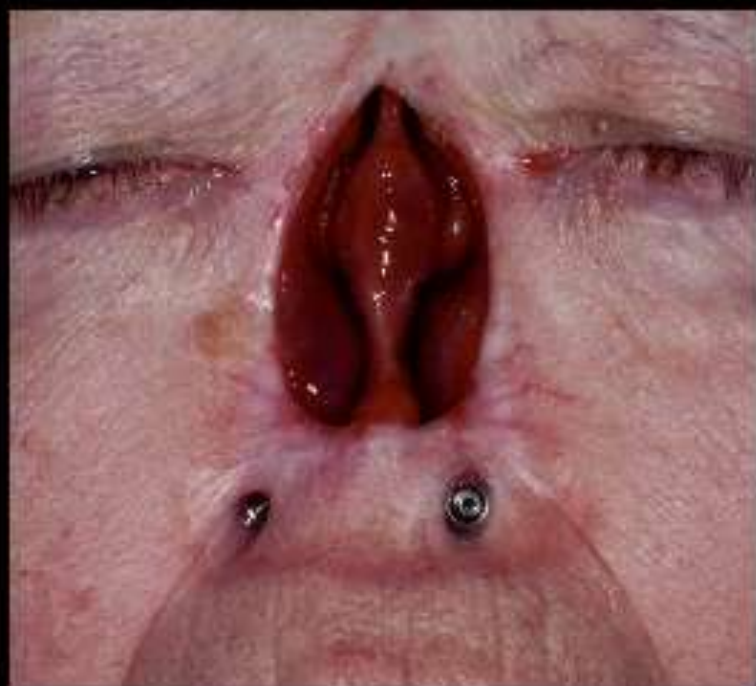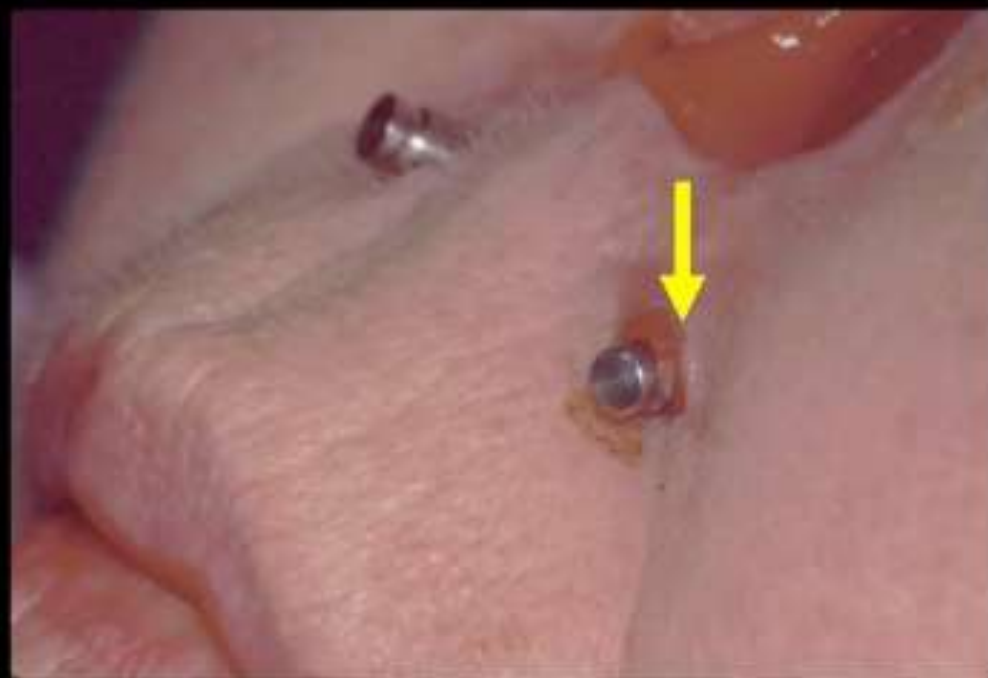
# Magnetic retention



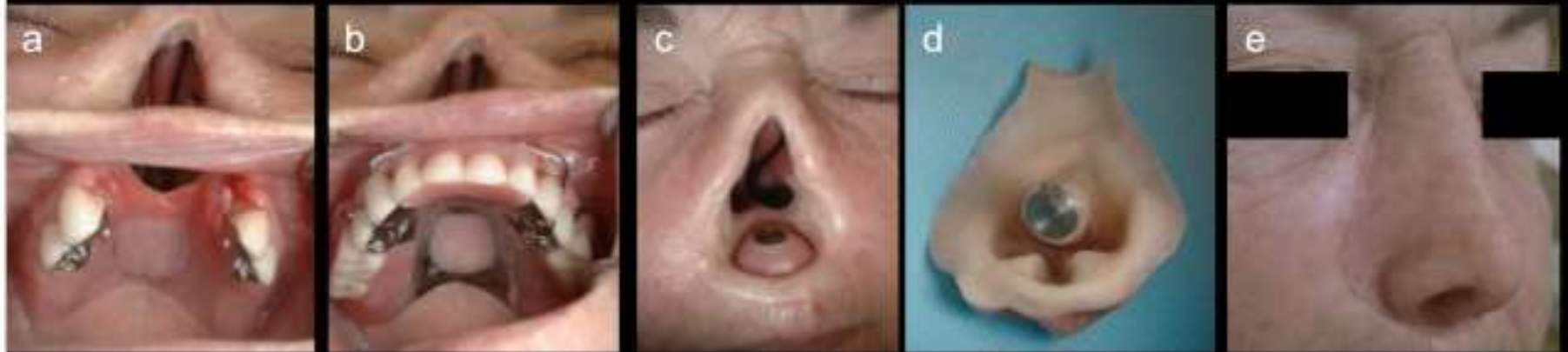
- ❖ Originally two implants were placed but 5 years later only one implant remained. Bar-clip retention was changed to magnetic retention to reduce the stresses on the surviving implant. The tissue bar engages hex atop implant fixture to prevent rotation of bar and loosening of screw (a).
- ❖ Posterior surface of nasal prosthesis. Note magnetic attachments (b).
- ❖ Prosthesis in position (c).

# Complications

- ❖ Implants placed in the mobile tissues of the upper lip. Clinical result: Tissue hypertrophy around the implants (arrow).
- ❖ **Solution:** Subcutaneous resection



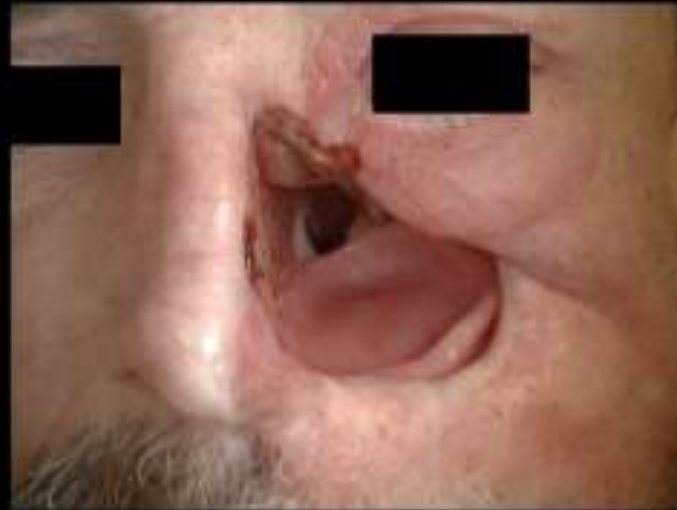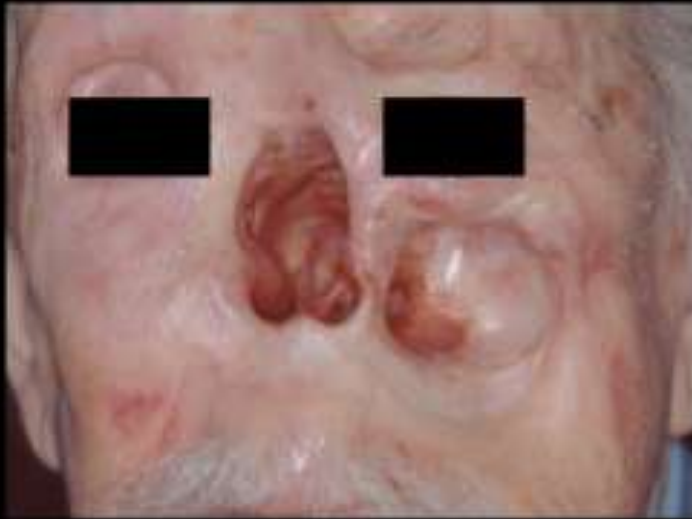## Combined nasal oral defects



Nasal prosthesis retained by RPD obturator prosthesis with a magnet. a: Oral-nasal defect. Surveyed crowns made to retain Obturator-RPD. b and c: Obturator-RPD in position. Note magnetic attachment. d: Nasal prosthesis. e: Prosthesis in position.



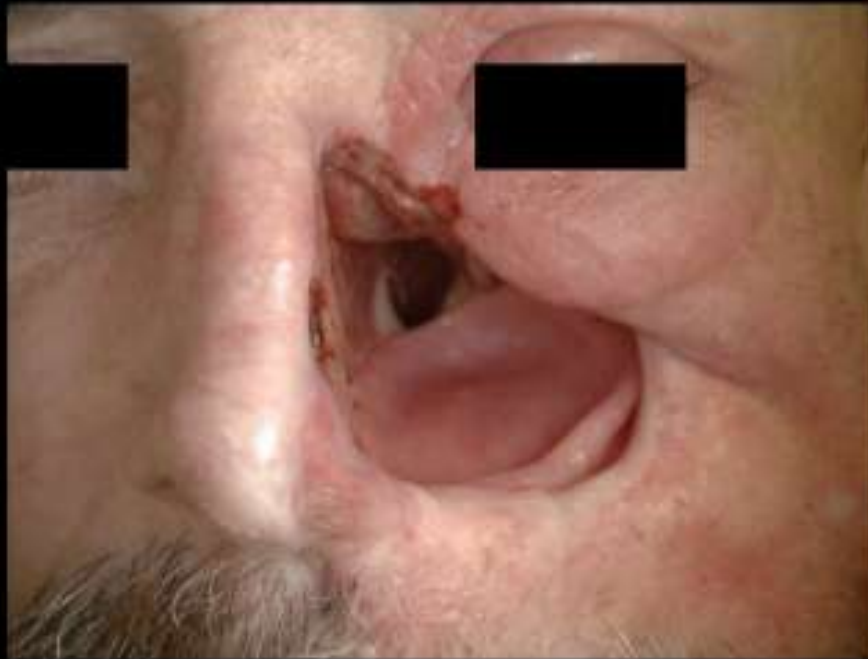# Combined nasal cheek defects



## Challenges

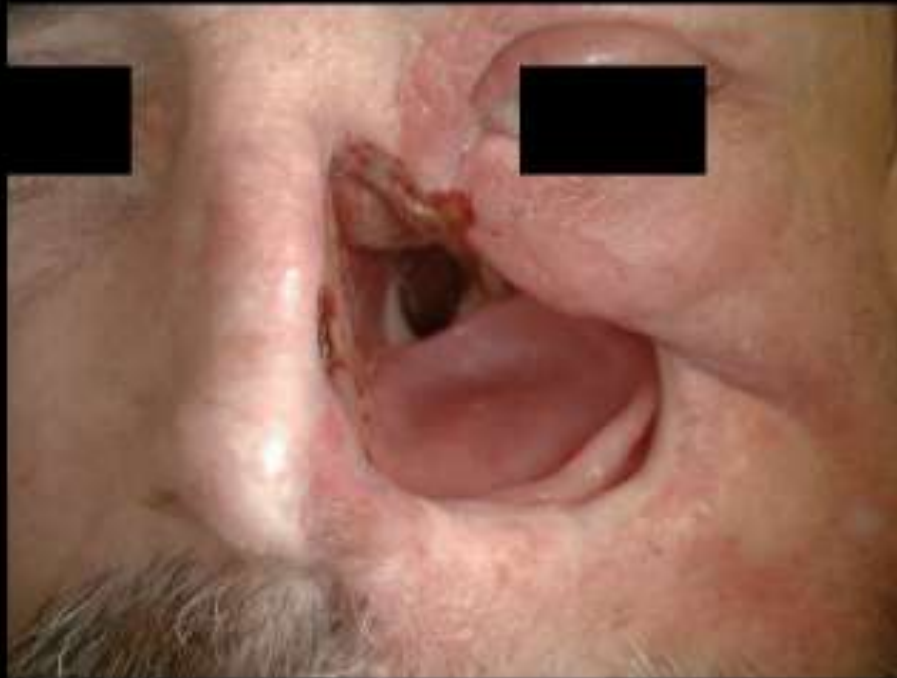- ❖ Retention
- ❖ Significant distortions of adjacent tissues
- ❖ Extensions and margins
- ❖ Contour of prosthetic cheek
- ❖ Movable tissues

## Combined nasal cheek defects



- ❖ Patient presents status post maxillectomy with the resection extending to involve the cheek and half the nose.
- ❖ The maxillary obturator restores the contour of the upper lip.
- ❖ The remaining portion of the nose is in a favorable position and normal in contour.

# Combined nasal cheek defects

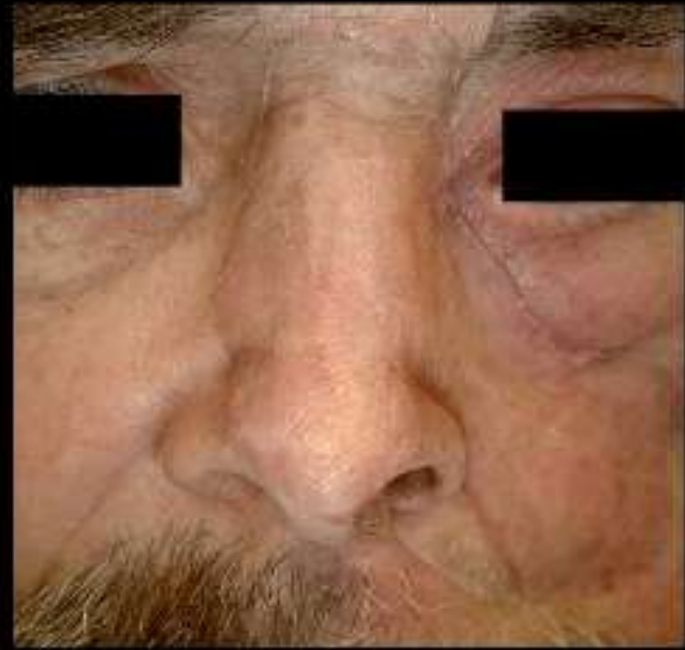
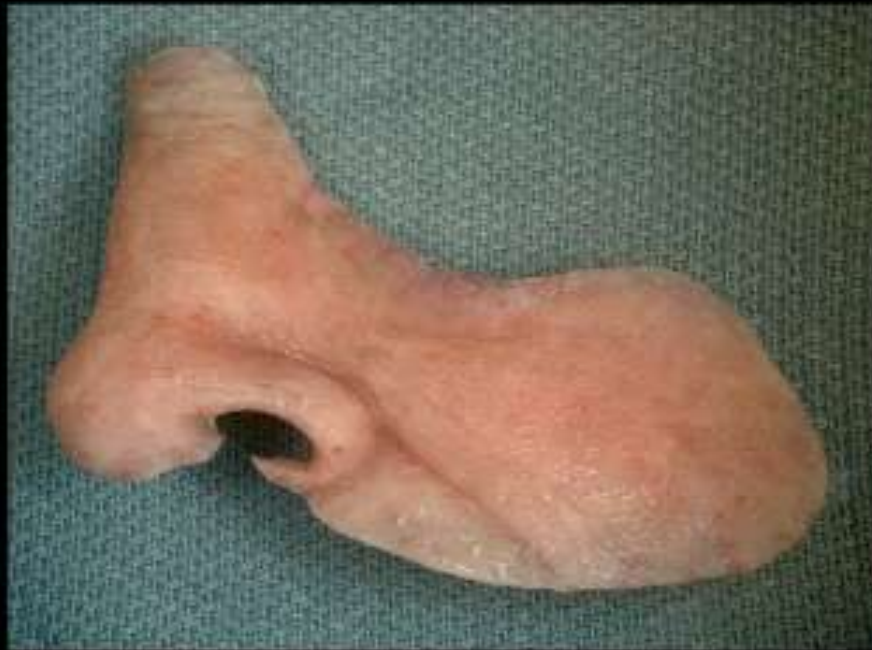
## Issues in this patient

- ❖ Should the oral prosthesis engage the maxillary obturator to facilitate retention?
  - ❖ Yes!!! This will facilitate retention and stability
- ❖ Where should the nasal margins terminate?
  - ❖ On the lateral wall of the nose

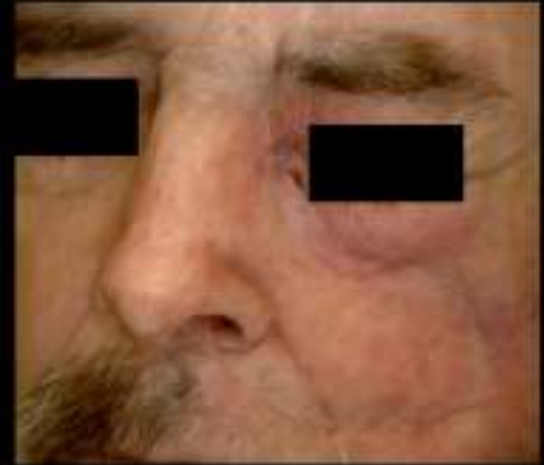
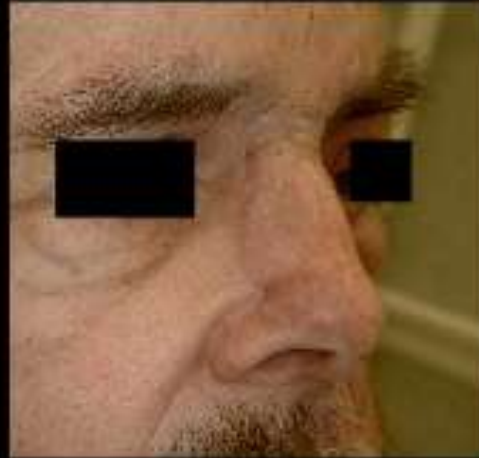
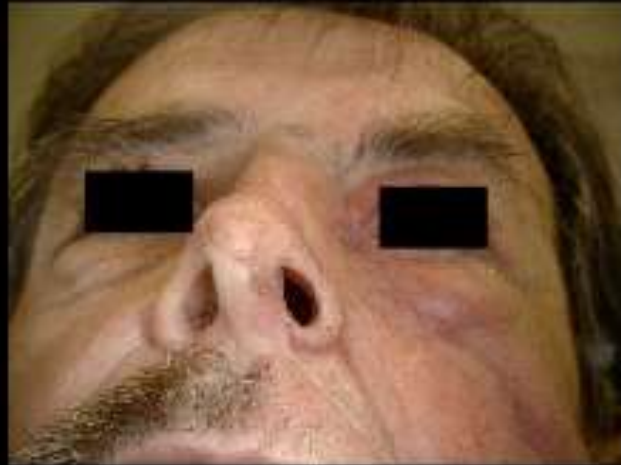# Combined nasal cheek defects



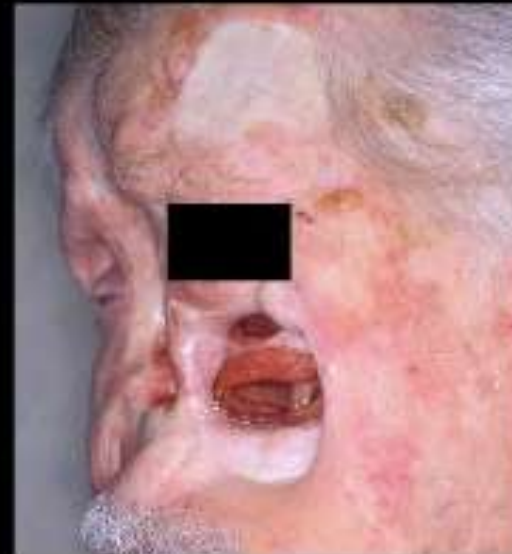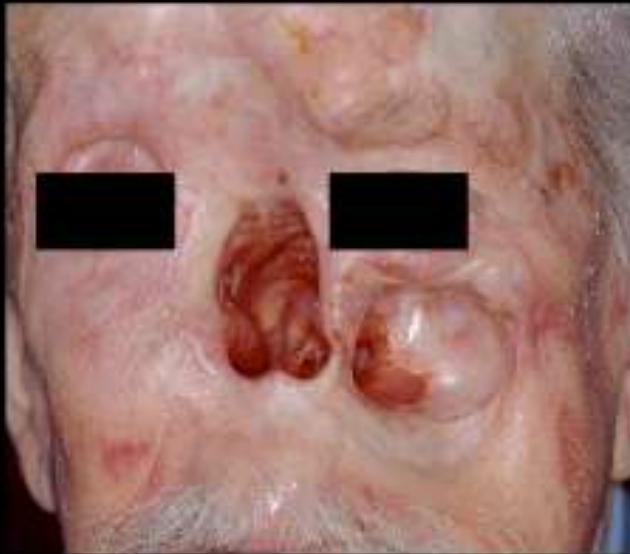
This facial prosthesis engages the maxillary obturator via magnets in a manner shown on previous patients. The prosthesis covers the tip of the nose and is extended laterally on the right side of the nose.

# Combined nasal cheek defects



- ❖ Note the contour of the prosthetic nostril and how the alar groove flows into the nasolabial fold.
- ❖ Extending the nasal margin laterally makes this margin less detectable.

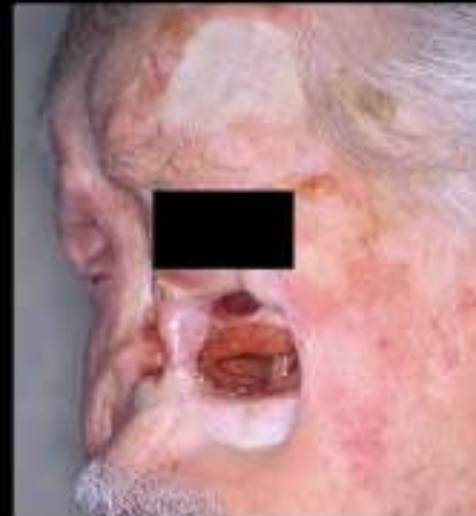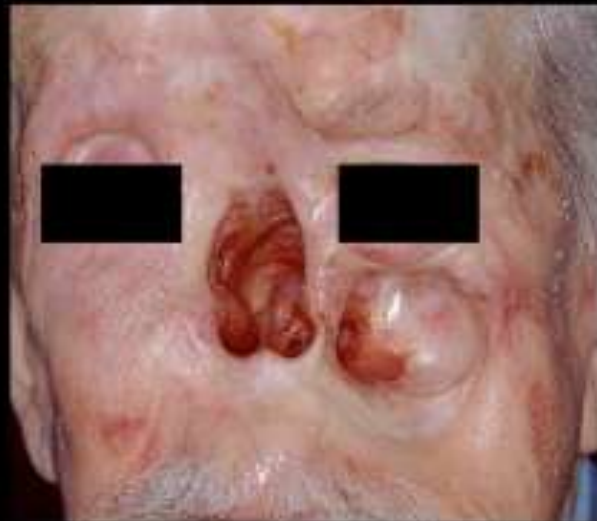## Combined nasal cheek defects



- ❖ Patient is status post multiple resections for multiple and recurrent basal cell carcinomas
  - ❖ The defect extends into the left maxillary sinus. This area is lined with a split thickness skin graft.
  - ❖ There is a large concave area above the glabella
  - ❖ The right eye lids are paralyzed in position
  - ❖ The upper lip is fairly mobile



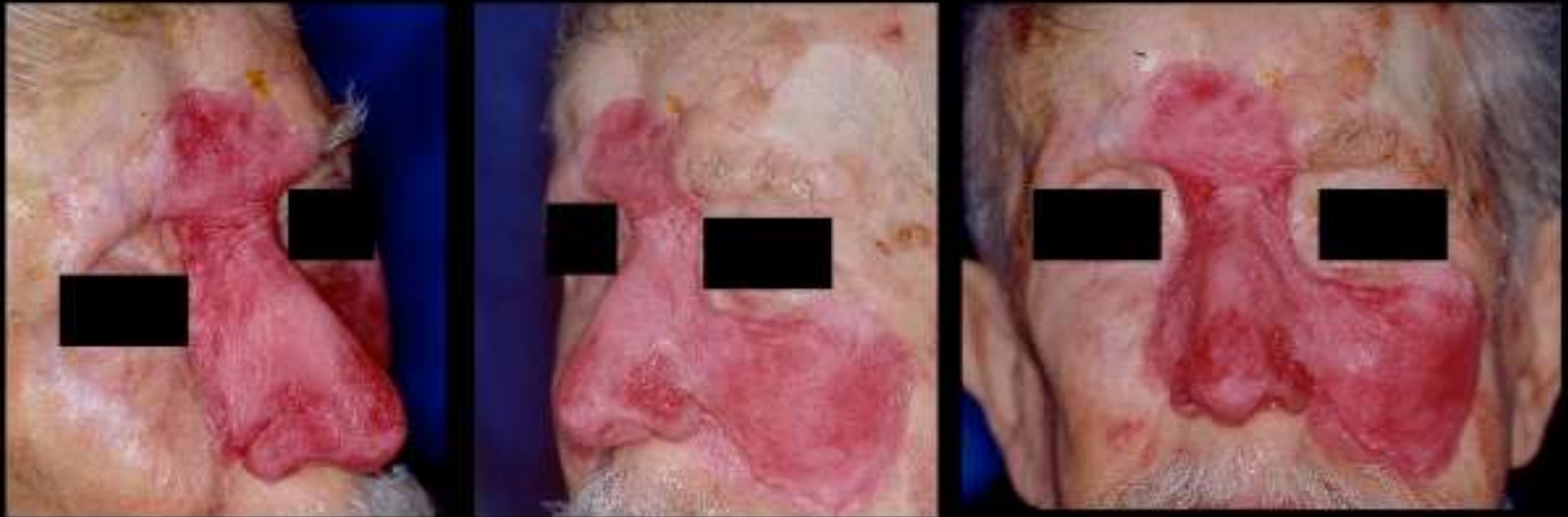# Combined nasal cheek defects



## Issues in this defect

- ❖ **Size and shape of the nose?**
  - ❖ Presurgical photos are most helpful
- ❖ **Contour of the left cheek?**
  - ❖ Best left under contoured to better blend with existing contours
- ❖ **Forehead margin?**
  - ❖ Extend to make prosthesis blend in smoothly with the unaffected forehead contours
- ❖ **Left cheek margin?**
  - ❖ Mobility of the cheek affects this margin. Generally one should try to minimize the margin so as to extend just beyond the margins of the defect
- ❖ **Left nasolabial fold?**
  - ❖ Try to achieve reasonable symmetry with the left nasolabial fold

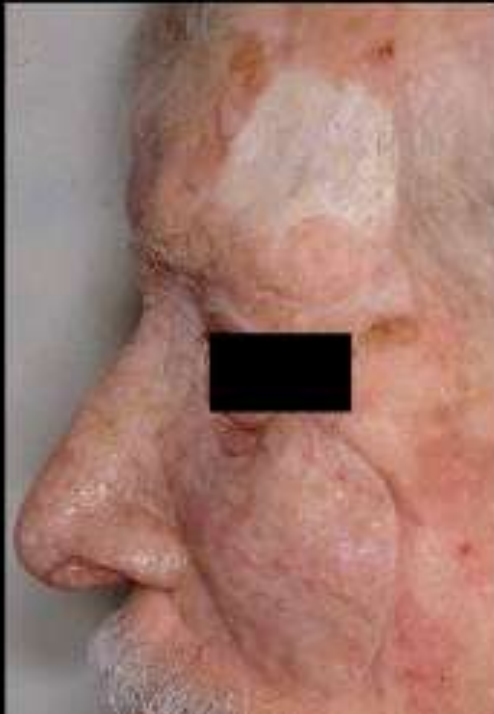
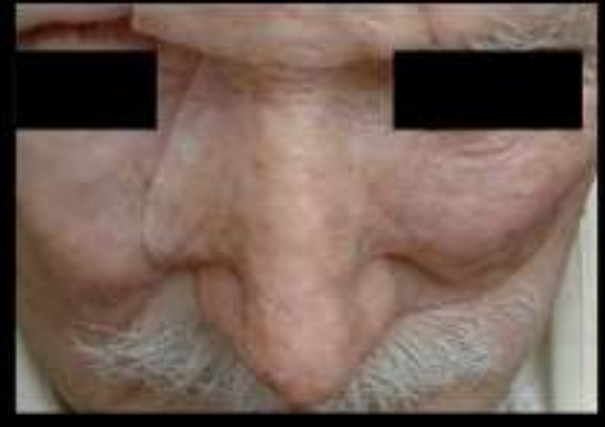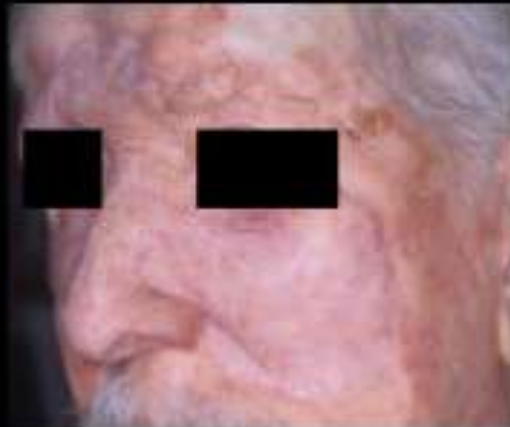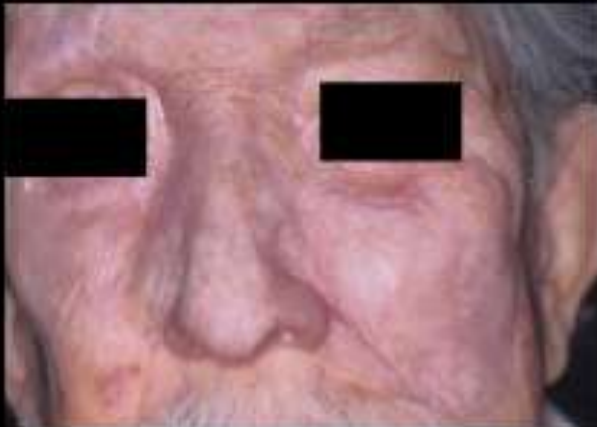# Combined nasal cheek defects



- ❖ Shape of the nose is based on presurgical photos. The width is based on the inter canthus distance.
- ❖ The contours of the forehead-glabella region have been restored
- ❖ The cast in the suborbital area has been slightly scored so as to effect positive pressure in this region.
- ❖ The left prosthetic cheek area has been under contoured to better blend with existing facial contours.
- ❖ The left nasolabial fold has been restored and this area extended onto the upper lip.



# Combined nasal cheek defects



## Finished prosthesis

- ❖ Note the contour of the left cheek portion of the prosthesis. It has been under-contoured to blend in with the existing facial contours.
- ❖ The contours of the left nostril-nasolabial fold interface has been made symmetrical with the right side and the prosthesis extended onto the lip on this side.



---

Thank you

