

## **Etiology of malocclusion(local factors)**

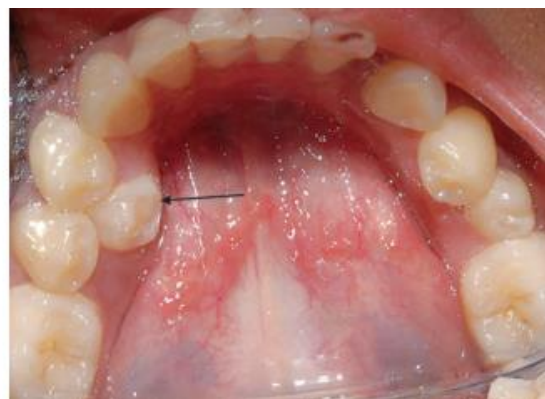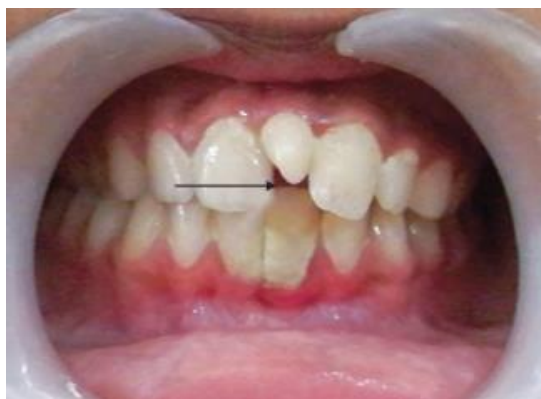- A. Anomalies of number
  - 1. Supernumerary teeth
  - 2. Missing teeth
- B. Anomalies of tooth size
- C. Anomalies of tooth shape
- D. Premature loss of deciduous teeth
- E. Prolonged retention of deciduous teeth
- F. Delayed eruption of permanent teeth
- G. Abnormal labial frenum
- H. Dental caries
- I. Improper dental restorations
- J. Ankylosis
- K. Abnormal eruptive path

### **Anomalies of tooth number**

Anomalies of tooth number include presence of extra teeth or absence of one or more teeth that can predispose to malocclusion.

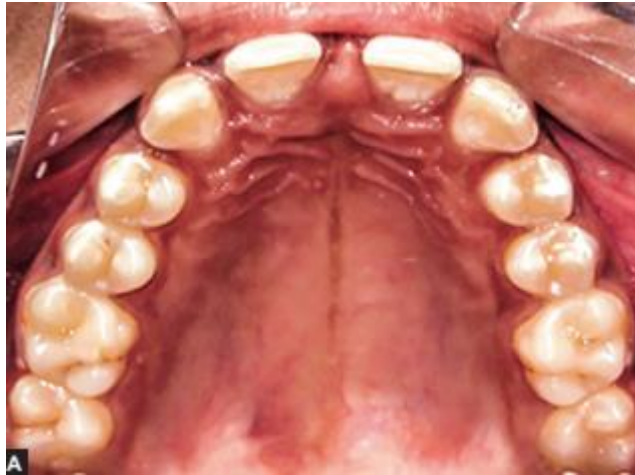#### **Supernumerary Teeth**

Extra teeth in relation to the normal complement of teeth are generally referred to as supernumerary teeth. These teeth usually have abnormal morphology and do not resemble normal teeth. Extra teeth, which closely resemble the normal teeth, are called as supplemental teeth, which are often observed to occur on lateral incisors and premolar regions.



#### **Congenitally Missing Teeth**

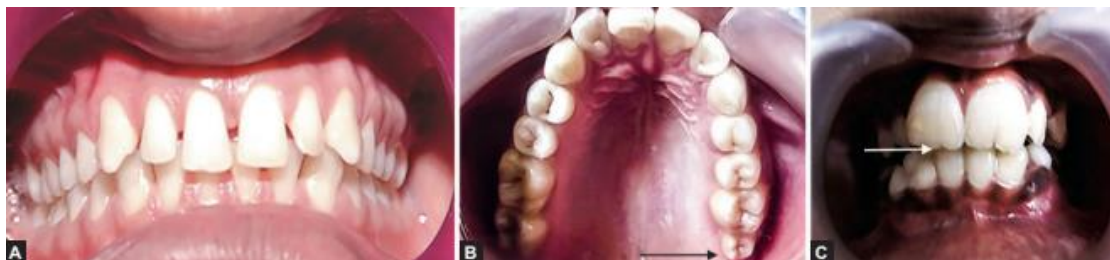The occurrence of congenitally missing teeth may be single or multiple, unilateral or bilateral and in one or both the jaws.



### **Anomalies of tooth size**

Anomalies of tooth size may occur as two forms: microdontia or macrodontia:

1. Microdontia is used to describe teeth, which are smaller than normal. Microdontia can be generalized involving all the teeth in a dentition or localized involving a single tooth
2. Macrodontia refers to teeth that are larger than normal. Macrodontia can also be generalized or localized.



### **Premature loss of deciduous teeth**

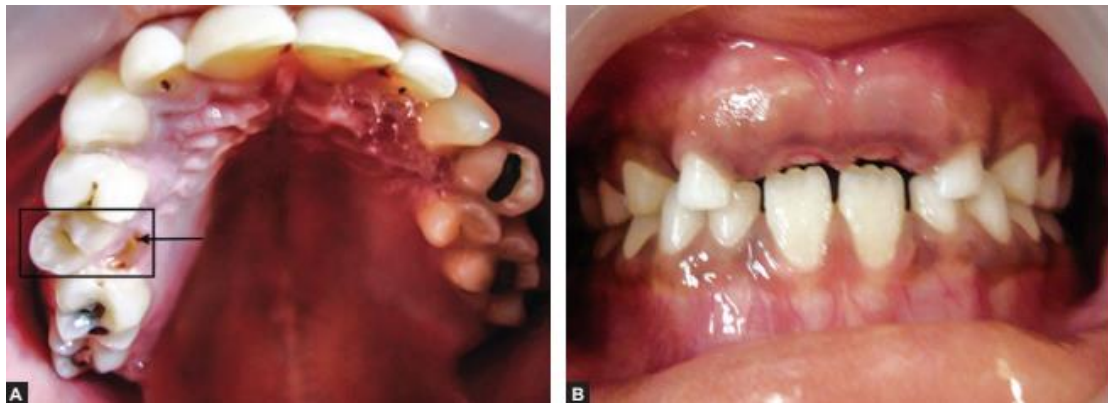
This is a condition where a primary tooth is lost before its permanent successor is ready to erupt. As the adjacent teeth get sufficient time to migrate into the created space, thereby delaying, preventing and deviating the path of eruption of the succeeding permanent tooth. Premature loss of deciduous teeth, if not intercepted often lead to malocclusion. Deciduous teeth may be lost prematurely due to dental caries or trauma.

### **Prolonged retention of deciduous teeth**

This is a condition in which there is undue retention of deciduous teeth beyond the usual exception age of their permanent successor.

There are number of causes for prolonged retention of deciduous teeth as listed below:

1. Absence of underlying permanent tooth,
2. Nonvital deciduous tooth, which fail to resorb,
3. Ankylosed deciduous tooth that do not resorb.



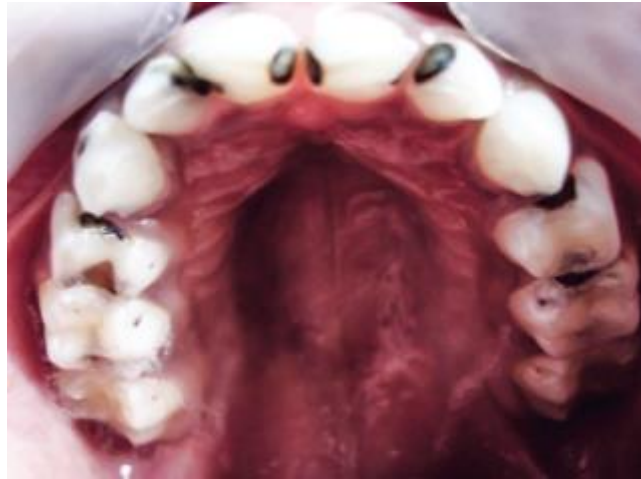
### **Delayed eruption of permanent teeth**

Permanent teeth erupt in a preprogrammed sequential manner throughout mixed dentition period to occupy their respective places. A delay in the eruption of any of the permanent teeth, out of normal time to meet, however, can cause migration of adjacent teeth into the available space.

### **Dental caries**

Dental caries is one of the most common local causes of malocclusions. Proximal caries or complete loss of affected tooth with dental caries may cause the following effects:

1. Premature loss of the affected tooth or proximal caries.
2. Proximal caries can cause drifting of adjacent teeth into space created with resultant loss of arch length
3. Premature loss of affected tooth can cause migration of adjacent teeth into the space.
4. Abnormal inclination of adjacent teeth.
5. Over eruption of antagonistic teeth.



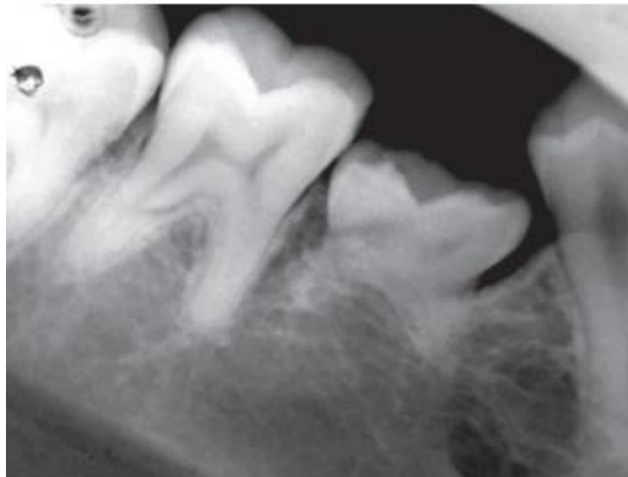### **Improper dental restorations**

While restoring any tooth, it is important to restore the normal occlusal anatomy and proximal contours, so as to maintain normal intercuspation of the teeth and their mesiodistal dimension. Improper restoration of proximal contours may result in an increased arch length and occlusal irregularities.

Over contoured proximal restorations	<ul style="list-style-type: none"> <li>▪ Too tight proximal contact leading to elongation of restored tooth or adjacent teeth</li> <li>▪ Overcontoured restoration in a segment can cause increase arch length</li> </ul>
Under contoured proximal restoration	Loss of arch length due to drifting adjacent teeth into the space
Overfilled occlusal restoration	<ul style="list-style-type: none"> <li>▪ Functional occlusal prematurities</li> <li>▪ Intrusion of antagonistic tooth—pseudo class III</li> </ul>
Underfilled restoration	Supraeruption of antagonistic tooth Functional occlusal disturbances

### **Ankylosis**

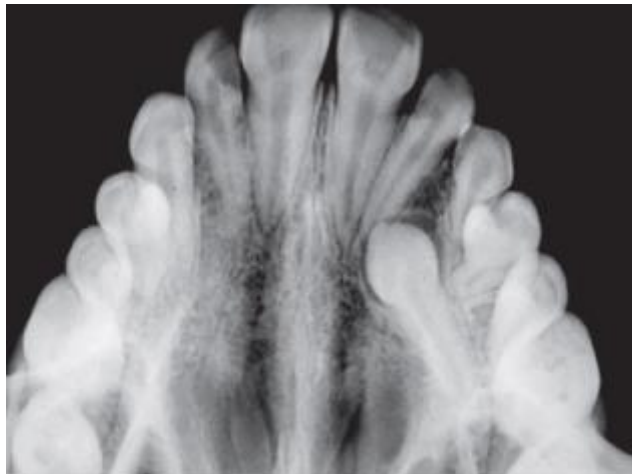
The tooth is said to be ankylosed when a part or whole of its root surface is directly fused to the bone without intervening periodontal ligament. Deciduous second molars are most commonly affected. Ankylosis of deciduous teeth prevents their natural exfoliation and replacement by their successional permanent teeth. Once the adjacent permanent teeth erupt to their normal level, the ankylosed tooth appears to be below the level of occlusion.



### **Abnormal eruptive path**

Malocclusions resulting from abnormal eruptive path of the teeth are not uncommon. Some of the factors, causing delayed eruption of permanent teeth may also deviate their path of eruption, such as:

1. Trauma to the tooth during development
2. Presence of supernumerary teeth
3. Prolonged retention of deciduous teeth
4. Retained deciduous root fragments
5. Deficiency of arch length and excess of tooth material.



## **Introduction**

**Orthodontics:** Is a specialty of dentistry that is concerned with the study and treatment of malocclusions (improper bites), which may be a result of tooth irregularity, disproportionate jaw improved bite (*occlusion*).

The orthodontic can be divided into three categories based on the nature and time of procedures into:-

- 1. Preventive orthodontics**
- 2. Interceptive orthodontics**
- 3. Corrective orthodontics**

### **Preventive orthodontics:**

It is the action taken to preserve the integrity of what appears to be normal occlusion at a specific time. For example:

1. Caires control,
2. Anatomical dental restoration,
3. Space maintenance.

### **Interceptive orthodontics:**

It is phase of orthodontics that used to recognize and eliminate potential irregularities and malpositions in the developing dentofacial complex. For example:

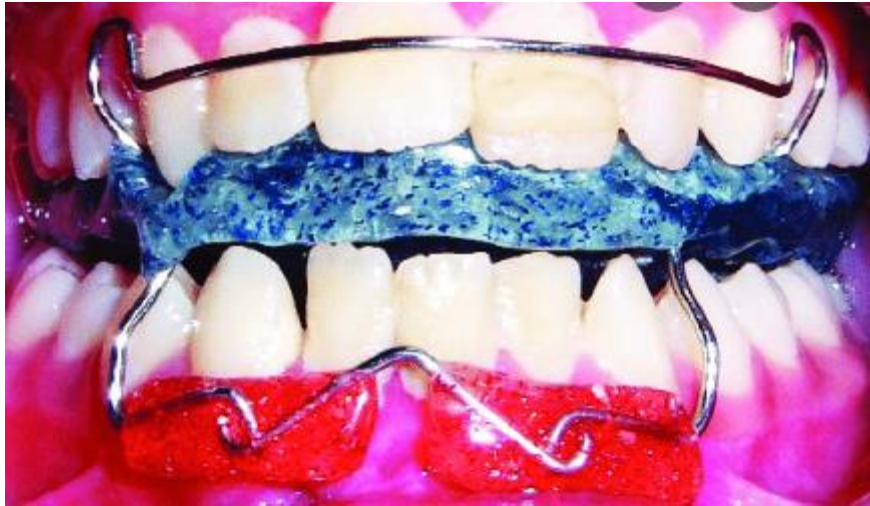1. Space regaining,
2. Correction of anterior and posterior cross bites,
3. Elimination of oral habits,
4. Interception of developing skeletal malocclusions.

### **Corrective orthodontics:**

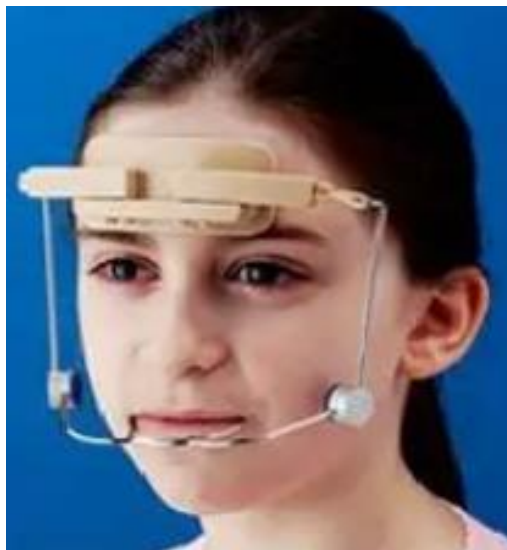Find the extension of the condition and determine technical procedures to reduce or eliminate the problem.

- Functional: Indicated to reduce and eliminate any possible problems. Sometimes by using myofunctional orthodontic devices.

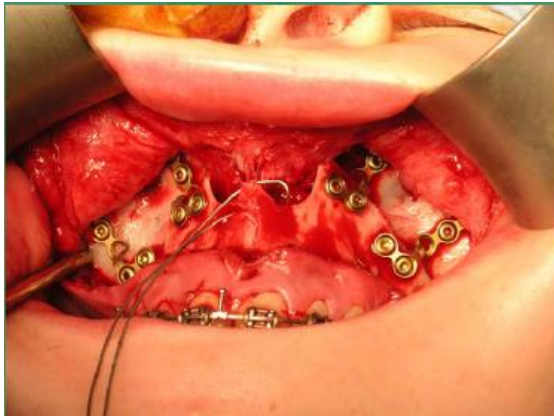




- Mechanical: When extra/intraoral devices are used, to correct the present anomalies



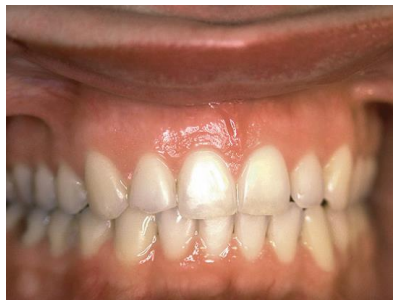- Surgical: Indicated especially in adults and/or when orthodontic methods can't fix the problems.



### Necessary terms

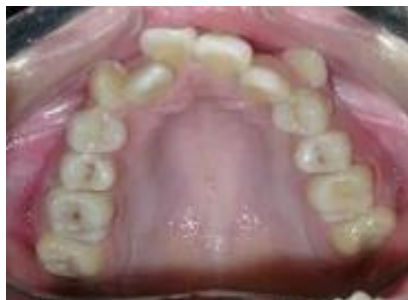**Occlusion** Any contact between teeth of opposing dental arches, usually referring to contact between the occlusal surfaces.

**Ideal occlusion:** A theoretical occlusion based on the morphology of the teeth. (or) The ideal relationship of the teeth can be defined in terms of static (or morphological) and functional occlusion.



**Normal occlusion:** An occlusion which satisfies the requirements of function and aesthetics but in which there are minor irregularities of individual teeth.

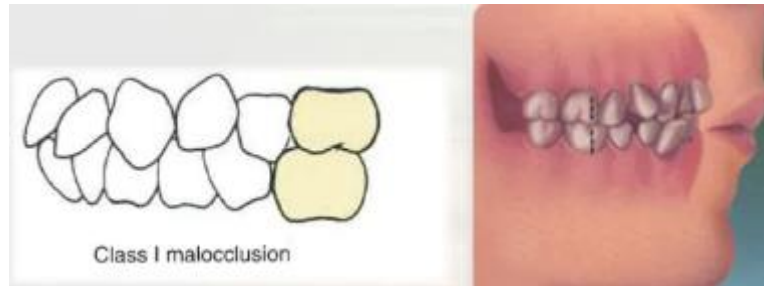
**Malocclusion:** Can be defined as an appreciable deviation from the ideal that may be considered aesthetically or functionally unsatisfactory. (or) An occlusion in which there is a mal-relationship between the arches in any of the planes of space or in which there are anomalies in tooth position beyond the limits of normal.



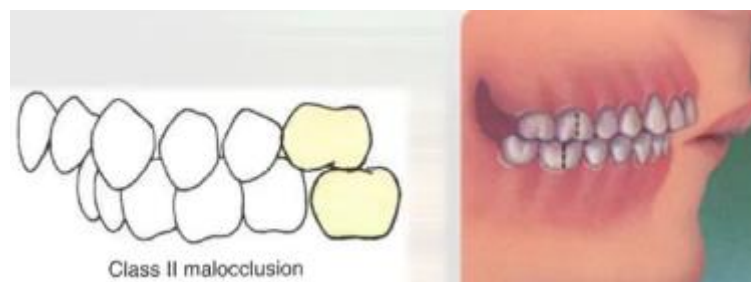


## Classification of malocclusion

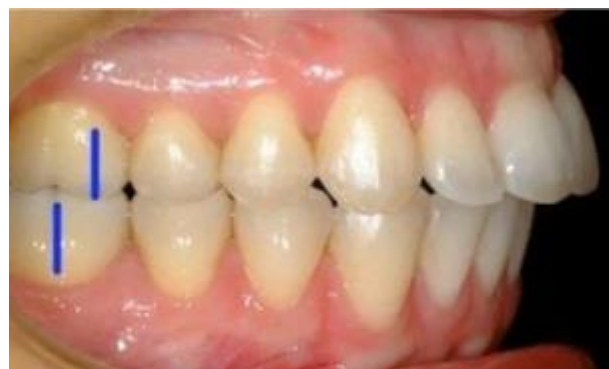**Class I malocclusion:** The mesiobuccal cusp of the upper first permanent molar occludes with the mesiobuccal groove of the lower first molar, but line of occlusion is incorrect because of malposed teeth, rotations or other discrepancies.



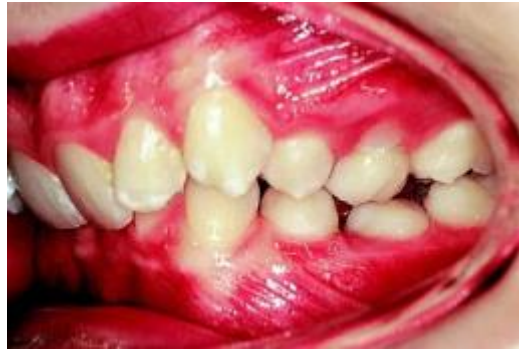**Class II malocclusion:** The mesiobuccal cusp of the lower first permanent molar occludes distal to the class I position.



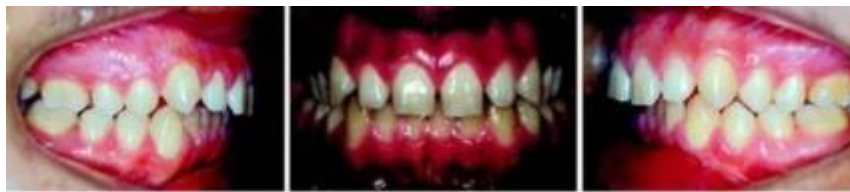**Class II division 1 condition:** When class II molar relationship is present with proclined upper central incisors. There is an increase in overjet.



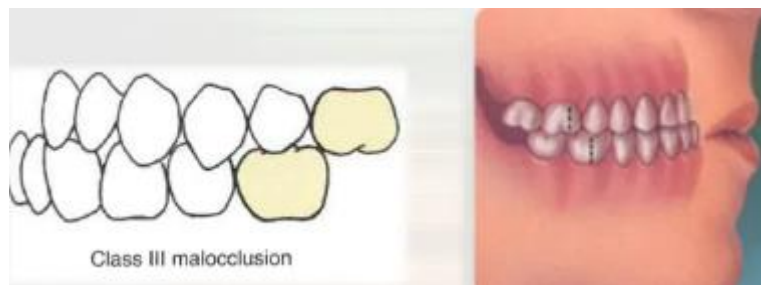
**Class II division 2 condition:** When class II molar relationship is present with retroclined upper central incisors, upper lateral incisors may be proclined or normally inclined. Overjet is usually minimal or may be increased.



**Class II sub-division:** Condition when the class II molar relationship exists on only one side with normal molar relationship on the other side.

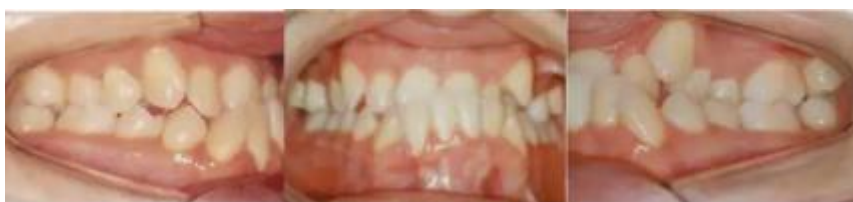

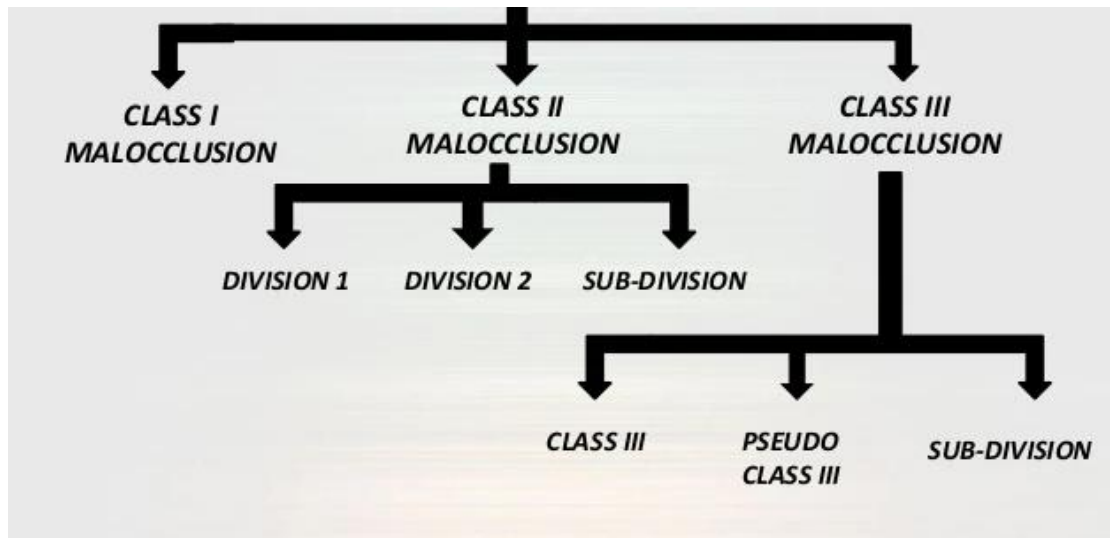
**Class III malocclusion:** The mesiobuccal cusp of the lower first molar occludes mesial to the class I position.



**Pseudo class III malocclusion:** Due to occlusal prematurity, when the mandible moves from rest position to occlusion, it slides forward into a pseudo class III position. It's also known as postural class III.

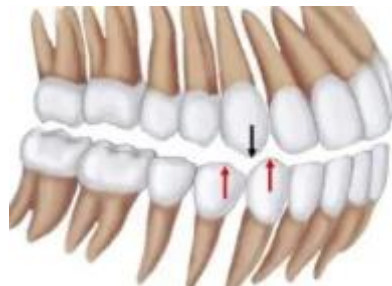**Class III sub-division:** Condition in which class III molar relationship is present only on one side with normal relation on the other side.



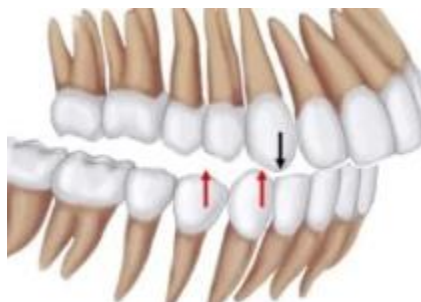


### Canine classification

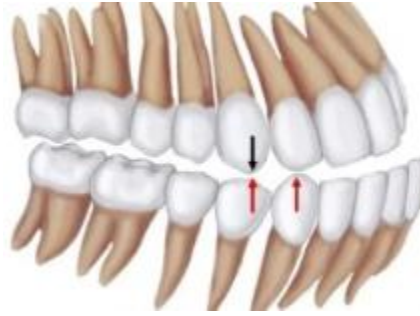
- **Neutroclusion:** Cusp of the maxillary cuspid (canine) occludes between the distal of the mandibular cuspid and the mesial of the mandibular first bicuspid.



- **Distoclusion:** Cusp of the maxillary cuspid (canine) is moved forward and occludes between the distal of the mandibular lateral incisor and the mesial of the mandibular cuspid.

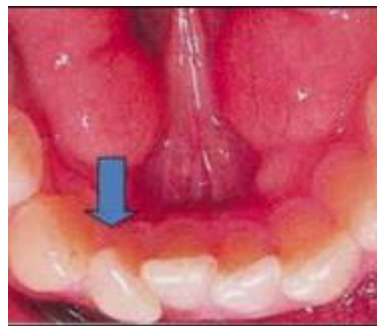


- **Mesioclusion:** Cusp of the maxillary cuspid (canine) is moved back and occludes behind the mandibular cuspid and in the middle of the mandibular first molar.

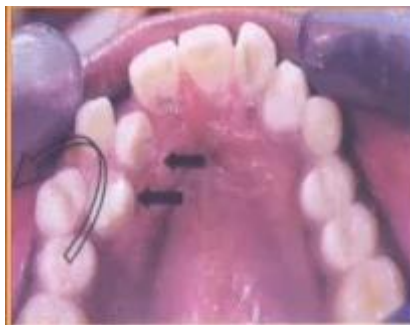

### Malposition of Individual Teeth

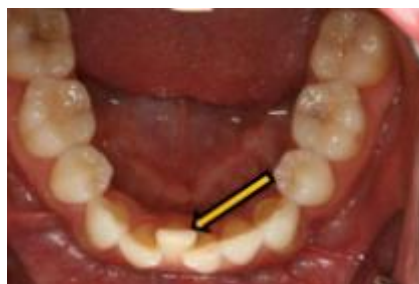- Torsion: Tooth is rotated or turned



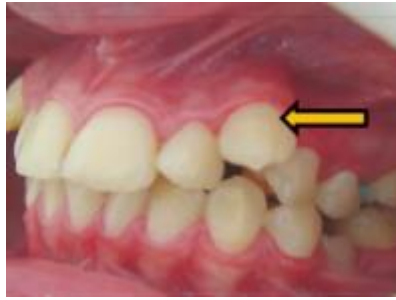- Mesioversion: Tooth is mesial to normal position
- Distoversion: Tooth is distal to normal position



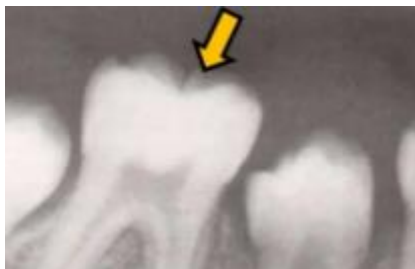- Linguoversion: Tooth is lingual to normal position



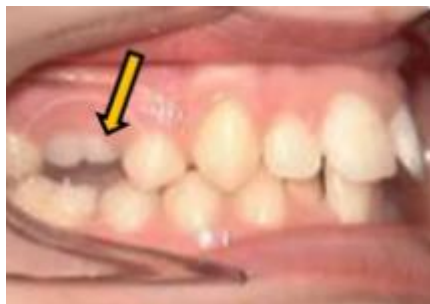- Labioversion or buccoversion: Tooth is tipped toward the lip or cheek



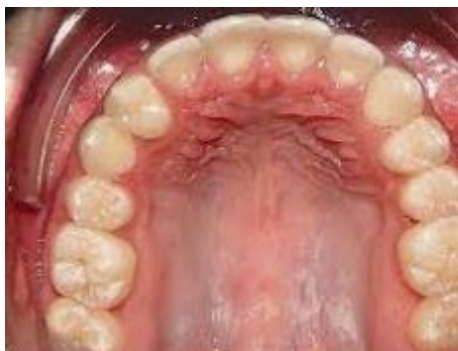- Supraversion: Tooth extends above the normal line of occlusion



- Infraversion: Tooth is positioned below normal line of occlusion



- Transversion or transposition: Tooth is in the wrong order in the arch.



## **Dental occlusion**

**Dental occlusion:** Is defined as the static or dynamic inter-arch relation and corresponds to all possible contacts established between the opposing teeth.

**Physiological Occlusion:** Physiological occlusion refers to an occlusion that deviates in one or more ways from ideal yet it is well adapted to that particular environment, it shows no pathologic manifestations or dysfunctions.

**Static Occlusion:** It is the relationship between the maxillary and mandibular teeth when the teeth are brought to maximum intercuspation. This is presented by the six keys of occlusion.

**Dynamic Occlusion:** It is the occlusal contacts of the maxillary and mandibular teeth during function (speech, mastication, and swallowing). Therefore, this type of occlusion should be free of interferences in the non-working side.

**Working Side:** The side the mandible moves to-wards in lateral excursion.

**Non-Working side:** The side the mandible moves away from during lateral excursions.

**Functional malocclusion:** Occlusal dysfunctions without obvious structural impairments or functional impotency. This adaptive function (called eufunction) is a common situation in the natural development of the individual dentition.

The following conditions appear to be the least pathogenic for the greatest number of patients over the longest time:

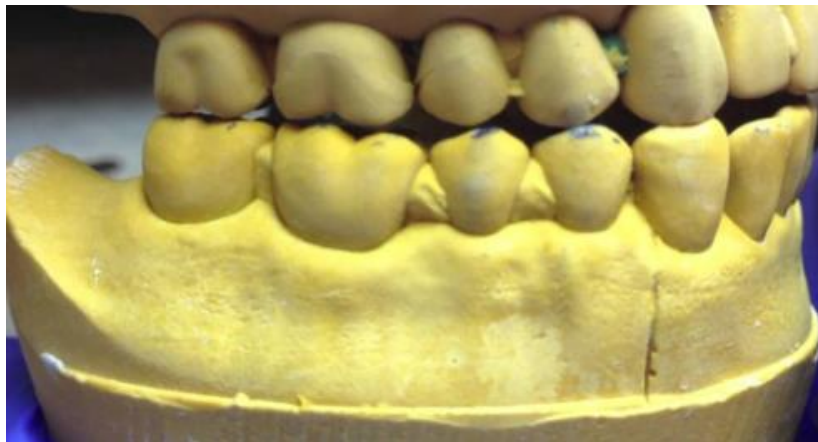1. When the mouth closes, the condyles are in their most supero-anterior position, resting against the posterior slopes of the articular eminences with the discs properly interposed. In this position, there is even and simultaneous contact of all posterior teeth. The anterior teeth also contact but more lightly than the posterior teeth.
2. All tooth contacts provide axial loading of occlusal forces.
3. When the mandible moves into laterotrusive positions, there are adequate tooth-guided contacts on the laterotrusive (working) side to disocclude the mediotrusive (nonworking) side immediately. The most desirable guidance is provided by the canines (canine guidance).
4. When the mandible moves into a protrusive position, there are adequate tooth-guided contacts on the anterior teeth to disocclude all posterior teeth immediately.



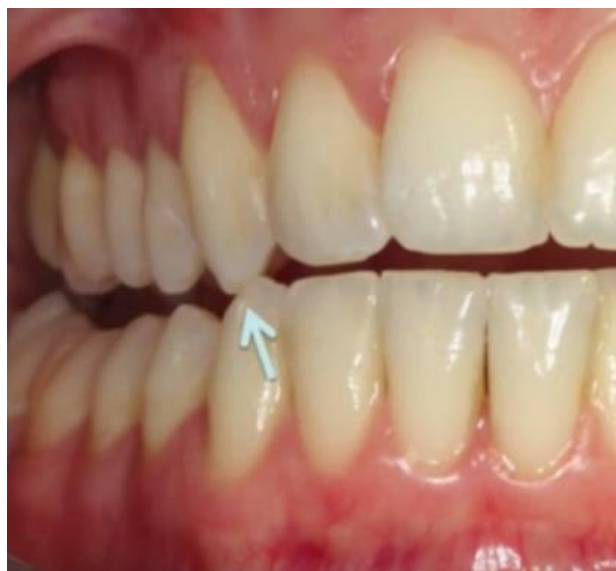5. In the upright head position and alert feeding position, posterior tooth contacts are heavier than anterior tooth contacts.

These types of occlusion can be aimed at to be the goal of functional occlusion, which are:

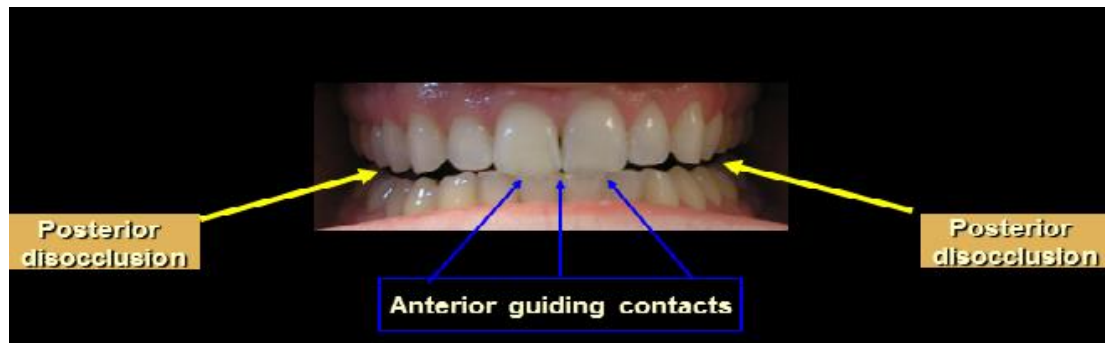1. Group Function: During the entire lateral movements the buccal cusps of the posterior teeth on the working side are in contact. There are no tooth contacts on the non-working side.



2. Canine guidance occlusion: During the lateral excursion, contact occurs only between the upper and lower canine on the working side. There is no contact between the teeth on the non-working side. The canine tooth is the most appropriate tooth to guide the mandibular excursion.

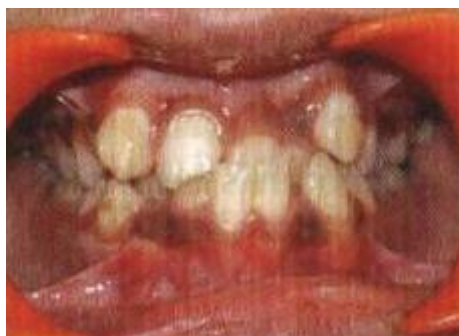

3. Anterior/ Incisal guidance occlusion: When the front teeth are placed together on their biting edges the posterior teeth should not touch.



Pathocclusion: Obvious occlusal disorders characterized by clear dental instability and functional impotency; this occlusal pathofunction is corrected in routine dentistry.

Traumatic occlusion: It is an occlusion which is judged to be a causative factor in the formation of traumatic lesions or disturbances in the supporting structures of the teeth, muscles and TMJ. Almost every dentition has supra contacts that have traumatic potential to alter the status of muscle tones and induce stress. However, the criterion which determines if an occlusion is traumatic or not is not how teeth occlude but **whether it produces any injury**.



Therapeutic occlusion: An occlusion that has been modified by appropriate therapeutic modalities in order to change a non-physiological occlusion to one that is least physiologic.

**Classification of occlusion is done on the base of:**

1. Based on mandibular position.

- a) Centric Occlusion: The relationship of the maxillomandibular occlusal surfaces when they are in maximum intercuspation (tooth to tooth relation).
- b) Eccentric Occlusion: An occlusion other than centric occlusion.
  - 1. Lateral occlusion

2. Protruded occlusion

3. Retrusive occlusion

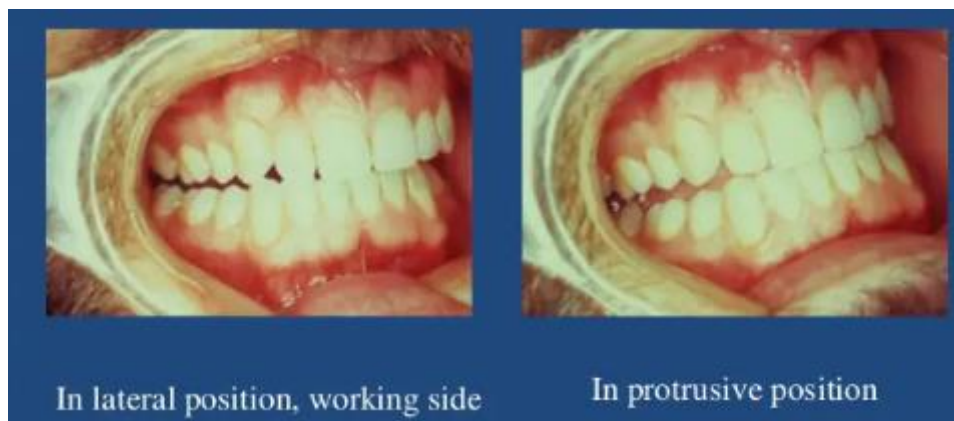2. Based on relationship of 1st permanent molar.

- a) Class I
- b) Class II
- c) Class III

3. Based on organization of occlusion.

- a) Canine guided or protected occlusion
- b) Mutually protected occlusion

Occlusal scheme in which the posterior teeth prevent excessive contact of the anterior teeth in maximum intercuspation. Also, the anterior teeth disengage the posterior teeth in all mandibular excursive movements.



c) Croup function occlusion

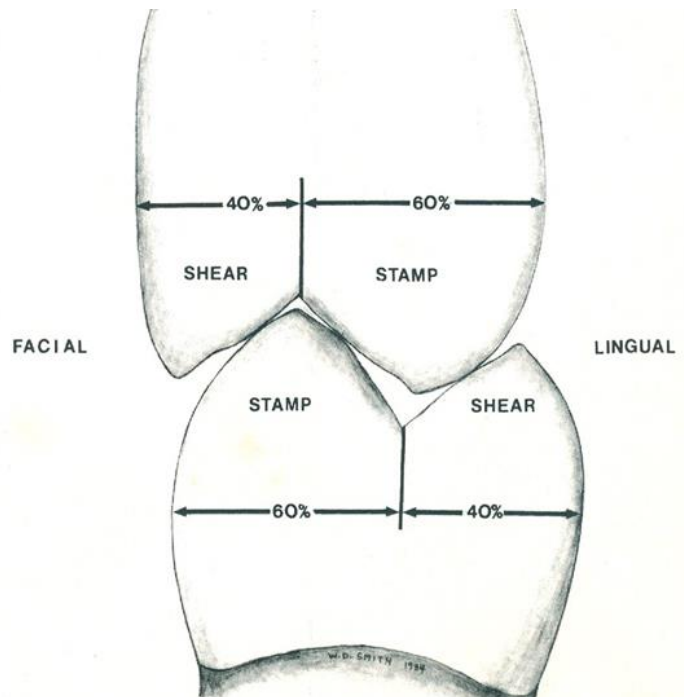
4. Based on pattern of occlusion.

- a) Cusp to embrasure/marginal ridge occlusion
- b) Cusp to fossa occlusion

## Occlusal relationship

### Types of cusps

Lingual cusp of maxillary teeth and facial cusp of mandibular teeth are stamp or centric holding cusp. The facial cusp of maxillary teeth and lingual cusp of mandibular teeth are shearing cusp.

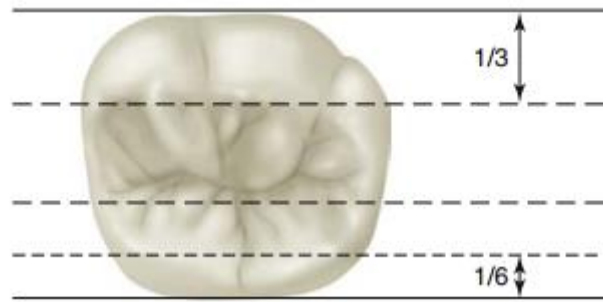


#### Centric Holding Cusp/Stamp Cusp/Supporting Cusp:

Buccal cusp of mandibular posterior teeth and lingual cusp of maxillary posterior teeth occlude with opposing central fossa. These cusps are called **centric or supporting cusps**. These cusps are mainly important for keeping distance between maxilla and mandible, this distance supports the vertical facial height and is called vertical dimension of occlusion.

#### Guiding Cusp/Shear Cusp/Non-supporting Cusp:

Buccal cusps of maxillary posterior teeth and lingual cusp of mandibular posterior teeth area called **guiding or non-centric cusp / shearing cusp**. The major role of non-centric cusp is to minimize tissue impingement and maintain bolus of food on occlusal table for mastication. they also give stability to mandible, so that, when teeth are in full occlusion tight definite occlusal relationship results. This relationship of teeth in their maximum intercuspation is called maximum inter cuspal position.

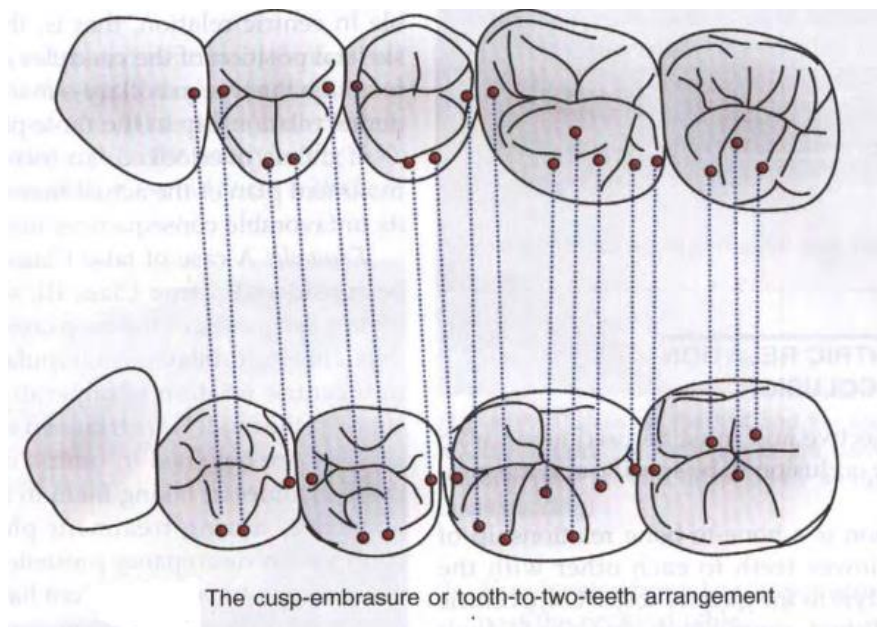


### patterns of occlusal centric contact

There are two types:

#### a. Cusp to embrasure occlusion

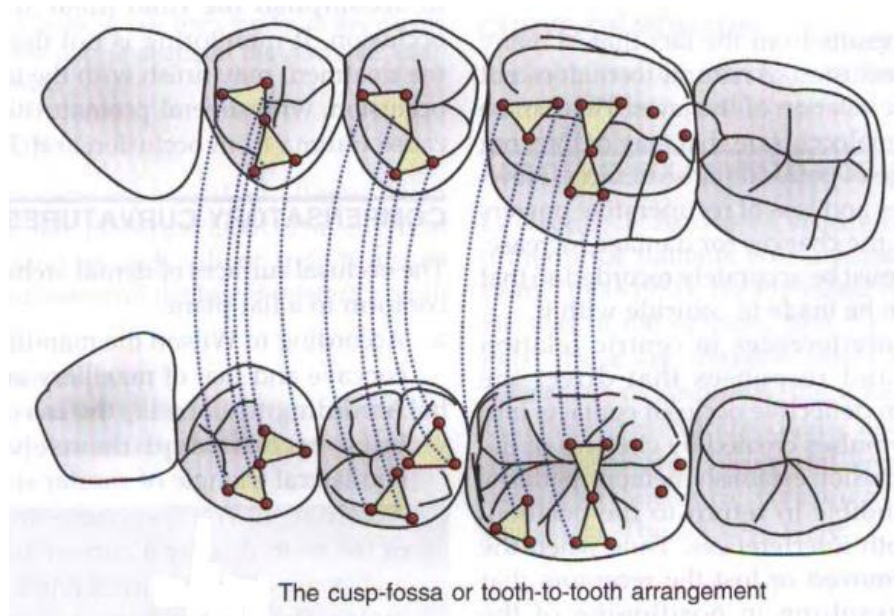
Development of occlusion can result in fitting one stamp cusp into fossa and fitting another stamp cusp into embrasure area of two opposing teeth ( against two marginal ridges of adjacent teeth). It is also called as tooth -to- two teeth occlusion or cusp-embraisure occlusal pattern.



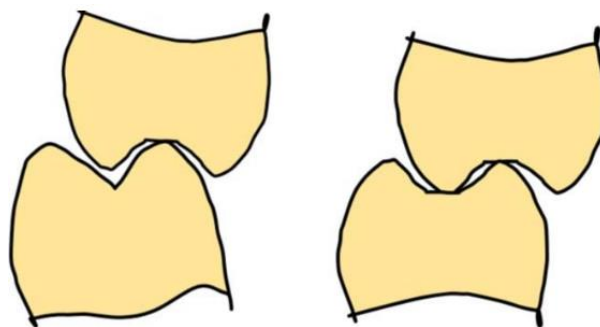


### b. Cusp to fossa occlusion

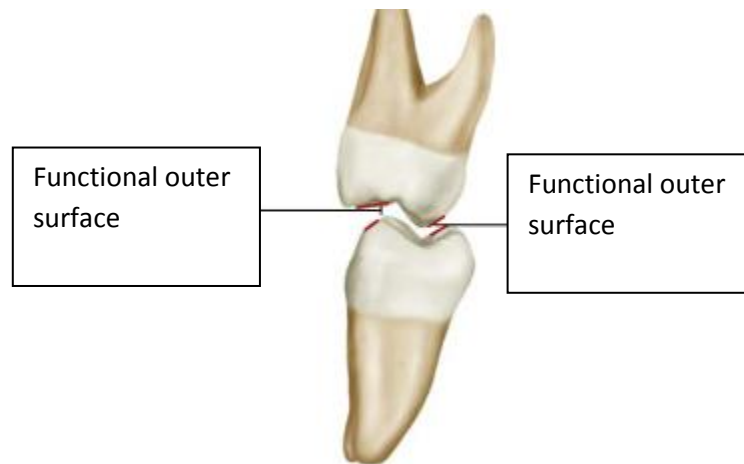
Development and growth of the masticatory apparatus results in most or all of the stamp cusps fitting into fossa. This cusp-fossa relationship normally produces an inter-digitations of the cusps and fossa of one tooth with the fossa only on opposing tooth. This is a tooth-to-one-tooth relation. This has some distinct advantages over the cusp-embrasure arrangement.



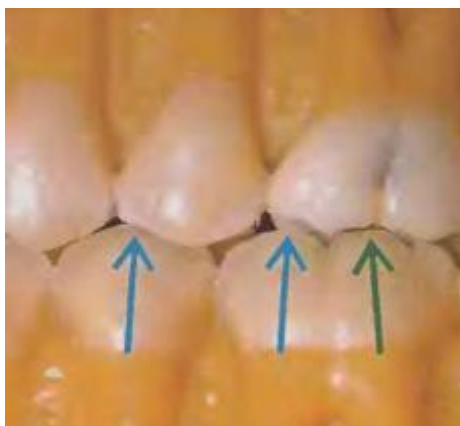Contacts between cusp tips and CF area have been involved to grinding of pestle in mortar. When 2 unlike curved surfaces meet, only certain portions come into contact at given time, leaving other areas free of contact to act as spillways for substance being crushed. When mandible shifts during mastication, different areas contact, creating different spillways. This shifting increases efficiency of mastication.







The other occlusal contact is between cusp types and marginal ridges. Marginal ridges are slightly raised convex areas at mesial & distal borders of occlusal surfaces that joins with inter proximal surface of teeth. The most elevated portion of marginal ridge is only **slightly convex**. Therefore his type of contact is best depicted by cusp tip contacting flat surface. **In this relationship the cusp tip can penetrate through food easily and spillways are provided in all directions.** When mandible moves laterally, actual contacts areas shifts, increase efficiency of chewing stroke. Exact cusp tip is not solely responsible for occlusal contact. Circular area around true cusp tip with radius about 0.5mm provides contact area with opposing tooth surface.



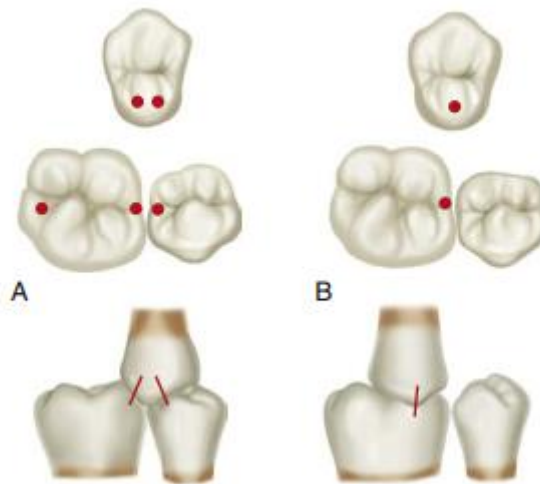
Cusp to marginal ridge occlusion



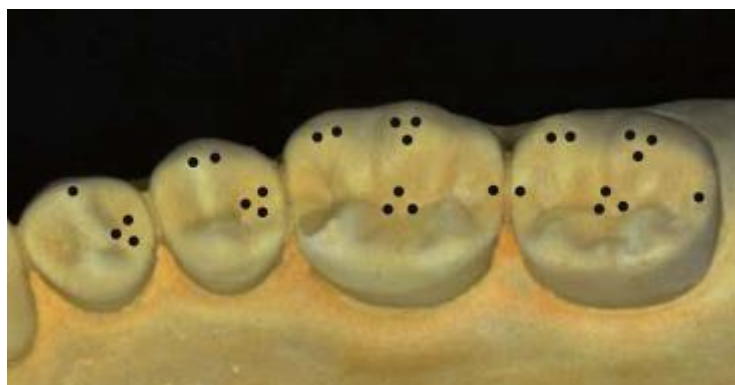Cusp to embrasure occlusion

#### Advantages of cusp-fossa arrangement over cusp-embrasure arrangement

1. Forces are directed more towards the long axis of the teeth.
2. The arrangement leads to greater stability of the arch, decreasing the tendency towards tooth movement.
3. The chance of food impacting in the embrasures is less.

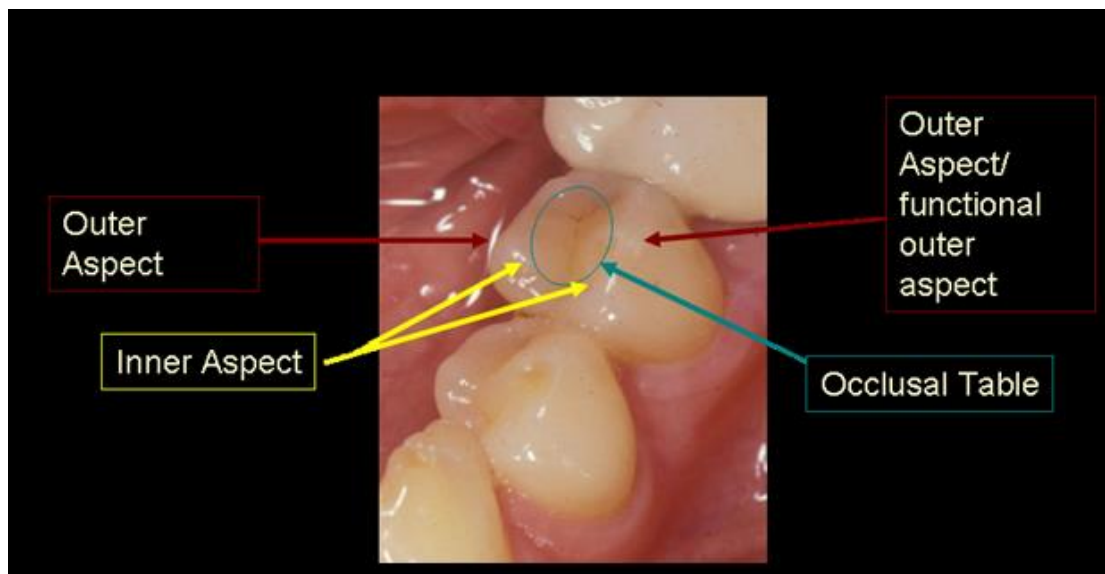
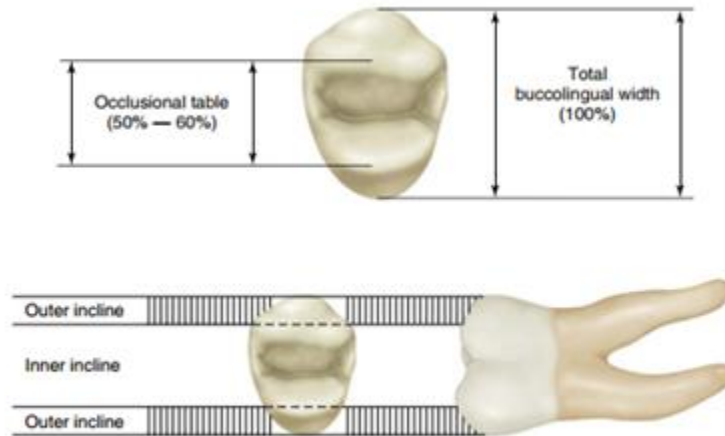


In complete closure in a normal young mouth, the contact point of the supporting cusp is neither at the very tip of the cusp and nor it is a single point. In fact, the supporting cusps are held in firm position by at least three contacts. These contacts occur on the inclines of the cusps. They are called tripod contacts, and the phenomenon is called tripodization. They provide occlusal stability both buccolingually and mesiodistally. There is one buccal and one lingual contact for each cusp along with one mesial or distal contact. With advancing age, there occurs attrition and wear of dentition. The supporting cusps become more and more blunt and seat closer and closer to the bottoms of opposing fossae. Tripodization does not remain as prominent. Eventually, numerous flat cusps and surface contact are formed. These flat, smooth contacts do not allow any definite locking of the jaws which otherwise occurs



The area of tooth between, buccal and lingual cusp tips of posterior teeth is called occlusal table. The major forces of mastication are applied on this area. The occlusal table represents approximately 50% - 60% of total buccolingual dimension of posterior tooth and is positioned over long axis of root structure. It is called inner

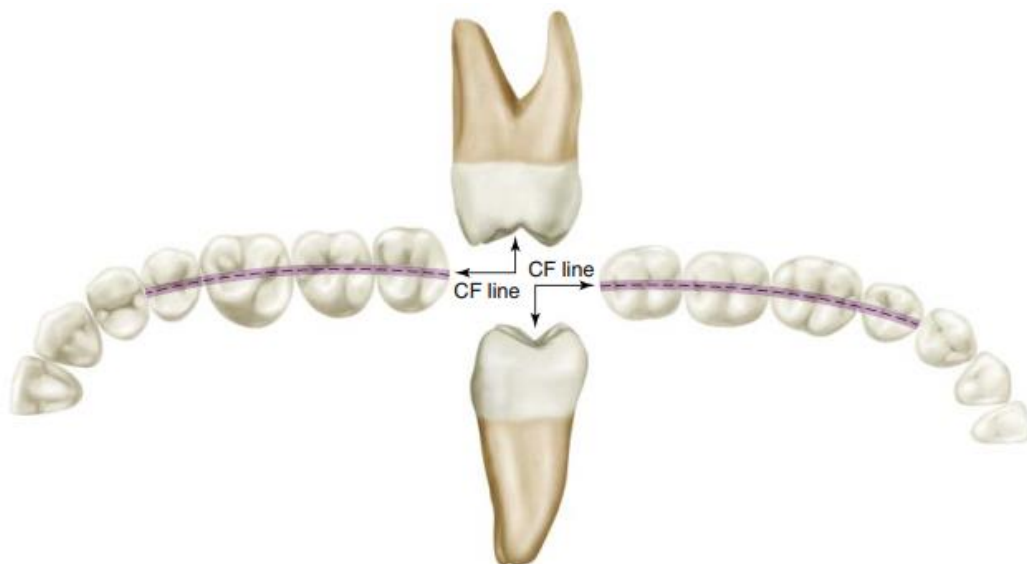
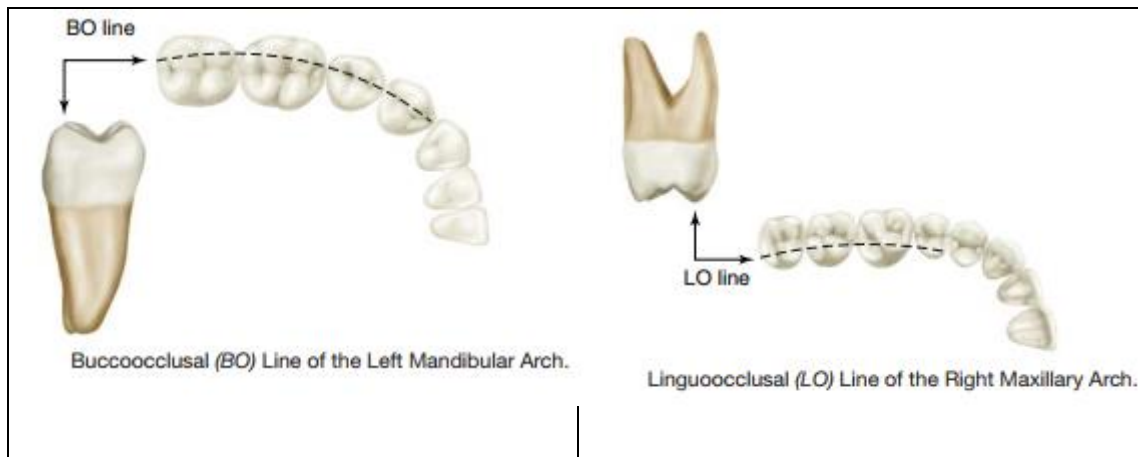
aspect of tooth because it falls between cusps tips. Likewise, occlusal area outside cusp tips is called outer aspect.



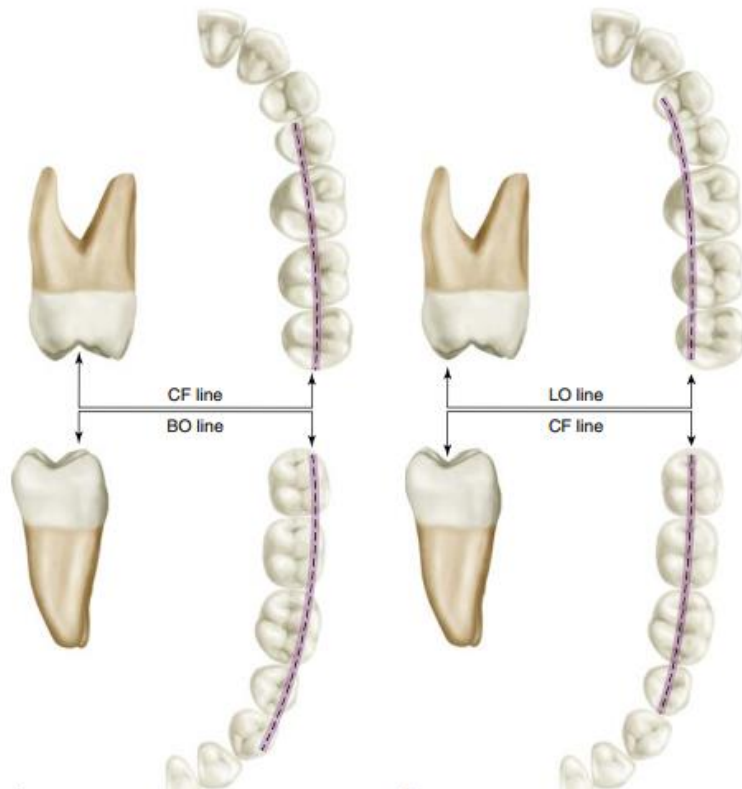
#### Buccolingual occlusal - contact relationship

If imaginary line is extended through all buccal cusp tips of mandibular posterior teeth, bucco-occlusal line is established. In normal arch this line flows smoothly and continuously, revealing general arch form. It also represents demarcation between inner and outer aspects of buccal cusps. If imaginary line is extended through lingual cusps of maxillary posterior teeth, linguo-occlusal line is observed. This line reveals general arch form and represents demarcation between outer and inner aspects of

centric cusps. If third imaginary line is extended through central develop mental grooves of maxillary and mandibular posterior teeth, the central fossa (CF) line is established.



To visualize buccolingual relationship of posterior teeth in occlusion appropriate imaginary lines must be matched. The bucco-occlusal (BO) line of mandibular occludes with CF line of maxillary teeth. Simultaneously the lingo-occlusion(LO) maxillary teeth occludes with CF line of mandibular teeth.



### Mesiodistal occlusal - contact relationship

As it has been explained previously Occlusal contacts occur when centric cusp contact opposing CF Viewed from facial, these cusps typically contact in one of 2 areas.

- CF areas
- Marginal ridge / embrasure areas.

### Alignment and Occlusion of Dentition:

#### Intra arch alignment

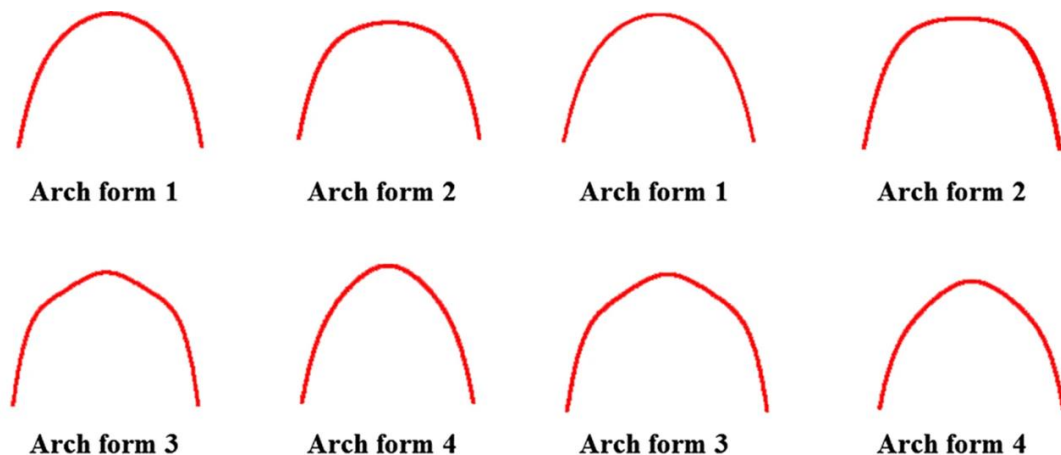
Intra arch tooth alignment refers to relationship of teeth to each other within dental arch. The occlusal planes of dental arches are curved in manner that permits maximum use of tooth contact during function. As flat occlusal plane will not permit simultaneous functional contact in more than one area of dental arch. The occlusal surfaces of teeth are made up of numerous cusps, grooves and sulci. During function these occlusal elements permit effective breaking up of food and mixing with saliva to form bolus that is easily swallowed.

## Inter arch tooth alignment

Refers to relationship of teeth in one arch to those in other. When two arches come in contact, as in mandibular closure, occlusal relationship of teeth is established.

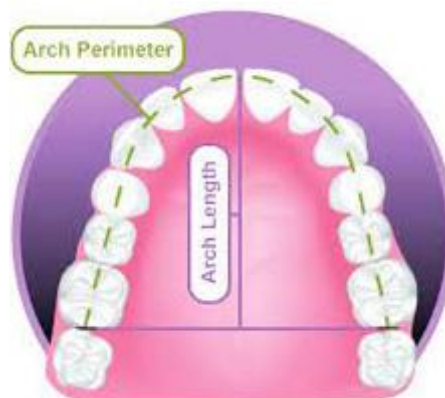### Dental arch form:

The teeth are positioned on maxilla and mandible in such a way as to produce curved arch when seen from occlusal surface. The arch form is determined by shape of underlying basal bone. General shape of palatal arch could be U-shaped, round and horse shoe shape. Discrepancies in arch between the maxillary and mandibular arches generally result in poor occlusal relationships.



### Arch perimeter (circumference):

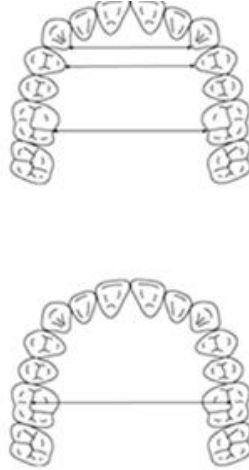
The distance of line that begins at distal surface of first molar extends mesially through all proximal contact areas around entire arch and end at distal surface of opposite first molar.





### Arch Width:

Is distance across the arch. The width of mandibular arch is slightly less than maxillary arch., thus when the arches occlude, each maxillary tooth is more facially positioned than occluding mandibular tooth.



**Because maxillary teeth are more facially positioned, normal occlusal relation is:**

- Buccal cusps of posterior mandibular teeth occlude along central fossa area of maxillary teeth.
- Lingual cusps of posterior maxillary teeth occlude along central fossa of mandibular teeth.

In orthodontics Roth presented the following functional aspects of the occlusion as being fundamental for completion of the orthodontic cases:

1. Teeth must present maximum intercuspal (MI) position with the jaw in centric relation (CR);
2. In centric relation, all posterior teeth must present axial occlusal contacts, and the anterior teeth must maintain a distance of 0.0005 inches between them;
3. During laterotrusion, the canines must disocclude the posterior teeth (canine guidance);
4. During protrusion, the upper anterior teeth must occlude with the lower anterior teeth and the first premolar or the second premolar (in extraction cases), aiming at disoccluding all posterior teeth (immediate anterior guidance);
5. No interference must be present on the balancing side.

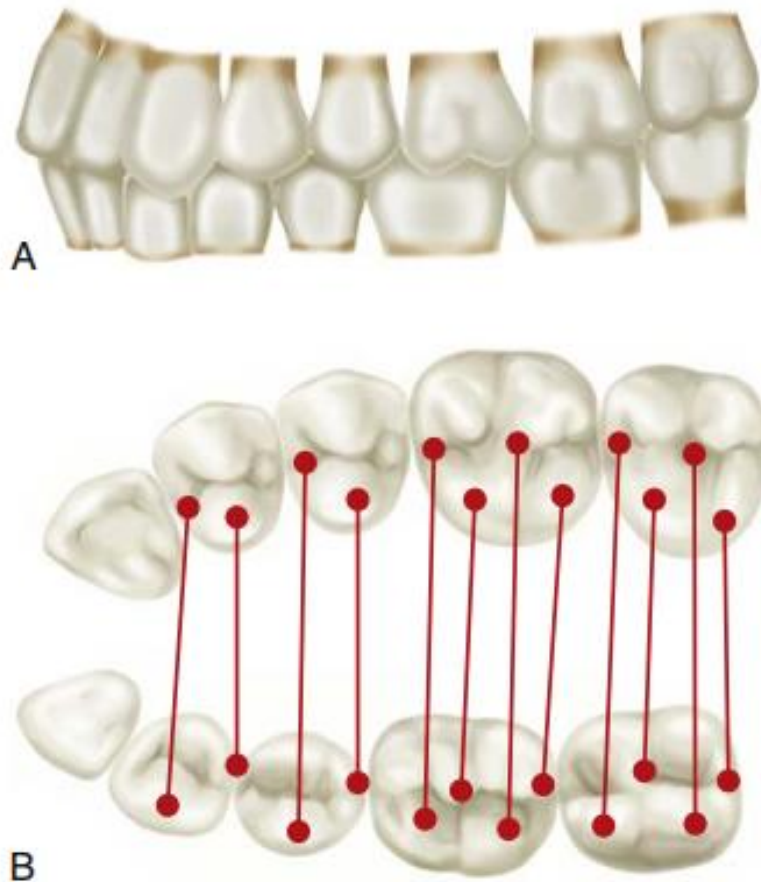
## Occlusal relationship

### Occlusal relationships of posterior teeth:

#### Class-I

- (i) Mesiobuccal cusp of mandibular first molar occludes in embrasure area between maxillary 2<sup>nd</sup> premolar and 1<sup>st</sup> molar.
- (ii) Mesiobuccal cusp of maxillary first molar is aligned directly over buccal groove of mandibular 1<sup>st</sup> molar.
- (iii) Mesiolingual cusp of maxillary first molar is situated in CF area of mandibular 1<sup>st</sup> molar.


In this relationship each mandibular tooth occludes to its counterpart and adjacent mesial tooth. Contacts between molar occur on both cusp tips and fossae and on cusp tips and marginal ridges. Two variation in occlusal contact patterns can result with respect to marginal ridge areas. In some instances cusps contacts the embrasure area directly, resulting in 2 contacts on area of cusp tips. In other instance, cusp tip is positioned so that it contacts only one marginal ridge, resulting in only one contact on cusp tip.



## **Class II**

In some patient maxillary arch is large or advanced anteriorly or mandibular arch is small or positioned posteriorly. These conditions will result in mandibular 1st molar being positioned distal to class I molar relationship. Described as Class II molar relationship.

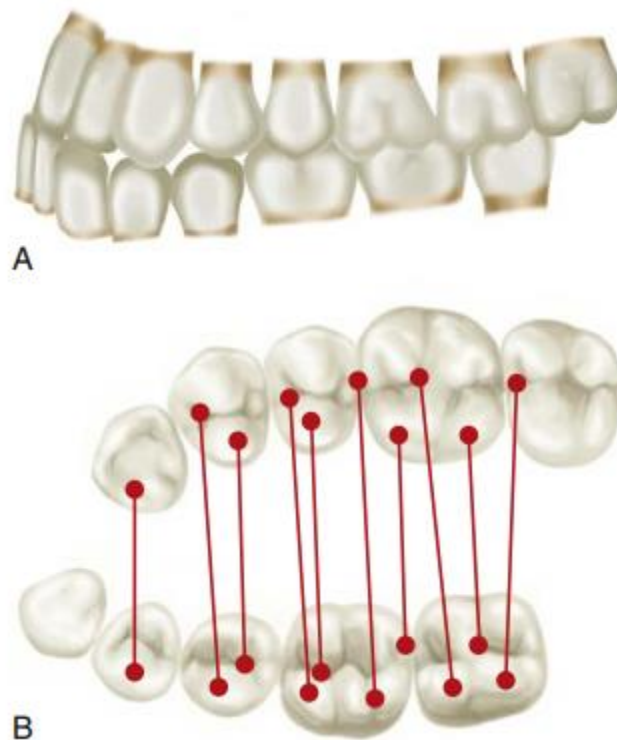
- (i) Mesio Buccal cusp of mandibular 1st molar occludes in CF area of maxillary 1st molar.
- (ii) Mesio Buccal cusp of mandibular first molar is aligned with buccal groove of maxillary 1st molar.
- (Iii) Distolingual cusp of maxillary first molar occludes in CF area of mandibular 1st molar.



### **Class-III**

Due to predominant growth of mandible. In this relationship, growth positions mandibular molar mesial to maxillary molars.

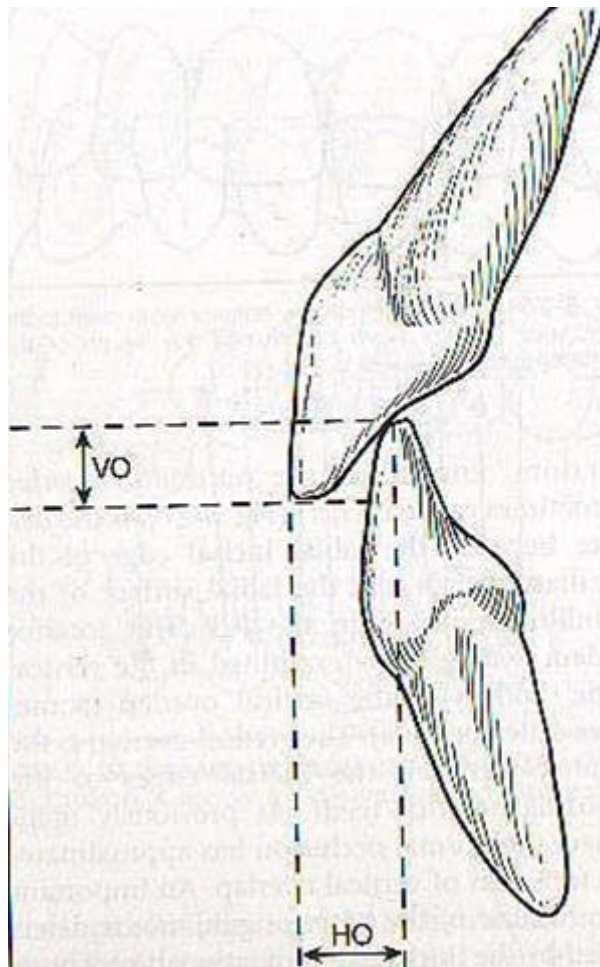
- (i) Distobuccal cusp of mandibular 1st molar is situated in embrasure between maxillary 2nd premolar and 1st molar .
- (ii) Mesiobuccal cusp of maxillary 1st molar is situated over embrasure between mandibular 1st and 2nd molar.
- (iii) Mesolingual cusp of maxillary 1st molar is situated in mesial pit of mandibular 2nd molar



### **Occlusal relationship of anterior teeth**

- Maxillary anterior teeth are normally positioned labial to mandibular anterior teeth.
- Both maxillary and mandibular anteriors are inclined to the labial, ranging 12-28° from vertical reference line.
- Incisal edges of mandibular incisors contacting lingual surfaces of maxillary incisors. These contacts commonly occur in lingual fossae of maxillary incisors approximately 4mm gingival to incisal edges.

- Purpose of anterior teeth is to guide mandible during various lateral movements. The anterior tooth contacts that provide guidance of mandible are called **Anterior Guidance**. Characteristics of anterior guidance are dictated by exact position and relationship of anterior teeth, which can be examined both horizontally and vertically.
- Horizontal distance by which maxillary anteriors overlap mandibular anteriors is called **Horizontal overlap - Overjet**. It is the distance between labial nasal edge of maxillary incisor and labial surface of mandibular incisor in ICP.
- Vertical overlap is distance between incisal edges of opposing anterior teeth which is approximately 3 - 5mm.
- Important function of anterior teeth is that of performing initial acts of mastication. Anterior teeth function to incise food when introduced in oral cavity.
- Anterior teeth also plays significant role in speech, lip support and aesthetics.



**Occlusion adjustment:**

Adjustment of occlusion can be done by-

- ✕ Selective reshaping of ridges of cusps.
- ✕ Changes can be made at angles of marginal ridge.
- ✕ Reduction of cusp height can be done.
- ✕ Reduction of sulcus by reducing angles of triangular and oblique ridges.

*While reduction do not create flat areas, always maintain rounded contours polished surface of cusps and ridges. All eccentric interferences should be removed first then only centric relation interferences should be removed.*



## **Etiology of malocclusion**

A malocclusion is the sum of a number of complex occlusal traits, which demonstrate multifactorial inheritance. Although in certain cases specific factors and pathologies can be identified as the cause of a malocclusion; in the majority, the etiology is less clear. In each individual there is a close interaction between genetics and the environment during development and growth of both the jaws and dentition.

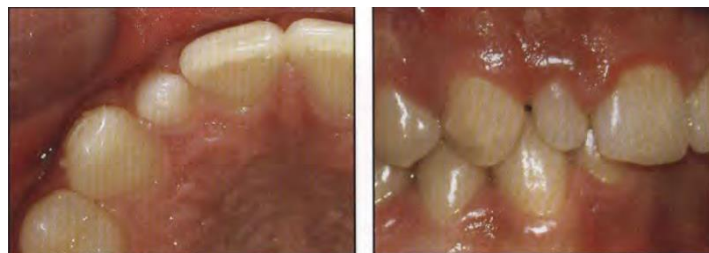### **Central factors:**

#### **1. Heredity**

Hereditary causes of malocclusion include all factors that result in a malocclusion and are inherited from the parents by the offspring. These may or may not be evident at birth, but are likely to express themselves as the child grows. These can be those influencing the:

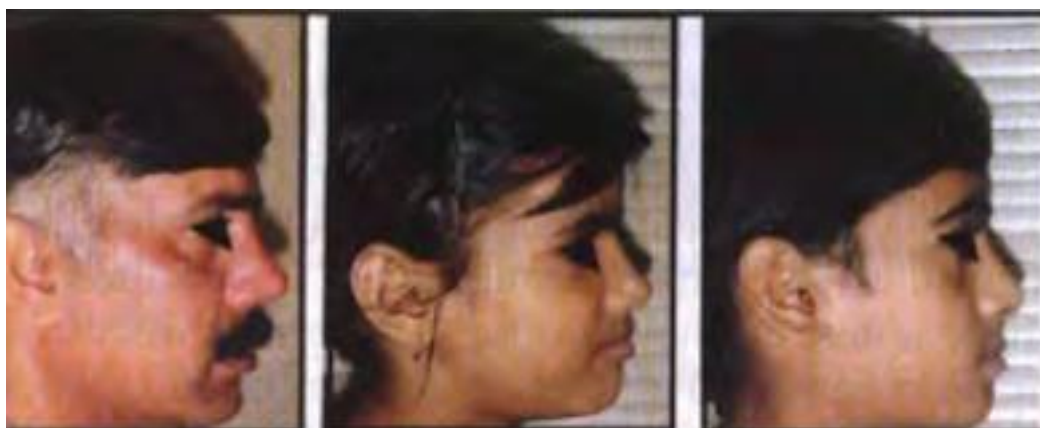- Dentition

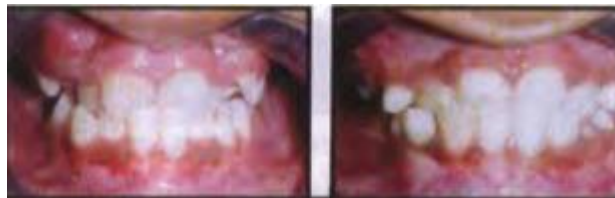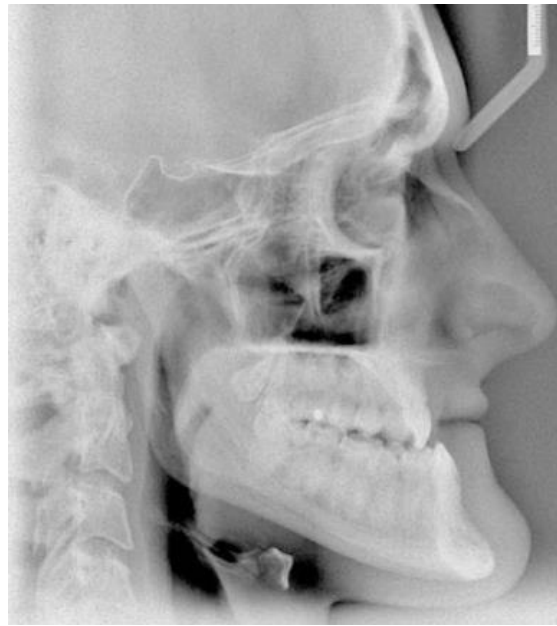1. Size and Shape of the Teeth: Peg shaped lateral are the most commonly seen and noticed abnormally shaped teeth encountered clinically



2. Number of Teeth: The most frequently missing teeth are the maxillary lateral incisors.

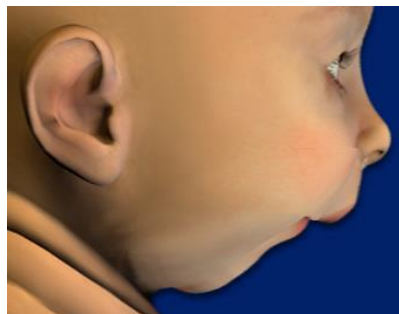- Skeletal structures: For example class III





**2. Congenital:** Congenital defects include those malformations that are seen at the time of birth (Although congenital anomalies may be the result of one or more genetic, infectious, nutritional or environmental factors, it is often difficult to identify the exact causes):

- Micrognathia: Means lower jaw that is smaller than normal.



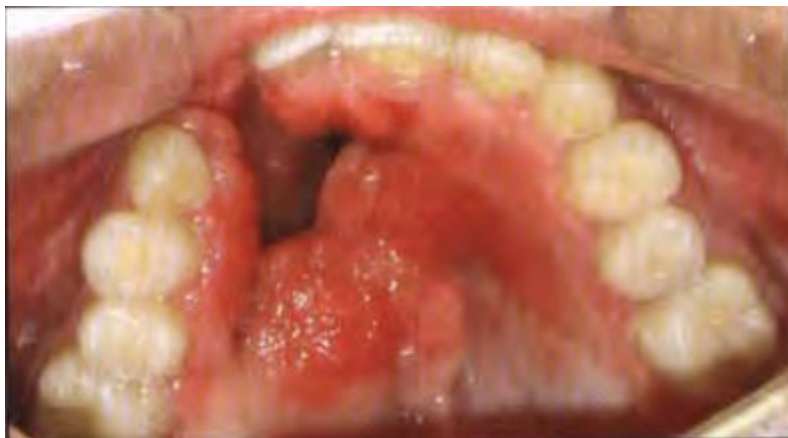- Anodontia: A genetic disorder defined as the absence of all teeth.
- Hypodontia : The majority of persons with hypodontia (80%) lack only one or two teeth , permanent second premolars and upper lateral incisors being predominantly affected.

- Oligodontia: The agenesis of more than 6 teeth.

Hypodontia	Oligodontia	Anodontia
		

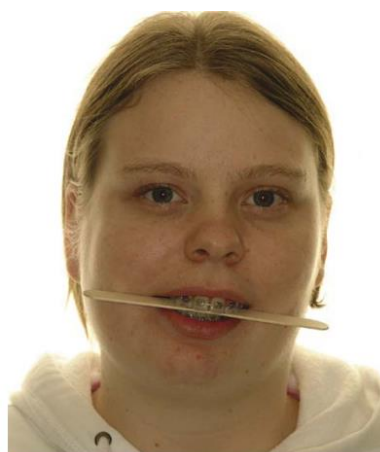
Hypodontia, oligodontia, and anodontia defined according of the number of missing teeth and genes related to these abnormalities.

- Cleft lip and palate



### 3. Environment

- Prenatal (trauma, maternal diet, German measles, etc.).
- Postnatal (birth injury, cerebral palsy, TMj injury).



#### **4. Predisposing metabolic climate and disease**

- a. Endocrine imbalance: Hypopituitarism or Hyperpituitarism
- b. Metabolic disturbances
- c. Infectious diseases: The effects of infectious diseases are dependent not only on the severity and duration of the disease but also at what age it affects the child of the mother. Such as Osteomyelitis, Tuberculosis, Mumps, Measles.

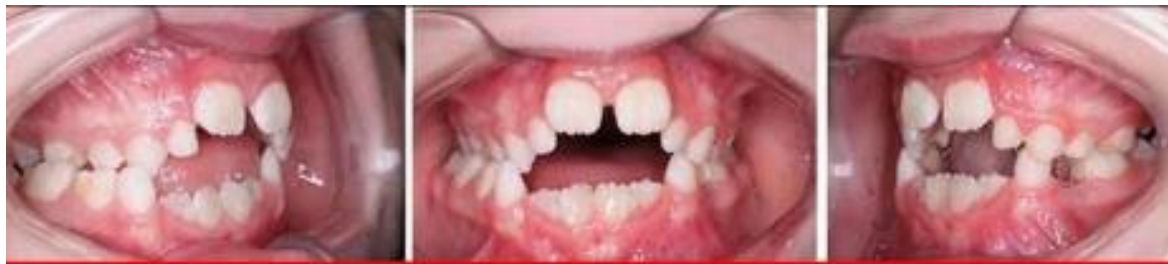#### **5. Dietary problems (nutritional deficiency)**

Nutritional imbalances in the pregnant mother have been associated with certain malformations in the child as:

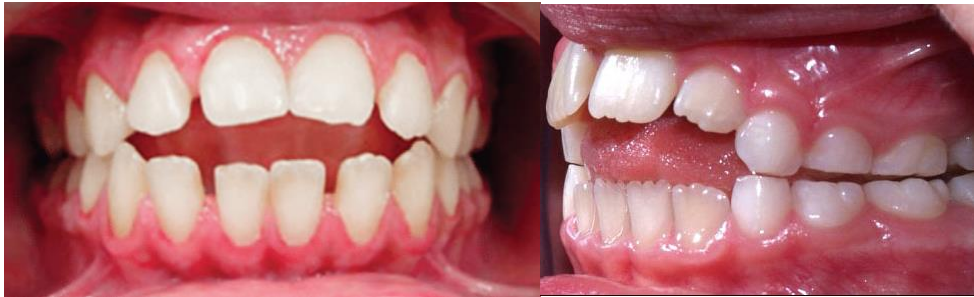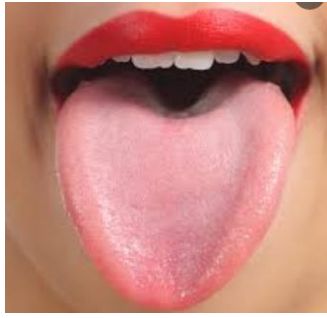- 1. Vitamins and Folic acid deficiency: Cleft lip and palate, Mental retardation.
- 2. Protein deficiency : Delayed eruption.
- 3. Vitamin C deficiency: Red, edematous tender bleeding gums, Loosening of teeth.
- 4. Vitamin D deficiency: Disturbed calcification of teeth, Poor quality of enamel, Retarded eruption, Early loss of deciduous teeth, underdeveloped mandible.
- 5. Hypervitaminosis D: Poorly calcified teeth, Decalcification of bones

#### **6. Abnormal pressure habits and functional aberrations:**

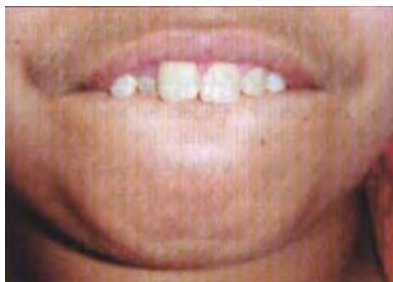- a. Abnormal sucking
- b. Thumb and finger sucking



- c. Tongue thrust and tongue sucking: Tongue thrust appears when the tongue presses forward too far in the mouth, resulting in an abnormal orthodontic condition called an open bite.



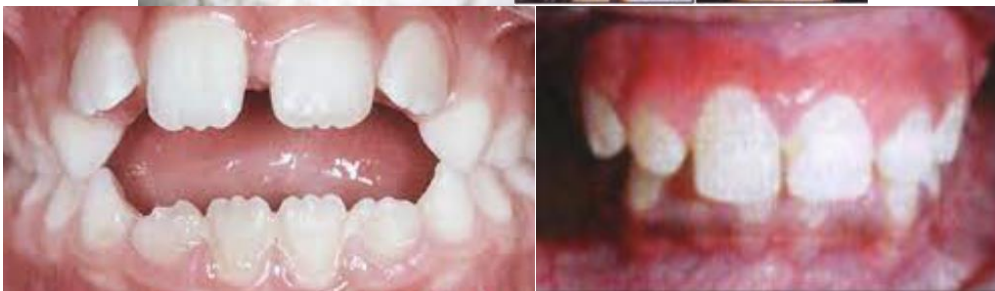
d. Lip and nail biting



e. Abnormal swallowing habits (improper deglutition)

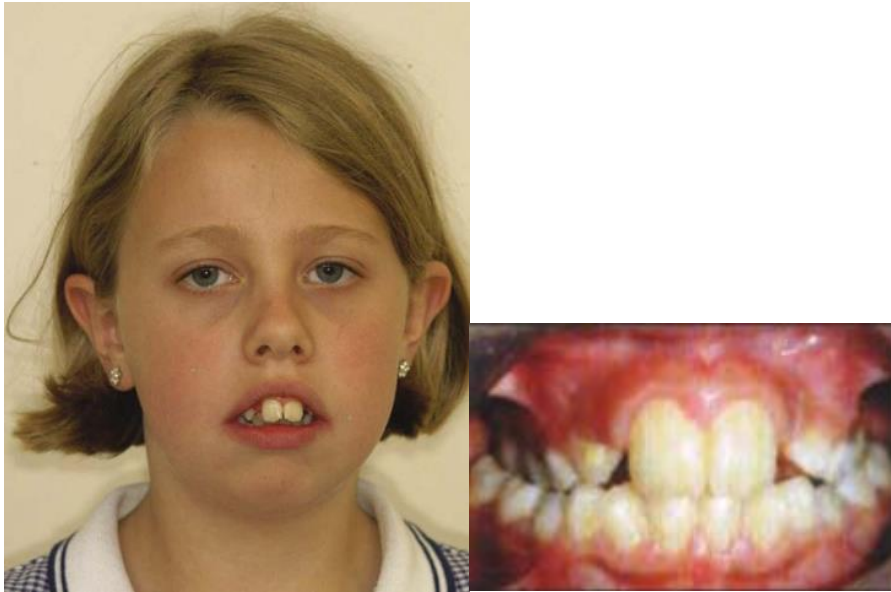f. Speech defects

g. Respiratory abnormalities (mouth breathing, etc.)

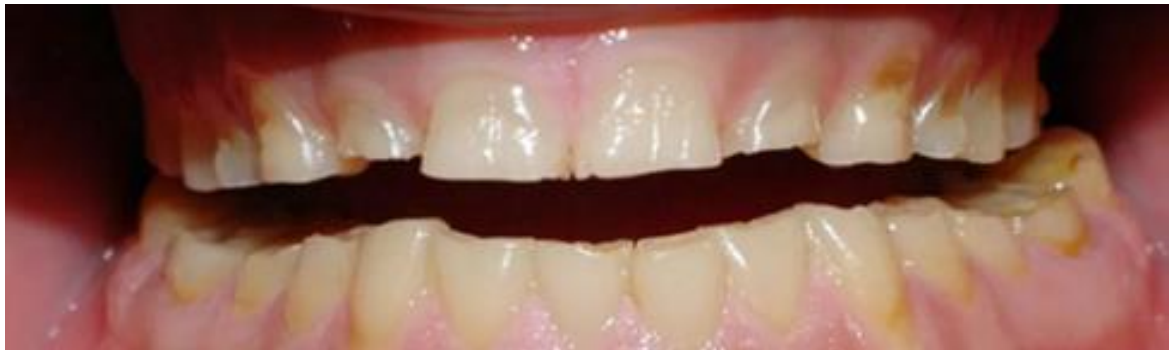



h. Tonsils and adenoids

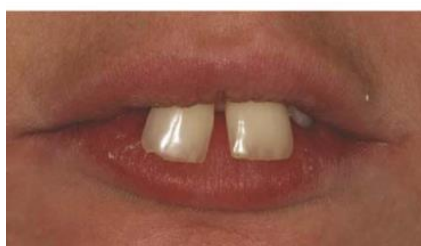
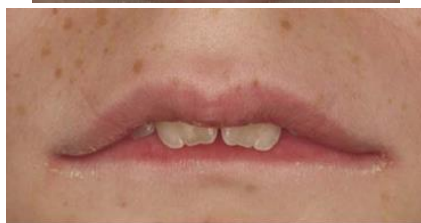
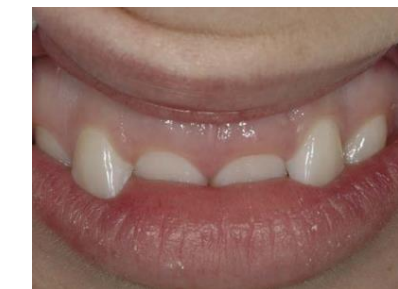I. Psychogenetics and bruxism :Is a condition in which grind, gnash or clench teeth. If bruxism when awake (awake bruxism) or clench or grind them during sleep (sleep bruxism).



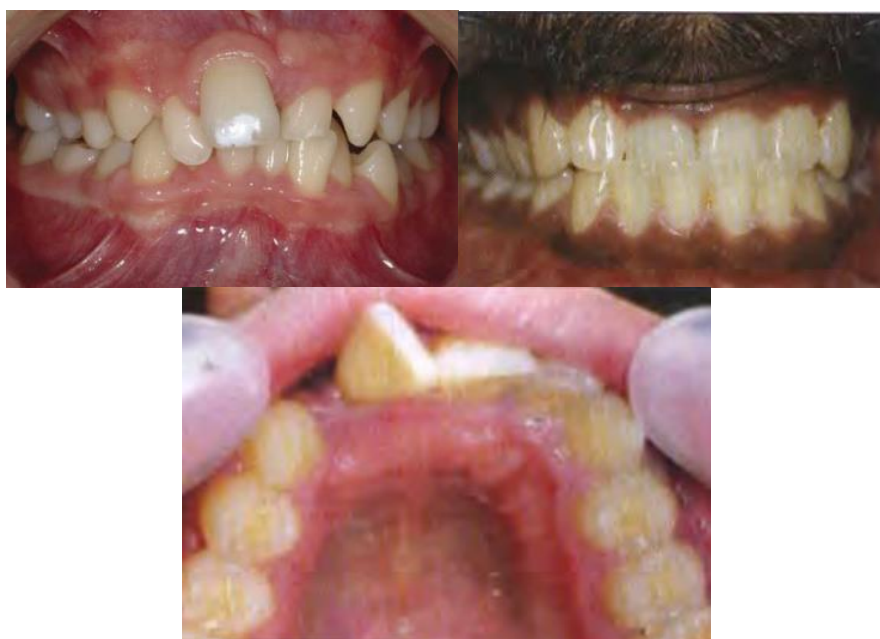**7. Posture:** Lip and tongue: Abnormal postural habits are said to cause malocclusions, Though not directly. They may be associated with other abnormal pressure or muscle imbalances increasing the risk of malocclusion.





## 8. Trauma and accidents

Trauma to the primary maxillary incisors can result in displacement of the tooth into the developing tooth bud of the permanent successor. Damage to the crown or dilaceration of the root can occur, resulting in failure of eruption and impaction of the tooth. Loss of a permanent incisor due to trauma can result in space loss and shift in the dental center line in crowded dentitions.



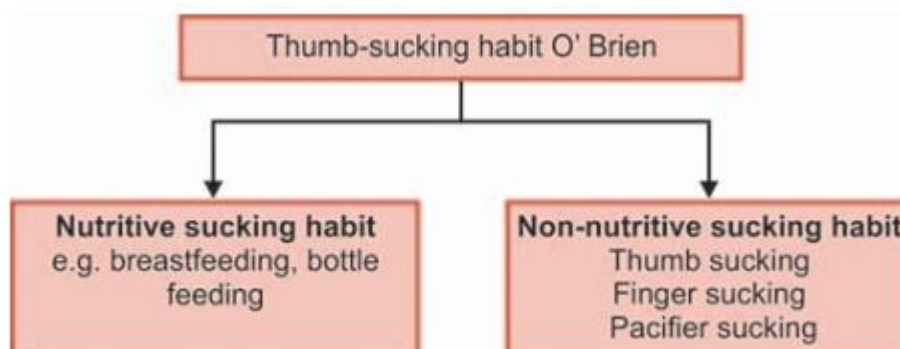
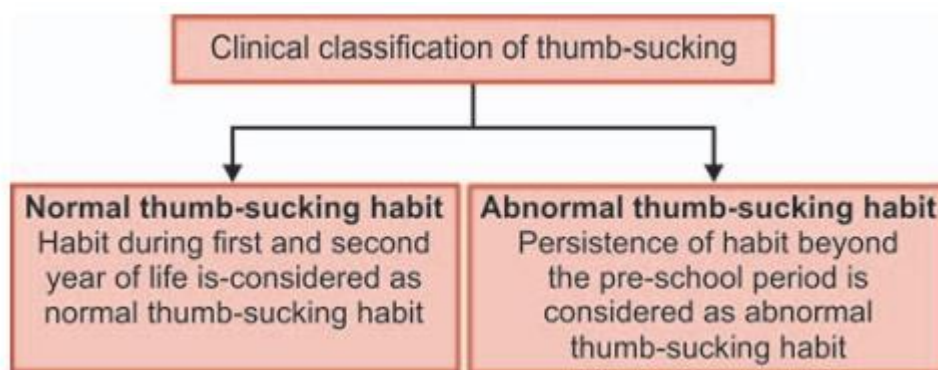
## Oral Habits

Habit can be defined as actions, which have become automatic or characteristic by repetition. Another definition: Habit is an act which gets fixed to an individual due to constant repetition.

The various deleterious oral habits are (i) thumb sucking and finger sucking, (ii) tongue thrusting, (iii) mouth breathing, (iv) lip sucking and lip biting, (v) nail biting, (vi) postural habits, (vii) bruxism, (viii) masochistic habits.

### Thumb or finger sucking:

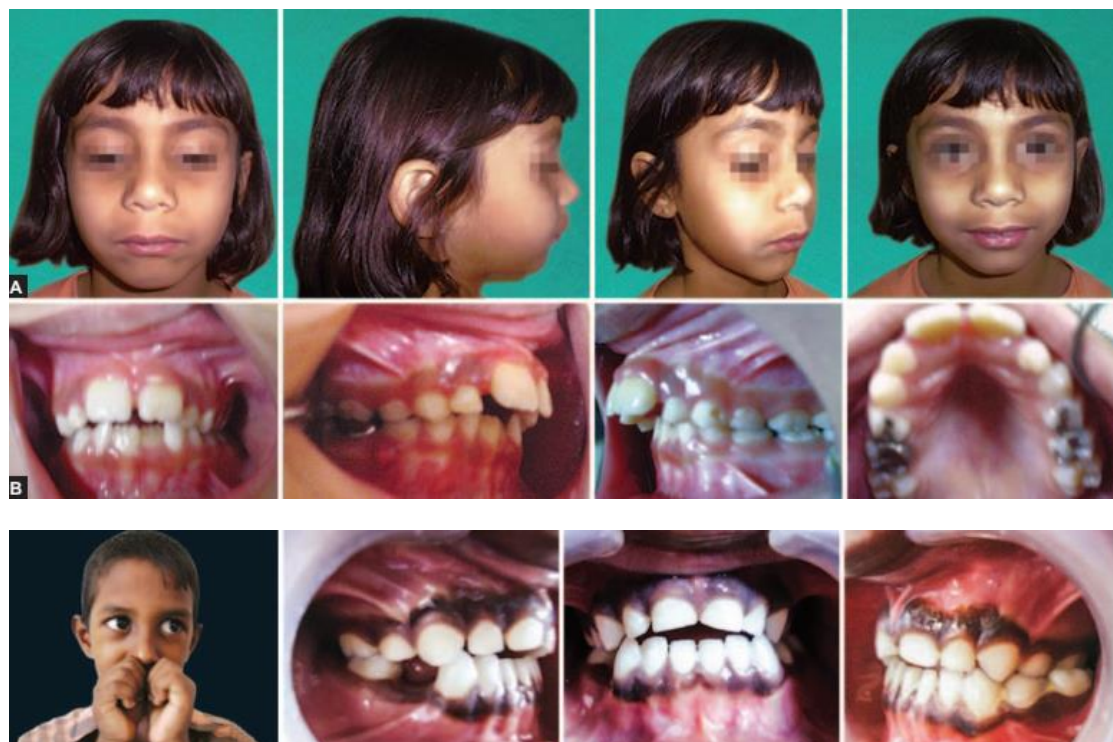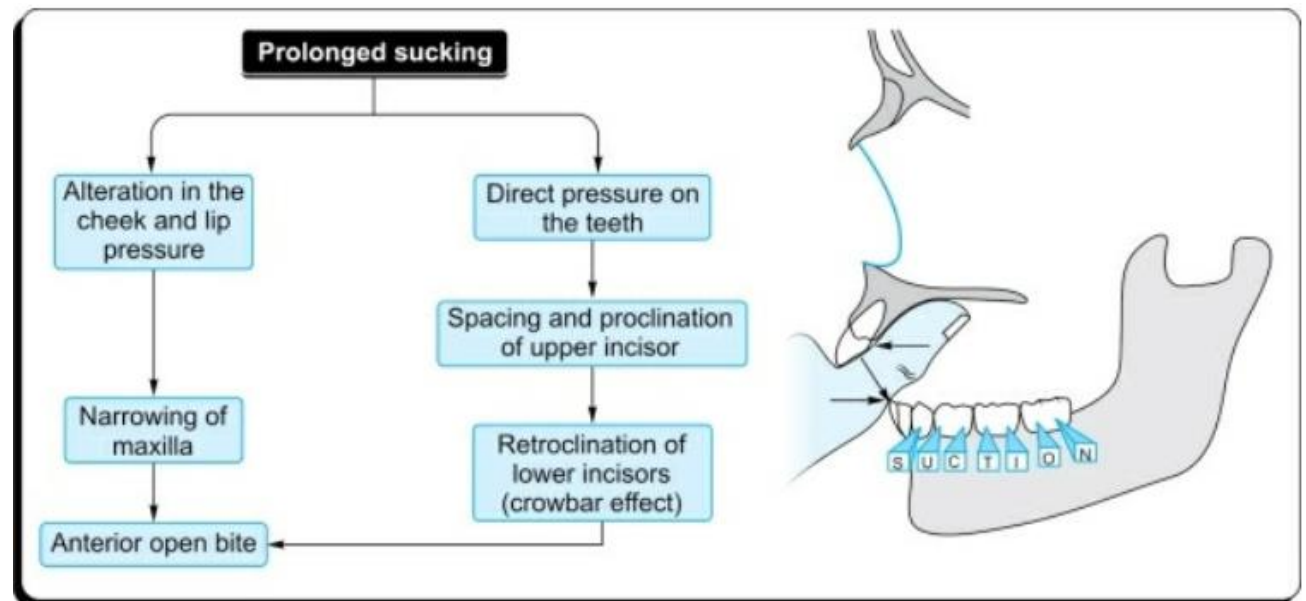
Thumb/finger sucking collectively called as digit sucking, is one of the most commonly observed oral habits among children. Although presence of such a habit in first two years of life is considered as a part of normal development of the child, its persistence beyond preschool years would have profound deleterious effects on the developing dentofacial structures and occlusion and thus can lead to malocclusion. The facial bones are not densely calcified in early childhood, so the sucking pressure between the maxillary and mandibular teeth creates an abnormal developmental force, which results in malocclusion.

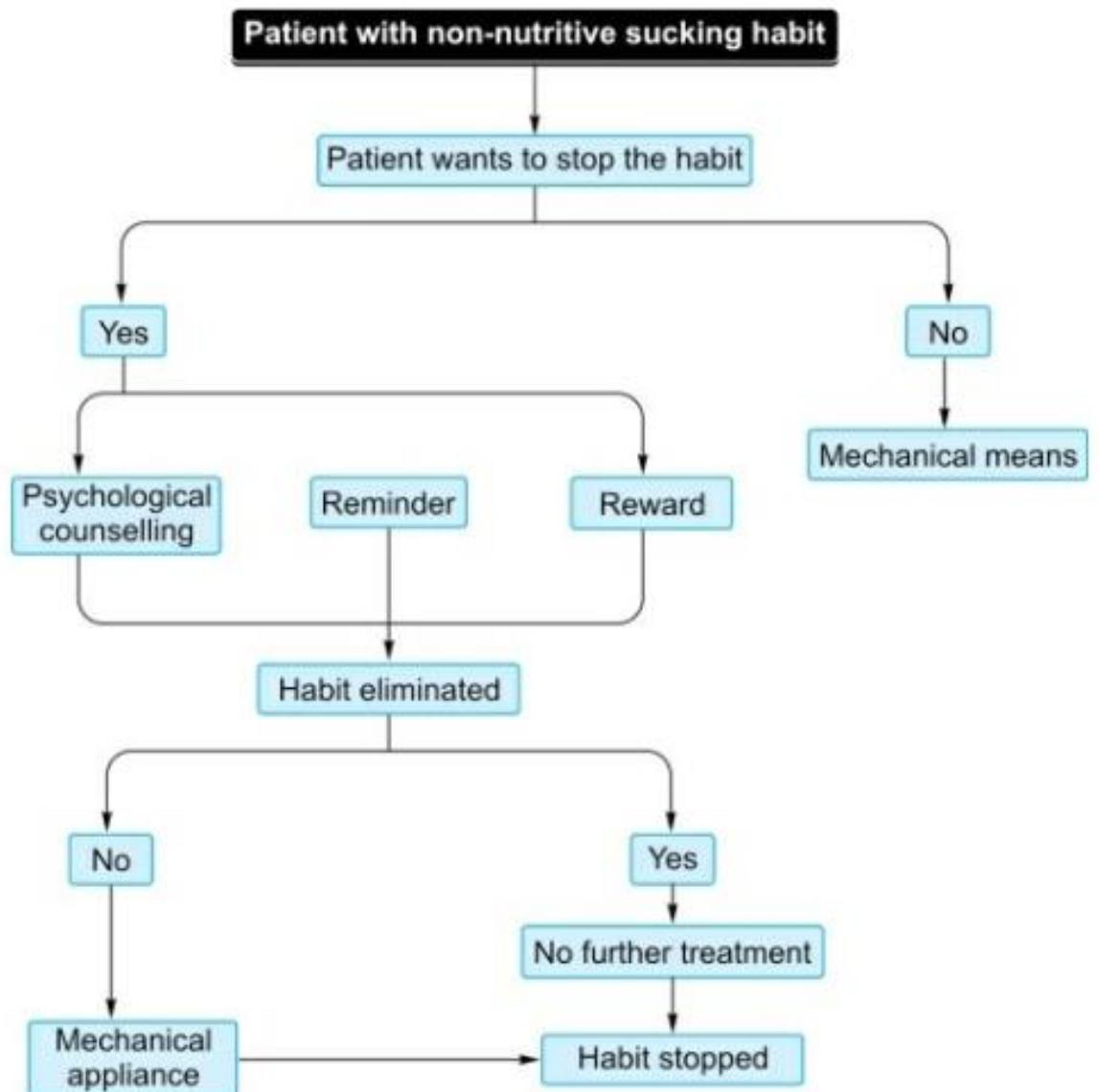
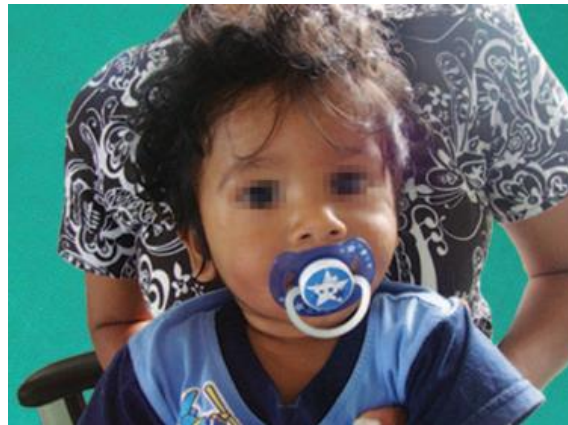

Two important types of digit sucking, nutritive and non-nutritive sucking.

1. Nutritive sucking – appears during the very first weeks of life and is due to feeding problems.
2. Non-nutritive digit sucking – due to various psychological reasons. Sucking could be related to hunger, satisfying the sucking instinct, due to feeling of insecurity, desire to attract attention.

**Clinical features and effects:**







## Removable Habit-Breaking Appliances:

Removable habit-retraining appliance consists of a palatal wire assembly embedded in the removable acrylic appliance. The appliance is retained by clasps on maxillary deciduous 2nd molars or 1st permanent molars.

1. Cribs
2. Rakes/spurs
3. Lingual arch with palatal crib
4. Lingual arch with rakes/spurs
5. Quad helix

### How Does Habit-breaking Appliance Work?

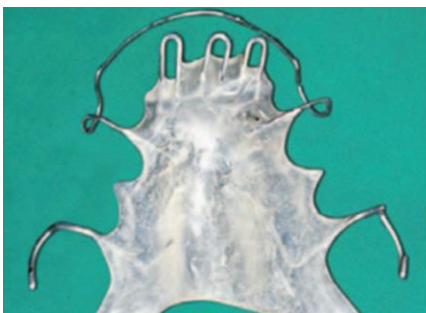*Cribs:* Incorporated in removable or fixed appliances, the palatal crib acts as follows: Renders the habit meaningless by breaking the suction. Makes the habit non-pleasurable as thumb cannot touch the palate. Breaks the thumb and tongue pressure applying on maxillary incisors. Appliance forces the tongue backward, distributes the pressure to posterior teeth as well. Acts as reminder not to indulge in the habit.

*Rakes/spurs:* The blunt spurs projecting into palatal vault discourage not only thumb sucking but also tongue thrusting and improper swallowing habits as well.

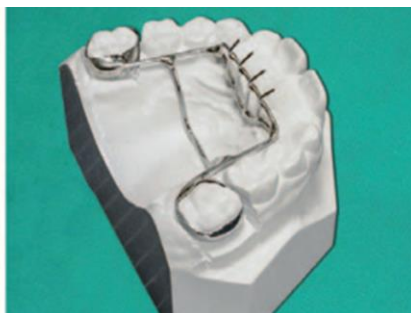*Quad helix:* It includes the following: It is the ideal appliance for correction of posterior crossbite caused due to digit-sucking habit. Activation of Quad helix causes expansion of the dental arch. Its anterior portion with two helixes placed near the anterior palatal region acts as a reminder.

*Corrective mechanotherapy:* After cessation of the habit any residual malocclusion present well after eruption of permanent incisors is treated by removable orthodontic appliances or fixed mechanotherapy. It is also true for patients with continuation of the habit into adolescence and adulthood.

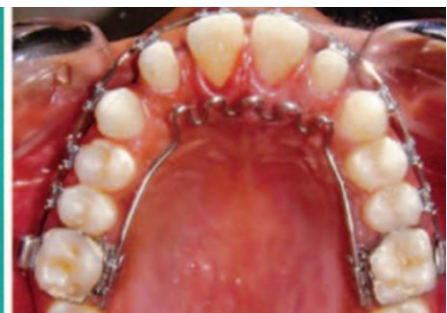Removable crib



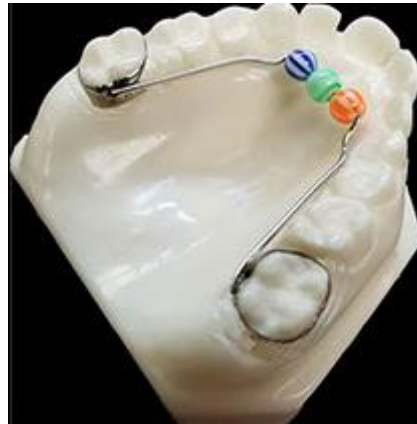fixed rake



removable palatal arch



**appliance and rake appliance.** The bluegrass appliance uses a spinning roller to help break the patient's habit and allow the anterior teeth to return to their normal position.



Patients turn the beads which replaces the desire to suck the thumb. Appliance may be made with beads or a silicon roller.

Multiple appliance:

The palatal crib (Figure 1(b)) and the U-loop are made of 0.9 mm stainless steel wire. Three to four spurs are bent on either sides of the bead, starting from the canine region on one side, running anteriorly as a smooth curve (in conventional crib appliances, the cribs run obliquely from one canine to the other side canine) and lying 1 mm lingual to the cervical margin of the maxillary anterior teeth. In the region of the incisive papilla, the acrylic bead is incorporated in such a way that it lies over the posterior one-third of the incisive papilla. The tip of the crib should be almost in line with the incisor tip of the maxillary central incisor or 2 mm longer without interfering with the lower incisors when in occlusion. In cases with anterior open bite, the crib should be longer and can be up to 3/4th of the interincisal distance between the upper and lower central incisors. This is to avoid the tongue from thrusting over the tip of the crib. The palatal crib acts as a barrier against the thrusting tongue and works as a mechanical restrainer. The U-loop (Figure 1(c)) is incorporated in the second premolar region and it helps to reposition the appliance posteriorly during the retraction phase, when it is used along with fixed orthodontic appliances. The appliance can be engaged into a lingual sheath (Figure 2(a)) on the molar bands or can be soldered directly to the molar band (Figure 2(b)). If it is engaged in a lingual sheath, a tight ligature tie should be wound around the lingual sheath and the distal end of the appliance to avoid the appliance from slipping out of the sheath into the oral cavity.



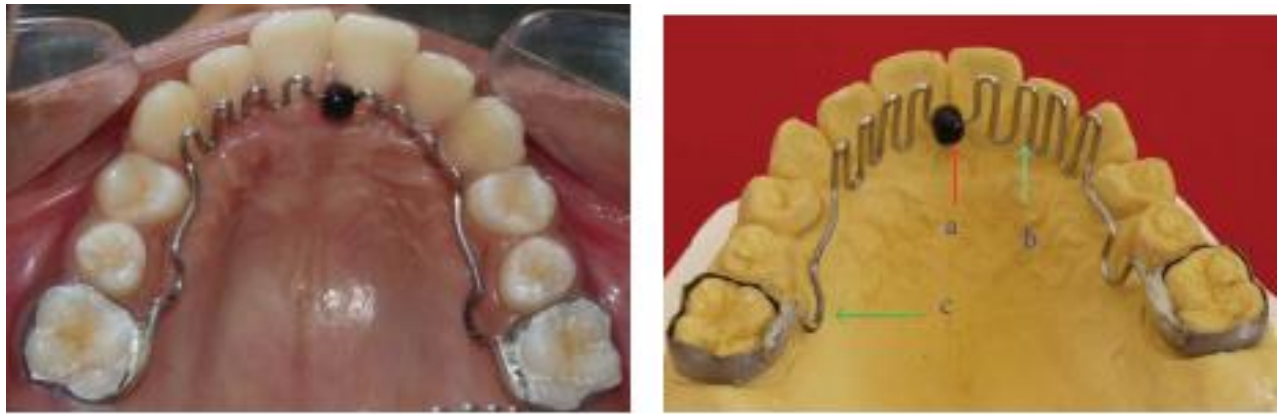

Figure 1

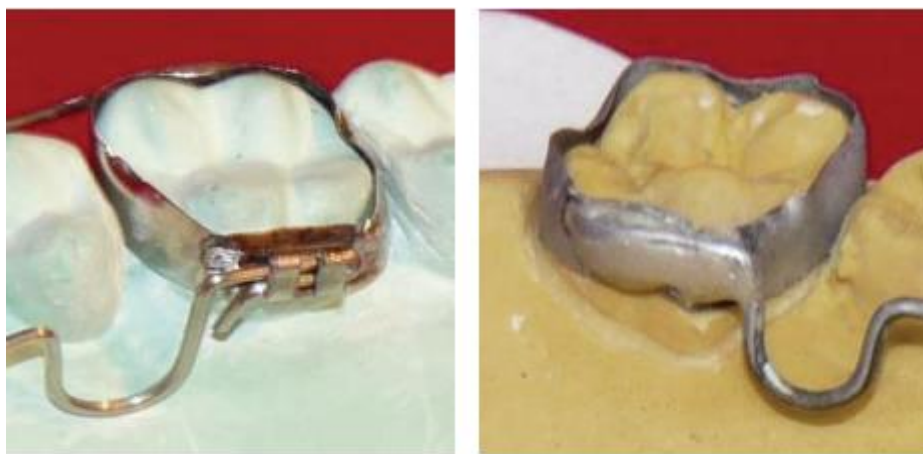
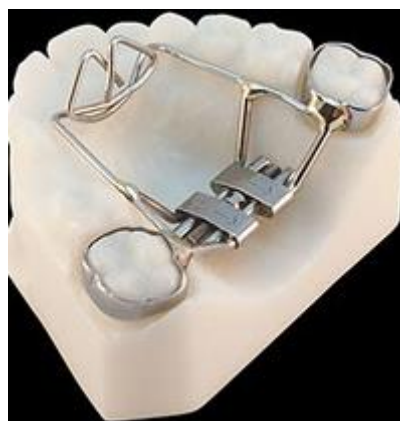

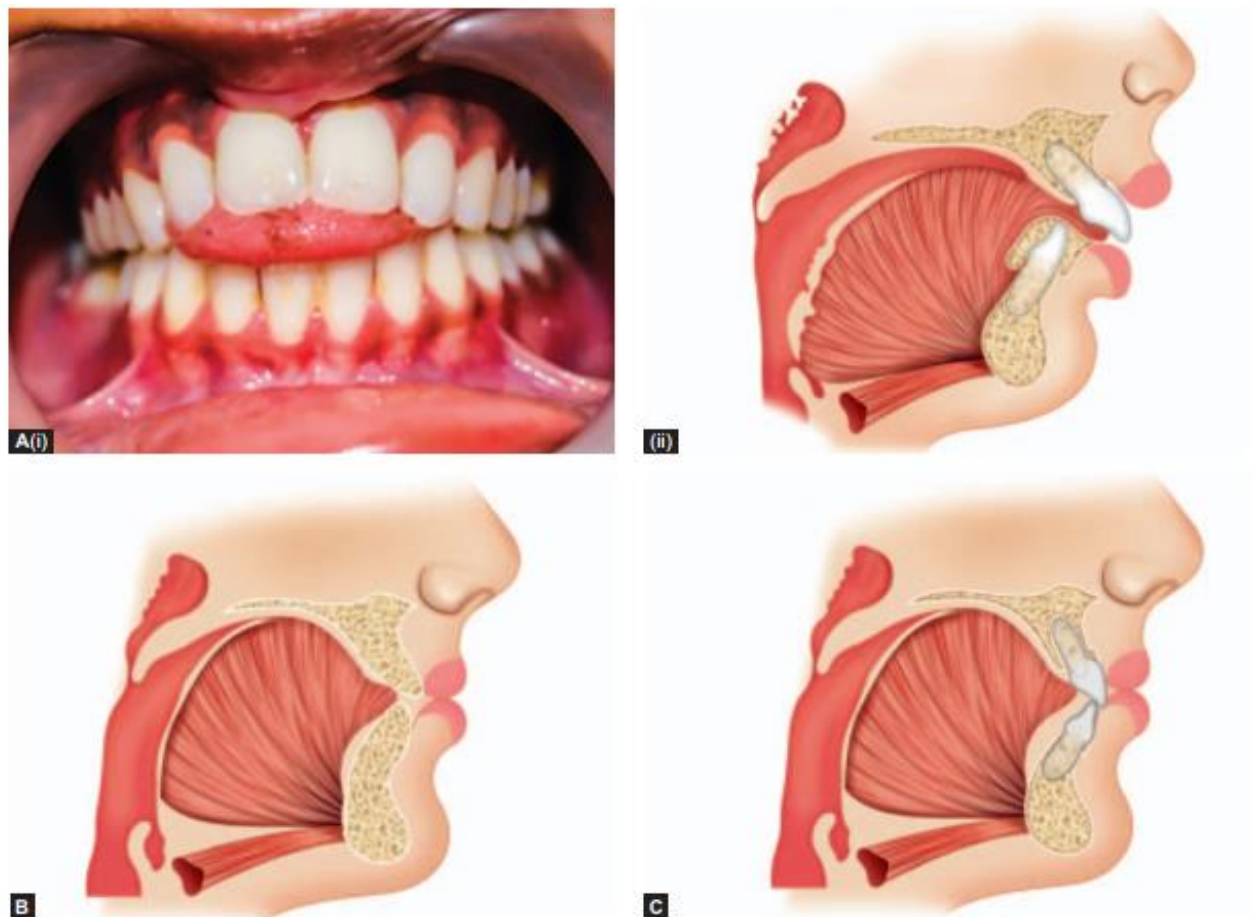
Figure 2

This is ideal for patients exhibiting an anterior open bite, thumb finger habit and needing controlled moderate to significant palatal expansion.



## Tongue-thrusting habit

It is an abnormal tongue activity in which the tongue is thrust between the upper and lower teeth during swallowing. It often causes proclination of anteriors and an anterior open bite. Tongue thrusting may be present in association with digit-sucking habit and should be considered in the diagnosis.



**Fig. A to C:** A(i) and (ii) Tongue thrusting habit has resulted anterior open bite. (B) In infantile swallow: Tongue is placed between the gum pads and the tip of the tongue is in contact with lower lip (C) Mature swallow: Tip of the tongue is placed against anterior palate behind upper incisors; posterior teeth are in occlusion during swallowing; mandible is stabilized by contraction of muscles of mastication; downward and forward growth of mandible and vertical growth of alveolar bone increases intra-oral volume and assists in normal posture

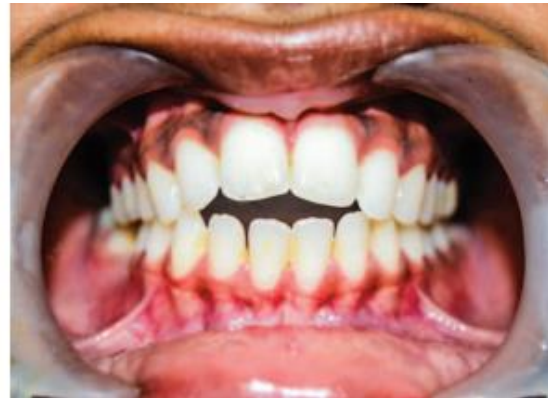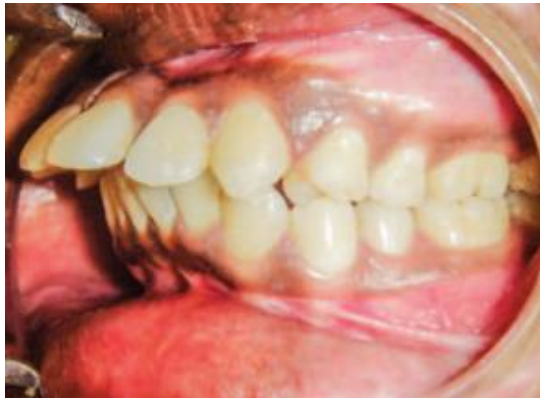## Effects of Tongue Thrusting

Depending on the duration, frequency and intensity of tongue-thrusting habit, some/all of the following features can be seen.

It includes the following:

1. Retroclination of mandibular anteriors.
2. Proclination of mandibular anteriors.
3. Increased overjet
4. Anterior open bite

5. Posterior open bite—In case of lateral tongue thrust. It may be unilateral or bilateral
6. Effect on speech: Hampered speech.



### **Treatment**

The treatment of tongue thrust can be divided into various steps:

**1. Training of correct swallow and posture of the tongue.**

**2. Orthodontic Trainers:**



A. Tooth Guidance

Molded into the anterior section (similar to orthodontic arch wire).

1. Tooth channels
2. Labial bows.

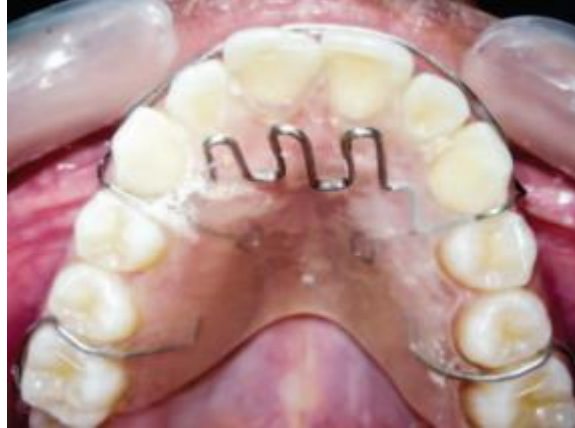B. Myofunctional Training

1. Tongue tag: For the proprioceptive positioning of the tongue tip as in myofunctional and speech therapies.
2. Tongue guard: Stops tongue thrusting when in place and forces child to breathe through the nose.
3. Lip bumpers: Discourage overactive mentalis muscle activity.

C. Jaw Positioning

### 3. Appliance Therapy

Using Removable Appliance: Various removable orthodontic appliances are used to break tongue-thrusting habit along with the correction of resultant malocclusion.

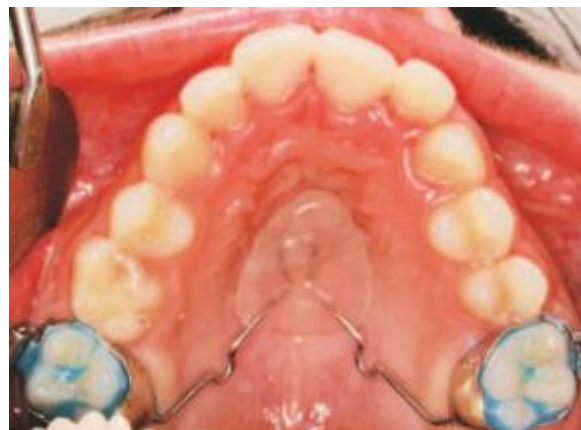

1. Habit-breaking appliance with tongue crib: This appliance is used to treat tongue-thrust habit.

Parts: Tongue crib is comprised of the following parts:

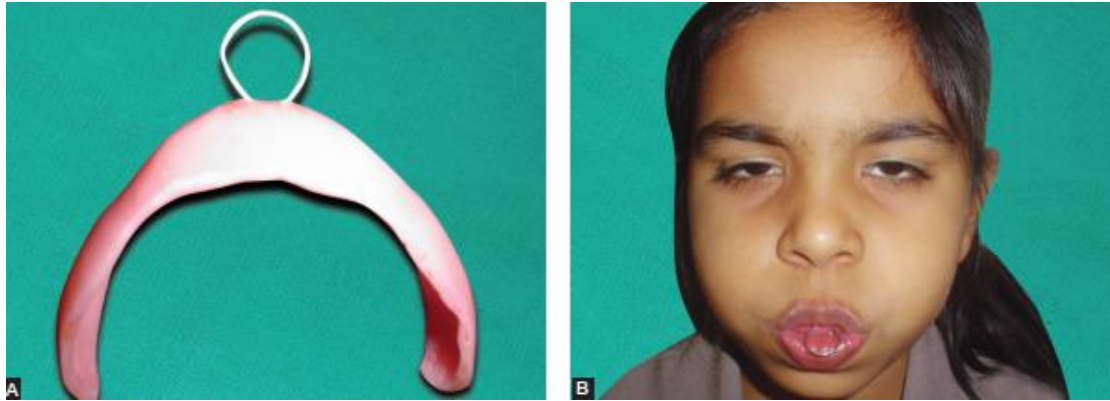
1. Active component—bow
2. As a remainder—tongue crib
3. Retentive components
  - A. Clasps—C clasp or Adam's clasp on maxillary 1st molars
  - B. Plate—acrylic base plate.

2. Nance palatal arch appliance: In this appliance, acrylic button can be used as a guide to place the tongue in the correct position.





3. Oral screen: Another effective means of controlling abnormal muscle habits like tongue thrusting and at the same time utilizing the musculature to effect a correction of the developing malocclusion is vestibular/oral screen.



4. Using Fixed Orthodontic Appliances: Fixed orthodontic appliance with fixed rake or crib can be used to correct tongue thrust habit.

#### **4. Surgery**

Skeletal malocclusion: The treatment of the retained infantile swallow behavior beyond adulthood is difficult and often consists of orthognathic surgical procedure to correct the skeletal malocclusion. Tongue thrusting due to excessive lymphoid tissue: Surgical reduction of lymphoid tissue will eliminate tongue thrusting.

## **Space maintainer**

Definition; Space maintainer is a fixed or removable appliance designed to preserve the space created by premature loss of a tooth or a group of teeth.

Why we use space maintainer?: Whenever primary teeth are lost prematurely, the arch integrity is disturbed due to loss of space and decrease in arch length. Migration of adjacent primary and/or permanent teeth can occur and the available space may be reduced by an amount sufficient to cause some degree of crowding in the permanent dentition.

### **Classification of space maintainers**

Removable Appliances

Fixed Appliances

### **Indications**

The premature loss of primary molars may require the placement of a space maintainer to prevent the migration of the adjacent teeth.

When loss of a primary canine occur, the dental arch midline may be compromised and the arch length also may be reduced. ,,

The premature loss of primary incisors does not usually require the placement of a dental appliance for the maintenance of space because the mesial movement of the adjacent teeth is not generally expected.

### **Requirements of Space Maintainer**

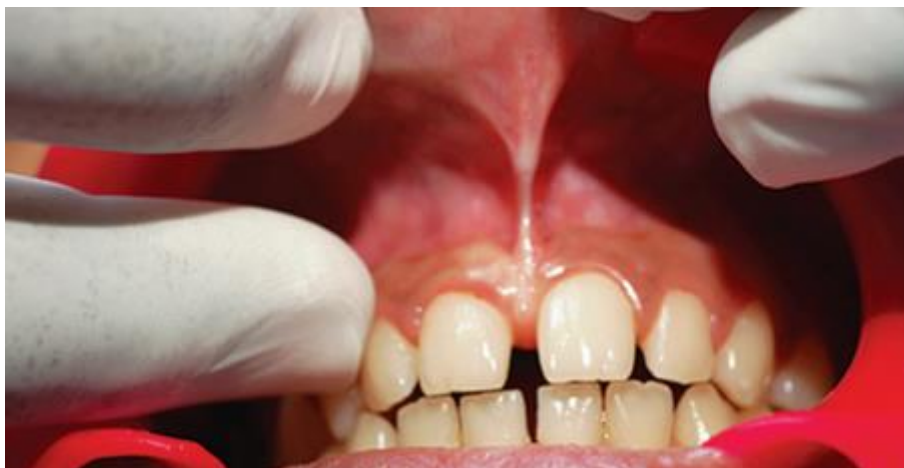1. Space maintainers should maintain the mesiodistal dimensions of the lost teeth.  
,,
2. They must not compromise the remaining teeth by imposing excessive stresses on them.
3. They must be easily cleaned and not serve as trays for debris, which might enhance dental caries and soft tissue pathologies.
4. Their construction must be such that they do not restrict normal growth and development process or interfere with functions, such as mastication, speech or deglutition.



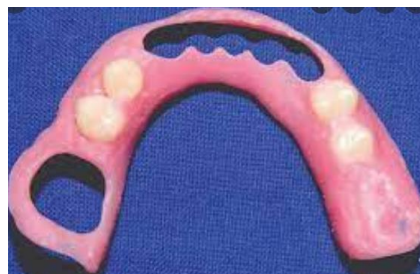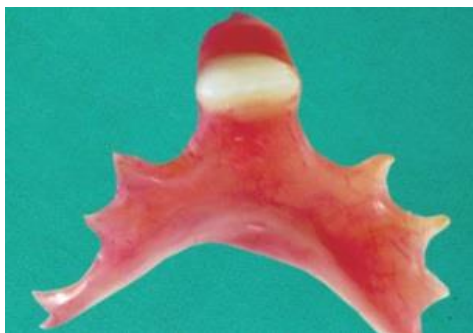5. Depending on the tooth lost, the segment involved, the type of occlusion, possible speech involvements and cooperation, particular type of space maintainer may be indicated.

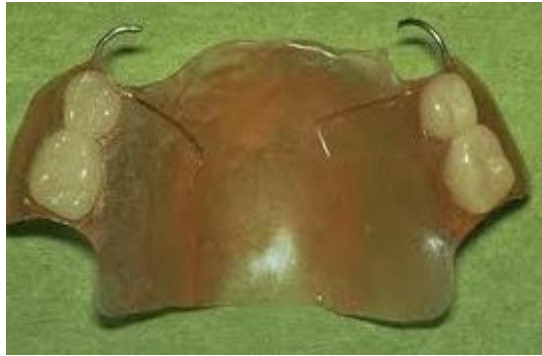#### **A. Removable space maintainers/Functional space maintainers/Removable acrylic space maintainers**

Functional space maintainer is a removable type of space maintainer and is the choice of space maintainer, when there is multiple premature loss of deciduous teeth. This type of space maintainer is fabricated with acrylic material. It not only helps in esthetic but also helps in the regaining of lost masticatory functions. This type of space maintainer consists of acrylic plate, acrylic teeth and clasps on molars. The incisors of acrylic teeth help in regaining lost masticatory functions and esthetics. Clasps may be a simple “c” clasps on molars which aid in retention.



Thick, fibrous maxillary labial frenum attachment, causing midline diastema,





Removable space maintainers/functional space maintainers/removable acrylic space maintainers

### **Indications**

When multiple teeth are lost and the space maintenance and the mastication are of concern.

### **Advantages**

Can maintain space, as well as aid in mastication.

### **Disadvantage**

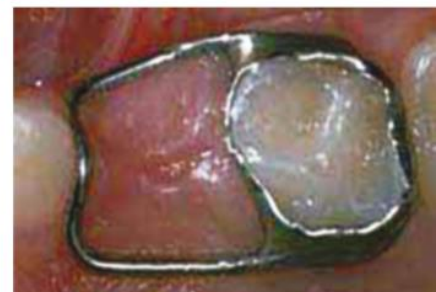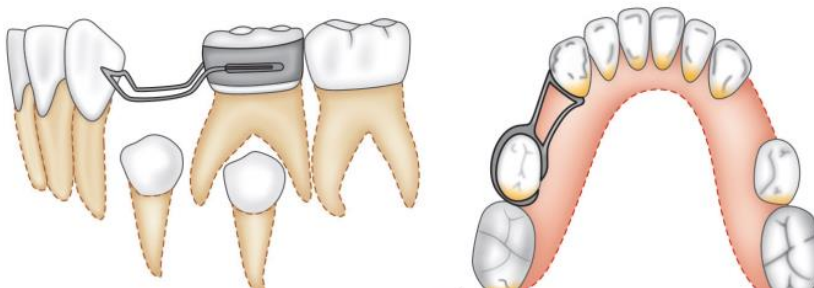
Susceptible to fracture or loss.

## **B. Fixed Space Maintainers**

Fixed space maintainers are the appliances, which are fixed onto the teeth and utilize bands or crowns for their fabrication.

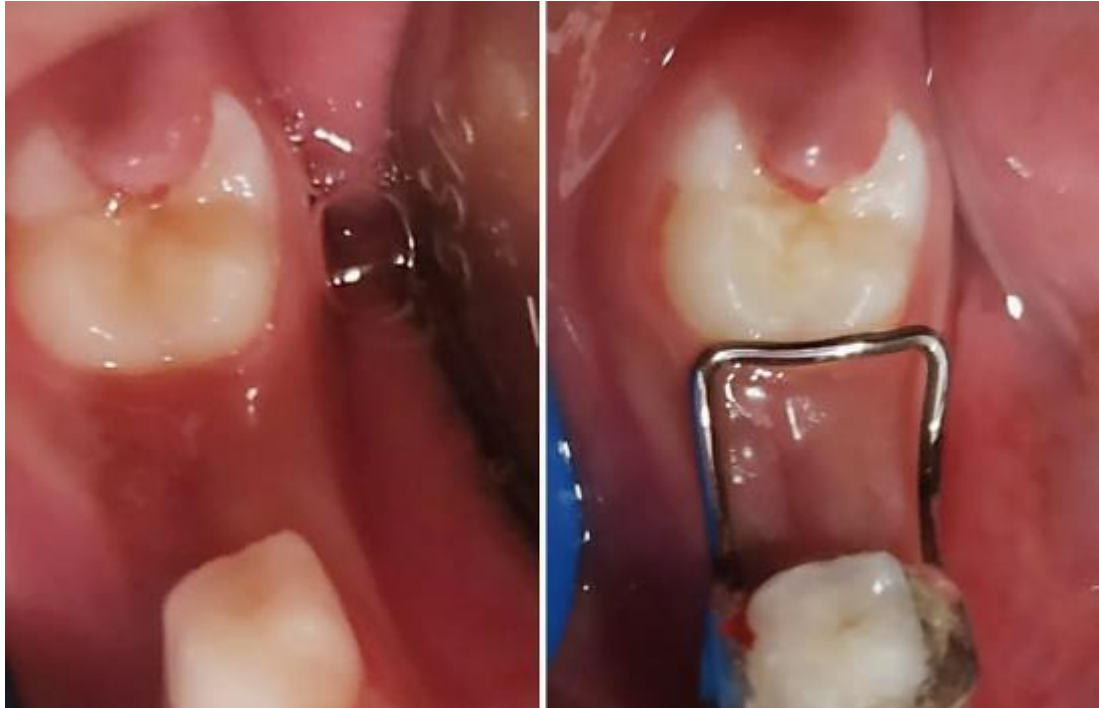### **1. Band and Loop Space Maintainer**

Band and loop space maintainer is a fixed space maintainer and is one of the most commonly used space maintainers in the dental practice. It can be constructed on one side of the arch or on the both



## **2. Reverse Band and Loop Space Maintainer**

This type of space maintainer is given when there is premature loss of primary second molar and the permanent molars have not erupted fully to support a band. In such cases, deciduous first molar is banded and loop is made that touches just below the marginal ridges of permanent molars.



### **Advantages of band and loop space maintainers or band and loop space maintainers**

1. Is economical
2. Requires less chair time
3. Allows transverse growth of the jaws.

### **Disadvantages band and loop space maintainers or band and loop space maintainers**

1. Is nonfunctional-therefore does not restore mastication.
2. Does not prevent supraeruption of opposing permanent tooth.
3. May lead to slight mesial tipping if the loop slips below the contact area. Therefore, the loop fabrication and adaptation has to be precise.

### **Modifications of band and loop space maintainer**

1. Crown and loop space maintainers-post-pulp therapies and or if the tooth is having extensive caries.
2. Band pinched on a stainless steel crown on to which the loop is fabricated.
3. Band and loop space maintainer with occlusal stop to prevent supraeruption of opposing permanent teeth. But, this may not allow the premolar to erupt fully, which would erupt between the loops at a later date. Therefore, requires a constant recall and review regimen.
4. Extended band and loop space maintainer with a reinforcement.
5. Bonded band and loop- though requires the least chair time as it uses the advantages of adhesive dentistry. But it also has a higher failure rate clinically.

*In case of bilateral loss:* Permanent first molars are the first choice as abutments followed by deciduous second molars. If placed on the deciduous second molars, the space maintainers may be lost due to exfoliation even before they need to be discarded.

### **3. Mayne's Space Maintainer**

Mayne's space maintainer is a type of band and loop space maintainer where the loop is halved.

#### **Indication**

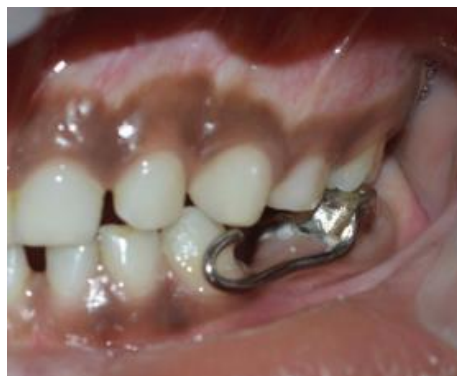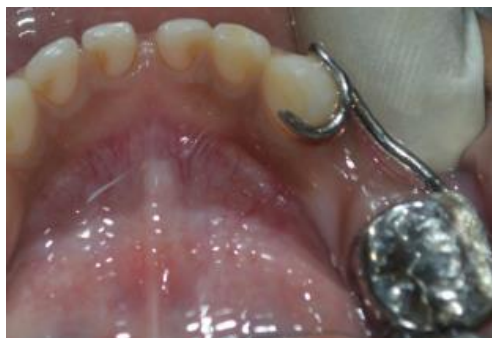Loss of first primary molar.

#### **Advantage**

Ease of fabrication for the clinician and ease of maintenance for the patient.

#### **Disadvantages**

„ Opposing tooth may supra-erupt. This type of space maintainer cannot be used for the multiple loss of deciduous teeth.

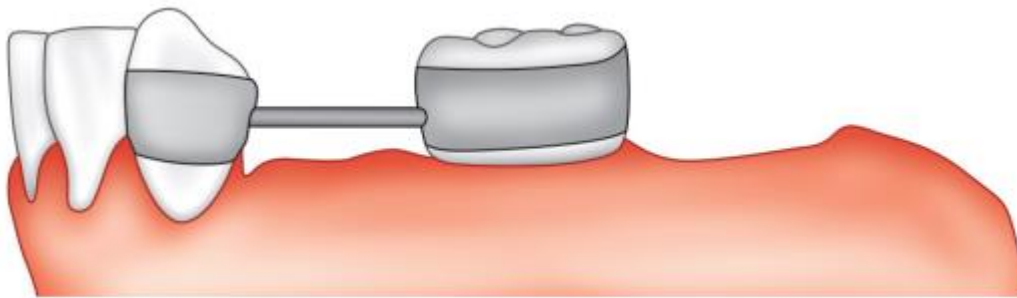


The loop was fabricated on the cast with 19-gauge stainless steel wire. The loop encircled from the center of the lingual surface of the tooth just above the cingulum along the distal surface of the tooth extending buccally, covering the distal one-third of the buccal surface. The loop then extends distally and is soldered to the buccal surface of the crown.

#### **4. Band and Bar Space Maintainer**

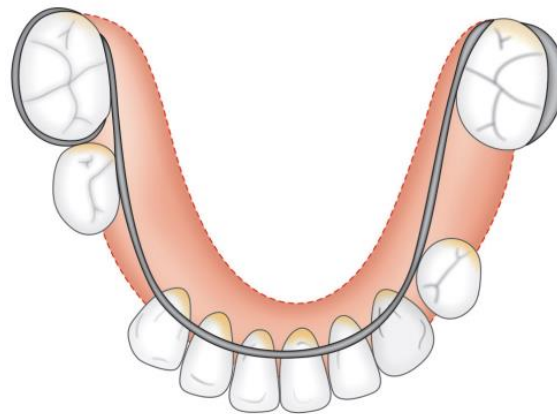
Band and bar space maintainer is a fixed type of space maintainer in which the abutment teeth on either side of the extraction space are banded and connected to each other by a bar. Band and bar space maintainer is a fixed type of space maintainer, in which tooth mesial and distal to the extraction space are banded either using direct or indirect banding procedure and connected to each other by a bar.

A bar is a thick stainless steel wire, its ends is soldered to the mesial surface of banded distal tooth at the contact point level and it's another end is soldered to the distal surface of the banded tooth at the contact point level, which is mesial to the extraction site. In some cases, band and bar space maintainer may consist of only one banded tooth and a bar soldered to it.



## Lower Lingual Holding Arch (LLHA) Space Maintainer

This type of space maintainer is used only in mandibular arch, in this type of space maintainer either first or second deciduous molar are banded using either direct or indirect banding procedure and a lingual arch is fabricated with thick stainless steel wire in such a way that it should contact the lingual surface of all mandibular incisors and is soldered to the lingual surface of band on either side of the same arch



This type of space maintainer is used to preserve the space created by multiple loss of deciduous molars and also it helps in preventing drifting of molars, thereby help in maintaining arch perimeter.

### Indication

Loss of second primary molar in the mandible (counterpart to Nance).

### Advantages

Maintains the tooth space and the leeway space.

### Disadvantages

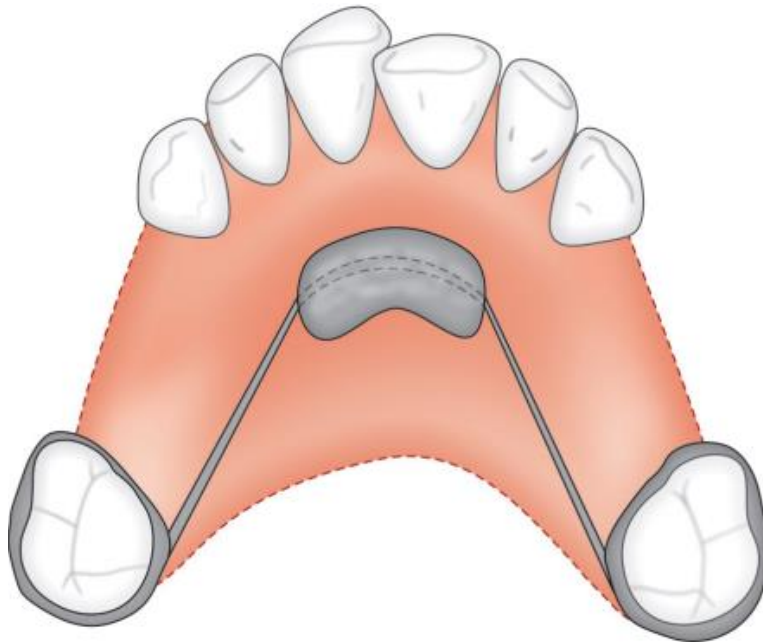
First permanent molars may be susceptible to decalcification; may be prone to breakage unless the patient is well-informed on maintenance.

## Nance Palatal Arch Space Maintainer

Nance palatal arch space maintainer consists of two molar bands of a wire component (palatal arch) and acrylic or palatal button. It is used only in maxillary arch. Bands are fabricated either using direct or indirect banding procedure on maxillary molars on either side of the same arch. A wire component (palatal arch) is fabricated using 0.036-stainless steel wire like lingual arch (**Fig. 19.18**). Both ends of the palatal arch are soldered to the palatal surface of the band on both sides of the same arch and its



anterior portion is made to get embedded in the acrylic portion or palatal button or Nance button. This type of space maintainer is used to prevent mesial migration of maxillary molars.

**Indication**

Loss of second primary molar in the maxilla-counterpart to lower lingual holding arch.

**Advantage**

Maintains the tooth space and the leeway space.

**Disadvantages**

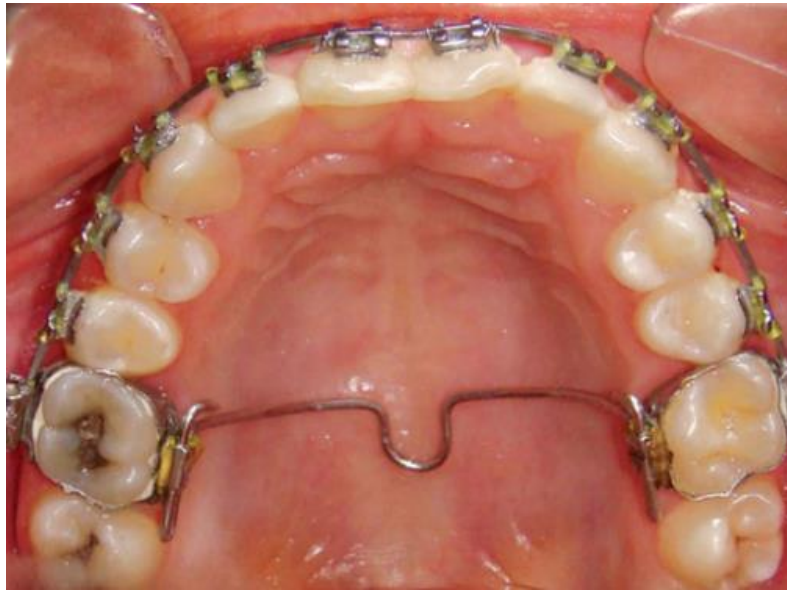Meticulous hygiene of the acrylic button is required. This type of space maintainer cannot be used in patients allergic to acrylic.

**Transpalatal Arch**

The transpalatal arch, as the name implies, extends from one maxillary first molar along the contour of the palate to the molar on the opposite side. The transpalatal arches can be either removable when they are inserted into the lingual sheath welded on the lingual surface of molar band or fixed when they are soldered to the lingual surface of molar band. Transpalatal arches are made from 0.036-inch stainless steel wire and that is soldered to the molar bands at their mesiolingual line angles.

### **Functions of Transpalatal Arch**

The major function of transpalatal arch in the mixed dentition is to prevent the mesial migration of the maxillary first molars during the transition from the second deciduous molars to the second premolars. The transpalatal arch can also be used for molar distalization and anchorage. The transpalatal arch routinely is left in place until the final comprehensive phase of orthodontic therapy is completed.



### **Fabrication of band and loop space maintainer:**

#### **Step 1:**

(a) Select and fit a band on the abutment tooth. Band selection is on trial and error basis, bands are tried over the abutment tooth until one can be nearly seated on the tooth with finger pressure and to gain an appropriate final occlusal and gingival dimension. Utilization of band pusher and band better accomplished.

(b) A properly placed band is seated approximately 1 mm below the mesial and distal marginal ridges. If needed orthodontic separators can be used to gain or create space for the band material placement.

#### **Step 2:**

Next, make a quarter arch impression of band and edentulous area with alignate impression material with use of perforated tray so that impression material can flow in perforations and can prevent distortion of impression when it is removed.

#### **Step 3:**

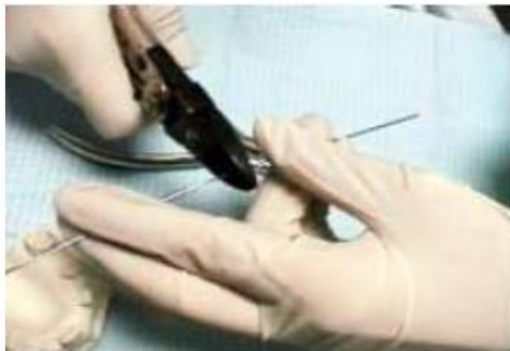Next, stabilize the band in impression in the correct position.

#### **Step 4:**

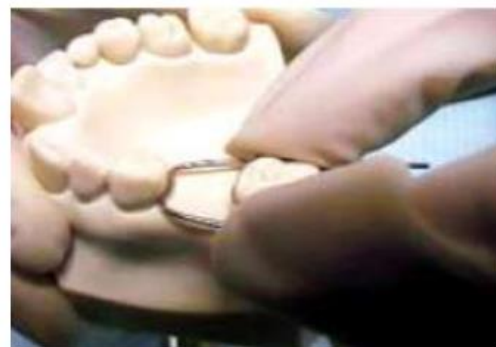The impression is poured in stone with band in place; the cast is separated.

#### **Step 5:**

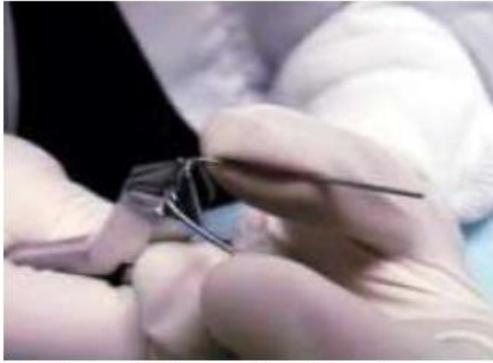The wire is shaped into a loop and is well contoured to fit the band and alveolar ridge.



**Figure 1:-** Cut 2.5" of 0.36 wire.



**Figure 2:-** Try on cast for close fit.



**Figure 3:-** Prong pliers for contour.



**Figure 4:-** Prong for vertical contour.

#### **Step 6:**

Adjustment: After fabrication of band and loop it should be fitted and adjusted accordingly.

#### **Step 7:**

Cementation: Band should be cemented onto dry, clean tooth with zinc phosphate or glass ionomer cement.

#### **Step 8:**

Patient recall visits: The patient is recalled every 6 months to check that appliance is working as per requirements as well as to check for fit of appliance and also that the cement has not washed out with also taking care of condition of abutment tooth.

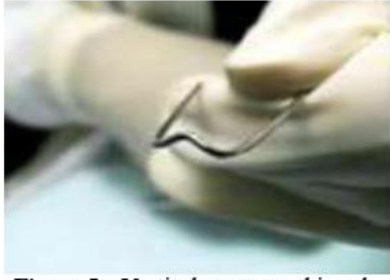#### **Step 9:**

Indication of removal: Eruption of permanent tooth is easily recognized indication of removal of space maintainer.

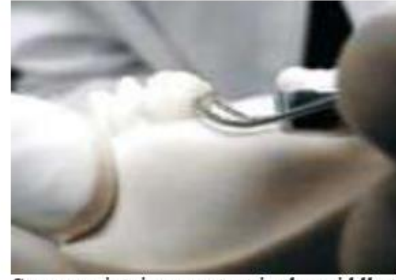### **How to Bend a Band Loop Spacer:**

#### **Requirements:**

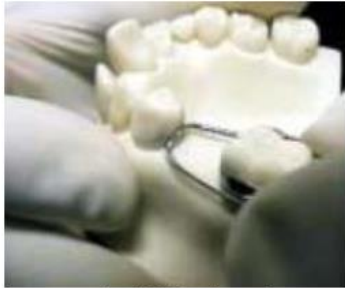1. The loop should parallel the edentulous ridge 1 mm off the gingival tissue and must rest against the adjacent tooth at the contact point. Facio-lingual dimension of loop should be approximately 8 mm.
2. The required dimensions must be included in fabrication to allow the permanent tooth to erupt freely but not impinge on the buccal mucosa or tongue.
3. The fabricated loop should not restrict any physiological tooth movement such as increase in inter-canine width which occurs during eruption of permanent lateral incisors.



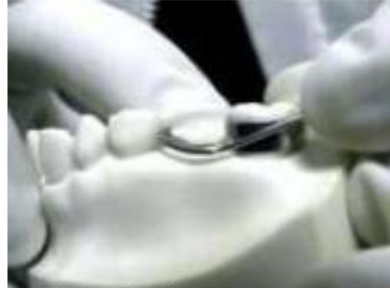**Figure 5:-** Vertical contour achieved.



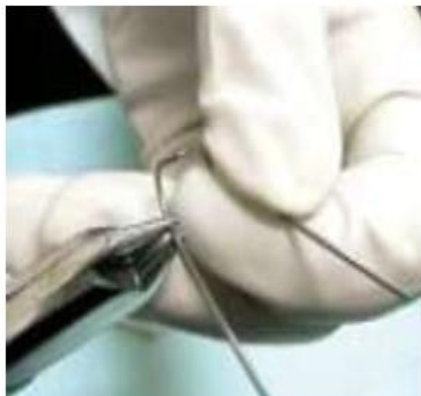**Figure 6:-** Space maintainer contact in the middle third of tooth mesial of the space.



**Figure 7:-** Check it for fit on the cast.



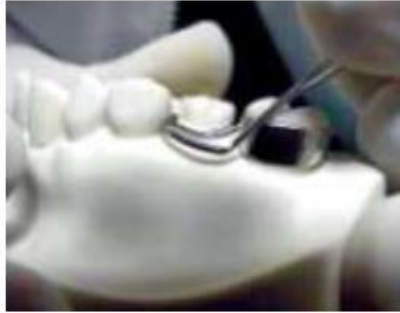**Figure 8:-** Mark for "S" bends; contour is about 1 mm above tissue



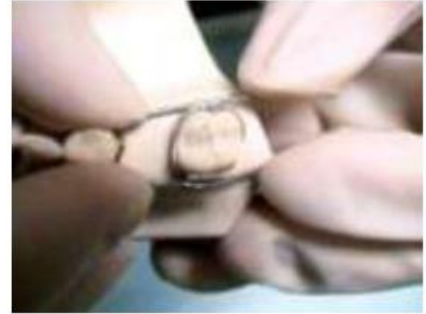**Figure 9:-** Contour buccal and lingual arms with 3 prong.



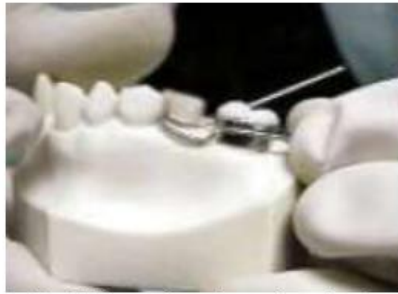**Figure 10:-** 45 degree bend with birdbeak pliers.



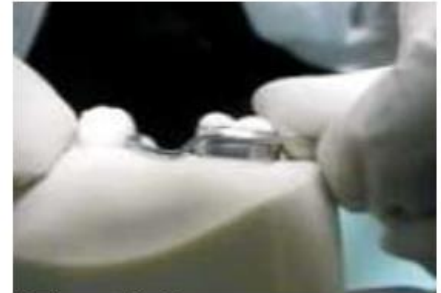**Figure 11:-** 45 degree "up" bend.



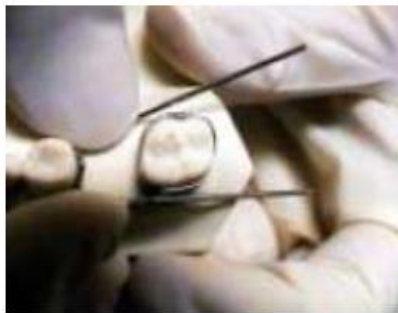**Figure 12:-** Improved buccal contour.



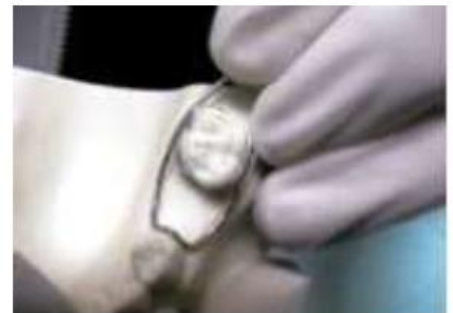**Figure 13:-** Wire at junction of occlusal and middle third of the band.



**Figure 14:-** Proper contour.



**Figure 15:-** Wire should now be contoured to the buccal and lingual contour of the tooth.



**Figure 16:-** Occlusal view.



<b>Indication</b>	<b>Space maintainers of choice</b>
Premature loss of deciduous incisors	<ul style="list-style-type: none"> <li>▪ Functional space maintainers</li> <li>▪ Removable space maintainers</li> </ul>
<b><i>Premature loss of deciduous canines</i></b>	
Unilateral premature loss of deciduous canines when deciduous first molar is sound (free of caries).	<ul style="list-style-type: none"> <li>▪ Band and loop space maintainers</li> <li>▪ Band and bar space maintainers</li> </ul>
Unilateral premature loss of deciduous canines when deciduous first molar is decayed.	<ul style="list-style-type: none"> <li>▪ Crown and loop space maintainers</li> <li>▪ Crown and bar space maintainers</li> </ul>
Bilateral premature loss of deciduous canine in maxillary arch.	<ul style="list-style-type: none"> <li>▪ Nance palatal arch space maintainers</li> </ul>
Bilateral premature loss of deciduous canine in mandibular arch.	<ul style="list-style-type: none"> <li>▪ Lingual arch space maintainers</li> </ul>
<b><i>Premature loss of deciduous first molar</i></b>	
Unilateral premature loss of deciduous first molar with sound second molar.	<ul style="list-style-type: none"> <li>▪ Band and loop space maintainers</li> <li>▪ Band and bar space maintainers</li> </ul>
Unilateral premature loss of deciduous first molar when second deciduous molar adjacent to missing is decayed.	<ul style="list-style-type: none"> <li>▪ Crown and loop space maintainers</li> <li>▪ Crown and bar space maintainers</li> </ul>
Bilateral premature loss of first deciduous molar in maxillary arch.	<ul style="list-style-type: none"> <li>▪ Nance palatal arch space maintainers</li> </ul>
Bilateral premature loss of first deciduous molar in mandibular arch.	<ul style="list-style-type: none"> <li>▪ Transpalatal arch</li> <li>▪ Bilaterally placed band and loop space maintainers</li> <li>▪ Lingual arch space maintainers</li> <li>▪ Bilaterally placed band and loop space maintainers</li> </ul>
<b><i>Premature loss of deciduous second molar</i></b>	
Unilateral premature loss of deciduous second molar	<ul style="list-style-type: none"> <li>▪ Band and loop space maintainers</li> </ul>
Bilateral premature loss of deciduous second molar in the maxillary arch.	<ul style="list-style-type: none"> <li>▪ Nance palatal arch space maintainers</li> <li>▪ Transpalatal arch</li> </ul>
Bilateral premature loss of deciduous second molar in the mandibular arch.	<ul style="list-style-type: none"> <li>▪ Bilaterally placed band and loop space maintainers</li> <li>▪ Bilaterally placed band and bar space maintainers</li> </ul>
Premature loss of deciduous second molar prior to eruption of permanent first molar	<ul style="list-style-type: none"> <li>▪ Lingual arch space maintainers</li> <li>▪ Bilaterally placed band and loop space maintainers</li> <li>▪ Bilaterally placed band and bar space maintainers</li> <li>▪ Distal shoe space maintainers.</li> </ul>

## **Space regainers**

This type of space maintainer as the name suggests is active and brings about the movement of the tooth/ teeth. It can be a removable or fixed, unilateral or bilateral appliance.

The goal of space regaining intervention is the recovery of lost arch width and perimeter and/or improved eruptive position of succedaneous teeth. Space regained should be maintained until adjacent permanent teeth have erupted completely and/or until a subsequent comprehensive orthodontic treatment plan is initiated.

### **Indication**

- When there is a need to re-establish about 3 mm or less of space.

### **Factors to be considered in planning of space regainer**

- It is easy to regain space in maxilla than in mandible, due to increased anchorage provided by the palatal vault and possibility of extraoral anchorage. Also the bone in maxilla is cancellous compared to the compact bone of mandible.
- Space loss by tipping can be regained when the crown of the tooth is tipped back.
- Space loss by bodily movement of the adjacent tooth should be regained by moving the tooth back bodily.

### **Types of space regainers**

1. Fixed space regainers
2. Removable space regainers

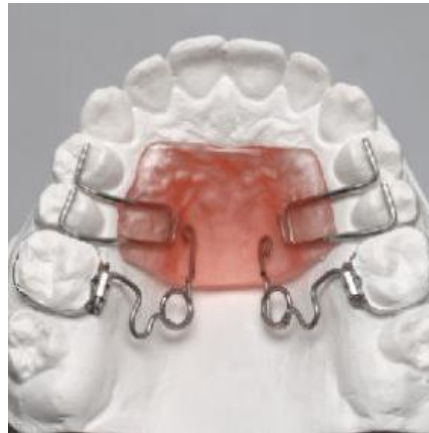### **Fixed space regainers**

#### **Pendulum appliance**

Pendulum appliance is used mainly to regain space in case of mesial drift of upper first molar due to early loss of primary molars.

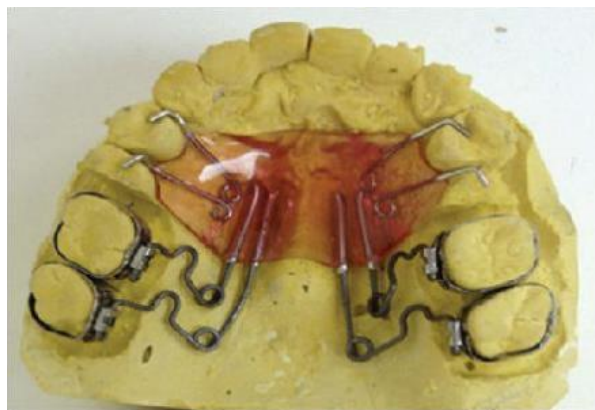
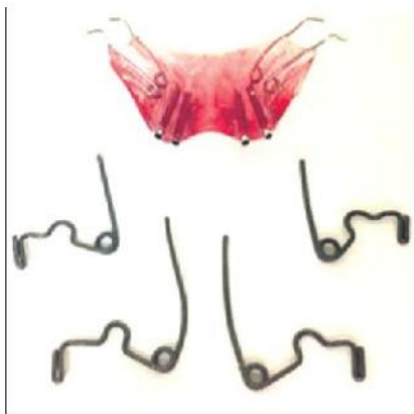
It consists of large Nance acrylic button in palate for anchorage and 0.032'' titanium molybdenum alloy (TMA) springs that provide light and continuous force to maxillary first molars for their distalization without having any effect on Nance palatal button. Acrylic button covers midpoint of palate and connected to upper first

and second premolars through occlusal rests. The two posteriorly directing TMA springs are also attached to it.



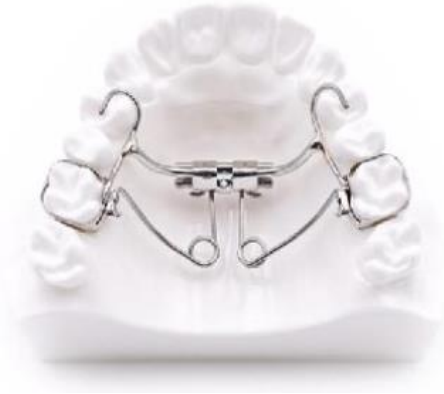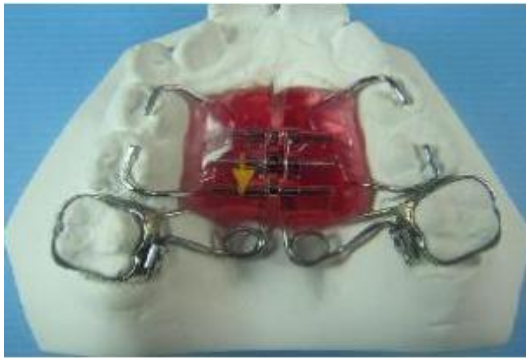### **Modified pendulum with removable arms**

modified version of pendulum in which springs of appliance can be removed for extra oral activation. Rest part of appliance remains fixed. The active components of pendulum appliance are inserted into acrylic sheaths of Nance palatal button and these can be easily removed from sheaths for activation. This modified can be controlled more accurately as compared to opening of loops intraorally.



### **Mini distalizing appliance (MDA)**

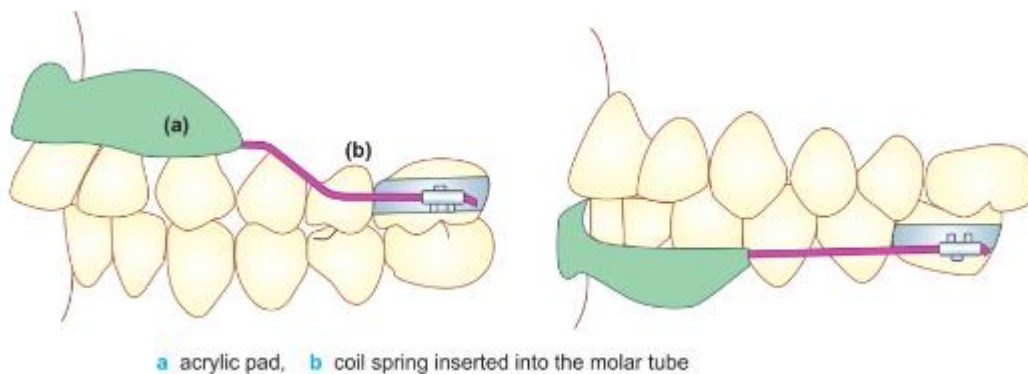
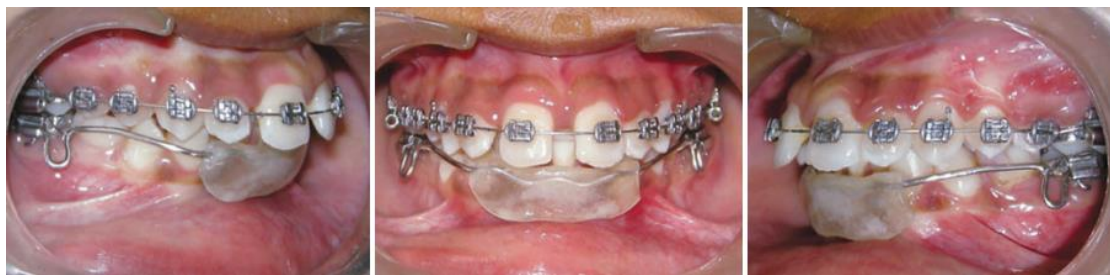This appliance combines features of pendulum appliance and rapid palatal expander (RPE). It is also an all metal appliance, used for both expansion as well as molar distalization using RPE and pre activated 0.032'' removable TMA springs. It gives more patient comfort, easy access for oral hygiene and there is no tissue impingement.



### Lip bumper appliance

Lip bumper appliance is used in the mandibular arch for gaining space or for distalization of molar and its counterpart in the maxillary arch is Denholtz appliance. Molar bands are prepared on permanent first molar and molar tubes are welded on the buccal side of each molar band. Labial archwire is then engaged in both the buccal tube and acrylic button is prepared on the labial vestibule.

The lip bumper has a removable part and a fixed part. The removable part is composed of a 1.0-mm stainless steel that runs in the lower vestibule from molar to molar between teeth, lip and cheeks. Fixed part of lip bumper is composed of two molar bands. The custom made lip bumper has only two loops and is located mesial to each molar.



### **Band and U loop space regainer**

It is a reciprocal active space regainer that is used in the mandibular or maxillary arch. It is also known as Open coil space regainer

#### **Construction - steps**

1. A molar band is fitted to the first permanent molar.
2. Molar tubes are soldered or spot welded in horizontal position both buccally and lingually to the band.
3. An alginate impression is made
4. stainless steel wire slightly smaller than the tube size is selected and bent into a 'U' shape.
5. Base of the U should contain a reverse bend to contact the distal surface of first premolar.
6. The wire comes out of the tube towards the premolar at a point below the greatest convexity of the first premolar.
7. A spaced coil spring is selected and is cut about 2 to 3mm longer than the anterior stop to the molar tube. The band is cemented with the coil springs compressed.



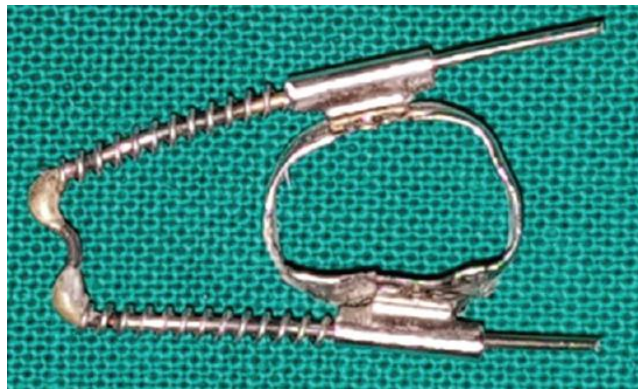

### Gerber space regainer

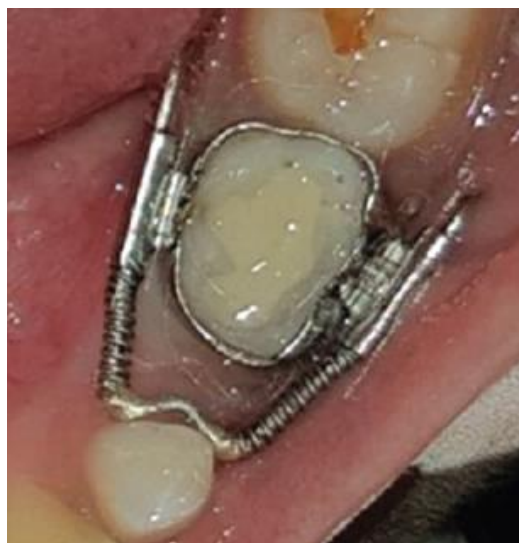In this appliance, weldable tube stops are soldered on the U bend of the wire and open coil spring sections are cut to fit over the wire between “stops” and ends of “U” loop. The springs are loaded and floss is tied through eyelet and over “U” wire to hold stored force in compressed spring. The springs are compressed so that the assembly should fit in the edentulous space.. The molar was banded with band containing molar tubes (0.7 mm diameter, 10 mm length) welded to band buccally as well as lingually; a 23 gauge wire was used with an open coil spring.

Note: If the coil spring is to be used as an open or compression coil spring they are compressed from their initial length of 15mm to 6mm. The closed or tension coil spring are distracted from their initial of 3mm to 6mm.

Or An open coil spring of approximately 2mm in excess of the space to be regained is cut and inserted into the prepared loop.



The assembly was cemented onto the tooth with the springs held in compression to half their lengths.

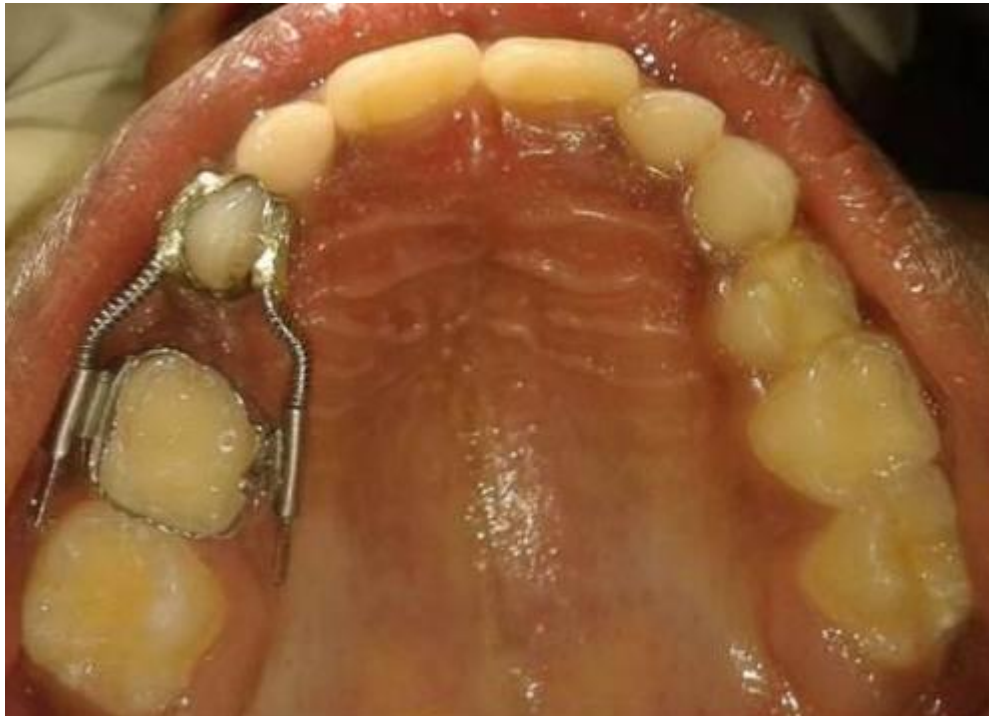



### **Double banded space regainer**

In this appliance, both the teeth adjacent to edentulous area are banded so that the possibility of tipping is avoided as compared to when only one tooth is banded.

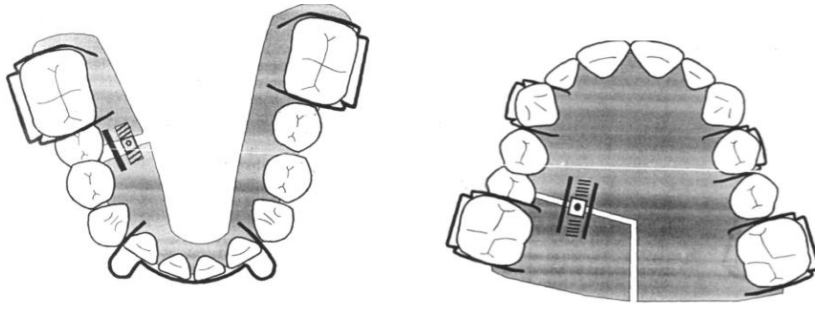
The primary left second molar was banded ( $0.005 \times 0.180$  inch) with molar tubes (0.7 mm diameter, 10 mm length) welded to it buccally and palatally. The primary left canine was also banded ( $0.005 \times 0.180$  inch) with two stainless steel wires (0.7 mm width) soldered to it buccally and palatally, extending posteriorly to insert into the molar tubes of the primary second molar. NiTi open coil springs were cut 2-3mm longer than the distance between anterior stop (solder joints) and molar tubes posteriorly, and incorporated into the wires. The assembly was cemented on to the teeth with the springs held in compression to half their lengths.



### **Removable Space Regainers**

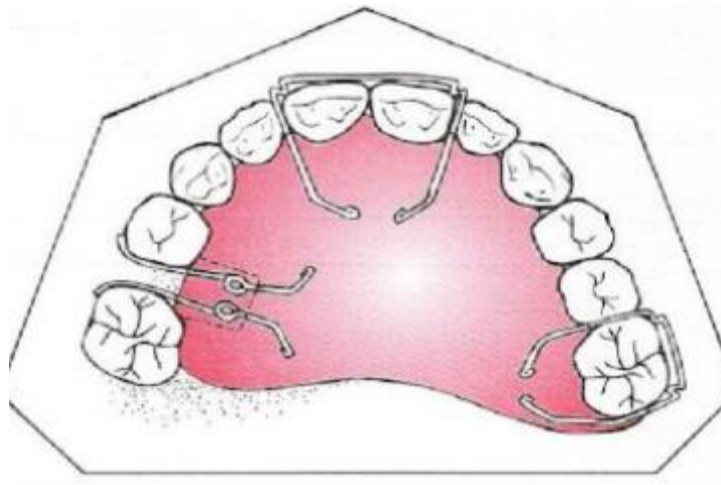
It consists of retentive components like the Adams clasp, an active component such as springs or screws and acrylic base plate.

- It is used when space loss is present on one quadrant only.
- Screw design has the advantage that the tooth to be moved can also be clasped to help retain the appliance.
- Single or double cantilever spring can be used with adequate anchorage.



### **Spring type space regainer**

In this appliance, springs are incorporated to produce the movement. This is used to produce distal movement of first permanent molar. The movement is achieved by the force produced by the spring using 0.7 mm wire



### **wires gauge:**

- 19 gauge = 1mm
- 20 gauge = 0.9mm
- 21 gauge = 0.8mm
- 22 gauge = 0.7mm
- 23 gauge = 0.6mm
- 24 gauge = 0.5mm

## Arch expansion

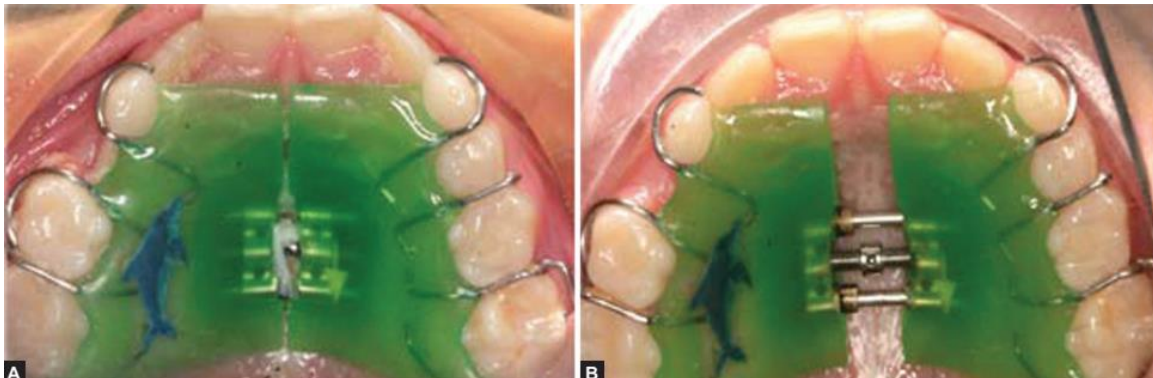
Arch expansion is one of the methods of gaining space in orthodontics. Arch expansion can be slow or rapid, removable or fixed. Slow arch expansion (SME) brings about mainly dentoalveolar expansion whereas, rapid maxillary expansion (RME) brings about both skeletal as well as dentoalveolar expansion. Removable expansion appliance may be a simple expansion appliance with incorporated jackscrew or coffin appliance. Fixed arch expansion appliances are tooth borne expansion appliances (Hyrax, Isaacson) or tooth and tissue-borne expansion appliances (Haas expansion appliance).

### Types of rapid maxillary appliances

1. Removable Appliances
2. Fixed Appliances
  - A. Tooth-borne
  - B. Tooth and tissue borne

### Removable Rapid Maxillary Expansion Appliances

Removable rapid maxillary expansion appliances consist of an expansion screw in the midline with split acrylic plate. It may also consist of retentive clasps ("C" or Adam's clasp) on the posterior teeth and a labial bow on the anterior teeth.



### Fixed Rapid Maxillary Expansion Appliances

Fixed rapid maxillary expansion appliances are fixed expanders which cannot be removed by the patient.

These fixed expanders can be classified into **tooth and tooth tissue-borne** appliances.

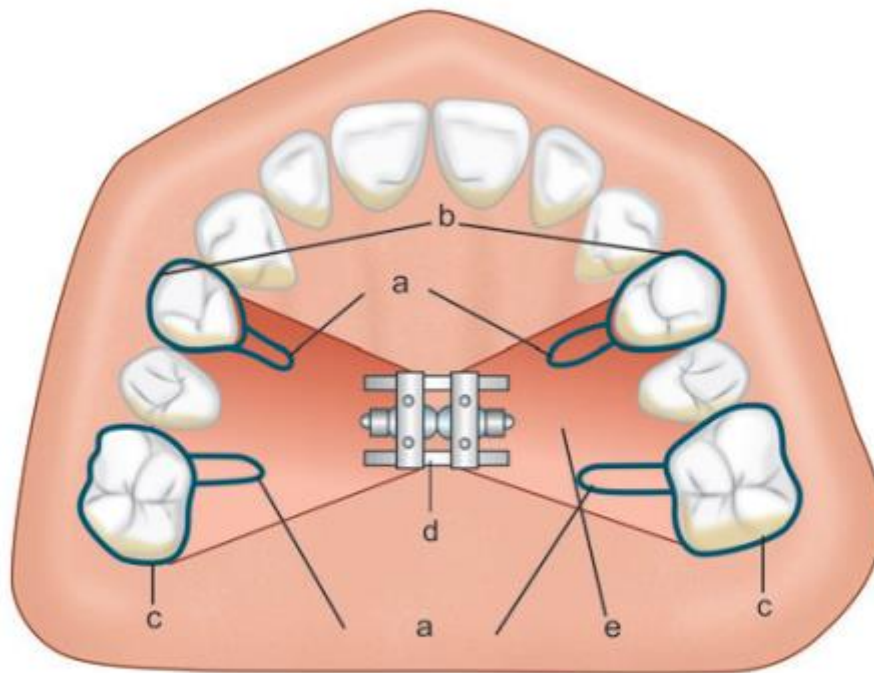
1. Tooth and tissue-borne appliances are:
  - A. Derichsweiler type.
  - B. Haas type.

2. Tooth-borne appliances are:

- A. Hyrax.
- B. Isaacson type.

### Derichsweiler-type Expander

Derichsweiler expansion appliance consists of molar bands on right and left permanent first molars and first premolars with wire tags soldered into the palatal surface of all molar and premolar bands. The outer free ends of wire tags are inserted into split palatal acrylic, incorporating a jack expansion screw in its center.

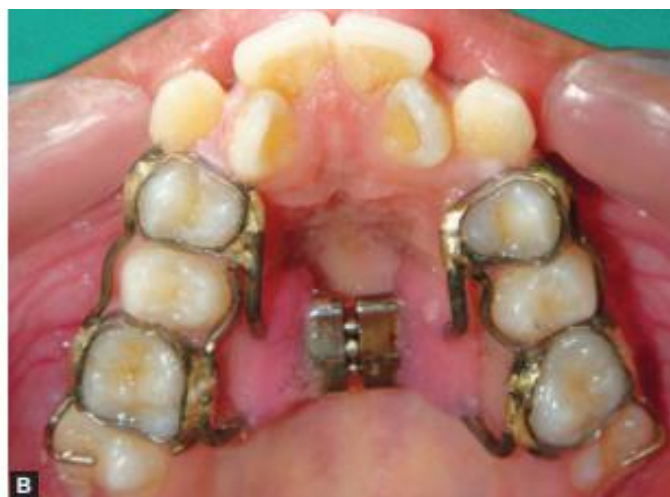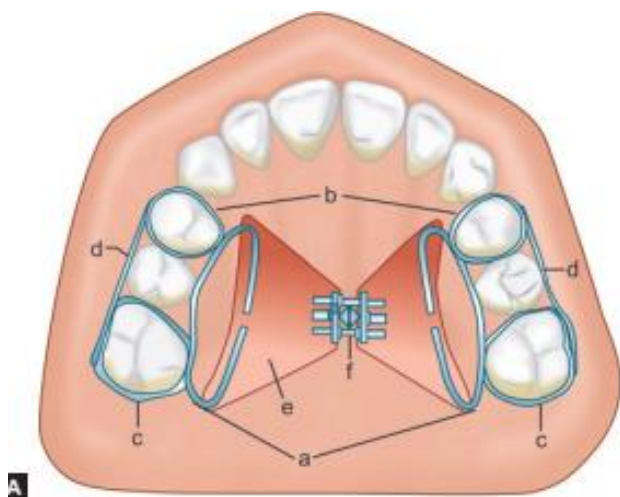


Parts of Derichsweiler expansion appliance. (a) Wire tags, (b) Premolar bands, (c) Molar bands, (d) Expansion screw, (e) Acrylic plate

### Haas-type Expander

This appliance consists of molar bands on right and left permanent molars and premolars. A jack screw is incorporated in the midline into the two acrylic pads that closely contact the palatal mucosa. Support wires also extend anteriorly from the molars along the buccal and lingual surface of the posterior teeth to add rigidity to the appliance. Haas states that more bodily movement and less dental tipping is produced when acrylic palatal coverage is added to support the appliance thus permitting the forces to be generalized not only against the teeth but also against the underlying soft and hard palatal tissues.

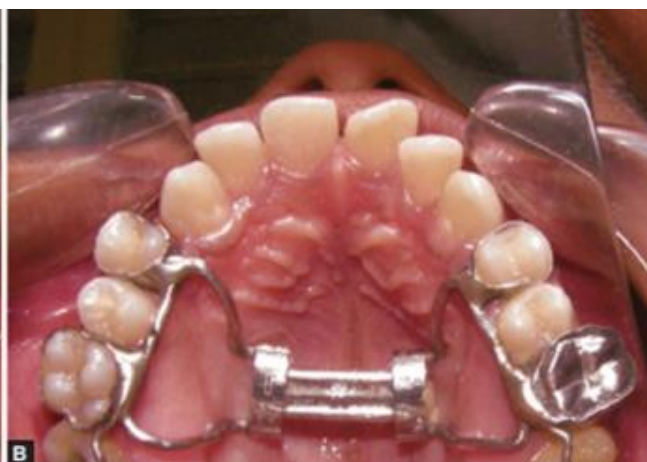
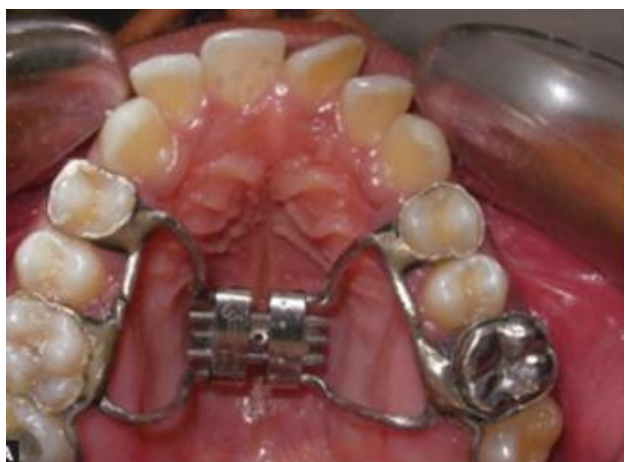


(A) Haas type of expansion appliance. (a) Lingual support wire, (b) Premolar bands, (c) Molar band, (d) Buccal support wire, (e) Acrylic plate, (f) Expansion screw (B) A case treated with Haas Derichsweiler type of expansion appliance

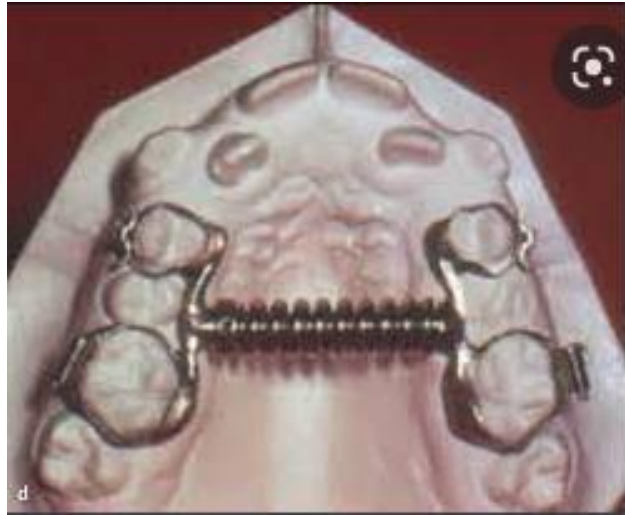### Hyrax-type Expander

This type of expander is made entirely from stainless steel. Bands are placed on the maxillary first molars and first premolars. The expansion screw is localized in the palate in close proximity to the palatal contour. Buccal and lingual wires may be added for rigidity.



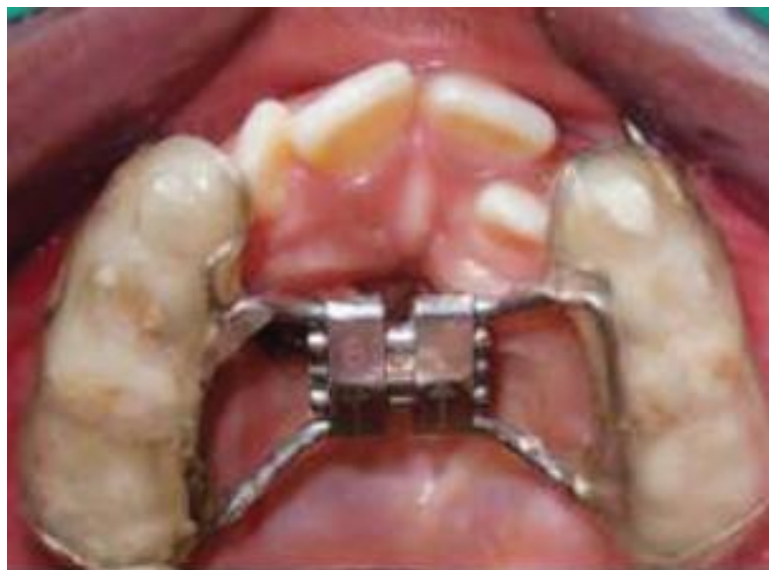### Isaacson Expansion Appliance

Isaacson expansion appliance is a fixed tooth-borne appliance without acrylic covering. This appliance consists of molar bands on first right and left permanent molars and premolar bands on right and left permanent premolars. Metal flanges are soldered into the molar and premolar bands on buccal and palatal sides. A spring-loaded expansion screw (MINNE) expander, having a nut, which can compress the spring and is made to extend between palatal metal flanges.



### **Bonded Rapid Maxillary Expansion**

Bonded rapid maxillary expansion appliances consist of an acrylic splint, covering variable number of teeth on either side in the maxillary arch, to which a jack screw is attached. Splint can be either cast cap made of silver copper alloy or acrylic splint made of polymethyl methacrylate. A wire framework may be adapted around the teeth to reinforce the acrylic.

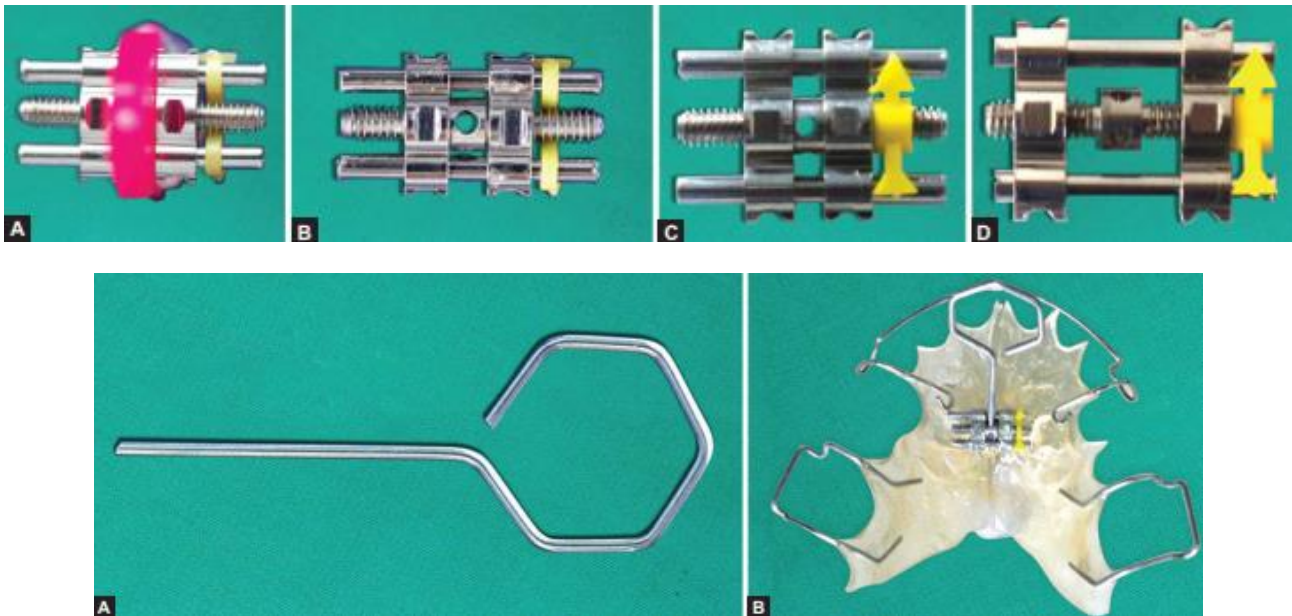


Bonded rapid maxillary expansion appliances consist of an acrylic splint, covering variable number of teeth on either side in the maxillary arch to which a jackscrew is attached

### **Expansion Screw**

A typical expansion screw consists of an oblong body divided into two halves. Each half has a threaded inner side that receives one end of a double ended screw. The screw has central bossing with four holes. These holes receive a key called expansion screw key, which is used to turn the screw.





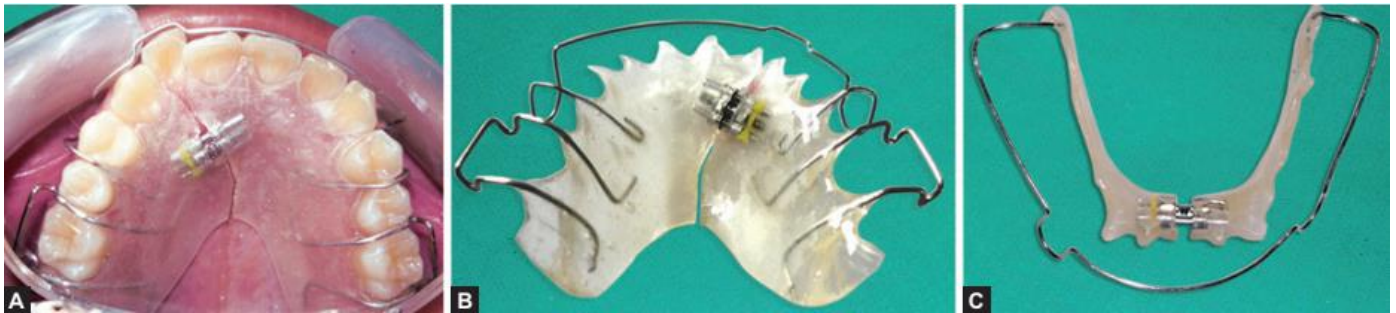## Different types of expansion screws

Expansion screw type	Use
Symmetrical bilateral expansion screw	Bilateral expansion
Traction screw	Closing spaces
Expansion screw with split activator	Separate expansion of maxilla or mandible
Three-dimensional screw	Anterior and bilateral expansion

## Types of slow maxillary appliances

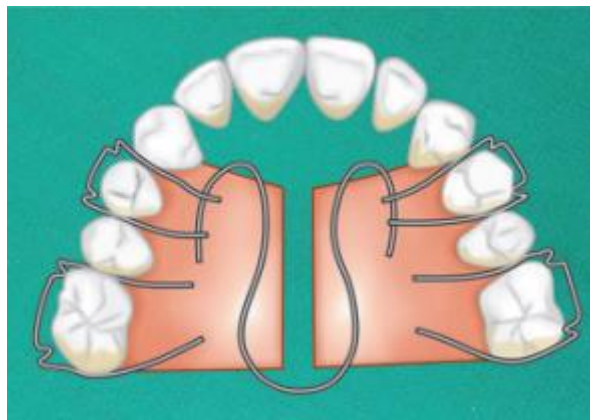
### Jackscrew

Various types of screws used for the rapid maxillary expansion can be used in slow arch expansion. Slow expansion using jackscrew can be used for expansion in both arches. Screws used in slow expansion are of smaller pitch and are less frequently activated as compared to screws used for the RME.



### Coffin Spring

Coffin spring is a type of removable orthodontic expansion appliance, which when used, brings about slow dentoalveolar expansion.



#### Design of coffin spring:

The coffin spring consists of an omega-shaped wire, fabricated with 1.24 mm hard stainless steel wire and placed in the mid-palatal region. Only two outer free ends of omega wires are incorporated into the acrylic base material and the rest part of omega wire is kept free from acrylic. The outer two free ends of omega wire are incorporated into acrylic base material covering the slopes of the palate. The coffin spring is used to expand the arches in cases of unilateral crossbite.

## Quad Helix Appliance

It is believed that the Quad Helix is evolved from the coffin spring. As the name suggests, the appliance has four helices incorporated in its design. Quad helix can be used as a removable expansion appliance when its outer arms are placed in the lingual sheath and it can be made fixed orthodontic appliance when its outer arms are soldered to the palatal surface of molar bands.



Design of quad helix: The parts of quad helix are as follows:

### 1. Helices

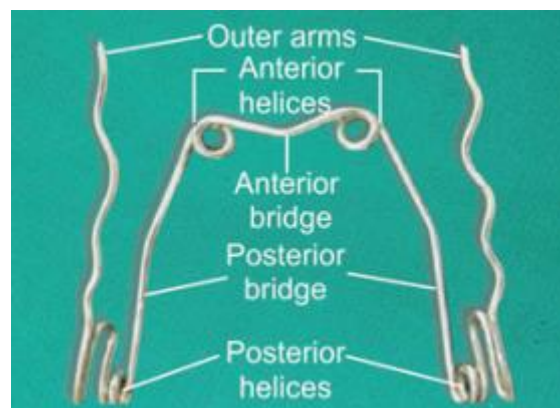
The quad helix consists of four helices, two anterior and two posterior. The diameter of each helix is about 3 mm.

2. Anterior bridge: Anterior bridge is the portion of wire between anterior helices and is one in number.

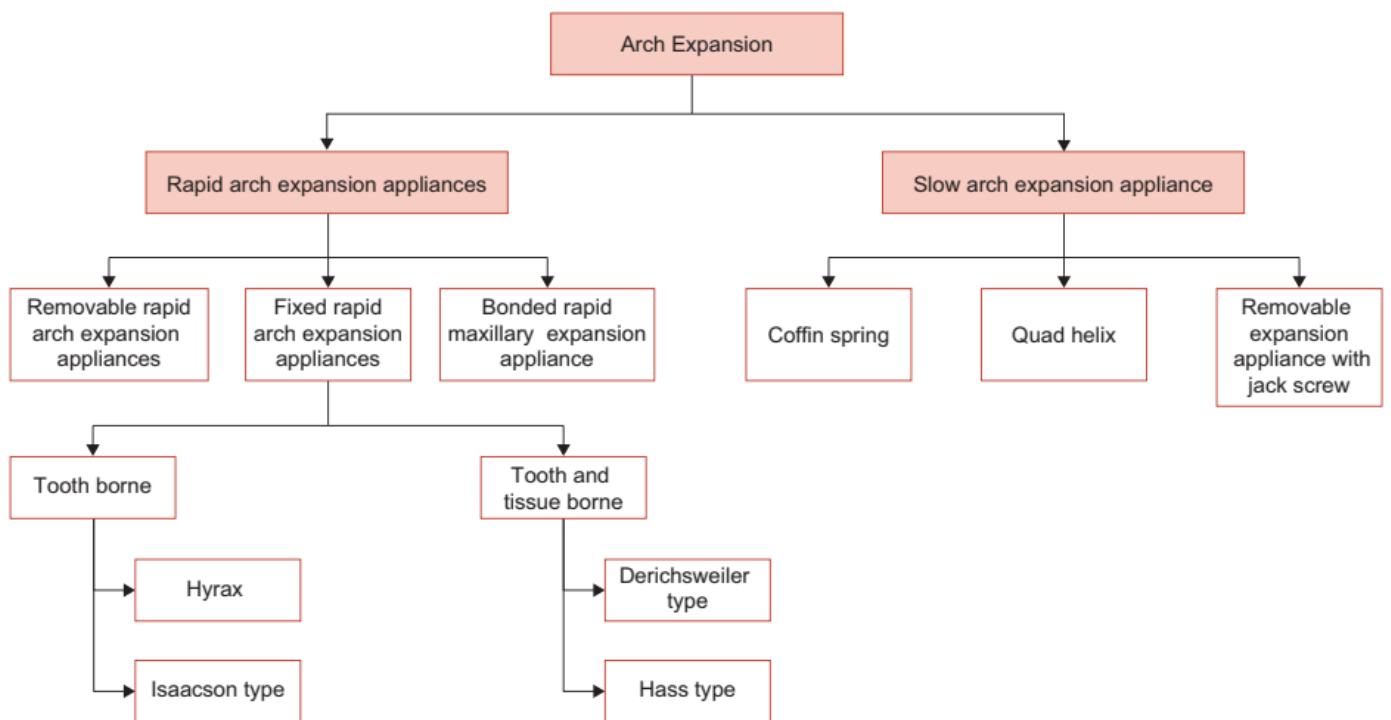
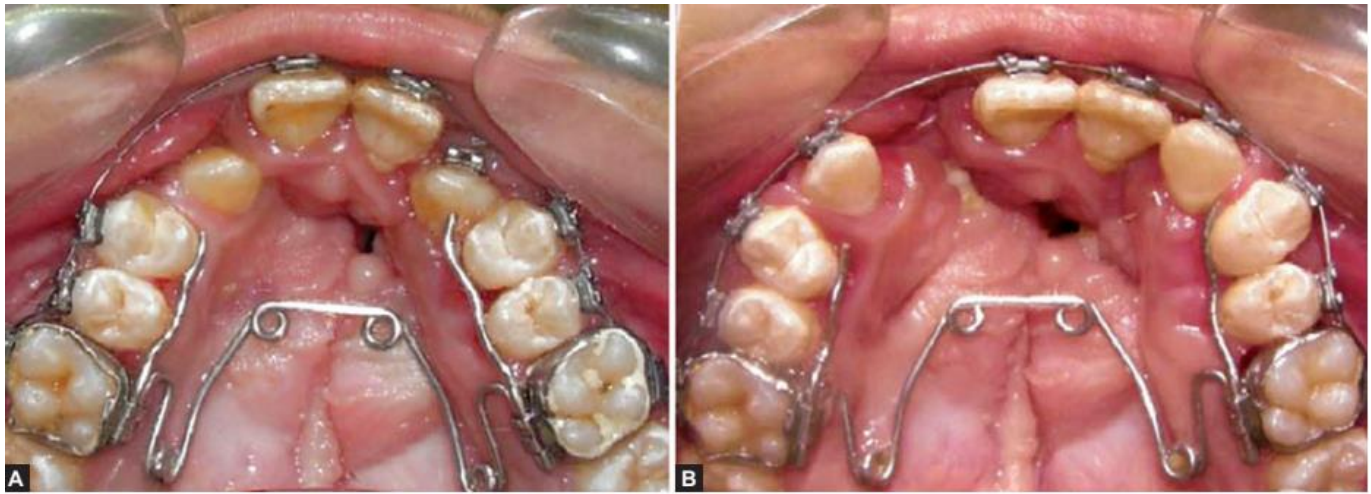
3. Palatal bridge: Palatal bridge is that portion of the wire that connects the anterior helix to posterior helices and are two in number.

### 4. Outer arms

There are two outer arms and are usually adapted close to the premolar teeth. The outer arms are either soldered to molar bands. Slow expansion using jackscrew can be used for expansion in both arches or placed in lingual sheath (welded to palatal surface of band).



**Use:** Quad helix appliance is used to expand constricted maxillary arch and also to bring about rotation of molars



## **Occlusal Wafers**

The treatment of severe malocclusions and facial deformities of skeletal origin often involves a combined orthodontic and surgical approach. Most orthognathic surgical procedures involving single or double jaws require occlusal wafers to facilitate surgical efficiency, accuracy, and stability of the jaws. The constructed occlusal splints are then used to transfer the postoperative position to the patient at the time of surgery

The orthognathic surgery wafers are used in orthognathic surgery as:

- (a) an intermediate guide for repositioning the mobilized maxilla relative to the intact mandible,
- (b) an aid to achieve the planned final occlusion,
- (c) post-operative proprioceptive guidance: After rigid fixation of the mandible the wafer may be wired to the maxilla or mandible to provide postoperative proprioceptive guidance for up to two weeks. This will help the patient to gain the occlusion in the finally planned position.



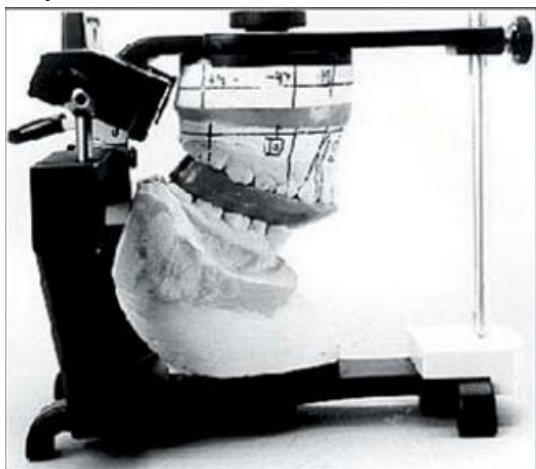
## **Materials and Types of Occlusal Wafers for Orthognathic Surgery**

The wafers may be fabricated from self-cured or heat-cured methyl methacrylate or, more rarely, cast in silver or cobalt chromium alloy for difficult cleft palate cases. It is essential to use recent models for wafer fabrication; impressions must be taken at least two weeks after any final adjustment of the orthodontic stabilizing arch wire. Similarly, it is useless to use models which precede the removal of an appliance preoperatively.

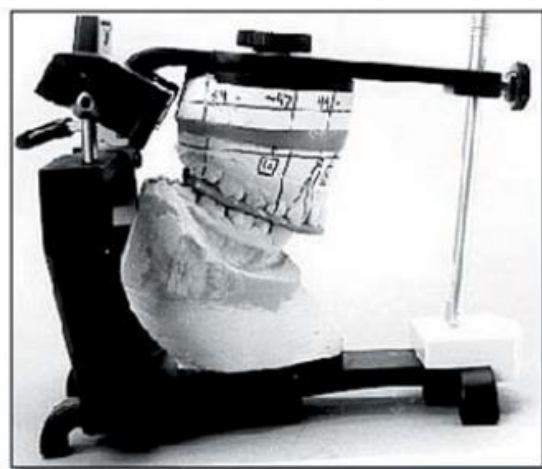


For patients whose arches had been leveled before surgery, the thinnest practical wafers had 1 to 2 mm of material between the teeth, the minimum necessary to keep the wafers from breaking easily during use. This problem may be resolved by the use of high impact acrylic. It has also been suggested making the wafer slightly thicker posteriorly (<2 mm) will allow some problems in the condyle postoperatively.

Thick occlusal wafer in high impact acrylic.



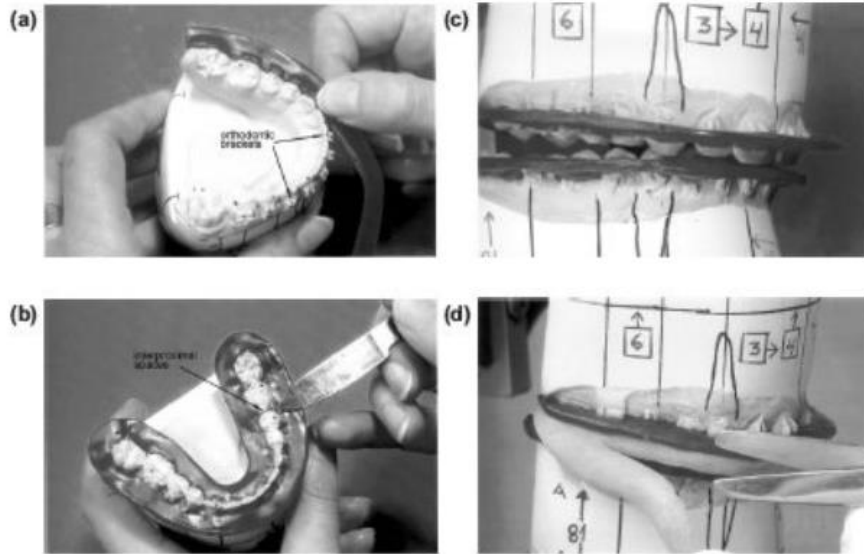
Thin occlusal wafer in high impact acrylic



### ***Wafer Fabrication***

Wafers may be fabricated from cold cured (autopolymerising) or quick cure methylmethacrylate. A poorly designed inaccurate wafer will spoil the most skillful surgical technique. It is common practice to construct both the intermediate and the final wafers as thin as possible. The justification has been that thick wafers introduce discrepancies in the final occlusion.

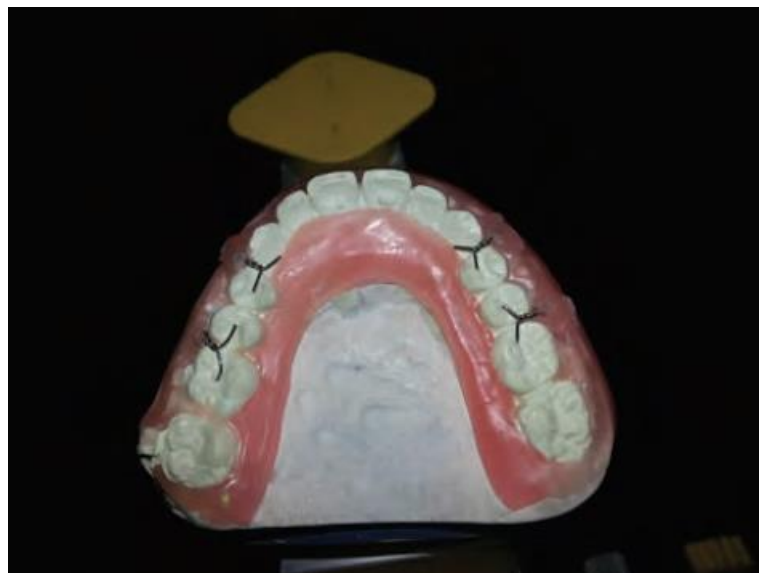



(a), (b), (c) and (d) After the model surgery, the maxillary and mandibular models with the mounting assembly are removed from the articulator for wafer fabrication.

### **The Construction Technique Using Quick Cure Acrylic**

After the model surgery, the maxillary and mandibular models with the mounting assembly are removed from the articulator. All the undercuts along the palatal, lingual and buccal aspects of the dental arches are relieved by applying a strip of soft red beading wax.



Blocking out the undercuts on the dental models using wax in order to prevent the acrylic from locking into the undercuts, which will result in damage to the model when removing the splints. Wire loops in position, which may be used intraoperatively to ligate the splints to the orthodontic archwires.

The occlusal margins of the orthodontic brackets are the limit of the coronal extension of the wafer. It is advisable to have about 1 mm space between the acrylic wafer and the orthodontics brackets or arch bar to avoid any interference at the time of insertion. The Interproximal spaces are blocked out with the wax to ensure that the wafer does not extend into these unwanted areas and impair fit during the surgery.

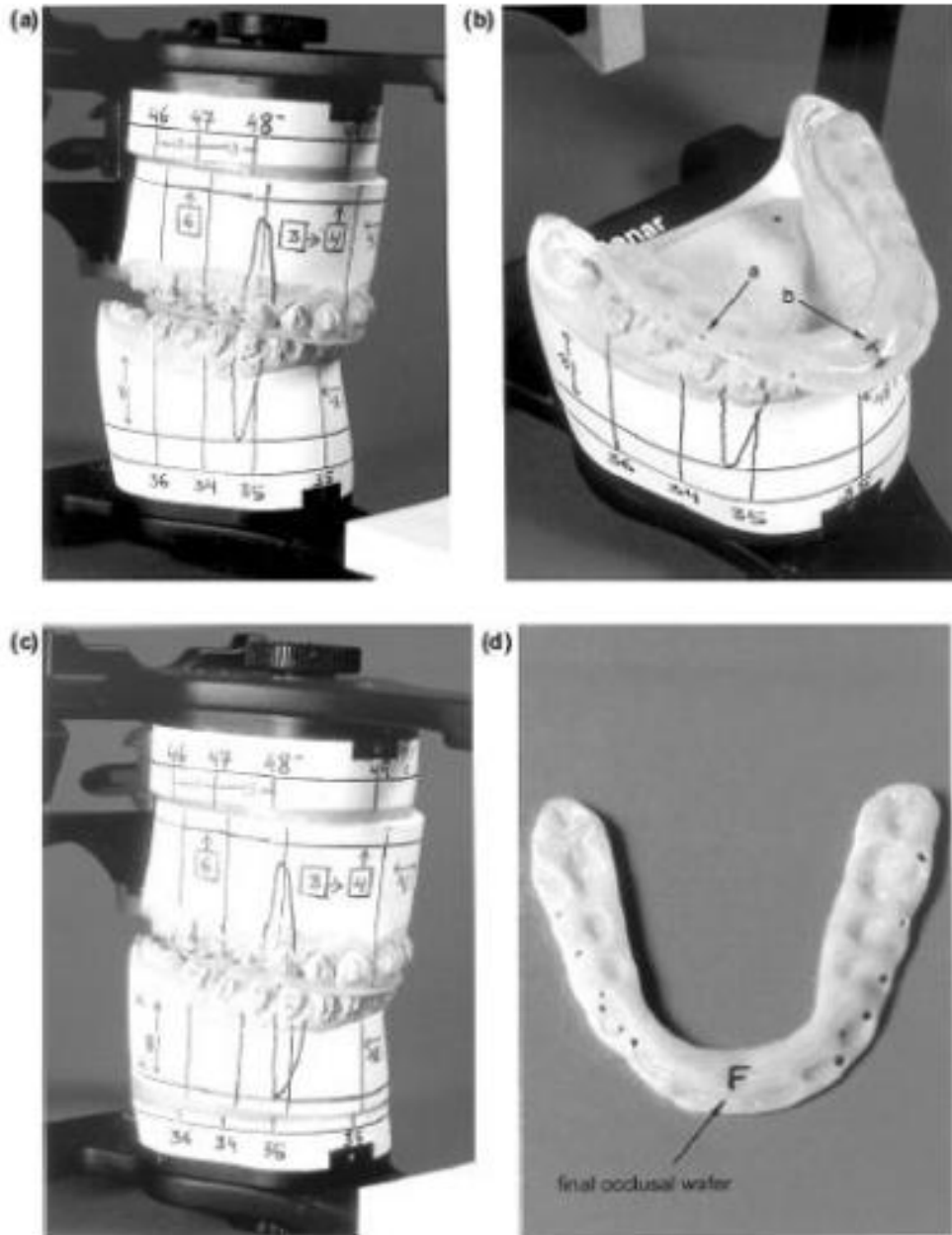
The tips of the plaster teeth are soaked in the water for 10 minutes and the dental arches are coated with sodium alginate separating medium for easy separation of the acrylic from the casts. The upper postoperative and the lower preoperative models are placed back onto the articulator to fabricate the intermediate occlusal wafer.

A quick cure high impact acrylic is mixed using 70% high impact polymer, and 30% rapid repair polymer with its monomer. When the mix is at the dough stage, a U shaped role is placed over the occlusal surface of the mandibular arch. The acrylic dough is moulded and directed towards the buccal and lingual surfaces of the teeth with a spatula, ensuring full coverage of the occlusal surfaces.

The upper arm of the articulator is closed down firmly until its incisal pin touches the incisal table. The acrylic material is thus sandwiched between the maxillary and mandibular dental arches indexing the occlusal surfaces of the teeth. While still soft, the excess acrylic is trimmed with a pair of scissors. At the initial polymerization stage, the articulator is carefully opened and closed, to ensure that the wafer could be removed from both the upper and lower models when processed. This will also eliminate acrylic contraction around the incisal tips and minimize any damage to the teeth at wafer removal, when fully polymerized and hard.

After removal of the excess acrylic and ensuring that the dental arches are fully covered, the articulator with the models and wafer is secured with a rubber band and placed in the hydro-flask for 10 minutes for curing. Once processed, the upper arm of the articulator is unlocked and removed gently before removing the wafer. It is then trimmed and polished, avoiding frictional heat, which may warp the acrylic. The process is repeated with both postsurgical models for the final wafer.

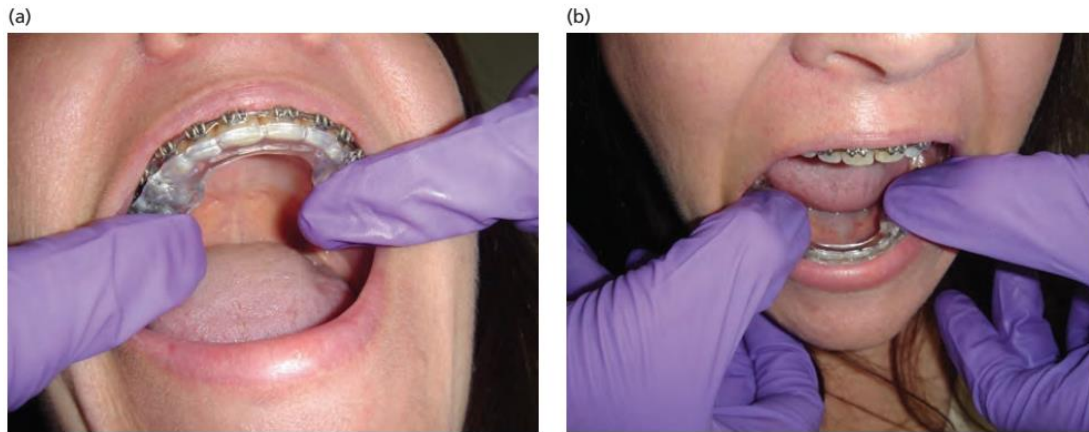




**a)** The buccal and lingual aspect of the wafers should blend into the tooth morphology. **(b)** On buccal aspects of the wafer small holes are drilled using a round bur No. 5 to pass wires through to suspend the wafer to orthodontic brackets or arch bars. **(c)** Final occlusal wafer is tried in on the models. **(d)** For identification letter (I) for intermediate and (F) for final is engraved and a groove representing the midline can also be marked with No. 2 bur. These letters can be reinforced with lumocolor permanent pen.

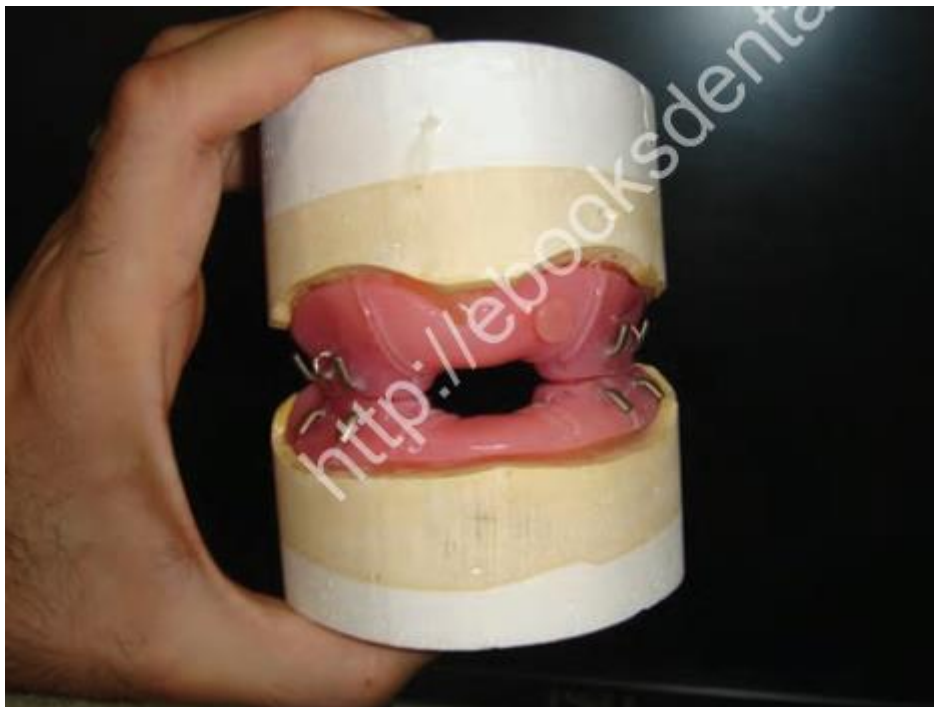The completed wafers are seated on each model for a final check. The buccal, labial and lingual aspects should blend into the tooth morphology. On the buccal sides, small holes are drilled using a round No. 5 bur for suspensory wires to orthodontic brackets or arch bar. A groove representing the facial midline should also be marked with a No. 2 flat fissure bur. These are reinforced with a Lumocolor permanent pen

and can be embedded with self-curing clear resin, thus ensuring ready identification. Although it is convenient to drill small holes for wire loop maxillary suspension, embedded ball end clasps are occasionally a useful alternative.



(a, b) The splints being tried in to ensure a secure and passive fit on the patient's dental arches without rocking.

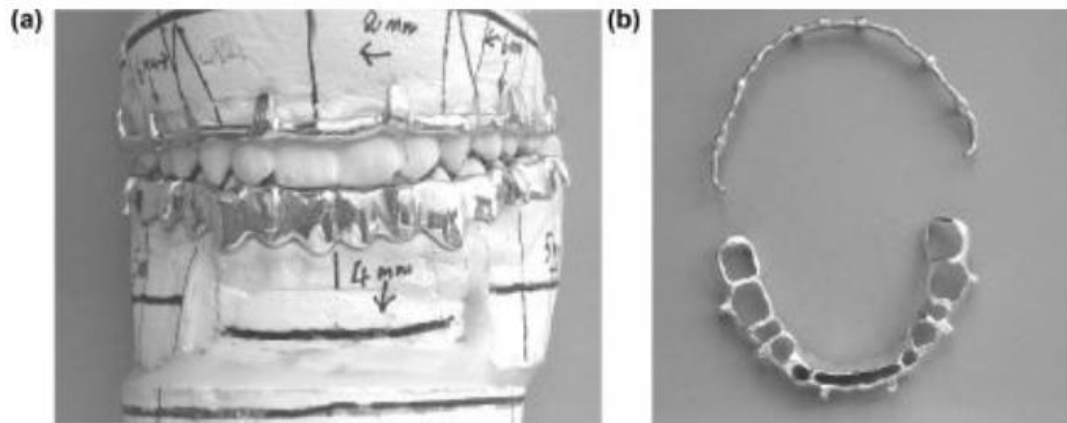
#### **Splint wafer modification or edentulous patients**



### ***Cast Metal Cap Splints***

In procedures for gross facial deformity where prolonged fixation is required, metal cap splints still prove to be more reliable than any other method. Many variations exist. For repositioning of dentoalveolar fragments, the splint can be made

- i) in separate parts and joined together with precision locks and connecting bars;
- ii) as a one-piece open cast splint can be constructed on the surgical planning cast and fitted both as a template and fixation at the operation;
- iii) the splints can be secured to the mandible with circumferential wires during the operative procedure.



**(a) and (b)** A combination of a custom-made arch bar and open occlusal metal splint.




(a)



(b)



(c)



(d)



(e)



(f)







(a) Maxillary model positioned on the bite fork on the articulator; 12 mm plastic plate in position, which will provide space for the preoperative plaster spacer; (b) a pin and sleeve system may be used to position the spacers to the articulator and (c) the models to the spacers; (d) plastic plate removed and preoperative plaster spacer in position (coloured green); (e) mandibular model articulated in preoperative position using the wax occlusal registration; (f) preoperative position with preoperative spacers (coloured green); (g) postoperative position of the maxilla with postoperative maxillary spacer (coloured peach); (h) postoperative position of mandible and maxilla with postoperative spacers (coloured peach); (i) interocclusal putty used to create the intermediate and final acrylic wafer splints.

## Computer-aided design/Computer-aided manufacturing (CAD/CAM)

CAD / CAM systems in dentistry consist, basically, of three components:

- The first component is a device that reflects the preparation of teeth and other supporting tissues and is responsible for spatial data digitalization (CAI - Computer Aided Inspection).
- The second component consists of computer which plans and calculate body form of restoration, equivalent to the area of CAD-s.
- The third component represents a numerically controlled milling machine which from the basic shape produces dental restoration, corresponding CAM area.

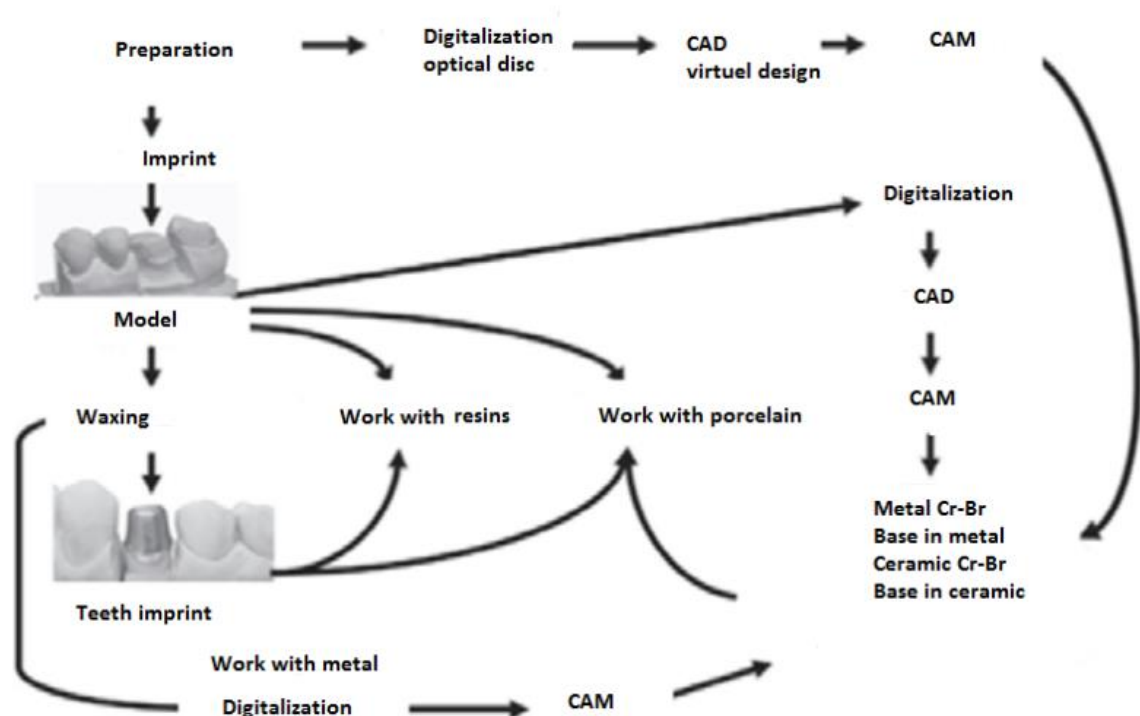
As a rule, there are recommended additional processing such as polishing or individual preference by a dental technician or doctor.

Restorations are made in several phases, which are allocated by the following order :

1. Overview and history- Based on the indications and the status of the tooth, as shown in Figure 6, the dentist diagnoses and recommends several options, explaining the pros and cons, depending on the indication.
2. Preparation of teeth for placing prosthetic restorations. Process begins by grinding of teeth and its suppression, which is carried out by dentist depending on the type of the ceramics to be used for the certain clinical case, i.e. to create prosthetic restoration.
3. Taking the tooth imprint. The dentist performs the tooth imprint (one or more, depending on which prosthetic restorations works), on which it will carry out further construction and casting of prosthetic restoration.
4. Casting of the model. Based on the tooth imprint plaster model is casted, on which is carried out further work, on the basis of tooth imprint.
5. 3D scan of the model. 3D oral camera captures teeth, after which the image is transferred to a computer and processed using the software. These cameras allow a high degree of accuracy and efficiency, and are particularly suitable for the restoration of individual crown.
6. Modeling. CAD / CAM software modeling the teeth based on the entered requirements.
7. 3D teeth printing. Before you start teeth printing, you need to install ceramic blocks in the milling. The ceramic block is fixed on the wheel that allows block to be inserted. Bridge is produced by milling process on the basis of the 3D model from the

block set in the CAD-CAM device. Milling machine develops the desired shape in accordance with the instructions of a computer. The ceramic block is processed by turning on its axis, a diamond disk rotates, moves up and down around the ceramic block and processes it. The movement of the diamond disc is enabled via electric rail.

8. Cementation. Prosthetic restorations are cemented with special aesthetic cement for metal-free ceramics. There are two types of cementing - temporarily and definitively. Temporary cementing of restoration is done in the period of adaptation of prosthetic restoration to the jaw, while definitive cementing is done after ensuring that the prosthetic restorations is accepted.



### General Classification Of CAD/CAM Systems:

Optical methods of spatial digitalization, are divided as:

- intraoral and,
- extraoral methods.

1. Intraoral scanning means work in a dental office, while the extraoral methods, mainly related to laboratory work. Today in the practical application is present only a single intraoral.

The requirements set for them are different. For ergonomic reasons, intraoral scanner should not be fixed to the remaining teeth. This affects the request of its shape, size, weight and ability to maintain hygiene, but above all the speed of scanning. Empirically it is proven that trained user can keep the scanner head immovable and still versus the scanned tooth, mostly for 0.5 seconds.

The data on the speed of data measurements acquisition, in addition to the resolution, is one of the most important in the choice of the system and its broad applicability. Size of the scanning field is minimally 14x14mm, and optimally 25x14mm. The range of scanning depth should be at least 10 mm, but should not be greater than 14 mm. Scanner resolution should be at least  $\pm 25\mu\text{m}$ .

2. Extraoral systems scan is carried out on the model, and for this reason there is a need for dental technical laboratory. In these systems it is not critical high speed data collection, because the head of the scanner and the object that is scanned are immovable.

\*\*\*\*\*CAD/CAM using networks for outsourcing dental lab work: Technologies using CAD/CAM with network machining center which means outsourcing the framework fabrication using an internet have been introduced as the design and fabrication of the framework for high strength ceramics is technique sensitive (9)

Advantages of using CAD / CAM technology for dentists are:

- The patient spends less time in the office;
- A simplified procedure;
- Significantly reduced costs for dental technical laboratories;
- Reduced consumption of materials;
- Increased productivity;
- Easier way of producing;
- Precisely produced restorations;
- Increased productivity.

Advantages of using CAD / CAM technology in dental-technical laboratory:

- Easier way of producing;
- More precisely made restorations;
- Lower consumption of materials;
- Higher productivity. Advantages of using CAD / CAM technology to produce onlays:
- Very often saves the tooth structure compared to traditional crowns.

Advantages of using CAD / CAM technology to produce inlays:

- Much better restoration than traditional fillings.

Disadvantages:

1. The primary consideration in a CAD/CAM purchase is the length of the learning curve, which may range from a few days to several months and may result in the loss of office production and loss of patient treatment time.
2. Other major problem is the potential for the dental team to resist the system's use and the clinician's lack of confidence in using a computerized system.
3. Capital costs of these systems are quite high and rapid large scale production of good quality restoration is necessary to achieve financial viability.
4. Matching the patient's tooth shade to the blocks of materials used to fabricate the restorations can be a challenge to the dentist initially.
5. Some CAD/CAM system relies on margin capture for digitization, thus making subgingival margin capture challenging .
6. CAD/CAM is ever advancing technology. Upgrades and updates are to be expected. The existing software takes no time to become obsolete.

It is wise to question how long the technology has been on the market and how soon a revision will become available. Thus, the dentist may need to budget for monthly expenses for technical support and software up gradation

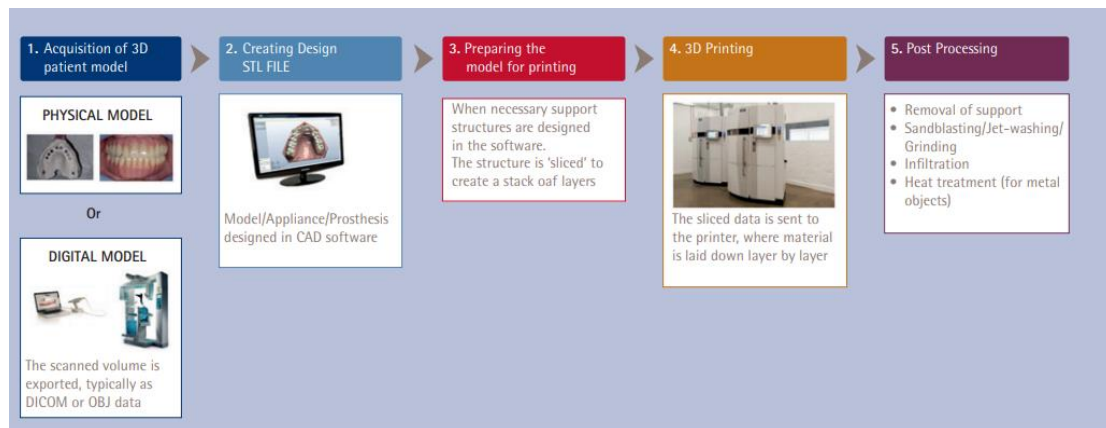
### 3D Virtual planning in orthognathic surgery and CAD/CAM surgical splints:

Developments in 3D imaging technology enabled the creation of new computerized tools to assist in preoperative planning and manufacture of surgical splints. The surgical plan and acrylic surgical splints generated by conventional planning methods were available as backup during the surgery. At the same time, the process of obtaining 3D images was initiated, in order to develop a 3D treatment plan and manufacture the CAD/CAM surgical splints. The process followed involved: 3D image generation. 3D surgical planning. Designing CAD/CAM Surgical splints. After these steps, in the CAD/CAM Centre the virtual splints (STL files) were exported to a milling machine which milled the surgical splints on polymethyl methacrylate (PMMA), a transparent rigid thermoplastic material.



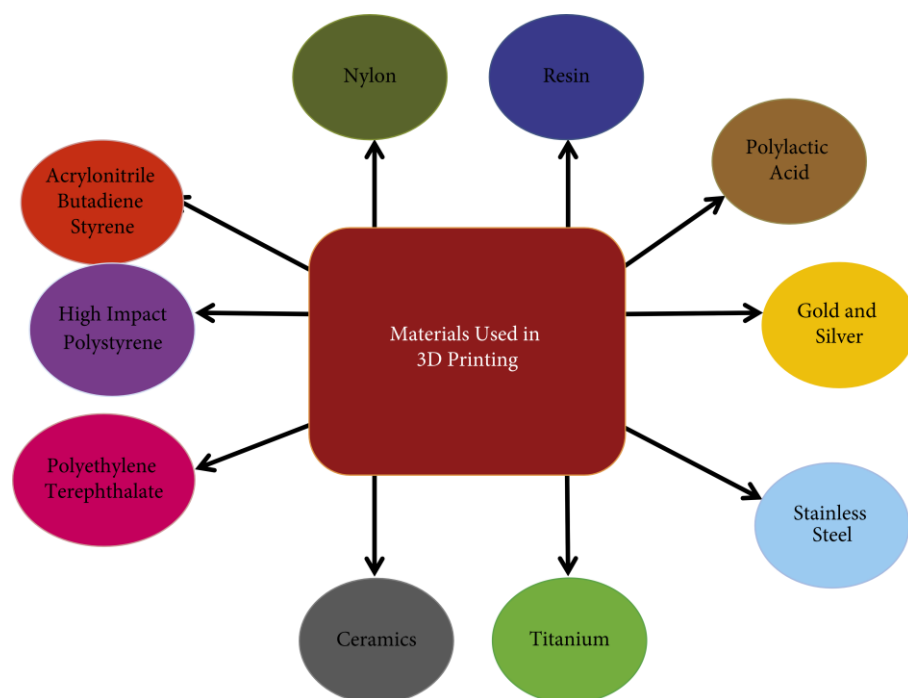
## Three dimensional digital printing

3D printing (or AM) is a procedure of linking materials to create parts from 3D model information, generally layer over layer. The component is designed using the CAD software, which is later sent out to a 3D printer.



## Types of 3D printers

Currently, there are three major kinds of printers; SLA, which uses a beam of laser to cure the photopolymer; DLP (direct light processing), which uses a light projector that projects slides of the 3D object to cure the resin, and MSLA (masked stereolithography), or LCD, which uses a panel of LCDs and a mask in order to allow the light needed to cure the resin.



Types of materials used in 3D printing

## **Powder Bed Fusion (PBF)**

Any powdered material, which can be sintered or fused by laser radiation and solidified by cooling, could be suitable for laser sintering or fusion technologies. PBF is divided into the following printing technologies:

- selective laser melting (SLM),
- selective laser sintering (SLS),
- electron beam melting (EBM),
- and direct metal laser sintering (DMLS)

In dentistry, PBF is used to manufacture all kinds of metal products including AM titanium (Ti) dental implants, custom sub-periosteal Ti implants, custom Ti mesh for bone grafting-techniques, cobalt-chromium (Co-Cr) frames for implant impression procedures, and Co-Cr and Ti frames for dental implant-supported prostheses.

Moreover, PBF shows considerable potential for manufacturing ceramic restorations, which can be used to manufacture frame crowns, model casting abutments, and models.

Operating ambient temperatures of SLS and DMLS do not reach the materials' melting points. The metal powder is partially melted, which results in a large porosity and a rough surface. However, in the SLM process, the powder melts directly at the melting point.

Another technique, electron beam melting (EBM), differs from SLM by using an electron beam to melt the material. Both technologies completely melt the metal powder in an inert build chamber containing purified argon gas.

Ti and its alloys are particularly suitable for 3D printing technologies, particularly SLS. Ceramics can also be used in SLS; however, manufacturing ceramics for dental applications employ an indirect technical measure that relies on polymer bonding to fuse ceramic particles.

The fabrication time based on PBF is also shorter than that of other 3D printing technologies. However, higher heating and cooling rates may lead to thermal shock and rupture. This can be avoided by preheating the powder. SLS-based products can be weak and porous and require complex post-processing.

## **Fused Deposition Modeling**

FDM is one of the most popular and cheap 3D printing technologies in dentistry. The filamentous thermoplastic material is heated and melted by the nozzle. Under the control of the computer, the nozzle and worktable move in the X- and Y-axis directions, respectively, and the material in the molten state is extruded and finally solidified through the accumulation of materials layer-by-layer to form the product. Polylactic acid (PLA), polycarbonate, and polyamide, acrylonitrile-butadiene-styrene copolymers are some of the engineering thermoplastics commonly used for FDM applications.

## **Stereolithography (SLA, SL)**

A stereolithography apparatus uses a scanning laser to build parts one layer at a time, in a vat of light-cured photopolymer resin. Each layer is traced-out by the laser on the surface of the liquid resin, at which point a 'build platform' descends, and another layer of resin is wiped over the surface, and the process repeated.

Supports must be generated in the CAD software, and printed to resist the wiping action and to resist gravity, and must later be removed from the finished product. Postprocessing involves removal of excess resin and a hardening process in a UV oven. The process is costly when used for large objects, but this technology is commonly used for the industrial production of 3D printed implant drill guides.

the first step into this digital workflow is the acquisition of data from intraoral scanners or cone beam computed tomography (CBCT). These data are then turned to standard tessellation language (STL) files and uploaded in a software program for 3D processing and designing of the device of choice.

The next step is the uploading of the digital file on the 3D-printer digital platform, which utilize beams of UV light for the curing of photopolymers, direct light processing (DLP), which uses a light projector that projects slides of the 3D object to cure the resin, and material jetting (MJ). The last step is post-manufacturing modification to ensure the proper construction of the product.

Three dimensional (3D)-printed dental appliances directly from a digital file, such as 3D-printed surgical splints, implant guides and indirect bonding transfer trays or biomedical and pedodontics appliances have been reported.

CAD technology and 3D printing have also introduced new tools and materials for the direct 3D-printing fabrication of either of the two types of retainers. Intraoral scanners produce 3D digital models that so far have many diagnostic and treatment planning applications. The 3D-printed models can also serve as plaster analogues for the thermoforming procedure of plastic retainers; however, directly 3D-printed clear or fixed retainers are not well established in clinical practice.

Post-printing processing usually uses a washing machine where isopropyl alcohol 91% cleans the excess resin after 3D printing and a UV curing unit that cures the uncured part of the printed object. Powder bed fusion (SLS) printers are very big printers using a large laser tube in order to melt, join, or solidify metallic or plastic powder in order to create a 3D object. As mentioned before, those printers cannot be installed in an office. Units for sintering and debinding are needed, together with a gas supply to the printer's chamber (argon), in order to remove oxygen, which creates problems in 3D printing. SLS printers mostly use CoCr powder for manufacturing customized appliances such as space maintainers, lingual arches, and RPEs. Stainless steel and titanium can also be used for printing in SLS printers.

### **Photopolymer jetting (PPJ)**

This technology uses light cured resin materials and print heads rather like those found in an inkjet printer (but considerably more costly), to lay down layers of photopolymer which are light cured with each pass of the print head. A support structure is laid down in a friable support material. A variety of materials may be printed including resins and waxes for casting, as well as some silicone-like rubber materials. Complex geometry and very fine detail is printed.

They are useful for printing dental or anatomical study models, but these are expensive when produced in this way. Implant drill guides may be quickly and cheaply produced with this technology as they are less bulky. A particular advantage of this technology is that the use of multiple print heads allows simultaneous printing with different materials, and graduated mixtures of materials, makes it possible to vary the properties of the printed object, which may for example have flexible and rigid parts, eg for the production of indirect orthodontic bracket splints.

### **Selective laser sintering (SLS)**

A scanning laser fuses a fine material powder, to build up structures layer by layer, as a powder bed drops down incrementally, and a new fine layer of material is evenly spread over the surface. A high (60µm) level of resolution may be obtained, and as the structures that are printed are supported by the surrounding powder, no support material is required.

Polymers used in this process have high melting points (above autoclave sterilization temperature) and excellent material properties, making objects made in this way useful as anatomical study models, cutting and drilling guides, dental models, and for engineering/design prototypes.

The materials are intrinsically dusty, have some health and safety requirements, and are rather messy to work with. Materials available include nylon, which is perhaps the most versatile, flexible elastomeric materials, and metal-containing nylon mixtures.

An interesting possibility for medical implants is the use of polyether ether ketone (PEEK), although this requires high temperatures and complex control – and a great deal of wastage.

### **Fused deposition modelling (FDM)**

FDM is one of the earliest 3D printing technologies. An FDM printer is essentially a robotic glue gun; an extruder either traverses a stationary platform, or a platform moves below a stationary extruder. Objects are ‘sliced’ into layers by the software and coordinates transferred to the printer. Materials must be thermoplastic by definition. A commonly used material is the biodegradable polymer polylactic acid; this or similar materials have been used as key components of scaffold structures used for ‘bioprinting’. Building complex geometries usually necessitates the laying down of support structures which may be either formed from the same material, or from a second material laid down by a second extruder – which, for example, might extrude a water soluble support material. Accuracy will depend upon the speed of travel of the extruder, as well as the flow of material and the size of each ‘step’.

### 3D printing modalities and materials

Techniques	Advantages	Disadvantages
<b>Light cured resin</b>		
1- Stereolithography (SLA) Light sensitive polymer cured layer by layer by a scanning laser in a vat of liquid polymer	Rapid fabrication. Able to create complex shapes with high feature resolution. Lower cost materials if used in bulk.	Only available with light curable liquid polymers. Support materials must be removed. Resin is messy and can cause skin sensitisation, and may be irritant by contact and inhalation. Limited shelf life and vat life. Can not be heat sterilised. High cost technology.
2- Photojet - Light sensitive polymer is jetted onto a build platform from an inkjet type print-head, and cured layer by layer on an incrementally descending platform.	Relatively fast. High-resolution, high-quality finish possible. Multiple materials available various colours and physical properties including elastic materials. Lower cost technology.	Tenacious support material can be difficult to remove completely. Support material may cause skin irritation. Can not be heat sterilised. High cost materials.
3- DLP (digital light processing) Liquid resin is cured layer by layer by a projector light source. The object is built upside down on an incrementally elevating platform.	Good accuracy, smooth surfaces, relatively fast. Lower cost technology.	Light curable liquid polymers and wax-like materials for casting. Support materials must be removed. Resin is messy and can cause skin sensitisation, and may be irritant by contact. Limited shelf life and vat life. Can not be heat sterilised. Higher cost materials.
<b>Powder binder</b>		
Plaster or cementaceous material set by drops of (coloured) water from 'inkjet' print head. Object built layer by layer in a powder bed, on an incrementally descending platform.	Lower cost materials and technology. Can print in colour. Un-set material provides support. Relatively fast process. Safe materials.	Low resolution. Messy powder. Low strength. Can not be soaked or heat sterilised.
<b>Sintered powder</b>		
Selective laser sintering (SLS) for polymers. Object built layer by layer in powder bed. Heated build chamber raises temperature of material to just below melting point. Scanning laser then sinters powder layer by layer in a descending bed.	Range of polymeric materials including nylon, elastomers, and composites. Strong and accurate parts. Self-supported process. Polymeric materials – commonly nylon may be autoclaved. Printed object may have full mechanical functionality. Lower cost materials if used in large volume.	Significant infrastructure required, eg. compressed air, climate control. Messy powders. Lower cost in bulk. Inhalation risk. High cost technology. Rough surface.
Selective laser sintering (SLS) – for metals and metal alloys. Also described as selective laser melting (SLM) or direct metal laser sintering (DMLS). Scanning laser sinters metal powder layer by layer in a cold build chamber as the build platform descends. Support structure used to tether objects to build platform.	High strength objects, can control porosity. Variety of materials including titanium, titanium alloys, cobalt chrome, stainless steel. Metal alloy may be recycled. Fine detail possible.	Elaborate infrastructure requirements. Extremely costly technology moderately costly materials. Dust and nanoparticle condensate may be hazardous to health. Explosive risk. Rough surface. Elaborate post-processing is required: Heat treatment to relieve internal stresses in printed objects. Hard to remove support materials. Relatively slow process.
Electron beam melting (EBM, Arcam). Heated build chamber. Powder sintered layer by layer by scanning electron beam on descending build platform.	High temperature process, so no support or heat treatment needed afterwards. High speed. Dense parts with controlled porosity.	Extremely costly technology moderately costly materials. Dust may be hazardous to health. Explosive risk. Rough surface. Less post-processing required. Lower resolution.
<b>Thermoplastic</b>		
Fused deposition modelling (FDM) First 3DP technology, most used in 'home' printers. Thermoplastic material extruded through nozzle onto build platform.	High porosity. Variable mechanical strength. Low – to mid-range cost materials and equipment. Low accuracy in low cost equipment. Some materials may be heat sterilised.	Low cost but limited materials – only thermoplastics. Limited shape complexity for biological materials. Support material must be removed.