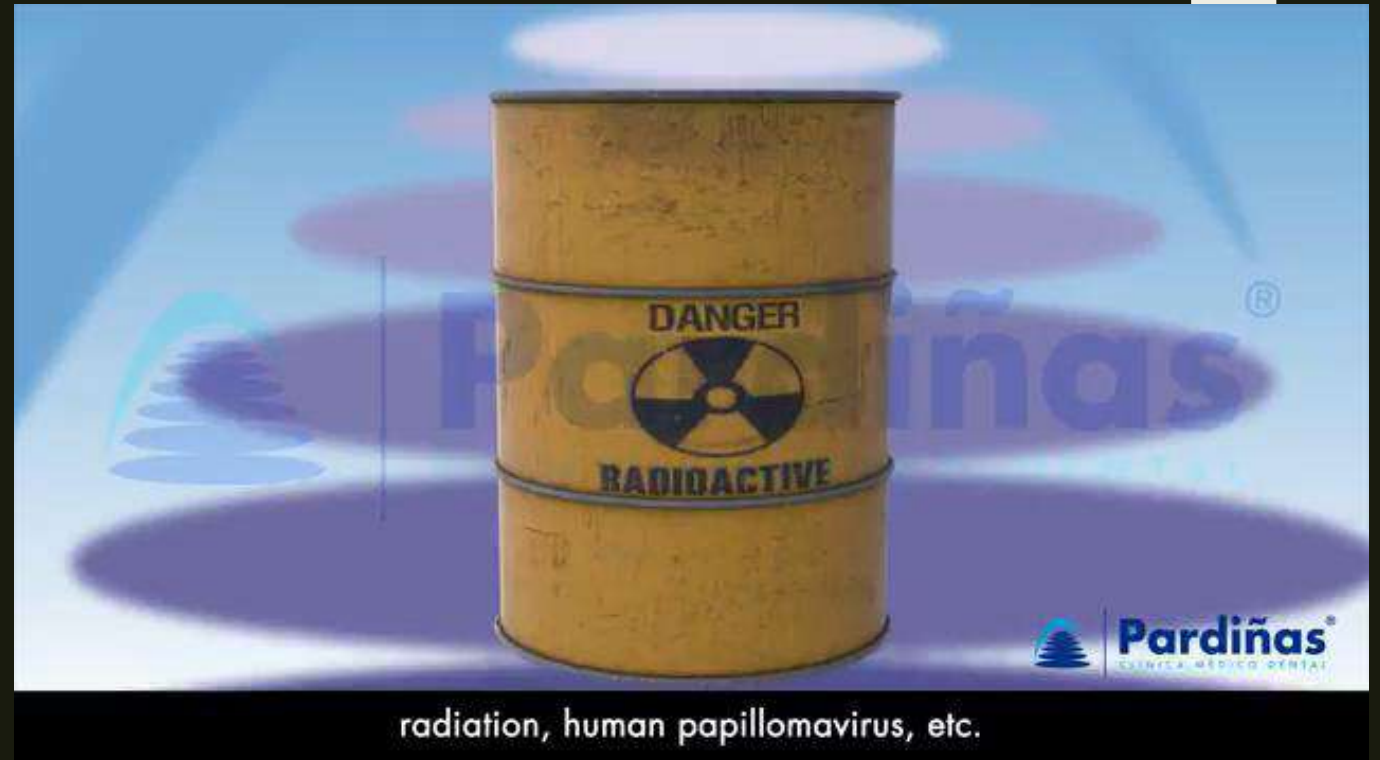
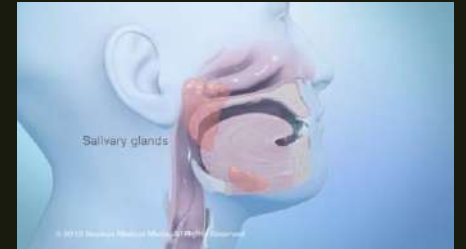
ORAL CANCER

Bashar Abdul-Ghani
FICMS. MaxFacs Cons.
MFDS. RCSEd. RCPS (Glasg).

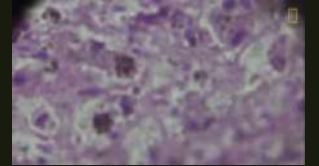




- Oral cancer accounts for less than **3%** of all cancers.
- Squamous cell carcinoma (**SCC**) is the predominant form of oral cancer
- SCC accounts for greater than **90%** of malignant pathology.
- Other forms include **Salivary Gland Tumors, Mesenchymal Tumors, Lymphoma, and Melanoma.**
- Oral cancer is predominantly a disease of older age + 40 years mostly male.



The Natural History of Oral SCC



- The genetic changes caused by exposure to carcinogens like tobacco and alcohol tend to accumulate over time in the entire mucosa exposed to this insult.
- The fundamental regulatory mechanism in carcinogenesis is thought to be the cellular balance between oncogenes and tumor suppressor genes.
- The proto-oncogenes stimulate cell growth and proliferation and are under negative control of the tumor suppressor genes, which prevent overgrowth.
- The most frequently observed molecular abnormality is mutation of the 'p53 tumor suppressor gene' which is seen in 40-70% of malignant lesions and 20% of premalignant lesions.



Etiology

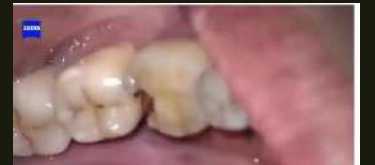

The cause of oral SCC is **multifactorial**. No single causative factor (carcinogen) has been clearly defined or accepted, but both extrinsic and intrinsic factors may be at work.

1- **Tobacco smoking, Smokeless tobacco use, Betel quid** : 2-3 times greater than the general population. The risk of oral SCC is **dose and time dependent**.

Approximately 50% of all oral cancers occur at the site where the tobacco is habitually placed.

2- **Alcohol**: in combination with tobacco is a significant risk factor (**15 times**).



3- **Chronic Irritation**: such as poor oral hygiene and **ill-fitting prostheses**.

4- **Phenolic agents**: increased risk for workers in the wood products industry.



5- **Radiation**: this includes **ultraviolet radiation and X-irradiation**, which reduces immune reactivity and produces chromosomal abnormalities.

6- **Iron deficiency**: especially severe chronic form (**Plummer-Vinson syndrome**). Iron is essential to the normal functioning of epithelial cells of the upper digestive tract.



7- Vitamin A deficiency: producing **excessive keratinization** of the skin and mucous membrane.

8- Syphilis (tertiary stage): have a strong association with the development of dorsal tongue CA.

9- **Candidal infection**: **Candidal Leukoplakia** is considered a precancerous condition.

10- **Oncogenic viruses**: **Human Papilloma Virus** is implicated in oral cancer development.

11- **Immunosuppression**



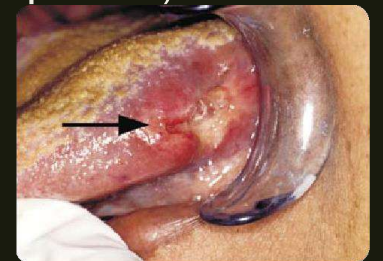
12- Oncogenes and Tumor suppressor genes: which are chromosomal components capable of being acted on by a variety of causative agents.

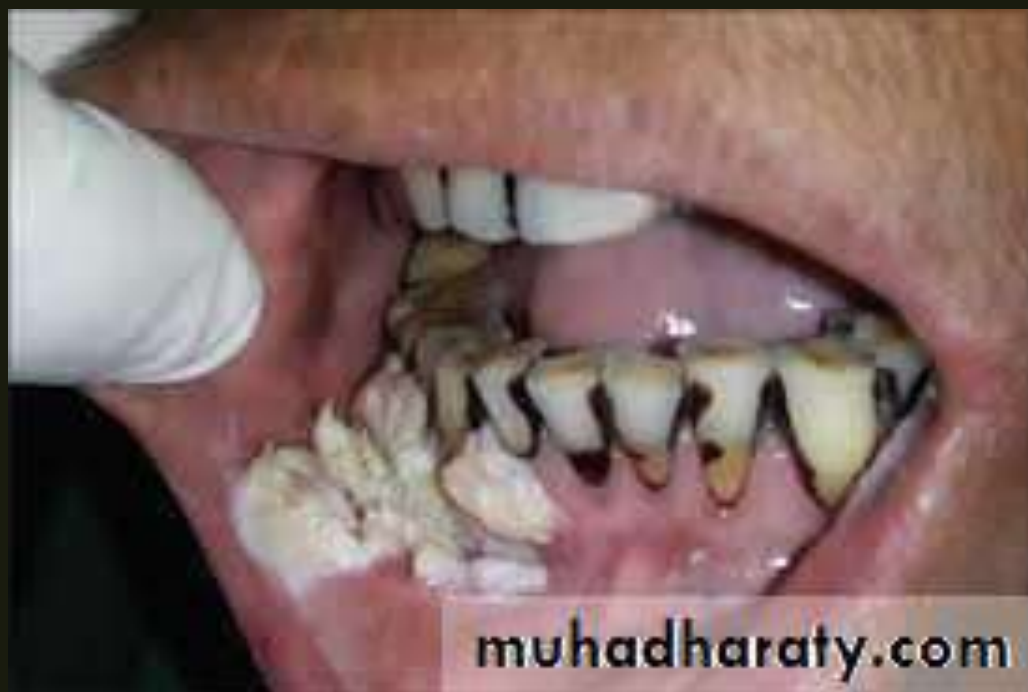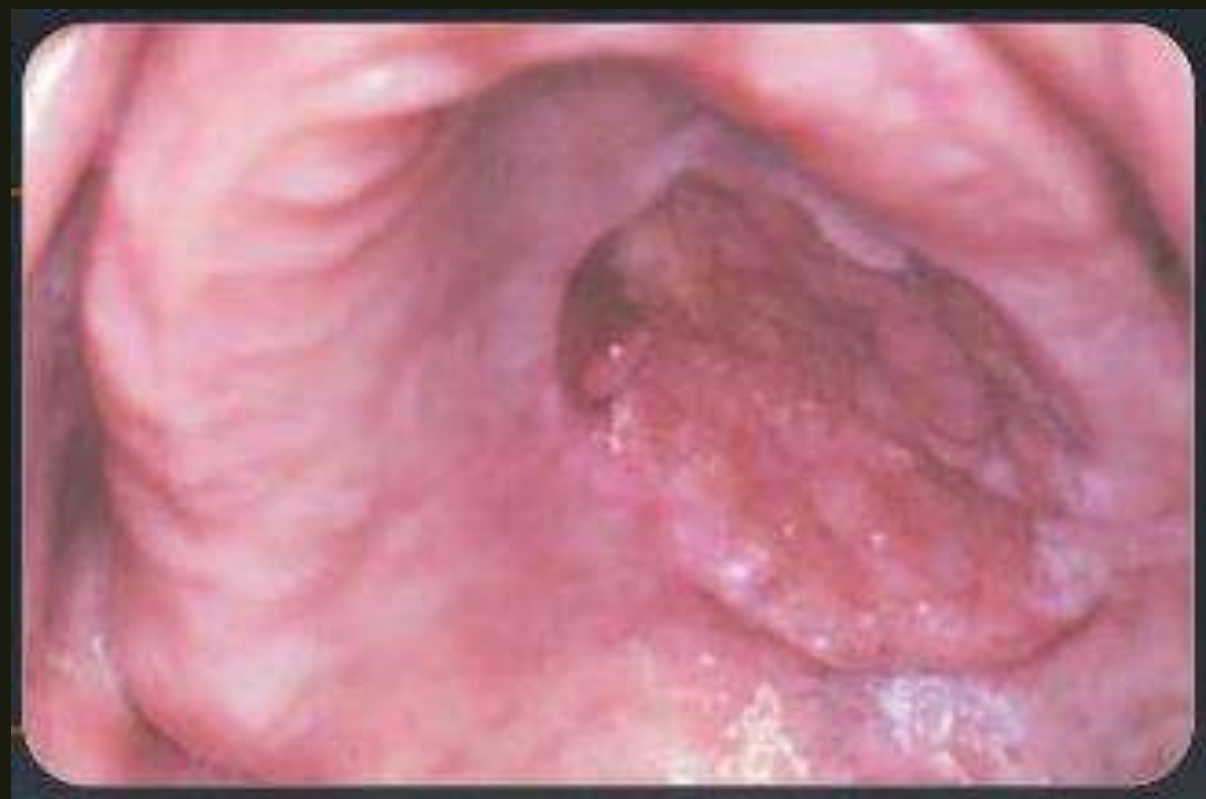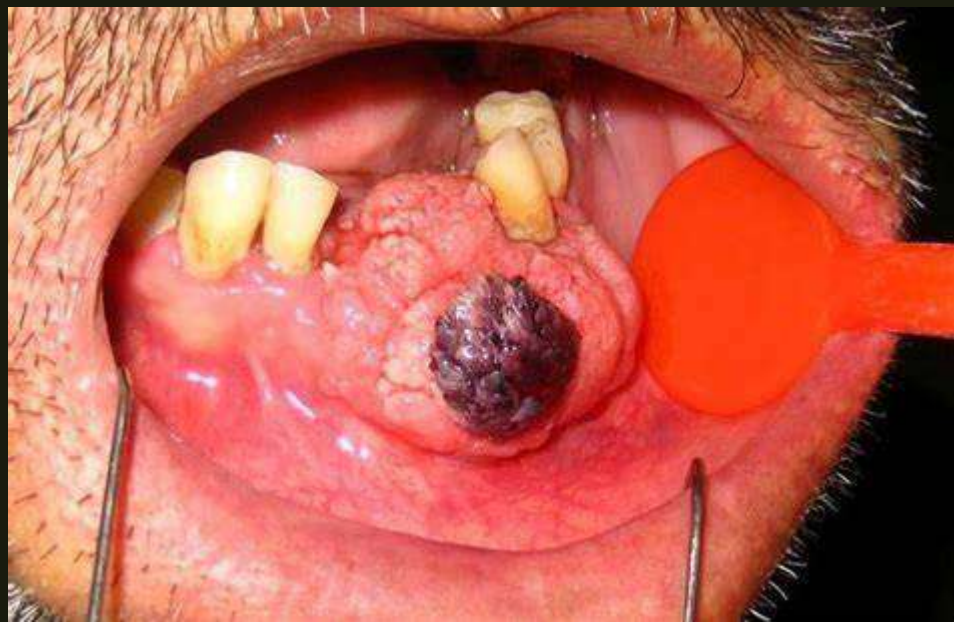Site Distribution

- Most oral cancers occur in mucosa where saliva pools due to gravity exposing it to salivary carcinogens.
- The site distribution of oral SCC is varied but the general trend is as follows:
 - Tongue → 35% (31% lateral border, 2% tip and 2% dorsum).
 - Floor of mouth → 30% (25% anterior and 5% posterior).
 - Lower alveolus → 15%. - Buccal mucosa → 10%. - Upper alveolus → 5%.
 - Hard palate → 3%. - Retromolar trigone → 2%.
- The distribution of oral cancer in developing countries is different and may be explained by certain habits peculiar to that population.

Clinical Presentation

- Large number of **oral CA present late** because of the painless and vague nature of the symptoms.
- The **Clinical Manifestation** is varied including:
- **Exophytic or mass forming lesion** : the surface is irregular, fungating, papillary, or verruciform. color vary from normal to red to white, depending on the amount of keratin and vascularity. and the tumor is **indurated on palpation**.
- **Endophytic growth** pattern which has a depressed, irregularly shaped, **ulcerated central area with a surrounding rolled border** of normal, red or white mucosa, with **induration of the underlying tissues**.
- **Leukoplakic, Erythroplakic or combined Erythroleukoplakic** lesions (speckled leukoplakia) which has a high incidence of malignant transformation.





Symptoms (Vague Nature of the symptoms)

- Pain (lesions in the tongue).
- Difficulty in swallowing or speaking (when spreads to floor of the mouth).
- Pain while chewing,
- Intermittent bleeding,
- Loose teeth or ill-fitting dentures (as in gingival or alveolar ridge lesions).
- Trismus or altered sensation or anesthesia of the lower lip (signify locally advanced disease).

Clinical Staging

TNM system

- T - Tumor size.
- N - Nodal status in the cervical region.
- M - Metastatic disease beyond the cervical lymph nodes.

As a general rule, **More Advanced Stage Implies a Worse Prognosis.**

- **Initial Staging** is performed by using all available **clinical** and **radiographic** data (**cTNM**).
- **Final Staging** incorporates **histopathologic** data if surgery is performed (**pTNM**).

Definition of Primary Tumor (T)

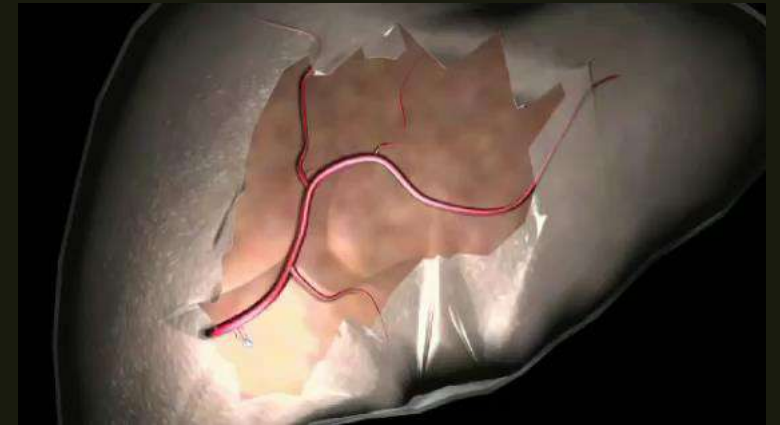
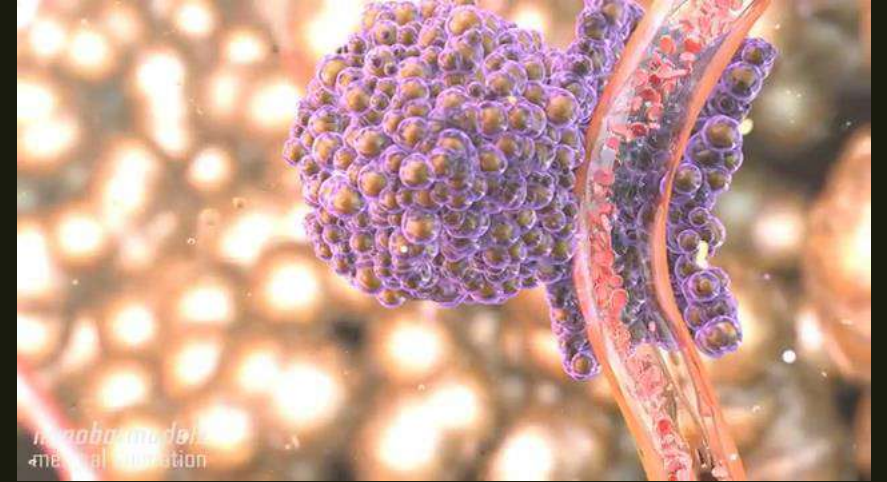
T	T CRITERIA
CATEGORY	
TX	Primary tumor cannot be assessed
Tis	Carcinoma in situ
T1	Tumor < 2 cm , < 5 mm depth of invasion (DOI) DOI is depth of invasion and not tumor thickness.
T2	Tumor < 2 cm, DOI > 5 mm and < 10 mm or tumor > 2 cm but < 4 cm, and < 10 mm DOI
T3	Tumor > 4 cm or any tumor > 10 mm DOI
T4a	Moderately advanced local disease (Lip) Tumor invades through cortical bone or involves the inferior alveolar nerve, floor of mouth, or skin of face (i.e., chin or nose) (Oral cavity) Tumor invades adjacent structures only (e.g., through cortical bone of the mandible or maxilla, or involves the maxillary sinus or skin of the face) Note: Superficial erosion of bone/tooth socket (alone) by a gingival primary is not sufficient to classify a tumor as T4.
T4b	Very advanced local disease Tumor invades masticator space, pterygoid plates, or skull base and/or encases the internal carotid artery

Definition of Regional Lymph Node (N)

N Category	N Criteria
NX	Regional lymph nodes cannot be assessed
N0	No regional lymph node metastasis
N1	Metastasis in a single ipsilateral lymph node, 3 cm or smaller in greatest dimension ENE(-)
N2a	Metastasis in a single ipsilateral node larger than 3 cm but not larger than 6 cm in greatest dimension, and ENE(-)
N2b	Metastasis in multiple ipsilateral nodes, none larger than 6 cm in greatest dimension, and ENE(-)
N2c	Metastasis in bilateral or contralateral lymph nodes, none larger than 6 cm in greatest dimension, and ENE(-)
N3a	Metastasis in a lymph node larger than 6 cm in greatest dimension and ENE(-)
N3b	Metastasis in any node(s) and clinically overt ENE(+)

Distant Metastasis (M)

- **M0** - No Distant Metastasis
- **M1** - Distant Metastasis



AJCC prognostic stage groups

When T is...	And N is...	And M is...	Then the stage group is...
T1	N0	M0	I
T2	N0	M0	II
T3	N0	M0	III
T1, T2, T3	N1	M0	III
T4a	N0, N1	M0	IVA
T1, T2, T3 T4a	N2	M0	IVA
Any T	N3	M0	IVB
T4b	Any N	M0	IVB
Any T	Any N	M1	IVC

Grading

- Histopathologic grading of SCC is based upon the degree of differentiation and resemblance to normal squamous epithelium and the amount of keratin production. It consists of 3 grades:
 - **Grade 1 (Well Differentiated)** - Low-Grade Tumor
 - **Grade 2 (Moderately Differentiated)**
 - **Grade 3 (Poorly Differentiated)** - High-Grade Tumor

Physical Examination

During examination the following points should be considered:

- Tumor's location, size, and relationship to adjacent anatomic structures.
- Fixation to the jaw.
- Proximity to the midline.
- Trismus or decreased tongue mobility may be an indication of invasion into deeper structures.
- Cranial nerve deficits suggest tumor involvement (Perineural Invasion)
- The status of the dentition assessed before radiation therapy (risk for xerostomia-related caries and osteoradionecrosis).
- Biopsy of the primary tumor is required for histologic diagnosis and treatment planning.
- Lymph nodes in the neck palpated carefully to assess local metastasis.
- Identify distant sites that may be used for reconstructive purposes.



Radiographic Assessment

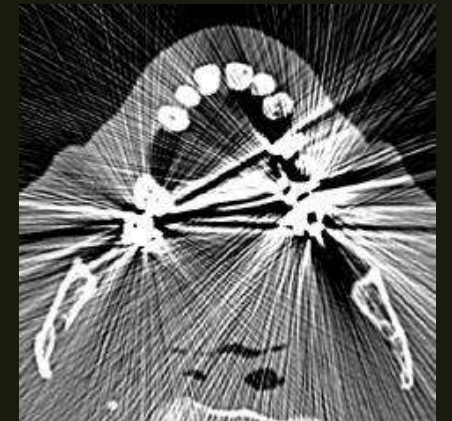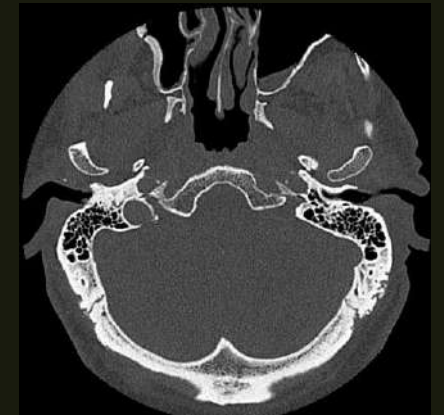Pre-treatment Imaging is important to evaluate:

- The tumor **size and extent**.
- Involvement of **adjacent anatomic** structures.
- **Staging the cervical lymph nodes**.
- **Tumor invasion** for the bone especially the mandible.

The modalities used include:

■ Computed Tomography (CT)

- The **most common imaging** modality used.
- The **Main Advantages** are: excellent bone detail, adequate soft tissue enhancement, and relatively low cost and availability.
- The **Main Disadvantages** include; ionizing radiation, artifacts created by metallic dental restorations.



Magnetic Resonance Imaging

- **Advantages:** superior **soft tissue** details and **lack of ionizing radiation**.
- **Disadvantages;** more sensitive to motion artifacts, expensive, difficult for patients with **claustrophobia**, and it is contraindicated in patient with pacemaker.

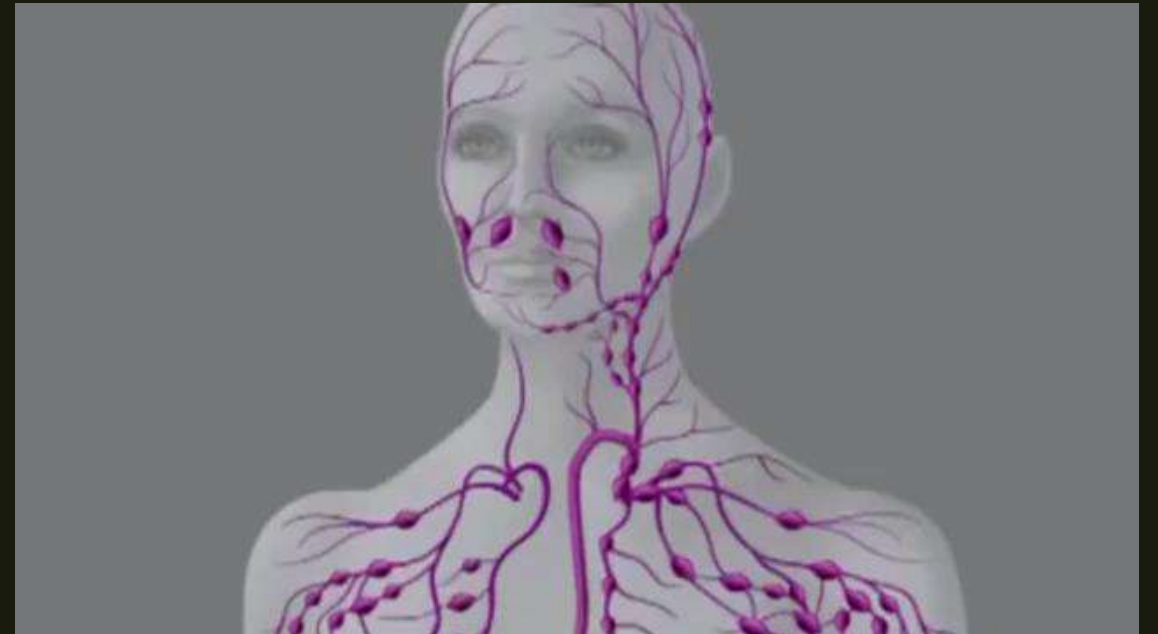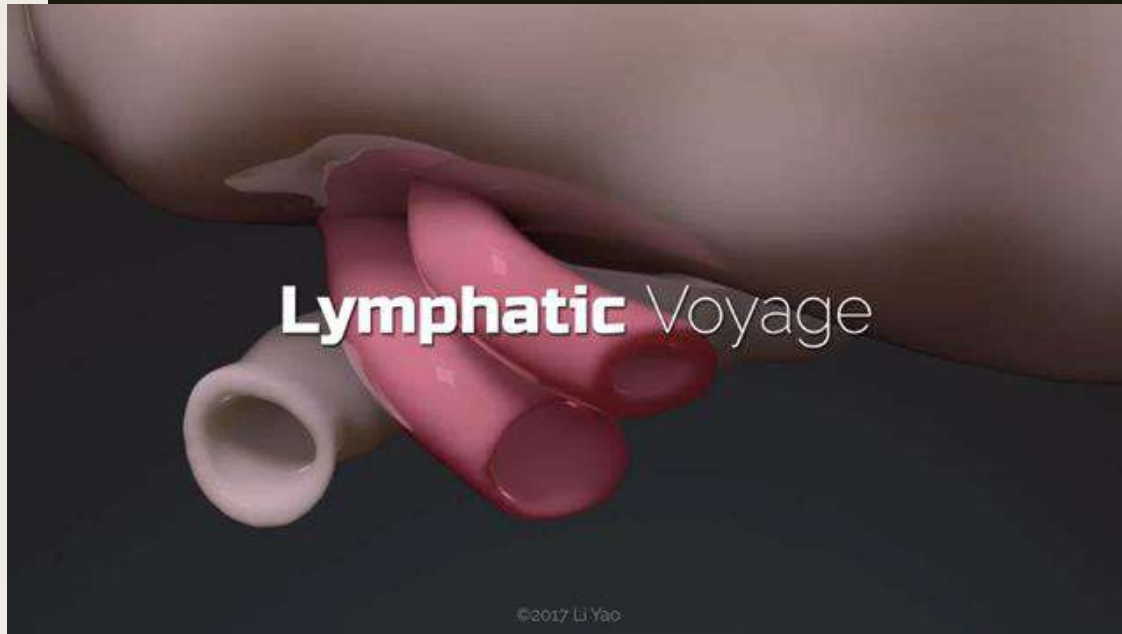Ultrasound

- **Advantages:** quick, inexpensive, non-invasive, lymph nodes sampled under ultrasound guidance.
- **Disadvantages;** limited utility in the oral cavity, bone does not transmit sound, it is highly technique sensitive, and **Operator Dependent**.

Positron Emission Tomography (PET)

- Functional imaging with **^{18}F -fluorodeoxyglucose PET** has been shown to be an effective tool in the diagnosis of head and neck cancer.
- **The integration of PET and CT technology is more accurate than either modality alone** in the description of head and neck malignancies.


Lymphatic System



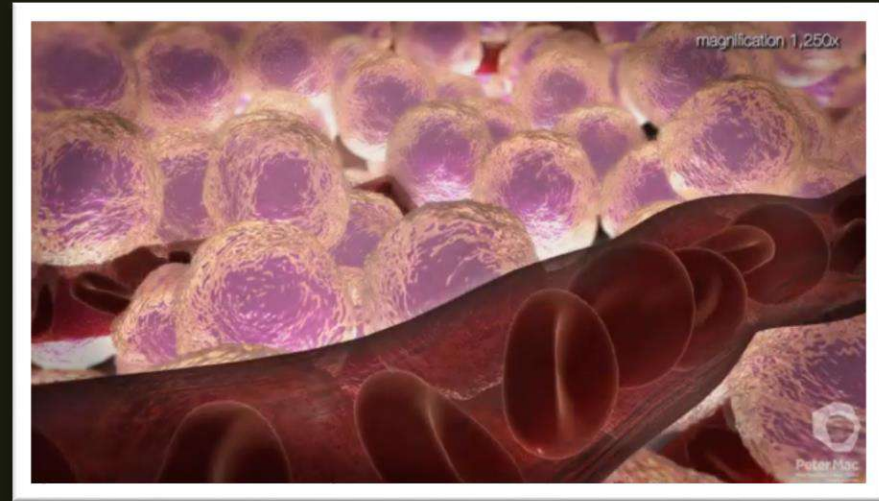

Risk of Smoking



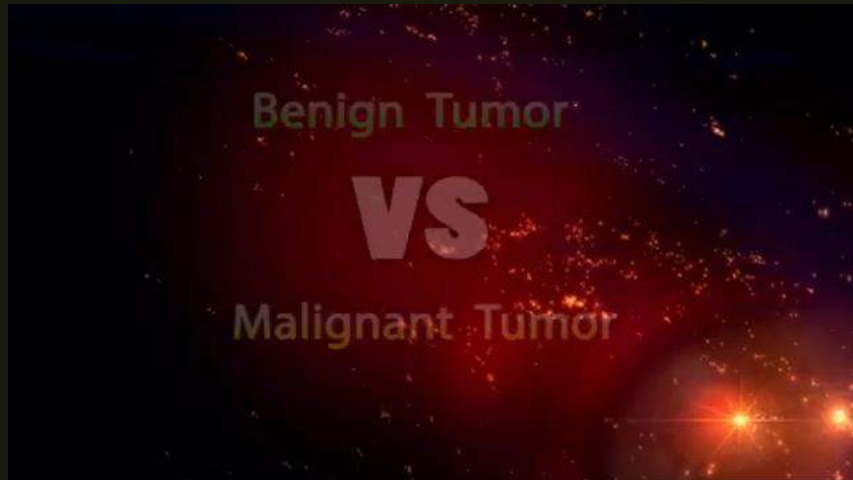Biology of Cancer



CANCER
RESEARCH
UK



Benign and Malignant



SCC




Metastasis

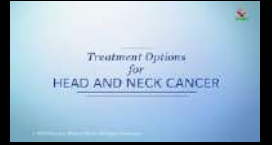

ORAL CANCER - TREATMENT

Bashar Abdul-Ghani
FICMS. MaxFacs Cons.
MFDS. RCSEd. RCPS (Glasg).




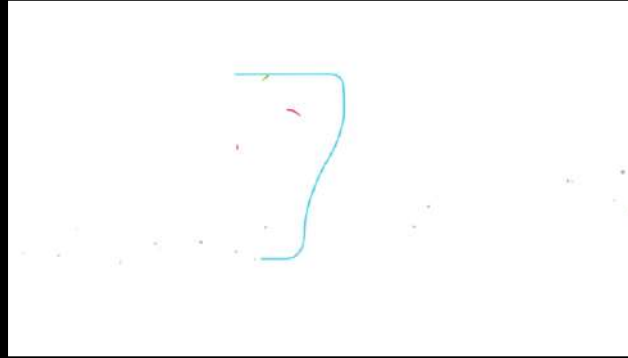
The main modalities of treatment are **Surgery, Radiotherapy and Chemotherapy**



- (others: Immunotherapy, Photodynamic Therapy, Targeted, and Laser).
- Small, superficial tumor (T1) equally cured by surgical resection or radiotherapy, **Surgery is the preferred treatment.**
- In advanced stage (T3 and T4) combining surgery with postoperative radiotherapy.

Surgical Treatment

- **Surgical excision is a loco-regional treatment.** It allows histopathological assessment of the clearance margins.
- The excision should include at least **1 cm of adjacent normal tissues** as safe margin.



Access to the Oral Cavity - The main surgical approaches are

- Peroral (Transoral)
 - Mandibulotomy,
 - Lower Cheek Flap Approach,
 - Visor Flap Approach,
 - Upper Cheek Flap Approach.
- Maxillary Resection Procedures
 - Partial Maxillectomy
 - Medial Maxillectomy
 - Subtotal Maxillectomy
 - Midfacial Degloving Flap
 - Total Maxillectomy
 - Radical Maxillectomy with Orbital Exentration
 - Anterior Craniofacial Resection

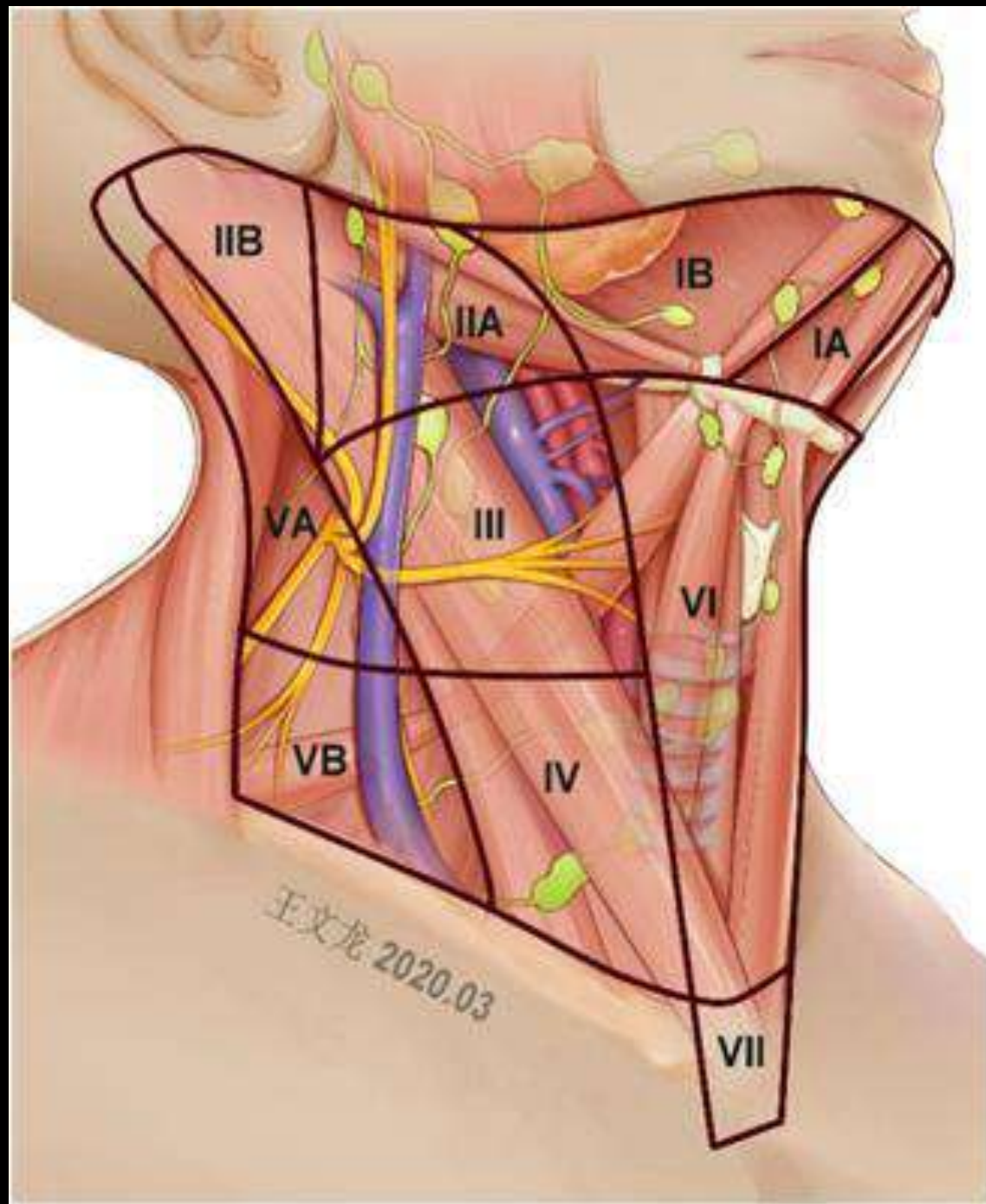
Management of the Neck (L.N. metastasis)

- The status of the cervical lymph nodes is the **most important prognostic factor in SCC**
- Survival rate decreases by **50%** in patients with LN metastases.
- The head and neck drain into an extensive network of cervical lymphatics.

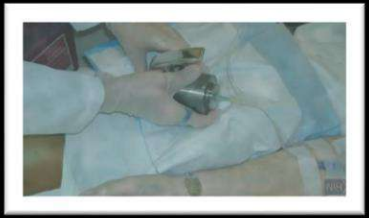Anatomy and Biology of Lymphatic Metastasis

- Cervical lymph nodes are categorized into **five nodal levels**, and additionally levels VI and VII represent central compartment and superior mediastinal nodes.
- For primary tumors, the regional LN at **highest risk for early dissemination are limited to levels I, II, and III.**





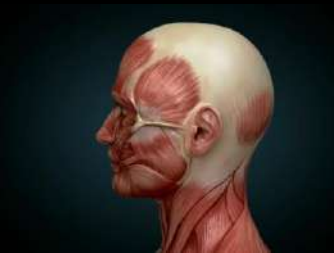Clinical Evaluation and Diagnostic Imaging



- Imaging modalities include **ultrasonography, CT, and MRI scans, and PET scans.**
- Although the presence of metastatic LN is a **histologic**, but **CT and MRI may be suggestive for metastatic LN** (Poorly circumscribed margins. Central necrosis. Nodal size + 1 cm).
- Lymph node size greater than 1 cm in diameter **does not automatically mean metastatic** cancer, **because** reactive lymphadenopathy following infection, inflammation, or surgical intervention may result in lymph nodes of such size.

Classification of Neck Dissection

- Radical Neck Dissection (RND) involves the en bloc removal of all ipsilateral lymph nodes, ipsilateral accessory nerve, internal jugular vein, and sternocleidomastoid muscle.
- Modified Radical Neck Dissection (MRND)
- Selective Neck Dissection (SND)
- Extended Neck Dissection



Subclassification into “Therapeutic” and “Elective” Neck Dissection

- “Therapeutic” neck dissection is used when cervical metastases are detected preop.
- “Prophylactic” or preferably “elective” neck dissection is used for patients who clinically have no enlarged LN.

- Studies have demonstrated that occult metastasis occurs in 20-45% of patients who were **clinically staged as N0** , So better to perform Elective (Prophylactic) Neck Dissection (END)

Prognostic variables of nodal metastasis

- Primary site.
- Peri-neural invasion.
- Lympho-vascular invasion.
- Histopathologic grading.

Postoperative follow up

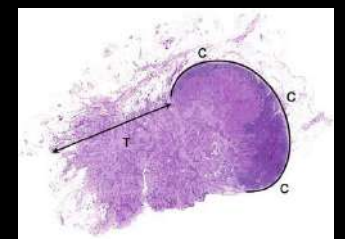
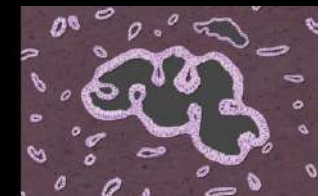
Postoperative visit	Examination schedule
0-3 months	Biweekly examination
3-12 months	Monthly examination
1-2 years	Examination every 2 months
2-4 years	Examination every 4 months
4-5 years	Examination every 6 months

Radiotherapy - Ionizing Radiation.

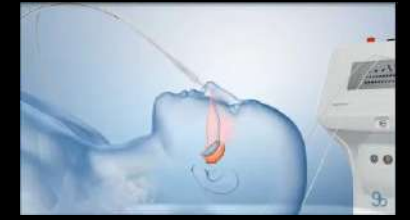

- It is loco- regional treatment, considered as complementary to surgery rather than competitive.
- Radiotherapy can be used as a definitive treatment or combined with other modalities, surgery or chemotherapy.
- The Basic Principle is to achieve high dose in the tumor while minimizing the dose to the normal tissues, this is difficult in the head and neck because:
 1. SCC is less sensitive to radiation, so require higher dose.
 2. The proximity of critically radiosensitive organs like the eyes and the brainstem.

- Preoperative radiotherapy is infrequently used.
- Postoperative radiotherapy - It should start no later than **6 weeks after surgery**.
- Its **indications** are:
 - **Absolute indications** are involved **(positive) margins** at the primary tumor resection site and **extracapsular spread of involved** lymph nodes.
 - **Near absolute indications** include close (less than 5 mm) margins, **two or more involved** cervical lymph nodes and **invasion of the soft tissues** of the neck.
 - **The relative indications** include the presence of **lymphovascular space invasion** and **perineural invasion**.



Techniques of Radiotherapy

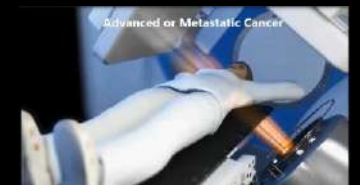


1 - Brachytherapy (Internal Radiotherapy)

- Brachytherapy describes the situation in which radioactive sources are brought close to the tumor mass (or even implanted within it) to deliver a highly localized radiation dose,
- it uses radioactive isotopes e.g., Radium, Iridium or Radon.

2 - Conventional (External Beam or Teletherapy) Radiotherapy

- Beam of radiation is directed toward the tumor bearing part of the patient who is a distance away.
- It uses photons (like X-rays or Gamma rays) or particles like protons.




3 - 3D Conformal Radiotherapy

- CT scan is taken, then Data from these scans provide the radiation oncologist with precise anatomical and electron density data on tumor and normal tissues.

4 - Intensity Modulated Radiotherapy (IMRT)

- IMRT uses computer to vary the shape and intensity of radiation delivered to different parts of the treatment volume.



Fractionation of Radiotherapy

- Since the maximum radiation in a single dose is limited by the normal tissue tolerance, the total dose is divided into a number of small doses (fractions):
 - **Conventional:** 65 Gy (Gray) is given in extended treatment course of 2 Gy × 30 fractions for 42 days (conventional).
 - **Hyperfractionation:** when the number of fractions is increased beyond the conventional levels, so the ratio of dose/fraction is reduced.
 - **Acceleration:** is reduction in overall treatment time.
 - **Continuous hyperfractionated accelerated radiation therapy :** 12 days, 3 fractions/ day.
 - **Split courses:** designed to reduce the severity of mucosal reaction, so the radiotherapy course is divided into 2 halves separated by 2 weeks.

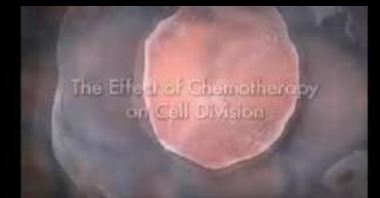

Chemotherapy

- Used in combination with radiotherapy and/or surgery or **alone in palliative treatment**.

Classes of chemotherapeutic agents: In general, **they are grouped as:**

- **Antimetabolites;** It includes: methotrexate, 5-fluorouracil (5-FU), cytarabine.
- **DNA damaging agents;** these include:
 - Alkylating agents like cyclophosphamide.
 - Antibiotics like mitomycin, actinomycin D and bleomycin.
 - Platinum derivatives like cisplatin and carboplatin.
- **Mitosis inhibitors;** includes vinca alkaloids and taxanes.
- **Cancer cell enzyme inactivators;** e.g., Tyrosine kinase inhibitors such as Imatinib.



Scheduling of Chemotherapy

- Before radiotherapy (Neoadjuvant or Induction).
- During radiotherapy (Synchronous or Concomitant).
- After radiotherapy (Adjuvant or Subsequent).

Response rate of Chemotherapy as a **single agent** is (40%) or **in combination** (75%).

- **Adjuvant chemotherapy is not a routine management in head and neck SCC.**
- Chemotherapy is also considered in patients with **significant symptoms due to advanced or recurrent tumors** only to improve symptoms with short lived benefit.

Concomitant Chemoradiation

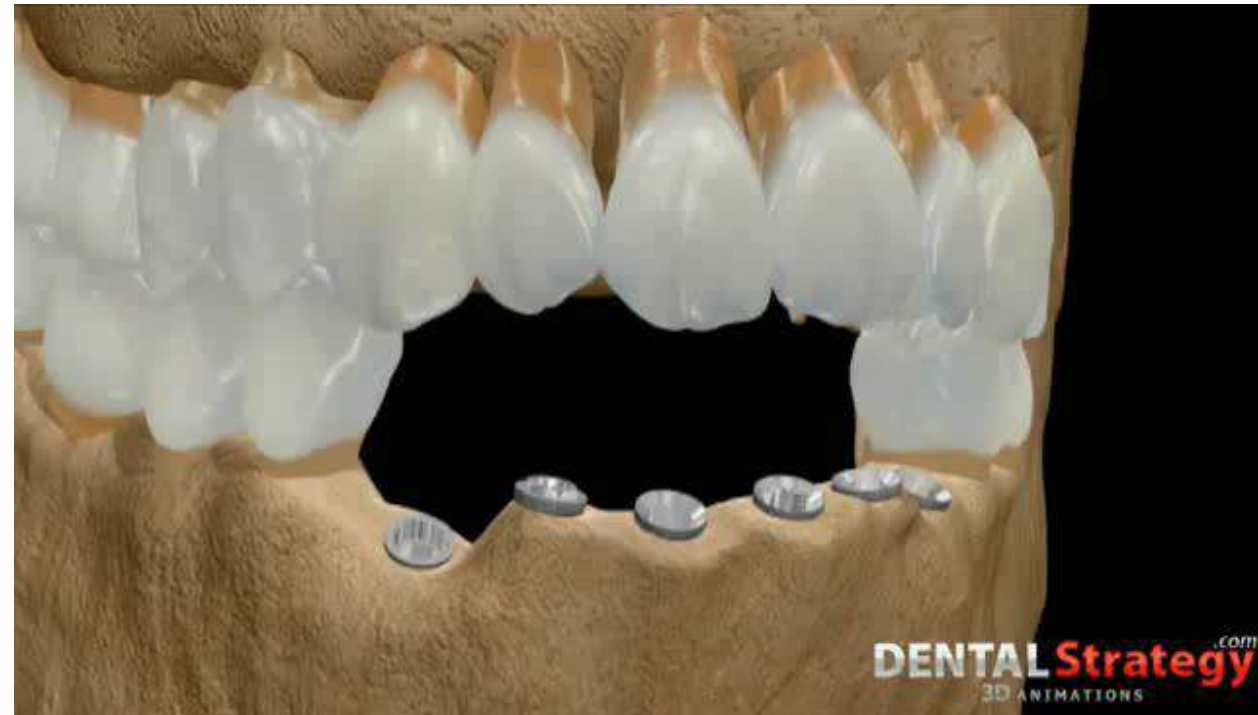
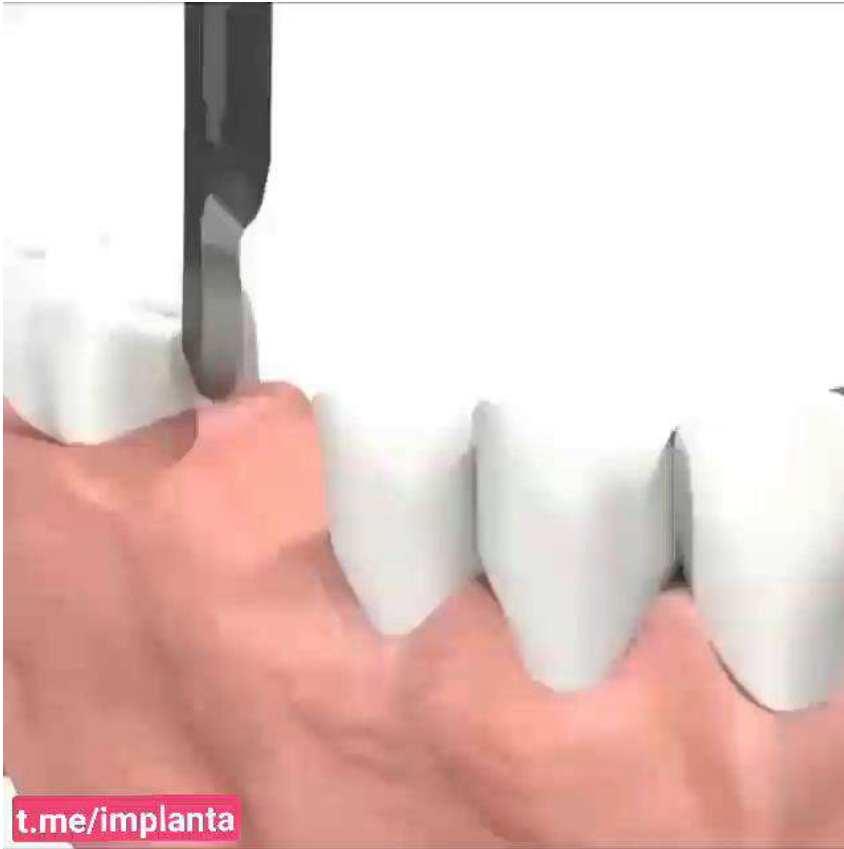
- Use of concomitant chemo-radiotherapy is based on a belief **that chemotherapy synergistically acts with radiotherapy** by:
- **Inhibiting repair of DNA damage** caused by radiotherapy, **arresting cells in radiosensitive phases** and possibly **preventing regrowth** between radiotherapy treatments.
- Chemotherapy may **treat radio-resistant tumor**.
- The **addition of chemotherapy to radiotherapy** shown to be superior to **radiotherapy alone** for **locoregional control and survival in head and neck SCC**

Palliative treatment and terminal care

- The treatment may progress to palliative and finally to terminal care which is a right to every patient and duty of every health professional.
- The aim of terminal care is to Make the patient free of pain, Mobile, Sufficiently alert.
- It is usually home care or in the hospital.

Implant Surgical Procedures



Bashar Abdul-Ghani
FICMS. MaxFacs Cons. MFDS. RCSEd. RCPS (Glasg).

Implant Components



Implant Body or Fixture

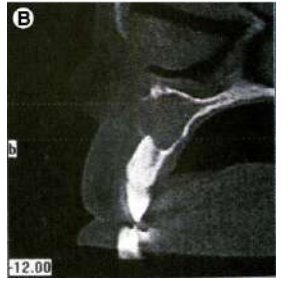
- it is the component placed within bone during the first stage of surgery.
- **Most fixtures are referred to as root form implants**, made of titanium or titanium alloy.
- A wide variety of external thread designs and different surface textures and coatings that attempt to maximize implant stability and the process of osseointegration.
- Most implant fixtures incorporate an antirotational design feature (Hex) at the interface of the adjoining prosthetic components.
- This antirotational feature may be located internally or externally to the implant platform.



Basic Implant Surgical Procedures

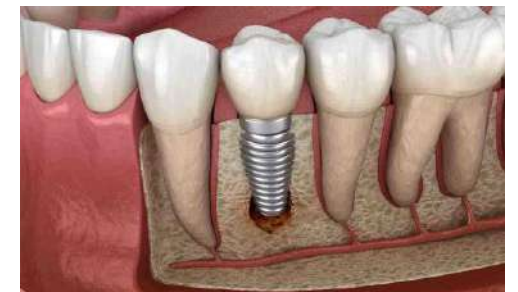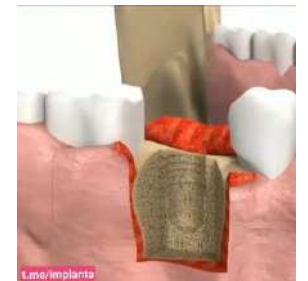
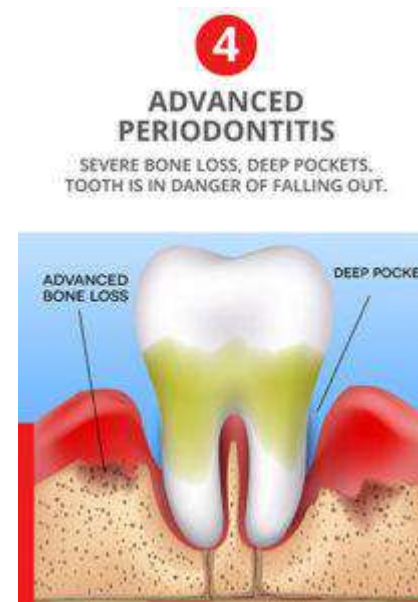
- Preparation for implant surgery requires a thorough review of the patient's chart, Radiographs, expected implant sizes and locations, surgical guides, possible complications, anesthesia, operating time, postoperative management, and Restorative Plan.
- Patient draped in a sterile fashion and the surgical team has been gloved and gowned
- Patient anesthetized, using local anesthetic block or infiltration techniques.
- For complex procedures, Sedation or General Anesthesia preferred.

- The surgical site should be kept aseptic.
- Mouth rinsing with chlorhexidine for 1-2 min before the procedure
- Every effort made to avoid contamination of the implant surface.
- Implant sites prepared using Gentle, Atraumatic Surgical Techniques to avoid overheating the bone.



To achieve osseointegration, the implant must be

- Placed in healthy bone
- Good primary stability
- Atraumatic technique.

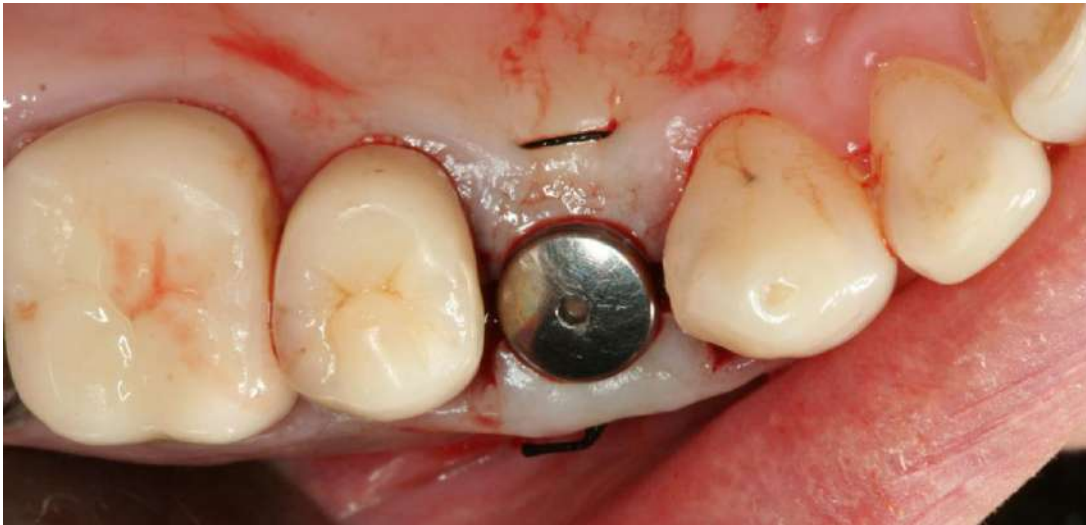

- Successful osseointegration occurs when true clinical guidelines are followed.
- Drilling without adequate cooling generates excessive heat, which increases the risk of failure.
- The Bone Quality (Compact versus Trabecular) influences the Bone - Implant Interface.
- The best results achieved when Bone-Implant Contact is intimate at time of implant placement.
- After initial bone remodeling in the first year (1-1.5 mm of Resorption “Normal Remodeling”).
- The average annual crestal bone loss after the first year in function is expected to be 0.1 mm or less.

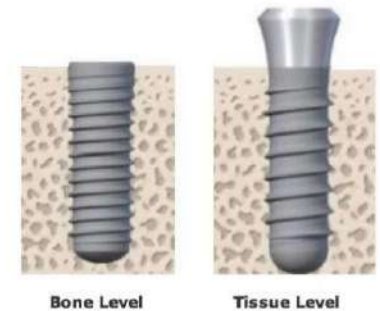


One-Stage versus Two-Stage Implant Placement Surgery

- Implants placed using either a one-stage (Tissue Level, Non-submerged) or a two-stage (Bone Level, Submerged) surgery.
- Implants are allowed to heal, without loading or micromovement.
- In two-stage implant surgery, the implant is surgically exposed following a healing period.

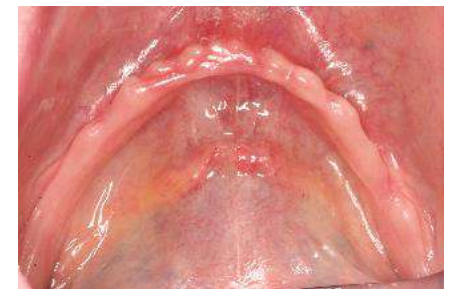

- Submerged
- Non-submerged

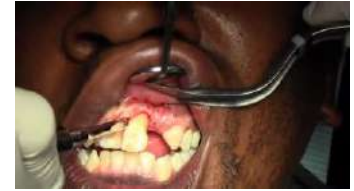

Implant Site Exposure

- Exposure of the implant site either with Flap (tissue elevation) or Flapless surgery.
- Flapless surgery may be indicated when there is adequate keratinized tissue over an ideal ridge form.
- This creates the least soft tissue trauma and may provide the best postoperative esthetics.
- When a flap is required for better access of the bone and when additional procedures such as bone or soft tissue grafting are done at the time of implant placement.

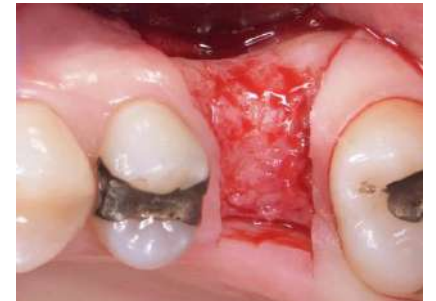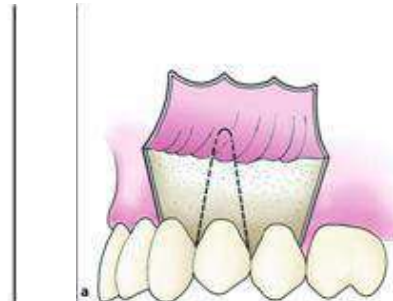
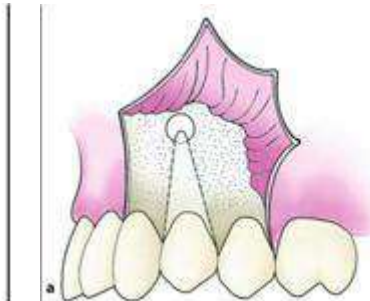

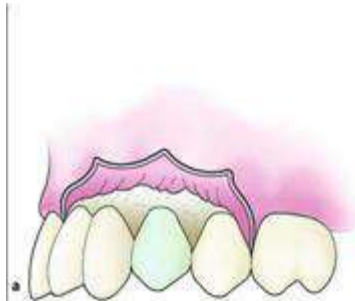
Implant Placement



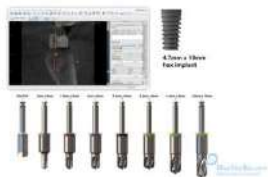
Flap Reflection

- Reflection at the papilla is initiated with a periosteal elevator, using gentle, well-directed, controlled pressure.
- Once the buccal flap is reflected, the palatal or lingual flap can be reflected enough to visualize the width of the ridge.
- It is extremely important to avoid inadvertent trauma to the flap with the tip of the retractors.

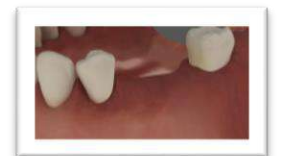

Preparing the Osteotomy

- The surgeon must confirm that the handpiece and motor are functioning properly:
- **Speed setting on the motor checked (800 -1500 rpm);** and drill is spinning in the forward mode.
- All drills copiously irrigated internally, externally, or both.
- The depth indicator markings on the precision and pilot drills should always be reviewed.
- The entry point and its ideal angulation determined with the Precision (First) Drill, (penetration)
- **The proper angulation verified from different points.**
- A surgical guide is usually used to facilitate orientation.




- Pilot drill - run in the same position and angulation to the intended depth of the implant (e.g., 10 mm deep for a 10-mm implant).
- Guide Pin - allows the surgeon to evaluate the position, spacing, and angulation of the developing osteotomy.
- Twist Drill - that corresponds to the intended platform position of the implant to the ridge. It run at full speed in a gentle pumping motion.
- Bone accumulated on the drill, either collected on a wet gauze to be used as autogenous graft around the implant bony defect or cleaned and removed.
- The site is sequentially prepared in this manner.
- The tip of the final twist drill will finalizes the osteotomy.




Inserting Implant

- The speed of the motor is changed to the recommended torque (around 30 Ncm)
- The implant is opened and placed on the handpiece driver.
- The implant is driven into position by keeping light pressure in an apical direction until the implant is almost completely seated or until the motor torques out.
- With hand torque wrench, the surgeon continues to seat the implant.
- The seating of the implant is finalized by verifying that the platform is even with the mesial and distal heights of bone.
- An implant with a torque value of 35 Ncm or greater is considered to have good primary stability, and single-stage healing is possible.
- For one-stage surgery, healing abutment (gingival former) is placed, while in two-stage surgery, cover screw is placed.
- The flap is sutured by resorbable suture (Vicryl) or non-resorbable suture (silk or proline).



Drilling

Operating System



Package



Step By Step

Postoperative Management

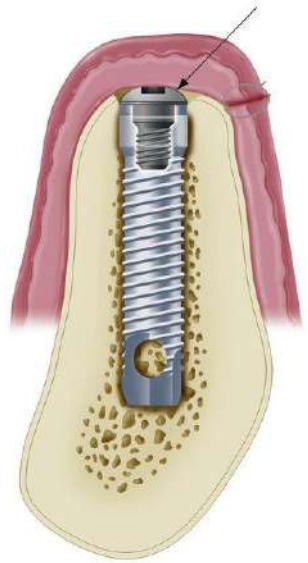
- Better to take a radiograph to evaluate implant position in relation to maxillary sinus and inferior alveolar canal.
- Patients given analgesics (avoid NSAIDs) and Prophylactic Antibiotics.
- Use 0.12% chlorhexidine gluconate rinses for 7 - 10 days.
- The patient is evaluated until soft tissue wound healing is complete.
- If the patient wears a denture, the denture can be relined with a soft liner after 1 week.
- Partial dentures or orthodontic retainers worn immediately but must be contoured to avoid soft tissue loading over the implant site.

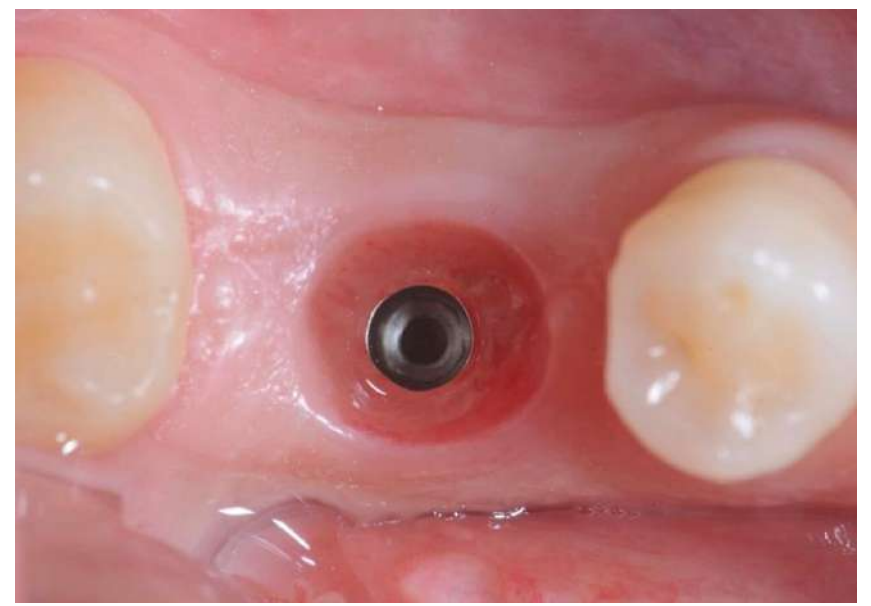
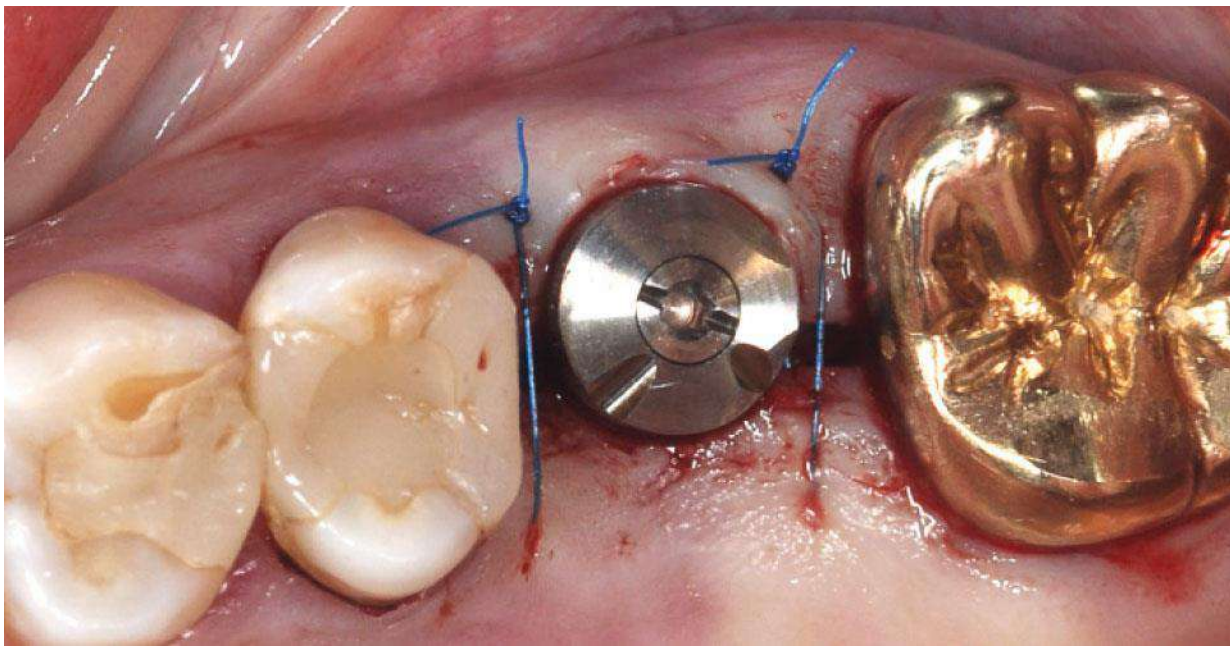
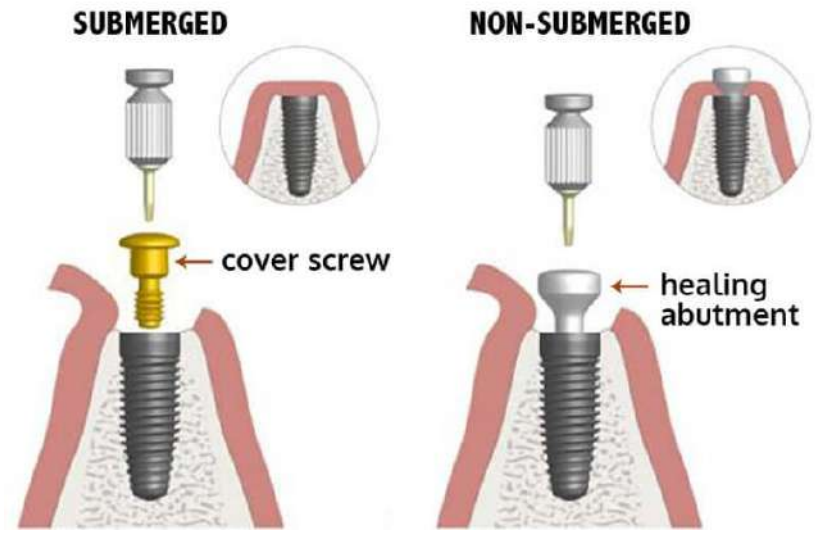
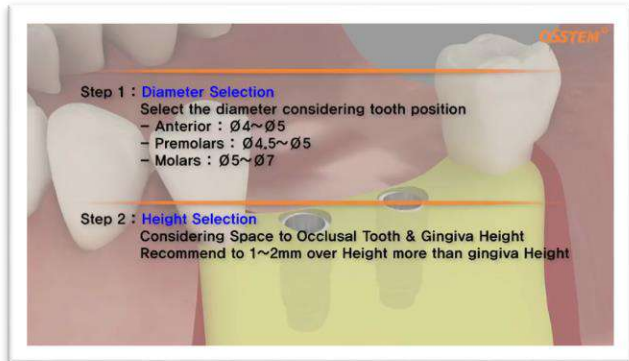
Cover Screw or Sealant Screw

- The implant fixture, after placement in bone, is sealed at its platform with a cover screw, prior to suturing, to prevent bone from growing between the screw and the implant.

Healing or Interim Abutment (Gingival Former)

- Healing abutments are dome-shaped screws, made of titanium or titanium alloy that provide permucosal access to the implant platform.
- It is placed at the completion of the implant placement in a one-stage surgery or after uncovering in a two-stage surgery.
- Its height is determined by the thickness of tissue present.
- It should project 1 to 2 mm superior to the height of the gingival tissue.
- It is used to shape soft tissue to a more appropriate emergence for the planned crown.
- It is important to allow for sufficient soft tissue healing time (7-10 days).



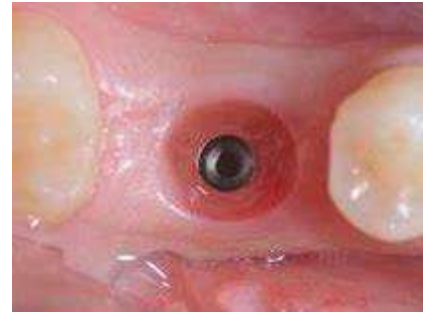

Uncovering - Two-stage Surgery - Gingival Former Placement.

- The healing time (Osseointegration) varies from site to site and from patient to patient.
- Insertion torque values, quality of bone, bone grafts, patient health, location, number of implants, and soft tissue health all have an impact on healing time.
- Typical healing times are 4 to 6 months.

The Goals of Surgical Uncovering are to

- ✓ Attach the healing abutment to the implant
 - ✓ Preserve keratinized tissue
 - ✓ Modify the form or thickness of tissue
- A soft tissue healing period, typically 7-10 days.



Gingival Former = Healing Abutment

- The simplest method of surgical uncovering is the “tissue punch”.
- The tissue punch is placed directly over the implant circumference and twisted through the soft tissue thickness..
- The exposed cover screw is then removed, and gingival former is placed.



Advantages

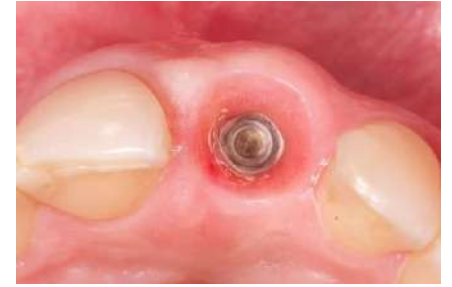- ✓ Less traumatic
- ✓ No periosteum needs to be reflected
- ✓ Only a short soft tissue healing time is required

Disadvantages

- ✓ Sacrifice the keratinized tissue
- ✓ Inability to visualize the bone surrounding the implant
- ✓ The inability to directly visualize the precise abutment–implant interface.

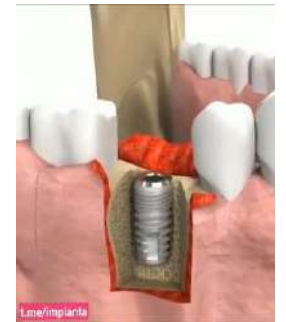Crestal Incision for gingival former placement - Indications

- The implants cannot be accurately located
- the clinician needs to visualize underlying bone
- If an adequate zone of keratinized tissue is present, the soft tissue flap can be contoured to the shape of the healing abutment.



Advantages of this technique

- Easy access, minimal invasiveness
- Ability to directly visualize the bone
- Precisely fit the healing abutment to the implant platform.



The Disadvantage

- The possibility of bone loss due to stripping the periosteum from bone.

Implant Stability

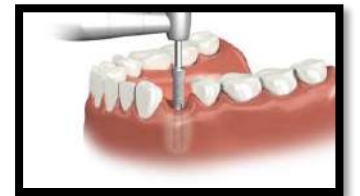- Initial implant stability is one of the most important predictors of long-term success.

This depends on

- Depth and density of bone.
 - Implant size.
 - Precision of the surgical technique.
- A good sense of implant stability obtained with adequate torque resistance capability of the seated implant.

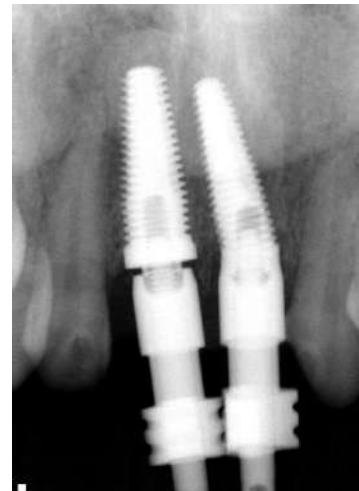
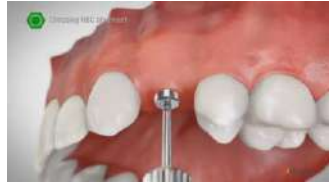
- Radiofrequency analysis measure implant stability.
- This technology involves attaching a transducer to an implant and applying a steady-state resonance frequency to the implant.
- The advantage of this technology is evaluating the complete bone-implant interface.



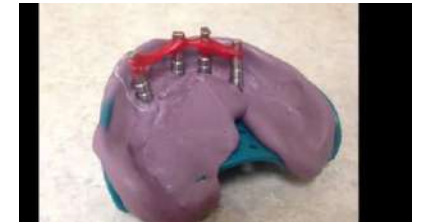Impression Coping (Transfer Coping)

- Impression copings facilitate transfer of the intraoral location of the implant to the same position on the cast.
- It is either screwed into the implant body or snapped onto an implant abutment.
- it could be either closed-tray transfer or open-tray transfer.
- The open-tray method is more accurate method and is indicated when large-span frameworks or when the implants are too divergent to easily remove the impression tray in the closed-tray technique.
- A heavy-body polyvinyl siloxane or polyether impression material is recommended.
- the coping should accurately seated on the implant platform, If not properly seated, the accuracy of the transferred location of the implant will be incorrect.
- This could be ensured by taking a radiograph
- On completion of the transfer impression, an analog is screwed onto the impression coping, and reinserted into the impression.



Implant Analog or Replica

- Implant analogues replicate exactly the top of the implant fixture in the cast.
- It is screwed directly into the impression coping.
- It is better to create a elastomeric soft tissue moulage (Gingival Mask) in the impression prior to pouring, this will simulate the soft tissue portion on the oral cavity.
- This allows the technician to have an accurate and flexible representation of soft tissue.
- The technician then has a working model that can be used to fabricate the abutment



Implant Abutment

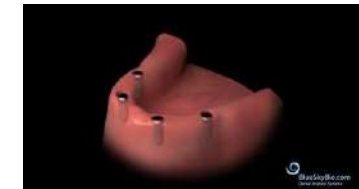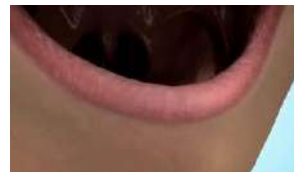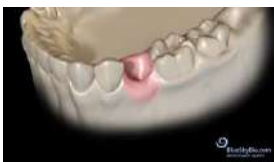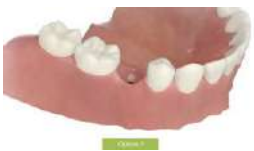- The abutment is the part of the implant that retains a prosthesis (superstructure).

- Abutments can be divided into three main categories:

(1) Screw retained, uses a screw to retain the prosthesis

(2) Cement retained, uses cement to retain the prosthesis

(3) Prefabricated attachment abutments, retain a removable prosthesis (e.g., locator, ball and socket, bar attachments)



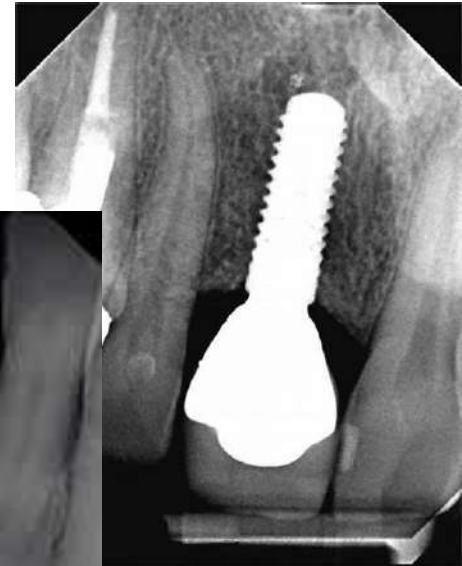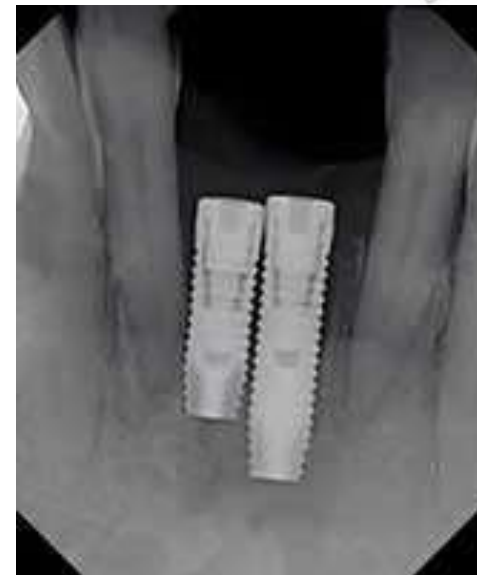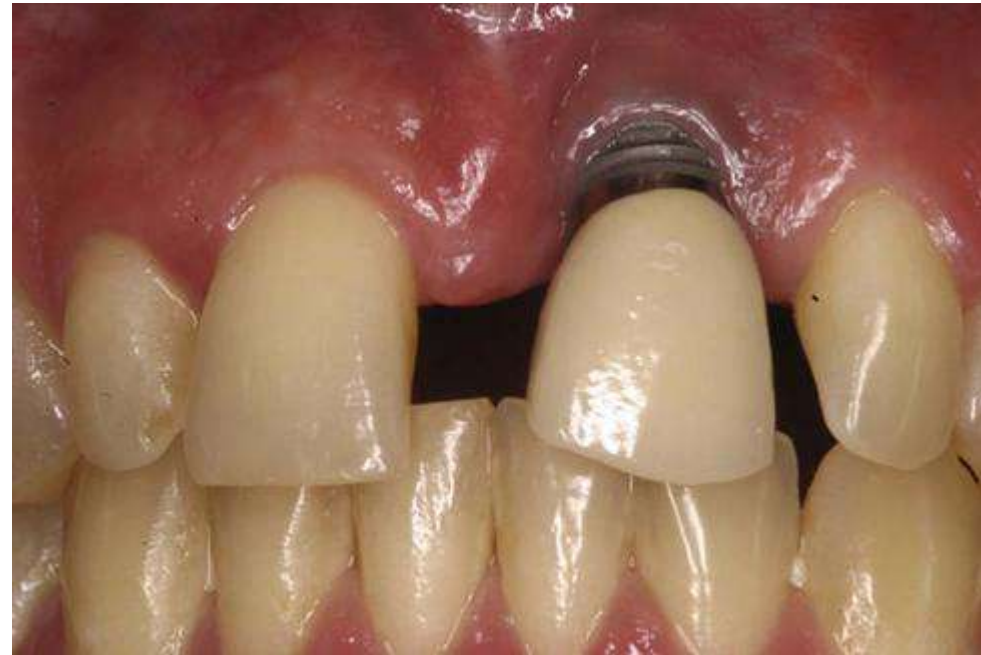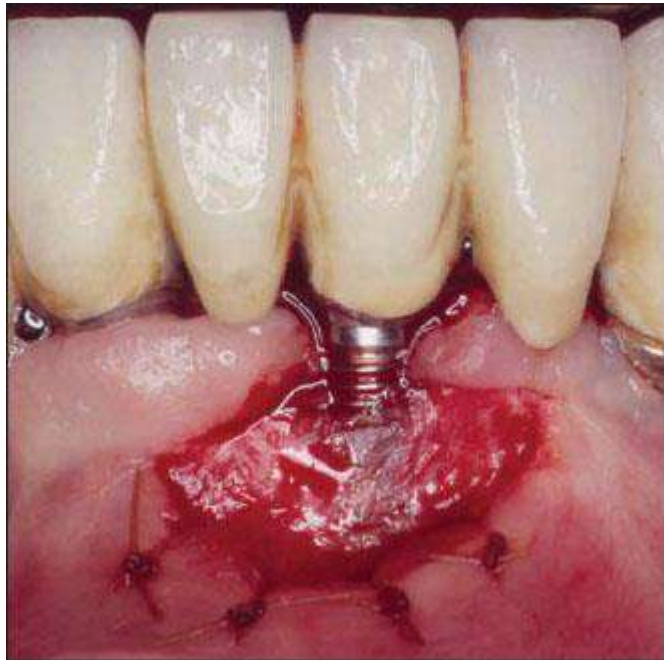
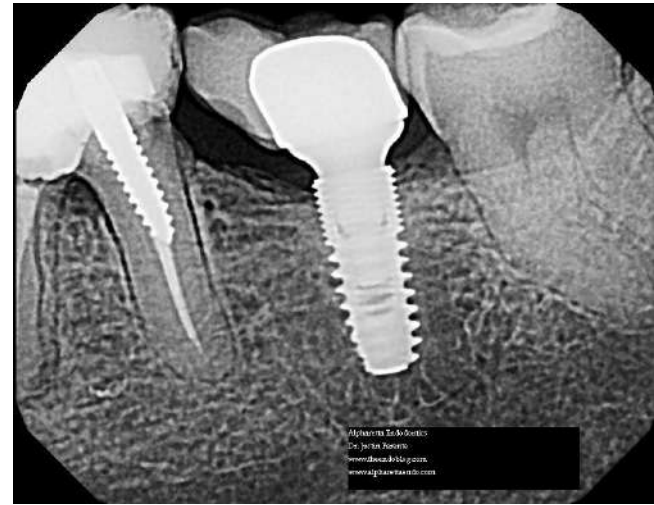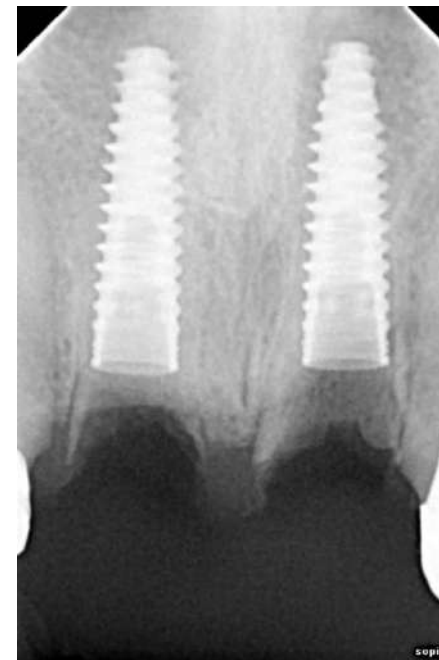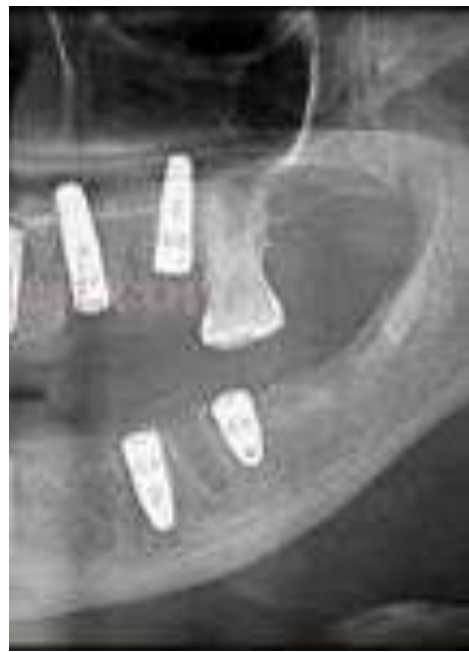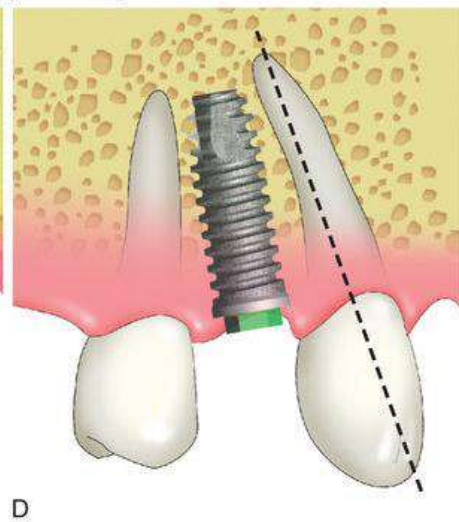
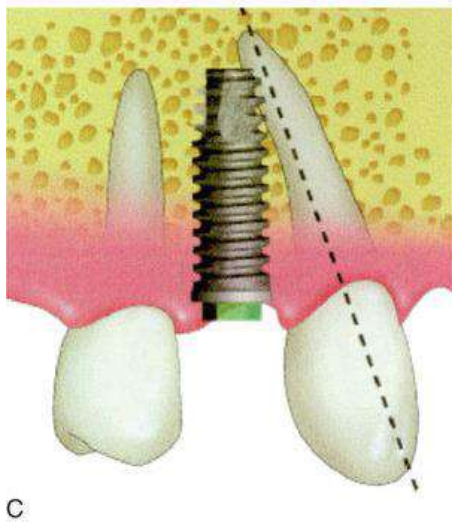
Prosthesis Retaining Screw

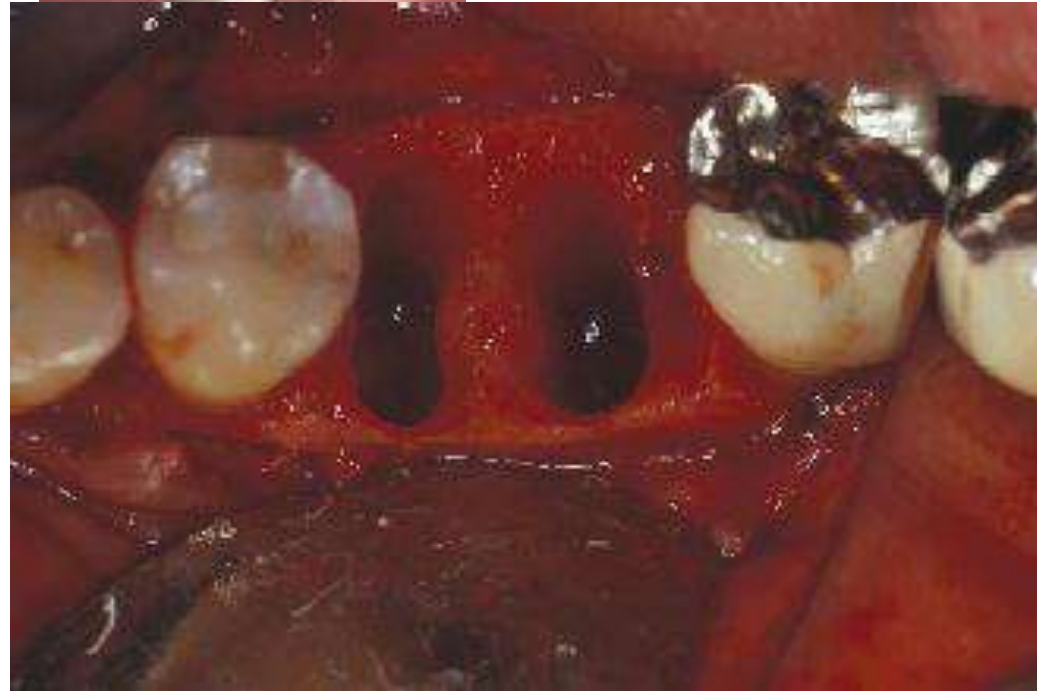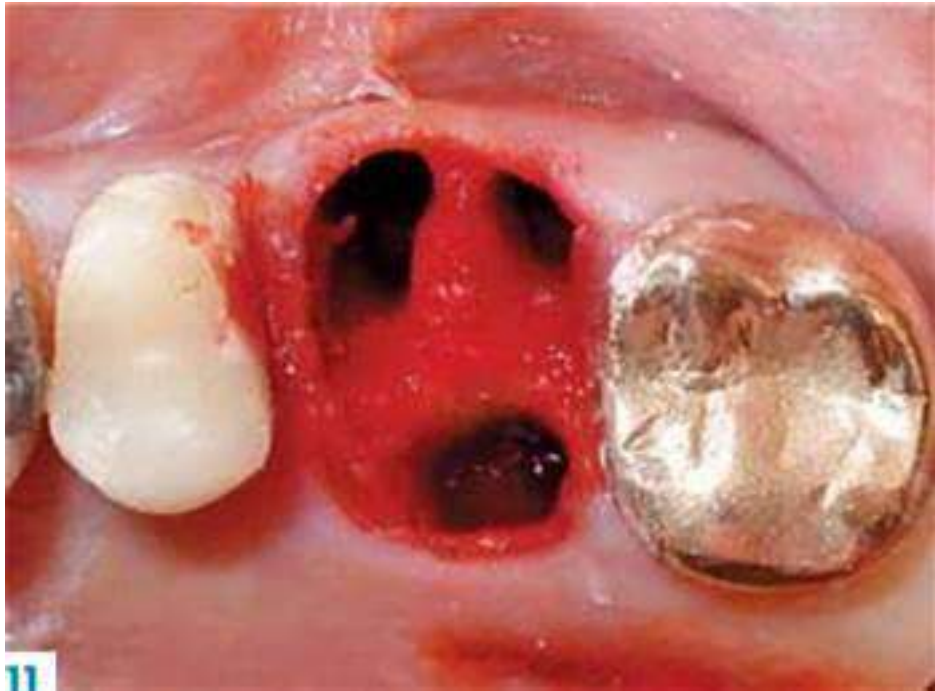
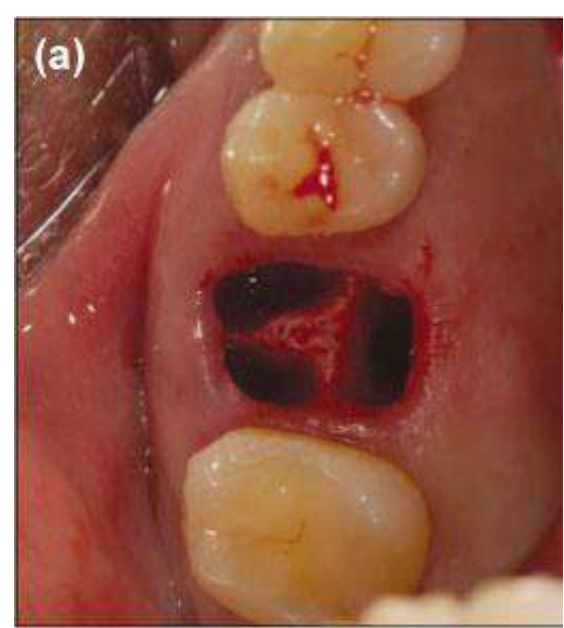
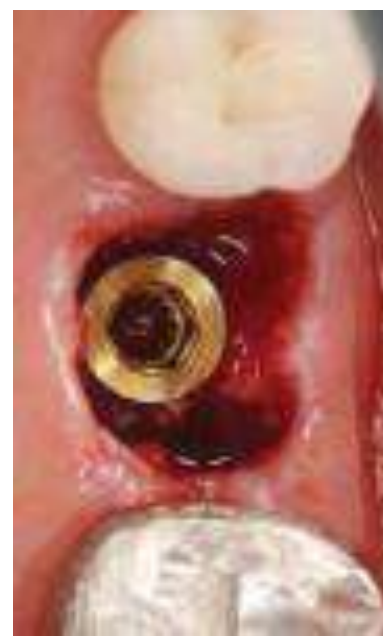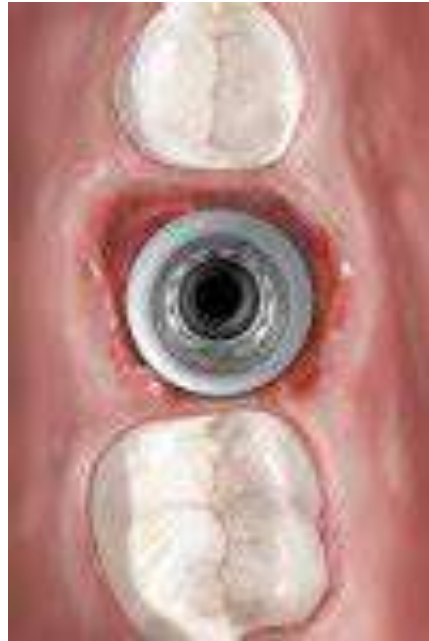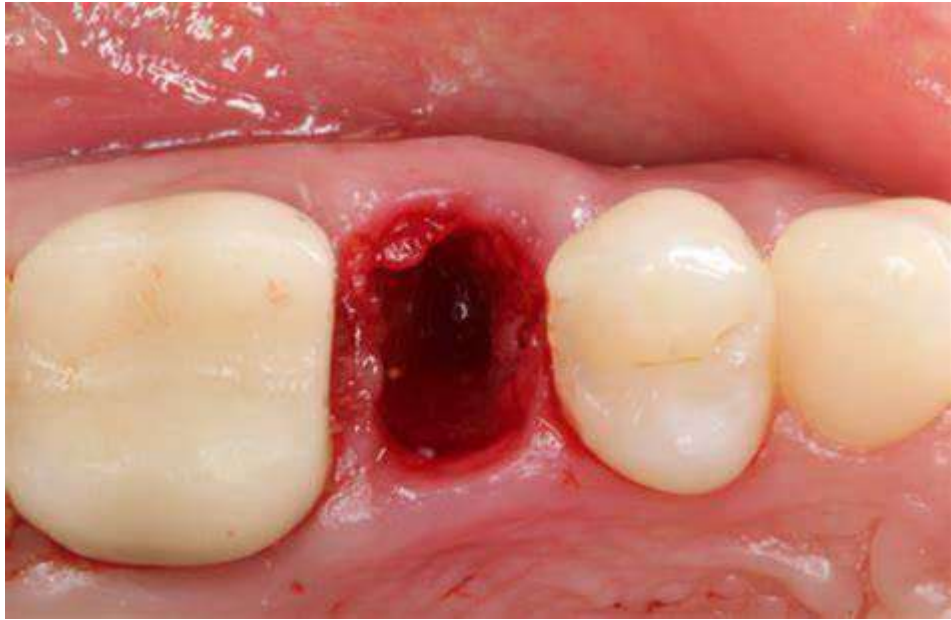- Screws are intended to attach abutments and crowns to the fixture.
- The screws made of titanium, titanium alloy, or gold alloy and sized specific to the type, size, and design of the implant system.
- The screws typically have a hex or square design to accept a driver.
- Screws are tightened by a torque wrench.
- The torque value ranged from 25 - 30 Ncm.



Complications

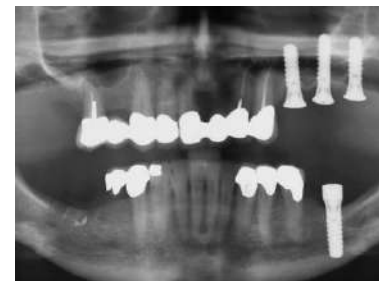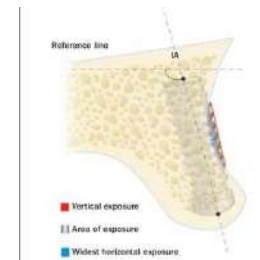
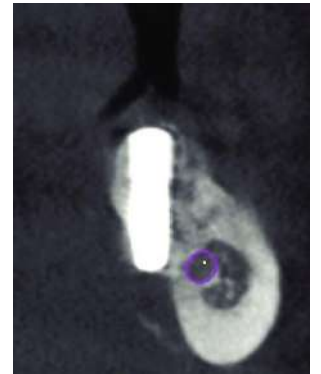
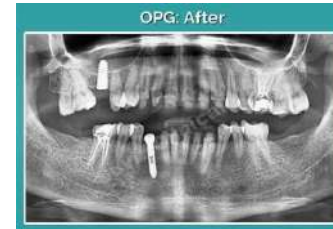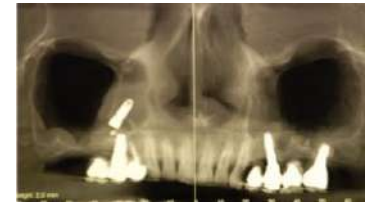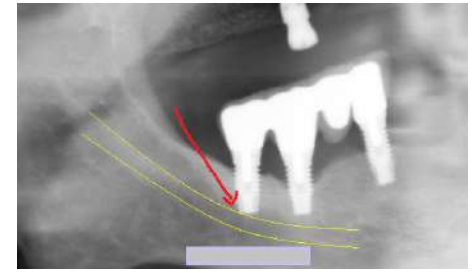
- Surgical Procedure complication - Pain, Bleeding, Swelling, or Infection (as any surgical procedure).
- **Positioning Error Complications** – If the Implant Placed
 - at a compromised angulation or position.
 - close to adjacent root or far to mesial, distal, or buccal aspect, compromising bony support.
 - too far into bone, making prosthetic access difficult.
 - supracrestal, leaving threads above the bone, compromise soft tissue health and esthetics.
- Surgical Technique Complications
 - Tear of the soft tissue flap, Poor closure of the incision, Excessive soft tissue trauma from retraction, all may result in tissue dehiscence, infection, and eventual loss of the implant.
 - Poor preparation such as overdrilling the diameter of the osteotomy could result in poor integration.

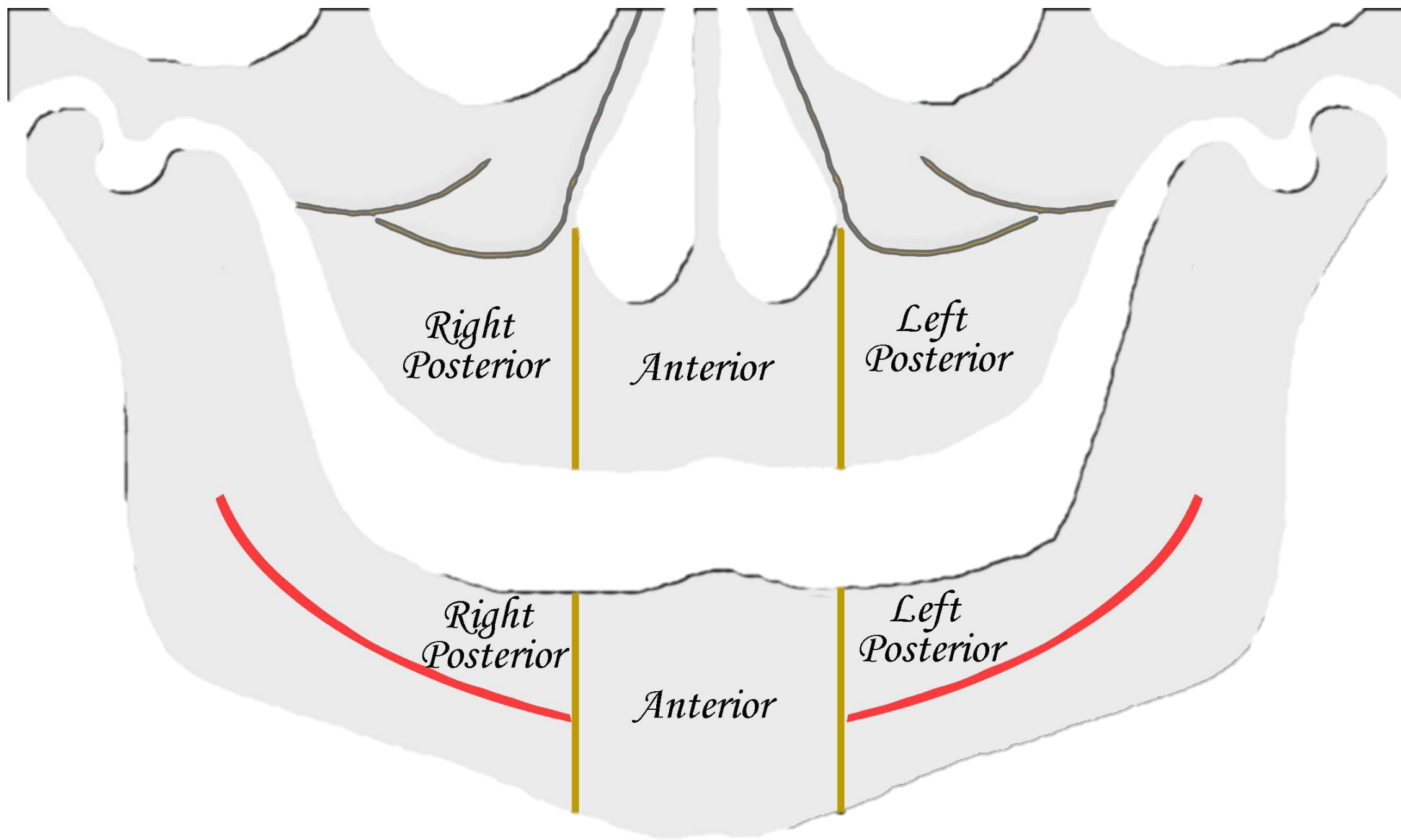




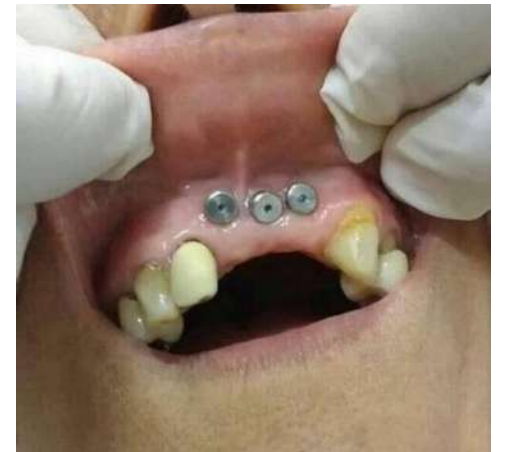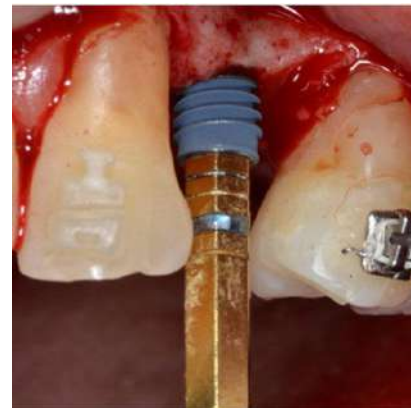
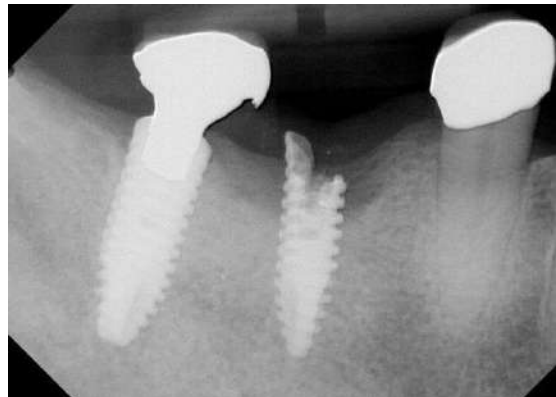
- Damage of the critical anatomic structures

- Impingement on the inferior alveolar canal, result in Paresthesia
- Invasion of the maxillary sinus or the nasal cavity, result in an infection.
- Dehiscence or fenestration of the buccal plate due to thin bone
- Perforation of the inferior border of the mandible due to inaccurate drilling depth.
- Perforation of the lingual aspect of the posterior mandible because of the lingual undercut from poor positioning or angulation of the implant drills.
- Wound Dehiscence occur from inadequate suturing or tension closure.



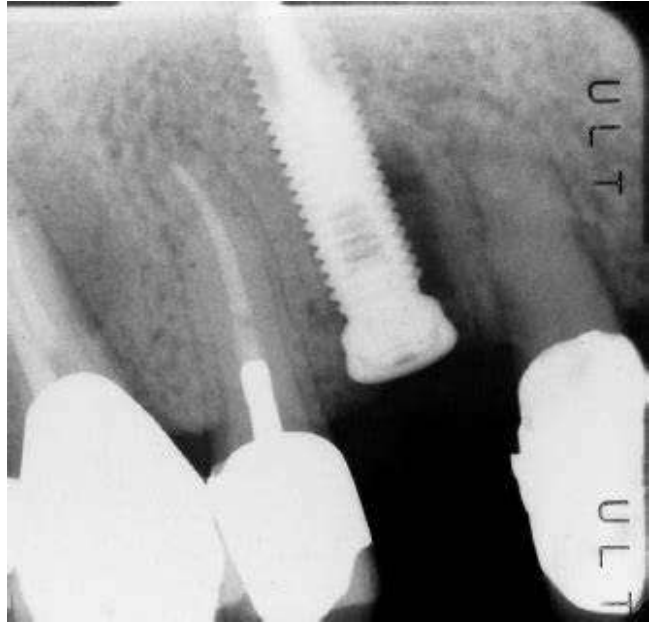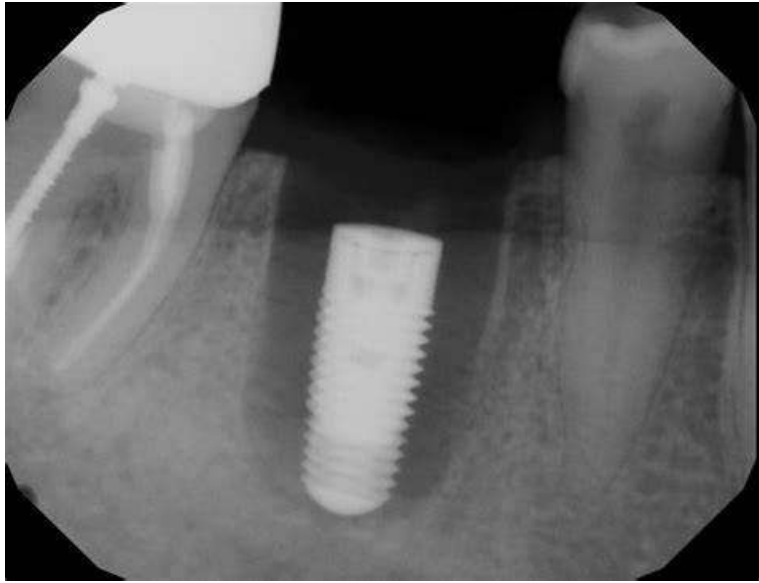
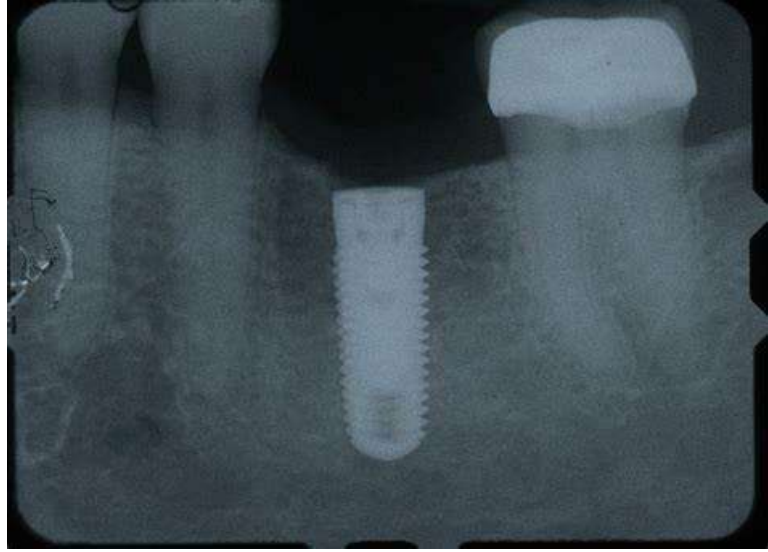



- Esthetic complications occur from poor positioning or angulation, making proper prosthetic restoration unrealistic.
- If the osteotomy is improperly prepared in dense bone,
 - Mechanical complications can present as an implant platform fracture because of excessive insertion torque.
 - it is possible to get the implant “stuck” in bone, short of complete seating, making it extremely difficult to retrieve the implant.



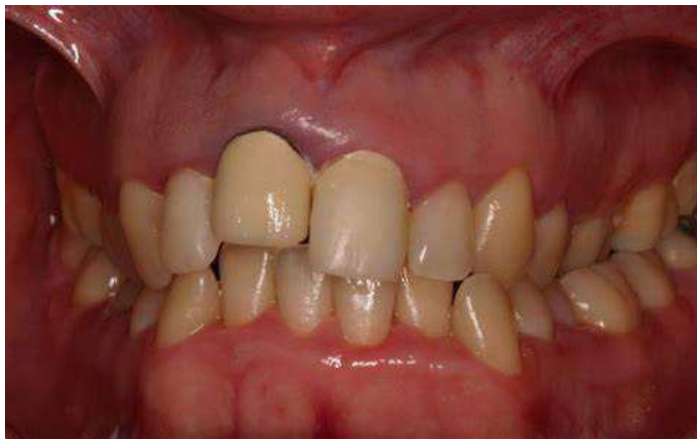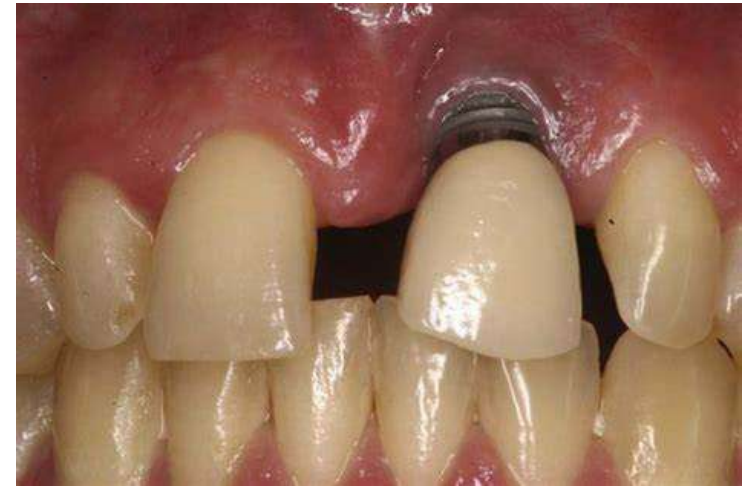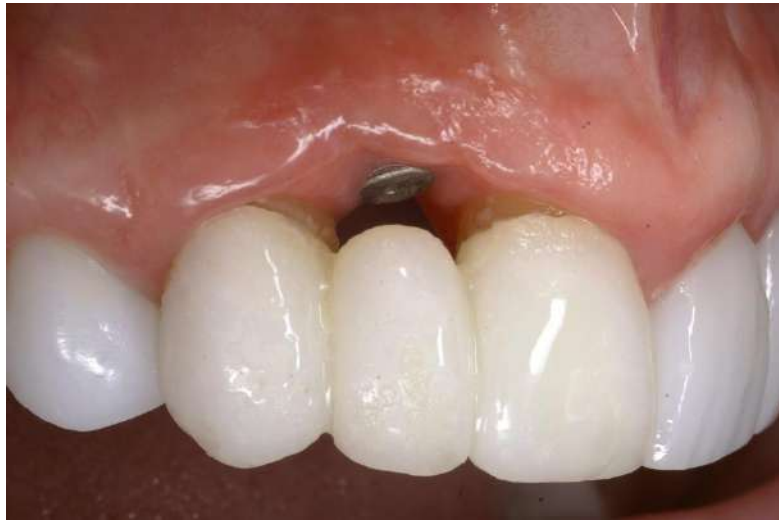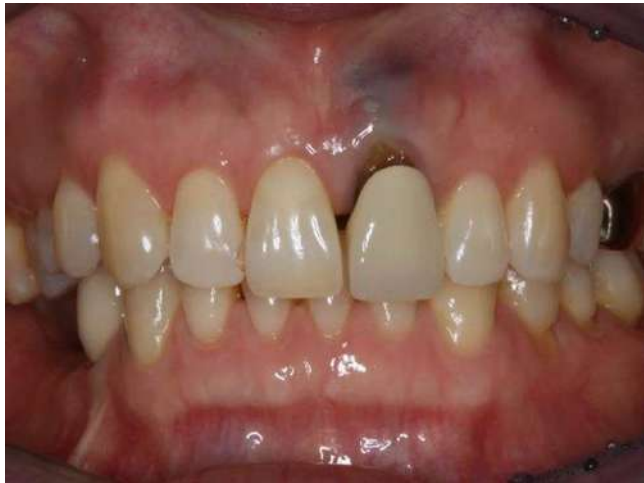Implant Outcomes

- Implant Survival : the presence or absence of the implant at the time of last examination, regardless of whether the implant was functional, with bone loss, or had other problems.
- This type of assessment should not be confused with Implant Success.
- Implant Success : is defined by a criteria used to evaluate the condition and function of the implant
- Criteria for implant success according to Albrektsson
 - No Pain, No Mobility, No Radiolucent Peri-implant Areas
 - Less than 0.2 mm of bone loss annually after the first year of loading.
- Implants that are osseointegrated but not functional are referred to as sleepers.

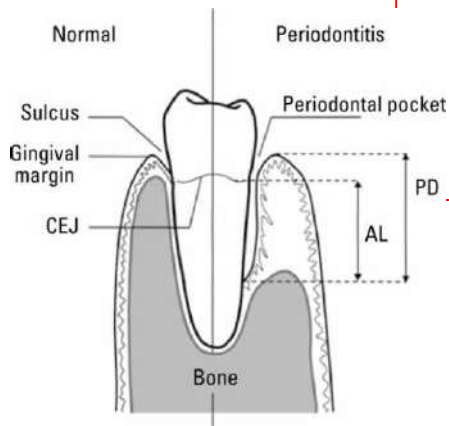


Aesthetic Results and Patient Satisfaction

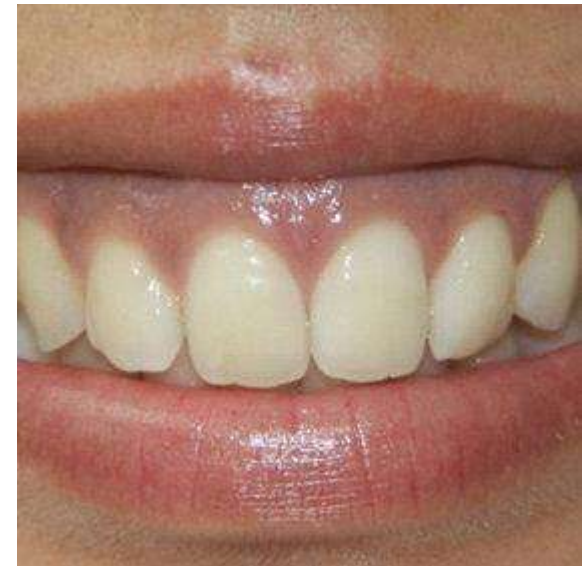- The aim is to achieve natural-appearing and functioning implant-supported tooth replacements
- Successful Aesthetic Factors are
 - Proper crown dimension and contour
 - Ideal soft tissue support
- If crown form, dimension, shape and gingival harmony around the implants are not ideal, the patient may consider the implant restoration unacceptable.
- Patients with severe alveolar deficiency, an ideal aesthetic outcome may be impossible because reconstructive surgical procedures are
 - Complex
 - Require long time
 - Remain unpredictable.



- Esthetic problems and dissatisfaction happen when results do not match a patient's expectations.
- Satisfaction with the aesthetic outcome of implant prosthesis varies among patients.
- The risk of esthetic failure is greater among those with high esthetic demands and risk factors such as



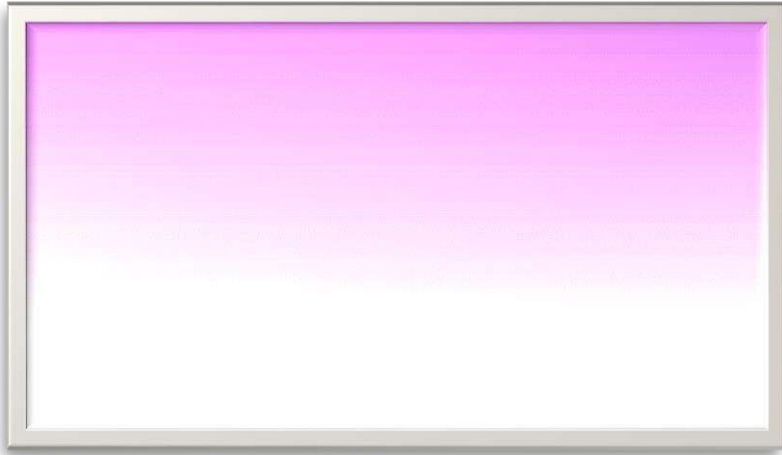- High smile line
- Thin periodontal soft tissues
- Compromised bone support.




Surgey and Prosthetic 3D



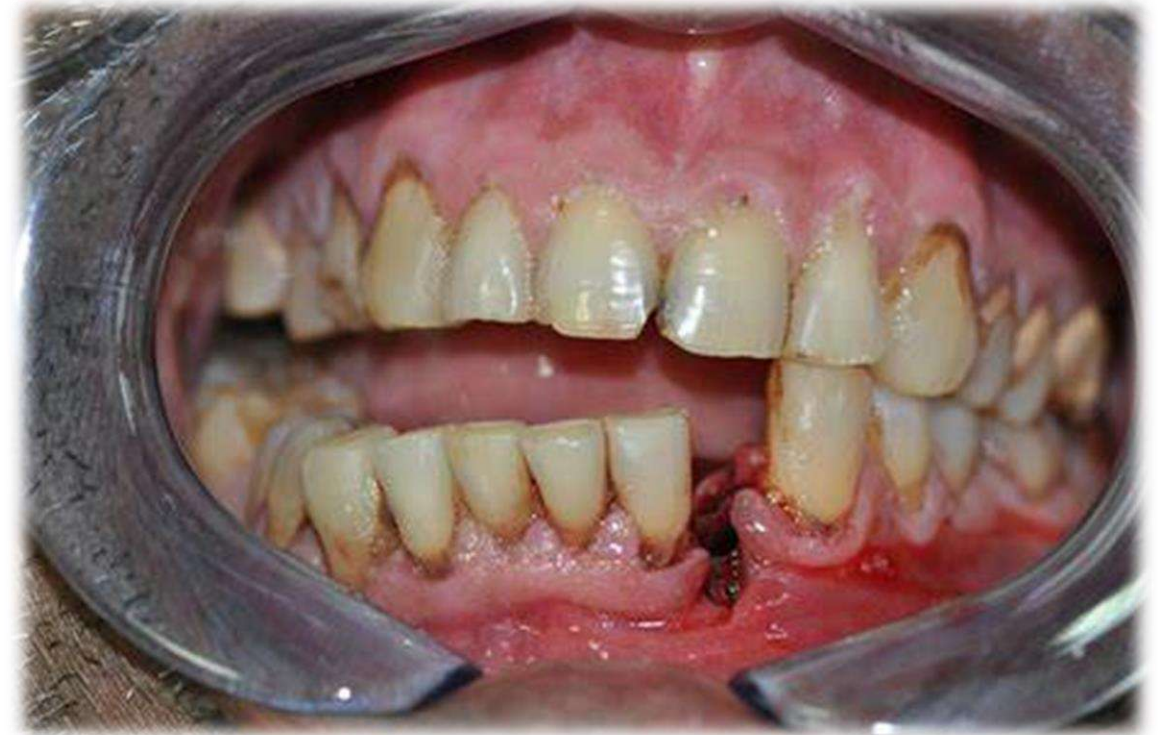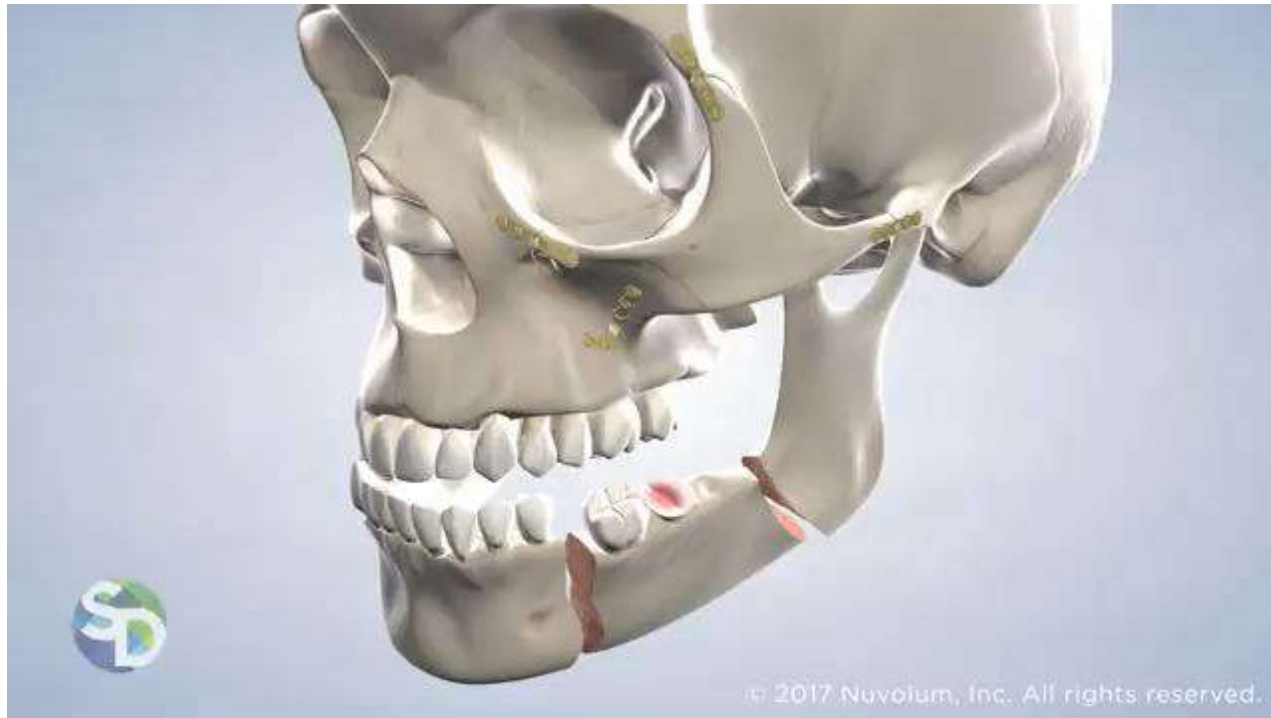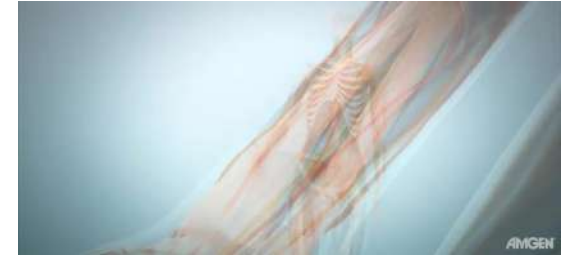procedure



Drill stopper



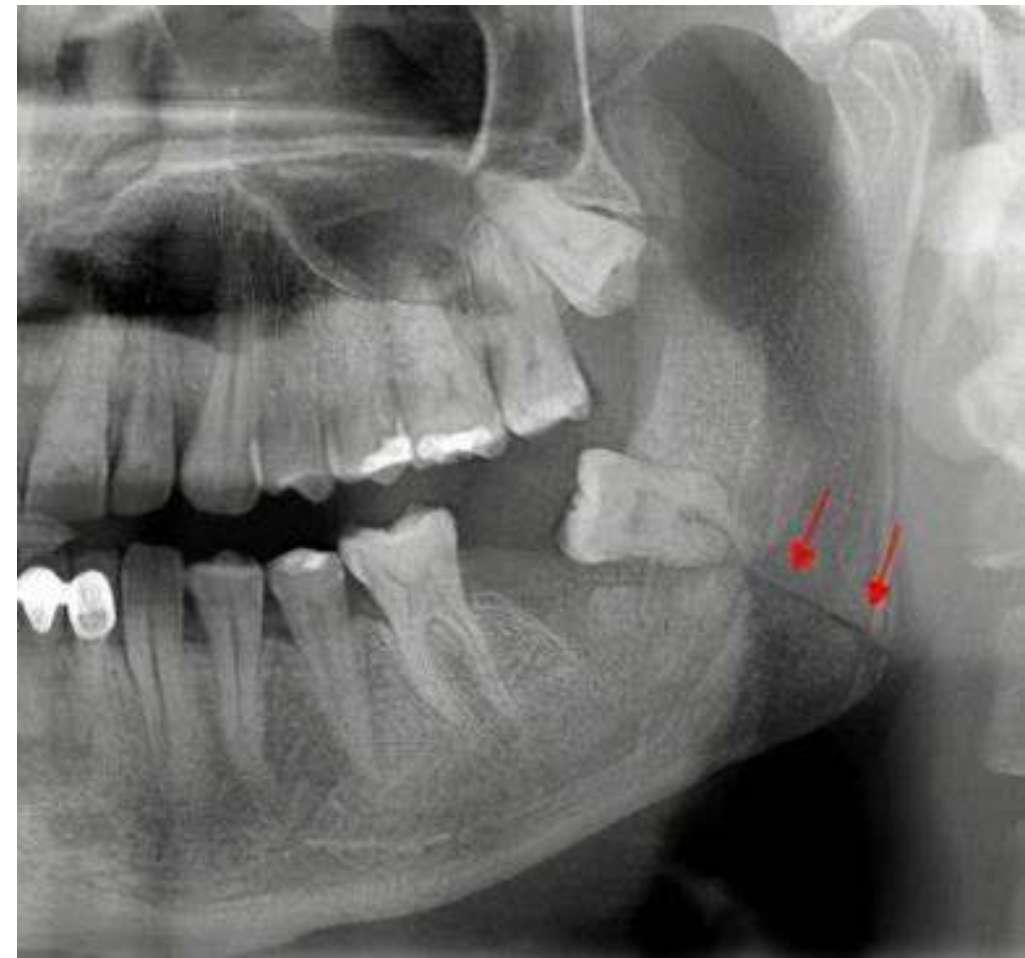
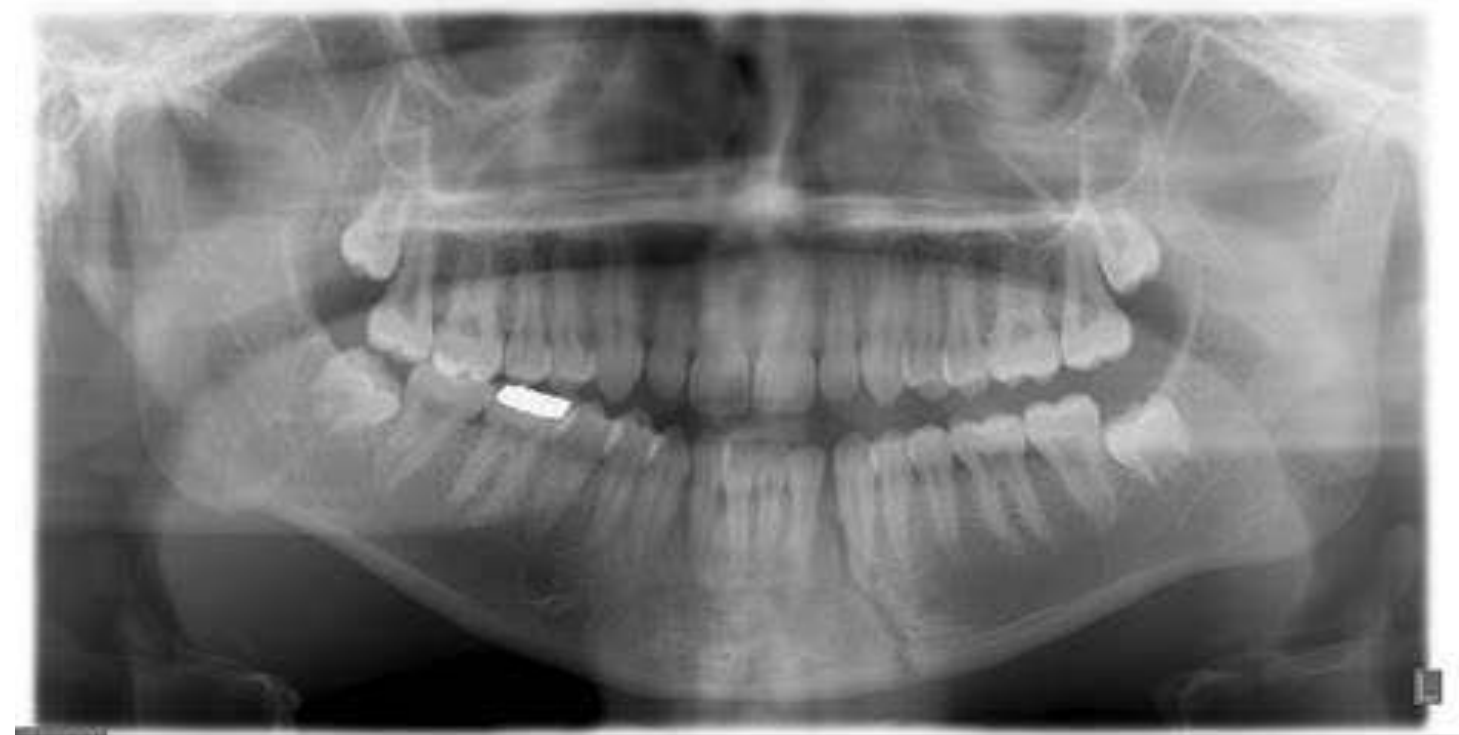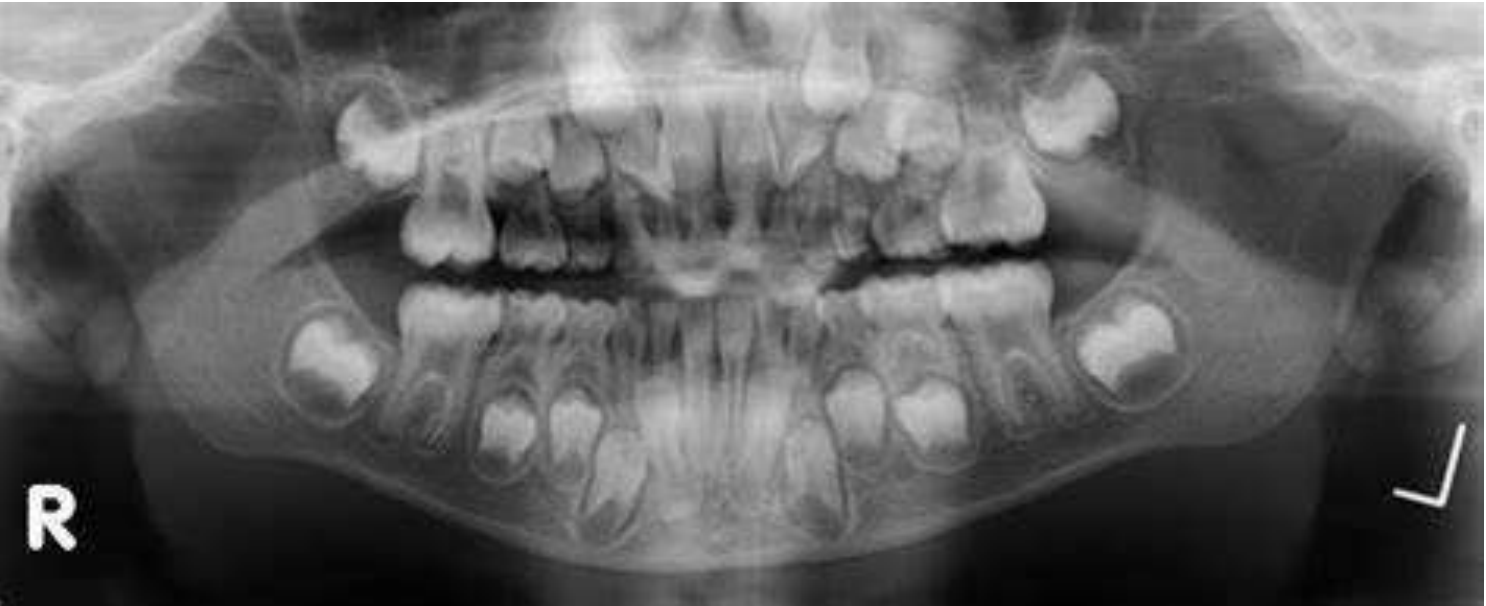
Fractures # of the Mandible



Bashar Abdul-Ghani - FICMS. MAXFACS CONS. MFDS. RCSED. RCPS (Glasg).

Lecture Quoted From Baghdad University Curriculum

- ▶ A Fracture is a **Break in the Continuity of the bone** which happens either as a result of violence or because the bone is unhealthy and unable to withstand normal stresses.
- ▶ Fractures of the mandible are **common due to the Prominence** of the mandible.
- ▶ The impact force required to **produce mandibular # are higher than those of the maxilla**
- ▶ The teeth are important in determining where fractures occur. The long canine tooth and the partially erupted or unerupted wisdom tooth both represent lines of relative weakness.



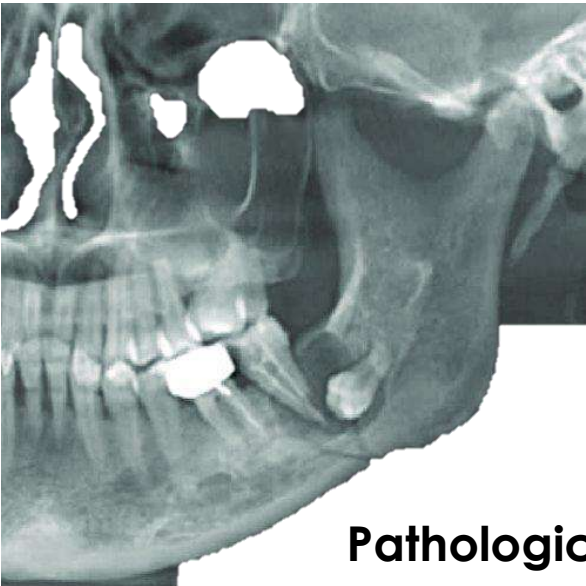
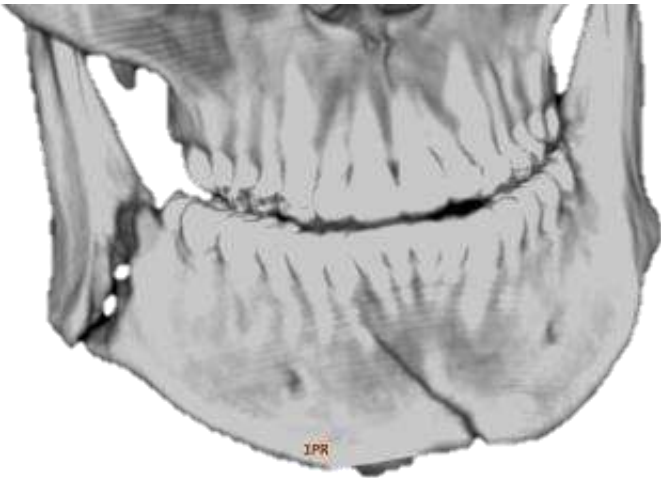
Classification - According to the Type of Fracture :

- ▶ Simple/closed: fracture without communication with the external environment.
- ▶ Compound/opened: fracture that extend externally through skin or mucosa.
- ▶ Comminuted: Bone is fragmented into multiple pieces.
- ▶ Greenstick: one cortex of bone is broken with other cortex being bent, it is found exclusively in children.
- ▶ Pathologic: Caused by pre-existing pathological condition of bone (osteomyelitis, cyst)
- ▶ Complicated/complex: Fractures associated with damage to the important vital structures, including the severely atrophied mandible.
- ▶ Single: Only one fracture line in the same bone.
- ▶ Multiple: Two or more lines of fractures on the same bone that do not communicate.

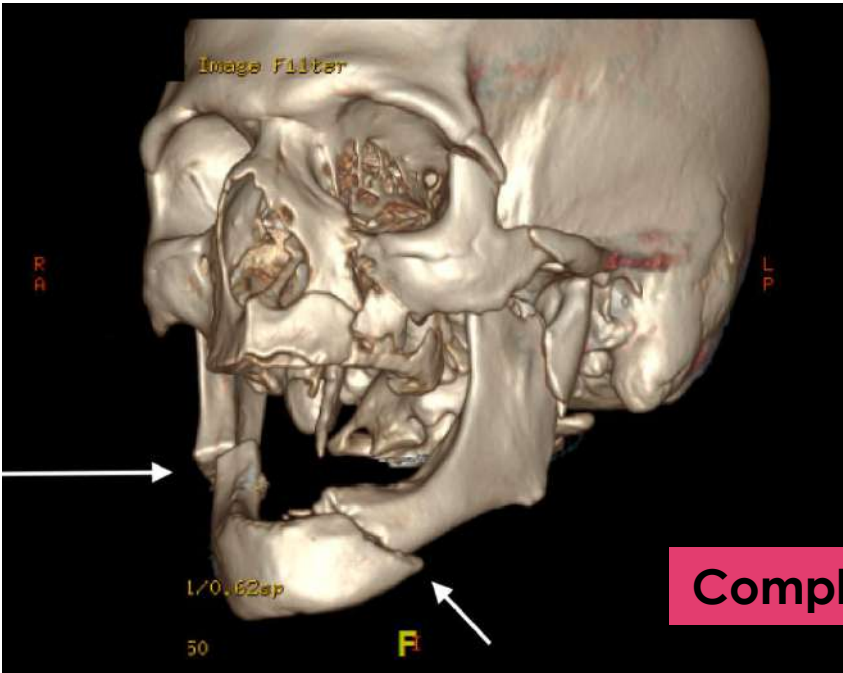
Greenstick



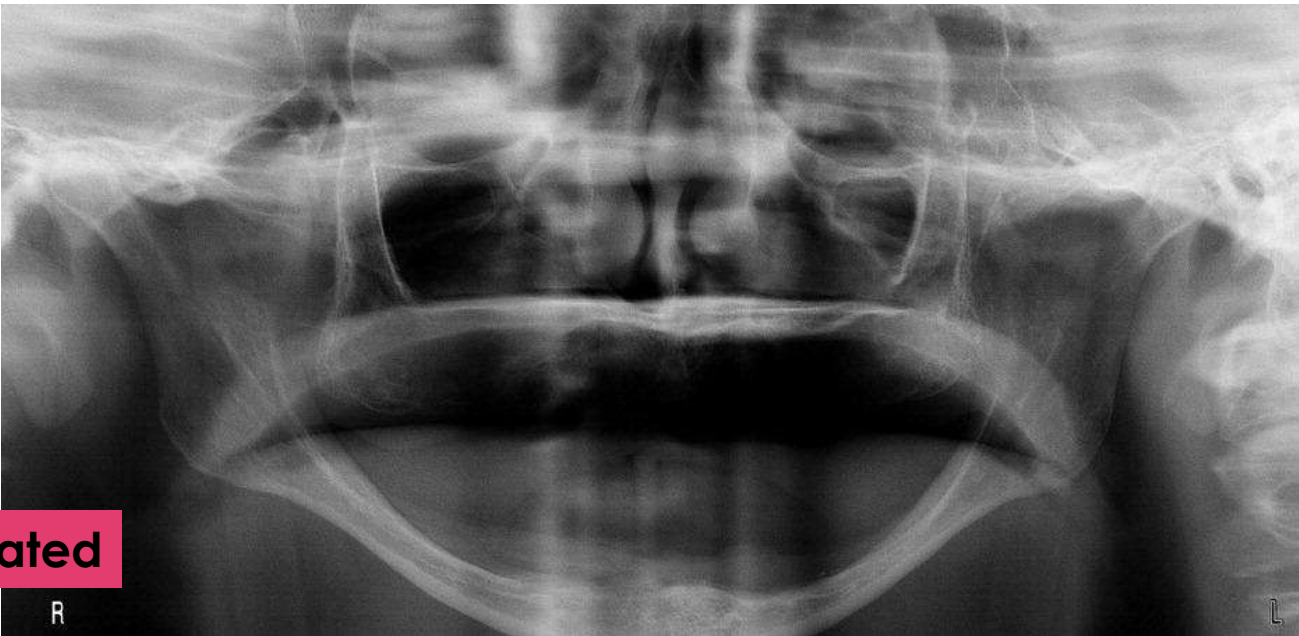
Multiple

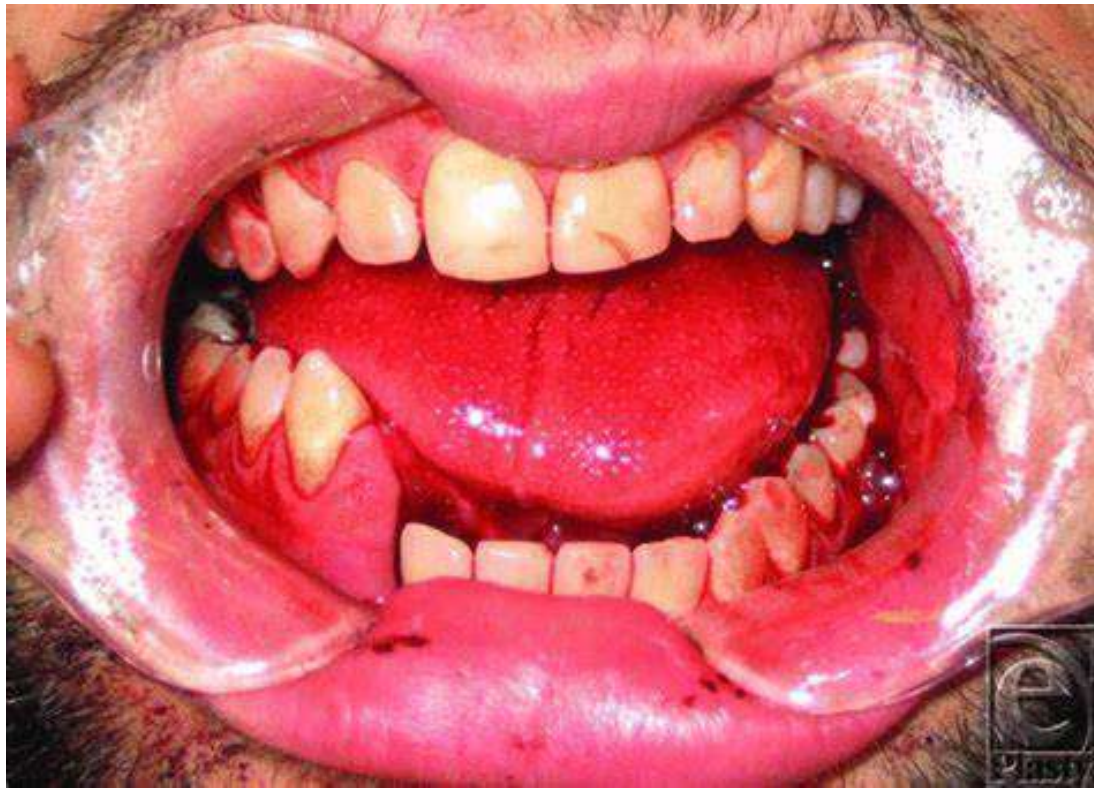

Pathologic



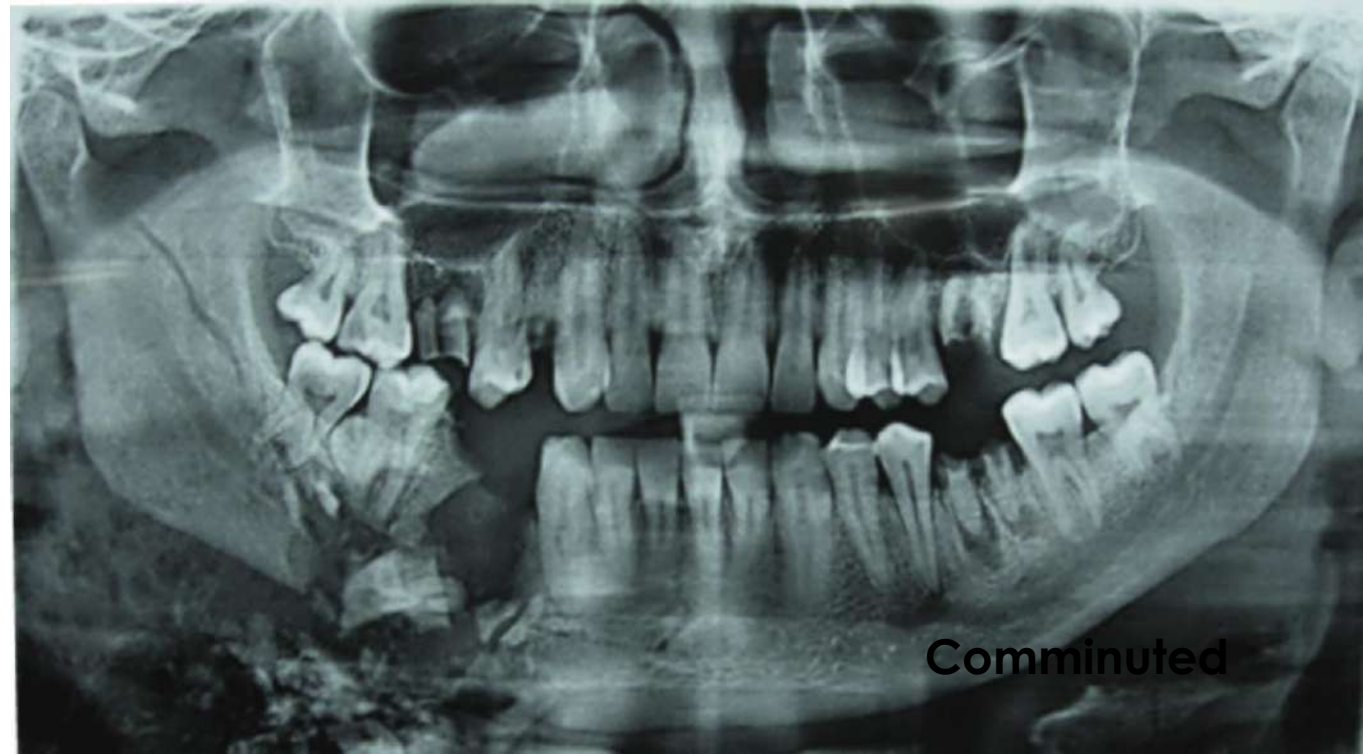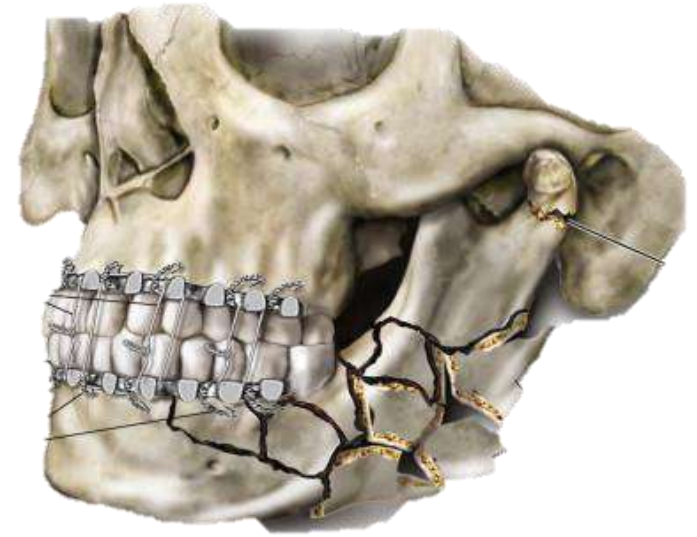
Complicated





Compound/opened

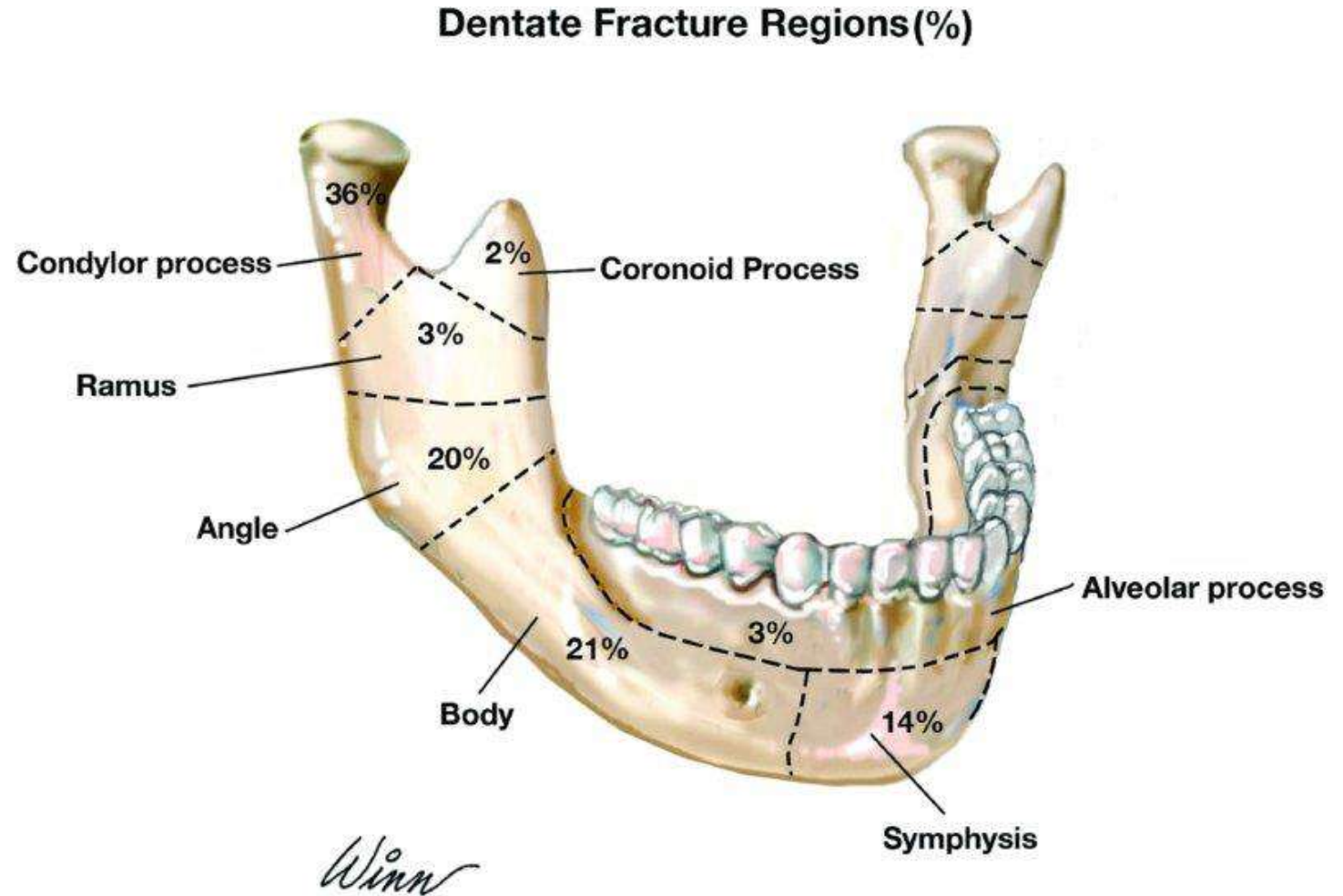
Comminuted



Comminuted

Classification - according to the **Anatomic Site** into:

- ▶ **Dentoalveolar**
- ▶ **Condylar**
- ▶ **Coronoid**
- ▶ **Ramus**
- ▶ **Angle**
- ▶ **Body (molar/premolar area)**
- ▶ **Symphysis/Parasymphysis**




Classification - according to their **Tendency to Displace** as a result of the pull of the attached muscles into:

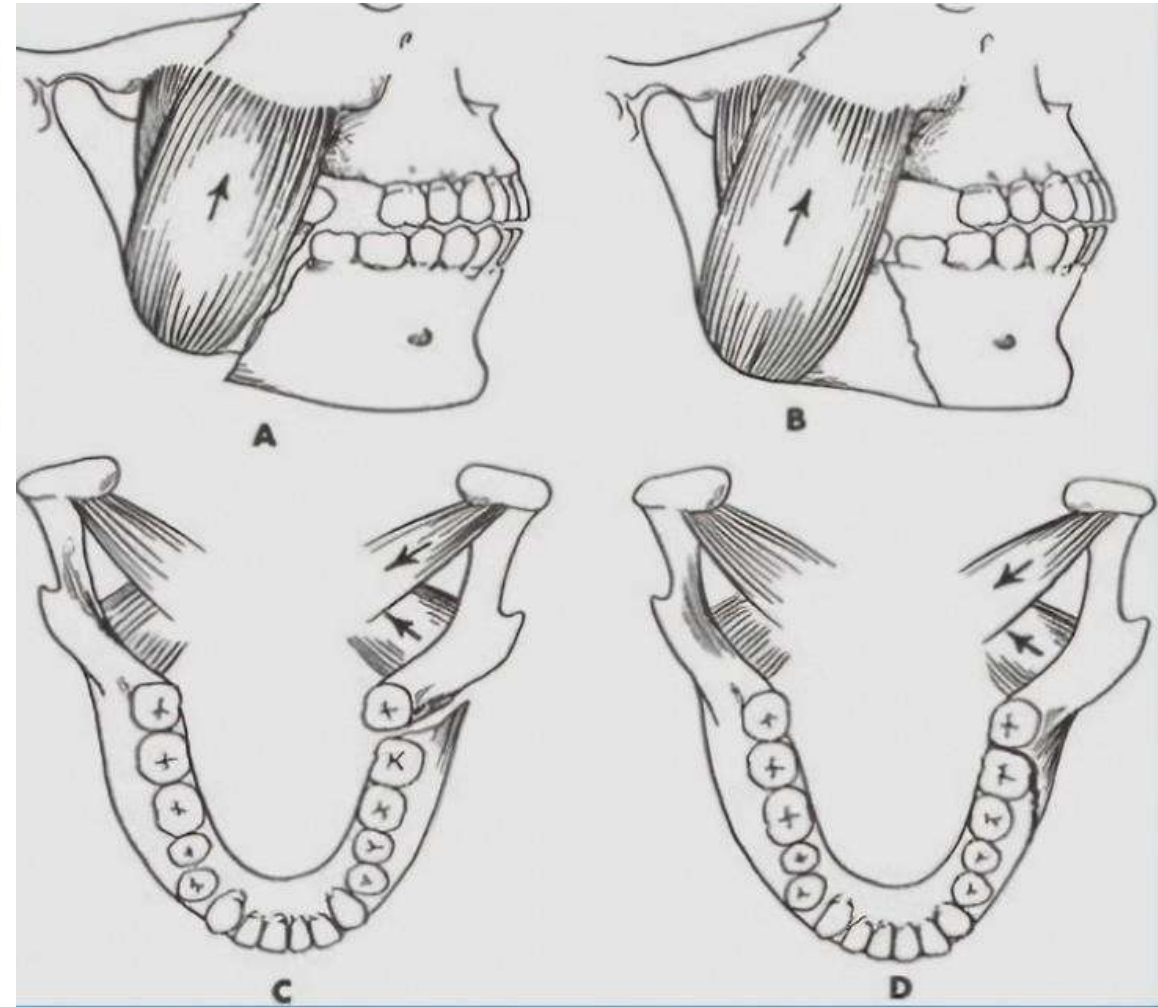
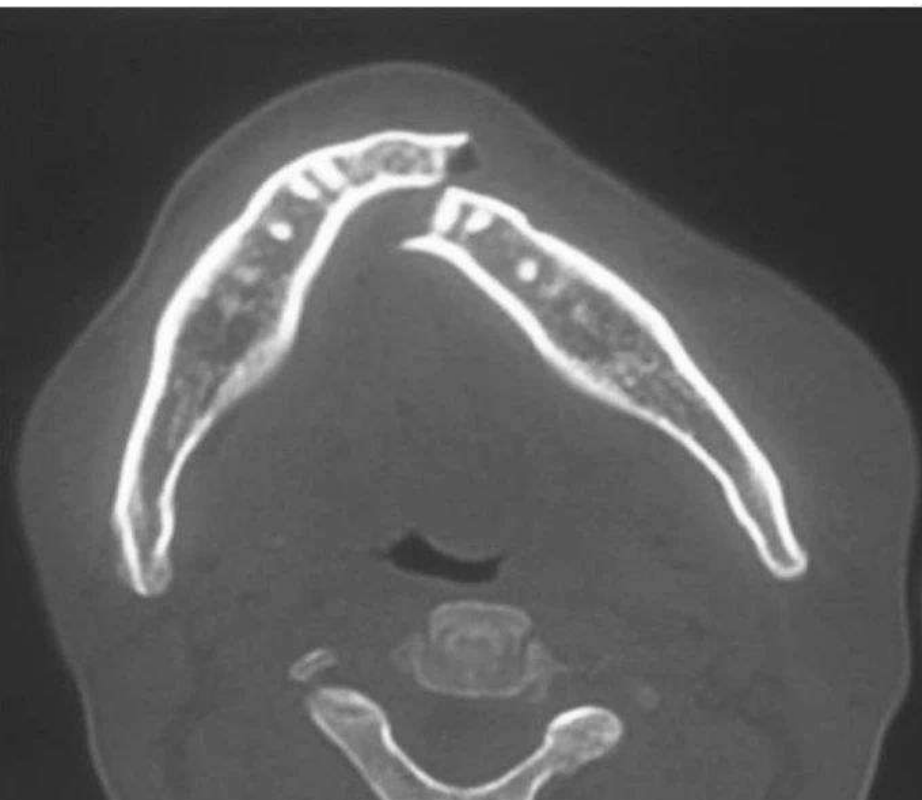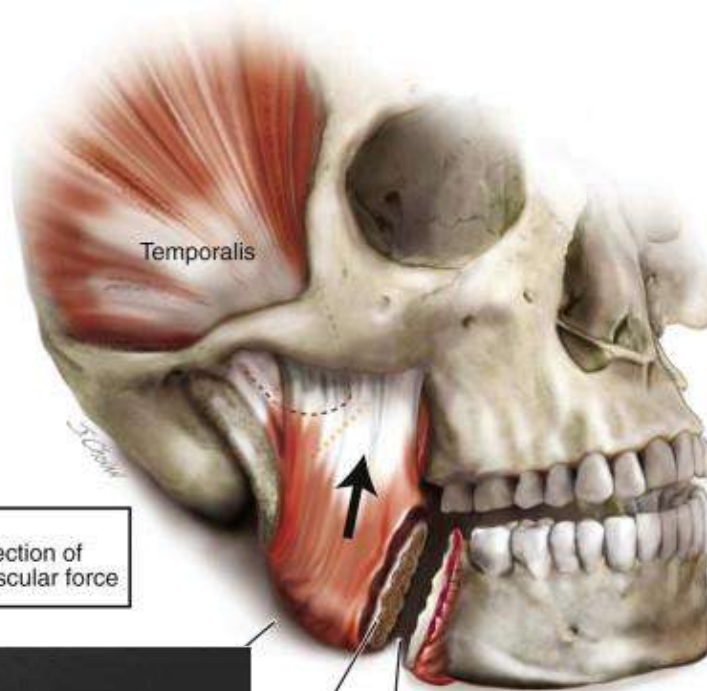
- ▶ **Favorable** when the muscles tend to pull the fragments together (minimizing displacement).
- ▶ **Unfavorable** when they are significantly displaced by the muscles.
- ▶ These are further considered as vertically or horizontally favorable or unfavorable.



Classification - **Direct and Indirect Fractures**

- ▶ **Direct #** - if # occur in the point of force application
- ▶ **Indirect #** - the resultant vector travels along the bone and applies tensile force on the point intersected by this vector.
- ▶ Whenever a direct # seen at the site of **primary impact**, one must examine the **corresponding site** and rule out the indirect fracture.

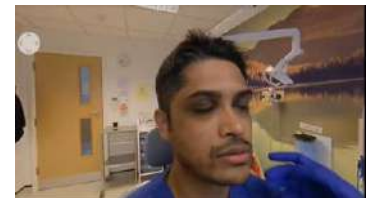
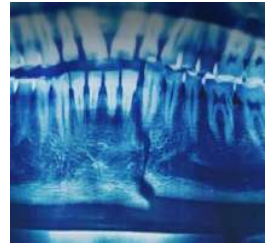




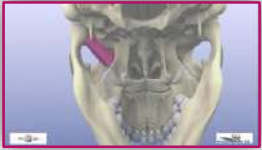Favorable / Unfavorable Fracture Lines

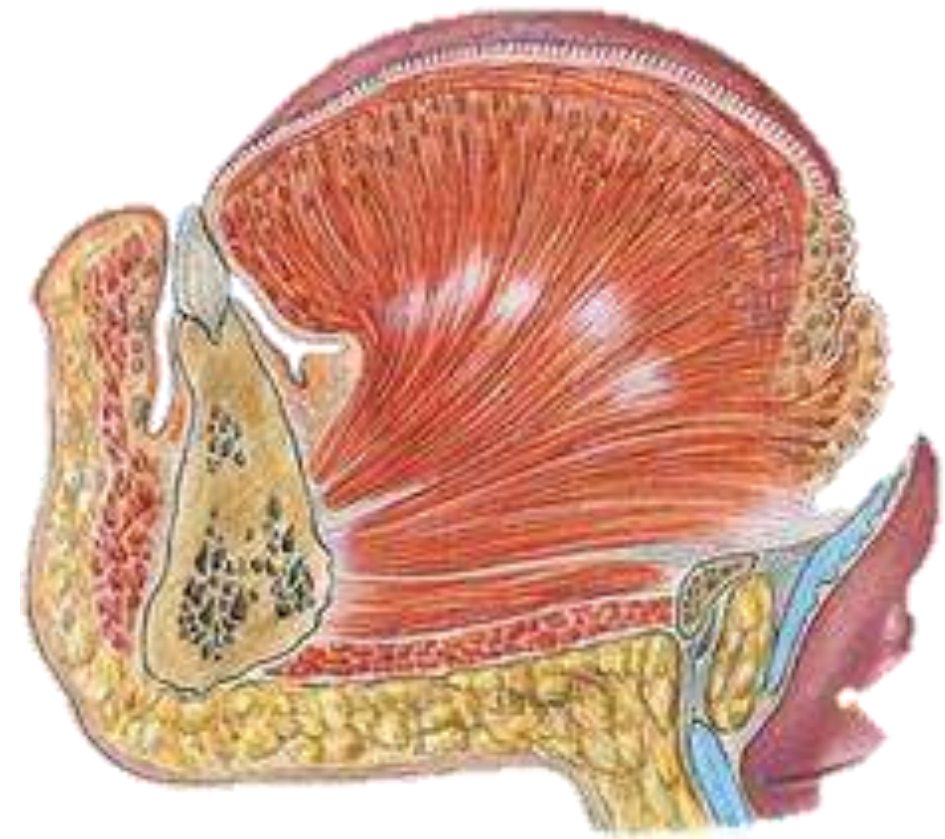
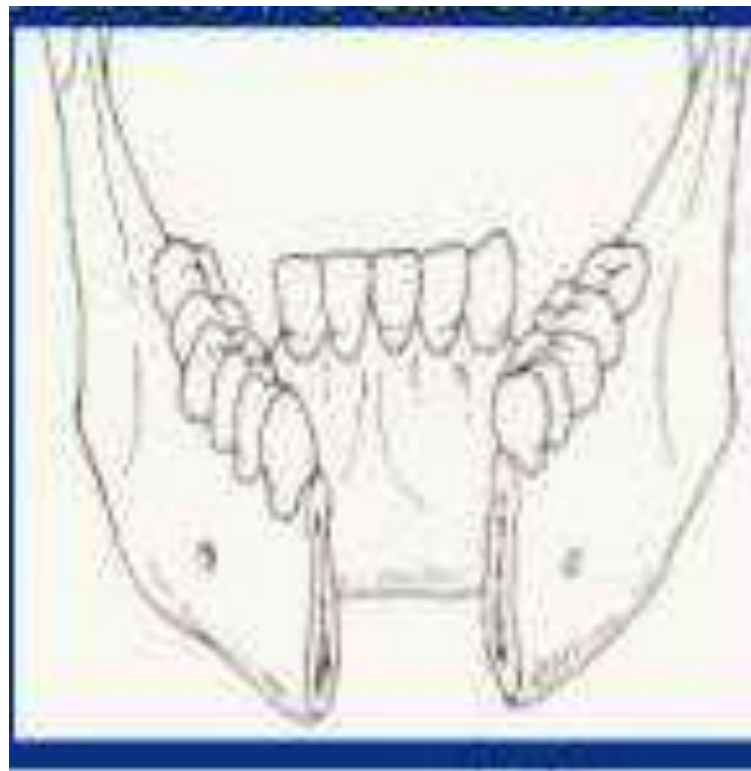
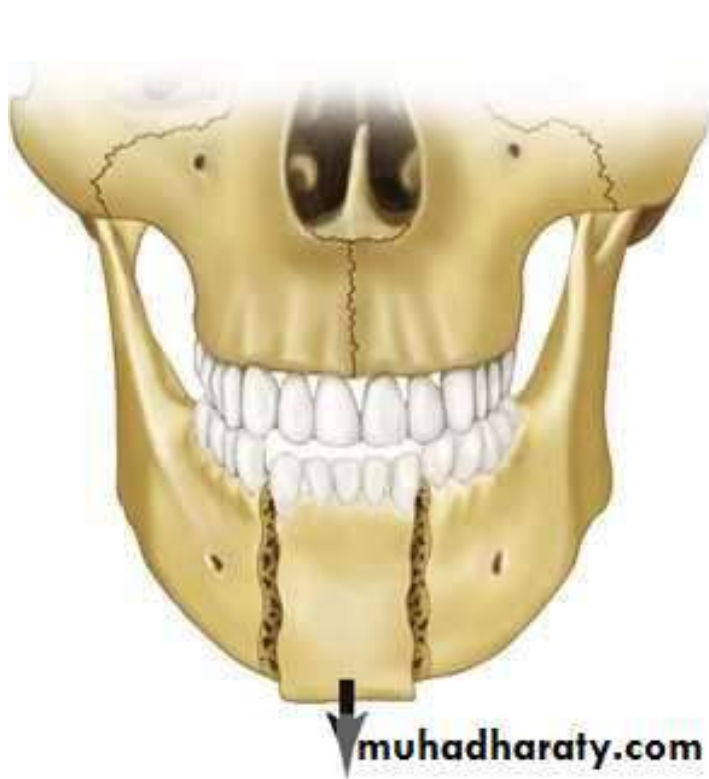
Clinical Features include:

- Pain especially on talking and swallowing leading to drooling of saliva.
- Swelling due to edema and hematoma causing facial asymmetry.
- The teeth near the fracture site may become loosened, displaced or avulsed.
- Bleeding from the fracture site.
- Trismus and difficulty in moving the jaw.
- Bone tenderness over fracture site.
- Mobility of fractured segment.
- Step deformity palpable due to displacement of the fractured segments.
- Numbness of the lower lip due to injury to the inferior alveolar nerve.
- Malocclusion.
- Sublingual hematoma which is regarded as a **Pathognomonic Sign** of fracture.
- Pain in bimanual pressure on ramus



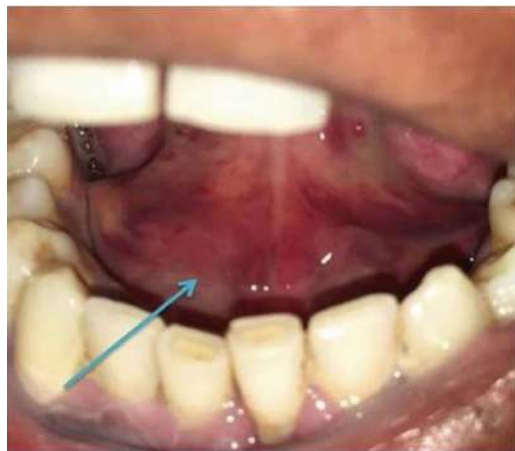
- ▶ In some cases of **Subcondylar Fractures** with condylar displacement and shortening of the ramus leads to premature contact of the posterior teeth and anterior open bite.
- ▶ **Bilateral Parasymphyseal Fracture** may be displaced posteriorly (pull of genioglossus and geniohyoid muscles) allowing the **tongue to fall back to the oropharynx** which constitutes a threat to the airway
- ▶ In condylar fractures, **bleeding from the ear (Otorrhea)** may result from laceration of the anterior wall of the external auditory meatus.
- ▶ It is important to **distinguish** bleeding originating in the external auditory canal from the more serious middle ear hemorrhage which signifies a fracture of the petrous temporal bone and may be accompanied by **Cerebrospinal (CSF) Otorrhea**.



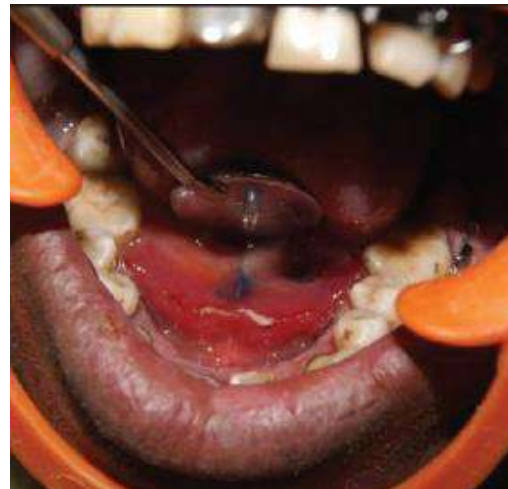

Bilateral Parasymphysal Fracture

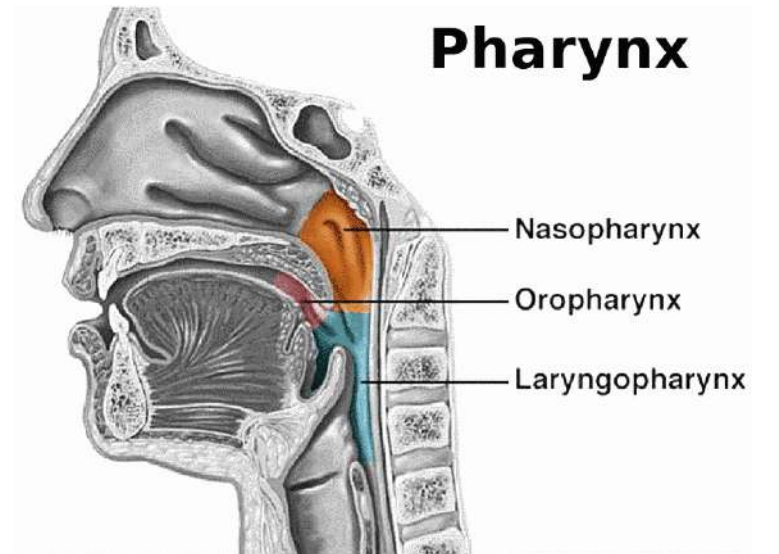
Sublingual Hematoma

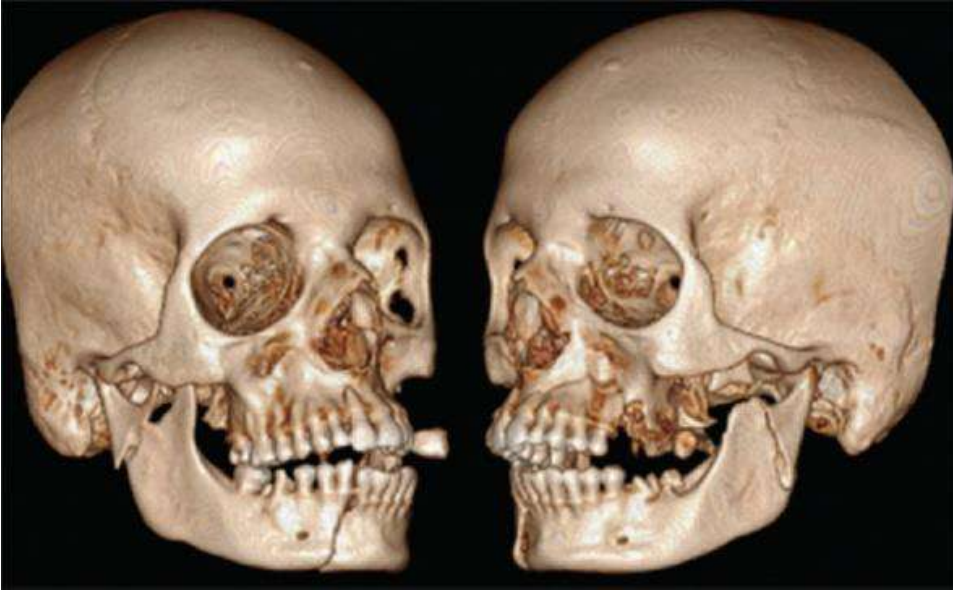

©Association of Oral and Maxillofacial Surgeons of India

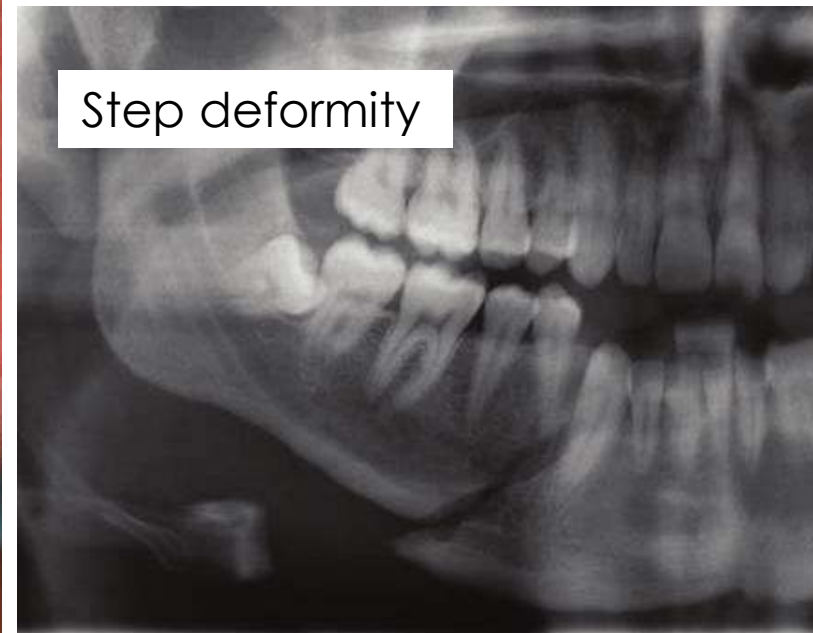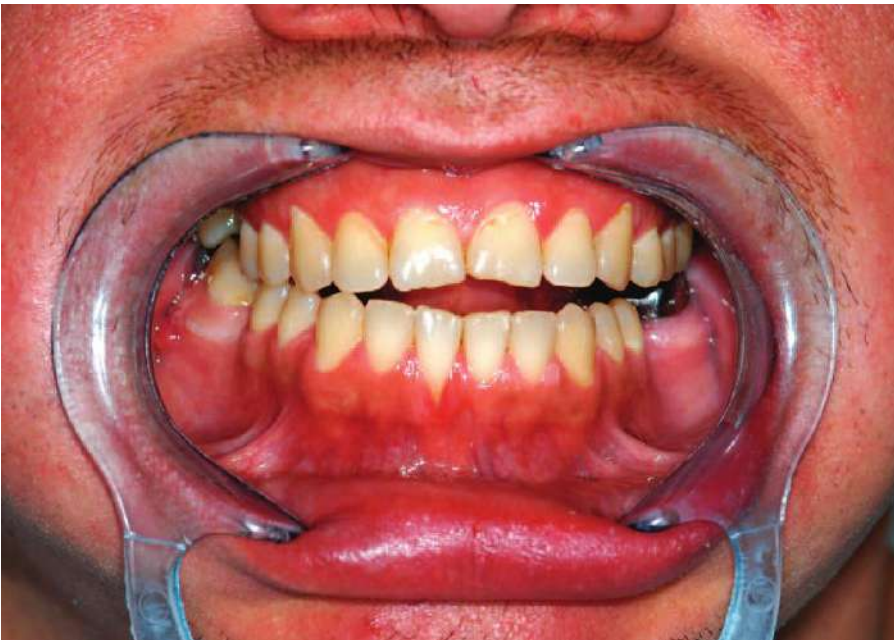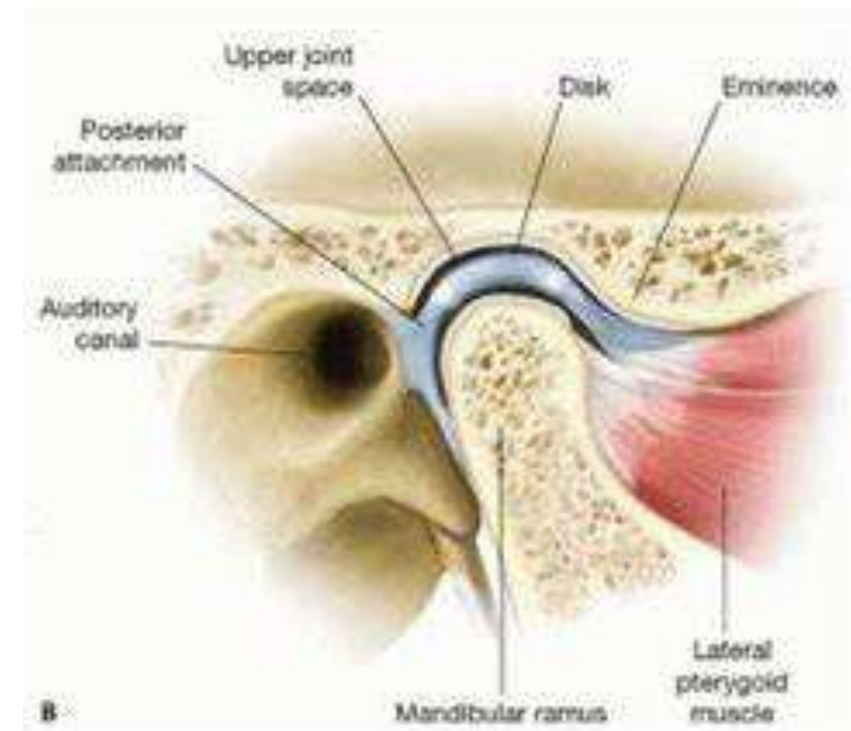


Pharynx

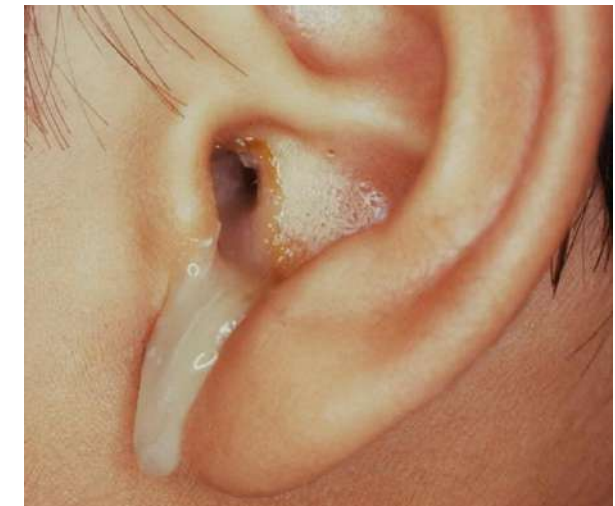



Bilateral Subcondylar #
with Anterior Open Bite.

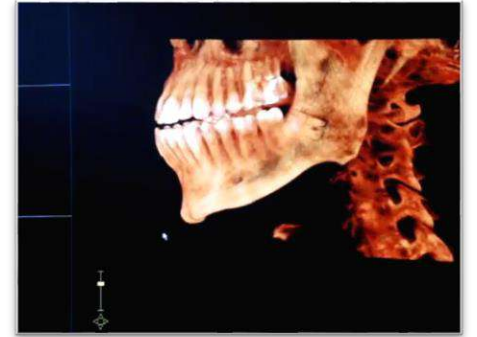

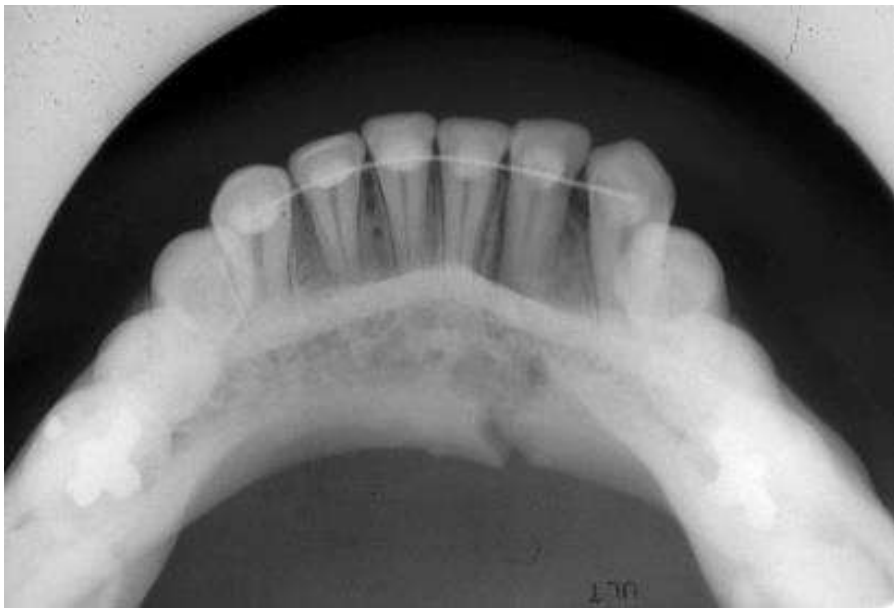
Cerebrospinal Otorrhea



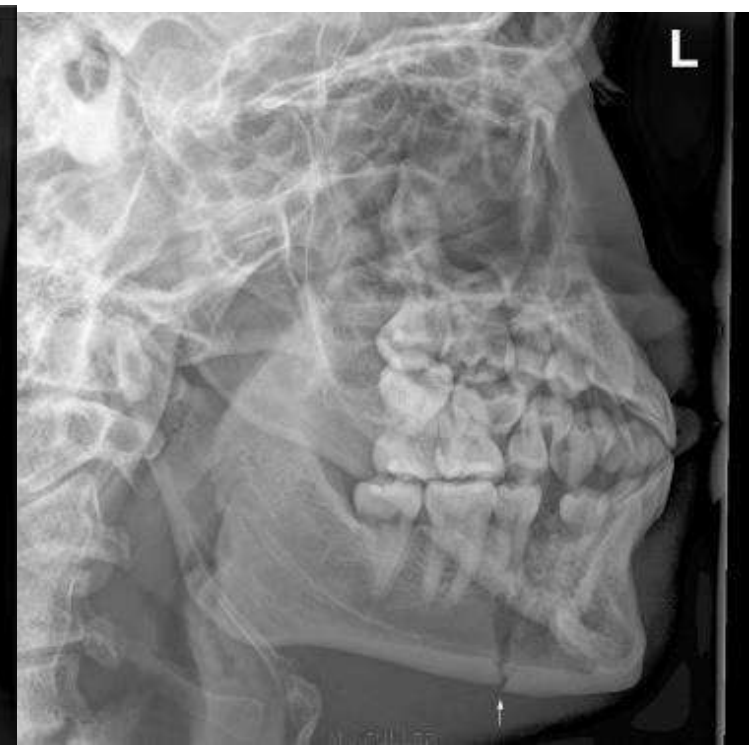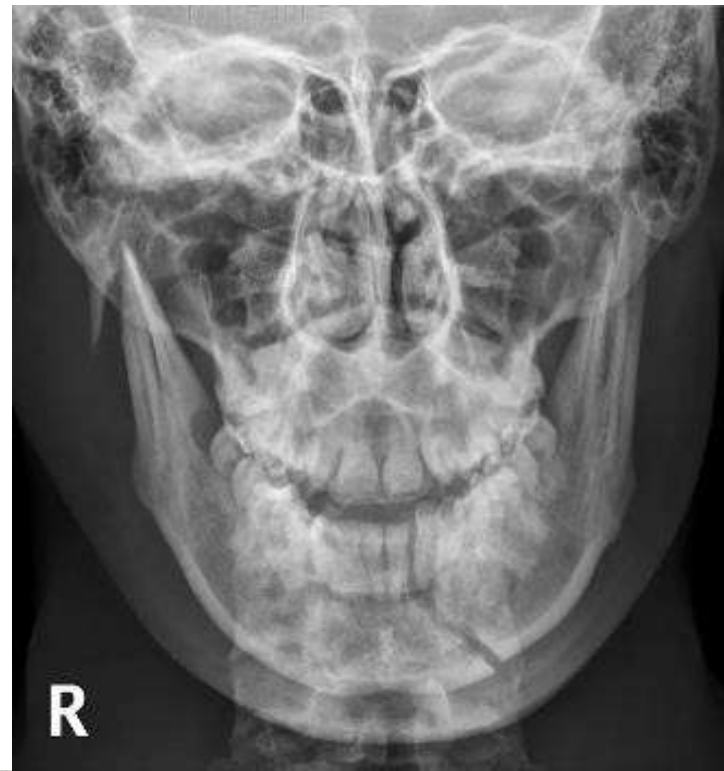IMAGING

- ▶ The principle is to obtain at least two views, each taken at right angles to the other, in order to assess the degree of displacement and angulation of the fragments.
- ▶ Occlusal views demonstrating midline fractures of the mandible.
- ▶ PA mandible view and (left and right) Oblique Lateral view.
- ▶ A Panoramic Radiograph (OPG) represents the best single overall view.
- ▶ CBCT - cone-beam CT is superior to standard and panoramic views.
- ▶ CT scan for complicated fracture and assessment of displaced condylar fractures.

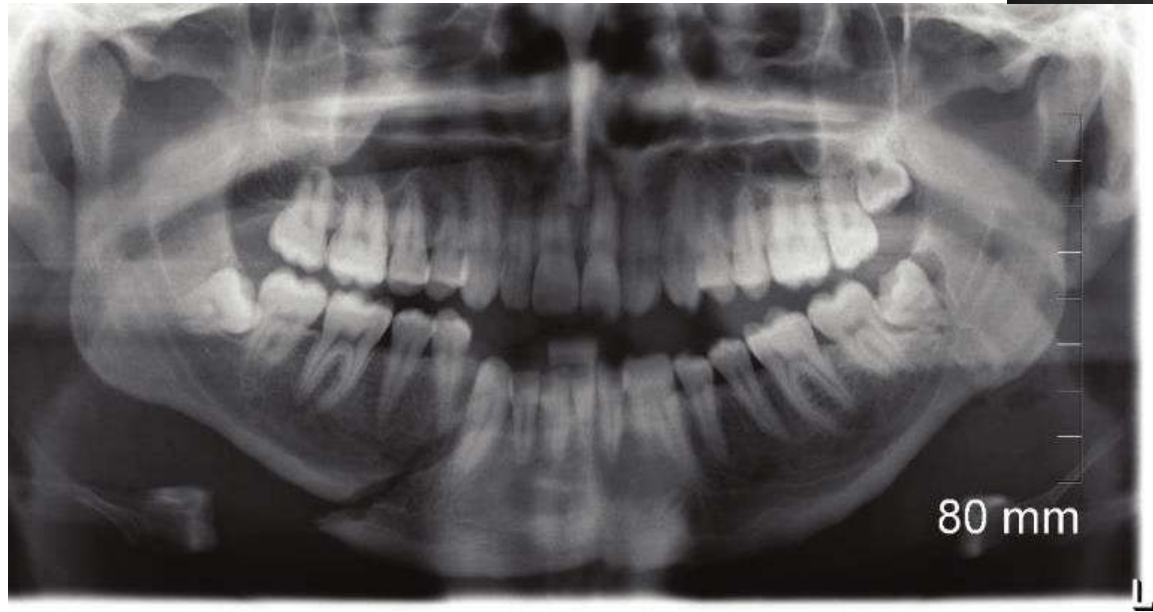



Occlusal view



PA mandible view and Oblique Lateral view.



TREATMENT

► The Aim of treatment is to restore **Function, Occlusion and Pain-free** TMJs movements.

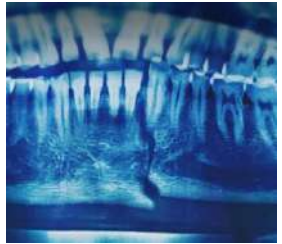
The Principles of Treatment of fractures are: **Reduction, Fixation, and Immobilization.**

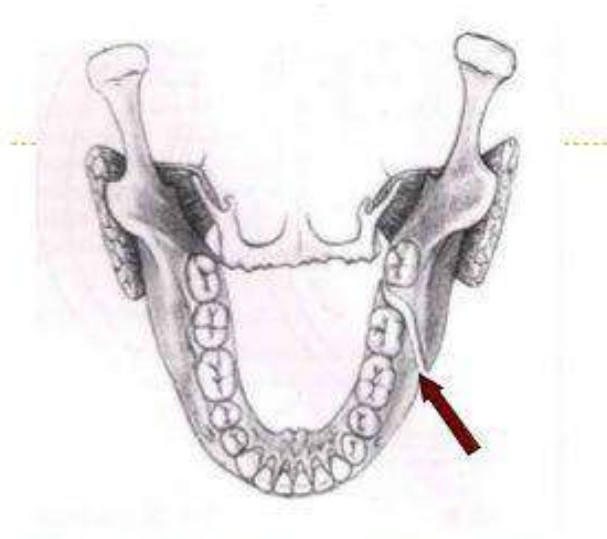
Factors affecting treatment of Mandibular Fractures

1. The fracture pattern.
2. The skill of the operator.
3. The resources available.
4. The general medical condition of the patient.
5. The presence of other injuries.
6. The degree of local contamination and infection.
7. Associated soft-tissue injury or loss.

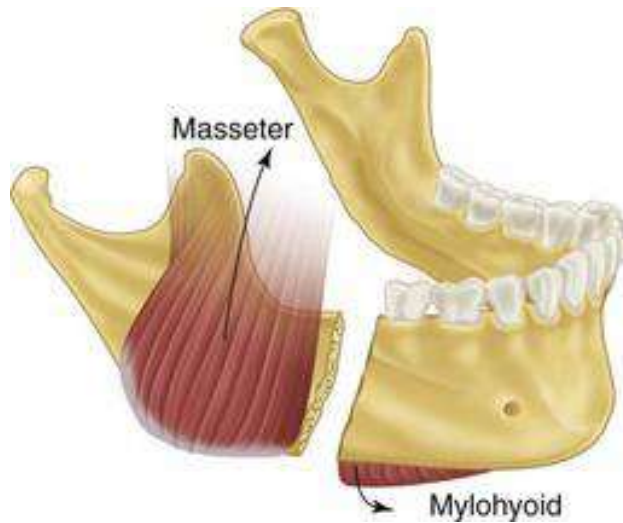
Treatment can be **Closed** or **Open**

- Closed Treatment - closed reduction with indirect fixation and immobilization with intermaxillary fixation (IMF).
- Achieved **without** surgical exposure of the fracture site, to place the teeth in normal occlusion and immobilize them **thus indirectly reduce the bone fragments**.
- It is the **Traditional Conservative Treatment** of mandibular fractures.
- Also used as temporary fragment stabilization in emergency cases.
- The main **Indications** of closed treatment are:
 - Non-displaced favorable fractures.
 - Limited resources and facilities for open treatment.
 - Medically compromised patients.
 - Grossly infected fractures.
 - Pediatric fractures with mixed dentition phase.
 - Edentulous fractures.

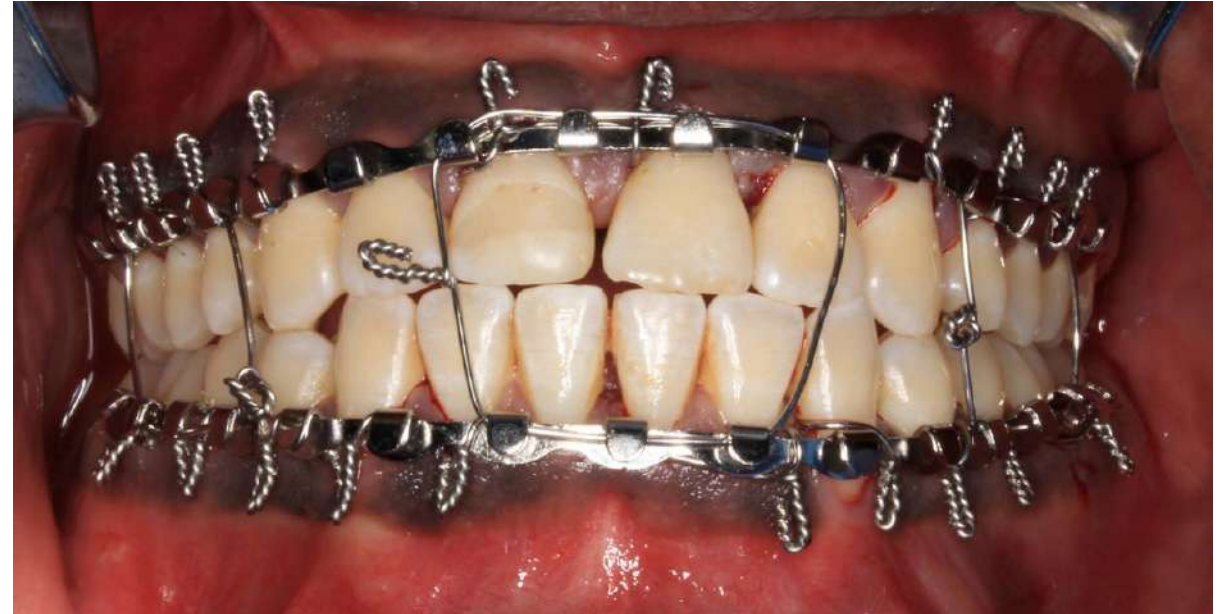



Non-displaced Favorable Fracture



Displaced Unfavorable Fracture



Intermaxillary Fixation - IMF

Methods of Immobilization

- ▶ After proper reduction (good occlusion), both jaws immobilized by fixing them together in occlusal relationship by IMF, this can be achieved by:

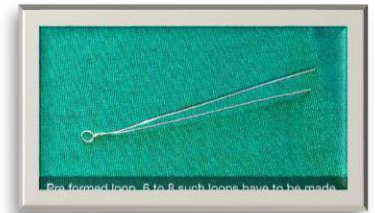1. **Bonded Orthodontic Brackets** - By bonding a number of modified orthodontic brackets and applying intermaxillary elastic bands.

2. **Interdental Wiring** – indicated in patient with suitable number of teeth.

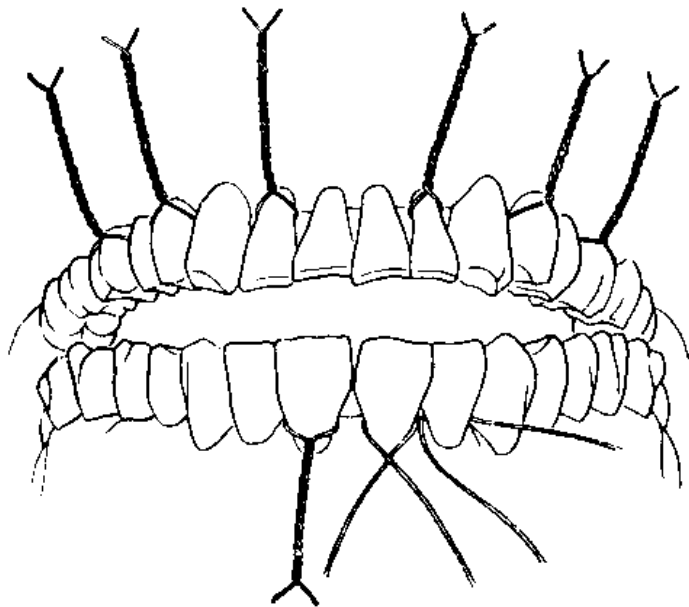
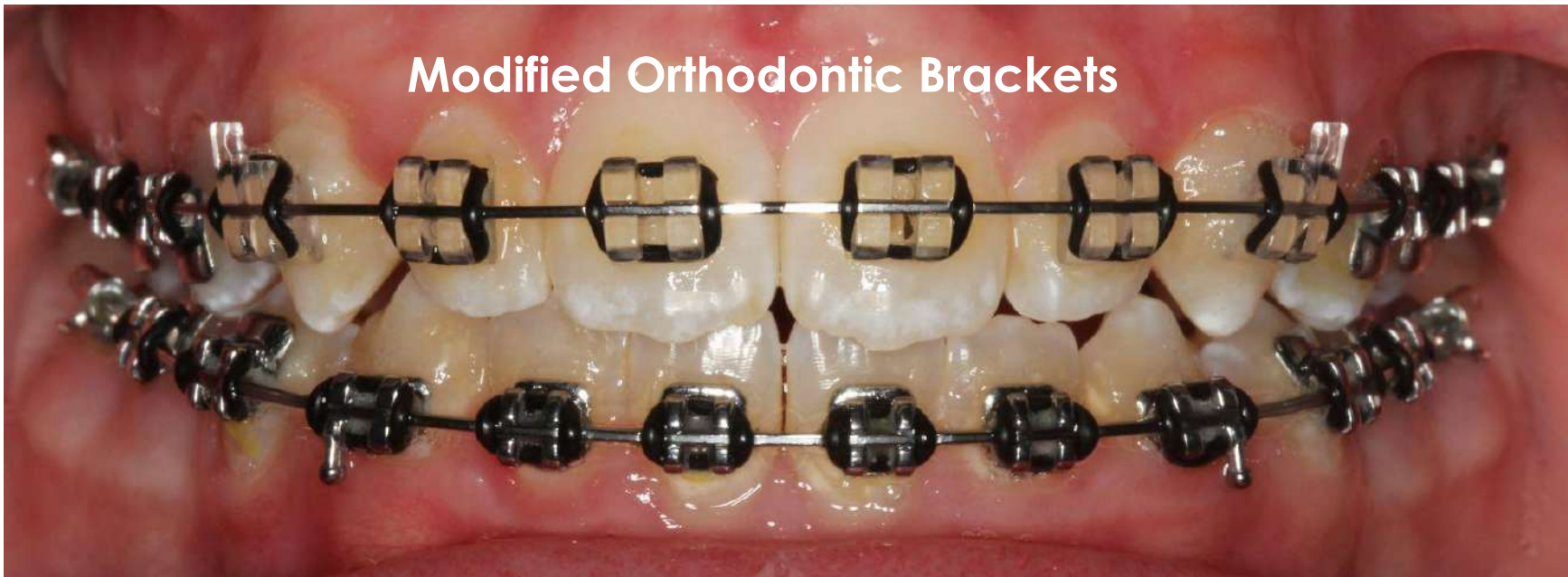- ▶ Surgical soft stainless 0.5 mm wire is used.

- ▶ Different techniques exist such as **Direct Interdental Wiring and Eyelet Loops**.


- ▶ After applying the fixation wires, tie wires are applied to immobilize the mandible.



Modified Orthodontic Brackets

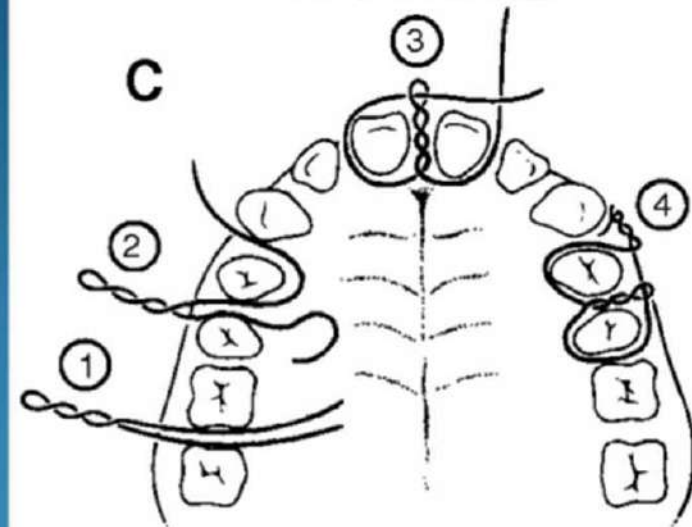



Interdental wiring



Juniordentist.com

FIXING AN EYELET



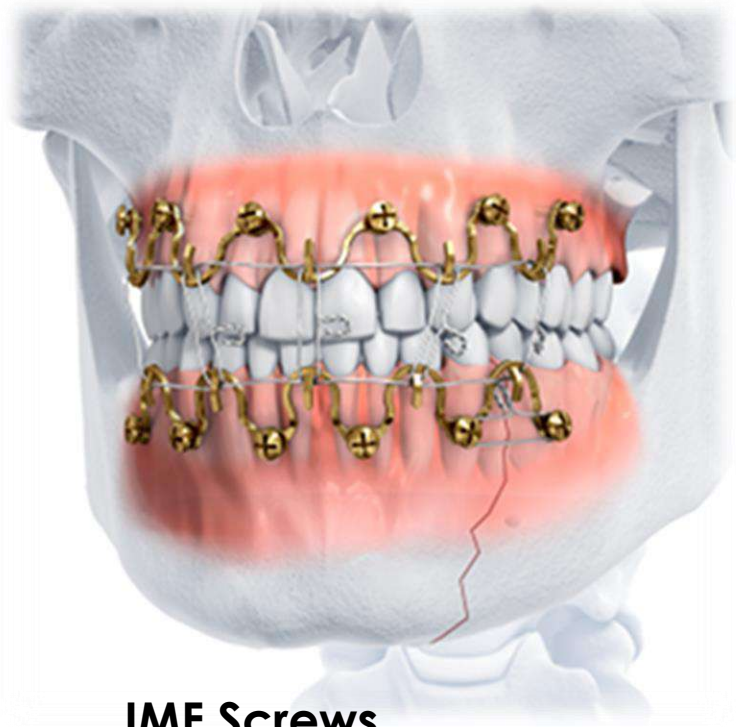3- Arch Bars

- ▶ A special metallic bar connected to teeth, used in IMF of dentate patients.
- ▶ They are the Most Versatile Form of IMF.
- ▶ Indicated in patient with sufficient number of teeth.
- ▶ Custom made or manufactured, available in aluminum, stainless steel, and titanium.
- ▶ Most pattern is Erich Arch Bar.

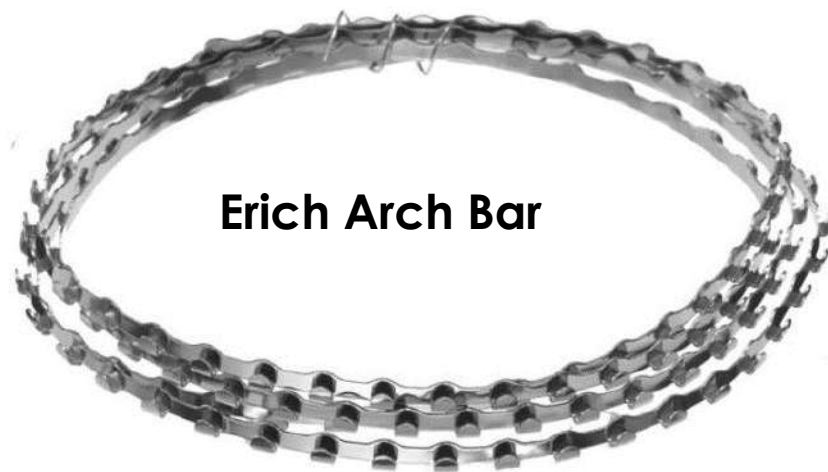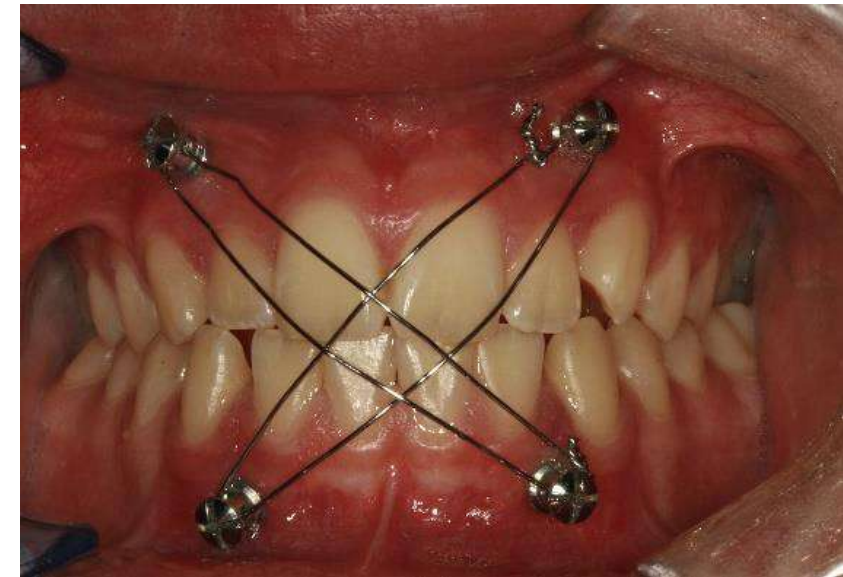
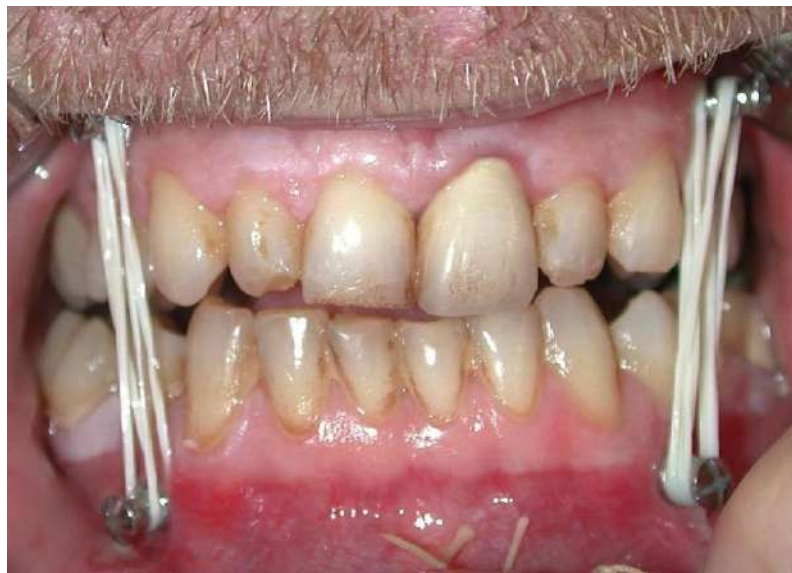4- IMF Screws

Self-drilling screws inserted through small incisions in the labial vestibule, it is regarded as a **rapid method to achieve IMF**.

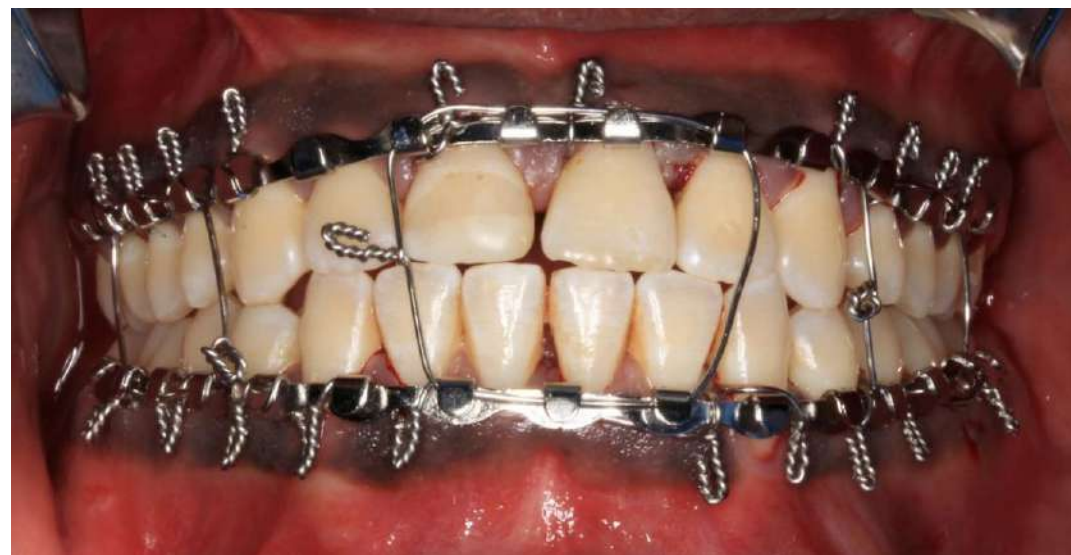



IMF Screws

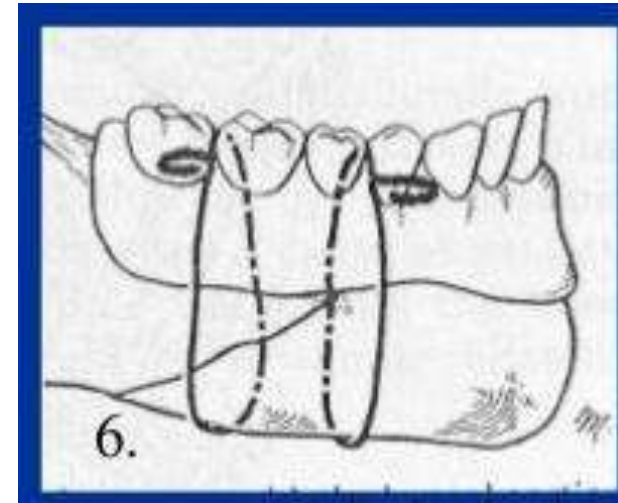


Erich Arch Bar



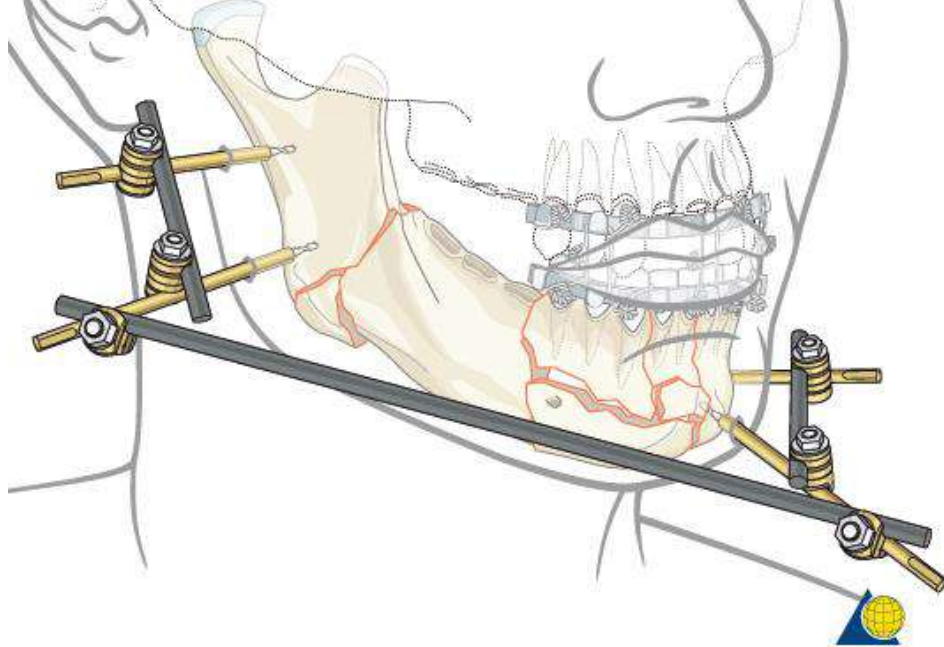
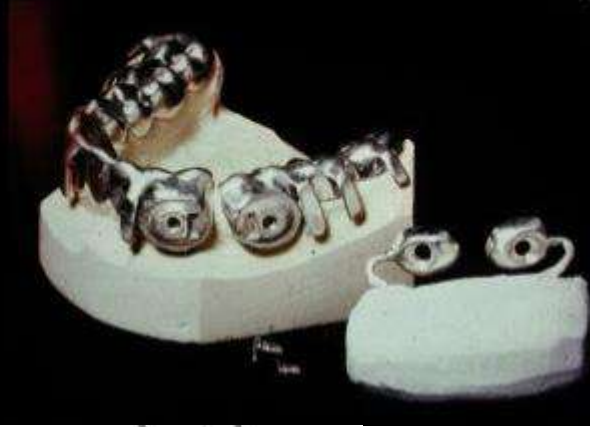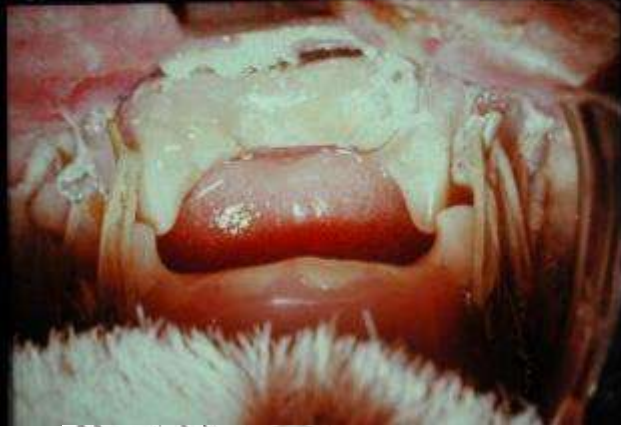- ▶ 5- **Cap splints** - They are made of acrylic or metal can be fabricated and used for fixation of the fracture.
- ▶ 6- **Dentures or Gunning-type splints** - In edentulous jaw, complete denture used as a splint and Gunning-type splints for non denture wearer. They are fixed to the jaws by circum-mandibular and maxillary peralveolar wires or screws.
- ▶ 7- **External pin fixation** - This method is seldom used nowadays, it is indicated in special conditions, such as infected fractures, fractures caused by gunshot injuries or pathological fractures.

circum-mandibular wires

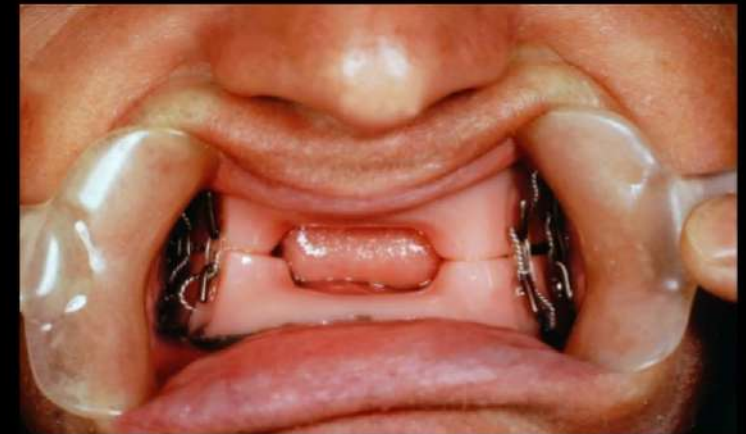

Gunning splint

Cap splint



Gunning Splints



Period of Immobilization

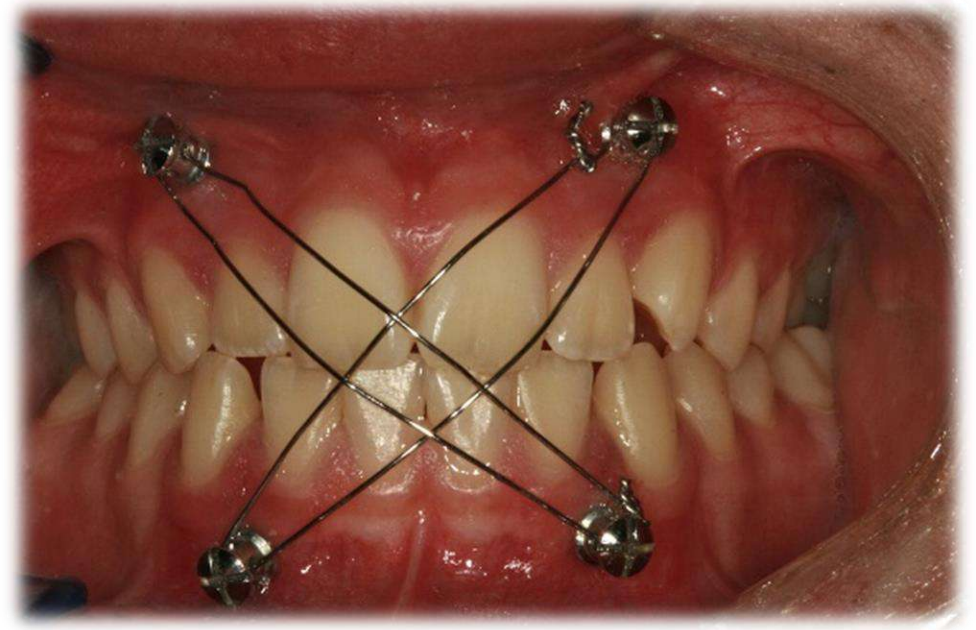
- ▶ Early treatment in a healthy young adult union, **fixation released after 3 weeks.**
- ▶ As a principle guide a further 1–2 weeks added for each of the following circumstances:
 1. Tooth retained in the fracture line.
 2. Patients over 40 years.
 3. Smoker Patient.
 4. Comminuted Fractures.

Advantages of closed treatment

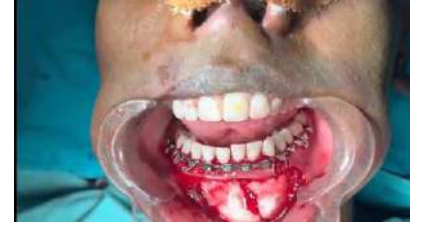- ▶ Non-invasive, simple, easy to master.
- ▶ Can be performed under local anesthesia.
- ▶ Less expensive.

Disadvantages of closed treatment

- ▶ Does not ensure anatomical reduction of the fracture.
- ▶ Difficult especially in cases of malocclusion, missing, diseased, or damaged teeth.
- ▶ The immobilization may not be perfect, so delays the healing.
- ▶ Morbidity to the patient due to the effect on feeding and speech.
- ▶ Closed treatment is **contraindicated** in some conditions, e.g., epilepsy, chronic respiratory diseases, in compliant patient, or chronic alcohol or drug abuse.



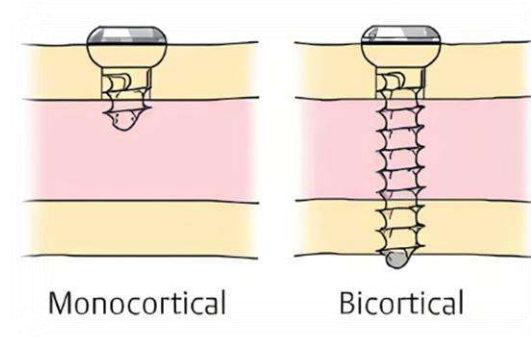
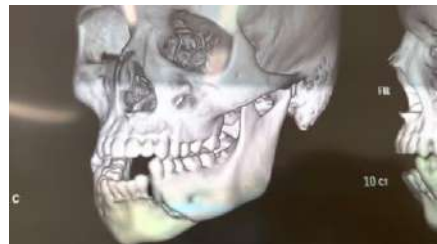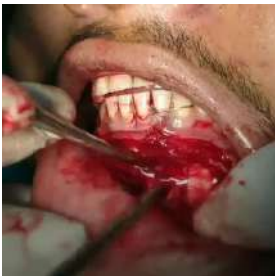Open Treatment



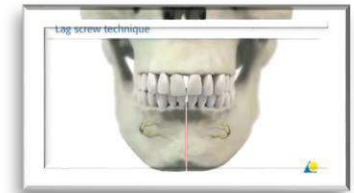
- ▶ It consists of **Open Reduction and Internal Fixation** (ORIF).
- ▶ The fracture surgically exposed and reduced under **Direct Vision** and the fragments are immobilized by **Internal Direct Fixation**.
- ▶ The main Indications for open treatment:
 1. Displaced unfavorable fractures.
 2. Multiple fractures of the facial bones
 3. Fractures of an edentulous mandible with severe displacement.
 4. Interposition of soft tissue between displaced fragments.
 5. Special systemic conditions contraindicating IMF.

Methods of Internal Fixation (Osteosynthesis)

- **Transosseous Wiring (Non-Rigid Fixation)** It is the direct fixation of two or more bone fragments with the aid of wire ligatures pulled through previously drilled holes.
- **Miniplates (Semi-rigid Fixation)** Most common form of internal mandibular fixation. The plate fixed using the outer cortical bone “monocortical” screws (2 mm diameter).
- Three-dimensional titanium miniplates - They are based on the principle of the geometrically stable configuration for support.

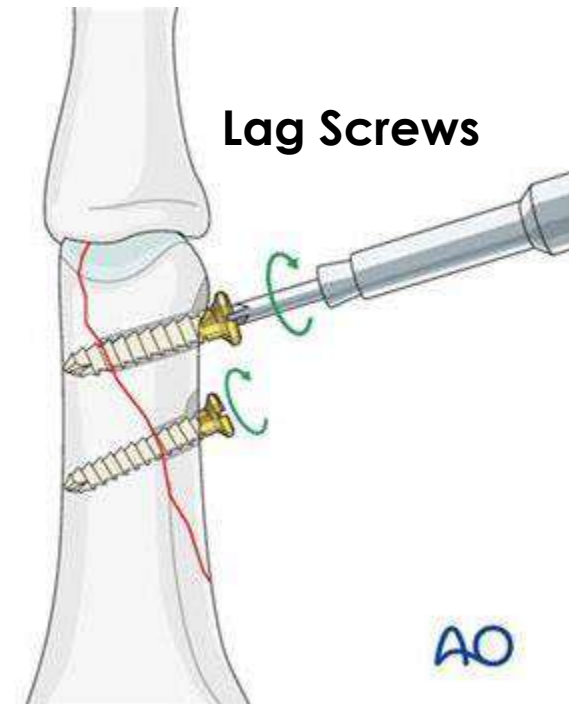
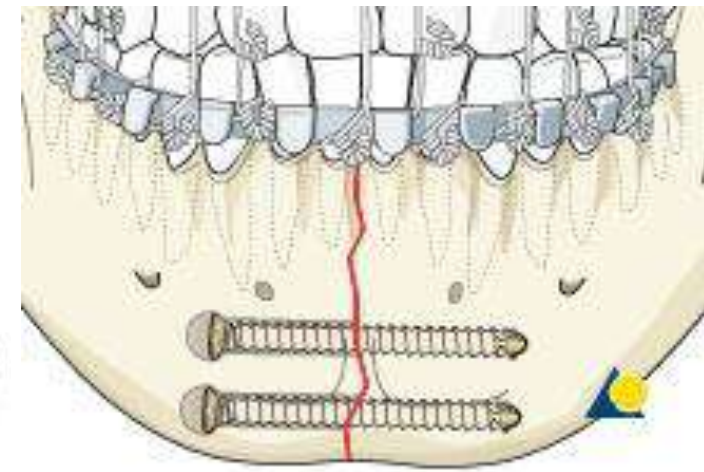
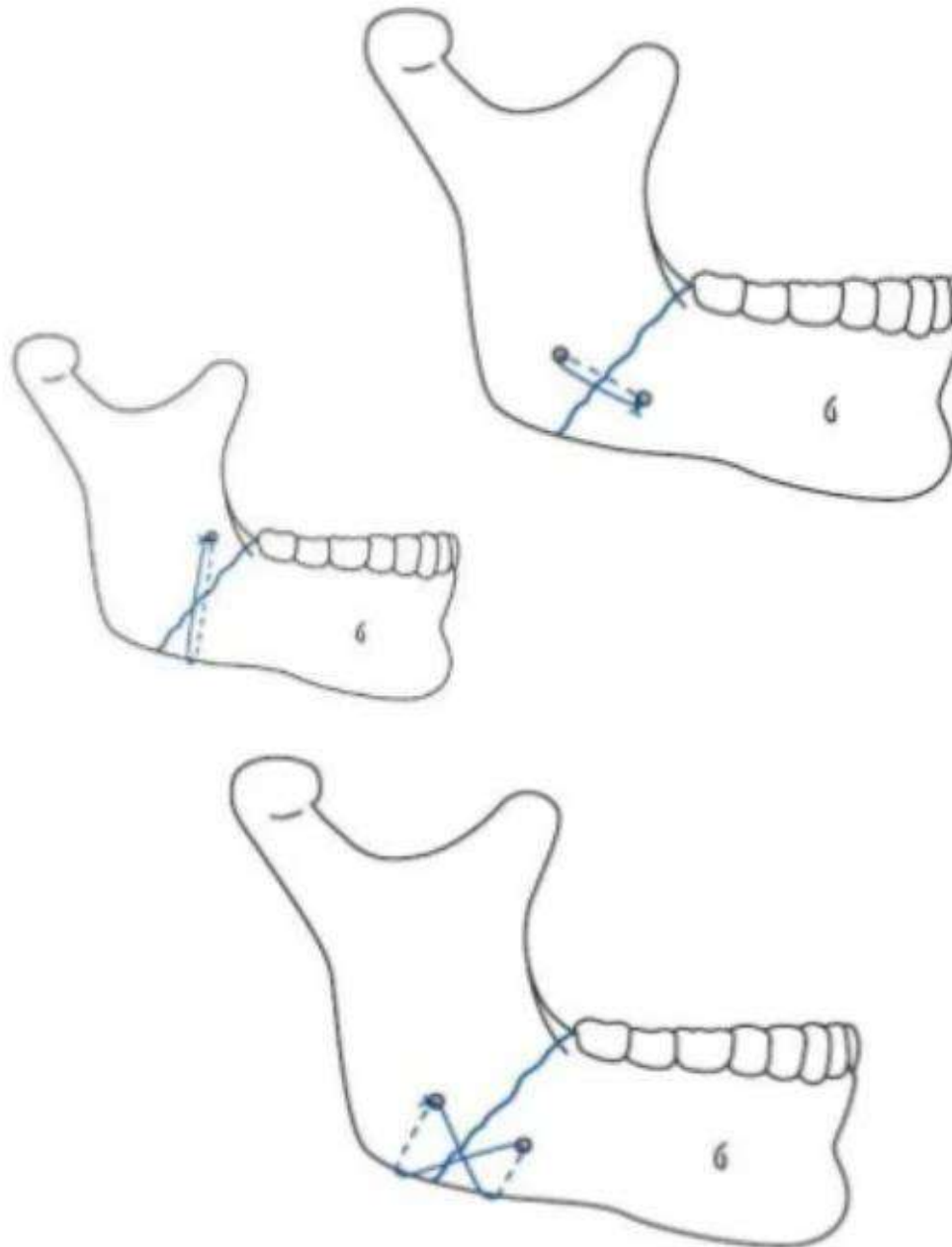
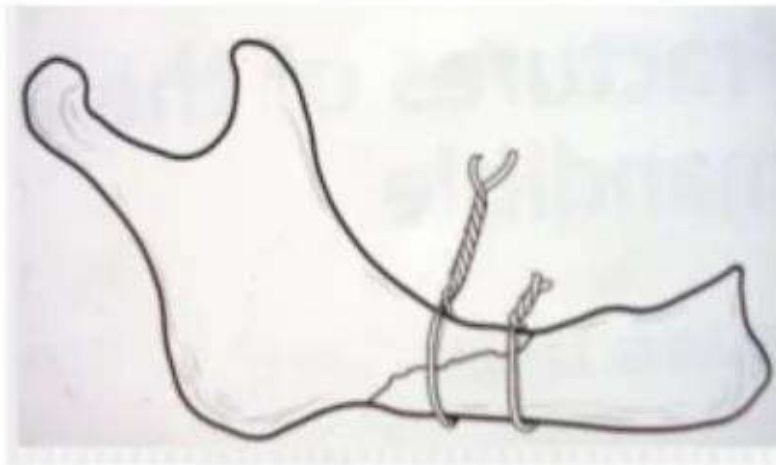


- ❑ **Non compression (Reconstruction) plates - Rigid Fixation**, used for infected, comminuted, in continuity defects and in non-union fractures. They require bicortical screws.
- ❑ **Compression plates** - rigid fixation, the principle of compression plating is by transforming the downward force of screw insertion into a compressive force.
- ❑ **Lag Screws** - In oblique fractures, compression lag screws, placed perpendicular across the fracture line.
- ❑ **Bioabsorbable Plates and Screws** - made from materials that undergo degradation, so they do not have to be removed after fracture healing.



Non rigid fixation with intraosseous wiring:

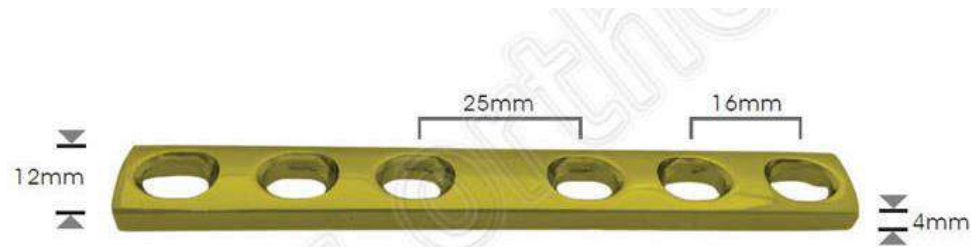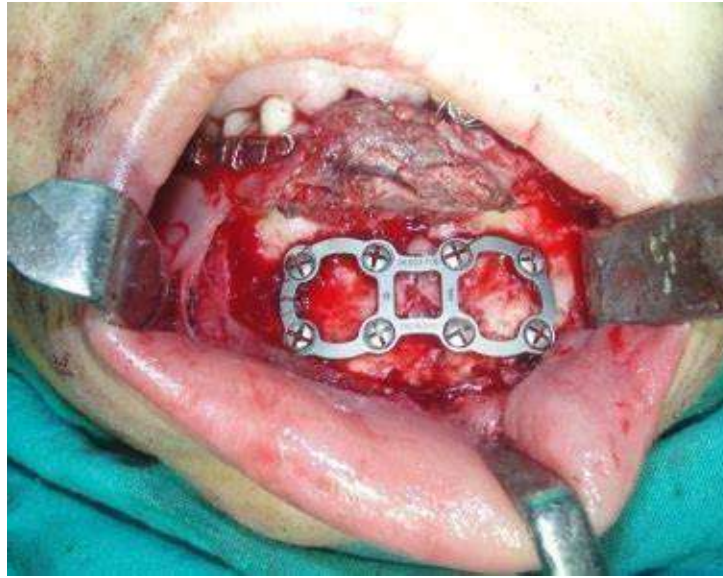
- Straight wire
- Figure of eight
- Transosseous circum-mandibular



Titanium Miniplates



Three-dimensional titanium miniplates



(Reconstruction plates)

Compression plates



Teeth in The Line of Fracture

- ▶ Teeth in the fracture line may cause infection of the fracture site. which result in delayed healing or even non-union.

Absolute Indications for Removal of a tooth from the Fracture Line:

1. Longitudinal root fracture.
 2. Dislocation or subluxation of the tooth from its socket.
 3. Presence of periapical infection.
 4. Advanced periodontal disease.
 5. Already infected fracture line.
 6. Acute pericoronitis.
 7. Where a displaced tooth prevents reduction of the fracture.
- ▶ Teeth in line of fracture should be followed up for 1 year.
 - ▶ If fracture becomes infected, immediate extraction should be performed.

Relative indications

1. Functionless tooth that would probably be removed.
2. Advanced caries.
3. Doubtful teeth that could be added to existing dentures.

Complications of Mandibular Fractures

► Intraoperative and Early Postoperative Complications

- 1- Misplaced fixation
- 2- Infection of the fracture site
- 3- Nerve damage

► Late Complications

- 1- Malunion
- 2- Delayed union
- 3- Non-union
- 4- Complications associated with internal fixation
- 5- Sequestration of bone

1- Misplaced Fixation

- ▶ Damage caused by misplaced fixation devices like transosseous wires or plates, the risk of damage to structures is less when using mono-cortical screws.

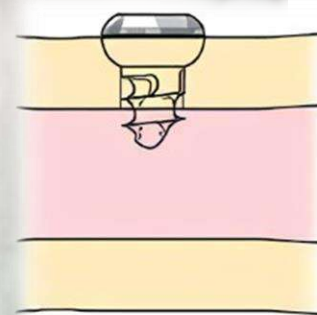
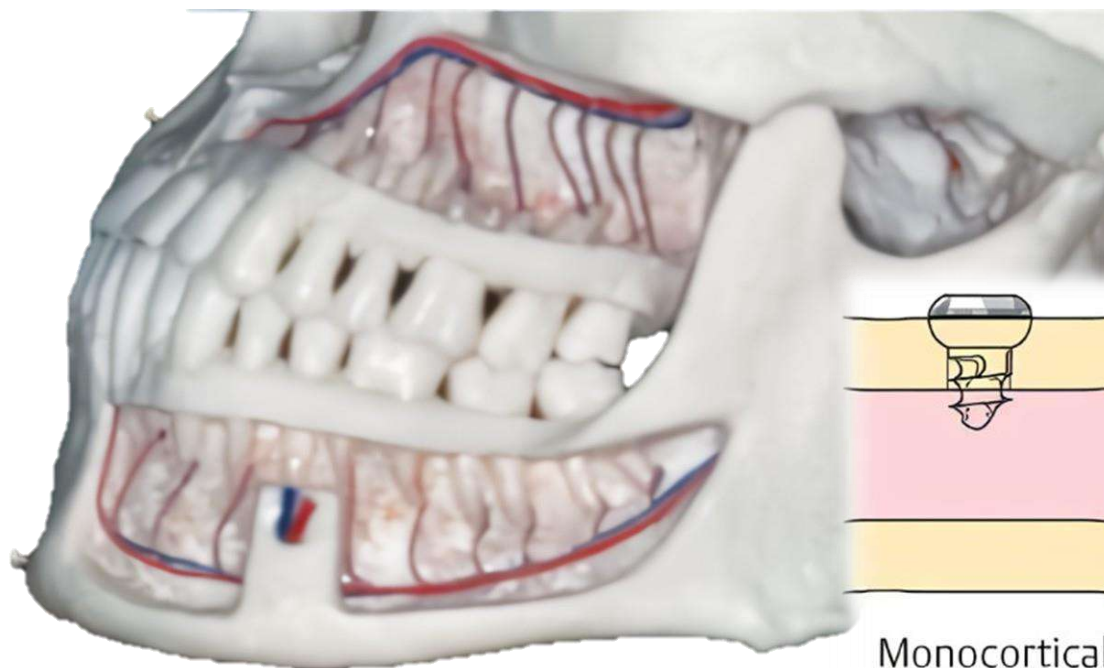
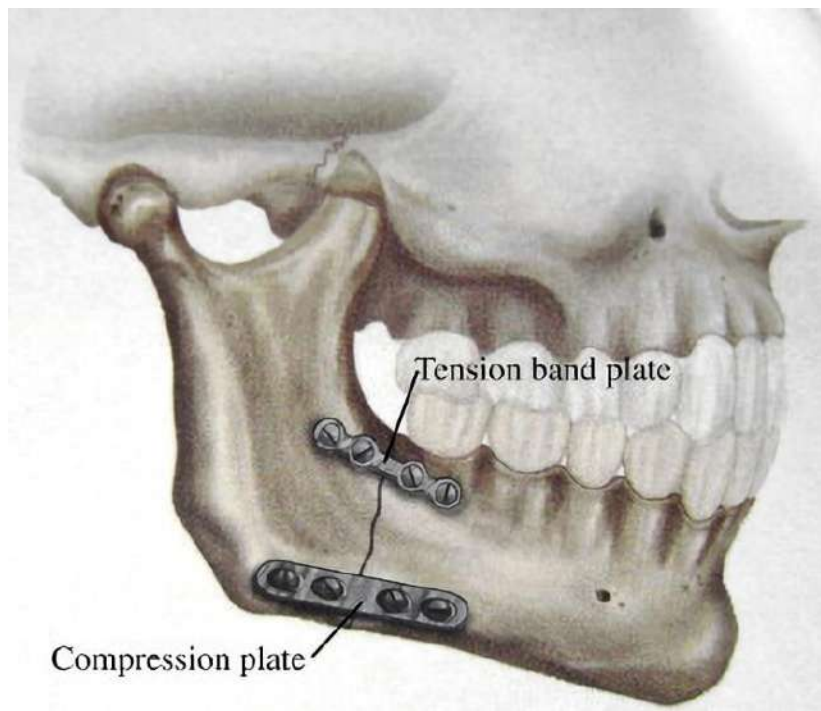
2- Infection of the Fracture Site

The Principles of Management are

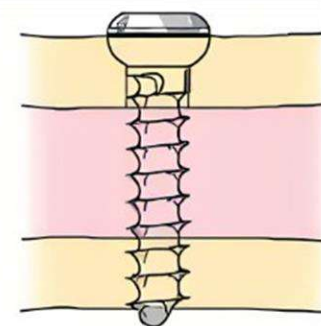
- ▶ Control the infection (incision and drainage, and antibiotics)
- ▶ Remove any focus of infection (teeth, sequestra, or plates and screws)
- ▶ Optimize the healing environment (patient's health, oral health)
- ▶ Immobilize the fracture.

3- Nerve Damage

- ▶ Paresthesia of lower lip as a result of injury to the inferior dental nerve is the **most common complication**, mostly associated with open treatment.
- ▶ **Facial nerve damage** may complicate some fractures of the ramus and condyle, either as a result of a penetrating injury severing branches of the nerve, or blunt trauma.

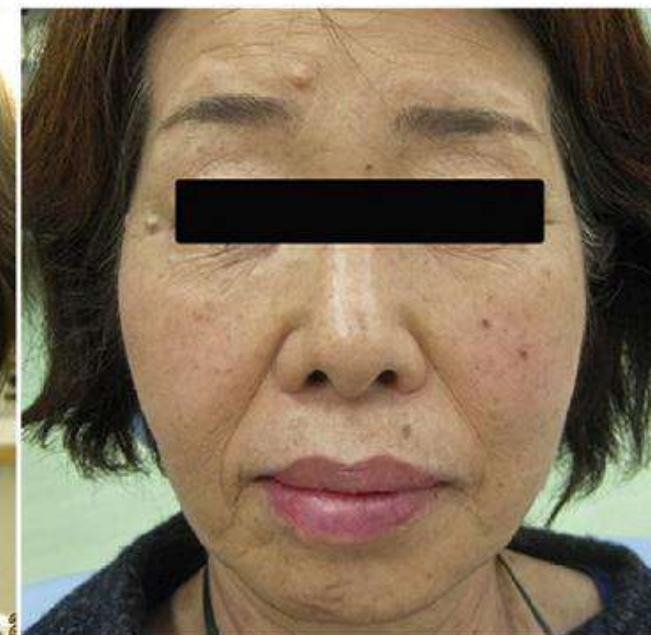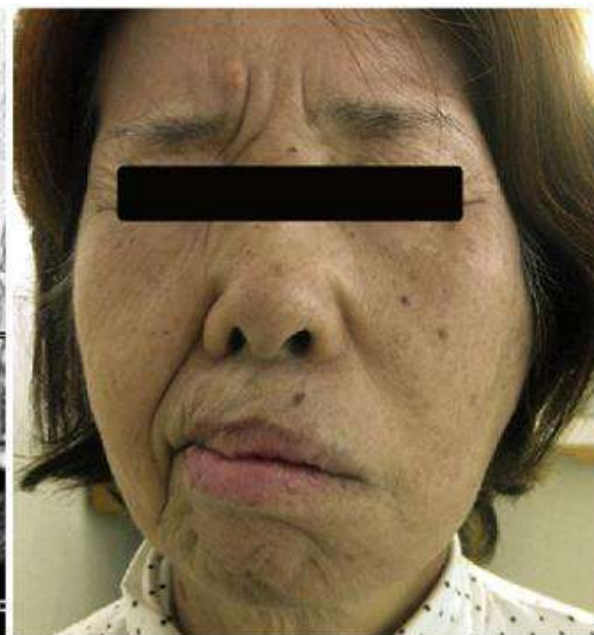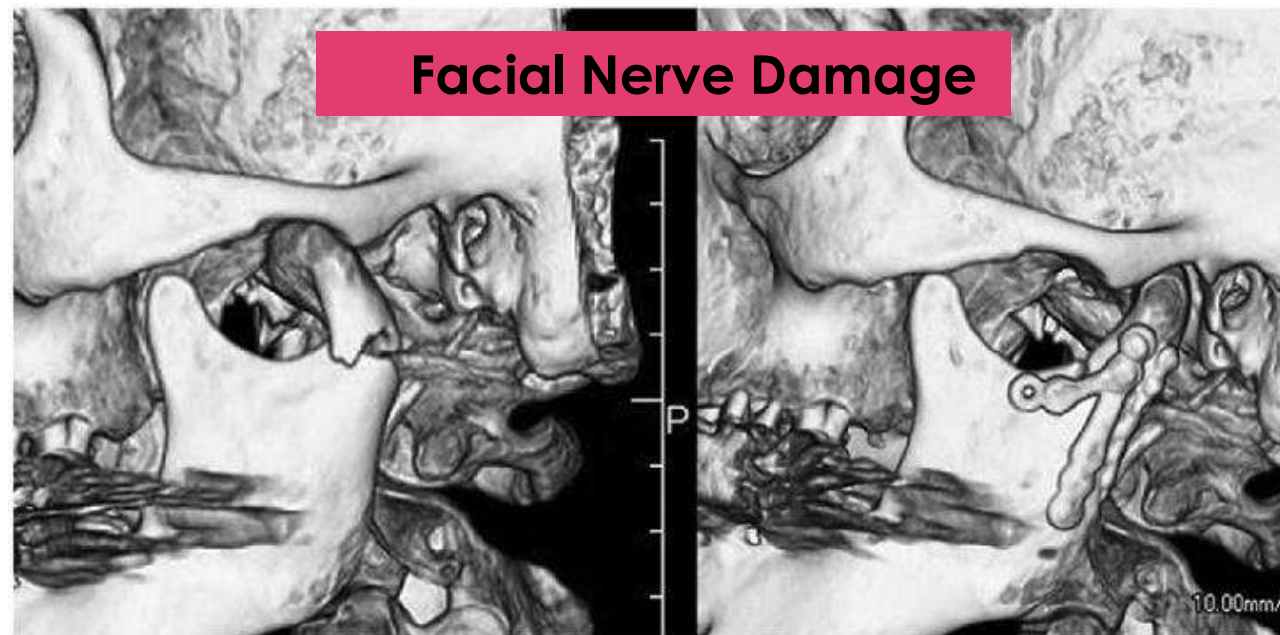


Monocortical



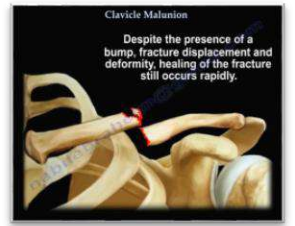
Bicortical

Facial Nerve Damage



LATE COMPLICATIONS

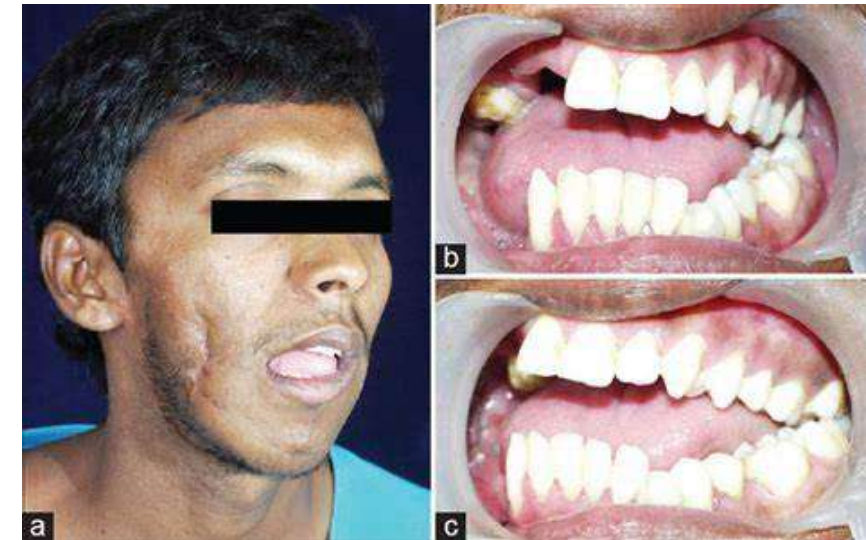1- Malunion



- ▶ The healing of the fracture in an abnormal or non-anatomical position. It can occur as a result of inadequate reduction, immobilization or if no treatment is done.
- ▶ **Minor Malunion** do not usually cause major problems, because the dentition often readjusts to a new bite.
- ▶ **Significant Malunion** of the mandible produce gross occlusal derangement and facial deformity, resolved by refracture with rigid fixation, bone graft may be required in some cases.

2- Delayed Union

- It occurs when the union is delayed beyond the expected time for that particular fracture.
- The delay in union is **managed by** prolonging the period of immobilization.



3- Non-Union

It is failure of the fracture to unite on its own.

- ▶ In nonunion, the fracture line filled by fibrous tissue rather than the bone, and pseudarthrosis (false joint) results.
- ▶ Treatment is surgical exploration of the fracture site. The bone ends freshened and immobilized with rigid fixation. Bone graft may be needed.

4- Complications associated with internal fixation These may include

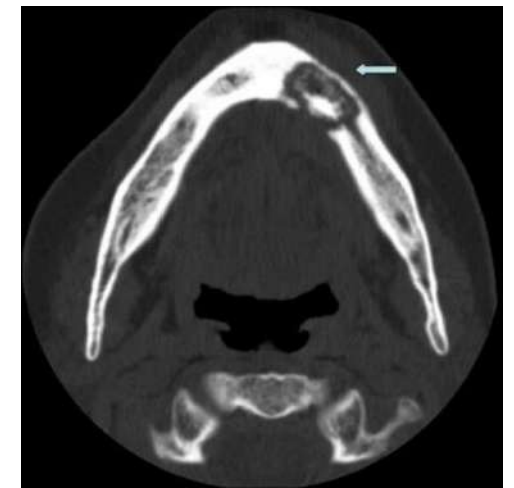
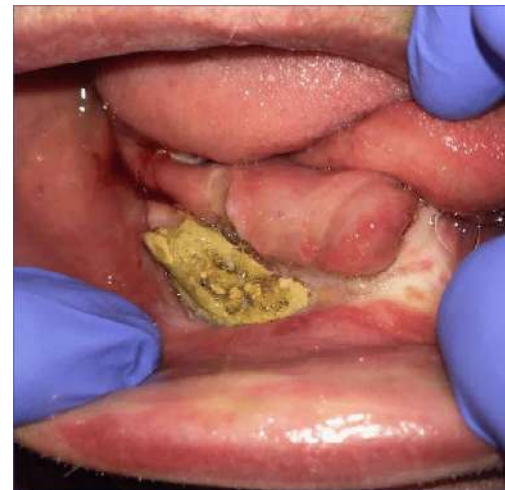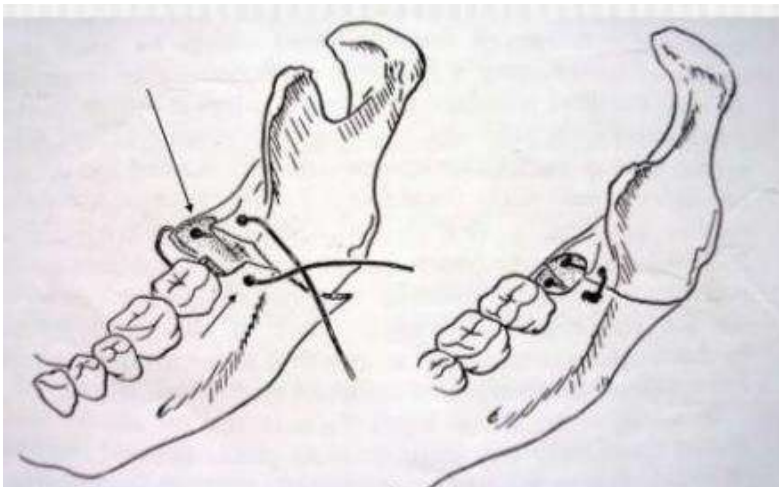
- ▶ Exposure of the plates especially when placed near the oral mucosa.
- ▶ Plates may also become infected.
- ▶ Transosseous wires may cause pain or discomfort.

- Non-union can be caused by Local or General Factors:

1. Infection of the fracture site.
2. Inadequate immobilization and excessive mobility of fractured fragments.
3. Unsatisfactory apposition of bone ends with interposition of soft tissue.
4. The ultra-thin edentulous mandible in an elderly debilitated patient.
5. Loss of bone and soft tissue as a result of severe trauma, e.g. missile injury.
6. Inadequate blood supply to fracture site, e.g. after radiotherapy.
7. The presence of bone pathology, e.g. a malignant neoplasm.
8. General disease, e.g. osteoporosis, severe nutritional deficiency, disorders of calcium metabolism.

5- Sequestration of Bone

- ▶ Comminuted fractures may be complicated by the formation of **Bone Sequestra**.
- ▶ A **Sequestrum** may lead to delayed union or act as a potential source of infection.
- ▶ Management - a sequestrum may **extrude spontaneously** into the mouth, but otherwise a localized abscess forms and **Surgical Removal** of the dead bone becomes necessary.



Sequestration of bone

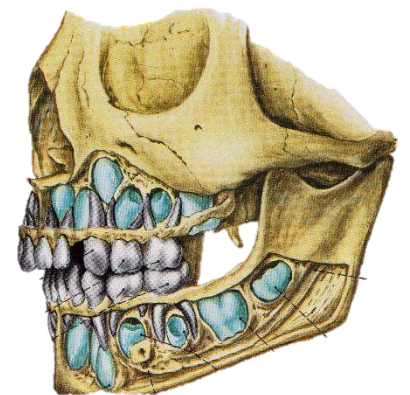
Mandibular Fractures That Require Special Considerations

Pediatric Fractures

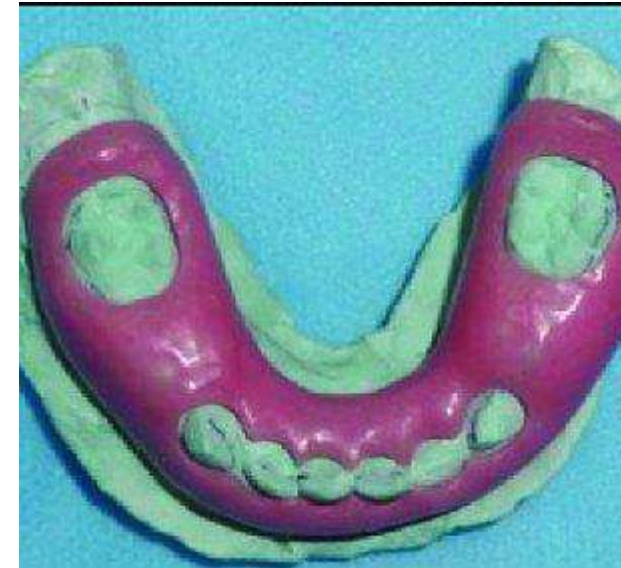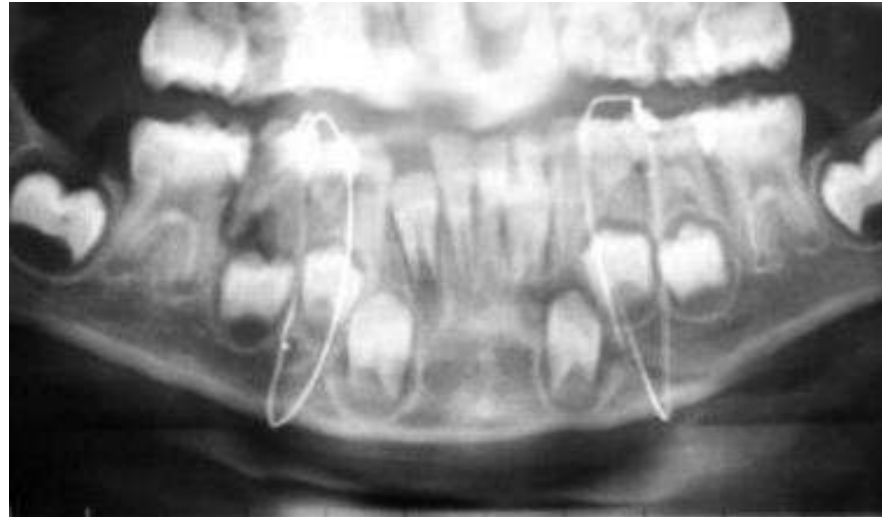
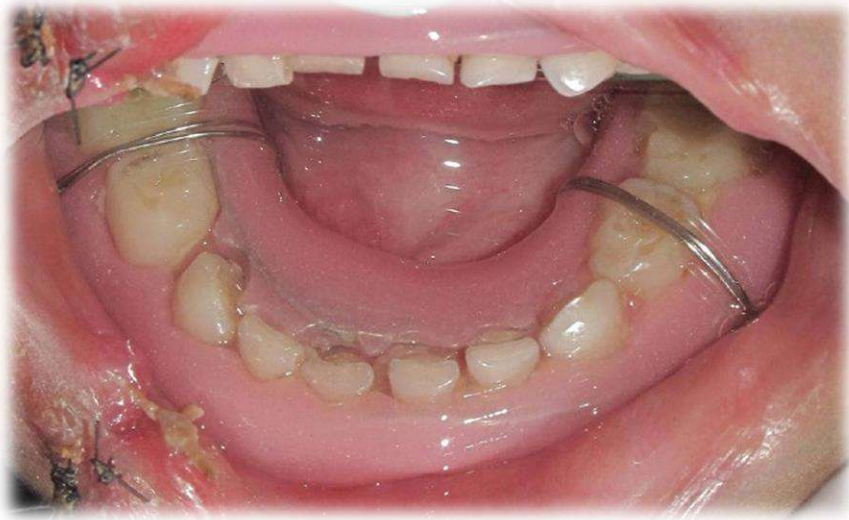
- ▶ Fractures of mandible uncommon in children and some modifications to the principles of treatment.

The main **Characteristics** of mandibular fractures in children are:

- ▶ Bone is resilient and greenstick fracture usually occur
- ▶ There is a greater risk of damage to developing teeth.
- ▶ the fractures heal rapidly, usually stable within a week, and firmly united within 3 weeks.
- ▶ Treatment is generally of a conservative nature.
- ▶ Mandibular fractures may disturb the growth of the mandible.
- ▶ Fractures of the condyle require special consideration.



- ▶ When fixation is needed, an **acrylic splint for the lower jaw alone** retained by two circum-mandibular wires.
- ▶ **Slight imperfection in reduction can be accepted**, because continuing growth and eruption of teeth will compensate for the imperfect alignment.
- ▶ **Prolonged follow-up is required to ensure normal mandibular growth** and the normal development of the permanent dentition.



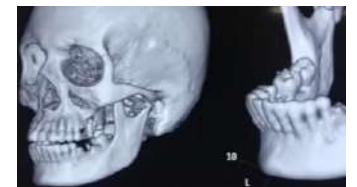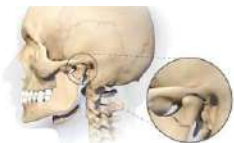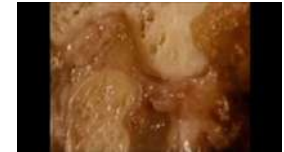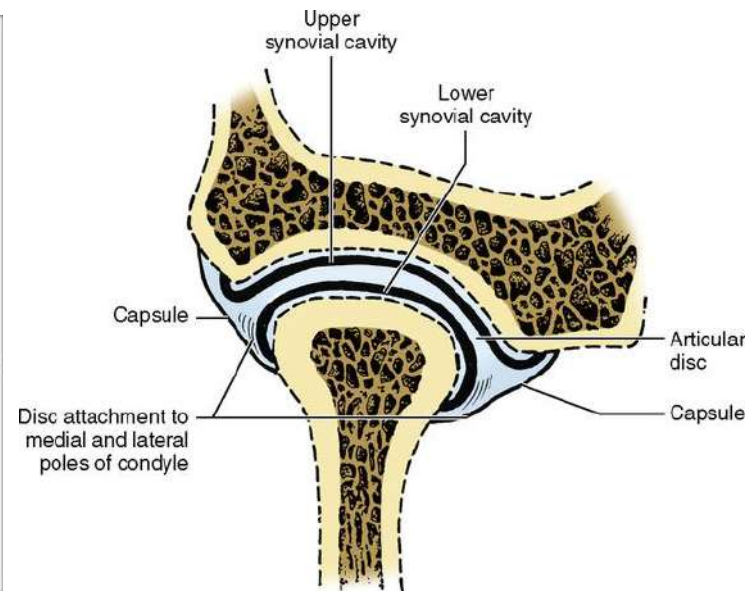
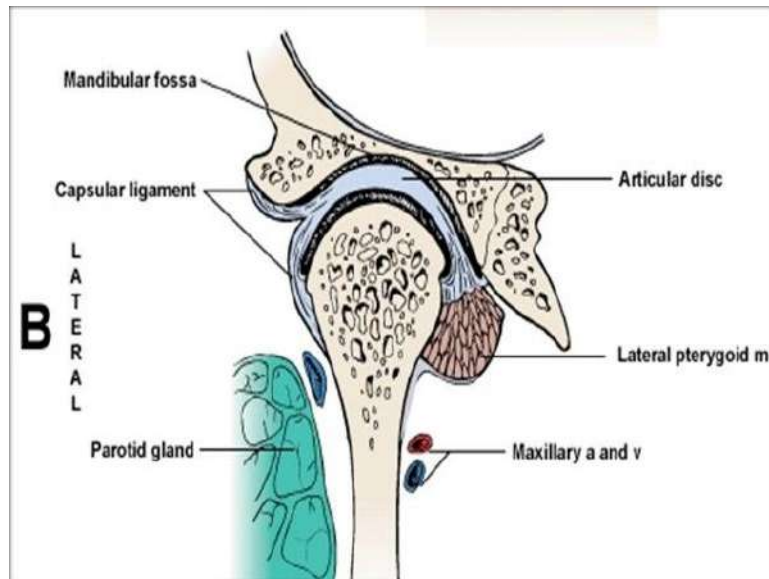
Fractures of the Condyle

► Classification

- Head of the condyle (Intracapsular)
- Neck of the condyle (Extracapsular)

► Treatment

- ❑ All intracapsular fractures and all fractures in growing children treated conservatively.
- ❑ Immediate or early mobilization should be encouraged.
- ❑ If occlusion is disturbed, IMF immobilization not exceed 10-21 days.

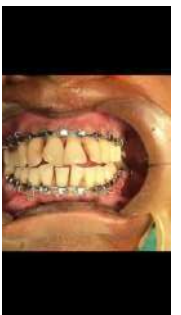

► **Absolute indications of ORIF:**

1. Displacement of condyle into middle cranial fossa
2. Impossibility of restoring occlusion with closed treatment.
3. Lateral extra-capsular displacement.
4. Invasion by foreign body (e.g. missile)

► **Relative indications:**

1. Bilateral fracture with associated mid-face fracture (particularly where one condylar fracture is dislocated or angulated)
2. Bilateral fracture with severe open bite deformity
3. Unilateral fracture with dislocation, overlap or significant angulation of the condylar head
4. When IMF is contraindicated for medical reasons.

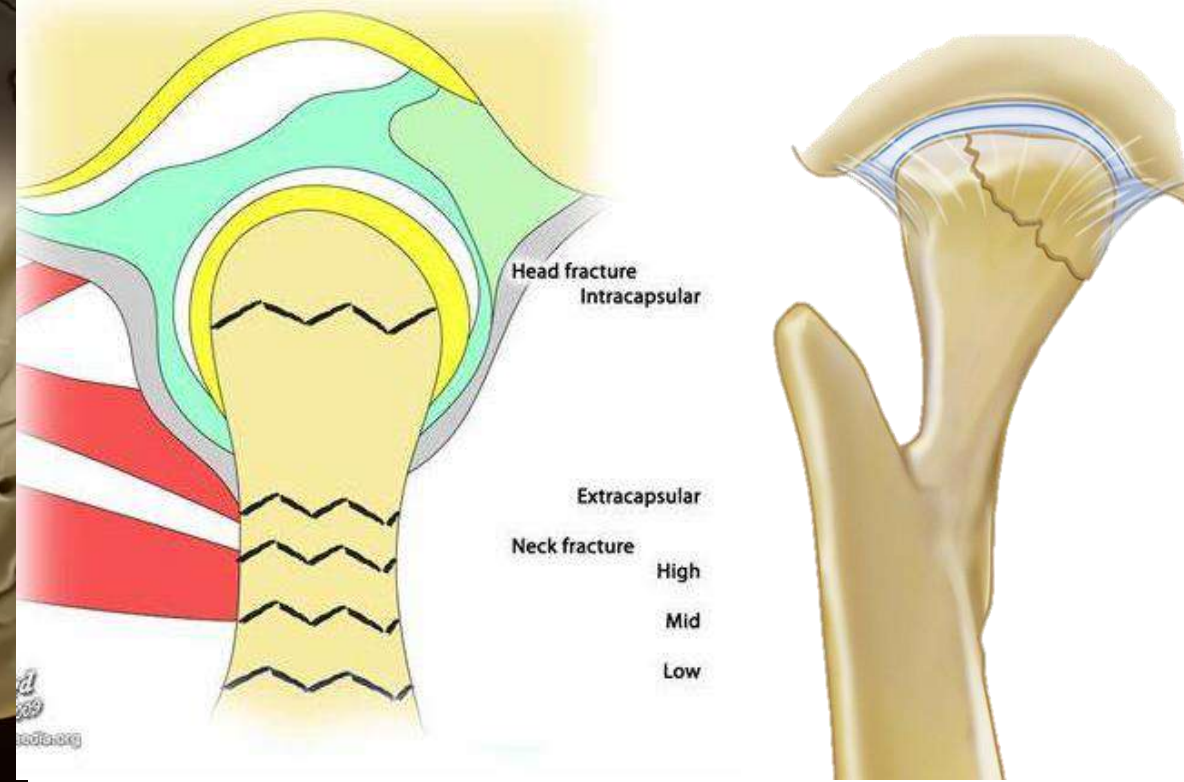


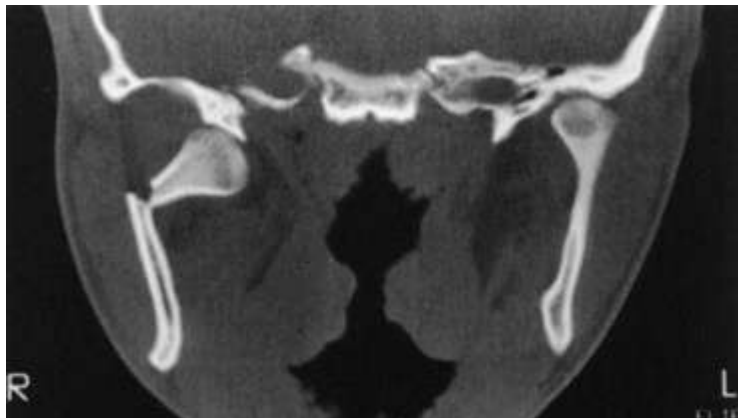
ARTICULAR DISC

MEDVIZZ

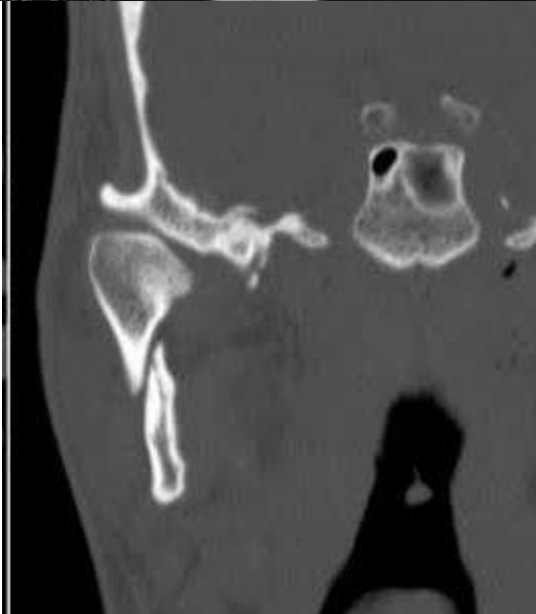
Fibrous capsule

The periphery of the disc is attached to the fibrous capsule

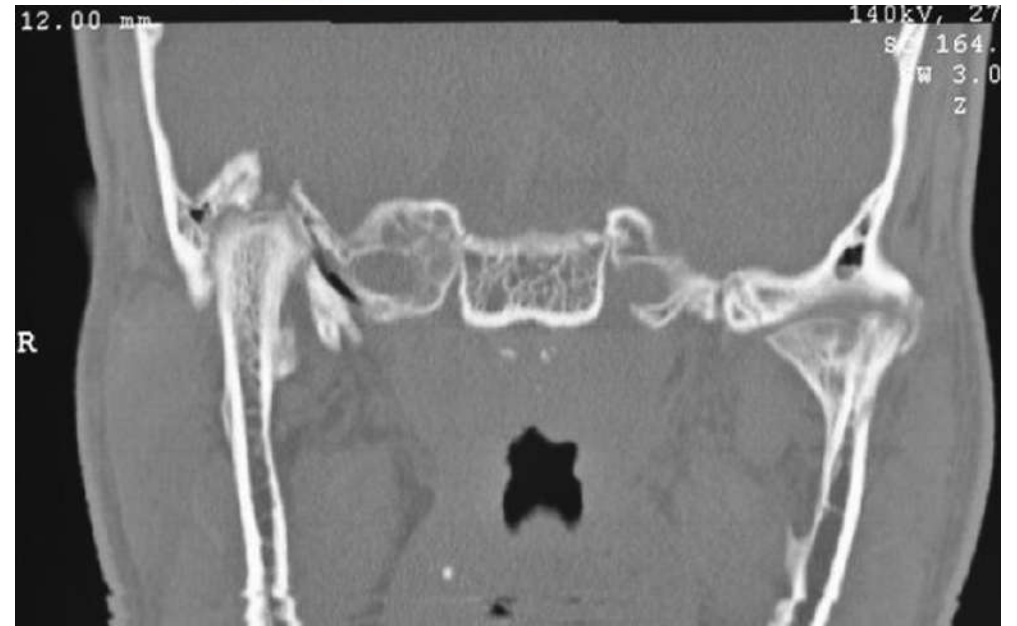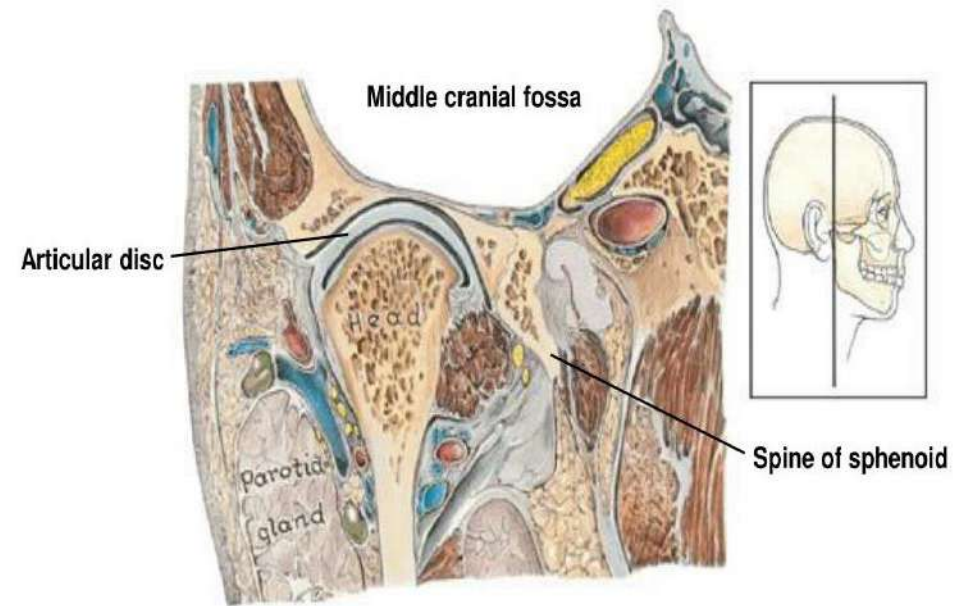




Unilateral fracture with dislocation



Lateral extra-capsular displacement.



Displacement of condyle into middle cranial fossa

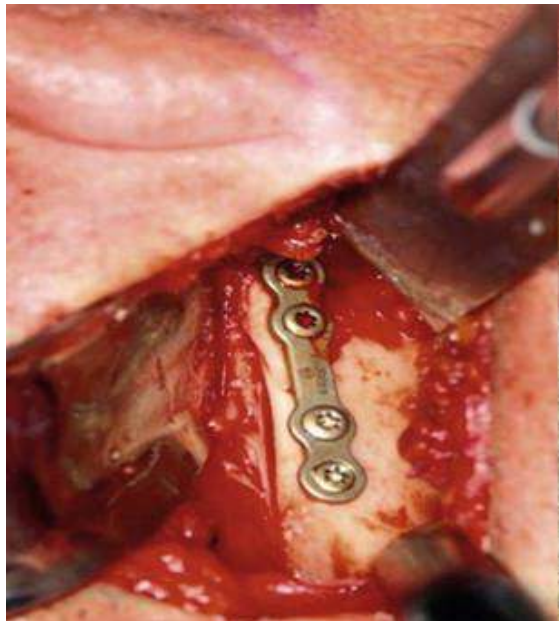
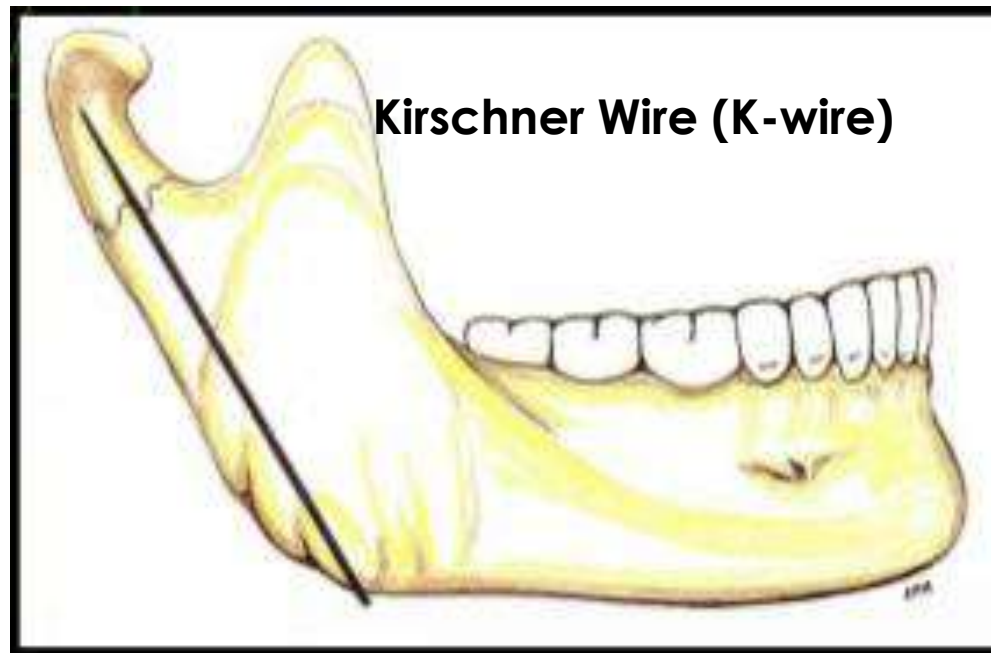
Surgical Approaches for ORIF

- ▶ The main approaches are the Pre-auricular, Submandibular, Retromandibular or Transparotid Approaches.
- ▶ The intraoral approach has the advantage of Avoiding Facial scarring and Risk of injury to the facial nerve.
- ▶ Minimally invasive endoscopic repair offers less morbidity and operating time.

Fixation Methods in ORIF


- ▶ Among the fixation methods that have been used are;

Transosseous Wire \ Kirschner Wire (K-wire) \ Miniplates \ Lag Screws \ Bioresorbable Plates and Pins \ and more recently ultrasound activated resorbable plates and pins.



Miniplates

Lag Screws

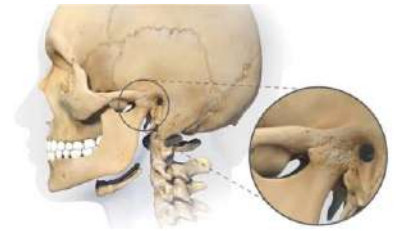
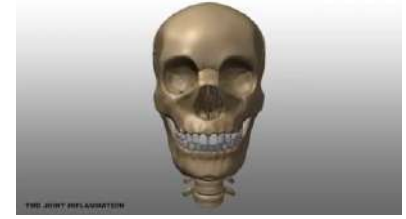

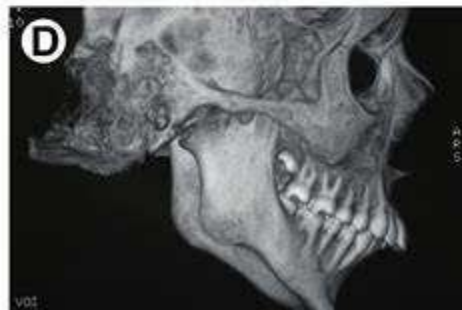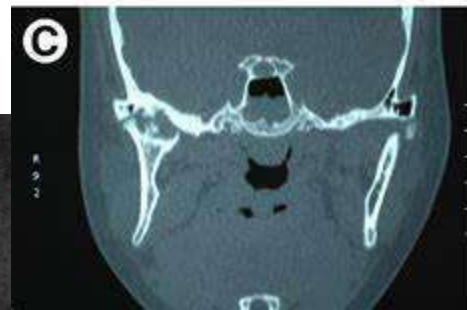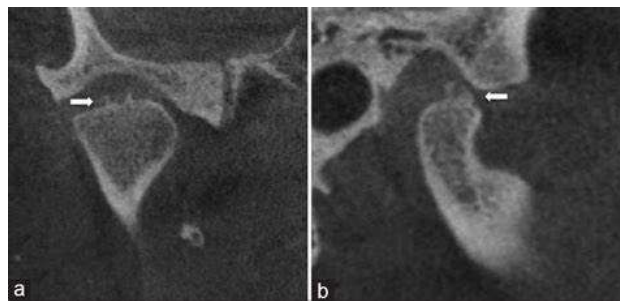
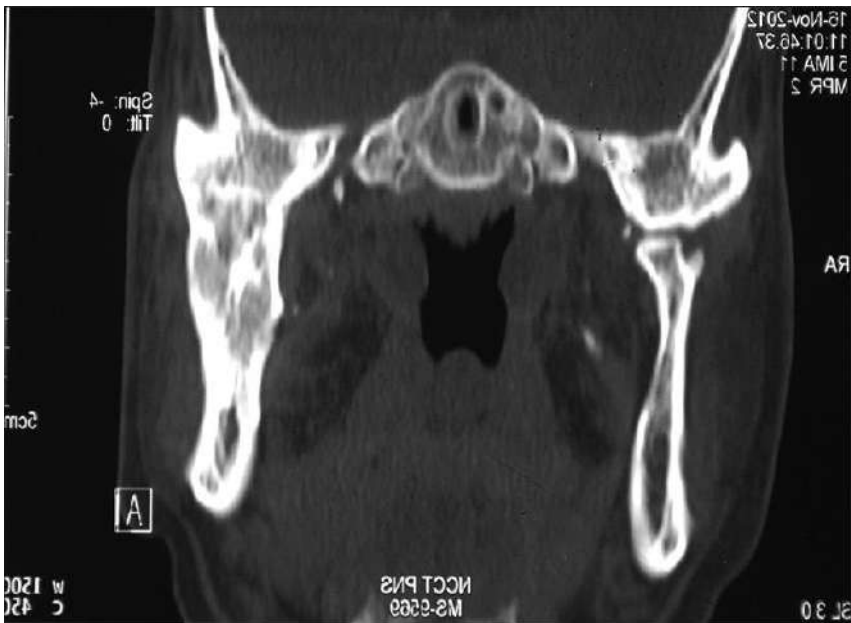
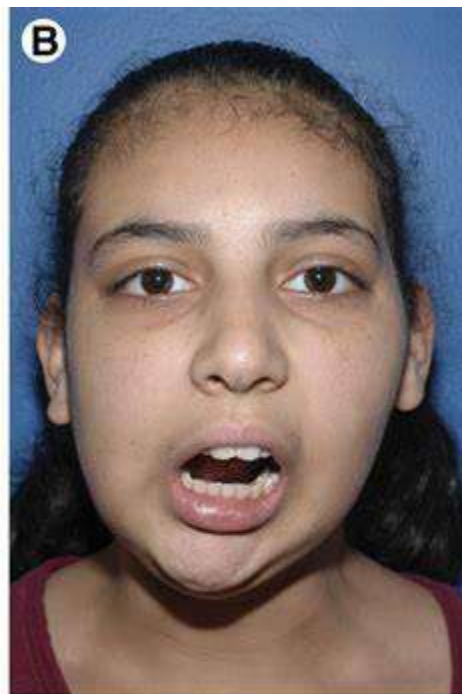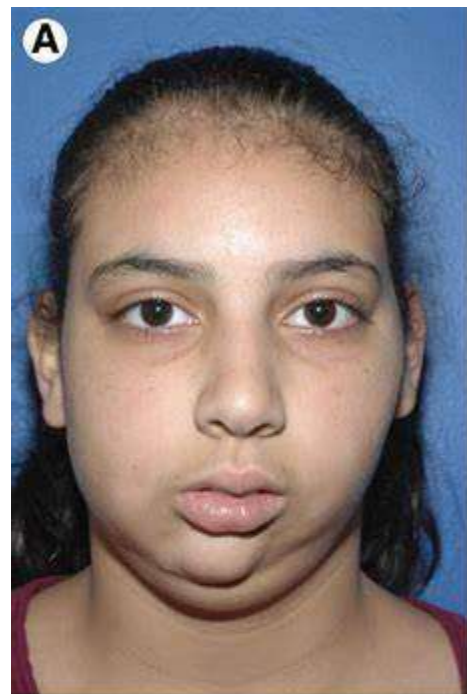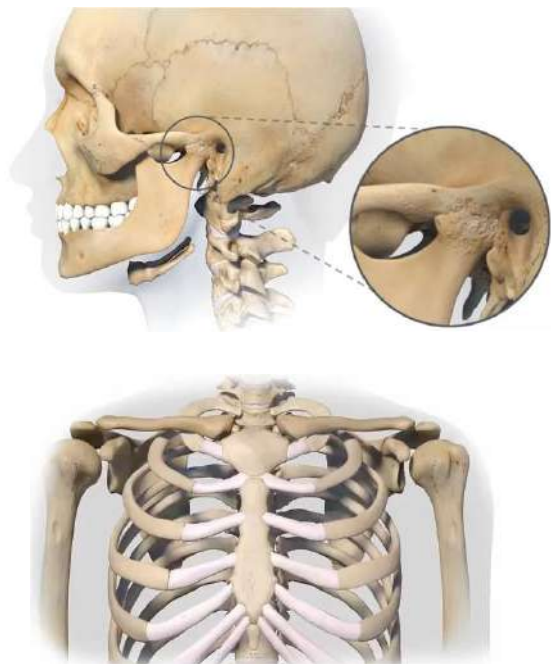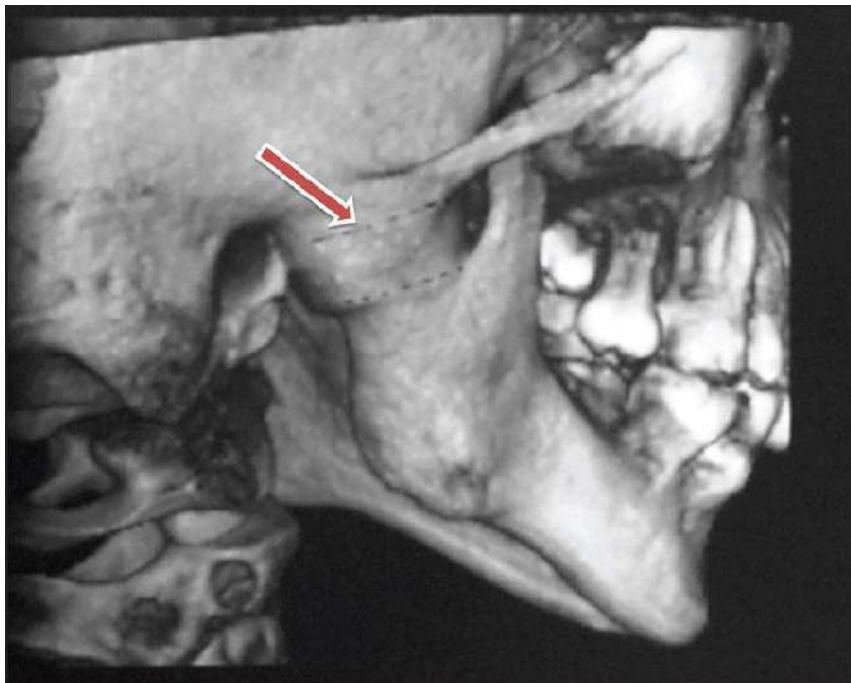
Complications of Condylar

1. Malocclusion.
2. Limitation of range of movement.
3. Displacement of the disc.
4. Chronic pain associated with dysfunctional movement or with osteoarthritis.
5. Ankylosis of the TMJ; due to fractures that involve the joint space.

Ankylosis can be fibrous or bony. Predisposing factors include:

1. Age: the major incidence is below the age of 10 years.
 2. Type of injury: intracapsular trauma with crushing of the condyle.
 3. Damage to the disc: occur in two particular types of fracture: a severe intracapsular compression injury or a fracture dislocation.
- ▶ Disturbance of growth in children; when the fracture involves the condylar cartilage and the articular surface, disturbance of growth occur.
 - ▶ **The effect of damage is failure of development of the condylar process and a smaller mandible on the affected side.**

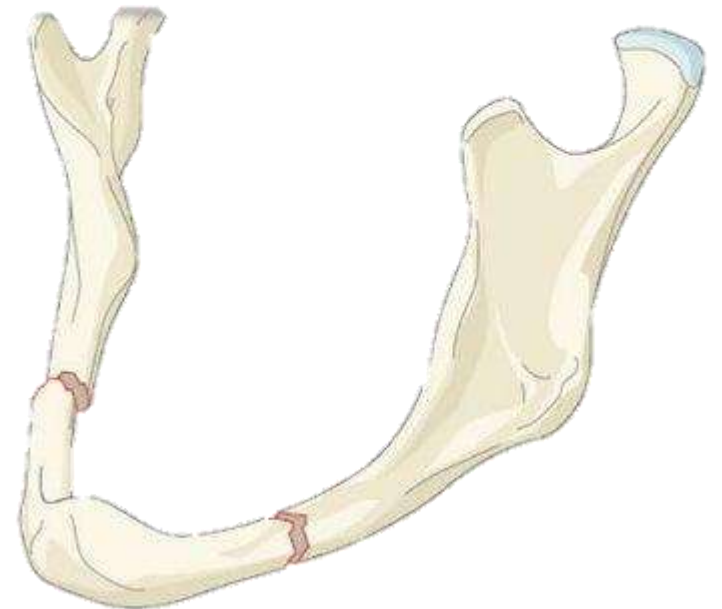
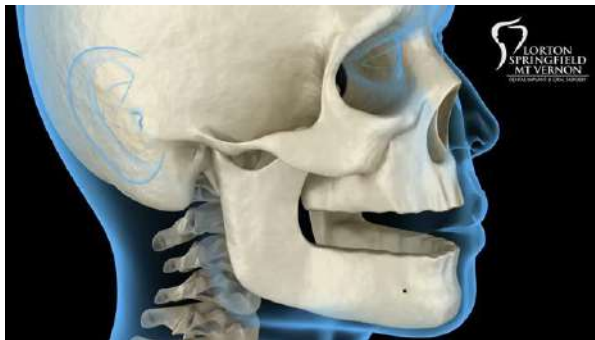



Fractures of the Edentulous Mandible

The Physical Characteristics of mandible are altered following the loss of the teeth:

- ▶ The alveolar process undergoes resorption and mandible becomes atrophic and thin.
- ▶ The resistance of the bone to trauma is further reduced with the process of aging.
- ▶ The blood supply is more periosteal due to the diminished endosteal blood supply.
- ▶ The healing potential of the bone is reduced (non-union may occur).
- ▶ Smaller cross-sectional area of bone at the fracture site.

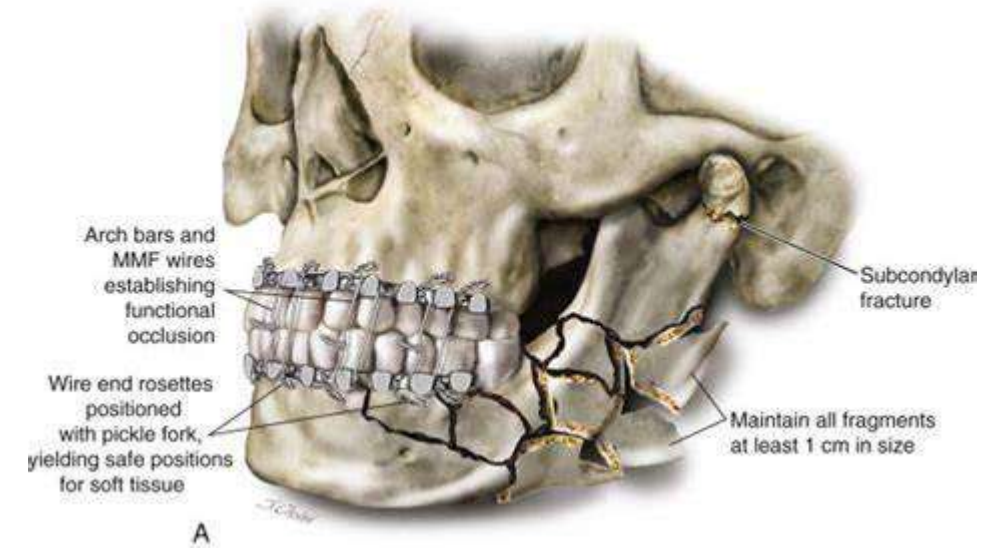
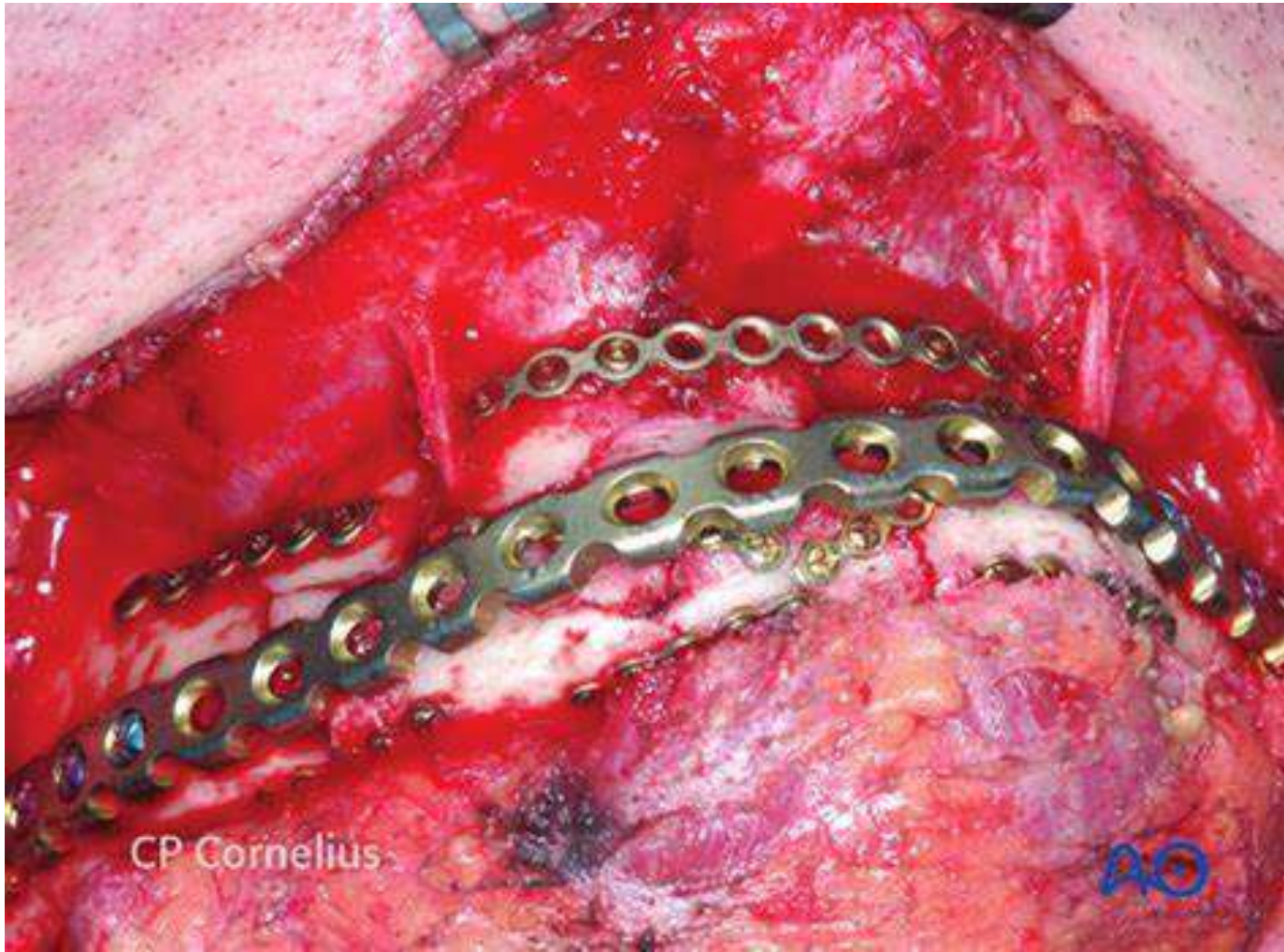

TREATMENT

- ▶ Undisplaced stable fractures require no active treatment.
- ▶ Treated by closed reduction (Gunning type splints) or if the patient is a denture wearer, can be used as a splint.
- ▶ When ORIF is required, reduction made with minimum exposure of the fracture site to minimize interference with the periosteal blood supply.
- ▶ Autogenous bone grafting may be needed in very thin mandible.
- ▶ It must be remembered that accurate anatomical reduction is not required.

Comminuted Mandibular Fractures

- ▶ It result from **High Energy Injuries** such as missile injuries
- ▶ Associated with **soft tissue damage** and many of these fractures are open (compound) and contaminated.
- ▶ The **bone fragments are difficult to manipulate and secure**, while maintaining their soft tissue attachments and are therefore at **Risk** of becoming loose or devitalized.
- ▶ The **Traditional Method** of treatment of these fractures used **Closed Techniques**, thereby avoiding periosteal stripping and further devitalizing the bone.
- ▶ Recently ORIF has been advocated by the use of **Reconstructive Plate Fixation** and stability across the fracture.



Reconstructive Plate Fixation

▶ Pathognomonic Sign of mandibular fracture is

- A. Pain
- B. Trismus
- C. Mobility of teeth.
- D. Sublingual hematoma
- E. Swelling due to edema and hematoma

▶ The submandibular incision for approaching angle fracture placed one finger breadth below the lower border of the mandible

- A. To keep the incision line masked
- B. To prevent injury to the facial vessels
- C. To prevent injury to the marginal mandibular nerve
- D. Access become easy
- E. All of the above

► A patient with bilateral subcondylar fracture presents with

- A. Inability to open the mouth
- B. Anterior open bite
- C. On opening mandible move forward
- D. Closed bite
- E. Occlusion not affected

► With respect to closed treatment of mandibular fractures, one statement is incorrect

- A. It is associated with indirect fixation and immobilization.
- B. It requires surgical exposure of the fracture site.
- C. It can be definitive or temporary treatment.
- D. Reduction can be performed by elastic traction.
- E. It requires mandibulomaxillary fixation.

► The Principal sequence of treatment of mandibular fracture are:

- A. Immobilization, Fixation, Reduction, then Rehabilitation
- B. Reduction, Rehabilitation, Immobilization, then Fixation.
- C. Rehabilitation, Reduction, Fixation, then Immobilization.
- D. Fixation, Reduction, Rehabilitation, then Immobilization.
- E. Reduction, Fixation, Immobilization, then Rehabilitation.

► Concerning imaging for mandibular fractures, one statement is correct

- A. Townes or reverse Townes projections are indicated in parasymphseal fractures.
- B. PA mandible view is the best for condylar fractures.
- C. Occlusal view is valuable for all mandibular fractures.
- D. OPG provides an overall view of the mandible.
- E. CT scan is indicated for all mandibular fractures.

► One of the following is a relative indication for removal of a tooth in the mandibular fracture line

- A. Longitudinal fracture involving the root.
- B. Already infected fracture line.
- C. Advanced periodontal disease.
- D. Where a displaced tooth prevents reduction of the fracture.
- E. Carious tooth.

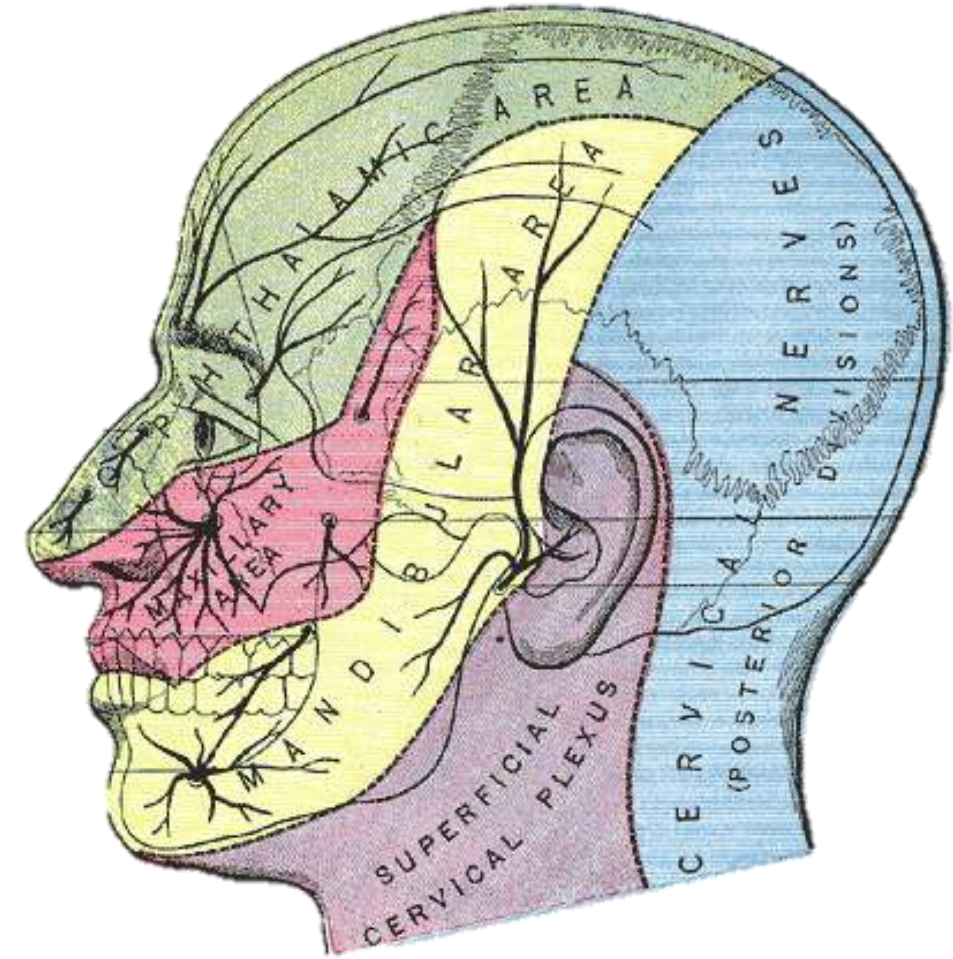
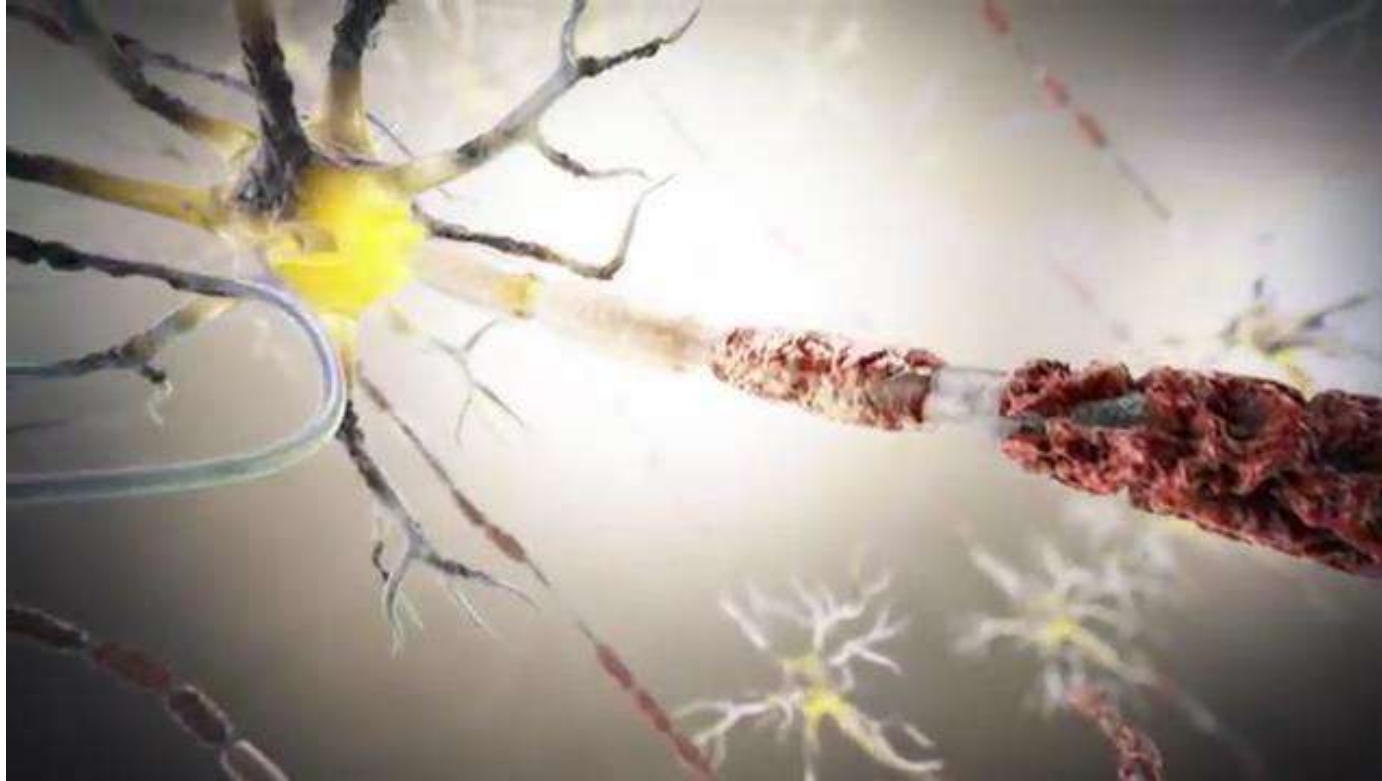► All are indications for open treatment of mandibular fractures EXCEPT

- A. Multiple fractures of the facial bones
- B. Fractures of an edentulous mandible with severe displacement.
- C. Non-displaced favorable fractures.
- D. Delay of treatment and interposition of soft tissue between non-contacting displaced fracture fragment
- E. Special systemic conditions contraindicating IMF.

► An unfavorable displaced fracture of the mandibular angle is difficult to treat because of;

- A. Complicated surgical approach.
- B. Muscle pull causes distraction.
- C. Malocclusion secondary to the injury.
- D. Injury to nerves and vessels.
- E. Bone in that region is very thick.

OROFACIAL PAIN



Bashar Abdul-Ghani

FICMS. MAXFACS Cons. MFDS. RCSED. RCPS (Glasg).

Lecture Quoted From Baghdad University Curriculum

PAIN



- ▶ Pain is an unpleasant emotional feeling due to either **Physical or Psychological** trauma.
- ▶ It is **subjective symptom** usually initiated by a noxious stimulus and transmitted through a specialized neural network to the central nervous system, where it is interpreted as pain.

It may classified according to the **Duration and Severity** into:

- ▶ **Acute Pain** is of short duration, moderate to severe in severity and may be not relief by mild analgesics.
- ▶ **Chronic Pain** is of long duration, mild to moderate in severity and is often associated with feelings of depression.

- ▶ **I. Typical Orofacial Pain:** - A. Dental B. Periodontal C. Mucosal D. Bone E. Salivary gland F. Temporo-Mandibular Joint G. Maxillary sinus
- ▶ **II. Psychogenic Orofacial Pain:** A. Facial arthromyalgia B. Atypical facial pain C. Atypical odontalgia D. Oral dyesthesia E. Factitious ulceration
- ▶ **III. Vascular Orofacial Pain:** A. Migraine B. Cluster headache C. Giant cell arteritis
- ▶ **IV. Neuralgia:** A. Primary neuralgia: i. Trigeminal neuralgia ii. Glossopharyngeal neuralgia - B. Secondary neuralgia:
 - ▶ i. Extra cranial lesions: a. Two mental nerves neuralgia b. Causalgia c. Frey's auriculo-temporal syndrome d. Herpes zoster e. Post herpetic neuralgia f. Nasopharyngeal CA
 - ▶ ii. Cranial base lesions: a. Petrous Temporal osteitis b. Cholesteatoma
 - ▶ iii. Intracranial lesions: a. Posterior cranial fossa b. Middle cranial fossa c. Multiple sclerosis
- ▶ **V. Other Orofacial Pain (Referred pain):** A. Ocular B. Cardiac C. ENT D. Elongated styloid process

In order to diagnose any pain and to distinguish between organic and psychogenic origin of pain it is essential to take the history which includes the following informations:

1. Character of the pain: sharp, dull, throbbing, burning or stabbing.
2. Severity of the pain: mild, moderate or severe.
3. Site at which it felt and any pain radiation.
4. Timing: frequency and duration of subsequent attacks.
5. Provoking factors: hot, cold, sweet, bruxism.
6. Relieving factors: analgesic, narcotic, application of heat.
7. Associated clinical features: swelling, ulcer, trismus.
8. If the patient suffers from pain elsewhere in the body: abdominal pain or cervical pain.
9. General medical history.
10. Patient's emotional history: anxiety, depression, antidepressant drug.
11. Family history: ill health, death of parents, brothers, etc.

I. Typical Orofacial Pain:

A. Dental Pain (odontalgia)

- ▶ Pulpitis presented as transient dull or sharp pain, well localized but occasionally becomes diffuse or referred to the opposite tooth.
- ▶ Treatment: filling, RCT, or Extraction.



B. Periodontal Pain

- ▶ Periodontitis presented as continuous dull pain, relieved by clenching the teeth, but later on is aggravated by this action.
- ▶ Treatment: Acute periodontal abscess treated by drainage of exudates, periodontal surgery when the acute phase has been subsided.

C. Mucosal Pain

- ▶ Traumatic ulceration, aphthous stomatitis, viral ulceration, erosive lichen planus, etc, which may involve the oral mucosa, causing burning sensation which is provoked by spiced or hot food.
- ▶ Investigation: biopsy if ulcer persists for more than two weeks.
- ▶ Treatment: Each condition requires specific therapy.

D. Bone Pain

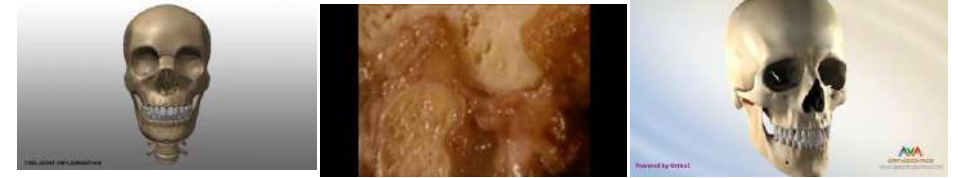- ▶ Alveolar osteitis (Dry Socket), Fracture, Osteomyelitis and Tumor causing bone pain which is vary from continuous dull ache to a severe throbbing.
- ▶ Investigation: x-ray and biopsy.
- ▶ Treatment: Analgesic and antibiotic or surgery.

E. Salivary Gland

- ▶ Diseases of the salivary glands such as Sialadenitis, Obstructed Duct, Mump and Tumors presented as well localized intermittent dull pain and associated with a swollen gland and xerostomia.
- ▶ Investigation: Plain radiography or sialography.
- ▶ Treatment: Each condition requires specific therapy.

F. Temporo-Mandibular Joint (TMJ)

BiteFX
TMJ Disorders
Not for use in dental clinics
Copyright © 2011, D2Effects LLC



❖ Traumatic arthritis of TMJ:

- ▶ This occurs following **Damage** to the capsule and meniscus due to direct trauma.
- ▶ It is presented as moderate to severe pain, well localized and aggravated by mandibular movements and tender joint on palpation.
- ▶ Investigation: X-ray (TMJ, PA, OPG views or MRI).
- ▶ Treatment: Conservative therapy, resting the joint and analgesics.

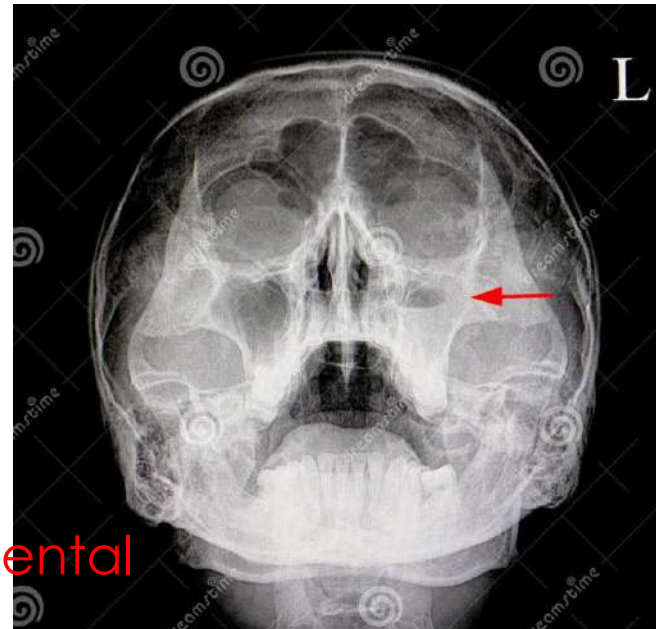
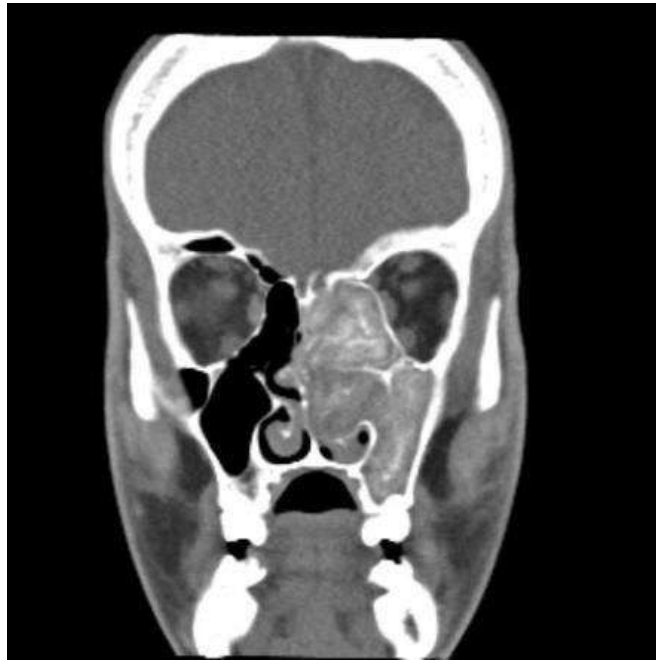❖ Osteoarthritis of the TMJ:

- ▶ It is a **Degenerative Condition**, pain is well localized to the affected joint, provoked by jaw movements and there is tenderness and audible crepitus (clicking) in the joint.
- ▶ Investigation: X-ray (TMJ, PA or OPG views) and Serum uric acid.

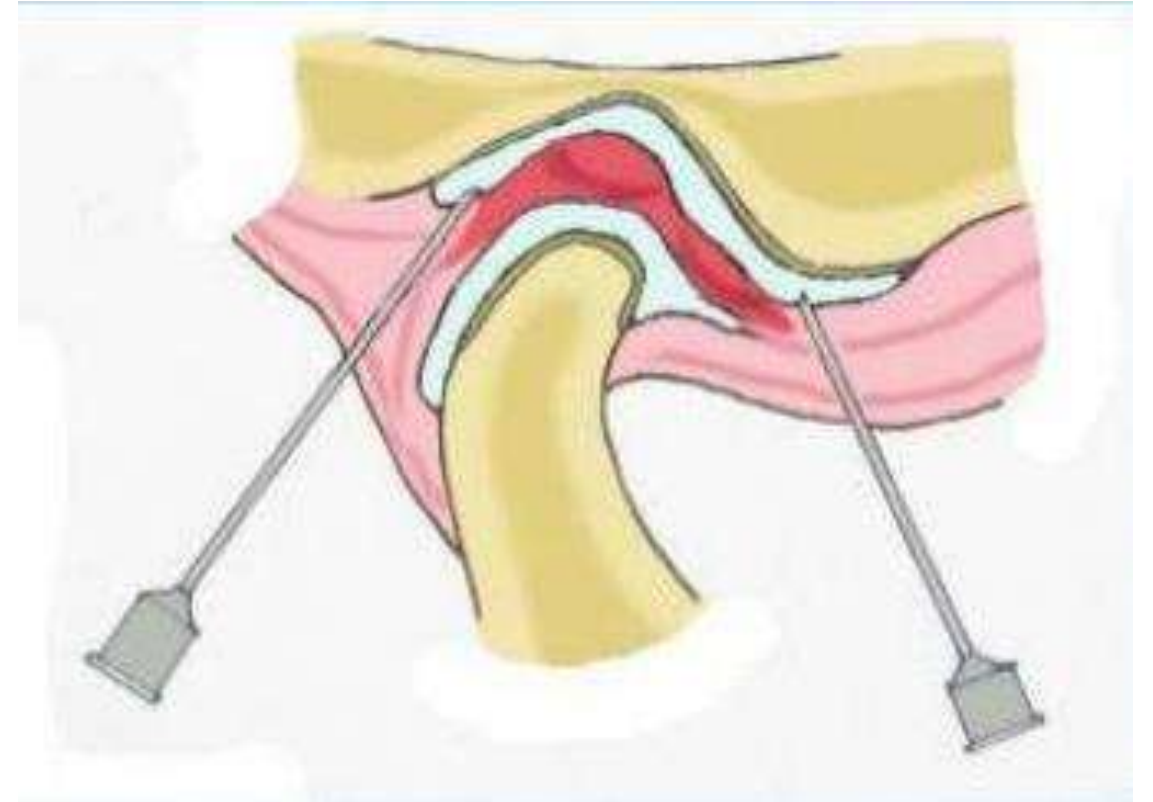
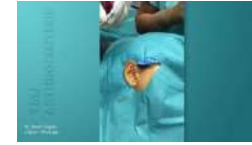Treatment: Correction of the occlusion, Ibuprofen 400 mg t.i.d., arthrocentesis, Intracapsular injection of 1ml Dexamethasone or smoothing of the condylar head by open surgery.

G. Maxillary Sinus

- ▶ **Sinusitis** presents as dull or severe maxillary pain, either unilateral or bilateral which is become worse on head bending. It may be obscured by sensitivity in the upper premolar and molar teeth which are tender to percussion giving the impression of pulpitis.
- ▶ Investigation: X-ray; Occipitomenal view reveals radioopaque sinus.
- ▶ **Treatment: Antibiotic, Analgesic, Nasal Decongestant, or Surgery.**



Occipitomen-
tal



Arthrocentesis

II. Psychogenic Orofacial Pain: (as tension headache)

- ▶ Occur due to stressful life, anxiety, neurosis or depression.
- ▶ The clinical presentations include:

A. Facial Arthromyalgia (TMJ Myofascial Pain Dysfunction Syndrome)

- ▶ The condition may vary from joint clicking to a severe continuous ache
- ▶ pain may radiate to the temporal, occipital regions, or angle of the mandible.
- ▶ Tenderness in the TMJ and muscles (temporalis, masseter, medial & lateral pterygoid).
- ▶ May be associated with cervical pain and irritable colon.
- ▶ In **Nocturnal Bruxism**, morning TMJ pain with trismus, improve during the day.
- ▶ In patient with stress, TMJ pain occur during the course of the day.



Treatment:

1. Adjustment of the occlusion and all dental diseases must be treated.
2. Reassuring that emotional tension expressed as bruxism which create muscle spasm.
3. Muscle relaxant medications as Norgesic or Myogesic.
4. Benzodiazepine 2-5 mg (anxiolytic and mild muscle relaxant) at night.
5. A bite-guard at night or during the day to discourage bruxism.
6. Tricyclic antidepressant (Nortriptyline 10 mg at night for 2-3 weeks). If there is no remission prescribe; Motival (Flufenazine 0.5 mg and nortriptyline 10 mg at night).
7. Psychiatric consultation for severely disturbed cases.
8. Surgery is controversial, and the need for condylotomy in some cases.

B. Atypical Facial Pain

- ▶ Intermittent or continuous dull pain of many years.
- ▶ It is localized to non-muscular, non-joint area but explained as burning or aching in facial bones, alveolus and teeth on one side of the face.
- ▶ Clinical examination and investigations are all negative and like facial arthromyalgia it may associate with pains elsewhere in the body.
- ▶ **Treatment:** Tricyclic antidepressant and Psychiatric consultation.

C. Atypical Odontalgia

- ▶ Persistent or throbbing pain provoked by biting, chewing and thermal changes, arise without any detectable structural lesion.
- ▶ patient complains from painful healthy teeth for more than one quadrant.
- ▶ **Treatment:** Tricyclic antidepressant and Psychiatric consultation.

D. Oral Dysesthesia

- ▶ Abnormal sensation, more commonly occur in elderly with overt problem, menopause and loneliness.
- ▶ In some cases, there may be evidence of an organic psychosis due to cerebral ischemic changes.
- ▶ Clinical presentations are: burning tongue, dry mouth in the presence of saliva, feelings of sand in the saliva, denture intolerance and abnormalities of taste.
- ▶ **Treatment:** Reassurance, and Trifluoperazine 2-4 mg twice a day.

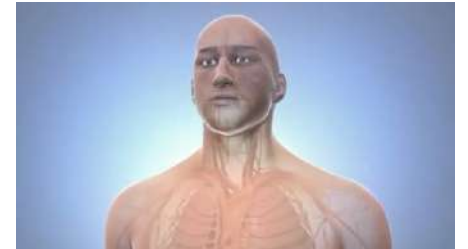E. Factitious Ulceration

- ▶ It is a self-inflicted ulceration by finger nails or the application of Aspirin.
- ▶ Resembles an aphthous ulcer.
- ▶ The patient usually denies causing the lesion.
- ▶ The lesion is investigated by biopsy with no evidence of any pathological lesion.
- ▶ **Treatment:** Trifluoperazines 2-4 mg a day.

III. Vascular Orofacial Pain:

A. Migraine

- ▶ It is a recurrent unilateral throbbing headache associated with visual disturbances and nausea lasting for several hours.
- ▶ The pain is preceded by **Aura** (visual and speech disturbances) and intensified by sneezing, light, smell and noise. Mostly affects women.
- ▶ It appears to be due to either
 - ▶ **Irregularities in the brain's blood vessel system**
 - ▶ **Abnormalities of brain chemicals and nerve pathways.**



Treatment:

1. Analgesics.
2. Vasoactive Ergotamine Tartrate (2 mg sublingually or 0.5 mg inhaler).
3. Antidepressant; Motival (Flufenazine 0.5 mg with Nortriptyline 10 mg).

B. Cluster Headache (Alarm Clock Headache)

- ▶ It is a **Spastic Dilatation of the Maxillary Artery**, it mostly affects men and occurs at night, waking the patient in the early hours.
- ▶ It is an intense, throbbing pain (hot metal rod around the eye) usually lasting about half an hour.
- ▶ **Treatment**: Ergotamine suppositories at night or Tricyclic antidepressant drugs.

C. Giant Cell Arteritis

- ▶ Arteritis of the **Superficial Temporal Artery** present as a headache or local pain.
- ▶ Arteritis of the **Maxillary Artery** present as pain in the masticatory muscles.
- ▶ Arteritis of the **Lingual Artery** present as ulceration and necrosis of the tongue.
- ▶ Investigation: **Biopsy of the artery**.

▶ **Treatment:**

- ▶ Prednisone 60 mg or Dexamethasone 10 mg a day for 10 days
- ▶ then reduced (tapering) until the condition is under control.

Etiology

Autoimmune

Genetics → Toll-like receptor 4 gene polymorphism

Environment → Infectious agents include: Mycoplasma, Varicella zoster virus and Herpes virus.

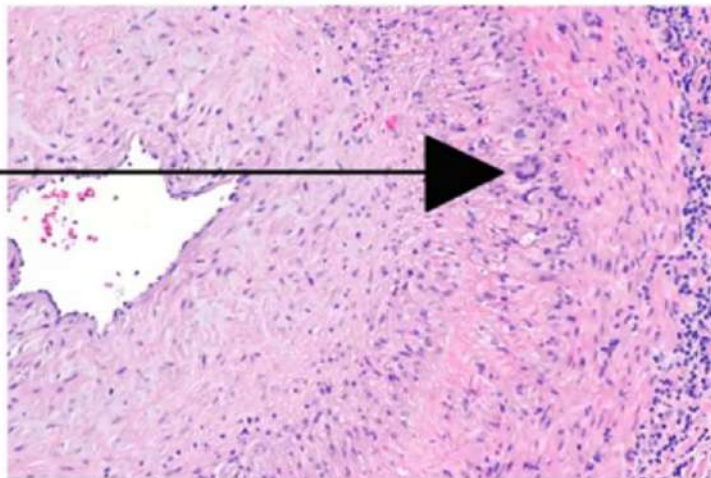
Diagnosis

Biopsy is the gold standard

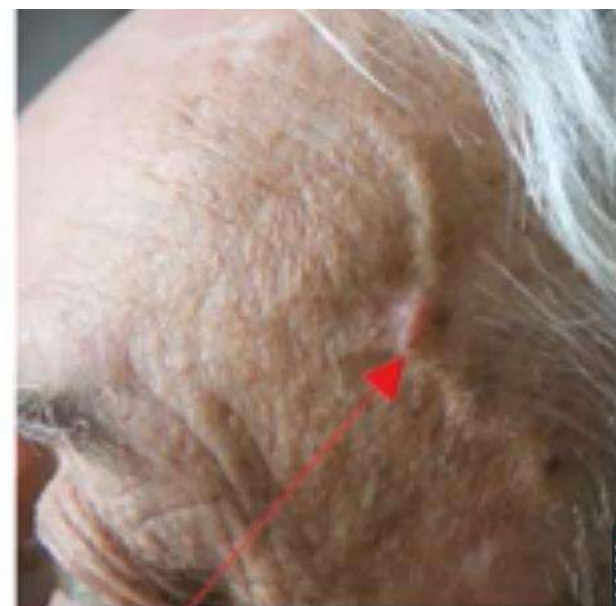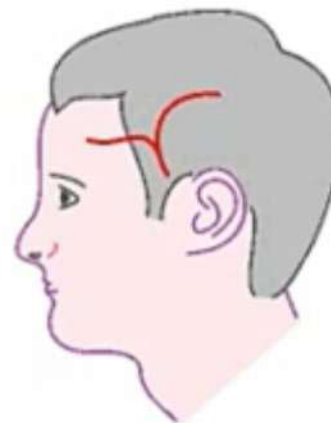
Giant Cells

Treatment:

Corticosteroids, typically high-dose prednisone, should be started as soon as the diagnosis is suspected.



Temporal Arteritis



Tender, Firm nodules

IV. Neuralgia

Types of Neuralgia

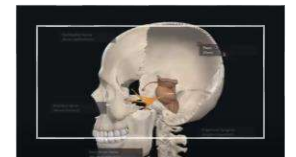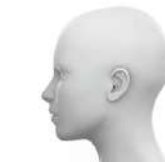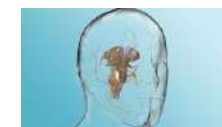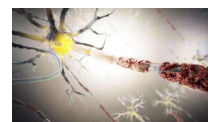A. Primary Neuralgia:

The etiology is unclear

- ▶ Viral infection of the ganglion
- ▶ Nerve roots demyelination due to
 - ▶ Nerve compression by vascular loop
 - ▶ Narrowing of the nerve foramina.

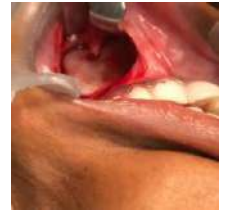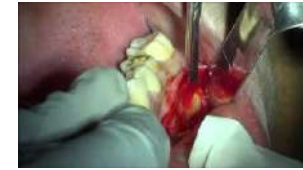i. Paroxysmal Trigeminal Neuralgia

- ▶ The pain is sharp, electric shock or stabbing, lasting within seconds
- ▶ Provoked by talking, swallowing, shaving or touching specific areas "trigger zone".
- ▶ Affect the middle age and elderly and often women are more affected than men.
- ▶ The most common sites involved are the mental area and the upper canine area.
- ▶ The ophthalmic distribution of the trigeminal nerve is rarely affected.
- ▶ There is a remission period but it tends to recur or persist throughout the patient's life.
- ▶ The pain can be also an early manifestation of **Multiple Sclerosis**.



Treatment:

1. Anticonvulsant: **Carbamazepine (Tegretol) 100-400 mg**, every 6 hours. The alternative drug is Phenytoin 200-400 mg twice a day.
2. When drug therapy is inadequate or immediate relief is essential, injection of 1 ml **60% or 90% Alcohol** into the mental or infraorbital foramina.
3. Peripheral Neurectomy
4. Cryotherapy
5. Intracranial preganglionic section of the mandibular and maxillary nerve trunk.



ii. Glossopharyngeal Neuralgia

- ▶ This pain is brought on by swallowing and the pain radiate to the throat and ear.
- Treatment: Tegretol 100-400 mg every 6 hours.

B. Secondary Neuralgias:

- ▶ This may be due to irritation of ganglion or nerve by some identifiable lesion
- ▶ either mimic exactly the primary type or present as a less specific disturbance.
- ▶ The important differentiating features are the associated local sensory reflex or motor impairment.
- ▶ The lesion can arise either extra cranial, within the cranial base or intracranial.

i. Extra Cranial Lesions:

a. Two Mental Nerves Neuralgia : due to

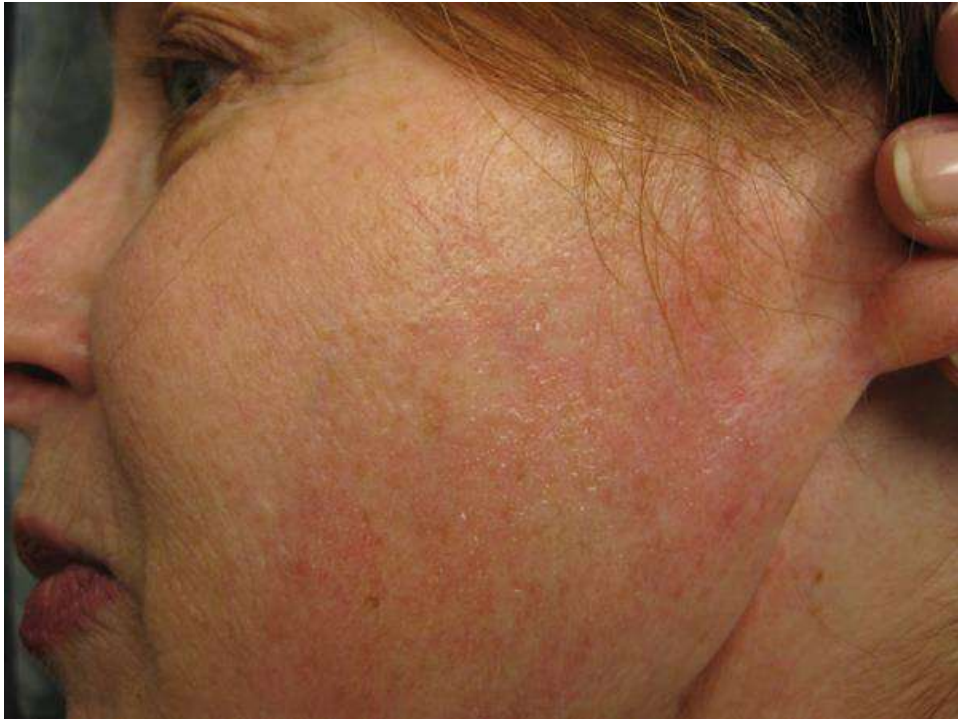- ▶ Pressure of lower denture flange on the mental nerve (treated by relieving the denture)
- ▶ Entrapment of the nerve due to narrowing of the mental foramen. (Treated by decompression)

b. Causalgia

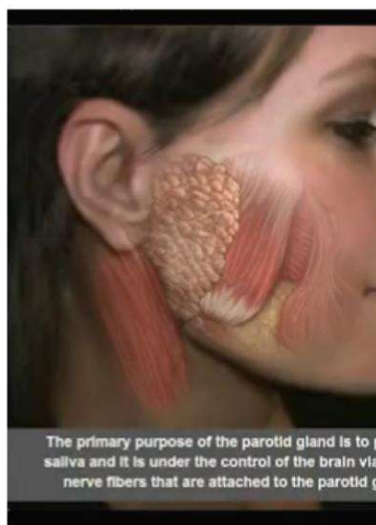
- ▶ It is a well localized persistent burning pain at the site of peripheral nerve injury.
- ▶ Excision of scar tissue results in temporary relief of pain, which returns as healing is completed and new scar tissue forms.
- ▶ **Treatment:** Antidepressant, Cryotherapy, or Avulsion of the peripheral nerve.

c. Frey's Auriculotemporal Syndrome (following parotid gland or TMJ surgery or trauma)

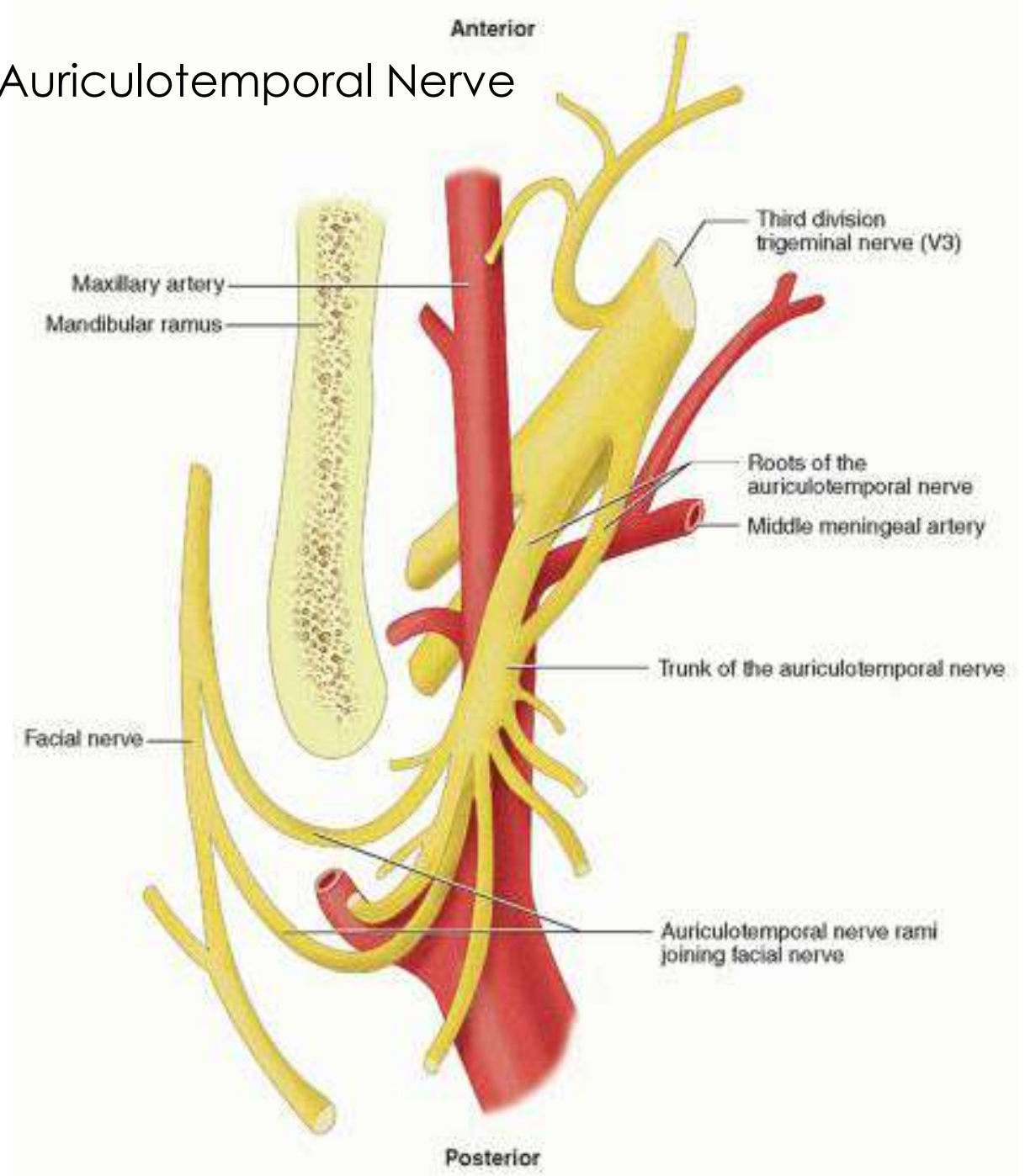
- ▶ Burning sensation in temporal or facial region with flushing and sweating on eating.
- ▶ It is attributed to parasympathetic secretomotor fiber of the auriculotemporal nerve reinnervate the cut ends of the sympathetic fibers.
- ▶ **Treatment:** Conservative therapy with parasympathetic blocker using Poldine Methyl Sulphate or use topical application of Anticholinergic (hyoscine) cream produce relief lasting up to 48 hours.



Facial Region Flushing



Auriculotemporal Nerve



d. Herpes Zoster

- ▶ Pain and burning sensation unilaterally precede the vesicular eruption which may affect any peripheral nerve.
- ▶ It is due to activation of the Varicella virus resident in the nerve ganglion.
- ▶ If the virus involves the geniculate ganglion and nervous intermedius of facial nerve, the patient will have ipsilateral facial palsy, otalgia and erythematous vesicular rash of the auricle and oropharynx, this condition called **Ramsay Hunt Syndrome**.
- ▶ **Treatment:** Acyclovir systemically as well as applied topically to the lesion.

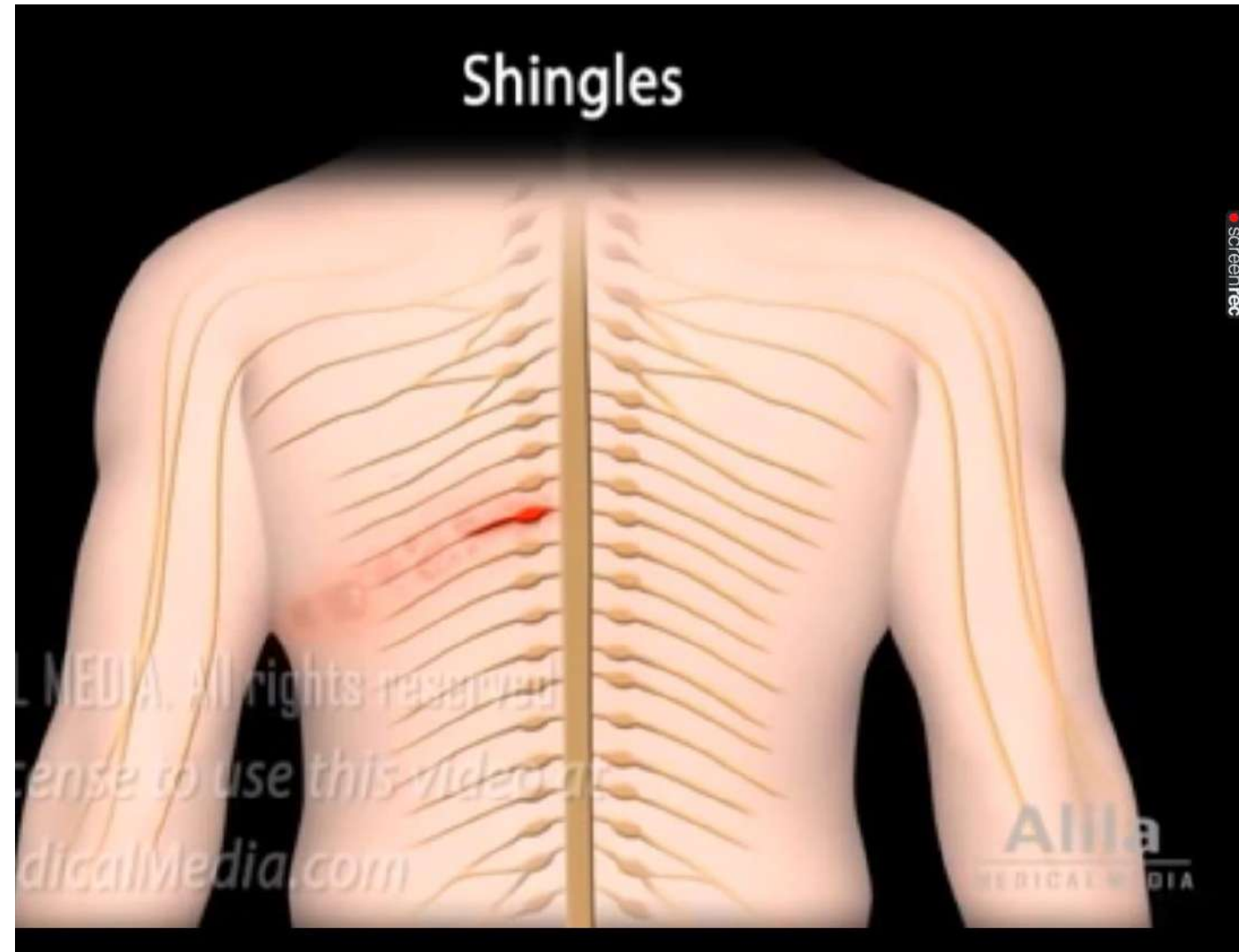
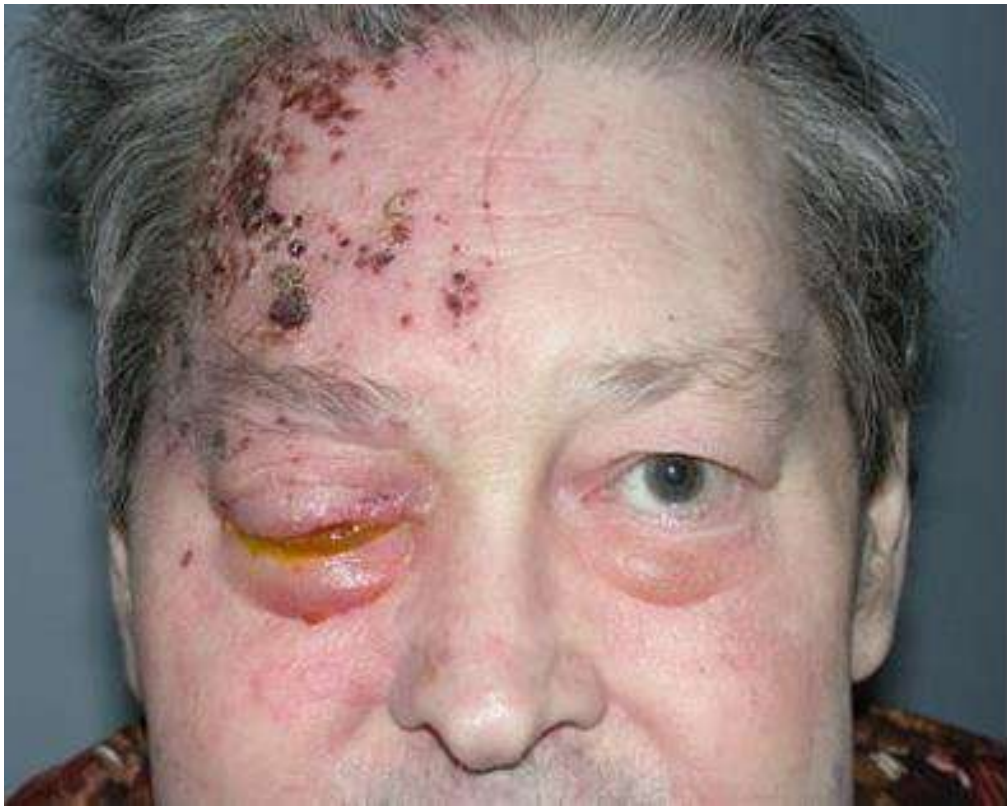e. Post Herpetic Neuralgia

- ▶ It may arise following untreated herpes zoster virus
- ▶ Persistent burning pain in an area of a diminished sensation.
- ▶ It is lead to destruction of the large myelinated sensory fibers by the Varicella virus.
- ▶ **Treatment:** Ibuprofen 400 mg, 4-6 hourly and supplemented by Tricyclic antidepressant.



f. Nasopharyngeal Carcinoma

- ▶ The mandibular and maxillary nerves are involved giving rise to a combination of facial pain, hypoesthesia and wasting of the masseter muscle.
- ▶ **Treatment:** Radiotherapy and Cytotoxic drug.



ii. Cranial Base Lesion:

- a. **Petrous-Temporal Osteitis** - rarely occurred
 - ▶ infection of the middle ear spread to the meninges and involves **Abducent Nerve** and **Trigeminal Ganglion**, producing a lateral rectus palsy and facial pain with hypoesthesia.
 - ▶ **Treatment:** Careful debridement of the infected bone, a course of Metronidazole and vascularization of the dead space with a temporalis muscle flap.

b. Cholesteatoma

- ▶ It is an abnormal skin growth in the middle ear behind the eardrum. It develops as cysts or pouches that shed layers of skin, which may increase in size and destroy the surrounding delicate bones of the middle ear leading to hearing loss, chronic facial pain and hypoesthesia. **The diagnosis made by CT scan and treated by surgery.**

iii. Intracranial Lesions:

a. Posterior Cranial Fossa Lesions

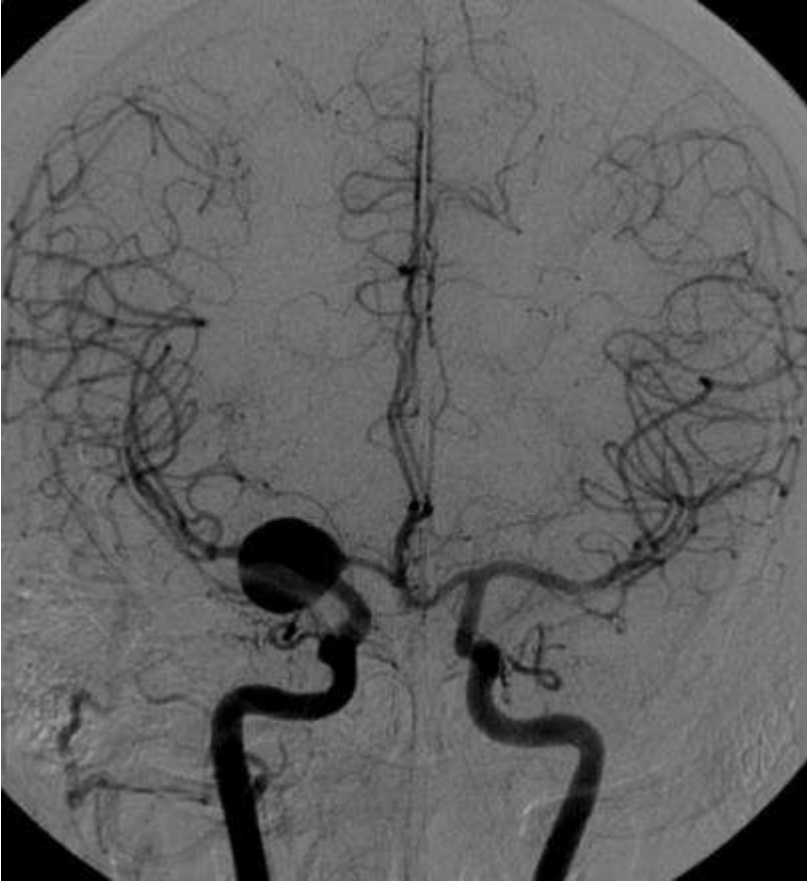
- ▶ **Schwannoma** of the trigeminal, facial and cochleovestibular nerves leads to facial pain, sensory loss, deafness and ataxia. **Diagnoses** by CT scan and **treated** by surgery.

b. Middle Cranial Fossa Lesions

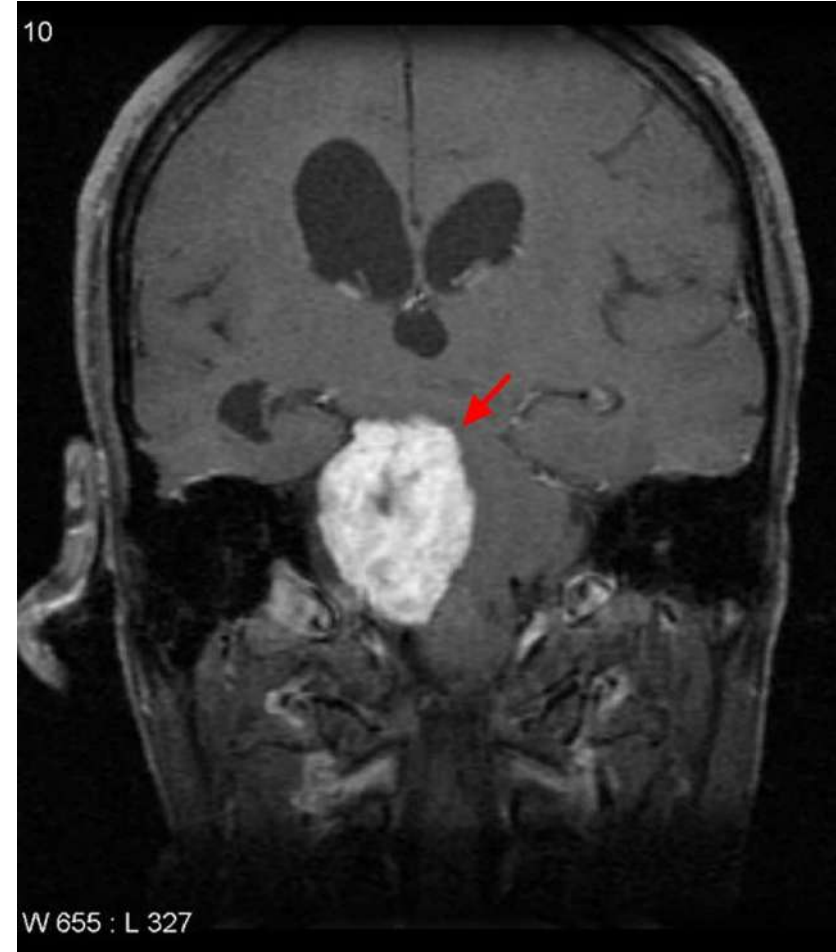
- ▶ Include **pituitary tumors and aneurysms of the internal carotid artery**
- ▶ Facial pain, hypoesthesia with disturbance of the vision and ocular movements.
- ▶ Diagnosis achieved by skull radiographs, angiography and CT scan. Treated by surgery.

c. Multiple Sclerosis

- ▶ It may present as trigeminal neuralgia, but in most cases have accompanying neurological disturbances such as loss of taste, disturbance of facial sensation, neurological deficit of sensory reflex or motor.



aneurysms of the internal carotid artery



Schwannoma

V. Other Orofacial Pain (Referred Pain):

A. Ocular Pain

- ▶ Ophthalmic diseases : acute glaucoma presents as ill-defined **facial pain** and treated by ophthalmologist.

B. Cardiac Pain

- ▶ pain of ischemic heart disease may refer to the **left mandibular teeth** via their common autonomic sensory innervations. The pain is provoked by effort, diagnosed by ECG and treated by cardiologist.

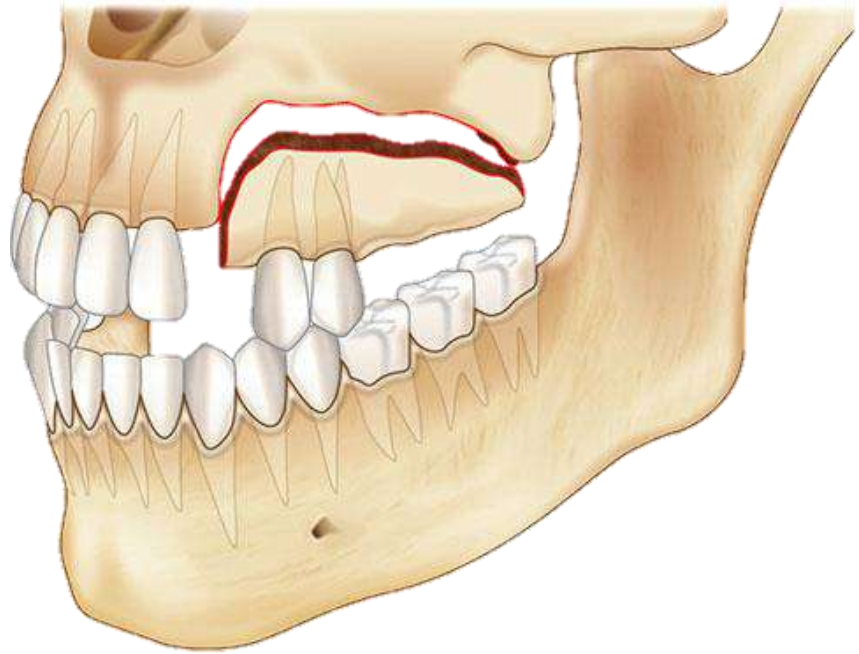
C. Ear, Nose And Tonsil

- ▶ A painful otitis externa due to furuncle, impacted wax or a fungal infection, pain may **referred to the mandible**.
- ▶ Peritonsillar abscess (quinsy) occasionally presents as **pain in the maxilla** and the patient misinterprets as toothache. Treatment: by ENT specialist.

D. Elongated Styloid Process (Eagle's Syndrome)

- ▶ The pain arising from an elongated styloid process (diagnosed by x-ray) and there is a **tenderness on swallowing** and palpation in the tonsillar fossa.

DENTO-ALVEOLAR INJURIES

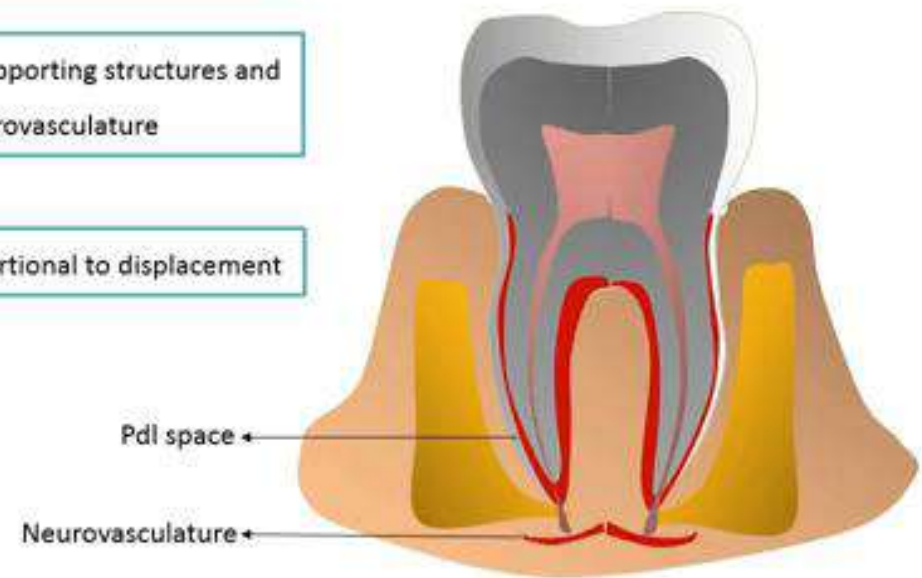


Luxation injuries

Sudden impact injuries

Damage to supporting structures and
neurovasculature

Severity proportional to displacement



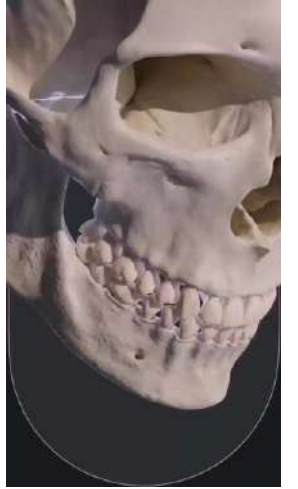Bashar Abdul-Ghani

FICMS. MAXFACS Cons. MFDS. RCSED. RCPS (Glasg).

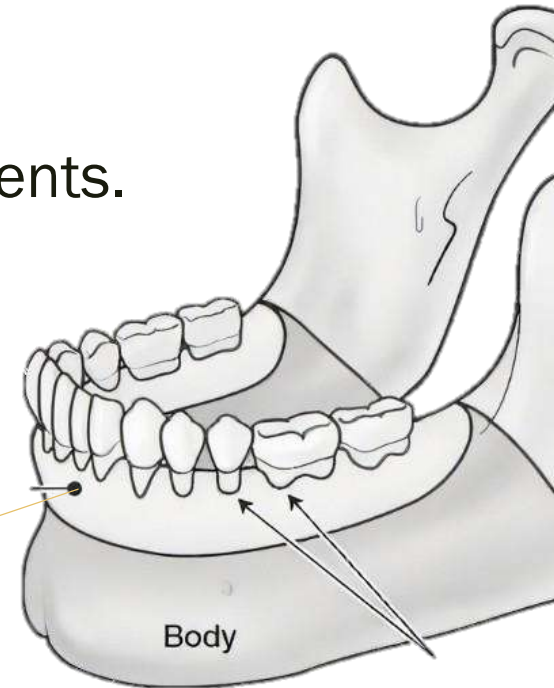
Lecture Quoted From Baghdad University Curriculum

Introduction

- Trauma localized to the **Teeth and the Alveolus**.
- Occur in isolation, or as part of a more serious maxillofacial injury.
- Occur in all age groups but they are **more common in children**.
- In **children the most common cause is fall**
- In adult, injuries caused by RTA, contact sports, and industrial accidents.
- Males are more frequently involved in such injuries than females.



Dento-Alveolar Segment



Factors Affecting Dentoalveolar Injuries

1- Direct or Indirect Trauma.

- In Direct trauma - **Maxillary Incisors** are the most frequently traumatized teeth
- In Indirect trauma - injury to the posterior teeth, anterior soft tissue or both, results from the forceful impact of the mandible with the maxilla

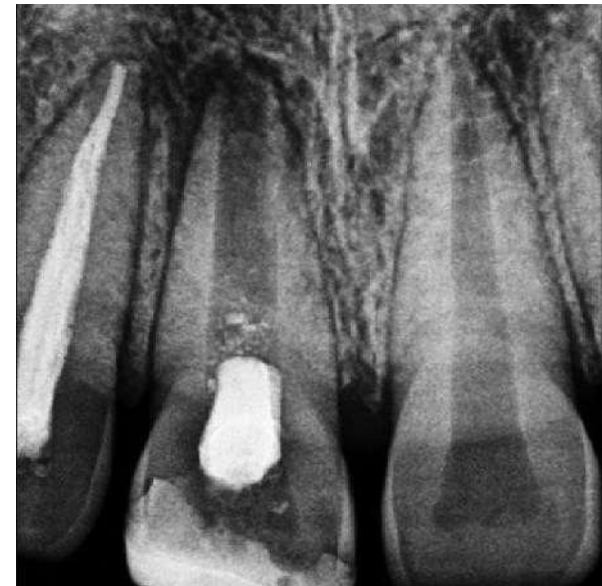2- Energy of Impact.

- Low-velocity blow - causes damage to the supporting dentoalveolar structures.
- High-velocity impact - results in crown fractures.

3- The Objects

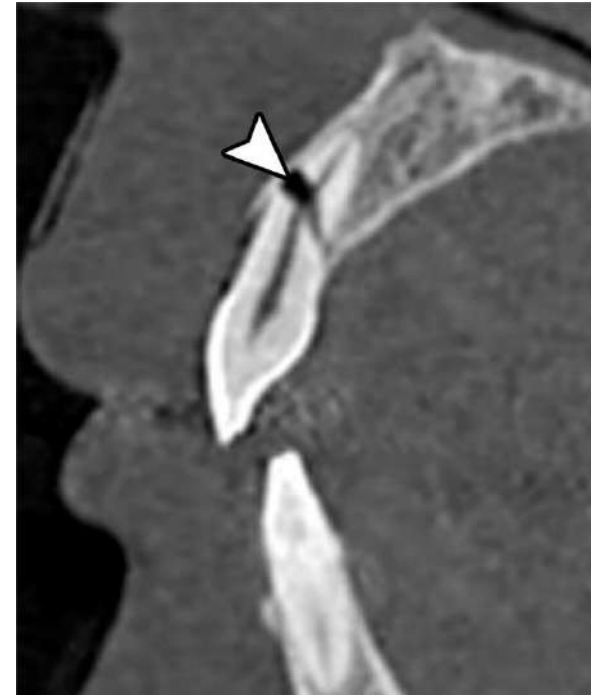- Sharp objects - crown fractures.
- Blunt objects - result in luxations or root fracture.

4- Direction of the Impacting Force.



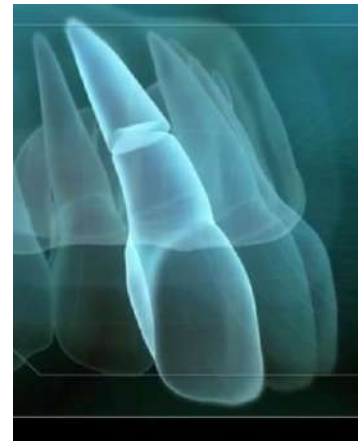Classification

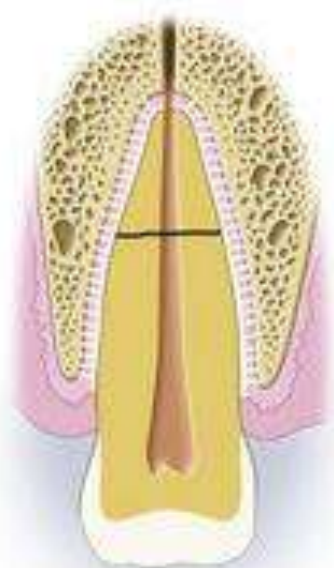
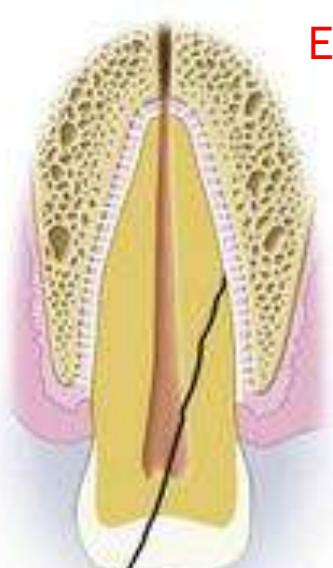
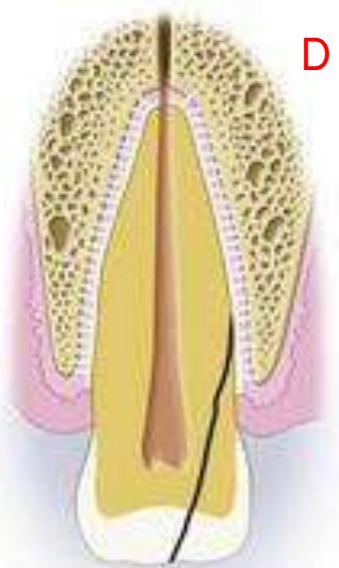
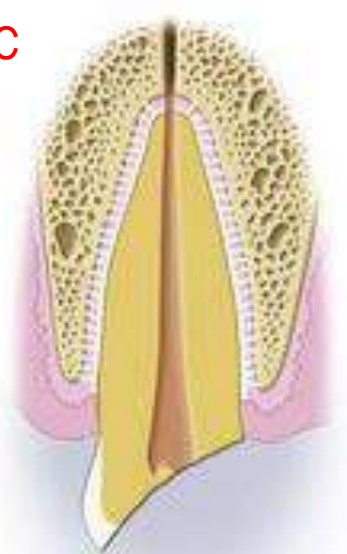
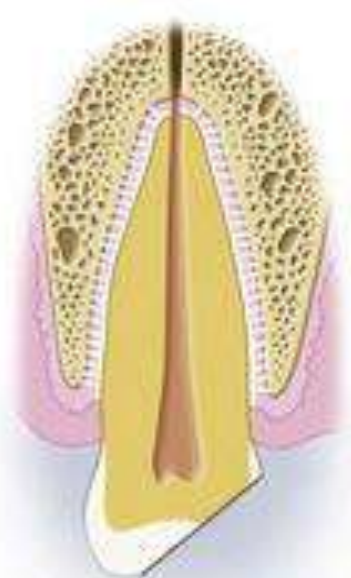
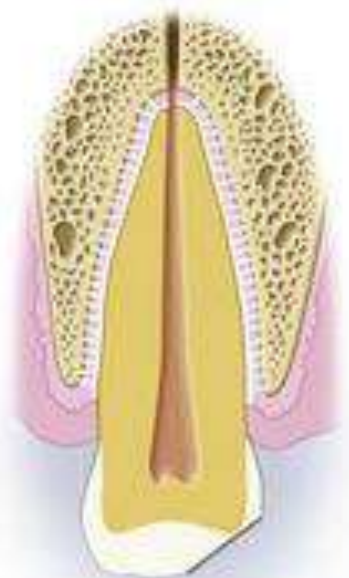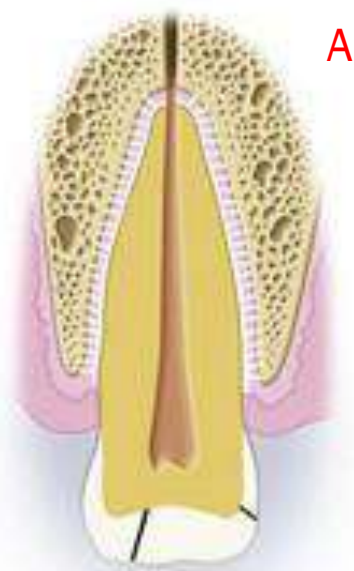
- Injuries to the **Teeth**.
- Injuries to the **PD Tissue**.
- Injuries to the **Alveolar Bone**.
- Injuries to the **Gingiva and Oral Mucosa**.
- Combination.



Injuries to the Teeth

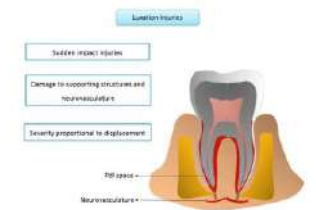- A. **Crown Infraction**; incomplete fracture or crack of enamel without loss of tooth substance.
- B. **Uncomplicated crown fracture**; which is confined to the enamel or involving the enamel and dentin without pulp exposure.
- C. **Complicated crown fracture**; involves enamel and dentin with pulp exposure.
- D. **Uncomplicated crown-root fracture**; involving enamel, dentin and cementum without pulp exposure.
- E. **Complicated crown-root fracture**; involving enamel, dentin and cementum with pulp exposure.
- F. **Root fracture**; involving dentin, cementum and pulp.

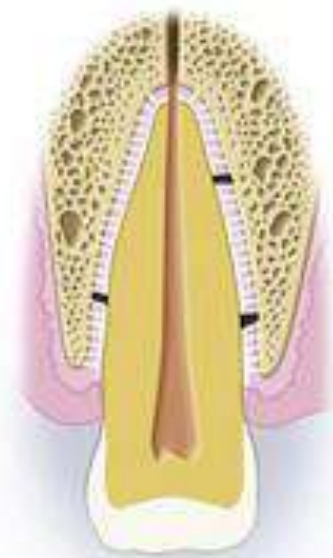



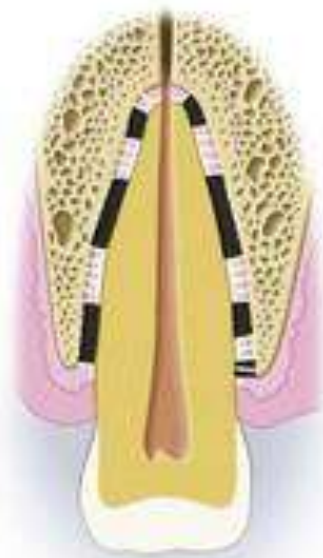Injuries to the Periodontal Tissue

- A. **Concussion;** is an injury to the tooth-supporting structures without abnormal loosening or displacement of the tooth but with marked reaction to percussion.
- B. **Subluxation;** (Loosening) is an injury to the tooth-supporting structures with abnormal loosening but without displacement of the tooth.
- C. **Intrusive luxation;** (Central Dislocation) is displacement of the tooth into the alveolar bone with comminution or fracture of the alveolar socket.
- D. **Extrusive luxation;** (Peripheral Dislocation or partial avulsion) is partial displacement of the tooth out of the alveolar socket.
- E. **Lateral luxation;** is displacement of the tooth in a direction other than axially, accompanied by a comminution or fracture of the alveolar socket.
- F. **Avulsion;** is a complete displacement of a tooth out of the alveolar socket.

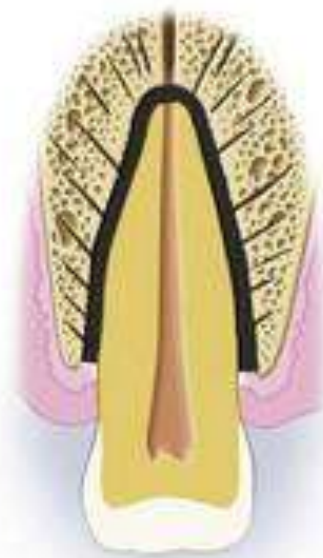




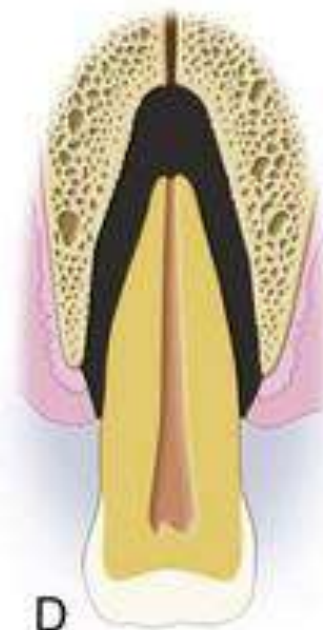A



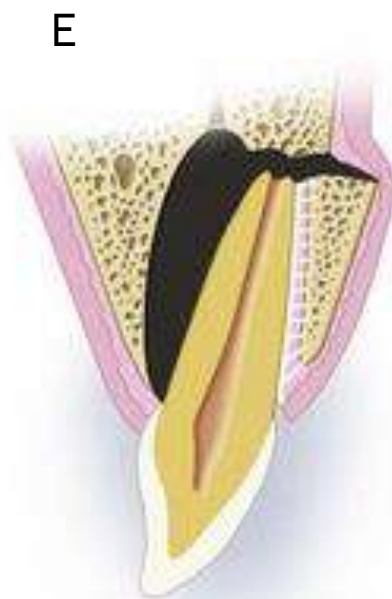B



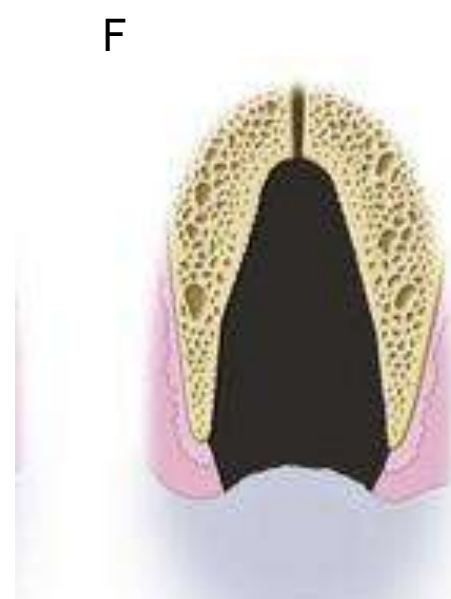
C



D



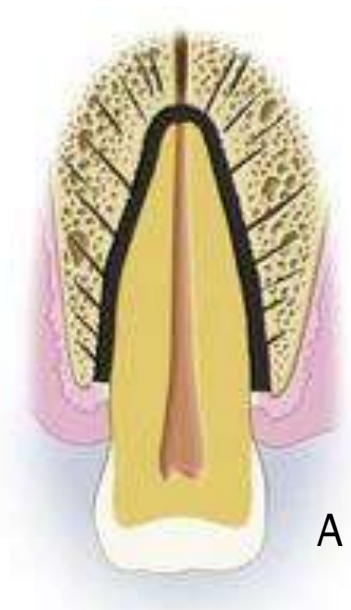E



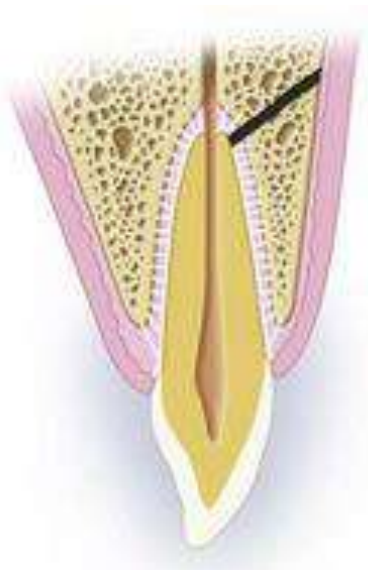
F

Injuries to the Supporting Alveolar Bone

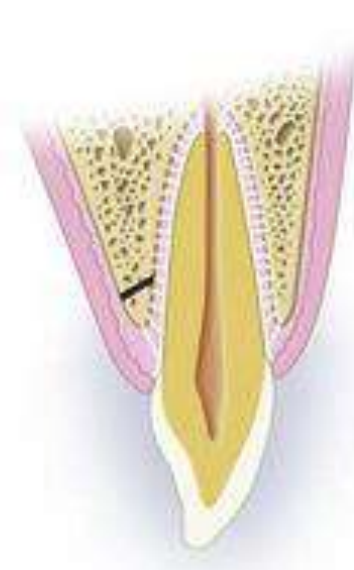
- A. **Comminution** of alveolar socket; it can occur with Intrusive and Lateral Luxation.
- B. Fracture of **a Single** alveolar socket wall; confined to facial or lingual wall.
- C. Fracture of **Both Walls** of socket or alveolus.
- D. Fracture of **Maxilla Or Mandible**; involving the alveolar bone with or without the socket.



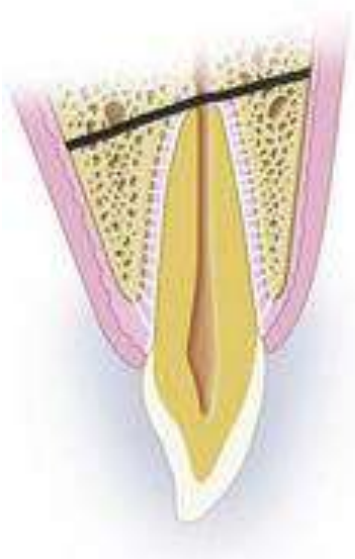
A



B



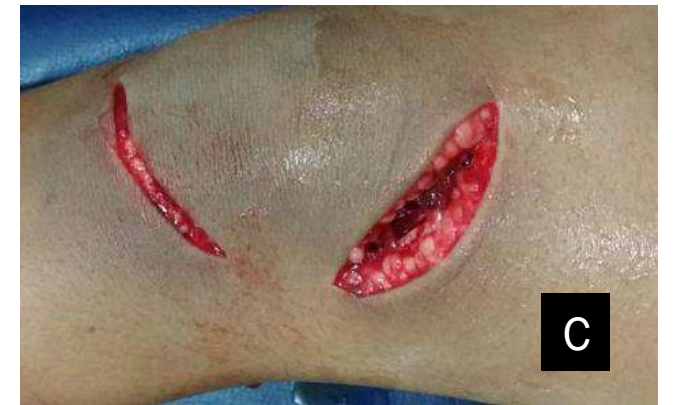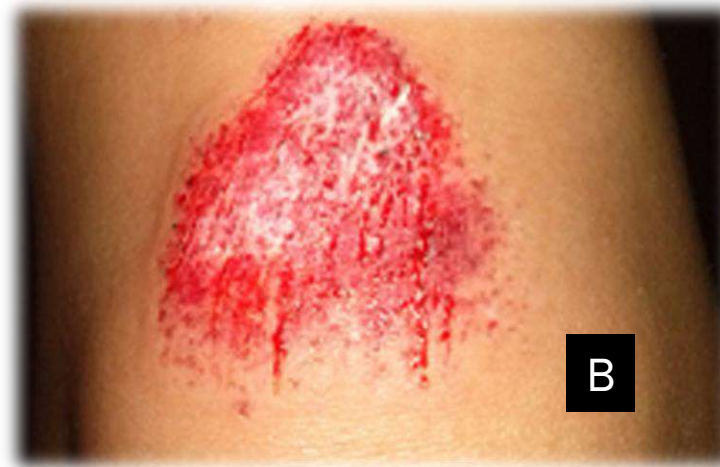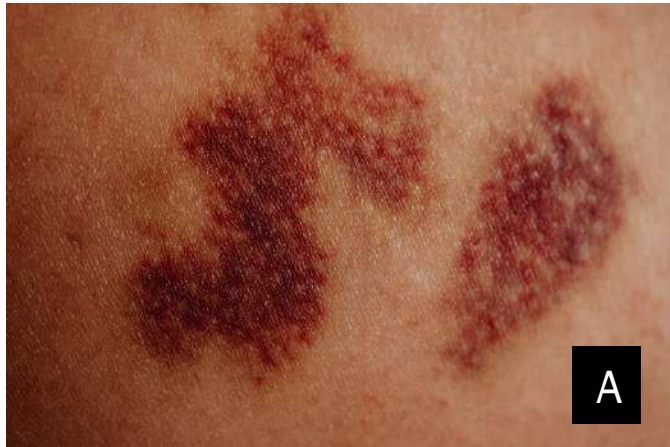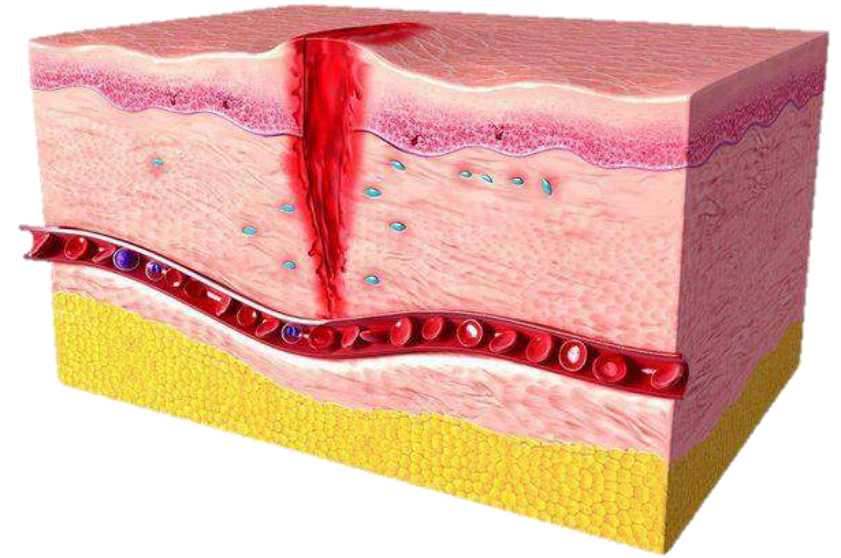
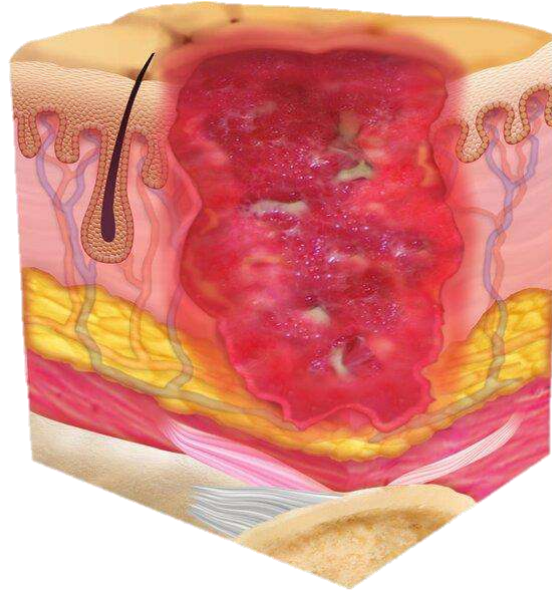
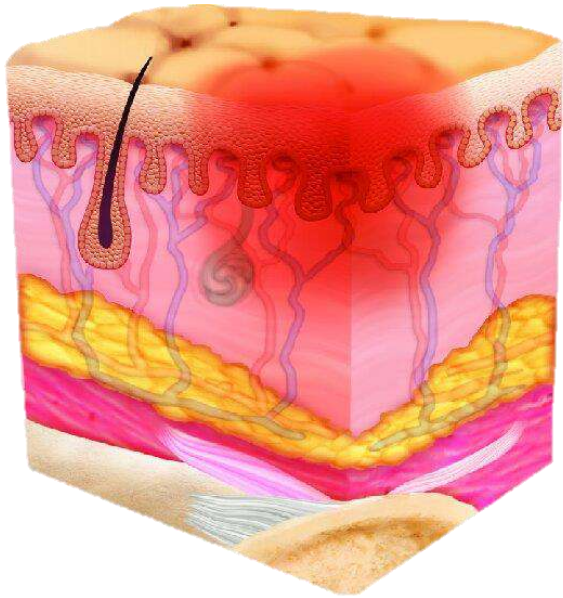
C



D

Injuries to the Gingiva or Oral Mucosa

- A. **Contusion**; a bruise is usually produced by impact from a blunt object and results in submucosal hemorrhage without a break in the mucosa.
- B. **Abrasion**; a superficial wound produced by rubbing or scraping of the mucosa, leaving a raw, bleeding surface.
- C. **Laceration**; a shallow or deep wound in the mucosa results from a tear and is usually produced by a sharp object.



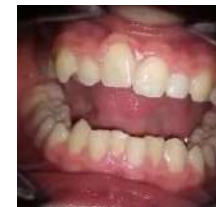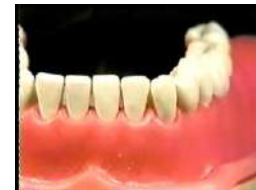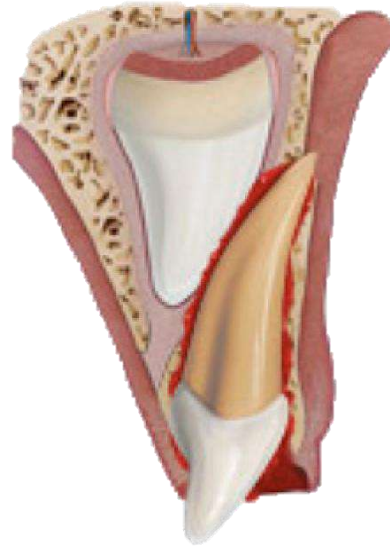Examination and Clinical Manifestations

- A complete history of the mechanism and events of the injury should be obtained and a thorough clinical examination and radiographic investigation performed quickly to ensure proper diagnosis and treatment.

Clinical Examination

- Inspection of soft tissue for embedded fragments of tooth or debris.
- Lacerations, abrasions, and contusions evaluated for damage to Vital Structures.
- The teeth should be examined for abnormal mobility.
- Missing teeth or pieces of teeth (aspirated, swallowed, or displaced into soft tissue of the lip, cheek, floor of the mouth, neck, nasal cavity, or maxillary sinus).

- Dentoalveolar fractures are commonly associated with **significant damage** to the lips.
- Portions of tooth or foreign bodies embedded in the soft tissues
- The direction of tooth displacement should be noted. In the primary dentition, the dislocation of the apex of the Displaced Primary Tooth can possibly damage the permanent successor.
- The involved teeth should be tapped or percussed with the handle of a mouth mirror
- **Pain with Percussion** is suggestive of injury to the periodontal ligament.
- **Sound by Percussion; Hard Metallic Ring** is elicited with teeth locked into bone
- **Dull Sound** indicates a subluxated tooth.
- Pulp testing during the acute phase of injury is of questionable value.

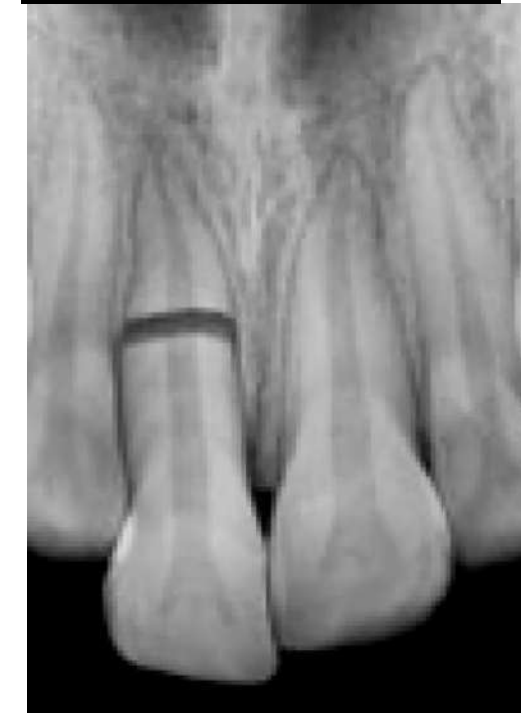
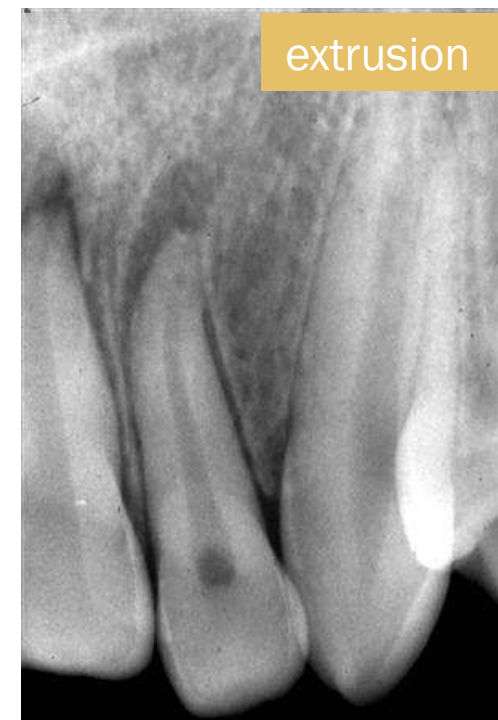
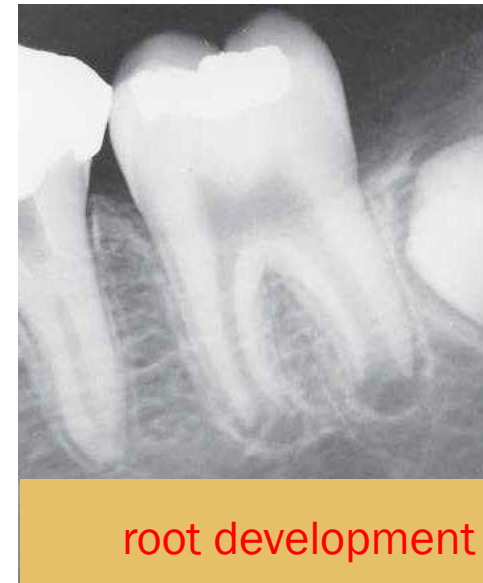Radiographic Evaluation

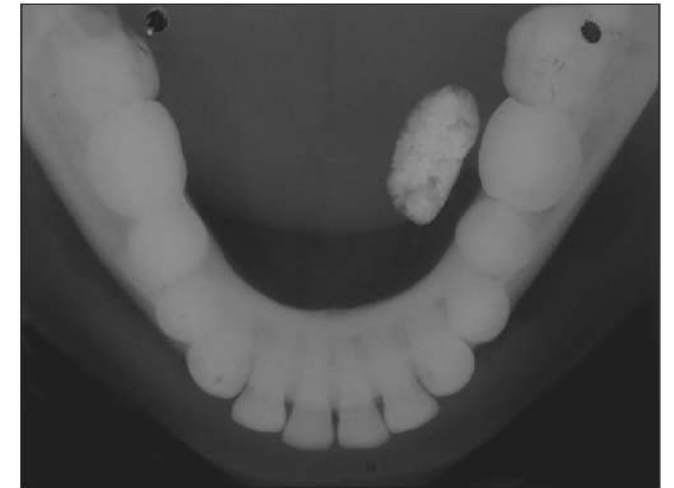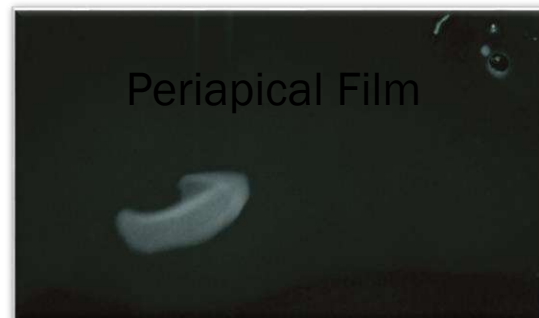
- A single radiograph may not be sufficient
- Most commonly both occlusal and periapical radiographs used,

It should provide the following information:

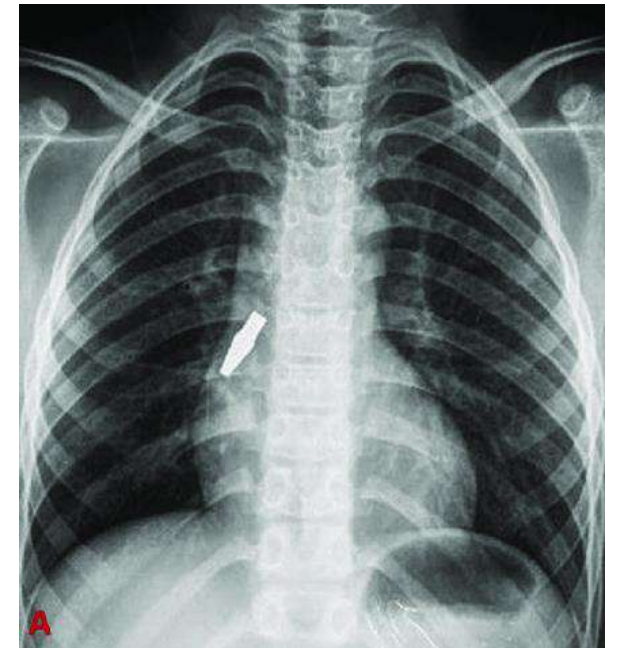- Presence of root fractures
- Degree of extrusion or intrusion
- Extent of root development
- Size of the pulp chamber and root canal
- Tooth fragments and foreign bodies lodged in soft tissue.



- A radiographic examination of the **head, neck, chest and abdomen** must be performed to rule out the presence of teeth or fragments.
- Radiographic evaluations for foreign bodies within the **soft tissues of the lips or cheeks** are taken with the radiographic periapical film, placed labial to the alveolus with a reduced exposure time.
- Foreign bodies in the **floor of the mouth** are viewed with **occlusal radiograph**.



Occlusal Radiograph.



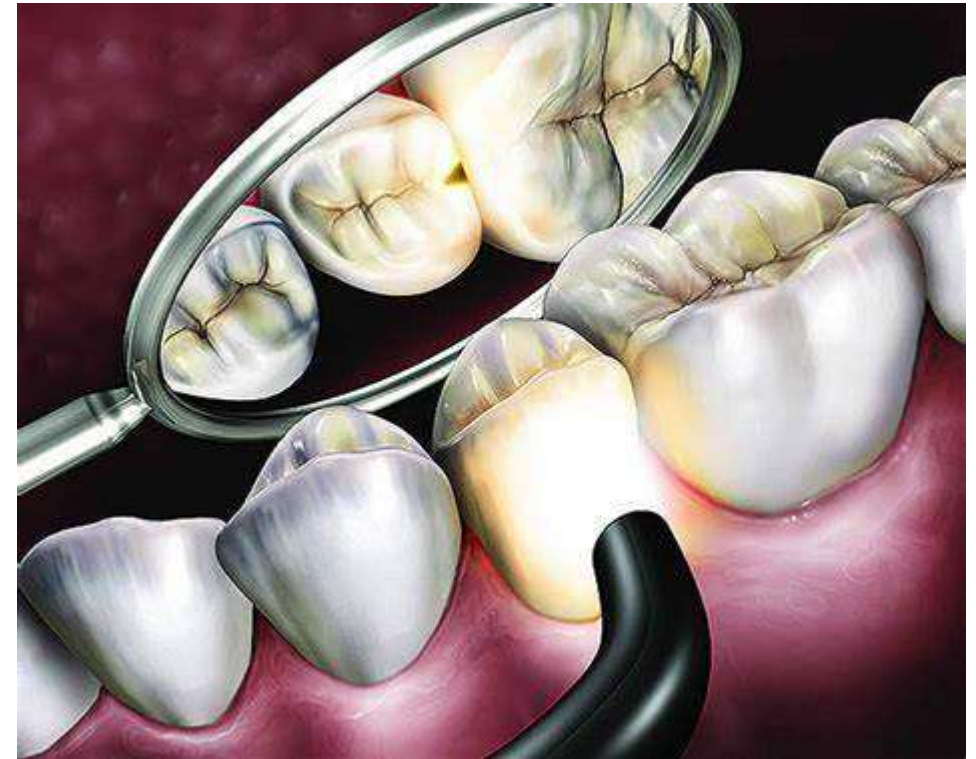
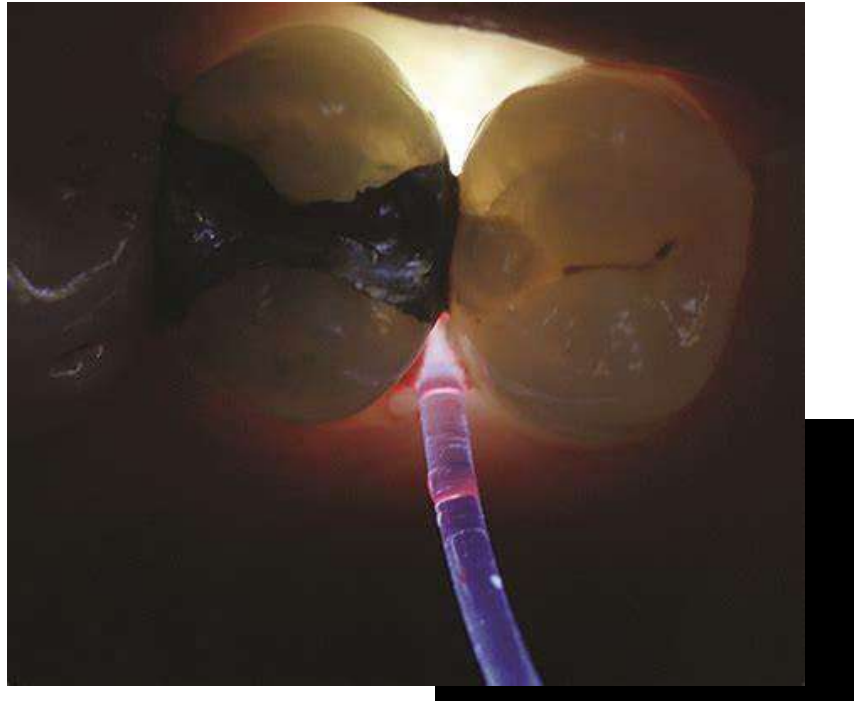
Chest X-ray

Treatment - Factors to be considered:

- Age of patient and degree of cooperation.
- If the injury involves primary or permanent teeth and the degree of root development and if the apical foramen is wide or narrow.
- Location and extent of injury.
- Residual bone support.
- Periodontal health of the remaining teeth.
- Vitality of the teeth.
- Injury to the soft tissues.
- Concomitant injuries.
- Time between trauma and treatment.

Treatment of Crown Infraction

- Evaluation is by direct trans-illumination. (directing a light beam perpendicular to the long axis of the tooth from the incisal edge).
- **No treatment** is required for cracks, vitality test should be performed at the time of diagnosis with periodic follow up.



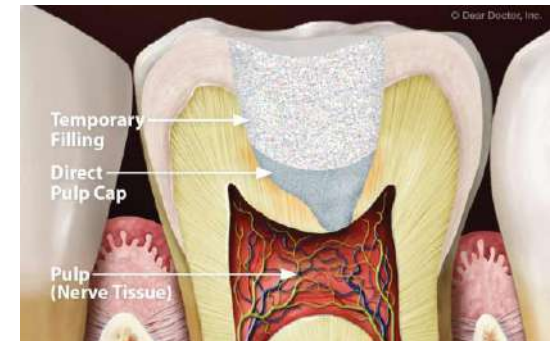
Treatment of Crown Fracture

- **Limited to enamel** → smoothing of the sharp edges and restoration with composite.
- **Enamel and dentin** → covering the exposed dentin with a liner and restoration with composite.
- **Crown fracture with pulp exposure** → pulp capping with CaOH liner or MTA, pulpotomy or endodontic treatment.
- **Crown-root fracture** → preserve the root fragment to support a (post and crown) prosthesis.

Primary teeth should be extracted.

If the fracture line is above cervical margin, the tooth can be restored.

If the fracture continues apically, extraction of the tooth may be indicated.



- **Complicated crown-root fracture** → the level of the root fracture determines the treatment. Extraction indicated if the coronal segment includes more than $\frac{1}{3}$ of the clinical root or in cases of vertical root fractures; otherwise, the tooth treated endodontically and restored.

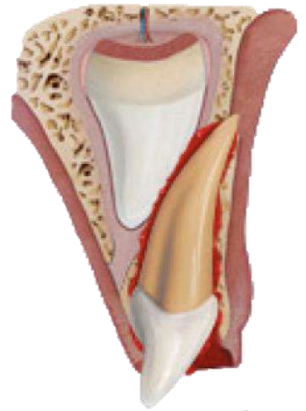
Treatment of Root Fracture

In **Primary Teeth** without mobility → can be preserved.

- If there is mobility, the tooth should be removed without attempts to remove the apical fragments.
- Normal physiologic resorption of the apical fragment can be expected.

In **Permanent Teeth** → the prognosis depends on the level of fracture.

- Fractures near the gingival level have a **poor prognosis**.
- Fractures in the middle to apical one third of the root have a **good prognosis** for survival of the pulp and healing of the root fragments to one another.
- These fractures treated with repositioning and firm immobilization for 2 to 3 months.
- During this time, bridging of the fracture with calcified tissue usually occurs, and the tooth remains vital.
- **Vertical root** fractures should be extracted.



Treatment of Injuries to the Periodontal Tissue

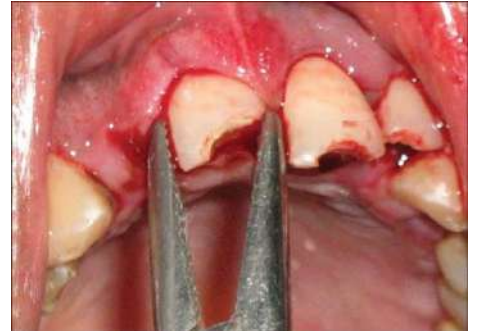- **Concussion** → No treatment, Occlusal adjustment, Periodic follow up.
- **Subluxation** → Treatment includes soft diet or occlusal adjustment. Splinting for 7-10 days.
- **Intrusive luxation** → For Primary Dentition, extract immediately.

For Permanent Teeth the recommended treatment includes:

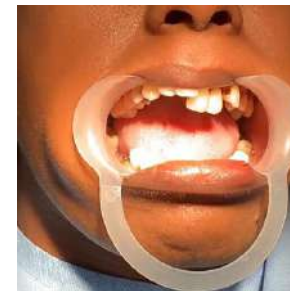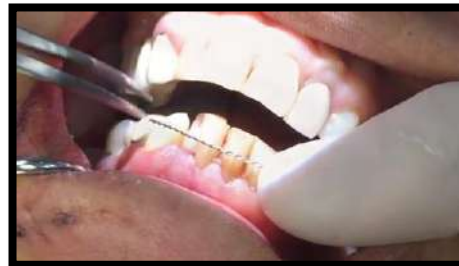- **The tooth allowed to Erupt if Immature.**
- **Surgical repositioning with splinting.**

In future, External Root Resorption and Marginal Bone Loss because of additional trauma to the periodontal structures.

- **Low-force Orthodontic Repositioning** of teeth can be carried out over a period of 3 to 4 weeks to allow remodeling of the bone and periodontal fibers.



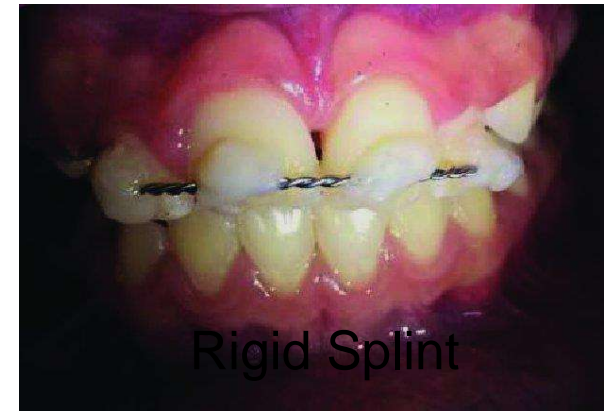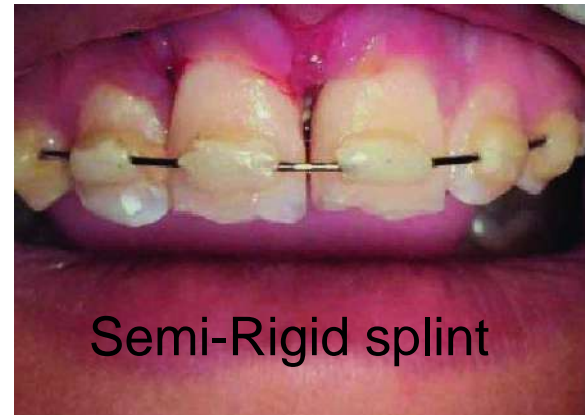- **Extrusive luxation** → The tooth manipulated digitally into position and splinted for 1 - 2 weeks.
- **Lateral luxation** → is accompanied by comminution or fracture of the alveolar socket. The tooth and alveolar bone manipulated digitally (usually with force) and splinted for 2-8 weeks.
- If delayed more than 48 hours, it is difficult to reposition the tooth manually, orthodontic intervention may be necessary.
- **Avulsion (ex-articulation)** → is an urgent situation requiring immediate action.



Factors that influence **SUCCESS** of avulsed tooth are:

- The stage of root development; survival of pulp is possible with incomplete root formation
- The length of time the tooth is allowed to dry; 30 min to 2 hours
- The length of storage outside the mouth.
- The medium used and correct handling.
- Storage media include: saliva, saline, milk, it provide pH compatibility to vital cells, freedom from bacteria, and maintaining vitality of the PDL cells 3 hours
- Hank's balanced salt solution (HBSS), is composed of inorganic salts and supplemented with glucose, excellent storage potential.
- Water is the least desirable, hypotonic environment, which can cause cell lysis.

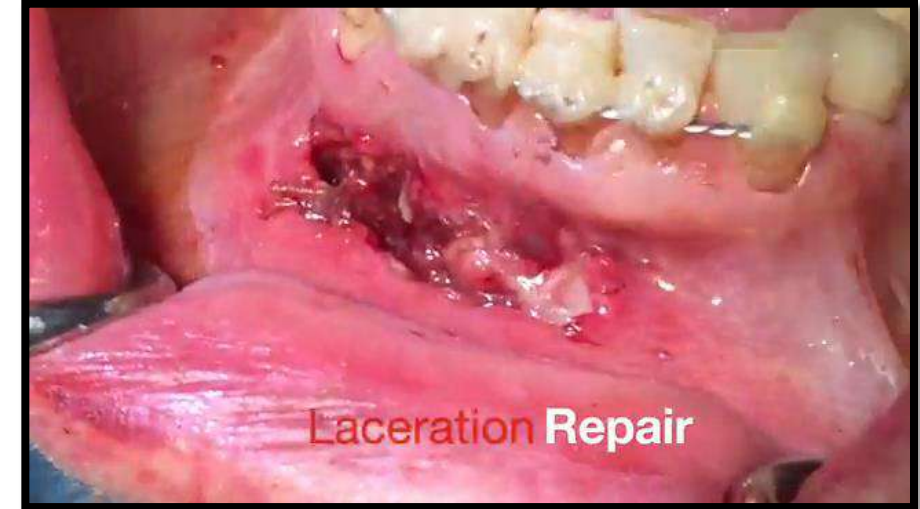- Immediate replacement is still the ideal treatment.
- The involved tooth should be splinted with a **Semi-Rigid Splint** for 7 to 10 days.
- **Rigid splinting** of reimplanted teeth increases the extent of root resorption; thus, a minimum of 1 week is sufficient.
- If there is associated alveolar fracture, a Rigid Splint should be used for 3 to 4 weeks
- Replanted teeth should be followed up regularly.



Treatment of Injuries to the Supporting Alveolar Wall

Fractures of alveolar socket wall or alveolar process :

- Closed Reduction of the fracture by Digital Manipulation
- Occlusion checked and corrected.
- Soft tissue lacerations sutured
- Rigid splint 4 weeks for involved teeth.
- Open reduction is rarely performed.
- The children, a soft diet for 2 weeks, with periodic follow-up to monitor pulp health.



Splinting Techniques

- Splinting provides **Stabilization** of traumatized teeth and **Prevents** further damage to the pulp and periodontal tissue during the healing period, allowing the attachment apparatus time to regenerate.
- In most cases splints maintained for 10-14 days.
- For alveolar bone fractures 6 weeks.
- For root fractures 2-4 months.

The **Requirements** for an acceptable splint are as follows:

- It is easy to fabricate directly in the mouth, without LAB procedures.
- It can be placed passively without force to the teeth.
- It does not contact the gingival tissue and thus cause gingival irritation.
- It does not interfere with normal occlusion.
- It is easily cleaned and allows proper oral hygiene.
- It does not traumatize the teeth or gingiva during application.
- It allows an approach for endodontic therapy.
- It is easily removed.

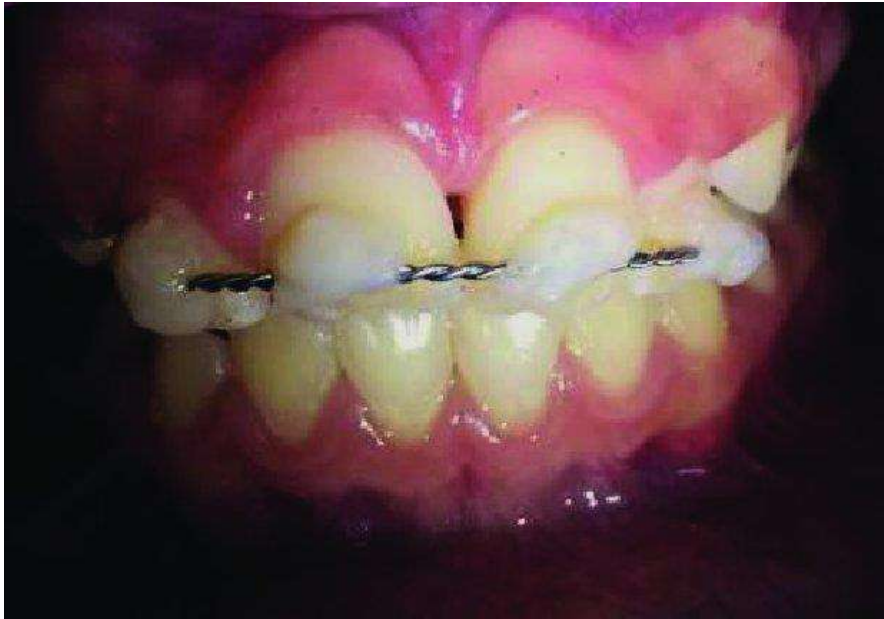- It provides good esthetic results.
- It does not injure the pulp of the traumatized teeth or adjacent teeth.
- It does not interfere with intraoral radiographic techniques.
- It allows placement of a rubber dam in all types of dentition.
- It does not promote root resorption.
- It allows slight mobility so that the position of the tooth after reimplantation exerts minimal pressure between the root surface and the alveolar bone.
- It is economical and requires minimal specialized equipment.

Splint Types

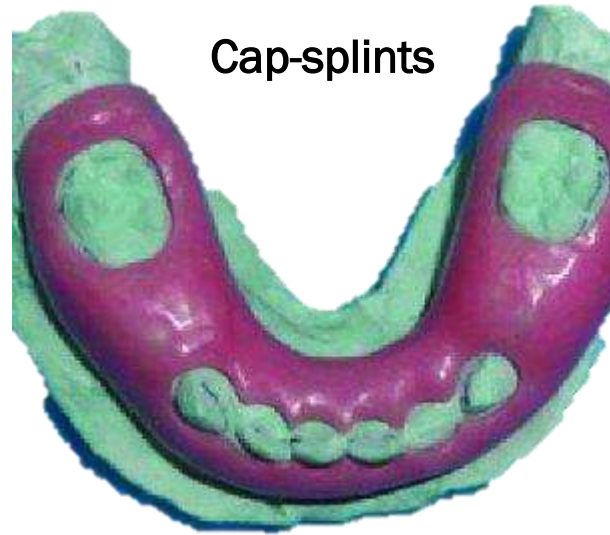
- Enamel bonded composite resin splints
- Etch wire composite splint
- Cap-splints
- Vacuum-formed plastic splints
- Orthodontic appliance
- Arch bars
- Interdental wiring techniques - Figure-of-eight wiring

Loop wiring

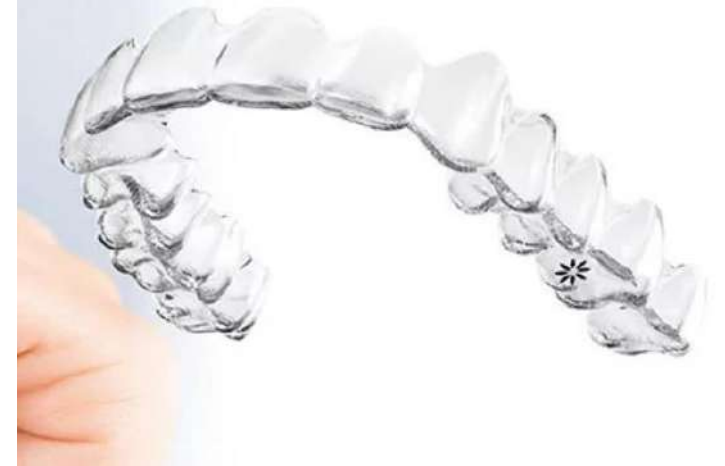Etch wire composite splint



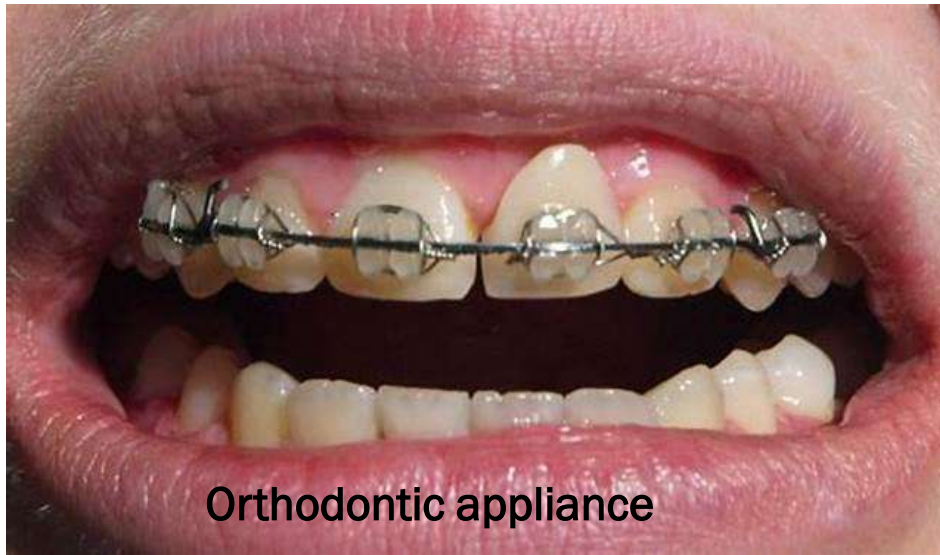Cap-splints



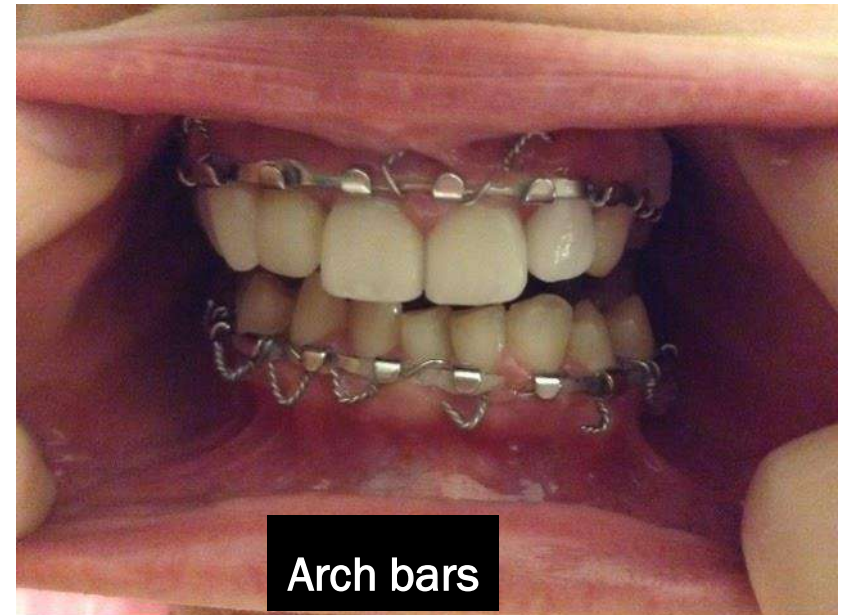Vacuum-formed plastic splints



Orthodontic appliance



Arch bars



Complications

- Traumatized teeth may develop Pulpitis or become devitalized. So treated endodontically.
- Internal Discoloration due to canal obliteration or pulp necrosis.
- Local Gingivitis when fixation involves wires or arch bars.
- Untreated alveolar fractures either unite in an incorrect position or infected.
- Tooth Fragments embedded in the lip, heal over and remain as hard lumps
- Root resorption (External more than Internal) due to inflammatory stimulus.
- Ankylosis due to severe dental trauma.
 - Damaged PDL and cementum replaced by bone.
 - Avulsed, re-implanted teeth with extended extra-alveolar dry time and closed apices are susceptible to ankylosis.
 - Rigid stabilization of teeth predispose to ankylosis and external root resorption.
 - Physiologic movements of the tooth promote fibrous (desired) attachment instead of osseous attachment of the root to alveolar bone (ankylosis).

Soft Tissue Injuries

- Soft tissues include all the non-bony structures: skin, fat, muscle, nerves and blood vessels.
- Soft tissue facial injuries can be in the form of: Abrasions, Contusions, Lacerations or A Combination.

Contusion (Bruise – Closed Wound)


- Results from subcutaneous or submucosal hemorrhage without a break in the soft tissue surface, caused by blunt trauma.
- **No treatment.** Within several days the body resorbs the hemorrhage formed within a contusion
- **Ecchymosis** caused by extravasation of blood into the skin or mucosa will change in color from purplish to blue, green, and yellow before fading.



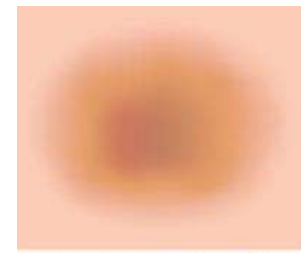
Stage 1 - Reddish



Stage 2 - Purple



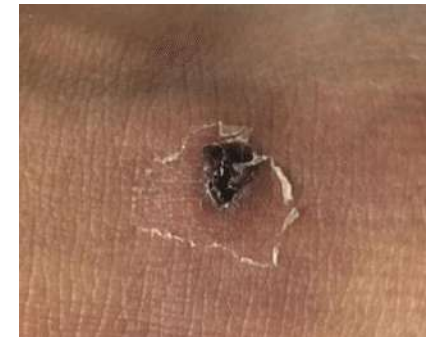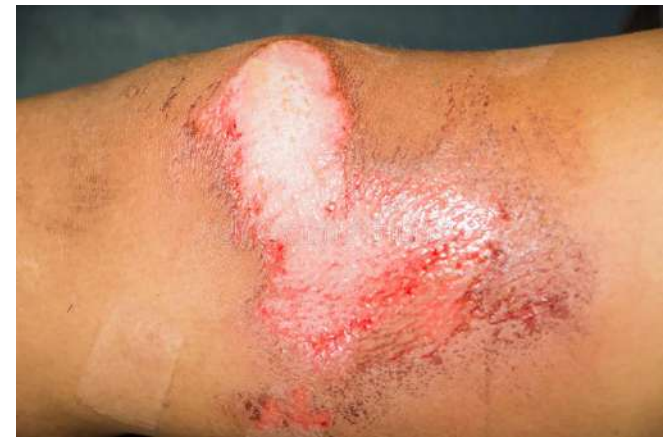Stage 3 - blueish



Stage 4 - yellowish

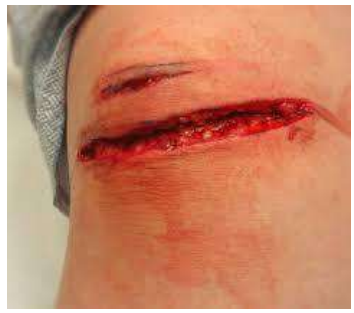Abrasion

- Superficial wound denudes the epithelium, Caused by friction.
- Painful because they involve the terminal nerve endings.
- Capillary Bleeding responds well to application of gentle pressure.
- Re-epithelialization occurs without scarring.
- Healing of the deeper dermis tissues occurs with scar formation.
- Management - Cleansing to remove foreign material.
- If particles remain within the tissue, a permanent “tattoo”.
- Deep contaminated abrasions require anesthesia and a surgical scrub brush.
- Topical application of an antibiotic ointment is adequate treatment.
- A loose bandage can be applied if the abrasion is deep.
- Systemic antibiotics are not usually indicated.
- Re-epithelialization occurs under the eschar (scab) the eschar will then drop off.



Laceration

- It is a tear in the epithelial and subepithelial tissues caused by a sharp object.
- If the object is not sharp, the lacerations created may be jagged.
- The depth may involve the external surface only, others may extend deep, disrupting nerves, blood vessels, muscle, and other major structures.



- Management Involves Four Major Steps:

1. Cleansing; with normal saline, a brush may be needed.

2. Débridement; removal of contused, devitalized tissue and jagged pieces of surface tissue to enable linear closure.

- In the maxillofacial region, which has a rich blood supply, the amount of debridement kept to a minimum.

3. Hemostasis; it may necessitate ligation or cauterization

4. Closure ; proper positioning of all tissue layers from inside out.

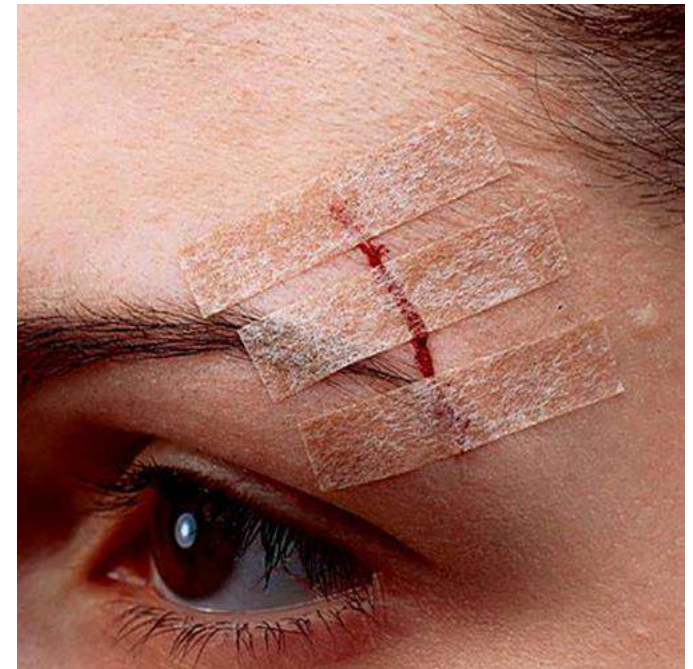- Resorbable sutures should be used to close the muscle layer,
- After which the mucosa and/or skin is sutured.
- The wound edges should be well aligned to prevent scar.

Blood Vessel Ligation



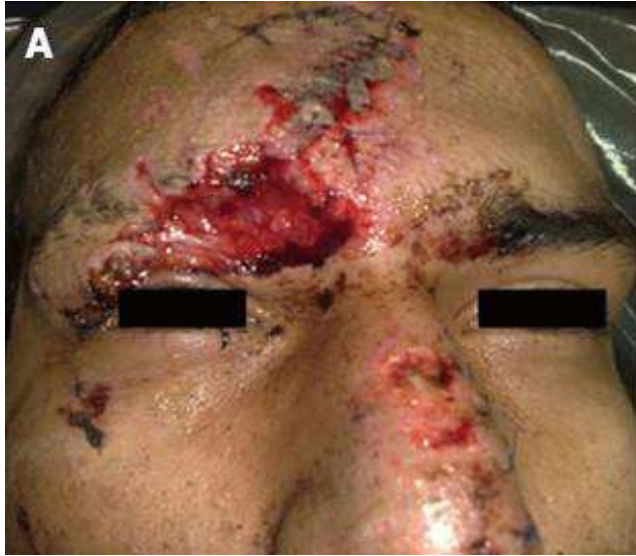Health Education
Yorkshire and the Humber

- Systemic Antibiotics (e.g., Penicillin) considered in deep and full thickness lacerations; otherwise the dermal surface covered with an topical antibiotic ointment.
- Facial skin sutures should be removed 4 to 6 days postoperatively; adhesive strips can be placed to give external support to the wound.

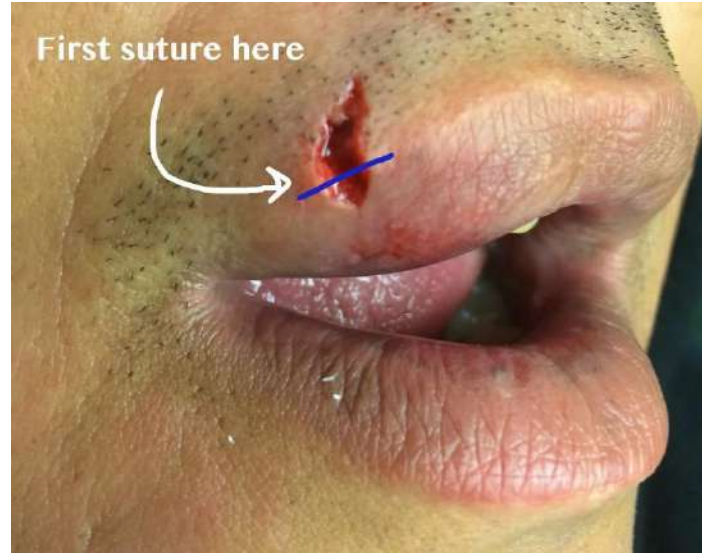

Facial Wounds of Special Significance

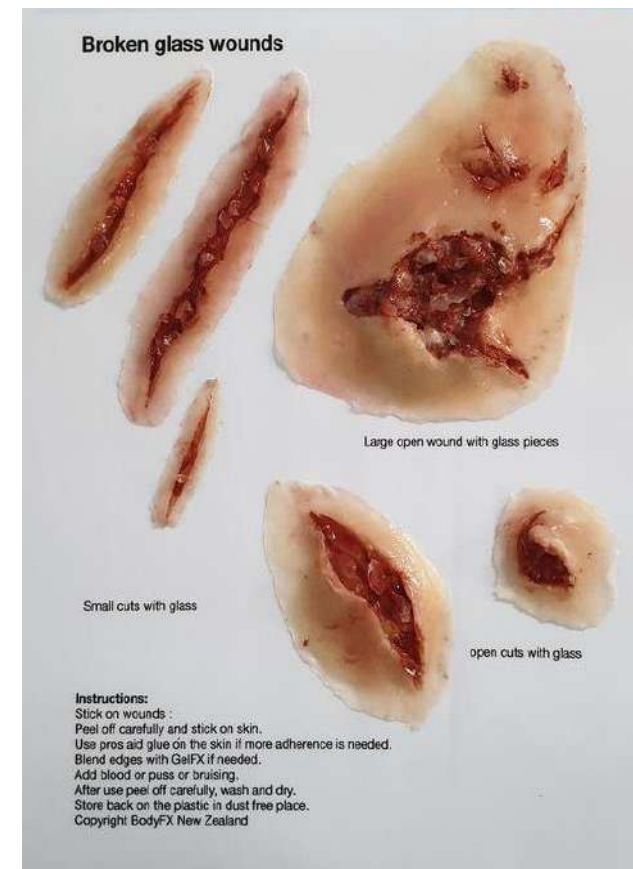
1. Wound with tissue loss (missile injuries) not suitable for primary repair because of tissue necrosis.
2. Animal and Human Bites. The bacteria and saliva contamination interfere with healing.
3. Shelved wounds such as those produced by glass fragments.
4. Lacerations of the eyelids and eyebrow particularly those involving the lacrimal canaliculi.
5. Lip lacerations involving the red margin, need accurate realignment of the vermilion.
6. Cheek lacerations transecting major branches of the facial nerve or parotid duct.



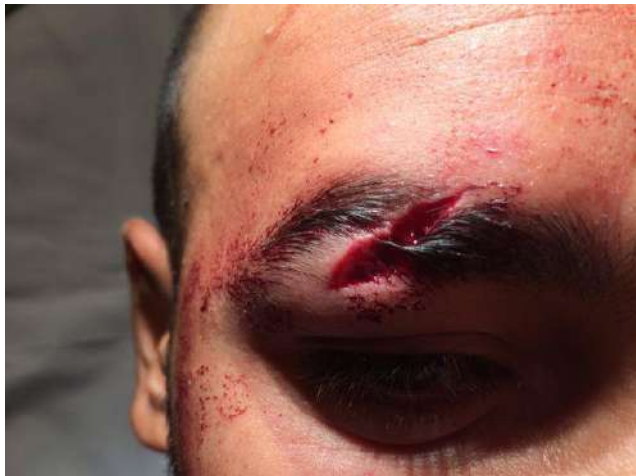missile injuries



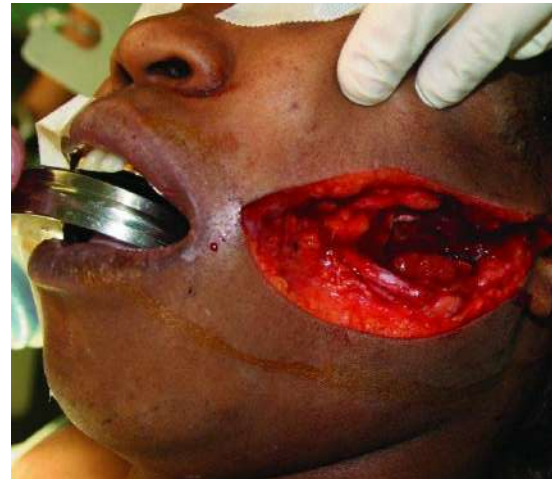Lip lacerations



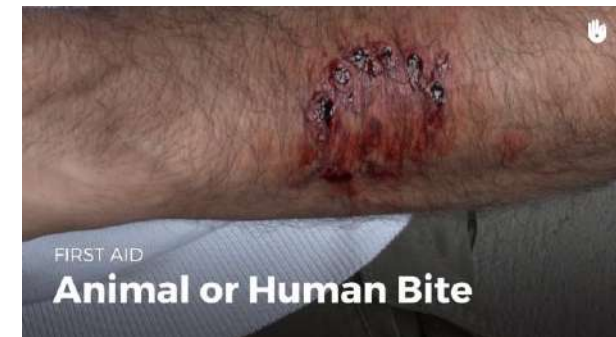Shelved wounds



Lacerations of the eyebrow



Cheek lacerations (facial nerve or parotid duct.)



1- With respect to splinting in dentoalveolar injuries, the longest period of splinting is required in

- A. Extrusive luxation.
- B. Alveolar bone fracture.
- C. Intrusive luxation.
- D. Root fracture.
- E. Subluxation.

2. is an injury to the tooth supporting structures with mobility and without displaced tooth

- A. concussion
- B. Lateral luxation.
- C. subluxation
- D. Avulsion.
- E. Intrusive luxation.

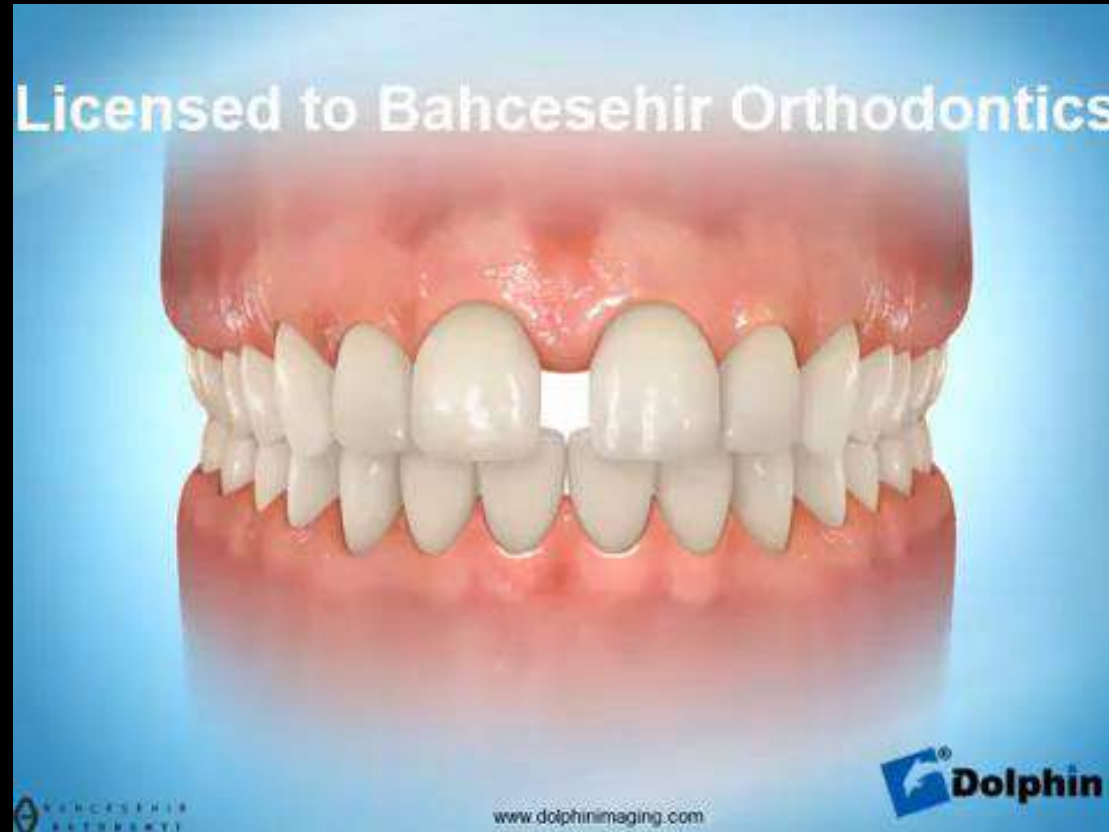3. Debridement of the wound referred

- A. The removal of contused and devitalized tissue from a wound.
- B. Remove debris by copious irrigation with normal saline.
- C. Proper positioning of all tissue layers from inside out.
- D. Ligation or cauterization of the bleeding.
- E. None of the above.

4. In cases of avulsion, the least desirable storage media is

- A. Water.
- B. Saliva.
- C. Saline.
- D. Milk.
- E. Hank's balanced salt solution (HBSS).

PREPROSTHETIC SURGERY



Bashar Abdul-Ghani

FICMS. MAXFACS Cons. MFDS. RCSED. RCPS (Glasg).

Lecture Quoted From Baghdad University Curriculum

Definition

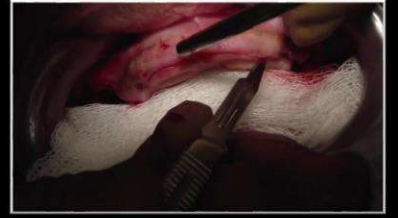- Preprosthetic surgery comprises a group of soft and hard tissue procedures.
- Preprosthetic surgery exists to serve the needs of dentists who provide patients with replacements for missing teeth and associated tissues.
- The **purpose** is to **facilitate** the fabrication of prostheses or to **improve** the outcome of prosthodontic treatment.
- **Bony recontouring procedures:** alveoloplasty, maxillary tuberosity reduction, exostoses and excessive undercuts, mylohyoid ridge and genial tubercle reduction and torus removal.
- **Soft tissue procedures:** unsupported hypermobile tissue on the alveolar ridge, inflammatory fibrous hyperplasia (epulis fissuratum), labial frenectomy, lingual frenectomy, ridge extension (vestibuloplasty)

Bony Recontouring Procedures

- Preoperative Planning: begins with

1. Thorough history (**Systemic Conditions** that may directly affect bone healing).
2. **Clinical examination focuses on Bony Projections and Undercuts**, large tori, and other gross ridge abnormalities. The interarch relationship should be evaluated.
3. **Radiographs** are reviewed for bony pathology, impacted teeth, retained root tips, degree of maxillary sinus pneumatization, and the position of the inferior alveolar canal and mental foramina.

Alveoloplasty



- Alveolar bone irregularities found at the time of extraction or after healing.

1- An incision along the crest of the alveolus, flap extension 1 cm mesial and distal to the site.

2. A full-thickness envelope flap is then elevated. Note that Extensive flap reflection may lead to devitalization of bone and should be avoided. Why!?

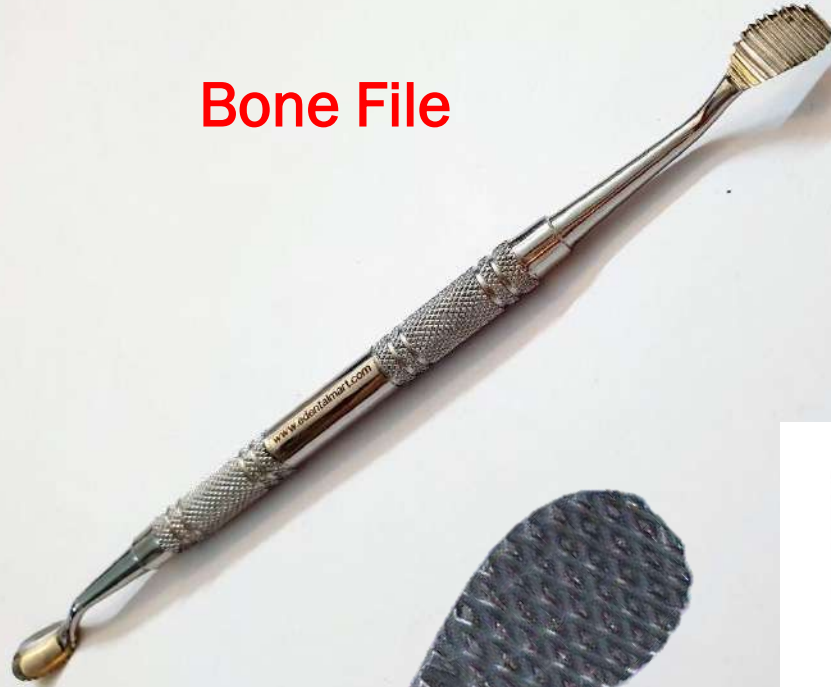3. Smaller irregularities require **Digital Compression of the Socket Walls**. While **Rongeur, Bone File, Handpiece with Bur, or (Mallet And Osteotome)** used for larger one.

4. Irrigation with normal saline is critical to maintain bony temperature less than 47 C°.

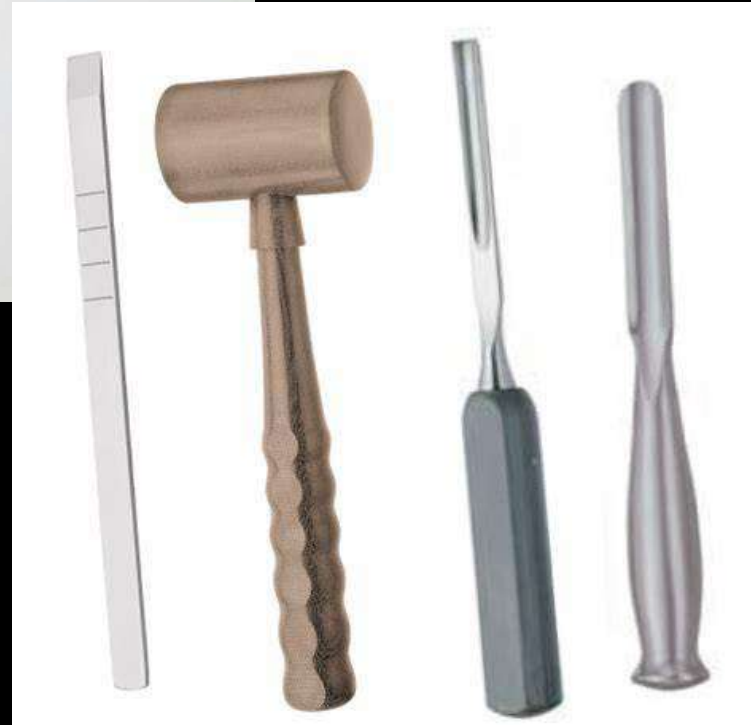5. The site is inspected carefully. Undetected residual **Free Bony Fragments** lead to delayed postoperative healing or possibly infection.

6. The mucoperiosteal flap is reapproximated. Excess soft tissue should also be removed at this time. The flap is then closed with a resorbable suture, (fewer knots are more comfortable and hygienic).

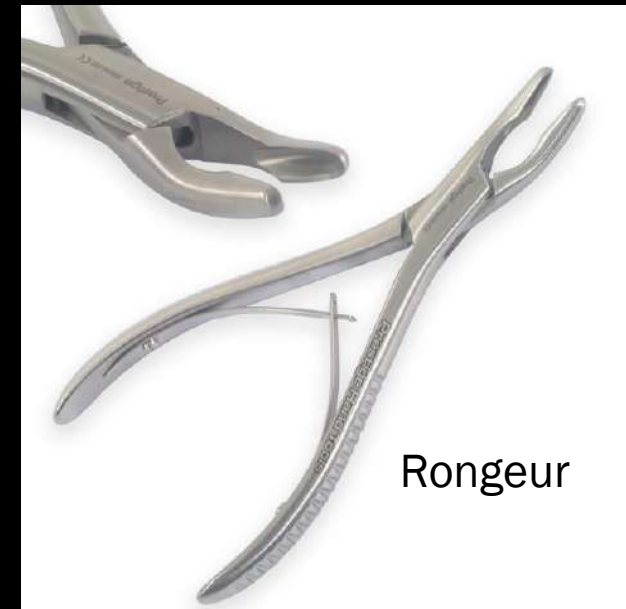
Bone File



Rotary Instrument



Mallet And Osteotome

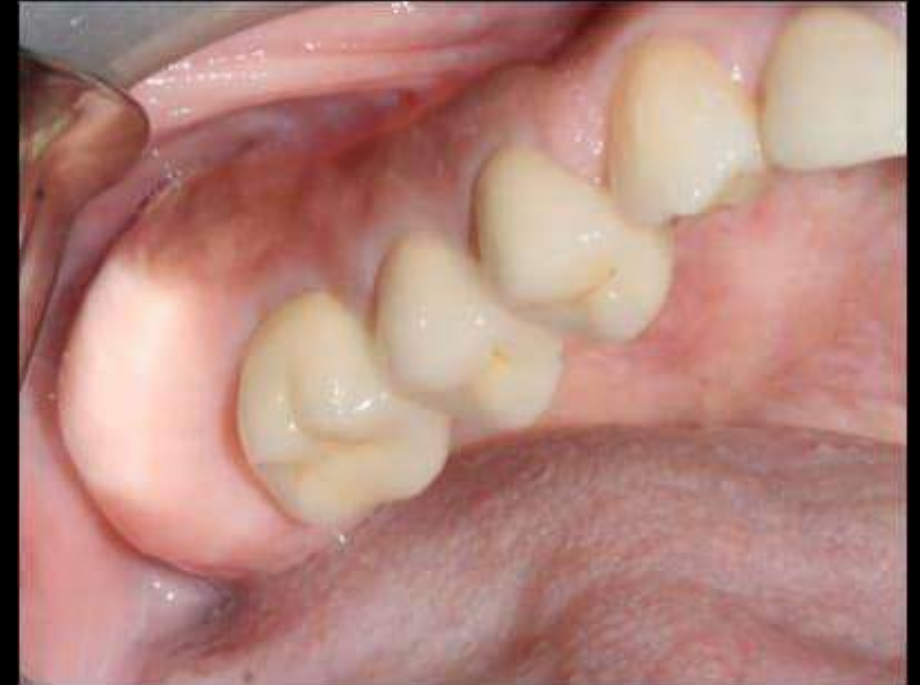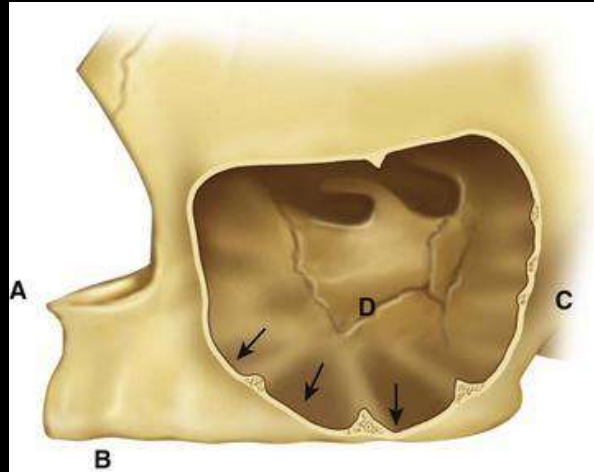


Rongeur

Maxillary Tuberosity Reduction (Hard Tissue)

1. **Find the cause:** An OPG (to locate the floor of the maxillary sinus) and selective probing with needle (to determine the extent of soft tissue).

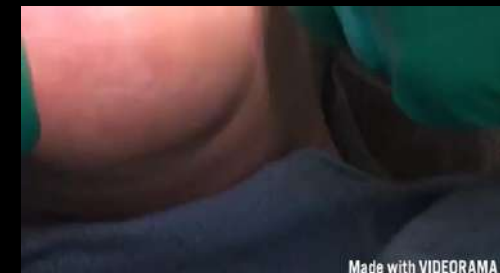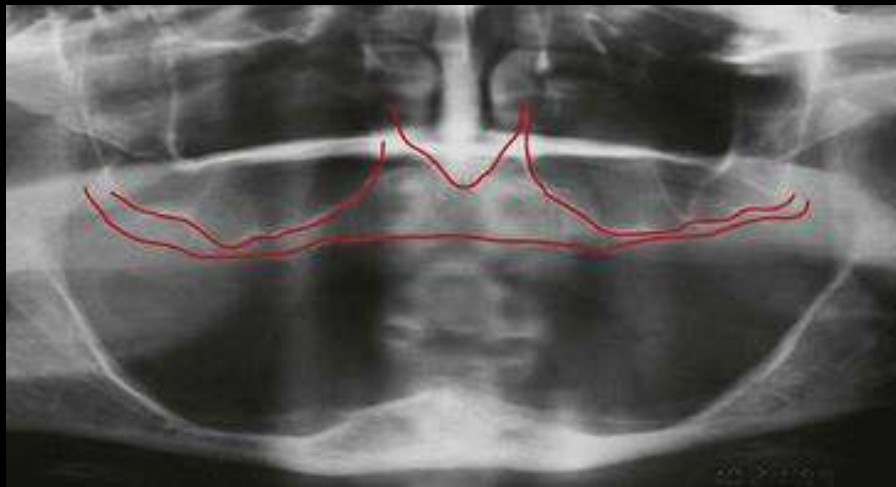
2. **Intermaxillary Distance:**



- It should be at least 1 cm.
- The mirror pass free between tuberosity and retromolar pad suggests adequate **Vertical Clearance**.
- The mirror then placed laterally to the tuberosity, patient instructed to open and close. If the mirror intrudes on the mandible's path during function, **Horizontal Reduction** of the tuberosity is required.

3. Surgery:

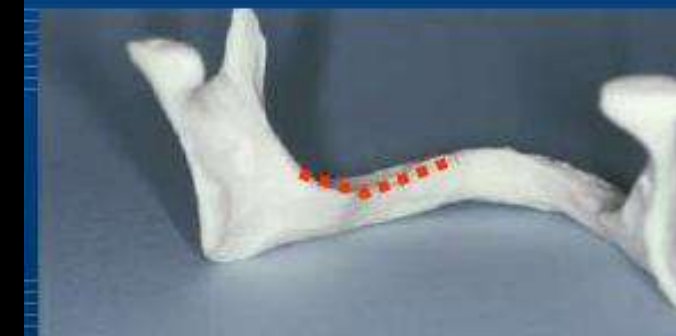
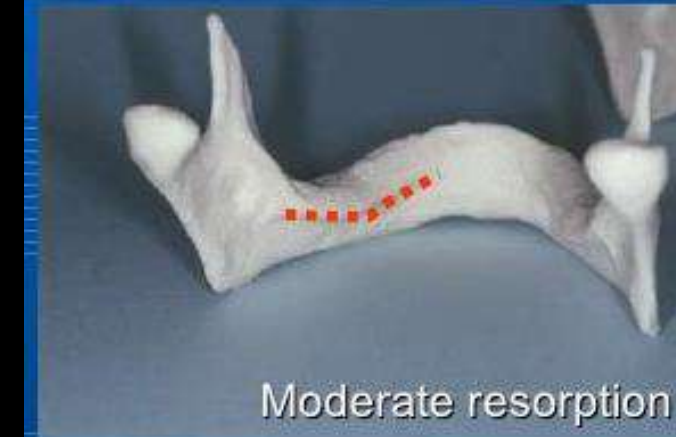
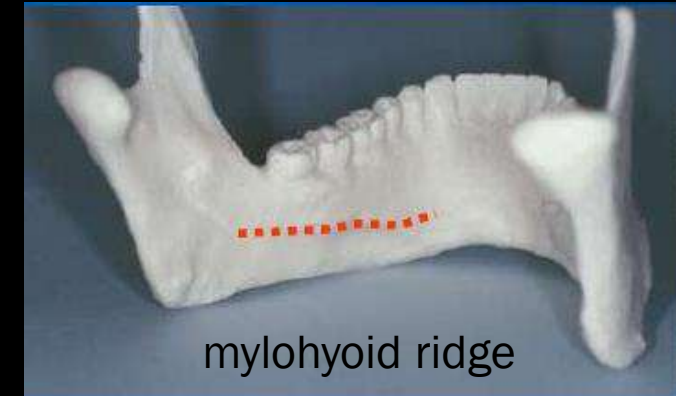- Local anesthetic infiltration. a Crestal incision extends to the posterior aspect of the tuberosity area.
- Reflection of a full-thickness Mucoperiosteal flap.
- Bone removed using a Rongeur or Rotary instruments with copious irrigation.
- Flap sutured, remain in place for 7 days.
- Initial denture impressions can be completed 4 weeks after surgery



Mylohyoid Ridge Reduction

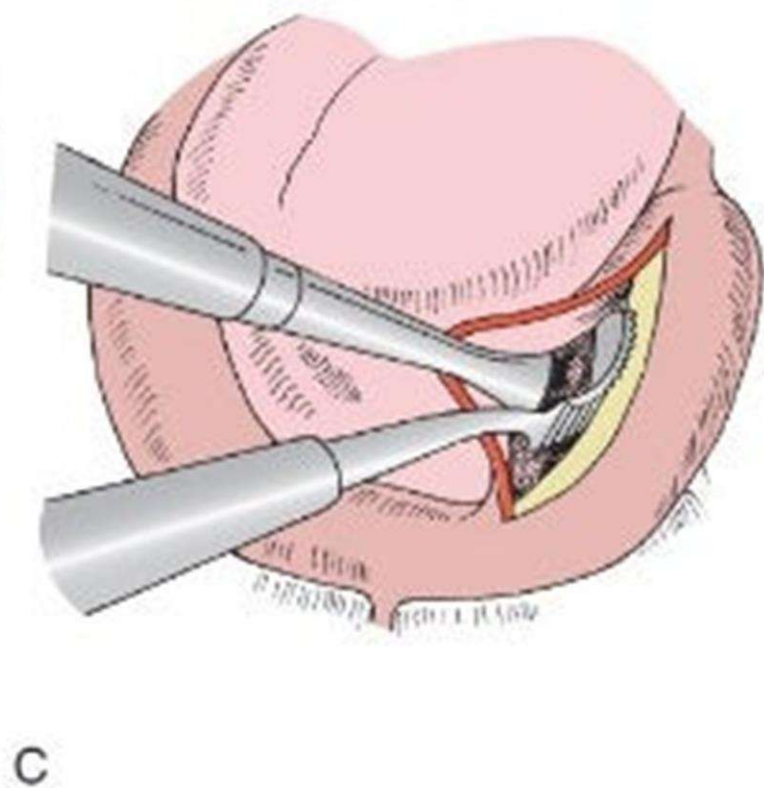
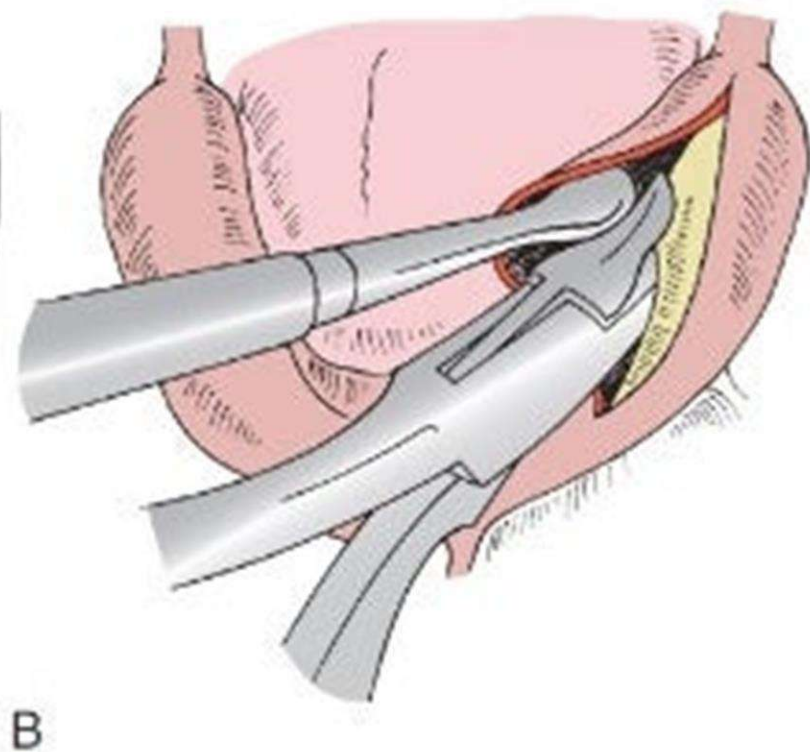
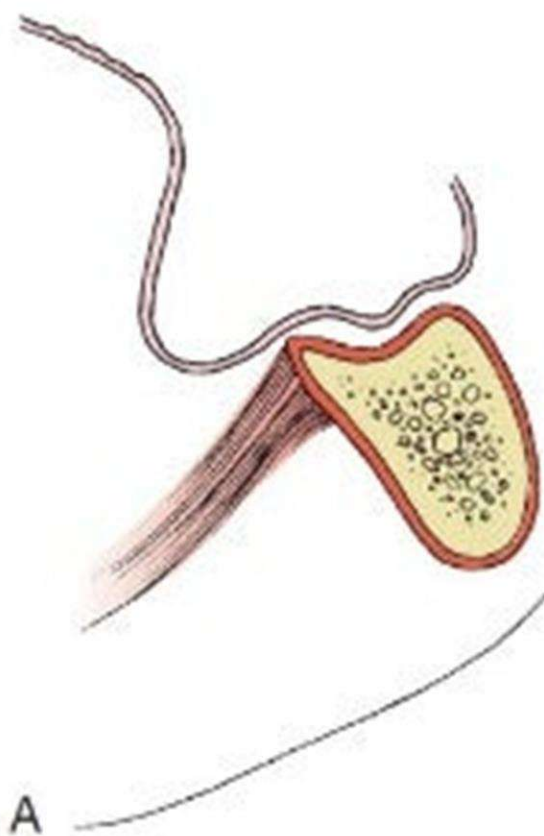
Reasons for Removal

1. Interfering with proper denture construction
2. Easily damaged thin covering mucosa
3. Muscular attachment to this area is responsible for dislodging the denture.
4. Denture pressure may produce significant pain in this area.



○ Procedure

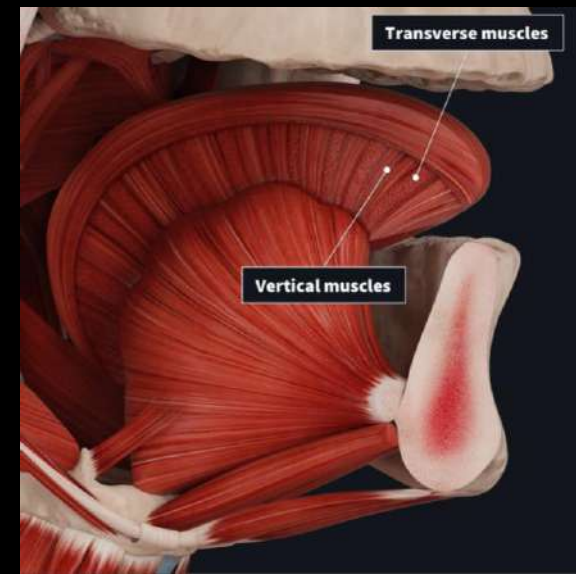
1. Anesthesia: Inferior alveolar, buccal, and lingual nerve blocks
2. A crestal incision in the posterior aspect of the mandible. **Not to the Lingual Aspect** to avoid lingual nerve injury.
3. A mucoperiosteal flap is reflected, exposes the mylohyoid ridge area and muscle attachments.
4. The muscle fibers are removed from the ridge by **sharply incising the attachment** at the area of bony origin.
5. A Rotary instrument or Bone File used to **remove the sharp prominence** of the mylohyoid ridge.
6. **Immediate Replacement** of the denture **because** it facilitate a more Inferior Relocation of the muscular attachment.

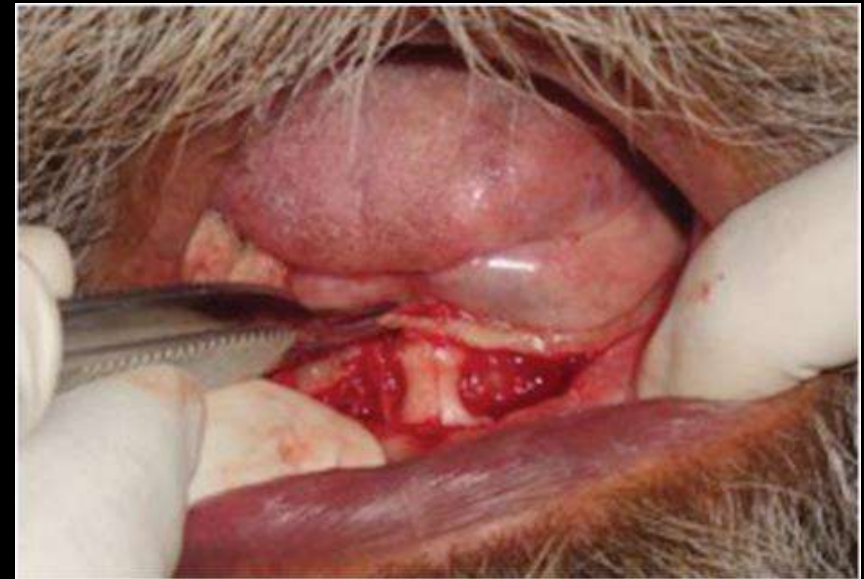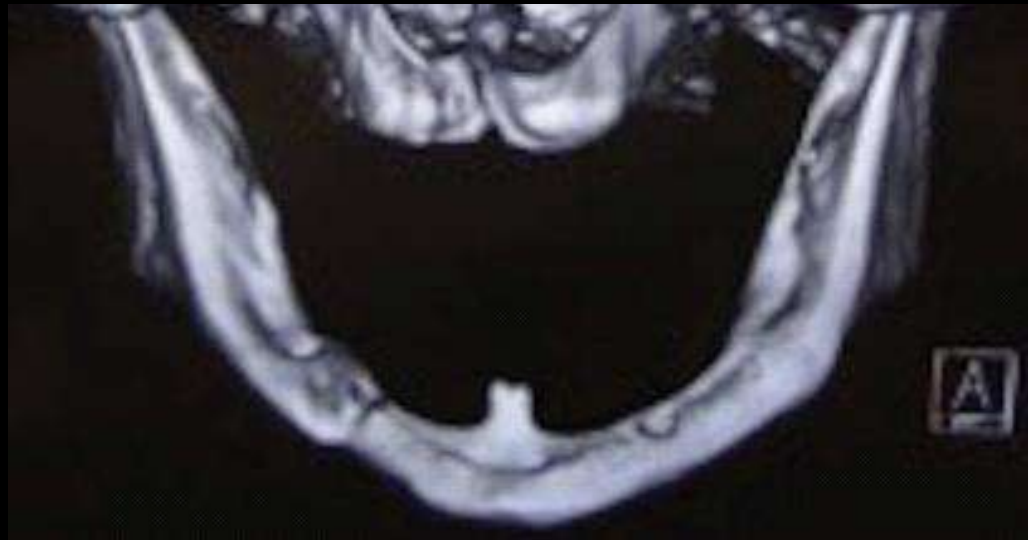
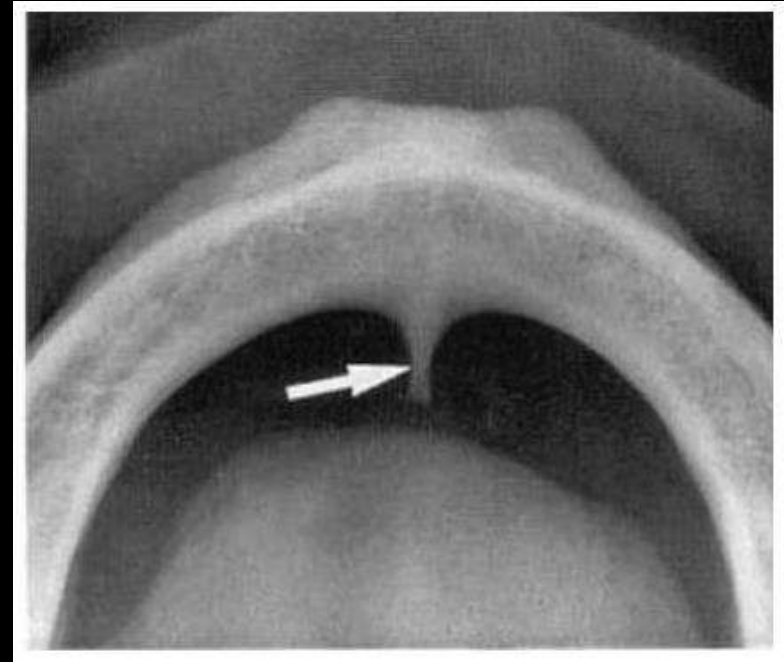
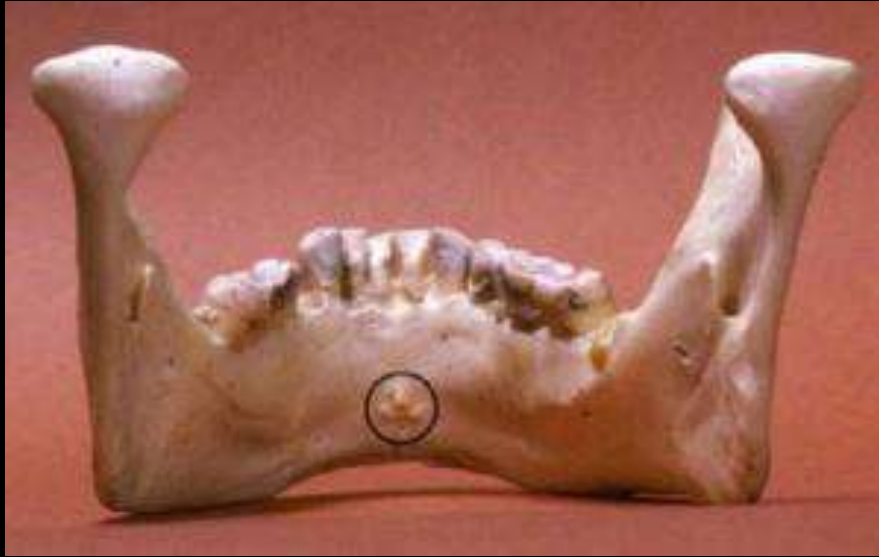


Genial Tubercle Reduction

As the mandible resorped, the attachment of genioglossus muscle in the anterior portion of the mandible may become prominent.

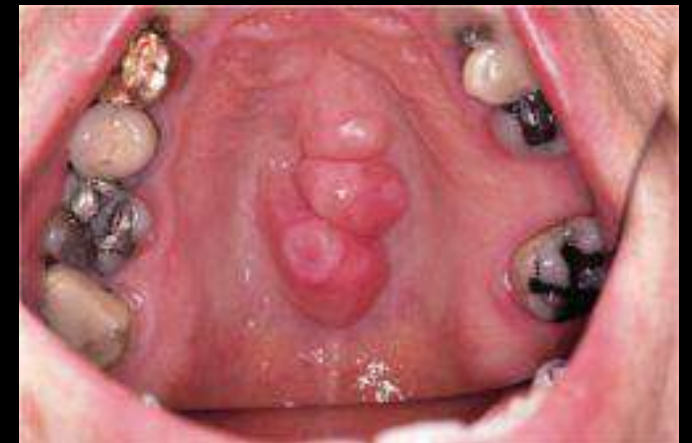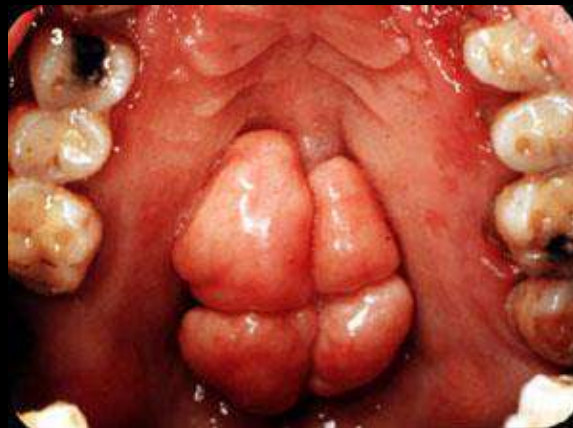
1. Local anesthetic infiltration and bilateral lingual & mental nerve blocks.
2. A crestal incision is made from premolar-to-premolar area
3. A full-thickness mucoperiosteal flap is reflected lingually to expose the genial tubercle.
4. The genioglossus muscle attachment can be removed by a **Sharp Incision**.
5. The genial tubercle removed with a burr or a rongeur followed by a bone file.
6. The genioglossus muscle is **left to reattach in a random fashion**.





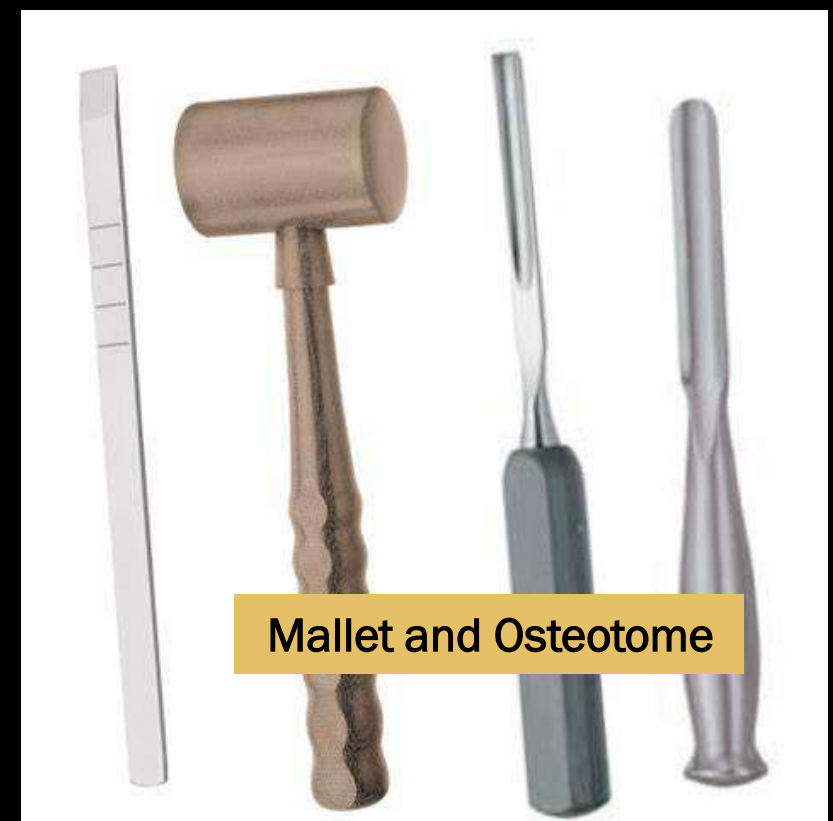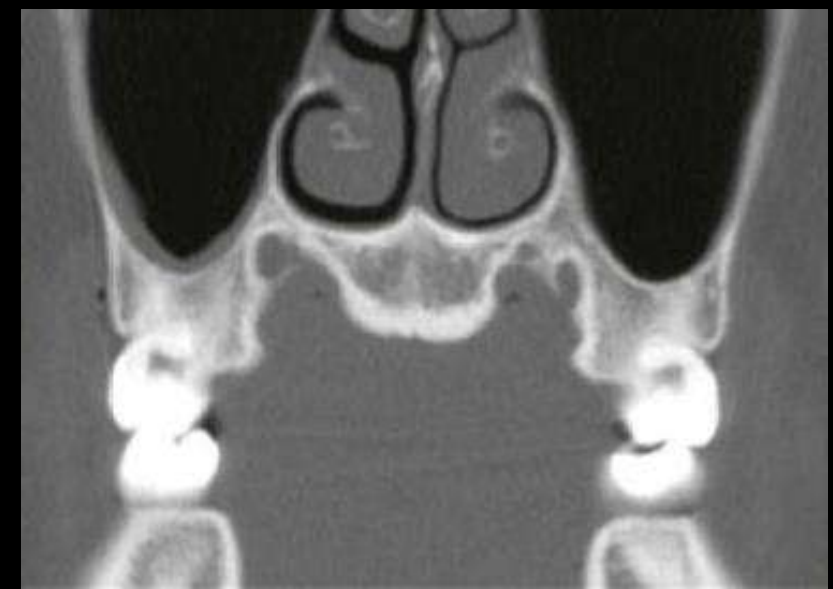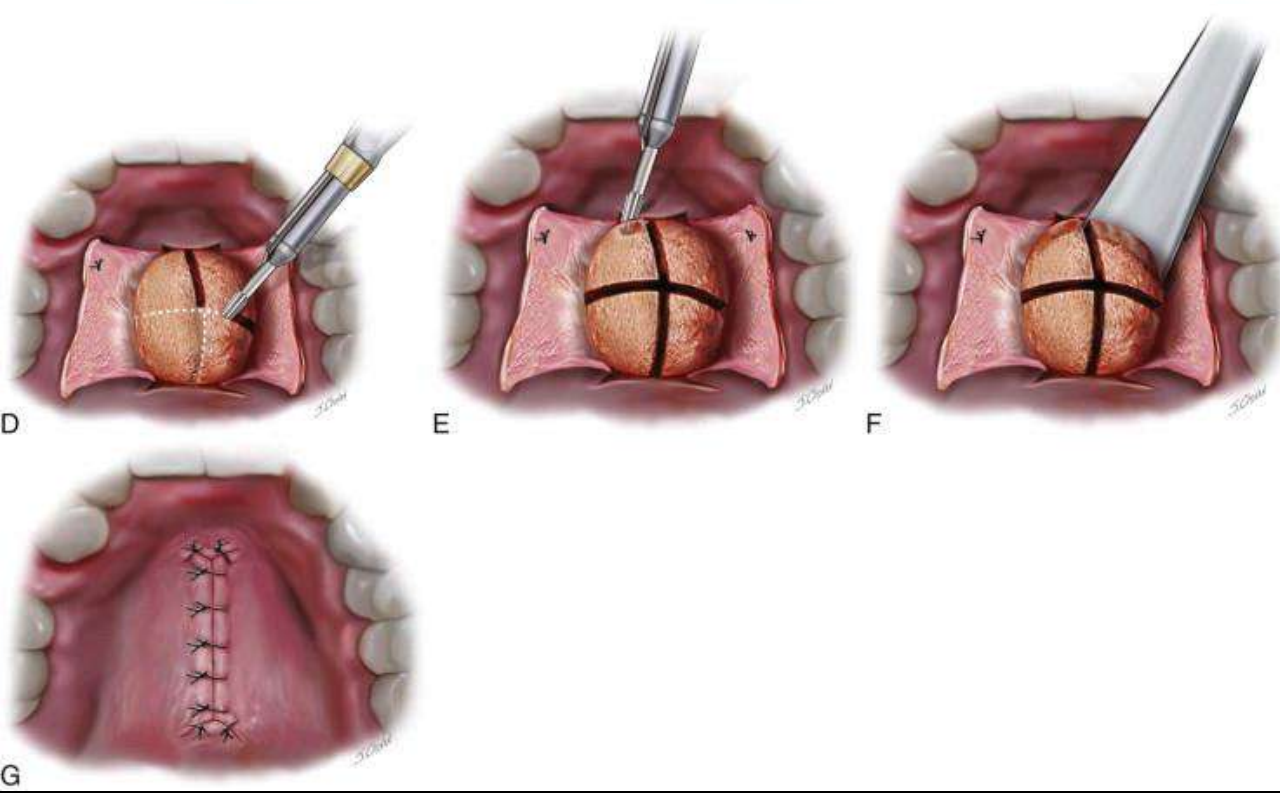
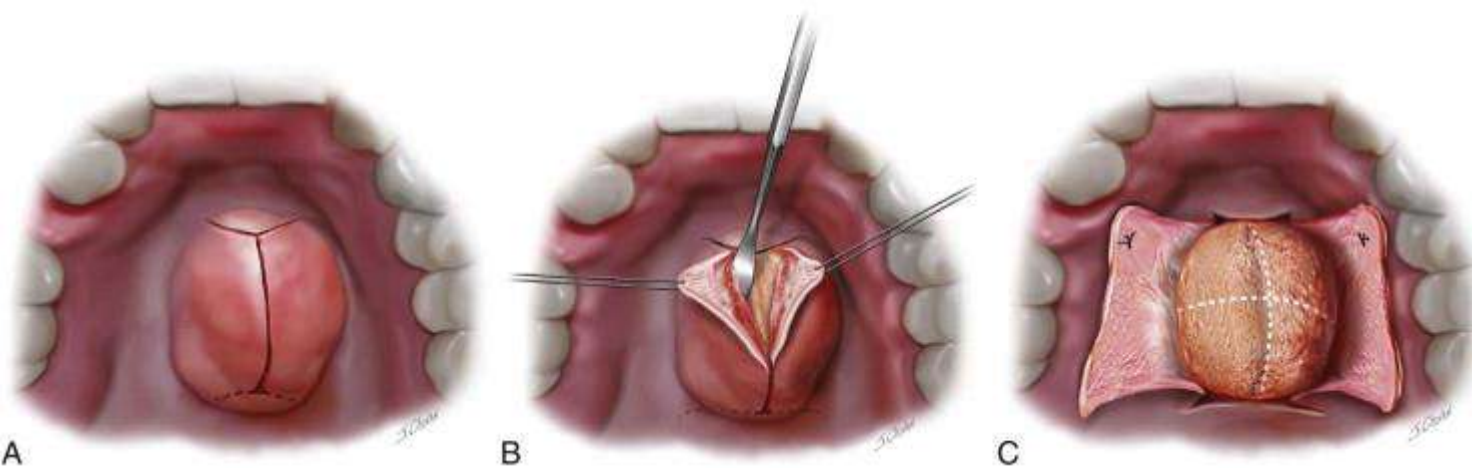
Maxillary Tori (torus Palatinus) - Tori Removal

- ✓ Maxillary tori are approximately **twice** the prevalence rate in males
- ✓ Tori may **interfere with speech or become ulcerated** from frequent trauma to the palate.
- ✓ When the teeth lost, need denture construction, **tori interfere with design and function**.
- ✓ **Large maxillary tori** should be removed before denture construction.
- ✓ Smaller tori often left because they do not interfere with denture construction or function.
- ✓ Small tori may necessitate removal when they are Irregular, Extremely Undercut, or in the area where a posterior Palatal Seal would be expected.



Surgical Steps:

1. Anesthesia: bilateral greater palatine and incisive blocks and local infiltration.
2. **Incision in the midline** of the torus with oblique releasing incisions at one or both ends.
3. For larger tori, it is best to section the tori into multiple fragments with a burr. Careful attention must be paid to the depth of the cuts to avoid perforation of the floor of the nose.
4. After sectioning, the portions of the tori removed with a mallet and osteotome, and mucosa sutured.
5. Pressure dressing: some form of pressure dressing placed over the area of the palatal vault, or a temporary **denture or splint placed** to prevent pressure necrosis, to support thin mucosa and **to prevent hematoma formation.**



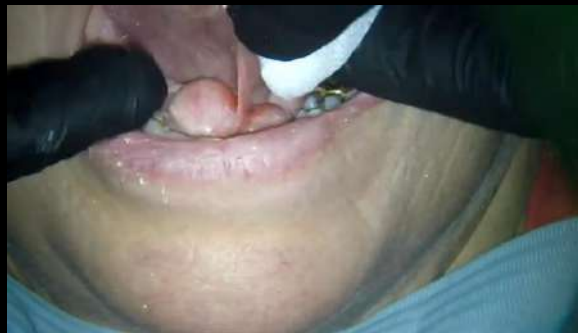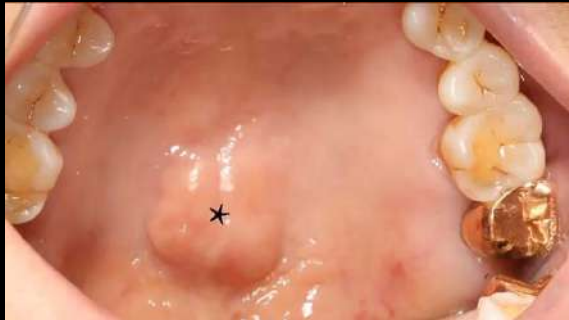- **Mandibular Tori (Torus Mandibularis)**

- Bony protuberances on the lingual aspect of the mandible - Usually in Premolar Area.
- In dentate patient, Large tori interfere with **Speech or Tongue Function** during eating, require removal.
- After removal of teeth **for denture construction**, it is necessary to remove mandibular tori.

Surgical Steps

- 1. Anesthesia: Bilateral lingual and inferior alveolar injections.
- 2. A crestal incision extending 1 to 1.5 cm beyond each end of the tori.
- **Note:** When bilateral tori are to be removed, **it is best to leave a small band of tissue attached at the midline**, to eliminate hematoma and maintains the lingual vestibule as possible in the anterior mandibular area.

3. The use of a Surgical Burr better than the use of a Mallet and Osteotome, due to possible trauma to anatomic structures in the floor of the mouth.
4. Interrupted or continuous Suturing with 3\0 black silk suture.
5. Pressure Gauze packs placed for several hours are helpful in reducing postoperative hematoma formation.



FOTONA ERBIUM LASER TORI REMOVAL
BOYNTON LASER
DENTAL CENTER

HARVEY S. SHIFFMAN DDS

Alveolar Ridge Preservation

- ❖ It's a procedure aimed to minimize alveolar bone resorption after tooth extraction by using a variety of bone materials can aid in the minimizing loss of alveolar bone height and width.

Materials Used in Preservation:

- ❖ Alloplastic, Allogeneic and Xenogeneic bone materials have been used.
- ❖ These inorganic materials are derived from

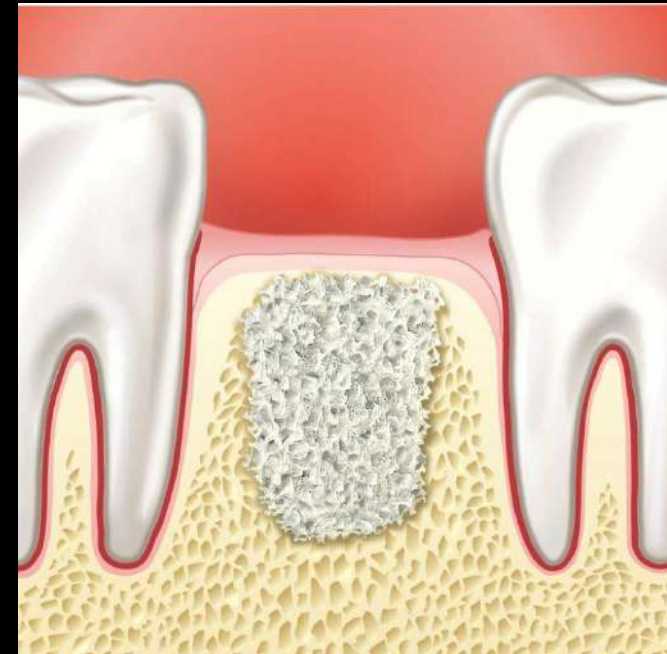1) Bovine Source (Xenograft) or 2) Processed Cadaveric Bone (Allograft) or 3) Synthetic Hydroxyapatite Crystals and Tri-calcium Phosphate (Alloplastic).

- ❖ Note: Atraumatic extraction with maintenance of the buccal and lingual cortical walls is essential to preservation of alveolar bone.

Surgical procedure:

1. The site is curetted and irrigated after extraction.
 2. Graft material is placed in extraction site and **compressed to the level of the alveolar crest.**
 3. The extraction site usually is NOT closed primarily.
- ✓ In most cases, the graft material is covered with resorbable collagen membrane that is held in place with resorbable sutures under the attached gingiva.
 - ✓ Mucosal re-epithelialization occurs over the grafted site within a few weeks.
 - ✓ **Implant placement usually proceeds in 2 to 6 months.**

Bond Apatite®
Bone Graft Cement

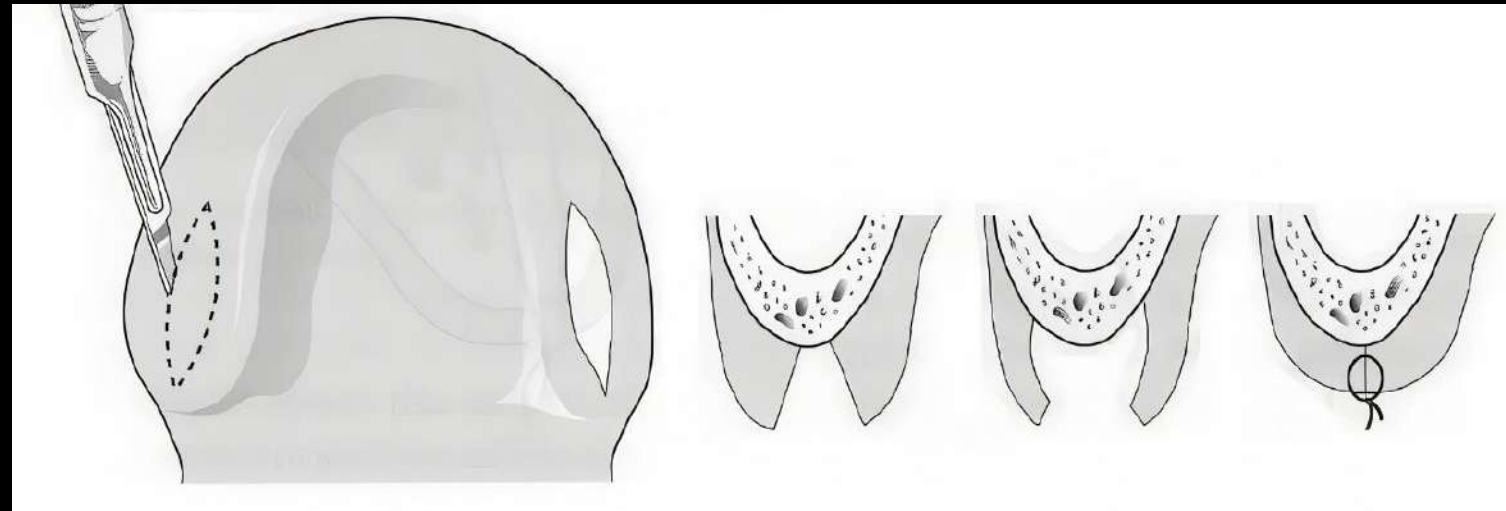


Soft Tissue Abnormalities

With bone resorption, immediately after tooth removal, muscular and frenal attachments may interfere with proper denture construction.

Maxillary Tuberosity Reduction (Soft Tissue)

1. **Elliptical Incision** is made over the tuberosity, and this section of tissue is removed
2. Margins of the excision must be thinned to remove excess soft tissue, which allows further soft tissue reduction and provides a tension-free soft tissue closure, suturing.

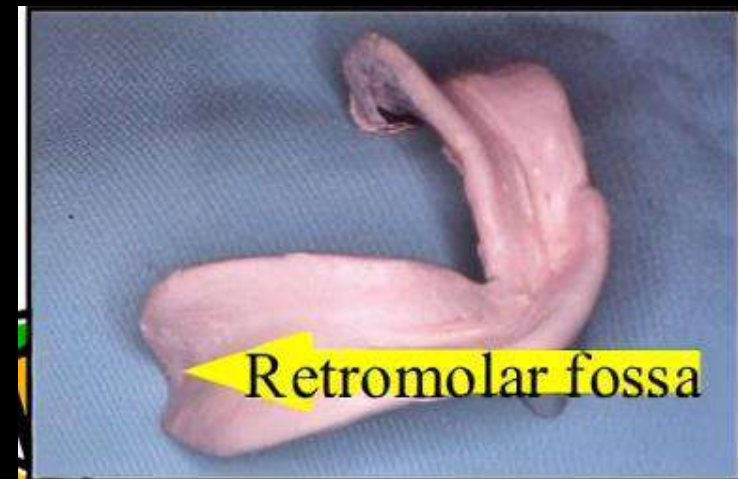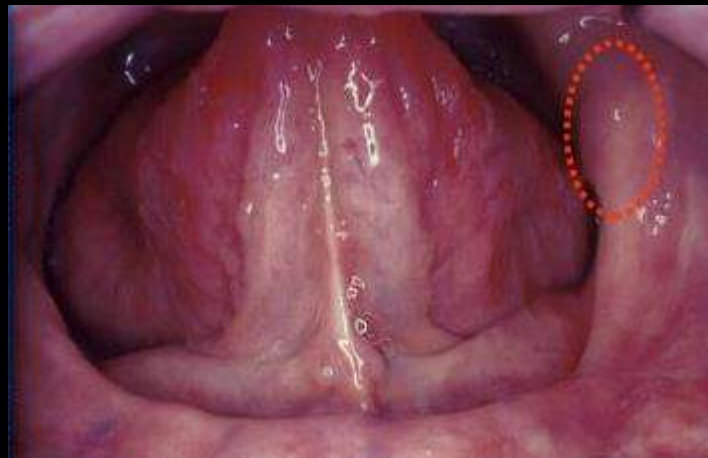


Mandibular Retromolar Pad Reduction

- Real indication for hypertrophic tissue is rare
- During clinical evaluation, Patient is not posturing the mandible forward or over-closed, **false indications**

Surgical procedure:

1. An elliptical incision is made to excise the greatest area of tissue thickness.
2. Majority of tissue reduction on the labial aspect. Excess removal of tissue in the submucosal area of the lingual flap result in damage to the lingual nerve, Suturing.



Unsupported Hypermobile Tissue

Excessive hypermobile tissue without inflammation on the alveolar ridge is the result of

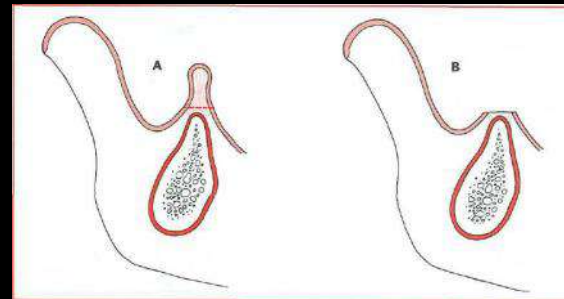
Resorption of the underlying bone
ill-fitting dentures.

Management:

- If a bony deficiency is the primary cause of soft tissue excess, then augmentation of the underlying bone is the treatment of choice.
- If adequate alveolar height remains after reduction of the hypermobile soft tissue, then excision may be indicated.

Surgical Procedure:

- Two parallel full-thickness incisions on the buccal and lingual aspects of the tissue, Suturing.
- A tangential excision of small amounts of tissue in the adjacent areas may be necessary to allow for adequate soft tissue adaptation during closure.
- Denture construction 3 to 4 weeks after surgery.

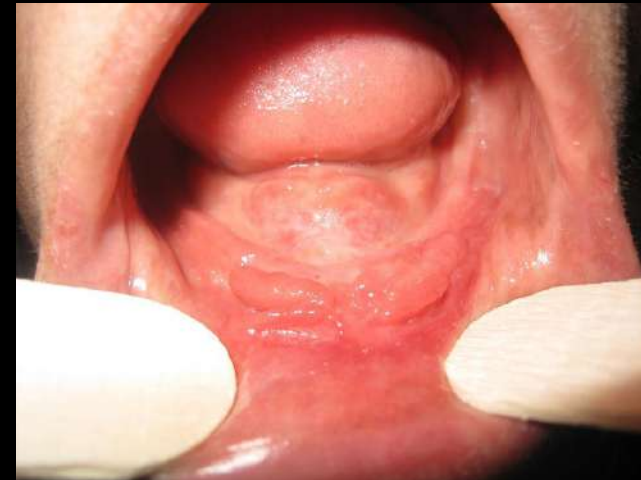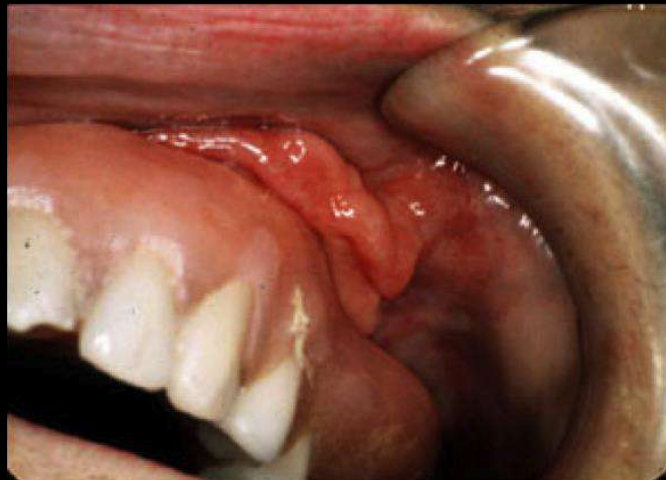


Inflammatory Fibrous Hyperplasia (Epulis Fissurata or Denture Fibrosis)

- It is a Generalized **Hyperplastic** Enlargement of mucosa and fibrous tissue in the alveolar ridge and vestibular area, which most often results from ill-fitting dentures.

Management:

- Early Stages: when fibrosis is minimal, **Nonsurgical Treatment** with a denture in combination with a soft liner.
- Delayed Stage: significant fibrosis within the hyperplastic tissue. **Excision**.

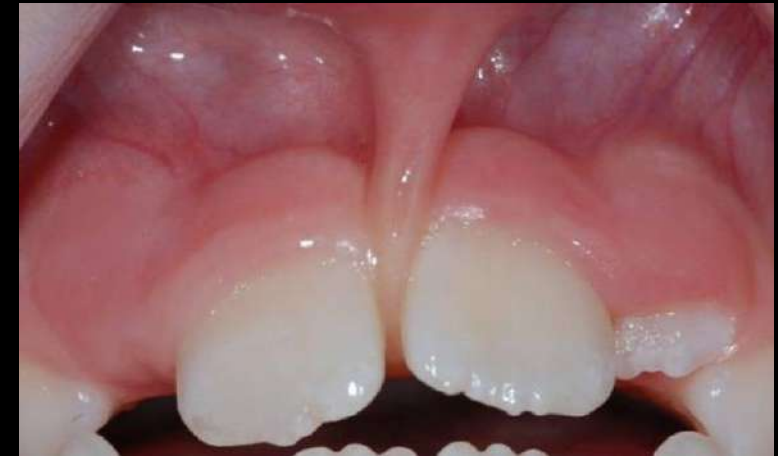

Surgical procedure:

1. Local anesthetic infiltration.
2. An incision is made at the base of the excessive fibrous tissue down to the periosteum,
3. the hyperplastic tissue is removed. The adjacent tissue is gently undermined and reapproximated with interrupted or continuous suturing.

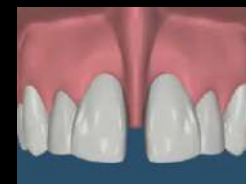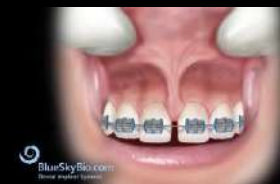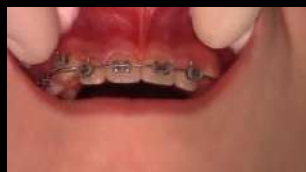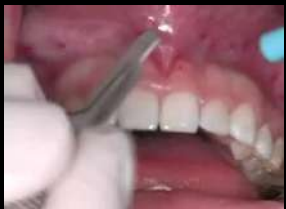Labial Frenectomy

- ✓ Labial frenal attachments consist of **thin bands of fibrous tissue covered with mucosa**, extending from the lip and cheek to the alveolar periosteum.
- ✓ In dentate patient, Frenal attachments **do not cause a problem, except** of the midline labial frenum with a diastema.
- ✓ Movement of the soft tissue adjacent to the frenum may create discomfort and ulceration and **may interfere with the peripheral seal and dislodge the denture**.




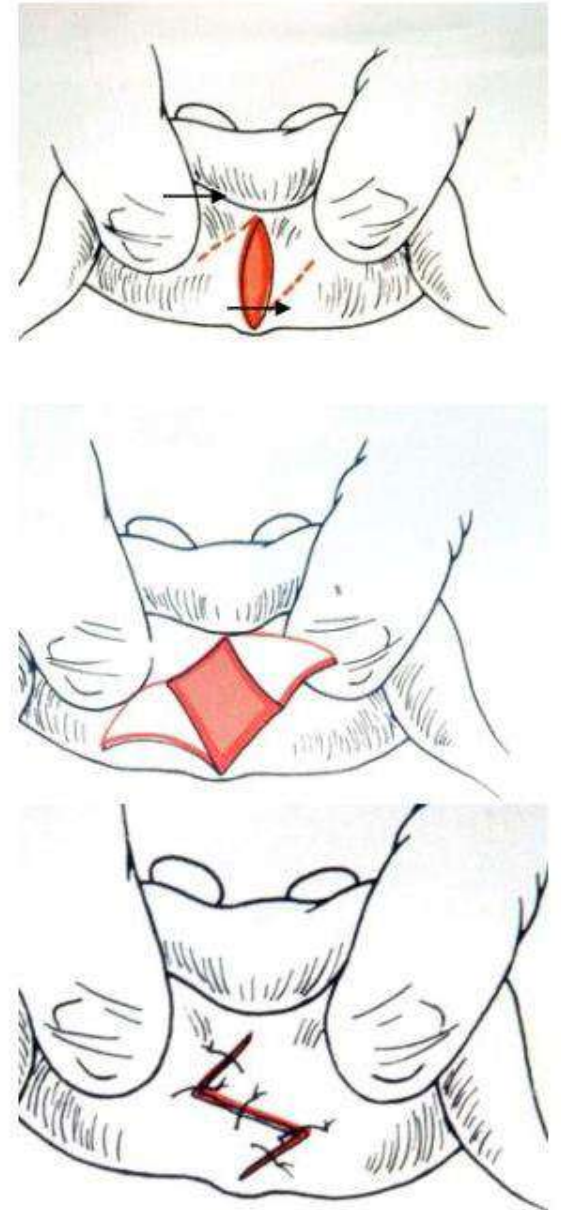
Surgical Procedure:

- A) - Simple Excision Technique, an **Elliptical Incision** around the frenal area down to the Periosteum.
- The frenum sharply dissected from the underlying periosteum, and the margins of the wound sutured.
- Placement of the first suture at the maximal depth of the vestibule and with both edges of mucosa and underlying periosteum beneath the anterior nasal spine. This technique **reduces hematoma formation** and allows for **adaptation of the tissue** to the maximal height of the vestibule.
- The remainder of the incision should then be closed with interrupted sutures.



For the private use by
licensee's patients.
This movie may not be
posted publicly.

- B) - In the Z-Plasty Technique,
- An excision same as simple excision procedure.
- After excision, two oblique incisions are made in a Z fashion. The two-pointed flaps are then gently undermined and rotated to close the initial vertical incision horizontally.
- This technique may decrease the amount of vestibular ablation.

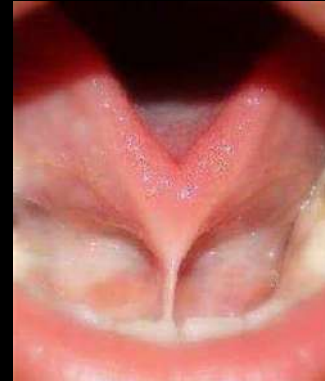
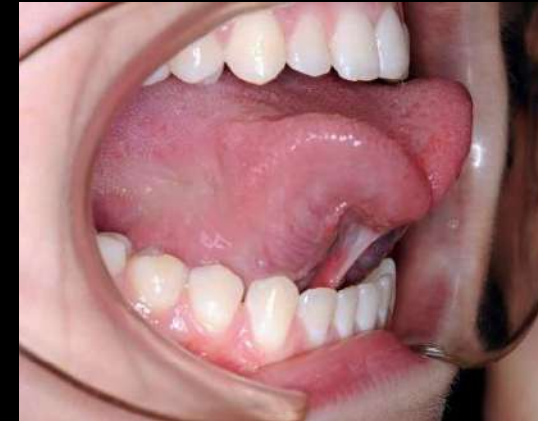
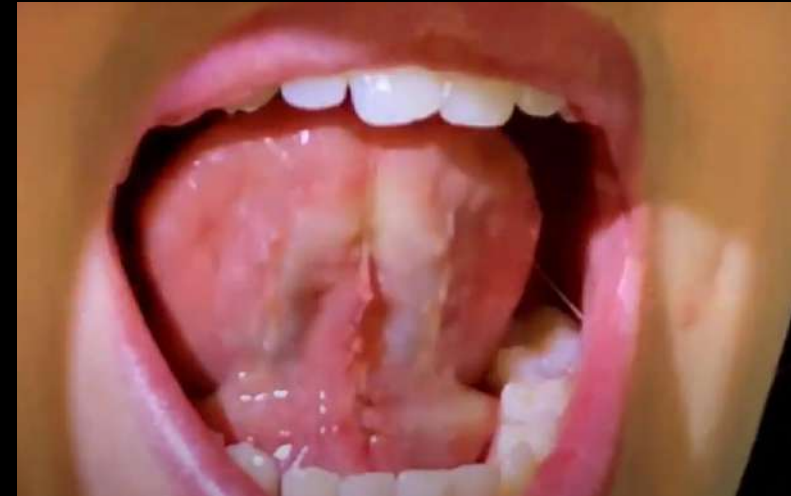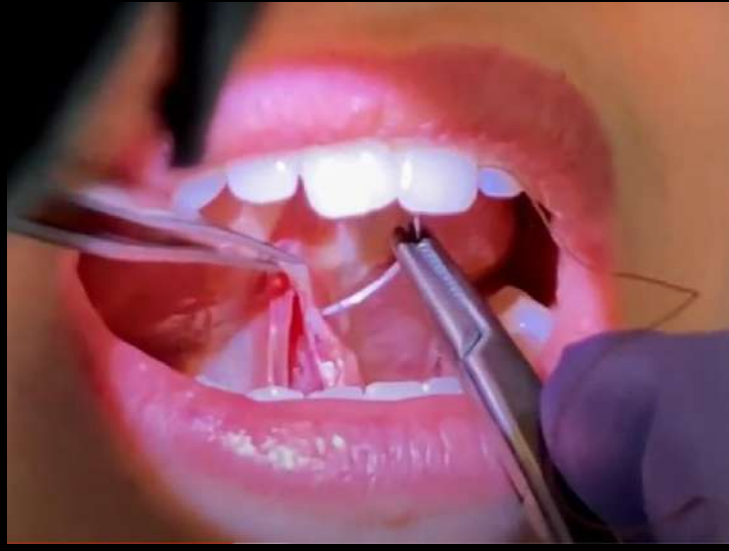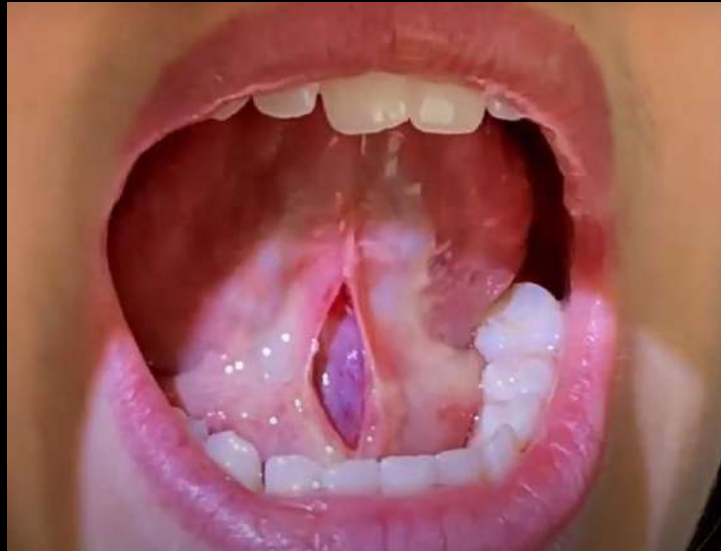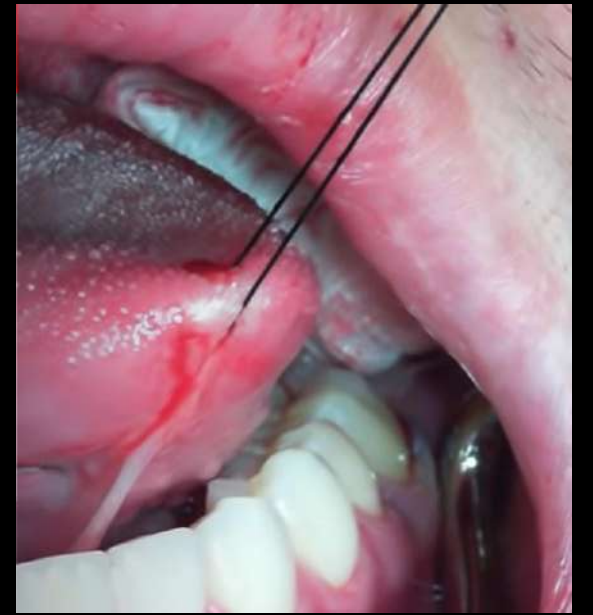
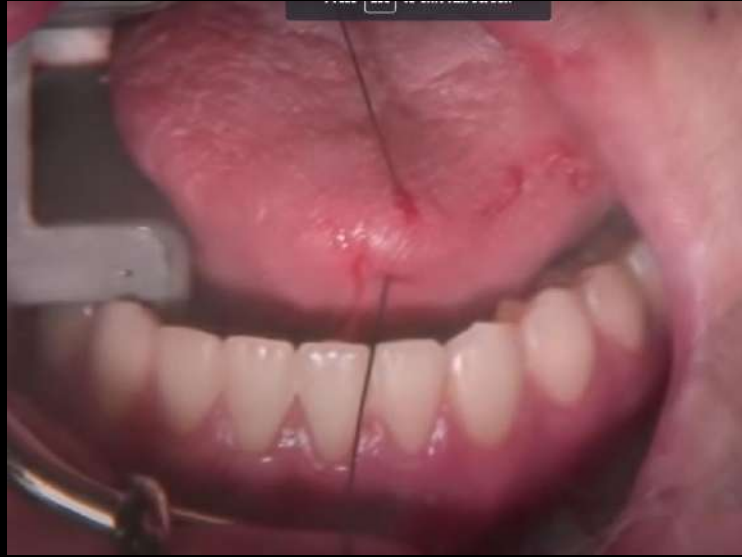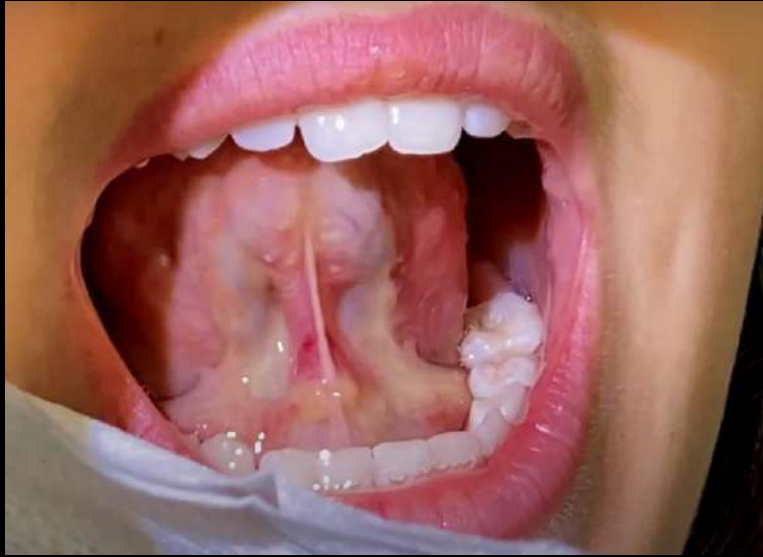Lingual Frenectomy (Tongue Tie - Ankyloglossia)

- ✓ An abnormal lingual frenal attachment consists of mucosa, dense fibrous connective tissue, and superior fibers of the genioglossus muscle.
- ✓ It **binds the tip of the tongue** to the posterior surface of the mandibular alveolar ridge.
- ✓ May affect speech and interferes with denture stability.

Surgical Technique:

1. Bilateral lingual blocks and local infiltration.
2. The tip of the tongue is best controlled with a traction suture.
3. Placement of a hemostat across the frenal attachment (3 min) provides vasoconstriction.
4. Remove the hemostat, an incision through the area previously closed with the hemostat.
2. an incision with No. 15 surgical blade or with electrocautery.



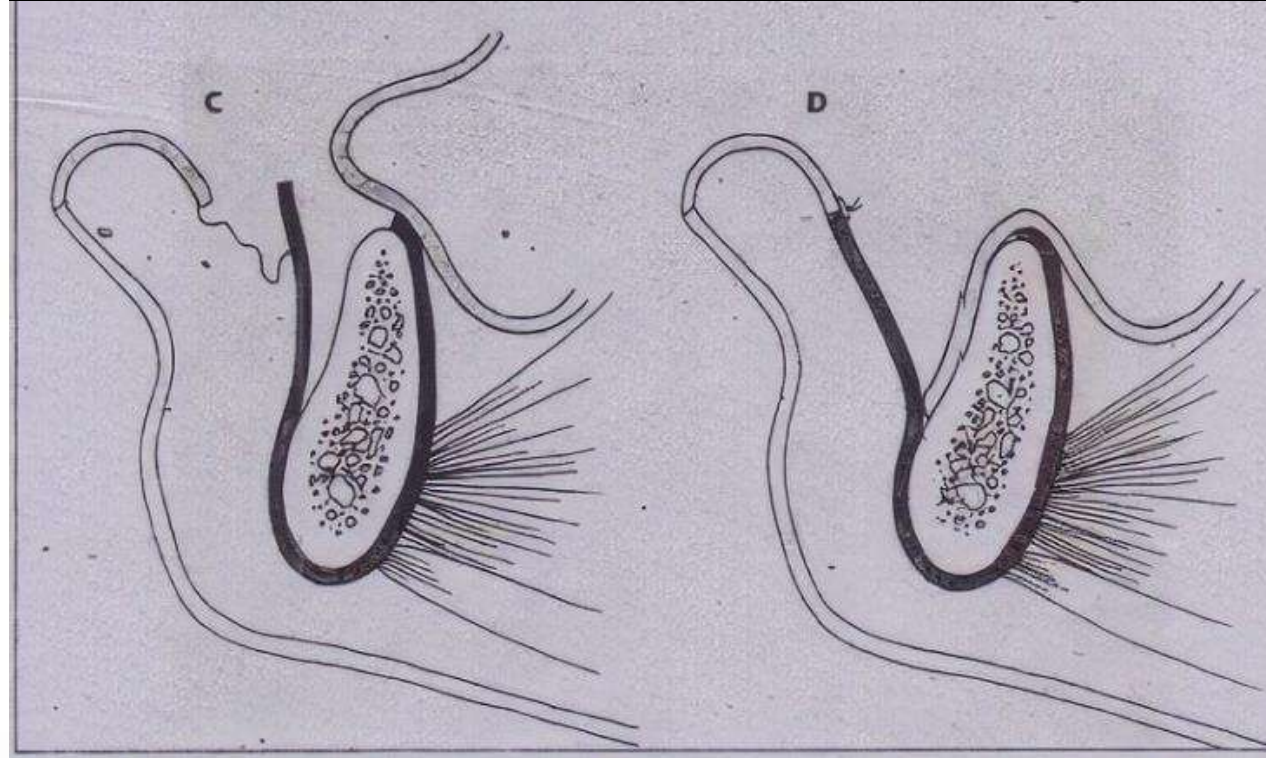
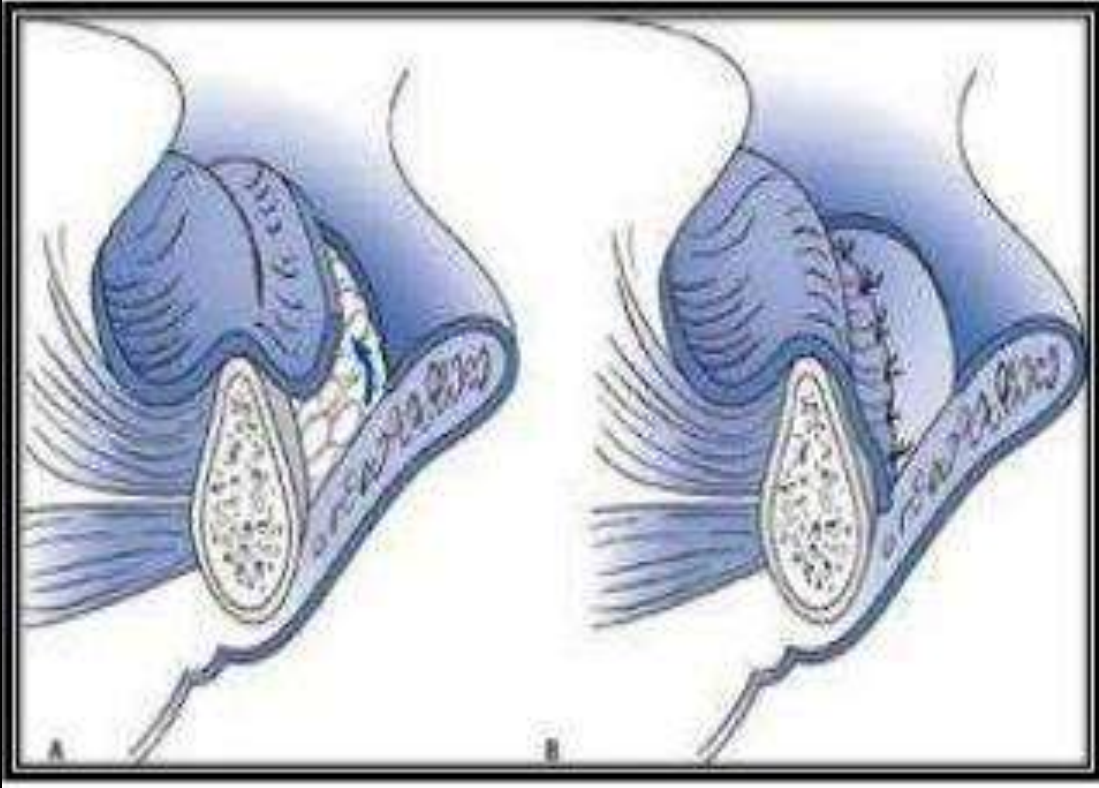


Soft Tissue Surgery for Extension of the Mandible

- The Primary Goals of soft tissue preprosthetic surgery are to provide an enlarged area of fixed tissue in the primary denture-bearing or implant area and to improve extension in the area of the denture flanges by removing the dislodging effects of muscle attachments in the denture-bearing or vestibular areas.

Transpositional Flap Vestibuloplasty (Lip Switch)

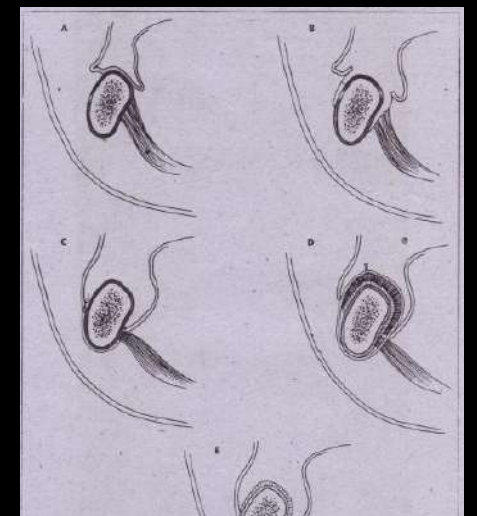
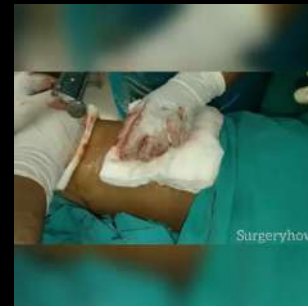- A lingually based flap vestibuloplasty was first described by Kazanjian.
- In this procedure, a mucosal flap (pedicle from the alveolar ridge) is elevated from the underlying tissue of the lip and sutured to the depth of the vestibule.
- The inner portion of the lip is allowed to heal by secondary epithelialization.
- This procedure has been modified, and the use of a technique transposing a lingually based mucosal flap and a labially based periosteal flap (transpositional flap) has become popular.



Vestibule and Floor-of-Mouth Extension Procedures

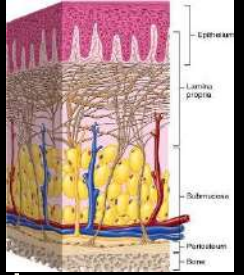
- On the lingual aspect of the mandible, detaching the mylohyoid muscles from the mylohyoid ridge area and repositioning them inferiorly, (Trauner procedure).
- This procedure effectively deepening the floor of the mouth area and relieving the influence of the mylohyoid muscle on the denture
- **Macintosh and Obwegeser** later described the effective use of a labial extension procedure combined with the Trauner procedure to provide maximal vestibular extension to the buccal and lingual aspects of the mandible.
- The technique for extension of the labial vestibule is a modification of a labially pedicled suprapariosteal flap described by Clark.
- After the two vestibular extension techniques have been performed, a **skin graft** can be used to cover the area of denuded periosteum.

- The combination procedure effectively **eliminates the dislodging forces** of the mucosa and muscle attachments and provides a broad base of fixed keratinized tissue on the primary denture bearing area.
- **Soft tissue grafting procedure is indicated when mandibular bone height remains at least 15 mm.**
- Palatal tissue grafting offers the potential advantages of providing a firm, resilient tissue, with minimal contraction.



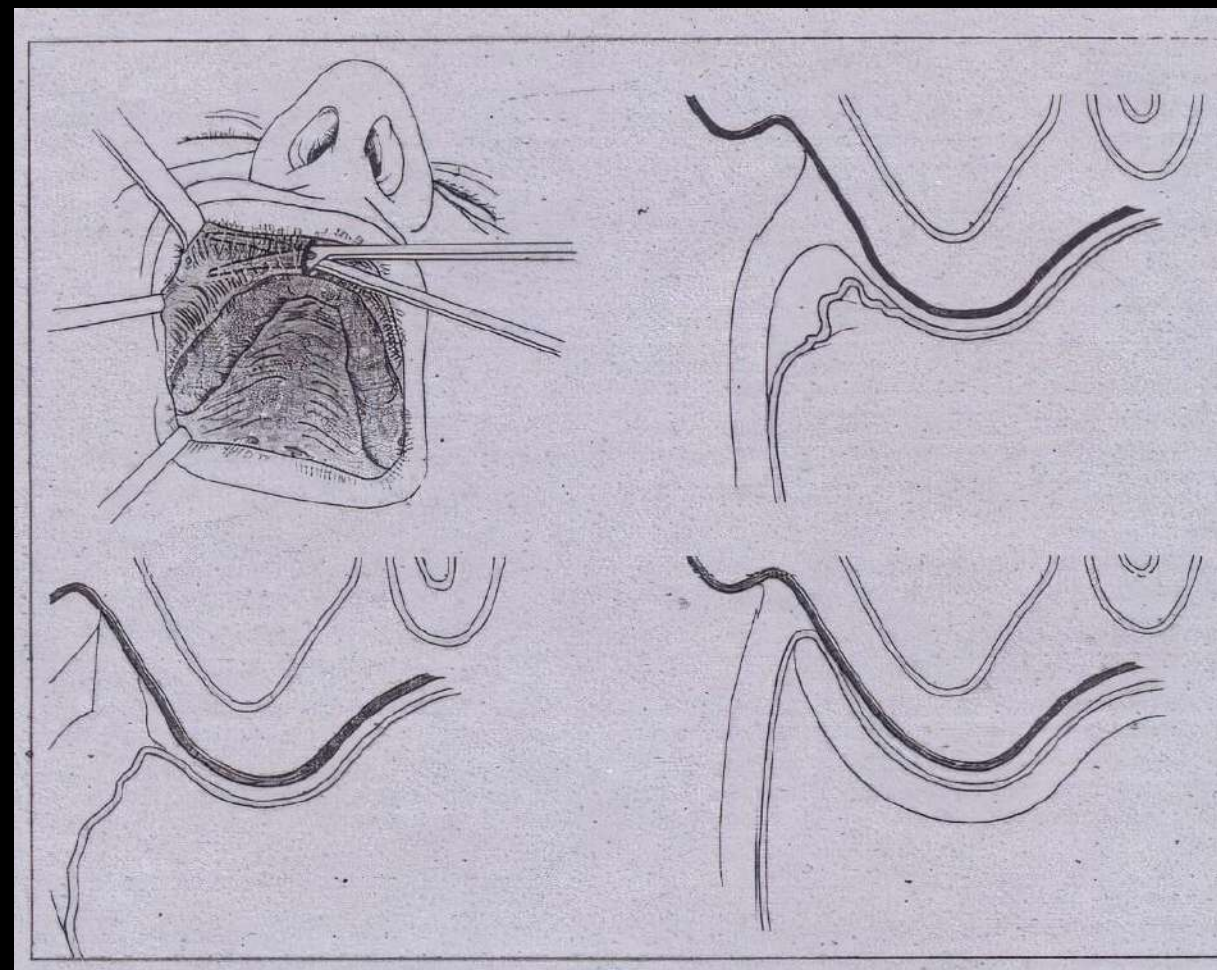
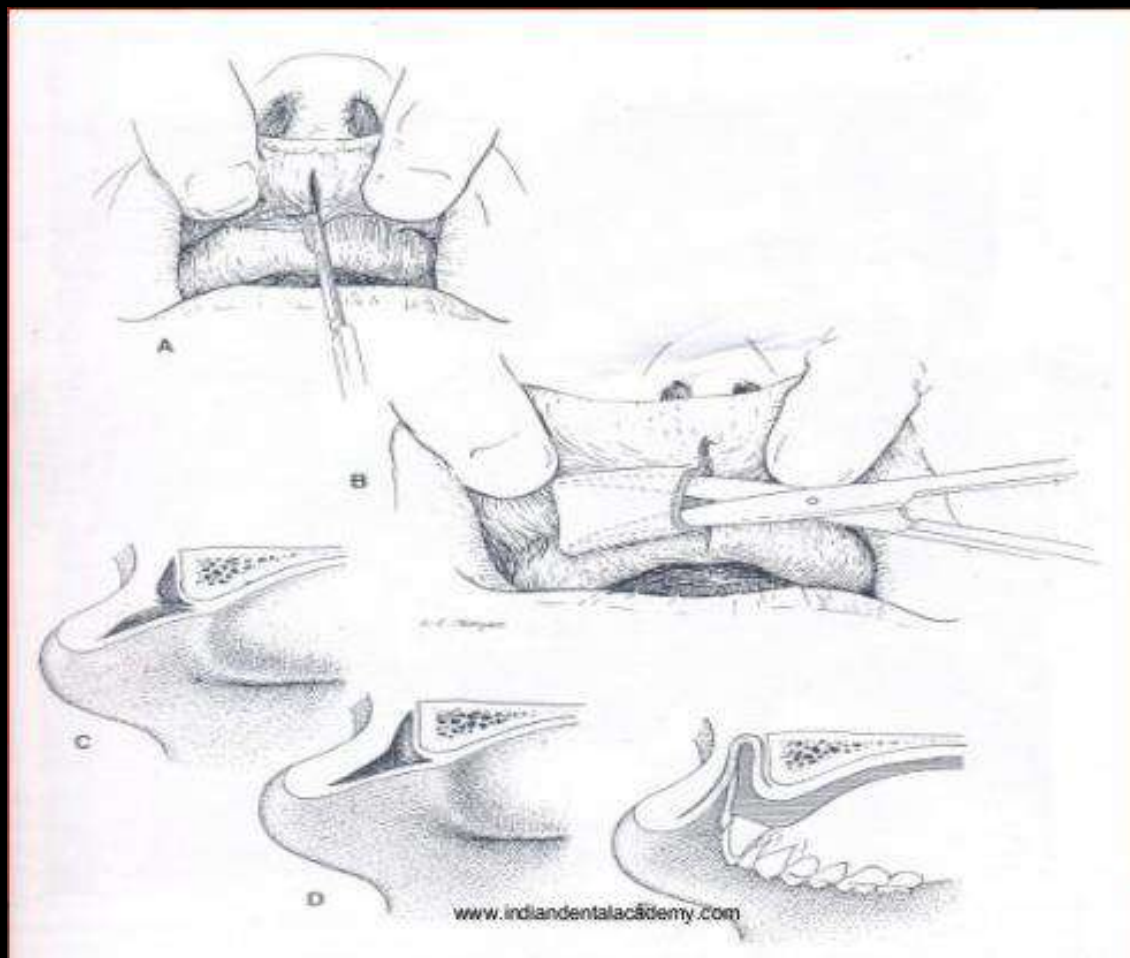
Soft Tissue Surgery for Maxillary Ridge Extension

Submucosal Vestibuloplasty



- It can be performed with local anesthetic and intravenous sedation in an outpatient setting
- A midline incision is made in the anterior maxilla, and the mucosa is undermined and separated from the underlying submucosal tissue.
- A supraperiosteal tunnel is then developed by dissecting the muscular and submucosal attachments from the periosteum.
- This submucosal and muscular tissue can be repositioned superiorly.
- After closure of the midline incision, a preexisting denture modified to extend into the vestibular areas and is secured with palatal screws for 7 to 10 days to hold the mucosa over the ridge in close apposition to the periosteum.

- When healing takes place, usually within 3 weeks, the mucosa is closely adapted to the anterior and lateral walls of the maxilla at the required depth of the vestibule.
- These techniques provide a predictable increase in vestibular depth and attachment of mucosa over the denture-bearing area.
- A properly relined denture can often be worn immediately after the surgery, and impressions for final denture construction can be completed 2 to 3 weeks after surgery.



During the removal of mylohyoid ridge which of the following nerves should be protected

- A. Mental nerve.
- B. Lingual nerve.
- C. Mylohyoid nerve.
- D. Inferior dental nerve.
- E. None of above.

Which of the following is true about the excision of torus palatinus

- A. It should be excised with the help of burs and rongeurs.
- B. It should not be excised with chisel and mallet.
- C. It should be excised with chisel and mallet.
- D. Both A and B.
- E. None of above.

When performing a maxillary labial frenectomy where the base of the frenum is extremely wide, the effective surgical technique is:

- A. Z-Plasty
- B. Simple excision (diamond excision).
- C. Localized vestibuloplasty.
- D. Kazanjian technique (lip switch).
- E. All of the above are equally effective.

Vestibuloplasty is:

- A. Deepening of the vestibule.
- B. Most commonly done in maxilla.
- C. Most commonly done in mandible.
- D. Both A & C.
- E. None of the above.

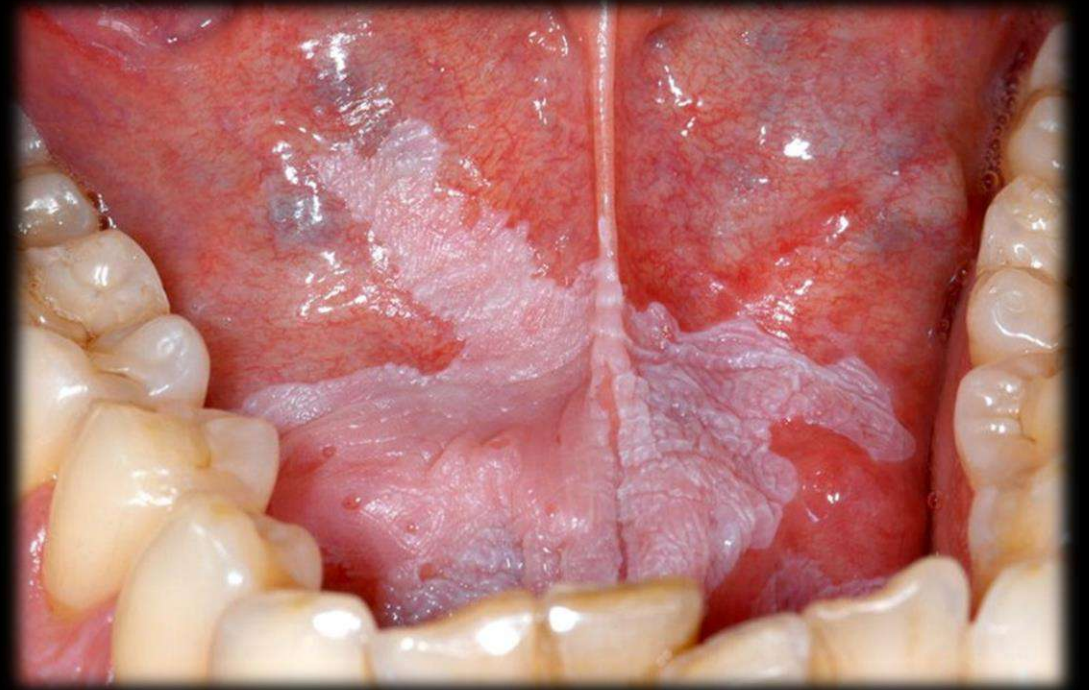
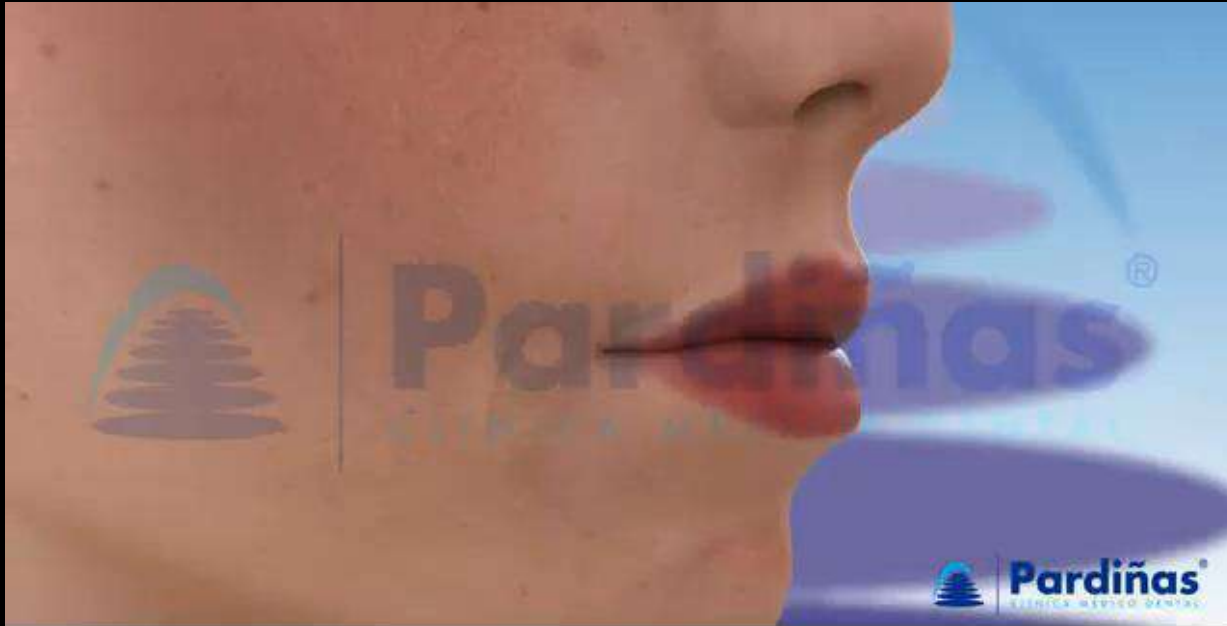Indications for Reduction/Removal/Excision of Tori include the following, EXCEPT

- A. A large torus that may extend beyond the post-dam area.
- B. Ulceration/traumatization/hyperkeratinization of the overlying mucosa.
- C. Deep bony undercuts.
- D. Malignant transformation.
- E. All of the above.

The principal problem with tuberosity reduction is;

- A. Poor access.
- B. Formation of oroantral fistula.
- C. Infection.
- D. Damage to posterior superior alveolar artery.
- E. Damage to the greater palatine artery

Potentially Malignant Disorders of the Oral Mucosa



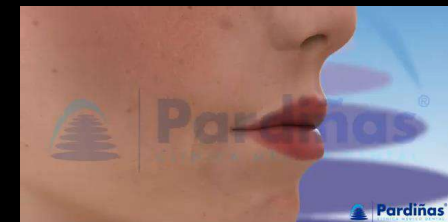Bashar Abdul-Ghani - FICMS. MAXFACS Cons. MFDS. RCSED. RCPS (Glasg).

Lecture Quoted From Baghdad University Curriculum

- ▶ **Oral carcinogenesis** involves a complex, multistage process of cumulative sequence of cellular (atypia) and tissue (dysplasia) changes resulting from multiple genetic alterations during a protracted period.
- ▶ Some of these **changes may be reversible**, but when the overall effect of these changes surpasses the inherent reparative ability of the cells, **they will be transformed ultimately into invasive malignant cells.**
- ▶ In the course of this process, many physical and morphological alterations of the oral tissues that are of diagnostic and prognostic relevance occur; these changes are termed **premalignant or precancerous changes.**

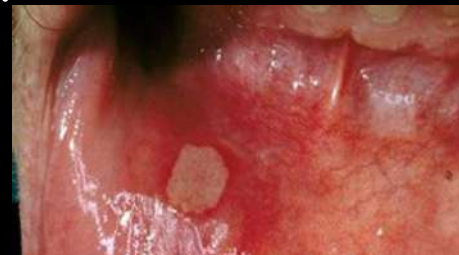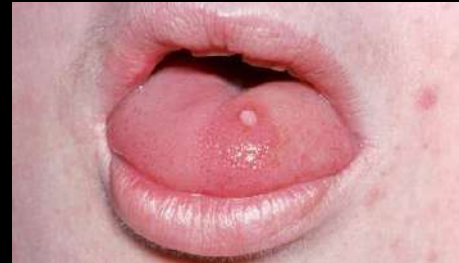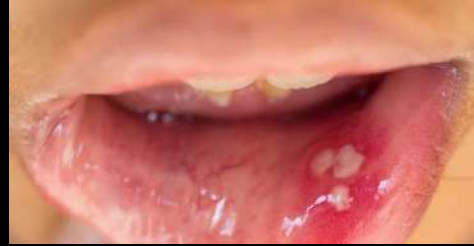Classification of Potentially Malignant Disorders

- ▶ In 1978 the WHO classified into two broad groups; **Lesions and Conditions**.
- ▶ **Premalignant lesions** - Morphologically altered tissue in which cancer is more likely to occur. eg: leukoplakia; erythroplakia; Palatal changes associated with reverse smoking
- ▶ **Premalignant conditions** - Generalized condition associated with risk for cancer. eg: oral submucous fibrosis; lichen planus; discoid lupus erythematosus; actinic keratosis.
- ▶ The term “**Potentially Malignant**” is more **accurate term** for these lesions than the term “**Premalignant**”.



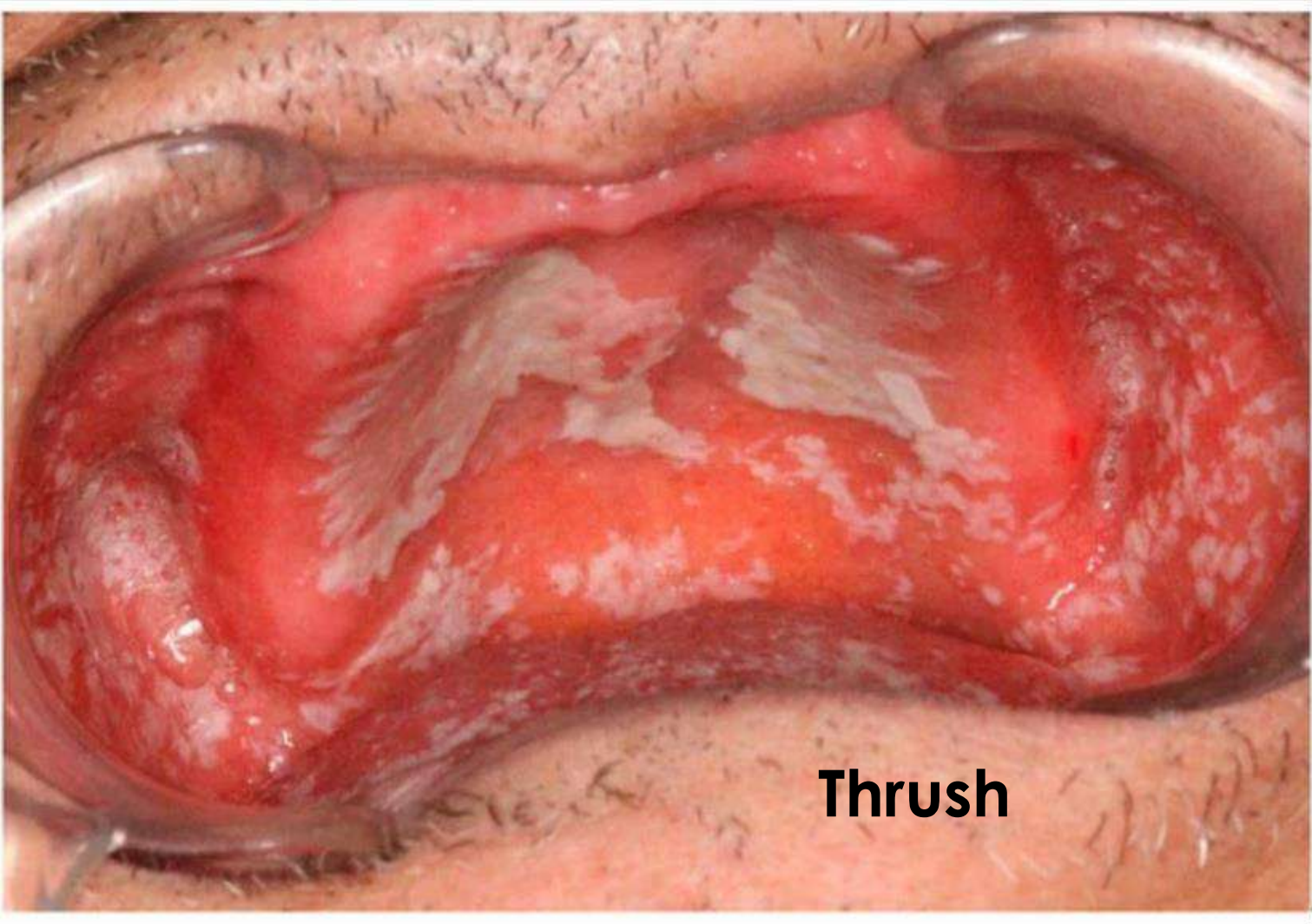
Risk factors

- ▶ Inherent susceptibility; **genetic predisposition**, age (usually older than 45 years), ethnicity, and socioeconomic status.
- ▶ **Tobacco use**; smoking and smokeless.
- ▶ Betel quid (pan) use; betel nut, tobacco and spices wrapped in betel leaf.
- ▶ Alcohol use.
- ▶ Diet and nutrition; **nutritional deficiency**, high intake of processed meat products
- ▶ Poor oral health and dental hygiene
- ▶ Infective agents; **human papillomavirus HPV**, candida, syphilis.
- ▶ Immunodeficiency; congenital, immunosuppression, HIV infection and AIDS.
- ▶ Ultraviolet irradiation.



Diagnostic Method

- ▶ Patient history : Identification of risk factors and recognition of medical conditions predisposing to premalignant lesions or conditions.
- ▶ Clinical examination – inspection and palpation
- ▶ Careful and thorough **inspection** of the mucosal surfaces by a trained clinician in a good light remains the standard method for identifying suspicious oral lesions.
- ▶ Any detected lesion, palpated by a gloved finger to determine its texture.
- ▶ **Leukoplakic lesions wiped away by careful use of a soaked gauze or a wood spatula, in such case the diagnosis will be an acute pseudomembranous candidiasis (thrush).**
- ▶ All findings must be recorded, **clinical photographs** of the lesions may be helpful during follow up visits.



Thrush



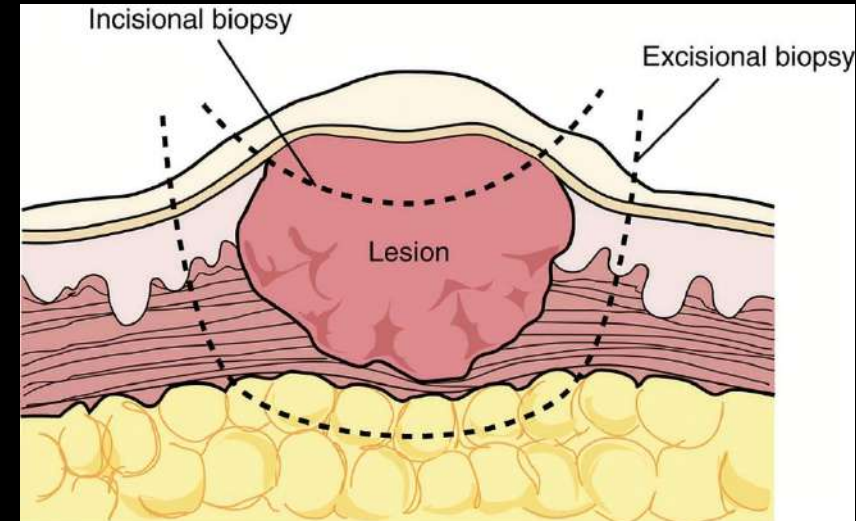
Wooden Spatula

Investigations

- ▶ These may include **blood** investigations, oral **swab** for microbiological assessment, and **incisional or excisional biopsy** for histopathological examination and diagnosis.
- ▶ In case of incisional biopsy, it is important to select a specific site for biopsy that includes clinically severe-looking region, **together with the lesion margin and adjacent normal-looking tissue.**

Diagnostic Aids for Clinical Detection of Oral Premalignant Lesions

- ▶ Vital tissue staining.
- ▶ Light-based detection.
- ▶ Brush biopsy and exfoliative cytology.
- ▶ Salivary analysis.



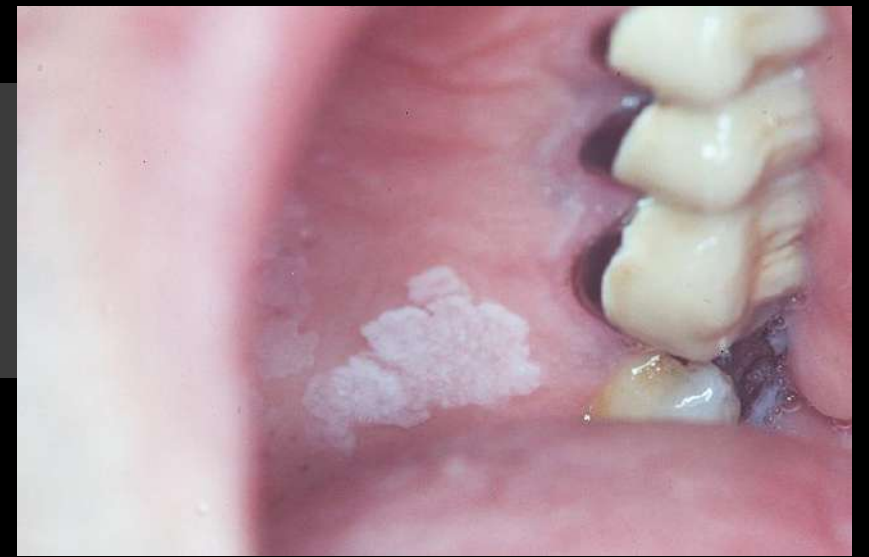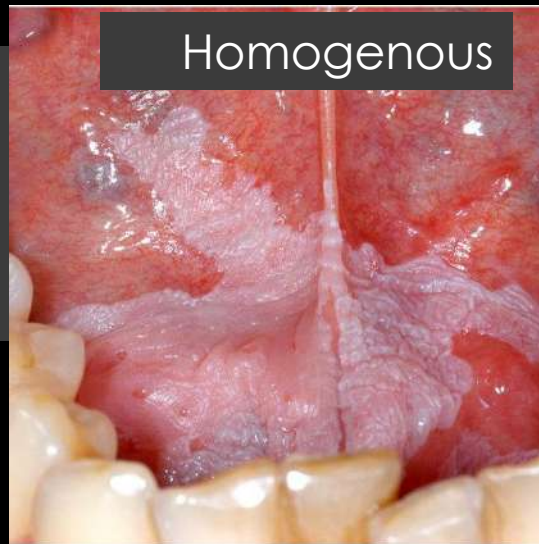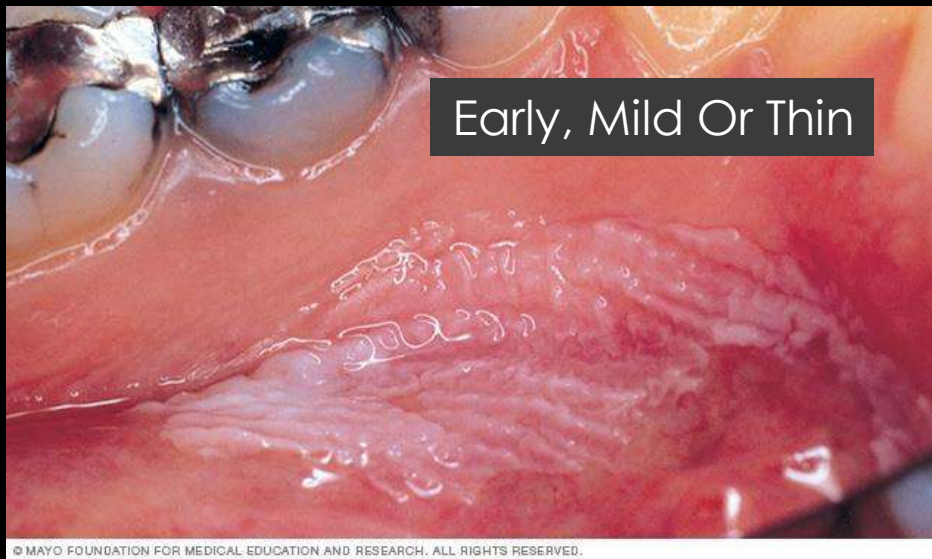Potentially Malignant Disorders

L e u k o p l a k i a

- ▶ A white patch or plaque which cannot be wiped off and cannot be characterized clinically or pathologically as any other disease.
- ▶ It is the most common of all potentially malignant lesions (60%-70%).
- ▶ It is six times **more common among smokers** than non-smokers
- ▶ Affect any part of the oral cavity and oropharynx (most common buccal mucosa, gingiva, alveolar mucosa, and lower lip).
- ▶ It is a Clinical Descriptive Term, a (diagnosis of exclusion) and has no diagnostic or prognostic implication.

Clinical Appearance

- ▶ Based on clinical appearance (surface color and morphological or thickness characteristics), leukoplakia can be described as:
- ▶ Early, mild or thin; it is flat or slightly elevated, gray or white plaque, which may be somewhat translucent, fissured, or wrinkled.
- ▶ Thick (Homogenous); it is thickened, leathery, distinctly white plaque with deep fissures.
- ▶ Granular (Nodular); it has increased surface irregularities.
- ▶ Verrucous; with sharp or blunt, wart-like projections.



Verrucous leukoplakia

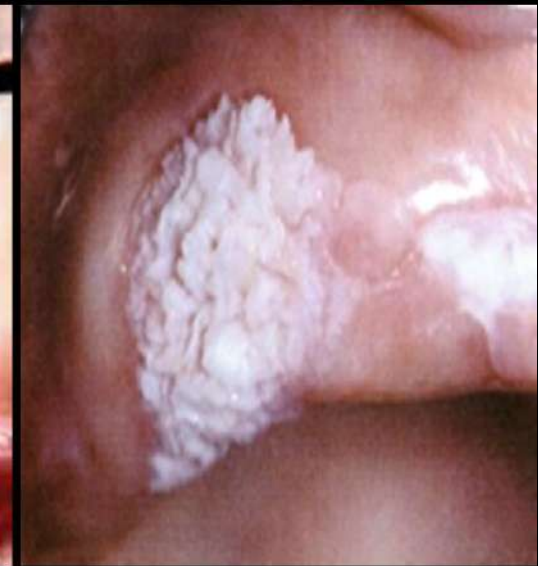
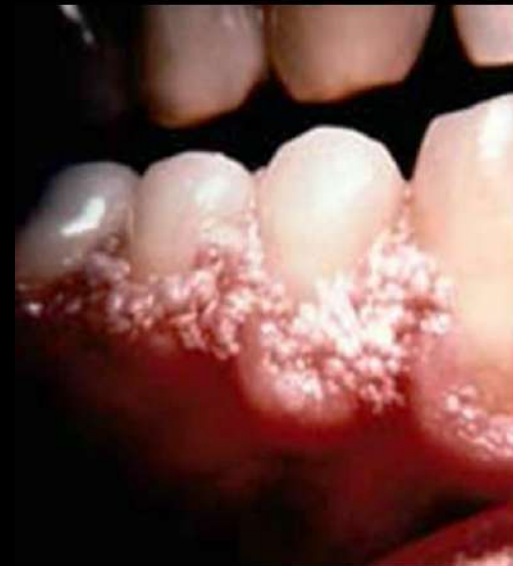
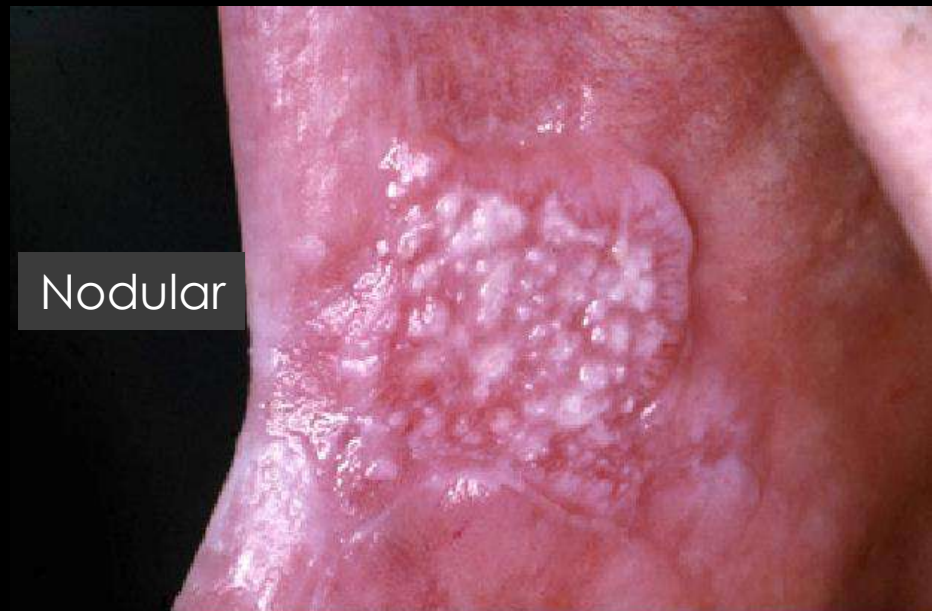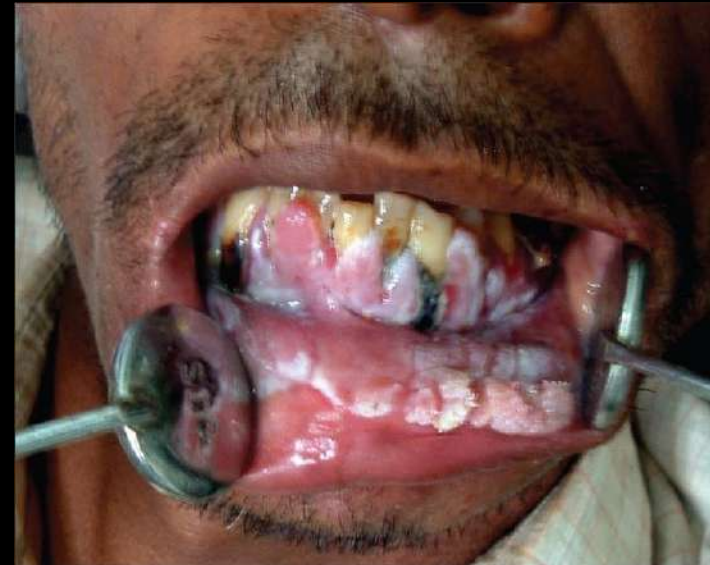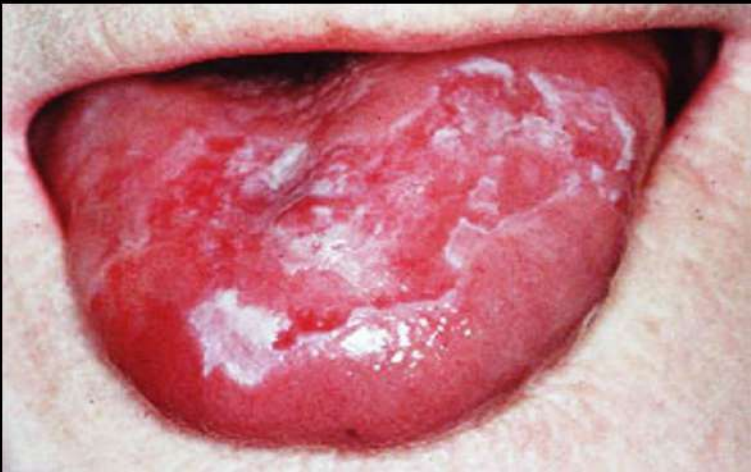Fig. 5. Non-homogeneous, nodular, leukoplakia in a 61-year-old

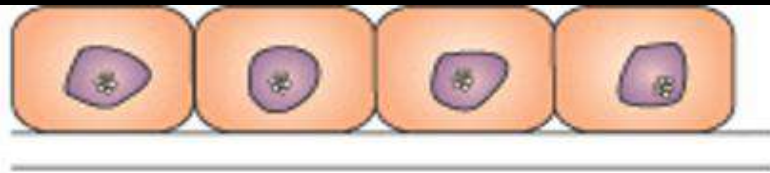
- **Speckled (erythroleukoplakia)**; scattered patches of redness which frequently exhibit high degree of dysplasia.
- Proliferative verrucous leukoplakia (PVL). It is a high risk type.
- Some lesions may exhibit a mixture of these subtypes.
- Lesions may disappear, remain in one stage or change and progress over time.

Speckled (erythro) leukoplakia




Proliferative
verrucous leukoplakia

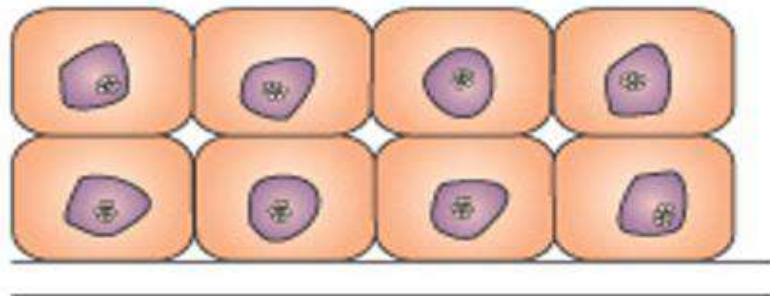
Normal cells



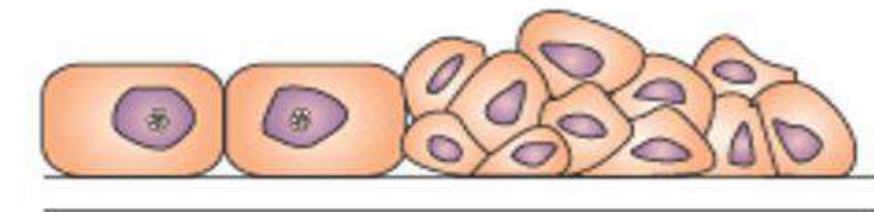
Atrophy



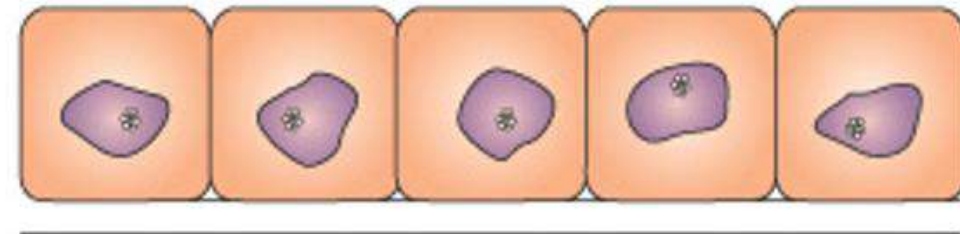
Hyperplasia



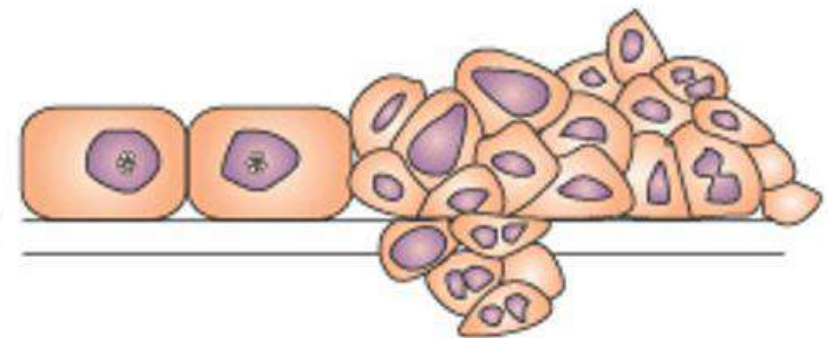
Dysplasia



Hypertrophy

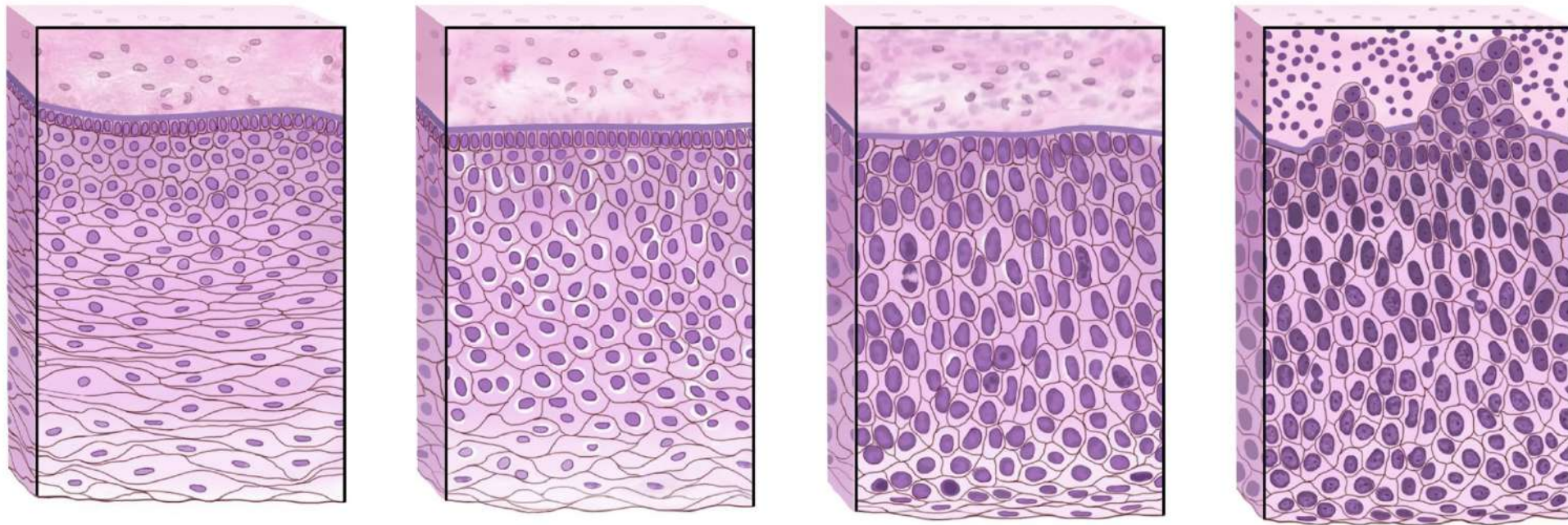


Neoplasia
(malignancy)



Normal Cells May Become Cancer Cells

Normal → **Hyperplasia** → **Dysplasia** → **Cancer**



Histological Features

- ▶ Leukoplakia is characterized by a **thickened keratin layer** of the surface epithelium (**hyperkeratosis**), with or without a thickened spinous layer (**acanthosis**).
- ▶ Some leukoplakias demonstrate surface hyperkeratosis but show atrophy or thinning of the underlying epithelium.

Malignant transformation

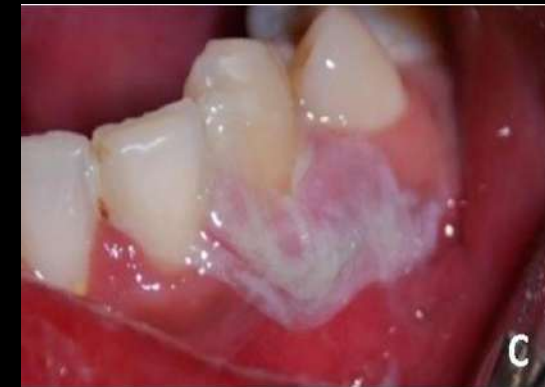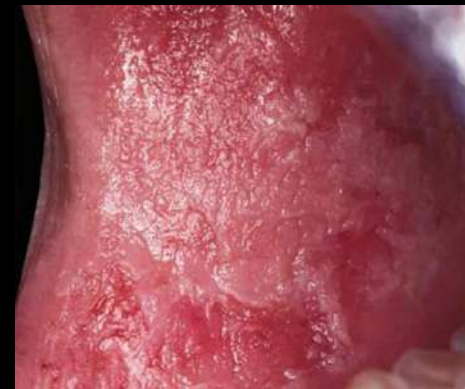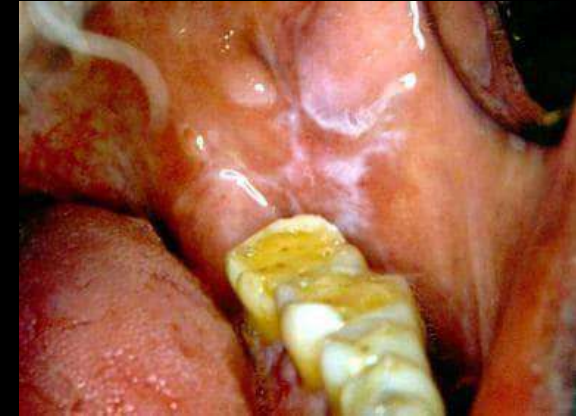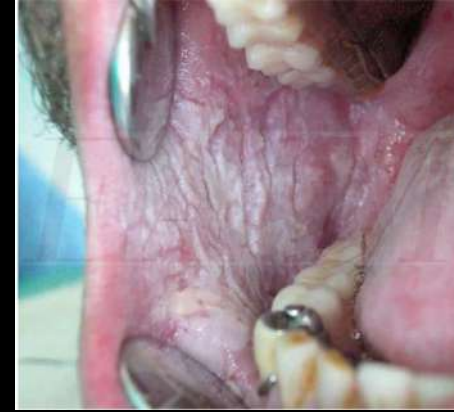- ▶ A meta-analysis published in 2020 presented an estimated **transformation rate of 9.7%**.

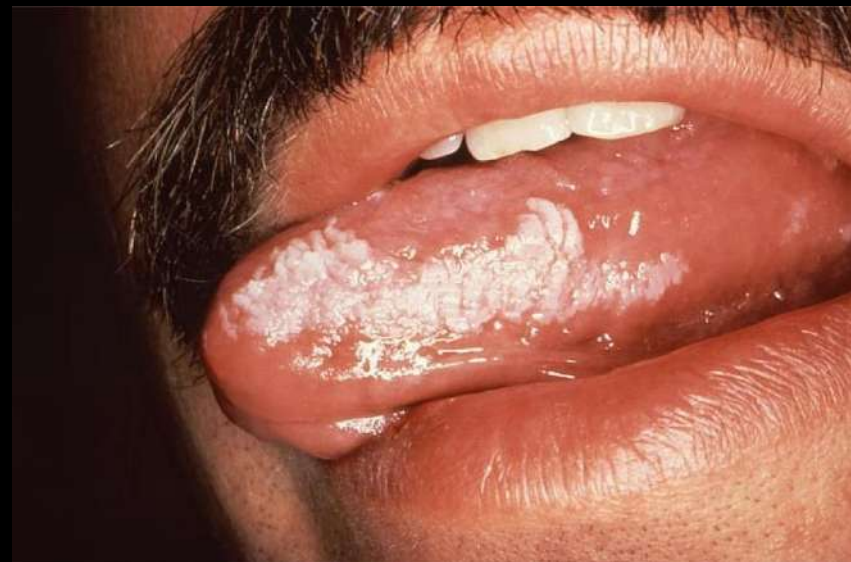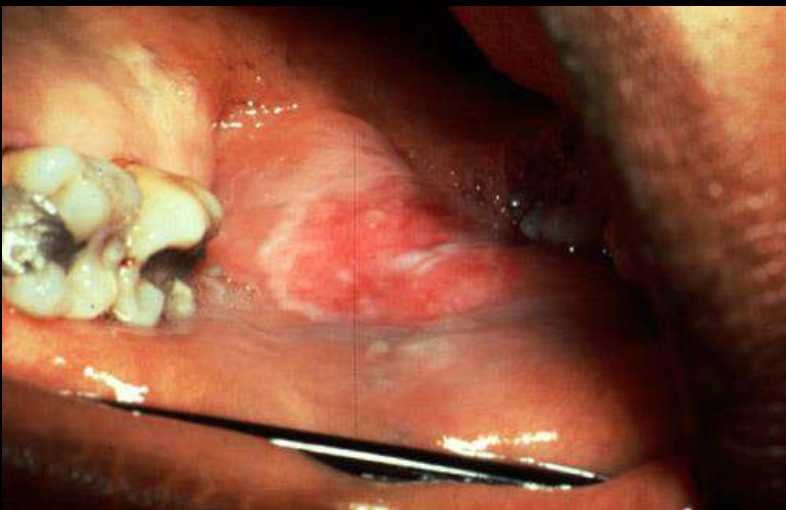
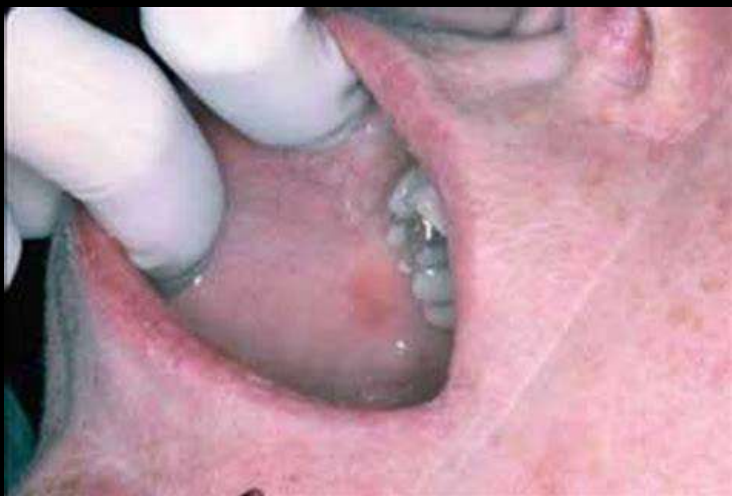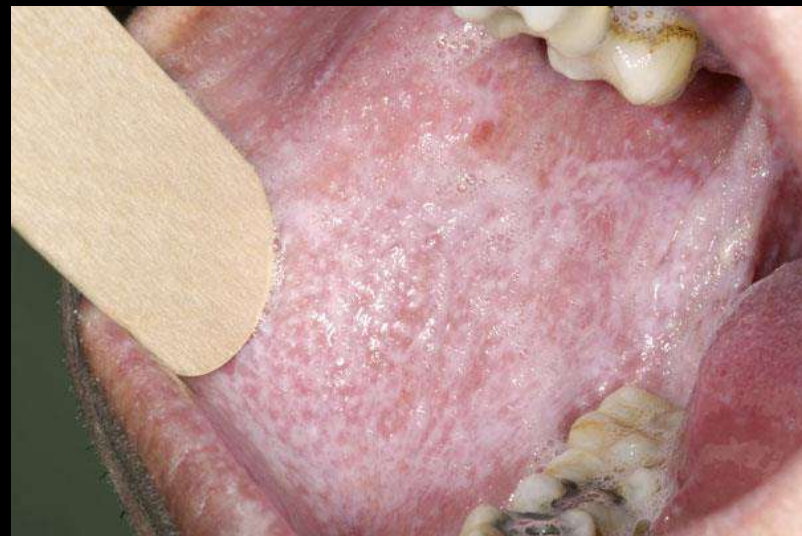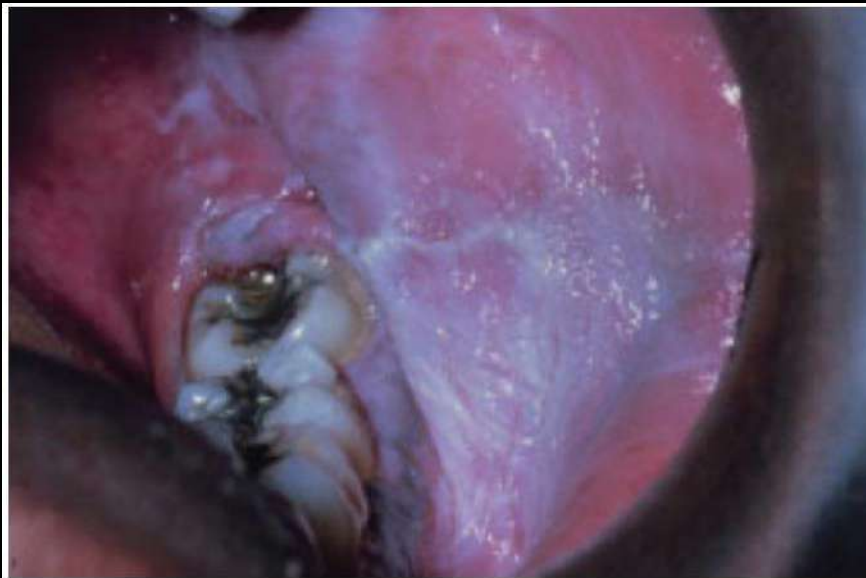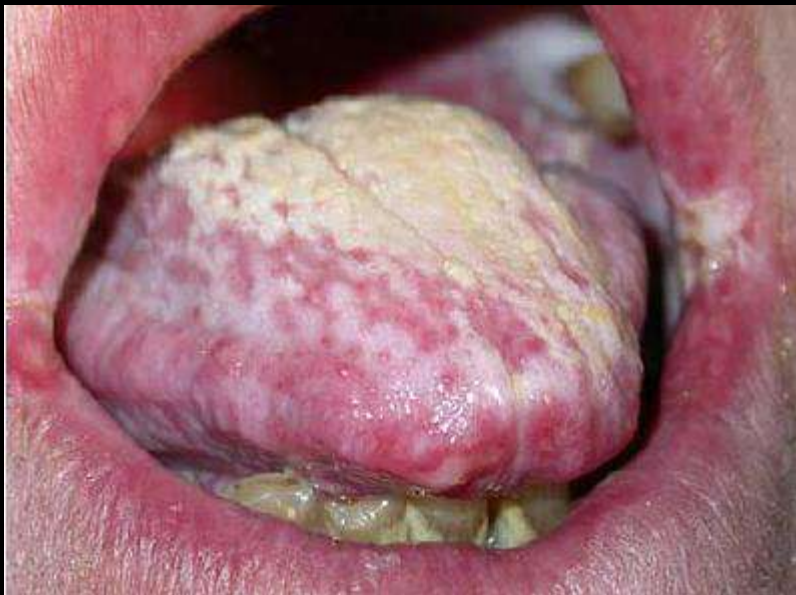Risk factors for malignant transformation include:

- ▶ **Site**; leukoplakia of **floor of mouth had the highest risk** followed by tongue and lip.
- ▶ **Type**; speckled leukoplakia and Proliferative verrucous leukoplakia has the highest risk.
- ▶ **Thickness**; probability of dysplasia or malignancy increases with increases in thickness.
- ▶ Long **duration** of leukoplakia.
- ▶ Leukoplakia in **non-smokers**.
- ▶ Female patients.
- ▶ Presence of *Candida albicans* within the lesion.

Differential Diagnosis

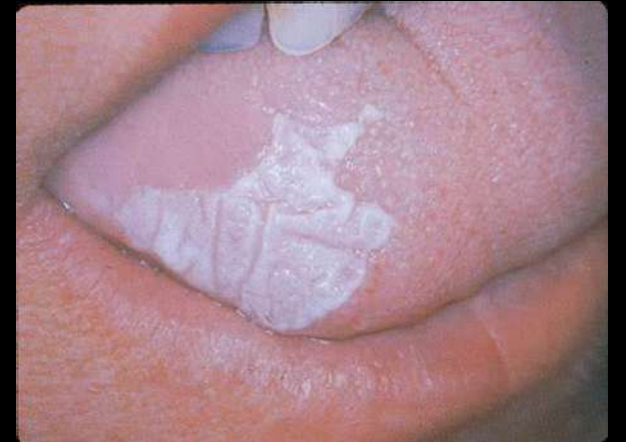- White sponge nevus.
- Frictional keratosis.
- Morsicatio buccarum.
- Chemical injury.
- Acute pseudomembranous candidiasis.
- Leukoedema.
- Lichen planus.
- Lichenoid reaction.
- Discoid lupus erythematosus.
- Hairy leukoplakia.
- Skin graft.





Diagnosis

- ▶ **Exclusion** of other white lesions (differential diagnosis).
- ▶ **Biopsy**; all leukoplakias should be considered at risk for malignant transformation and biopsy should be obtained after diagnosis and exclusion of other white lesions.
- ▶ Biopsies should be taken from areas of a lesion most likely to harbor dysplasia or carcinoma (e.g., red atrophic areas in speckled leukoplakia).



► Following biopsy, **if no other disorder is confirmed**, the lesion is characterized as leukoplakia.

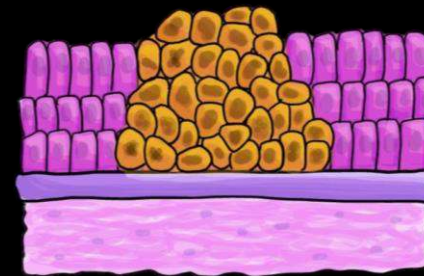
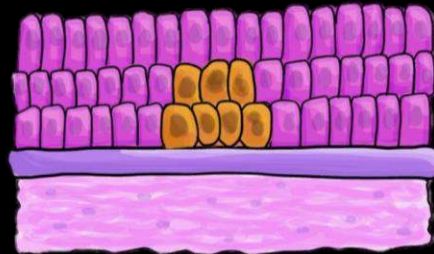
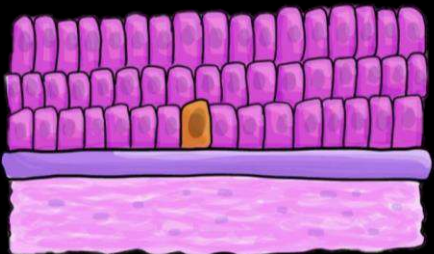
► The **grade of epithelial dysplasia** refers to its severity or intensity:

1. **Mild dysplasia**: alterations limited to the basal and parabasal layers.

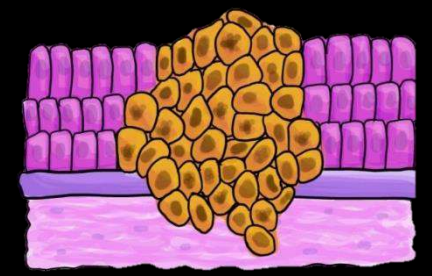
2. **Moderate dysplasia**: involvement from basal layer to the midportion of the spinous layer.

3. **Severe dysplasia**: alterations from basal layer to a level above the midpoint of the epithelium.

4. **Carcinoma in situ**: dysplasia involving **entire thickness** of epithelium.



Carcinoma in situ



Invasive Carcinoma

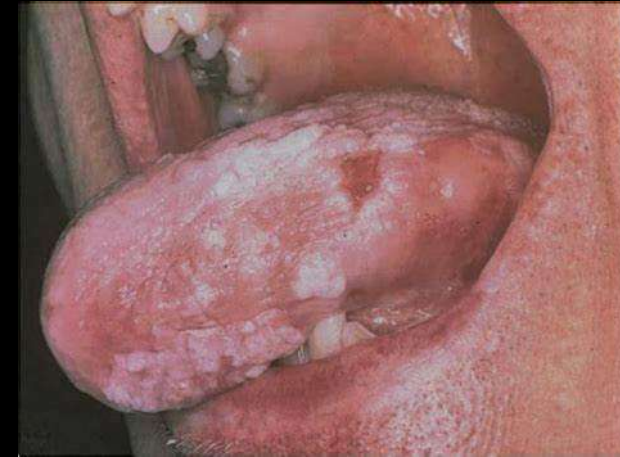Treatment

- No dysplasia or mild dysplasia; the decision to **observe**.
- Moderate to severe dysplasia, and mild dysplasia in high-risk sites; treatment is indicated with variable treatment options.
- **Carcinoma in situ or early invasive SCC; excision with free margins**

Options of Treatment

1- Observation

- This is reserved for mild lesions with no dysplasia, **any possible cause should be removed** and patients are instructed to discontinue bad habits.



2- Surgical excision

- ▶ Using a scalpel with blade No. 15.
- ▶ It is the **traditional method** of treatment indicated for smaller, localized lesions persist more than 2-3 weeks.

Disadvantages:

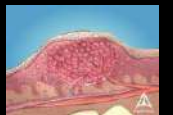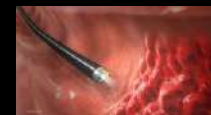1. Inability to excise widespread or diffuse lesions.
2. Scarring of the residual tissue bed.
3. Excessive bleeding especially in the floor of mouth and tongue.
4. The defect may require reconstruction.

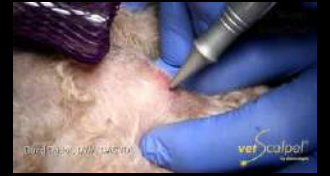3- Cryosurgery

- ▶ This ablates soft tissue by therapeutic freezing, it is easy to perform.

Disadvantages:

1. Lack of depth control in the freezing process.
2. Lack of specimen availability because of the ablative process.
3. Pain and swelling.





4- CO2 Laser

- ▶ It can be used either to ablate the entire lesion without obtaining tissue for biopsy or to excise a lesion and provide a tissue sample.

Advantages:

- ▶ Decreased morbidity.
- ▶ Adequate hemostasis.
- ▶ Healing is by secondary intention (no need for reconstruction).
- ▶ Decreased tissue distortion.

5- Non-surgical treatment

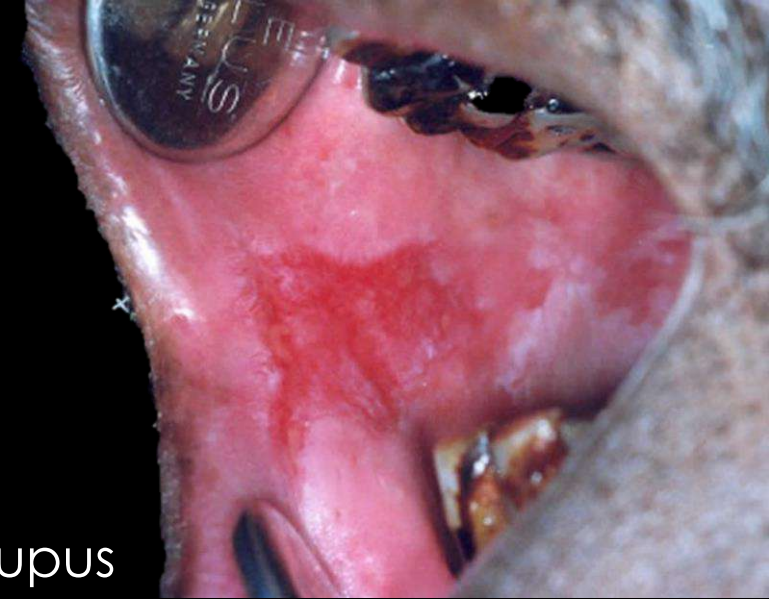
- ▶ This may include vitamin A, retinoids, beta-carotene, vitamin E, bleomycin, and alpha tocopherol used topically or systemically.

Erythroplakia

- ▶ Red patch can't be defined clinically or pathologically as any other definable disease.
- ▶ Uncommon, appear as well-demarcated, erythematous patches or plaques with soft texture.
- ▶ The epithelium is atrophic and lacks keratin production allowing the underlying microvasculature to show through and produce a red appearance.
- ▶ The underlying connective tissue demonstrates chronic inflammation.
- ▶ It has the highest risk for malignant transformation rate ranges from **14% to 50%**.
- ▶ 90% of erythroplakia, histopathologically represent severe epithelial dysplasia, carcinoma in situ, or superficially invasive SCC.

Differential Diagnosis

- ▶ Infections (Mycotic infections e.g., erythematous candidiasis, histoplasmosis or Bacterial infections e.g., Tuberculosis).
- ▶ Mucosal Diseases (e.g., atrophic oral lichen planus, systemic lupus erythematosus, pemphigus, pemphigoid).
- ▶ Hamartomas and Neoplasms (e.g., hemangioma, vascular malformations, Kaposi sarcoma).
- ▶ Others (e.g., telangiectasias, lingual varices, oral purpura).



Diagnosis and Treatment

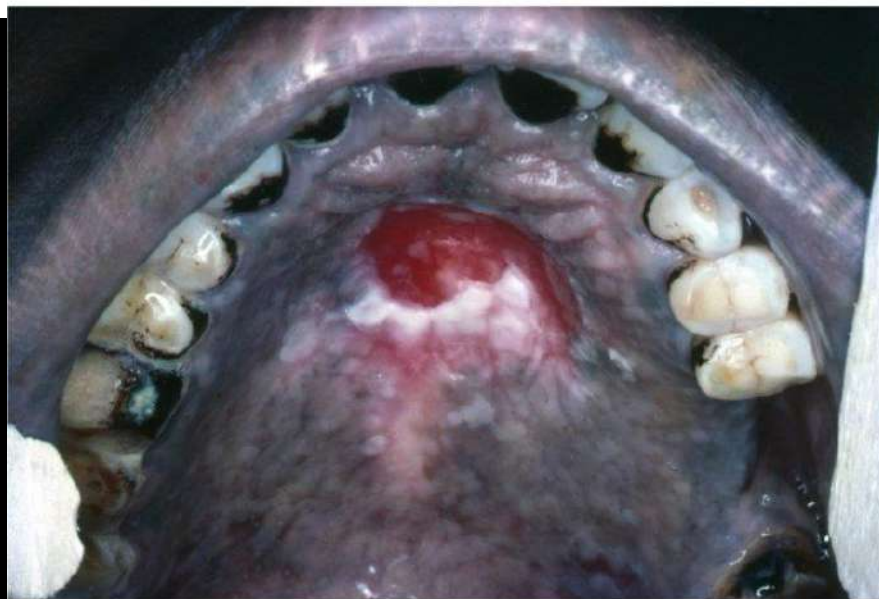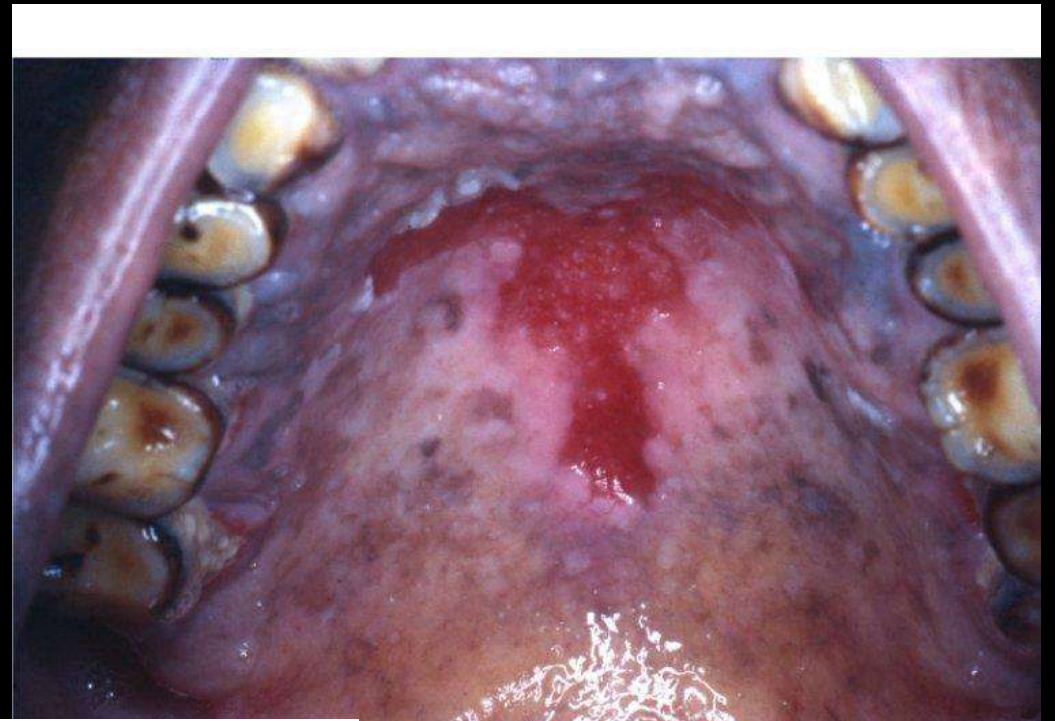
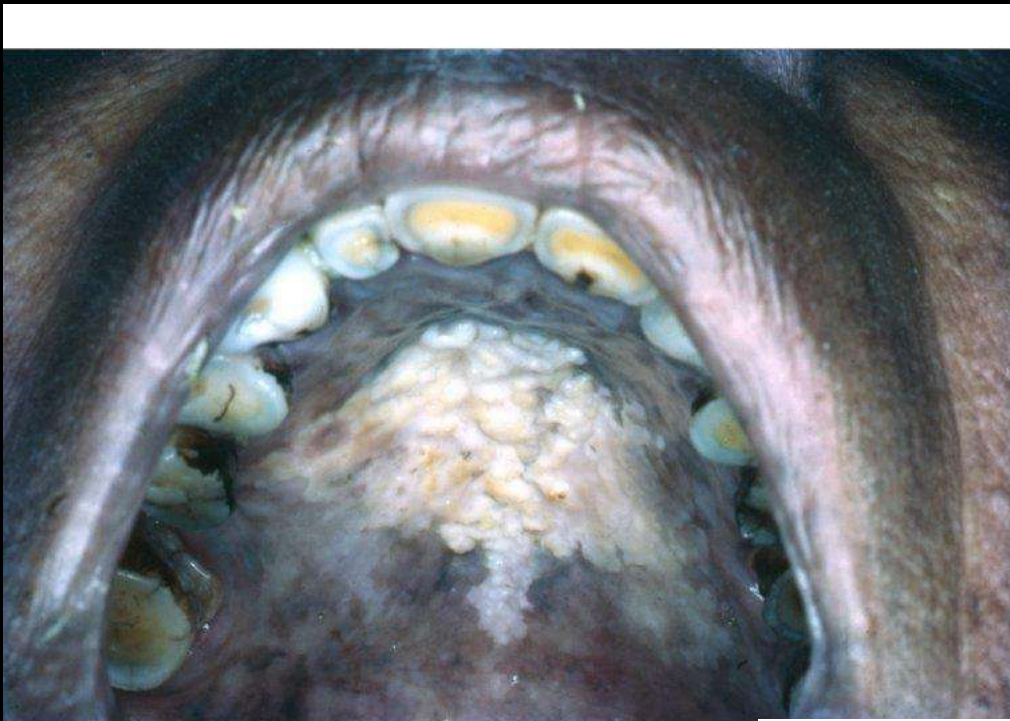
- ▶ Any source of irritation - removed,
- ▶ Lesions that have no identifiable cause or do not resolve within 2 weeks of removal of potential sources of irritation, then **biopsy** is indicated.
- ▶ Because of the high incidence of epithelial dysplasia, carcinoma in situ, or early invasive SCC at diagnosis, **Complete excision** is necessary with **clear margins** provides a specimen that can be assessed adequately for free margins and reduce the risk **for local recurrence**.

Palatal Changes Associated with Reverse Smoking

- ▶ This lesion is specific to populations who smoke with the lighted end of the cigar inside the mouth.
- ▶ No difficulties in diagnosing this lesion once this particular habit is noted. The reported **malignant transformation rate is 0.3%**.

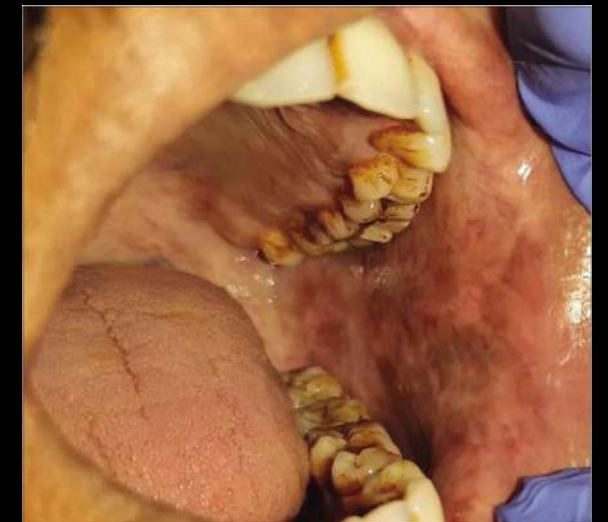Treatment

- ▶ **Discontinuation of habit and follow-up.**
- ▶ If **red areas**, ulcerations, patches persist, then **biopsy** carried out.
- ▶ Treatment is guided by histopathological diagnosis.
- ▶ **Surgical excision is indicated for dysplastic lesions.**



Oral Submucous Fibrosis

- ▶ It is a chronic disorder characterized by fibrosis of the lining mucosa of the upper digestive tract involving the oral cavity.
- ▶ It is seen primarily in the India.
- ▶ The etiology is linked to chewing of betel quid; with risk factors : excessive consumption of spices, deficiencies of iron, vitamin B, and protein and genetic.
- ▶ Histologically: Epithelial changes include hyperkeratosis, atrophy, epithelial dysplasia and carcinoma (1% transformation risk).



Treatment

- ▶ Oral submucous fibrosis **not regress with habit cessation**.

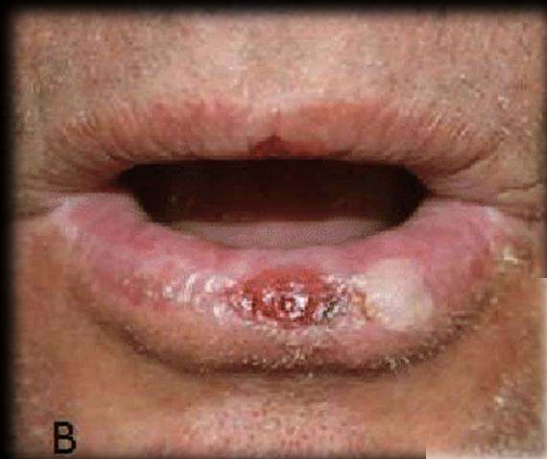
Treatment options are:

- ▶ **Nutritional**; vitamins and minerals; antioxidants (e.g. B complex).
- ▶ **Physiotherapy**; forceful mouth opening and heat therapy.
- ▶ **Intralesional injections**; of corticosteroids, interferon gamma, or proteolytics (e.g., hyaluronidase). These are used to **prevent or suppress inflammatory reaction**, thereby preventing fibrosis by decreasing fibroblastic proliferation and deposition of collagen.
- ▶ **Surgical**; for moderate to severe cases may require **surgical splitting or excision of the fibrous bands** with or without skin graft, or using flaps followed by lifelong physiotherapy.

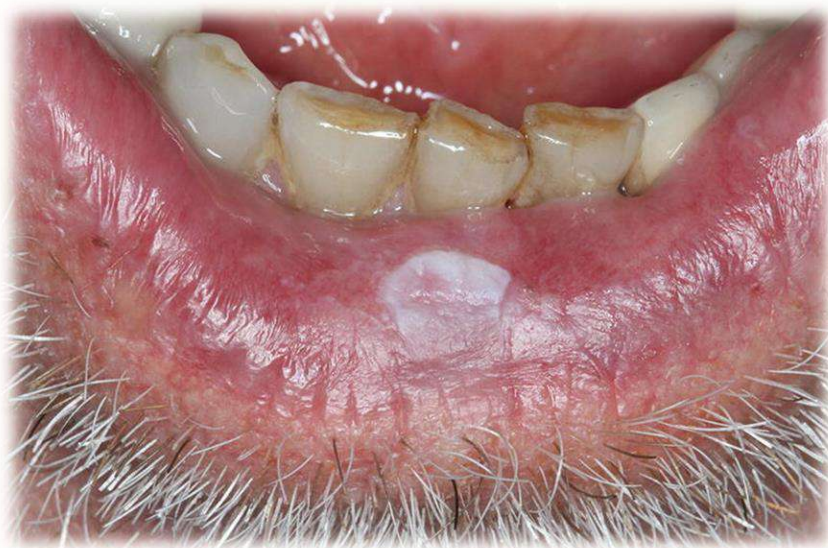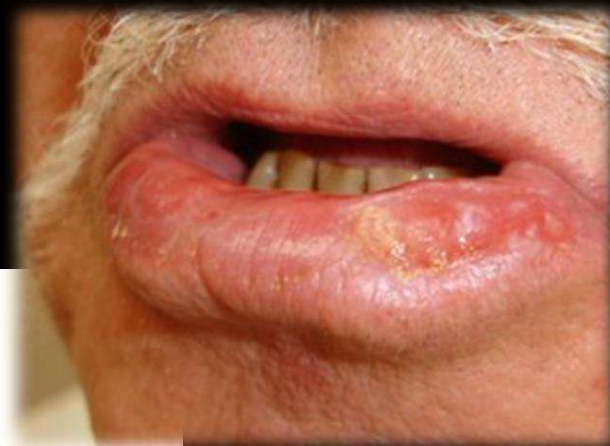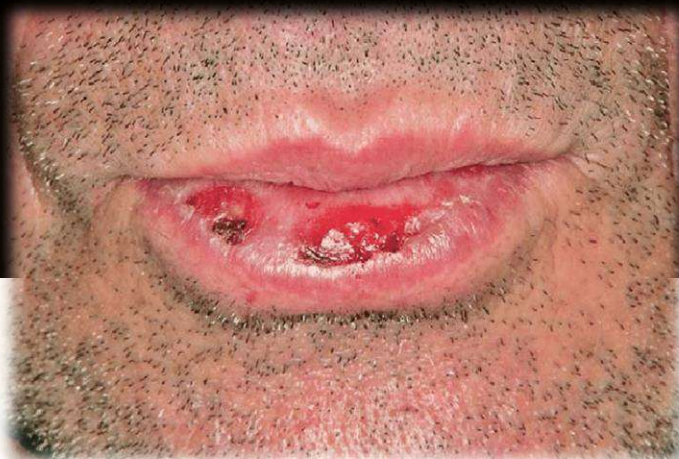
Actinic Cheilitis (Cheilosis)



- ▶ Common potentially malignant alteration of the lower lip vermilion.
- ▶ Results from long term exposure to the **ultraviolet component of sunlight**.
- ▶ other risk factors are fair complexion, old age, immunosuppression, arsenic exposure, certain genetic abnormalities and HPV.
- ▶ Early clinical changes include **atrophy of the lower lip** vermilion border.
- ▶ As the lesion progresses, **rough areas on the vermilion**, thickened and appear as leukoplakic lesions.
- ▶ Chronic focal **ulceration** may develop which often suggest progression to **early SCC**.
- ▶ **Malignant transformation** to SCC occurs in **6%-10%**.



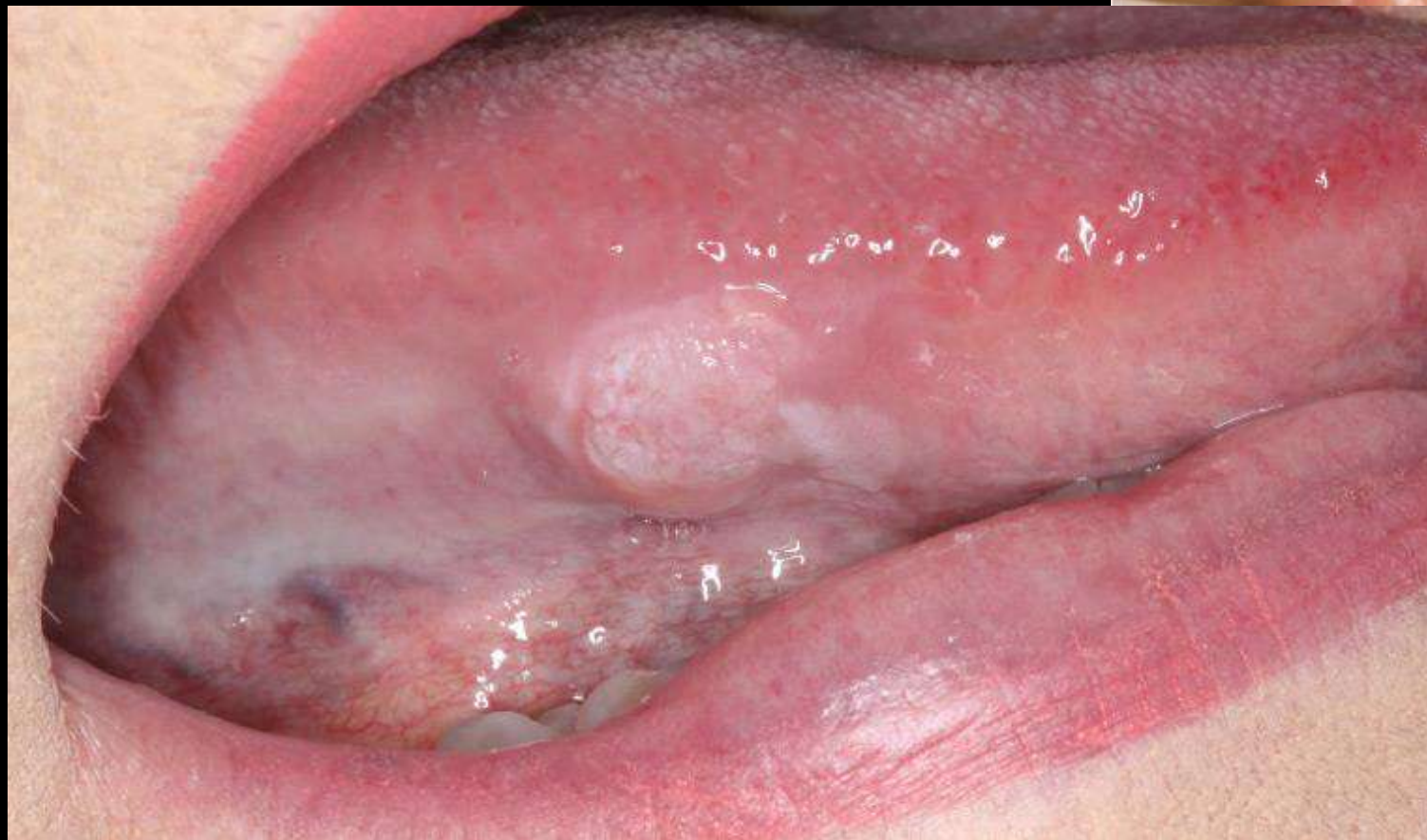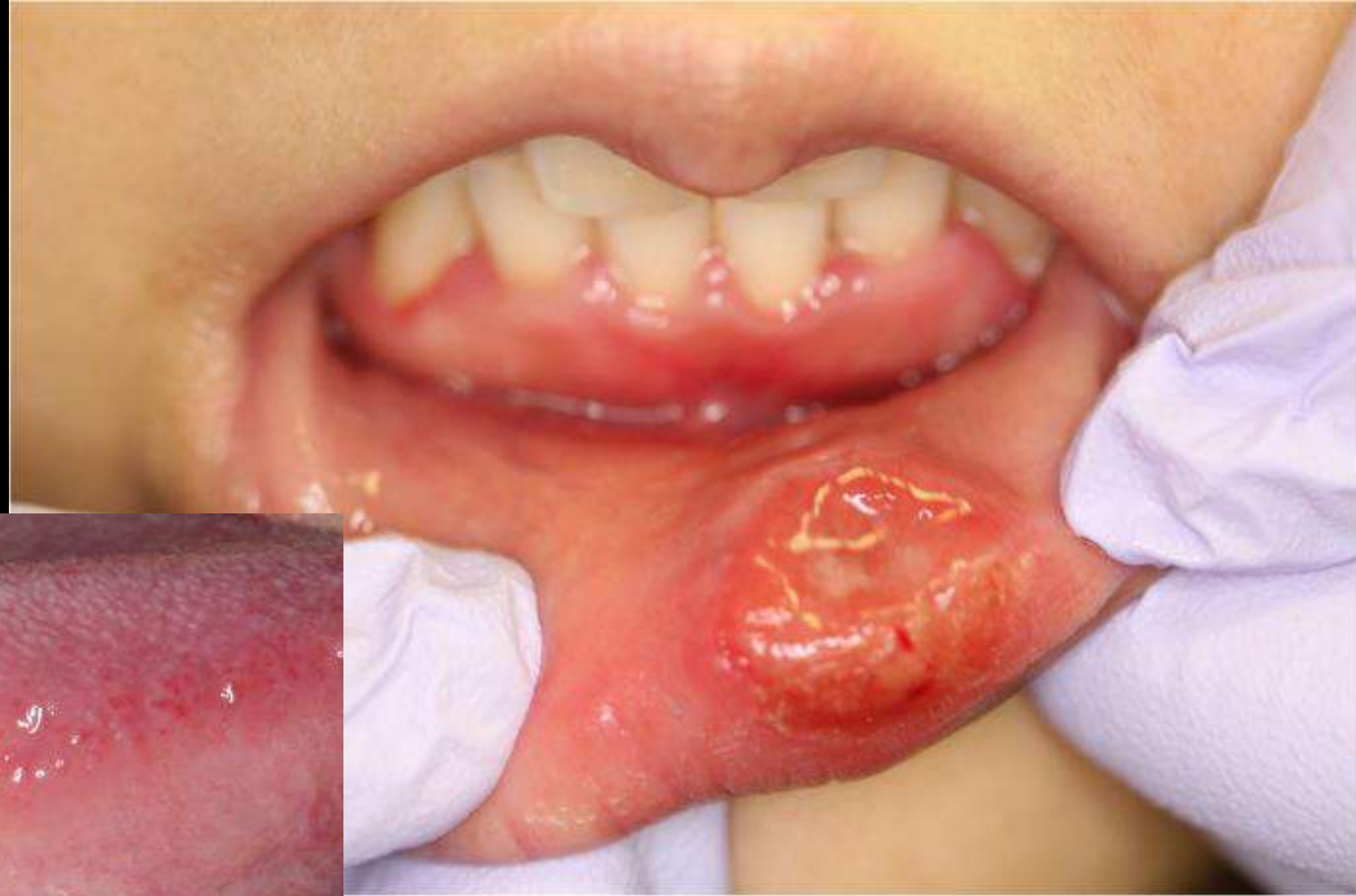
B

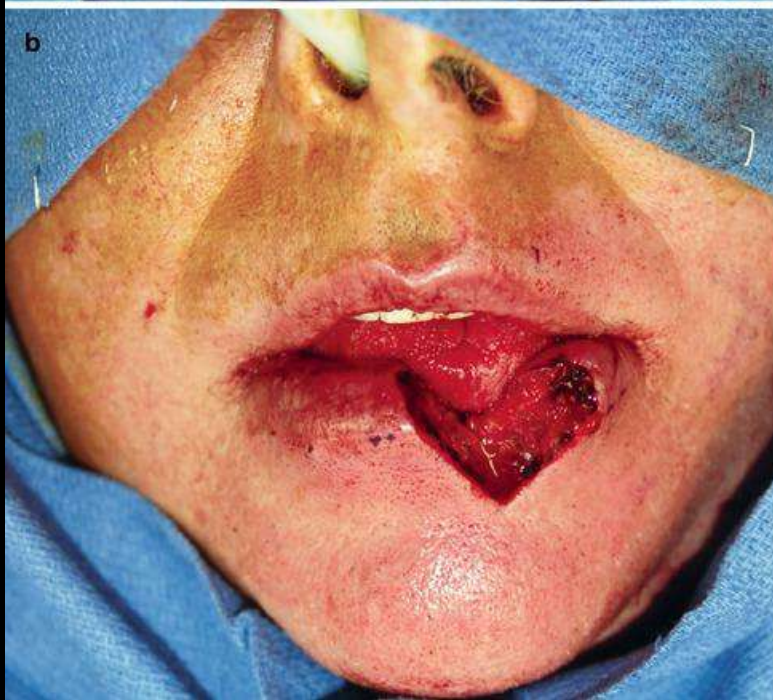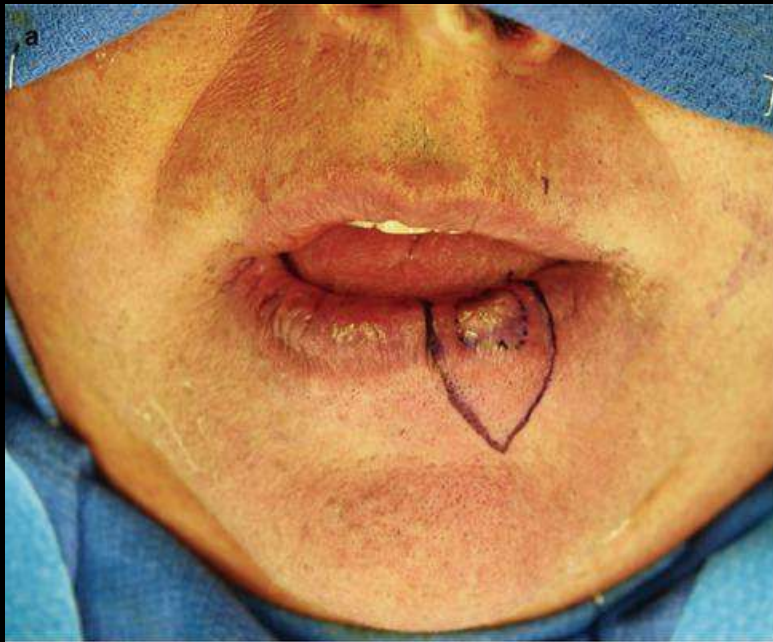


Treatment

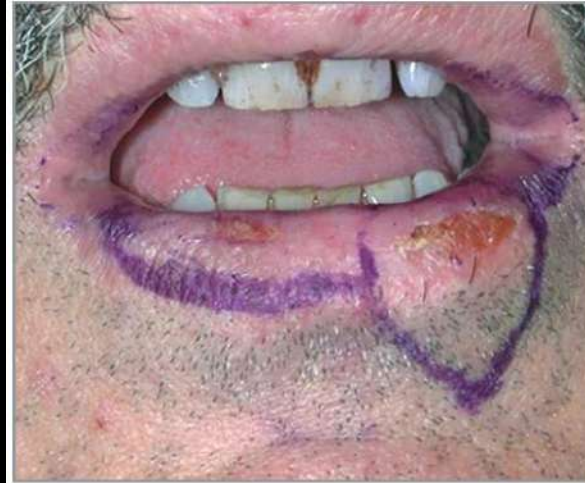- ▶ Instruction of patients to **avoid direct exposure** to sun and using sunscreens.
- ▶ **Areas of indurations, thickening, ulceration** should be submitted for biopsy.
- ▶ **Lip shave (vermilionectomy)** performed in cases of **dysplasia**. The vermilion mucosa is excised and the labial mucosa advanced to reconstruct the vermilion.
- ▶ Alternative treatments include laser ablation, electrodesiccation, cryotherapy and photodynamic therapy. Long-term follow-up is recommended.
- ▶ If a SCC is identified, then the involved lip is treated accordingly.

Indurations

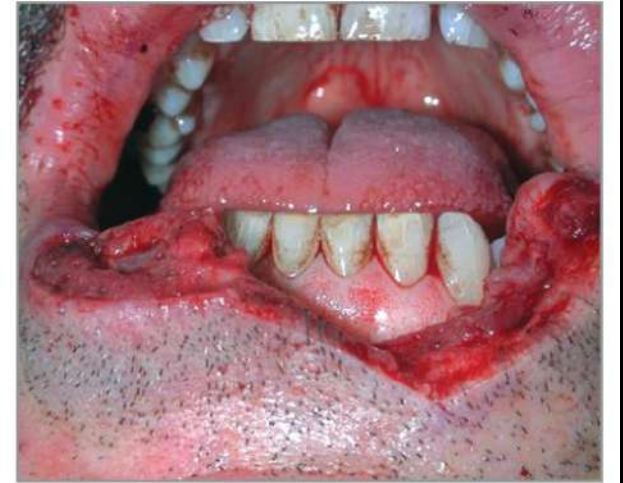



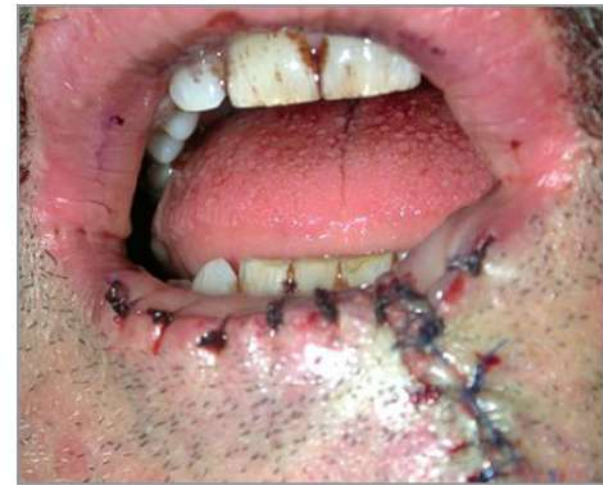A Preoperative image



B Vermilionectomy



D Postoperative image



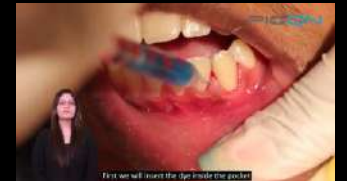Desiccation



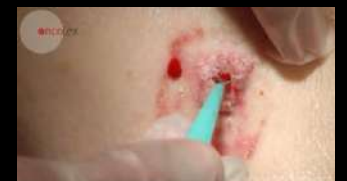cryotherapy

Cryosurgical Procedures
Richard P. Usatine, MD
The Journal of Family Practice

photodynamic
therapy



The Photodynamic Effect

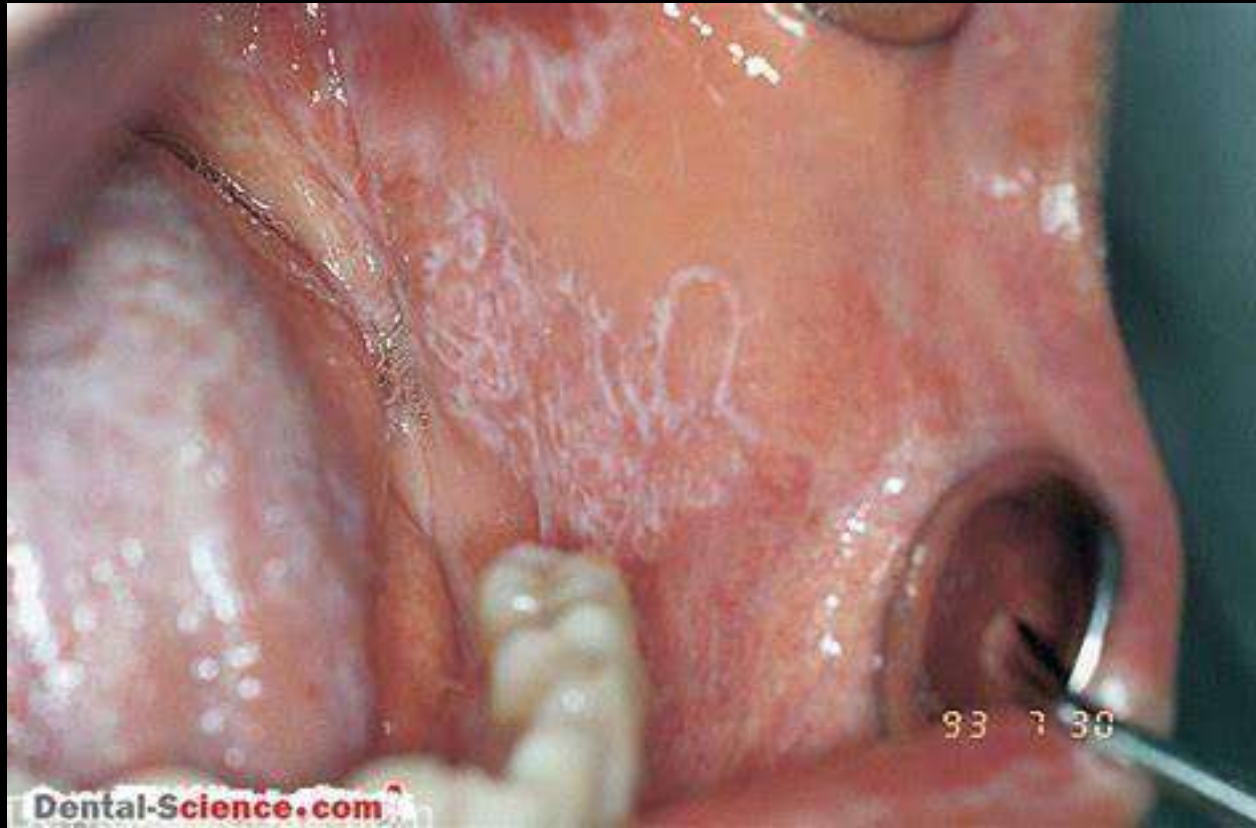

Lichen Planus

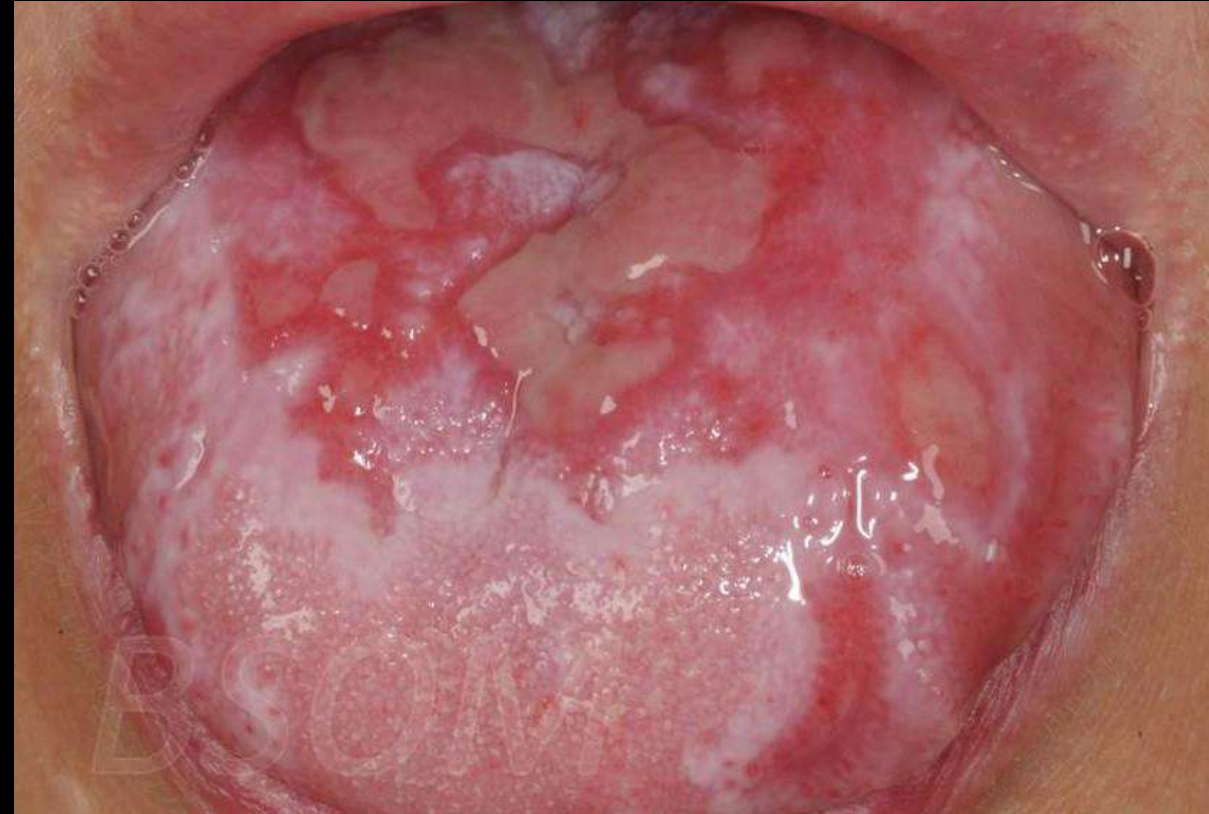- ▶ It is a chronic mucocutaneous disease that can affect the skin or mucosa.
- ▶ The cause is suggested to be an immunologically induced degeneration of the basal cell layer of the mucosa.
- ▶ The prevalence is between **0.1% and 2.2%**.
- ▶ Buccal mucosa is the most commonly involved site.
- ▶ Two main types of oral lichen planus; **reticular and erosive**, but other types of oral lichen planus were described in the literature; papular, plaque-like, **atrophic (erythematous)**, and bullous.

- ▶ **Reticular; most common type**, usually arises in the buccal mucosa **bilaterally** and characteristically has fine, radiating white striae known as **Wickham striae**, **asymptomatic** and diagnosed by its clinical features.
- ▶ Erosive; it appears as irregularly shaped, covered with a fibrinous plaque or pseudomembrane, **symptomatic** and has a greater potential for malignant change.
- ▶ **The skin lesions** described as purple, pruritic, polygonal papules usually affecting the flexor surfaces of the extremities.

Reticular



Erosive



Malignant Transformation

- ▶ Malignant transformation rate **0.3% to 3%**.
- ▶ The two types with an increased potential to undergo malignant transformation are the **erosive and atrophic forms**.

Treatment

- ▶ Topical or systemic corticosteroid **for symptomatic** lichen planus. Other agents have been used such as; cyclosporine, tacrolimus, griseofulvin, dapsone, azathioprine, and levamisole.

The site of leukoplakia with the highest risk of malignant transformation is

A. The tongue.

The buccal mucosa.

C. The floor of mouth.

D. The lip.

E. The hard palate.

With respect to actinic cheilitis, (one is incorrect)

A. Fair complexion is a risk factor

B. It mainly affects females.

C. It affects the lower lip.

D. It results from long-term exposure to the ultraviolet component of sunlight.

Which of the following diseases has the highest malignant transformation rate

A. Leukoplakia.

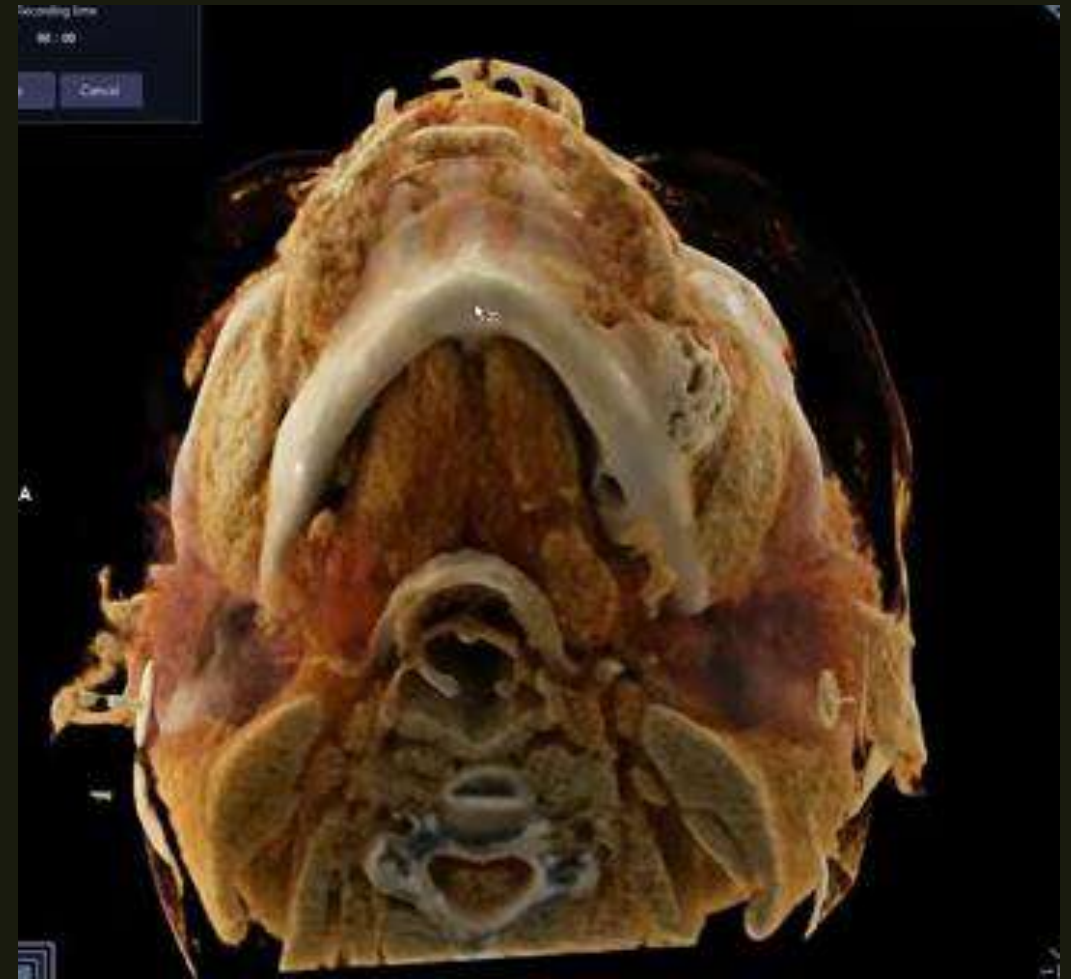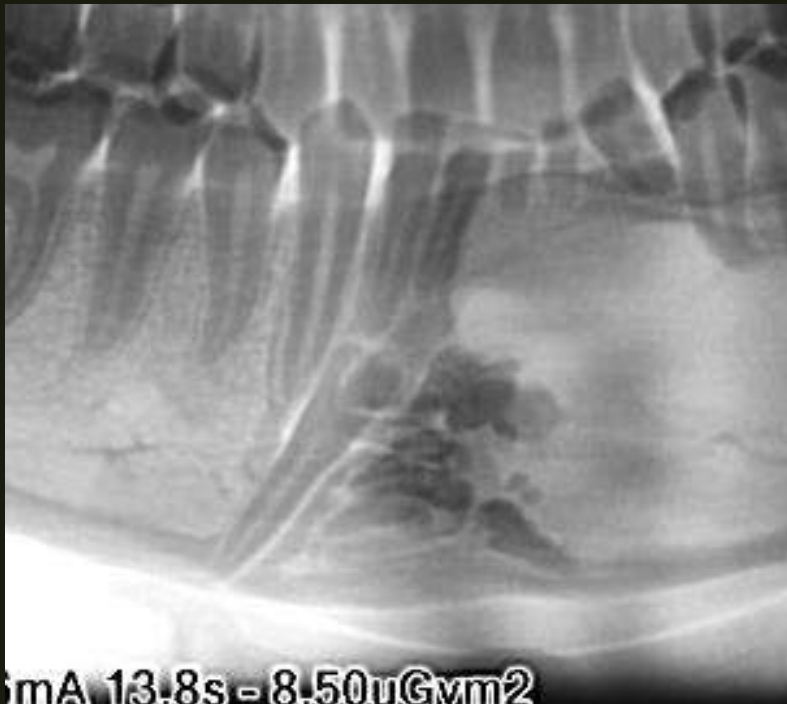B. Erythroplakia.

C. Lichen plannus.

D. Geographical tongue.

E. Chronic candidiasis of the oral cavity.

ODONTOGENIC TUMORS



Bashar Abdul-Ghani

FICMS. MAXFACS Cons. MFDS. RCSED. RCPS (Glasg).

Lecture Quoted From Baghdad University Curriculum

Topics

- Definition
- Classification of Odontogenic Tumors
- Epithelial odontogenic tumors
- Mixed epithelial and mesenchymal odontogenic tumors
- Mesenchymal odontogenic tumors
- Clinical features \ Radiographic features
- Ameloblastoma \ Unicystic ameloblastoma
- Peripheral/extraosseous)
- Odontoma \ Compound type \ Complex type
- Surgical treatment of odontogenic tumors
- Enucleation and/or curettage, adjunctive treatment
- Resection

- Odontogenic tumors are pathologic outcomes from tissue elements that are part of the tooth-forming apparatus, that is, odontogenic tissues.
- Odontogenic tumors comprise neoplastic growths of benign, malignant, or tumor like malformations originating from odontogenic tissues.
- These tumors occur exclusively in the jaw particularly around the teeth-bearing segments.
- Most of these swellings have tooth-associated (symptoms or radiological changes).
- The General Dentist possesses an opportunity to be the first health care professional to see anatomic or radiographic changes due to proximity of the structures that they routinely treat.
- The interactions between ectodermal and mesenchymal elements from odontogenic tissues can initiate tumor formation due to disturbance in signaling mechanism for their growth and proliferation.

The World Health Organization (WHO) Classification system for odontogenic bone tumors (5th edition, 2022)

1- Benign epithelial odontogenic tumours

- Adenomatoid odontogenic tumour
- Squamous odontogenic tumour
- Calcifying epithelial odontogenic tumour
- Ameloblastoma, extraosseous/peripheral
- Ameloblastoma, unicystic
- Ameloblastoma, conventional
- Adenoid ameloblastoma
- Metastasizing ameloblastoma

2- Benign mesenchymal

- ▶ Odontogenic fibroma
- ▶ Odontogenic myxoma
- ▶ Cementoblastoma
- ▶ Cemento-ossifying fibroma.

3- Benign mixed epithelial and mesenchymal

- ▶ Ameloblastic fibroma
- ▶ Primordial odontogenic tumour
- ▶ Odontoma
 - ▶ Odontoma, compound type
 - ▶ Odontoma, complex type
- ▶ Dentinogenic ghost cell tumour.

Clinical Considerations

- Odontogenic tumors, as a group, are relatively uncommon and rare.
- The clinical importance not measured by their numbers, but because they are destructive and surgical management involves the face, oral tissues, and jaws.
- Correlation of clinical, radiographic, and histologic analysis is necessary to prevent over- or under-treatment.
- There are no clinical signs, symptoms, or physical findings that permit diagnosis of specific odontogenic tumors.

Imaging

- Odontogenic tumors are most often **discovered by dental routine screening** radiography.
- Periapical, Occlusal, Panoramic, CBCT, CT, MRI, and Positron Emission Tomography (PET) scan, view the tumor in relation to the jaws and adjacent soft tissues.
- Mostly, Radiographic images **do not provide pathognomonic identification** of odontogenic lesions, because several odontogenic and non-odontogenic tumors may share imaging characteristics.
- However, highly useful visual information can be gathered to study a lesion for differential diagnoses, selection of biopsy sites, and management decisions.

- Overall viewing of bone and soft tissue by consecutive anatomic “slices” and planes is provided by CT and MRI, respectively.
- The volume of the tumor and the interface margins between the tumor and surrounding bone and soft tissue is roughly revealed by PET-CT, obtained after injection of a glucose isotope conjugate metabolized by the tumor.
- The 3D CT permits viewing the lesion in almost kaleidoscopic anatomic displays; the 3D CT generated model provides an excellent physical reproduction of the anatomic part and tumor. The model is useful for planning or carrying out a mock surgical procedure and provides a mechanical frame on which to contour a reconstruction appliance.

Diagnostic considerations (Biopsy)

- Definitive diagnosis is **established only after** incisional, excisional, or intraoperative frozen biopsy.
- The biopsy technique is selected **after good assessment of the patient** and the use of local, sedation, or general anesthesia to ensure patient cooperation, gain access, and obtain sufficient tissue

Excisional biopsy performed for

- Completely calcified lesions,
- Physically impaired patients.
- Small lesions (1 - 1.5 cm in diameter),

Intraoperative frozen section used to

- Study questionable soft tissue in areas not sampled by the incisional biopsy,
- Examine the **adequacy of the boundary** between lesion and normal tissue.
- The preparation of a good frozen section is technique-sensitive and requires proper specimen orientation.


■ Management

The objectives of the surgical management are

- The eradication of the lesion,
- Preservation of normal tissue to the extent possible,
- Restoration of significant tissue loss, form, and function.

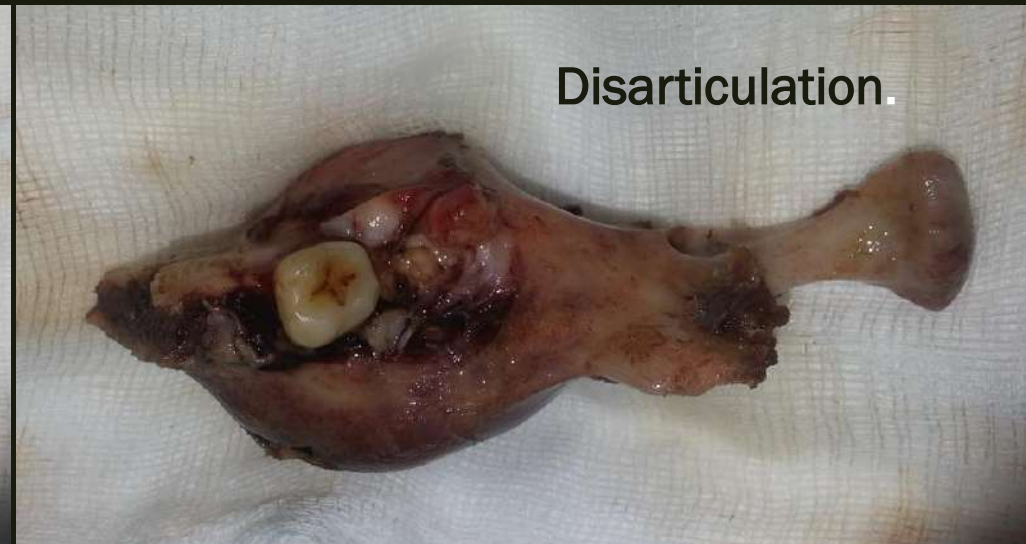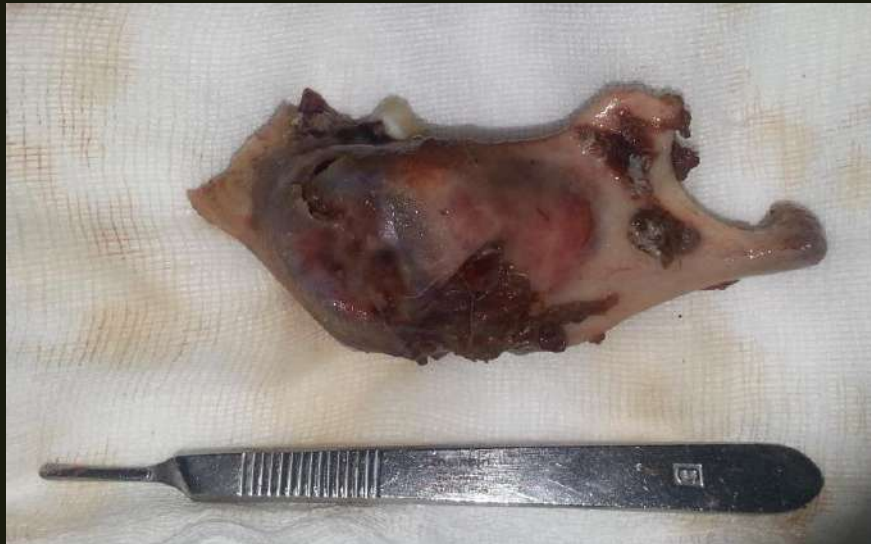■ All agree that the surgical procedure should be sufficient to the need.

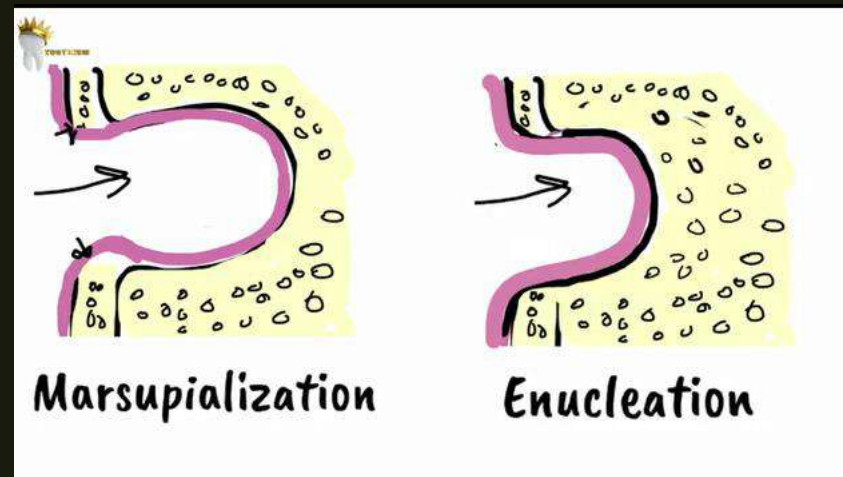
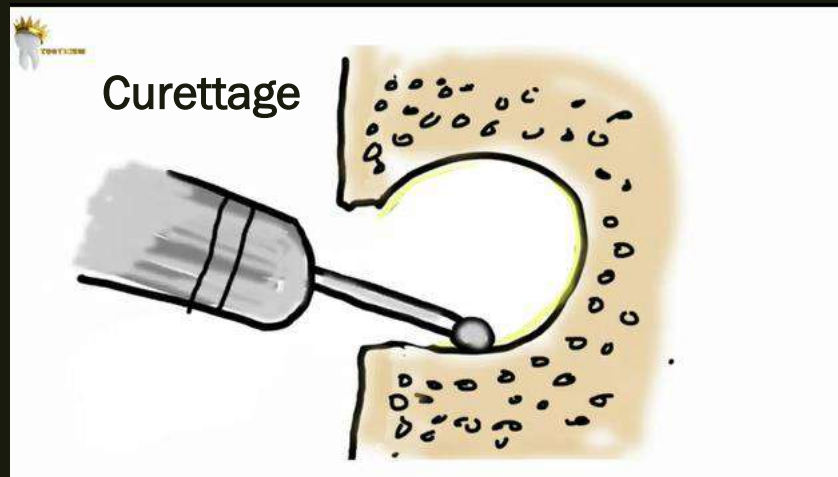
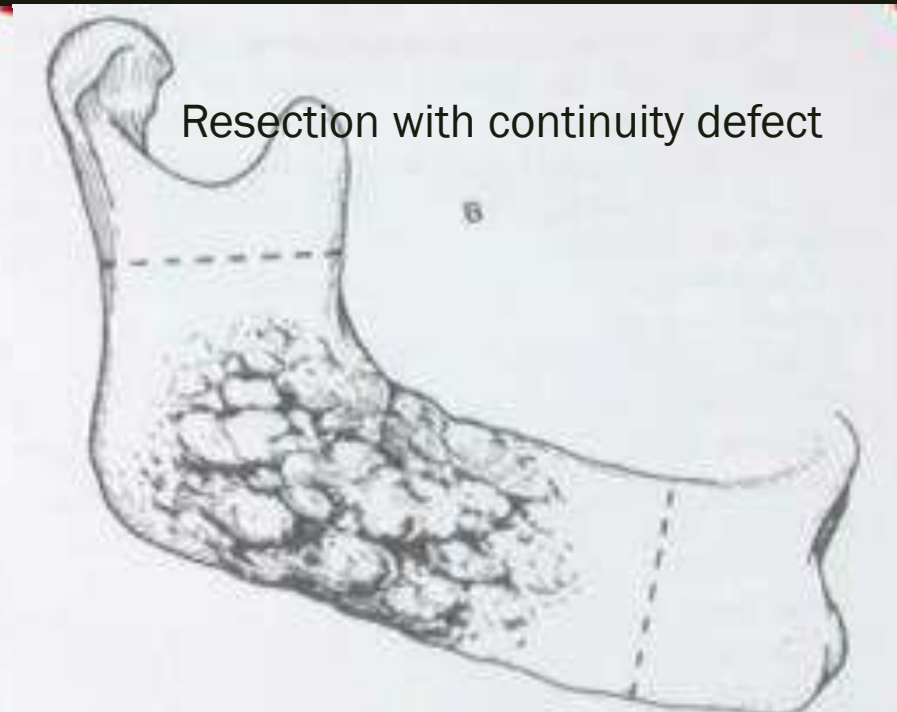
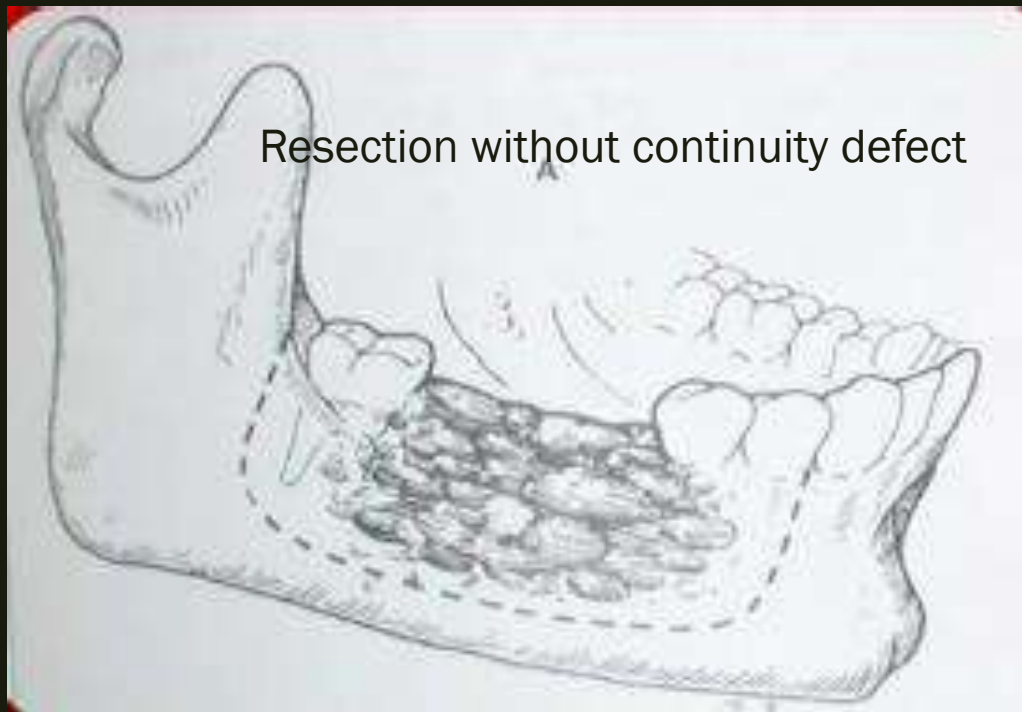
- Because all odontogenic tumors are benign, Some surgeons depend a conservative surgical approach, The basis for this opinion is the belief that a recurrence can be managed by a simpler procedure that can avoid jaw resection.
- Other surgeons are routinely aggressive in their approach, and sacrifice more normal tissue than is necessary to ablate the lesion.



All excisions involving bone can best be described by the following designations:

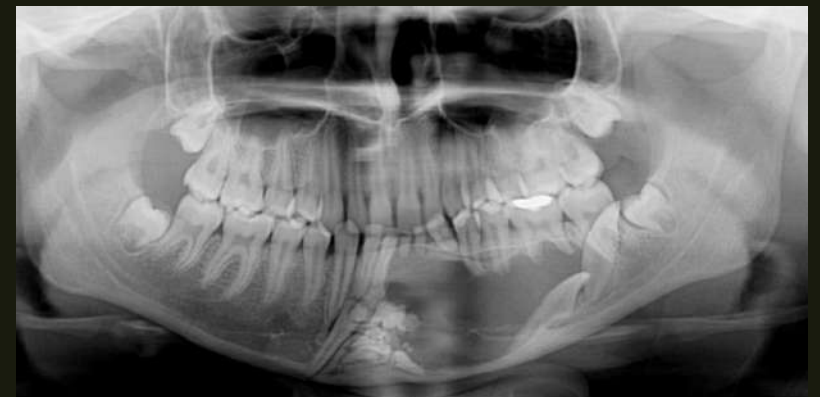- Enucleation, Curettage, Marsupialization, Recontouring, Resection without continuity defect, Resection with continuity defect, and **Disarticulation**.
- **Enucleation** means completely separating the lesion from the adjacent bone and removing it.
- **Curettage** involves raking out the lesion together with part of the adjacent bone (1-2 mm)
- **Marsupialization** is the surgical technique to uncover cyst by creating a persistent window.





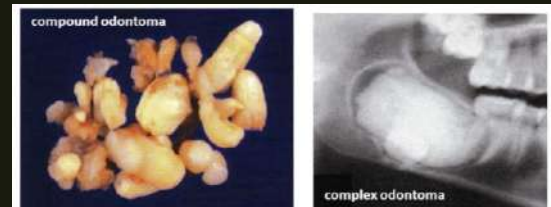
Odontoma - Compound and Complex.

- Odontoma is a **benign tumor of mixed odontogenic origins** consisting of both odontogenic hard and soft tissue.
- It is thought to be the **most frequent** odontogenic tumor.
- It consist of normal-appearing enamel/ dentin structures and have defects in their structural arrangement and so they are considered as hamartomas, or **tumor-like malformations, rather than true neoplasms.**
- The lesion is easily recognized in radiographic examinations and appears as a radiopaque mass with thin radiolucent rim.
- Managed by surgical enucleation.



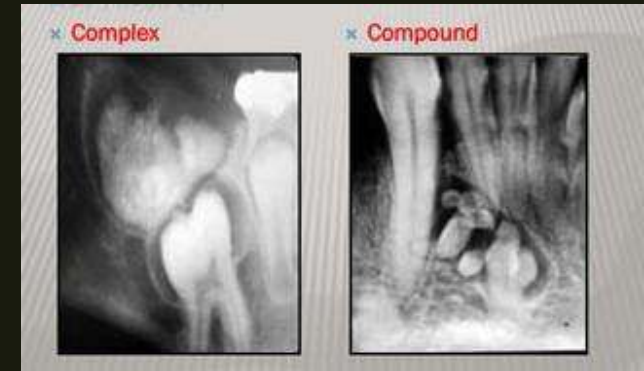Clinical Features

- Odontomas are slow-growing, expanding, and painless intra-bony lesions.
- Pain and inflammation may, however, result from secondary infection.
- The 2 types of odontomas are **Complex and Compound Odontoma**.
- **The distinction** between these 2 types is based on either the **appearance of tooth-like structures or disorganized mass of dental tissue**.
- Compound odontoma - **collection of multiple tooth-like structures** of varying size and shape with periphery of narrow radiolucent zone.
- The compound odontoma has **recognizable well-organized enamel, dentin, and cementum** and consists of individual recognized small teeth, located in the anterior maxilla.



- Complex odontoma - **calcified mass with radio-density of tooth structures** with periphery of narrow radiolucent zone.
- **The complex type is unrecognized disorganized as dental structures**, appearing as a radiopaque mass with varying densities, located in the posterior mandible

Diagnostic modalities



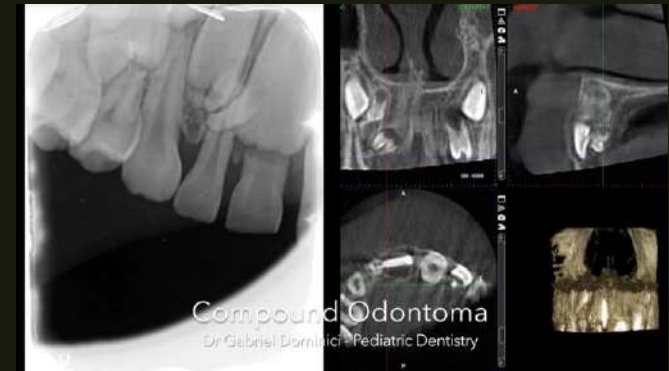- Odontomas can be diagnosed based on their **radiographic appearance alone**.
- The radiologic appearance **depends on the stage of the lesion**.
- **Resorption of adjacent tooth or roots are uncommon**.
- Association with **unerupted teeth** may be seen.
- Odontoma can also be associated with other odontogenic tumors.

Differential diagnosis : include Supernumerary Tooth, Ameloblastic Fibro-odontoma, and Osteoma.

- Radiographic appearance of odontoma, the radiolucent zone at the periphery, which represents the dental follicle along with the radiodensity of the mass.

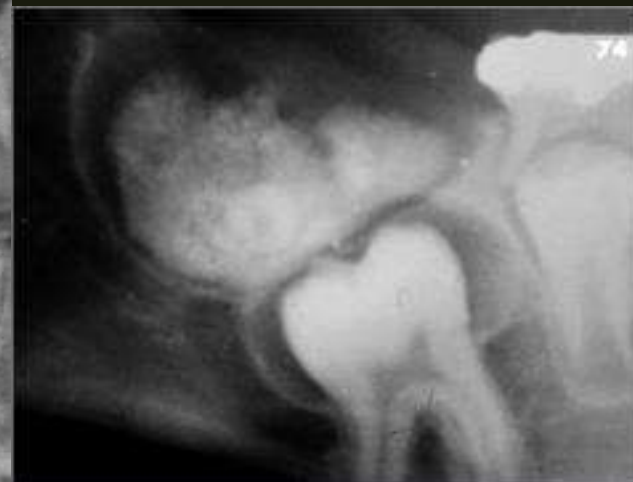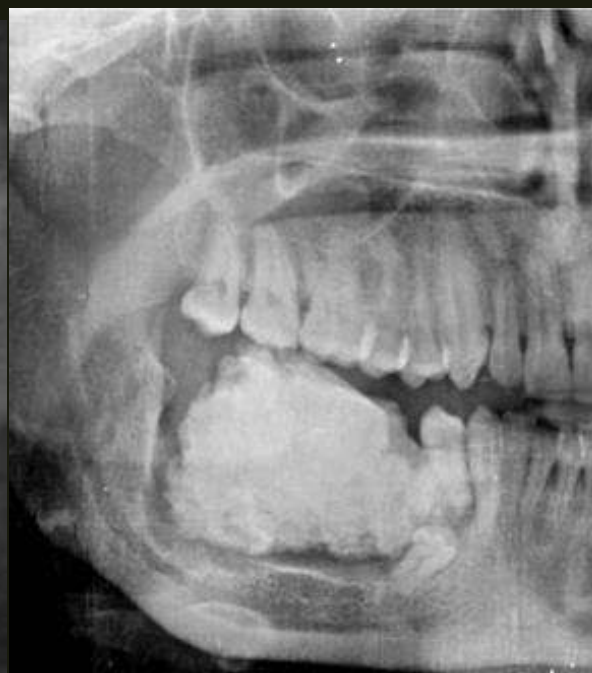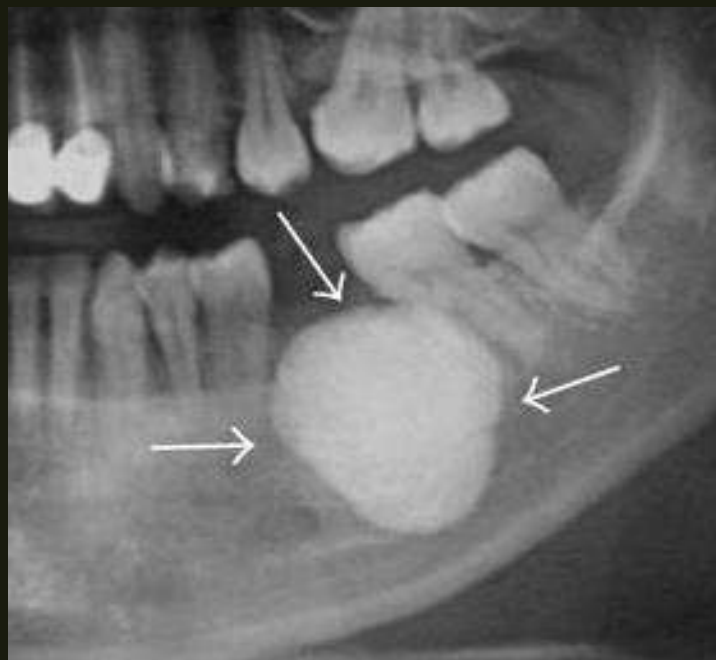
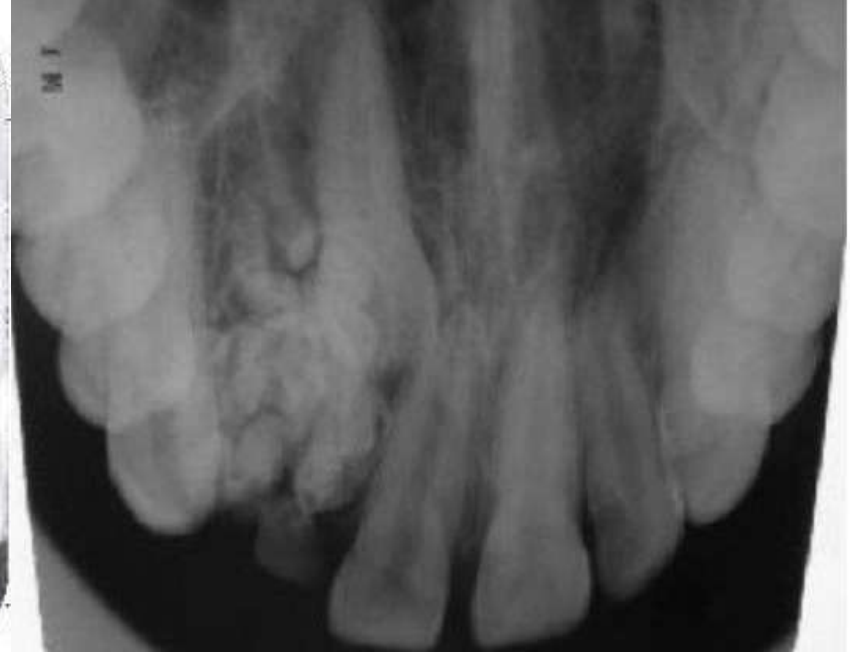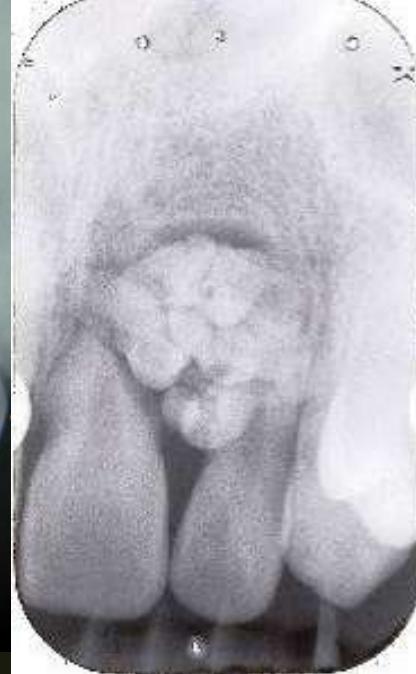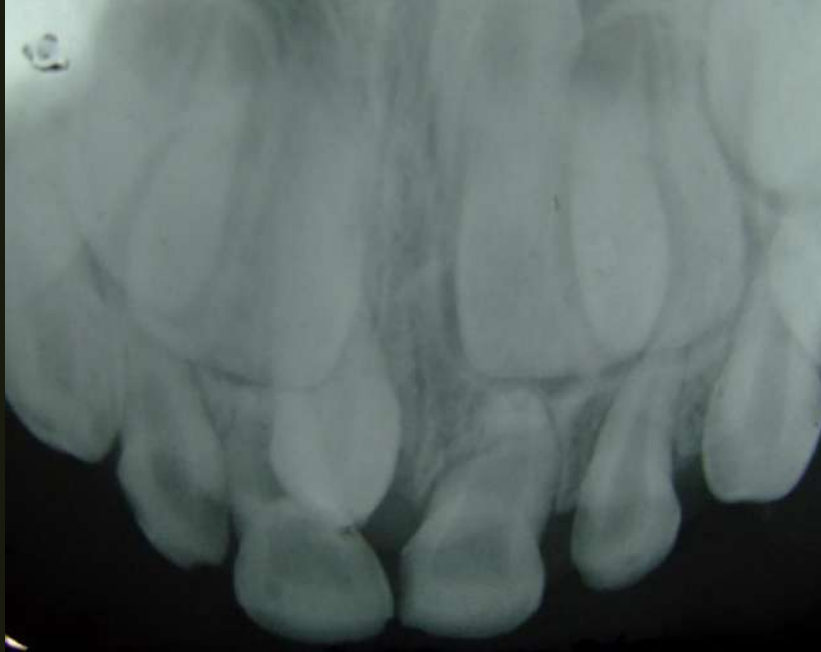Differentiated from

- Supernumerary tooth - number of tooth-like structures.
- Ameloblastic fibro-odontoma, the radiopacity is scattered.
- Osteoma, diffused radio-opacity



Management : managed with conservative surgery.

- The prognosis of the condition is usually excellent without recurrence.



Supernumerary vs compound

Osteoma vs complex

Ameloblastoma

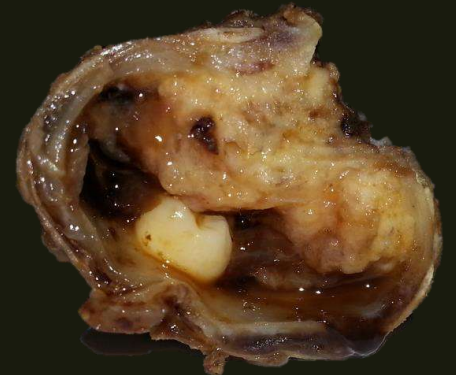
- Ameloblastomas are the **second most common benign** odontogenic tumor.
- They are **potentially aggressive, locally invasive, slow-growing benign tumors** that may originate from cell rests of dental lamina, epithelium from the enamel organ, epithelial lining of odontogenic cyst (ie, dentigerous cyst), and basal cell layer of oral mucosa.
- Based on clinical, radiologic, histologic, and prognosis aspects, classified as
 - (1) Conventional - Solid/Multicystic.
 - (2) Unicystic (Luminal, Intraluminal, Mural)
 - (3) Peripheral (Extra-osseous)
 - (4) Desmoplastic
 - (5) Malignant.
- **Histopathologic examination is mandatory** for confirmation of diagnosis.
- Managed by wide surgical resection, with expected recurrence.

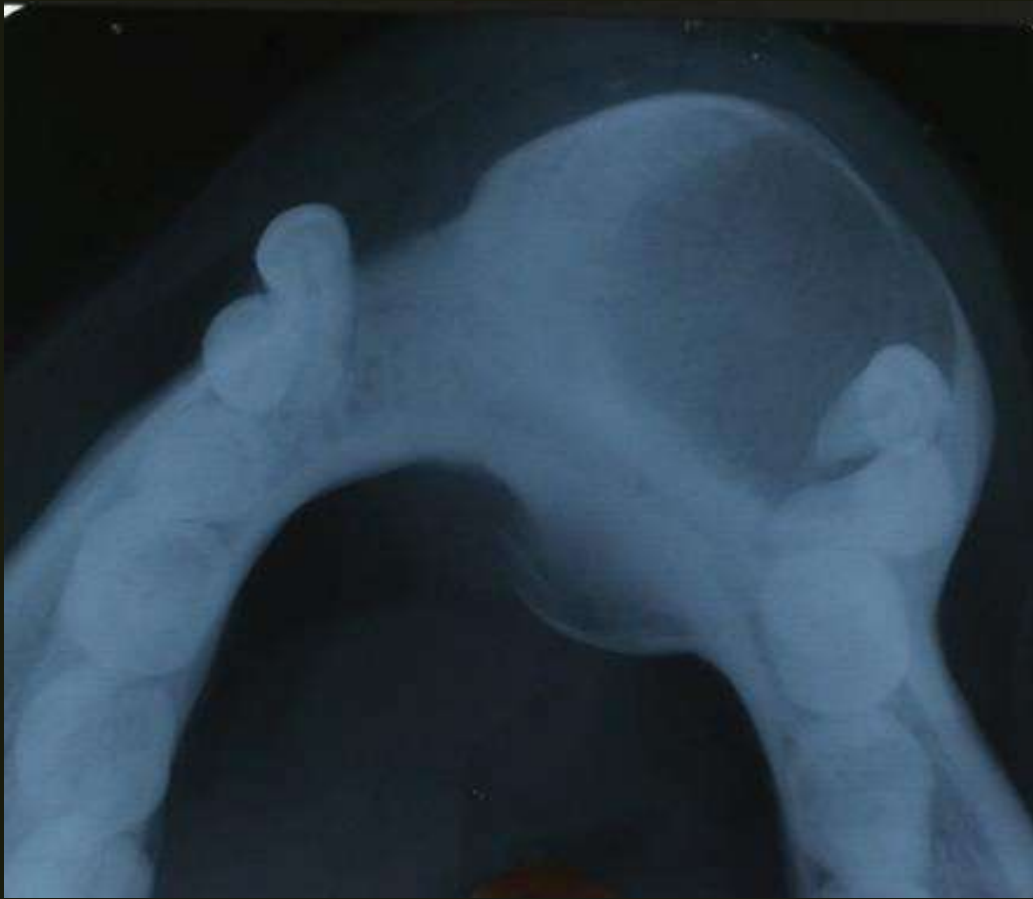Clinical Features

- The mandible is the favored site. Commonly posterior mandible (70% in angle of mandible).
- Asymptomatic and remains undiscovered until tumor growth produces (1) swelling, (2) malocclusion, or (3) incidental radiographic examination reveals a lesion.
- Paresthesia, pain and disfigurement is uncommon, may be seen as lesion advances in the size.
- The pain occurs due to pressure effects on nerves or due to secondary infection.
- Large mass can cause thinning of cortical plate, and crepitation or egg shell crackling occur while palpating jaw.

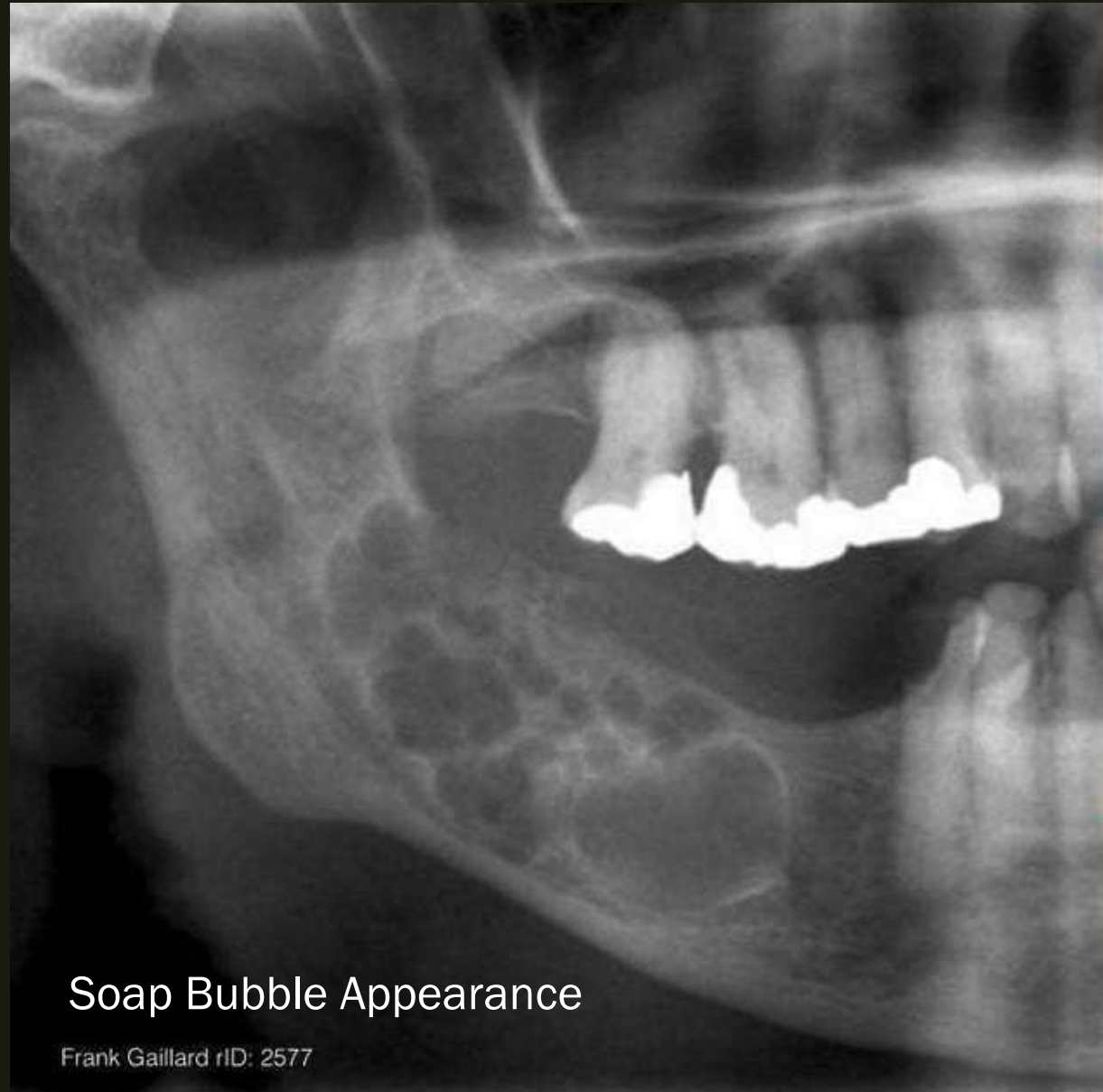Diagnostic Modalities

- The frequent presentation is solid, multicystic, which appears as multilocular radiolucent destruction of bone (appearance of **honeycomb or soap bubble appearance**).
- The destructive changes of the bone confined to alveolar bone or extend to mandible.
- Buccal and lingual **cortical plate expansions** are observed, well **recognized in occlusal film**.
- Resorption of adjacent roots of teeth is common.
- **Presence of unerupted tooth** is common and should be differentiated from dentigerous cyst.
- Unicystic ameloblastoma shows a **large unilocular radiolucent destruction**.





Unicystic Ameloblastoma
Cortical plate expansions
large unilocular radiolucent destruction

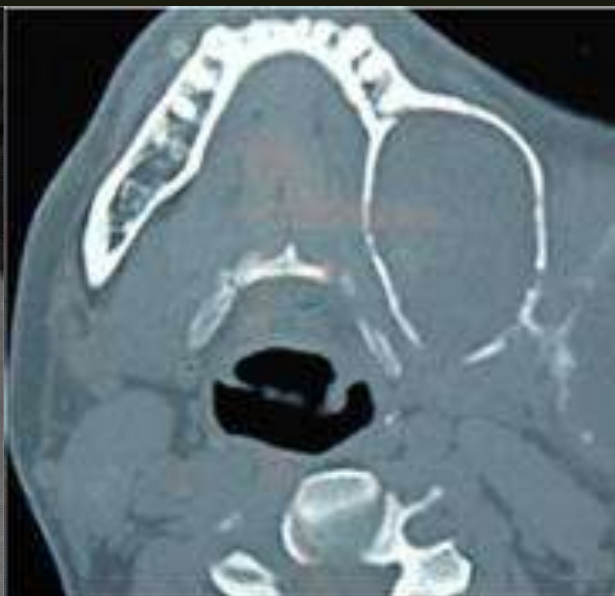
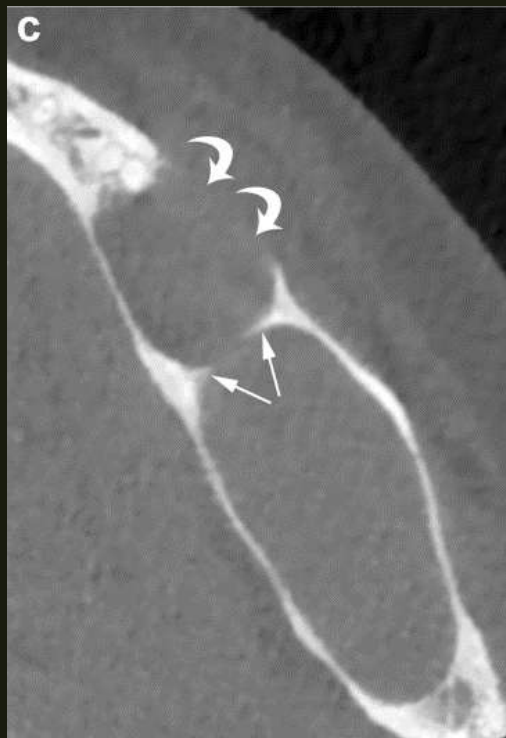

Soap Bubble Appearance

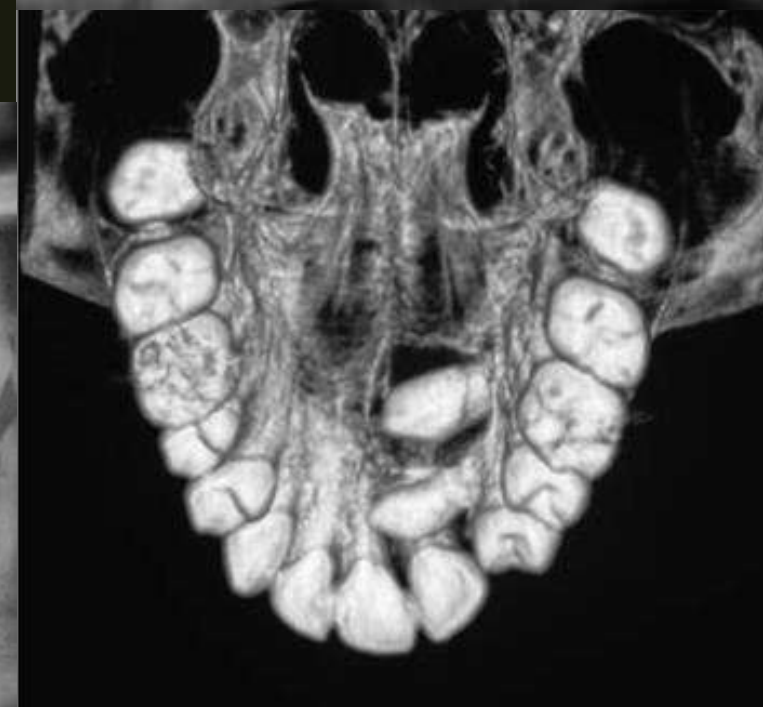
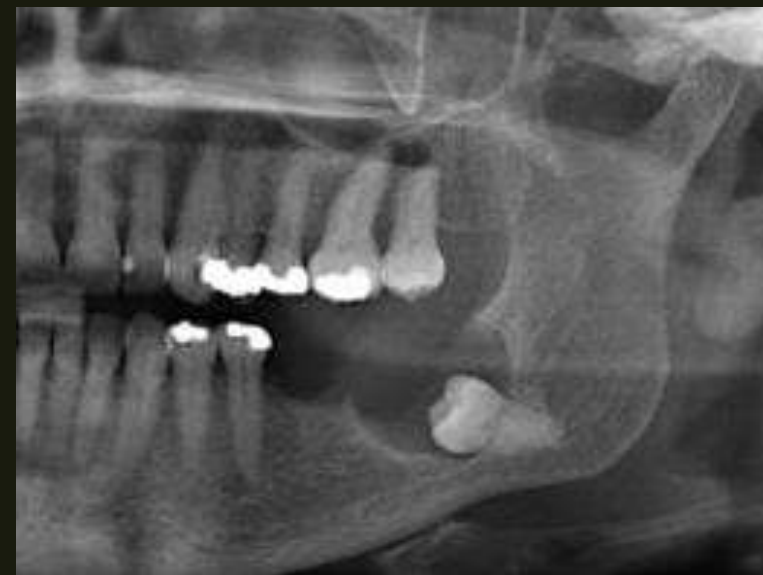Frank Gaillard rID: 2577

Differential diagnosis : looking for size, location, and presence/absence of mineralization.

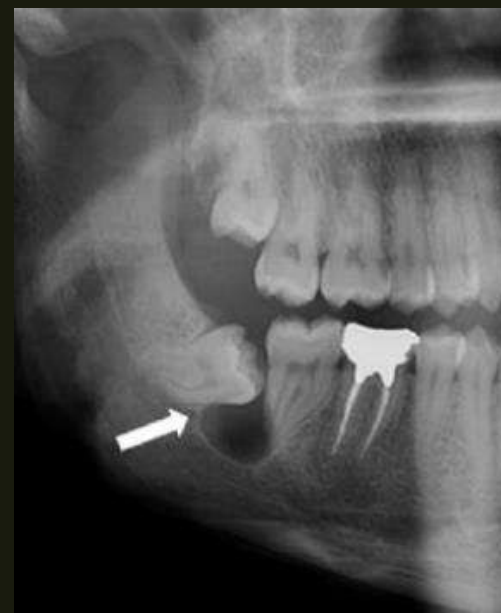- Differential diagnosis of uni-/multilocular radiolucency without mineralization includes odontogenic keratocyst, central giant cell granuloma, and dentigerous cyst.
- Differential diagnosis of uni-/ multilocular radiolucency with mineralization includes odontogenic myxoma, calcifying odontogenic cyst, and calcifying epithelial odontogenic tumor.
- Central **giant cell granuloma common in anterior mandible**, whereas ameloblastomas in posterior region.
- **Keratocyst expand antero-posteriorly**, whereas ameloblastomas expand bucco-lingually.
- **Dentigerous cyst show peri-coronal radiolucency**, whereas ameloblastomas with impacted tooth, not necessarily with pericoronal radiolucency.



Keratocyst vs ameloblastomas

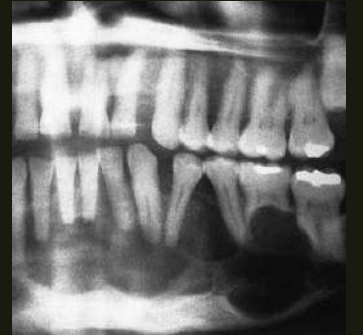


Dentigerous cyst vs ameloblastomas



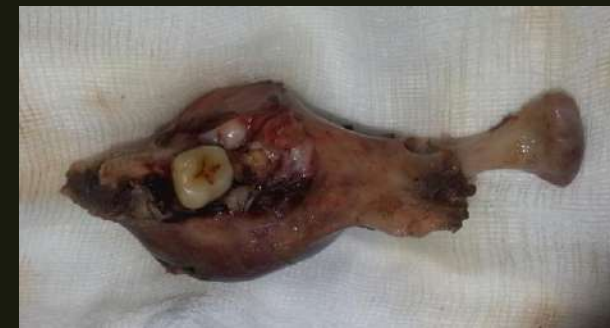Unicystic Ameloblastoma :

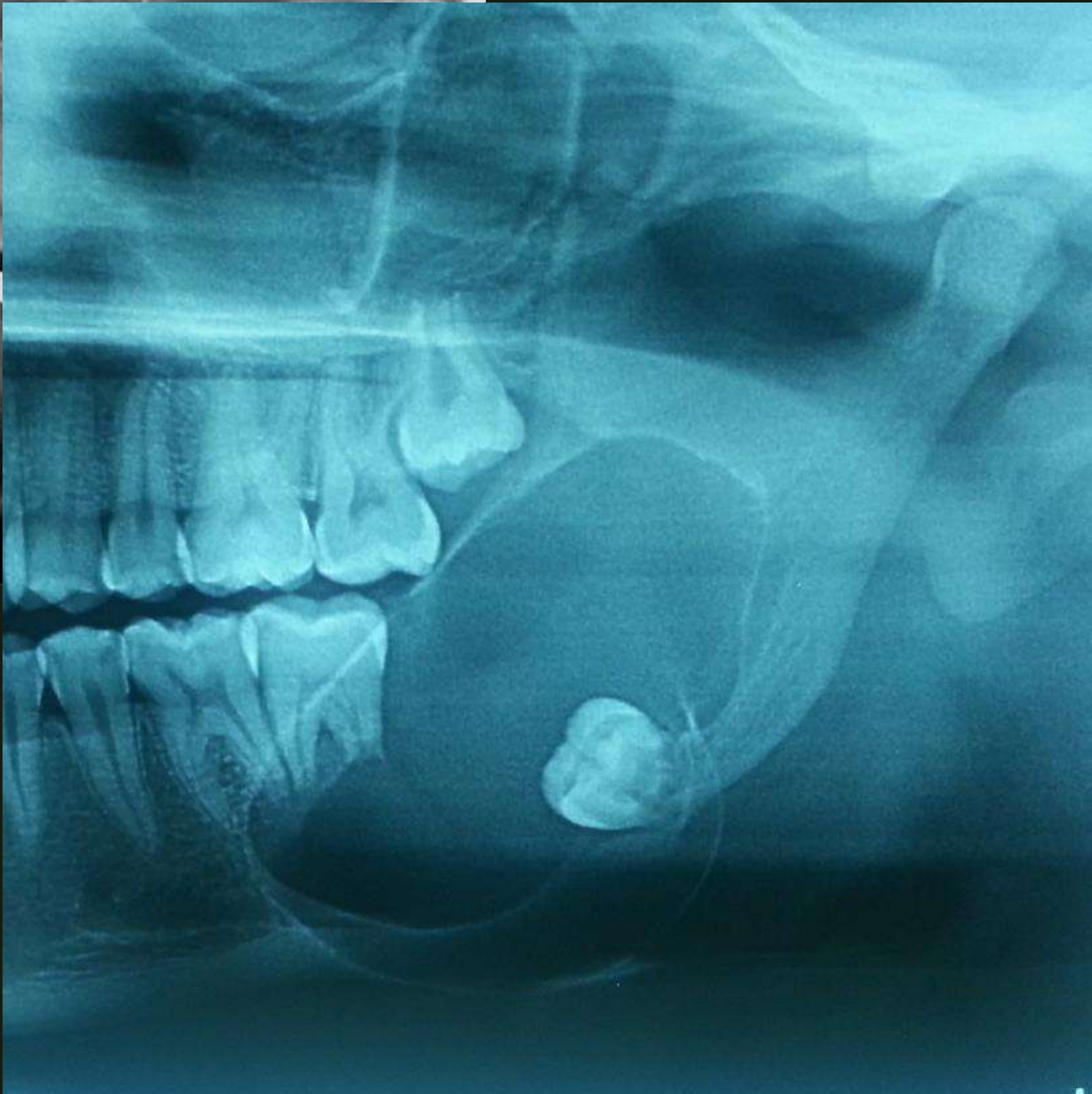
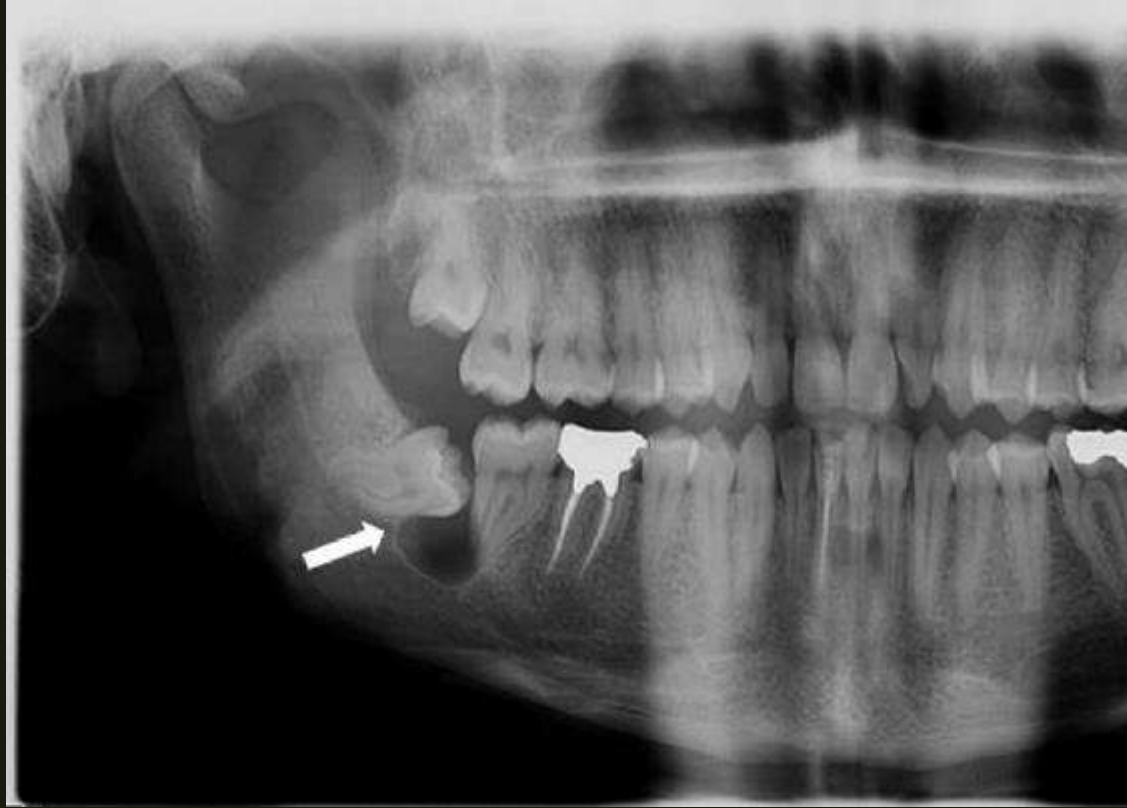
- May form primarily or develop secondarily in keratocyst or dentigerous cyst.
- Have good prognosis and lower recurrence rate (except mural type)
- The lesion may remain small, become large, or even develop into a multicystic form.
- Unicystic lesions may misdiagnosed radiographically as a dentigerous cyst or keratocyst.
- Radiologic feature is the partial resorption of roots, rarely occur in dentigerous or keratocyst.



Management of luminal or intraluminal is usually enucleation, whereas mural subtypes are managed by resection with a 1.5cm margin.

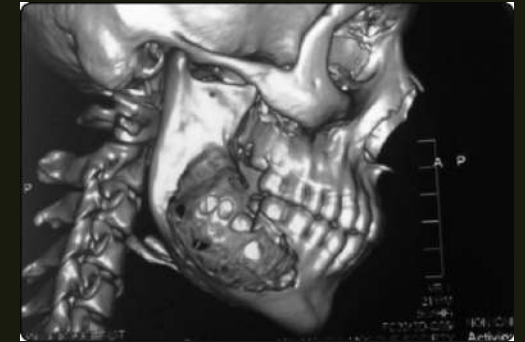- Curettage of the bone is insignificant because it may implant foci of ameloblastoma more deeply into bone.





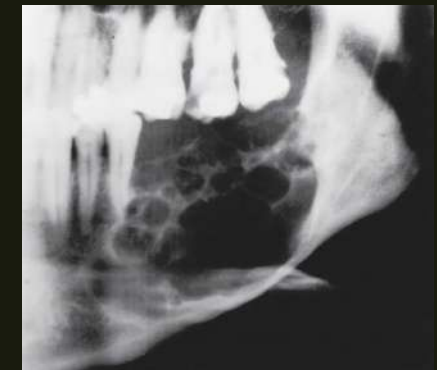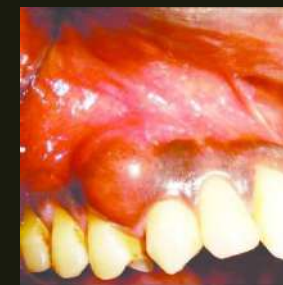Conventional (Solid and Multicystic) Ameloblastomas

- These are **the most common type**. They are usually radiolucent on radiography (honeycomb or soap bubble appearance) and clinically are partially or completely solid. **Management is resection with a 1.5cm margin.**



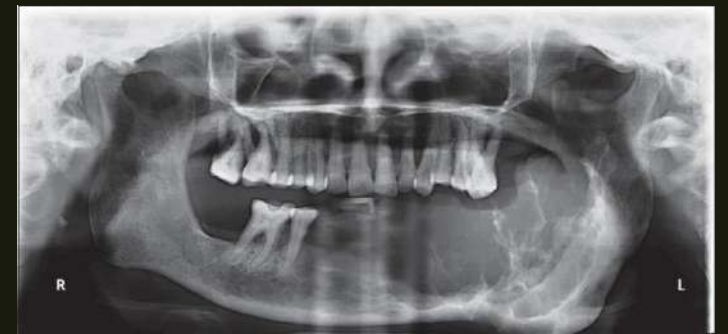Peripheral / Extra-osseous Ameloblastoma

- **These have a good prognosis**, arise from the gingiva rather than tooth
- Common in premolar area of mandible and tuberosity of the maxilla.
- A radiograph should be taken to **exclude a perforating intraosseous** ameloblastoma.
- **Management is conservative excision. Long term follow is required.**

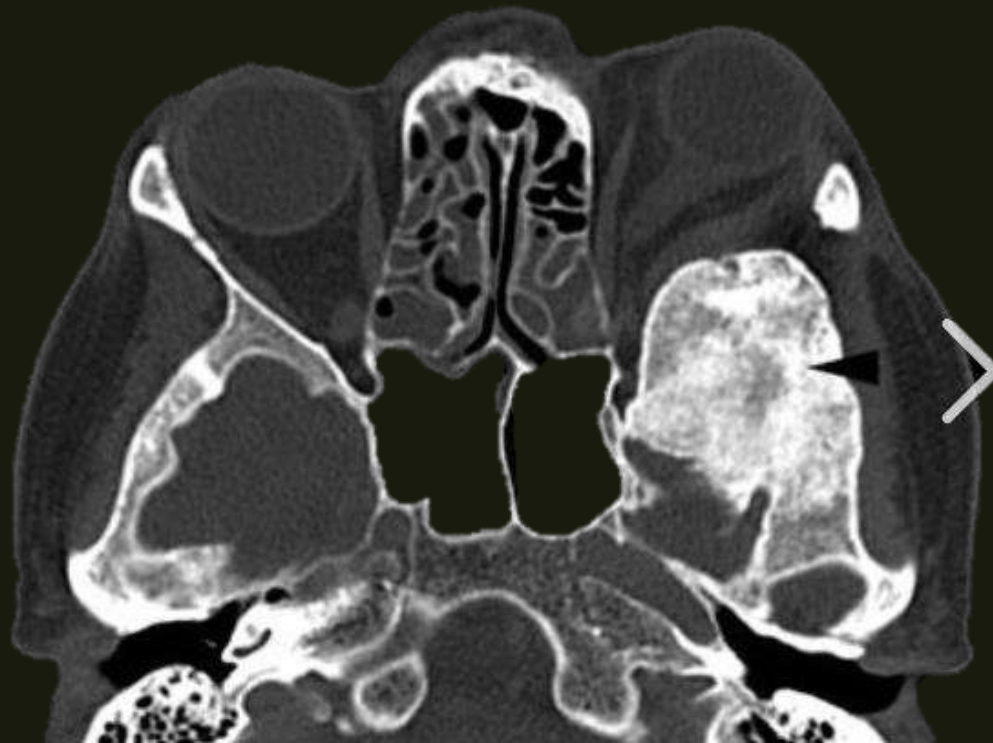

Malignant Ameloblastoma and Ameloblastic Carcinoma

- Ameloblastoma sometimes exhibit **behavior of metastases** that are most often found in the lungs.
- The diagnosis of malignant ameloblastoma should be made when a tumor in both primary and metastatic locations demonstrate histopathologic features of ameloblastoma.
- if surgically feasible, wide resection of both lesions.
- Radiation and chemotherapy are questionable for adjunctive treatment and should be reserved for palliation.



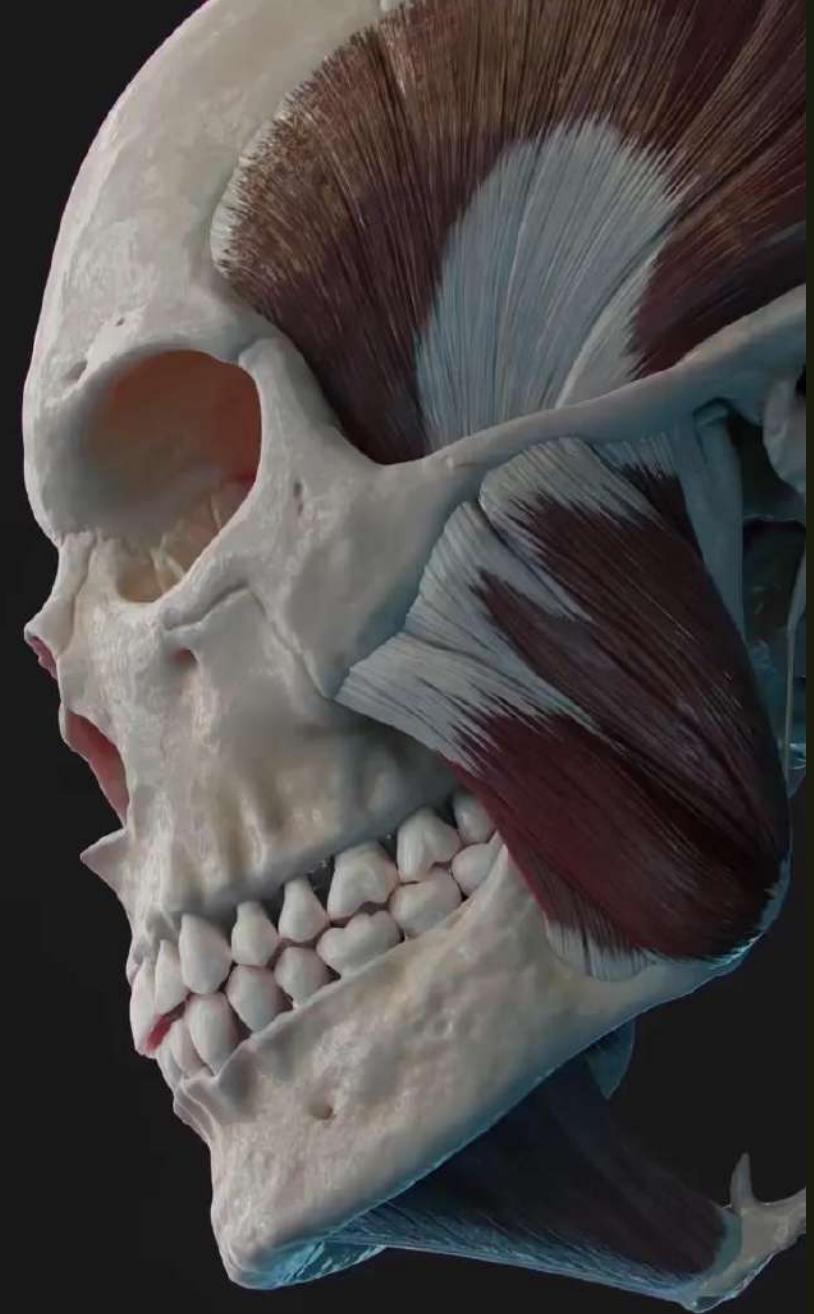
Non – Odontogenic Tumors



Bashar Abdul-Ghani

FICMS. MAXFACS Cons. MFDS. RCSED. RCPS (Glasg).

Lecture Quoted From Baghdad University Curriculum



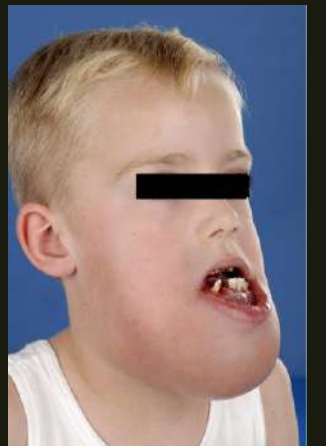Non- Odontogenic Tumors

Common in the pediatric jaws, including

- Giant cell lesions may be
 - Slowly growing, asymptomatic radiolucency discovered on routine radiographs
 - Rapidly expanding, aggressive tumors characterized by pain, root resorption, and a high recurrence rate.
- Fibro-osseous lesions: a group of benign conditions that are characterized by replacement of normal bone with fibrous connective tissue that gradually undergoes mineralization.
- Desmoplastic fibroma recognized as a benign bony neoplasm and as the intraosseous counterpart of soft tissue fibromatosis.

Giant Cell Lesions

- Central giant cell granuloma (CGCG) was first described by Jaffe in 1953 as a reparative granuloma to convey that it was not a neoplasm.
- Benign localized proliferation, non-neoplastic, osteolytic and sometimes aggressive and destructive, consisting of fibrous tissue containing giant cells.
- Multiple names such as central giant cell granuloma, giant cell lesion, giant cell tumor, or giant cell reparative granuloma have added to the complexity and confusion of this lesion.

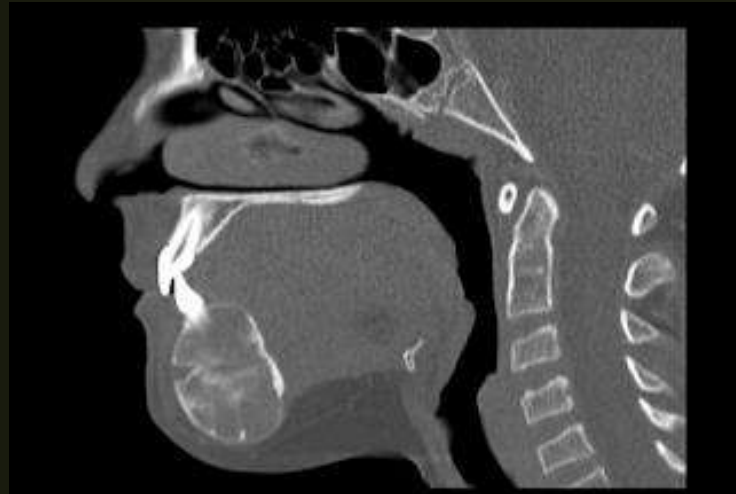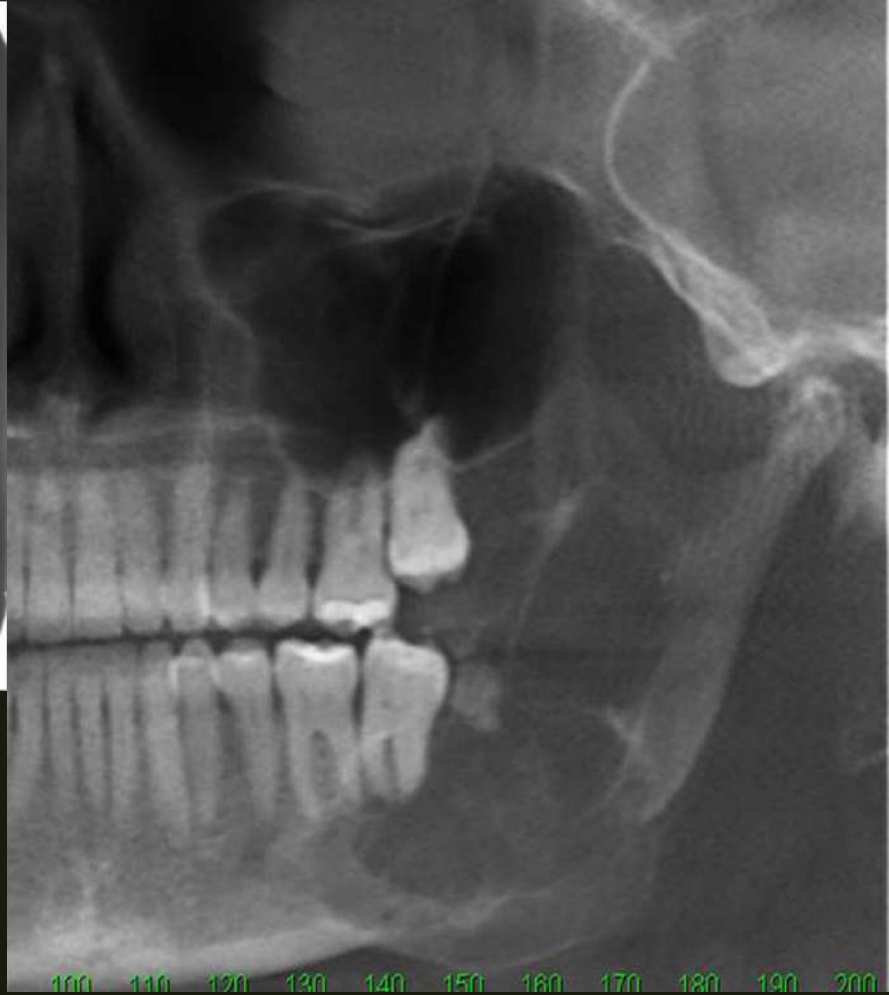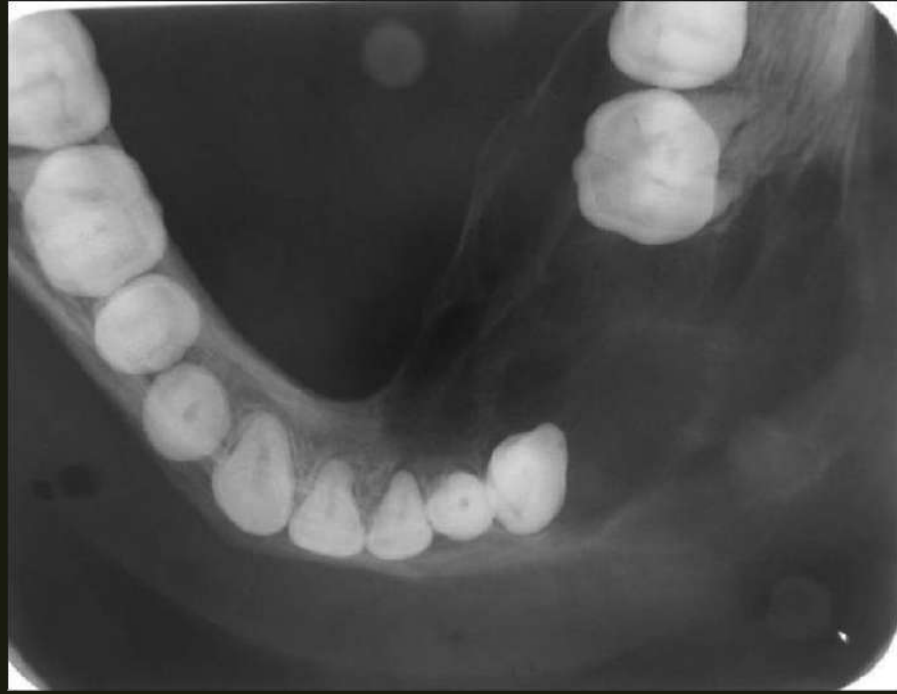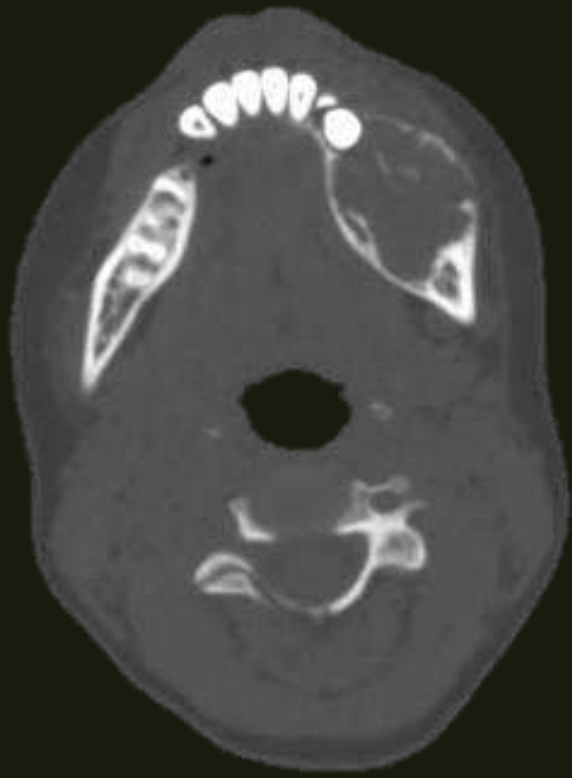


Clinical Findings


- Predilection for women
- Occurrence in the first 3 decades of life
- Mandible more than maxilla
- Most often anterior to the first molar
- Most often a solitary lesion
- Asymptomatic, but can be associated with discomfort, pain, paresthesia
- Teeth can be displaced or non-vital
- Maxillary lesions with nasal obstruction or epistaxis


Imaging

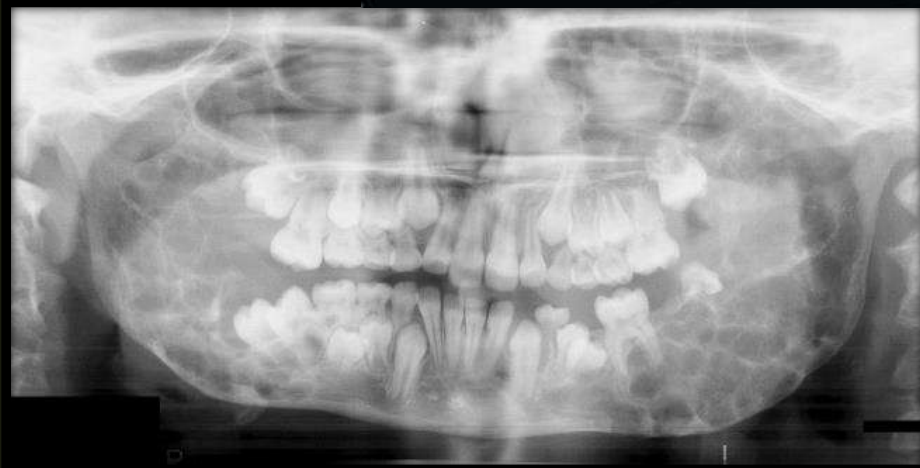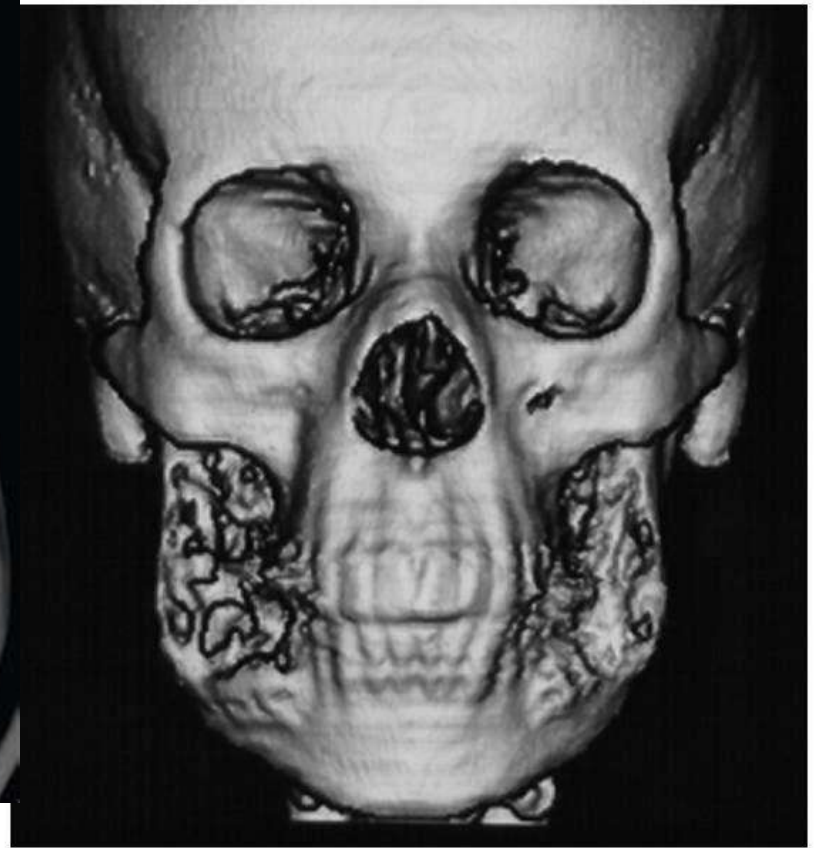
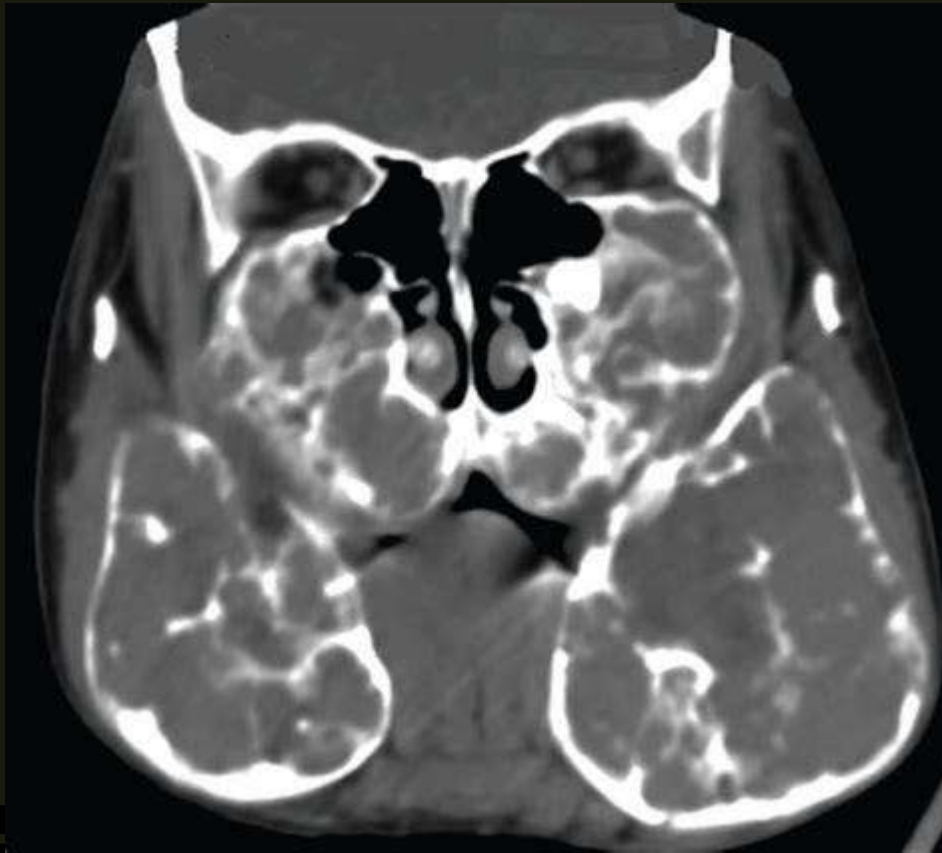
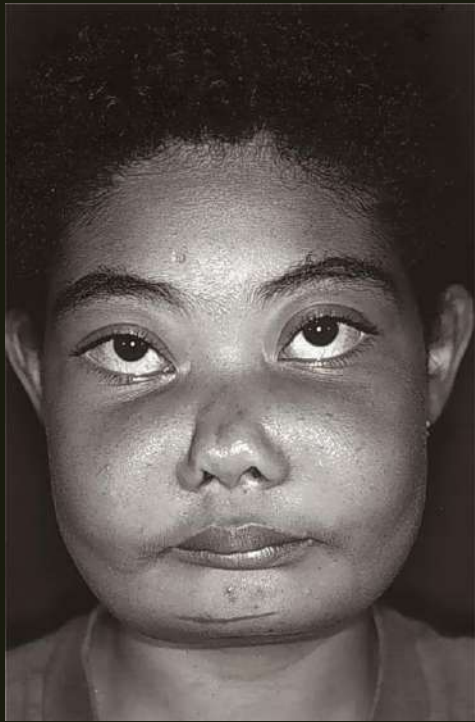- Mixed radiolucent/radioopaque and multilocular.
- Loss of lamina dura
- Root Resorption in aggressive lesions
- Displacement of teeth
- Smooth or scalloped margins
- Ill-defined or corticated
- Can cross the midline
- Contains numerous thin septa of wispy bone and osteoid



Differential Diagnosis : Several other lesions can resemble a giant cell lesion microscopically

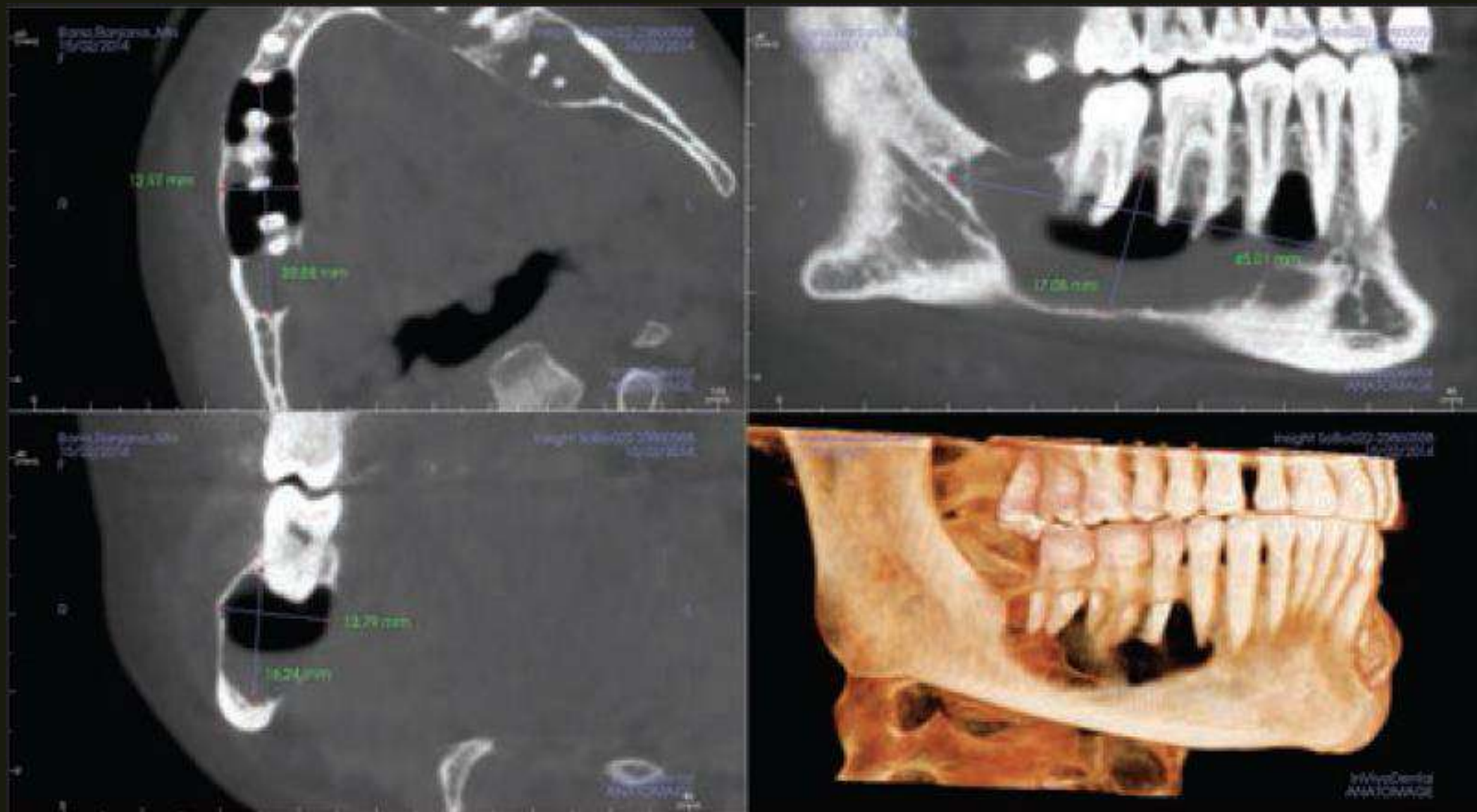
- ❖ **Brown tumor of hyperparathyroidism** - It is histologically same as CGCG, associated with **hyperparathyroidism** which result in bone resorption.
- ❖ **Cherubism** - This is same as CGCG; the lesions are **symmetric** and occur near the angles of the mandible. It is an autosomal dominant familial disease.


Occur in early childhood, as early as 14 months. **Regress with aging** and bone growth stop.
- ❖ **Aneurysmal bone cysts** - blood-filled benign (non-cancerous) rare **bone tumor**, presents in patients less than 20 years, **Diagnosis is made with radiographs** showing an expansile, eccentric, and lytic lesion with bony septa

- ❖ **Fibrous dysplasia** - On histologic examination they have limited foci of giant cells. They can also appear similarly on radiographs during the early stages.



Cherubism

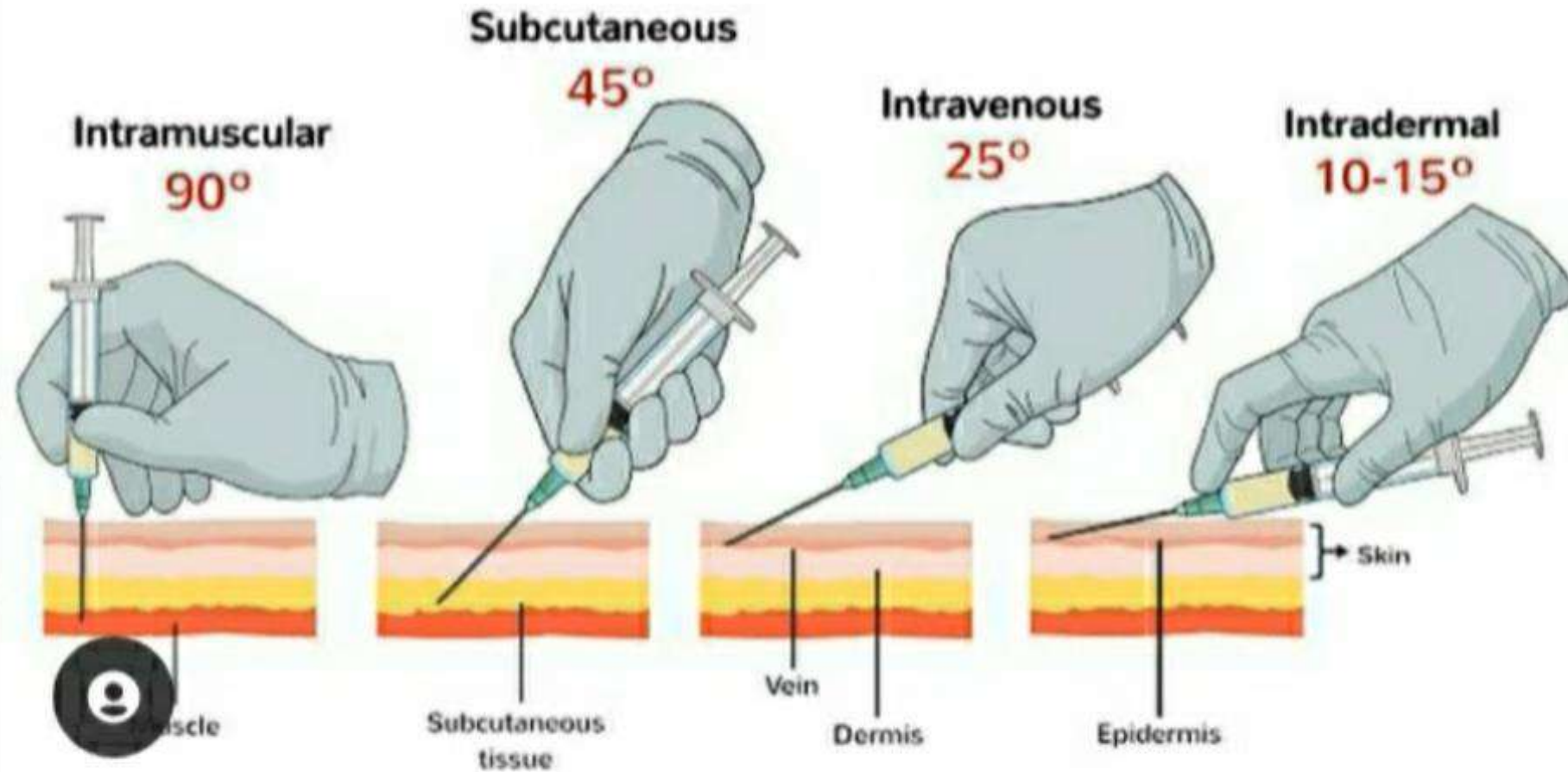
Aneurysmal Bone Cysts



Treatment

- Clinicians must take into account the behavior of the lesions.
- Non-aggressive CGCG respond to enucleation and curettage without other therapies such as steroids or calcitonin. Recurrence for these lesions is low.
- Aggressive CGCG resected with a 1.0-cm histologically clear margin. Postoperative adjuncts such as bisphosphonates, intralesional steroid injection, calcitonin therapy, or systemic interferon alfa therapy have all been reported with various levels of success.
- Brown Tumor of Hyperparathyroidism can be treated by curettage but usually regresses once the endocrine abnormality has resolved.

Injection technique



Fibro Osseous Lesions (FOLs)

- These lesions are fibrous dysplasia (FD), ossifying fibroma (OF), and osseous dysplasia.
- A group of benign conditions that are characterized by replacement of normal bone with fibrous connective tissue that gradually undergoes mineralization.
- The name given to this group presents a process rather than a diagnosis.
- The subtypes are similar microscopically, but has different clinical and radiological presentations.
- They show a wide range of biological behavior from dysplasia to benign neoplasia.
- Radiologic examination is important because histopathology for all FOLs is similar.
- Furthermore, once diagnosed, the management of each is different.

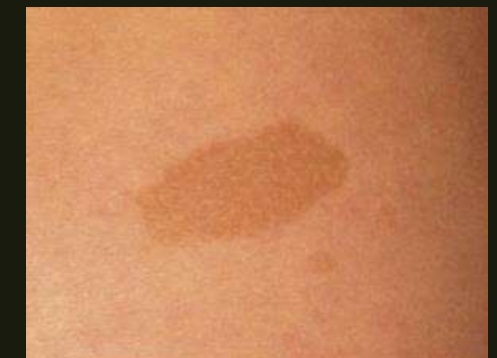
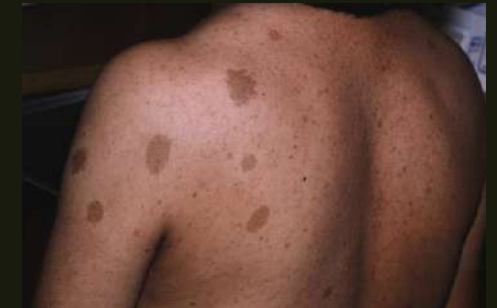Fibrous Dysplasia

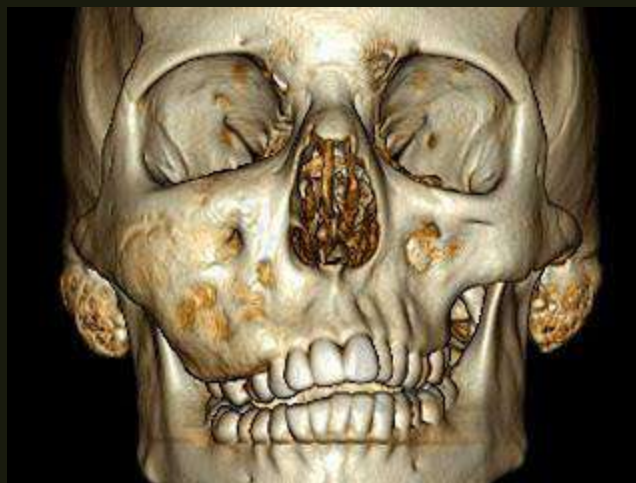
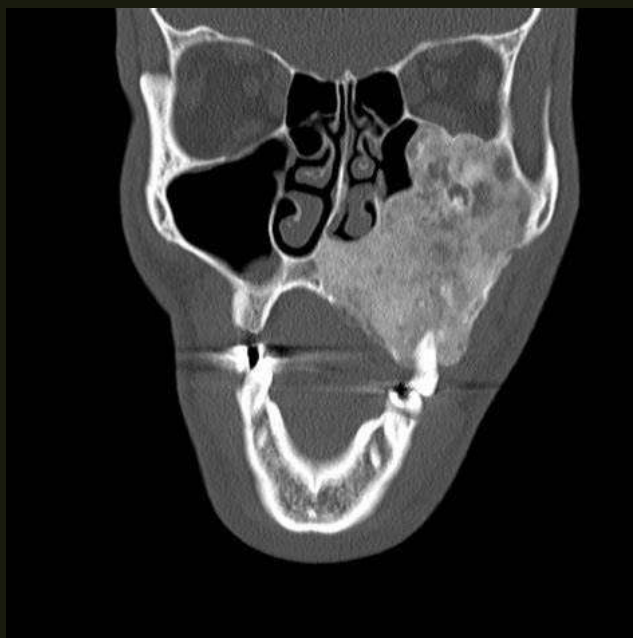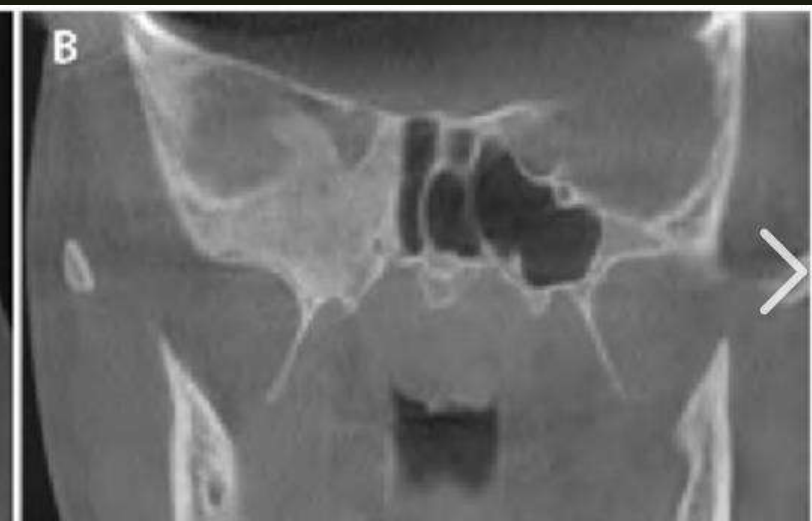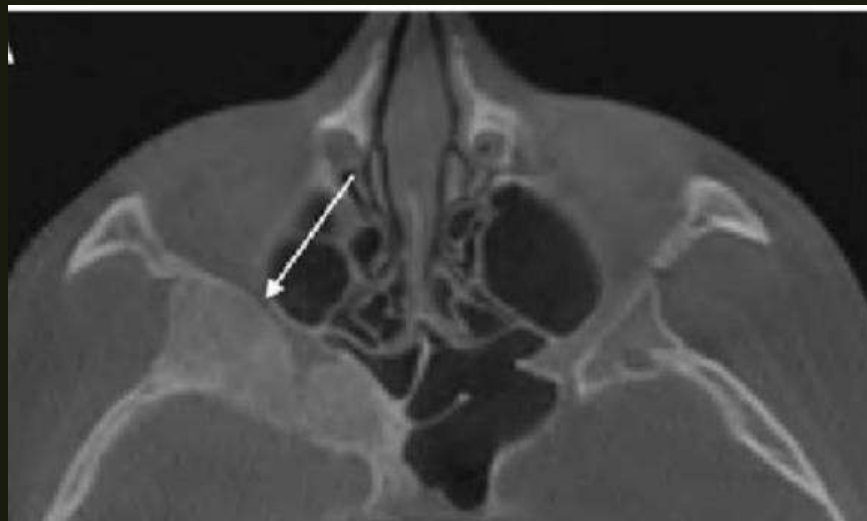
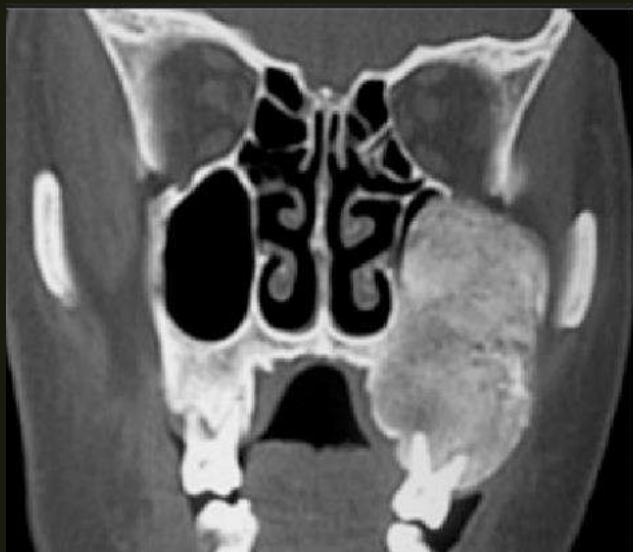Monostotic Fibrous Dysplasia

- Limited to one site, most common of FD types (80%).
- The jaws are the most commonly involved bone, in particular the maxilla.

Polyostotic Fibrous Dysplasia

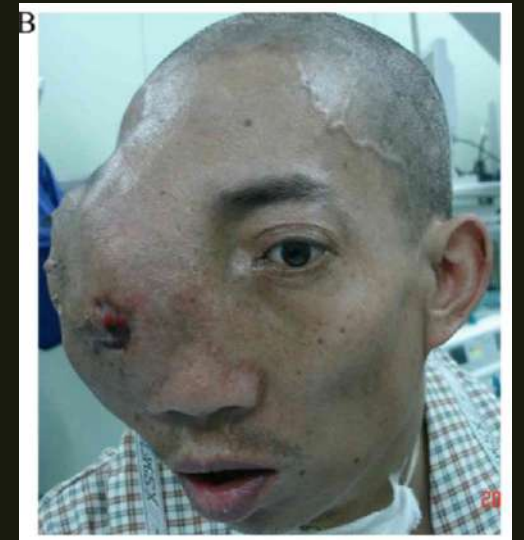- Two or more sites are involved. It can be considering syndromic if other abnormalities are found:
- Jaffe-Lichtenstein syndrome
 - Polyostotic FD with **Cafe´ au lait spots**
- McCune-Albright syndrome
 - Polyostotic FD, **Cafe´ au lait spots** and Multiple endocrinopathies.
- Mazabraud syndrome
 - Polyostotic FD and Intramuscular myxomas



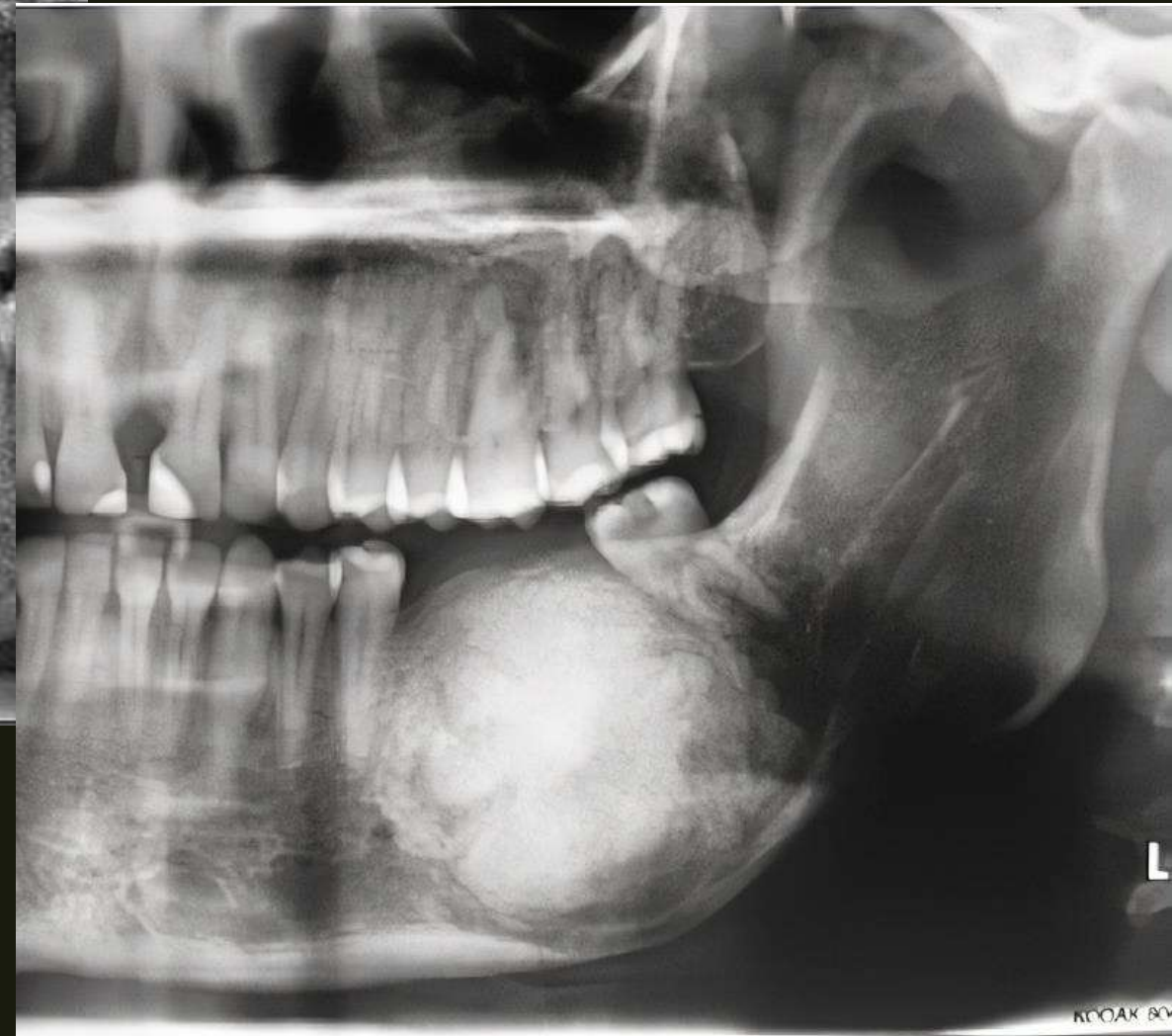
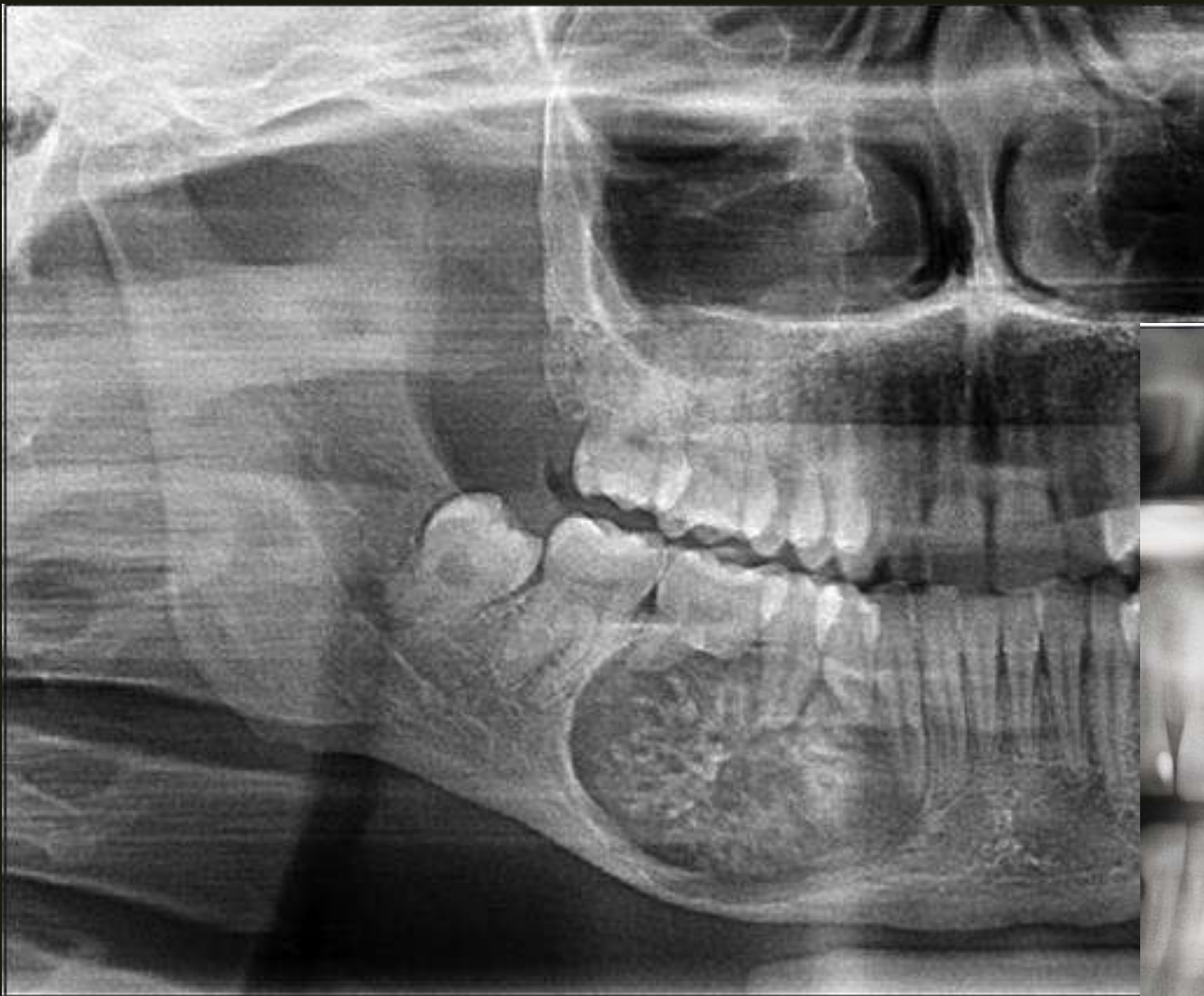

Ossifying Fibroma

- It is a true neoplasm. there are two forms based on Histology, Age and Clinical Behavior.
- Trabecular OF (children 8-12 years), occurs in the jaws, in particular the maxilla and
- Psammomatoid OF (adult 16-33 years), occur in the orbit, paranasal sinus, and calvaria.
- Radiographically both lesions are the same.



Psammomatoid OF

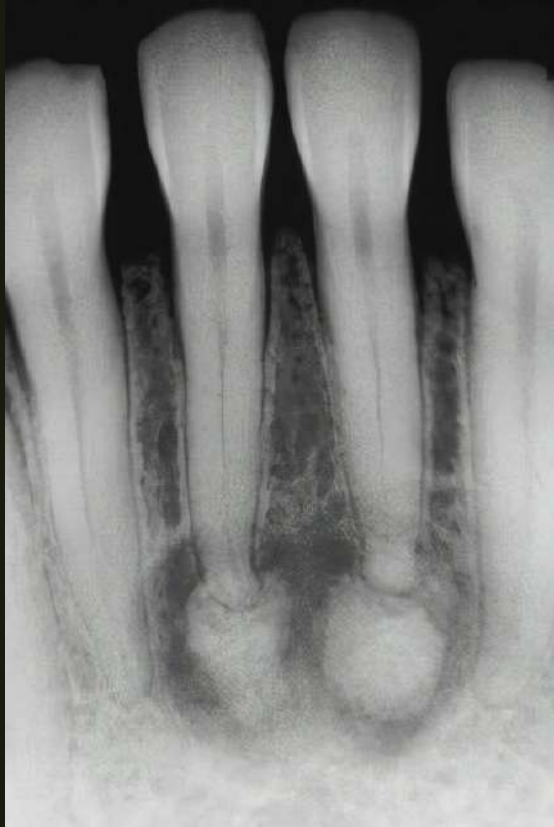

Osseous Dysplasia - Cemento-osseous Dysplasia

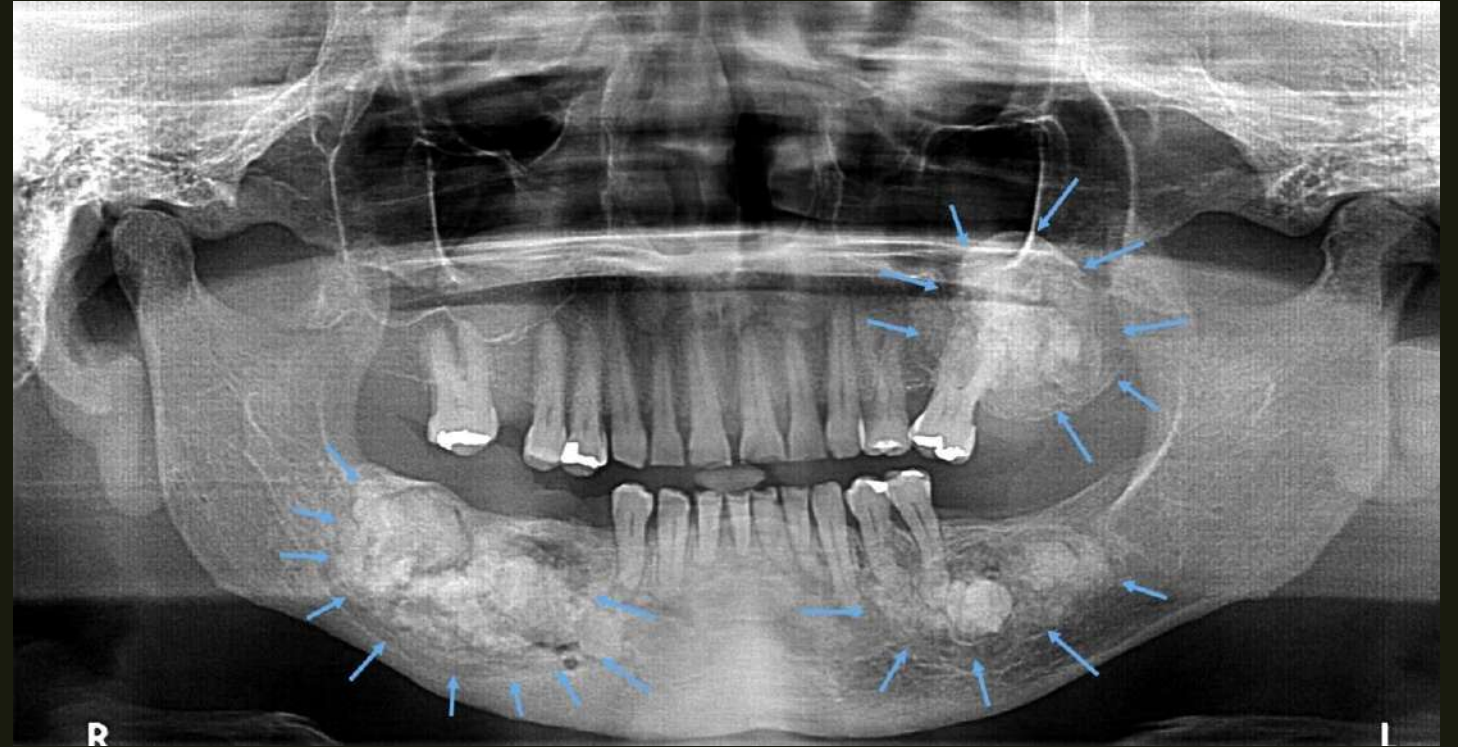
- Rare in the pediatric population.
- Subtypes are Focal, Periapical, or Florid cementoosseous dysplasia.

Clinical Findings

- These lesions are benign and non-inheritable.
- They are typically seen in the second and third decades
- Small lesions are discovered as incident findings on radiographs.
- Larger lesions presents as painless swelling of the involved bone.
- There is usually a resultant facial asymmetry, which is striking in some cases.



Peri-apical Cementoosseous Dysplasia.



Florid Cementoosseous Dysplasia.

Imaging of Fibro-osseous lesions (FOLs)

- The radiographic appearance is **the key to the diagnosis** and then the management.
- They typically have **varying degrees of radio-opacity based on their maturity.**

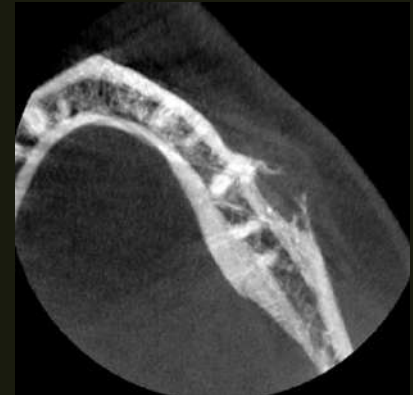- **FD:**
 - **Ground-glass appearance**
 - *Expansion of buccal and lingual cortices*
 - *Displacement of the inferior alveolar canal*
 - *Ill-defined lamina dura*
 - **Not well demarcated from adjacent tissue**
 - *Radiolucent or mixed*
- **Ossifying Fibroma**
 - **Well demarcated**
 - *Unilocular with sclerotic border*
 - *Can be radiolucent or radio-opaque*
 - *Root resorption or divergence possible*
- **Osseous Dysplasia**
 - *Mixed radiolucent/radiopaque*
 - **Well defined with irregular borders**
 - *Usually associated with dentition*

Treatment - depends on their diagnosis.

- The histopathology is often limited in aiding the diagnostic dilemma.
- For FD, **recontouring or shaving** after skeletal maturity when the growth of bones tends to stabilize.
- The deformity, psychological issues, and function problems, all drive the surgical intervention.
- For the polyostotic variant, treatment with intravenous pamidronate and oral alendronate have shown success, especially in **pain relief and skeletal strength**.
- The treatment of **ossifying fibroma involves enucleation** of the tumor.
- If there is considerable bony destruction, **resection and bone grafting** are warranted.
- The **prognosis is good** and the rate of recurrence is slow.

Desmoplastic Fibroma

- **Benign Bony Neoplasm** and as the intraosseous counterpart of soft tissue fibromatosis.
- It has a **locally aggressive behavior and a high recurrence rate**, locally destructive and easily extends into soft tissue.
- It is rare, with an incidence of less than 1% of all bone tumors.
- This fibroma represents the **osseous manifestation of aggressive fibromatosis**.
- Typically seen in the **younger population** with an average age around 16 years.
- **Commonly seen in the mandible (22%)**, femur (15%), pelvic bones (13%), with the ascending ramus being the most common of the gnathic sites.
- **Painless swelling** with symptoms present as the tumor invades adjacent structures.

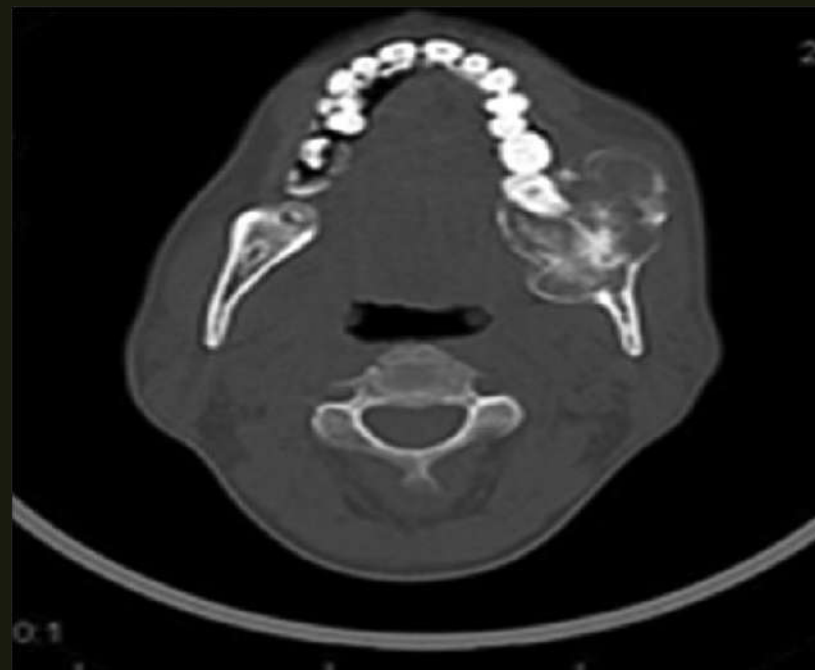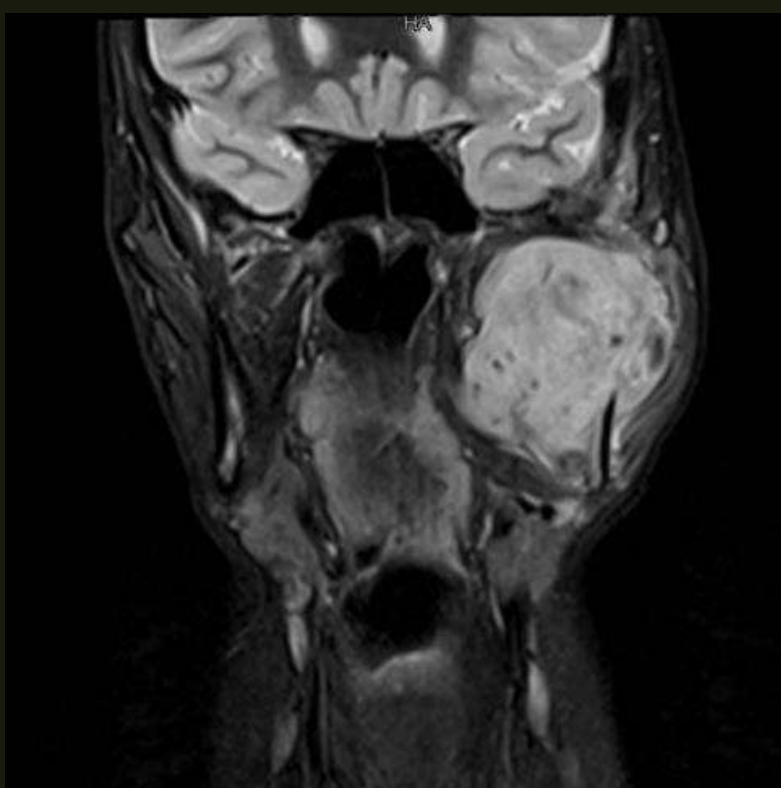


■ Physical Examination:

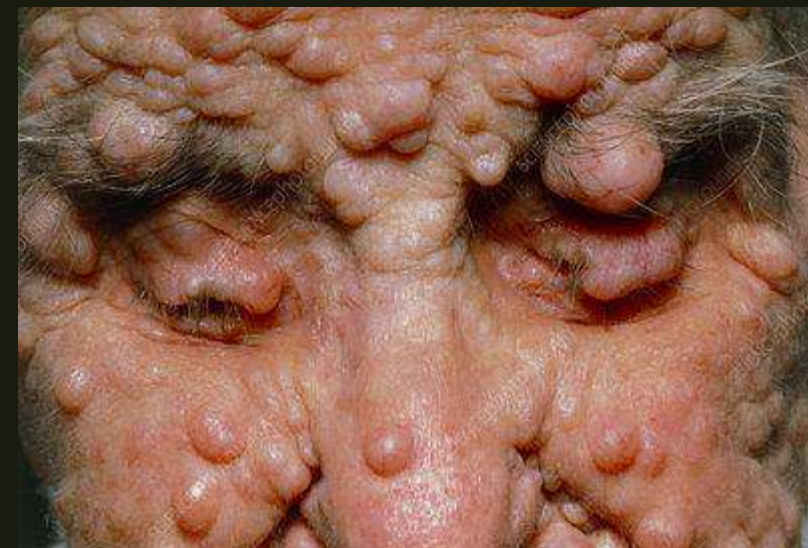
- Asymptomatic
- Pain
- Trismus with or without malocclusion
- Tooth mobility
- Dysesthesia
- Proptosis, elevated earlobe, infection.

Imaging

- They appear as a multilocular or unilocular, radiolucent area.
- There is **expansion and thinning of the cortices**
- the borders of the lesions can be well or ill defined.
- The adjacent teeth can show **displacement and root resorption**.
- This condition often **mimics other jaw disorders** like ameloblastoma, odontogenic myxoma, aneurysmal bone cyst, and central hemangioma.



Soft Tissue Fibromatosis

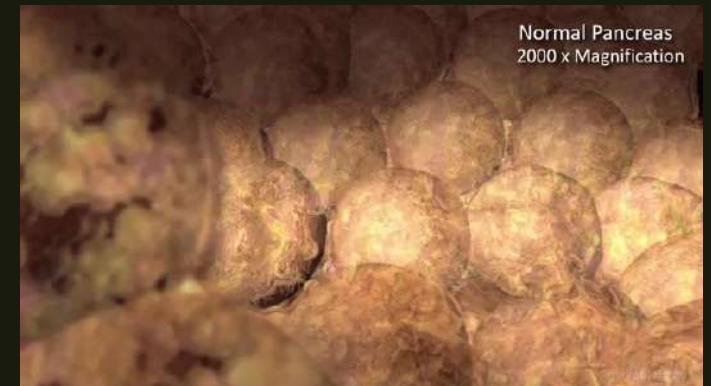

Pathology

- This tumor consists of abundant collagen fibers and fibroblasts.
- The degree of cellularity may vary in different regions of these lesions.
- At the periphery of the lesion, reactive bone can be seen and this can be confused with an FOL if biopsy size is inadequate.
- This tumor lacks abundant cellular pleomorphism, hyperchromatism, and mitotic figures.
- An increase in atypical cells can lead to a diagnosis of a malignancy, such as fibrosarcoma.

Diagnostic Challenge

- The challenge in differentiating it from a low-grade fibrosarcoma.
- This lesion has a similar clinical and radiographic appearance.
- Like desmoplastic fibroma, they are commonly seen in the pediatric population.
- On histology, increase in mitotic figure and pleomorphism.
- Treatment of fibrosarcoma is resection with wide margin, with 5-year survival ranging from 40%.



Treatment

- Even it is benign, **treated by resection of the lesion with margins**, because it is easily extends into soft tissue.
- Some clinicians have argued that treatment of desmoplastic fibroma, **confined within the bone, with curettage has a 70% recurrence rate**, whereas **resection with margins has shown recurrence rates around 20%**.
- Radiotherapy and chemotherapy have also been proposed, **with limited success and risk for malignant transformation**.
- For this reason, **patients need to be followed for several years**.

ORTHOGNATHIC SURGERY

Surgical Techniques



Bashar Abdul-Ghani

FICMS. MaxFacs Cons. MFDS. RCSED. RCPS (Glasg).

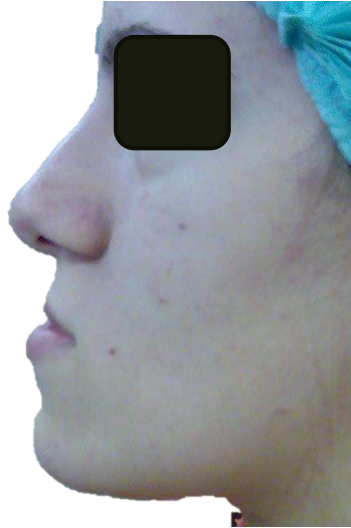SURGICAL TREATMENT PHASE - Mandibular Excess – Mand. Prognathism

Excess growth of the mandible results in Class III relationships and a reverse overjet.

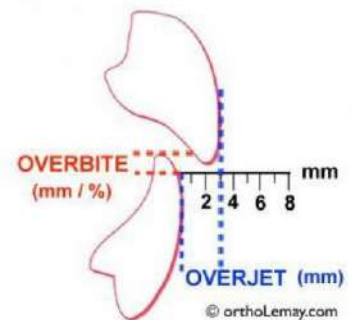
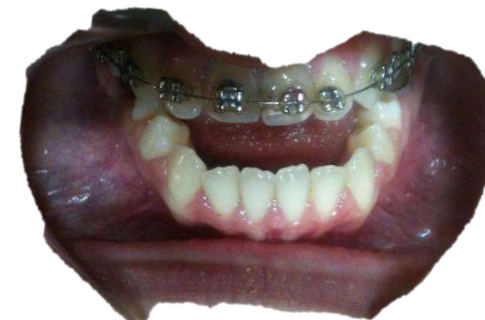Facial features include a prominence of

the lower third of the face

the area of the lower lip and chin



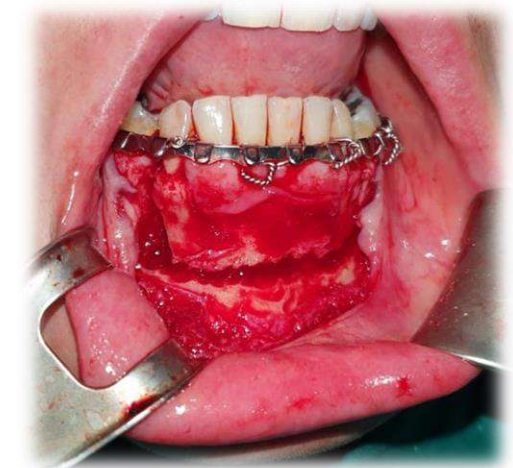
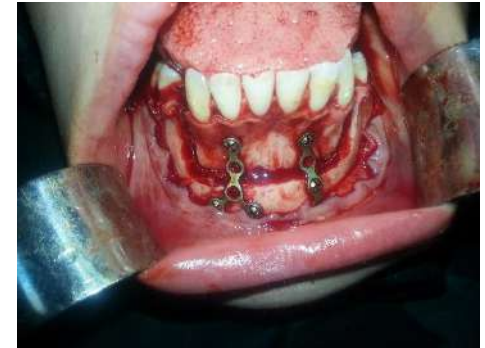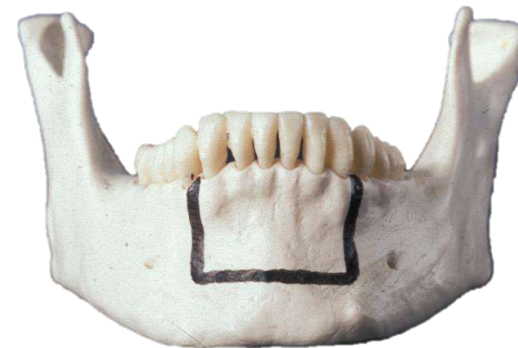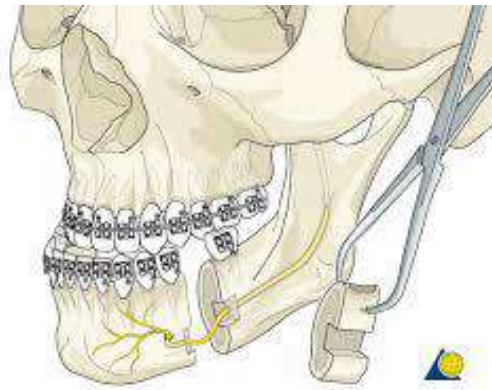
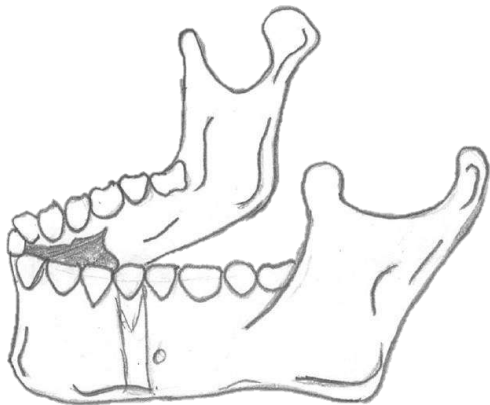
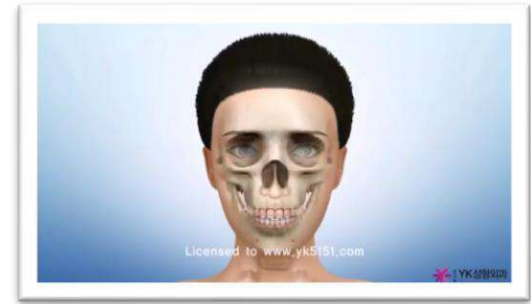In large reverse overjet - the patient unable to obtain adequate lip closure without abnormal strain of the orbicularis oris.

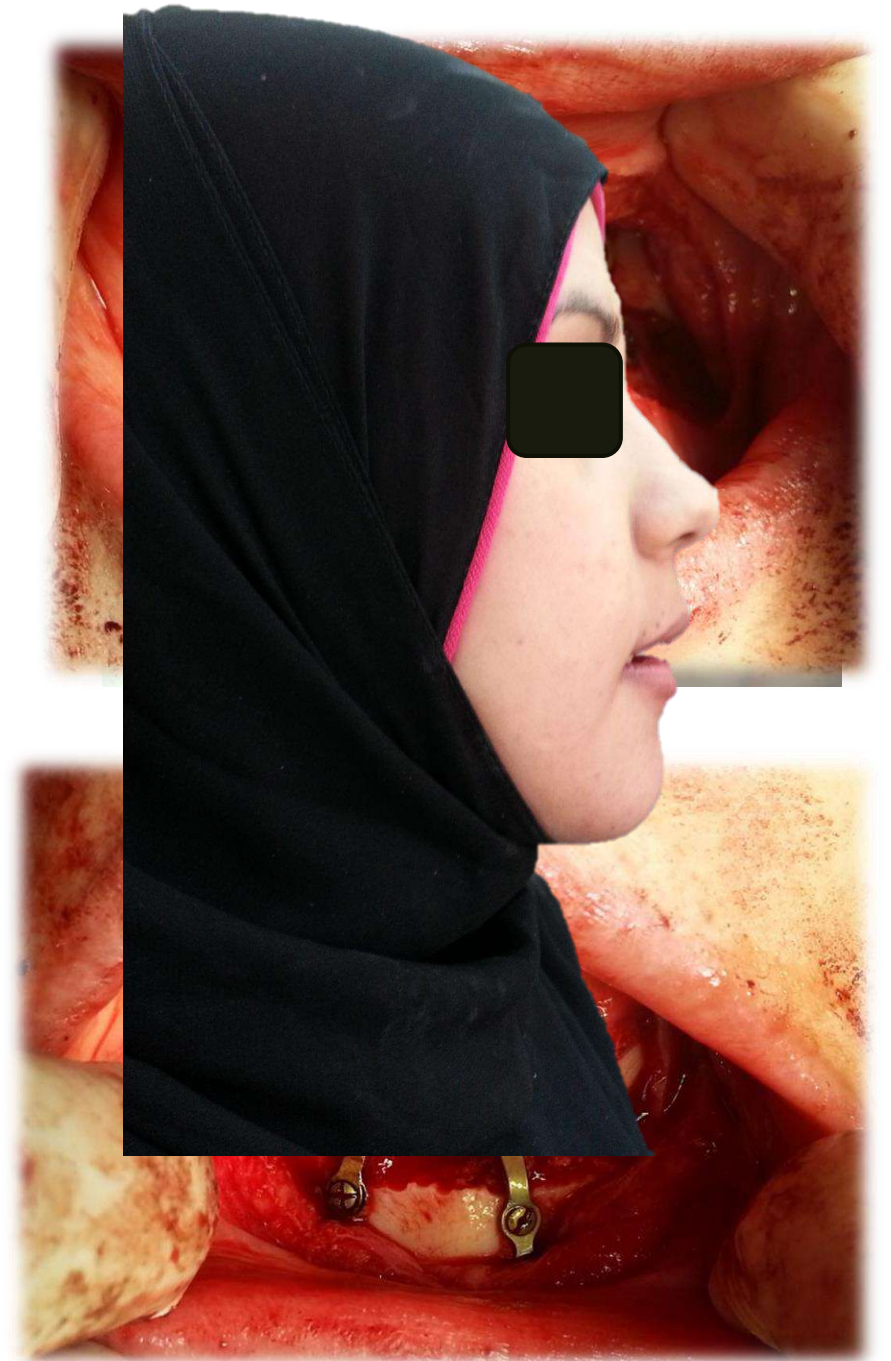
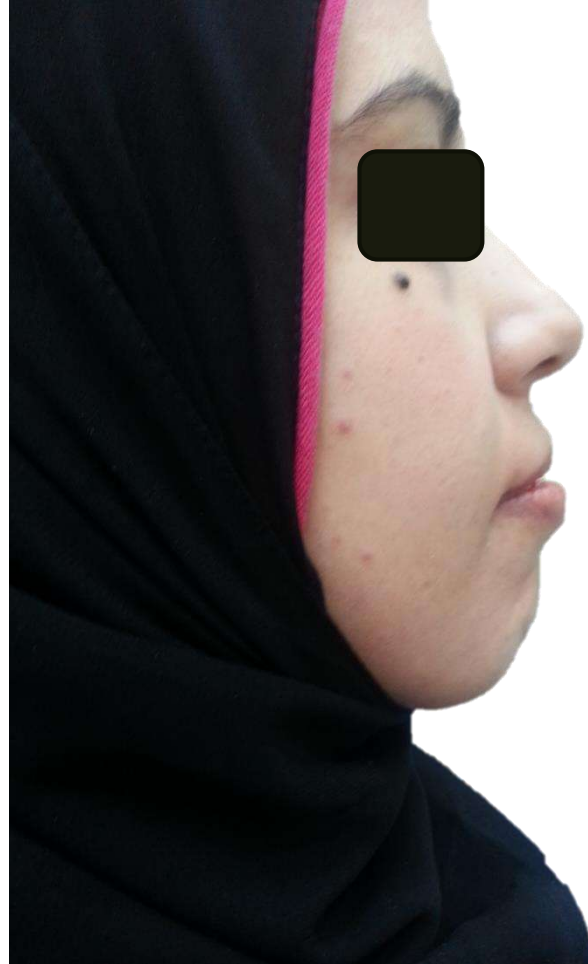


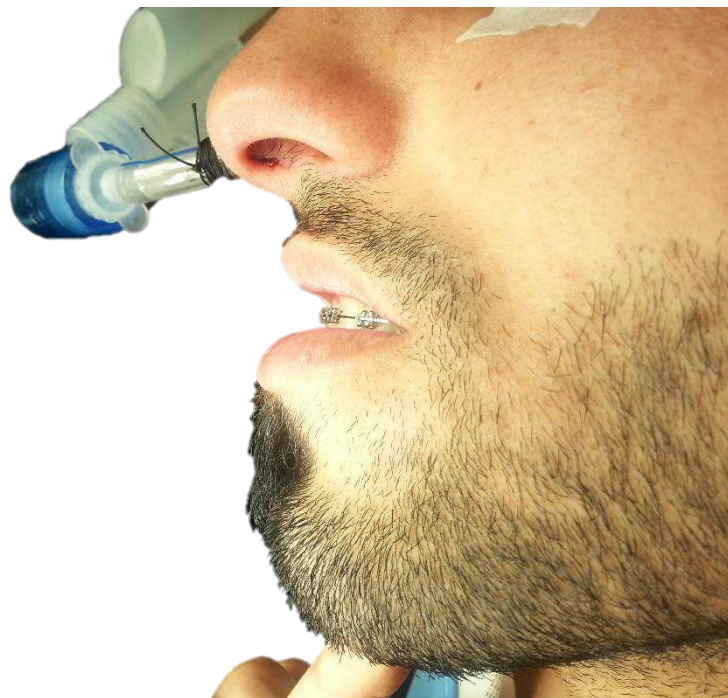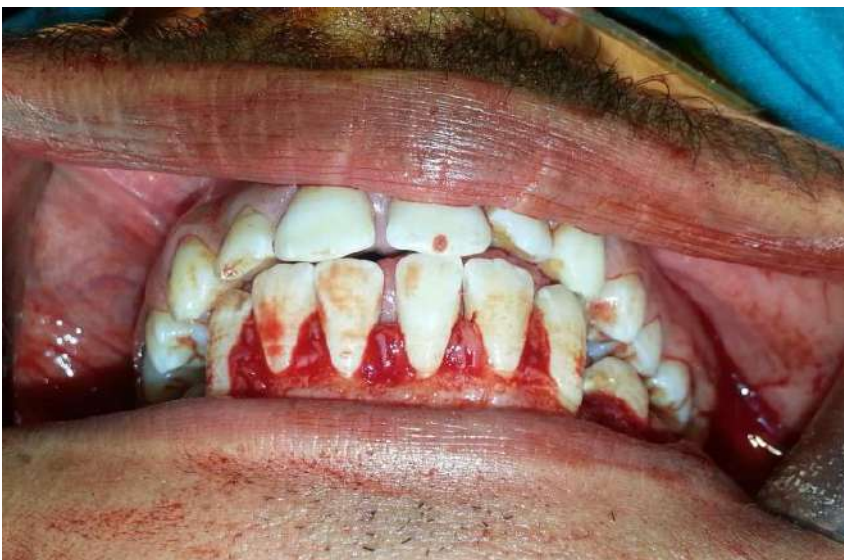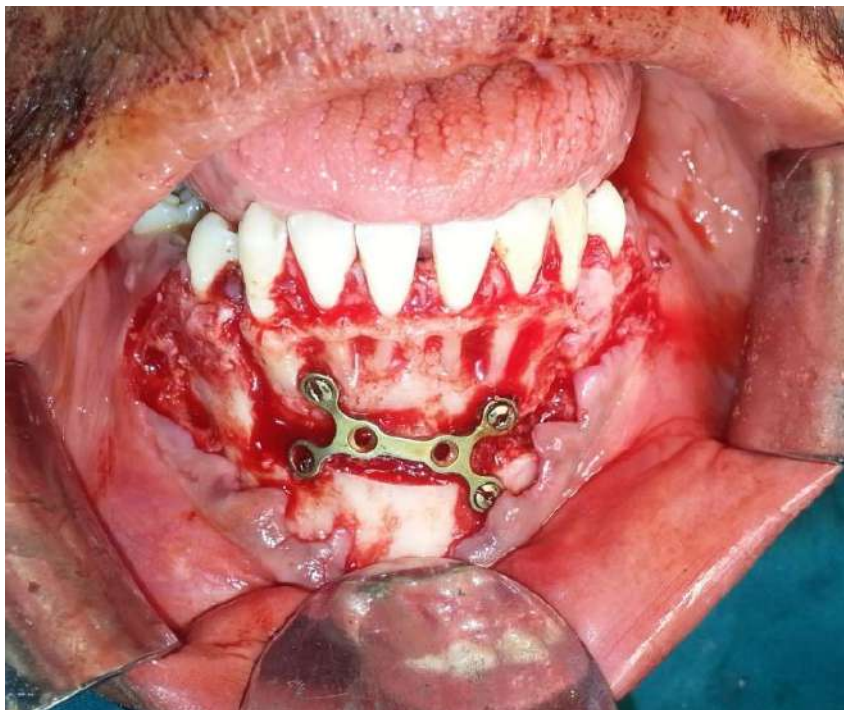
Surgical Techniques – Mand. Prognathism

Body Osteotomy: Early technique - removing sections from the body of the mandible (canceled).

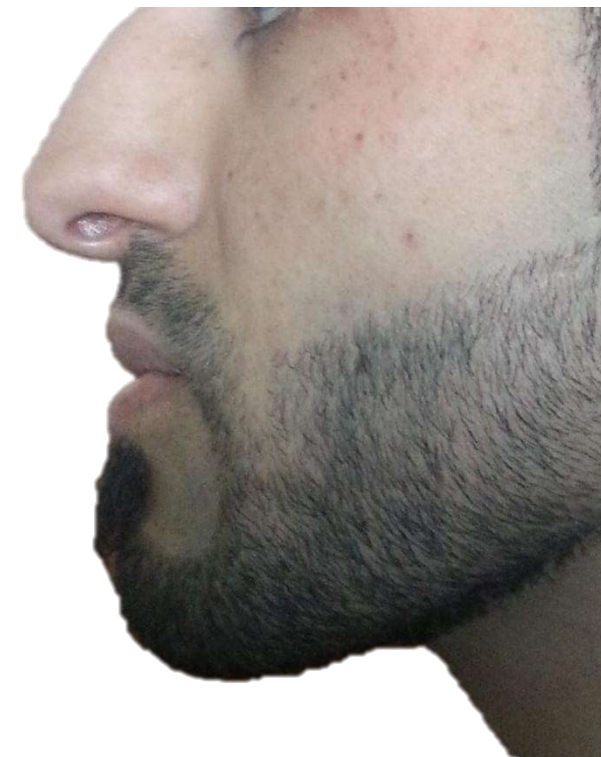Lower Anterior Subapical osteotomy: used when Dentoalveolar reverse overjet with normal chin position. (Kole osteotomy)







Preop



Postop

Subsigmoid Osteotomy (Vertical Ramus Osteotomy).

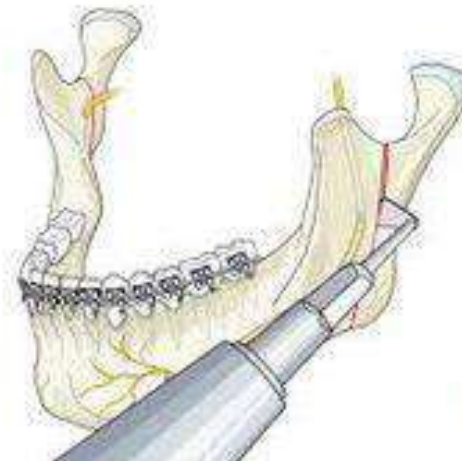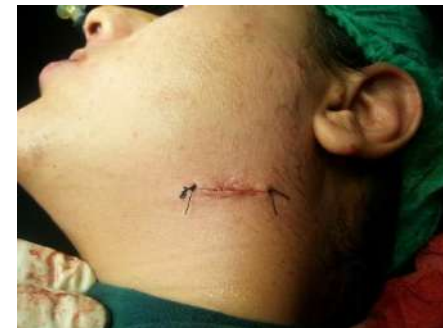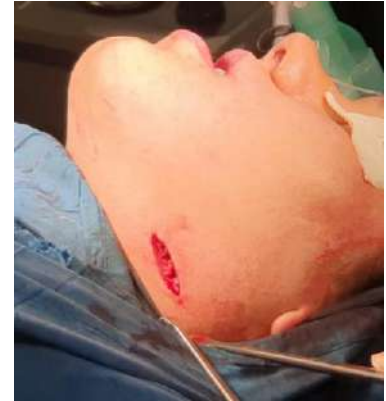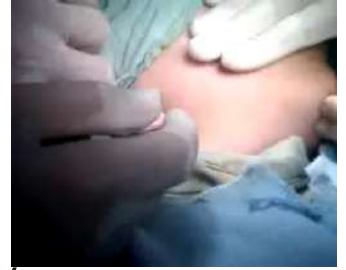Bilateral Submandibular 1.5 cm Risdon incision, (extra-oral approach)

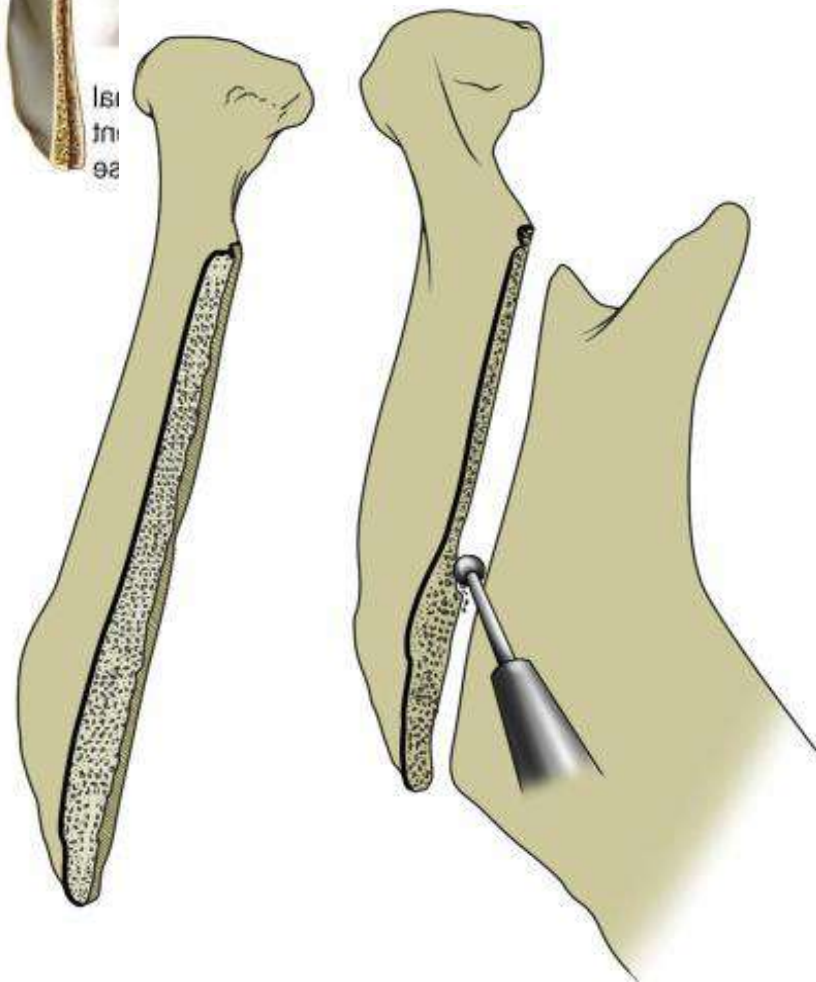
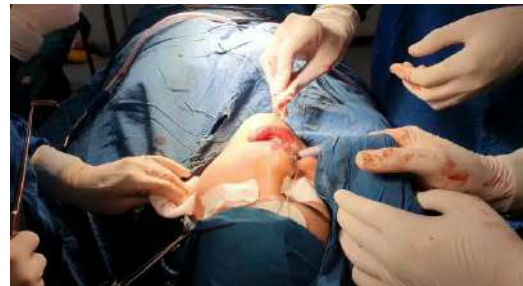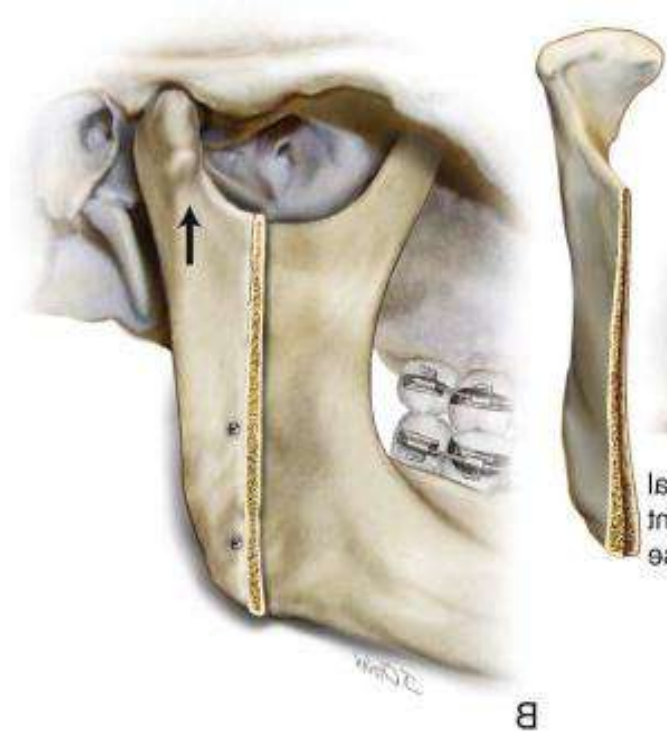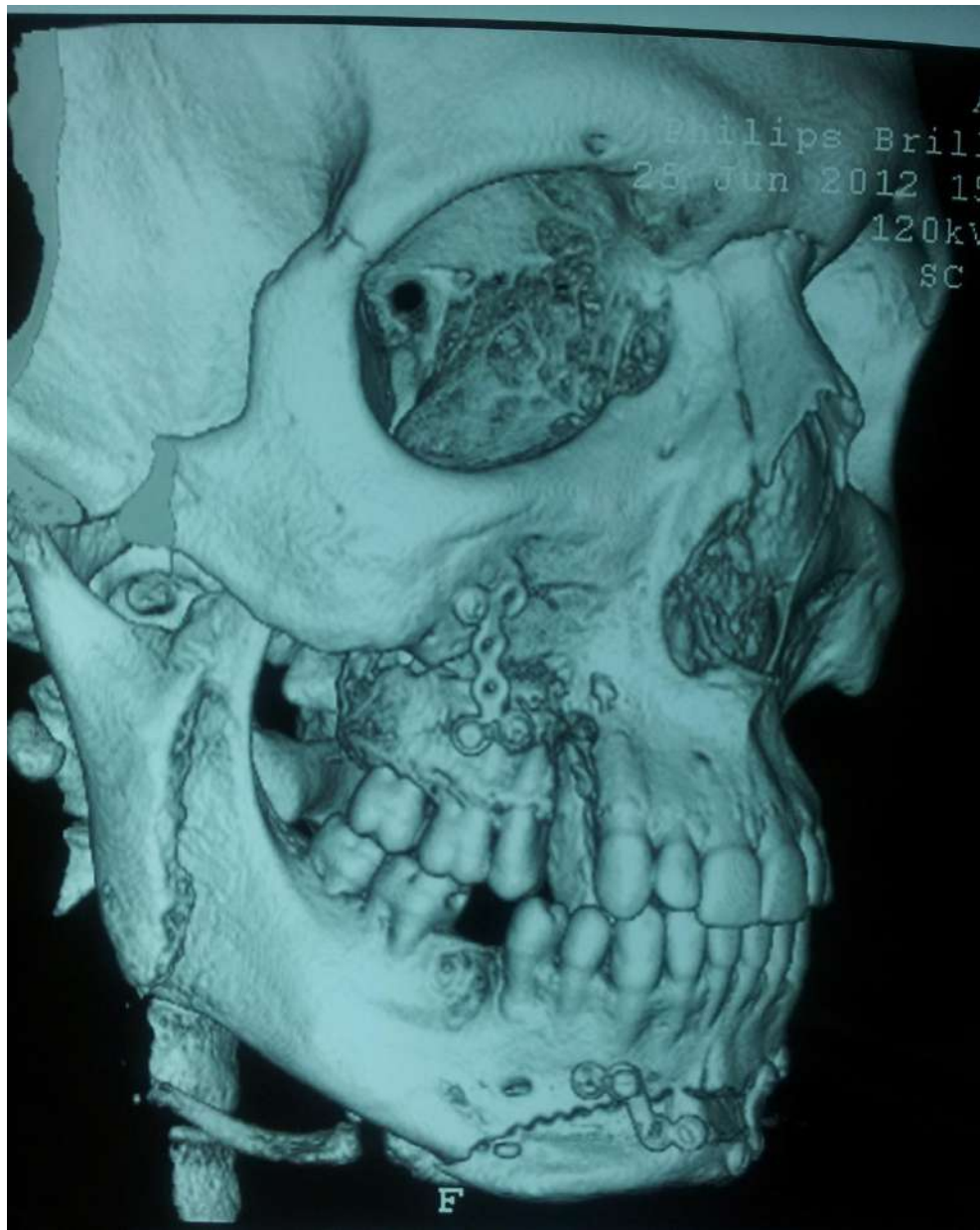Used only for class III skeletal relationship

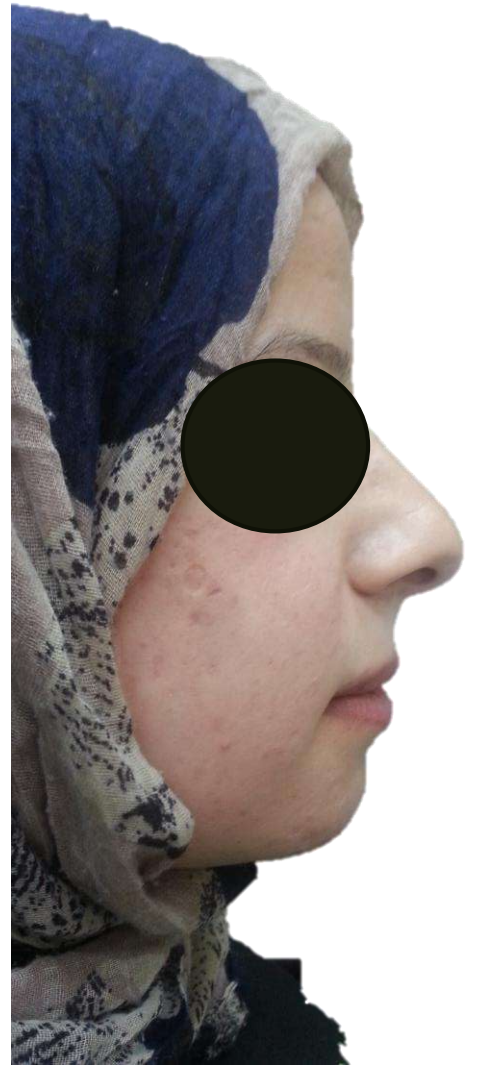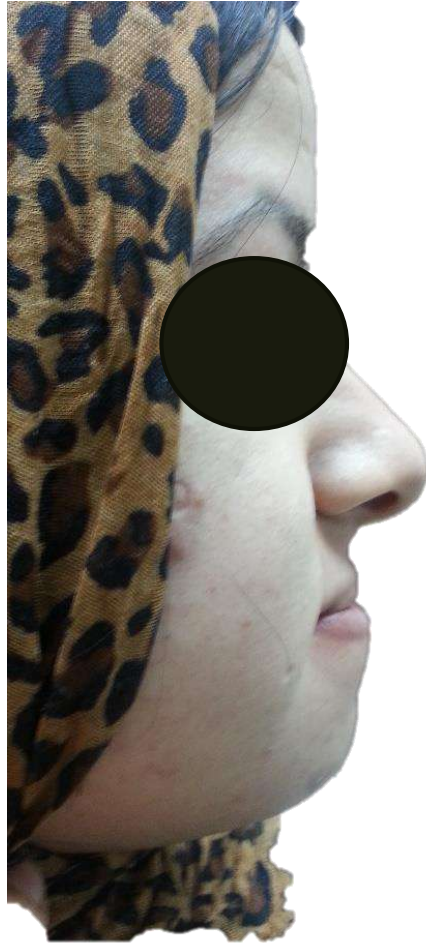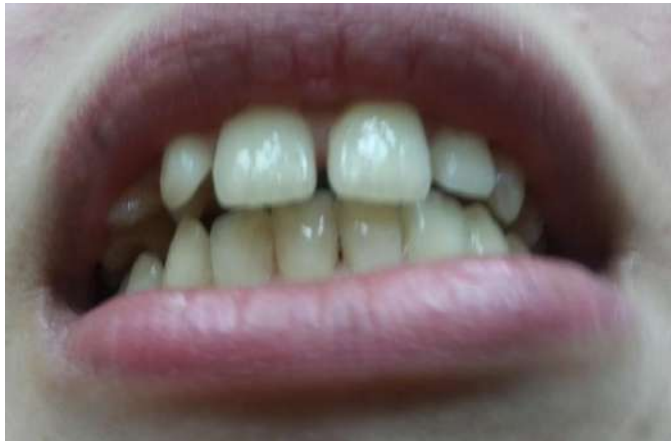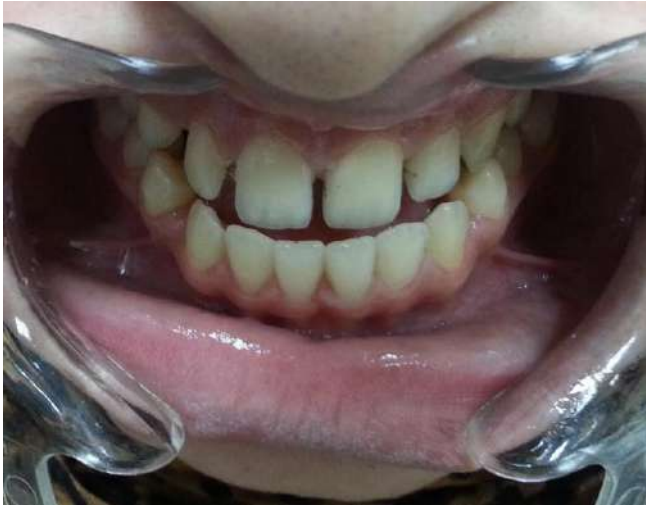A similar technique is performed with an intraoral incision, with oscillating saw.

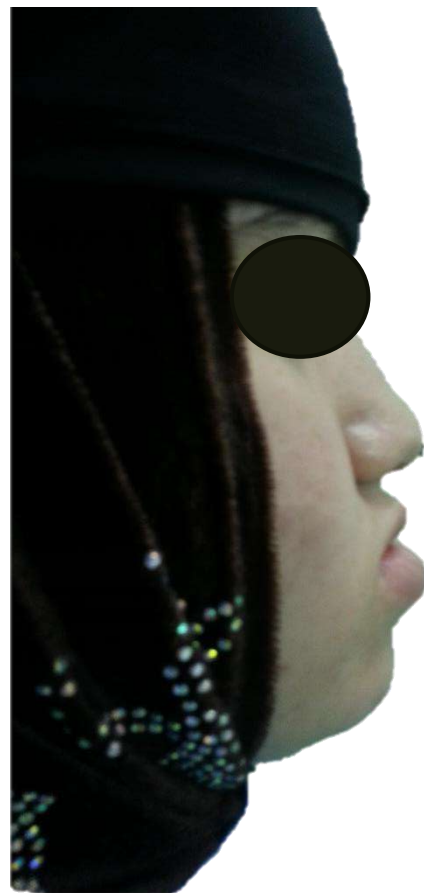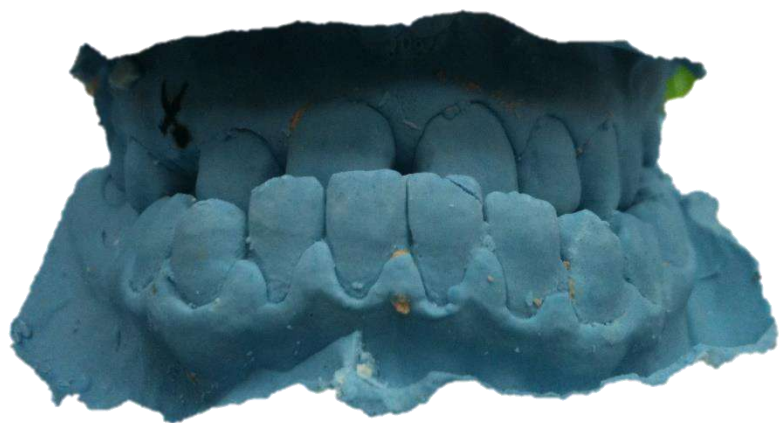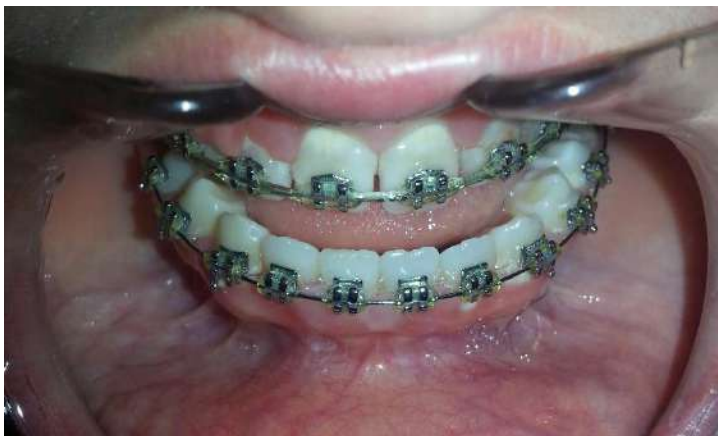Jaw is stabilized with IMF

It may traumatize facial N, inferior alveolar bundle

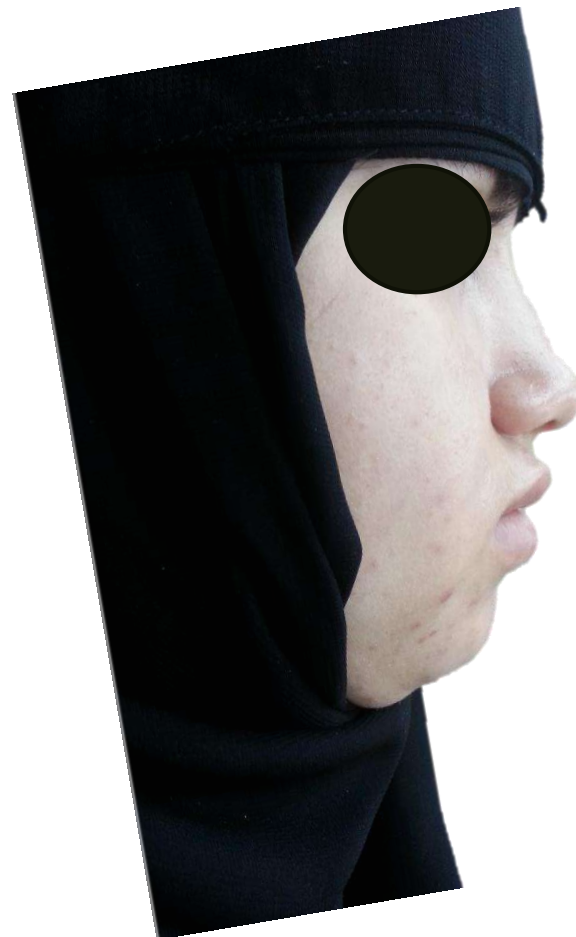



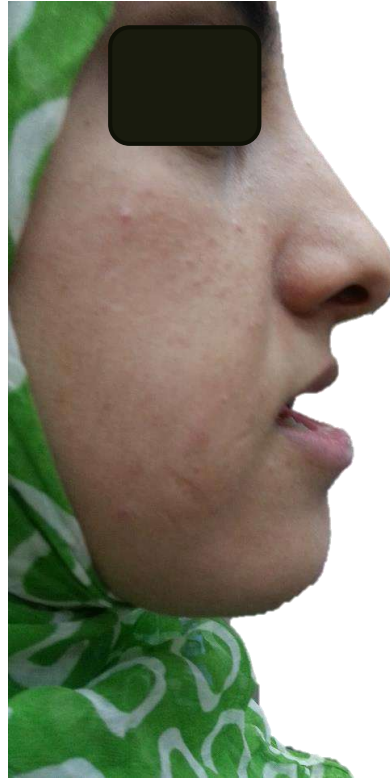

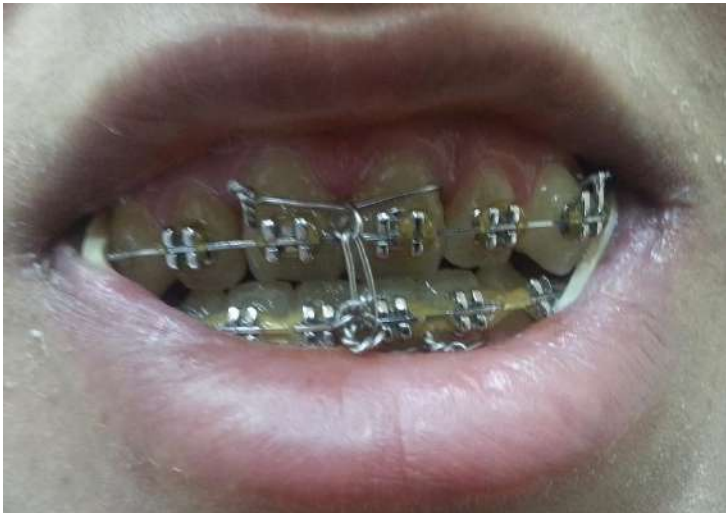
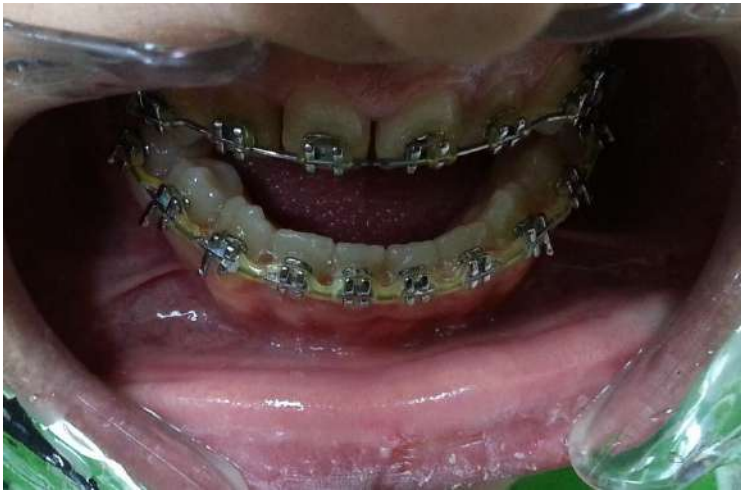

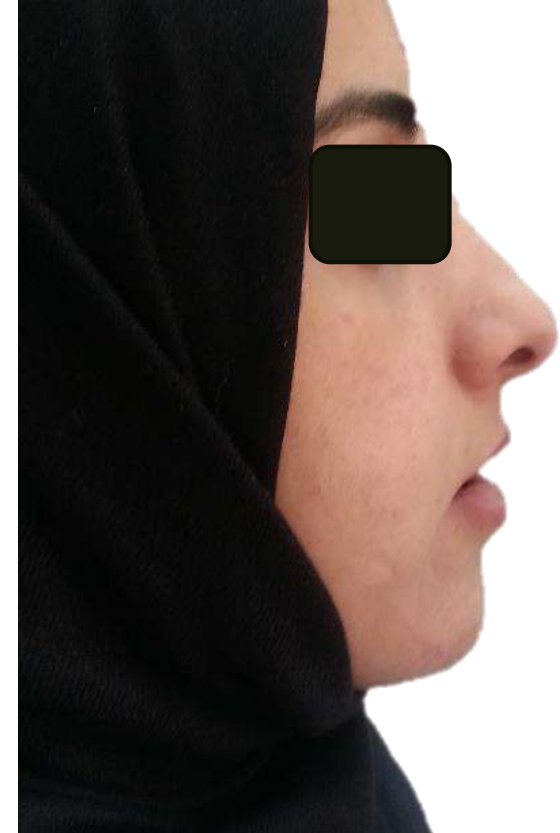Preop



Postop

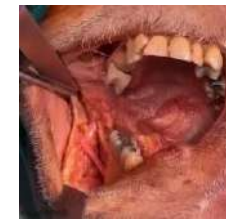

Preop



Postop

Bilateral Sagittal Split Osteotomy (BSSO)



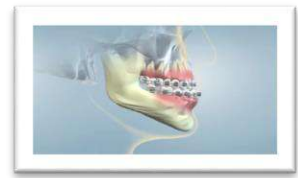It is one of the **most frequently performed** surgical procedures.

Developed in the middle of the last century by Hugo **Obwegeser**.

Two major characteristics delineated Obwegeser's technique from standard techniques used at that time:

(1) It was the first surgical procedure **performed to lengthen** the skeletal mandible

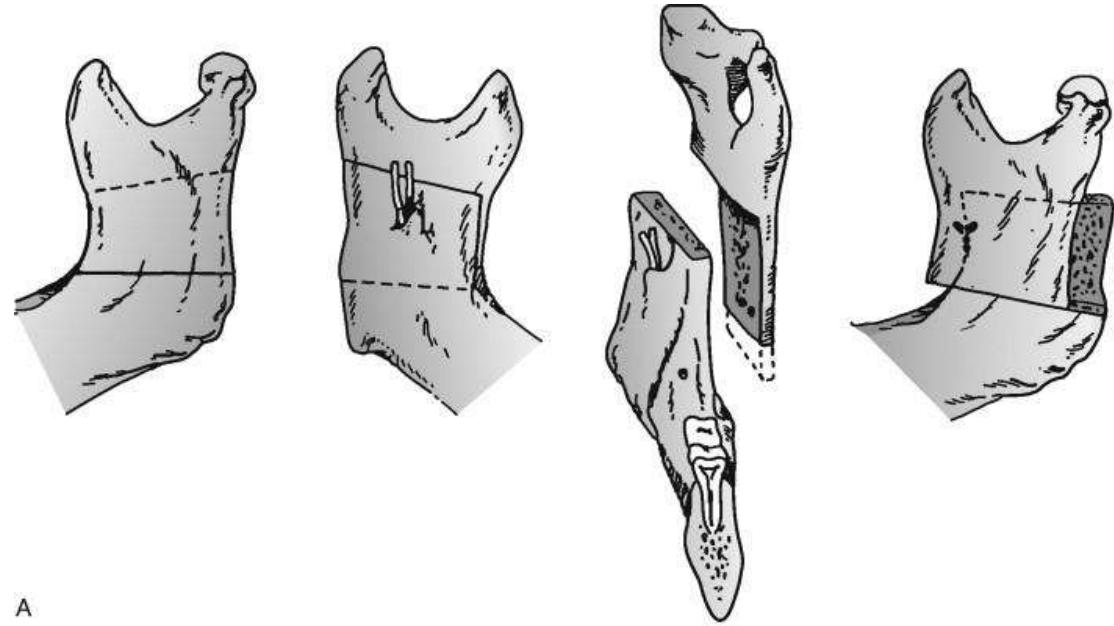
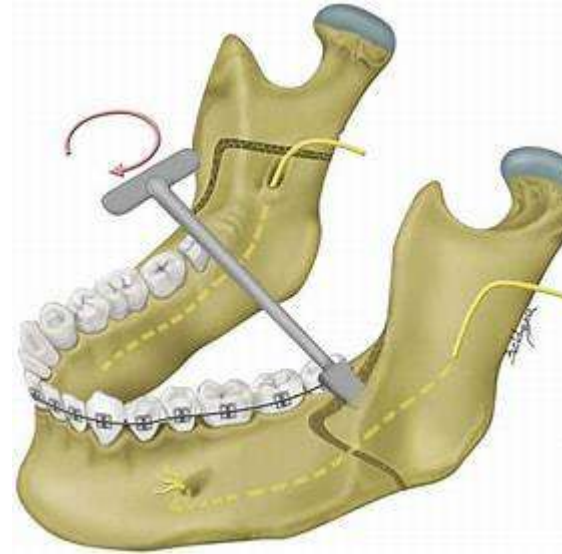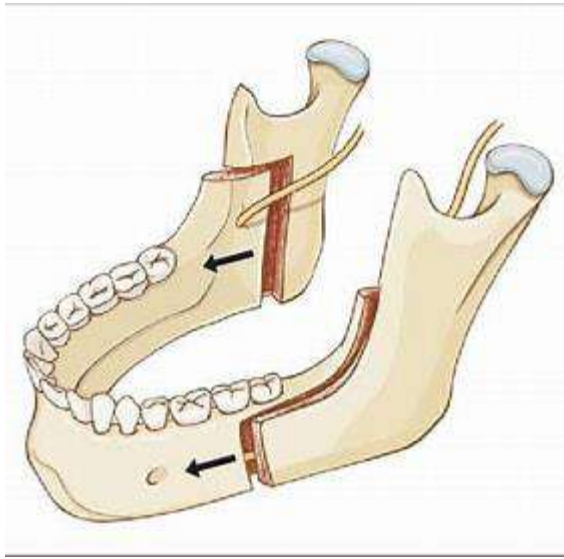
(2) the technique **permitted intraoral access** to the operating site.




Intra-oral incision, splits the ramus and posterior body of the mandible in a Sagittal Fashion

It can be employed for all mandibular movements (Forward, Backward, Rotation).

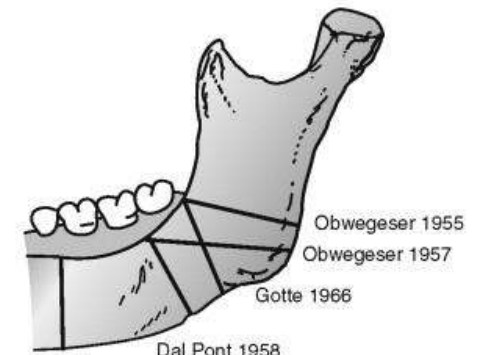
Disadvantages include **Potential Trauma** of the inferior alveolar nerve, this may be permanent, and possible **Relapse** in comparison with subsigmoid osteotomy.



A



Dal Pont 1958
Hunsuck 1968
B Epker 1977



Obwegeser 1955
Obwegeser 1957
Gotte 1966
Dal Pont 1958
C Obwegeser 1968

Mandibular Deficiency

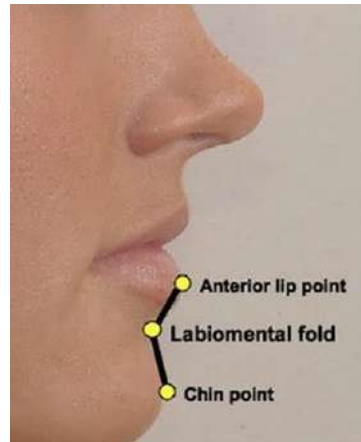
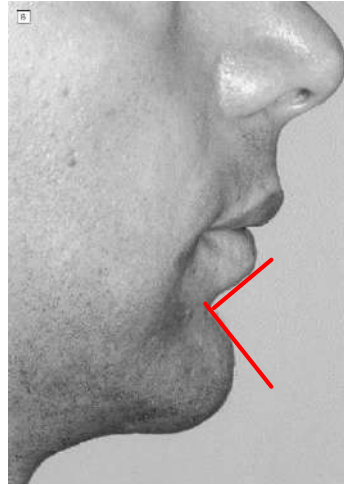The most obvious clinical feature is **retruded position of the chin** (in profile).

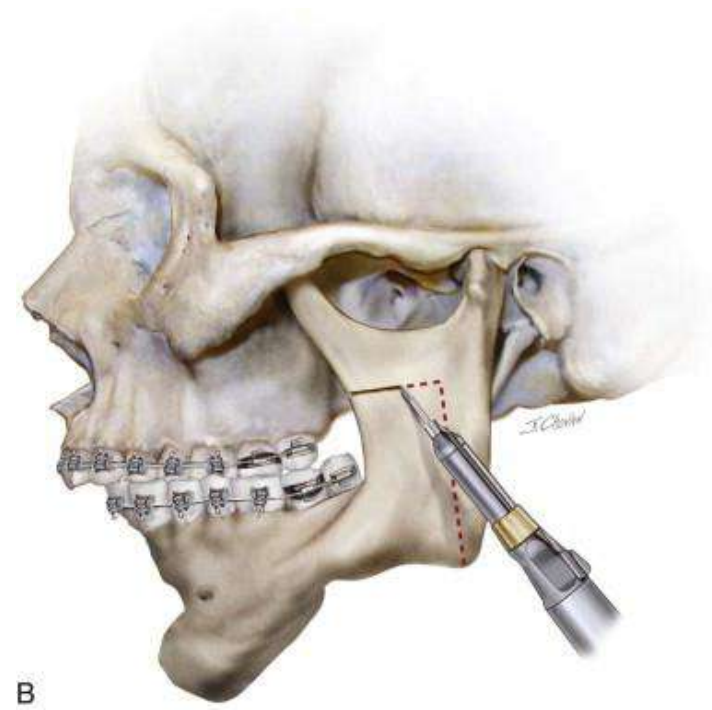
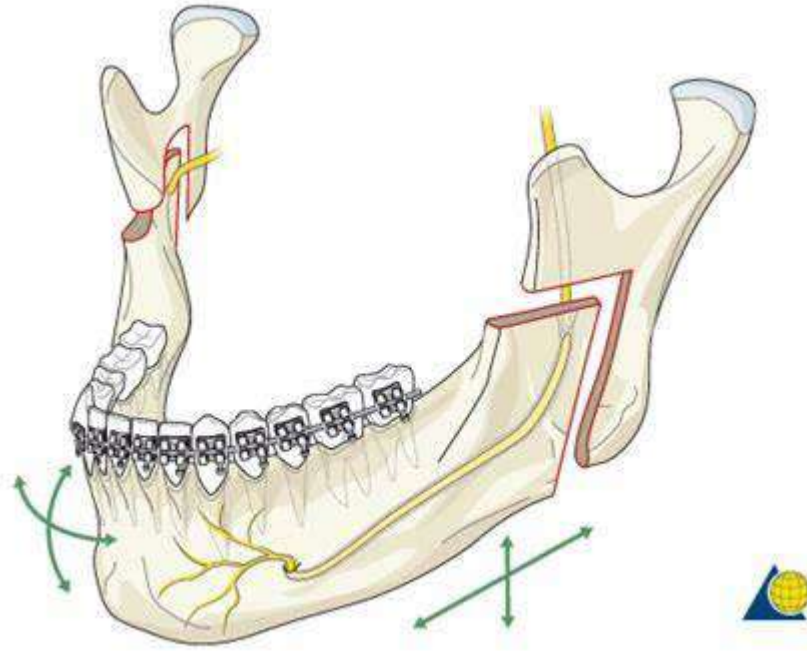
Intraorally, Class II relationship and increased overjet.

Surgery - BSSO is the **most popular technique** for mandibular advancement.

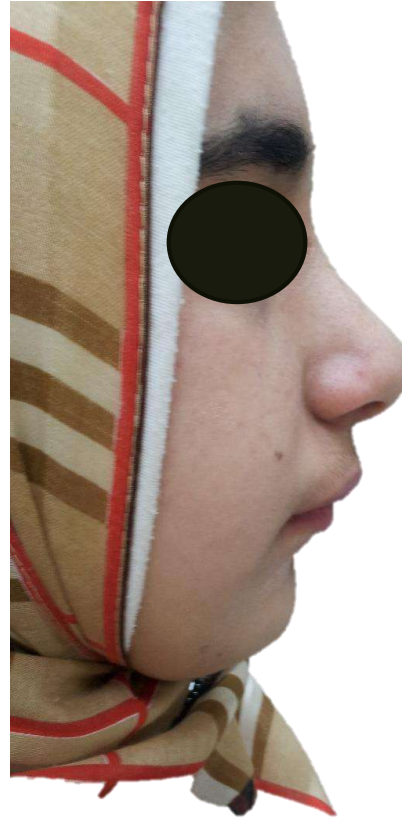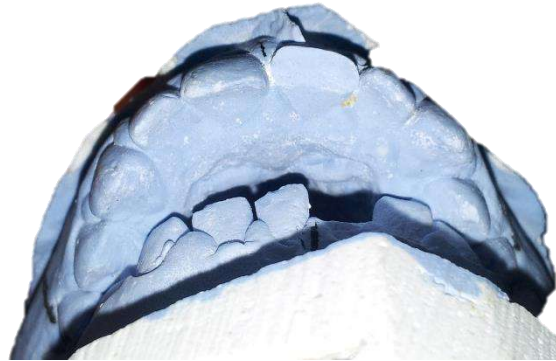
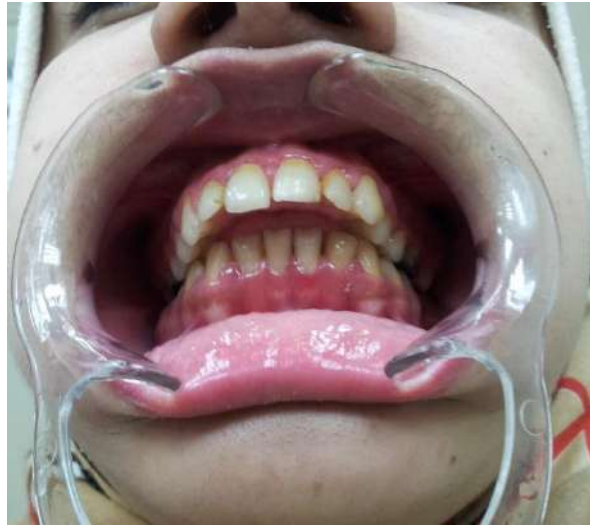The osteotomy is frequently stabilized with **rigid fixation plates or screws**,
eliminating the need for IMF.

For severe cases, **an Inverted L Osteotomy with iliac bone graft** is
indicated

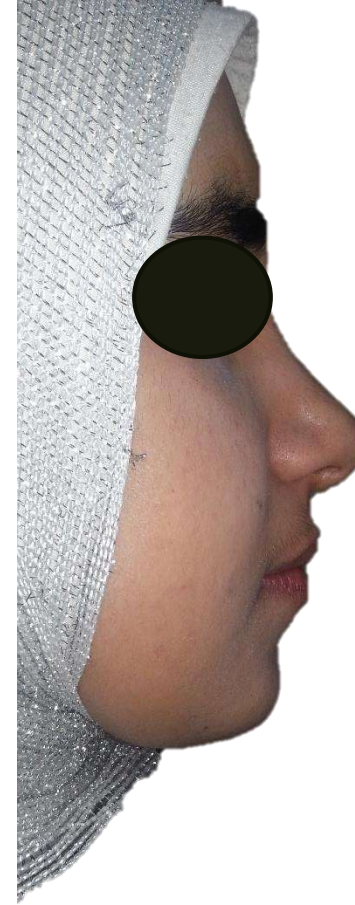



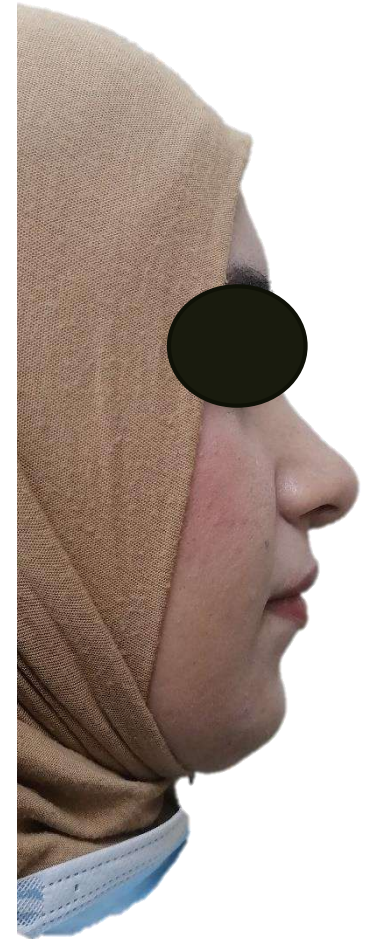Inverted L Osteotomy



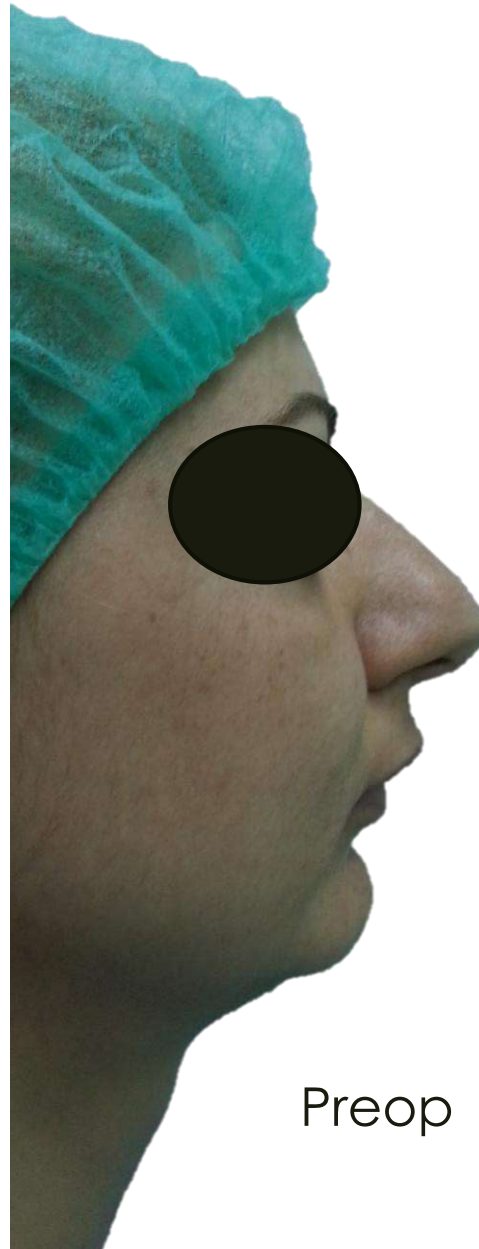
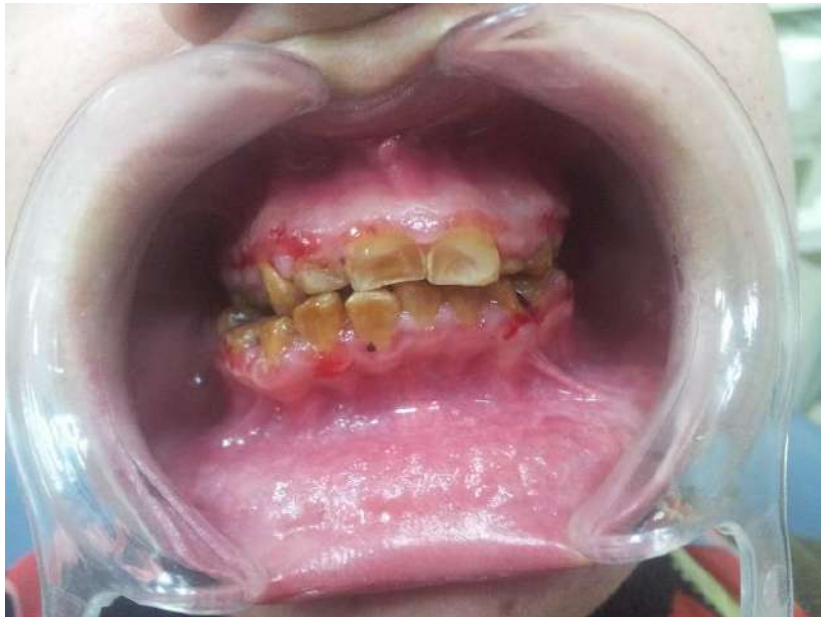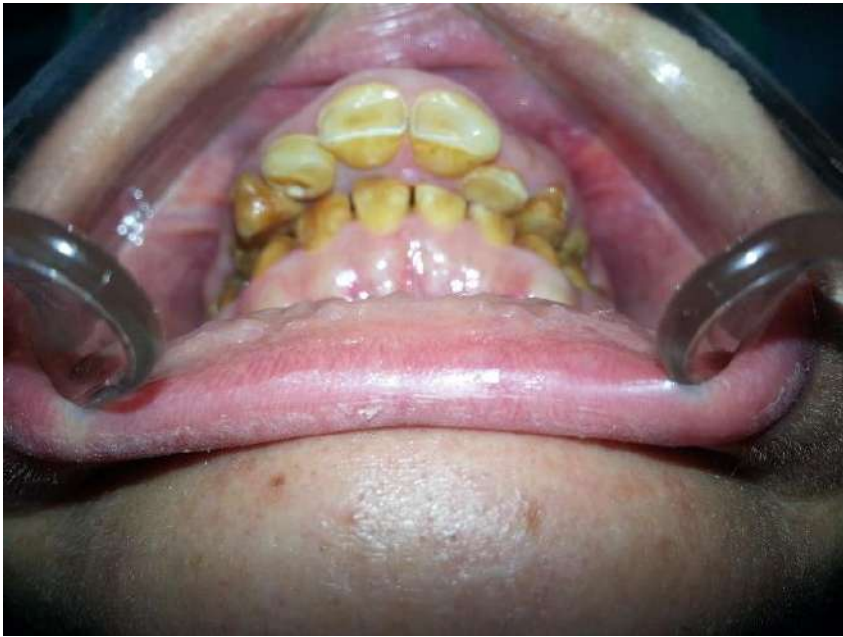Preop



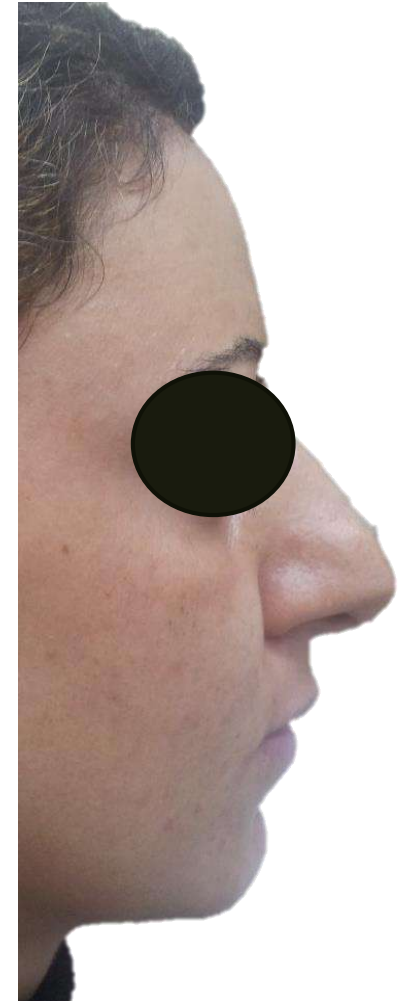
6 months postop



8 years postop



Preop



Postop

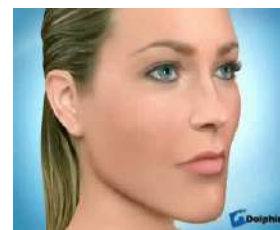
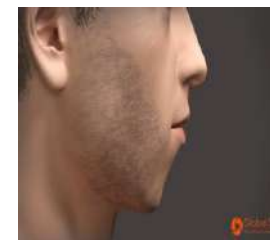
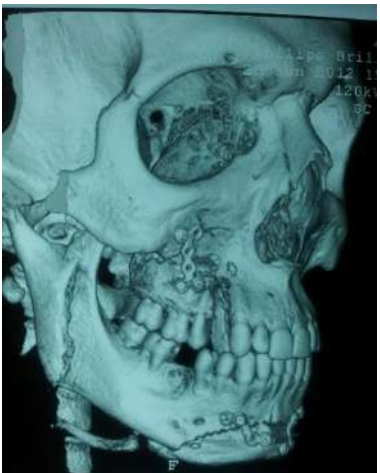Genioplasty

When a proper occlusal relationship exists with retruded chin, an inferior border osteotomy done with advancement.

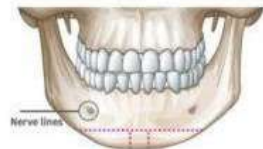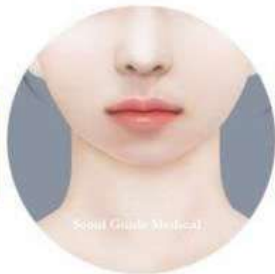Extra-Oral and Oral-Oral approach

Types : Vertical reduction, augmentation, correction of asymmetries, sliding, setback, overlapping genioplasty.

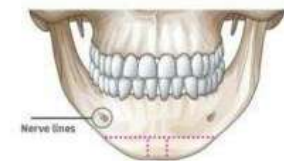
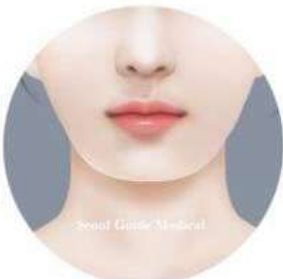Alloplastic materials can occasionally be used to augment chin projection; the material is onlayed in areas of bone deficiencies.



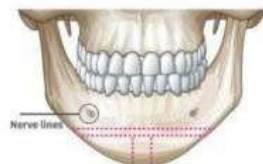
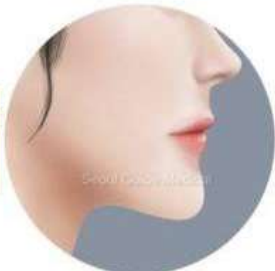Short
Chin



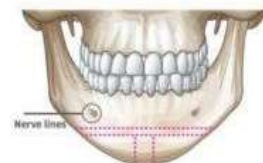
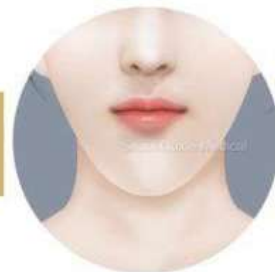Wide
Chin



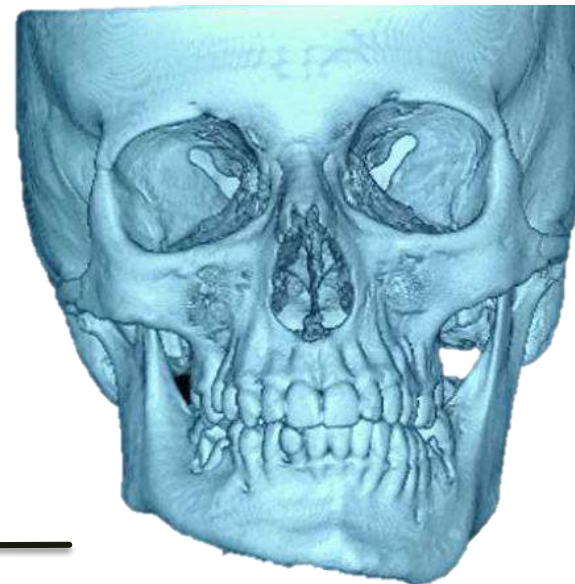
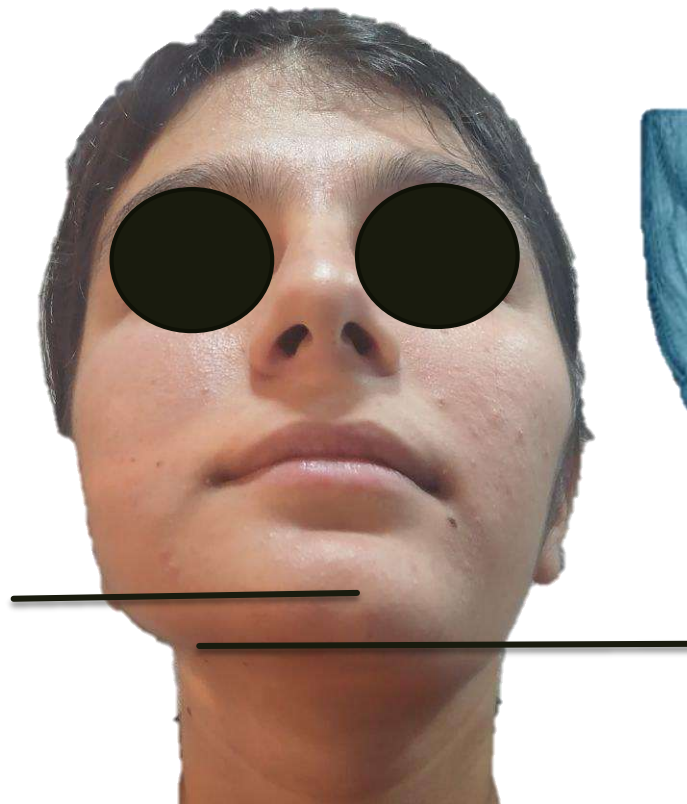
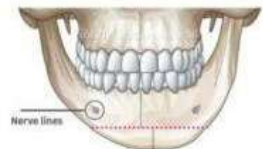
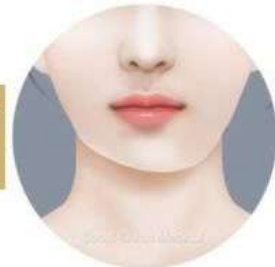Protruding
Chin

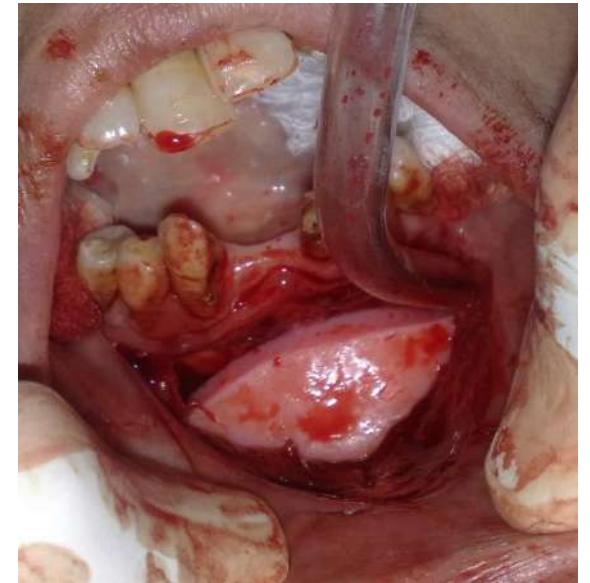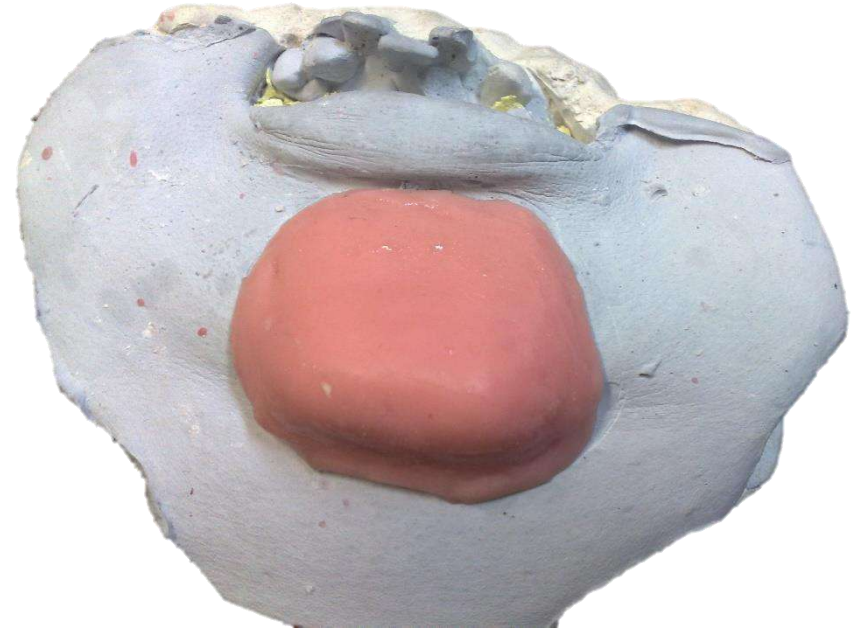

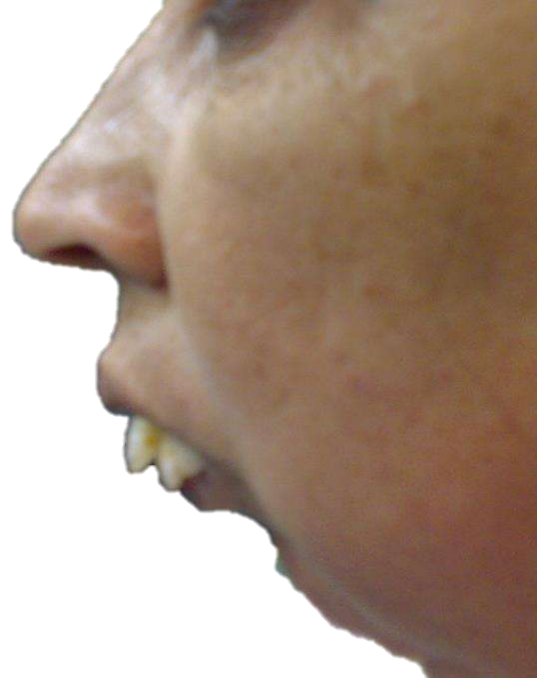
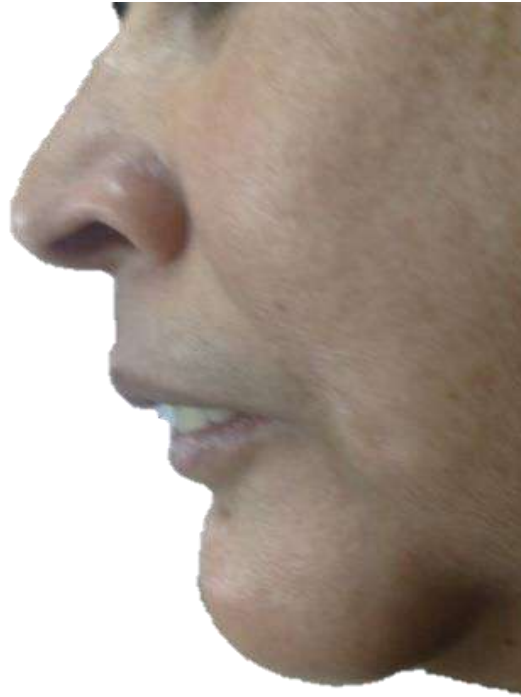Long
Chin

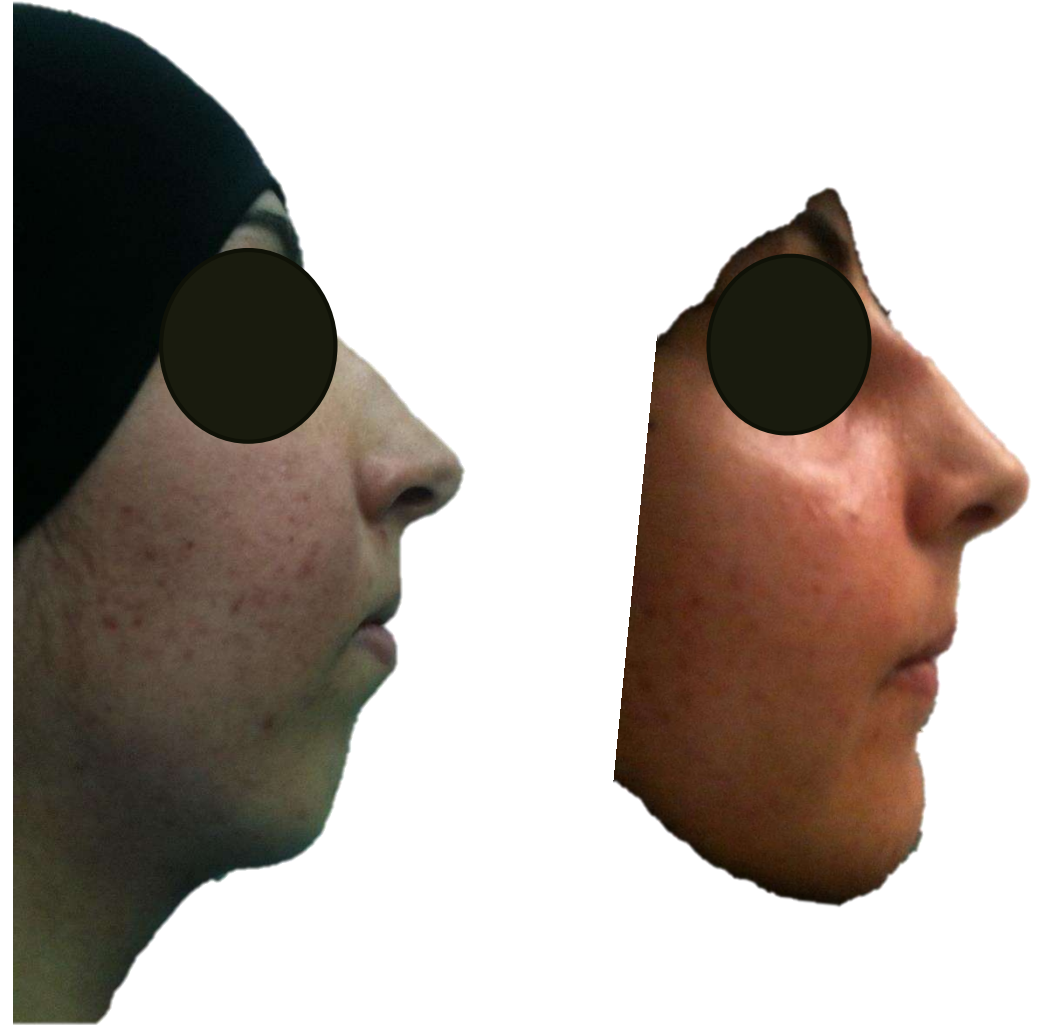
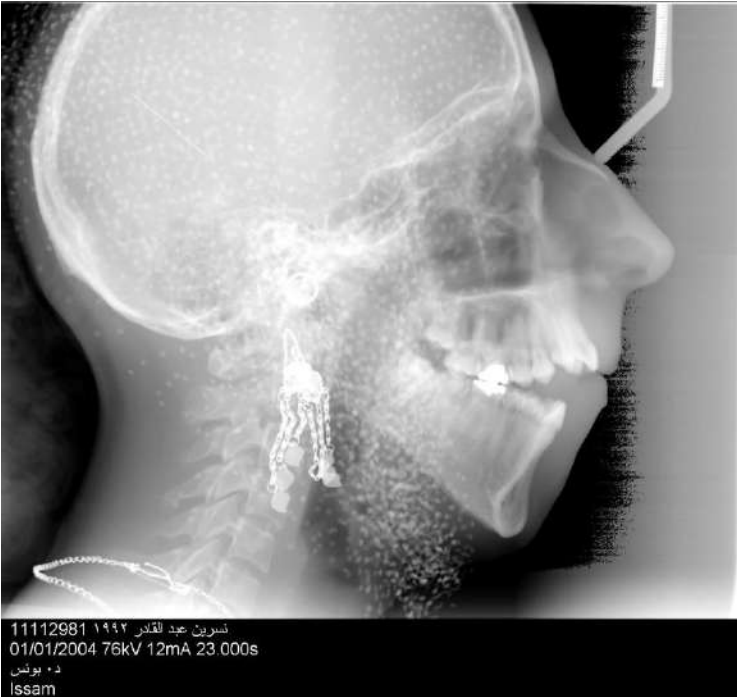
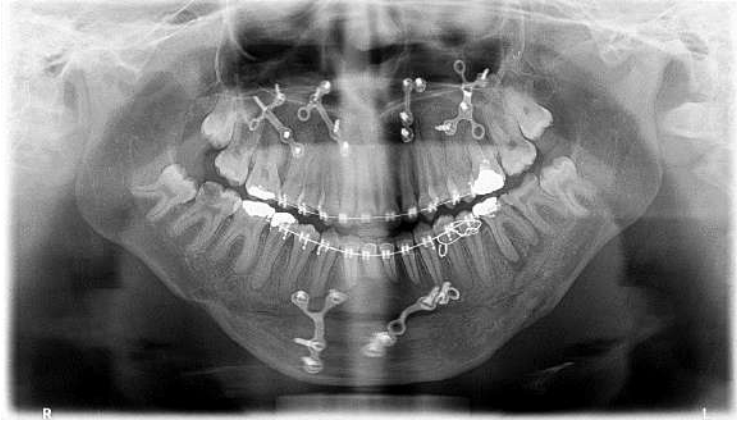Assymetry
Chin

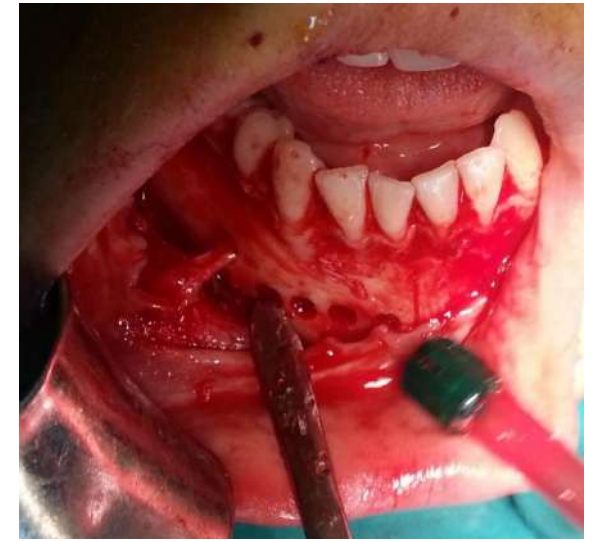
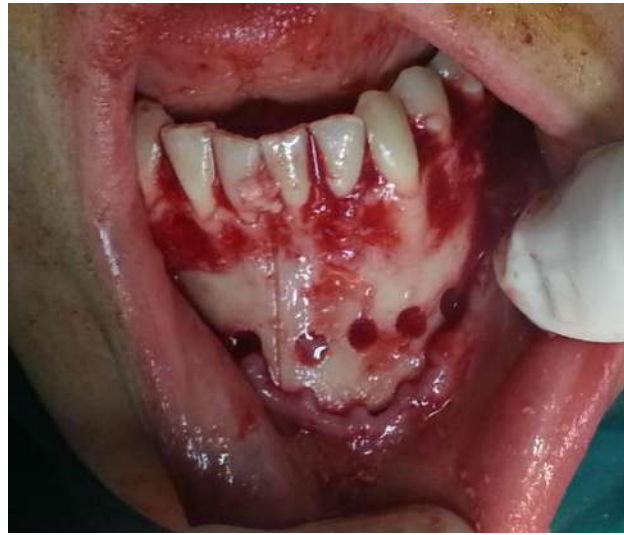
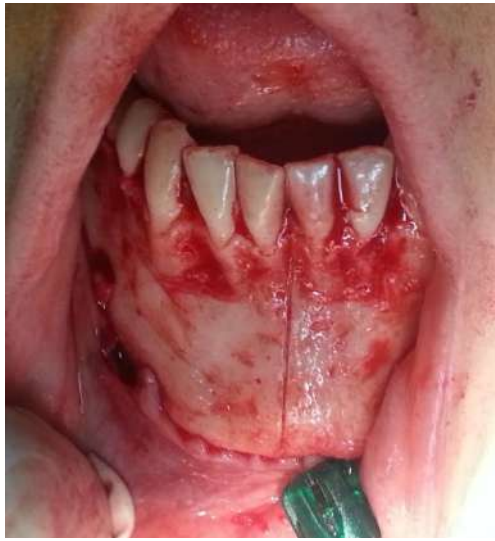

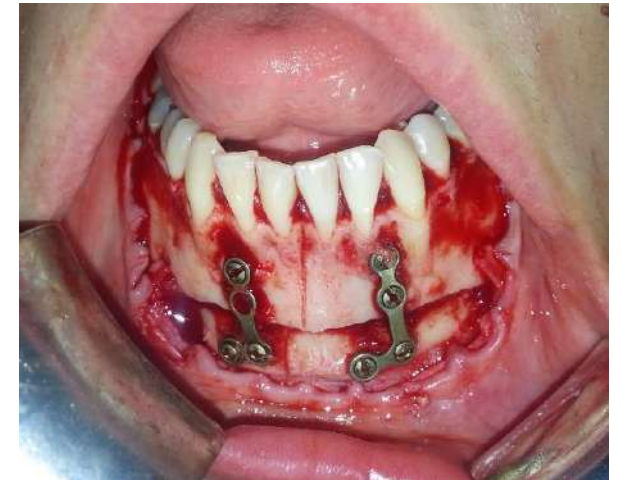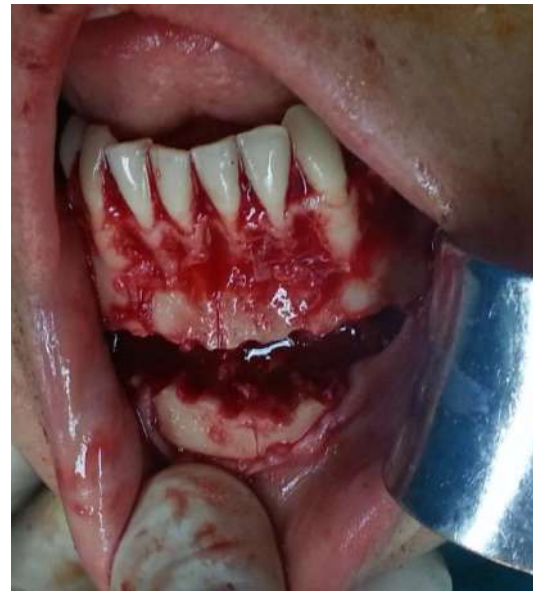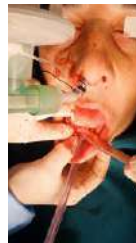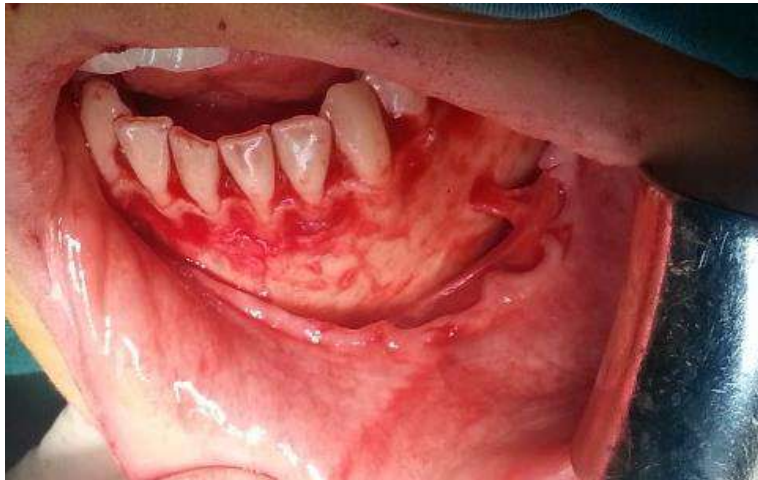Alloplastic Material Augmentation

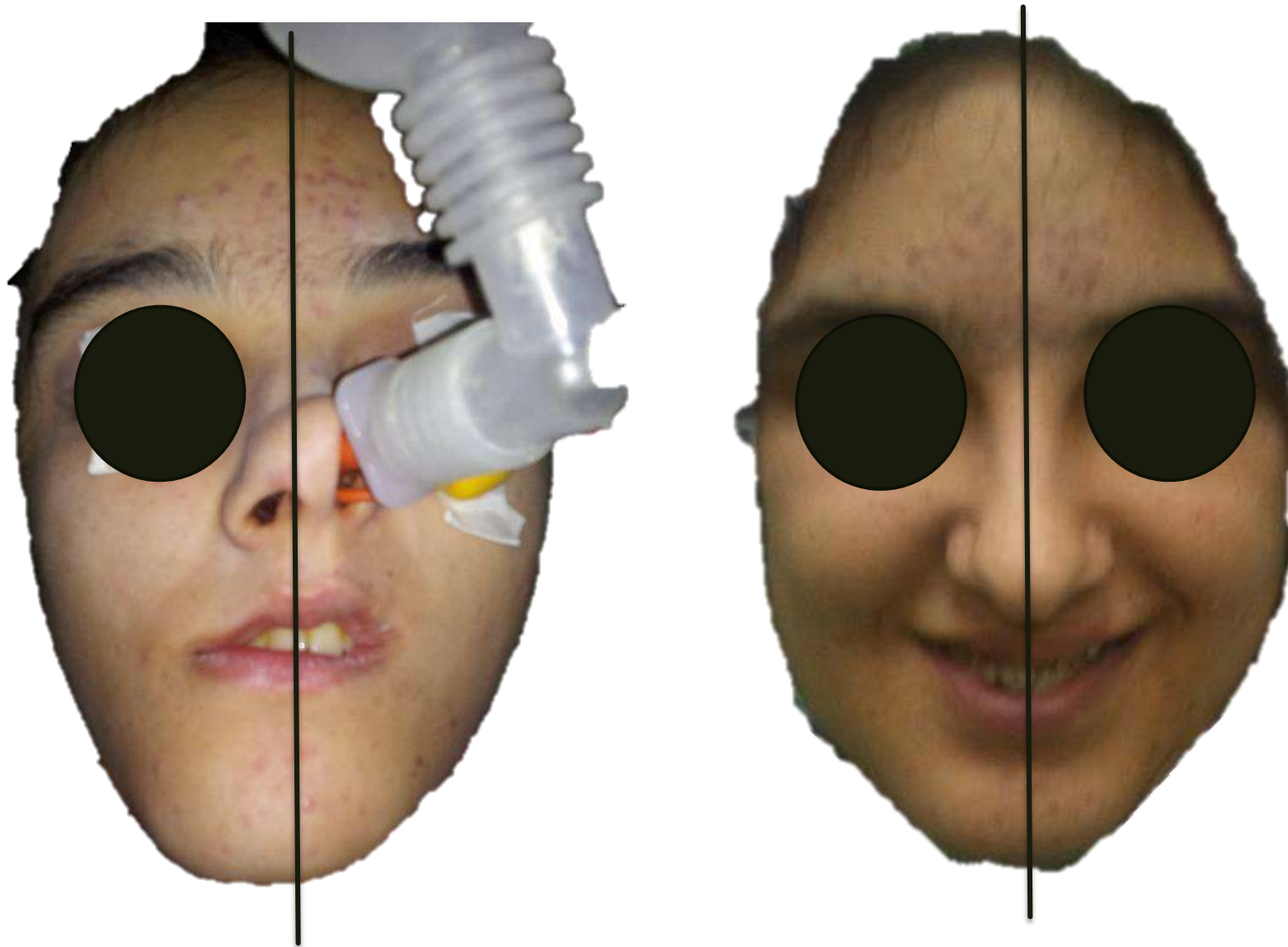


Overlapping Genioplasty



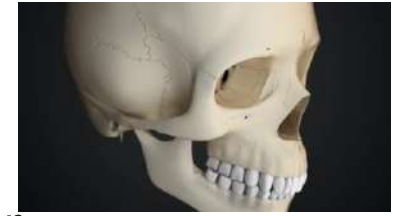Surgical Steps





Correction of Asymmetry

Maxillary Excess



Excessive growth of the maxilla may occur in the Anteroposterior, Vertical, or Transverse Dimensions.

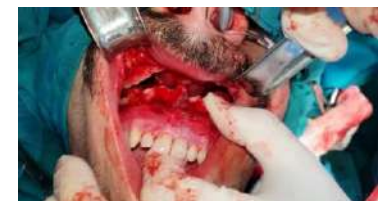Surgical correction with total maxillary surgery (**LeFort osteotomy**) has only become popular since the early 1970s.

Vertical Maxillary Excess

Gummy Smile - Elongation of the lower third of the face; excessive incisal show and gingival exposure with lip incompetence.

Management - LeFort I osteotomy with maxillary segment set-up (superior impaction).

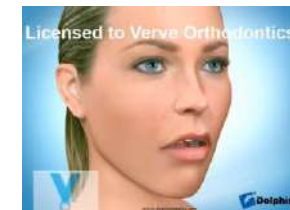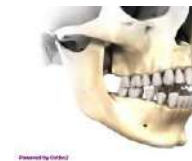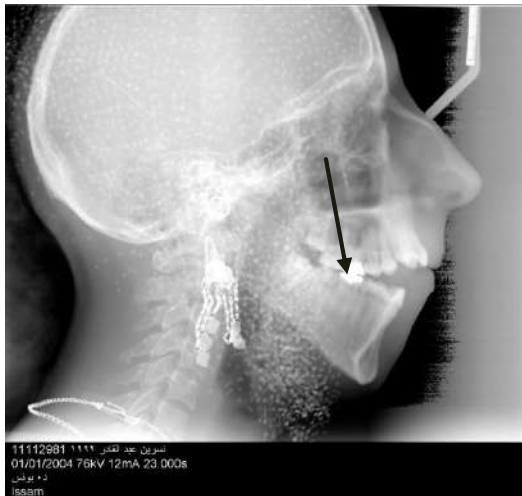Intra-oral Approach Only

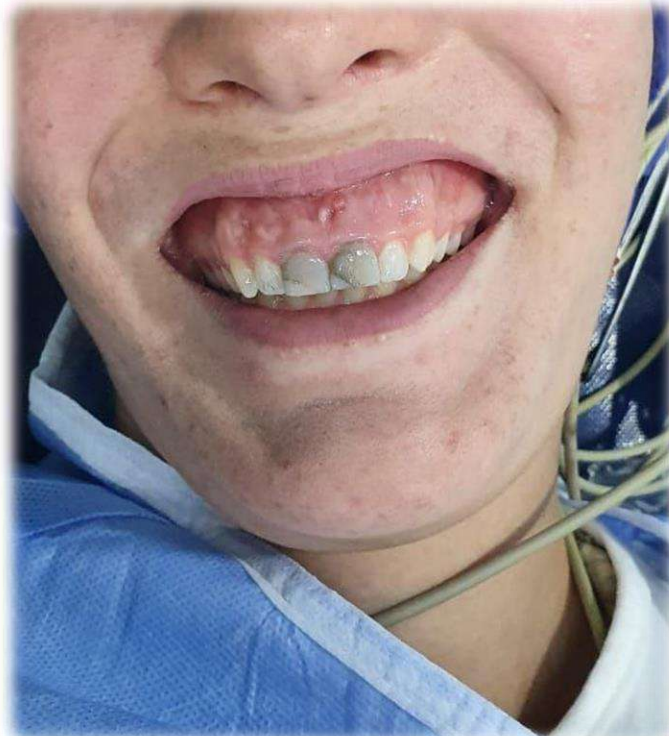
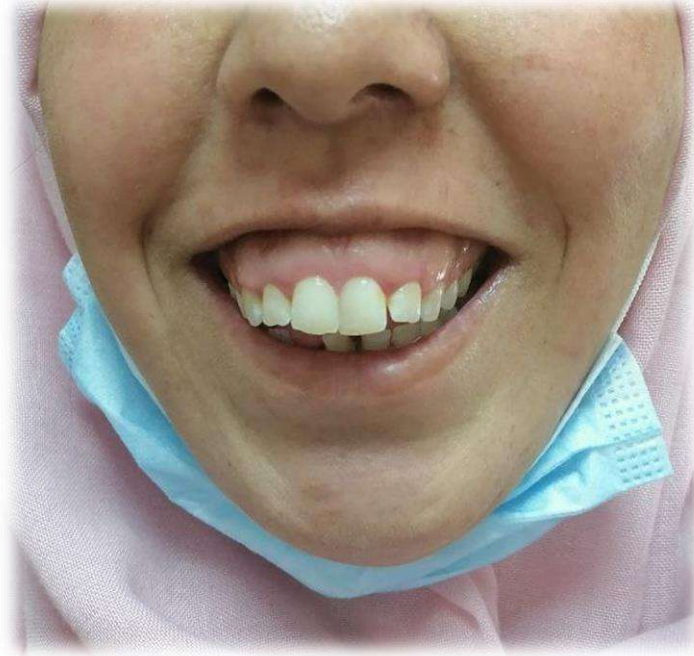
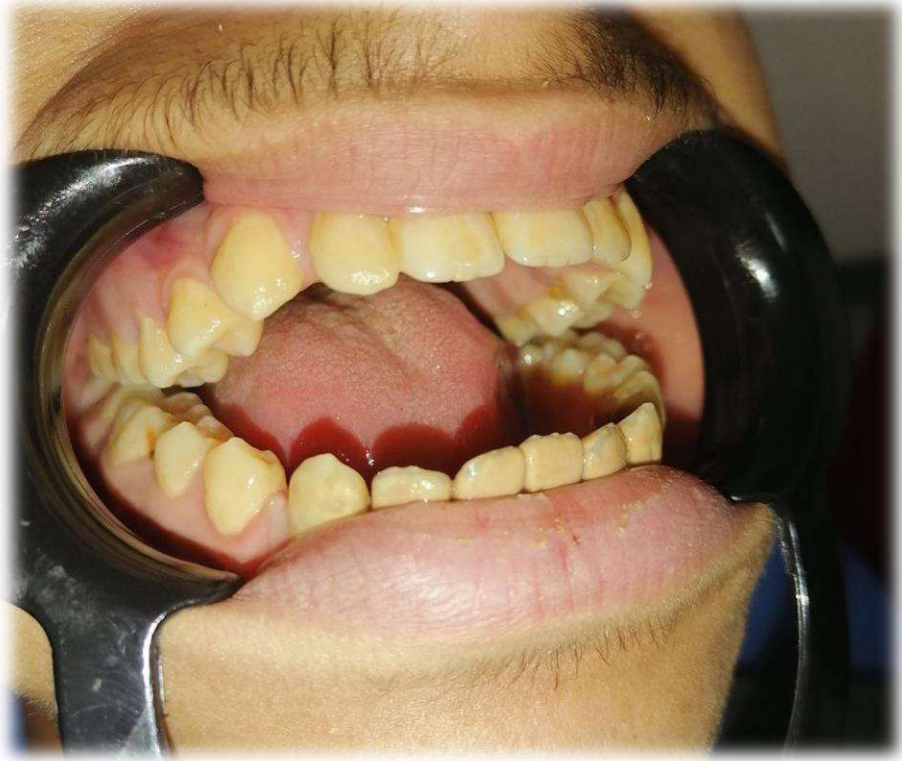

Anterior Open-bite (Apertognathia) - excessive posterior downward growth of the maxilla, causing downward rotation of the mandible as a result of premature contact of posterior teeth.

Management - LeFort I osteotomy with set-up of maxillary segment in the posterior area.

This allows the mandible to rotate upward and forward.





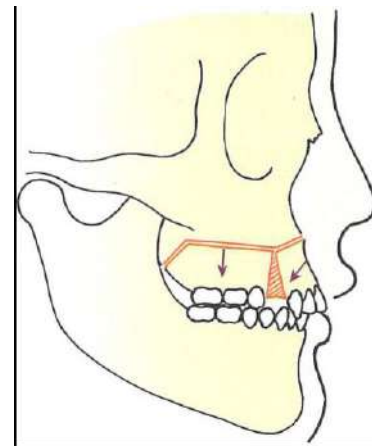
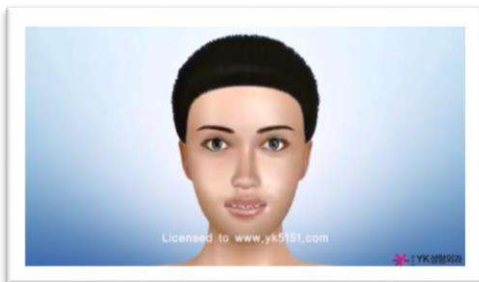
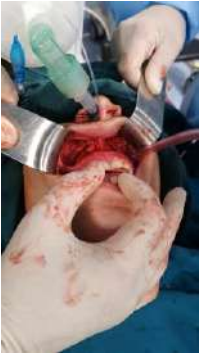Anteroposterior Maxillary Excess results in a convex facial profile usually associated with incisor protrusion and a Class II occlusal relationship.

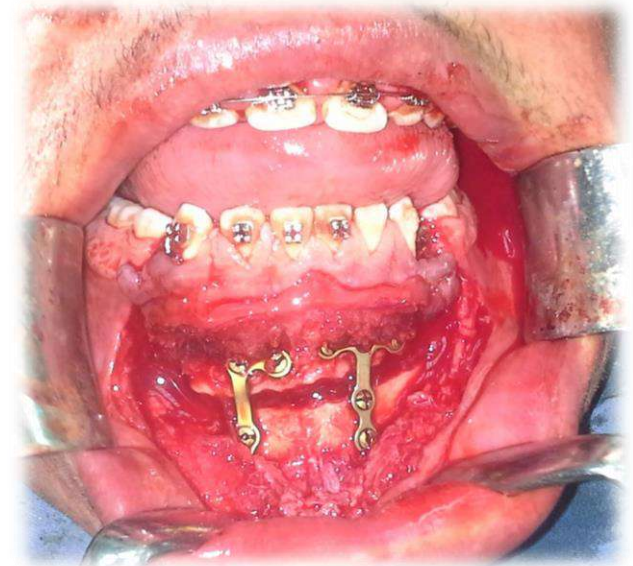
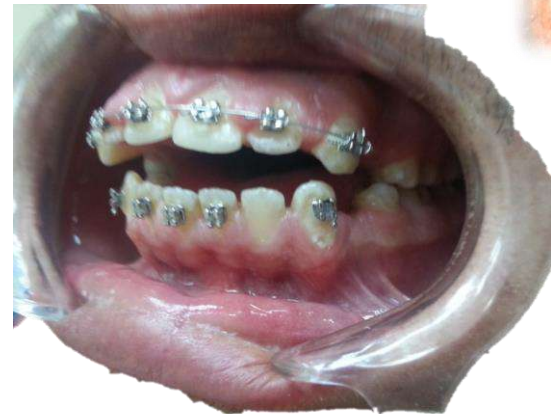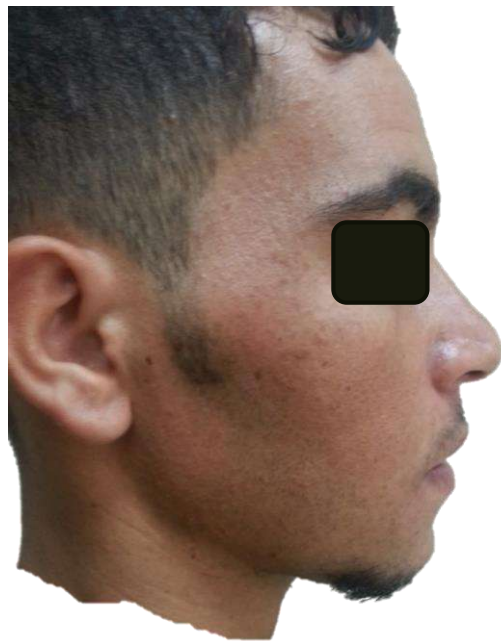
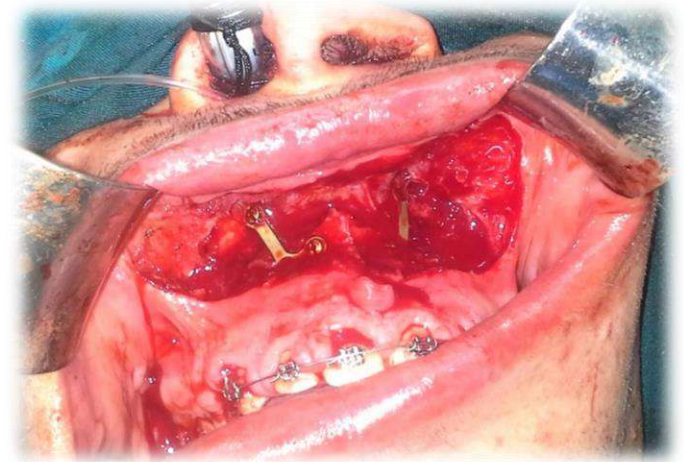
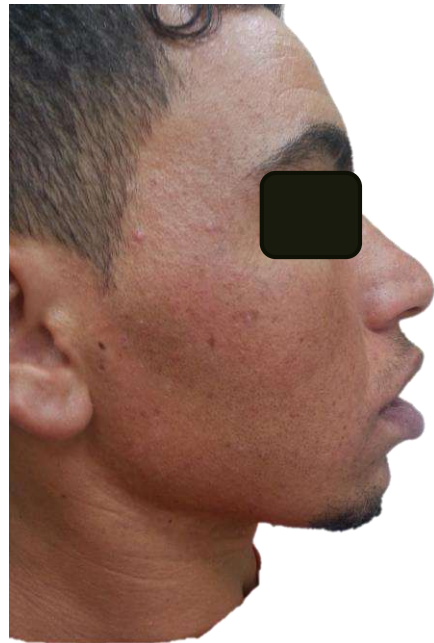
Correction –

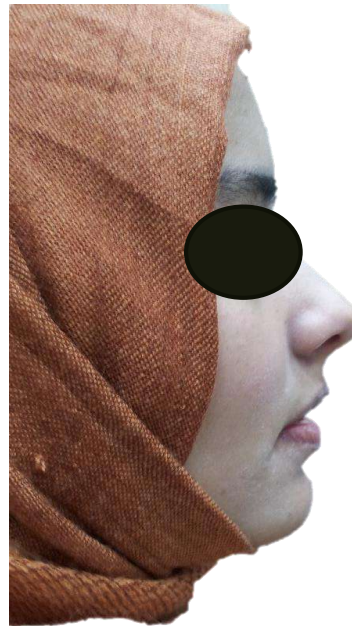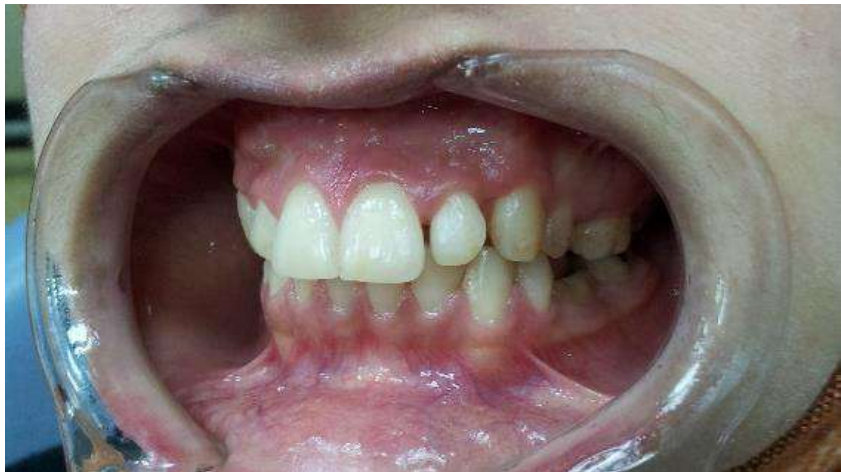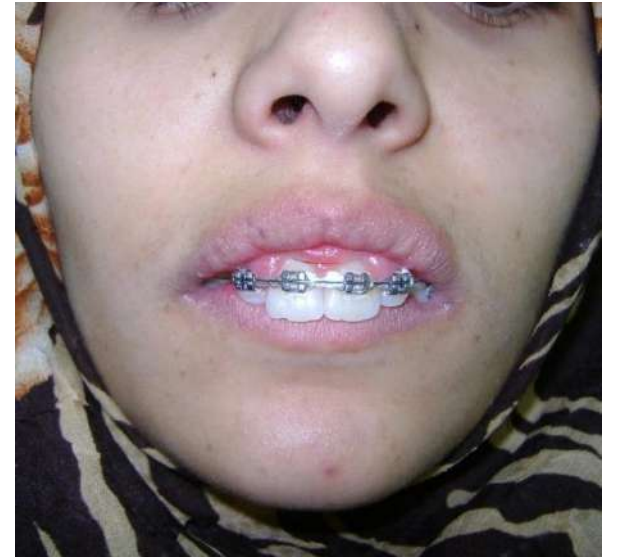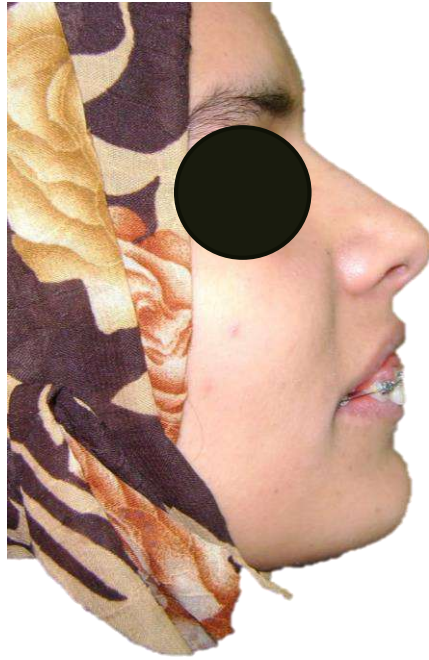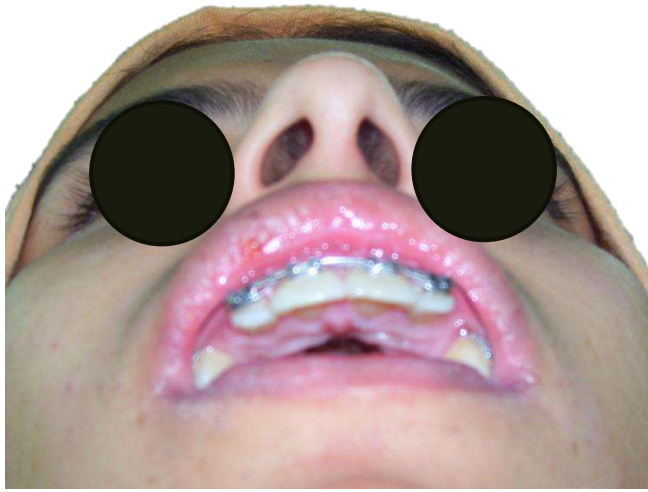Lefort I osteotomy with the maxilla moved backward.

Anterior segmental osteotomy, extraction of upper and lower first premolars, the premaxilla can be sectioned and repositioned up, rotation and/or backward directions (Wassmund osteotomy)

This could be applied for correction of Biprotrusion, selected cases of anterior open bite and dentoalveolar class II



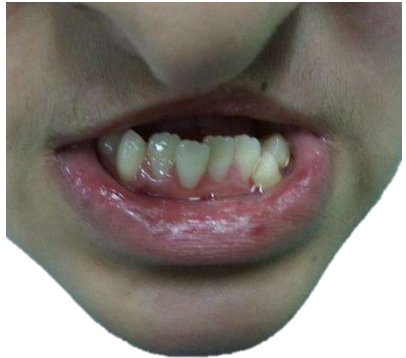



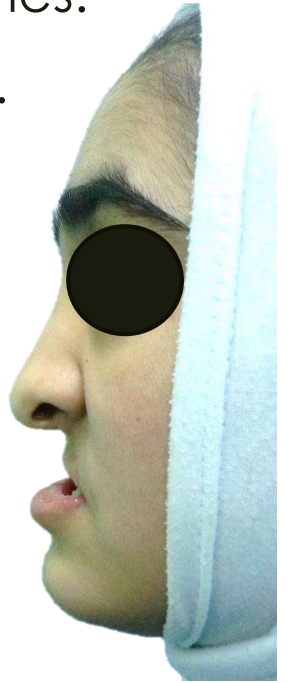Maxillary and Midface Deficiency

Maxillary deficiency occur in the anteroposterior, vertical, and transverse planes. The patient's appearance depends on location and severity of the deformity.

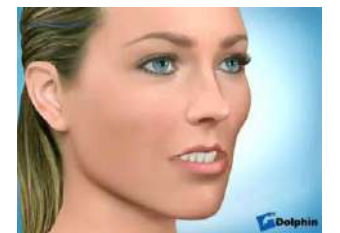Abnormal Facial Features



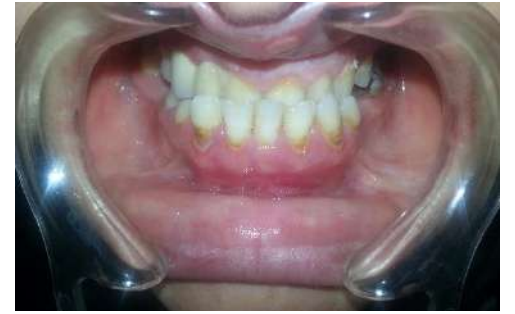- Class III malocclusion
- Reverse anterior overjet.
- Retruded upper lip
- Deficiency of paranasal area
- Inadequate tooth exposure during smile
- Prominent chin.



The Primary Technique for correction of maxillary deficiency is the LeFort I osteotomy, used for advancement of the maxilla.



Vertical Maxillary Deficiency

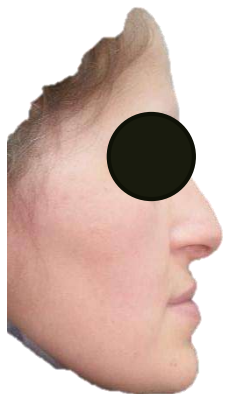
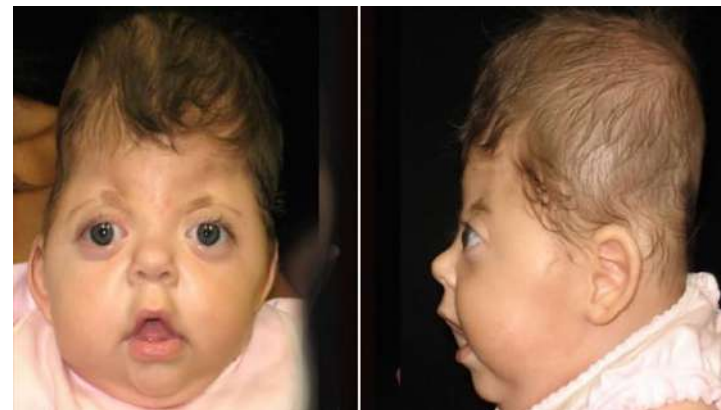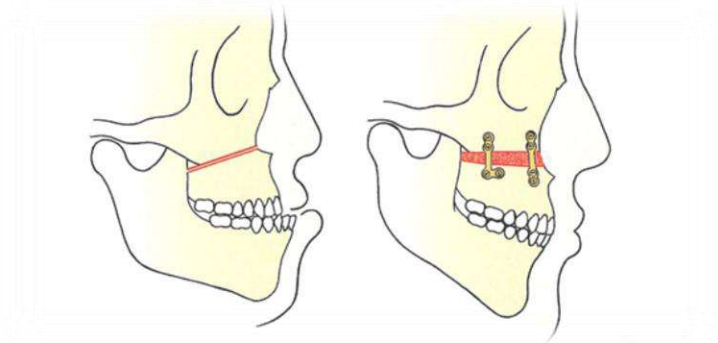


LeFort I set-down (inferior positioning), with bone graft

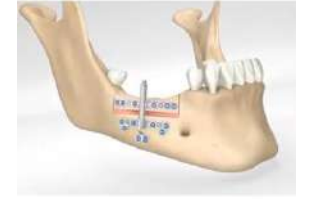
in patients with Class III malocclusions, the jaw blamed by the patients is the mandible, where as **the problem is actually maxillary deficiency**.

In severe midface deformities with infraorbital rim and malar eminence deficiency, a LeFort III osteotomy is indicated (set forward and set down).

Mostly required in craniofacial deformities such as Apert's or Crouzon's syndrome.



Distraction Osteogenesis (DO)

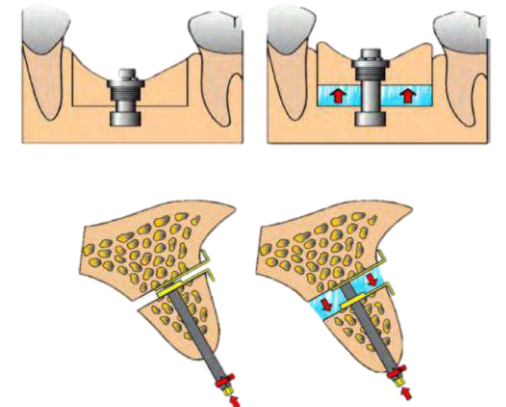


An approach to correct deficiencies in bone by a special appliance.

A Russian orthopaedic surgeon, Gavril Ilizarov, developed this current concept in 1950s.

DO facilitate the **Gradual and Incremental separation** of osteotomized bony segments.

The gradual tension placed on the distracting bony interface produces **continuous bone formation and adaptive changes** in all surrounding tissues, including muscles and tendons, nerves, cartilage, blood vessels, and skin, so DO also called **Distraction Histogenesis**.



Phases of DO : Osteotomy or Surgical, Latency, Distraction, Consolidation, Appliance Removal, and Remodeling.

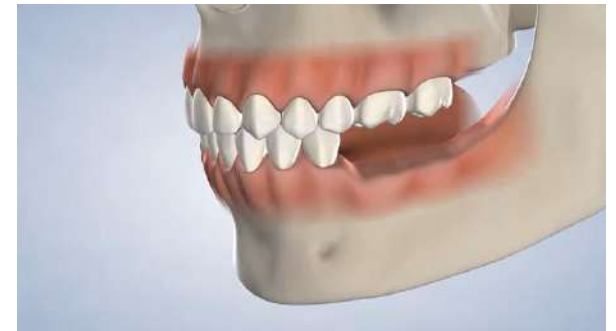In **Surgical Phase** an osteotomy is completed and the distraction appliance is secured.

In **Latency Period** early stages of bone healing begin to take place at the osteotomy site. It is generally 7 days during which the appliance is not activated.

In **Distraction Phase** activating the appliance 0.5 mm twice each day.

In **Consolidation Phase** the appliance remains in place, allowing for mineralization.

Remodeling period the period from the application of normal functional loads to the complete maturation of the bone.



Advantages

Larger skeletal movements,
Elimination of the need for bone grafts,
Better long-term stability,
Less trauma to the TMJs,
Decreased neurosensory loss.

Disadvantages

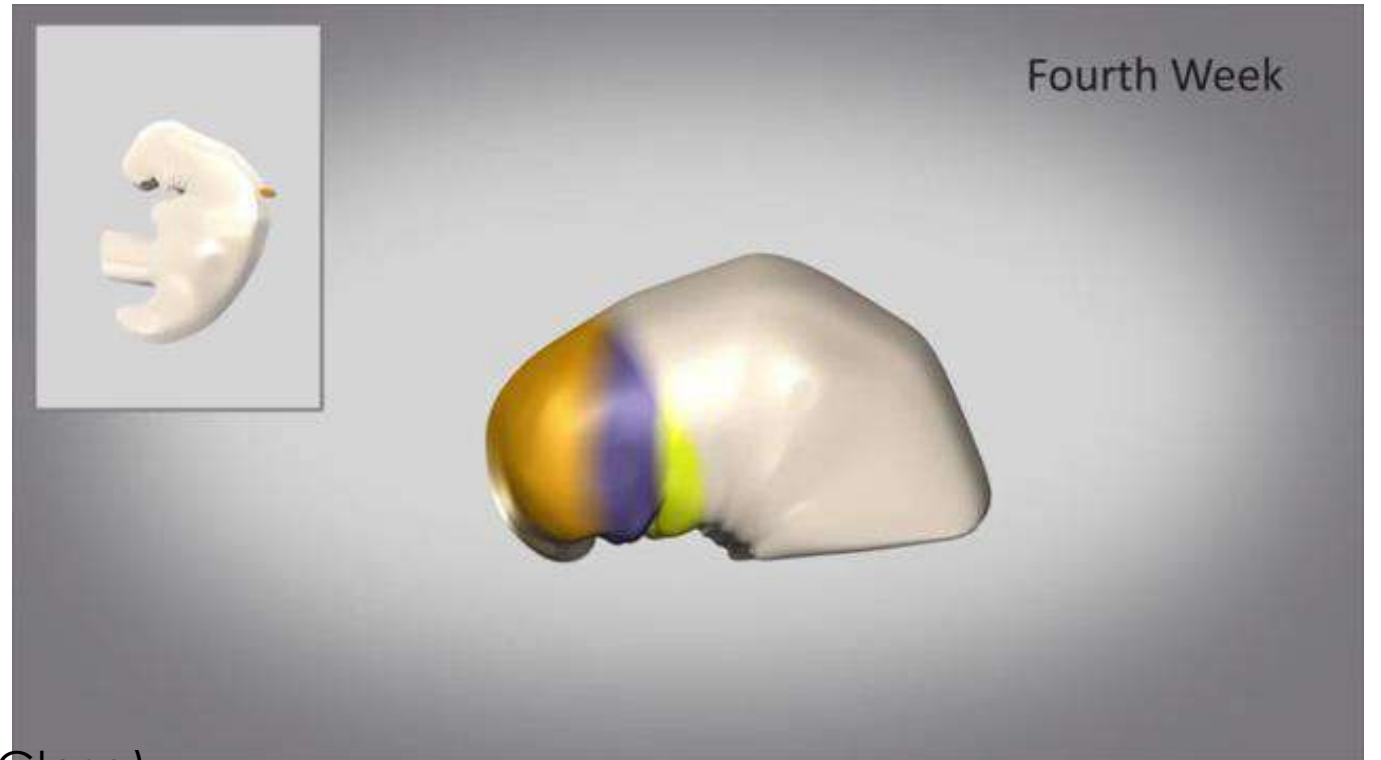
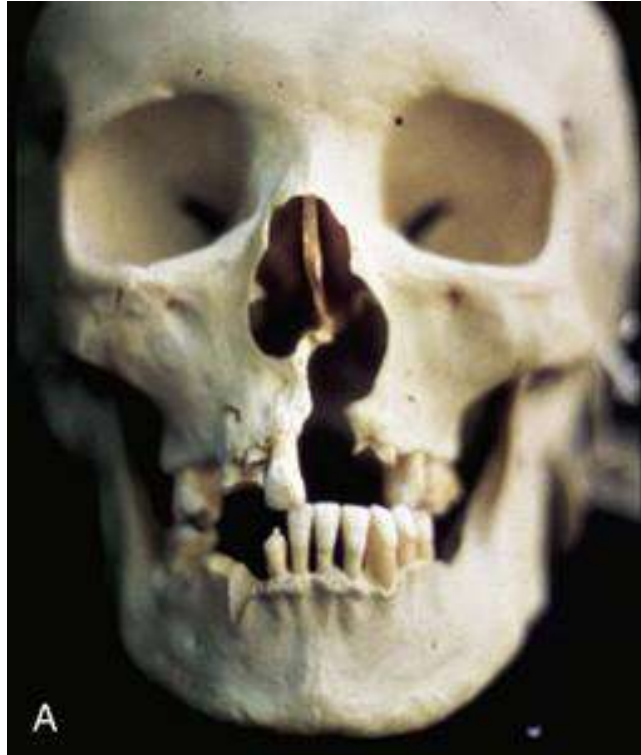
Technique Sensitive

Discrepancies in occlusal positioning, resulting in (small open bites or asymmetries).

the need for two procedures: placement and removal of the distractors

increased cost and longer treatment time, with more frequent appointments with the surgeon and the orthodontist.

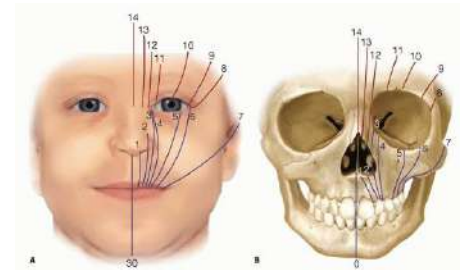
Cleft Lip and Palate (CLP)



Bashar Abdul-Ghani

FICMS. MaxFacs Cons. MFDS. RCSED. RCPS (Glasg).

- ▶ Cleft lip and palate (CLP) refers to a clinical spectrum of cleft lip (CL) with or without associated cleft palate (CP) or isolated cleft palate (CP).
- ▶ The estimated incidence (CLP) ranges from 1:500 live births to 1:2000 live births.
- ▶ Isolated CL is reported in 21%-25% of the cases.
- ▶ Isolated CP is reported in 33%-40% of the cases.
- ▶ CLP is reported in 35%-46%.
- ▶ Unilateral clefts X 9 times more than bilateral, more on left side than right.
- ▶ Males are predominant in CLP, whereas Females commonly with isolated CP.
- ▶ CLP can be associated with syndromes such as hemifacial microsomia.

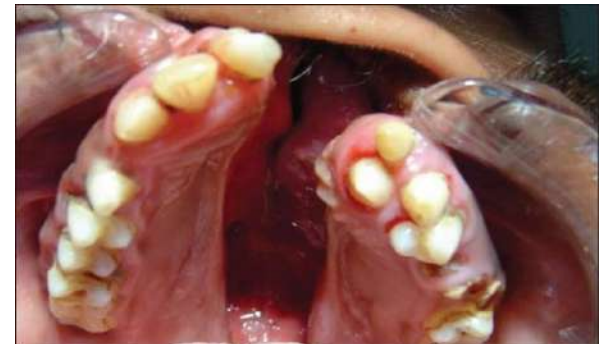

Etiology

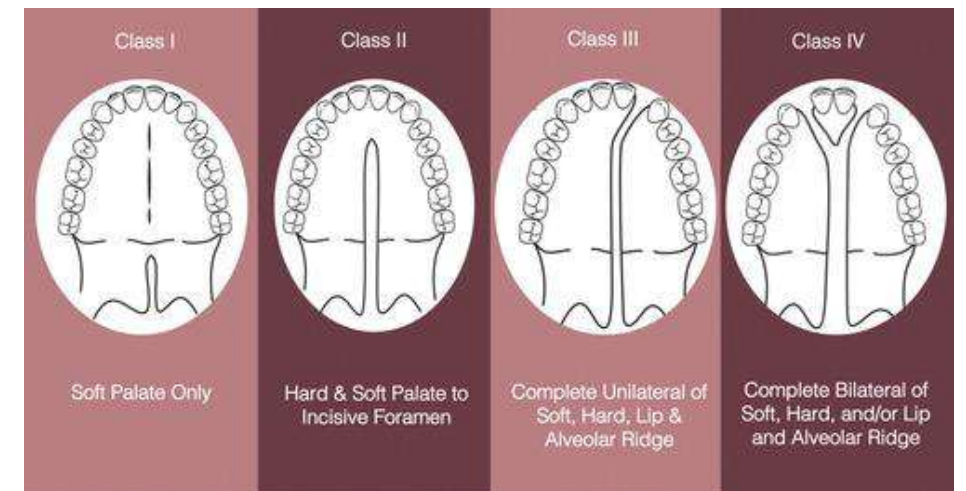
- ▶ It is thought to be of a multifactorial etiology with a number of potential environmental and genetic contributing factors.
- ▶ The environmental factors include; Smoking, Alcohol, Anticonvulsants, Steroids, Folic Acid Deficiency, Hypoxia, Retinoids, Radiation, Viral.

Classification - the description of CLP phenotypes should include

1. The Laterality (unilateral/bilateral/median) and Severity (complete/ incomplete).
2. Existence of an Alveolar Defect.
3. Morphological characterization of the Palatal Defect

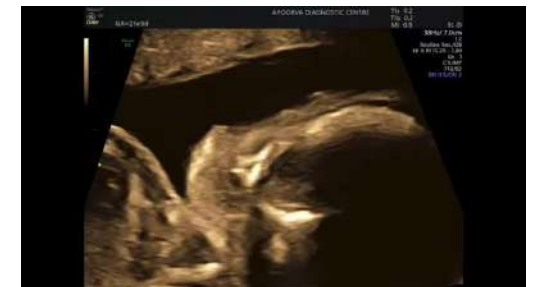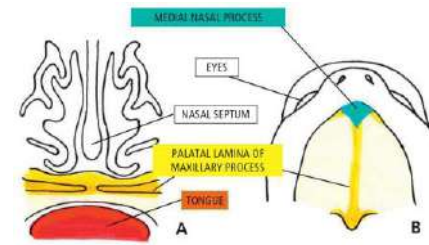
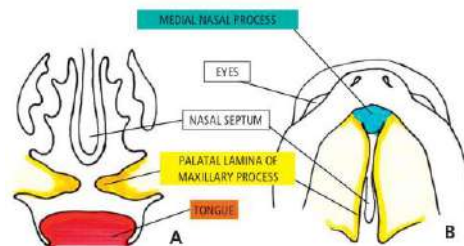
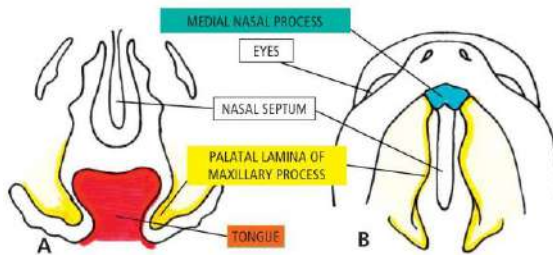
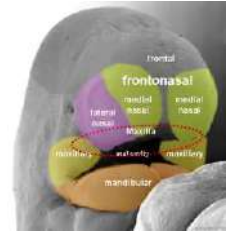


- ▶ Most accepted classification of palatal defects is that of Victor Veau, introduced in 1931:
- ▶ Group 1; Cleft of soft palate only.
- ▶ Group 2; Cleft of hard and soft palate up to the incisive foramen, involving secondary palate alone.
- ▶ Group 3; Complete unilateral cleft, extending from uvula to the incisive foramen in midline, then deviating to one side and extending through the alveolus at the position of the future lateral incisor tooth.
- ▶ Group 4; Complete bilateral cleft, same as group 3 with two clefts extending forward from the incisive foramen through the alveolus.



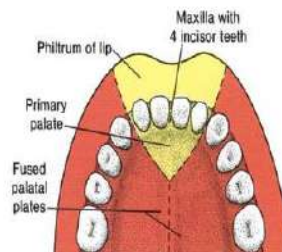
Prenatal Diagnosis

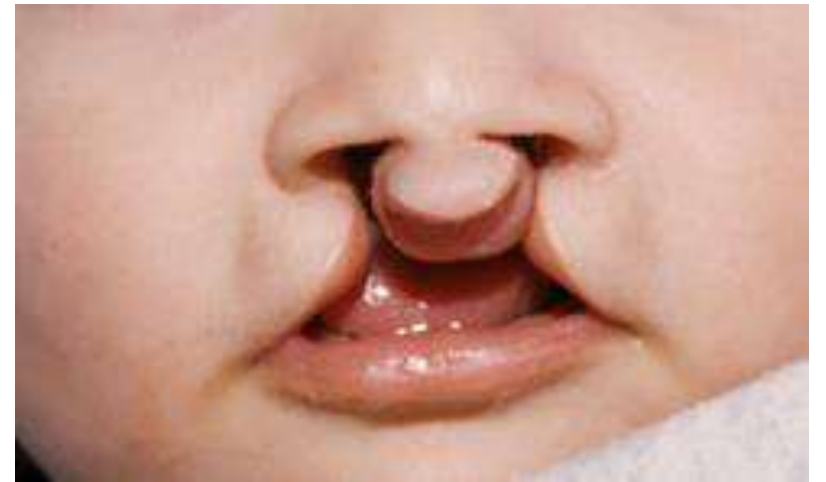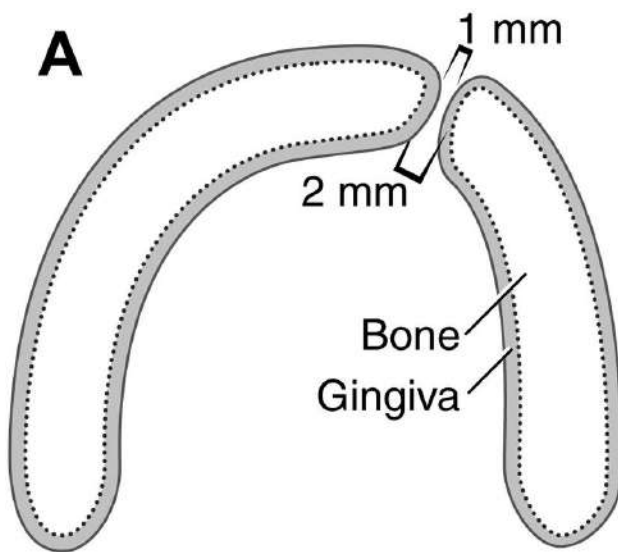
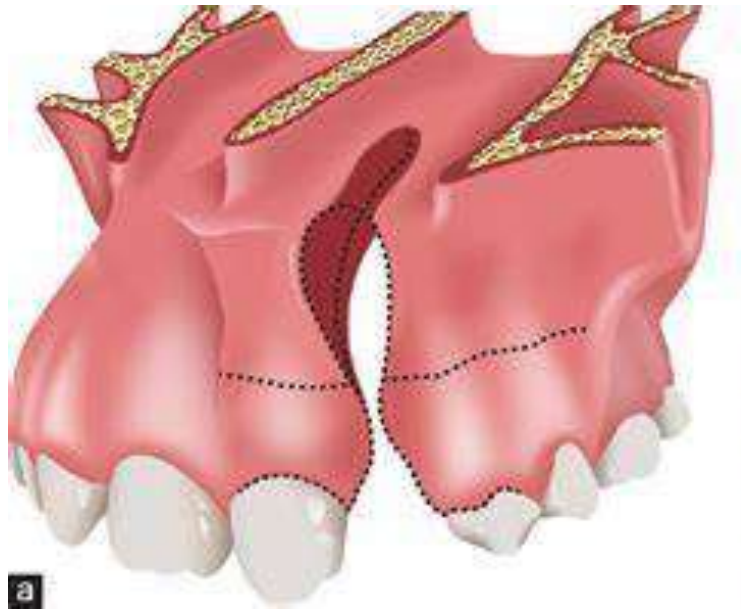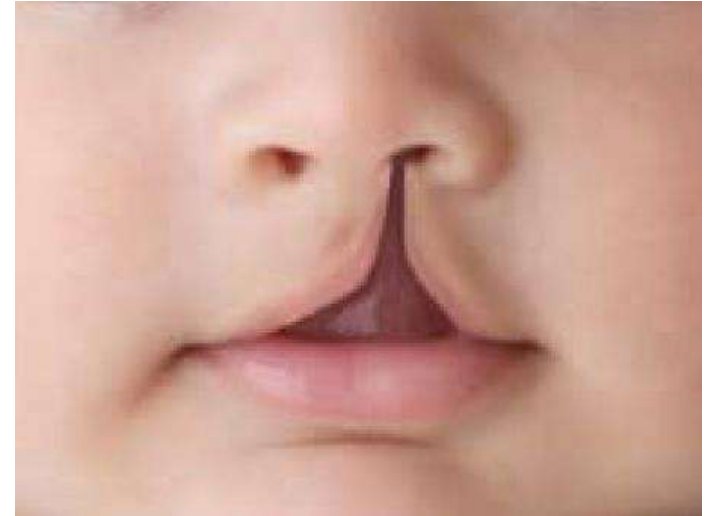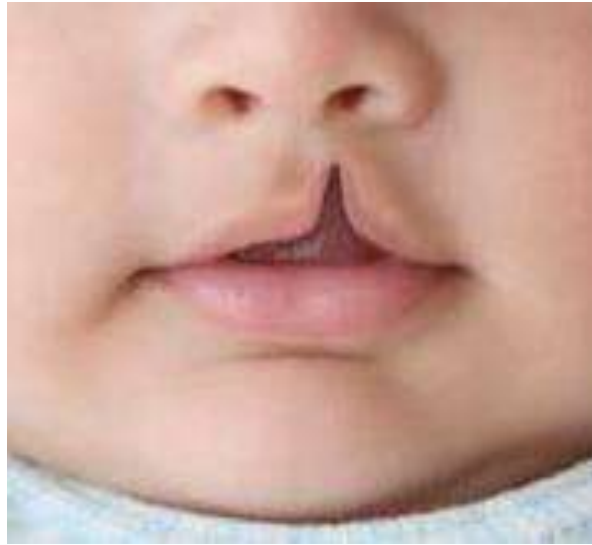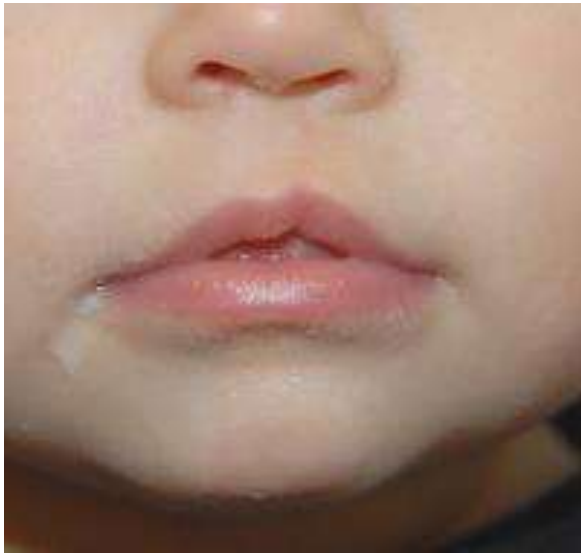- ▶ The lip forms between 4 – 7 weeks of pregnancy
- ▶ The palate is formed between 6 - 9 weeks of pregnancy
- ▶ **Ultrasound imaging** of CL can be **visualized 12-16 weeks**, whereas CP is difficult to acquire.
- ▶ Genetic factor should be offered to parents especially in syndromic cases.
- ▶ The risk of having a second child with CLP is 2-4%,
- ▶ Increases to 10% when 2 previous children had CLP.
- ▶ When one parent and one child had CLP the risk is 17%.



Clinical Manifestations

- ▶ Cleft Lip may be **Microform, Incomplete or Complete**. Complete cleft lips are often associated with an alveolar cleft.
- ▶ In unilateral CL there is rotation and distortion of the vermillion with loss of Cupid's bow and philtral landmarks on the cleft side.
- ▶ In bilateral CL, **the premaxilla grows independently of the maxilla** and may protrude considerably,
- ▶ The spectrum of CP ranges from a **submucous cleft to complete clefting** of the primary and secondary palate.
- ▶ CP is primarily characterized by disorientation of palatal muscles which lead to **feeding difficulties, velopharyngeal insufficiency, and speech problems.**





Management

- ▶ Successful management of the child born with CLP requires coordinated care provided by a number of different specialties including oral and maxillofacial surgery, plastic surgery, ENT, genetics, speech therapy, orthodontics, prosthodontics and others. (MDT clinic)

Specific goals of treatment include the following:

- Normalized esthetic appearance of the lip and nose
- Intact primary and secondary palate
- Normal speech, language, and hearing
- Nasal airway patency
- Class I occlusion with normal masticatory function
- Good dental and periodontal health
- Normal psychosocial development

The Management of CLP patients can be divided into:

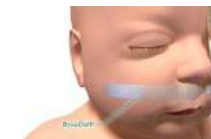1. Preoperative management.
2. Primary operative management.
3. Secondary operative management.

Preoperative Management

Feeding

- ▶ One of the major concerns in Infants with cleft palate.
- ▶ It is not very critical in children with isolated CL.
- ▶ Specialized bottles are necessary to improve feeding.



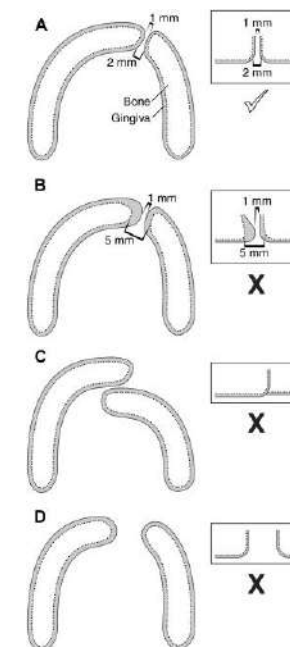
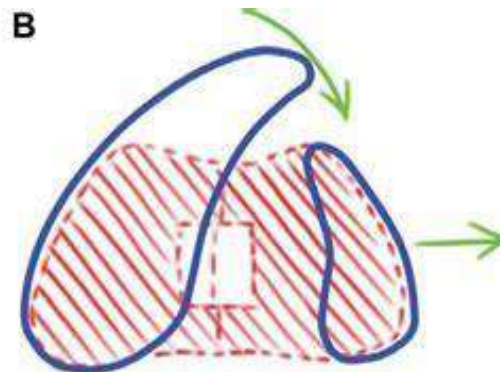
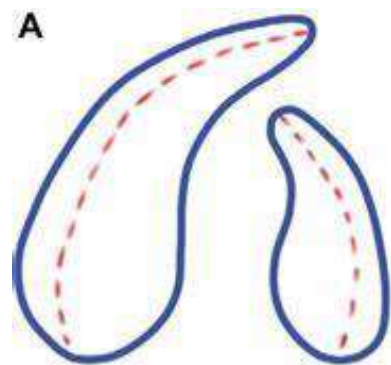


Pre-Surgical Orthopedics (PSO)

- ▶ Device to mold the perioral structures to **reposition the nasolabial and maxillary segments closer to each other.**
- ▶ It is mainly used in the first few weeks after birth and in the months prior to palate repair.

Examples of PSO are:

- ▶ **Alveolar molding**
- ▶ **Lip strap/lip taping**
- ▶ **Nasoalveolar molding (NAM)**



Primary Operative Management

Treatment planning and timing

- ▶ The timing of CLP repair is controversial.
- ▶ The decision to surgically manipulate the tissues of the growing child should take into account the possible growth restriction that can occur with early surgery.
- ▶ The safest time period for surgery outlined by the “rule of 10’s.”
- ▶ This referred to the idea of delaying lip repair until the child was at least 10 weeks old, 10 pounds in weight, and minimum hemoglobin value of 10 g/dl.

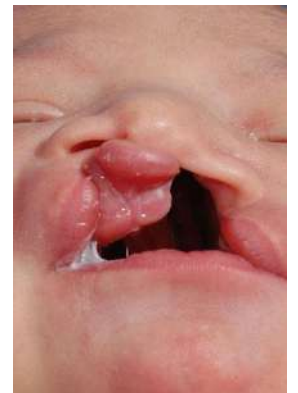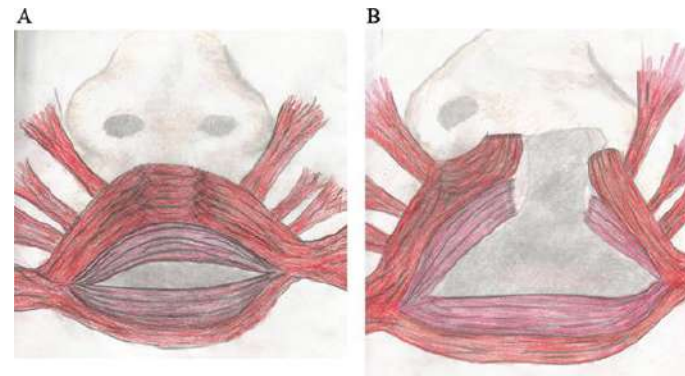
Procedure	Timing
CL repair	After 10 weeks
CP repair	9-18 months
Pharyngeal flap or pharyngoplasty	3-5 years or later based on speech development
Alveolar reconstruction	6-9 years based on dental development
Orthognathic surgery	14-16 years in girls, 16-18 years in boys
Rhinoplasty	After age 5 years but preferably at skeletal maturity; after orthognathic surgery when possible
Lip revision	Anytime once initial remodeling and scar maturation is complete but best performed after age 5 years

Surgical Procedures for CL

- ▶ The aim of the repair is to create a three-layered closure of skin, muscle, and mucosa
- ▶ Numerous techniques, as well as modifications to popular techniques, have been extensively described in the literature

Lip Adhesion

- ▶ Surgically approximate the segments of the wide bilateral cleft lip prior to definitive lip repair by sewing the edges together between 6 weeks and 3 months of age.
- ▶ It is usually used in wide bilateral clefts.
- ▶ The definitive lip repair is 3-9 months later.



Straight Line Repair (Rose-Thompson closure)

- ▶ It is rarely used as primary technique for cleft repair as it results in notching of the lip and vertical scar contracture.

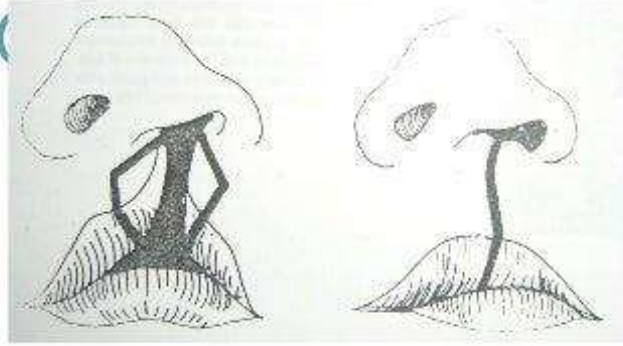
Tennison-Randall triangular flap repair

- ▶ It utilizes the interdigitation of triangular flaps (geometric design). The concept underlying the technique can be similarly compared to a Z-plasty reconstruction of the lip. This technique is based on careful measurements of specific landmarks.

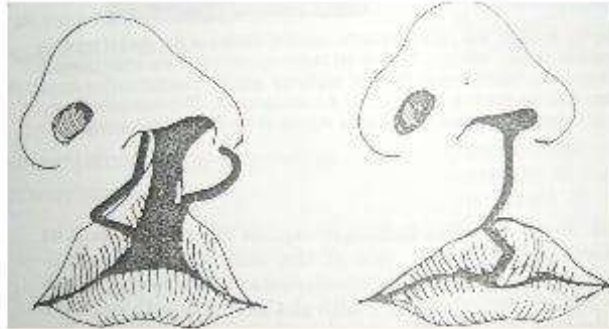
Millard's Rotation- Advancement Flap Repair

- ▶ It is the most used technique.
- ▶ The technique utilizes downward rotation of the superiorly displaced medial lip segment with advancement of the lateral lip flap to correct the defect below the nose.

- Rose (1891) and Thompson (1912) described angled excisions of short cleft edges to obtain length with closure

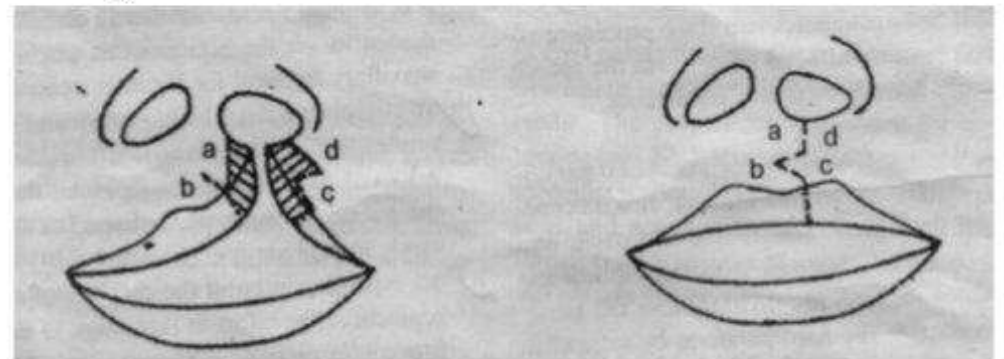


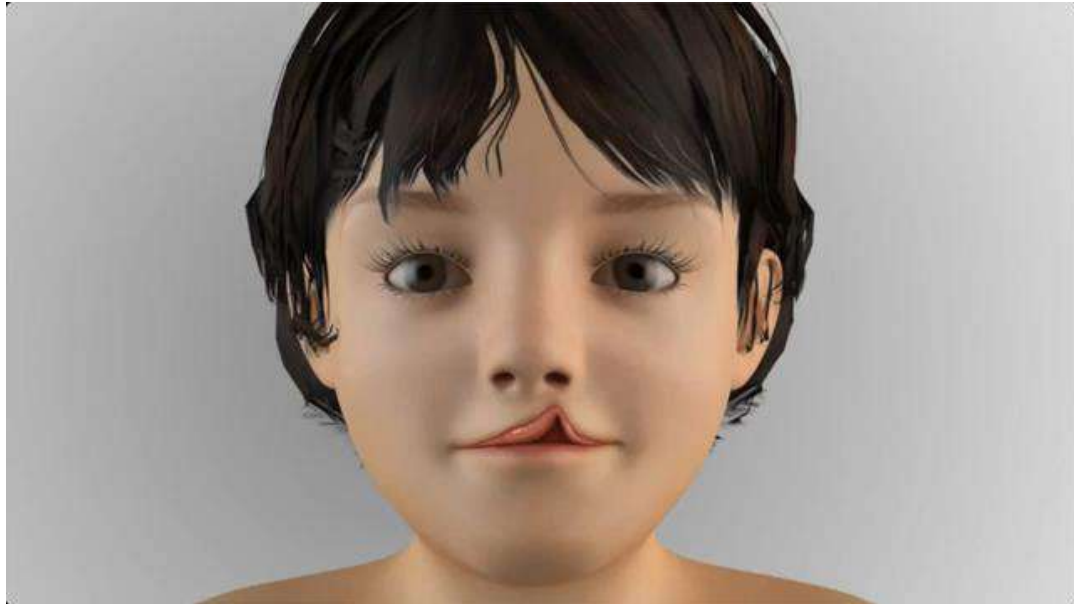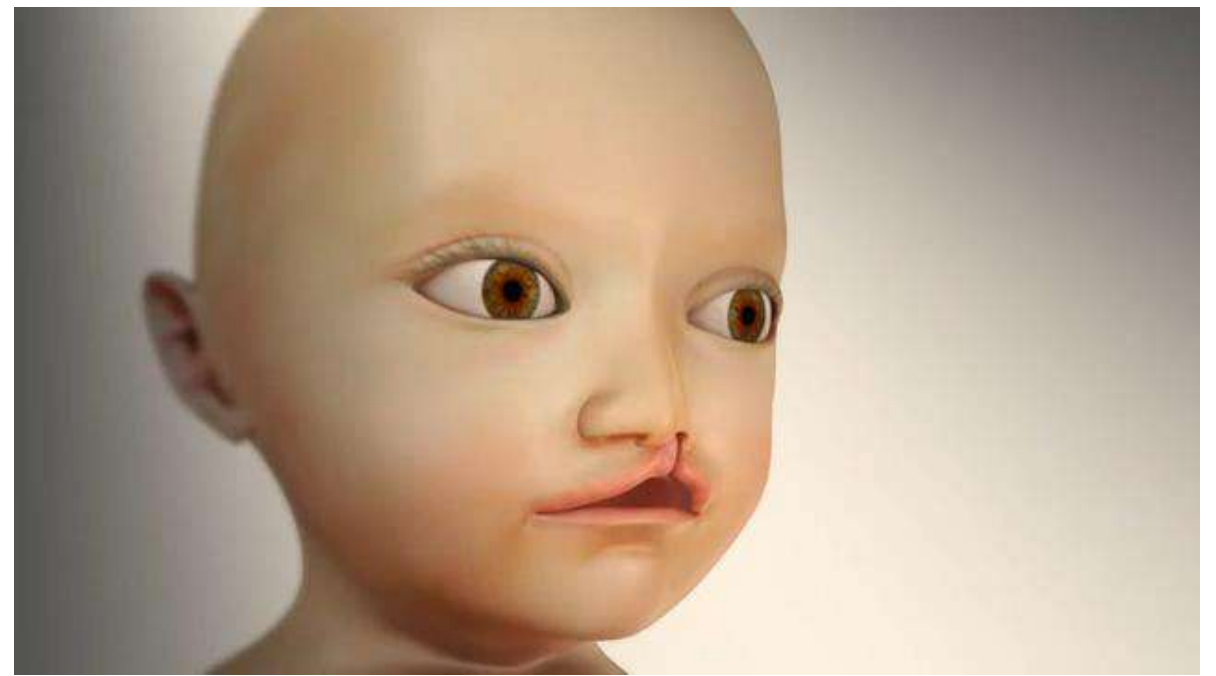

- Mirault (1844) described lateral inferior triangular flap to be approximated to a medial paring



Tennison Randall repairs

- A triangular flap is created on the lateral side of the cleft to fit in to the triangular defect produced on the medial side of the cleft. This procedure can be planned exactly after initially measurements. The results cannot be modified once the lip is cut. The scar is more prominent than in other procedures.



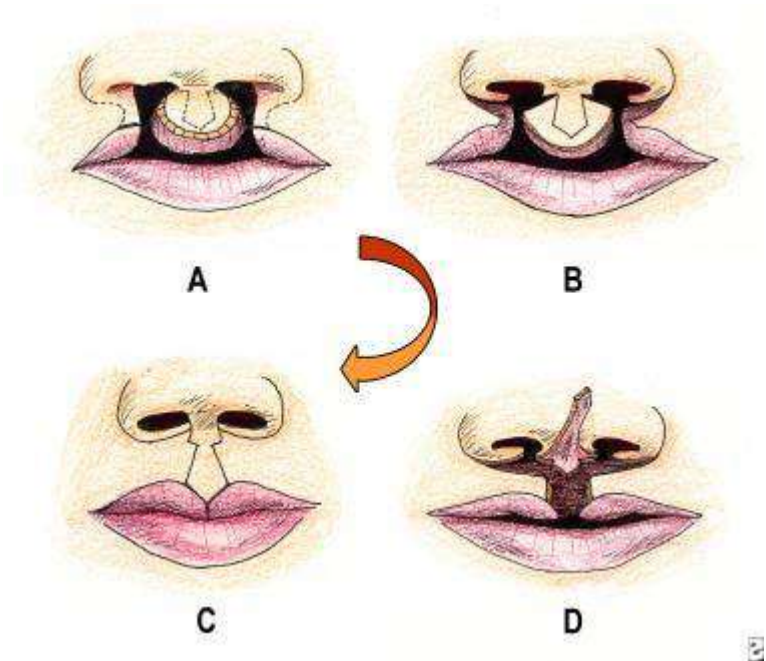


Millard Unilateral Cleft

A Left unilateral complete cleft lip is repaired with the Millard technique.

Bilateral CL Repair

- ▶ It is difficult than the unilateral CL repair due to the presence of the premaxilla and prolabium.
- ▶ Infant orthopedics, Nasoalveolar molding, and taping of the lip can be considered as an option with any of the techniques described earlier.



Surgical Procedures for CP

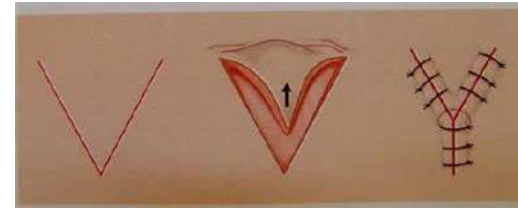
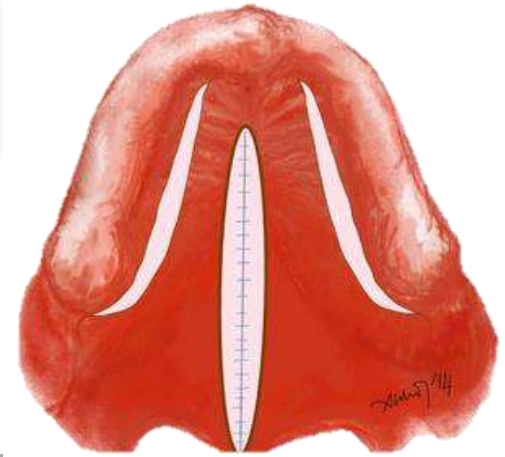
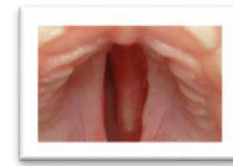

- ▶ Reconstruct the defect in a layered fashion.
- ▶ The hard palate is closed in two layers using nasal and then oral mucosa flaps.
- ▶ The soft palate is closed in three layers : Nasal Mucosa, Velar Musculature, and Oral Mucosa, so reconstruct the musculature of the velopharyngeal mechanism.
- ▶ Both the hard and soft palate repairs must be done in a tension-free manner to avoid wound breakdown and fistula formation.



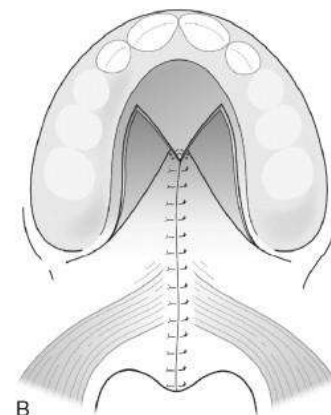
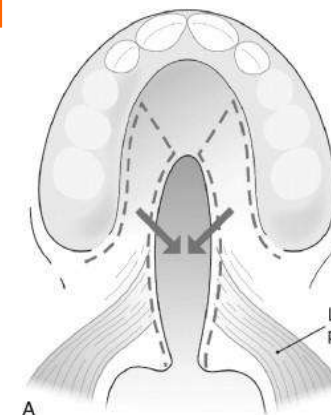
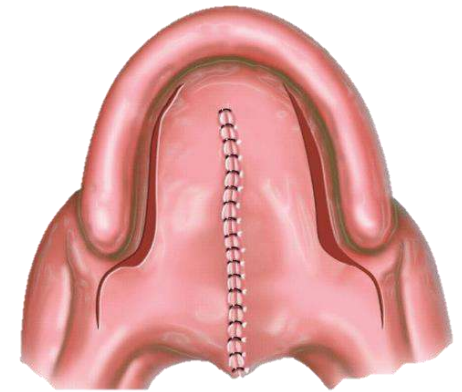
Von Langenbeck Technique

- ▶ Bipedicled flaps on both sides of the cleft. The nasal side is closed first, then the bipedicled flaps are approximated to cover the oral surface of the cleft.
- ▶ It results in insufficient length of the soft palate



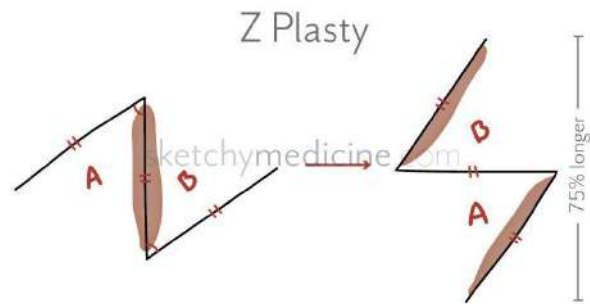
V-Y Pushback Technique

- ▶ It has the advantage of lengthening the palate and repositioning the levator muscle in a more favorable position.
- ▶ The technique involves extensive dissection and the denuded palatal bone.
- ▶ This technique also has a higher rate of fistula in complete cleft palate.



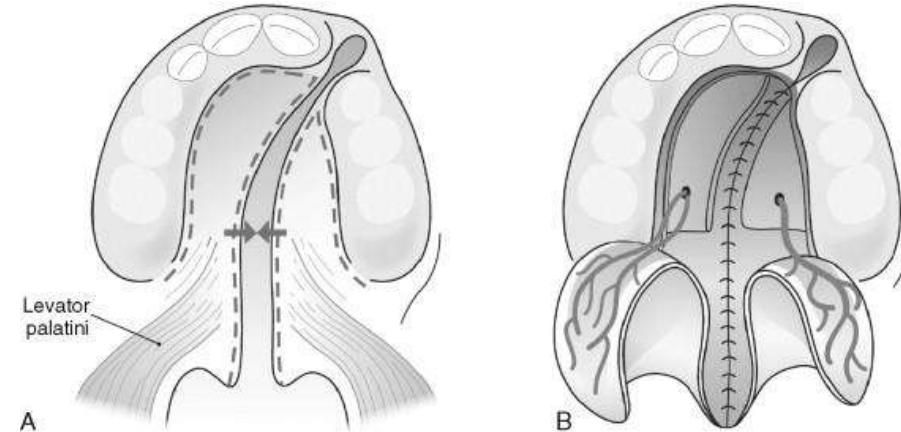
Two-flap technique

- ▶ Full-thickness mucoperiosteal flap is elevated on each side of the cleft, which preserves the palatal neurovascular bundle.



The Furlow technique

- ▶ It essentially consists of repairing palatal clefts using Z-plasty of oral and nasal mucosa.
- ▶ The advantage is that the soft palate may be lengthened while preventing longitudinal scar contracture and palatal shortening.



Postoperative care

- Normal feeding can be resumed as soon as the infant is stable.
- Elbow immobilizers may be used.
- Regular follow-up.

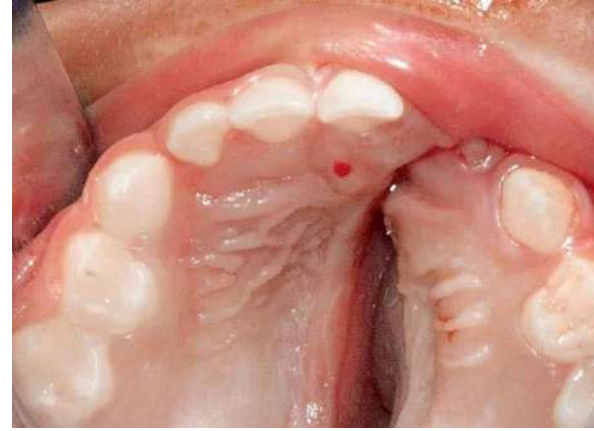Complications - Immediate Complications include

- Repair Breakdown due to tension, Palatal ischemia, Secondary trauma, Bleeding.
- It may result in the formation of an Oronasal Fistula.
- Long-term complications include Midface Growth Deficiency, Velopharyngeal Incompetence, Recurrent Fistula, and Sleep Apnea.

Secondary Operative Management

Alveolar bone grafting - Aims of alveolar bone reconstruction

1. To provide bone support for teeth adjacent to the cleft.
2. To close the remaining oronasal fistula.
3. To improve support of the nasal alar base and lip on the affected side(s).
4. To allow normal eruption of the permanent teeth in the cleft area
5. To create appropriate ridge form for optimization of orthodontic alignment.
6. To allow for stabilization of the premaxilla and continuity of the maxilla.
7. To improve nasal symmetry.
8. To provide support for the upper lip.



Timing of the alveolar bone reconstruction :

- ▶ Primary (Early) Grafting; performed at age younger than 2 years.

This phase associated with moderate to severe long-term maxillary growth restriction.

- ▶ Secondary (Delayed) Grafting; divided into:

1- Early Secondary; before the eruption of the permanent incisor teeth (3-6 years). The literature does not support early secondary grafting.

2- Secondary (mixed dentition); before the eruption of the maxillary canine, (6-12 years),

- it can also be divided into **early (6-8 years) (preferred)** and late (8-12 years).
 - Ideally the patient is between the ages of 8 and 12 years with a maxillary canine root that is one half to two thirds developed.
- ▶ **Late grafting**; after 12 or 13 years of age, after the eruption of the permanent canine.

Common Presenting Problems of oronasal fistula.

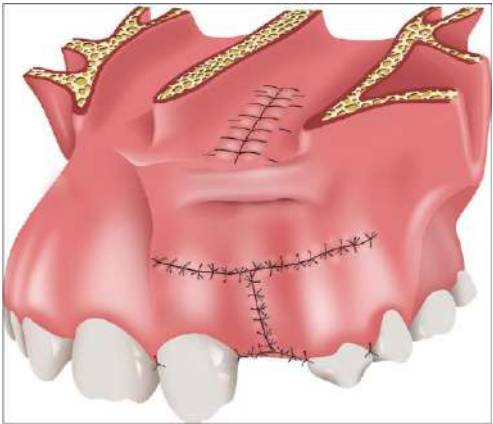
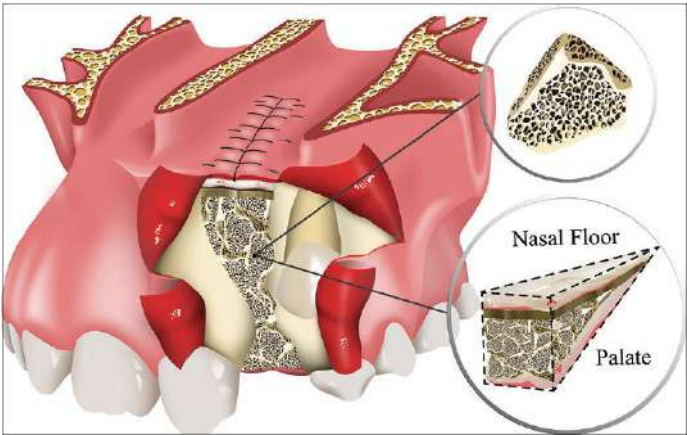
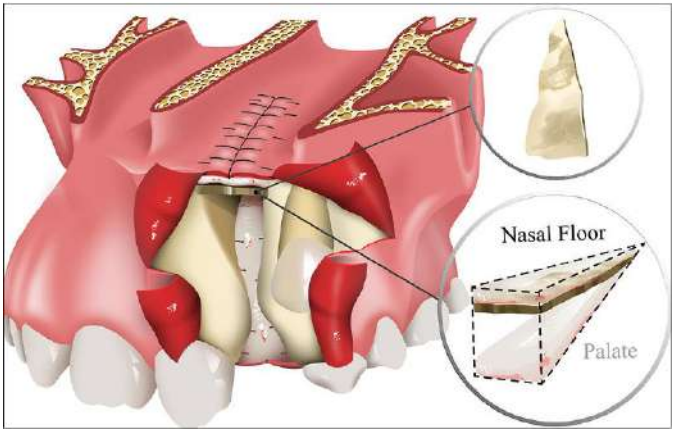
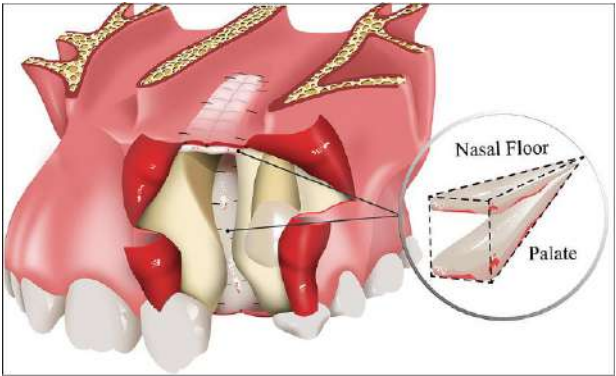
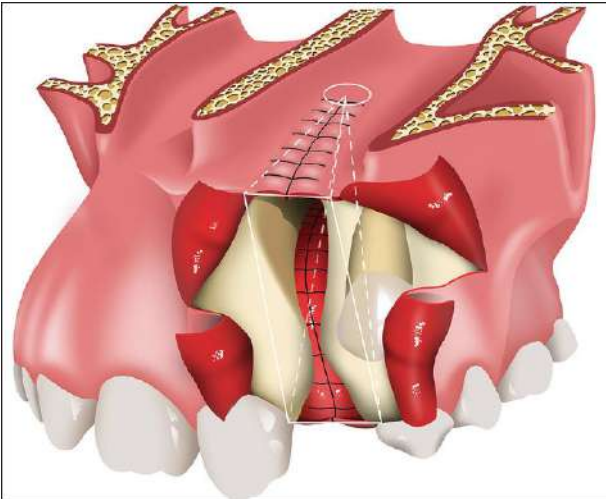
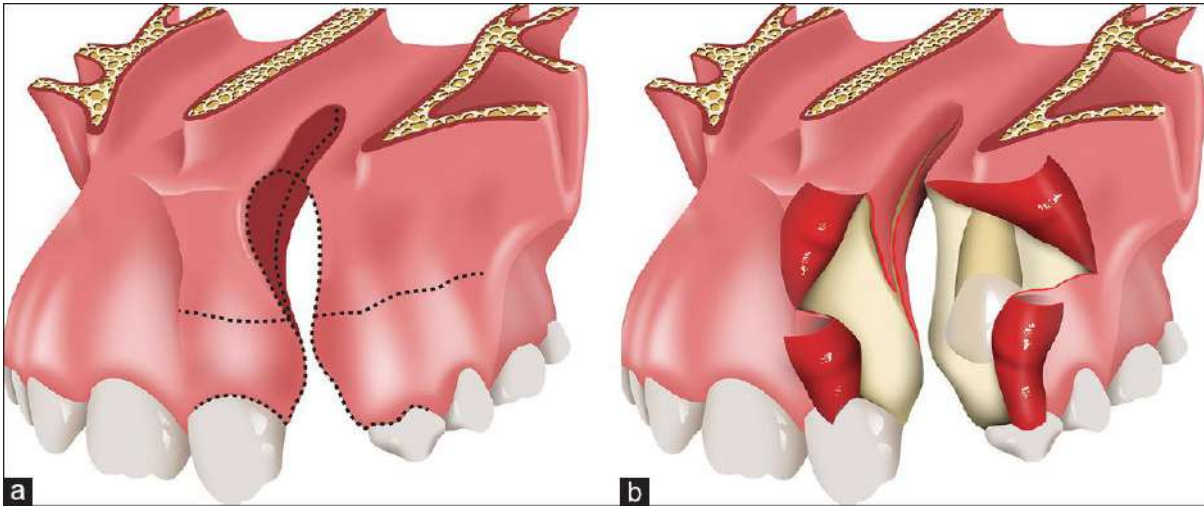
1. Discharge and smell from the nose.
2. Food/fluids leaking from the nose.
3. Poor speech.
4. Inability to blow up.
5. Poor appearance of the incisor teeth.
6. Missing or supernumerary teeth within the cleft area.
7. Difficulty cleaning teeth in the cleft area.
8. Poor facial appearance.

Assessment of the Patient

- ▶ History and clinical examination \ Presence of supernumerary teeth
- ▶ Meticulous dental care of caries and PD disease
- ▶ Extraction of hopeless teeth to prepare the cleft site for bone grafting.
- ▶ Radiographic examination : Panoramic (OPG), Occlusal and Periapical Films.
- ▶ CBCT is important for both pre and post operative to accurately assess the volume of successfully grafted bone.
- ▶ Study models are obtained.
- ▶ Orthodontic treatment required to align the maxillary arch in preparation for the bone graft.

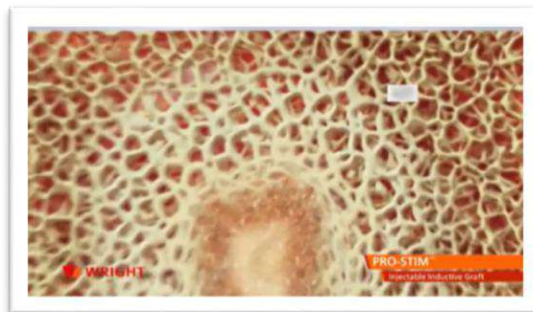
Procedure

- ▶ Full-thickness buccal and palatal mucoperiosteal flaps,
- ▶ Nasal mucosa reflected and sutured
- ▶ Palatal flaps closed.
- ▶ The graft material placed into the cleft
- ▶ Labial flaps advanced, and sutured.
 - release the periosteum to obtain a tension-free labial flaps closure.
 - It is best to use a resorbable monofilament suture.



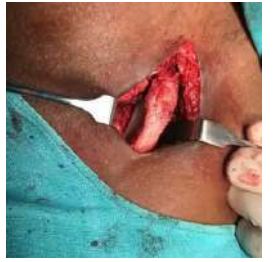Sources of Bone Graft Materials

- ▶ Autogenous, allogeneic, and xenogeneic bone materials have been used.
- ▶ Autologous cancellous bone is the ideal bone graft source.
- ▶ Both cortical and cancellous bones used, but cancellous bone is better because of **cell transfer and revascularization** in osteoinduction and osteoconduction.



Iliac Crest; is the most commonly used bone in bone grafting because

- it is easy to harvest
- it can provide a large amount of cancellous bone
- cleft preparation can be performed at the same time.



The Disadvantages : possible scar, postoperative pain, delayed ambulation, and risk of cutaneous nerve injury.

Cranium; it has little resorption, less postoperative pain, and a concealed scar.

The Disadvantages :

- long operative time,
- hematoma, seroma,
- dural tear, dural exposure,
- CSF leakage.

Tibia; it results in less bleeding, postoperative pain, operative time, and scarring.

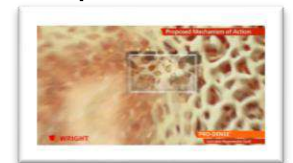- Disadvantages : it yields relatively small amounts of bone.
- Possibility of growth disturbance due to injury of the epiphyseal cartilage.

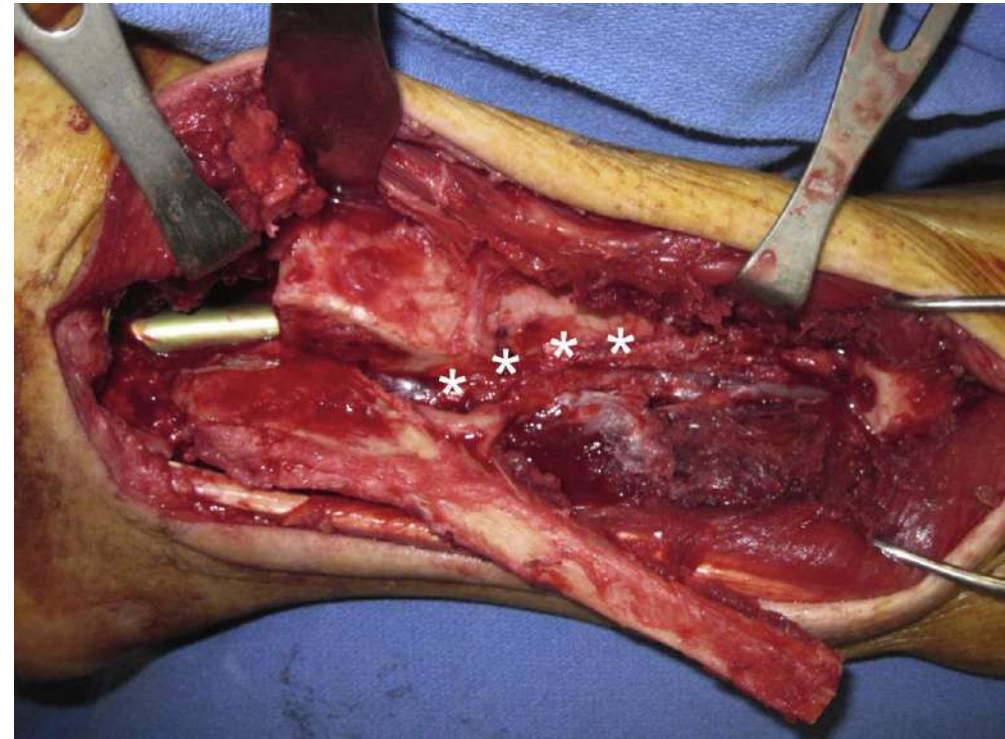
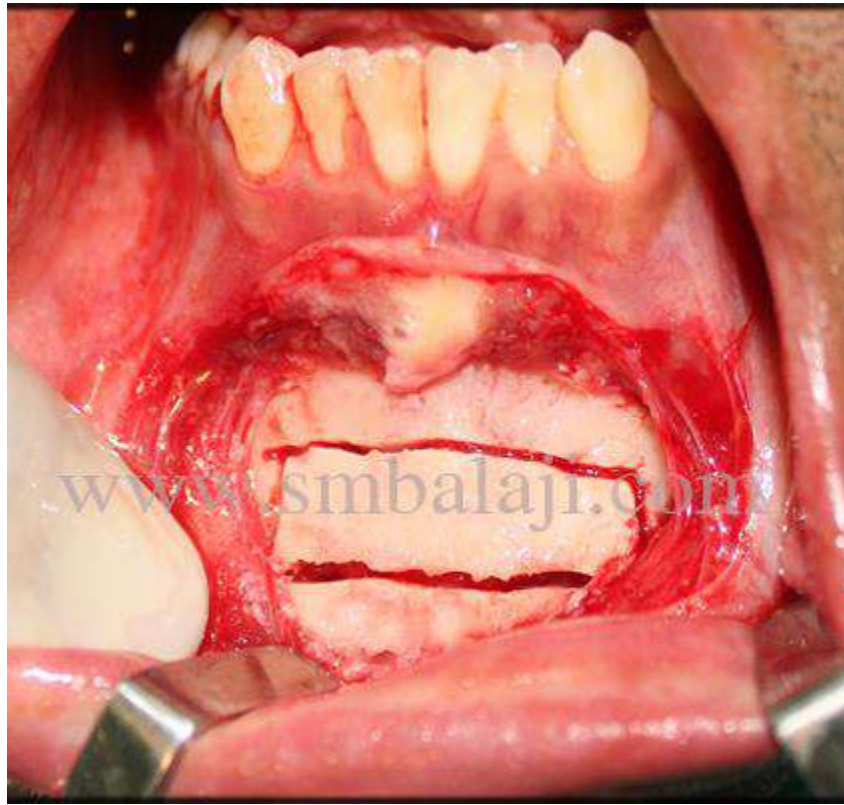Mandibular Symphysis;

- ▶ the mandible has the same embryonic origin as the maxilla which may contribute to low resorption, surgery is in the same operative field and postoperative discomfort is reduced.
- ▶ There is a risk of roots and mental nerve damage, and the amount that can be collected depends on the development of the mandible.

Bone Graft Substitutes; including hydroxyapatite (HA) or tricalcium phosphate (TCP).

- ▶ Recently the addition of growth factors such as platelet-rich plasma (PRP) and platelet rich fibrin (PRF) with graft materials have used.





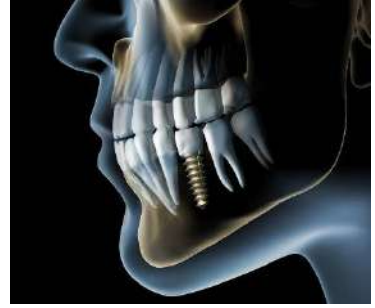Postoperative care

- ▶ Antibiotics for 7-10 days
- ▶ Mouth wash, excellent oral hygiene and good nutrition,
- ▶ Liquid and soft diet for 2-3 weeks
- ▶ Avoid any trauma to the operative site.

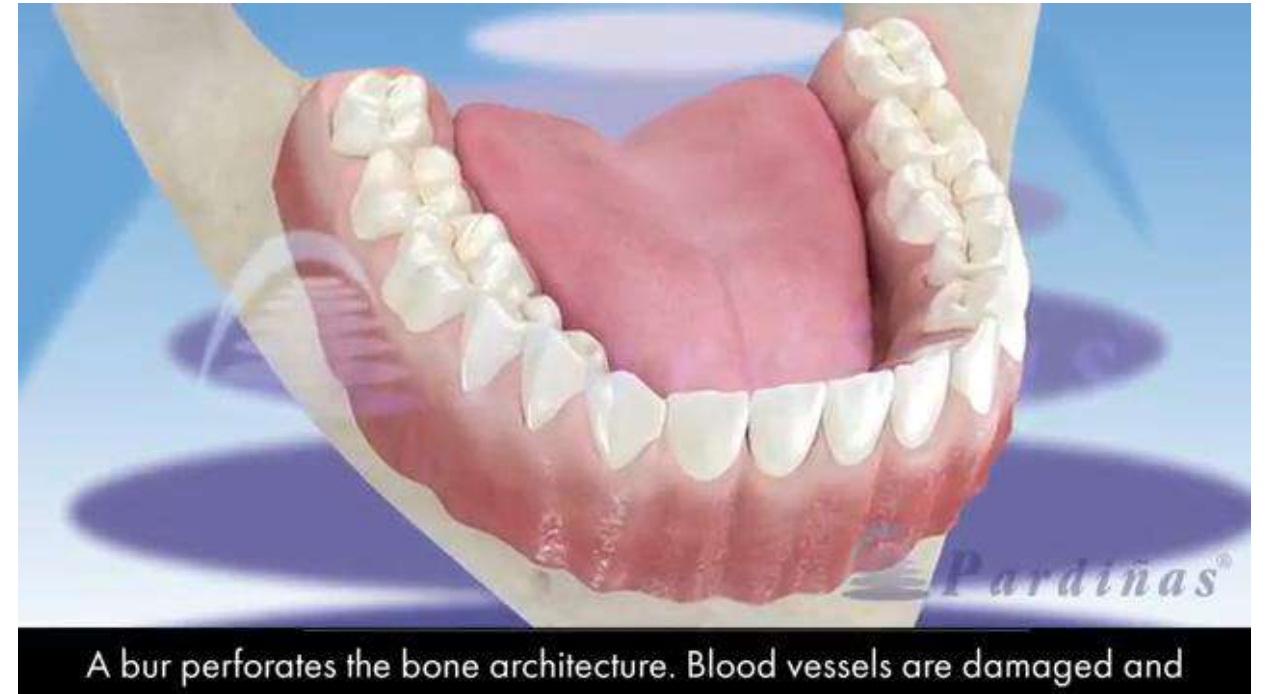Complications

- ▶ Wound dehiscence (managed by debridement and mouth washes).
- ▶ Infection (managed by antibiotics, debridement, daily irrigation)
- ▶ Persistent fistula (require subsequent procedures).

DENTAL IMPLANTOLOGY



Principles and Evaluation



Bashar Abdul-Ghani

FICMS. MaxFacs Cons. MFDS. RCSED. RCPS (Glasg).

Implant Treatment: Basic Concepts and Techniques

- In the 1950s, Brånemark, a Swedish professor of anatomy, had a accidental finding while studying blood circulation in bone that became a historical breakthrough in medicine.
- He call the phenomenon osseointegration and developed an implant system with a specific protocol to achieve it predictably.
- The first patient was successfully treated in 1965.

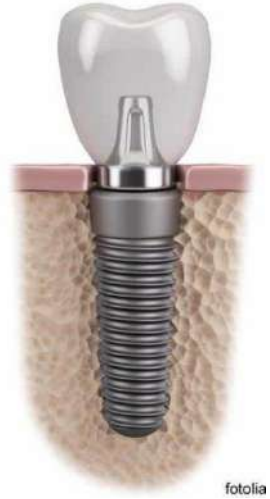
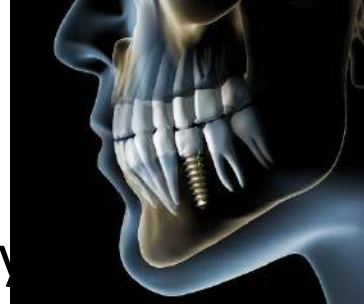
Implant Geometry (Macrodesign)

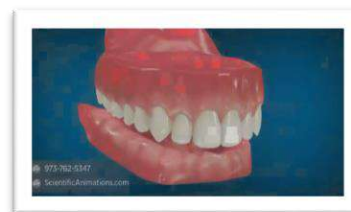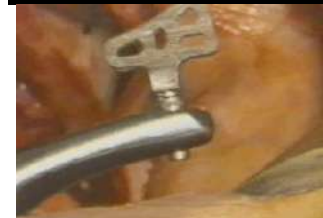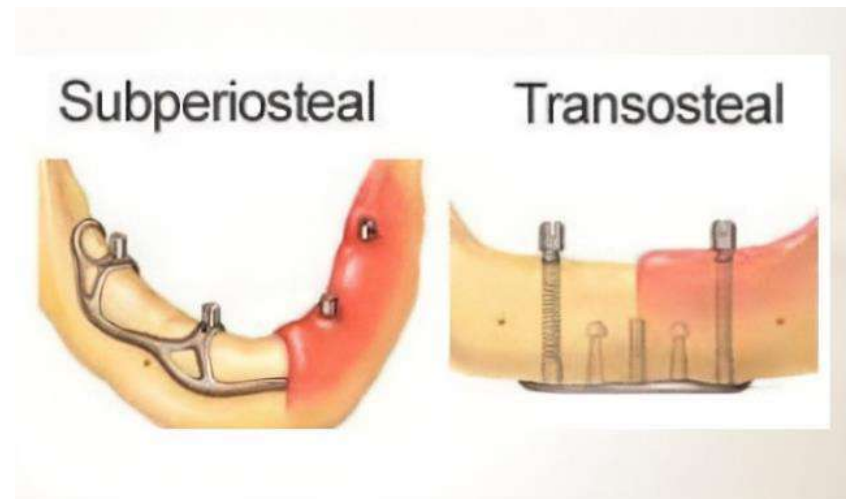
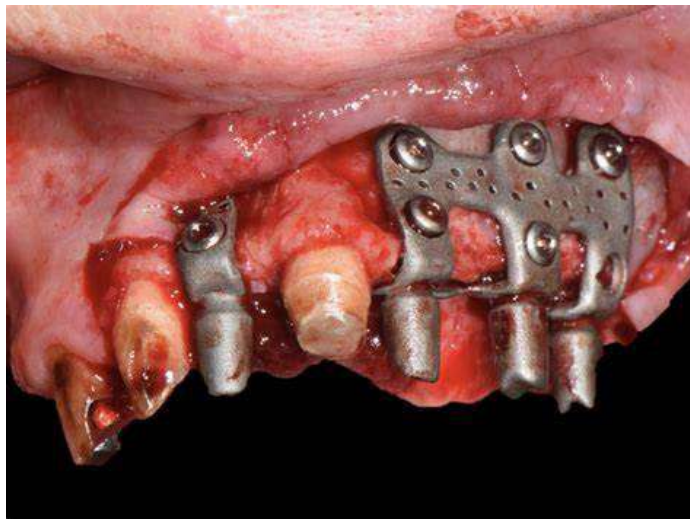
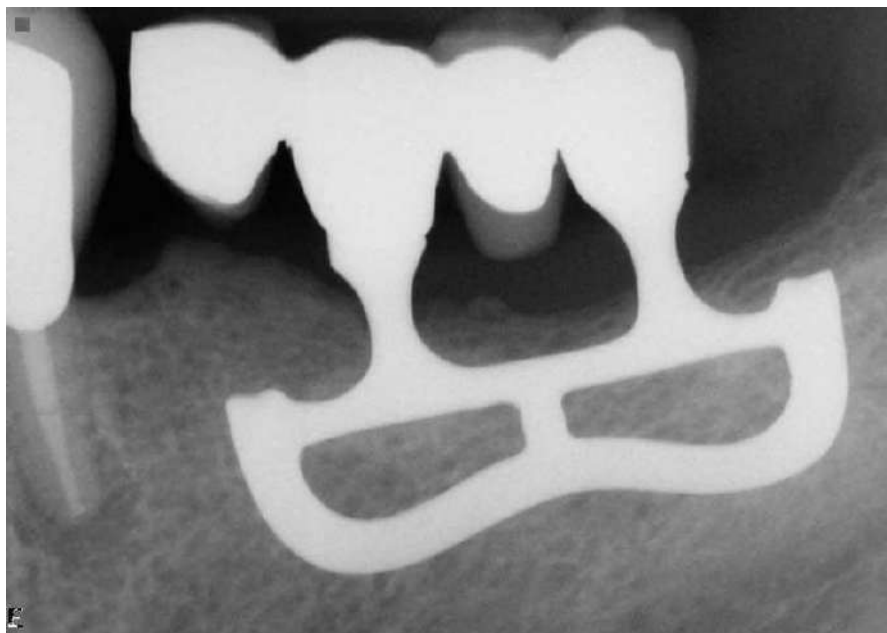
- **Blade vents** (narrow, flat shape; tapped into bony trough prepared with rotary)
- **Press-fit cylindrical** (bullet shape; pressed or tapped into prepared hole)
- **Subperiosteal** (custom-made framework; adapted to the surface of jawbone)
- **Transmandibular** (long rods or posts; placed through the anterior mandible).

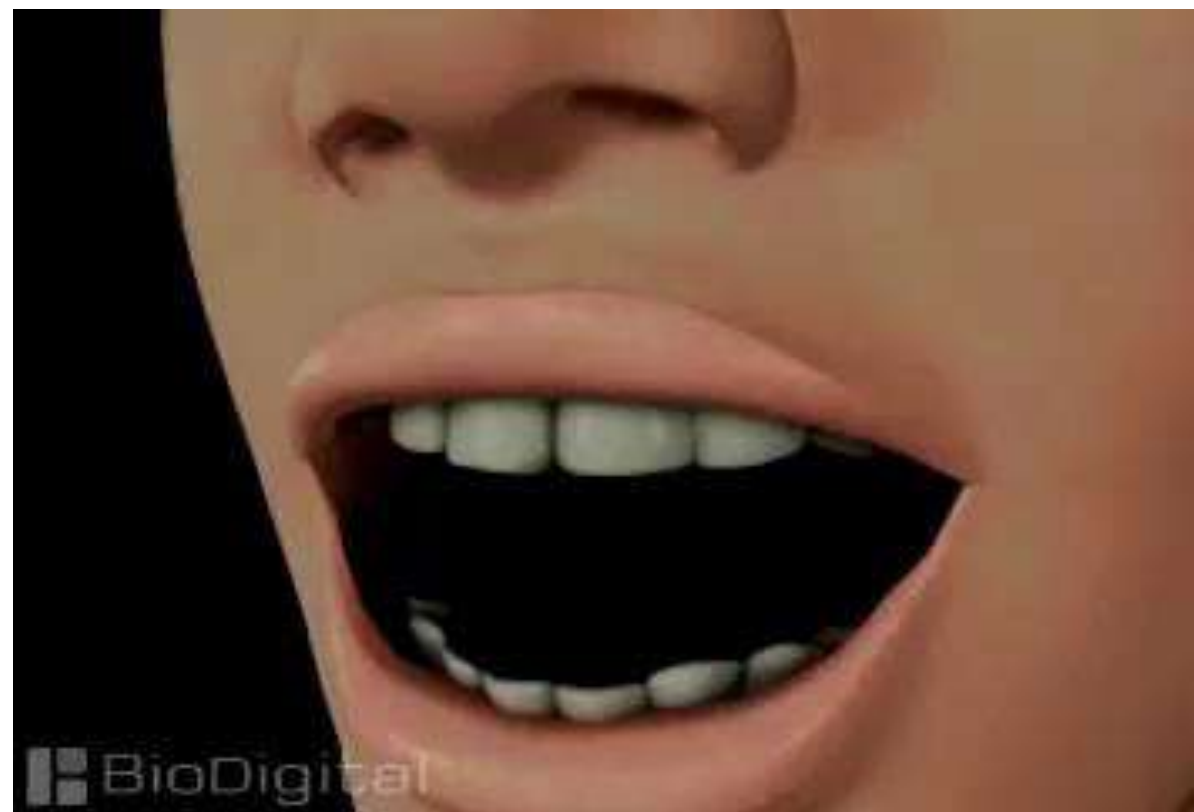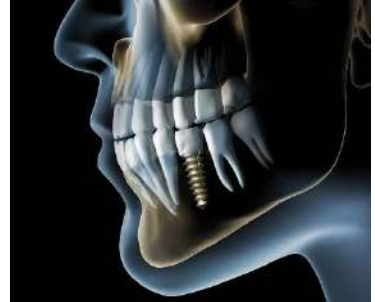these implant systems are no longer used.

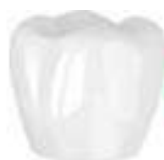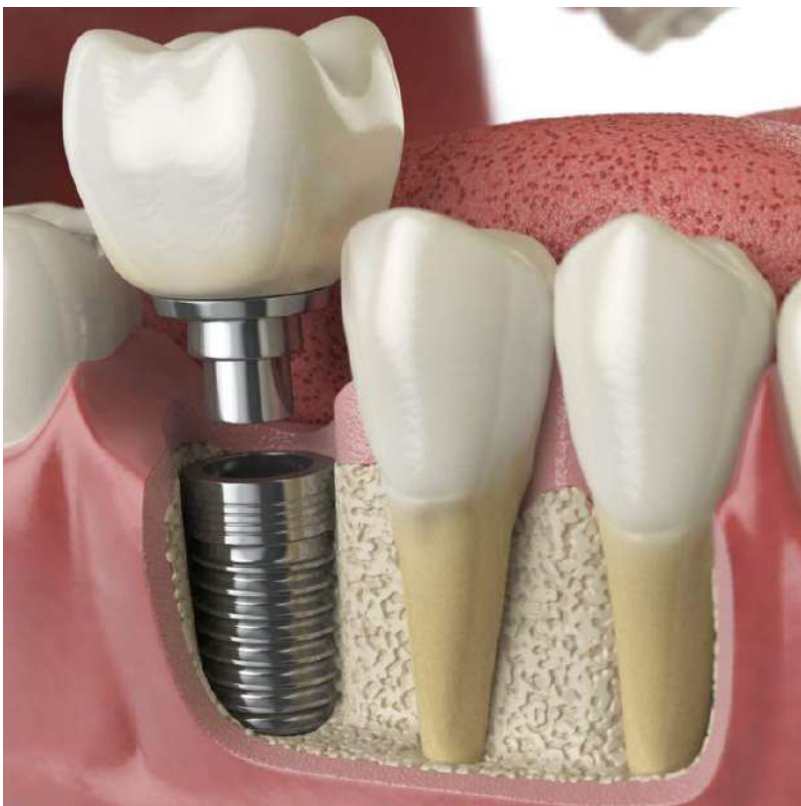- **Endosseous (root-form)- screw-shaped (threaded cylindrical) implant**, André Schroeder in the mid-1970s introduced a researches contributed to the success of this type.
- The most commonly used today because it engages bone well (achieve good primary stability)



fotolia







Crown

The role as teeth

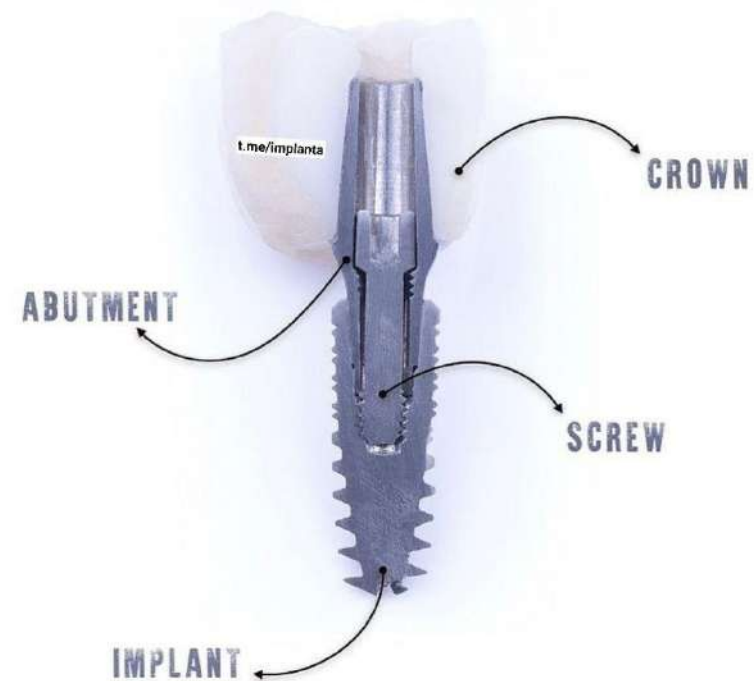


Abutment

The role to connect the crown and the fixture

Fixture

The role as teeth roots in the alveolar bone



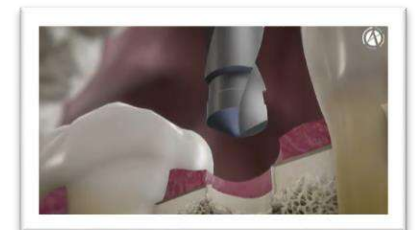
Implant Surface Characteristics (Micro-design)



- Implant surface characteristics positively influence the healing process.

Surface Energy (Bioactivity and hydrophilicity)
Chemical Composition
Surface Topography (nanotopography)

- Modifications are known to influence cellular activity and tissue responses, leading to enhanced osteogenesis.
- Implants are treated with a variety of technologies to modify surface characteristics (microscale or nanoscale) to enhance bone formation.





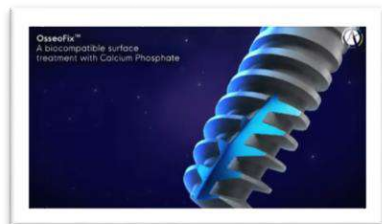At the molecular level, modified implant surfaces :

- Increase adsorption of serum proteins, mineral ions, and cytokines, which promote cellular migration and attachment.
- Retention of a fibrin clot, providing a migratory pathway for the differentiating osteogenic cells to reach the implant surface.

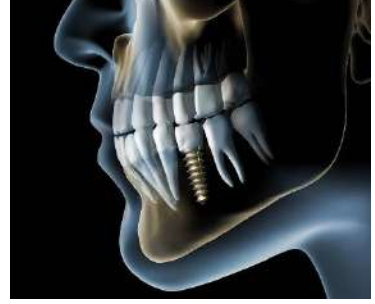

Additive Processes

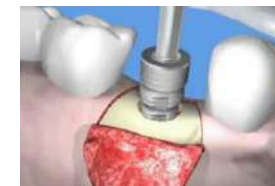
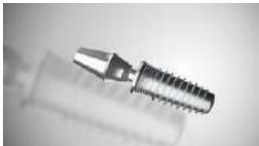- The additive process modifies the implant surface by Adding Materials or Chemicals, including
 - Inorganic Mineral Coatings, Plasma Spraying, Bio-coating with Growth Factors, Fluoride, and particulates containing Ca phosphates, sulfates, or carbonates.
 - Hydroxyapatite (Ca PO_4), accelerate the initial bone cells adaptation or proliferation.
- Additive surface modifications increase the surface texture greater than subtractive surface modifications, resulting in topographically “rougher” implant.



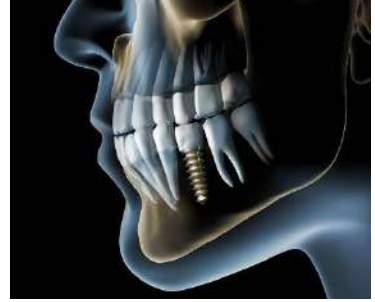Subtractive Processes



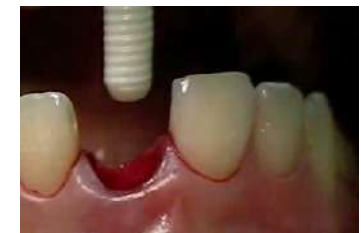- The subtractive process modifies the implant surface by removing or altering the existing surface.
- The roughness modified by machining, Acid Etching, Sandblasting, or a combination to enhance the amount or speed of osseointegration.
- Implant surfaces modified with acid etching promote favorable cellular responses and increased bone formation.
- SLA implant means : Sandblasted, Large Grit, Acid-Etched implant surface



Implant Surface Chemical Composition



- The majority of oral implants made of Commercially Pure Titanium (CP Ti) or Titanium Alloys.
- Titanium is a reactive metal that oxidizes within nanoseconds when exposed to air (TiO_2).
- Because of this passive Oxide Layer (10 nm), the titanium becomes Resistant to Corrosion.
- Pure titanium have excellent combination of **Biocompatibility, Corrosion Resistance (to acid, salt water, blood) and Mechanical Properties (low specific gravity and high strength)**.
- Titanium alloys (flexible and malleable), such as Titanium-Aluminum 6%, Vanadium 4% (Ti6Al4V).



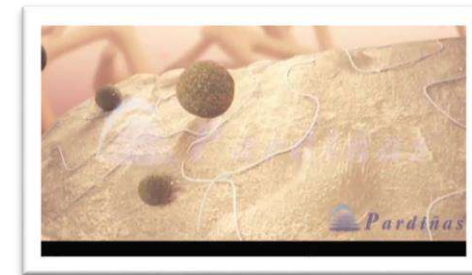
Hard Tissue Interface (Osseointegration).



- The primary goal in implant placement is to achieve and maintain an intimate bone-to-implant connection.
- Histologically defined, OSSEOINTEGRATION is the direct structural and functional connection between organized, living bone and the surface of a load-bearing implant without intervening soft tissue.
- Clinically is defined as the Asymptomatic Rigid Fixation of an alloplastic material (the implant) in bone with the ability to withstand occlusal forces.



- The osseointegration process can be compared with bone fracture healing.
- Implant site osteotomy preparation (bony hole) initiates a sequence of events, including an inflammatory reaction, bone resorption, release of growth factors, and attraction by chemotaxis of osteoprogenitor cells to the site.
- Differentiation of osteogenic cells into osteoblasts leads to bone formation at the implant surface.



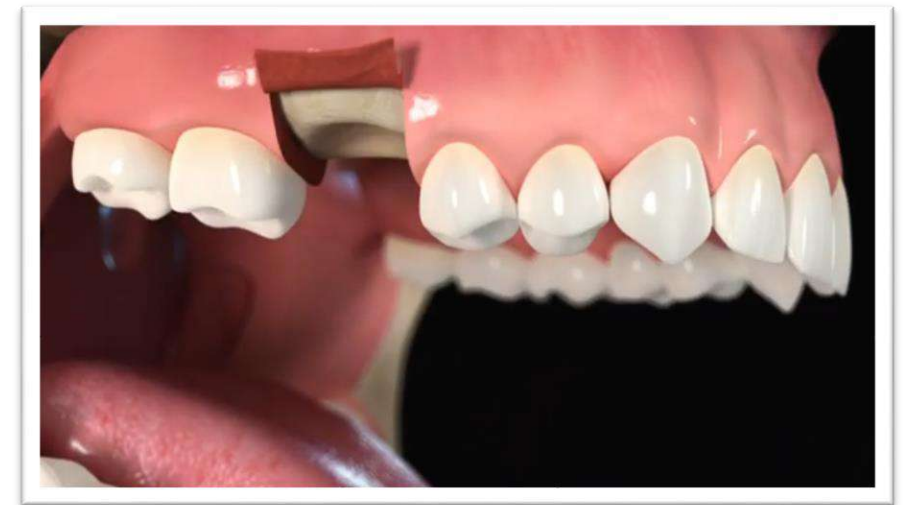For Osseointegration to occur, several Important Factors are required:

1. A biocompatible material (Titanium)
 2. Atraumatic surgery to minimize tissue damage
 3. Implant placement in intimate contact with bone
 4. Immobility of the implant, relative to bone, during the healing phase
-
- Titanium is the material of choice for dental implants.
 - It is biologically inert (No foreign body rejection reaction)



- Implant systems have specially designed drills used in a sequence to remove bone as atraumatically as possible.
- The drill sizes are matched to the size of the implant for developing initial stability.
- Atraumatic surgical technique in an aseptic environment is important to minimize mechanical and thermal injuries to bone.

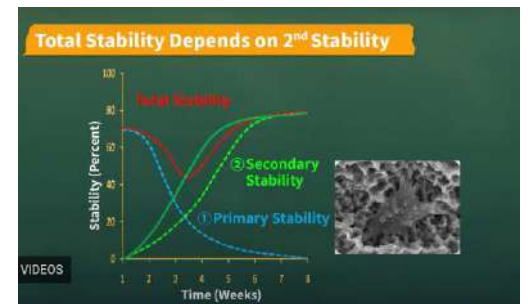
- This involves using
 - Sharp Drills
 - Slow Speed \ High Torque
 - Gentle, Intermittent Pressure
 - Irrigation



- The goal is to maintain bone temperatures below 47°C. (+47°C for 1 min is likely to cause bone necrosis and failure of osseointegration).

- Initial (Primary) Stability at the time of placement is depend on the quantity and quality of bone as well as the length and diameter of the implant.
- During the time required for osseointegration (about 3 months), immobility of the implant must be maintained and avoid occlusal loading.
- When micromovements at the bone - implant interface exceed 150 μm may impair differentiation of osteoblasts, so fibrous tissue will form (failed osseointegration).
- Woven bone is quickly formed (up to 100 μm /day). (biomechanical capacity is poor)
- Thus any occlusal load avoided in the early phase of healing.

- After several months, woven bone is replaced by lamellar bone, which occurs at a slow pace (only a few microns per day).
- Clinically, both primary and secondary stability are important for success.
- Primary stability decreased in the early weeks of post-insertion healing.
- Secondary stability, achieved over time with healing, depends on the implant surface (microdesign), as well as the quality and quantity of adjacent bone.
- Once osseointegration is achieved, implants can resist the forces of occlusion for many years.



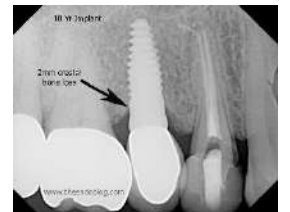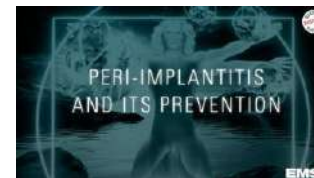Soft Tissue – Implant Interface

- Soft tissue has become a major focus of interest by the need for satisfactory esthetics and maintenance of a soft tissue seal against bacterial invasion.

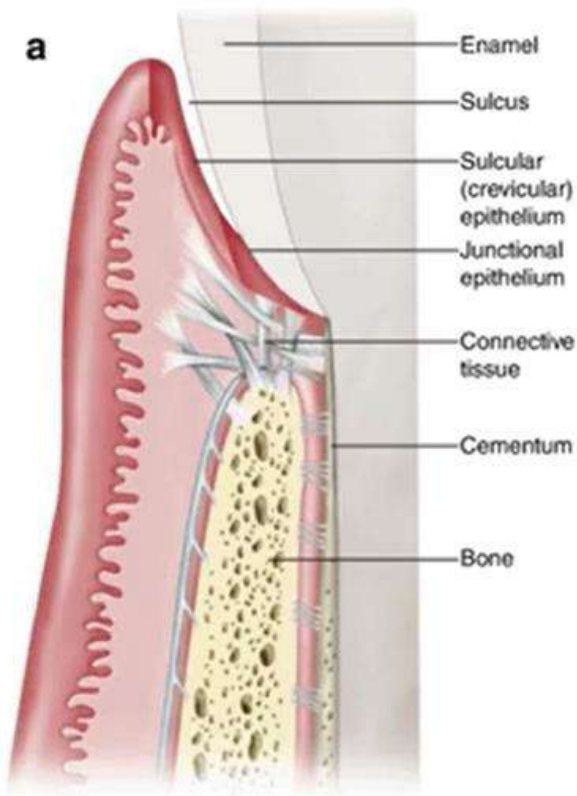
Differences between the Peri-implant and Periodontal Soft Tissue.

- Soft tissue consists of connective tissue covered by epithelium, which is continuous with an epithelium-lined gingival sulcus, the apical-most portion being lined with junctional epithelium forming an attachment.
- From that point down to the level of alveolar bone, both types of soft tissue possess a zone of dense connective tissue (responsible for maintaining a stable interface between soft tissue and the implant and acts as a barrier).

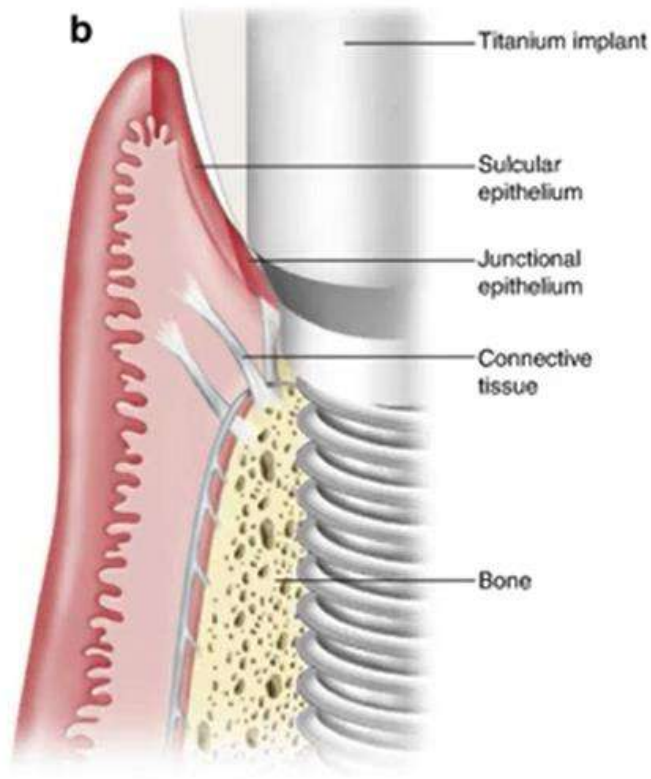
- 1- The orientation of connective tissue fibers adjacent to the implant is different from a natural tooth.
- This zone measured 1-2 mm in height. (important when examining the health of peri-implant soft tissue).
- 2- The teeth have a “shock absorbing” PDL that adapt the forces without pathologic bone loss. but implant is in direct contact with bone.
- This difference has a dramatic impact on the biomechanics, proprioception, and prosthetic consideration.
 - Because an implant does not have cementum, most connective tissue fibers run in a direction more or less parallel to the implant surface.



Tooth

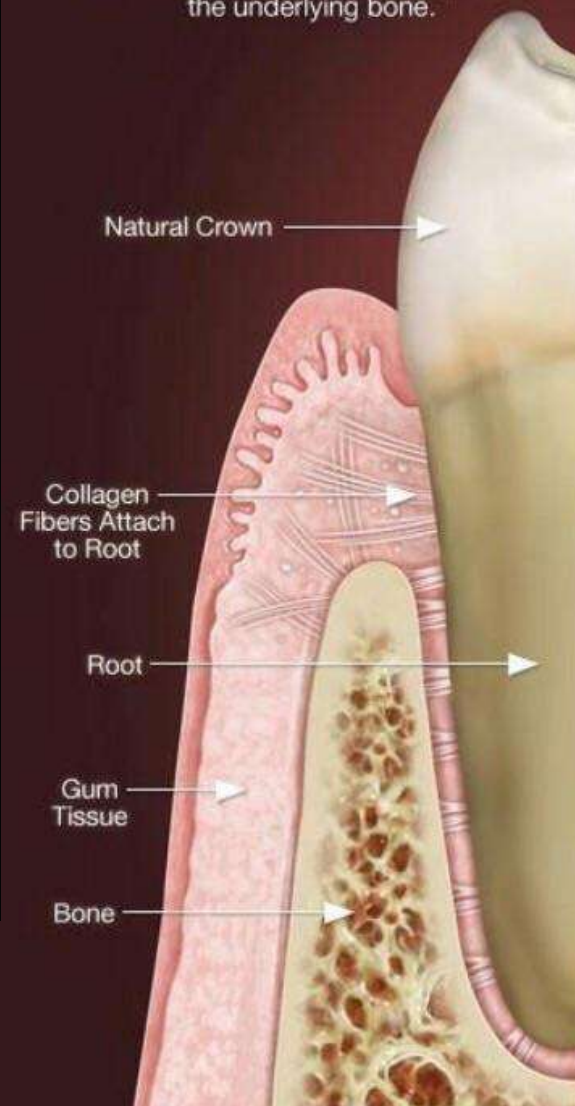


Implant



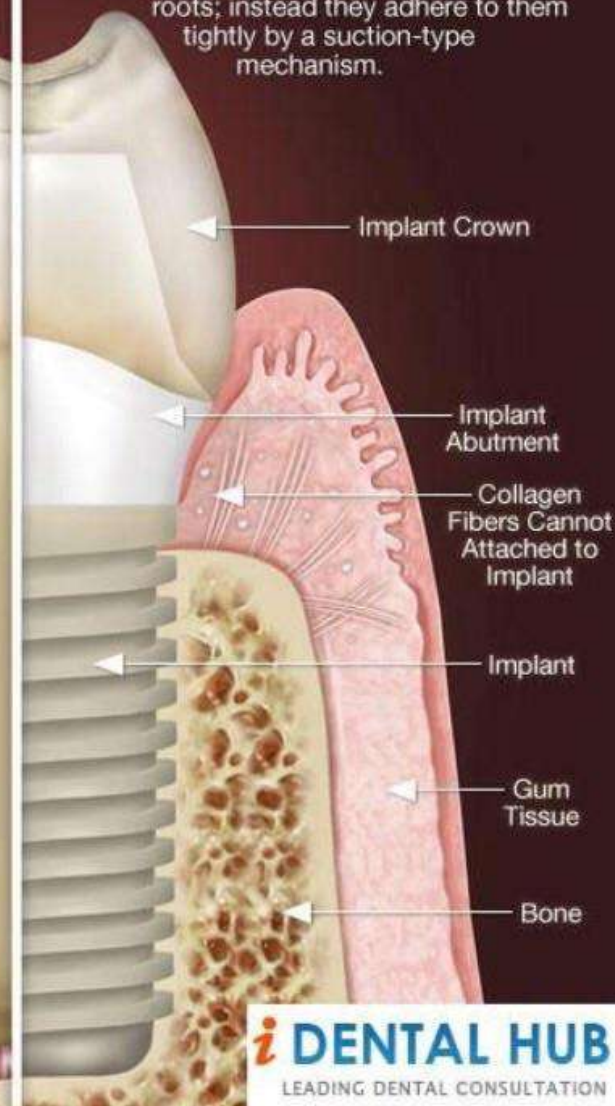
Natural Tooth

The periodontal tissues naturally attach the bone to the root surfaces of the teeth; they act as a shock absorber. The gum tissues attach into the root surfaces, helping to protect the underlying bone.



Dental Implant

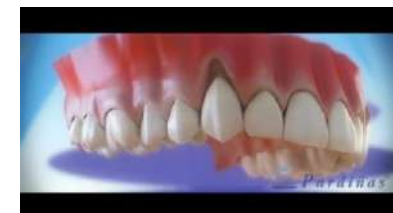Titanium, of which most dental implants are made, fuses to the jawbone giving implants great strength and stability. However, the gum tissues cannot attach to the implants in the same way as they do to tooth roots; instead they adhere to them tightly by a suction-type mechanism.



The need for keratinized tissue surrounding implants.



- Keratinized mucosa tends to be more firmly anchored by collagen fibers to the underlying periosteum than non-keratinized mucosa
- In clinical studies, implant success not affected by the presence or absence of peri-implant keratinized mucosa.
- In absence of keratinized tissue, patient may have pain and discomfort while performing oral hygiene procedures in the area.
- The symptoms controlled by increasing the amount of keratinized tissue around the implant via soft tissue grafting.

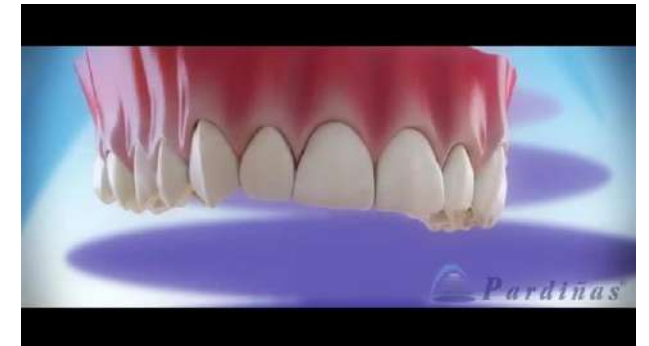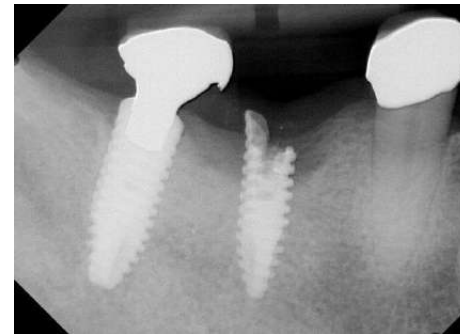


Bio-mechanical Considerations

Long-term success depend on biomechanical factors, (the load-bearing capacity of the integrated implant has to be greater than the load during function).

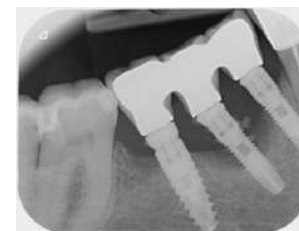
Mechanical Failure may present as

- Porcelain fracture
- Loosened or fractured abutment screw.
- Fracture of the implant fixture.

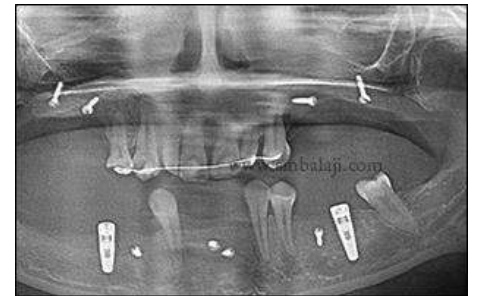
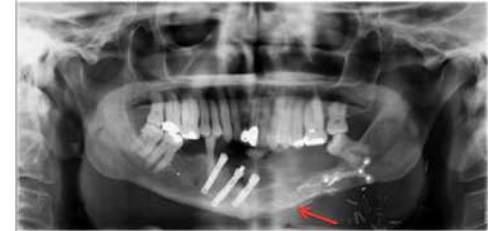
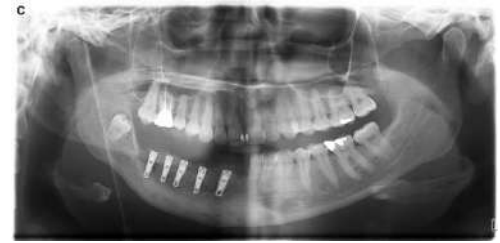A Biologic Failure may presents clinically as Bone Loss around the platform of the implant.

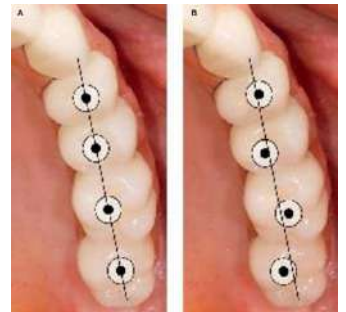
(The implant lacks the “shock absorbing” PDL)



- The load-bearing capacity of implants is qualified by several factors
 - Number and size of the implants
 - Arrangement and angulation of the implants
 - Volume and quality of the bone-implant interface.
- Loads directed via the long axis of the implants tolerated very well.
- Loads applied at angles greater than 20 degrees initiate bone loss at the implant-bone interface.
- Again, if excessive loads persist, bone loss will continue and will likely lead to implant failure.

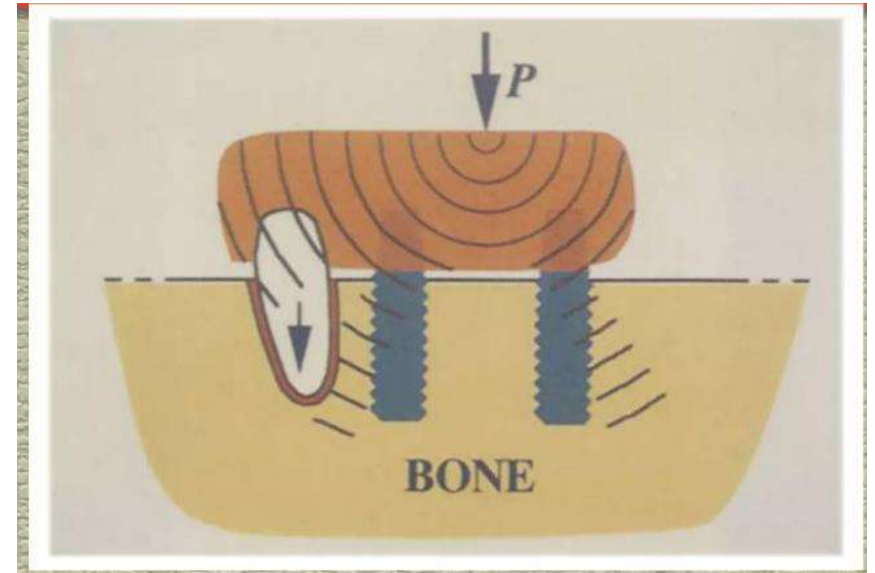
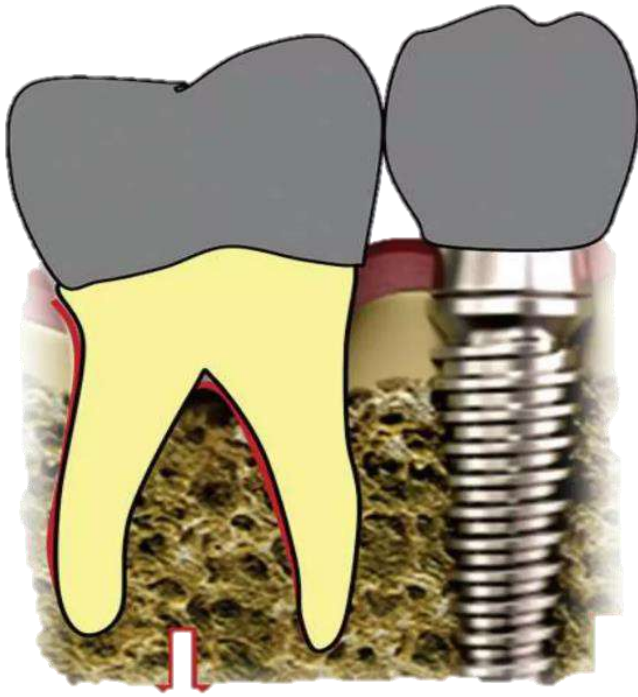

- Example - If there is a three-tooth edentulous span, the fixed prosthetic options to place
 - Three implants with three splinted crowns,
 - Three implants with three single-unit crowns,
 - Two implants as terminal abutments for three-unit bridge
 - Two adjacent implants with a fixed partial denture with a cantilevered pontic.
- The load-bearing capacity decreases with each successive option.
- Straight-line arrangement of multiple implants avoided, because it provides the least biomechanical advantage and resistant to torqueing forces caused by off-center occlusal and lateral loads.
- Implants should be placed in a more curvilinear or staggered fashion.



- Connecting an implant (immobile) to natural tooth (PDL) will create an excessively loaded cantilever situation.
- This can create stresses at the implant abutment junction up to two times the applied load on the prosthesis.
- Additional problems with a tooth to implant-supported include

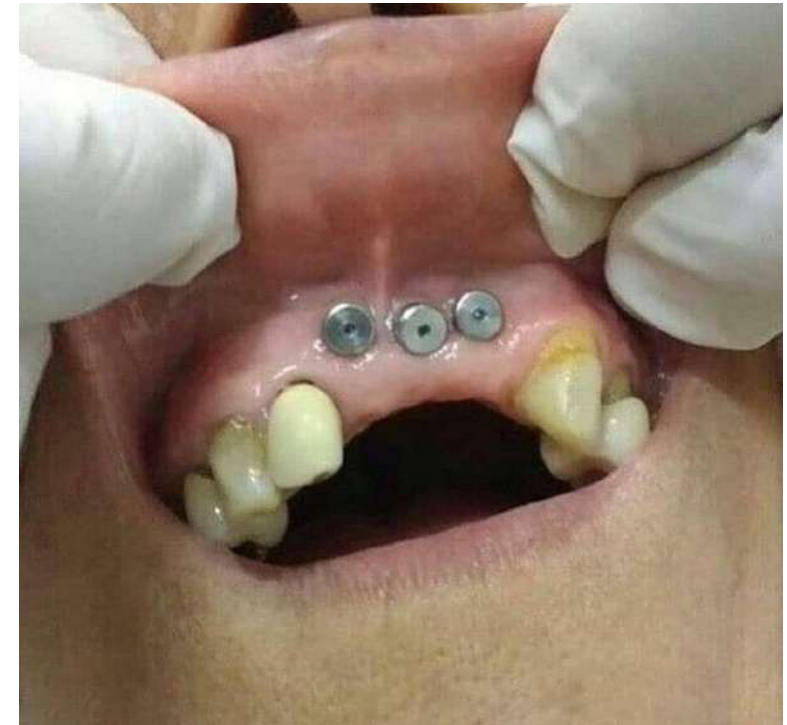Crestal bone resorption (implant)
Intrusion of the natural tooth
Cement failure on the natural abutment
Abutment's screw loosening
Possible failure of the implanted prosthetic components.



- PDL provide horizontal tooth movement **150 – 200 micro meter**
- In PD disease this movement can increae by 10 fold
- Implant mobility range from **17 – 66 micro meter**

Preoperative Assessment and Treatment Planning

- Aim of implant therapy to satisfy Patient's Desire in esthetic, function with long-term success.
- Do Not Let the Patient Desire Guide Your Treatment Plan
- **Successful Dental Implant Criteria**
 - Symptom-free implant function,
 - Implant stability,
 - Lack of peri-implant infection or bone loss.
 - Esthetic requirement
 - Patient satisfaction
- Ultimately, it is the clinician's responsibility to determine
 - Expectations for the outcome of therapy
 - Educate the patient about outcomes for each treatment option.



Medical History and Medical Risk Assessment

A thorough medical history is required

If the patient tolerate the proposed procedure and healing, with good prognosis.

- Absolute contraindications (acutely ill and those with uncontrolled metabolic disease).
- Relative contraindications (medical conditions affect bone metabolism and healing), include
 - Diabetes – uncontrolled.
 - Osteoporosis
 - Immune Compromise
 - Medications (e.g., Bisphosphonates)
 - Medical treatments such as Chemotherapy and Oral Irradiation
 - Psychological or Mental Conditions
 - Smoking, tobacco use, substance abuse (e.g., Drugs and Alcohol)
 - Parafunctional habits (Bruxism and Clinching)



Intra-Oral Examination - performed to assess

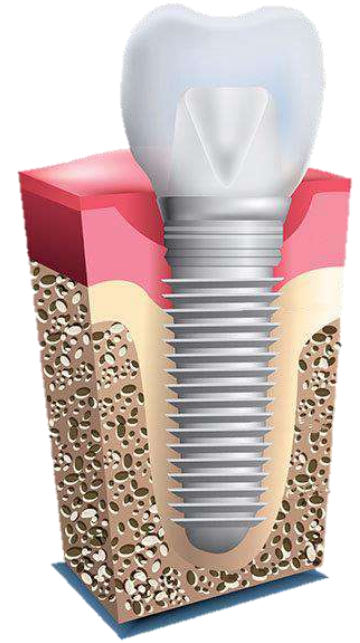

- The current health and condition of existing teeth.
- The condition of the oral hard and soft tissues.
- No pathologic conditions are present.
- All oral lesions diagnosed and treated.
- Overall dental and periodontal health.
- Temporomandibular joint condition.
- Occlusion
- Jaw relationship.
- Ability to open wide
- The patient's habits
- Level of oral hygiene

Implant Site

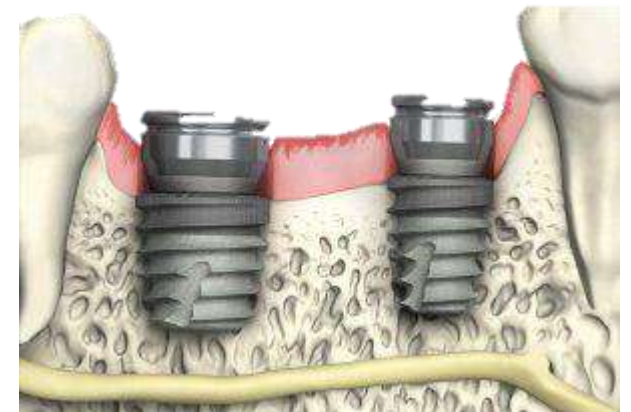
Clinically evaluate

- The available space for placement of fixture and prosthetic replacement.
- The mesio-distal and bucco-lingual dimensions of edentulous spaces
- The tilt of adjacent teeth and their roots.
- Edentulous areas measured using study models and imaging techniques.



How Much Space Is Required for Placement of One or More Implants?

- Assuming an implant is 4 mm in diameter and 10 mm long
- the Minimal Width needs to be 6-7 mm
- the Minimal Height should be 12 mm.
- Maintain 1.5 mm of bone around all surfaces of the implant.

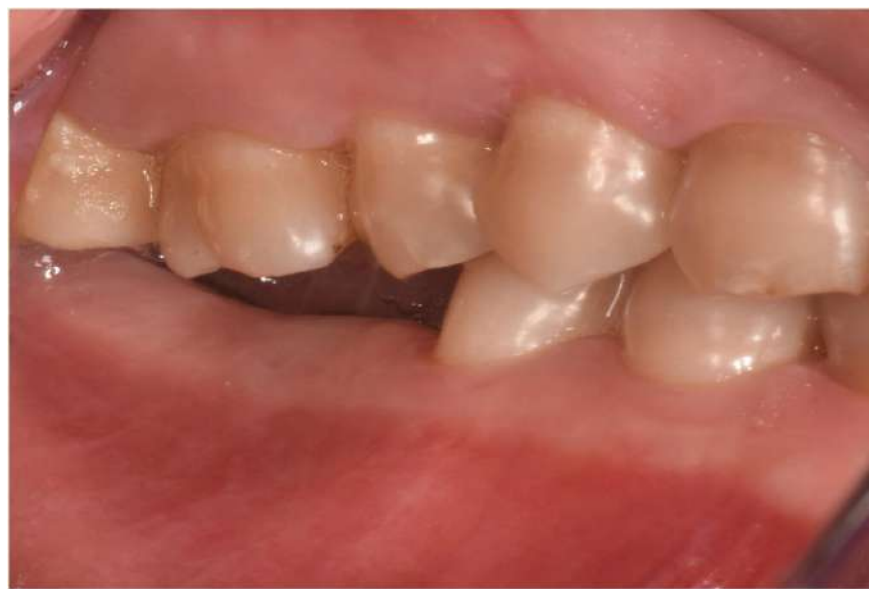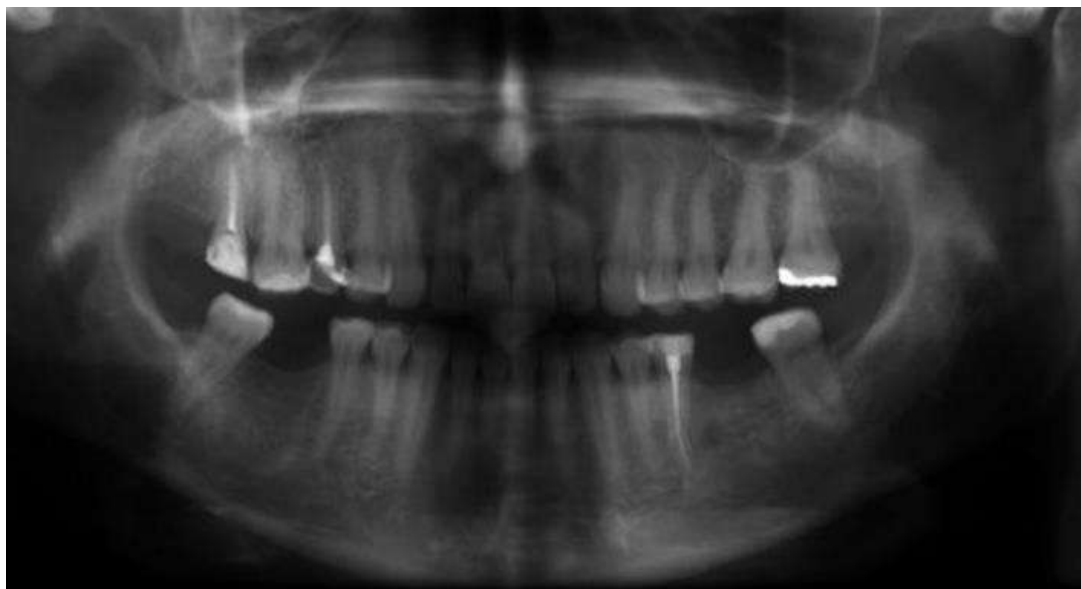

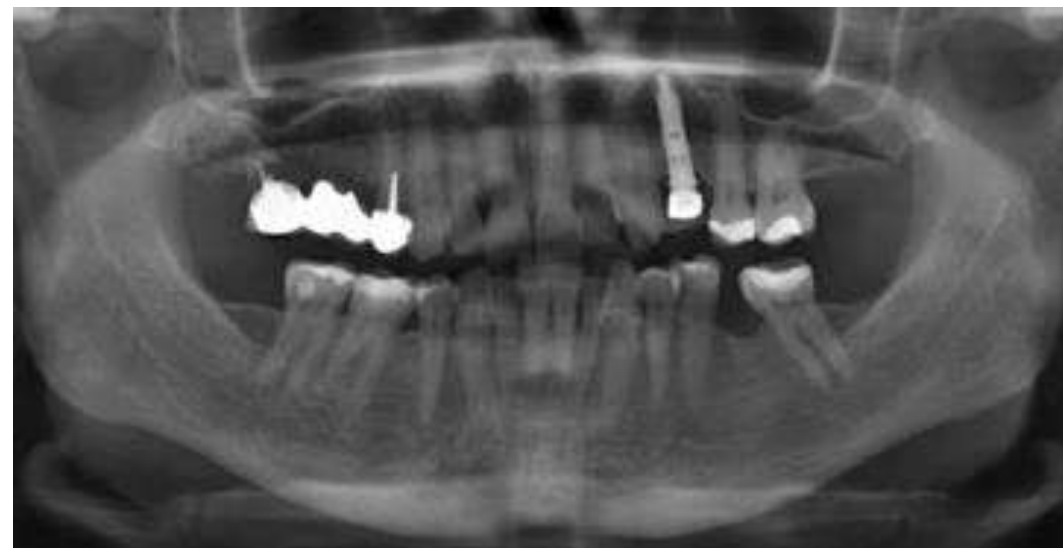
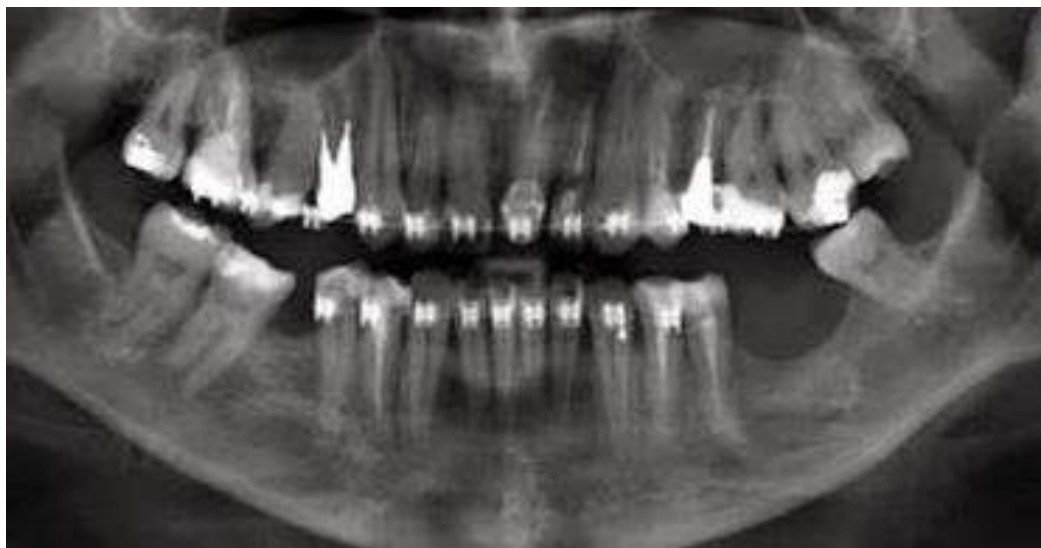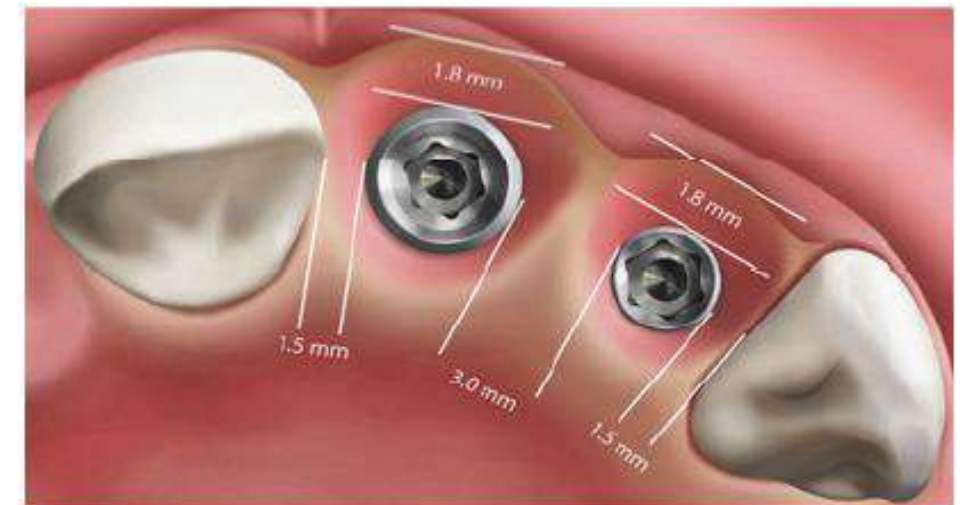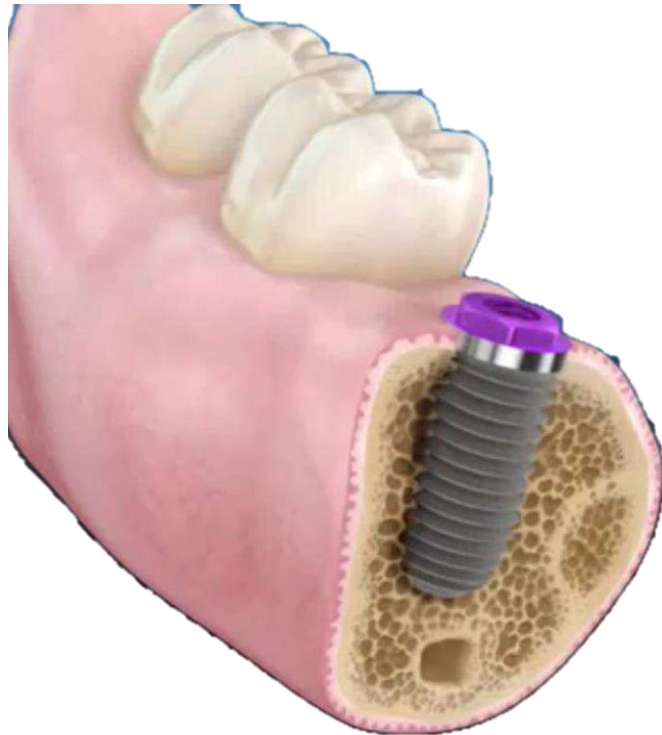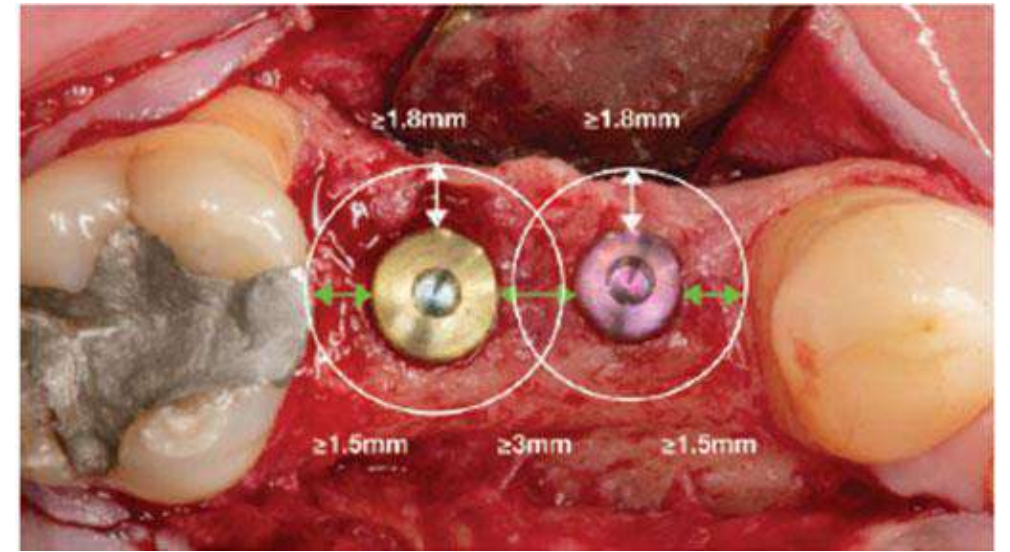
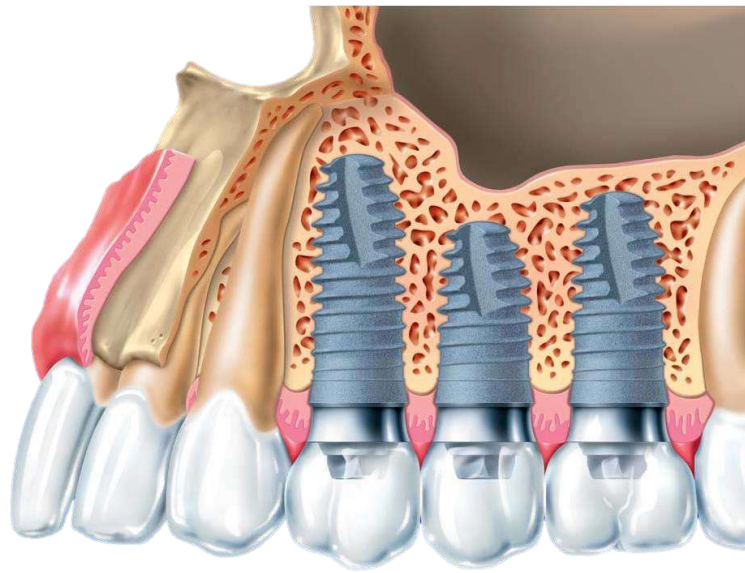
Inter-Dental Space

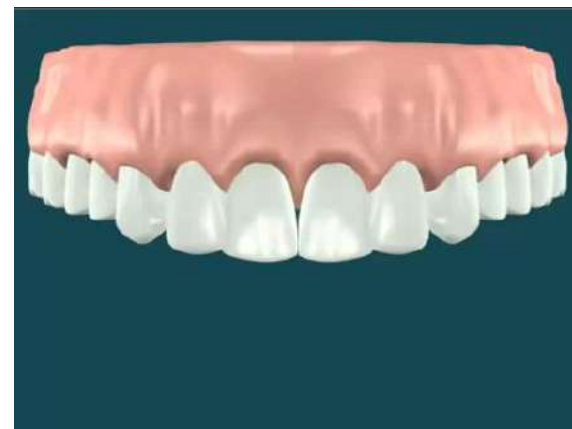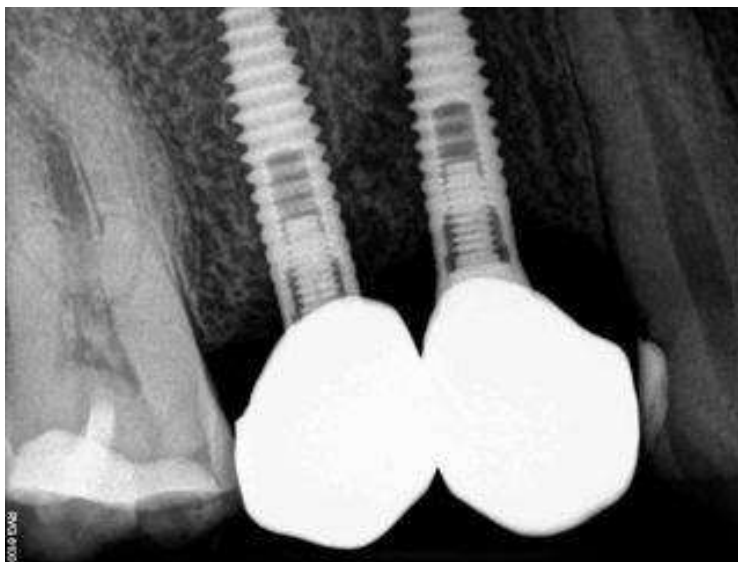
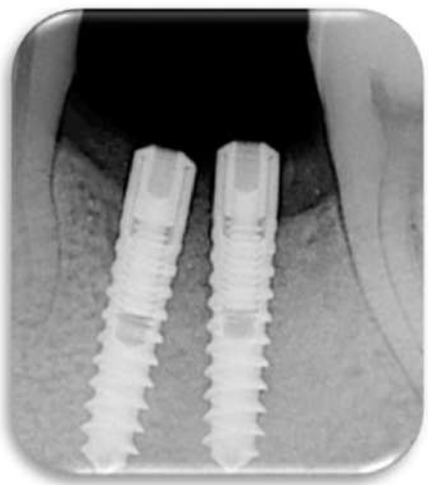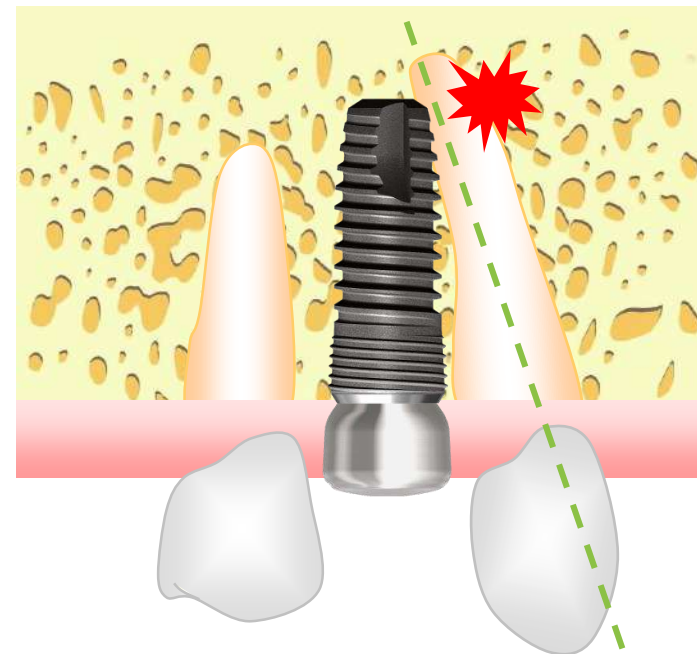
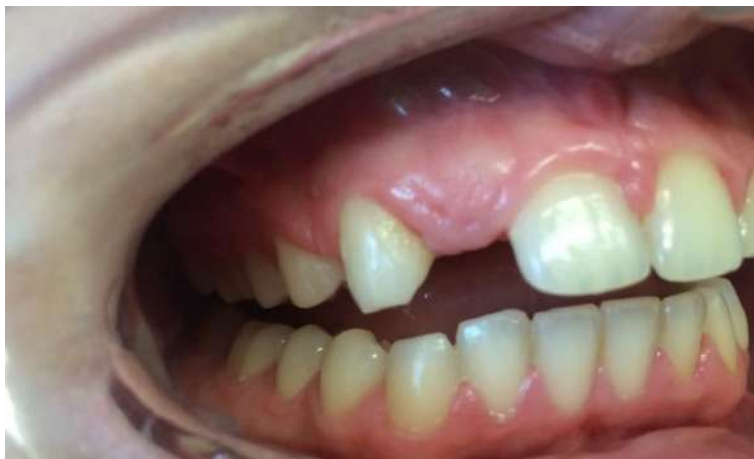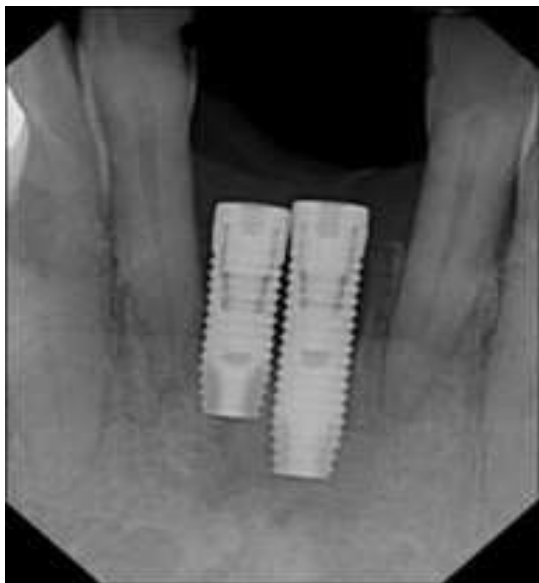- The minimal mesio-distal space for one implant placed between two teeth is 7 mm.
- The minimal mesio-distal space for two standard-diameter implants (4-mm diameter) between teeth is 14 mm
- Whenever the available space between teeth is greater than 7 mm and less than 14 mm, one wide-diameter implant inserted.
- Two narrow diameter implants could be positioned in a space that is 12 mm. (smaller implant more vulnerable to fixture fracture).

Interocclusal Space

- ✓ The restoration consists of abutment, abutment screw, and the crown
- ✓ The minimum interocclusal space for the restorative implant is 7 mm.

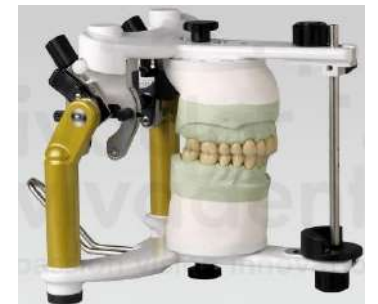





Diagnostic Casts and Photographs

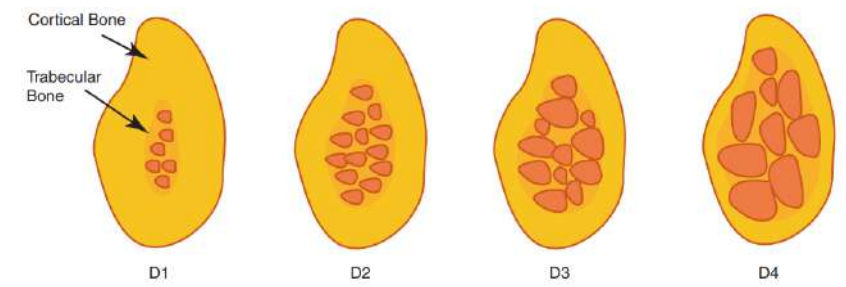
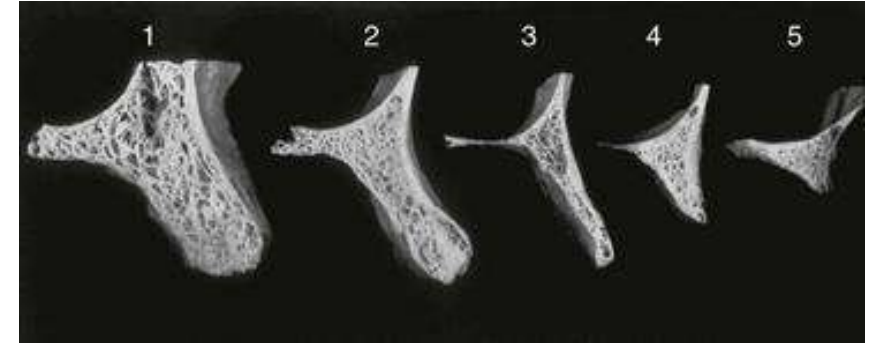
- Study models and photographs contribute to the assessment and treatment planning.
- Study models mounted on a semi-adjustable articulator, give the clinician a three-dimensional working representation of the patient.
- Elements evaluated from models include
 1. Occlusal relationships
 2. Arch relationships
 3. Inter-arch space
 4. Arch form, anatomy, and symmetry
 5. Preexisting occlusal scheme
 6. Curve of Wilson and curve of Spee
 7. Number and position of the existing natural teeth
 8. Tooth morphology
 9. Wear facets
 10. Ridge relationships to opposing arch
 11. Measurements for planning future implant locations
 12. Visualizing force vectors, both present and planned



- Intraoral photographs allow visual evaluation of the patient's soft tissue (e.g., quantity, quality, location, texture, color, symmetry).
- Extraoral photographs provide views of the patient from many different esthetic perspectives.

Elements that are easily assessed are as follows:

- Facial form
- Facial symmetry
- Patient's degree of expression and animation
- Patient's appearance (e.g., facial features, facial hair, complexion, eye color)
- Smile line
- Incisal edge or tooth display
- Buccal corridor display
- Potential esthetic demand

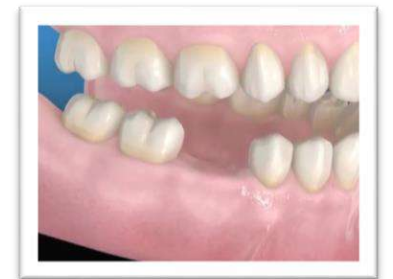
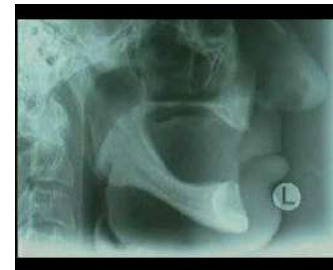
Hard Tissue Evaluation - clinically and radiographically.



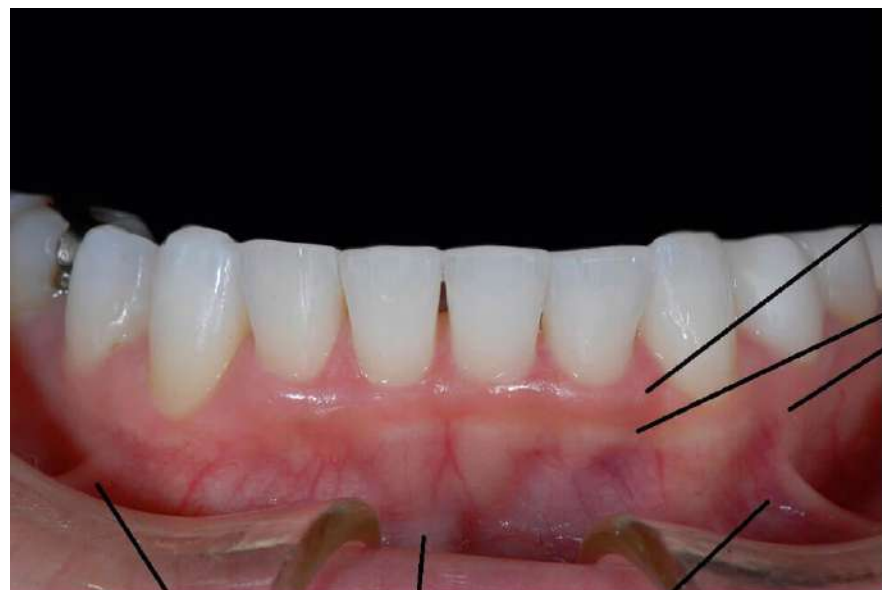Clinical Examination consists of

- Visual Examination can immediately identify deficient areas.
- Palpation to feel for anatomic defects (such as concavities and undercuts).
- Probing, if desired, through the soft tissue (intraoral bone mapping) with local anesthesia, to assess the thickness of the soft tissues.
- The bone must be evaluated in a 3D (CBCT)
- Bone augmentation procedures may be necessary for inadequate quantity of bone.



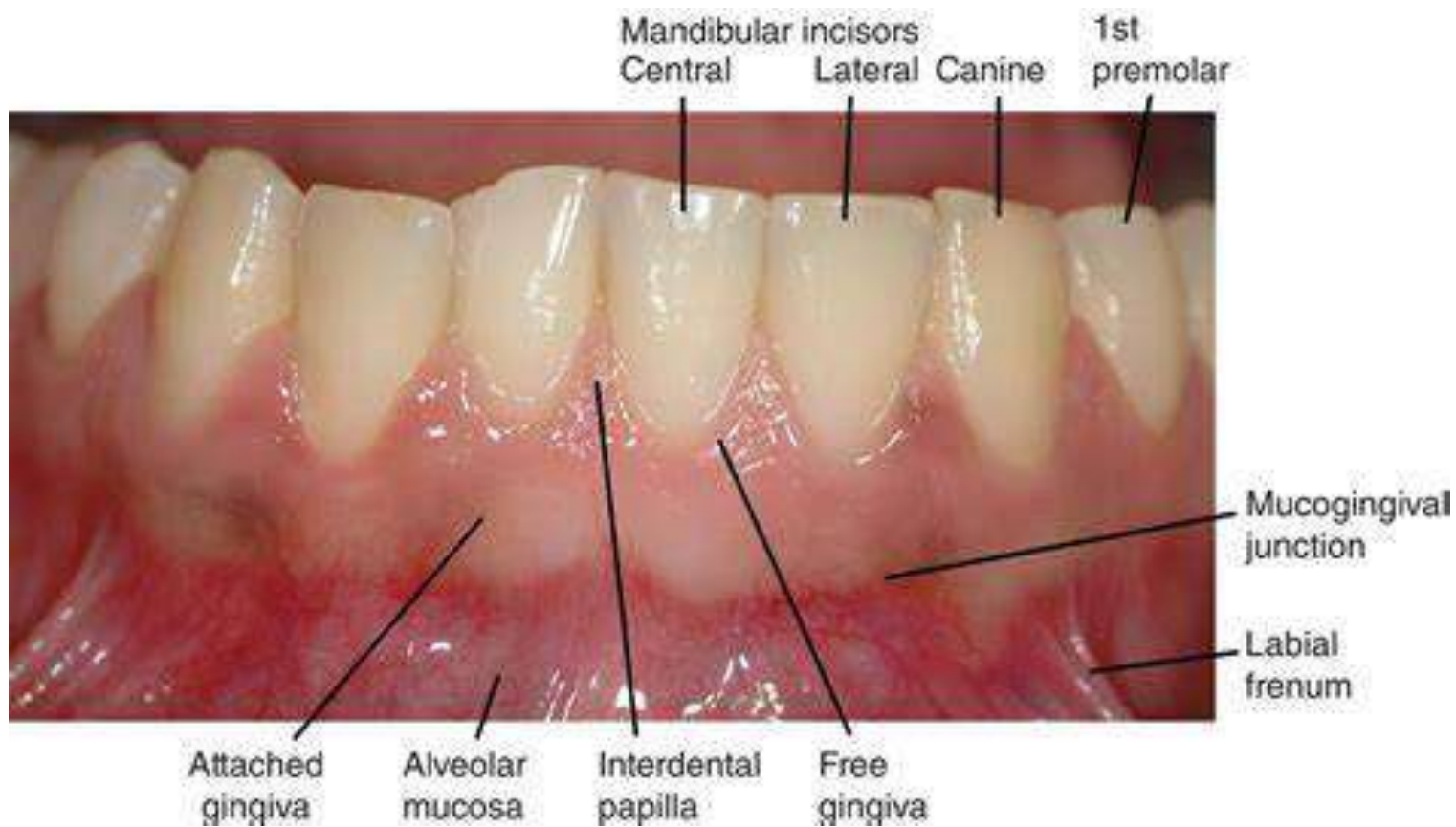
Soft Tissue Evaluation

- Evaluation of quality, quantity, and location of soft tissue in the implant site
- Areas with minimal or no keratinized mucosa may be augmented with gingival grafts.
- Other soft tissue concerns, such as frenum attachments that pull on the gingival margin, should be evaluated.
- In the presence of good oral hygiene, a lack of keratinized tissue not impair health of implants.
- Others believe that keratinized mucosa has better functional and aesthetic results for implant
- Keratinized mucosa is typically thicker and denser than alveolar mucosa (nonkeratinized). It forms a strong seal around the implant with a cuff of circular (parallel) fibers around the abutment.



**Keratinized
Mucosa**

Non-Keratinized Mucosa



Mandibular incisors
Central Lateral Canine 1st
premolar

Mucogingival
junction

Labial
frenum

Attached
gingiva

Alveolar
mucosa

Interdental
papilla

Free
gingiva

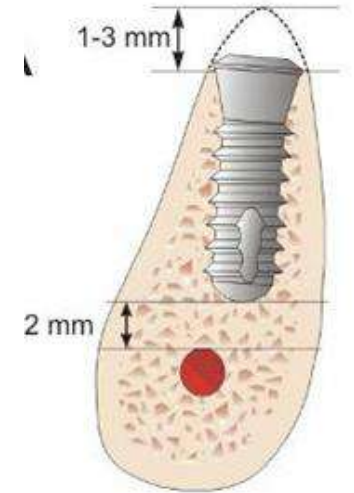
Radiographic Examination



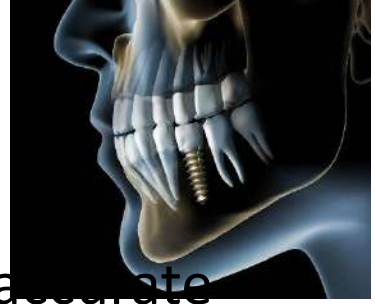- Options range from standard projections (e.g., periapical, occlusal, panoramic, cephalometric) to cross-sectional imaging (e.g CT, CBCT).
- Multiple factors influence the selection of radiographic techniques for any particular case. (cost, availability, radiation exposure)
- The Panoramic Radiography used for initial evaluation of the dental implant, supplemented with Periapical Radiographs as needed.

Areas of study radiographically include the following:

1. Location of vital structures (Mandibular canal, Mental foramen, Maxillary sinus, Nasal cavity, Incisive foramen)
2. Bone height
3. Root proximity and angulation of existing teeth
4. Evaluation of cortical bone
5. Bone density and trabeculation
6. Pathology (e.g., abscess, cyst, tumor)
7. Existence of anatomic variants (e.g., incomplete healing of extraction site)
8. Cross-sectional topography and angulation (determined by CT and CBCT)
9. Sinus health (best evaluated by CT and CBCT)
10. Skeletal classification (evaluated with lateral cephalometric images)

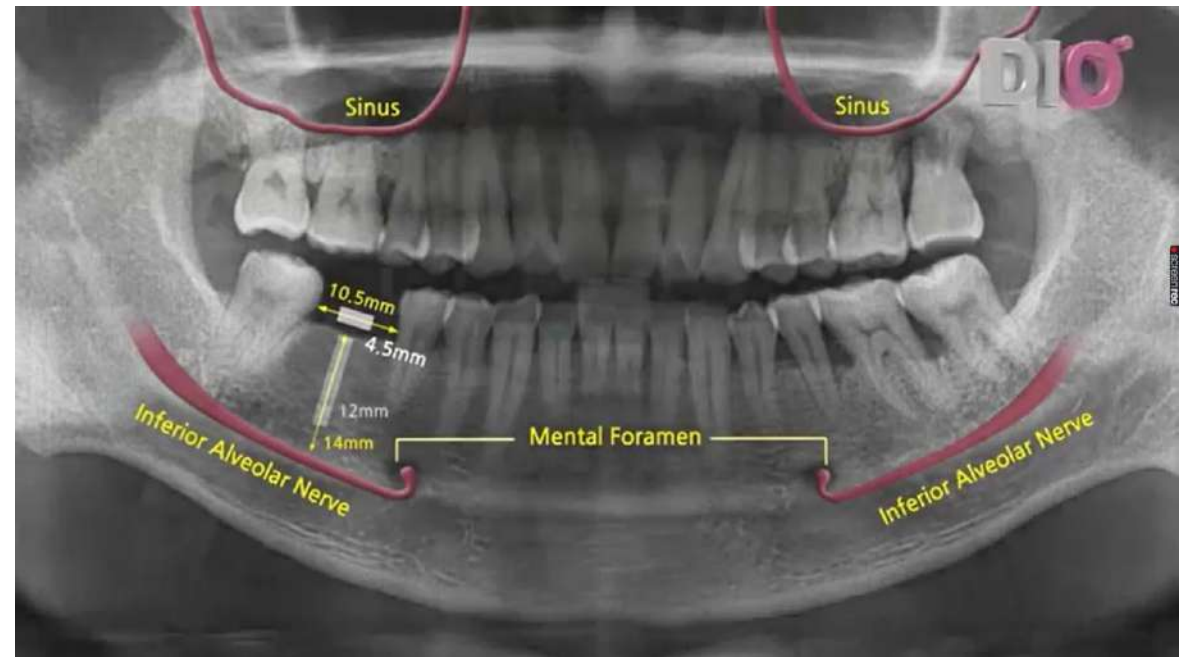


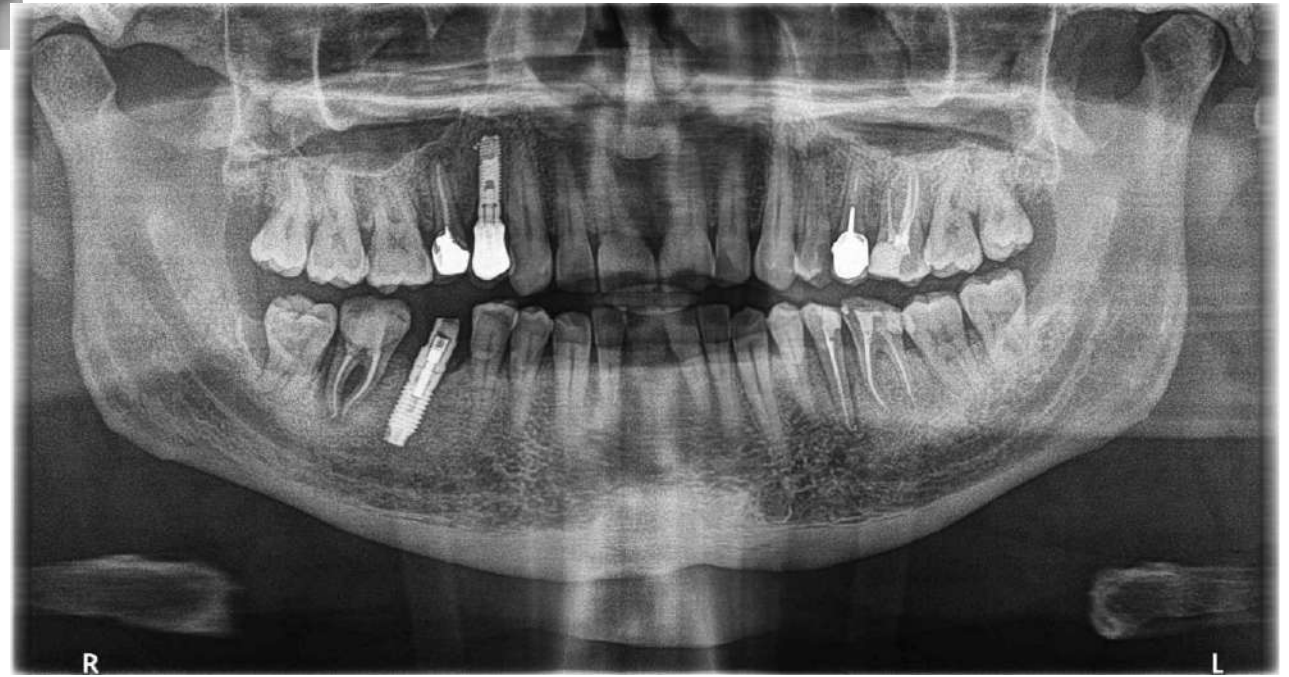
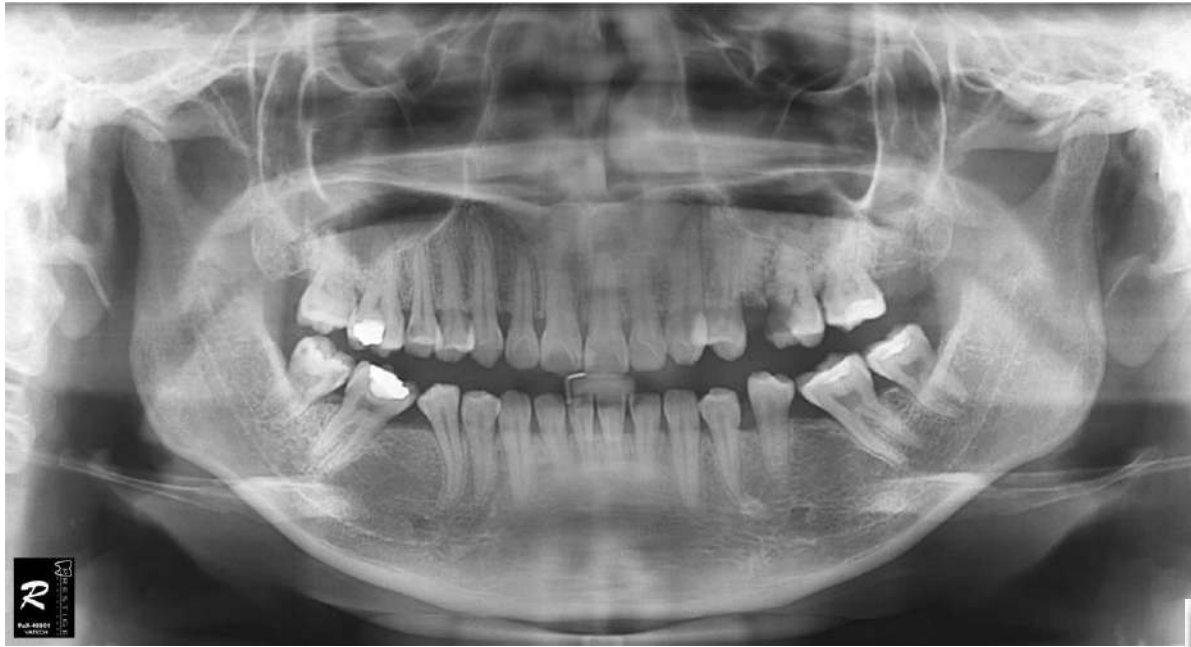- Traditional radiographs must be calibrated for potential magnification.
- Digitally acquired radiographs have software applications that allow for very accurate measurement.



Critical measurements specific to implant placement include the following:

- At least 1 mm inferior to the floor of the maxillary and nasal sinuses
- Maxillary Incisive canal to be avoided
- 5 mm anterior to the mental foramen
- 2 mm superior to the mandibular canal
- 3 mm from adjacent implants
- 1.5 mm from roots of adjacent teeth



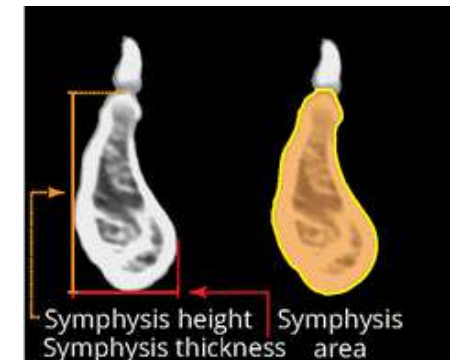
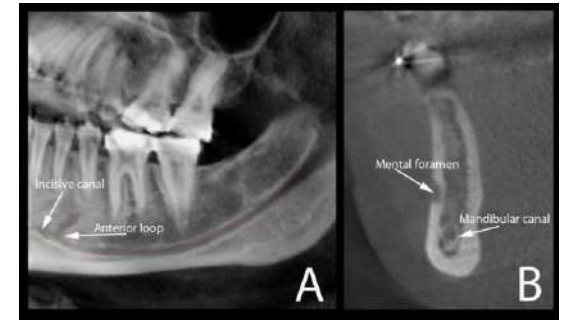


Surgical Treatment Planning Considerations

- The surgeon must be mindful of the proposed prosthetic goals.
- The surgeon must determine the prognosis of implant placement based on specific limitations as a result of anatomic variations, bone quality, and bone quantity.

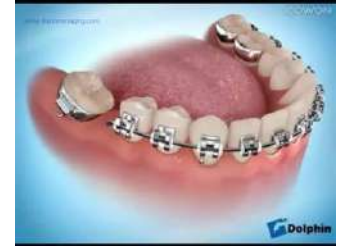The Anterior Mandible is usually tall and wide.

- Excellent Bone Quality, typically the densest of two arches.
- Primary surgical concerns in this area include
 - Proper angulation of the implants
 - Avoiding the mental foramen and anterior loop of mandibular canal.

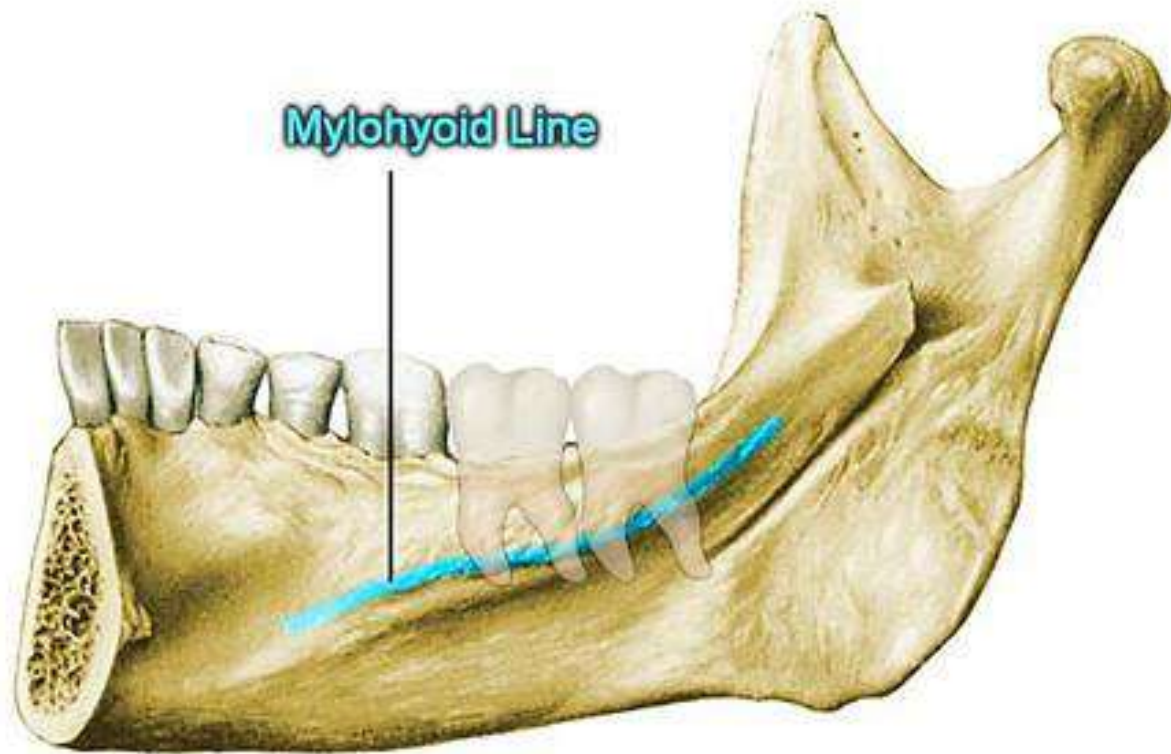


The Posterior Mandible

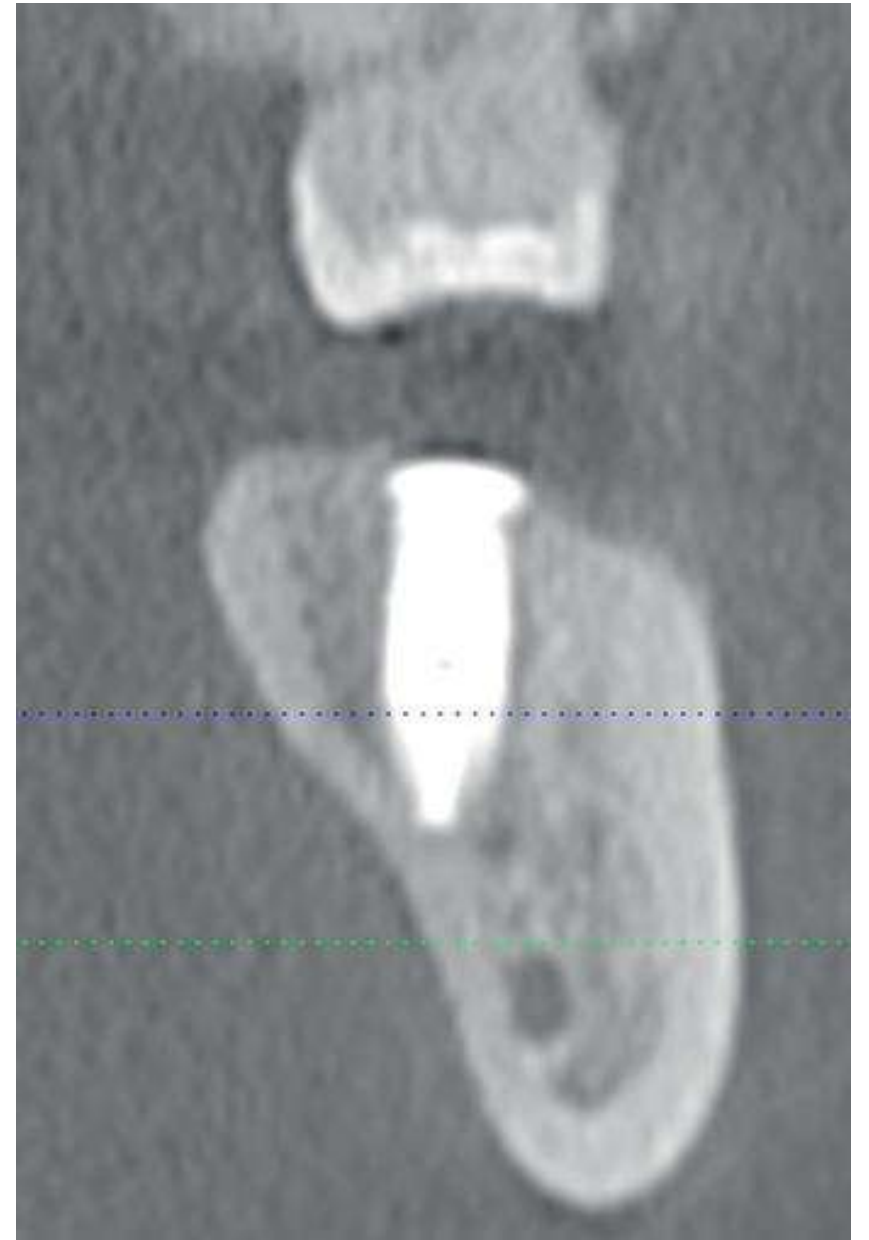
- Limited implant length due to the position of the mandibular canal.
- Tip of the implant at least 2 mm from the inferior alveolar nerve (IAN).
- It is important to consider the bucco-lingual position of the nerve as well.
- CBCT can be helpful in making this determination.
- The attachment of the mylohyoid muscle helps maintain the bony width along the superior aspect of the ridge.
- “The Lingual Undercut,” usually is present immediately below this attachment.
- This is a critical area to be examined and palpated during the clinical examination.



Medial Surface of the Mandible



Mylohyoid line is at the level of root apices of mandibular molars

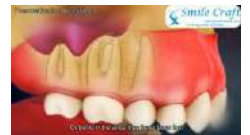

The Posterior Maxilla poses two specific concerns.

1- Bone quality is poor (poor primary stability) For this reason, more osseointegration time (6 months or longer).

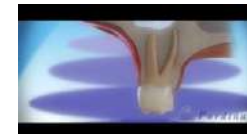2- The proximity of the maxillary sinus as a result of alveolar bone resorption and increased pneumatization of the sinus.

- If an adequate height of bone is present, the implant placed, leaving 1 mm of bone between the sinus floor and the implant.
- If there is inadequate bone height, then “sinus lift” procedure would be necessary.
- If primary stability is questionable,
 - Increase time for osseointegration (+3 months)
 - “Over-engineering” the case by using more implants



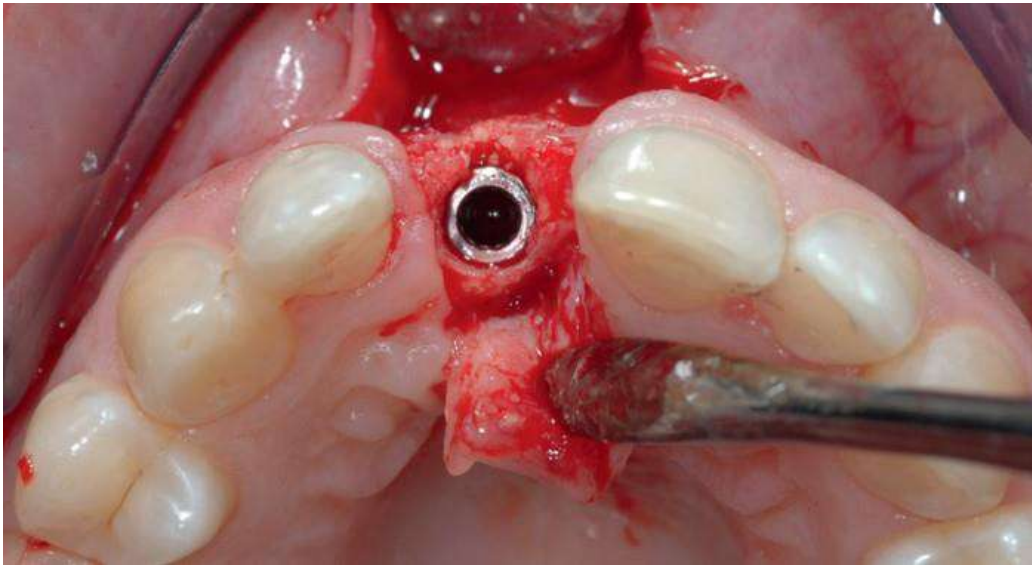
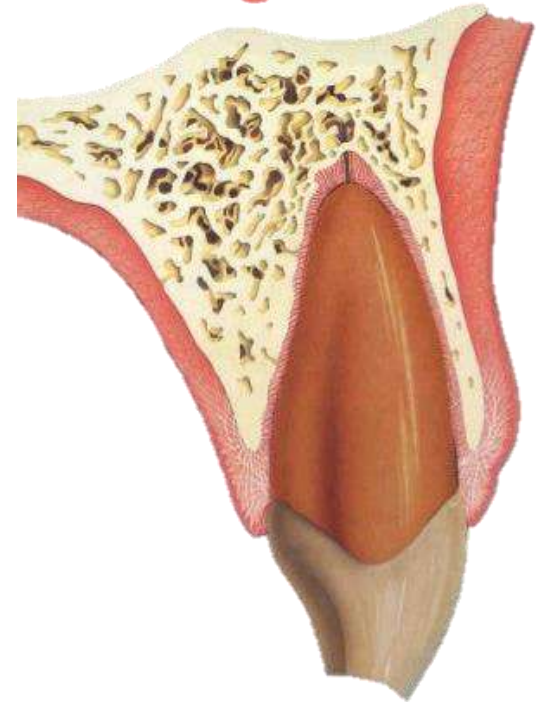
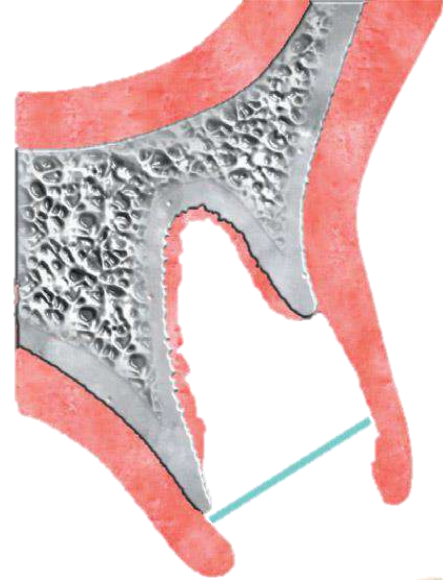
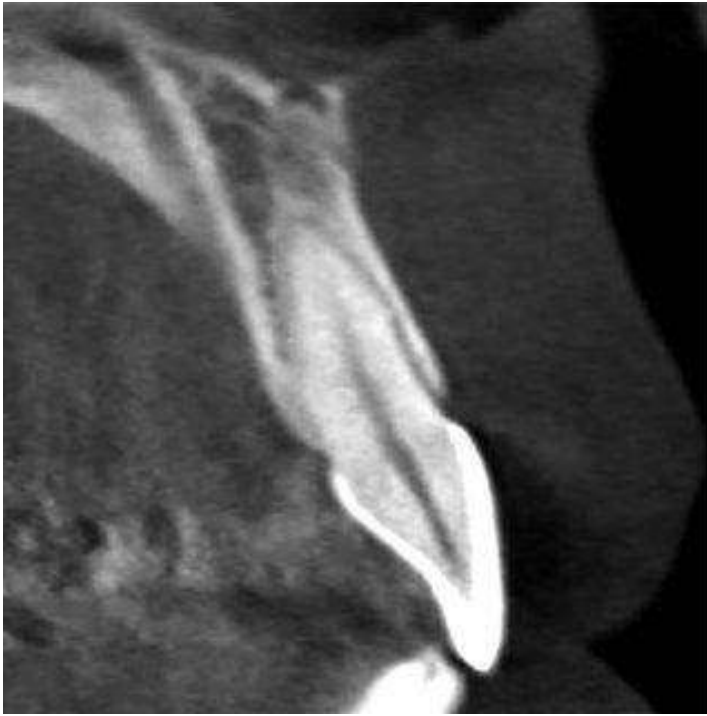Sinuses Post

Pneumatized Sinus



The Anterior Maxilla (Esthetic Zone)

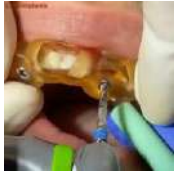- It is the most surgically assessable area, and most difficult region.
- This area, even when healthy teeth are present, usually has a thin buccal plate.
- After tooth loss, the resorption of the ridge follows a pattern of moving apically and palatally.
- The residual ridge is narrow and angulated such that ideal implant positioning may be impossible and the esthetic outcome may be compromised.
- Nasal cavity and the incisive canal are an anatomic limitations
- Implants should be placed 1 mm short of the nasal floor and should not be placed in the maxillary midline.



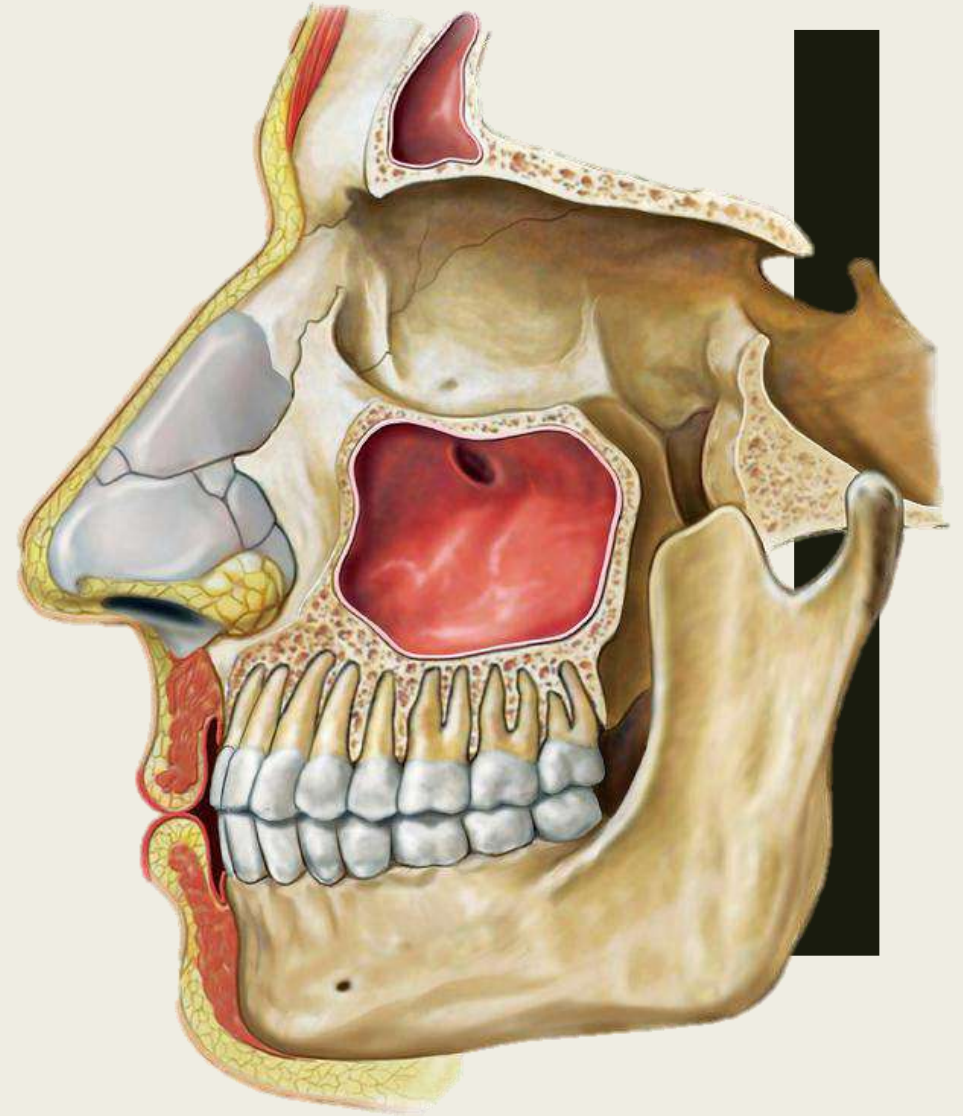
Final Treatment Planning

- All collected Clinical and Radiographic Information with surgical options and limitations to produce the best final result of the prosthetic treatment.
- The positioning and angulation of implant placement is important for the biomechanical stability and esthetics required for long-term success.
- So, Surgical Guides are frequently utilized, which is a critical factor for implants in an esthetic zone.

- The objectives of Surgical Guides:
- (1) Delineating the embrasure “black triangle.”,
- (2) Locating the implant within the tooth contour,
- (3) Aligning the implants with the long axis of the completed restoration.
- With the aid of CBCT data and computer technology, accurate “virtual” treatment planning can be accomplished. (position and angulation of the implant determined and ideal prosthetic position can be simulated)
- A computer-generated splint can then be constructed with guide sleeves matched to implant drill sizes. This allows precise placement of the implant at the time of surgery.



Diseases of Maxillary Sinus



Bashar Abdul-Ghani

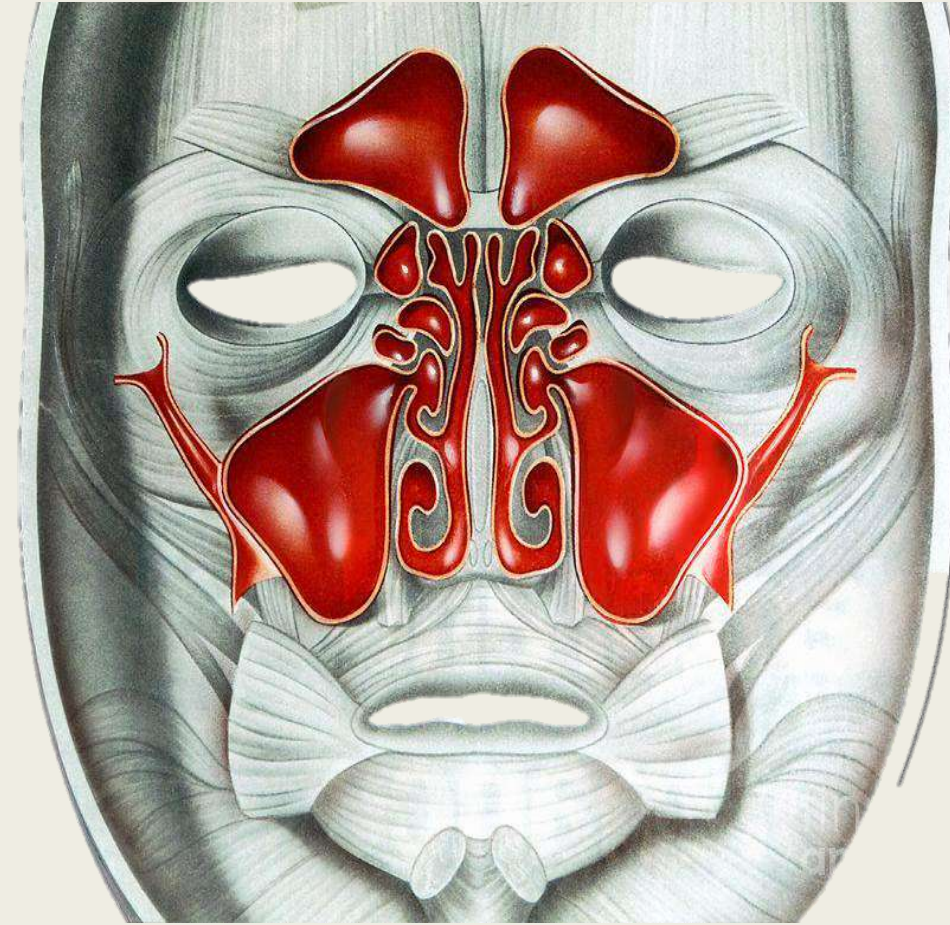
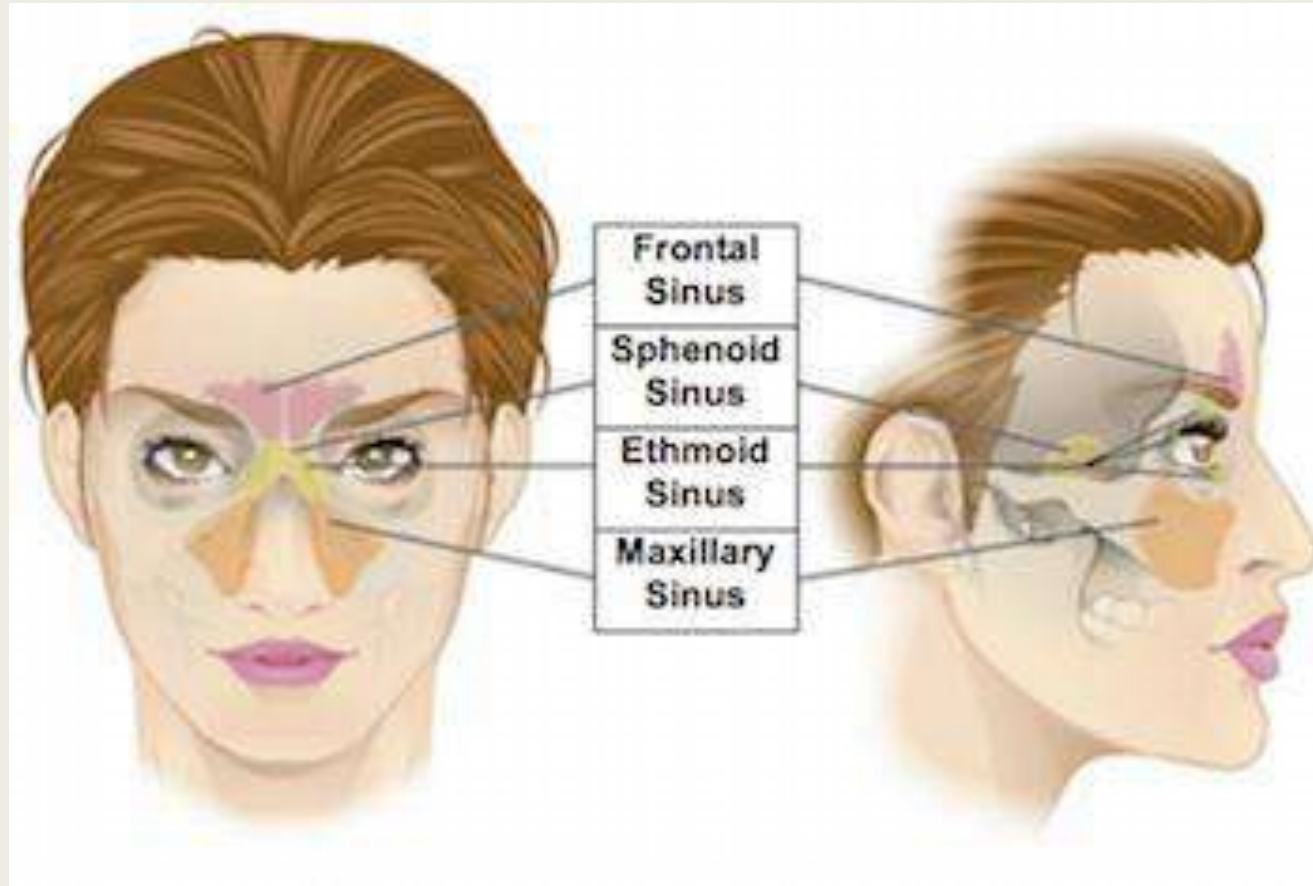
FICMS. MAXFACS Cons. MFDS. RCSED. RCPS (Glasg).

Lecture Quoted From Baghdad University Curriculum

Topics

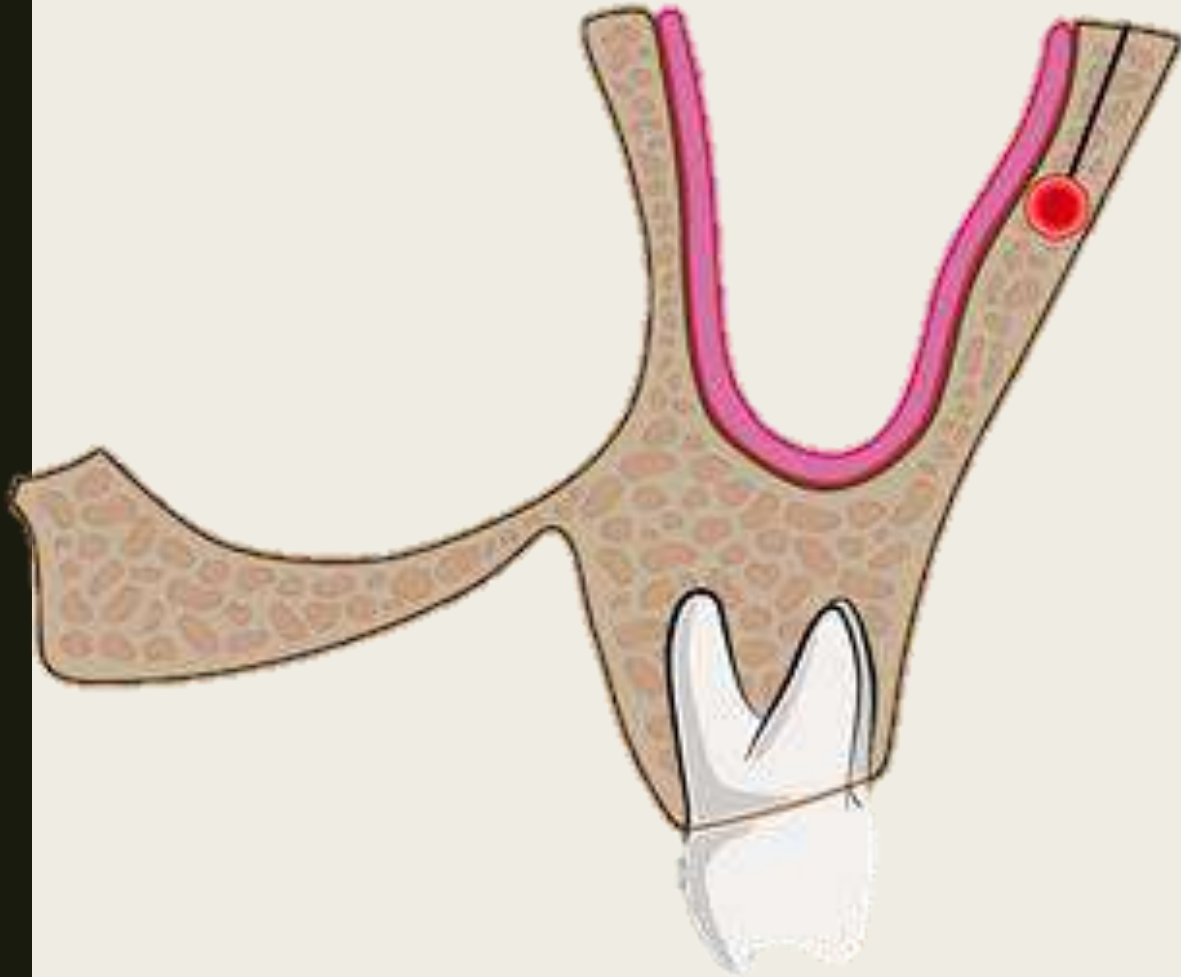
- Overview of the maxillary sinus
- Clinical and radiographic examination
- Non-odontogenic infections of the maxillary sinus
- Odontogenic infections of the maxillary sinus
- Oro-antral communications and fistulae
- Treatment

Paranasal Air Sinuses



- Maxillary sinus (antrum) **is larger than the other sinuses**, lies in the body of the maxilla.
- Presents at birth as a small cavity
- Starting its development during third fetal month & reaching maximum size in early adult life **about eighteenth year** (10 to 15 ml capacity).
- Tubular at birth, ovoid in childhood and pyramidal in adulthood.
- Complete absence is rare
- **Often sub compartments & crypts are present, formed by osseous & membranous septa always shows by X-ray film.**

- The floor of the sinus represent the alveolar process of the maxilla.
- **Ostium** is the opening to the nasal cavity, lies beneath **the middle conchae (turbinate)**.
- The inner walls are covered with mucous membrane (**Schneiderian membrane**).
- The wave action of cilia push foreign material toward the ostium.
- Pathological lesion may cause area which is **deficit in cilia**.
- Normally the thickness of the **Schneiderian membrane** varies from 0.13 mm to 0.5 mm.
- The thickness of sinus wall is vary from (2-5 mm) in the roof, (5-10 mm) in the floor.
- Superior alveolar nerve supplying the lining of the mucous membrane.
- Blood supply from the infra-orbital artery (branch of maxillary a.).
- **The lymphatic drainage is to the retro-pharyngeal lymph node & to the sub mandibular lymph node.**



INTACT SIDE
(NORMAL
ANATOMY)

Ostium of
Maxillary
Sinus

Uncinate
Process

Middle
Turbinate

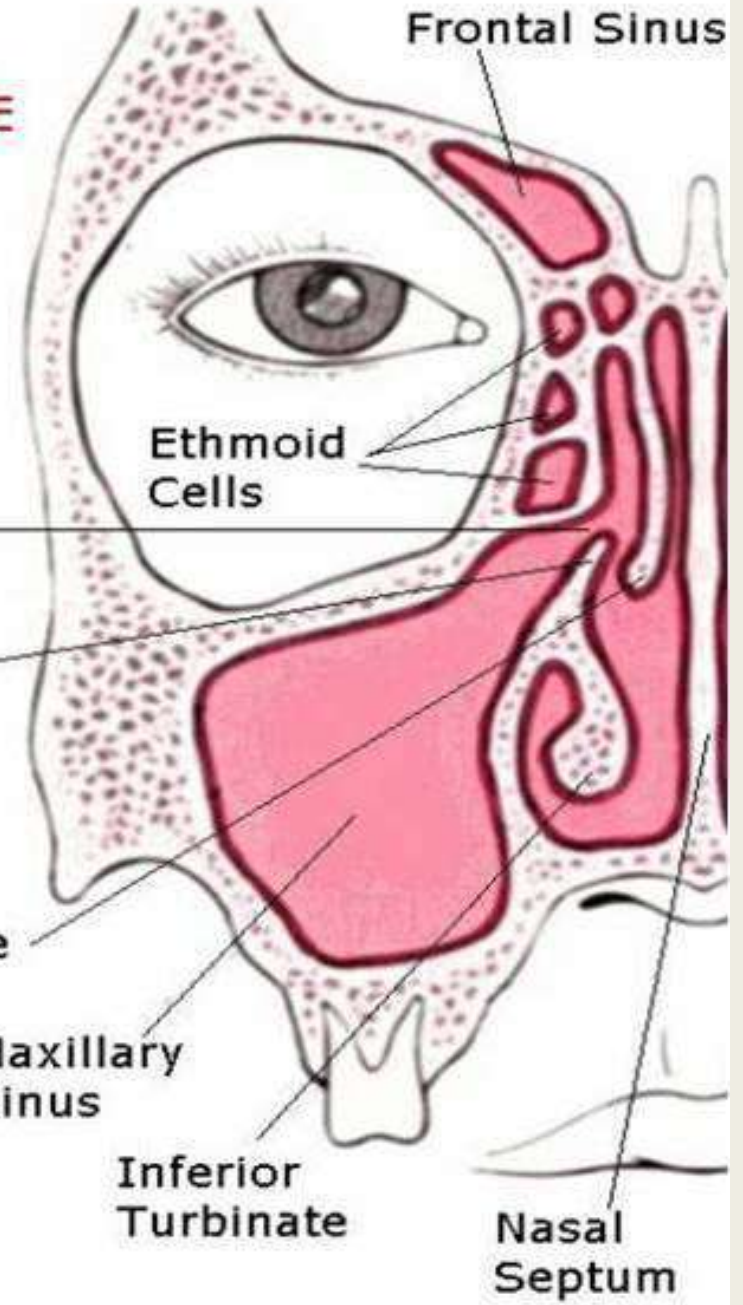
Maxillary
Sinus

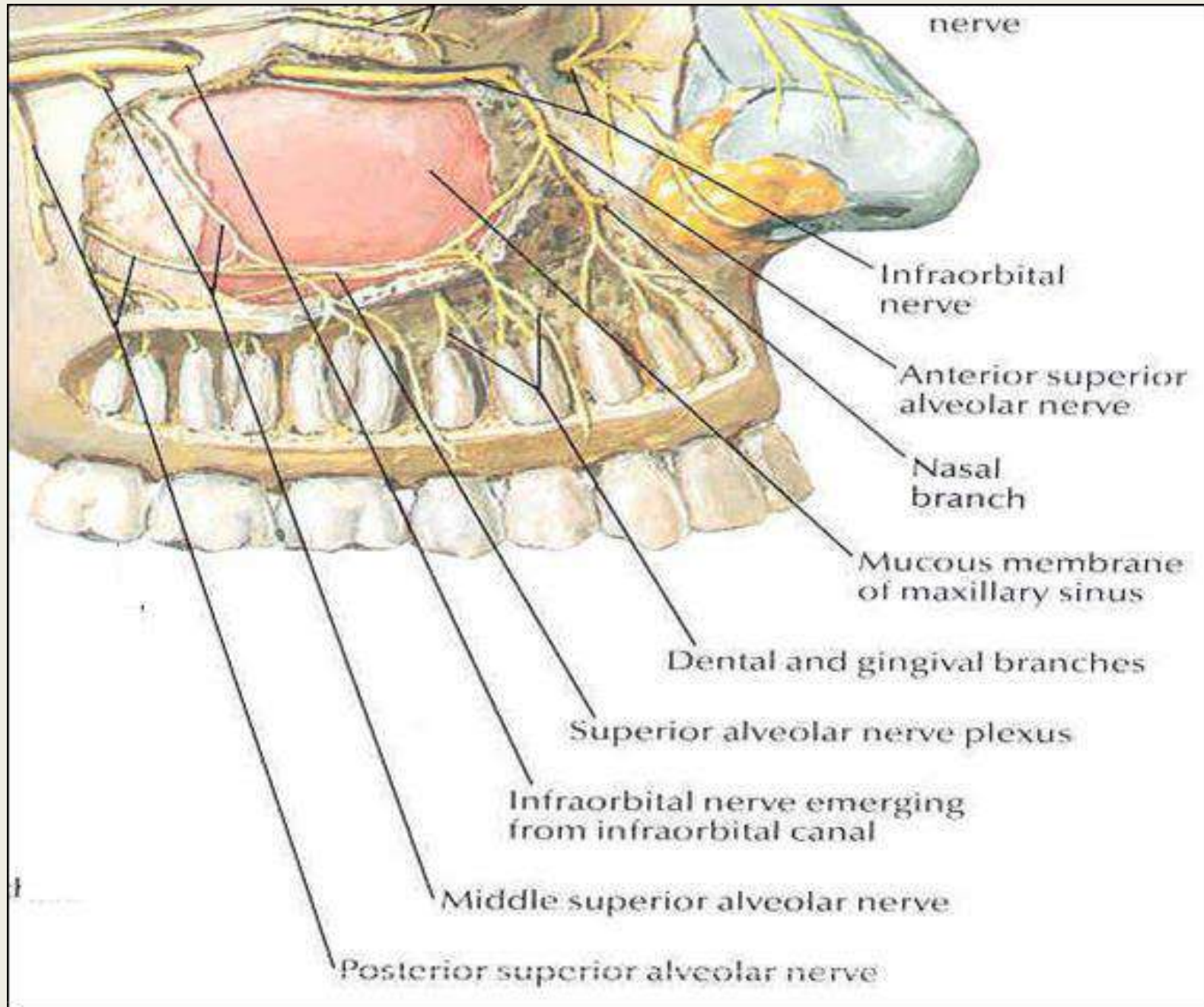
Inferior
Turbinate

Nasal
Septum

Frontal Sinus

Ethmoid
Cells



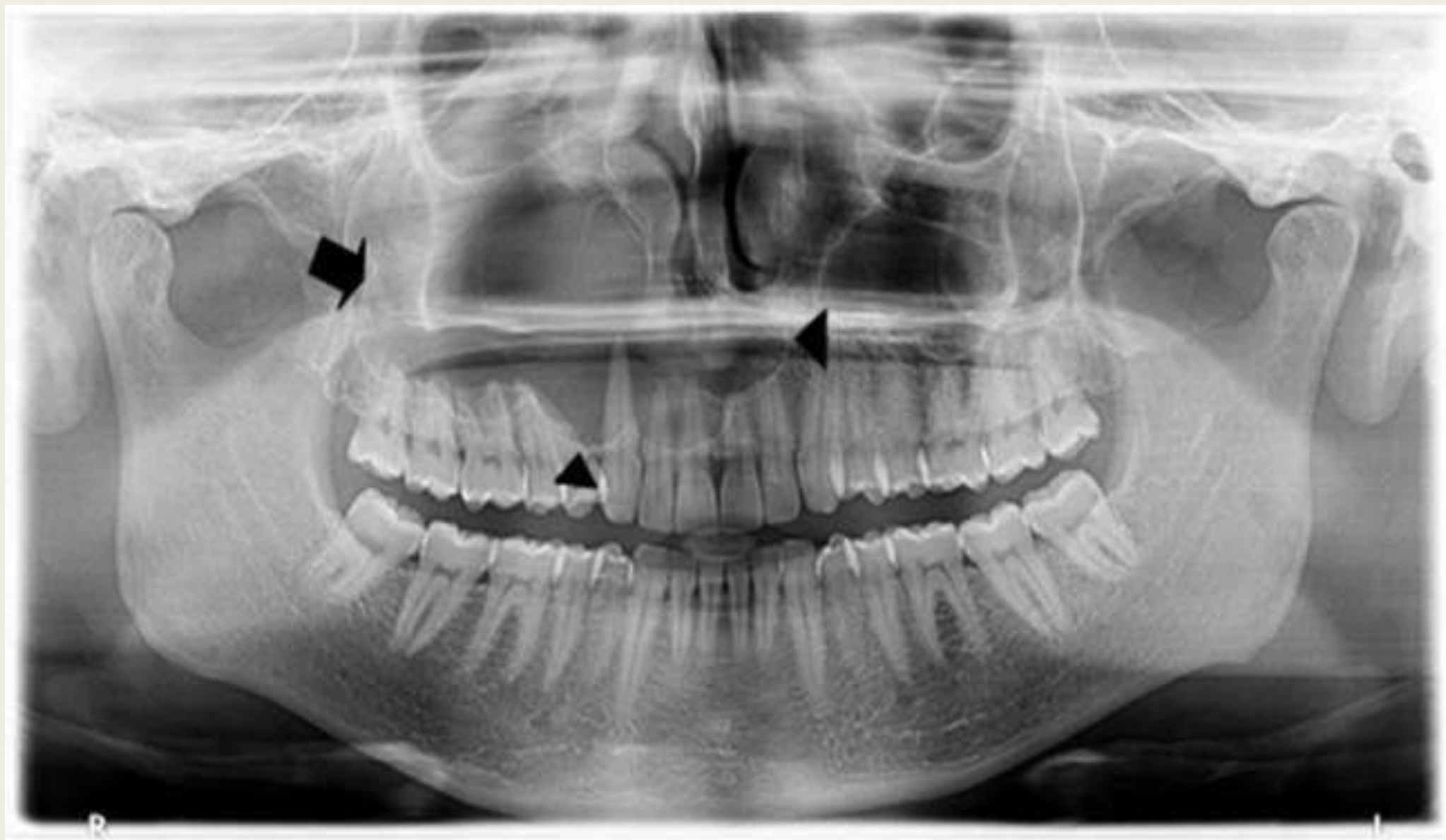

FUNCTION OF PARA-NASAL SINUSES

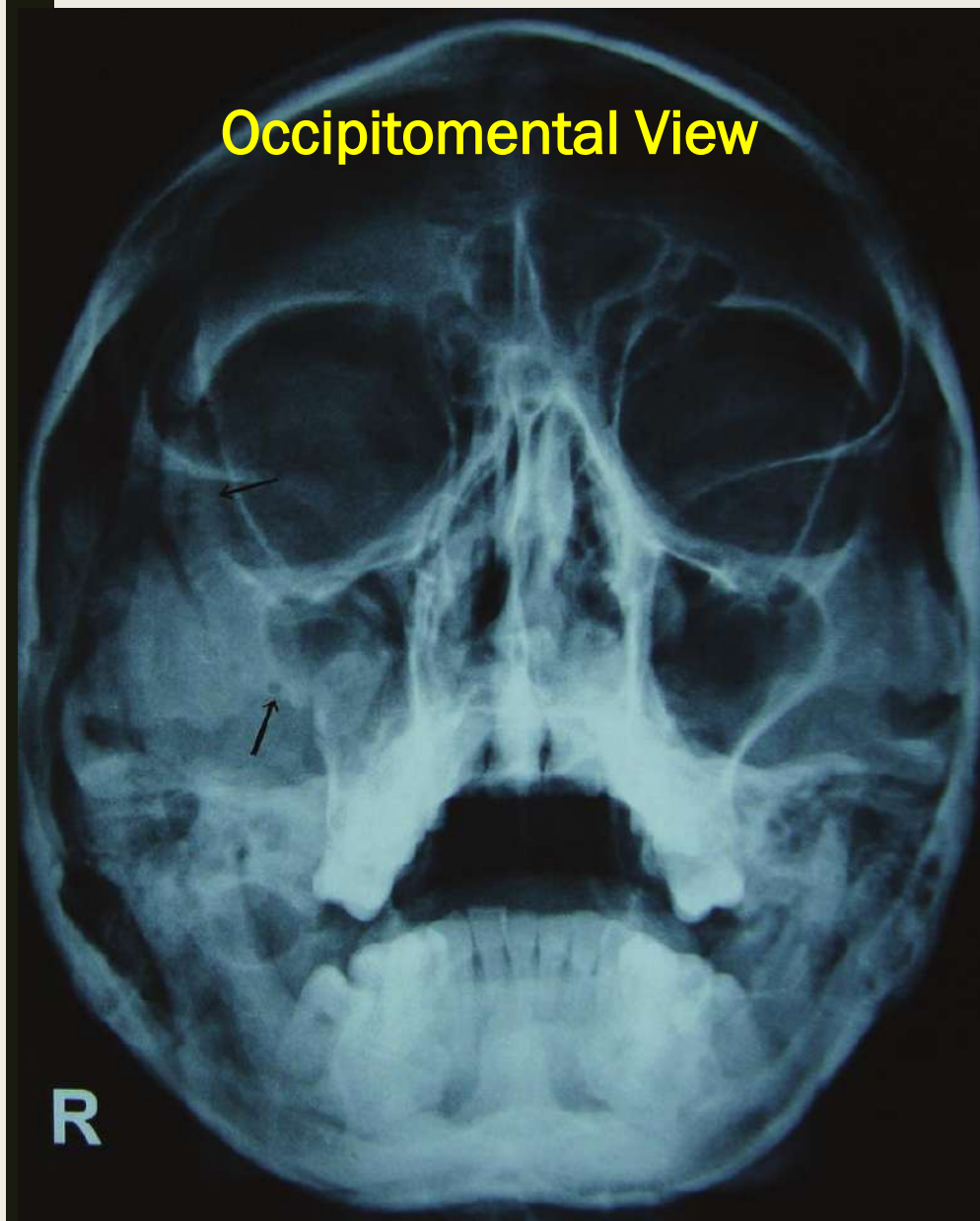
1. Reduce the weight of the skull.
2. Maintain Humidification ,warming and Filtration of inspired air.
3. Give resonance to the voice.
4. Act as Shock absorber to protect the base of the skull & brain from crushing.

RADIOGRAPHICAL APPEARANCE

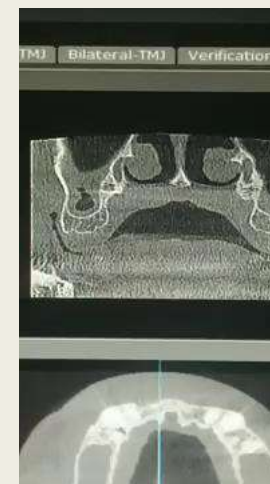
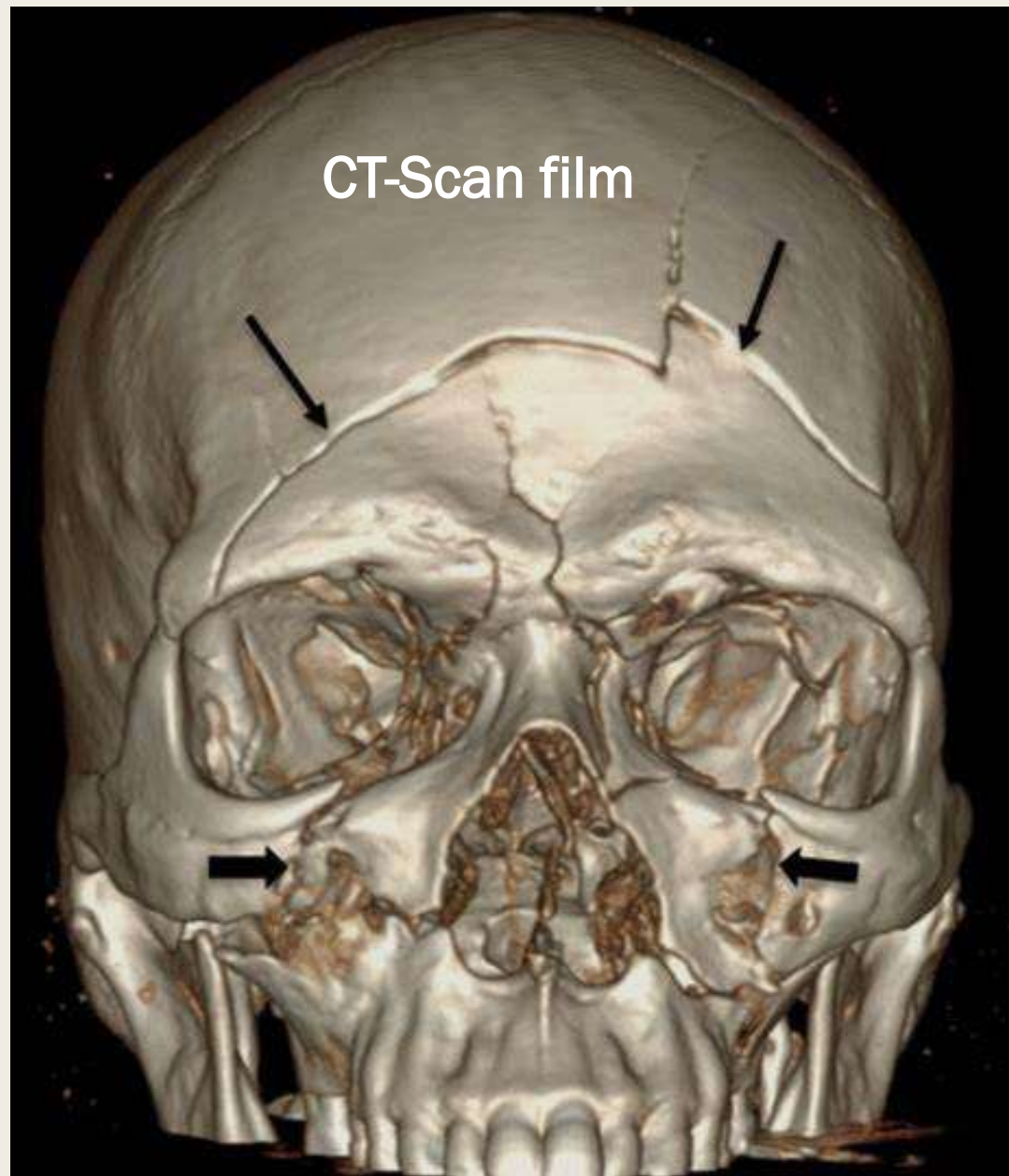
1. Plain x ray view is water view (occipitomenal view).
2. OPG (orthopantomogram).
3. Cone -Beam CT (CBCT).
4. CT-Scan film.
4. MRI magnetic resonance image.

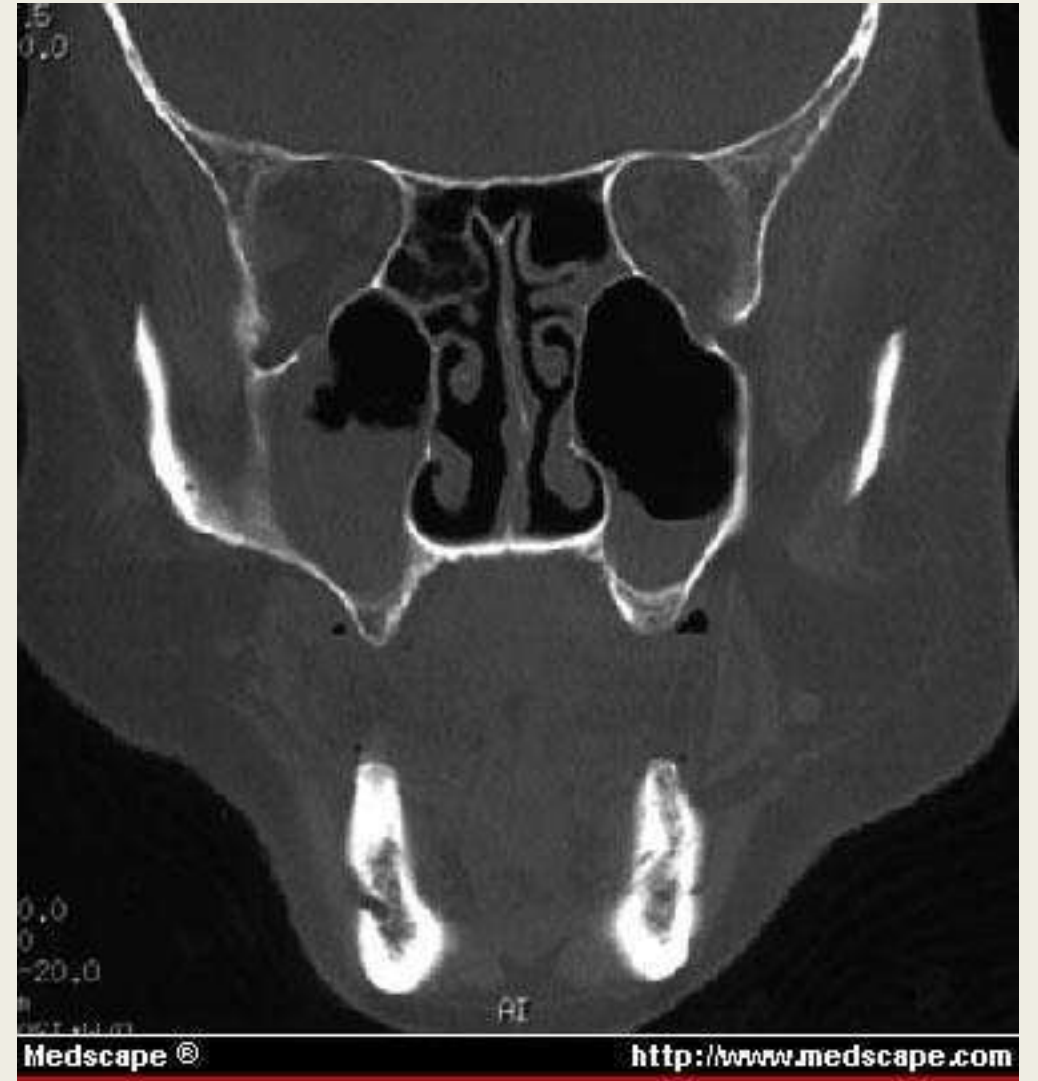
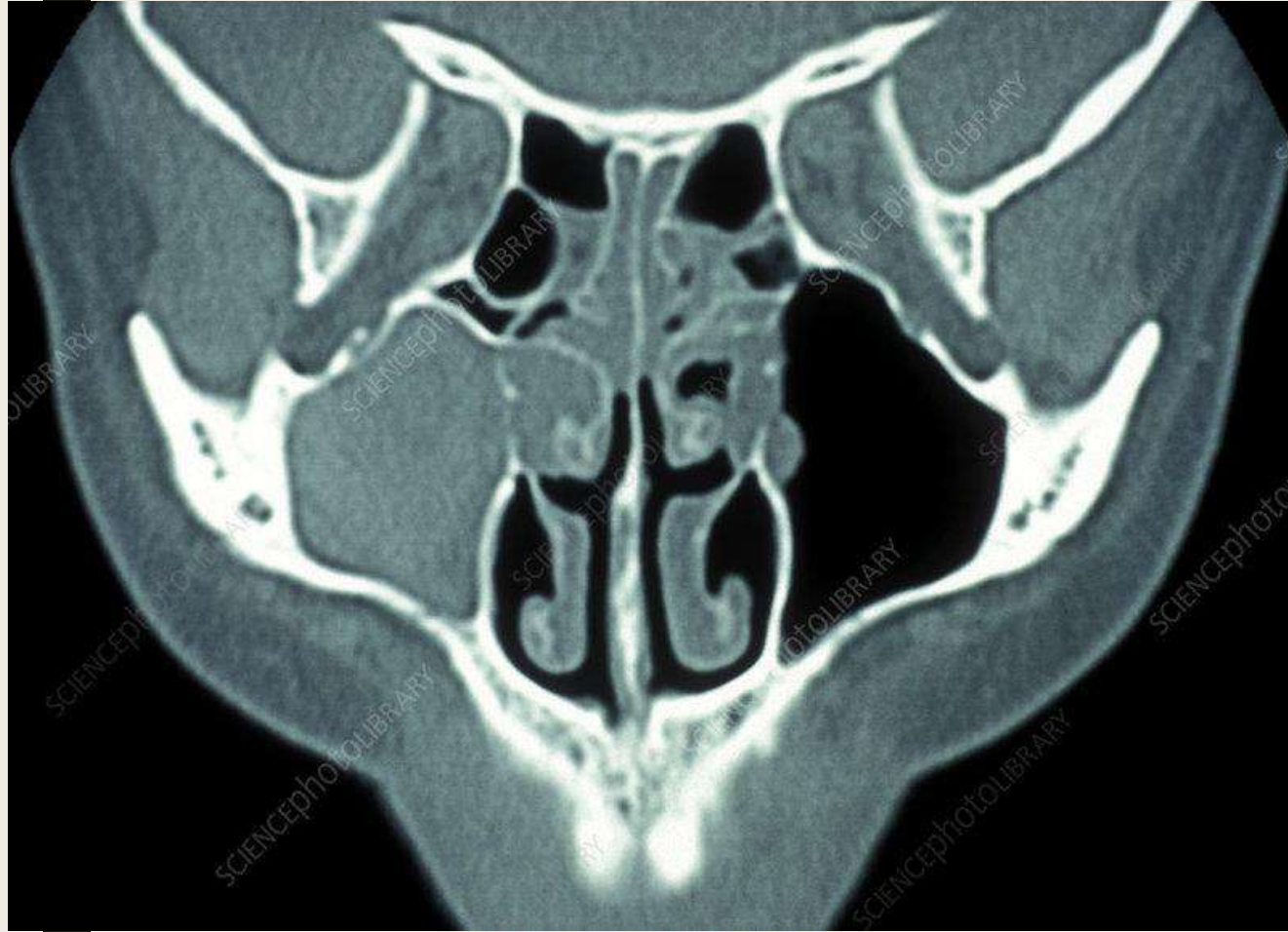


Occipitomental View



CT-Scan film

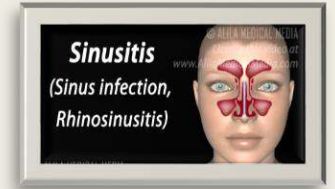




DISEASES OR COMPLICATIONS AFFECTING THE MAXILLARY SINUS

1. *Sinusitis.*
2. *OAF (Oro-Antral Fistula).*
3. *Displacement of root or tooth into the maxillary sinus.*
4. *Fracture of maxillary tuberosity.*
5. *Malignancy of maxillary sinus.*

1- SINUSITIS



- It May be an allergic condition or due to an infection.
- The infection may be **viral or bacterial** & it's either **acute or chronic** sinusitis.

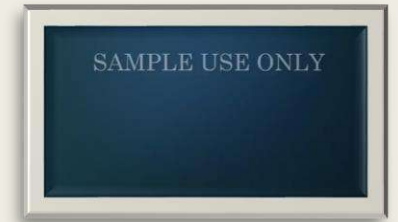Acute Maxillary Sinusitis

- Symptoms depend on the virulence of microorganism & presence of an occluded ostium
- The **Main Symptom** is severe pain which is constant & localized.
- The teeth in the region may become extremely sore & painful.
- The nasal discharge at first is thin, watery, serous but soon it becomes mucopurulent.
- Sinusitis due to **infected teeth present with very foul odor secretion.**
- General toxemia develops with the disease, producing chills, sweats, elevation of temperature.

Subacute Maxillary Sinusitis:

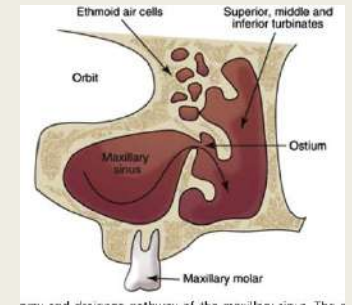
- Intermittent stage between acute & chronic sinusitis.
- Proper medical & surgical treatment is important to prevent the acute case from becoming a chronic.
- The relief may come slowly or suddenly, but it usually takes place soon after improvement of drainage from the sinus reaches the point that secretions are able to leave the cavity as rapidly as they form.

Chronic Maxillary Sinusitis



It's produced by following factors

1. Repeated attacks (or persist) of acute sinusitis.
2. Untreated dental focus.
3. Chronic infection in frontal or ethmoid sinuses.
4. Debilitating disease of all kinds.



- The lining appear thick in radiograph, this thickening lead to ostium blockage & accumulation of fluid, so antibiotic is of little value, the treatment is best be done by performing an intra-nasal antrostomy.
- TREATMENT:- If it is **allergic** condition treated by antihistamine or steroid; **bacterial** sinusitis treated by antibiotic. **Surgical treatment “antrostomy”** when needed.

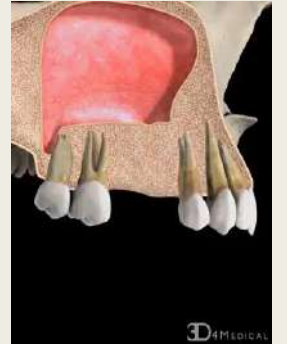
2- ORO-ANTRAL FISTULA (OAFistula\OACommunication)

- It is an abnormal connection between the oral cavity and the maxillary sinus.
- Average time 7 days, Oro- antral perforation epithelialize, become a fistula.

Causes of Accidental OAF

- 1) Increases size of the maxillary sinus extends downwards into the alveolar process roots of the premolars & molars.
- In some cases the apices separated from the antrum by thin lamellar bone, so heavy rocking movement of the tooth during extraction leads to OAF.

2) **The thin bone between the tooth** & the antrum may be destroyed by pathological process related to the apices of the teeth (**periapical granuloma or cyst**).

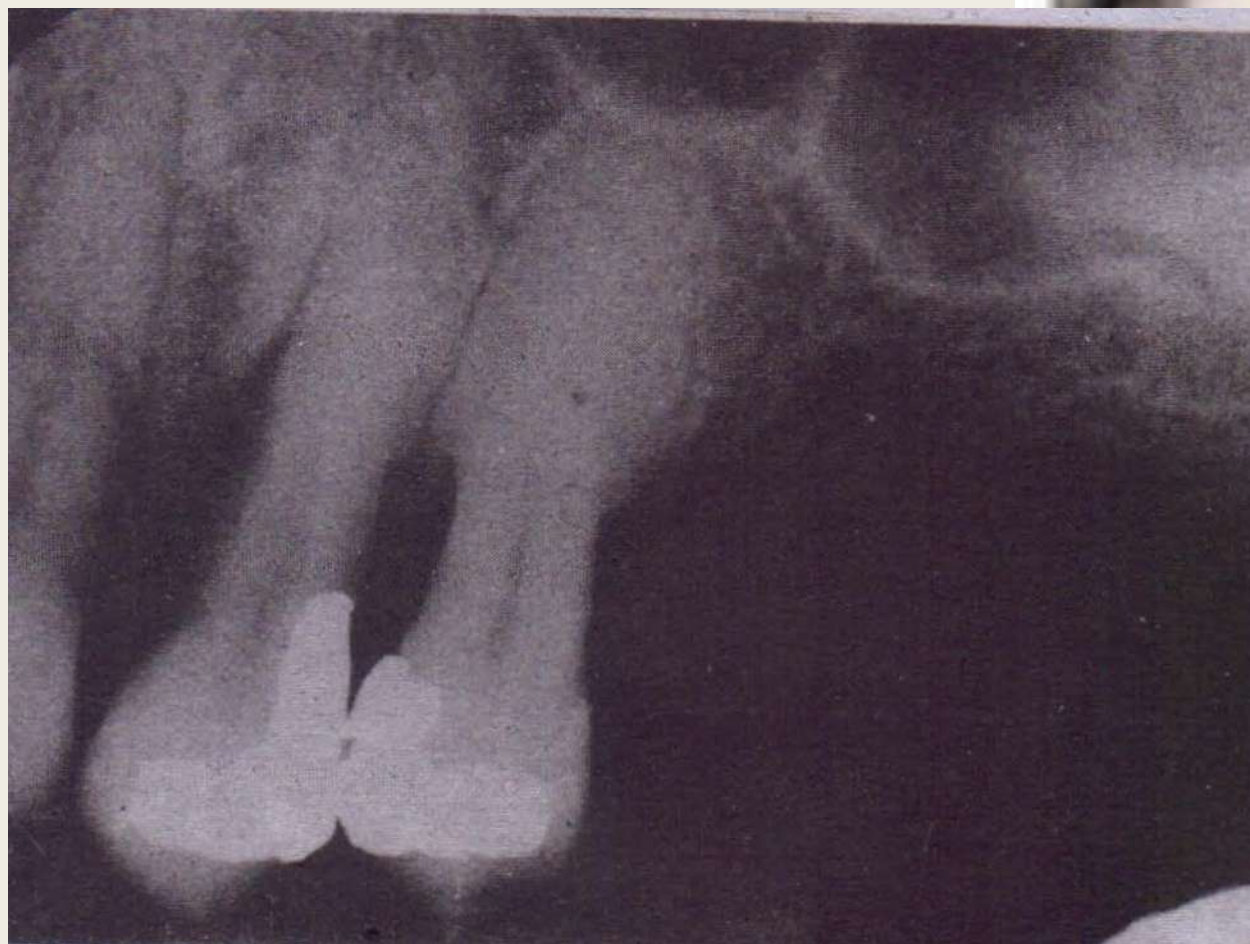
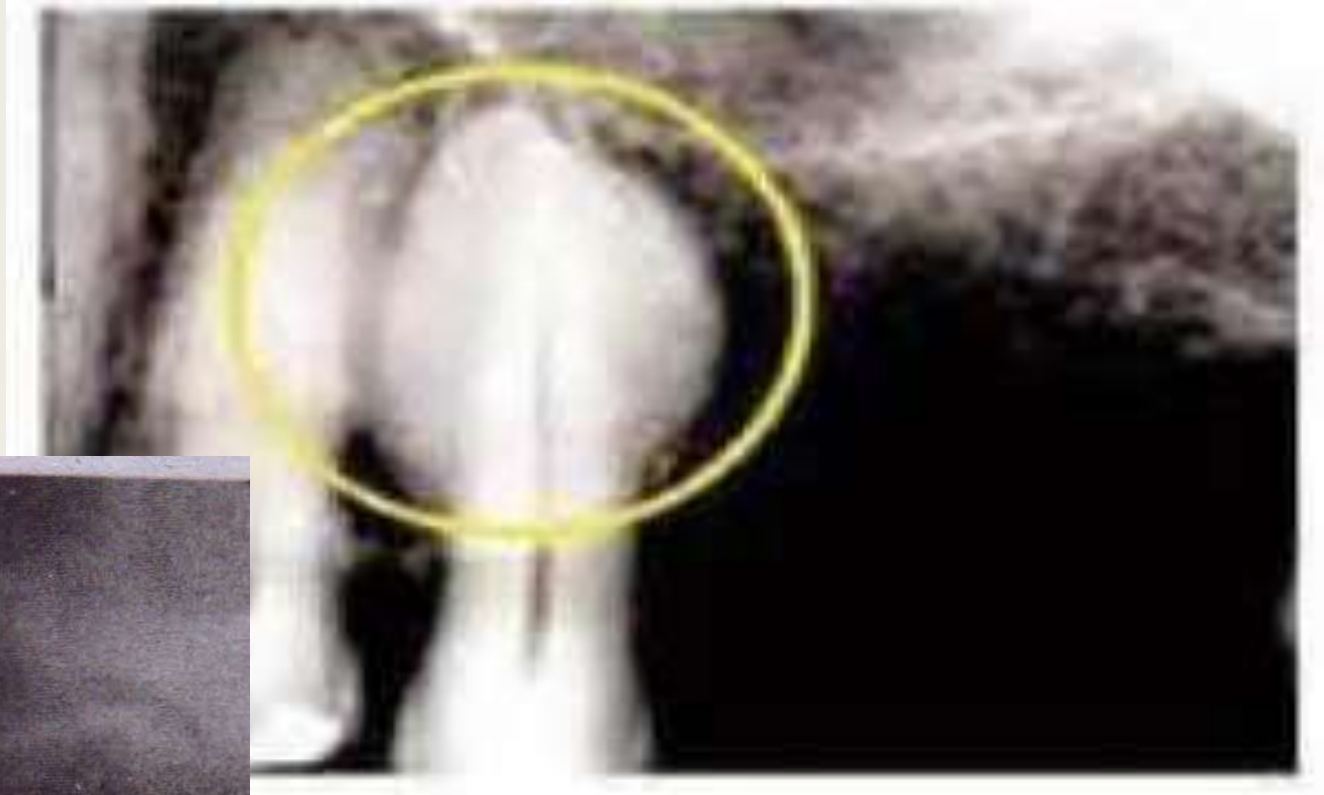
- **Never attempt to curate** the apical lesions related to upper roots.

3) **Hypercementosis**, bulbous root apex or the two buccal roots of a molar may fused at the apices embracing the inter-radicular bone, so that segments of socket wall will removed.

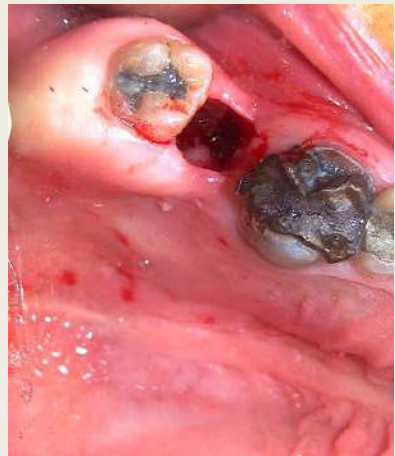- As a general rule, it's better **to leave in situ the apical one third of palatal root**, unless associated with periapical lesion.

4) For extraction of an **isolated molar** or there is a history of antral involvement complicating previous extraction (**due to** pneumanisation). **The tooth should be evaluated by radiograph.**



Diagnosis of OAF

- **Nasal blowing test** in which the patient attempts to blow through his occluded nostril with his mouth open, air will be heard to pass through the defect
- Nose-blowing test is **not always positive** even in presence of OA Communication,
- It's **wrong** to explore the socket with sucker or push probe into the socket.
- Radiographs used are periapical, occlusal, OPG and CBCT



TREATMENT - By surgical closure.

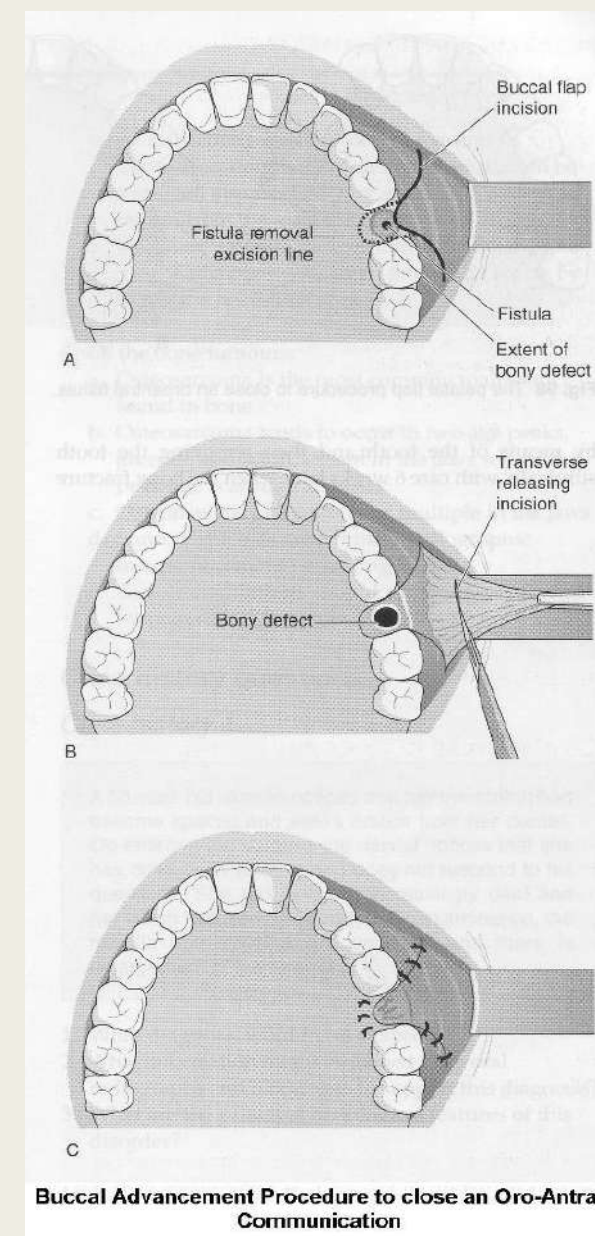
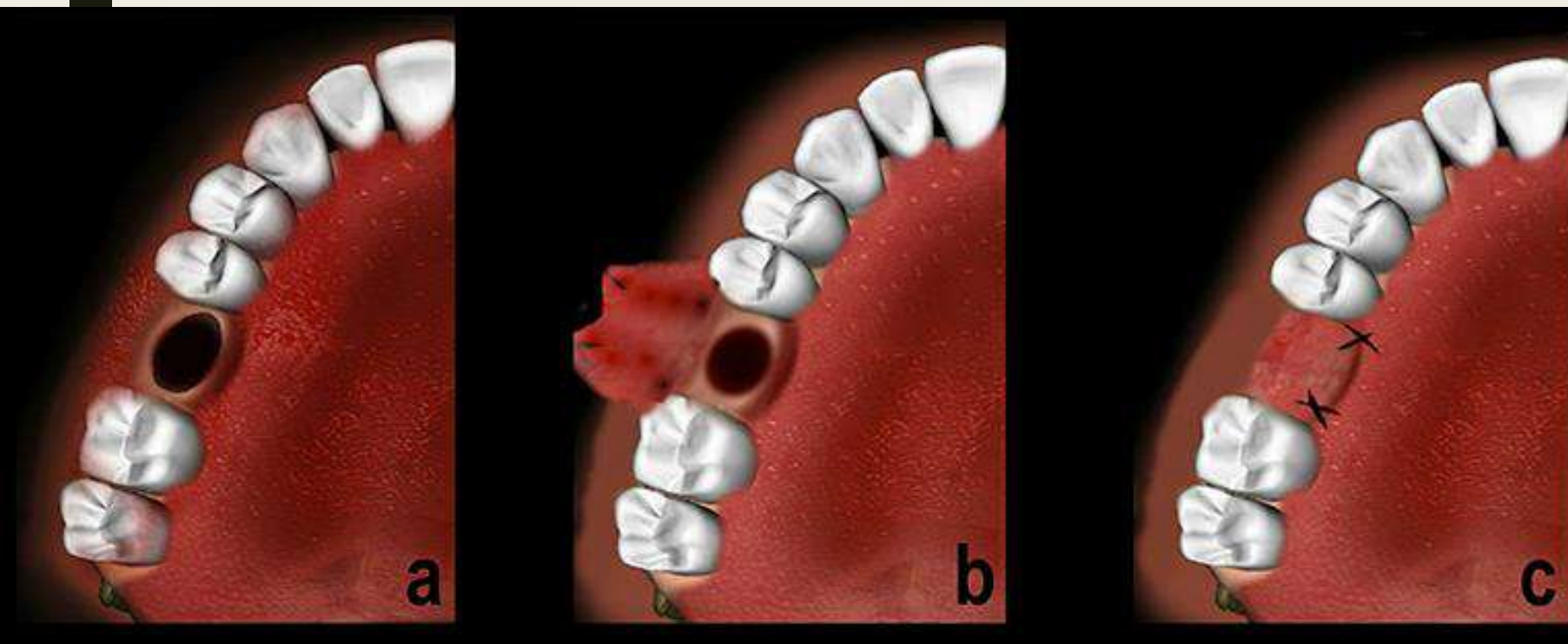
The patient warned that even suitable operation, it may fail & fistula re-established, ,

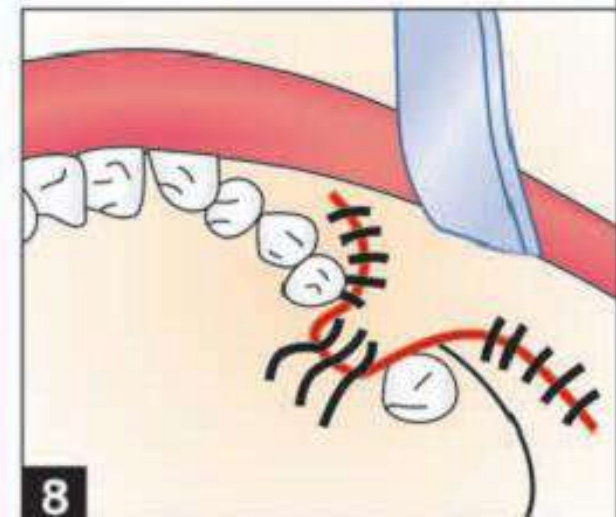
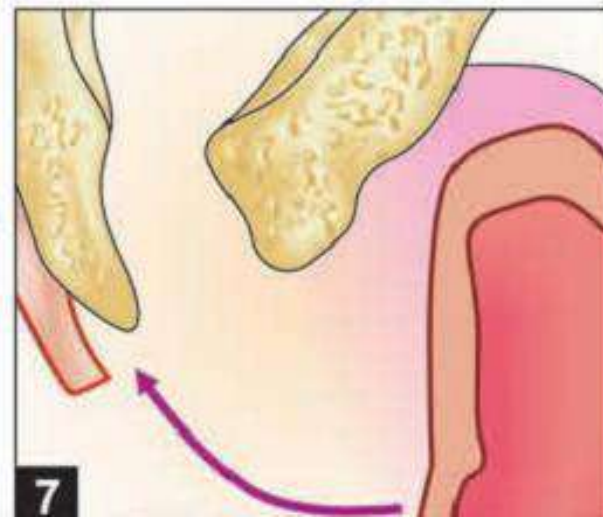
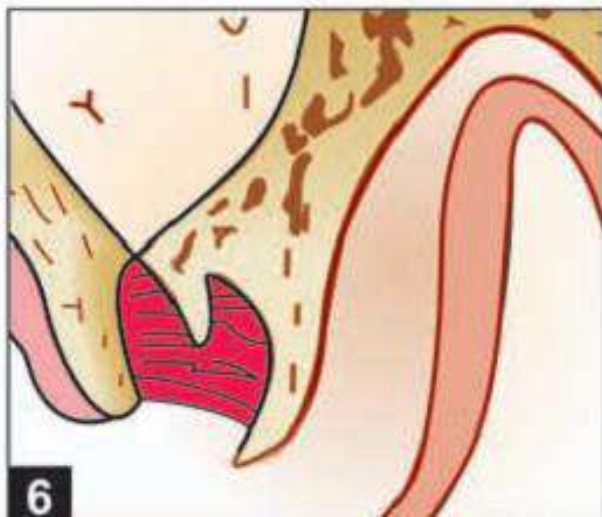
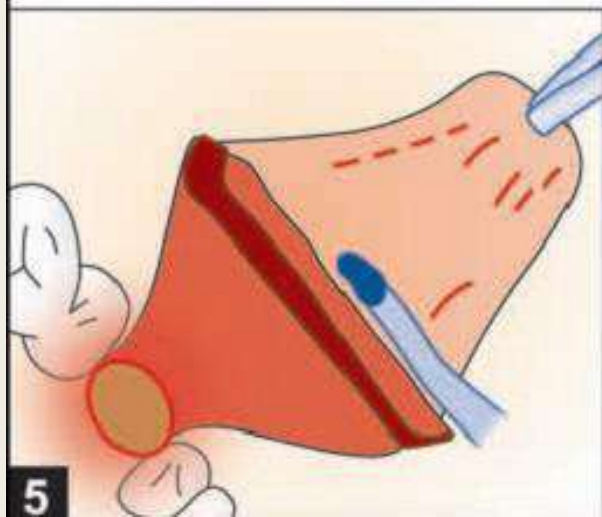
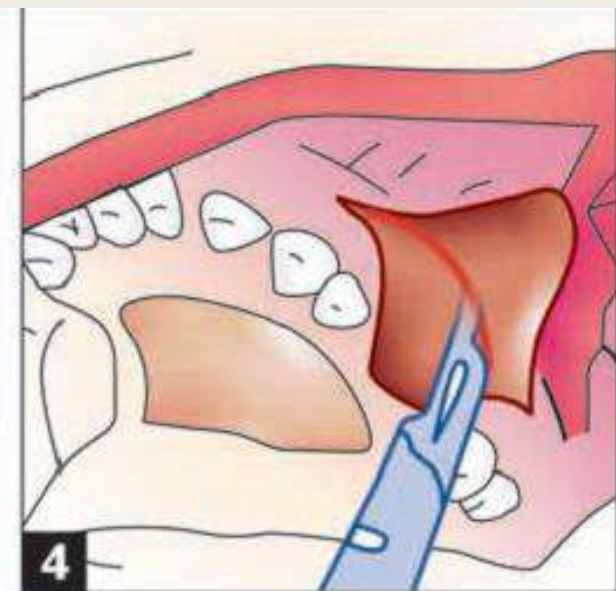
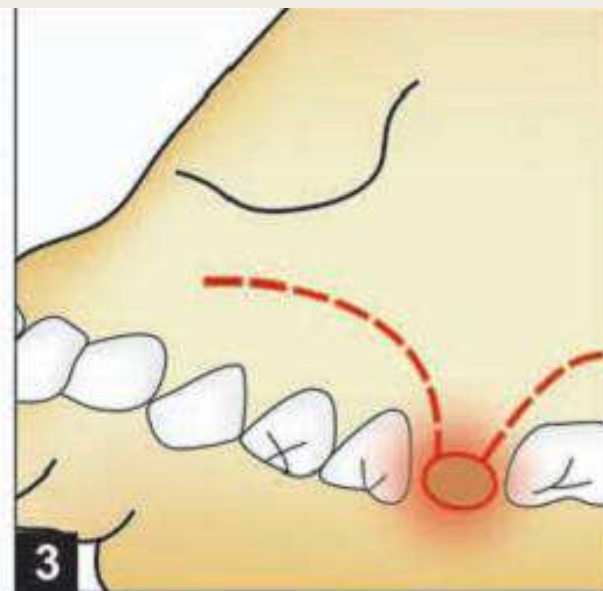
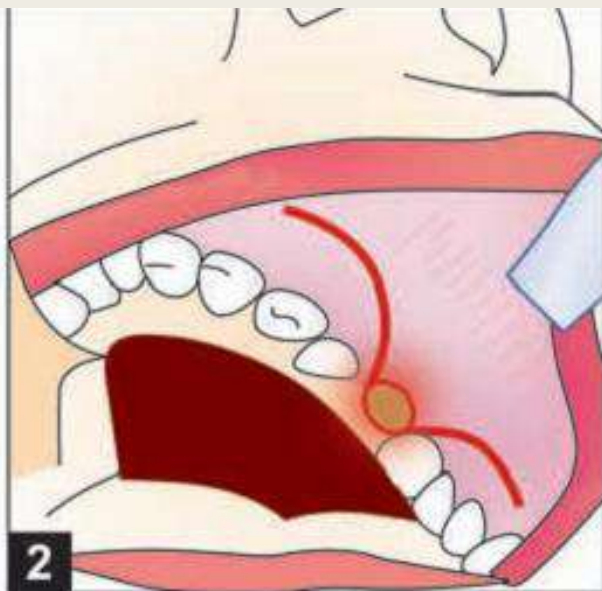
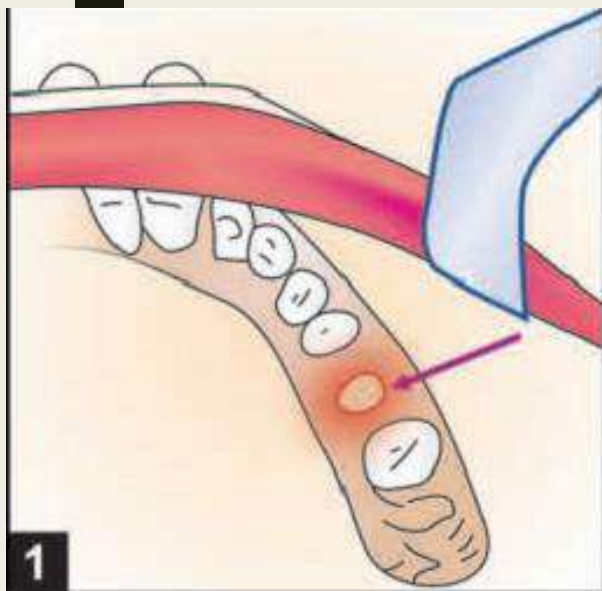
To avoid failure : -

- 1) The flap should cover **not only** the fistula but also the bone which support the suture line.
- 2) The flap should have a good blood supply, handled gently, **not crushed** with instrument.
- 3) The flap should **be sutured without tension**.
- 4) **Good homeostasis** before suturing because hematoma will cause tension on the flap & infection.
 - The **simplest method** for closure of new OAF by raising a mucoperiosteal flap buccally, and reduce the height of bone buccally, then sutured without tension.
 - Suture left **for 2 weeks**, a heavy dose of antibiotic **with nasal decongestant** drops & analgesics, also ask the patient to **not sneeze** or cough or shout.

Buccal Advancement Flap:

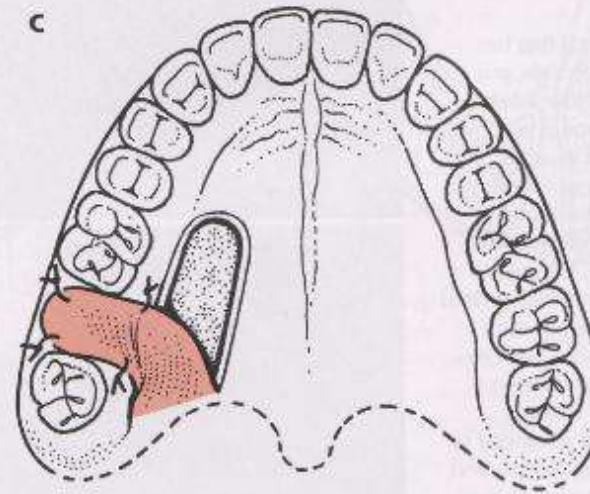
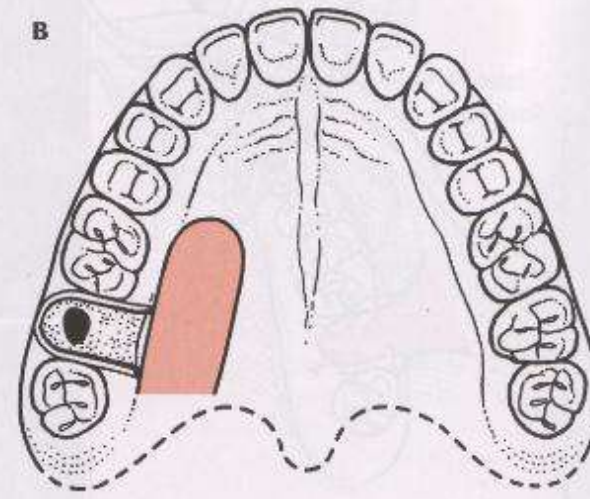
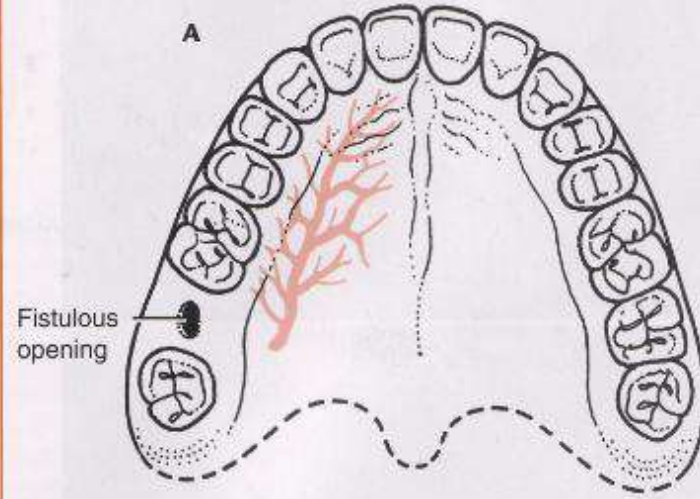
- This type of flap used to close
 - 1- **newly created opening** at the time of extraction
 - 2- or to close a fistula in combination **with displaced root.**
- Three-sided mucoperiosteal flap is raised buccally, the periosteum is incised from distal to mesial.
- Refresh the palatal edge about 2-3 mm, then the buccal flap pulled & sutured in eversion against the palatal flap without tension, otherwise ischemia will occur. Sutures left for 2 weeks.
- During the initial healing period, the patient must be advised to avoid movement which stretch the cheek.
- This procedure leave a shallow buccal vestibule.





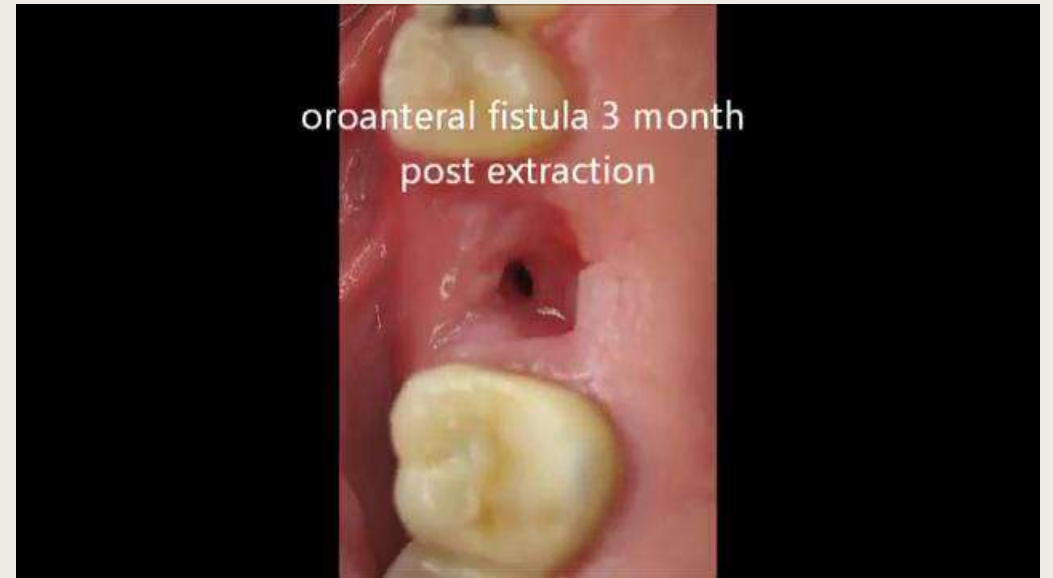
Palatal pedicled flap (rotational advancement flap) technique: Palatal Transpositional Flap

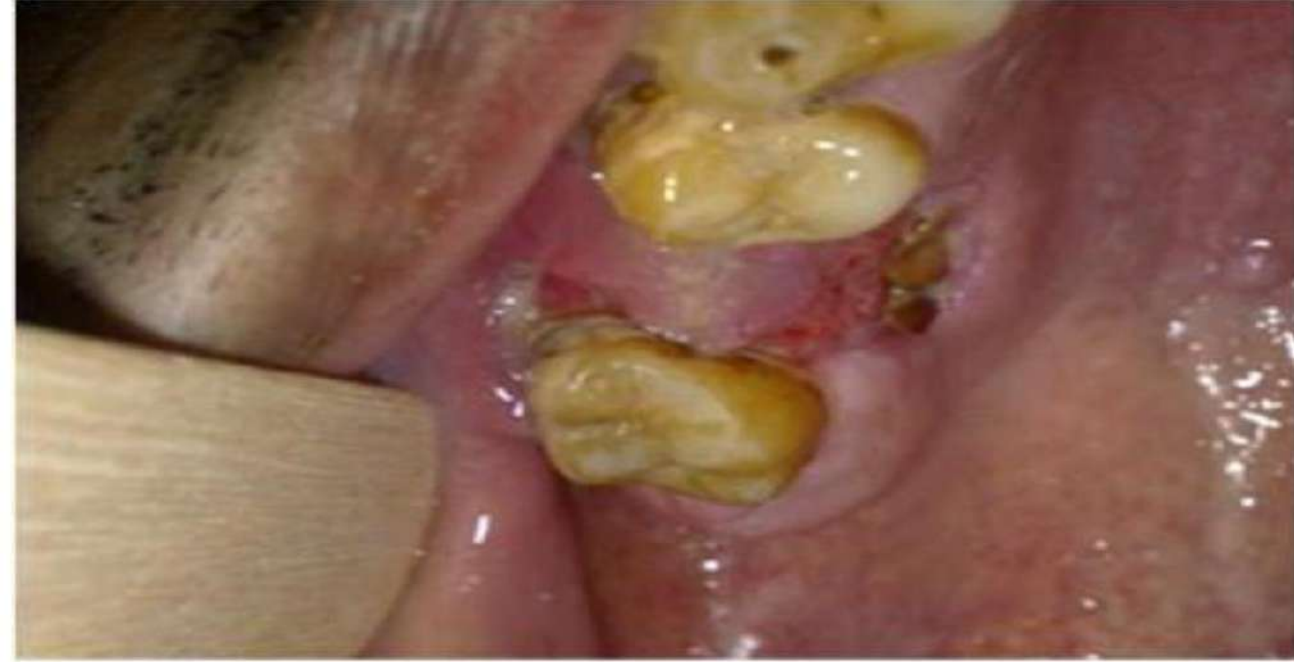- This type of flap used for **chronic fistula or for previous unsuccessful attempts** to close the fistula using a buccal advancement flap.
- In case of **chronic fistula, there is fibrous tract**, which excised & the bone exposed after removing this lining around the opening of the fistula.
- A pedicle or finger-like strip flap from the palate raised, which is thick & contain the greater palatine vessels. Such flap has high success rate because of good blood supply, this flap is more difficult to transposed because of it thickness.
- Then sutured with freshened end of buccal tissue by mattress suture, which should be occlude the cut artery.
- Palatal flap supported with further multiple interrupted sutures to the buccal tissue.
- Sutures should be left for 14 days, the exposed part of palatal bone (donor area) covered by dressing such as ribbon gauze & sutured with periosteal tissue of the palate.



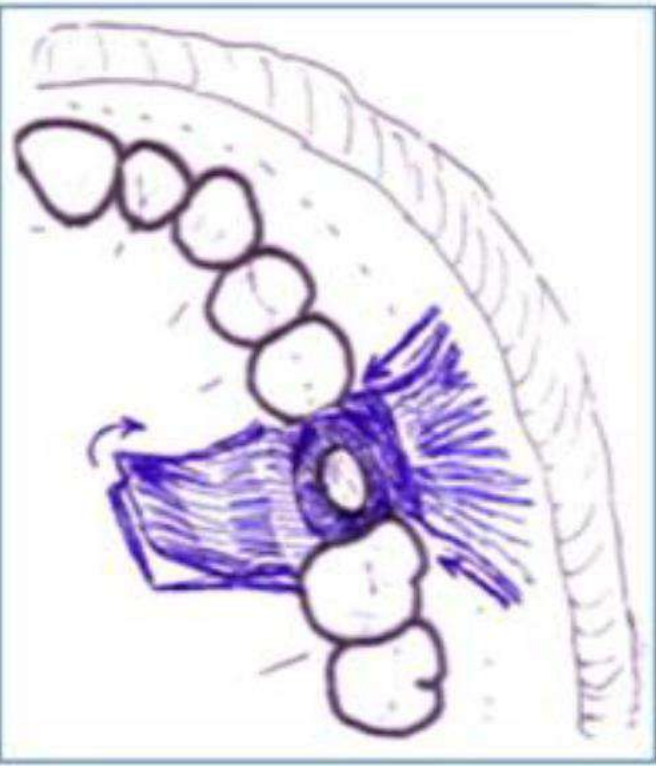
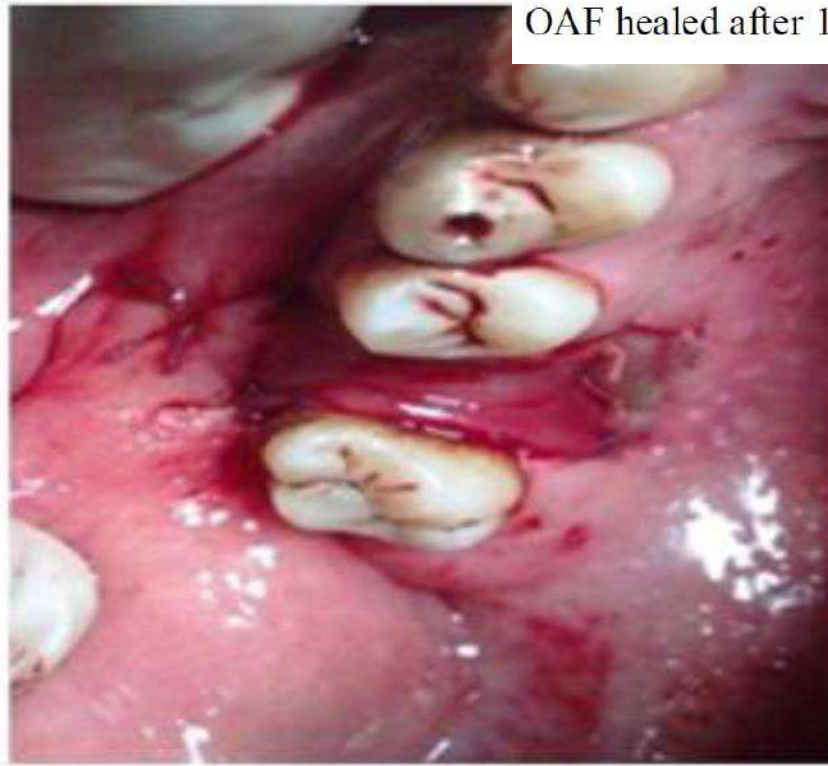Combination of Buccal and Palatal Flaps

- **Indicated** for the Closure of large defect and for failed repair.
- The Advantages gained from this combination are the **Double layer flap** so improve strength and minimize contraction and risk of infection.
- Disadvantage of this procedure; **bone of the hard palate is exposed**, and re-epithelialization requires from 2 to 3 months, healing by secondary intension .
- Fistulectomy by incising the wound edges of the fistula, followed by designing the palatal flap on the basis of the greater palatine vessels,
- The palatal flap was then inverted so that the oral palatal epithelial surface was covering the bone defect. Then covered by the buccal advancement flap.





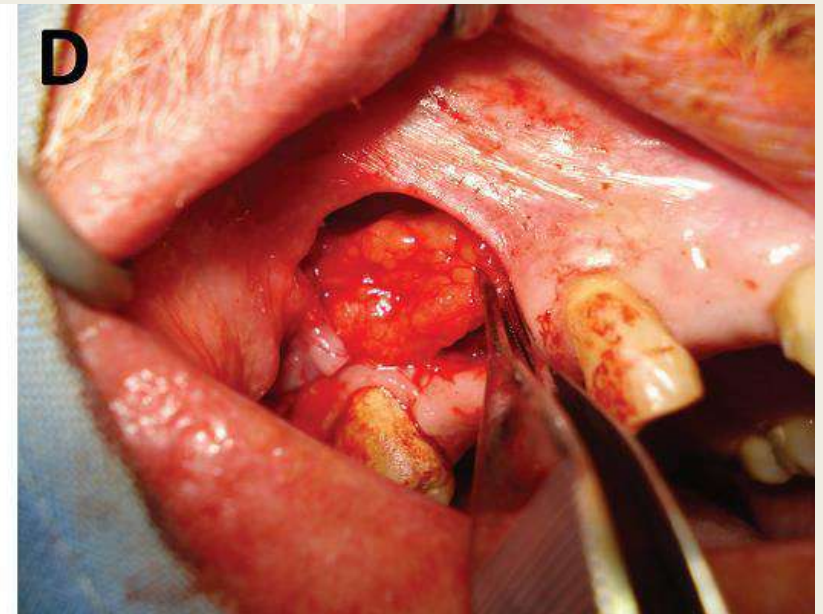
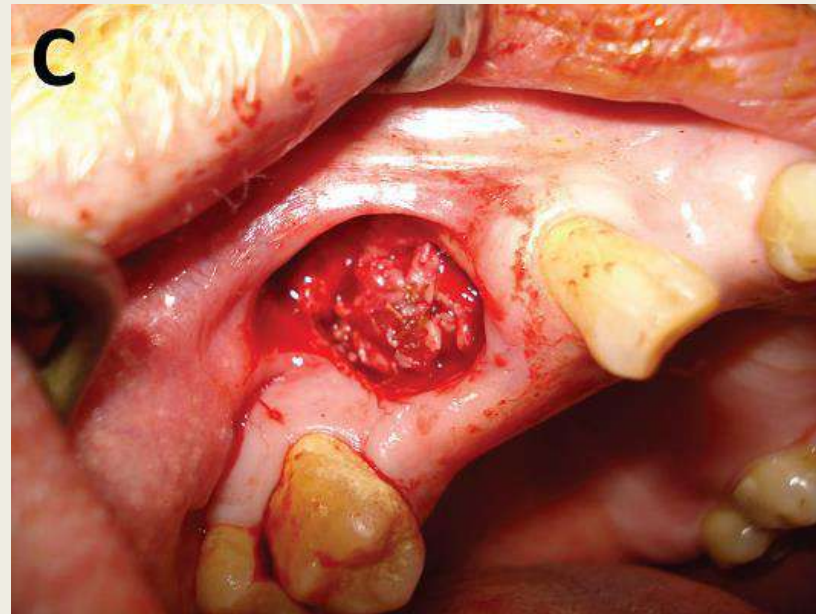
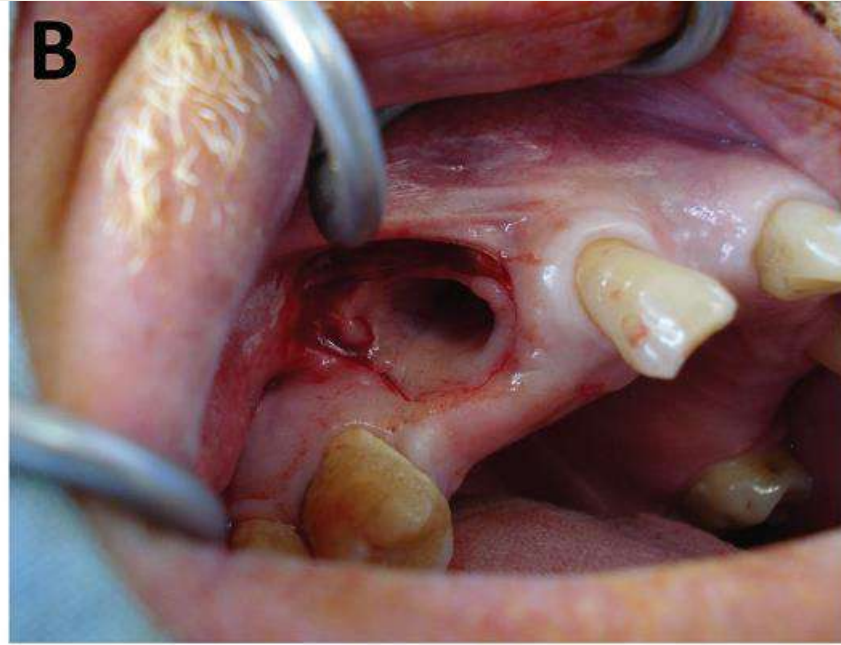
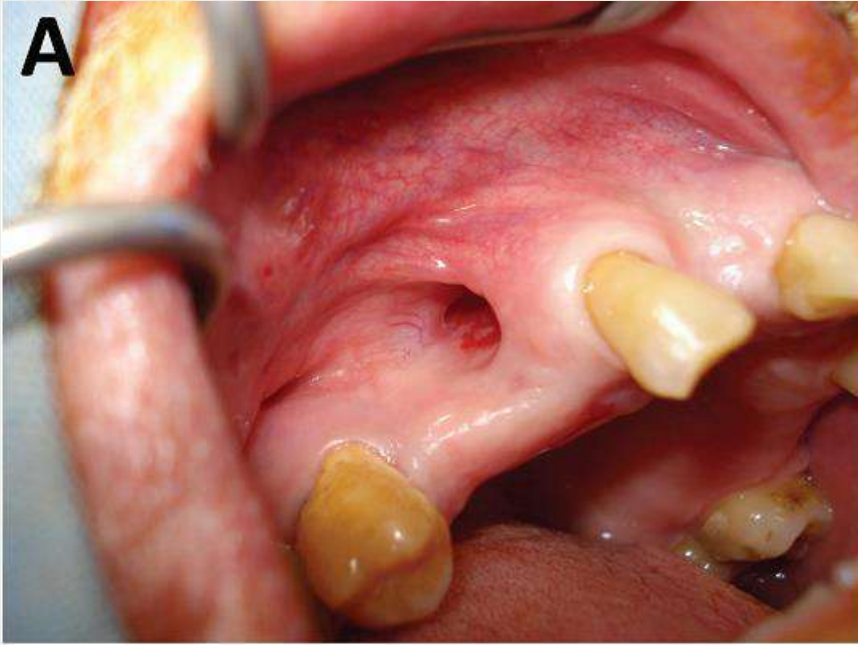
OAF healed after 1 month of surgery by this combination



Buccal Fat Pad flap BFP Technique

- BFP could be used as a pedicled graft for the closure of OA communications.
- The buccal pad of flap (also known as Boule de Bichat) is a simple lobulated mass covered by a capsule located between the buccinator muscle medially and zygomatic arch laterally .
- Buccal fat pad flaps recommended for the closure of fistulas of varied sizes and locations, and repaire of unsuccessful surgical cases.
- Among the advantages of this technique are the low morbidity rate, maintenance of the vestibular sulcus depth, its high applicability, the low incidence of failure, and the good flap vascularization and size .
- when fat tissue is exposed to the oral environment, it becomes epithelialized and replaced by fibrous connective tissue within a 30-40 days postoperative period.

- In order to reach the BFP an incision of the posterior mucosa must be made in the area of the zygomatic buttress, followed by a light incision of the periosteum and of the fascial envelope of the buccal pad.
- A gentle dissection with fine curved artery forceps exposes the yellowish-colored buccal fat.
- The buccal fat pad was dragged into the fistula site so that the latter was completely covered then sutured with simple 4-0 silk thread stitches, without tension
- Problems and complications that can be noted while harvesting BFP ranges from perforation to shrinkage of BFP and reduction in buccal sulcus depth .



Double-layered closure (Buccal Fat Pad BFP and buccal advancement flap)

- Wide and large defects (5-10mm), managed with the use of BFP with buccal advancement flap.
- This technique provides more stability to the surgical closure.
- Surgical Procedure Include (1 cm) vertical incision made inside the reflected periosteum posterior to the zygomatic buttress to allow exposure of the BFP, pulled over the bony defect and sutured to the palatal mucosa and buccal advancement flap was utilized to cover the fat pad.
- The flap sutured with simple interrupted 3/0 silk suture.
- The patient warned against blowing the nose for 2 weeks.

Postoperative instructions for all OAF closure procedures

- Nasal decongestant drops (Ephedrine nasal drops) for 3 days.
- Benzoin inhalation.
- Antibiotic; Amoxicillin 500g 8-hourly.
- Analgesic.

– *CHRONIC OAF: -*

- If the OA Communication untreated, **spontaneous closure not occur**, then a chronic fistula becomes established lead to reflux of food & drink from the mouth to the nose which cause trouble to the patient.

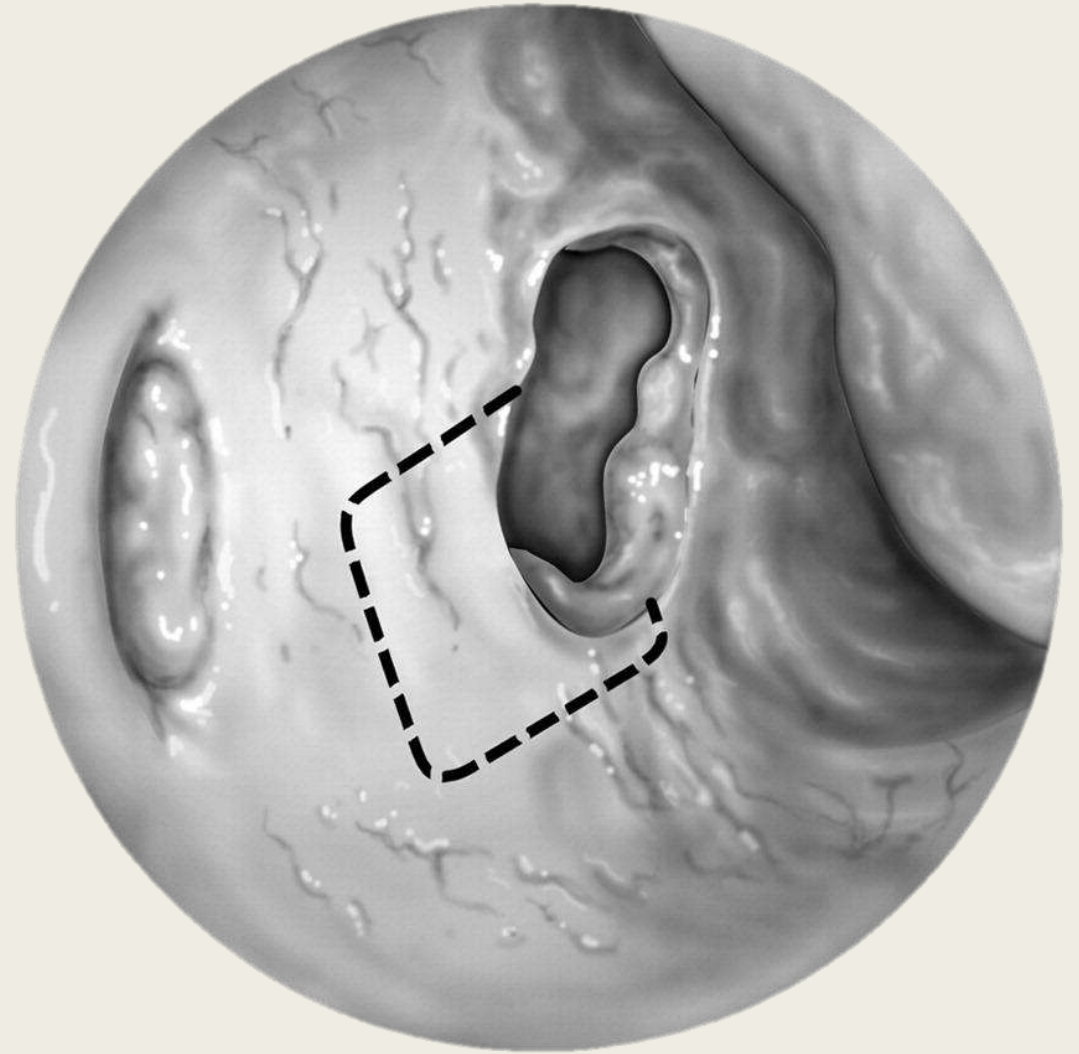
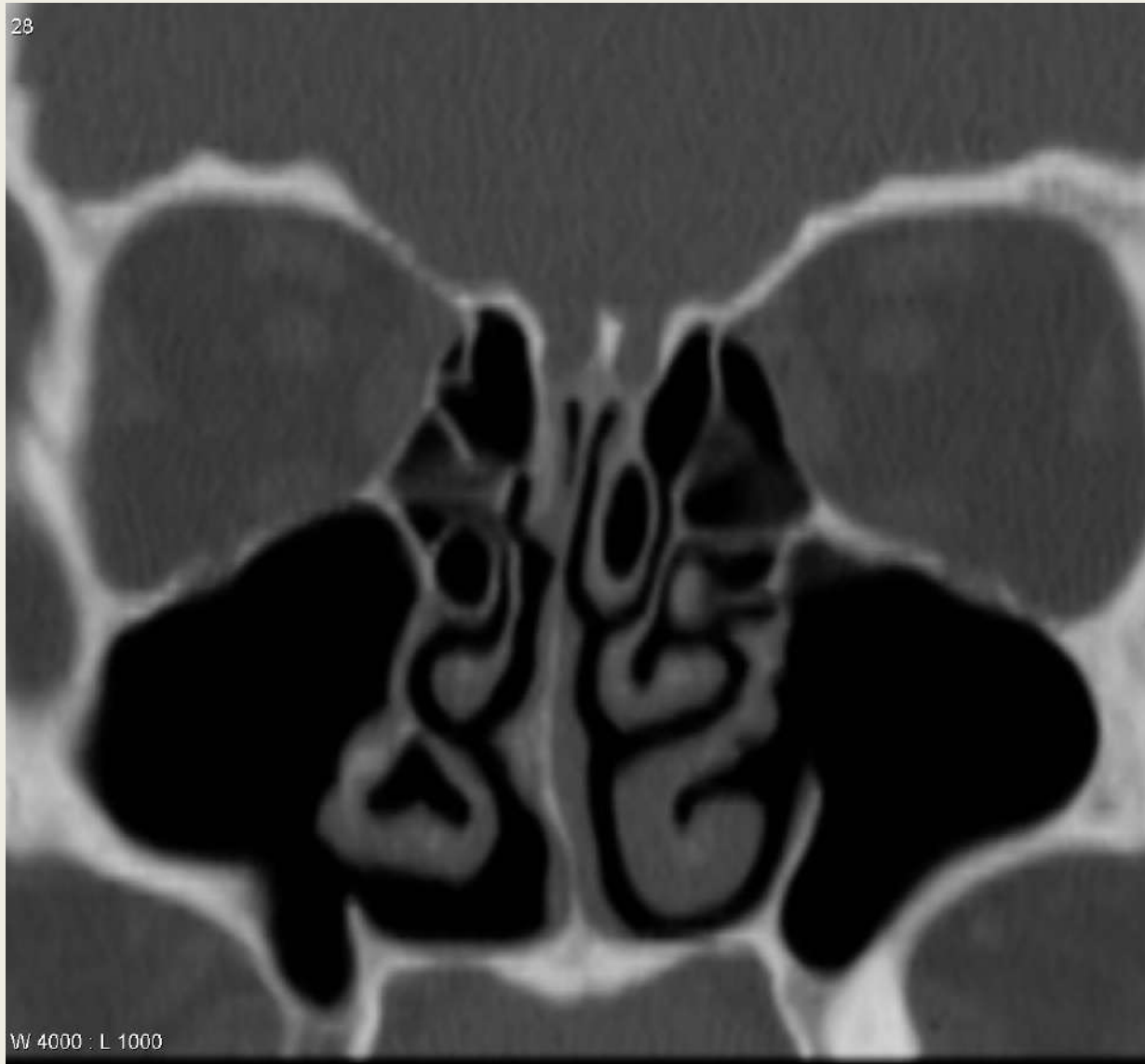
- *Causes of Persistence Fistula*

- 1) Unrecognized fistula.
- 2) Advanced periodontal diseases (shallow pocket).
- 3) Pre-existing infection, drain from the socket.
- 4) Insert of packs, sponges prevent clot formation.
- 5) Flap under tense suturing.

Management of Chronic Fistula (before surgery)

■ The aim is to eliminate antral infection & to prevent oro-antral reflux of fluids by:

- 1) Constructing acrylic base plate (obturator) which covers the defect.
- 2) Any polyp or granulation tissues excised to promote drainage through the fistula.
- 3) Irrigate the sinus with warm saline using 20 ml syringe and soft plastic catheter.
- 4) Prescribed antibiotic to control the infection.
- 5) Consultation with ENT specialist for antrostomy for chronic fistula.
- 6) Close the OA fistula with surgery.



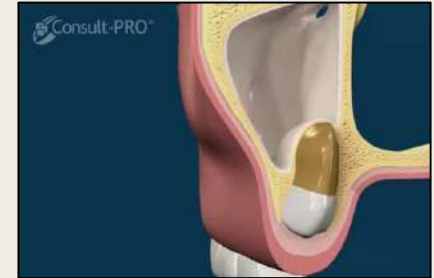Antrostomy

3- Displacement of a Tooth or Root Into the Sinus

- This complication occurs when there are:

- 1) Large maxillary antrum.
- 2) Erosion of the antral floor by periapical lesion.
- 3) Isolated upper molar tooth.
- 4) Faulty technique by dentist.

- Sometime the whole tooth may be displaced inside the sinus (impacted 3 and 8) due to poor pre-operative assessment & without good radiograph.
- When this happened, the position of the fragment demonstrated by multiple radiographs (periapical, occlusal, OPG & PA view), CBCT is the best.



- TREATMENT: -

- Do Not Try To Remove The Fragment Through The Socket

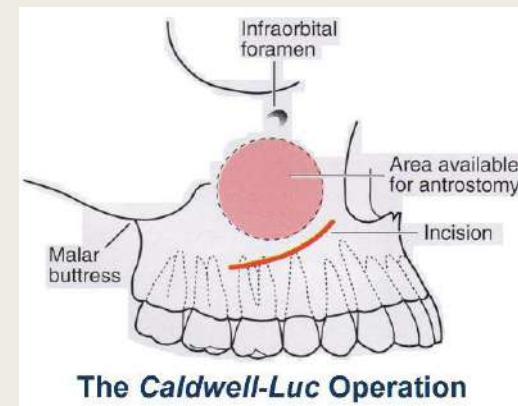
- If the root not enter into the sinus which is shown by radiographs, three sided flaps buccally raised & the buccal alveolar bone above apical area removed with round surgical bur & remove the root gently with the elevator,

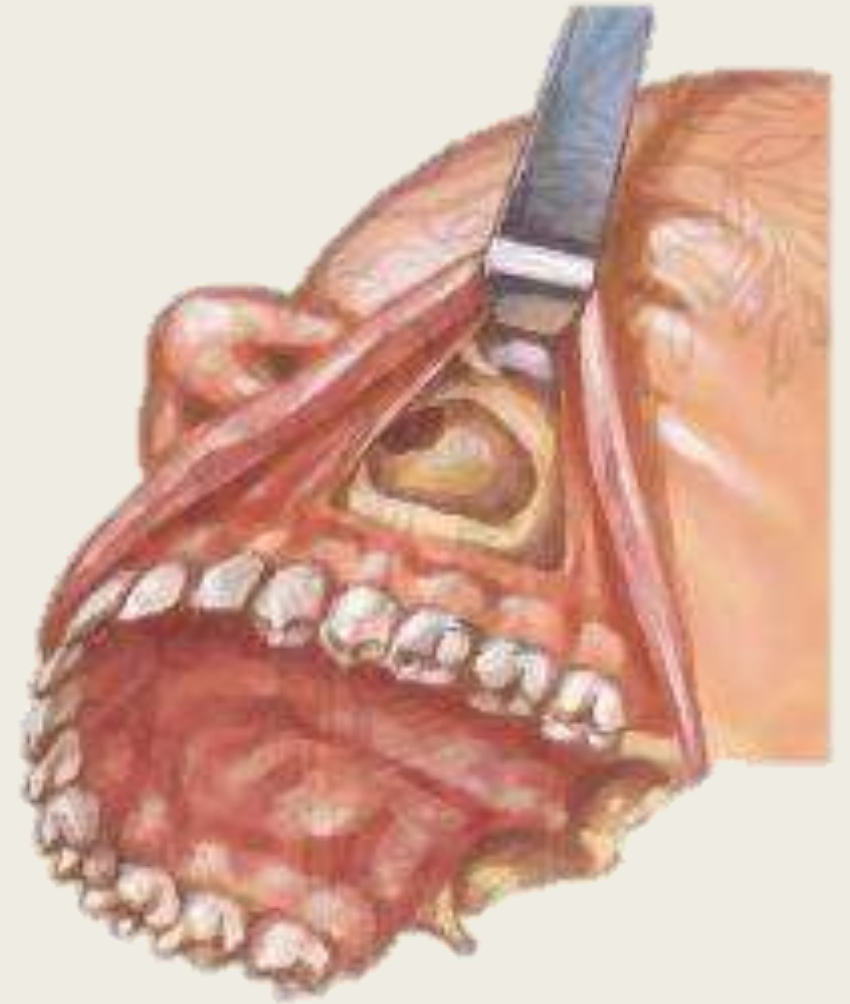
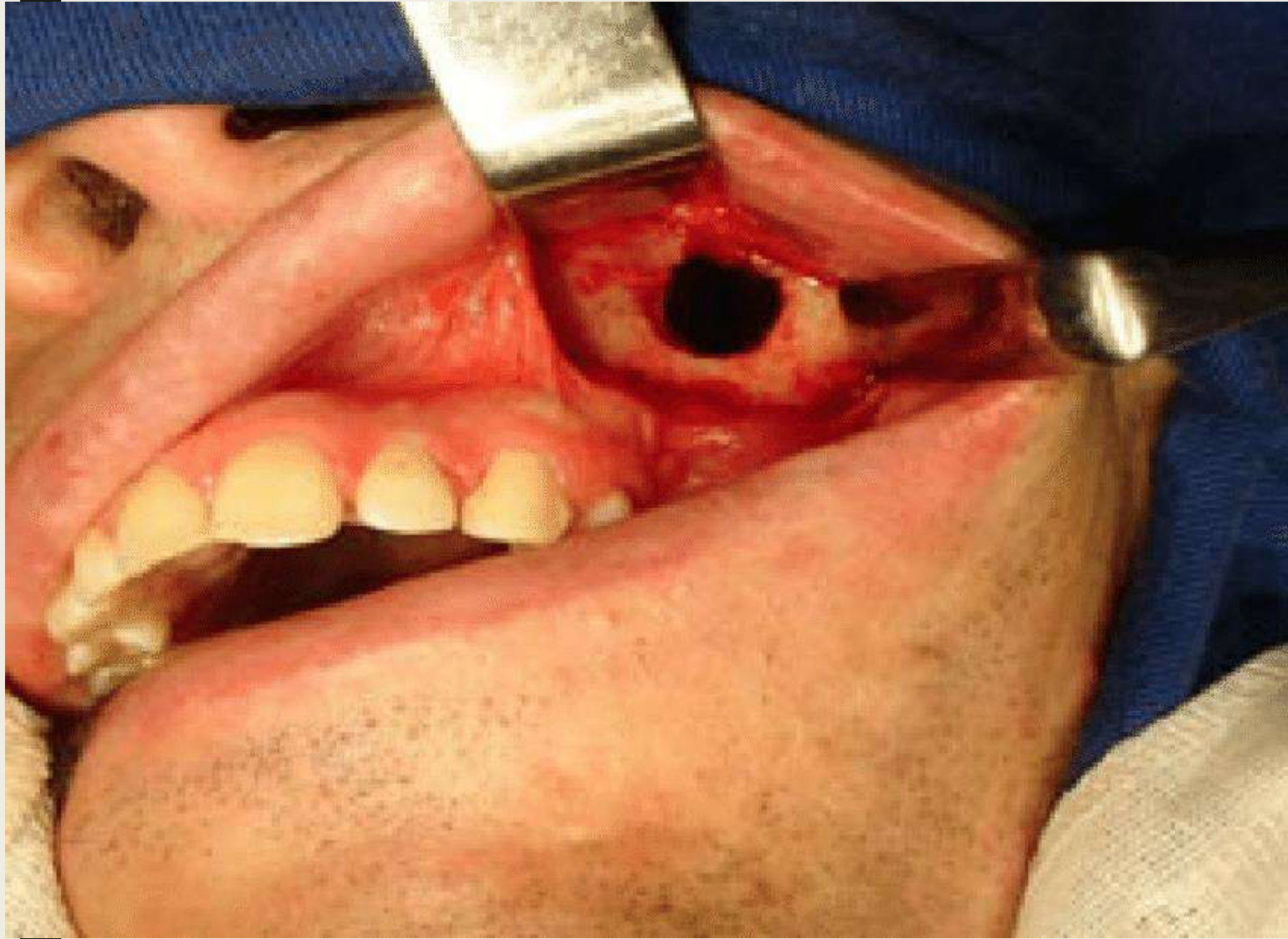

- If the root is pushed into the antrum, **Cald Well-Luc approach**, raising flap then the defect is explored with the sucker tip with profuse saline irrigation the sinus, by this method the tooth or root may be caught.

■ *Caldwell - Luc Operation 1893* : Indications:


- 1) **Removal of tooth or root fragments in the sinus**, because it provide better vision.
- 2) Trauma of the maxilla when the walls of the maxillary sinus are crushed or when the floor of the orbit has dropped.
- 3) **Management of hematoma** of the antrum with active bleeding through the nose.
- 4) **Chronic maxillary sinusitis** with polypoid degeneration of the mucosa.
- 5) Cysts in maxillary sinus.
- 6) **Biopsy from maxillary sinus** in the presence of tumor mass.





- *The Surgical Procedures:*

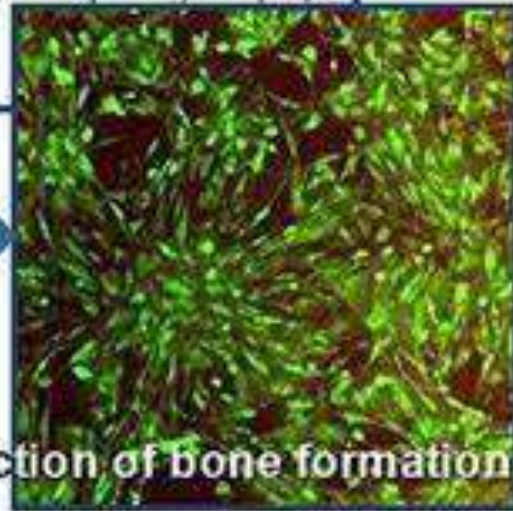
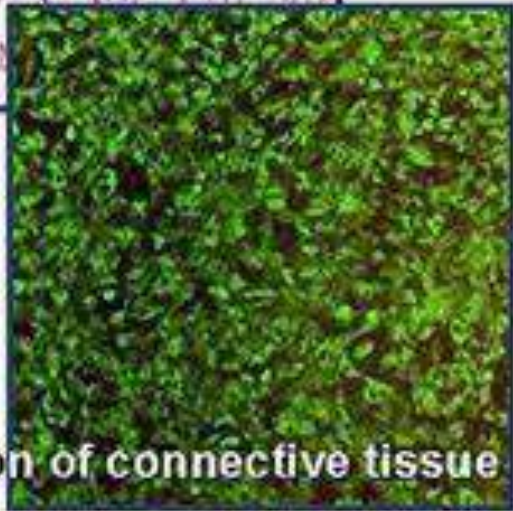
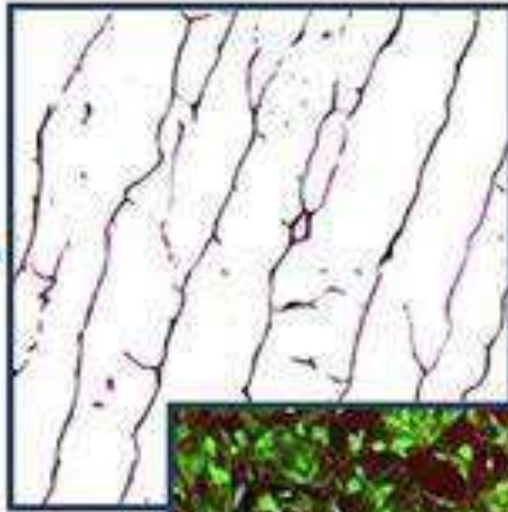
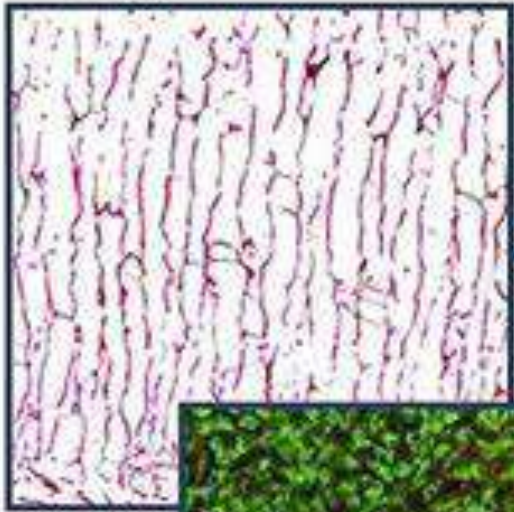
- **Muco-periosteal vestibular incision** (gingivobuccal sulcus above canine fossa) running horizontally opposing to the 1st molar & running forward to the central incisor.
- Then the flap is reflected until the infra-orbital nerve is identified to avoid nerve injury.
- A window of about 1.5 cm diameter is made with a surgical round bur in the maxilla & care must be taken not to approach too close to the apices of the canine tooth.
- The lining of sinus exposed and opened with No. 11 blade.
- Good lighting is essential, when the root is found, it lifted with sucker or grasped with a toothed forceps & withdrawn, placement of GTR, saline wash & suturing
- Five days of systemic antibiotic.



- Resorbable guided tissue regeneration (GTR) membrane bone substitute sandwich technique
- GTR is a pure collagen membrane.
- Derived from specially controlled and certified animals and is highly purified to avoid any antigenicity.
- It is sterilized in double blisters by gamma irradiation,
- it is a bi-layer structure. The **porous surface** facing the bone will allow the in-growth of bone-forming cells. The **dense surface** facing the soft tissue will prevent the in-growth of fibrous tissue into the bony defects.
- Used as a barrier membrane in bone cavities, it will resorb within 24 weeks.

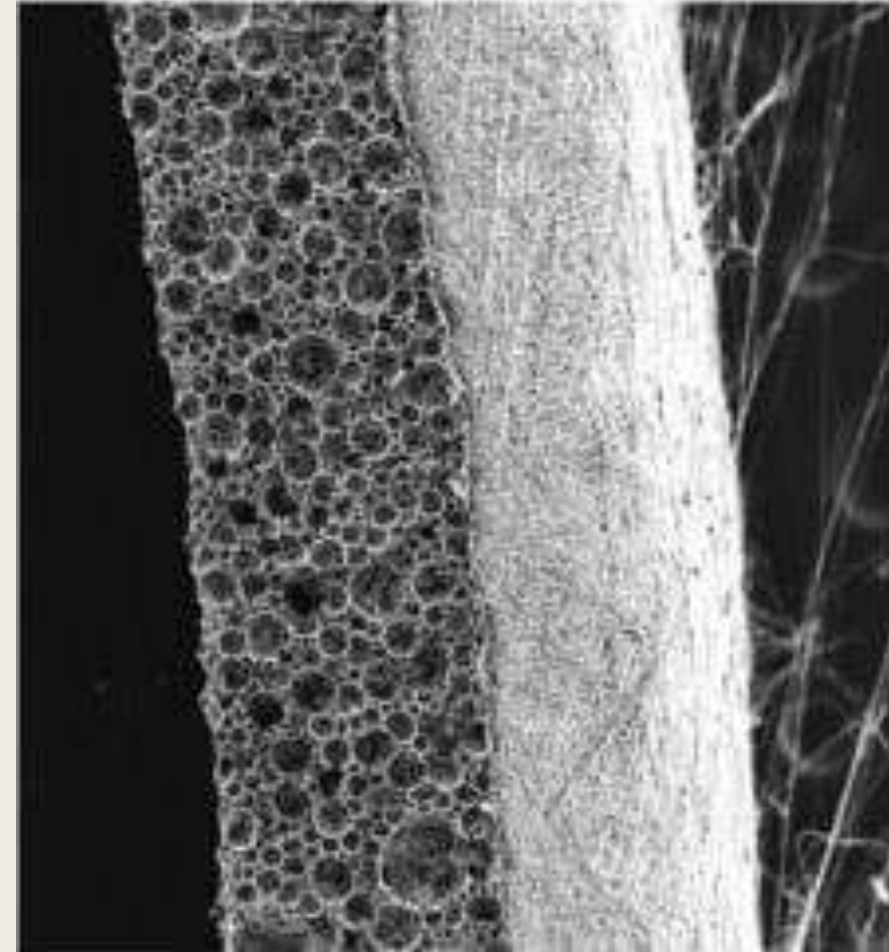


50 μm \leftarrow Collagen & β -TCP \rightarrow 250 μm



Formation of connective tissue

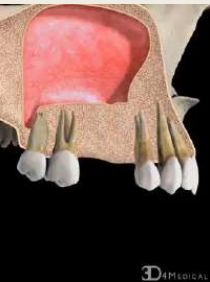Induction of bone formation

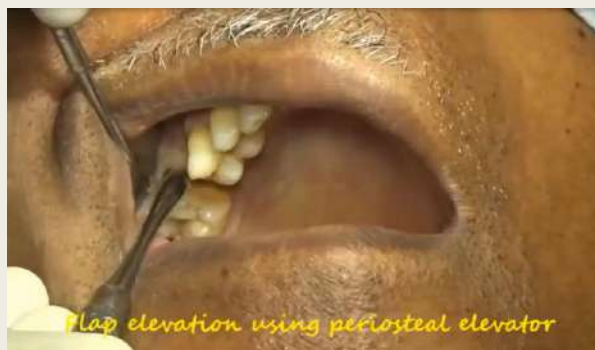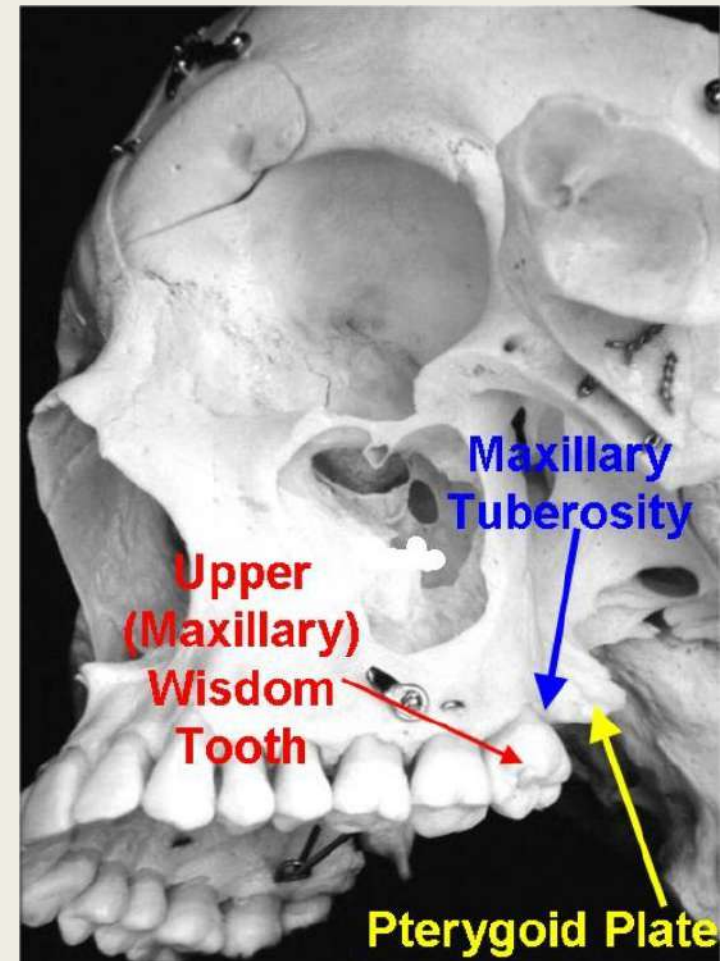
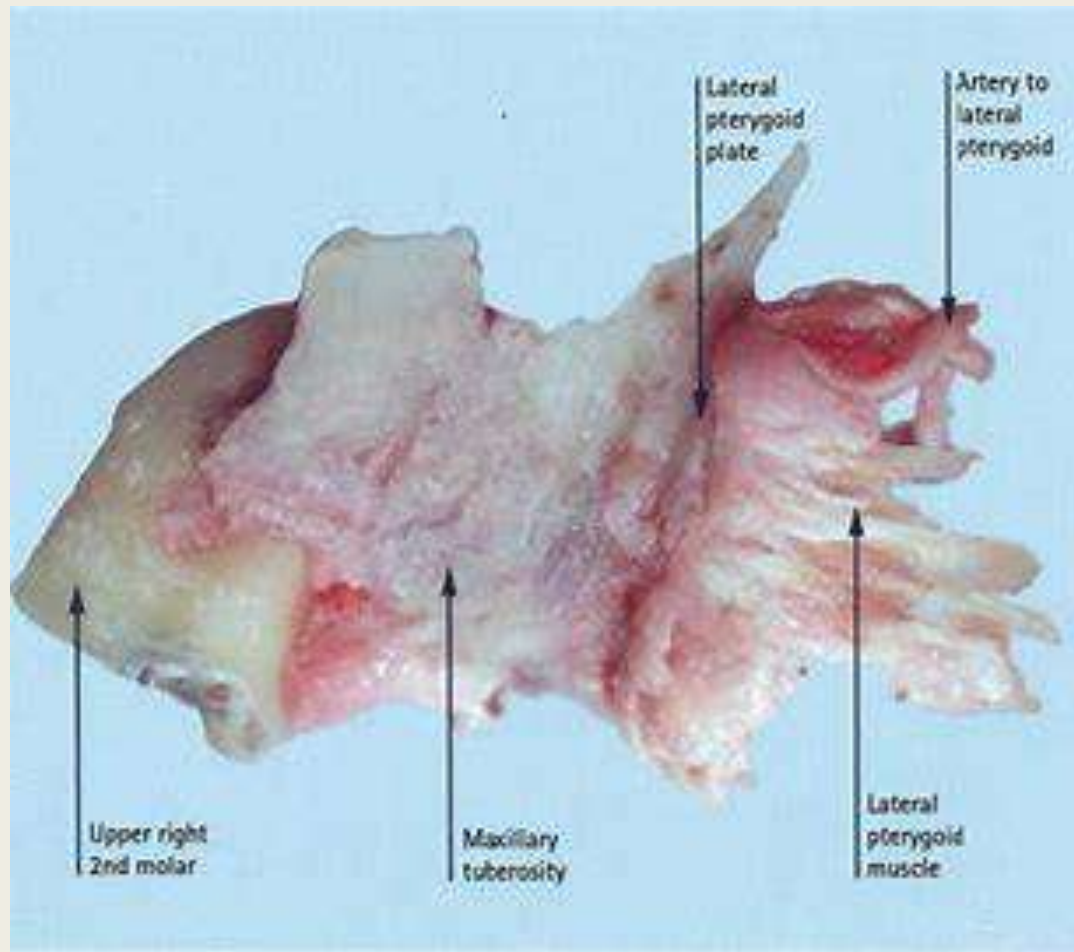


Porous Surface ---- Dense Surface

4- Fracture Of Maxillary Tuberosity

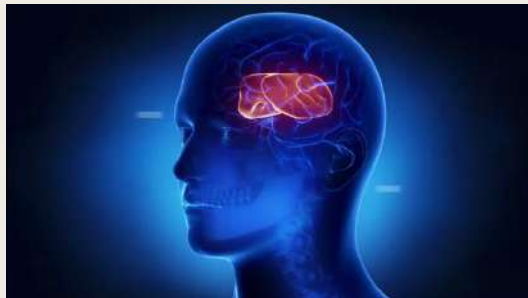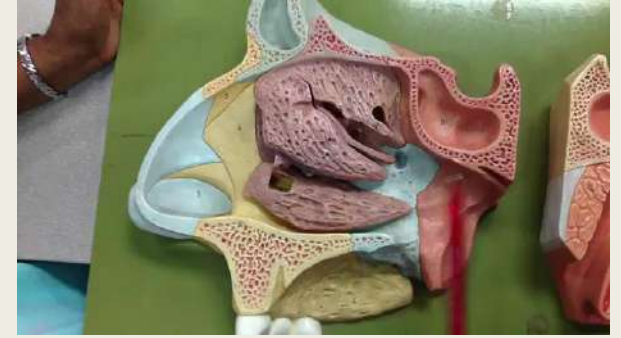
- During extraction of upper last molar, the supporting bone & maxillary tuberosity felt to move with the tooth (**most common complication**).
- This complication occurs due to the invasion of the tuberosity by the antrum (pneumanisation), when the tooth has divergent or hypercementosed roots, and with fault extraction technique.
- When fracture occur, a flap raised. **The bony fragment and tooth freed from the palatal soft tissue by blunt dissection** to prevent laceration of the soft tissue.
- The flap sutured and left in site For 14 days.





5- MALIGNANT DISEASES OF MAXILLARY ANTRUM

- The dentist play an important role in the detection of malignant disease of maxillary antrum
- Patient complaining from the following problems without dental cause or soft tissue infection (skin or mucosa)
 - Loosening of the upper molar teeth.
 - Excessive bleeding after dental extraction.
 - Failure of maxillary pocket to heal normally.
 - Proliferation of the soft tissue in socket.
 - Maxillary pain.
 - Epistaxis.
 - Swelling of the cheek.
 - Intra-oral swelling in the buccal sulcus.
- TREATMENT: -
 - By Cald Well - Lac operation to remove the maxillary sinus lining, with polypoid malignant tissue or by hemimaxillectomy or maxillectomy & combination of radiotherapy & chemotherapy.

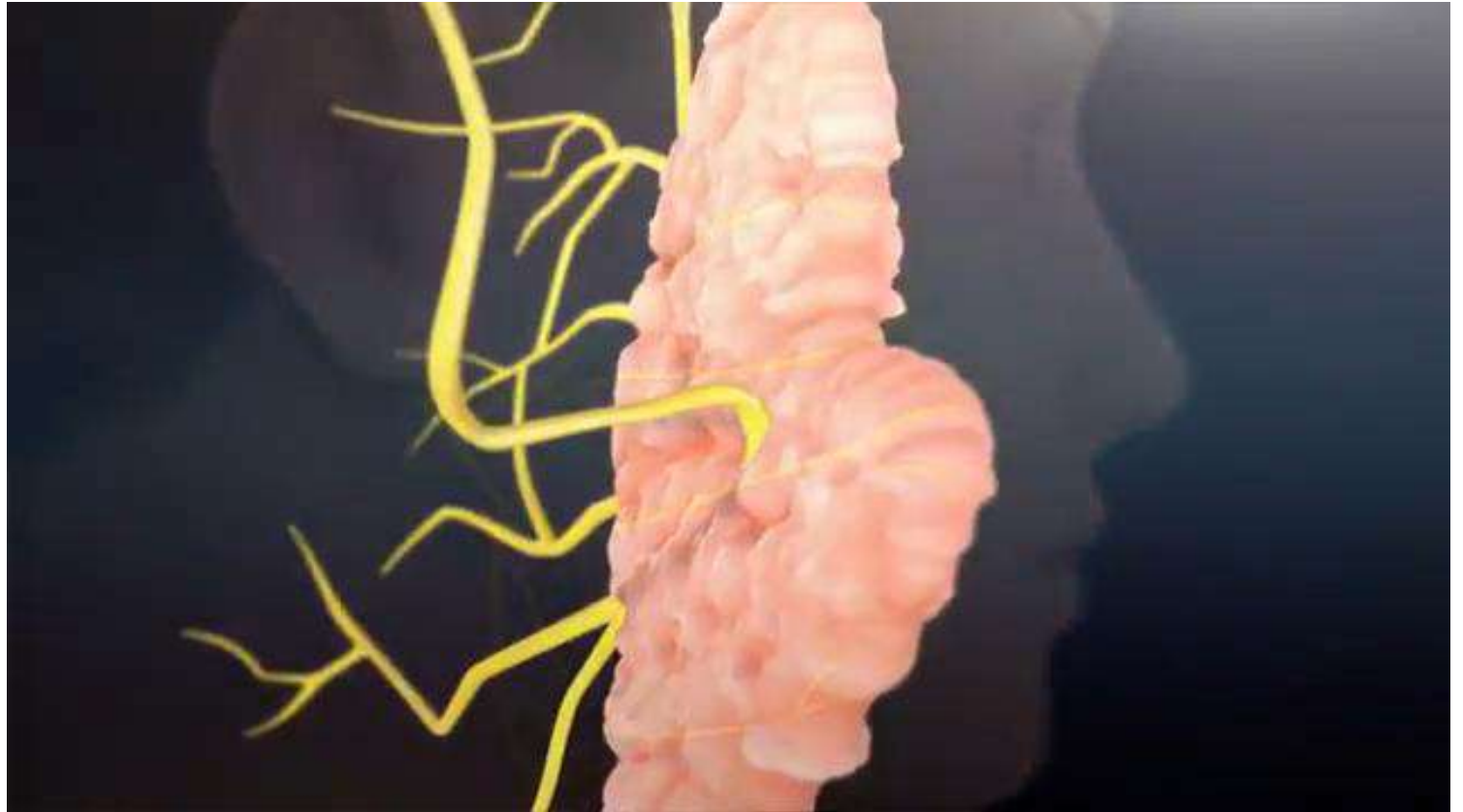


SALIVARY GLAND DISEASES

Bashar Abdul-Ghani

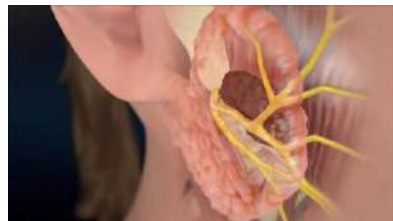
FICMS. MaxFacs Cons.

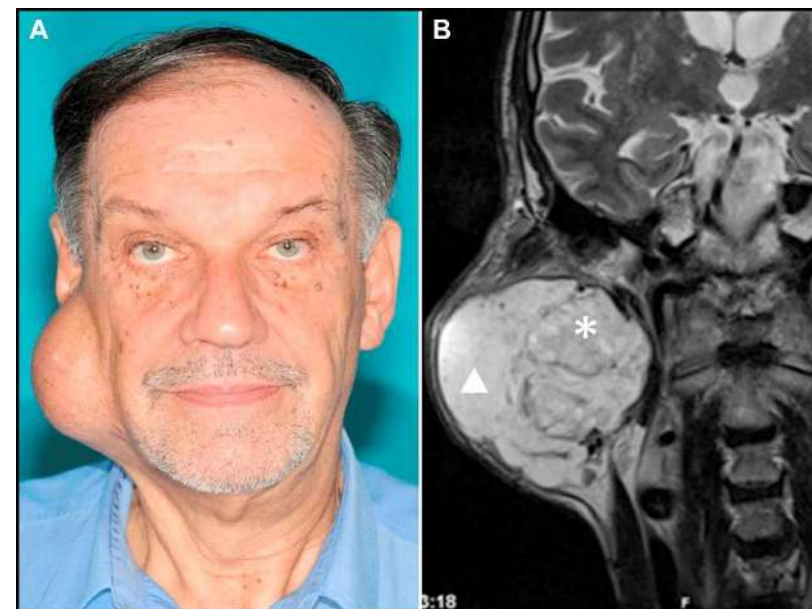
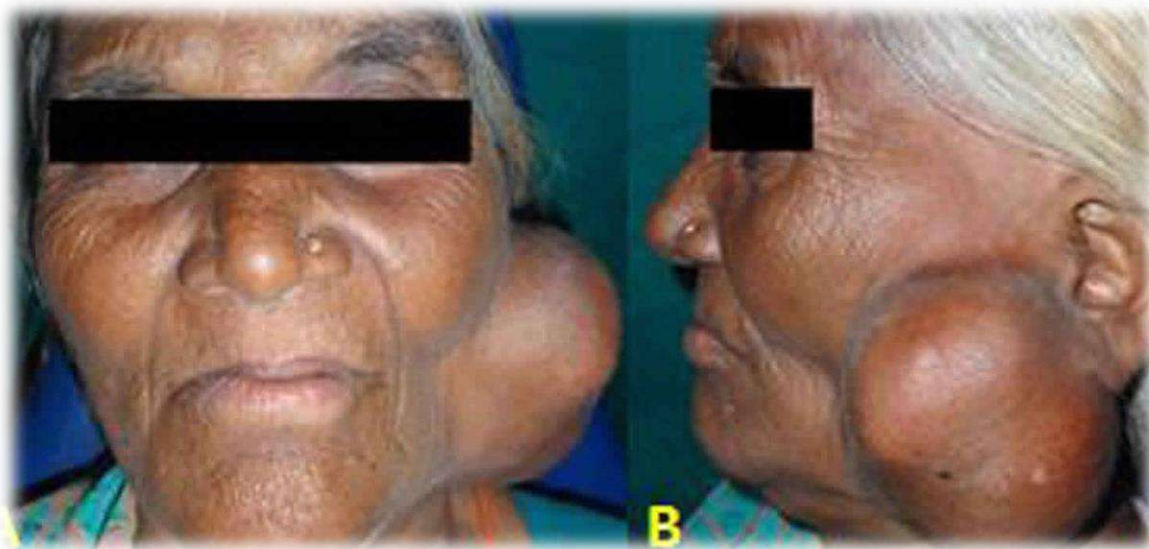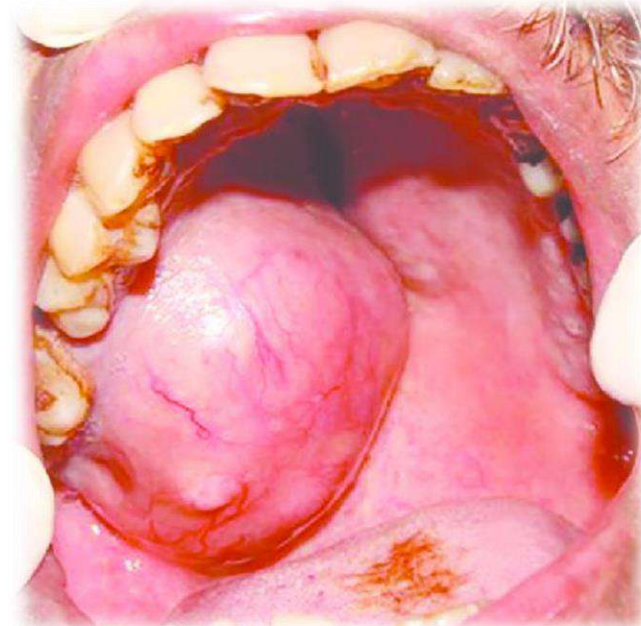
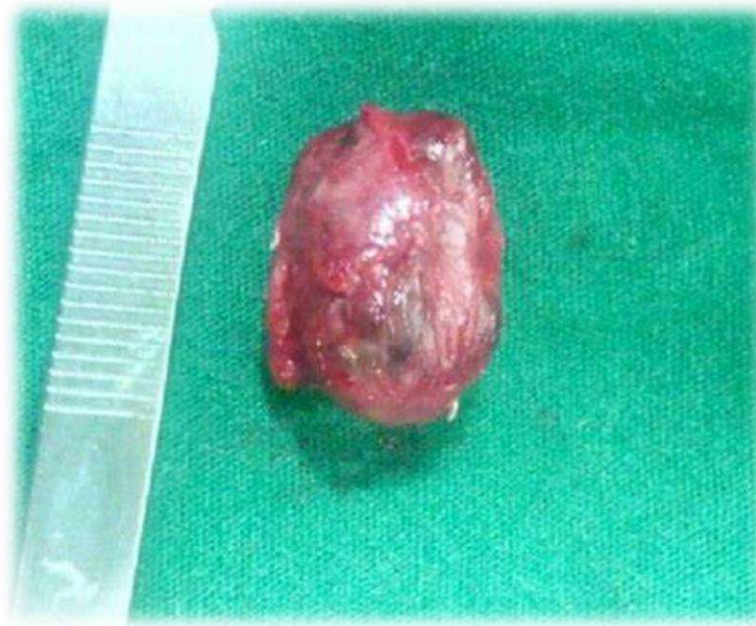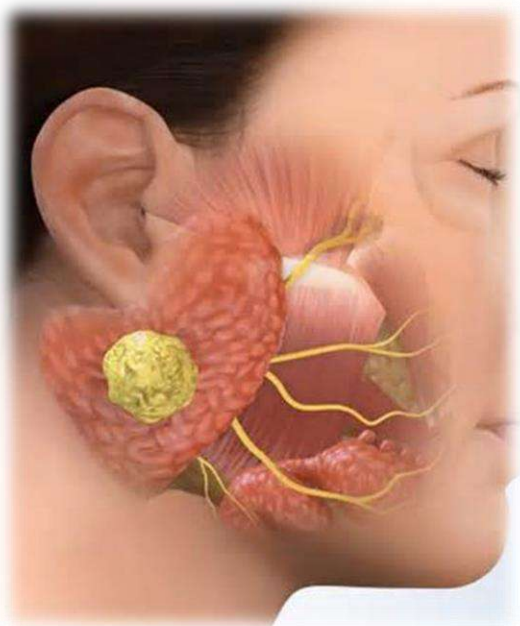
MFDS. RCSEd. RCPS (Glasg).



TUMORS OF THE SALIVARY GLANDS - BENIGN TUMORS

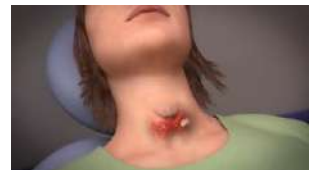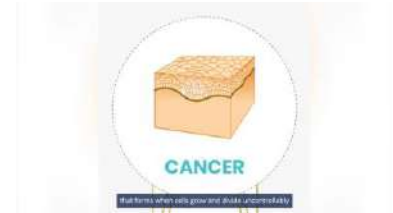- **Pleomorphic Adenoma** - Constitutes more than 90 % of all salivary benign tumors.
- It commonly affects the **Parotid Gland**, followed by minor glands of **the Palate**.
- Most of the workers believe that the tumor arises from **the myo-epithelial cell** of the salivary gland.
- The different tissue types of both epithelial and connective tissue elements are seen in the tumor giving the name “**Mixed Tumor**”.

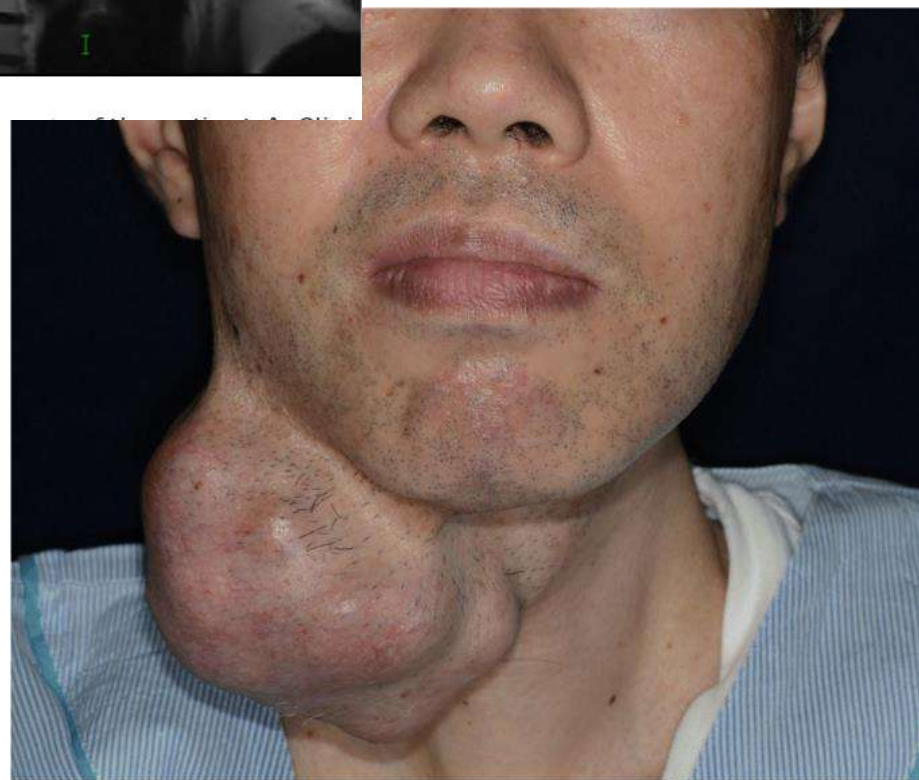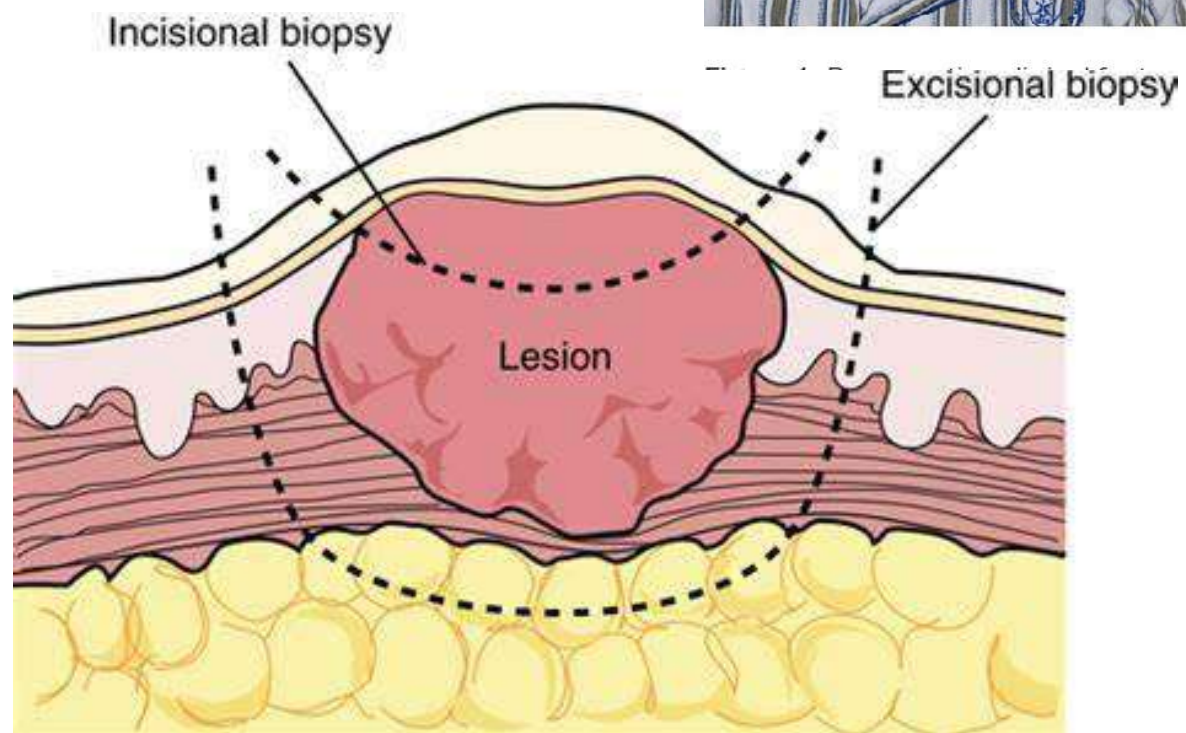

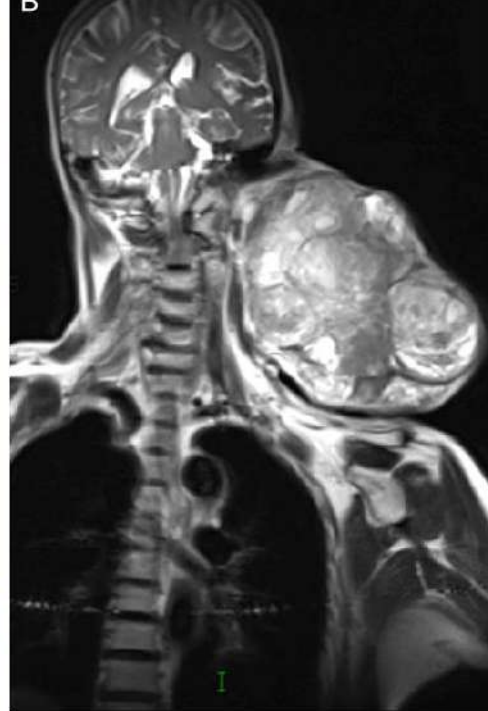
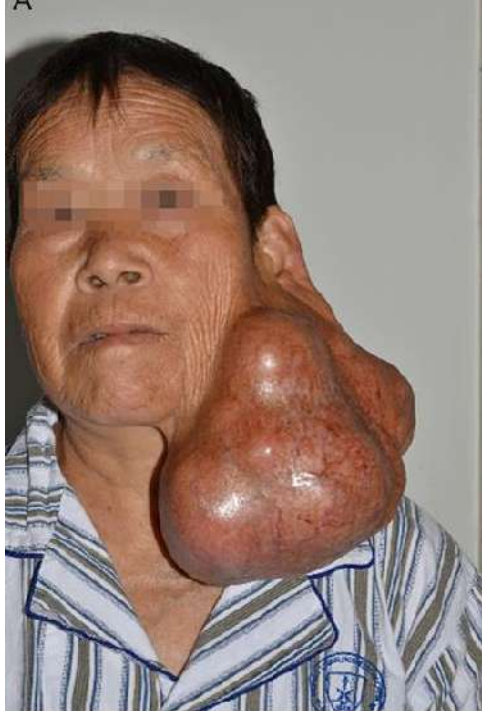

Clinical Features

- Starts as a small **Painless Nodule**, at the angle of the mandible or beneath the ear lobe,
- **Slowly increases in size.**
- **Well-circumscribed, Encapsulated and Firm.**
- **Movable without fixity** to the deeper tissues or to the overlying skin.
- May grow to a **very large size, but not ulcerate the skin.**
- **Tissue Destruction, Pain or Facial Paralysis are Not Seen.**
- The palatal tumor, show fixity (but not invade) to the underlying bone.
- Confirmed by **Fine Needle Aspiration Biopsy** (for parotid and large minor gland tumor).
- In minor gland lesions, (less than 2cm), it is better to perform **Excisional Biopsy.**



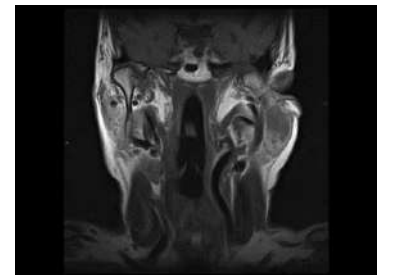
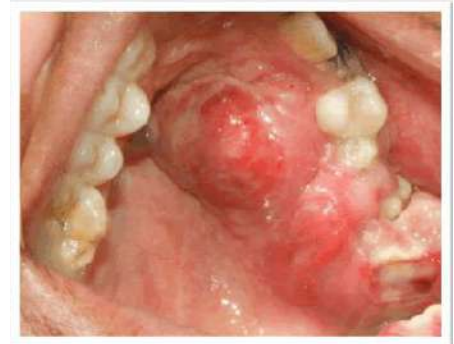

Treatment – Only Surgical

- In parotid and minor glands tumor, Surgical excision with adequate margins, whereas the intraoral lesions can be treated conservatively (without normal margins).
- Careful dissection and **preserving** the facial nerve,
- Not to spill any tumor tissue, as they are **highly implantable**.
- In case of submandibular glands, excision of the gland with the tumor is performed
- Irradiation is contraindicated as the tumor **is radio- resistant**.

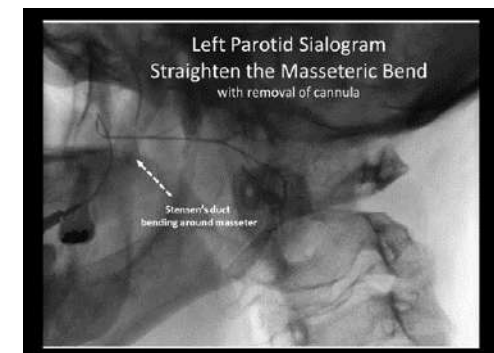Complications

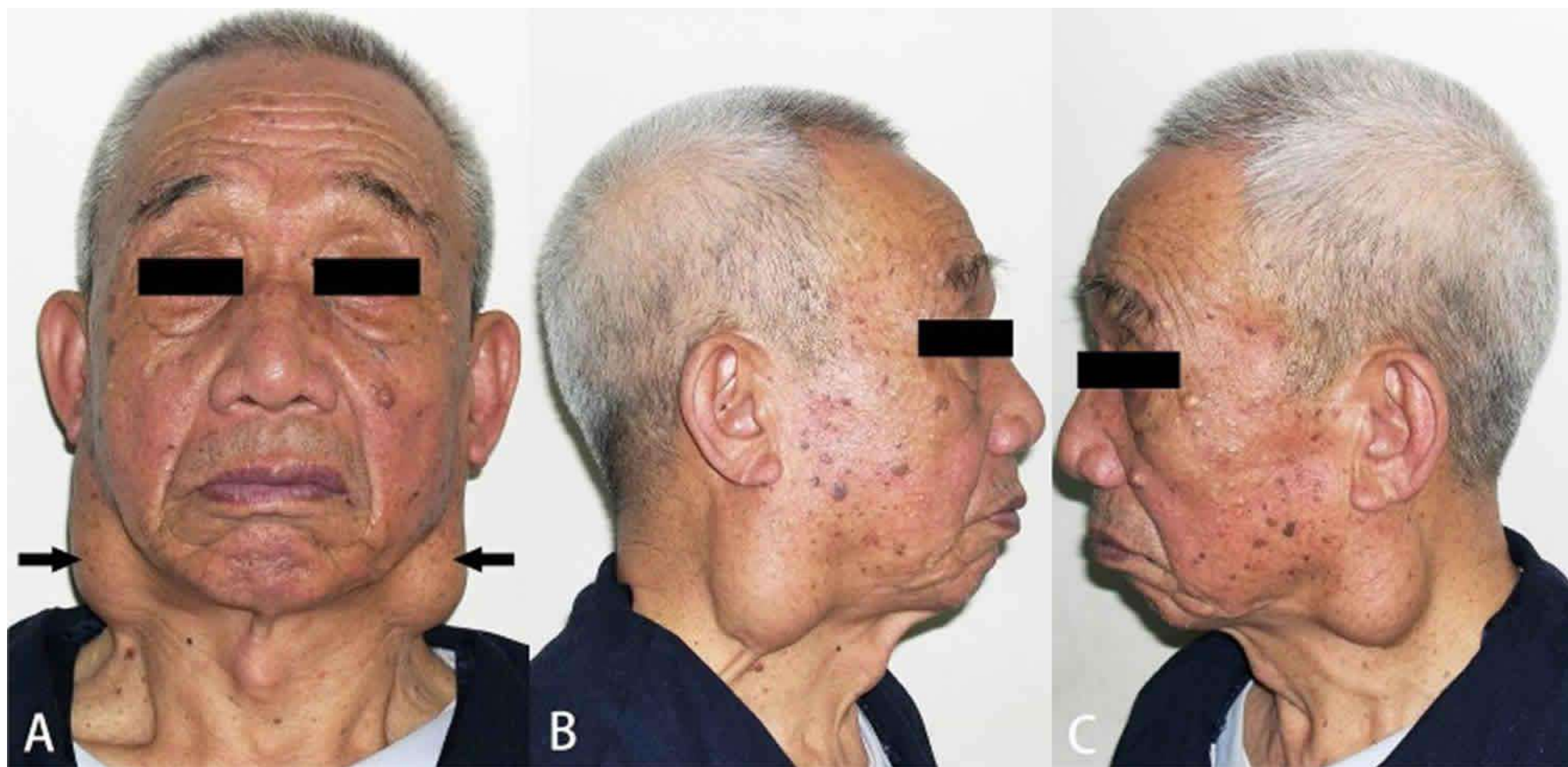- 1. Incomplete excision lead to **Recurrence**.
- 2. The long standing tumor may undergo **Malignant Transformation**, which is hard, ulcerates, **causes facial paralysis or lymph node involvement**. Why ?



WARTHIN'S TUMOR

- Affect the parotid glands. Very rare. Involve the submandibular or the minor glands.
- Associated with Smoking.
- Firm, non-tender, circumscribed mass.
- Both parotid glands affected, the swelling might start on one side following the other.
- Sialography: show non-filling, space occupying, tissue displacing tumor.
- Diagnosis may be confirmed by biopsy.
- Treatment: The tumor is surgically excised.





MALIGNANT TUMORS

- Affect both the major and the minor salivary glands.
- Occur in elderly people of 50-60 years.

Mucoepidermoid Carcinoma

- **The most frequent salivary malignant tumor**, which can affect the children also.
- The grading : low, intermediate and high grade (**behavior assessment**).
- **The low-grade tumor behaves almost like a benign tumor** with very good prognosis
- The high-grade tumor produce pain, ulceration or facial paralysis, local destruction and metastasis to regional lymph nodes and distant metastasis to the lung, bone and to the brain in later stages.
- **Diagnosis confirmed by biopsy.**
- **Treatment:** Surgically excised with safe margin.

Adenoid Cystic Carcinoma (Cylindroma)

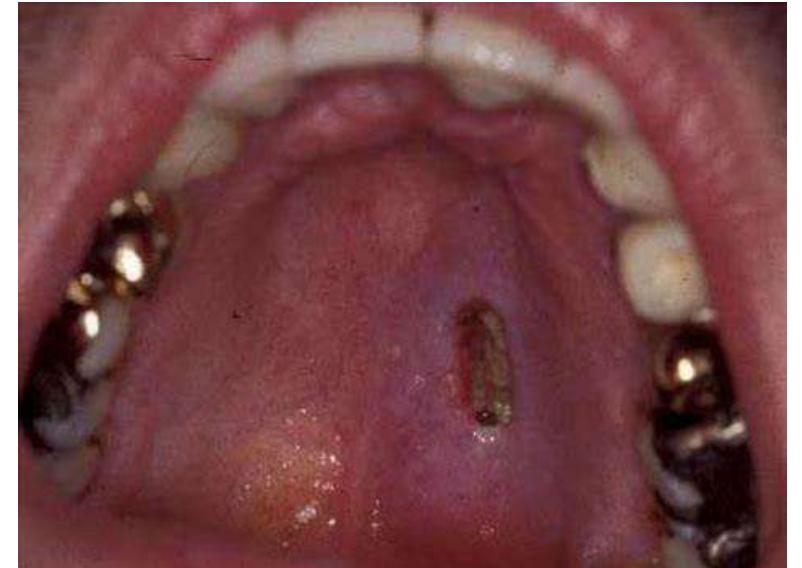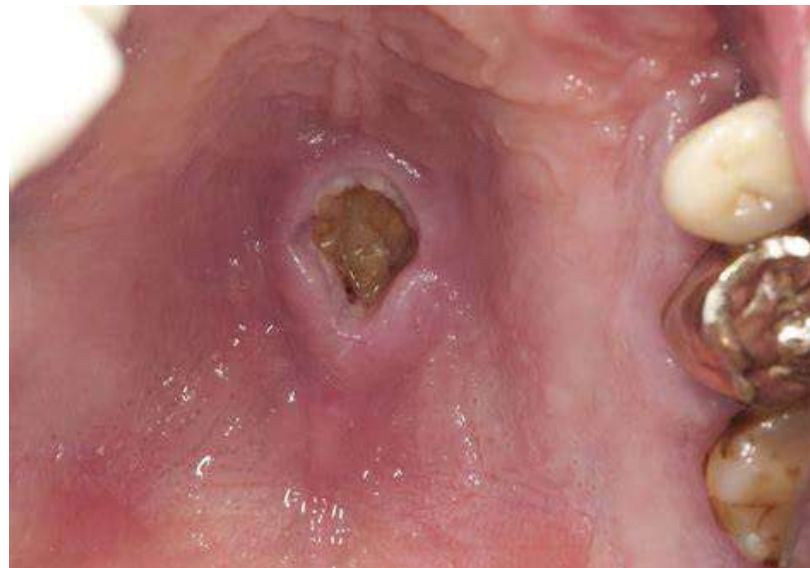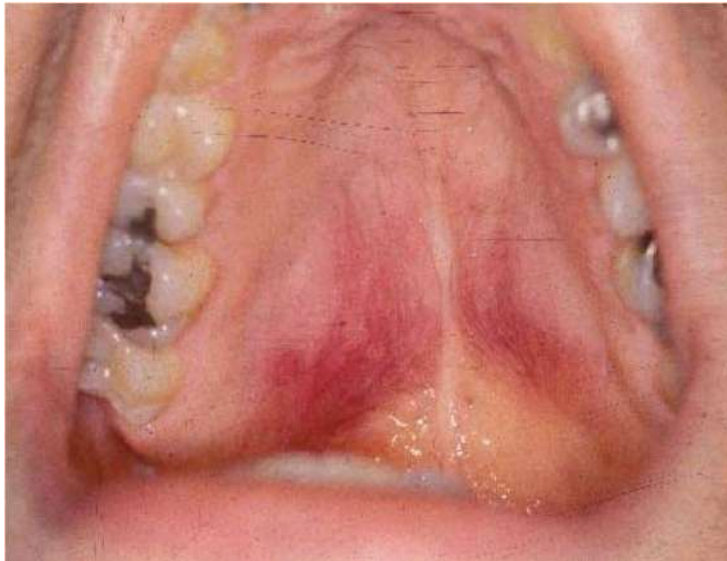- Start as slow growing swelling, sometimes may mimic a benign tumor clinically and histologically, but has greater potential for local destruction and invasiveness, commonly **Perineural Invasion**.

Treatment: Radical excision.

- As the tumor is **radio resistant**, irradiation is not a mode of primary treatment.

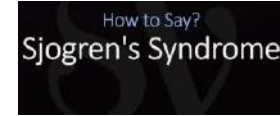
NECROTIZING SIALOMETAPLASIA

- An **inflammatory lesion** of unknown etiology,
- Affects the minor salivary glands.
- Expected Pathogenesis : Trauma leading to ischemia, acinar necrosis and squamous metaplasia of the ductal epithelium.
- **Since the lesion mimics a malignant lesion, both clinically and histologically, the diagnosis should be carefully done.**



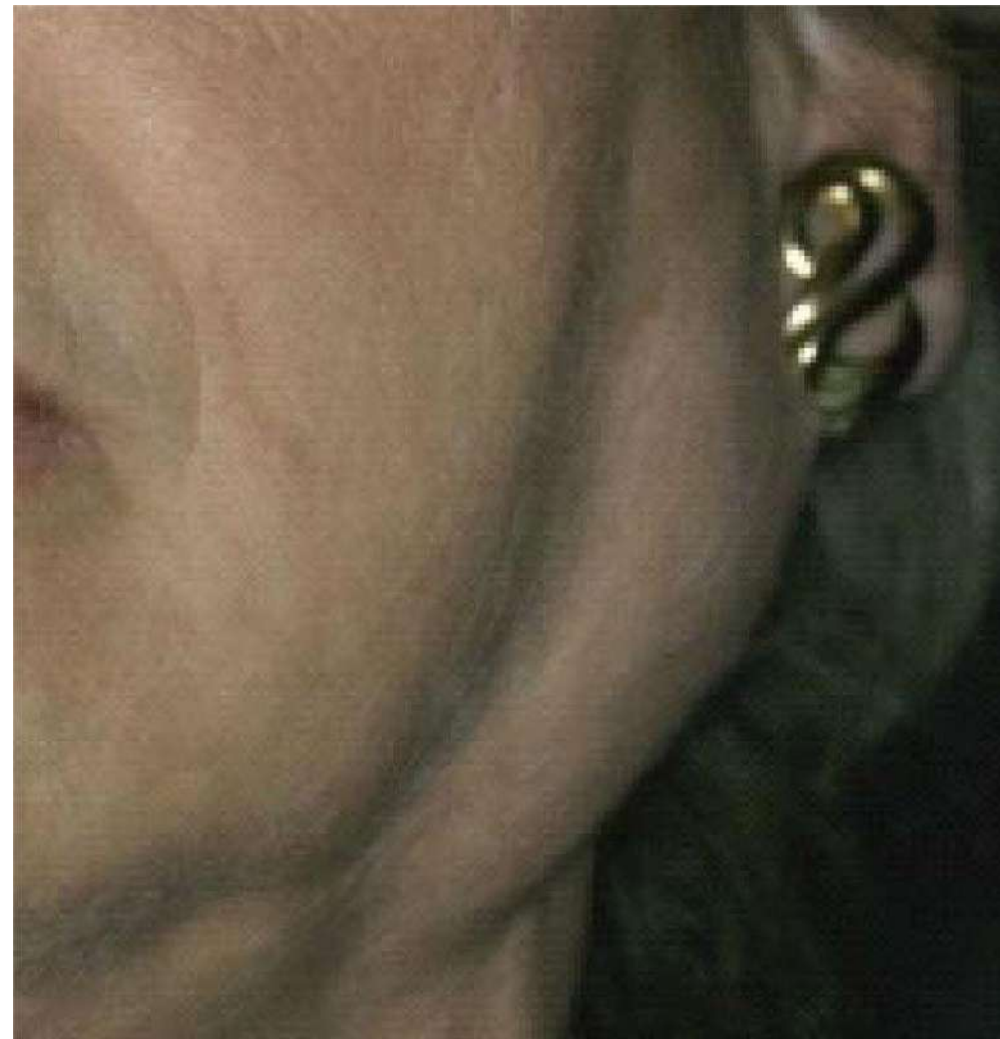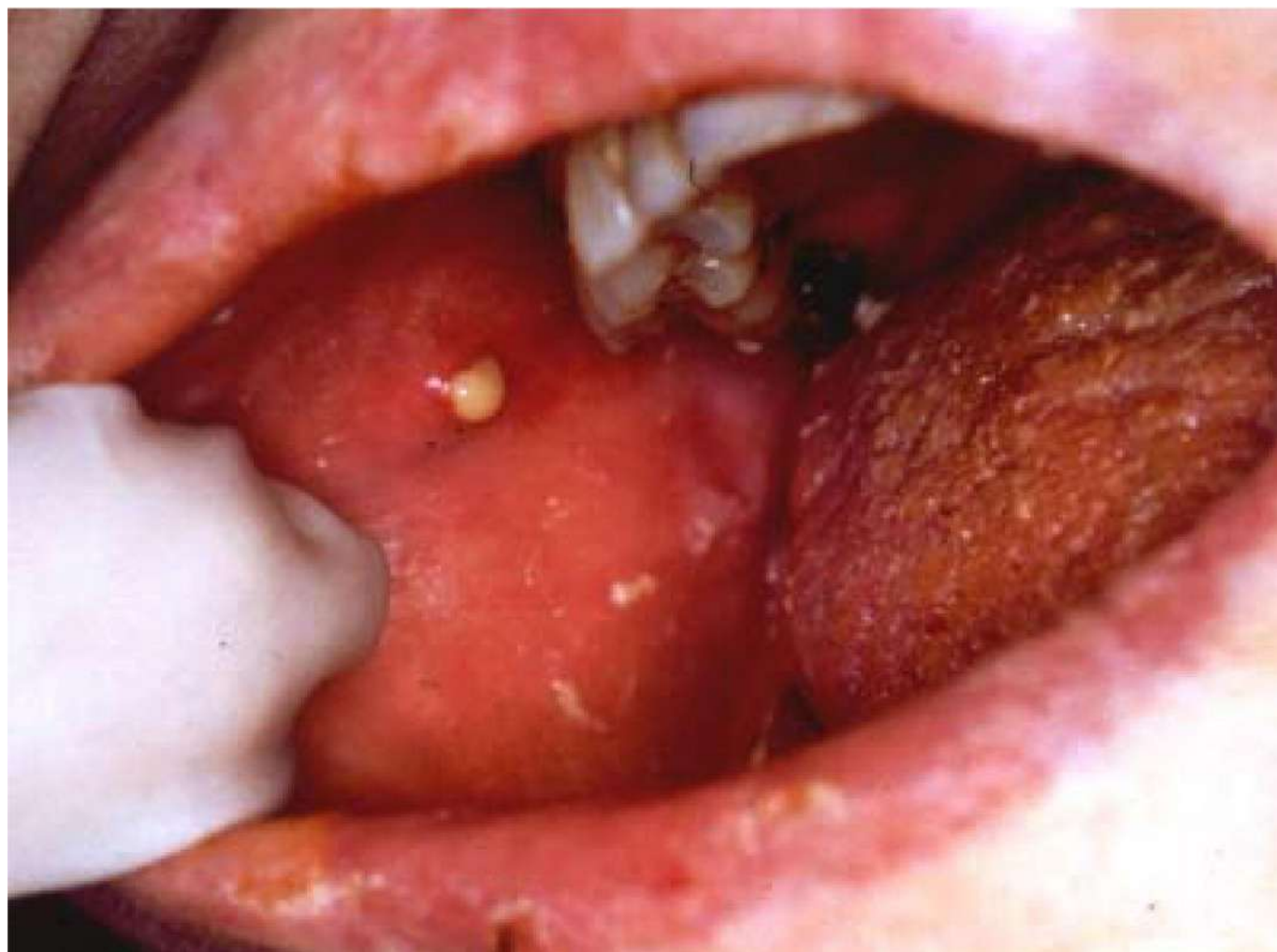
NON-INFLAMMATORY AUTOIMMUNE DISEASE

SJÖGREN'S SYNDROME



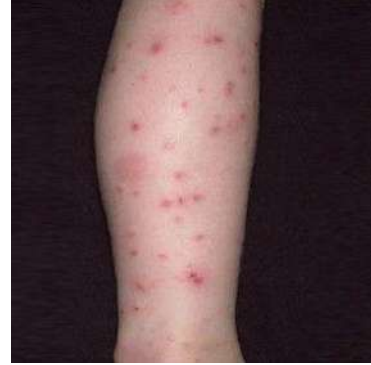- Described as a triad, consisting of **Dry Eyes, Xerostomia and Rheumatoid Arthritis.**
- **Primary Sjögren's Syndrome (Sicca Syndrome):** Dry eyes and xerostomia only
- **Secondary Sjögren's Syndrome :** the above two symptoms and accompanying **Rheumatoid Arthritis, Systemic Lupus Erythematosus, Polyarteritis Nodosa.**
- The etiology is **unknown**, but various causes suggested : genetic, hormonal, infection and immunologic.
- **Immunologic mechanism** had the main intrinsic factor in the etiology of this disease, so it is defined as an autoimmune disorder.



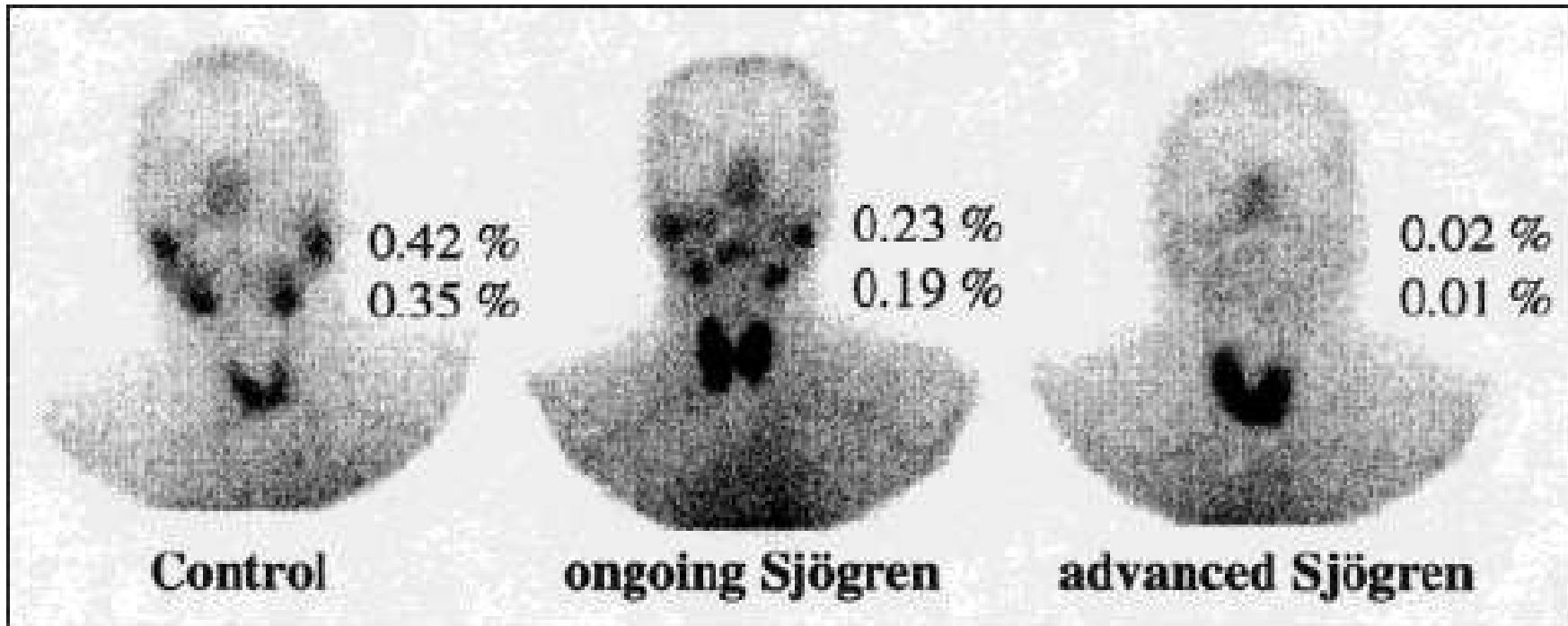


Clinical Features

- The female to male ratio is 10:1.
- Dry eyes and dry mouth due to **hypofunction** of lacrimal and salivary glands.
- **Pain, Burning Sensation and Ulcerations** on the oral and conjunctival mucosa.
- Other glands like nasal, bronchial, may also show hyposecretion.
- In primary Sjögren's, parotid gland enlargement, purpura, lymphadenopathy
- Salivary gland function measured by g **Parotid Flow Rate, Biopsy** and **Salivary Scintigraphy**.
- Sialochemistry studies have shown elevated levels of IgA, K, Na, etc. in these patients.
- **Sialography** demonstrates the cavitory defects which are filled with radiopaque contrast media, producing the “branchless fruit laden tree” or “cherry blossom” appearance.

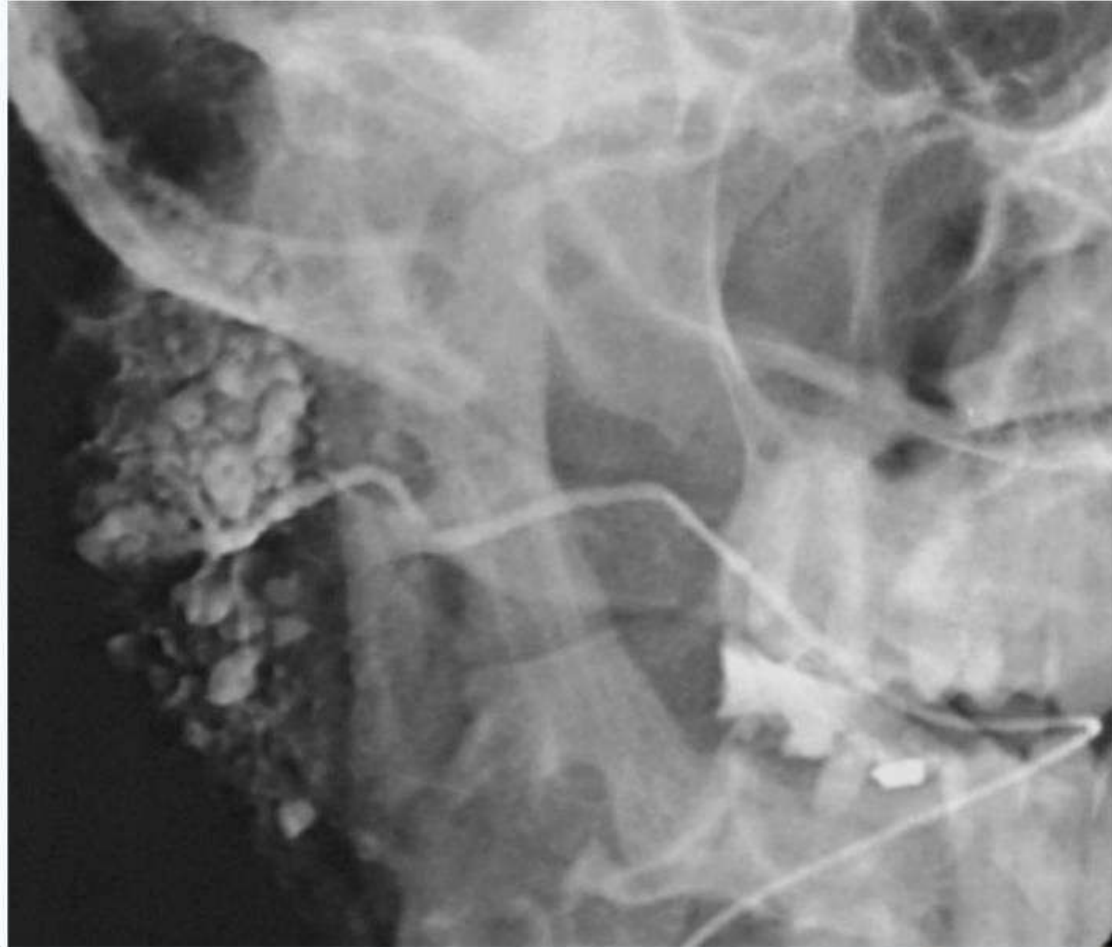


Salivary Scintigraphy



- Scintigraphy (Gamma Scan) - A procedure that produces pictures (scans) of structures inside the body, including areas where there are cancer cells. Scintigraphy is used to diagnose, stage, and monitor disease. A small amount of a radioactive chemical (radionuclide) is injected into a vein or swallowed.

Sialography



Sialogram in a patient suspected of **Sjögren's syndrome**

SIALORRHEA OR PTYALISM

- Excessive salivation (mild, intermittent or continuous profuse drooling), uncommon.
- **Minor Sialorrhea** due to **local irritation like aphthous ulcers** or ill-fitting dentures.
- **Idiopathic Paroxysmal Sialorrhea** - short episodes for 2 - 5 minutes.
- **Profuse salivation** in rabies, metal poisoning or after medications (lithium).
- **Mentally retarded** children also have excessive salivation.
- **Neurologically Disabled Persons** (cerebral palsy) also suffer from this disorder.
- **Drooling after the resection of the mandible**, due to poor neuromuscular control.

Conservative Treatment.

- Anticholinergic medication (Atropine).
- Behavioral modification, physical therapy.
- Injection of botulinum toxin type A into the parotid and submandibular glands, safe and effective in controlling drooling


Surgical Treatment

- Submandibular gland resection
- Transposition of parotid duct
- Parotid duct ligation.

XEROSTOMIA – DRY MOUTH

- Causes : Medications. Antihistamines, Decongestants, Antidepressants, Antipsychotics, Antihypertensives, Anticholinergics.
- Salivary Gland Aplasia, Aging, Excessive Smoking, Mouth Breathing, Local Radiation Therapy, Sjögren's Syndrome, HIV infection.
- Clinically, leathery appearance, fissured tongue with atrophy of the filiform papillae.
- Patients are more prone for oral candidiasis due to reduction in cleansing and antimicrobial action of saliva.
- Dental decay is rampant with more of cervical and root caries.
- Treatment is conservative, maintenance of oral hygiene, use of sialagogues, modification of medications in elderly patient.

SURGICAL MANAGEMENT - PAROTID GLAND



Superficial Parotidectomy

- Indications: - Tumor. - Massive enlargement (Sjögren's syndrome, Calculus in the gland, Chronic infection).

Approaches - i. Preauricular ii. Submandibular iii. Combination.

Complete Excision of Parotid Gland

- During complete removal of parotid gland, the prime concern is to conserve the facial nerve and its branches.
- In malignant lesions, removal of facial nerve, resultant deformity should be explained to the patient.

Submandibular Salivary Gland

- Extra-oral Procedures.

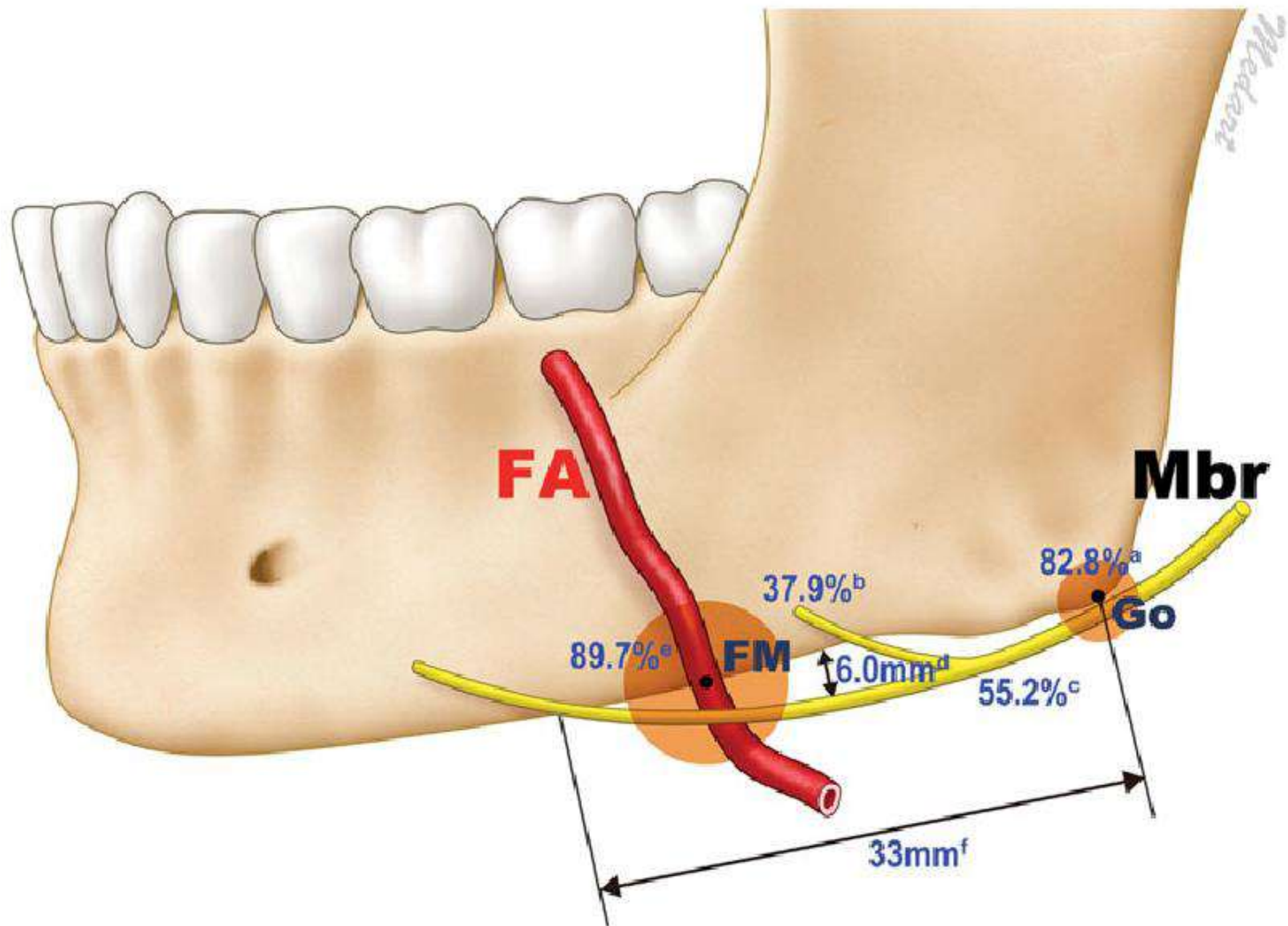
Complications of Surgery

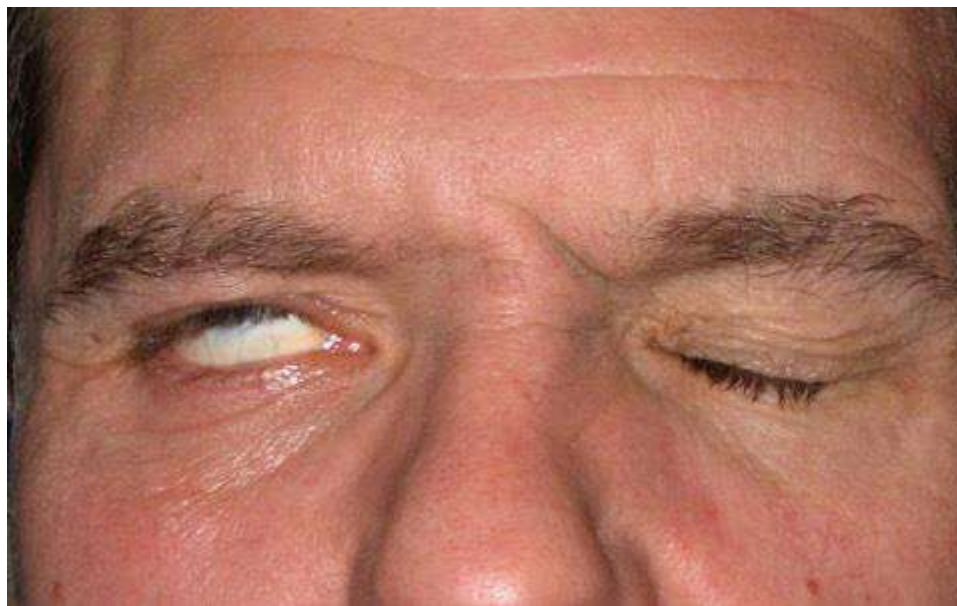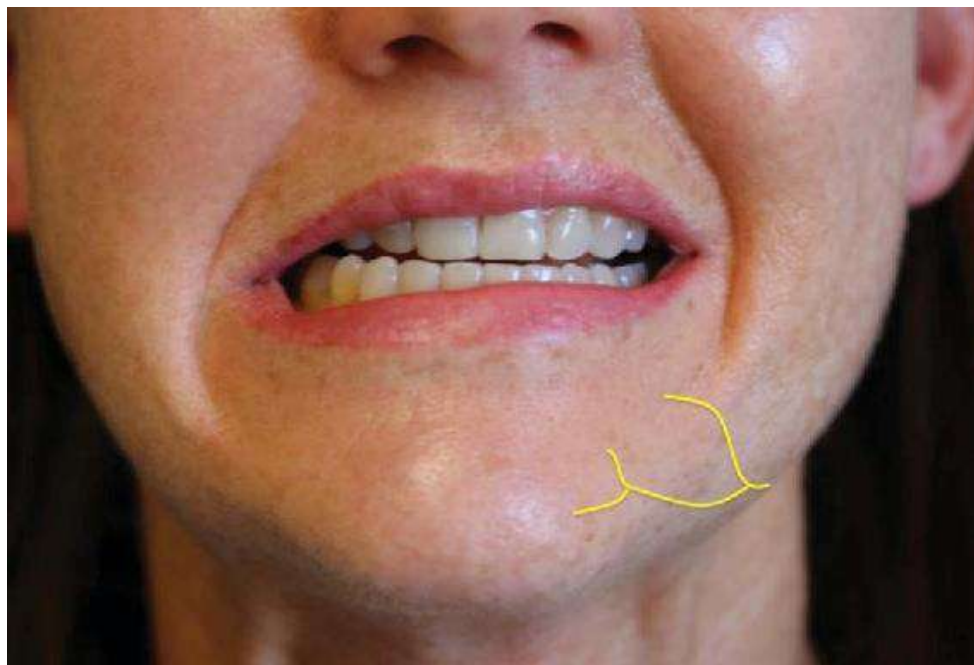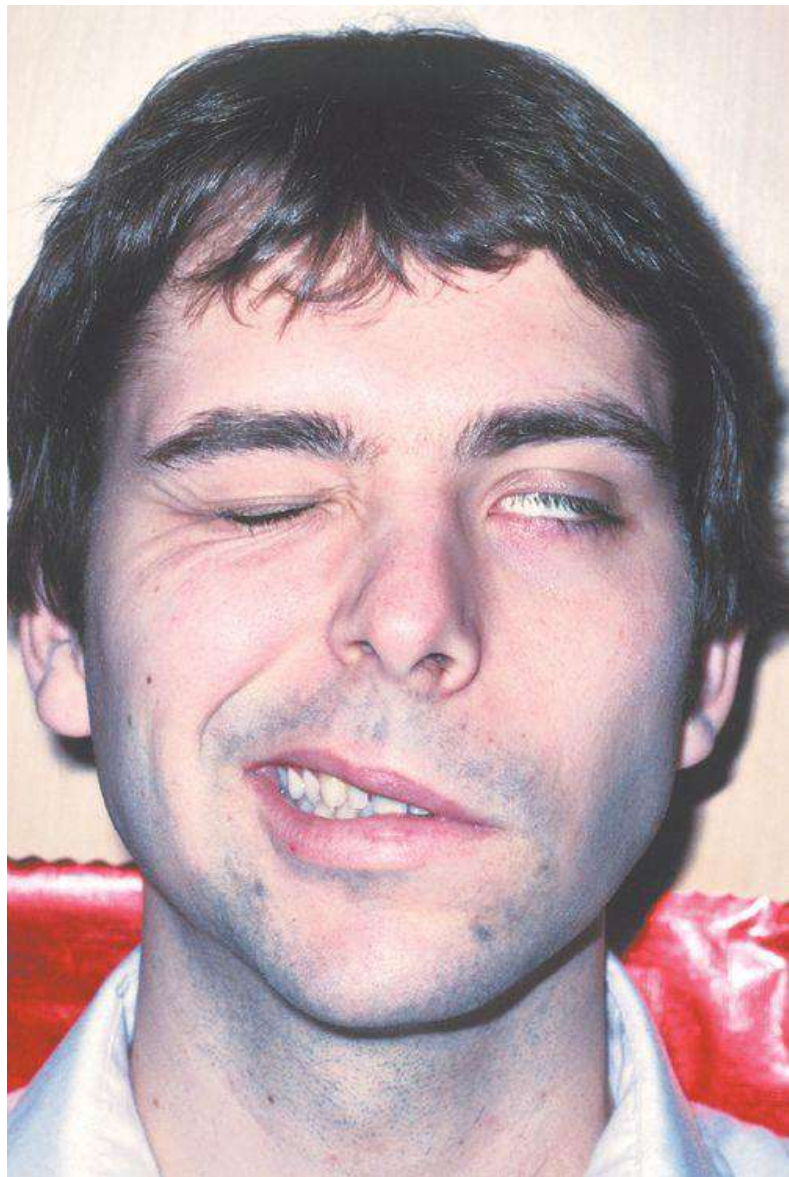
- Most of the complications are as a result of damage to nerves.
- Hence, the complications should be explained to the patient, and informed consent taken, prior to the surgery.

Facial Nerve Paralysis

- **Transient Facial Nerve Weakness**, due to surgical trauma, involving the **Marginal Mandibular Branch (Depressor Muscle of the Lip)**, but also occurring in the zygomatic branch (orbicularis muscle of the eye).
- **Supportive care** to prevent corneal irritation.
- **Full recovery usually occurs within days to months.**

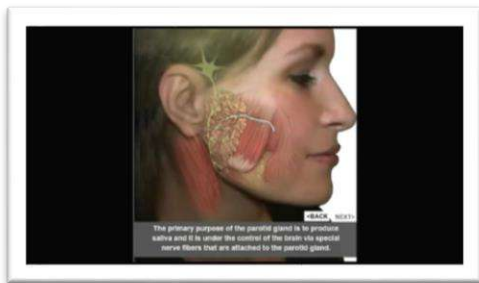






Frey's Syndrome (Gustatory Sweating)

- It is a sweating and sometimes flushing of the skin in the area of distribution of the **Auriculotemporal Nerve**; which is caused by a stimulus to secretion of saliva.
- Parasympathetic fibers from the otic ganglion united to sympathetic fibers arising from superior cervical ganglion going to supply the sweat glands of the skin.
- It rarely occurs and **has no treatment**.
- The syndrome can occur in the following circumstances:



- (i) Surgery of parotid gland.
- (ii) Surgery of TM Joint.
- (iii) Injuries to this area of the face.
- (iv) Injections into this region.

Parasympathetic Ganglia



Salivary Fistulae and Sialoceles

- Collection of saliva under the skin flap with drainage through the wound, uncommon.
- Treatment consists of
 - ❖ Aspiration of fluid,
 - ❖ Compression dressings,
 - ❖ Removal of salivary stimulants.
- The problem **usually resolves gradually** with this simple treatment regimen.

