
The digestive system

د. صديق بكر مرعي

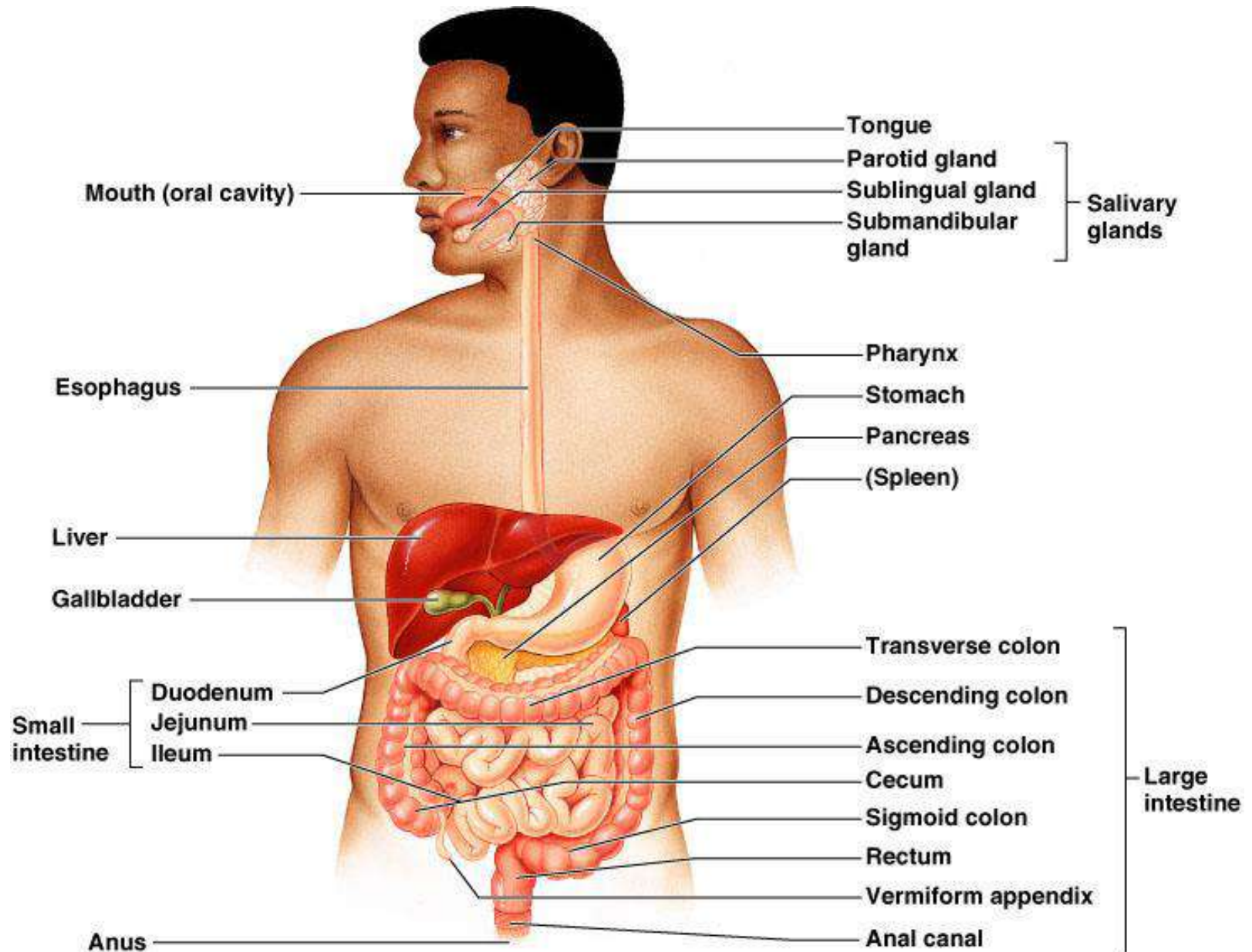
دكتوراه في الجراحة العامة

استشاري جراحة المسالك البولية

Digestive System: Overview

- The **alimentary canal** or **gastrointestinal (GI) tract** digests and absorbs food
- Alimentary canal – mouth, pharynx, esophagus, stomach, small intestine, and large intestine
- Accessory digestive organs – teeth, tongue, gallbladder, salivary glands, liver, and pancreas

Digestive System: Overview



Digestive Process

The GI tract is a “disassembly” line:

- Nutrients become more available to the body in each step

There are six essential activities:

- 1) Ingestion, 2) propulsion, and 3) mechanical digestion
- 4) Chemical digestion, 5) absorption, and 6) defecation

Digestive Process

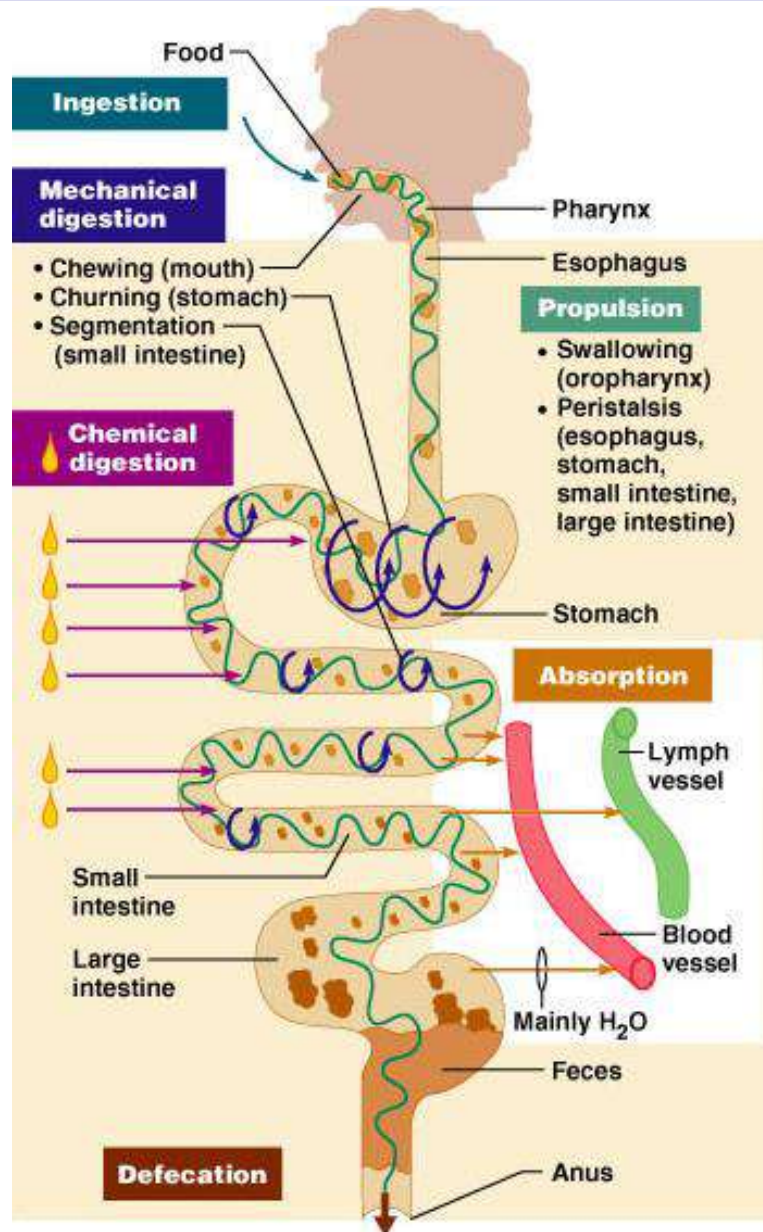


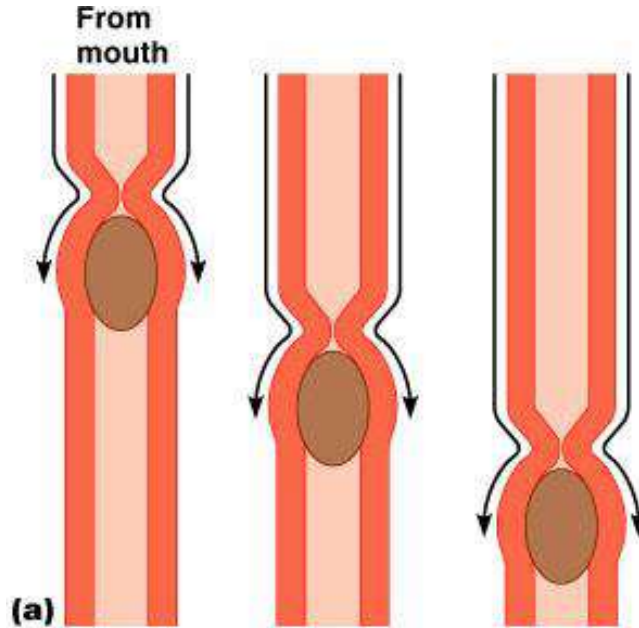
Figure 23.2

Gastrointestinal Tract Activities

- **1) Ingestion** – taking food into the digestive tract
- **2) Propulsion** – swallowing and peristalsis
 - **Peristalsis** – waves of contraction and relaxation of muscles in the organ walls
- **3) Mechanical digestion** – chewing, mixing, and churning food

Peristalsis and Segmentation

Esophagus



Intestine

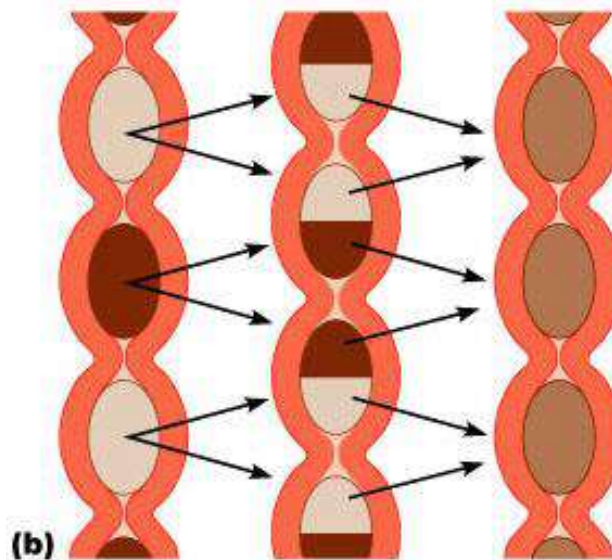


Figure 23.3

Gastrointestinal Tract Activities

- **4) Chemical digestion** – catabolic breakdown of food
- **5) Absorption** – movement of nutrients from the GI tract to the blood or lymph
- **6) Defecation** – elimination of indigestible and unabsorbed solid wastes

Peritoneum and Peritoneal Cavity

Peritoneum – serous membrane of the abdominal cavity

- Visceral peritoneum – covers external surface of most digestive organs
- Parietal peritoneum – lines the body wall

Peritoneal cavity

- Lubricates digestive organs
- Allows them to slide across one another

Mesentery – double layer of peritoneum that provides:

- Vascular and nerve supplies to the viscera
- A means to hold digestive organs in place and store fat

Blood Supply: Splanchnic Circulation

Arteries and the organs they serve include:

- The hepatic, splenic, and left gastric: spleen, liver, and stomach
- Inferior mesenteric and superior mesenteric: small and large intestines

Hepatic portal circulation:

- Collects nutrient-rich venous blood from the digestive viscera
- Delivers this blood to the liver for metabolic processing and storage

Mouth

Oral or buccal cavity:

- Is bounded by lips, cheeks, palate, and tongue
- Has the oral orifice as its anterior opening
- Is continuous with the oropharynx posteriorly

Mouth

1. **cheeks**
2. **lips** (labia), **labial frenulum** (attach to gums)
3. **hard palate** - anterior part of roof of mouth (palatine bones)
4. **soft palate** - posterior of roof of mouth (mucous membrane)
5. **uvula** - hanging portion of soft palate (punching bag)
6. **palatoglossal arch & palatopharyngeal arch**
 - a. palatine tonsils between arches

Anatomy of the Oral Cavity: Mouth

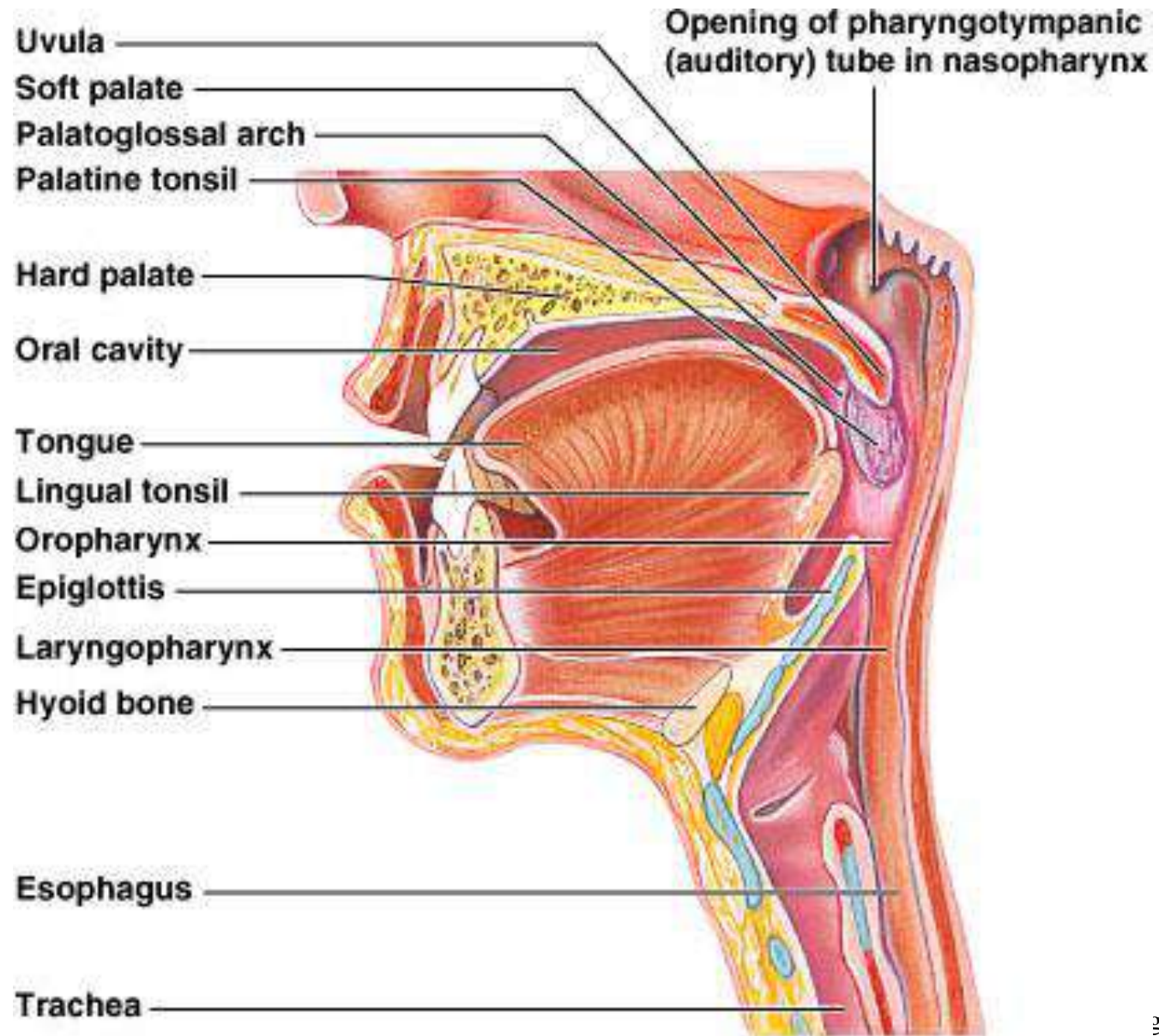


Figure 23.7a

Oral Cavity and Pharynx: Anterior View

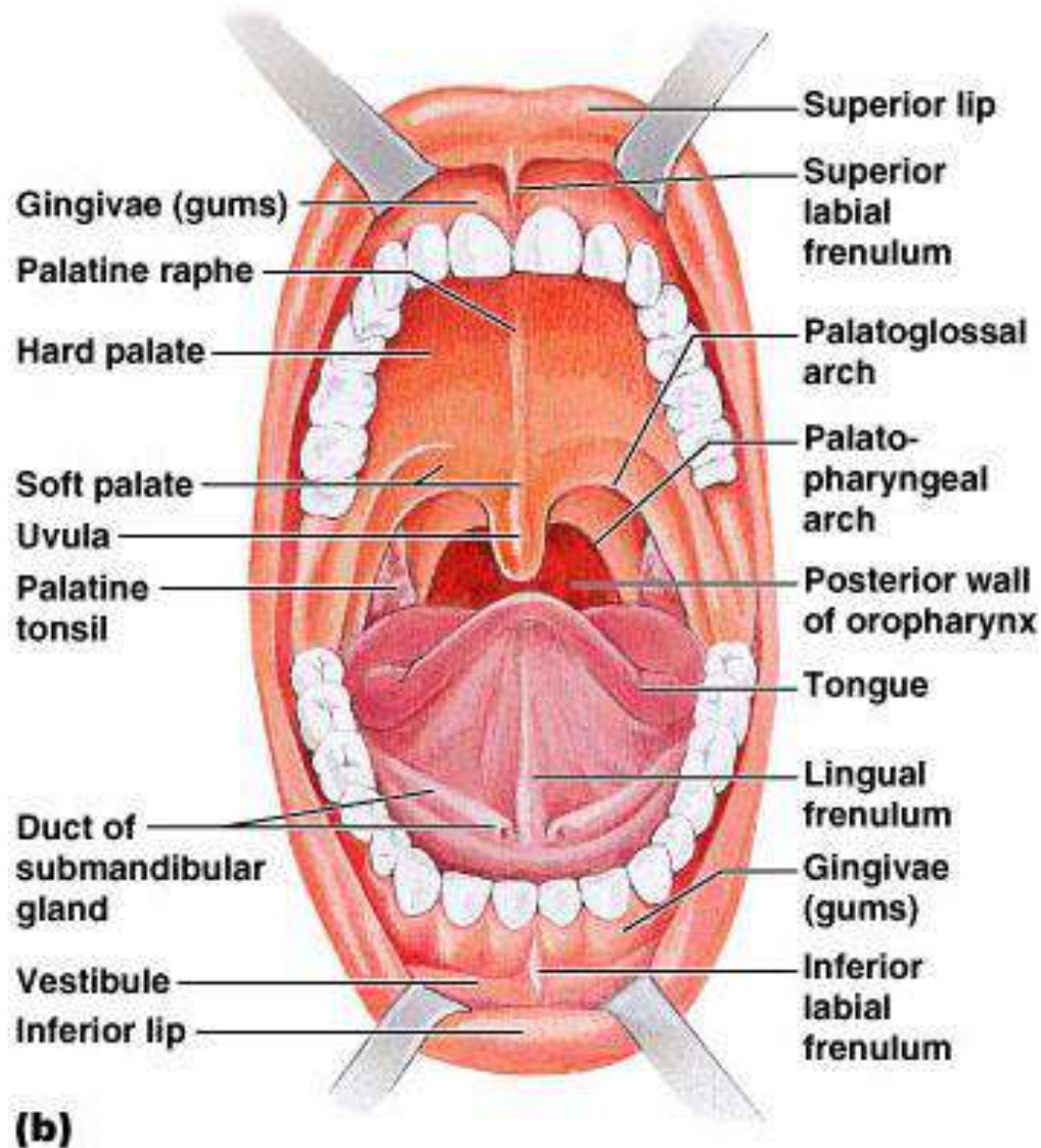


Figure 23.7b

Tongue

Functions include:

- Gripping and repositioning food during chewing
- Mixing food with saliva and forming the bolus
- Initiation of swallowing, and speech

Note: **Lingual frenulum** secures the tongue to the floor of the mouth

Salivary Glands

- **Parotid** – lies anterior to the ear between the masseter muscle and skin
 - Parotid duct – opens into the vestibule next to the second upper molar
- **Submandibular** – lies along the medial aspect of the mandibular body
- **Sublingual** – lies anterior to the submandibular gland under the tongue

Salivary Glands

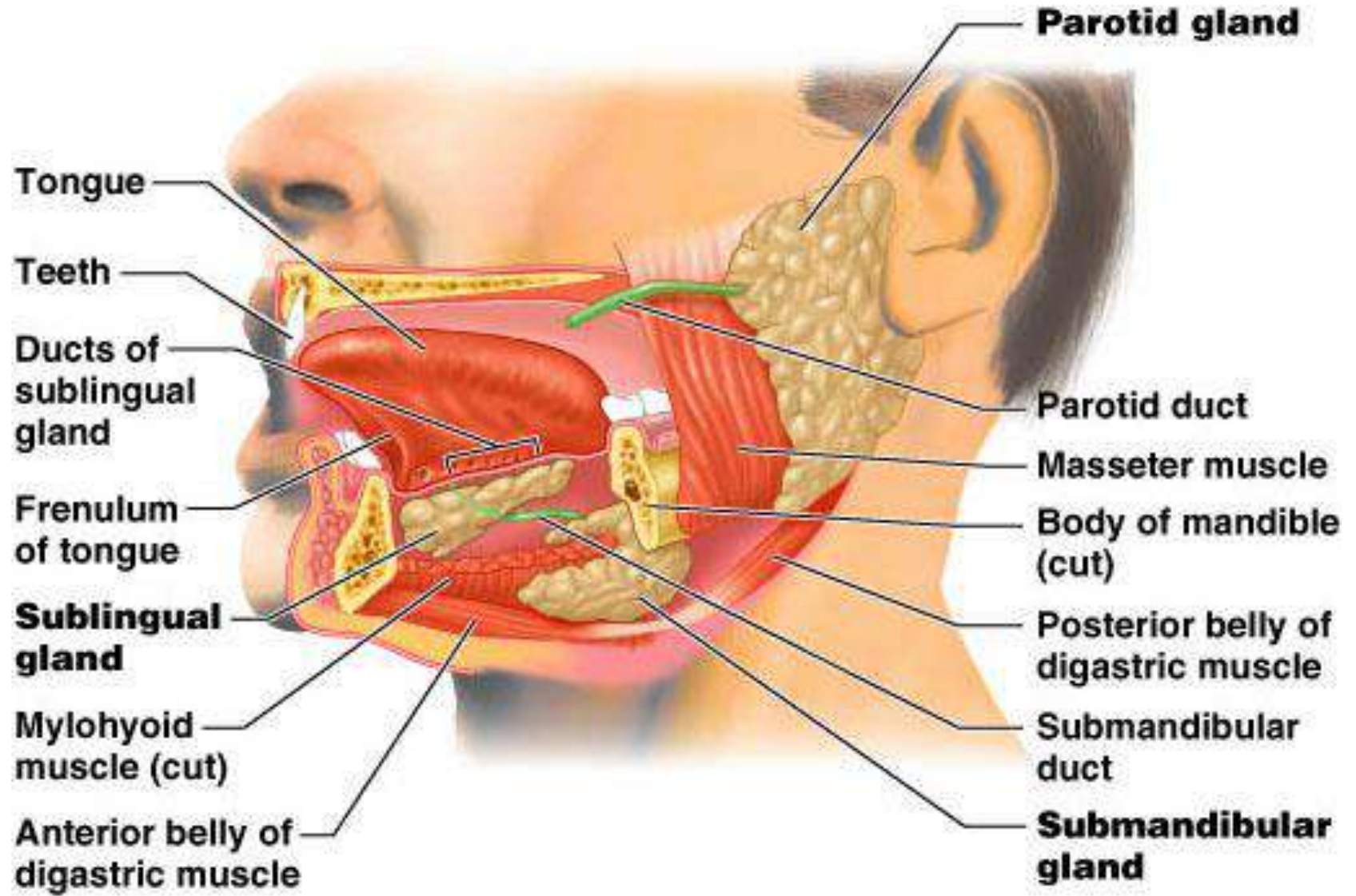


Figure 23.9a

Permanent Teeth

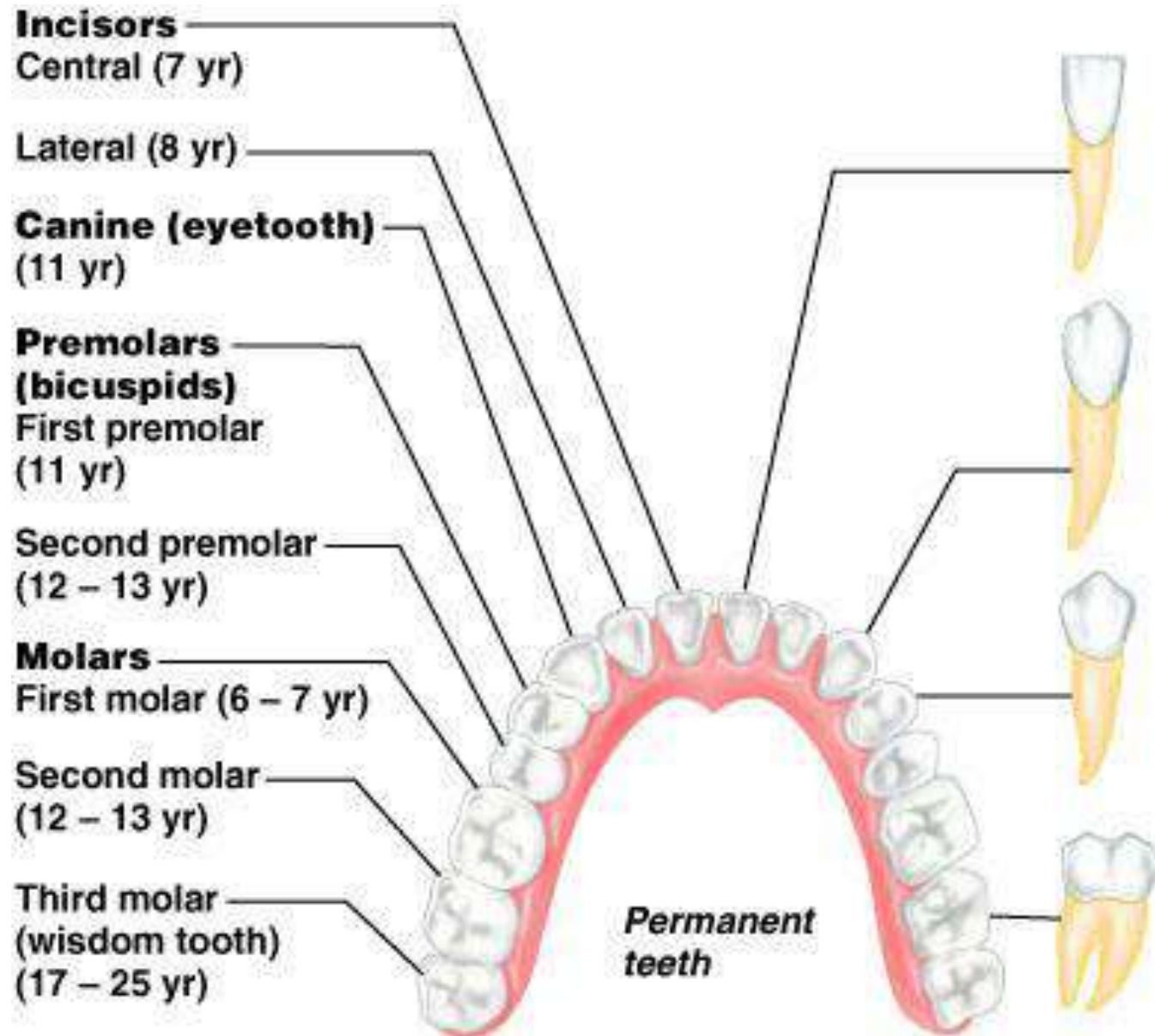


Figure 23.10.2

Classification of Teeth

Teeth are classified according to their shape and function:

- Incisors – chisel-shaped teeth adapted for cutting or nipping
- Canines – conical or fanglike teeth that tear or pierce
- Premolars (**bicuspid**s) and molars – have broad crowns with rounded tips and are best suited for grinding or crushing
- During chewing, upper and lower molars lock together generating crushing force

Esophagus

- Muscular tube going from the **laryngopharynx** to the **stomach**
- Travels through the mediastinum and pierces the diaphragm
- Joins the stomach at the **cardiac orifice**

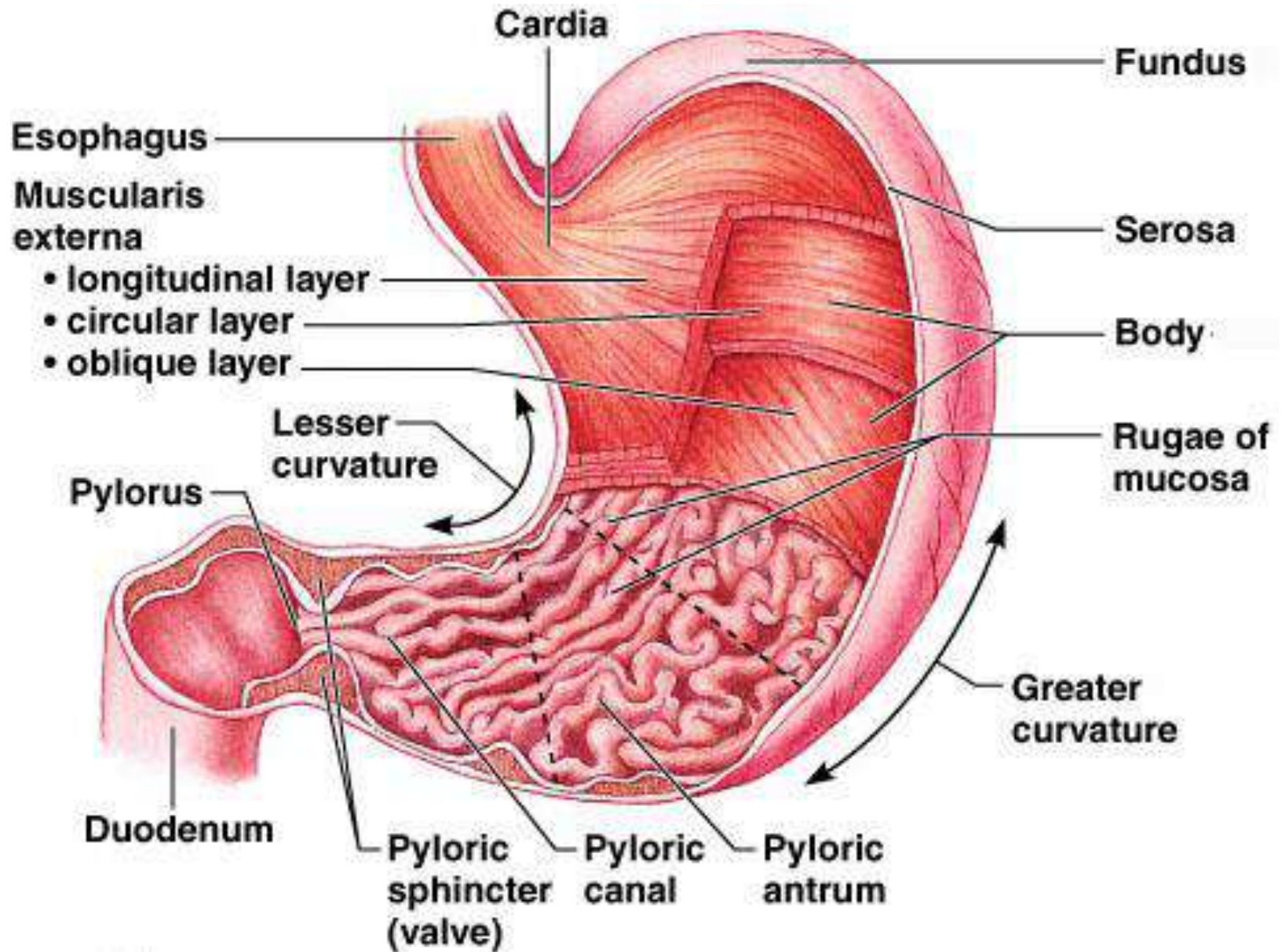
Stomach

- Chemical breakdown of proteins begins and food is converted to **chyme**
- **Cardiac region** – surrounds the cardiac orifice
- **Fundus** – dome-shaped region beneath the diaphragm
- **Body** – midportion of the stomach
- **Pyloric region** – made up of the antrum and canal which terminates at the pylorus
 - The pylorus is continuous with the duodenum through the **pyloric sphincter**

Stomach

- **Greater curvature** – entire extent of the convex lateral surface
- **Lesser curvature** – concave medial surface
- **Lesser omentum** – runs from the liver to the lesser curvature
- **Greater omentum** – drapes inferiorly from the greater curvature to the small intestine
- **Rugae** - folds in the inner lining of the stomach

Stomach



Stomach

- **Blood supply** – **celiac trunk**, and corresponding veins (part of the hepatic portal system)

Gastric glands of the fundus and body have a variety of secretory cells

- **Mucous neck cells** – secrete acid mucus
- **Parietal cells** – secrete HCl

Small Intestine: Gross Anatomy

- Runs from **pyloric sphincter** to the **ileocecal valve**
- The **bile duct** and main **pancreatic duct** join the duodenum at the **hepatopancreatic ampulla**
- The ileum joins the large intestine at the **ileocecal valve**

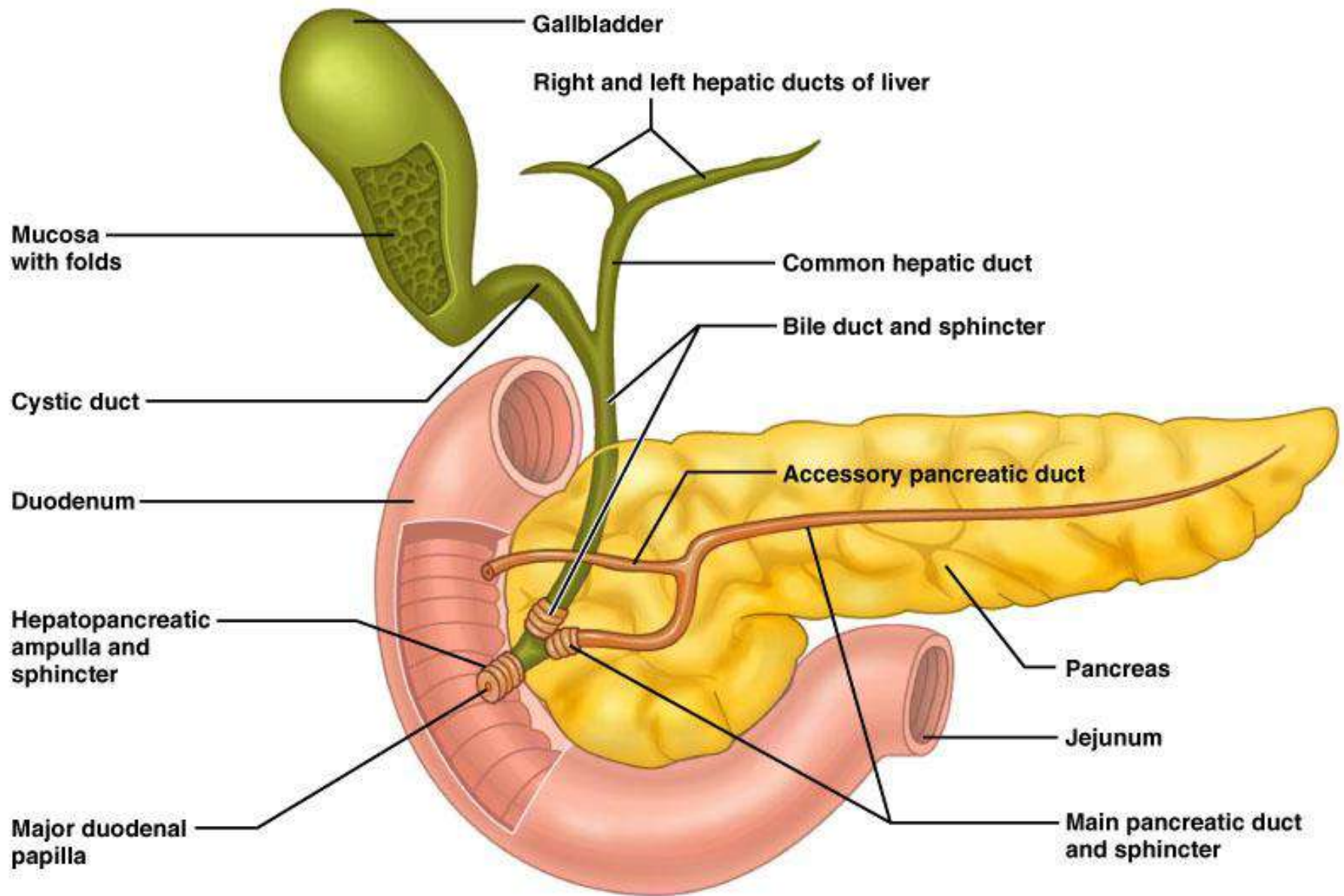
Has three subdivisions:

1. **duodenum**
2. **jejunum**
3. **ileum**

Pancreas - structure

posterior to great curvature of the stomach

1. **head** - enlarged portion in C-curve of the duodenum
2. **body** - tapers off beneath the stomach
3. **tail** - terminal part near the end
4. **pancreatic duct** - merges with bile duct to duodenum
 - a. hepatopancreatic ampulla (merging of both)
5. **accessory duct** - empties into duodenum, smaller



Pancreas - histology

1. made of *glandular epithelial cells*
2. pancreatic islets (of Langerhans) (1% of all cells)
 - a. hormones: glucagon, insulin, somatostatin
3. acini - (99% of the cells in pancreas)
 - a. mixture of enzymes called "pancreatic juice"

Liver

- Superficially has four lobes – **right, left, caudate, and quadrate**
- The largest gland in the body

Liver: Associated Structures

The falciform ligament:

- Separates the right and left lobes anteriorly
- Suspends the liver from the diaphragm and anterior abdominal wall

The ligamentum teres:

- Is a remnant of the fetal umbilical vein
- Runs along the free edge of the falciform ligament

Liver: Associated Structures

- The **lesser omentum** anchors the liver to the stomach
- The hepatic blood vessels enter the liver at the **porta hepatis**
- **gallbladder** - rests in a recess on the inferior surface of the right lobe; stores **bile** for digestion of fats

Bile

Bile leaves the liver via:

- Bile ducts, which fuse into the common hepatic duct
- The common hepatic duct, which fuses with the cystic duct
 - These two ducts form the bile duct

Gallbladder and Associated Ducts

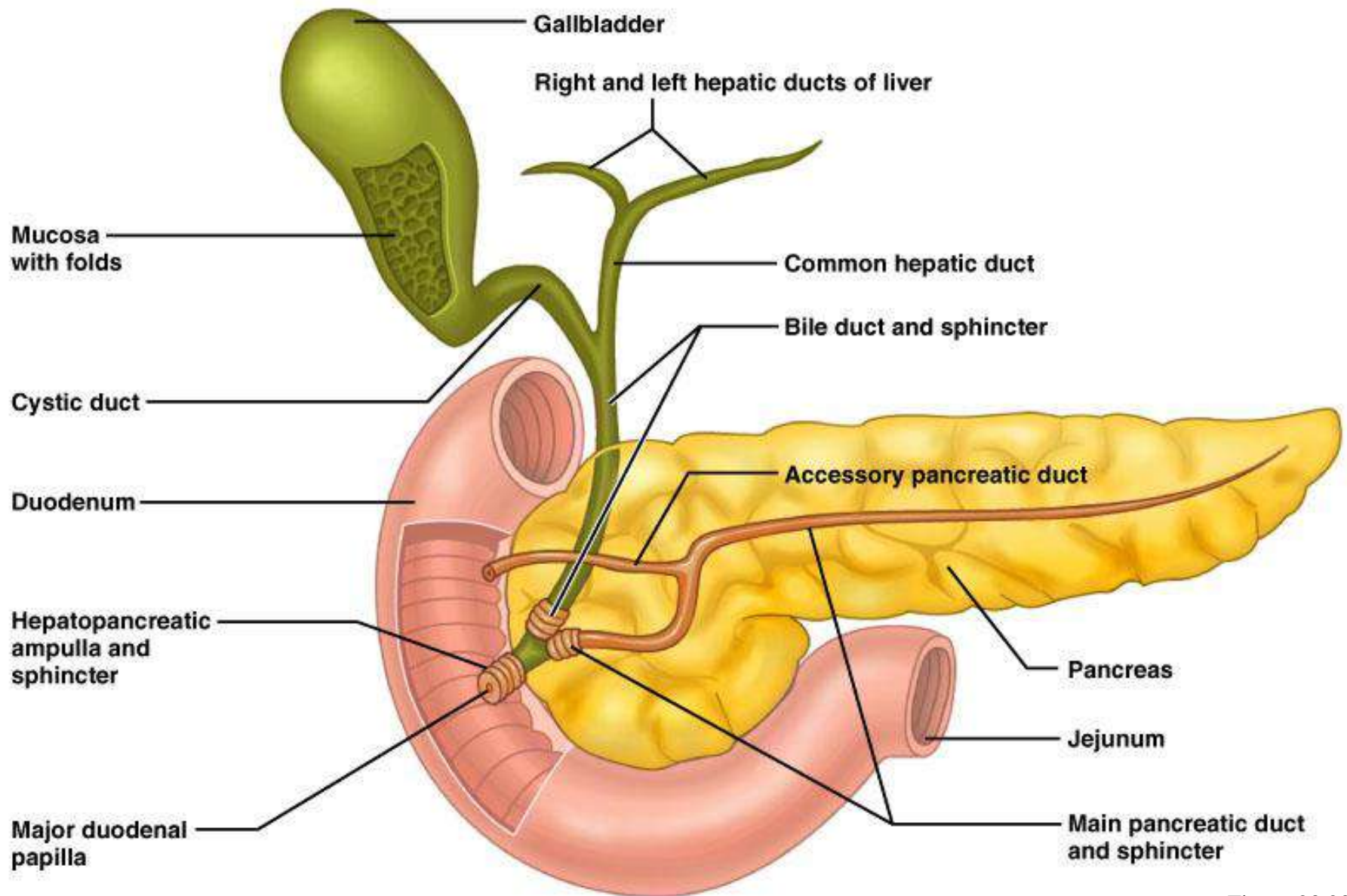


Figure 23.20

Liver: Anatomy

portal triads consist of a bile duct and

- **Hepatic artery** – supplies oxygen-rich blood to the liver
- **Hepatic portal vein** – carries venous blood with nutrients from digestive viscera

Hepatocytes

Hepatocyte functions include:

- Production of bile
- Processing bloodborne nutrients
- Storage of fat-soluble vitamins
- Detoxification

The Gallbladder

- Thin-walled, green muscular sac on the ventral surface of the liver
- Stores and concentrates bile by absorbing its water and ions
- Releases bile via the cystic duct, which flows into the bile duct

Large Intestine

- Is subdivided into the **cecum**, **appendix**, **colon**, **rectum**, and **anal canal**
- The saclike **cecum**:
 - Lies below the ileocecal valve in the right iliac fossa
 - Contains a wormlike vermiform appendix

Colon

Has distinct regions:

- **ascending colon**
- **hepatic flexure**
- **transverse colon**
- **splenic flexure**
- **descending colon**
- **sigmoid colon**

Large Intestine

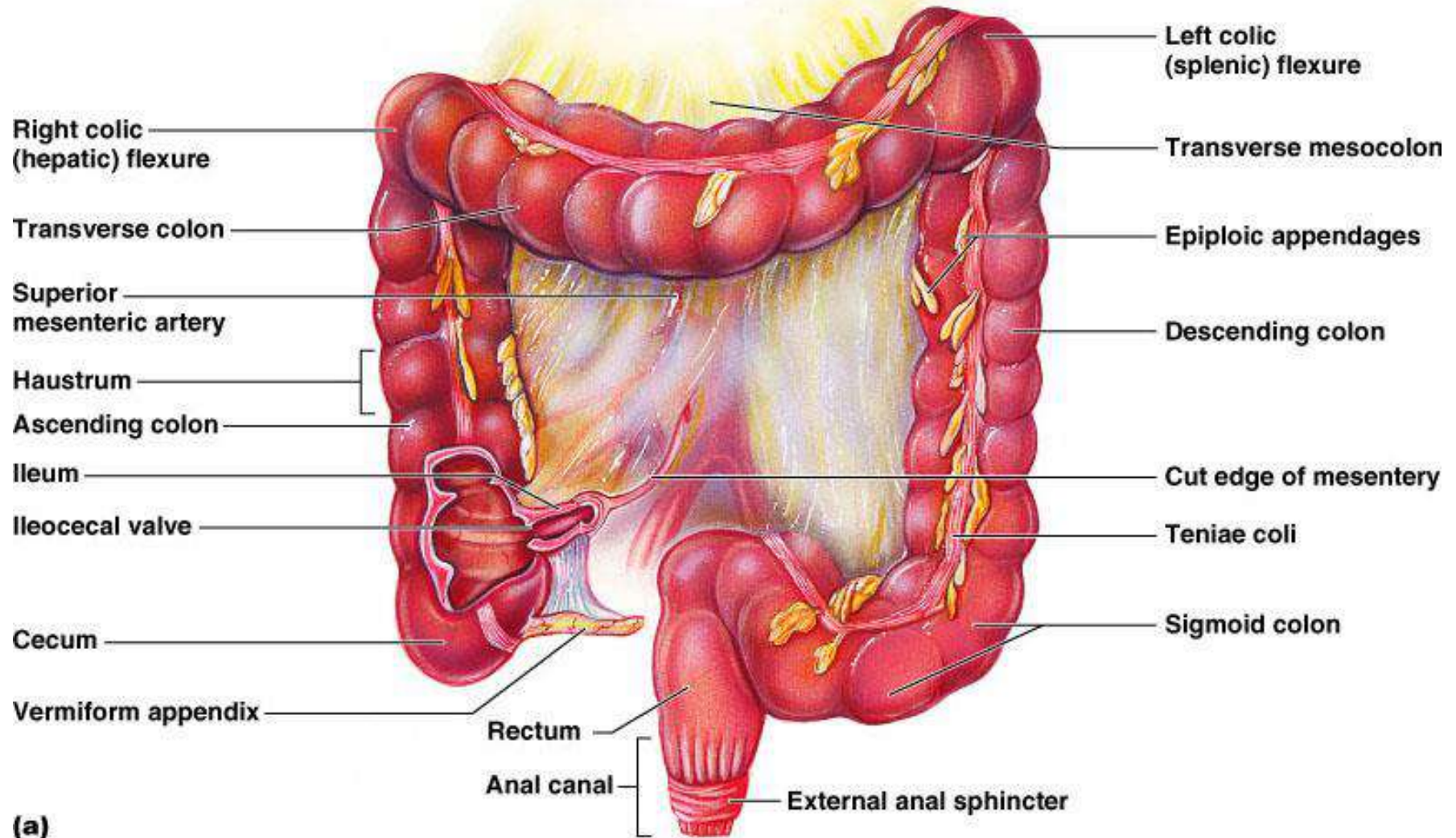


Figure 23.29a

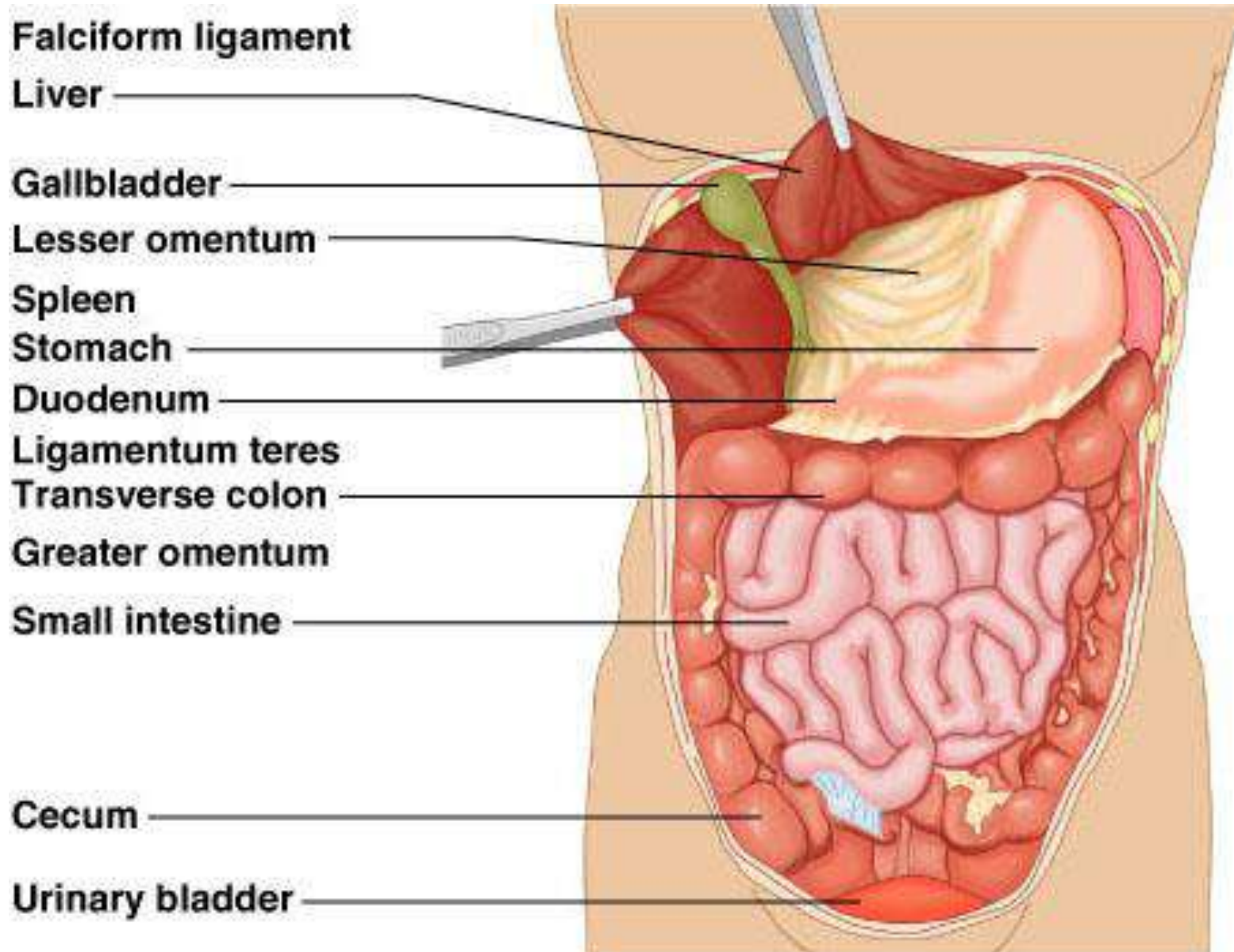
Colon

- The transverse and sigmoid portions are anchored via mesenteries called **mesocolons**
- The sigmoid colon joins the rectum
- The **anal canal**, the last segment of the large intestine, opens to the exterior at the **anus**

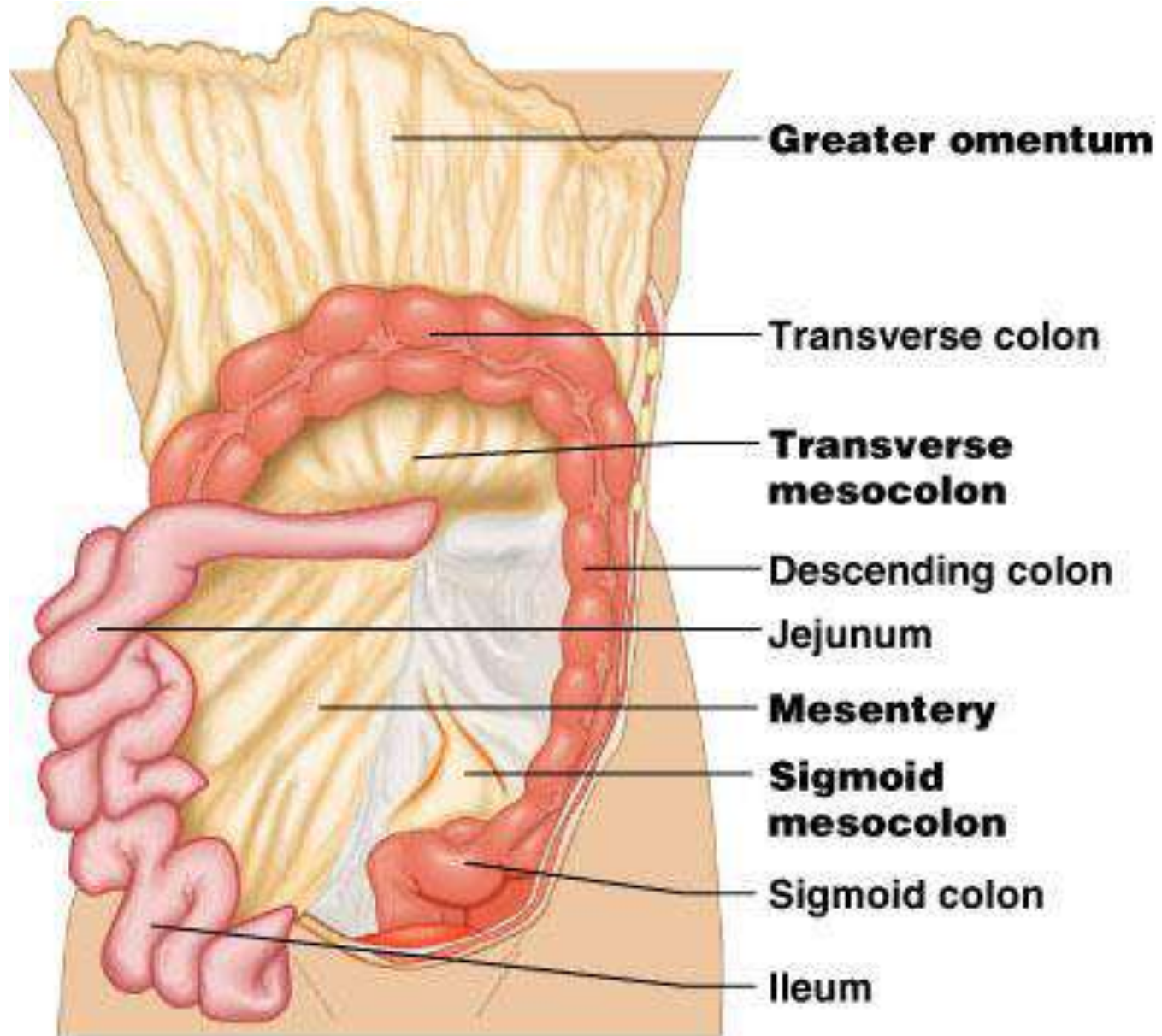
Anus

- **internal sphincter** - smooth muscle (involuntary)
- **external sphincter** - skeletal muscle (voluntary)

Mesenteries of Digestive Organs

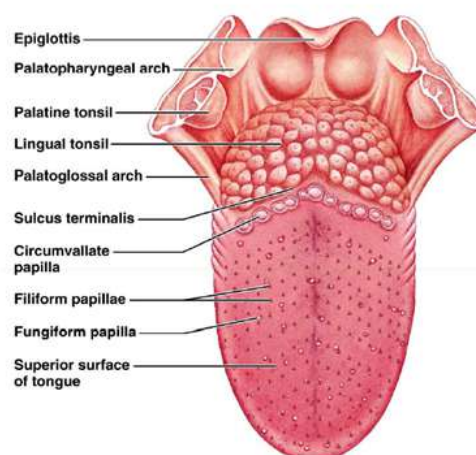
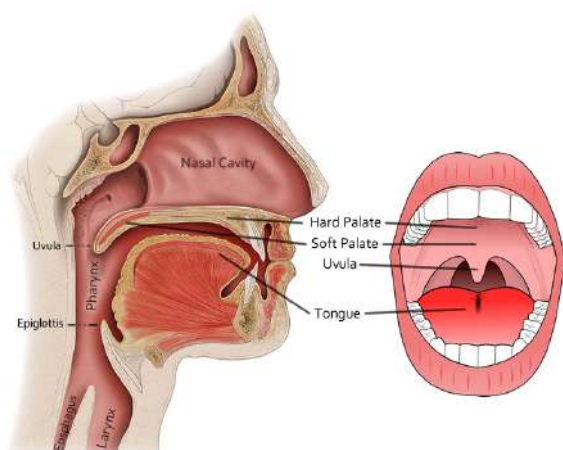


Mesenteries of Digestive Organs



The oral cavity

From the skin-vermilion border of the lips ant. to the junction of the soft palate sup. & the line of circumvallate papillae (the junction of the post. 1/3 and ant. 2/3 of tongue posteriorly).



NTAL ANOMALIES OF

1. **AGLOSSIA**: absence tongue.
2. **Microglossia**.
3. **Macroglossia** (cong./ acquired).
4. **CLEFT or BIFID TONGUE** : failure of fusion of 2 lingual processes.
5. **TONGUE TIE(ANKYLOGLOSSIA)**: short thick lingual frenum.

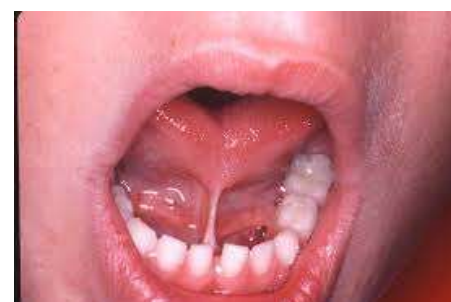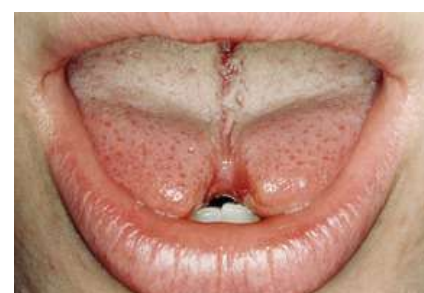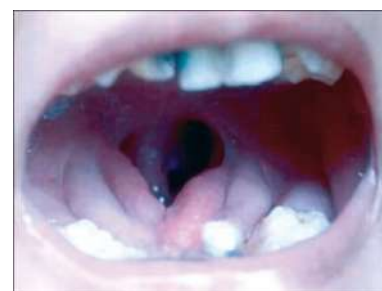o May cause:

- Impairment of tongue movements.
- deformity of dental occlusion.
- difficulty of swallowing & speech defects

Treatment: partial → self correction

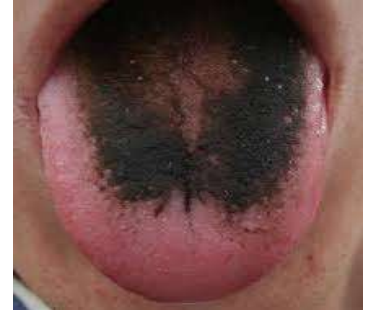complete → division of frenum

TONGUE



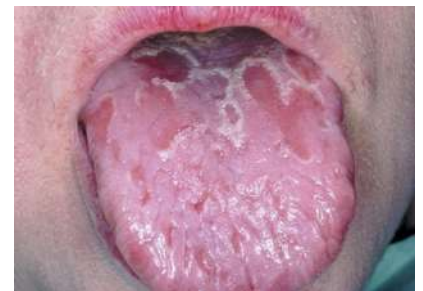6. Black hairy tongue (or lingua villosa nigra):

- o Painless.
- o benign disorder.
- o Hyperplasia of filiform papillae.
- o Overgrowth of pigment producing organism.
- o **Treatment:** cleaning and brushing the tongue.



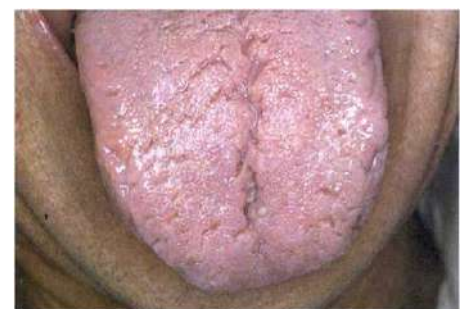7. GEOGRAPHIC TONGUE or benign migratory glossitis :

- o benign condition
- o alternating red & yellowish-white areas due to alternating hypertrophy / atrophy of tongue papillae
- o unknown etiology.
- o Treatment : proper tongue hygiene.



8. CONGENITAL FISSURED TONGUE (FURROWING):

- o furrowed surface of the tongue.
- o deep median fissure.
- o many short fissures run transversely from a median groove.
- o This sometimes get infected by candida albicans resulting in *median rhomboid glossitis*.



9. Median rhomboid glossitis

- o Candida albicans infection
- o Red, smooth, oval- or diamond-shaped de-papillation
- o on the dorsum of the tongue



- o just ant.to the circumvallate papillae.

Treatment : antifungals .

Tongue injury

CAUSES:

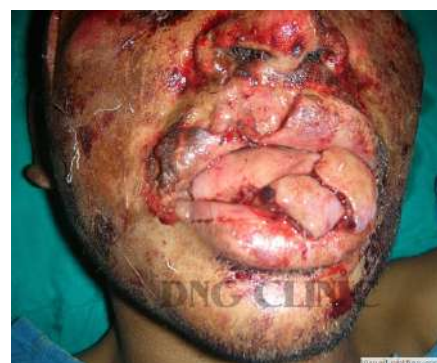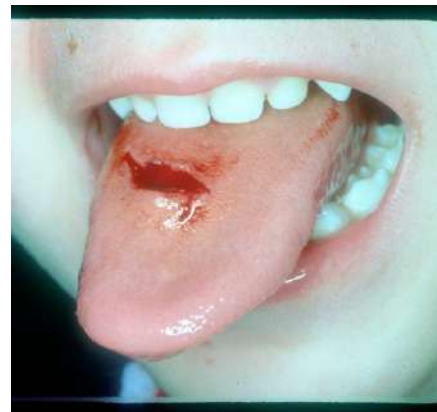1. Tongue biting (commonest) e.g. fall, seizure, or other blunt force
 2. Piercings, intoxication, and iatrogenic causes.
- bleeding

Why serious especially in unconscious?

1. Tongue hematoma can cause airway obstruction
2. If laceration → serious bleeding.

Treatment:

- o Usual heal well without repair
- o Repair indicated : (suturing by Absorbable sutures 4-0)



Tongue ulcer

1. TRAUMATIC ULCERS: DENTAL ULCER

- o repeated trauma by carious ,broken or ill-fitted denture.
- o At teeth side of the tongue.

- **Acute** :Painful oval-round ulcers with granulating floor , soft base & sloping margin +/- enlargement of draining LN
- **Chronic** : ulcer edge is raised & indurated base + LN enlargement so biopsy is

indicated to rule out ca.

Treatment. Removal of cause & antiseptic mouth wash.

2. INFLAMMATORY ULCERS:

A. **IDIOPATHIC APHTHOUS ULCERS (dyspeptic)**

- o Most common lesion .
- o Recurrent, very painful ulceration / healing
- o Etiology: ??,
- o TYPES:
 1. Minor
 2. Major
 3. Herpetiform

B. **HERPETIC ULCERS(herpes simplex type 1).**

- o Recurrent self limiting multiple small ulcers in children preceded by blisters at tip of tongue

C. **TUBERCULOUS.**

D. **SYPHILITIC (snail track / gummatous ulcers).**

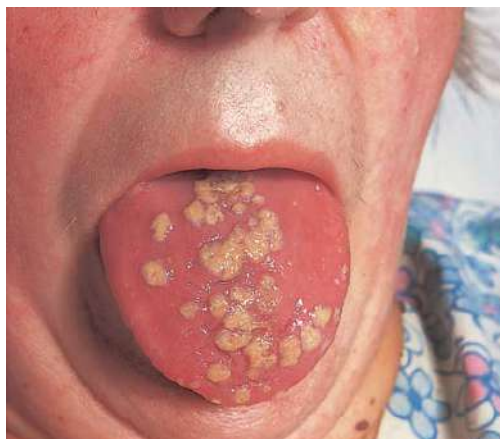
E. **CHRONIC SUPERFICIAL GLOSSITIS.**

3. NEOPLASTIC ULCERS:

- A- S.C.C (most common).
- B-Lymphoma.

Other Tongue lesions:

- o Monilial colonies of *and* mucous patches of



stomatitis. The *Monilia on the tongue* membranes look like cream-coloured paint.

Oropharyngeal cancer

- o Men
- o Elderly(>60)
- o frequently involved sites :
 - the floor of the mouth
 - the lateral border of the anterior tongue
 - the retromolar trigone.
- o Tobacco and alcohol are the main causes.
- o chronic irritation ZS (Smoking or tobacco chewing, Sharp tooth, chronic dental Sepsis, Syphilis, Spirits, Spices & Snuffing) .

Conditions associated with malignant transformation

1. Leucoplakia

- *White hyperkeratotic patches or plaque .*
- No pathological or clinical characteristics.
- variable Size: (small, well-circumscribed, homogenous white plaque to an extensive large surface areas) .
- May be smooth or wrinkled, fissured
- vary in colour (*white paint coated tongue* that can not be rubbed off)

Potential for malignant change

- increases with increasing age of the patient;
- increases with increasing age of the lesion;
- is higher in smokers;
- increases with alcohol consumption;
- depends on the anatomical site of the premalignant lesion; particularly high for leukoplakia on the floor of the mouth and ventral surface of the tongue, particularly in younger women, even in the absence of associated risk factors.

Pathology of oral cancer:

- **Main sites** : the floor of the mouth, the lateral border of the anterior tongue and the retromolar trigone:
- **GROSS TYPES:**
 1. Malignant ulcer: deep irregular necrotic floor, raised everted or rolled edge& hard red indurated base.
 2. Raised oval white plaque that fungates as cauliflower-like mass +central necrosis .(commonest)
 3. Hard sub mucous nodule (less common)
 4. Deep indurated chronic fissure that does not heal.
 5. Diffuse infiltrative wooden base i.e frozen tongue (rare)
- **MICROSCOPIC TYPES:**
 1. Ant. 2/3 well differentiated squamous cell ca. > 95%.
 2. Post 1/3 ca are less differentiated
 3. Basal cell ca & adenoca of minor salivary glands (rare)

SPREAD: CA in situ=no invasion to BM + no spread.

1. Direct (local) spread :

- o Ca ant 2/3 invades lat. then to floor of mouth then to mandible.
- o Post 1/3 ca invades tonsils, pharynx & larynx..

Fascial planes& periosteum act as barriers to direct spread

2. **Lymphatic spread:** occurs early with 30% clinical / subclinical
 - o Ca. tip of tongue drains bilaterally to submental LN.
 - o Ca. ant.2/3 to ipsilateral SMD& then to DCLN..
 - o Ca. post 1/3 drains bilaterally to upper DCLN.
3. **Blood spread:** very rare& occurs in post 1/3 ca & correlates with distant metastases (bad prognosis).
4. **Perineural invasion** (bad prognosis)

Main clinical features of oral cancer

- Elderly, males +/- risk factors .
- Persistent oral **swelling** or mouth **ulceration** for > 4 weeks.
- **Painless** unless deeply invasive (sore tongue).
- Difficulty swallowing.
- Jaw or facial swelling.
- Painless palpable submandibular or jugular **L. nodes** .
- Unexplained tooth mobility.
- Fixation of tongue (Ankyloglossia).

Complications

1. Inhalation of necrotic tissues bronchpneumonia.
2. Combined cancer cachexia & starvation due to pain & dysphagia.
3. Bleeding due to erosion of lingual vessels& erosion of ICA in post 1/3 tumors.
4. Asphyxia due to enlarged fixed LN or due to glottic edema.

Investigations of ca tongue:

Biopsy (for the suspicious lesion)

Additional investigations:

- o Plain radiography of the jaw
- o MRI of head and neck
- o Ultrasound & CT
- o radioisotope bone scan of the facial skeleton

Treatment of Tongue cancer

1. Carcinoma in situ Rx =

- o localized small lesions, on the lateral border of tongue Rx by surgical excision + primary closure.
- o Larger lesions = laser vaporization

2. T1 (< 2 cm diameter) tumour = either surgery or radioth.

- A. Surgery :Surgical excision of tumour by partial (hemiglossectomy 2 cm margin + Ipsilateral selective neck dissection.
- B. Radiotherapy.

3. Advanced tumours (T3 and T4 cross midline)

Rx= total glossectomy, floor of the mouth and mandible+ bilateral neck dissection.

Palliative treatment

Indicated for recurrence, metastasis ,fixed LN or unresectable tumours:

- Radiotherapy
- Palliative debulking of big primary
- Combination Chemotherapy

Radiofrequency thermal ablation:

Supportive care.

Prognosis: Depends on:

1. Site : posterior 1/3 poor prognosis

2. TNM Stage:

Size (T)= large tumours more LN metastasis.

Cervical node metastasis (N)= is the most significant factor in determining prognosis .

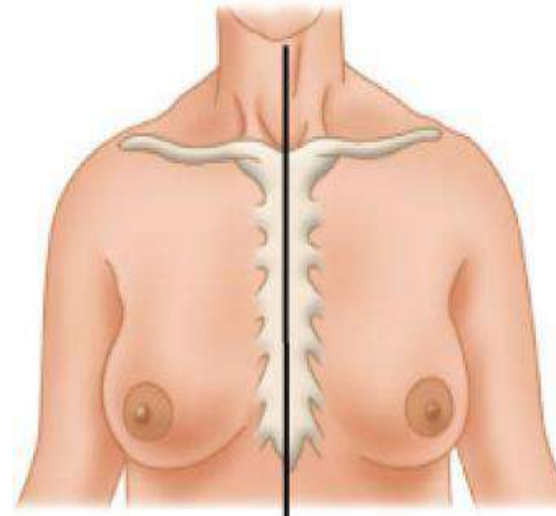
3. Concomitant medical problems as CVS or resp. disease.

BREAST DISEASES

د. صديق بكر مرعي

C.A.B.S. CONS. URO.

- The paired normally develops in the pectoral region, gland on each

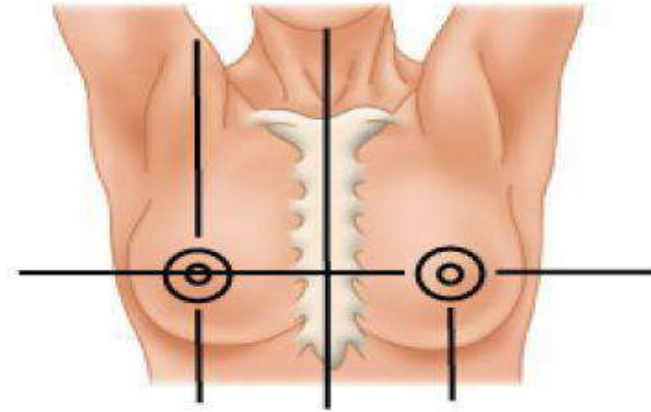


glands

**one
side.**

The breast is partitioned into 4 quadrants by vertical and horizontal lines across the nipple:

- Upper inner quadrant (UIQ)
- Lower inner quadrant (LIQ)
- Upper outer quadrant (UOQ)
- Lower outer quadrant (LOQ)



Breast Divisions 5 Segments

4 quadrants

— By horizontal and vertical lines

Tail of Spence

Majority of benign or malignant tumors in the upper outer quadrant

DIAGNOSIS OF BREAST DISEASE

questions focused on the presenting symptom, whether it be

- a mass,
- nipple discharge,
- palpable adenopathy,
- pain,
- abnormal imaging.

Examination

- The physical examination should be performed with respect for patient privacy and comfort without compromising the complete evaluation.

- The examination begins with **inspection**.

The breasts are visually observed and compared ,
any obvious masses, asymmetries, and skin
changes.

The nipples are inspected for the presence of
retraction OR inversion,

- **Palpation** the breast is examined
- patient upright with arms relaxed and supine with
the ipsilateral arm raised above the head.
- Finally the regional nodes should follow to include
the axillary, infraclavicular, supraclavicular, and
cervical nodes.

Pathologic discharge:

- unilateral,
- uniduct,
- spontaneous, and/or bloody discharge, should be evaluated with surgical duct excision.

INVESTIGATION

Mammography

Ultrasound

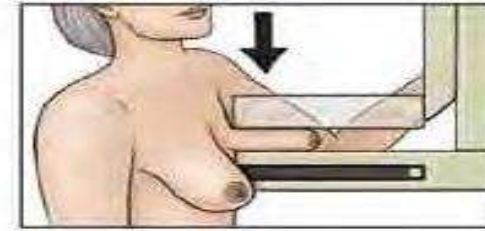
**Magnetic resonance
imaging (MRI)**

Computed tomography

Needle biopsy\cytology

Mammography

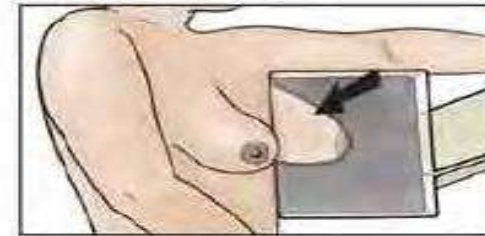
X-rays taken by placing the breast in direct contact with ultrasensitive film.
mammography is a very safe investigation.



Orientation for Part A

- **Ultrasound**

- Ultrasound initially used to differentiate solid masses from cystic masses, but it has become an important adjunct to mammography and is an excellent method for guiding some interventional procedures.



Orientation for Part B

Computed tomography

- appears to be the best way to image internal mammary nodes and to evaluate the chest and axilla after mastectomy.
- **Needle biopsy/cytology**
- **Fine-Needle Aspiration Cytology**
- **Core-Needle (Cutting-Needle) Biopsy Image-Guided by Ultrasound.**

Triple assessment

- any patient who presents with a breast lump or other symptoms suspicious of carcinoma,
- the diagnosis should be made by a combination of clinical assessment, radiological imaging and a tissue sample taken for either cytological or histological analysis, the so called triple assessment.
- The combinations should exceed 99.9%.

Diseases Of The Nipple

- Nipple retraction.
- Cracked nipple.
- Papilloma of the nipple.
- Retention cyst of a gland of Montgomery.
- Eczema.
- Paget's disease.
- Discharges from the nipple.

Nipple retraction

occur at puberty or later in life.

- pubertal retraction, known as simple nipple inversion, is of unknown aetiology.
- In 25% of cases it is bilateral.
- It may cause problems with breast-feeding and infection can occur, especially during lactation, because of retention of secretions.

Eczema

- Eczema of the nipples is a rare condition and is often bilateral; it is usually associated with eczema elsewhere on the body.
- It is treated with 0.5% hydrocortisone (not a stronger steroid preparation).

Discharges from the nipple

- Discharge can occur from one lactiferous ducts or more.

Box 32.2 Causes of nipple discharge

- Physiological (pregnancy, lactation)
- Duct ectasia
- Galactorrhoea
- Duct papillomas
- Fibrocystic disease
- Carcinoma
- Idiopathic

Workup

- Exam
- Labs- Prolactin, Heme
- Mammogram
- Cytologic evaluation of discharge

- Ductography

Bloody nipple discharge

- Most common cause is intraductal papilloma
- Cancer present 10% of cases .
- Management depends on:
 - the presence of a lump .
 - multiple or a single duct.
- Mammography is useful to exclude an underlying impalpable mass.

- Cytology may reveal malignant cells.

Treatment

- Treatment must firstly be to exclude a carcinoma by cytology.
- Simple reassurance of the patient,
- if the discharge is proving intolerable, an operation to remove the affected duct or ducts can be performed.

Intraductal papilloma

- Benign epithelial tumors arising in ducts of breast.
- Main cause of bloody nipple discharge.
- Usually women age (40-45).
- Size (2-5) mm, usually not palpable, nearly always situated within 4–5 cm of the nipple orifice.
- Present with spontaneous, bloody, serous or cloudy nipple discharge.

Management

- excisional biopsy

When the duct of origin of nipple bleeding is uncertain or when there is bleeding or discharge from multiple ducts, the entire major duct system can be excised for histological examination without sacrifice of the breast form.

BENIGN BREAST DISEASE

- The most common cause of breast problems.
- 30% of women will suffer from a benign breast disorder requiring treatment .

- The most common symptoms are pain, lumpiness or a lump.
- The aim of treatment is to exclude cancer and, once this has been done, to treat any remaining symptoms.

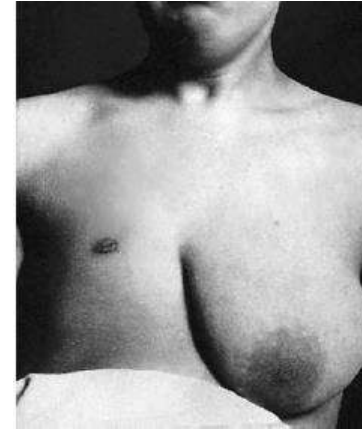
BENIGN BREAST DISEASE

- Congenital disorders.
- Infectious and inflammatory.
- Fibrocystic Disease
- Mastalgia.
- Benign mass.
- Injury.

Congenital abnormalities

Amazia

- Congenital absence of the breast may occur on one or both sides.
- It is sometimes associated with absence of the sternal portion of the pectoralis major (Poland's syndrome).
- It is more common in males.



Diffuse hypertrophy

- occurs in girls at puberty (benign virginal hypertrophy) and less often, during the first pregnancy.

The condition is usually bilateral.

- This is caused by an alteration in the normal sensitivity of the breast to oestrogenic hormones and some success in treating it with anti-oestrogens has been reported.
- Treatment by reduction mammoplasty.

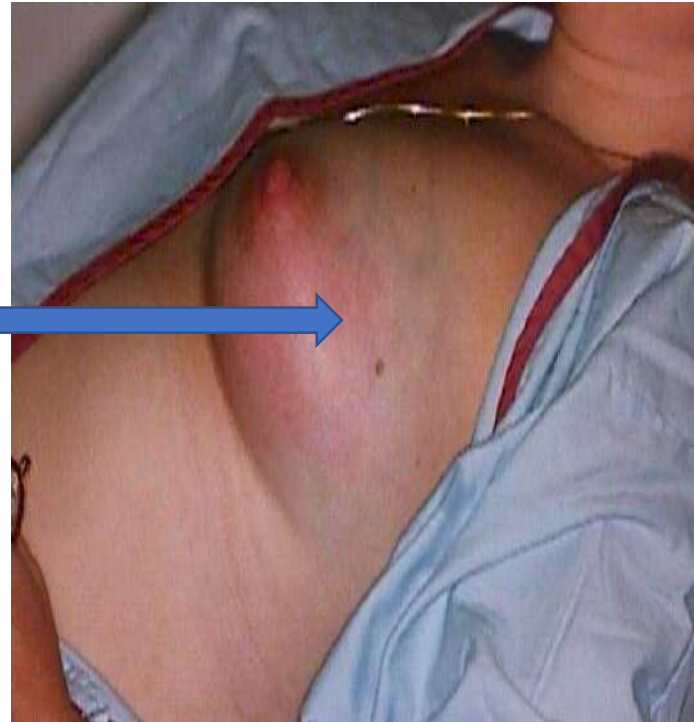Infections

Mastitis

- of Ascending infection
→ subareolar ducts
 - commonly occurs during lactation

Aetiology

- Lactational mastitis in most cases are caused by *Staphylococcus aureus* or *Streptococcus* spp .

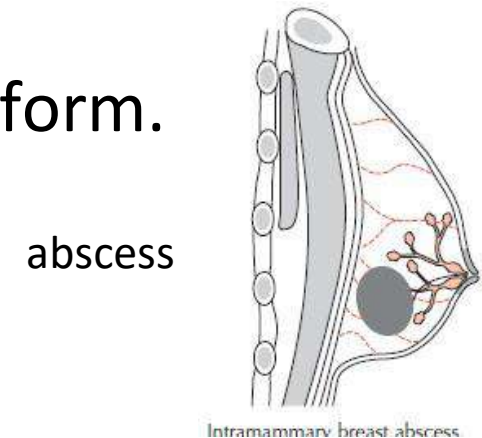
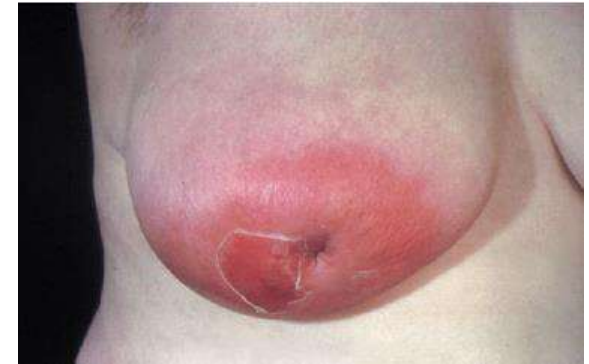

Clinical features

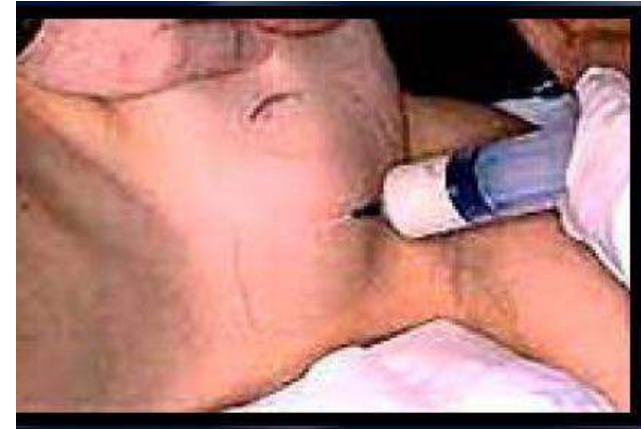The affected breast, or more usually a segment of it, presents the classical signs of acute inflammation. ^{abscess} focal tenderness with erythema and warmth of overlapping skin.

It is a generalized cellulitis but later, an abscess will form.

- The presence of pus confirmed with needle aspiration.



- the pus sent for bacteriological culture.
- When in doubt an ultrasound scan may clearly define an area suitable for drainage.



Treatment

- During the cellulitic stage the patient should be treated with an appropriate antibiotic, for example flucloxacillin or coamoxiclav.

.Support of the breast, and analgesia will help to relieve pain.

Salivary Glands

Dr. SIDDEEK BAKR MAR`IE

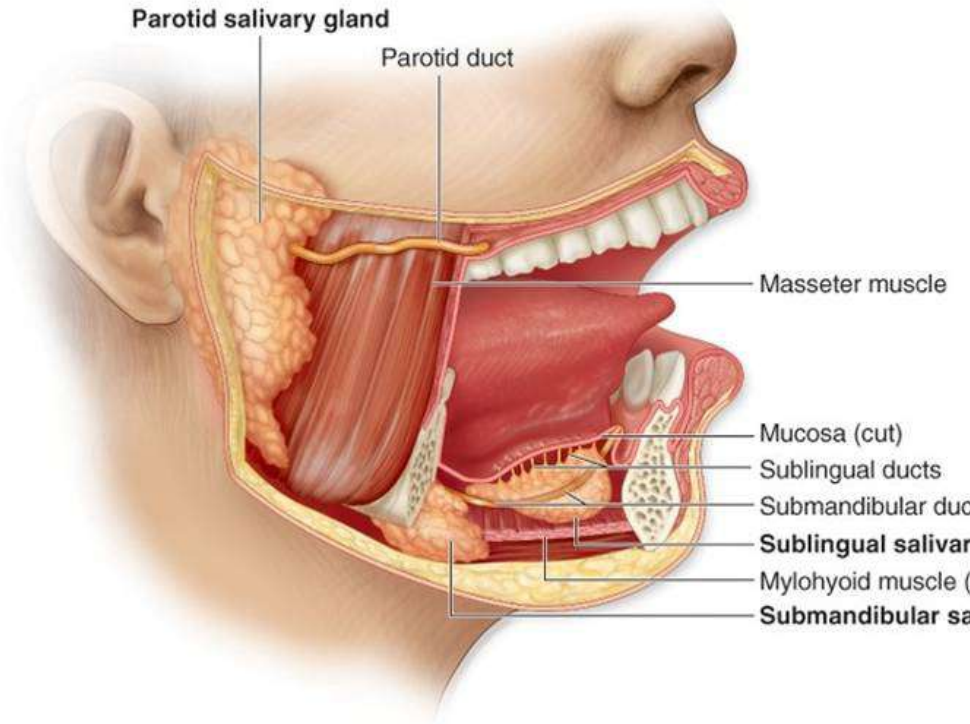
M.B;Ch.B. C.A.B.S.

Specialist General surgeon & Consultant Urologist



Anatomy of salivary glands

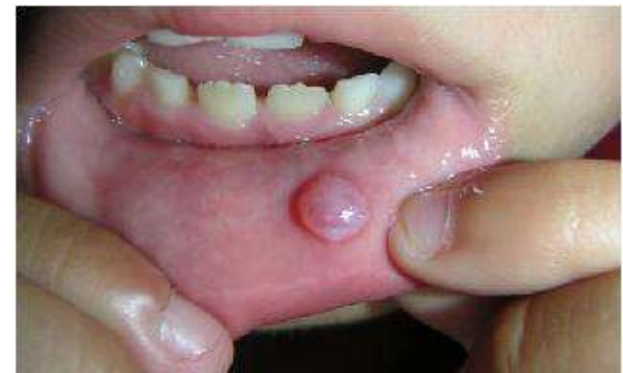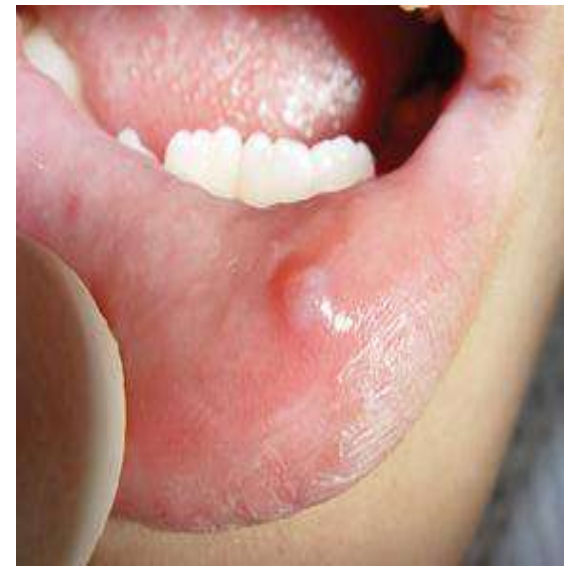- ❑ Two submandibular glands
- ❑ Two parotid glands
- ❑ Two sublingual glands
- ❑ Approximately 450 minor salivary glands



Common disorders of minor salivary glands

1- Extravasation Cysts

- Common
- trauma to the overlying mucosa.
- affect lower lip □ producing **painless** swelling and usually **translucent** .
- **resolve spontaneously**
- most require **formal surgical excision** +overlying mucosa +underlying minor salivary gland.
- Recurrence is rare.



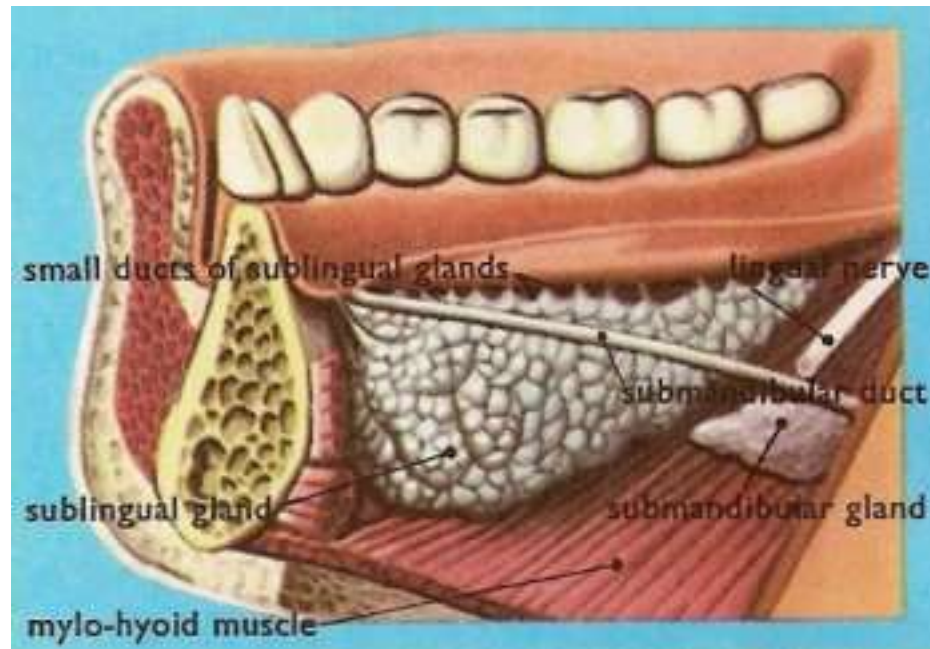
Tumours of minor salivary glands

- **90 % malignant.**
- common sites : upper lip, palate and retromolar regions.

Benign minor salivary gland tumors present as **painless, firm, slow-growing** swellings.

- Treatment: excision of the tumor +overlying mucosa+ primary closure

Sublingual Salivary Gland

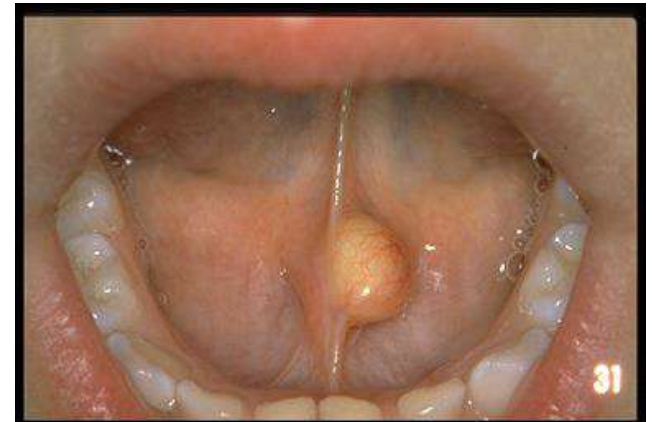


Common disorders of the sublingual glands

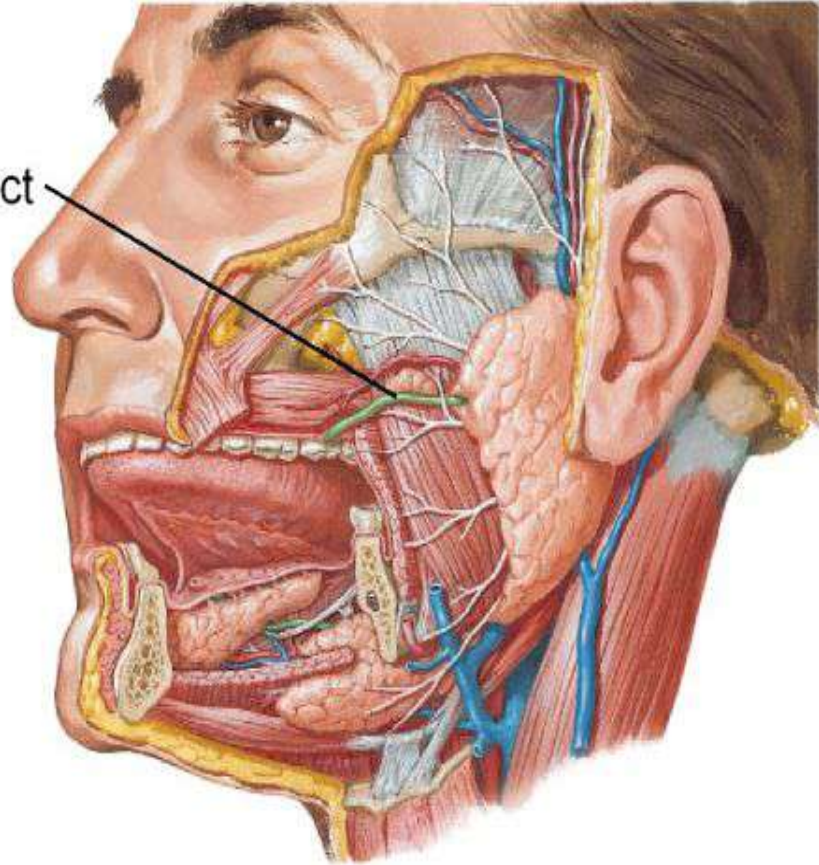
1- Cysts(ranula)

mucous extravasation cyst that arises from a sublingual gland.

- translucent swelling ‘frog’s belly’ .
- resolve spontaneously.
- many require formal surgical excision of the cyst and the affected sublingual gland.



Parotid duct



Inflammatory disorders of the submandibular gland(sialadenitis)

acute, chronic or acute on chronic.

Common causes are:

Acute submandibular sialadenitis:

1- Bacterial sialadenitis

more common than viral sialadenitis

- secondary to obstruction.
- antibiotics, if chronically inflamed □ formal excision.

2- Viral. The paramyxovirus (mumps)

Usually parotitis.

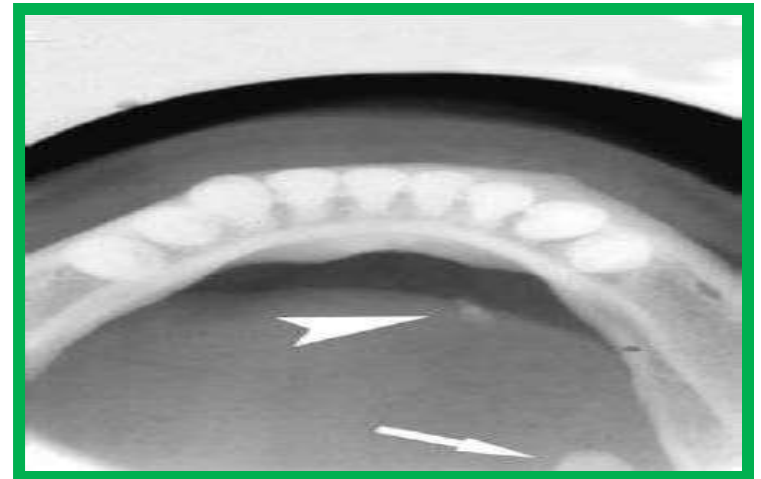
painful tender swollen glands.

Obstruction and trauma to submandibular gland

Stone formation (sialolithiasis): most common cause of obstruction within the submandibular gland is within the gland and duct system.

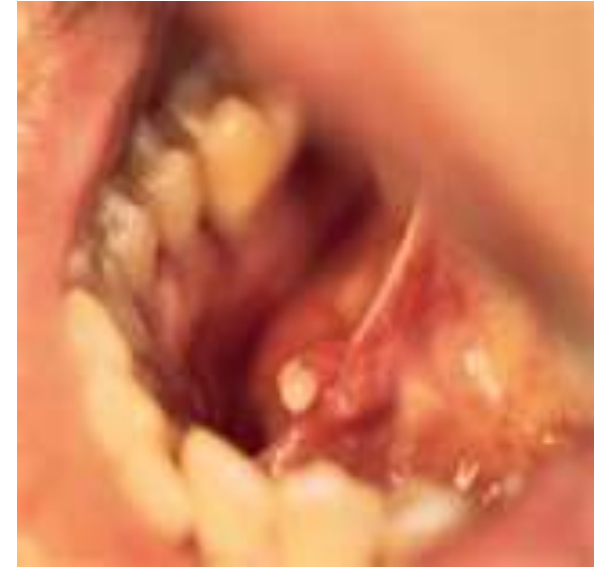80% of all salivary stones occur in the **submandibular** glands because highly viscous secretions .

80% **submandibular** stones are **radio-opaque**

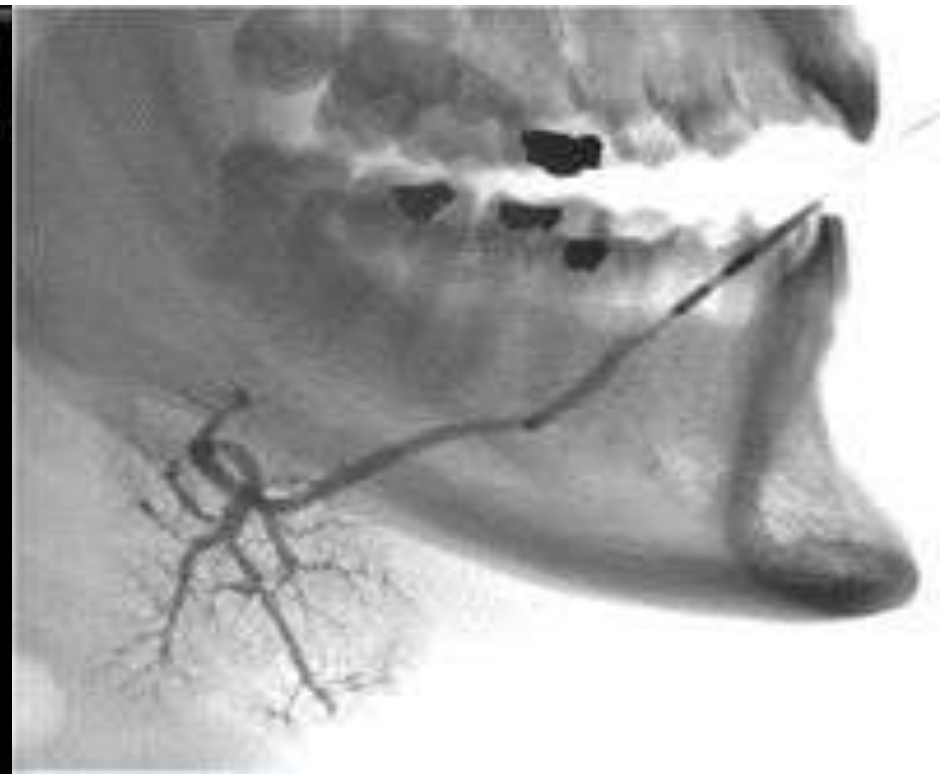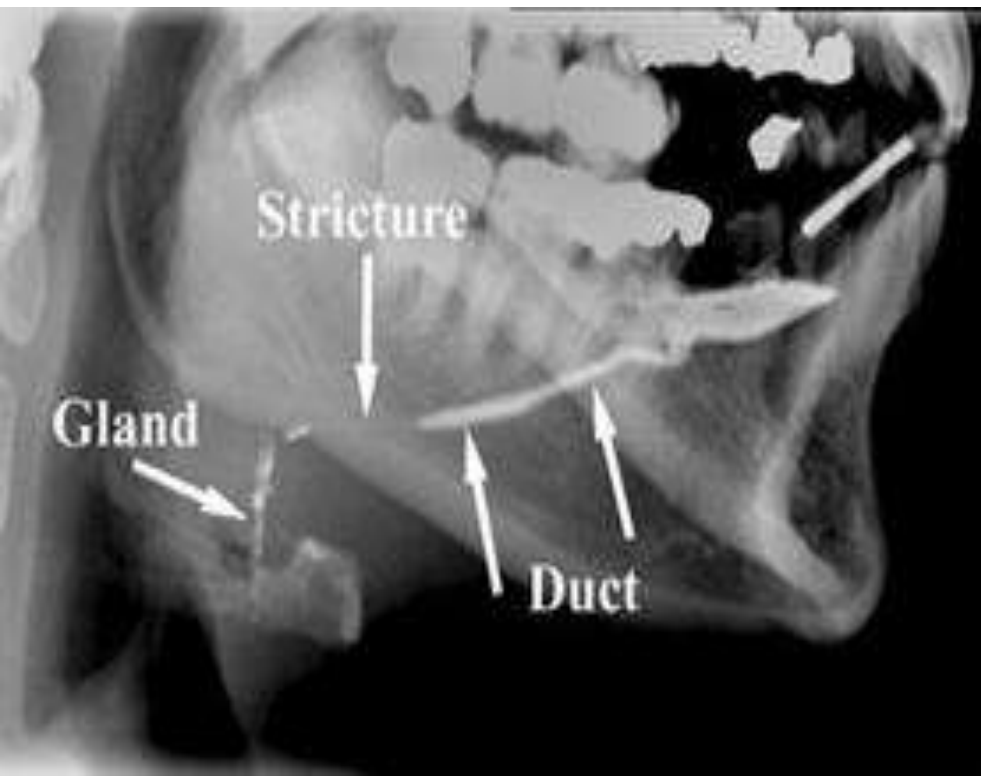


Clinical symptoms

- acute painful swelling in the region of the submandibular gland
- precipitated by eating
 - **completely obstruct(less common)** opening of the submandibular duct □ swelling develop rapidly □ 1–2 hours after the meal resolves spontaneously
 - **partial obstruction(more common)** (hilum of the gland or within duct in the floor of the mouth) □
 - infrequent symptoms
 - minimal discomfort and swelling
 - not confined to mealtimes.
 - examination □ enlarged firm submandibular gland, tender on bimanual examination.
- Pus from the sublingual papilla .



sialogram



Investigation

1-Computed tomography (CT) and MRI scanning

□ the extension, circumscribed

2- Biopsy

Open surgical biopsy is contraindicated .

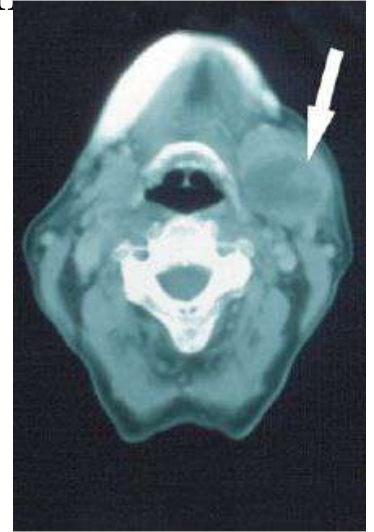
Fine-needle aspiration biopsy

no risk of seeding viable

Management

incising over the duct+stone delivered+ leave the wall of the duct

endoscopic retrieval of stone, lithotripsy(sialadenoscope)



THE PAROTID GLAND


Inflammatory disorders

Viral infections

Mumps (most common)

- **acute painful parotid swelling**
- Mostly affects **children**.
- spread by **airborne droplets** .
- 1–2 days fever, nausea and headache
- □ pain and swelling in parotid glands.
- pain □ very severe and exacerbated by eating and drinking.
- Symptoms resolve within 5–10 days.
- **Treatment** : regular paracetamol + adequate oral fluid intake.
- **Complications**

orchitis, oophoritis, pancreatitis, sensorineural deafness and meningencephalitis are rare.



Bacterial infections

Acute ascending bacterial sialadenitis

dehydrated elderly patients following major surgery

- *Staphylococcus aureus* / *Streptococcus viridans*
- presentation □ **tender, painful parotid swelling** that arises over several hours
- generalised **malaise, pyrexia** and occasional **cervical lymphadenopathy**.
- The pain is exacerbated by **eating or drinking**.

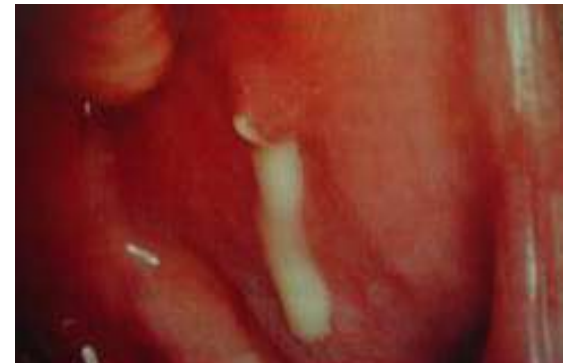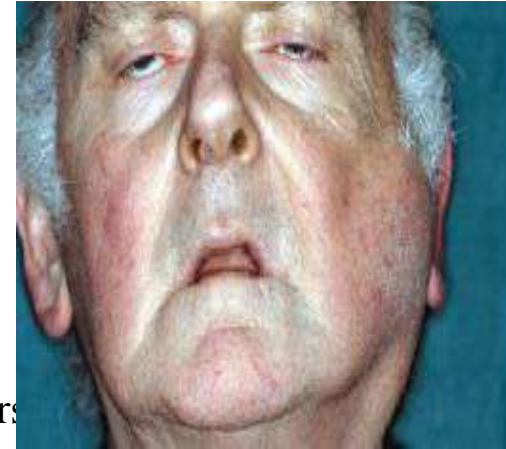The parotid swelling may be diffuse/localises (lower pole of the gland)

Pus may exuding from the parotid gland papilla

Treatment:

- intravenous antibiotics.

abscess □ drainage (large bore needle aspiration / drainage under general anaesthesia.



Stone formation(Sialolithiasis)

- less common in the parotid gland (20 %)
(**submandibular gland** (80 %)).
- Parotid duct stones □ **radiolucent**.
- Diagnosis: Parotid gland sialography.
- Treatment: stone located in the collecting duct or within the gland □ endoscopic retrieval, lithotripsy or rarely parotidectomy.

Tumours of the parotid gland

- The parotid gland is the **most common site** for salivary tumors.
- Most tumors arise in the **superficial lobe**
- 80–90 % of tumours of the parotid gland are **benign**
- the most common is **pleomorphic**
- **Slow growing, painless** swellings below the ear, in front of the ear or in the upper aspect of the neck.
- Rarely, tumours in **deep lobe** □ as **parapharyngeal masses** □ difficulty in swallowing and snoring.

Investigations


- CT and MRI scanning
 - Fine-needle aspiration biopsy
- (open surgical biopsy is contraindicated)
(no enucleation even if a benign lesion is suspected)

Treatment of parotid tumor

Superficial parotidectomy □ for Superficial lobe tumor

Or Radical parotidectomy for highly malignant T.

Complications of parotid gland surgery

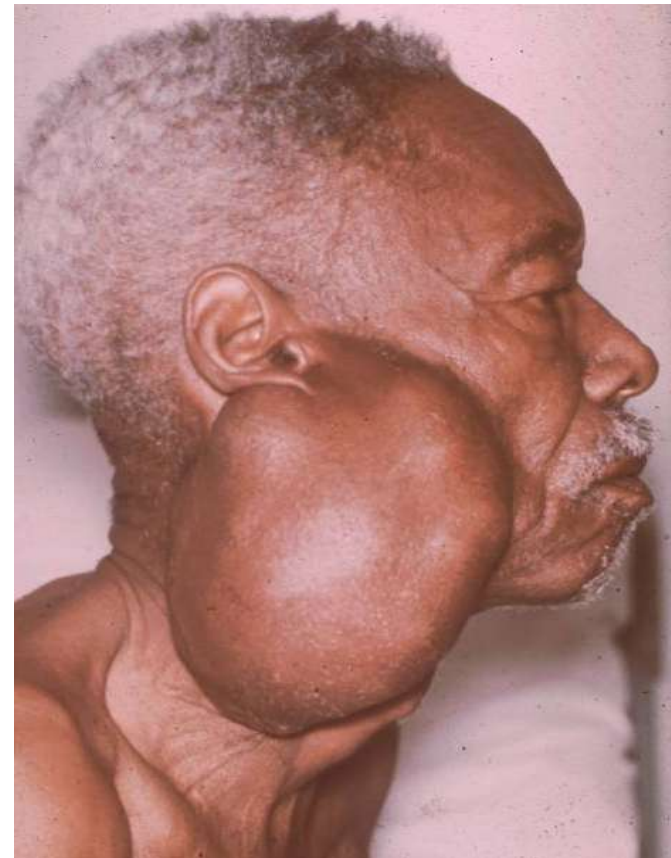- haematoma formation;
 - infection
 - temporary or facial nerve weakness
 - sialocoele
 - facial numbness
 - permanent numbness of the ear lobe associated with great auricular nerve transection;
- 

Pleomorphic adenoma

- ❑ Benign Tumor
- ❑ - **On gross inspection** : tumors is smooth and lobular and demonstrates a well defined capsule

MOST COMMON NEOPLASM IN THE PAROTID GLAND ACCOUNTS FOR 65% OF ALL OF THE PAROTID TUMORS.

- ❑ The most common salivary T.
- ❑ In **middle** aged & more in **woman** than in men,
- ❑ Slowly growing
- ❑ **Treatment** :
Superficial parotidectomy



The Esophagus

Introduction

- Anatomy
- Physiology
- Clinical features
- Investigations
- Diseases of esophagus

Surgical anatomy

- The esophagus is a muscular tube approximately 25 cm long.
- The musculature of the upper 5%, including the upper esophageal sphincter, is striated; the middle 40% has mixed striated and smooth muscle, the distal 55% is entirely smooth muscle.
- The parasympathetic nerve supply is mediated by the vagus.
- There are an upper and lower esophageal sphincters.

Physiology

- The main function of the oesophagus is to transfer food from the mouth to the stomach.
- The initial movement of food from the mouth is voluntary.
- The upper esophageal sphincter is normally closed at rest and serves as :
 1. A protective mechanism against regurgitation of esophageal contents into the respiratory passages.
 2. Also it serves to stop air entering the esophagus.
- The lower esophageal sphincter(LOS) is a physiological sphincter, about 3-4 cm in length and has a pressure of 10-25 mmHg.

- The tone of it is influenced by many things including food, gastric distension, smoking, and GI hormones.
- Its main function is to prevent gastric and duodenal contents from refluxing into the lower esophagus.

Clinical features:

Symptoms

Dysphagia:

Is the term used to describe difficulty, but not necessarily pain, on swallowing.

The type of dysphagia is important; it may be dysphagia for solids or fluids, intermittent or progressive.

Odynophagia

It refers to pain on swallowing.

Regurgitation and reflux

Regurgitation strictly refer to the return of esophageal contents from above an obstruction in the esophagus.

Reflux is the passive return of gastroduodenal contents to the mouth.

Chest pain

Chest pain similar in character to angina pectoris may arise from an esophageal cause.

Other symptoms of esophageal disorders include; loss of wt, anemia, cachaxia, change of voice, and cough.

Investigations

A- Radiography

- 1- Plain X ray; may show opaque foreign bodies.
- 2- Contrast radiography (Barium swallow) is a useful investigation for demonstrating narrowing, space-occupying lesions, anatomical distortion or abnormal motility.

B- Endoscopy

- Is the investigation of first choice for most oesophageal disorders.
- It is either for diagnostic or for therapeutic purposes.
- Diagnosis is by visual inspection of the inside of oesophagus and also by taking a biopsy or cytology specimen.
- For therapy, can be used for;
 - Removal of FB
 - Dilatation of strictures
 - Oesophageal varices

There are two types;

- 1- Rigid oesophagoscopy; which is now virtually obsolete.

Disadvantages:

Needs general anesthesia, difficult to introduce, and carry high risk of perforation

2- Fibre-optic endoscopy

- It has virtually supplanted the rigid instrument.
- It is done under local anesthesia on an out-patient basis, easy to enter, and carry low risk of perforation.

C- Oesophageal manometry

- Is widely used to diagnose esophageal motility disorders.
- Recordings are usually made either by;
 - 1- Multilumen catheter
 - 2- Catheters with solid-state transducer

D- 24-hour PH recording

Prolonged measurement of esophageal pH is now accepted as the most accurate method for the diagnosis of gastro esophageal reflux.

Diseases of the esophagus

Congenital abnormalities

- Atresia and tracheo-oesophageal fistula
- Oesophageal stenosis
- Dysphagia lusoria

Foreign bodies in the oesophagus

- A lot of things may become arrested in the oesophagus such as coins, pins, dentures. The commonest impacted material is food.
- Plain radiographs are the most useful examination.
- Endoscopy is good tool for the dx specially of non-opaque FB.

Treatment:

Flexible endoscopy is now the method of choice and the majority of objects can be extracted with suitable grasping forceps, a snare or a basket.

An impacted food bolus will often break up and pass on if the patient is given fizzy drinks and confined to fluids for a short time

Perforation of the oesophagus

Perforation of the oesophagus is a serious condition that requires prompt diagnosis and treatment

Causes:

A) Barotrauma _ Boerhaave's syndrome

- So-called “spontaneous” perforation of the oesophagus is usually due to severe barotrauma when a person vomits against a closed glottis.
- Usually at the lower third
- The clinical history is of severe pain in the chest or upper abdomen following a meal or a bout of drinking.

B) Pathological perforation

- Perforation of ulcers, such as a Barrett’s ulcer or tumours.
- Penetrating injury
- Foreign bodies
- Instrumental perforation

Diagnosis

- Beware and beware of perforation
- Chest pain
- Subcutaneous emphysema in the neck
- Emphysema around the pericardium can be detected on auscultation as a mediastinal crunch
- Chest XR may show gas in the mediastinum
- Contrast swallow using barium suspension

Treatment

- Prompt dx and treatment is essential for the best results
- There are two options:
 - ✓ Operative
 - ✓ Non-operative

Management options in perforation of the oesophagus:

Factors that favour

Nonoperative

Small septic load
Minimal CV upset
Perforation confined to
Mediastinum
Endoscopic perforation
Perforation of cervical
Oesophagus

Operative

Large septic load
Septic shock
Pleura breached

Boerhaave syndrome
Perforation of abdominal
oesophagus

Nonoperative management

- Analgesia
- Nil by mouth
- Antibiotics
- General supportive care...IV fluids
- When stable...enteral or parenteral nutrition
- Nasogastric tube is not recommended

Operative management

- It involves thoracotomy and repair of the perforation
- This is best done within a few hours of perforation

Corrosive injury

Sodium hydroxide

Sulphuric acid

Drug induced injury

Antibiotic tab

Potassium tab

Type A gastritis :

- Autoimmune Ab against parietal cell
- Gastric atrophy----achlorhydria
- Malabsorption of B12 Pernicious anaemia
- Predispose to gastric cancer

Type B gastritis :

- Due H.P. infection
- Affect the antrum
- Prone to peptic ulceration

Treatment

- Bile chelating or prokinetic agent
- Revisional surgery

•**Erosive gastritis:**

- Caused by agents that disturb the gastric mucosal barrier; like
 - NSAIDs and alcohol.

•**Stress gastritis**

- As a result of serious illness or injury
- May follow cardiopulmonary bypass
- May lead to stress ulceration that may bleed

Treatment

- Prevention; routine use of H2 antagonists, + -mucosal barrier agents like
 - sucralfate

Peptic Ulcer

- - All can be healed by using proton pump inhibitors
 - Can occur in the:
 - 1. 1st part of duodenum,
 - 2. lesser curve of stomach
 - 3. stoma of gastrojejunostomy,
 - 4. oesophagus,
- **causes:**
 - Gastric acid secretion:
 - – In DU usually above normal
 - – In Gu normal
 - – Healing can occur only in the absence of acid
 - • H.pylori infection: is the most important factor
 - • NSAIDs ingestion
 - • Cigarette smoking, predispose to peptic ulcer

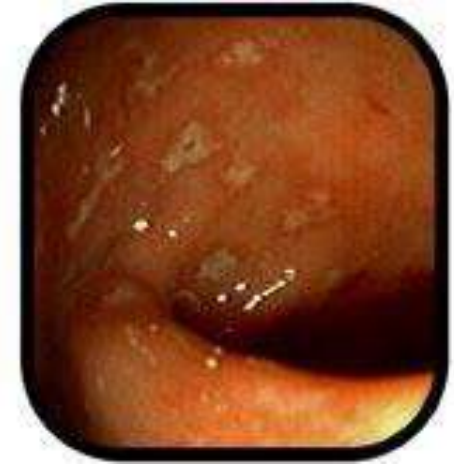Duodenal Ulceration

- **Incidence**

- Seen more in older age with a possibility of
- Bleeding and perforation

- **Pathology:**

- Most common in the 1st part of duodenum
- Penetrates the mucosa and into the muscle
- Healing by fibrosis leaving a narrow lumen



Gastric Ulcers

•Incidence:

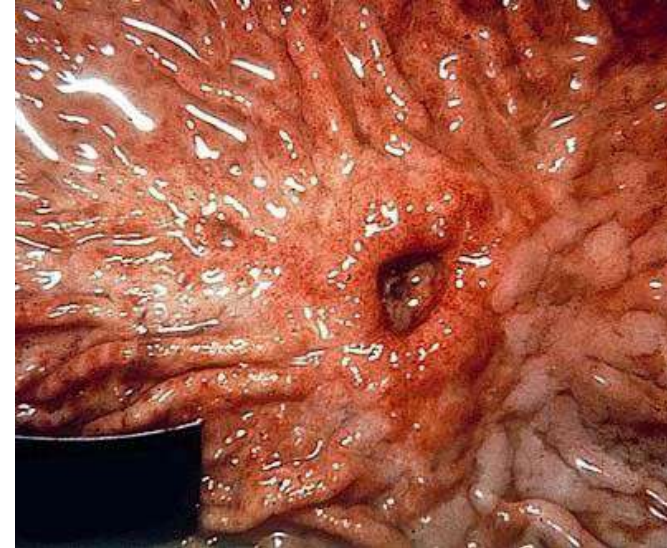
- Less common than DU
- Affected patients are older than DU patients & in low socioeconomic groups

Aetiology:

- H.pylori infection
- NSAIDs
- Smoking

Pathology:

- Similar to that of DU
 - Fibrosis Hour glass deformity
 - Penetration
 - Lesser curve of the stomach



Malignancy in gastric ulcers:

- GU may be associated with or change to gastric malignancy.
Or being malignant gastric ulcer from the start
- All GU should be regarded as being malignant until proved otherwise usually by multiple biopsies as many as 10

Clinical features of peptic ulcers

- **Pain:** epigastric, may radiate to back, eating may relieve the discomfort, intermittent
 - **Periodicity:** intermittent, spring and autumn
- **Vomiting:** indicates stenosis
- **Alteration in weight:** wt loss or gain may occur,,, wt loss more with GU
- **Bleeding:** all may bleed; may be: chronic anaemia
acute presentation with hematemesis and melaena

Clinical examination

- [?] Epigastric tenderness
- Investigation :
 - [?] Gastroduodenoscopy:is Investigation of choice
 - Highly specific and sensitive
- [?] Diagnosis:
 - ~ Visual
 - ~ Biopsy for any abnormal lesion in the stomach
 - ~ Antral biopsy for H.pylori & histology”

Treatment of peptic ulceration :

Medical treatment:

- Proton pump inhibitors; omeprazol, lansoprazole
- Eradication therapy; is now routinely given to patients with peptic ulceration except in patients with :
 - NSAID induced ulcers.
 - Stomal ulcers
 - Zollinger-Ellison syndrome

Protocol for GU :

- Dx of benign ulcer must be confirmed by Biopsy
- Give Medical treatment
- Endoscopic checking to ensure complete healing of the ulcer 6-8 wks later If un-healed
-----Surgery

•Operations for gastric ulcer :

- Vagotomy, pyloroplasty and ulcer excision

• **Perforated peptic ulcer**

Increase in the incidence in females & also with age.

Clinical features:

- History of peptic ulceration
- Sudden onset of severe generalised abdominal pain
- Avoid movement
- May be shocked with tachycardia
- The abdomen does not move with respiration

• **Clinical features:**

- History of peptic ulceration
- Sudden onset of severe generalised abdominal pain
- Avoid movement
- May be shocked with tachycardia
- The abdomen does not move with respiration
- Board like rigidity

Investigations:

- Erect plain chest radiograph
Air under the diaphragm in about 50 –70 % of cases
- Serum amylase
- Ct scan for both perforated DU and pancreatitis
- Water soluble contrast swallow --free peritoneal leak
- lavageDiagnostic peritoneal

Treatment:

- Resuscitation
- Analgesia
- Surgery
 - Laparotomy
 - Laparoscopy
 - Peritoneal toilet
 - Closure of perforation

Salivary Glands

Dr. SIDDEEK BAKR MARIE

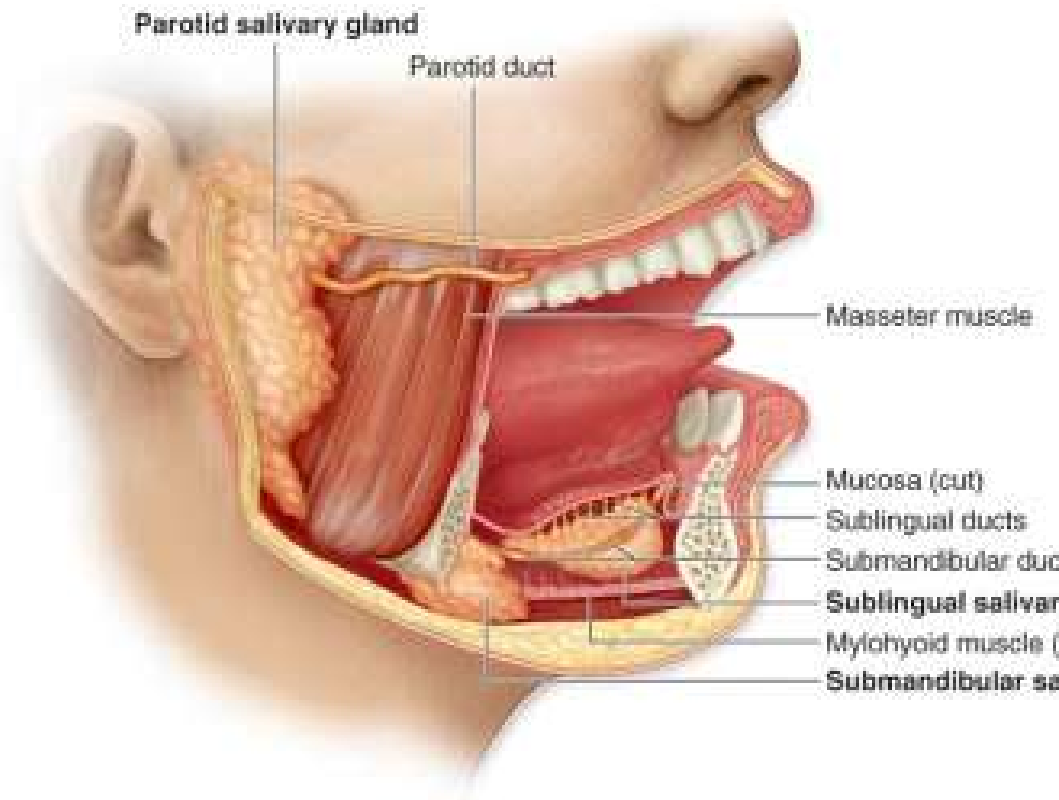
M.B;Ch.B. C.A.B.S.

Specialist General surgeon & Consultant Urologist



Anatomy of salivary glands

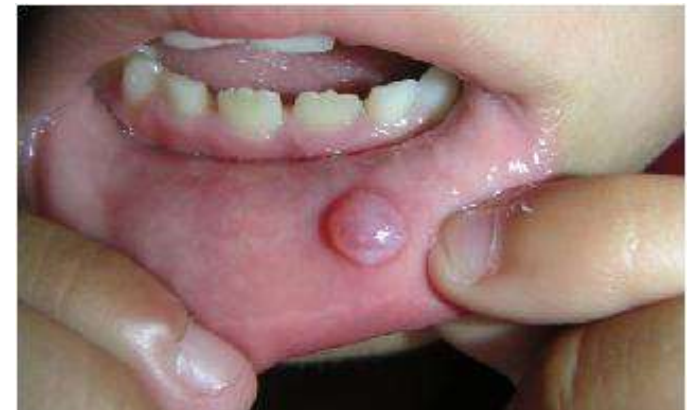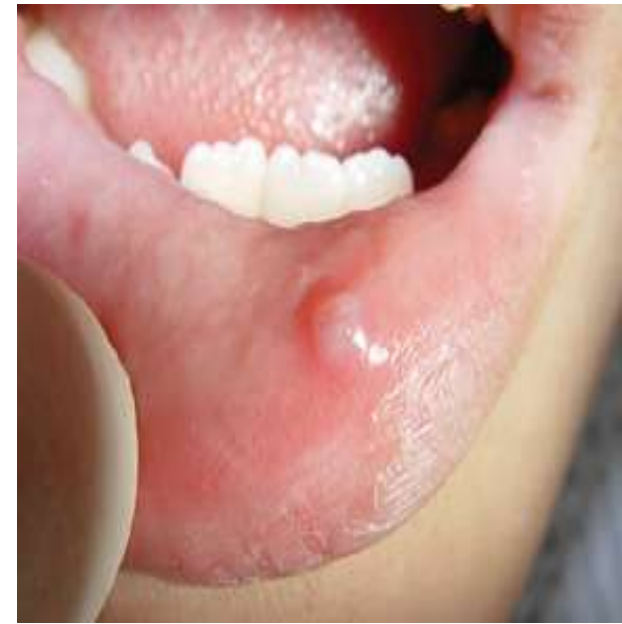- ❑ Two submandibular glands
- ❑ Two parotid glands
- ❑ Two sublingual glands
- ❑ Approximately 450 minor salivary glands



Common disorders of minor salivary glands

1- Extravasation Cysts

- Common
- trauma to the overlying mucosa.
- affect lower lip → producing **painless** swelling and usually **translucent**.
- **resolve spontaneously**
- most require **formal surgical excision** +overlying mucosa +underlying minor salivary gland.
- Recurrence is rare.



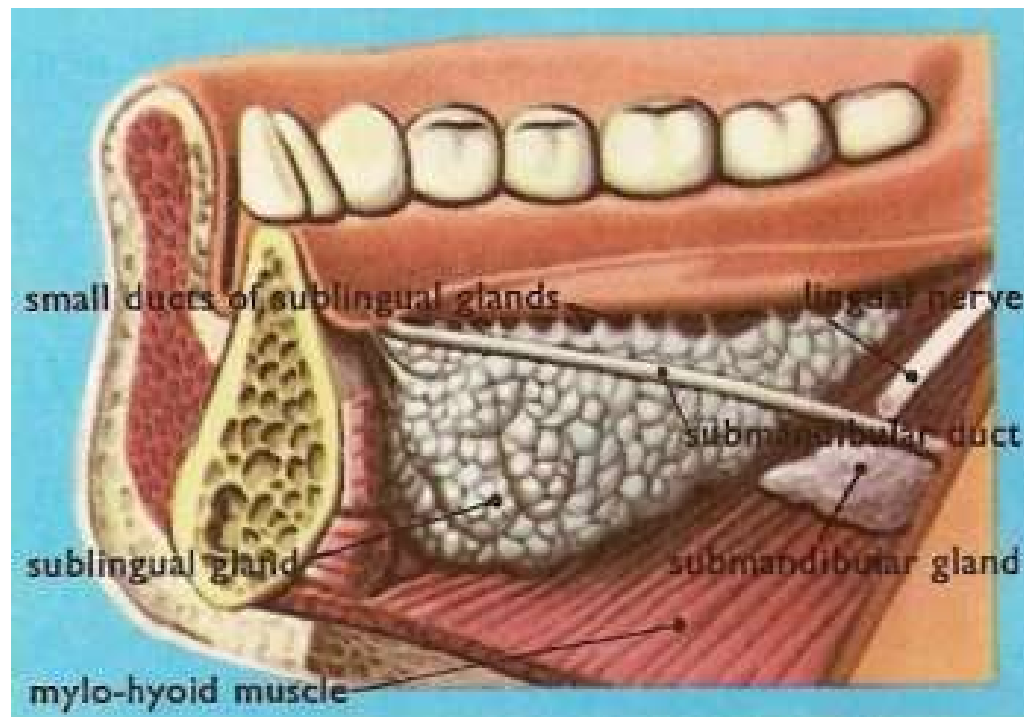
Tumours of minor salivary glands

- ⊠ 90 % malignant.
- ⊠ common sites : upper lip, palate and retromolar regions.

Benign minor salivary gland tumors present as **painless, firm, slow-growing** swellings. Overlying **ulceration** is extremely rare.

- ⊠ Treatment: excision of the tumor +overlying mucosa+ primary closure

Sublingual Salivary Gland

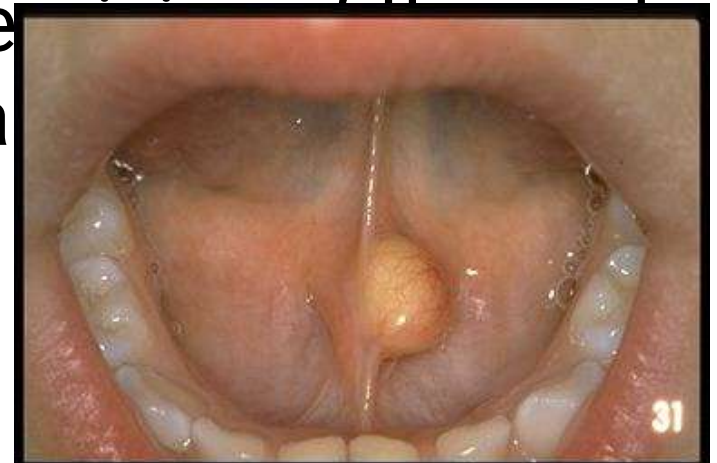


Common disorders of the sublingual glands

1- Cysts(ranula)

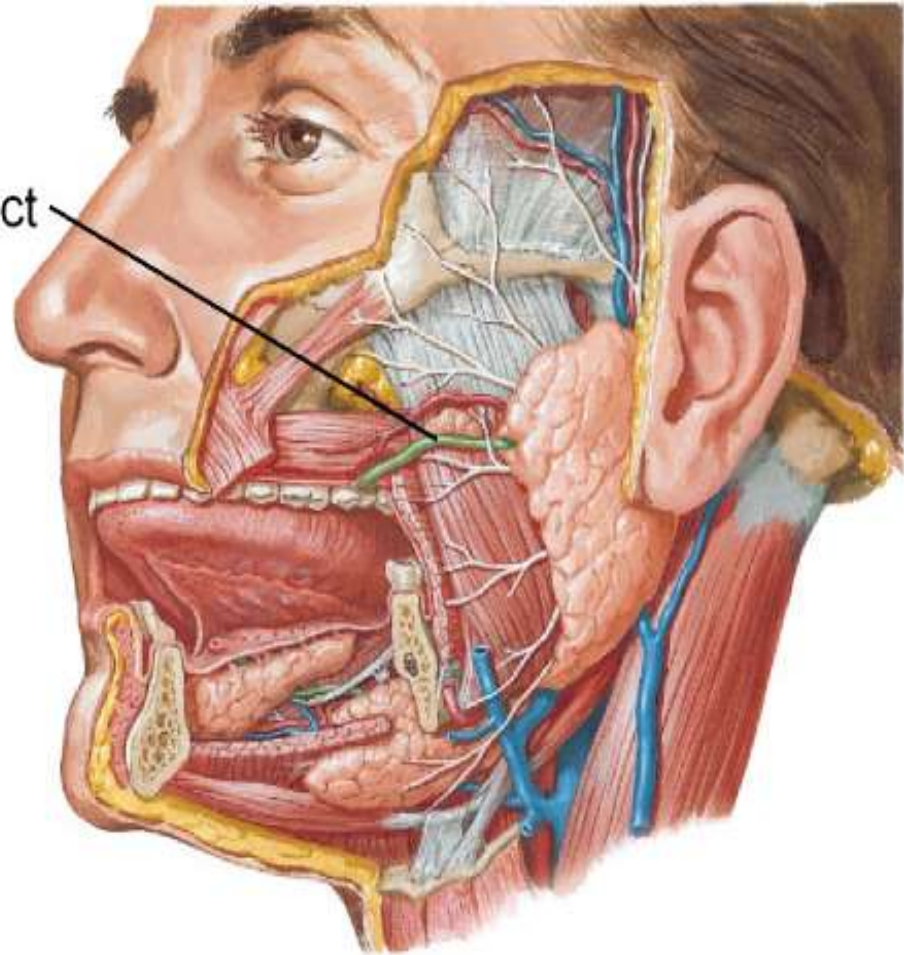
mucous extravasation cyst that arises from a sublingual gland.

- translucent swelling 'frog's belly' .
- resolve spontaneously.
- many require formal surgical excision of the cyst and the affected sublingual gland





Parotid duct



Inflammatory disorders of the submandibular gland(sialadenitis)

acute, chronic or acute on chronic.

Common causes are:

Acute submandibular sialadenitis:

1- Bacterial sialadenitis

more common than viral sialadenitis

- secondary to obstruction.
- antibiotics, if chronically inflamed → formal excision.

2- Viral. The paramyxovirus (mumps)

Usually parotitis.

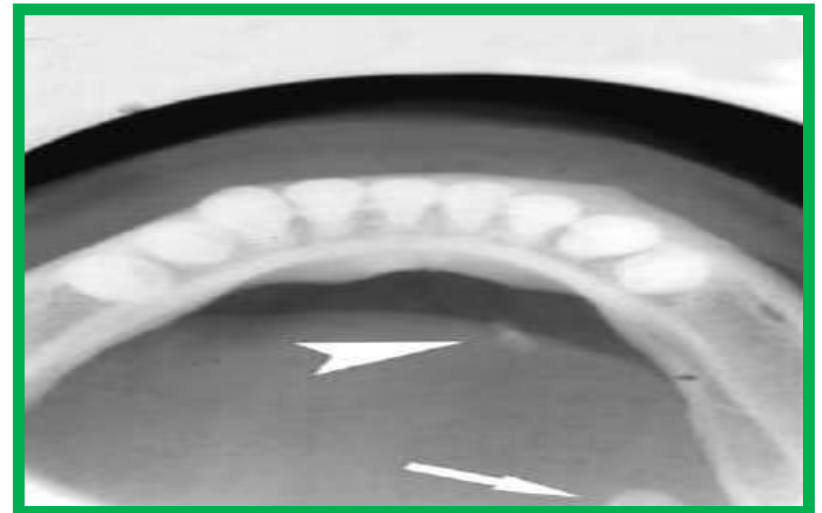painful tender swollen glands.

Obstruction and trauma to submandibular gland

Stone formation (sialolithiasis): most common cause of obstruction within the submandibular gland is within the gland and duct system.

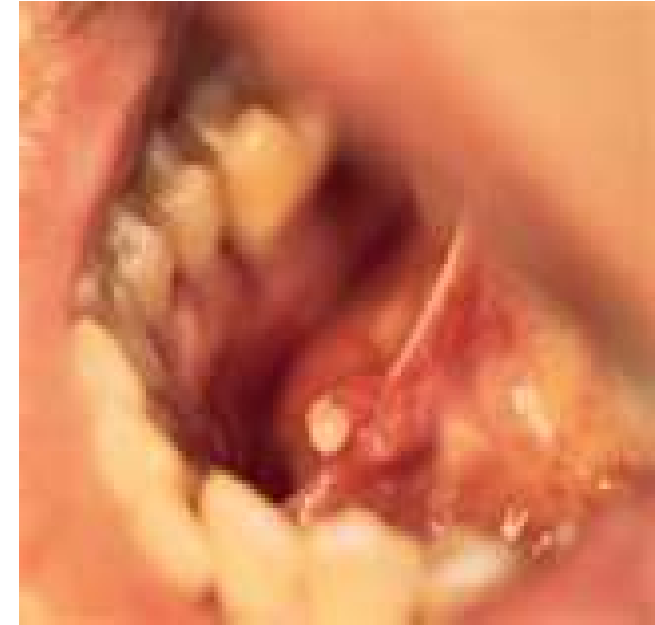80% of all salivary stones occur in the **submandibular** glands because highly viscous secretions .

80% submandibular stones are **radio-opaque**

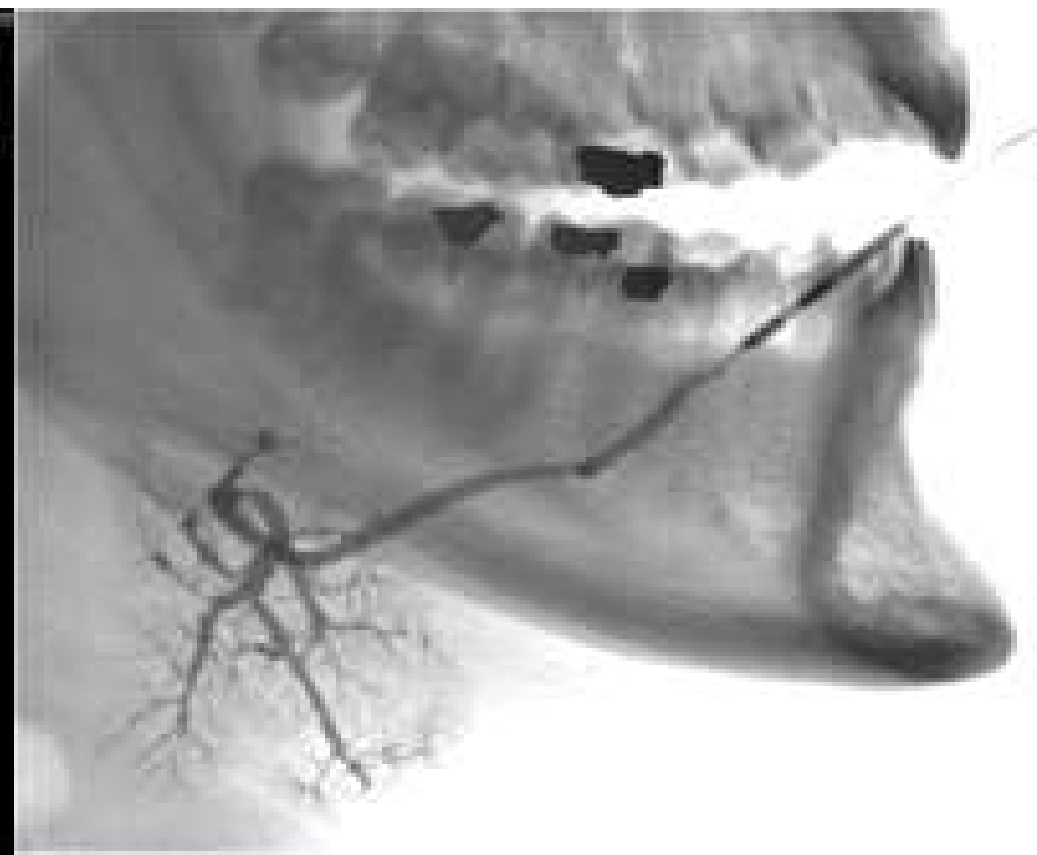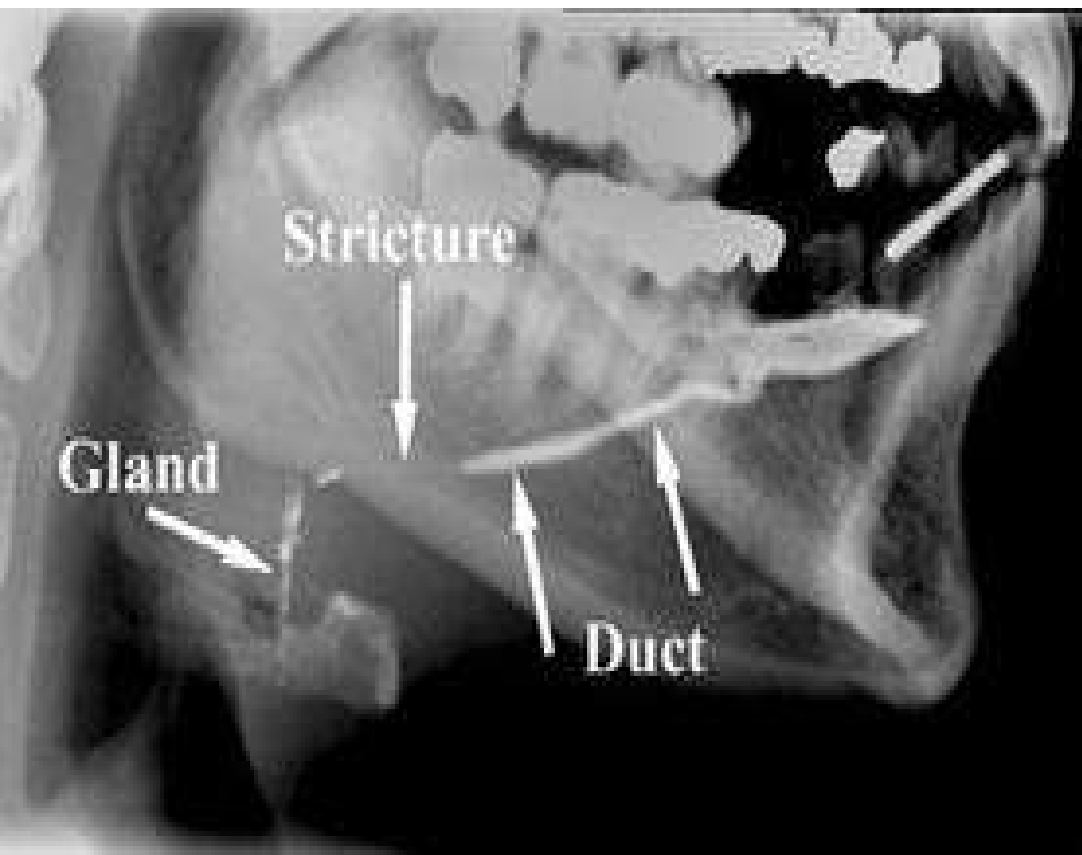


Clinical symptoms

- ⊠ acute painful swelling in the region of the submandibular gland
- ⊠ precipitated by eating
- **completely obstruct(less common)** opening of the submandibular duct → swelling develop rapidly → 1–2 hours after the meal resolves spontaneously
- ⊠ **partial obstruction(more common)** (hilum of the gland or within duct in the floor of the mouth) →
 - infrequent symptoms
 - minimal discomfort and swelling
 - not confined to mealtimes.
 - examination → enlarged firm submandibular gland, tender on bimanual examination.
- Pus from the sublingual papilla .



sialogram



Management

incising over the duct+stone delivered+ leave the wall of the duct

endoscopic retrieval of stone,
lithotripsy(sialadenoscope)

Investigation

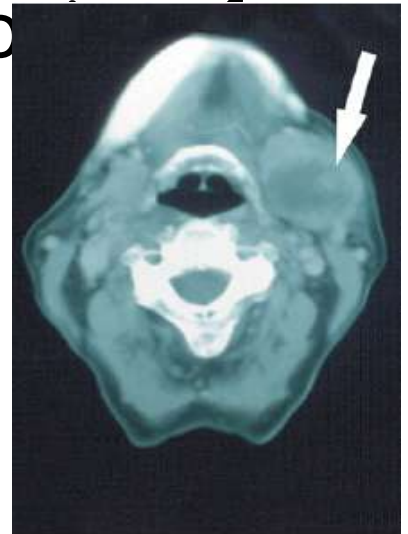
1-Computed tomography (CT) and MRI scanning showing

the extension, circumscribed (benign, or diffuse, invasive and probably malignant).

2- Biopsy

Open surgical biopsy is contraindicated as this may seed the tumour into surrounding tissues, making it impossible to eradicate microscopic deposits of tumour cells.

Fine-needle aspiration biopsy
no risk of seeding viable



Management of submandibular gland tumours

surgical excision with a cuff of normal tissue is the goal.

- Small tumor+ localised (entirely within the submandibular gland parenchyma)**
→ intracapsular submandibular gland excision is to be done.


the parotid

Inflammatory disorders

Viral infections

Mumps (most common)

- acute painful parotid swelling
- Mostly affects children.
- spread by airborne droplets .
- 1–2 days fever, nausea and headache
- → pain and swelling in parotid glands.
- pain → very severe and exacerbated by eating and drinking.
- Symptoms resolve within 5–10 days.
- **Treatment** : regular paracetamol + adequate oral fluid intake.
- **Complications**
orchitis, oophoritis, pancreatitis.



Bacterial infections

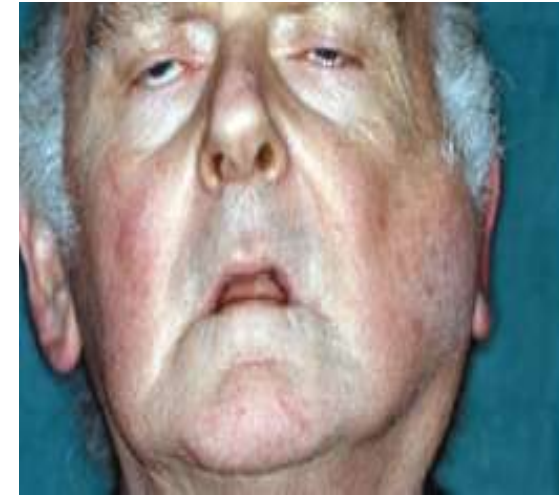Acute ascending bacterial sialadenitis

dehydrated elderly patients following major surgery

→ Reduced salivary flow → ascending infection.

- *Staphylococcus aureus* / *Streptococcus viridans*
- presentation → **tender, painful parotid swelling** that arises over several hours .
- generalised **malaise, pyrexia** and occasional **cervical lymphadenopathy**.
- The pain is exacerbated by **eating or drinking**.

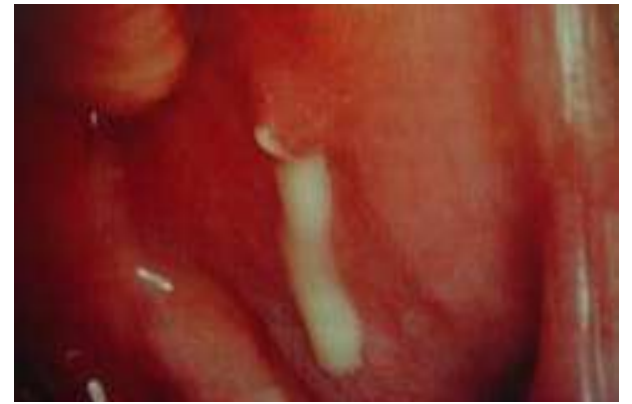Pus may exuding from the parotid gland papilla




Treatment:

- intravenous antibiotics.

abscess → drainage (large bore needle aspiration / drainage under general anaesthesia.



Tumours of the parotid gland

- The parotid gland is the **most common site** for salivary tumors.
 - Most tumors arise in the **superficial lobe**
 - 80–90 % of tumours of the parotid gland are **benign**
 - the most common is **pleomorphic**
 - **Slow growing, painless** swellings below the ear, in front of the ear or in the upper aspect of the neck.
- 

Investigations

- ⌘ CT and MRI scanning
 - ⌘ Fine-needle aspiration biopsy
- (open surgical biopsy is contraindicated)
(no enucleation even if a benign lesion is suspected)

Treatment of parotid tumor

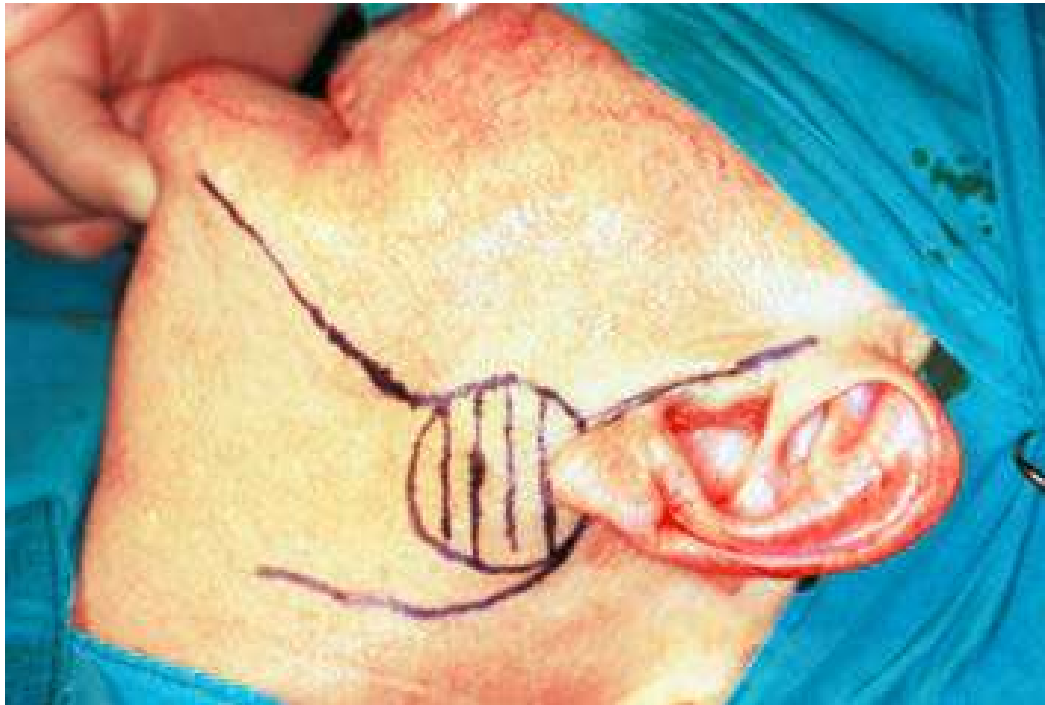
Superficial parotidectomy → for Superficial lobe tumor

The aim of superficial parotidectomy is to remove the tumor with a cuff of normal surrounding tissue.

Low-grade malignant tumours → superficial parotidectomy.

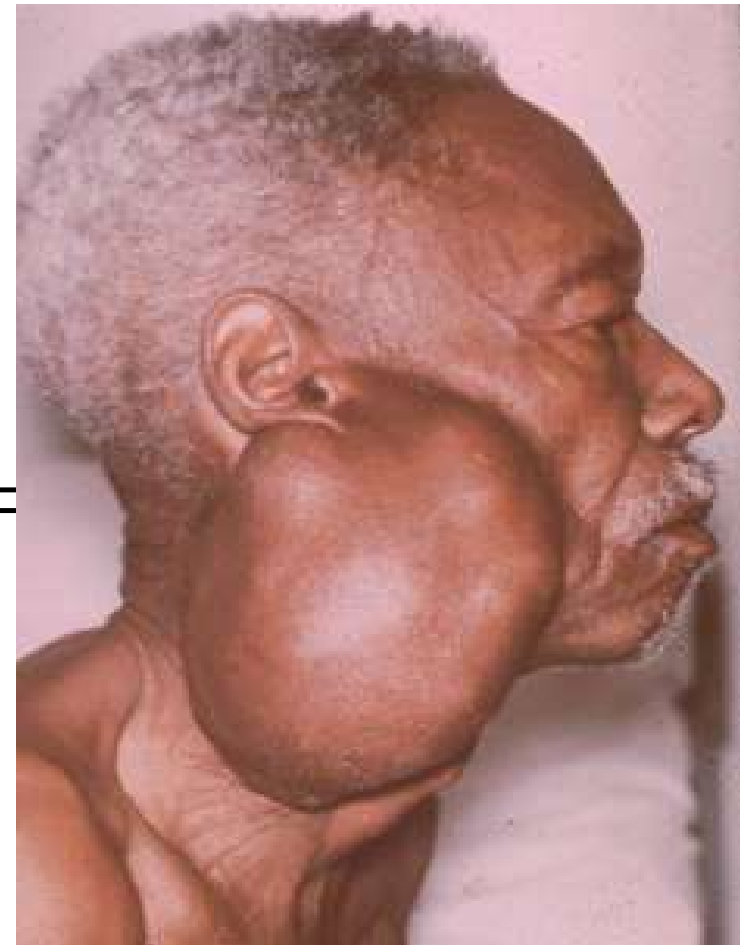

incision for parotid

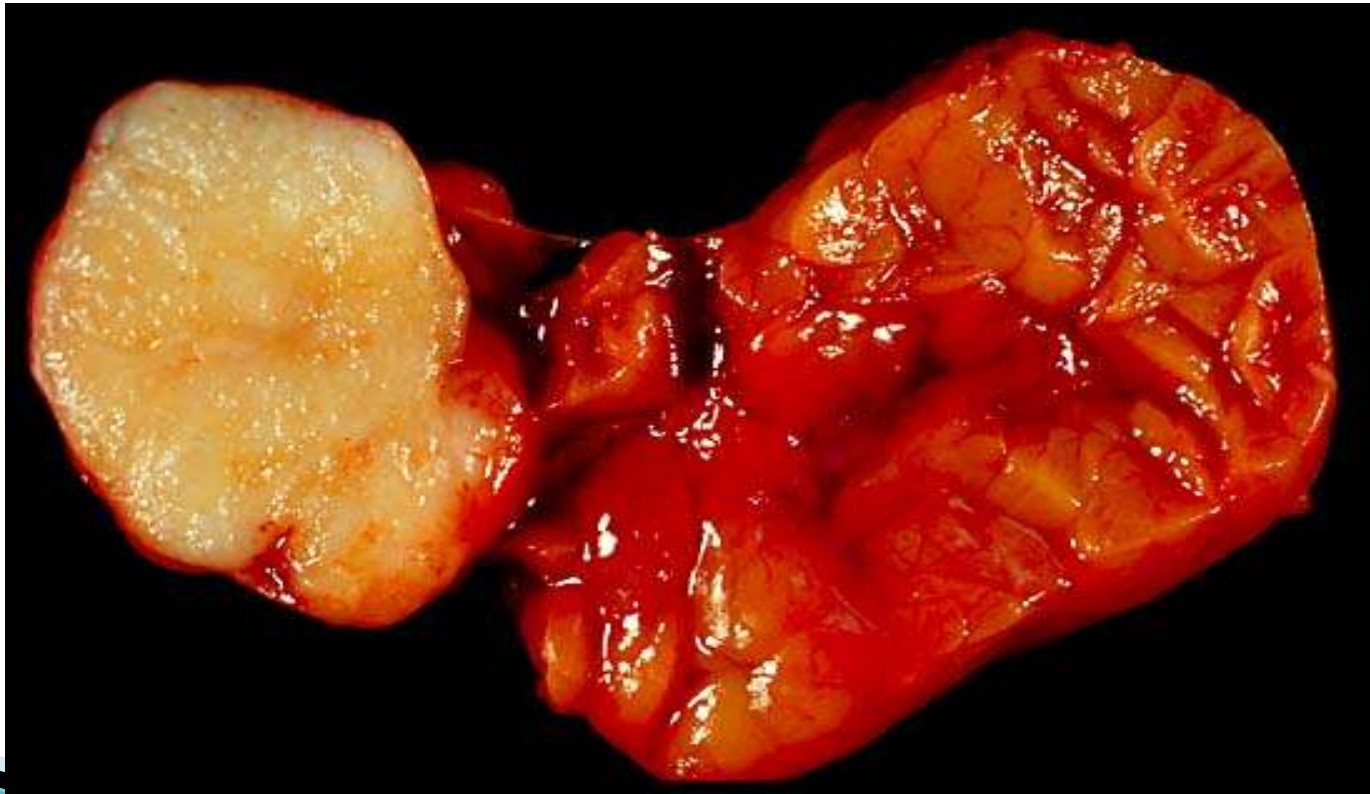

Pleomorphic adenoma

- ⌘ Benign Tumor
- ⌘ - **On gross inspection** : tumors is smooth and lobular and demonstrates a well defined capsule
- MOST COMMON NEOPLASM IN THE PAROTID GLAND ACCOUNTS FOR 65% OF ALL OF THE PAROTID TUMORS.
- ⌘ The most common salivary T.
- ⌘ In **middle** aged & more in **woman** than in men,
- ⌘ **Slowly** growing




☒ Pleomorphic Adenoma



Treatment :

Superficial parotidectomy

- ⌘ WIDE RESECTION OF THE TUMOR
 - ⌘ AVOID SHELLING OUT THE LESION
 - ⌘ RECURRENCE: PRIMARY DUE TO INADEQUATE RESECTION
 - ⌘ LESIONS ARE MORE AGGRESSIVE WHEN THEY RECUR
- 

WARTHIN'S TUMOR (ADENOLYMPHOMA)

- ⌘ SECOND MOST COMMON PAROTID TUMOR
- ⌘ MALE : FEMALE 5 : 1
- ⌘ BILATERAL 10%
- ⌘ May (MULTICENTRICITY).
- ⌘ TREATMENT: superficial parotidectomy
- ⌘ 90% CURED WITH RESECTION
- ⌘ 10% RECUR DUE TO MULTICENTRICITY OR INADEQUATE RESECTION

The digestive system

د. صديق بكر مرعي

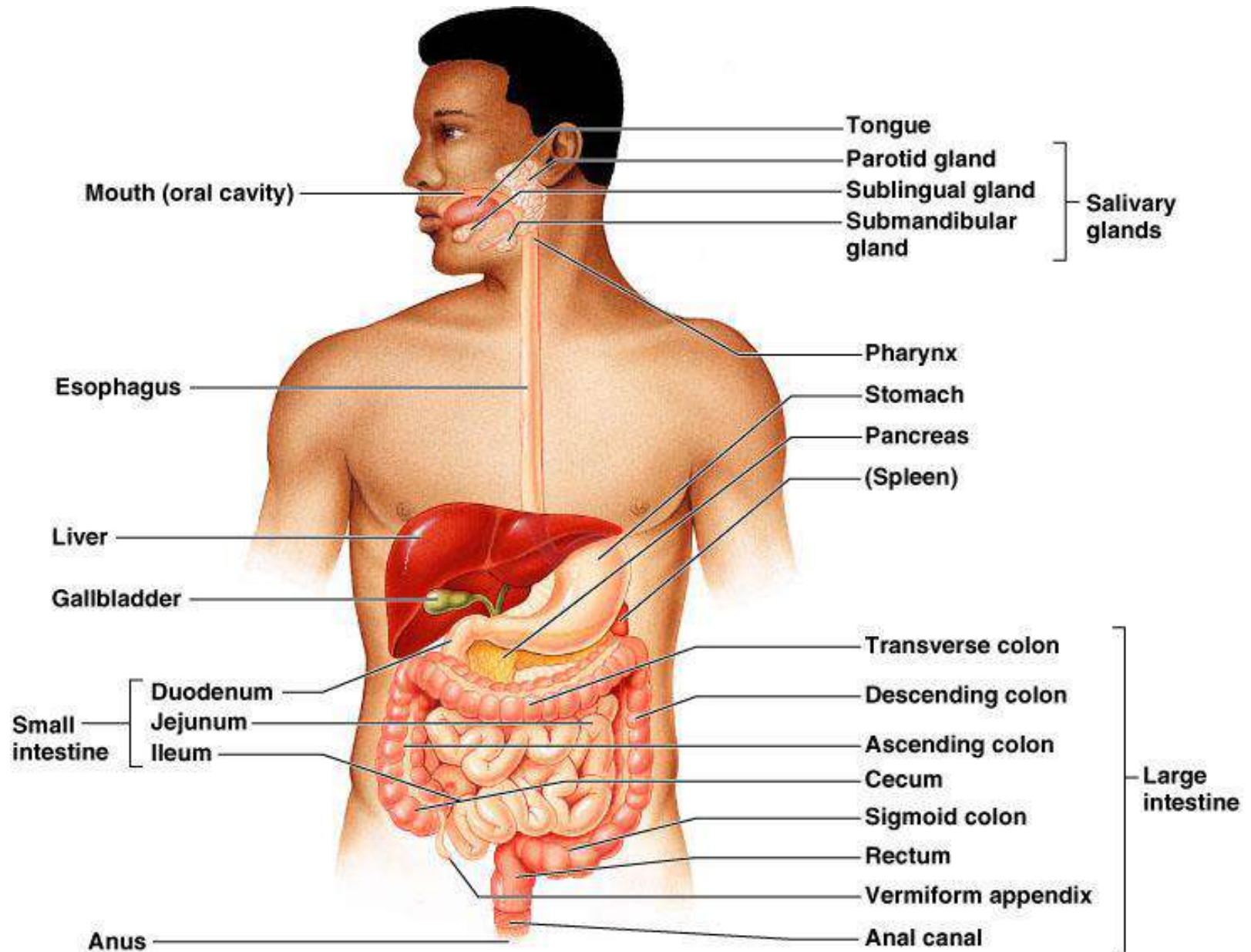
دكتوراه في الجراحة العامة

استشاري جراحة المسالك البولية

Digestive System: Overview

- The **alimentary canal** or **gastrointestinal (GI) tract** digests and absorbs food
- Alimentary canal – mouth, pharynx, esophagus, stomach, small intestine, and large intestine
- Accessory digestive organs – teeth, tongue, gallbladder, salivary glands, liver, and pancreas

Digestive System: Overview



Digestive Process

The GI tract is a “disassembly” line:

- Nutrients become more available to the body in each step

There are six essential activities:

- 1) Ingestion, 2) propulsion, and 3) mechanical digestion
- 4) Chemical digestion, 5) absorption, and 6) defecation

Digestive Process

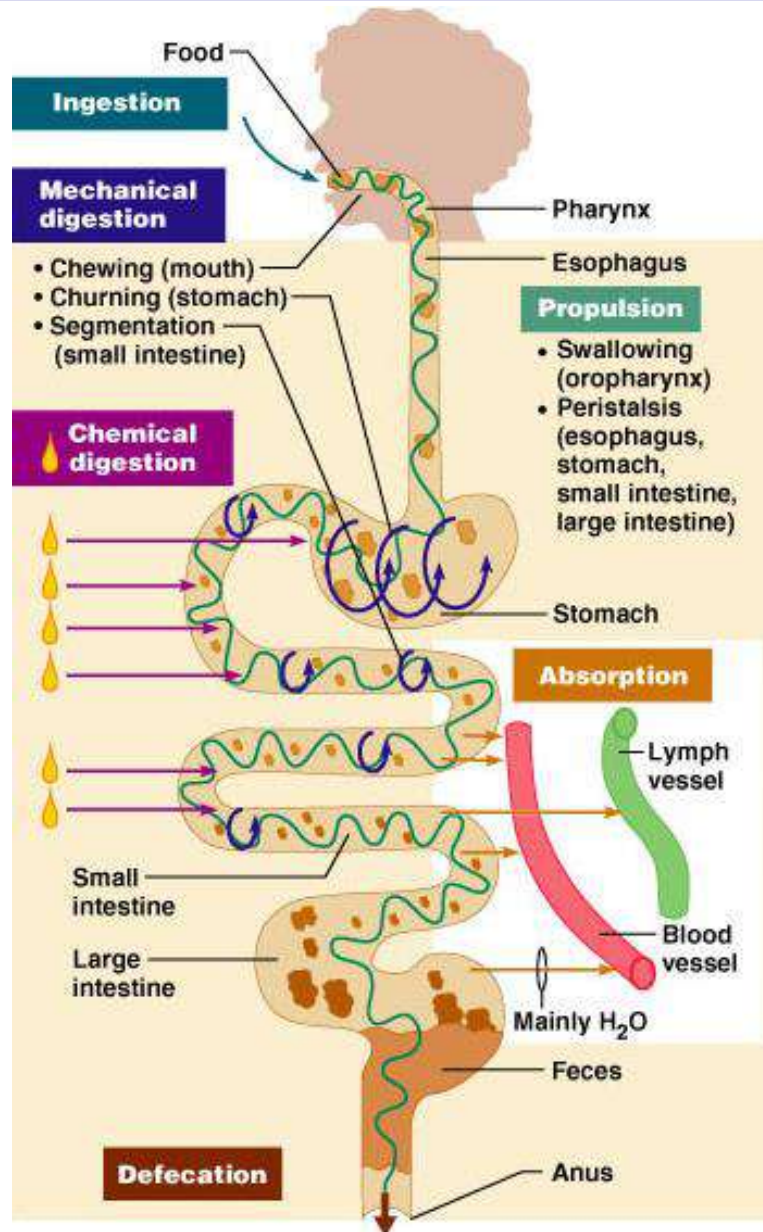


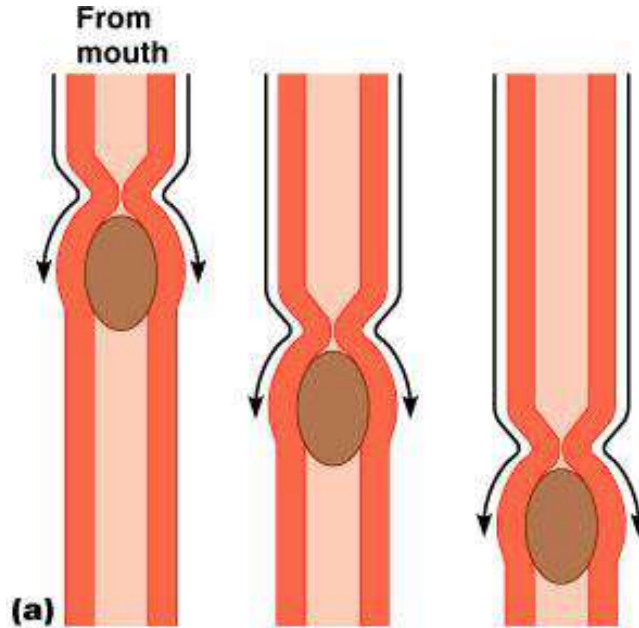
Figure 23.2

Gastrointestinal Tract Activities

- **1) Ingestion** – taking food into the digestive tract
- **2) Propulsion** – swallowing and peristalsis
 - **Peristalsis** – waves of contraction and relaxation of muscles in the organ walls
- **3) Mechanical digestion** – chewing, mixing, and churning food

Peristalsis and Segmentation

Esophagus



Intestine

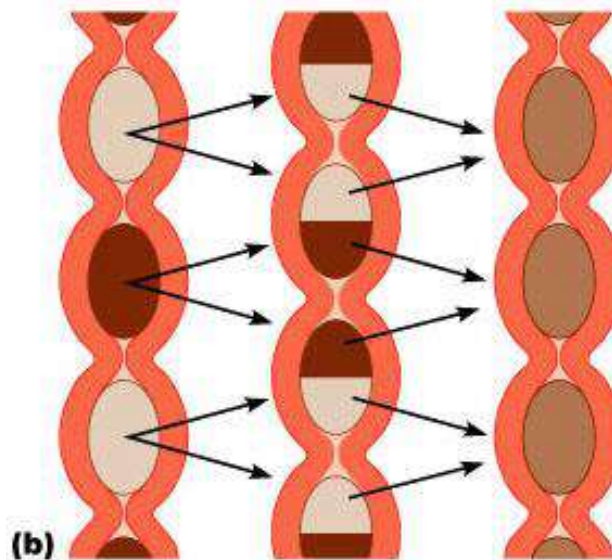


Figure 23.3

Gastrointestinal Tract Activities

- **4) Chemical digestion** – catabolic breakdown of food
- **5) Absorption** – movement of nutrients from the GI tract to the blood or lymph
- **6) Defecation** – elimination of indigestible and unabsorbed solid wastes

Peritoneum and Peritoneal Cavity

Peritoneum – serous membrane of the abdominal cavity

- Visceral peritoneum – covers external surface of most digestive organs
- Parietal peritoneum – lines the body wall

Peritoneal cavity

- Lubricates digestive organs
- Allows them to slide across one another

Mesentery – double layer of peritoneum that provides:

- Vascular and nerve supplies to the viscera
- A means to hold digestive organs in place and store fat

Blood Supply: Splanchnic Circulation

Arteries and the organs they serve include:

- The hepatic, splenic, and left gastric: spleen, liver, and stomach
- Inferior mesenteric and superior mesenteric: small and large intestines

Hepatic portal circulation:

- Collects nutrient-rich venous blood from the digestive viscera
- Delivers this blood to the liver for metabolic processing and storage

Mouth

Oral or buccal cavity:

- Is bounded by lips, cheeks, palate, and tongue
- Has the oral orifice as its anterior opening
- Is continuous with the oropharynx posteriorly

Mouth

1. **cheeks**
2. **lips** (labia), **labial frenulum** (attach to gums)
3. **hard palate** - anterior part of roof of mouth (palatine bones)
4. **soft palate** - posterior of roof of mouth (mucous membrane)
5. **uvula** - hanging portion of soft palate (punching bag)
6. **palatoglossal arch & palatopharyngeal arch**
 - a. palatine tonsils between arches

Anatomy of the Oral Cavity: Mouth

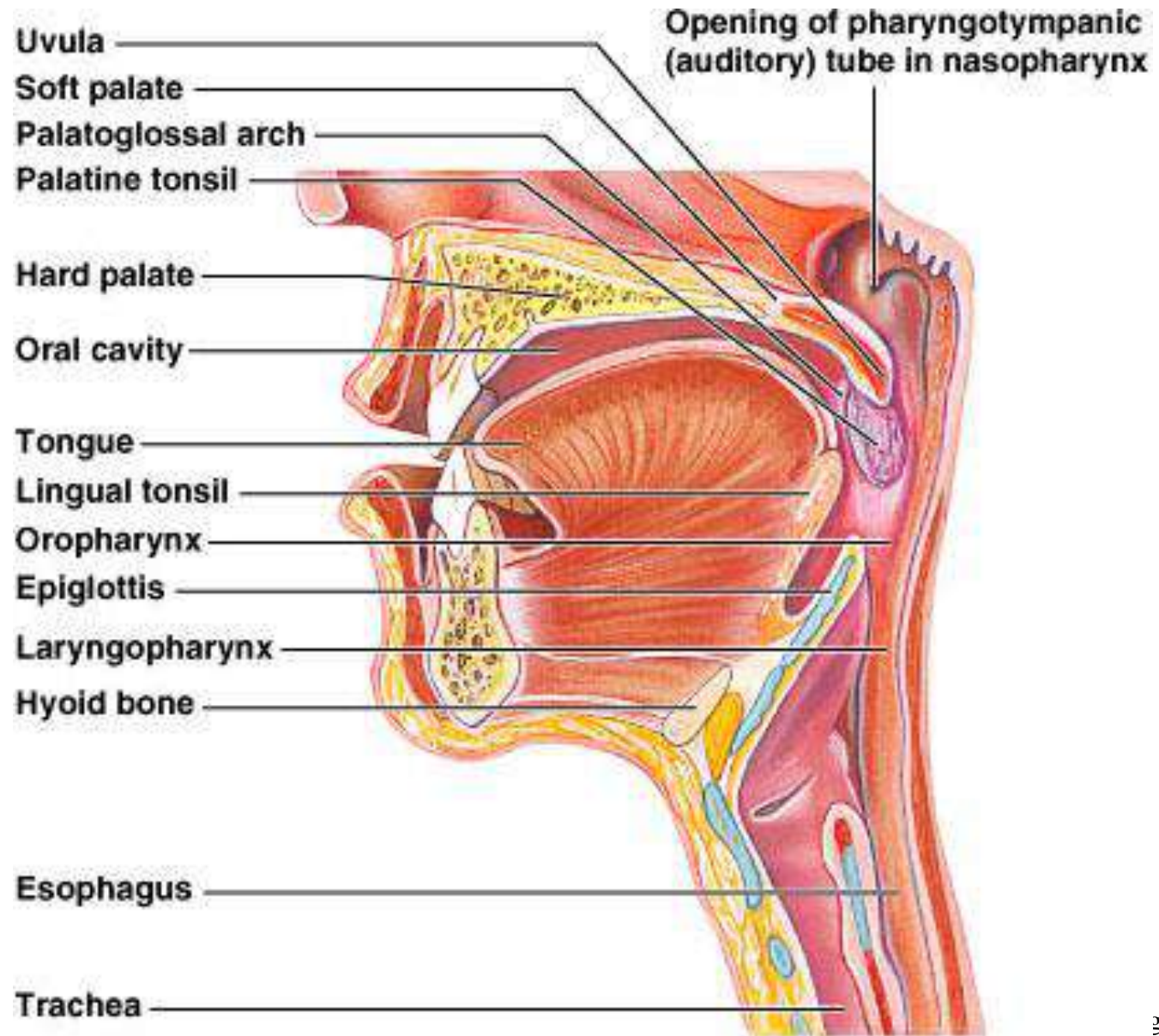


Figure 23.7a

Oral Cavity and Pharynx: Anterior View

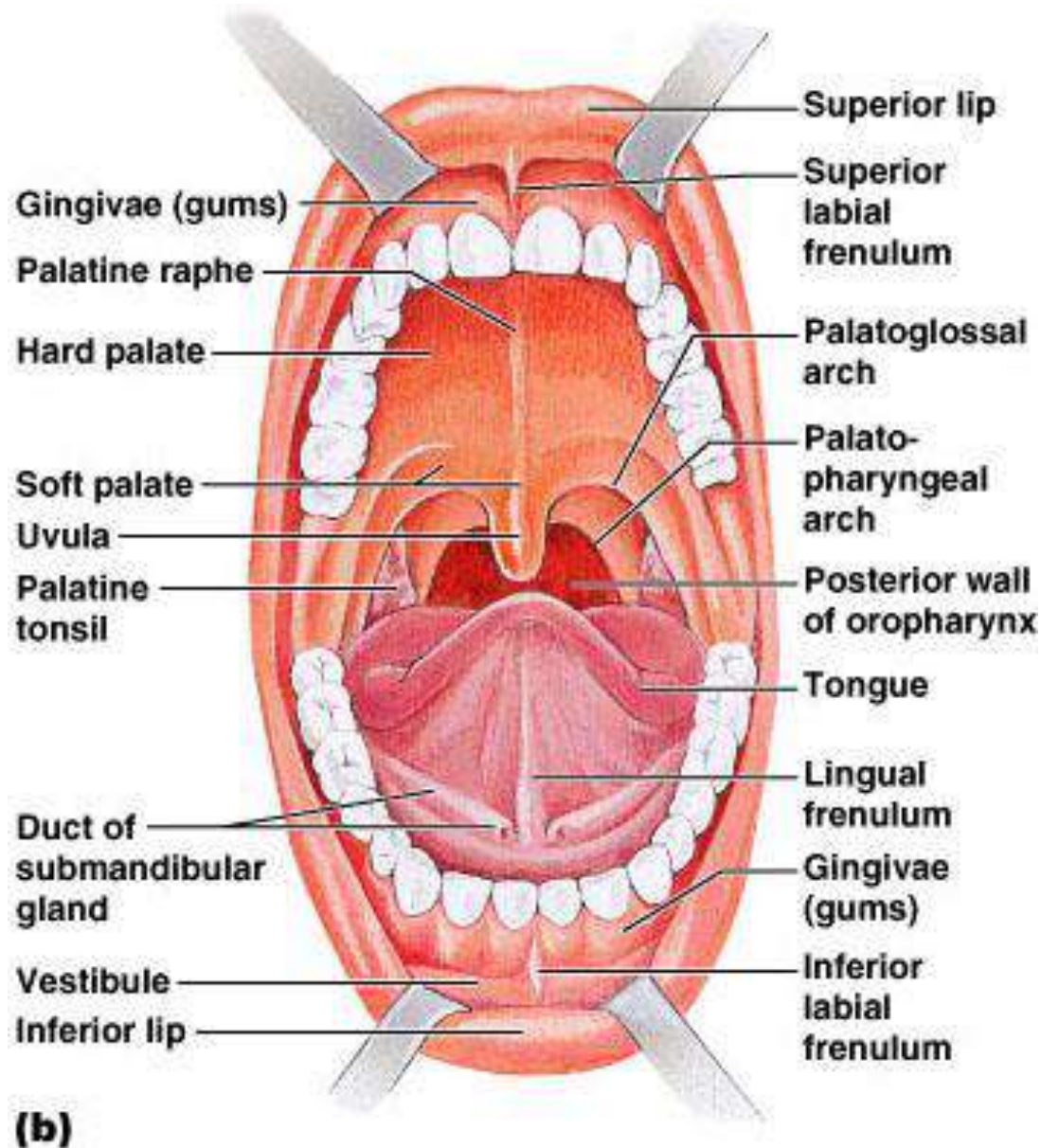


Figure 23.7b

Tongue

Functions include:

- Gripping and repositioning food during chewing
- Mixing food with saliva and forming the bolus
- Initiation of swallowing, and speech

Note: **Lingual frenulum** secures the tongue to the floor of the mouth

Salivary Glands

- Parotid – lies anterior to the ear between the masseter muscle and skin
 - Parotid duct – opens into the vestibule next to the second upper molar
- Submandibular – lies along the medial aspect of the mandibular body
- Sublingual – lies anterior to the submandibular gland under the tongue

Salivary Glands

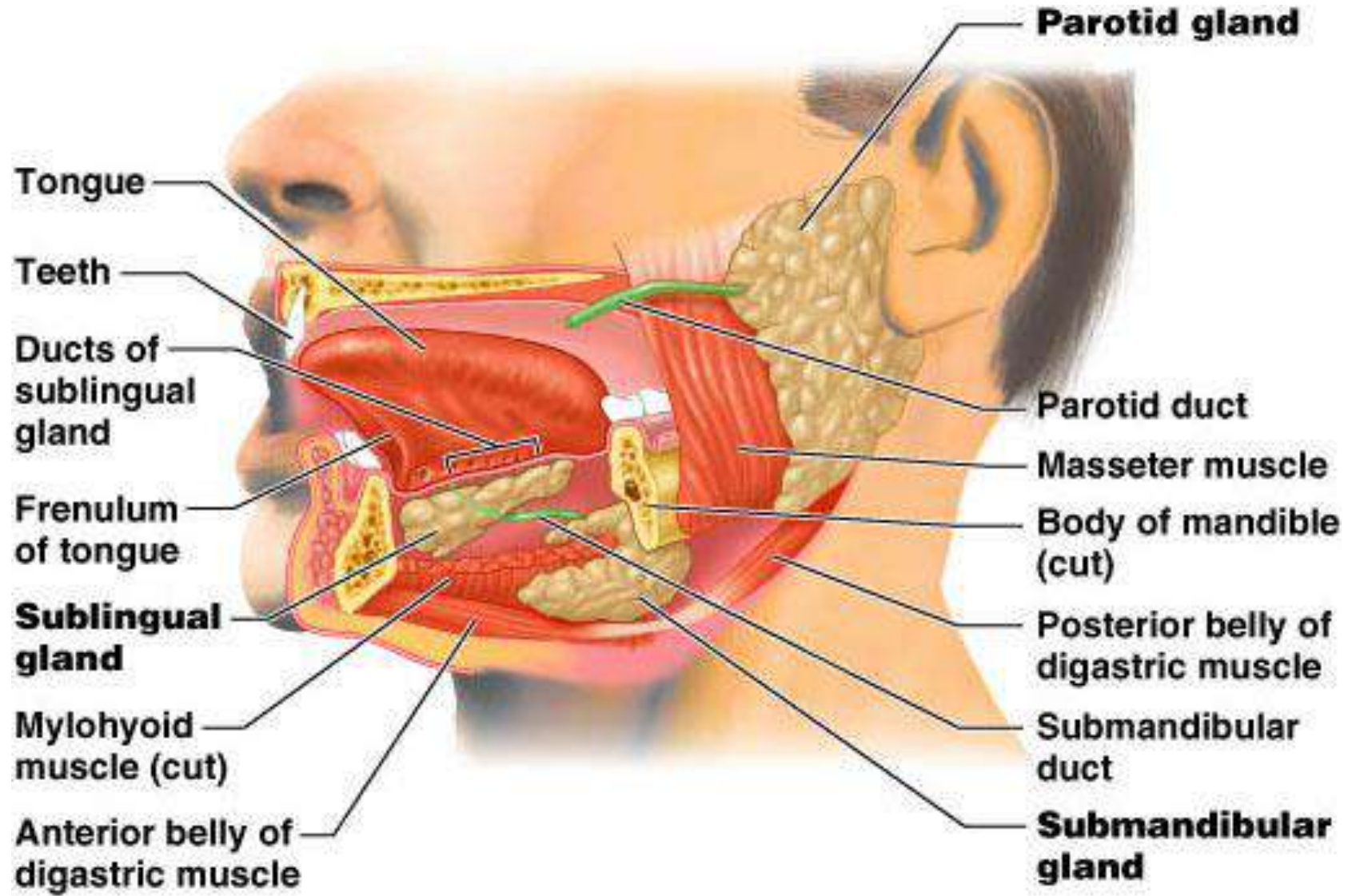


Figure 23.9a

Permanent Teeth

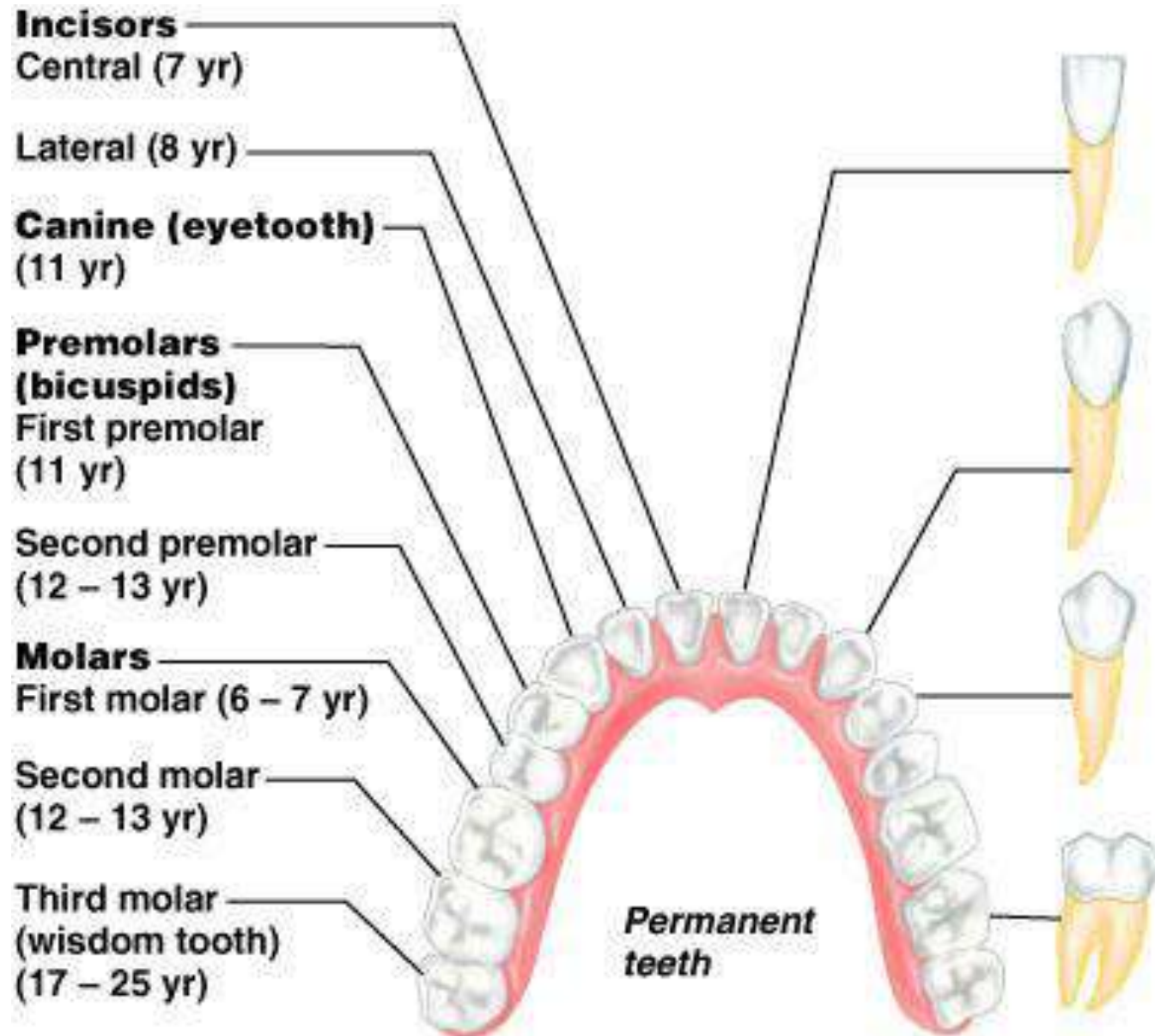


Figure 23.10.2

Classification of Teeth

Teeth are classified according to their shape and function:

- Incisors – chisel-shaped teeth adapted for cutting or nipping
- Canines – conical or fanglike teeth that tear or pierce
- Premolars (**bicuspids**) and molars – have broad crowns with rounded tips and are best suited for grinding or crushing
- During chewing, upper and lower molars lock together generating crushing force

Esophagus

- Muscular tube going from the **laryngopharynx** to the **stomach**
- Travels through the mediastinum and pierces the diaphragm
- Joins the stomach at the **cardiac orifice**

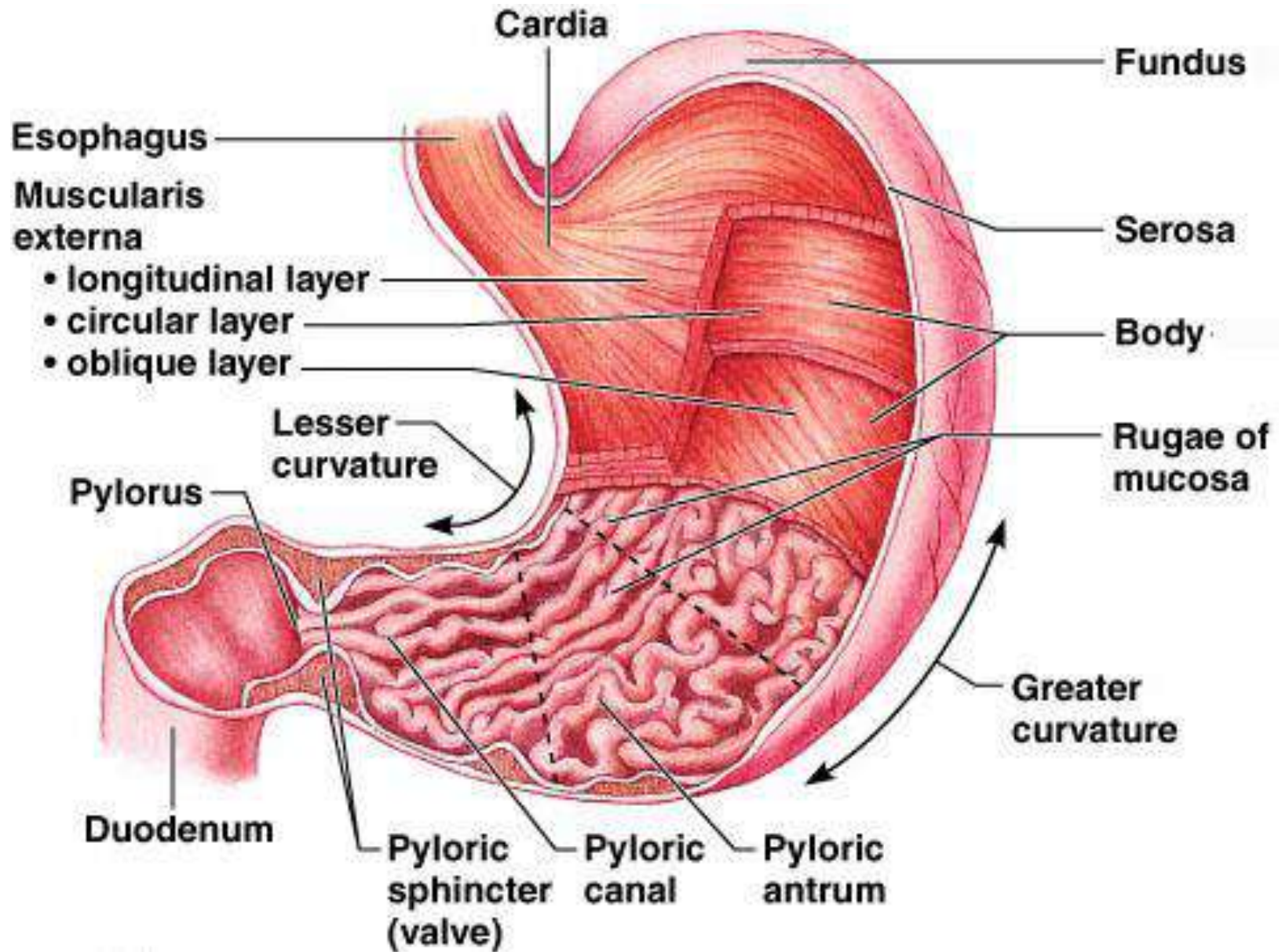
Stomach

- Chemical breakdown of proteins begins and food is converted to **chyme**
- **Cardiac region** – surrounds the cardiac orifice
- **Fundus** – dome-shaped region beneath the diaphragm
- **Body** – midportion of the stomach
- **Pyloric region** – made up of the antrum and canal which terminates at the pylorus
 - The pylorus is continuous with the duodenum through the **pyloric sphincter**

Stomach

- **Greater curvature** – entire extent of the convex lateral surface
- **Lesser curvature** – concave medial surface
- **Lesser omentum** – runs from the liver to the lesser curvature
- **Greater omentum** – drapes inferiorly from the greater curvature to the small intestine
- **Rugae** - folds in the inner lining of the stomach

Stomach



Stomach

- **Blood supply** – **celiac trunk**, and corresponding veins (part of the hepatic portal system)

Gastric glands of the fundus and body have a variety of secretory cells

- **Mucous neck cells** – secrete acid mucus
- **Parietal cells** – secrete HCl

Small Intestine: Gross Anatomy

- Runs from **pyloric sphincter** to the **ileocecal valve**
- The **bile duct** and main **pancreatic duct** join the duodenum at the **hepatopancreatic ampulla**
- The ileum joins the large intestine at the **ileocecal valve**

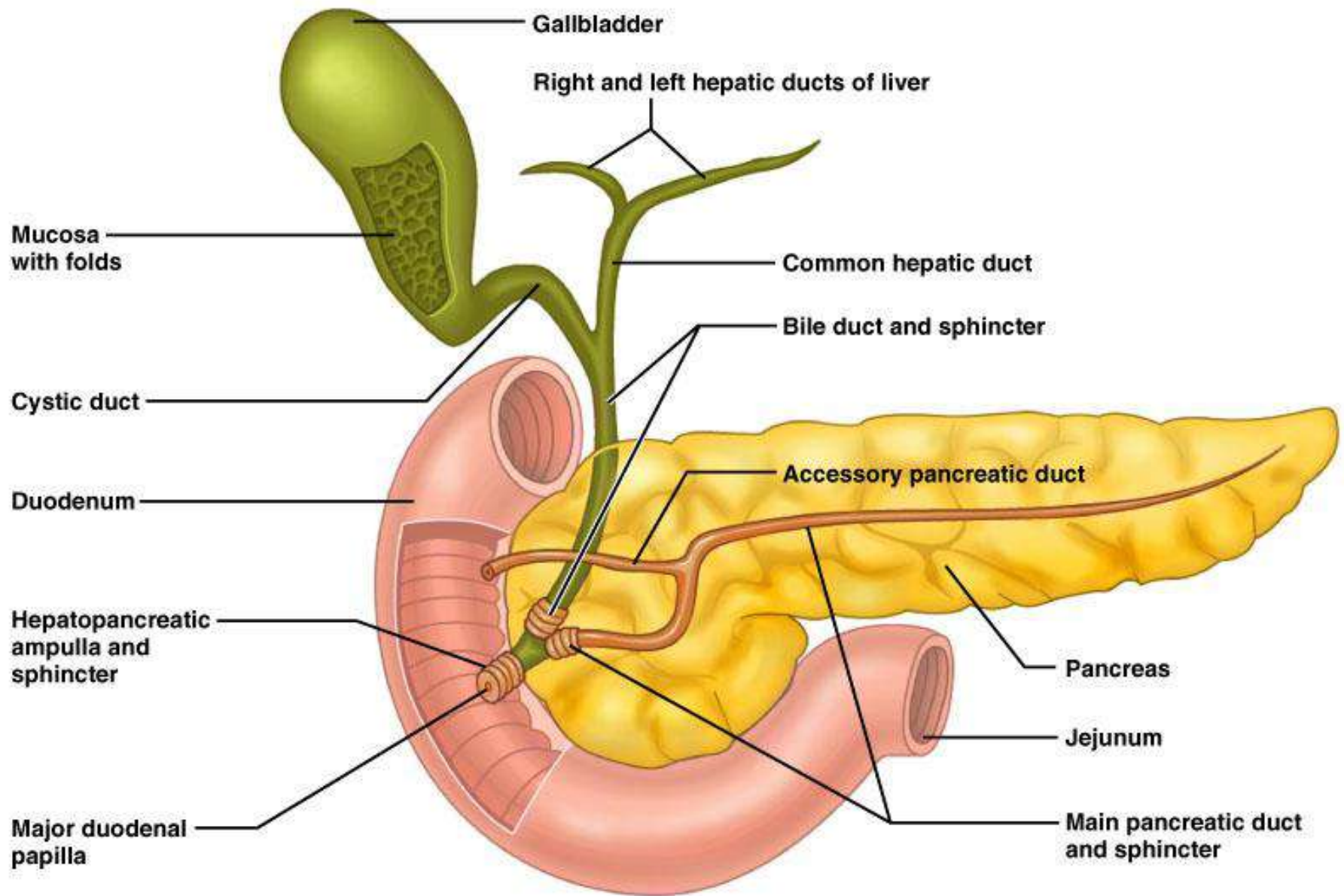
Has three subdivisions:

1. **duodenum**
2. **jejunum**
3. **ileum**

Pancreas - structure

posterior to great curvature of the stomach

1. **head** - enlarged portion in C-curve of the duodenum
2. **body** - tapers off beneath the stomach
3. **tail** - terminal part near the end
4. **pancreatic duct** - merges with bile duct to duodenum
 - a. hepatopancreatic ampulla (merging of both)
5. **accessory duct** - empties into duodenum, smaller



Pancreas - histology

1. made of *glandular epithelial cells*
2. pancreatic islets (of Langerhans) (1% of all cells)
 - a. hormones: glucagon, insulin, somatostatin
3. acini - (99% of the cells in pancreas)
 - a. mixture of enzymes called "pancreatic juice"

Liver

- Superficially has four lobes – **right, left, caudate, and quadrate**
- The largest gland in the body

Liver: Associated Structures

The falciform ligament:

- Separates the right and left lobes anteriorly
- Suspends the liver from the diaphragm and anterior abdominal wall

The ligamentum teres:

- Is a remnant of the fetal umbilical vein
- Runs along the free edge of the falciform ligament

Liver: Associated Structures

- The **lesser omentum** anchors the liver to the stomach
- The hepatic blood vessels enter the liver at the **porta hepatis**
- **gallbladder** - rests in a recess on the inferior surface of the right lobe; stores **bile** for digestion of fats

Bile

Bile leaves the liver via:

- Bile ducts, which fuse into the common hepatic duct
- The common hepatic duct, which fuses with the cystic duct
 - These two ducts form the bile duct

Gallbladder and Associated Ducts

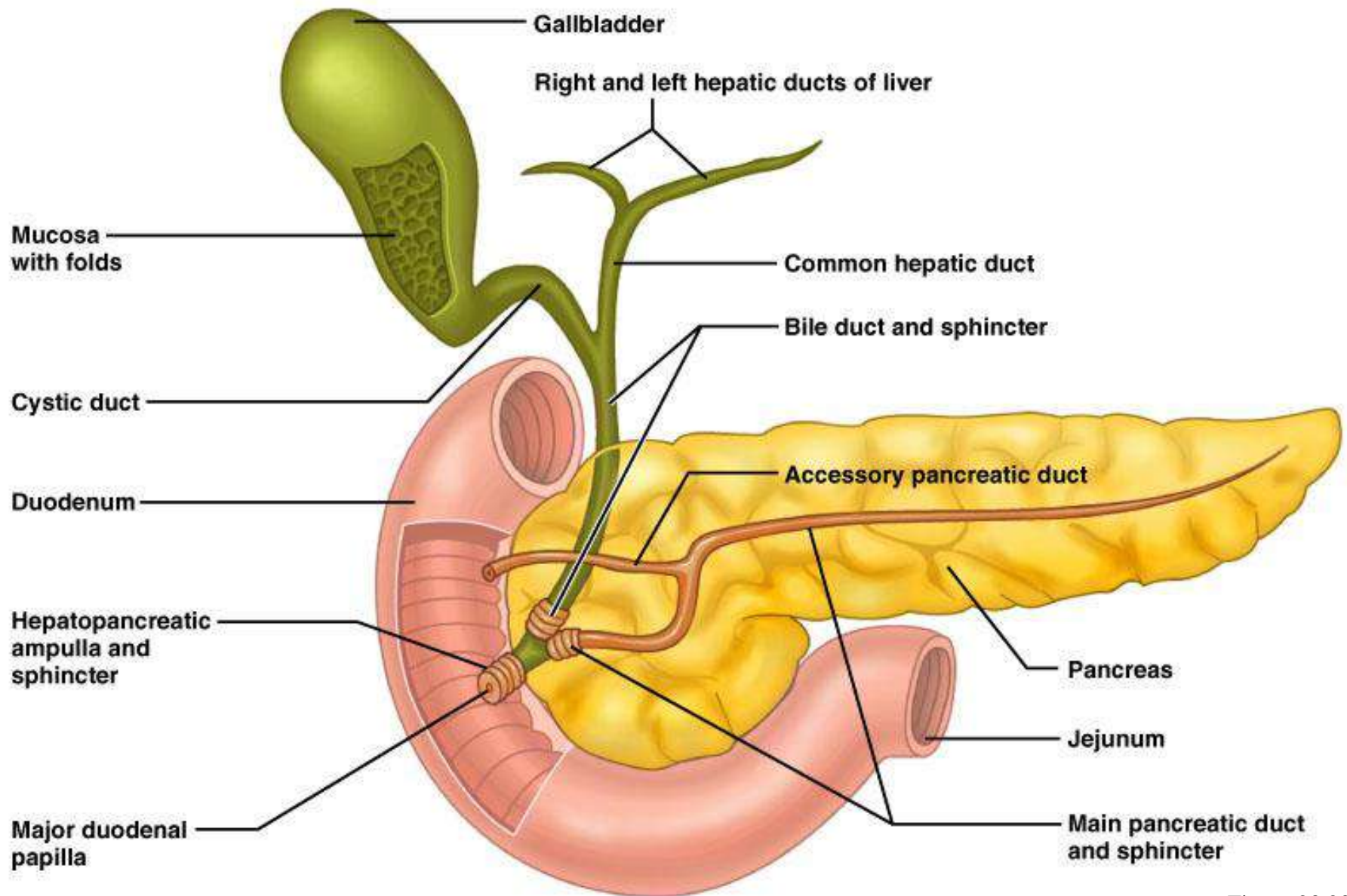


Figure 23.20

Liver: Anatomy

portal triads consist of a bile duct and

- **Hepatic artery** – supplies oxygen-rich blood to the liver
- **Hepatic portal vein** – carries venous blood with nutrients from digestive viscera

Hepatocytes

Hepatocyte functions include:

- Production of bile
- Processing bloodborne nutrients
- Storage of fat-soluble vitamins
- Detoxification

The Gallbladder

- Thin-walled, green muscular sac on the ventral surface of the liver
- Stores and concentrates bile by absorbing its water and ions
- Releases bile via the cystic duct, which flows into the bile duct

Large Intestine

- Is subdivided into the **cecum**, **appendix**, **colon**, **rectum**, and **anal canal**
- The saclike **cecum**:
 - Lies below the ileocecal valve in the right iliac fossa
 - Contains a wormlike vermiform appendix

Colon

Has distinct regions:

- **ascending colon**
- **hepatic flexure**
- **transverse colon**
- **splenic flexure**
- **descending colon**
- **sigmoid colon**

Large Intestine

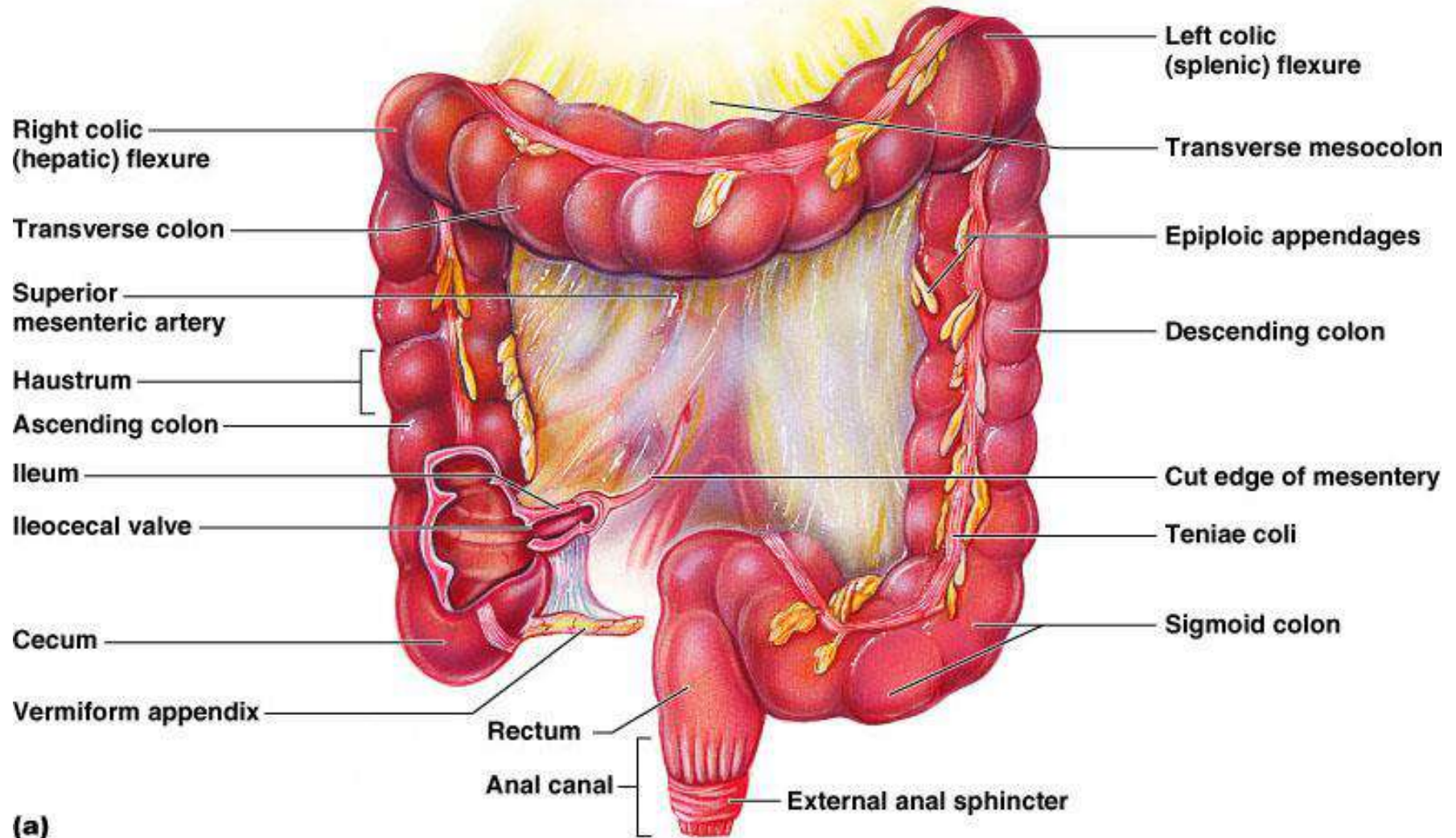


Figure 23.29a

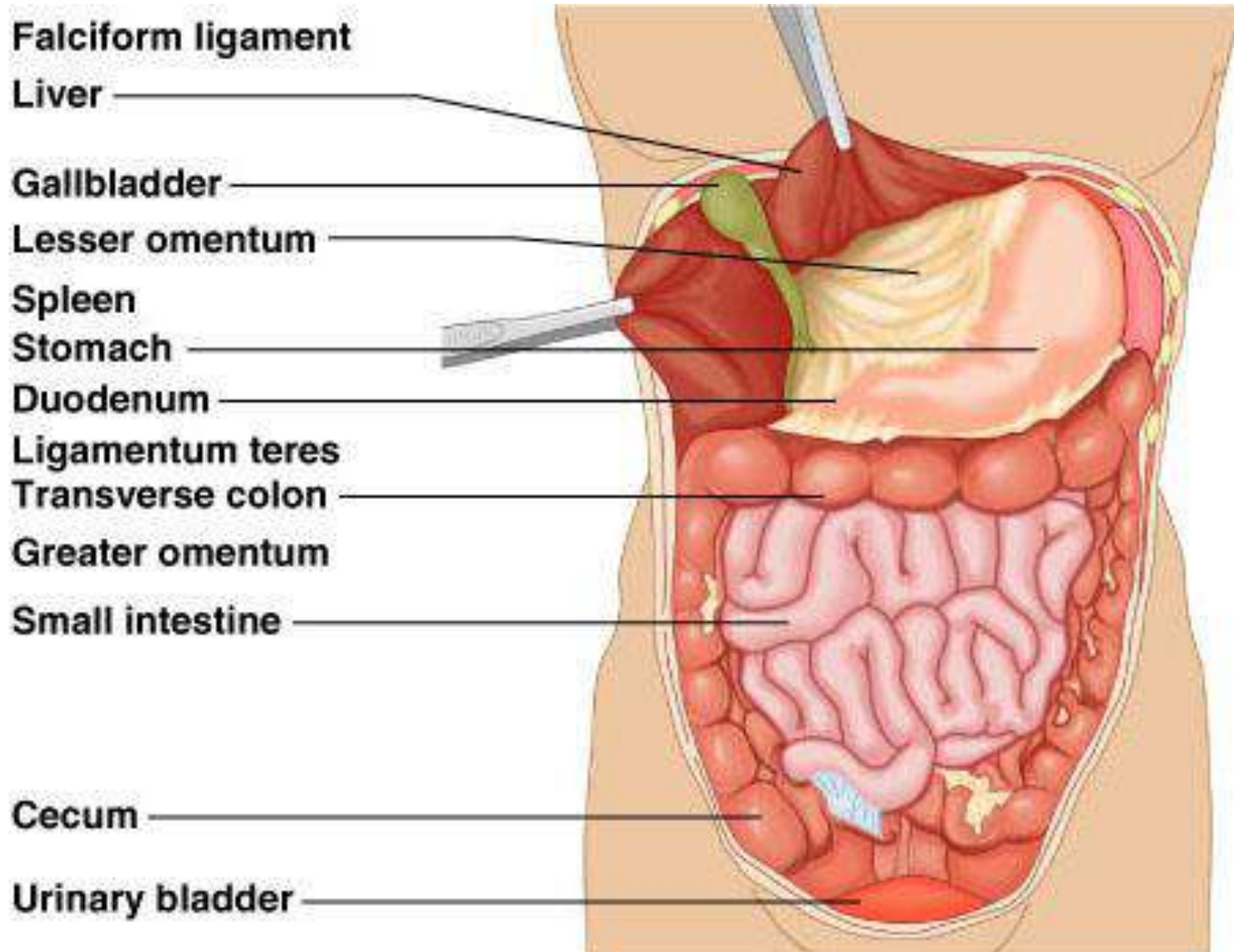
Colon

- The transverse and sigmoid portions are anchored via mesenteries called **mesocolons**
- The sigmoid colon joins the rectum
- The **anal canal**, the last segment of the large intestine, opens to the exterior at the **anus**

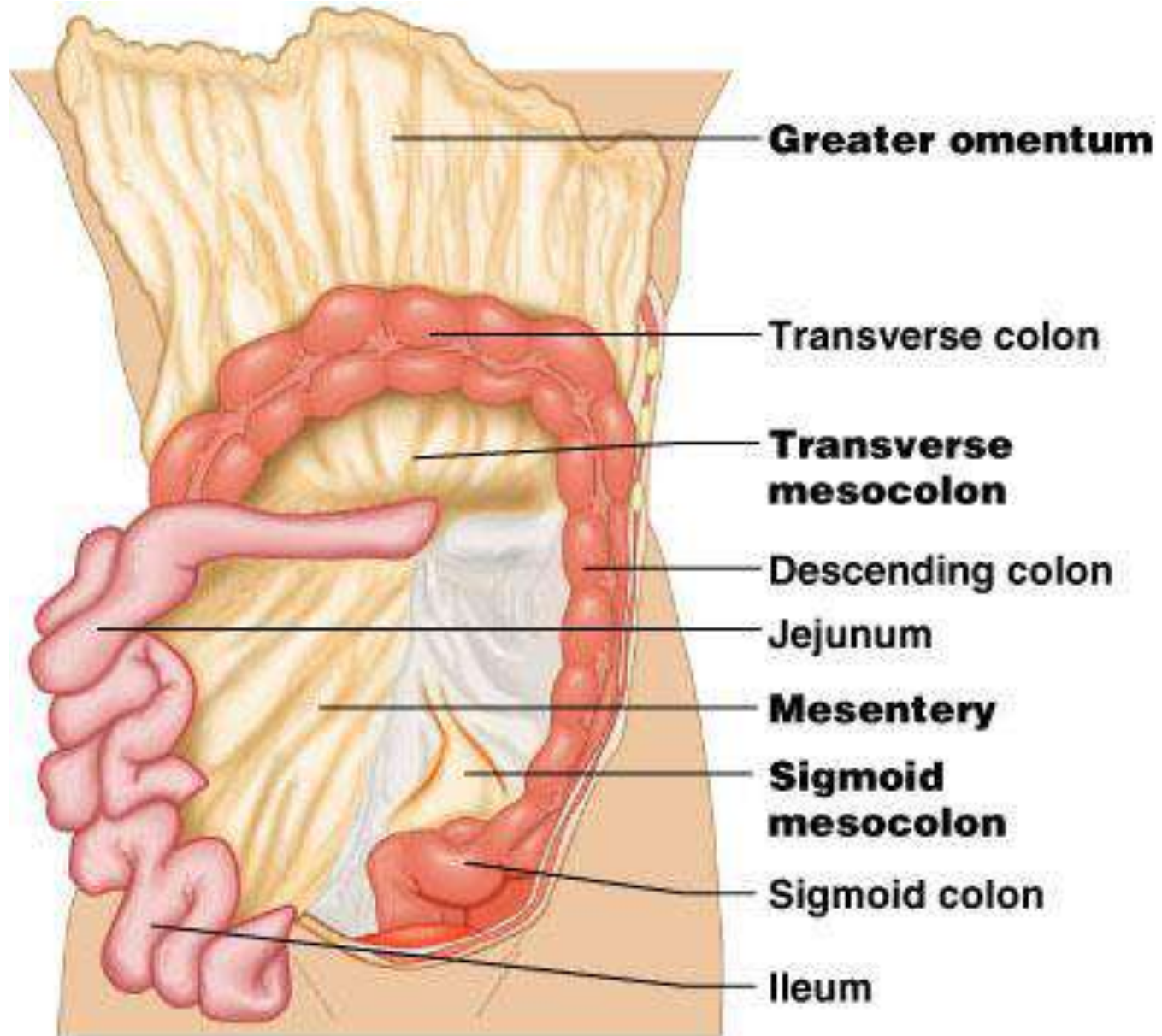
Anus

- **internal sphincter** - smooth muscle (involuntary)
- **external sphincter** - skeletal muscle (voluntary)

Mesenteries of Digestive Organs



Mesenteries of Digestive Organs



The Esophagus

Introduction

- Anatomy
- Physiology
- Clinical features
- Investigations
- Diseases of esophagus

Surgical anatomy

- The esophagus is a muscular tube approximately 25 cm long.
- The musculature of the upper 5%, including the upper esophageal sphincter, is striated; the middle 40% has mixed striated and smooth muscle, the distal 55% is entirely smooth muscle.
- The parasympathetic nerve supply is mediated by the vagus.
- There are an upper and lower esophageal sphincters.

Physiology

- The main function of the oesophagus is to transfer food from the mouth to the stomach.
- The initial movement of food from the mouth is voluntary.
- The upper esophageal sphincter is normally closed at rest and serves as :
 1. A protective mechanism against regurgitation of esophageal contents into the respiratory passages.
 2. Also it serves to stop air entering the esophagus.
- The lower esophageal sphincter(LOS) is a physiological sphincter, about 3-4 cm in length and has a pressure of 10-25 mmHg.

- The tone of it is influenced by many things including food, gastric distension, smoking, and GI hormones.
- Its main function is to prevent gastric and duodenal contents from refluxing into the lower esophagus.

Clinical features:

Symptoms

Dysphagia:

Is the term used to describe difficulty, but not necessarily pain, on swallowing.

The type of dysphagia is important; it may be dysphagia for solids or fluids, intermittent or progressive.

Odynophagia

It refers to pain on swallowing.

Regurgitation and reflux

Regurgitation strictly refer to the return of esophageal contents from above an obstruction in the esophagus.

Reflux is the passive return of gastroduodenal contents to the mouth.

Chest pain

Chest pain similar in character to angina pectoris may arise from an esophageal cause.

Other symptoms of esophageal disorders include; loss of wt, anemia, cachaxia, change of voice, and cough.

Investigations

A- Radiography

- 1- Plain X ray; may show opaque foreign bodies.
- 2- Contrast radiography (Barium swallow) is a useful investigation for demonstrating narrowing, space-occupying lesions, anatomical distortion or abnormal motility.

B- Endoscopy

- Is the investigation of first choice for most oesophageal disorders.
- It is either for diagnostic or for therapeutic purposes.
- Diagnosis is by visual inspection of the inside of oesophagus and also by taking a biopsy or cytology specimen.
- For therapy, can be used for;
 - Removal of FB
 - Dilatation of strictures
 - Oesophageal varices

There are two types;

- 1- Rigid oesophagoscopy; which is now virtually obsolete.

Disadvantages:

Needs general anesthesia, difficult to introduce, and carry high risk of perforation

2- Fibre-optic endoscopy

- It has virtually supplanted the rigid instrument.
- It is done under local anesthesia on an out-patient basis, easy to enter, and carry low risk of perforation.

C- Oesophageal manometry

- Is widely used to diagnose esophageal motility disorders.
- Recordings are usually made either by;
 - 1- Multilumen catheter
 - 2- Catheters with solid-state transducer

D- 24-hour PH recording

Prolonged measurement of esophageal pH is now accepted as the most accurate method for the diagnosis of gastro esophageal reflux.

Diseases of the esophagus

Congenital abnormalities

- Atresia and tracheo-oesophageal fistula
- Oesophageal stenosis
- Dysphagia lusoria

Foreign bodies in the oesophagus

- A lot of things may become arrested in the oesophagus such as coins, pins, dentures. The commonest impacted material is food.
- Plain radiographs are the most useful examination.
- Endoscopy is good tool for the dx specially of non-opaque FB.

Treatment:

Flexible endoscopy is now the method of choice and the majority of objects can be extracted with suitable grasping forceps, a snare or a basket.

An impacted food bolus will often break up and pass on if the patient is given fizzy drinks and confined to fluids for a short time

Perforation of the oesophagus

Perforation of the oesophagus is a serious condition that requires prompt diagnosis and treatment

Causes:

A) Barotrauma _ Boerhaave's syndrome

- So-called “spontaneous” perforation of the oesophagus is usually due to severe barotrauma when a person vomits against a closed glottis.
- Usually at the lower third
- The clinical history is of severe pain in the chest or upper abdomen following a meal or a bout of drinking.

B) Pathological perforation

- Perforation of ulcers, such as a Barrett’s ulcer or tumours.
- Penetrating injury
- Foreign bodies
- Instrumental perforation

Diagnosis

- Beware and beware of perforation
- Chest pain
- Subcutaneous emphysema in the neck
- Emphysema around the pericardium can be detected on auscultation as a mediastinal crunch
- Chest XR may show gas in the mediastinum
- Contrast swallow using barium suspension

Treatment

- Prompt dx and treatment is essential for the best results
- There are two options:
 - ✓ Operative
 - ✓ Non-operative

Management options in perforation of the oesophagus:

Factors that favour

Nonoperative

Small septic load
Minimal CV upset
Perforation confined to
Mediastinum
Endoscopic perforation
Perforation of cervical
Oesophagus

Operative

Large septic load
Septic shock
Pleura breached

Boerhaave syndrome
Perforation of abdominal
oesophagus

Nonoperative management

- Analgesia
- Nil by mouth
- Antibiotics
- General supportive care...IV fluids
- When stable...enteral or parenteral nutrition
- Nasogastric tube is not recommended

Operative management

- It involves thoracotomy and repair of the perforation
- This is best done within a few hours of perforation

Corrosive injury

Sodium hydroxide

Sulphuric acid

Drug induced injury

Antibiotic tab

Potassium tab

Intestinal obstruction

Dr. Siddeek B. MAR'IE

Intestinal obstruction

- **Intestinal Obstruction** (I.O.) may be classified into **2** types:-
- **1-Dynamic:** peristalsis working against a mechanical obstruction either acute or chronic.
- **2-Adynamic;**
peristalsis is absent(paralytic ileus)

Causes of Intestinal Obstruction

Dynamic

Intraluminal:

- Impaction
- Foreign Body

Intramural:

- Stricture
- Malignancy

Extramural :

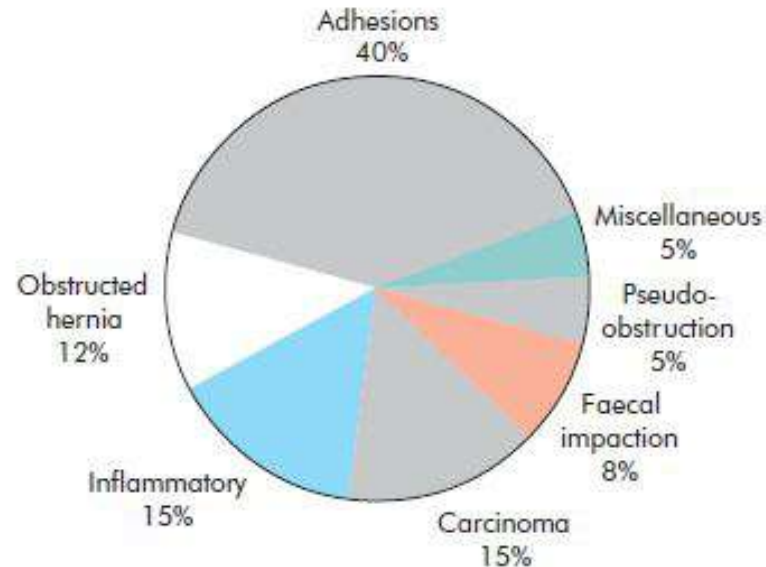
- adhesions
- Hernia
- Volvulus
- Intussusception

Adynamic

- Paralytic ileus

Relative frequency of the underlying diagnosis

- Adhesions 40%
- Inflammatory 15%
- Obstructed hernia 12%
- Fecal impaction 8%
- Pseudo obstruction 5%
- Miscellaneous 5%



CLINICAL FEATURES S&S

- ❖ **obstructed H** :there may be an area of localized tenderness at the site of the obstruction;
 - When strangulation occurs in an **external hernia** the lump is tense, tender, irreducible, there is **no** expansile cough impulse .
 - *Generalized* tenderness +rigidity in the *abdomen* are indicative of the need for early laparotomy.

Strangulation

- when it occurs, it affects the viability of the bowel
- The venous return is decreased before the arterial supply → haemorrhagic infarction .
- As the viability of the bowel affected there is systemic exposure to aerobic & anaerobic m. o. & its toxins → peritonitis → increased mortality & morbidity which increases by age & extent of the disease.

Causes of strangulation:

External

- hernial orifice
- adhesions

Interrupted blood supply

- volvulus
- intussusception

Clinical features of strangulation

- It is vital to distinguish **strangulating** from non-strangulating intestinal obstruction, as the former is a **surgical emergency**. The diagnosis is entirely clinical. In addition to the features outlined above, the following should be noted:
- the presence of shock indicates underlying ischaemia;
- in strangulation, pain is never completely absent;
- symptoms usually commence suddenly and recur regularly;
- the presence and character of any local tenderness are of great significance .

Dynamic Obstruction

The diagnosis is based on the classical quartet of:

- Pain
- Distention
- Vomiting
- absolute constipation

Obstruction may be classified clinically into two types;

- Small bowel Obstruction (high or low)
- Large bowel Obstruction

Features of Obstruction

a- small bowel obstruction

- In **high** small bowel Obstruction
 - vomiting early
 - minimal distention,
 - rapid dehydration,
 - with little evidence of fluid level in abdominal radiography
- In **low** small bowel Obstruction
 - mainly pain
 - central distention,
 - vomiting delayed,
 - multiple central fluid level in abdominal radiography

b-large bowel obstruction

- distention early,
- pain is mild,
- vomiting& dehydration is late
- the proximal colon & cecum are distended in abdominal radiography

Regarding the nature of onset & timing:

- **Acute:-** small intestine
- **Chronic :-** large Intestine

Presentation is also influenced by whether the obstruction:

- **Simple:** blood supply intact
- **Strangulation:-** blood supply interference (by hernial rings bands, adhesions)

Clinical Features vary according to:

- Location of obstruction
- Duration of obstruction
- Underlying pathology
- Absence or presence of Intestinal ischemia

Cardinal features:

1-pain:

- small bowel : sudden \sever \ colicky \central around umbilicus
- Large bowel the same ;but in lower abdomen
- Increase with the peristaltic activity
- with increasing distention , the colicky pain replaced by a (mild \ constant \ diffuse) pain
- development of severe pain indicate strangulation
- Pain not occurs in paralytic ileus.

• 2- vomiting :

- The more distal the obstruction the larger interval between onset of nausea & vomiting
- As obstruction progress the vomit change from digested food to feculent material ((due to bacteria overgrowth)).

3- distension :

- In small bowel is greater the more distal the lesion .
- visible peristalsis may be absent
- Distention is delayed in colonic obstruct.

4- Constipation :

Classified as :-

- absolute (neither faeces nor flatus is passed)
- relative (where only flatus is passed)
- Absolute constipation is cardinal sympt. of complete I.O.

Investigation

- Laboratory & radiology

Treatment of acute Intestinal obstruction.

1. Gastro- intestinal drainage (NPO&NGT)

2. fluid & electrolyt replacement

3. relief of obstruction

- The first two steps are always necessary before surgical relief of obstruction & are the mainstay of post op. management
- In some cases like adhesive obstruction, they may be used exclusively
- the surgical TTT is necessary for most of cases of I.O. but should be delayed until resuscitation is complete provided there is no sign of strangulation .

The principles of surgical intervention for obstruction:-

Management of:-

- The distended proximal bowel
- Underlying cause of obstruction

Supportive Management

- Nasogastric decompression is achieved by the passage of a NG tube
- The basic biochemical abnormality is sodium and water loss, and therefore the appropriate replacement is *Hartmann's solution or normal saline*. The volume required varies and should be determined by clinical haematological and biochemical criteria.
- Broad spectrum antibiotics

Surgical treatment

- The time of operation depend on
 1. clinical picture
 2. indication for early operation :
 - Obstruct or strangulation external hernia
 - Internal hernia intestinal strangulation
 - Acute obstruction

- If the site of obstruction is unknown, adequate exposure is best achieved by a midline incision. **Operative assessment is directed to:**
 - the site of obstruction;
 - the nature of the obstruction;
 - the viability of the gut.
- Identification and assessment of the **caecum** is the best initial manoeuvre. If it is collapsed, the lesion is in the small bowel and may be identified by careful retrograde assessment. A dilated caecum indicates large bowel obstruction.

Operative TTT

- The type of surgical procedure required will depend upon the nature of the cause — division of adhesions (enterolysis), excision, bypass or proximal decompression.
- Following relief of obstruction, the viability of the involved bowel should be carefully assessed .
- Whenever **small bowel is resected**, the exact site of resection, the length of the resected segment and that of the residual bowel should be recorded.

Large bowel obstruction

- This is usually due to underlying carcinoma or occasionally diverticular disease, and presents in an acute or chronic form.
- The condition of pseudo-obstruction should always be considered and excluded by a limited contrast study or air computerised tomography (CT) scan to confirm organic obstruction.

Rx

- After **full resuscitation** the abdomen should be opened through a midline incision.
- Distension of the caecum will **confirm** large bowel involvement. Identification of a collapsed distal segment of the large bowel and its sequential proximal assessment will readily lead to identification of the cause.
- When a **removable** lesion is found in the caecum, ascending colon, hepatic flexure or proximal transverse colon an emergency right hemicolectomy should be performed.
- If the lesion is **irremovable**, a proximal stoma (colostomy or ileostomy if the ileocaecal valve is incompetent) or ileotransverse bypass should be considered. Obstructing lesions at the splenic flexure should be treated by an extended right hemicolectomy with ileodescending colonic anastomosis.

2-Obstruction from enteric strictures

Small bowel strictures usually occur secondary to

- tuberculosis & Crohn's disease.
- Standard surgical management consists of resection & anastomosis.

3- Bolus obstruction

- food,
- gallstones,
- trichobezoar,
- phytobezoar,
- worms(ascaris).

4- Intussusception

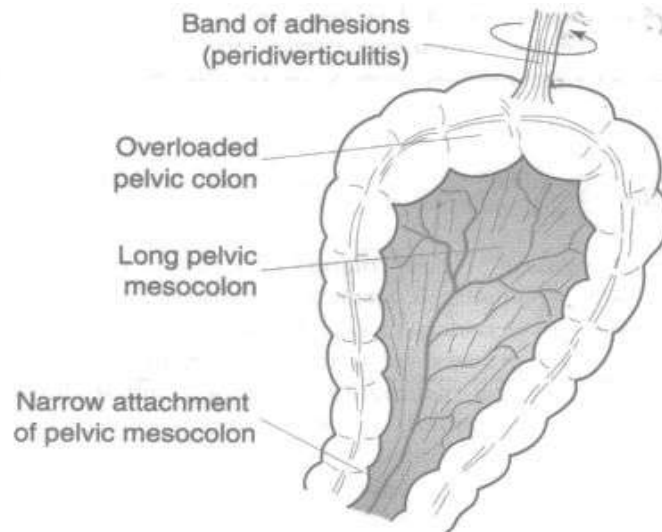
Volvulus

Of small intestine Rx by reduction of twist

Of cecum Rx by fixation& or cecostomy

Sigmoid volvulus

The predisposing cause is summarized in figure



Presentation :-

- Abdominal distension
- vomiting occurs late.
- Constipation is absolute(air&fecal mat.)
- A plain radiograph shows massive colonic distension. The classic appearance is of a **dilated loop of bowel with two fluid levels** seen, one within each loop of bowel.

Treatment

- Flexible sigmoidoscopy or rigid **sigmoidoscopy** and insertion of a **flatus tube** should be carried out to allow deflation of the gut. Success, as long as ischaemic bowel is excluded, will provide temporary cure allowing resuscitation and an elective procedure.

Treatment (continue)

- failure results in an early **laparotomy with untwisting** of the loop and per-anal decompression, When the bowel is viable, **fixation** of the sigmoid colon to the posterior abdominal wall

Or colostomy.

Or sigmoid colectomy and anastomosis

Adynamic obstruction

Paralytic ileus:-

failure of transmission of peristaltic waves secondary to **neuro muscular failure**

Varieties

- **1**-Postoperative — a degree of ileus usually occurs after any abdominal procedure for 24—72 hours.
- **2**- Infection — intra-abdominal sepsis
- **3**-Reflex ileus — may occur following fractures of the spine or ribs, retroperitoneal haemorrhage.
- **4**-Metabolic — uraemia and hypokalaemia.

- **Clinical features**

- Abdominal distension becomes more marked and tympanitic.
- Absent bowel sounds (– B.S.)

Management :-

- prevention, with the use of nasogastric **suction and restriction** of oral intake until bowel sounds and the passage of flatus return. **Electrolyte balance** must be maintained.
- **Conservative Rx** maintained but when ileus is prolonged, lapratomy considered excluding hidden cause & facilitating bowel decompression.