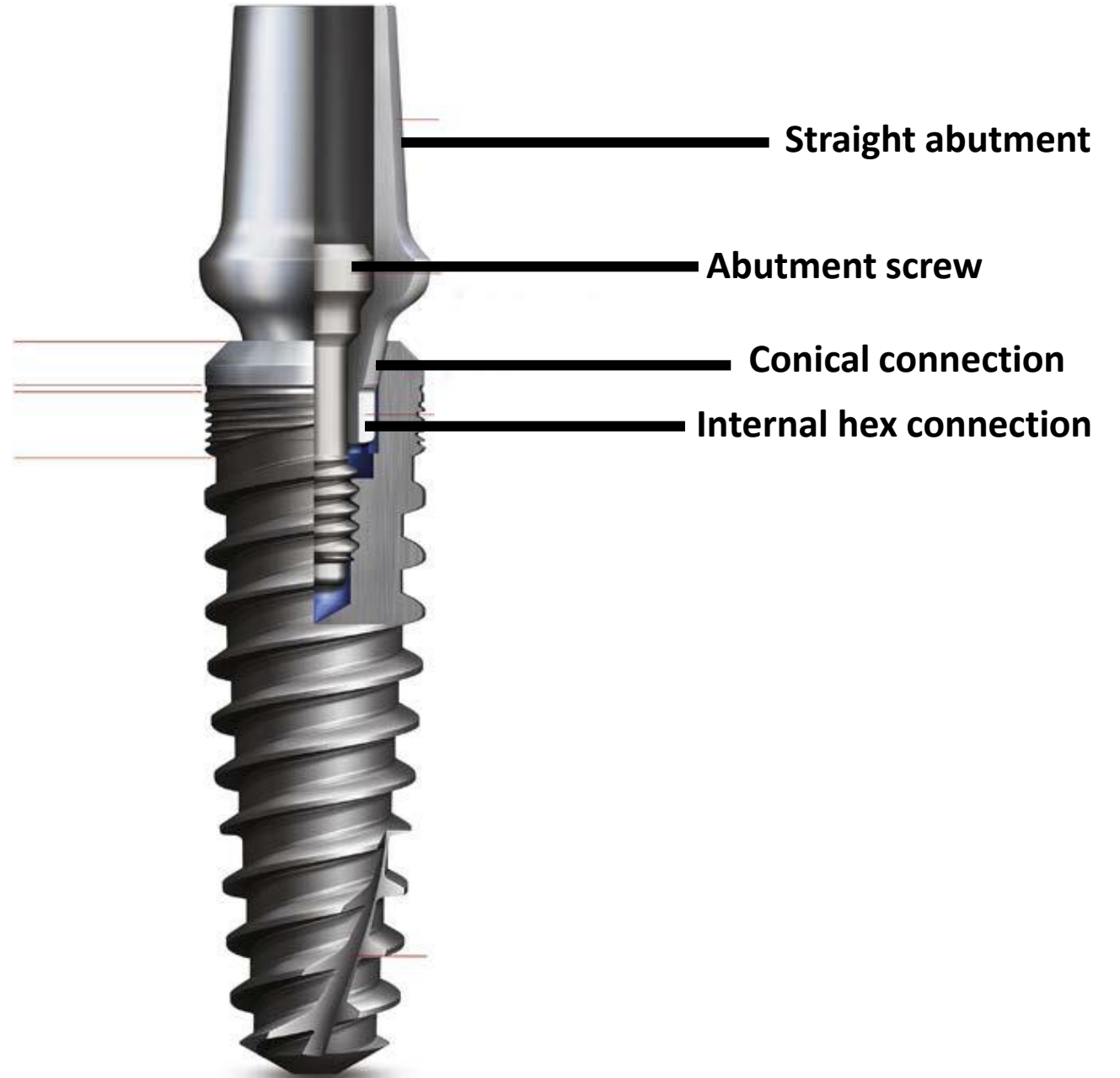


**Ball and socket
abutment**




One-piece mini-implant



External hex connection



Implant Fixture





Opening for
main screw

Opening for
second screw

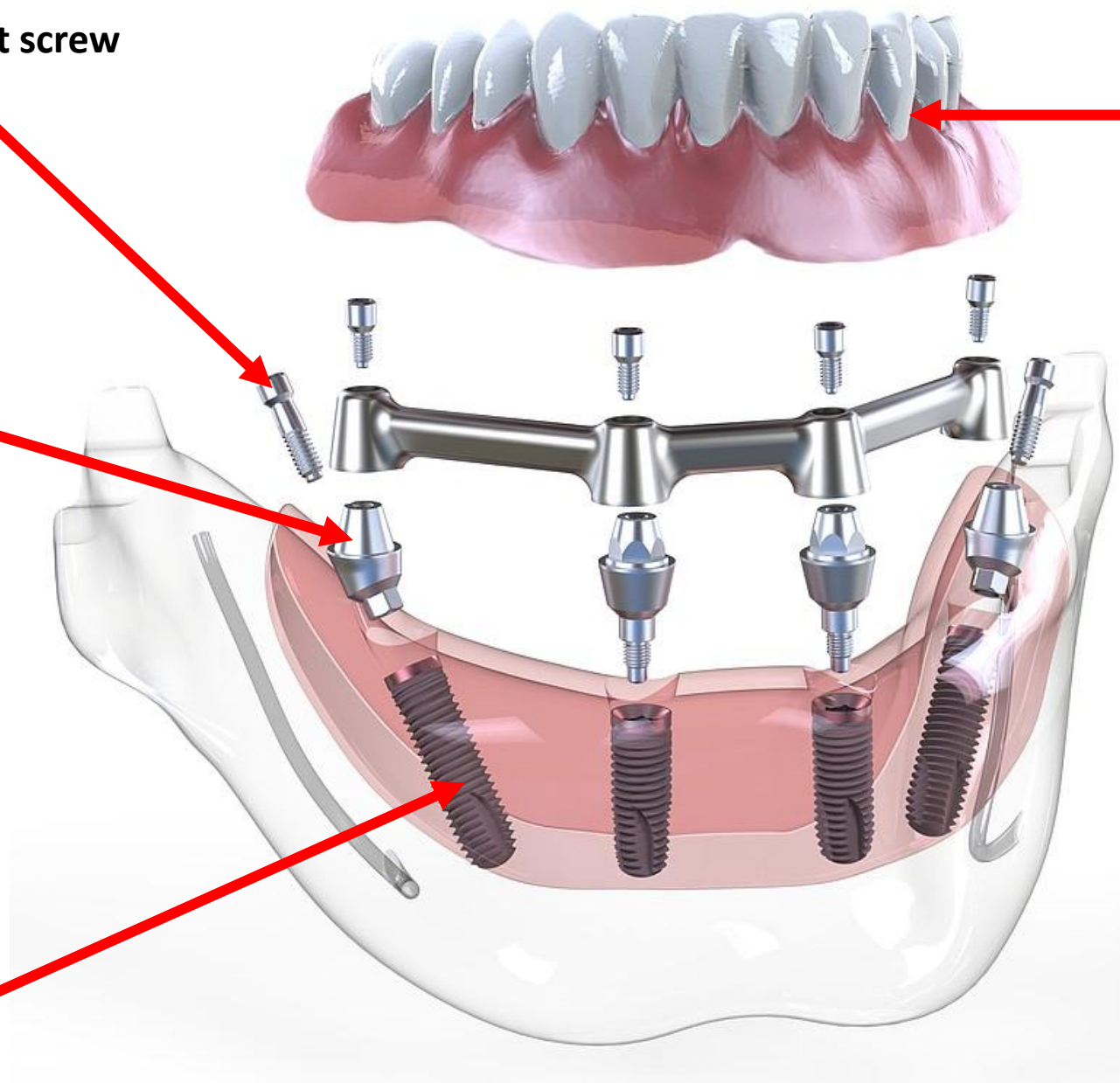


Main abutment screw

Hybrid denture

**Multiunit abutment
with screws**

Implant Fixture



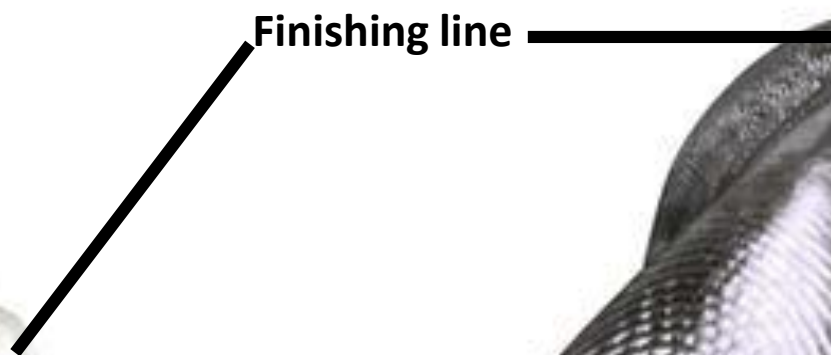



posterior milled titanium abutment

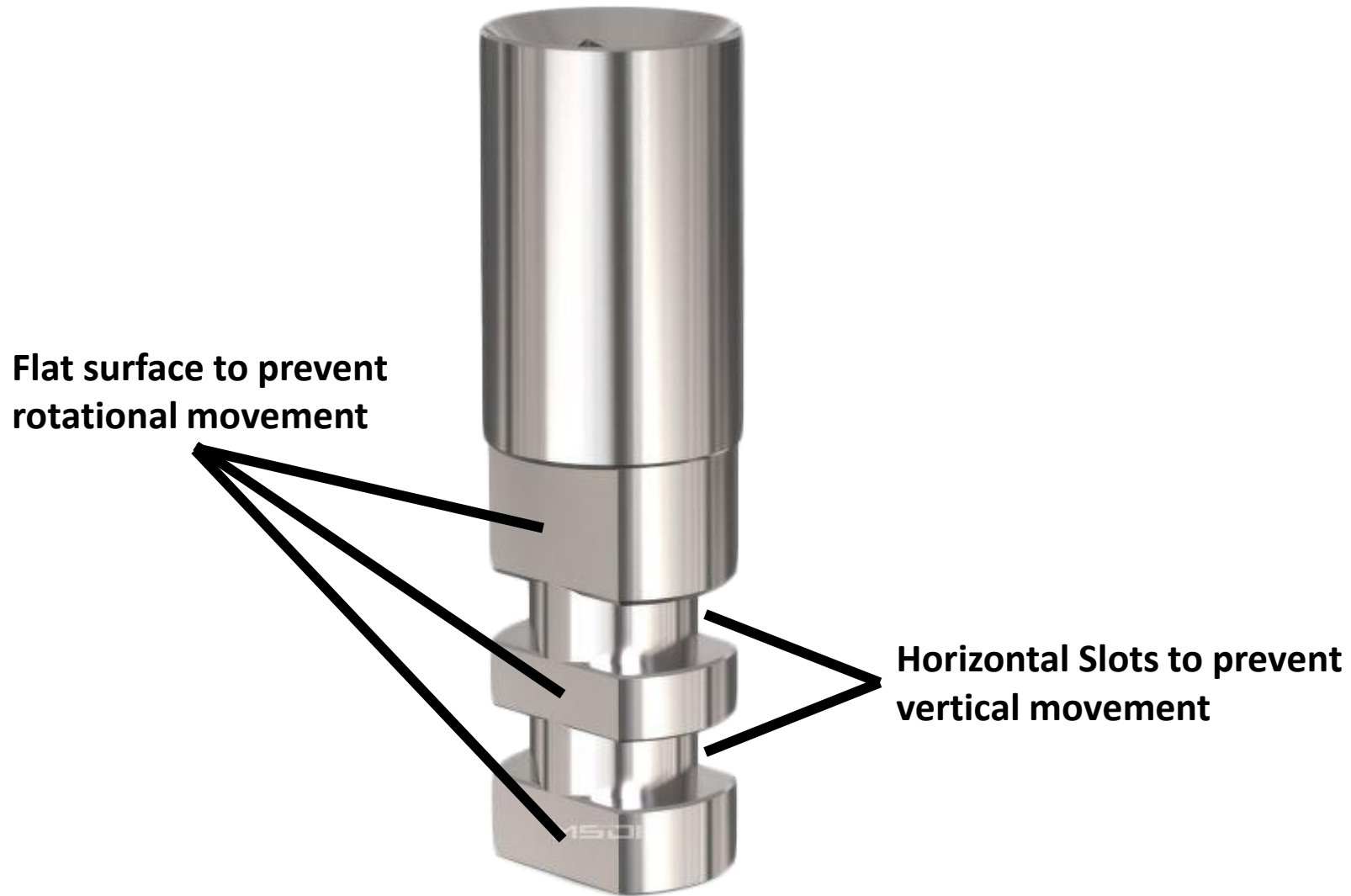


Anterior milled titanium
abutment

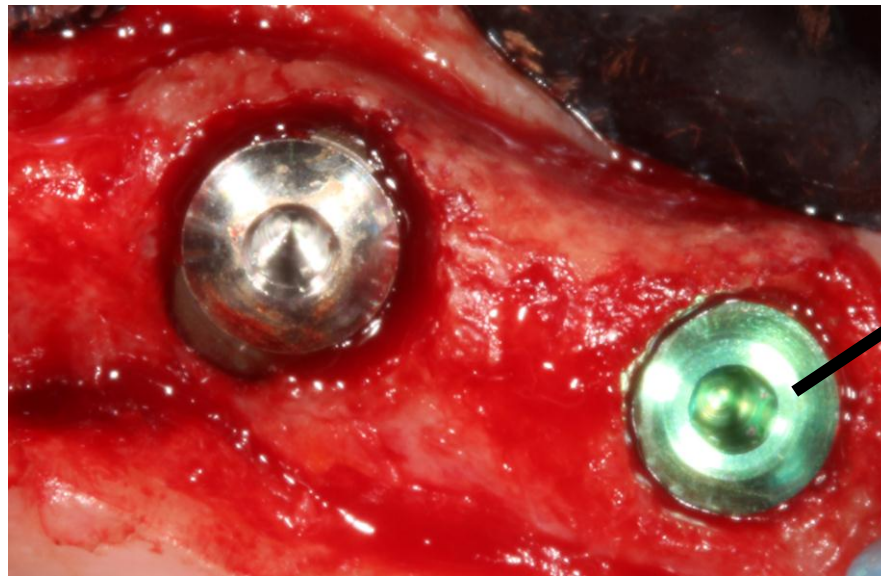
Finishing line





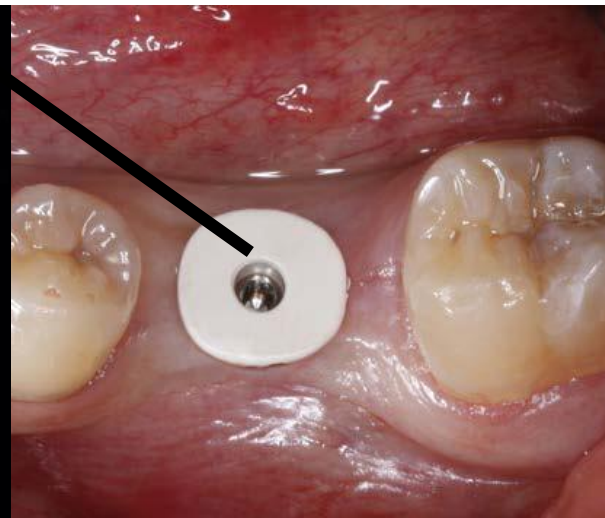


IMPLANT ANALOGUE

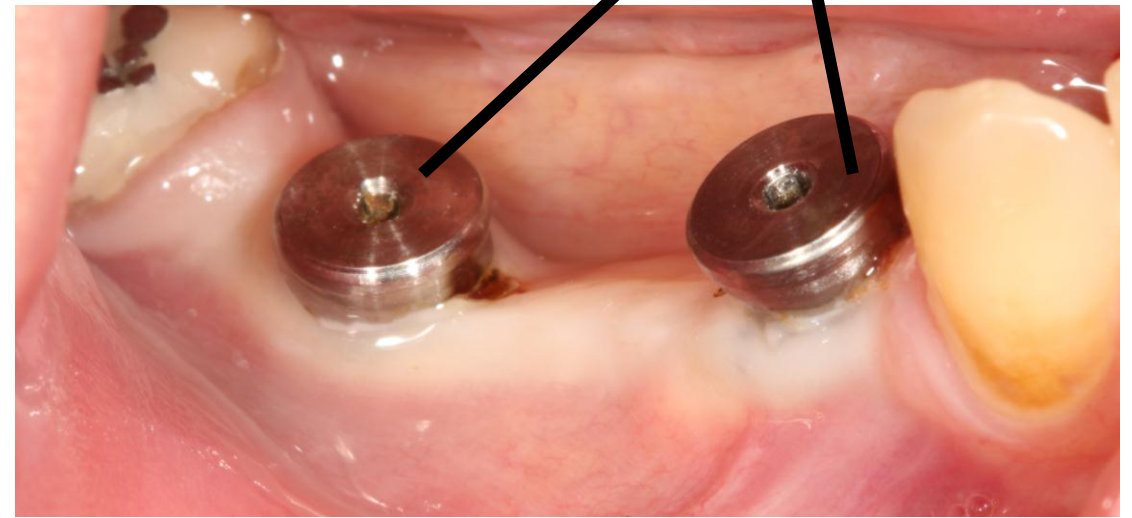


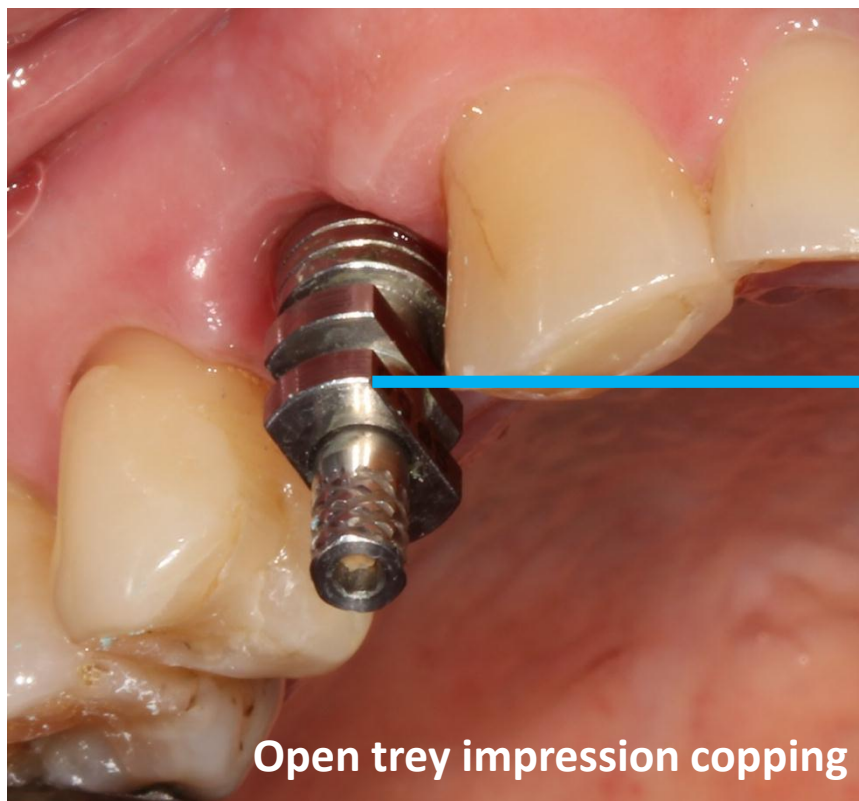
Cover screw

Customized
Gingival former



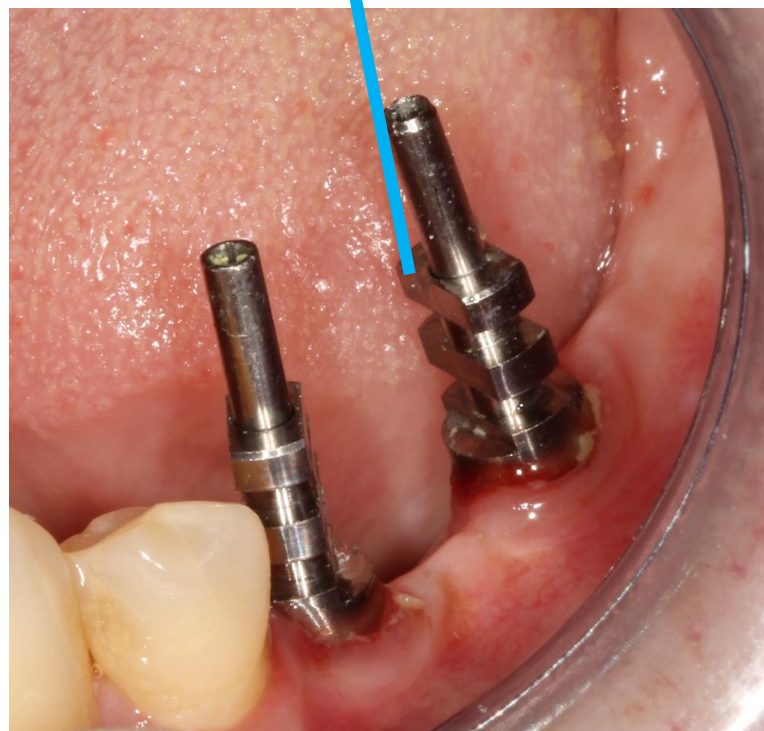Gingival former





Open tray impression coping

Horizontal wings to prevent vertical movement

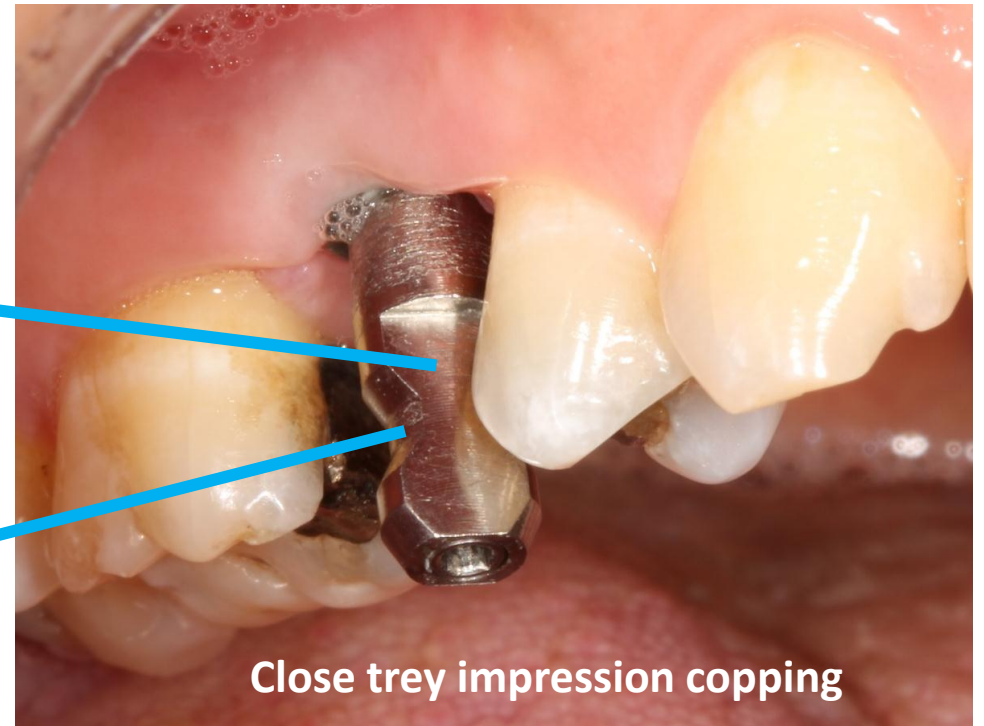


Open tray impression coping

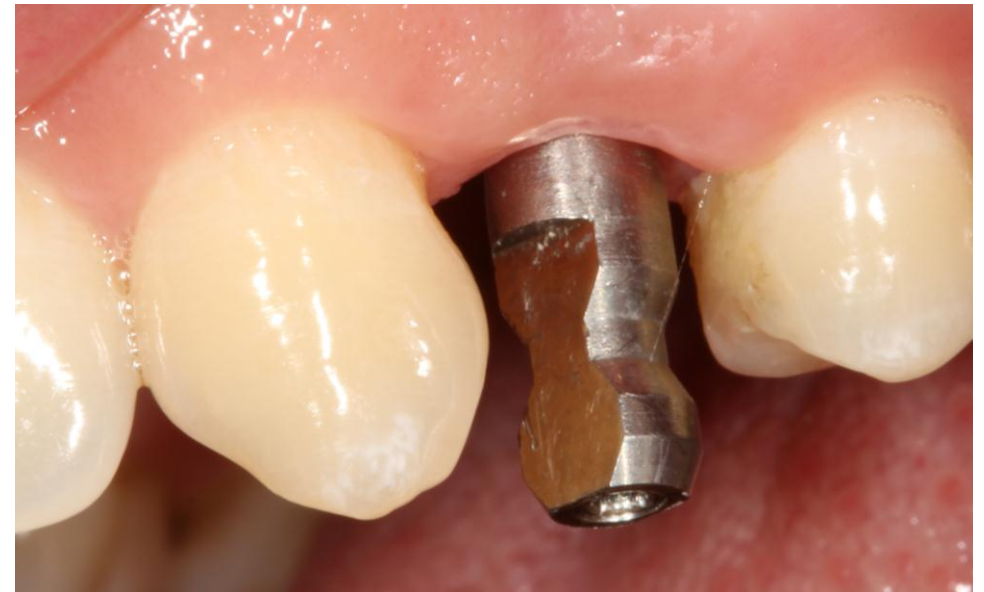

Vertical Slots to determine the correct horizontal position

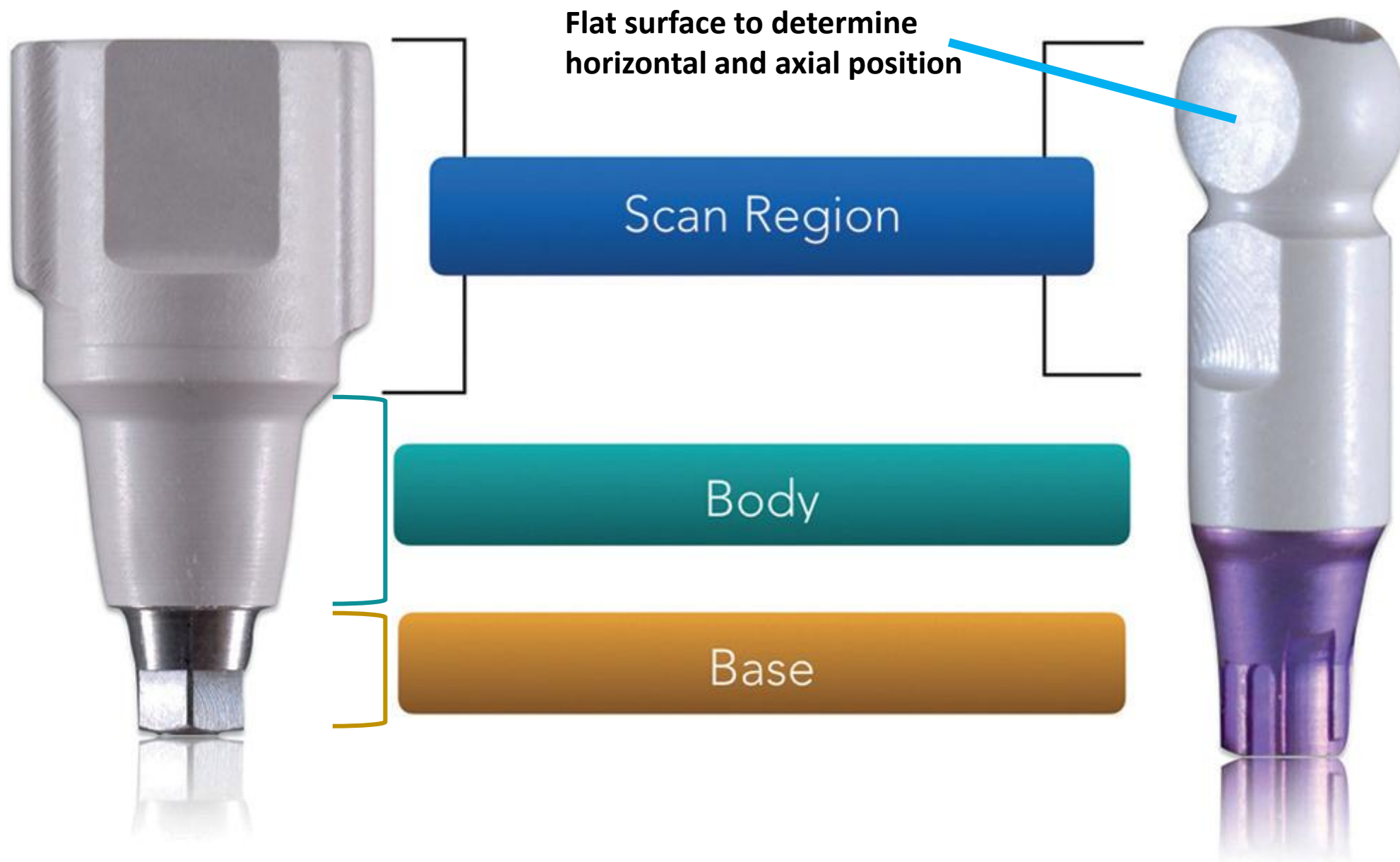
Horizontal Slots to determine the correct vertical position

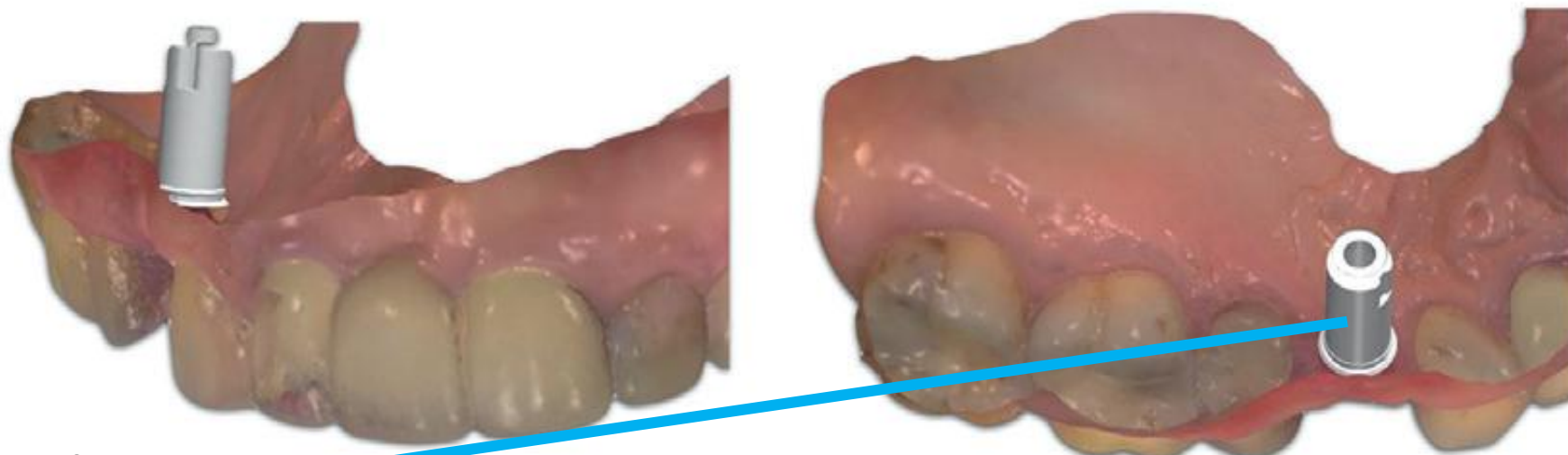


Close tray impression coping

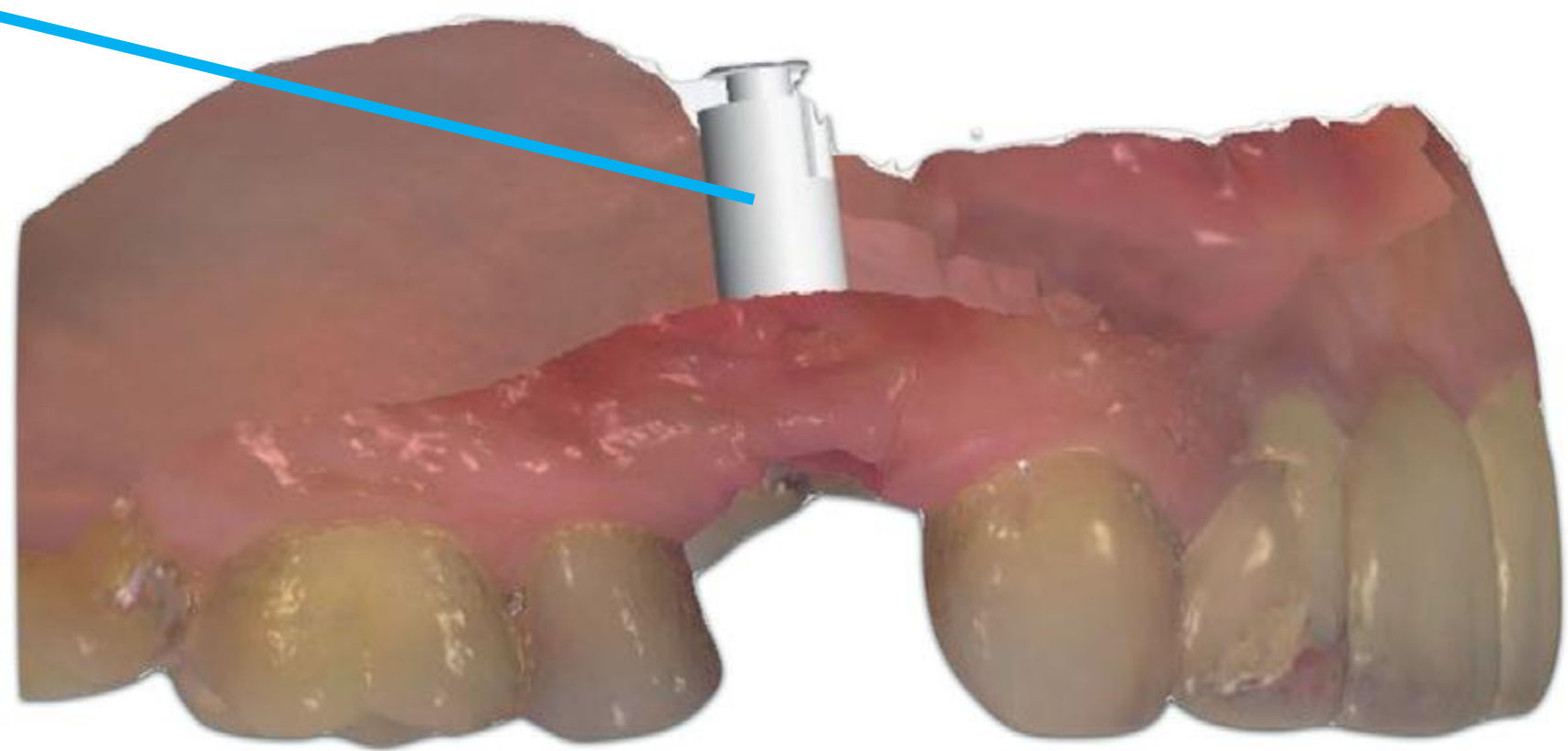
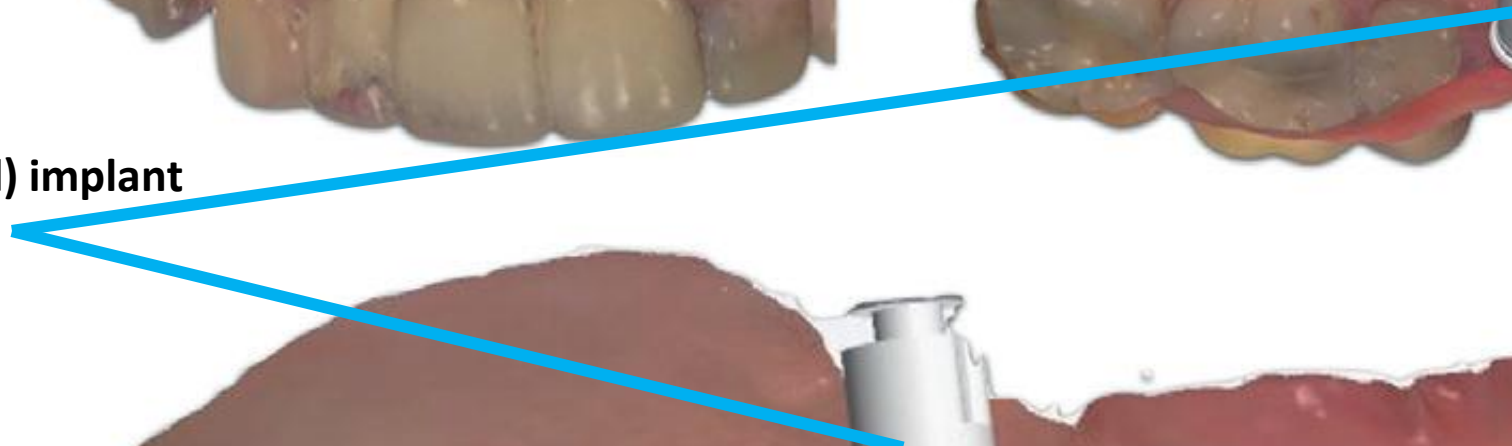

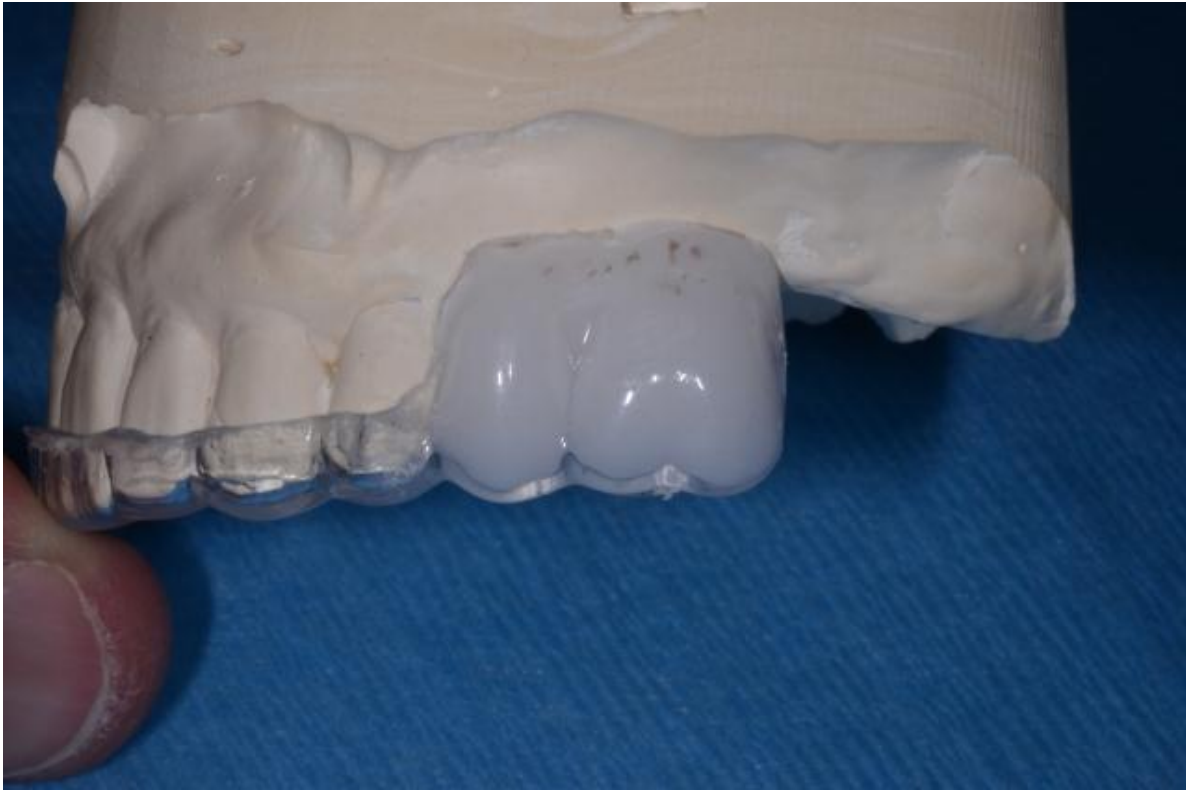
Close tray impression coping



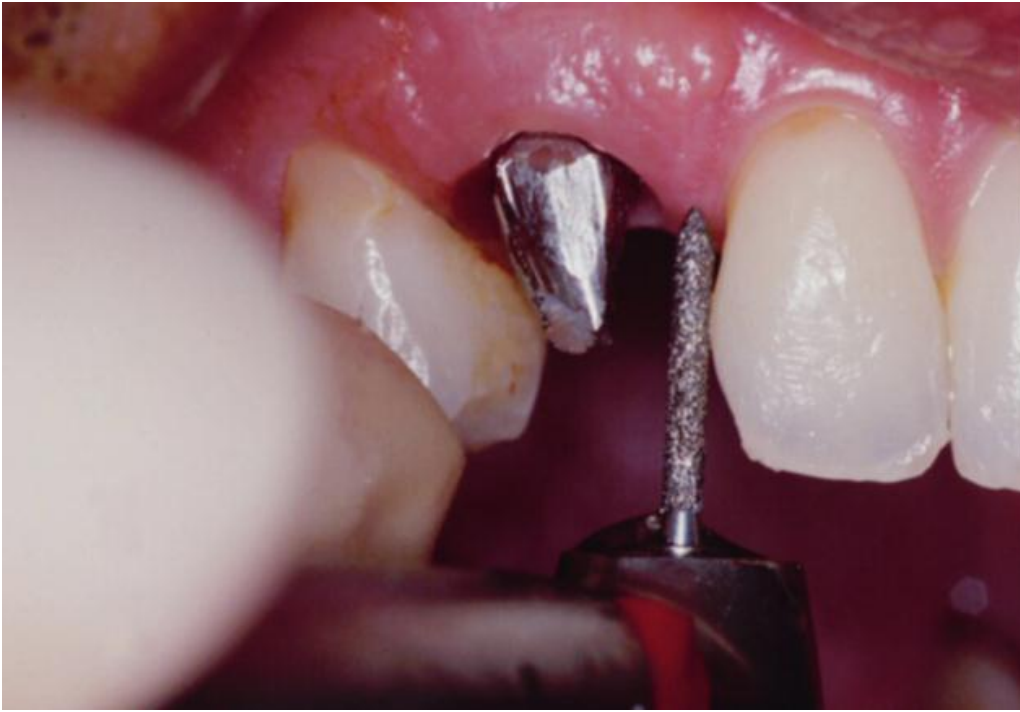

**Digital (virtual) implant
analogue**

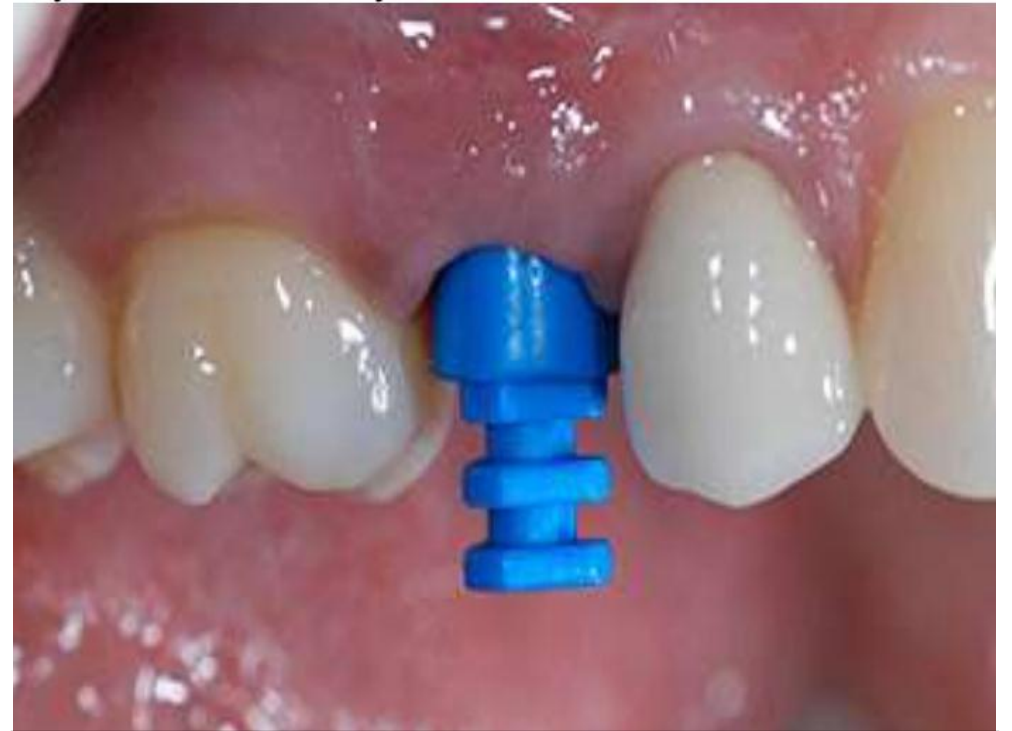



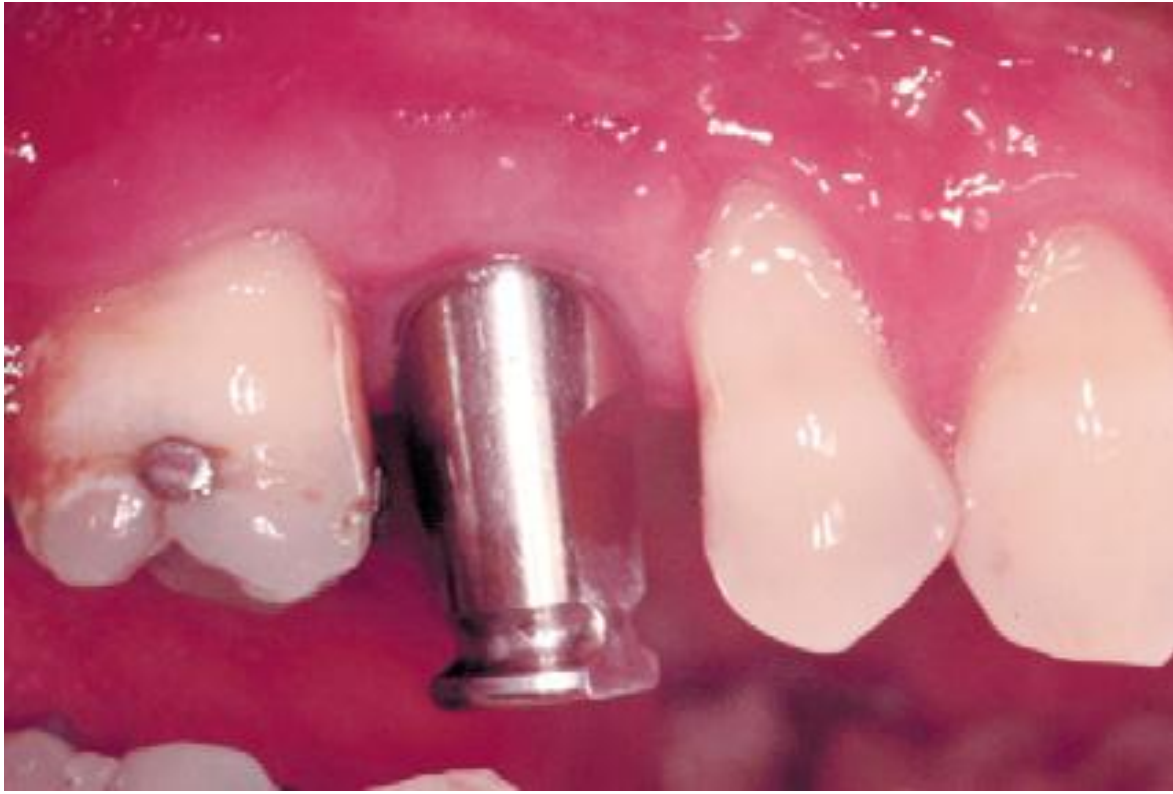Scanning Template



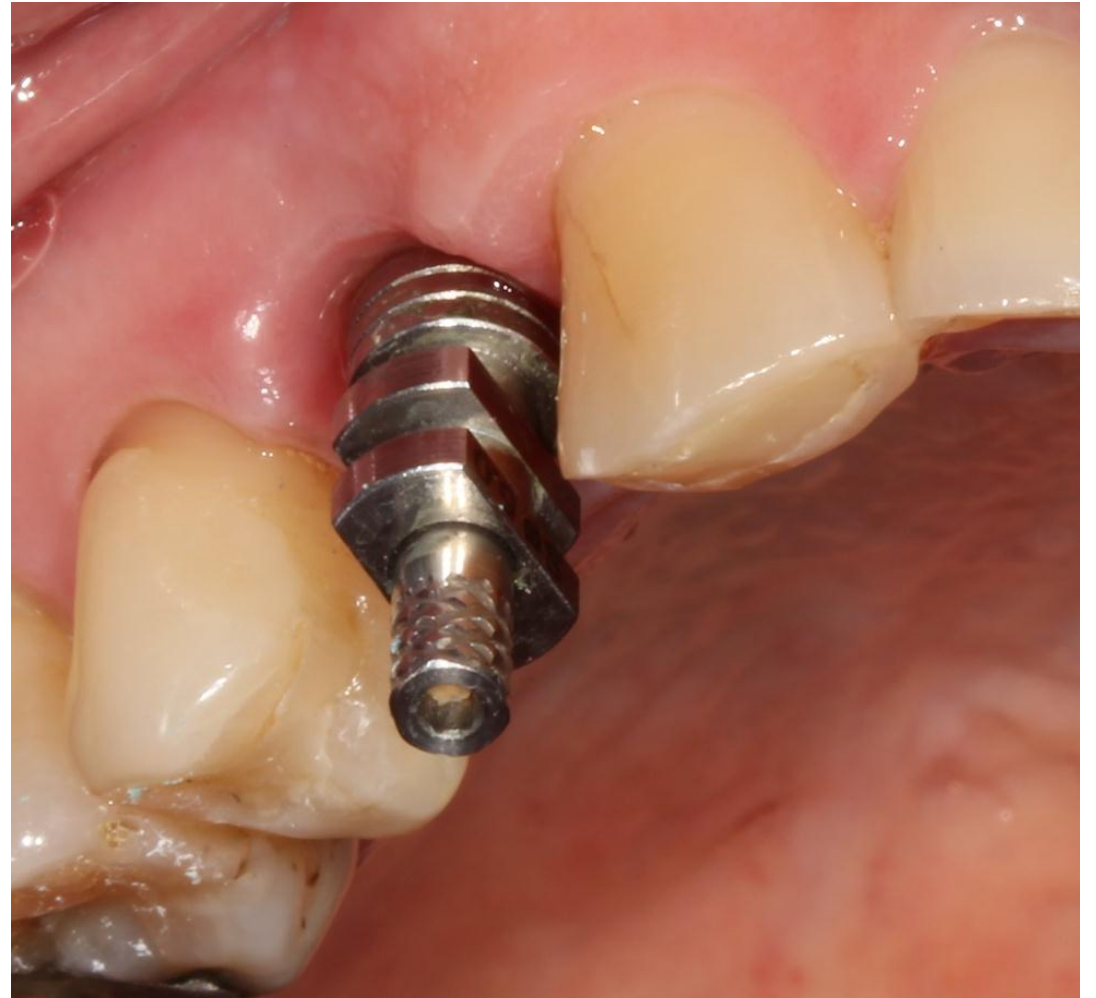Abutment preparation for direct impression technique



Plastic abutment coping for close tray




Impression coping for close tray technique



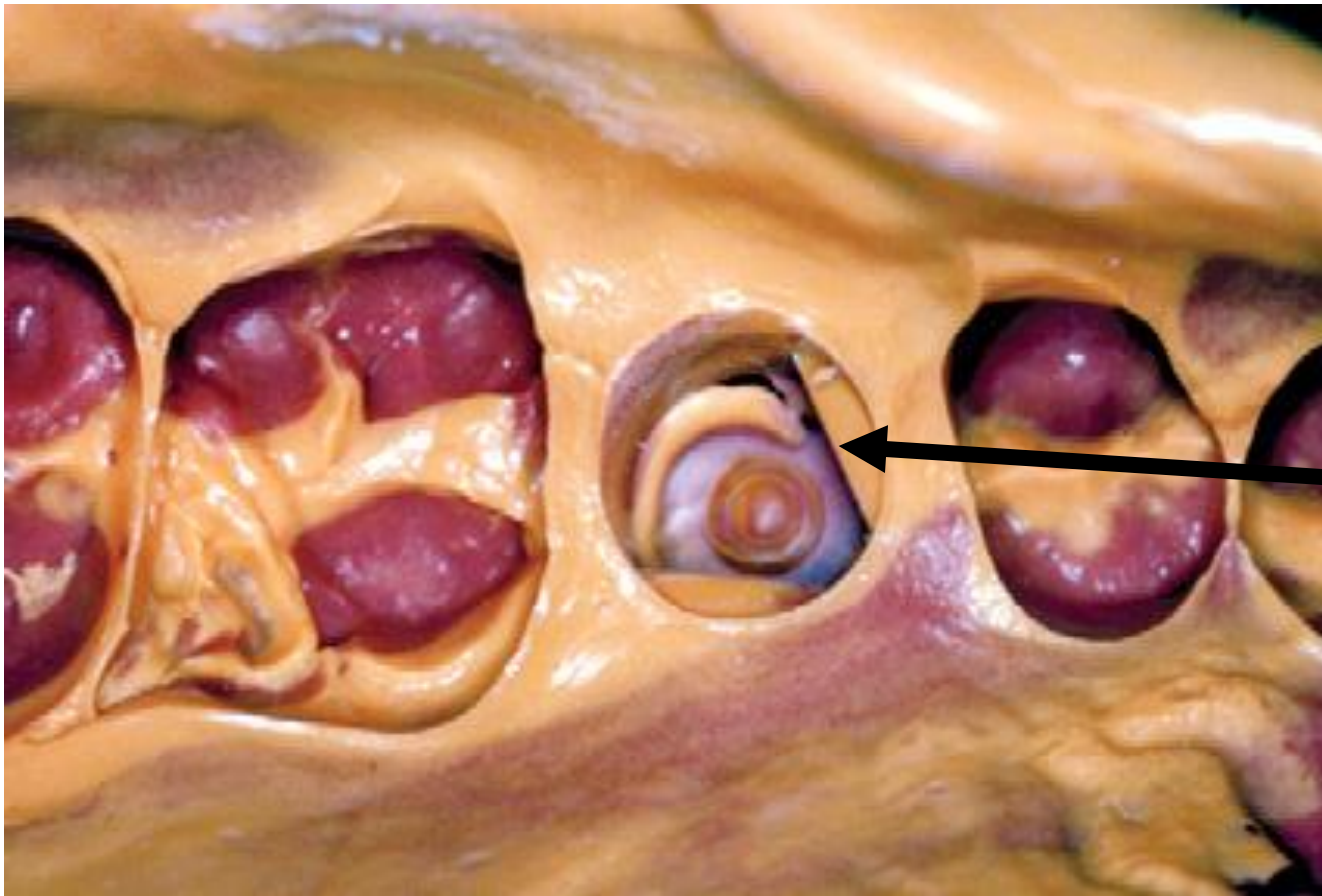
Impression coping for open tray technique

Impression copping not properly seated

Impression copping properly seated



X-ray for checking proper seating of impression copping



Flat surface clearly defined the impression coping direction

Complete impression of close tray technique



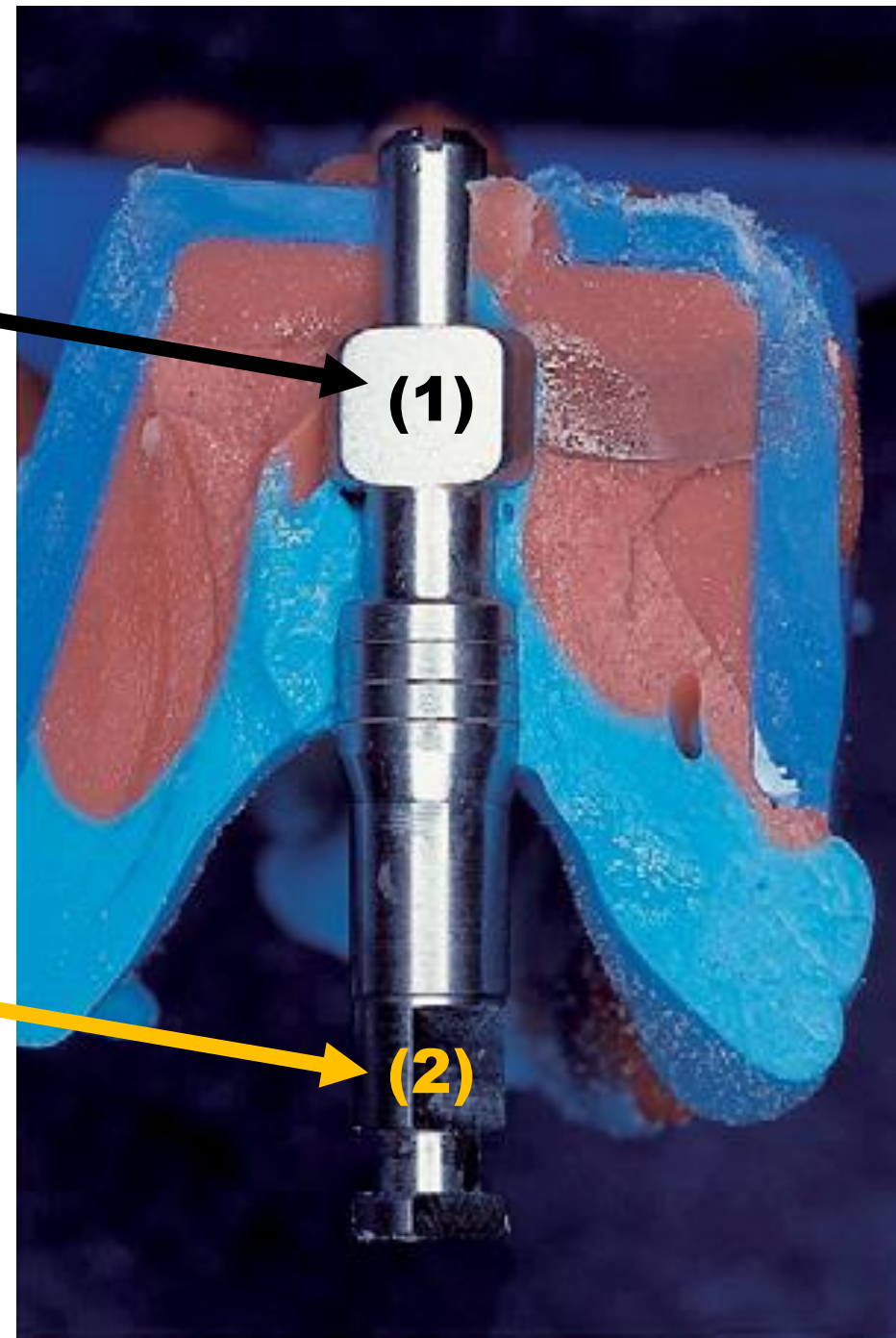
Closed Tray


impression coping



Open Tray

implant analog



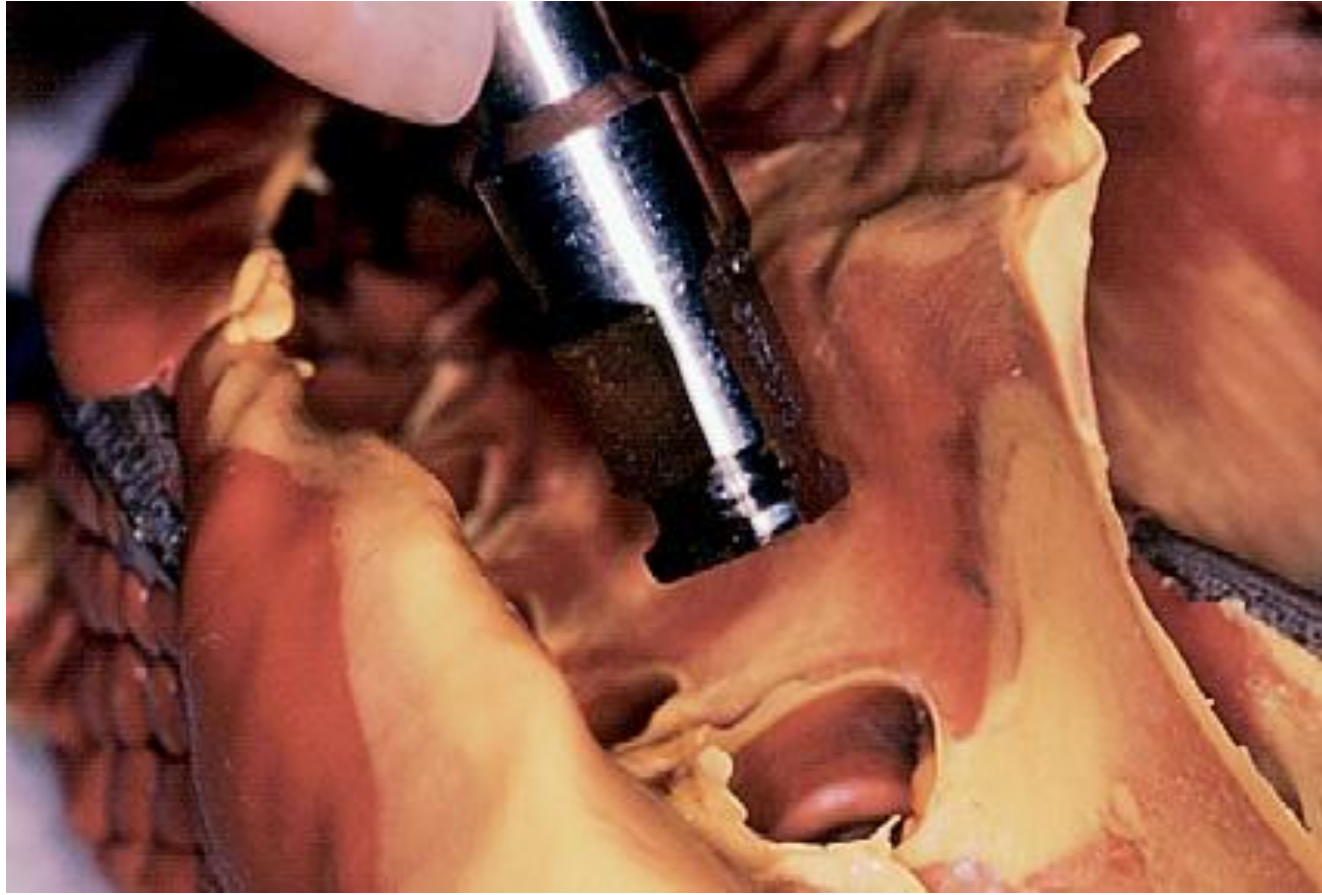

Impression
coping

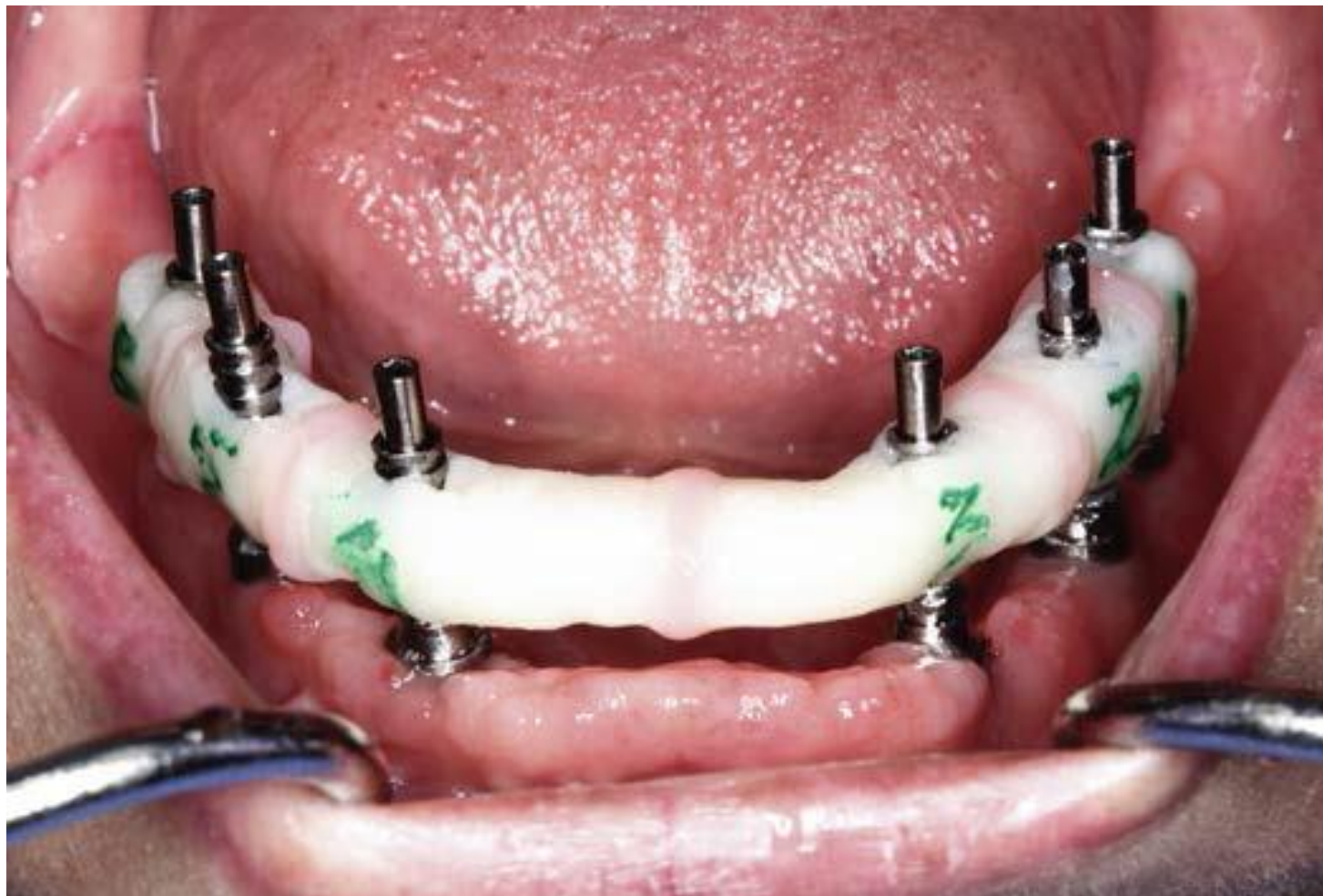Analogue



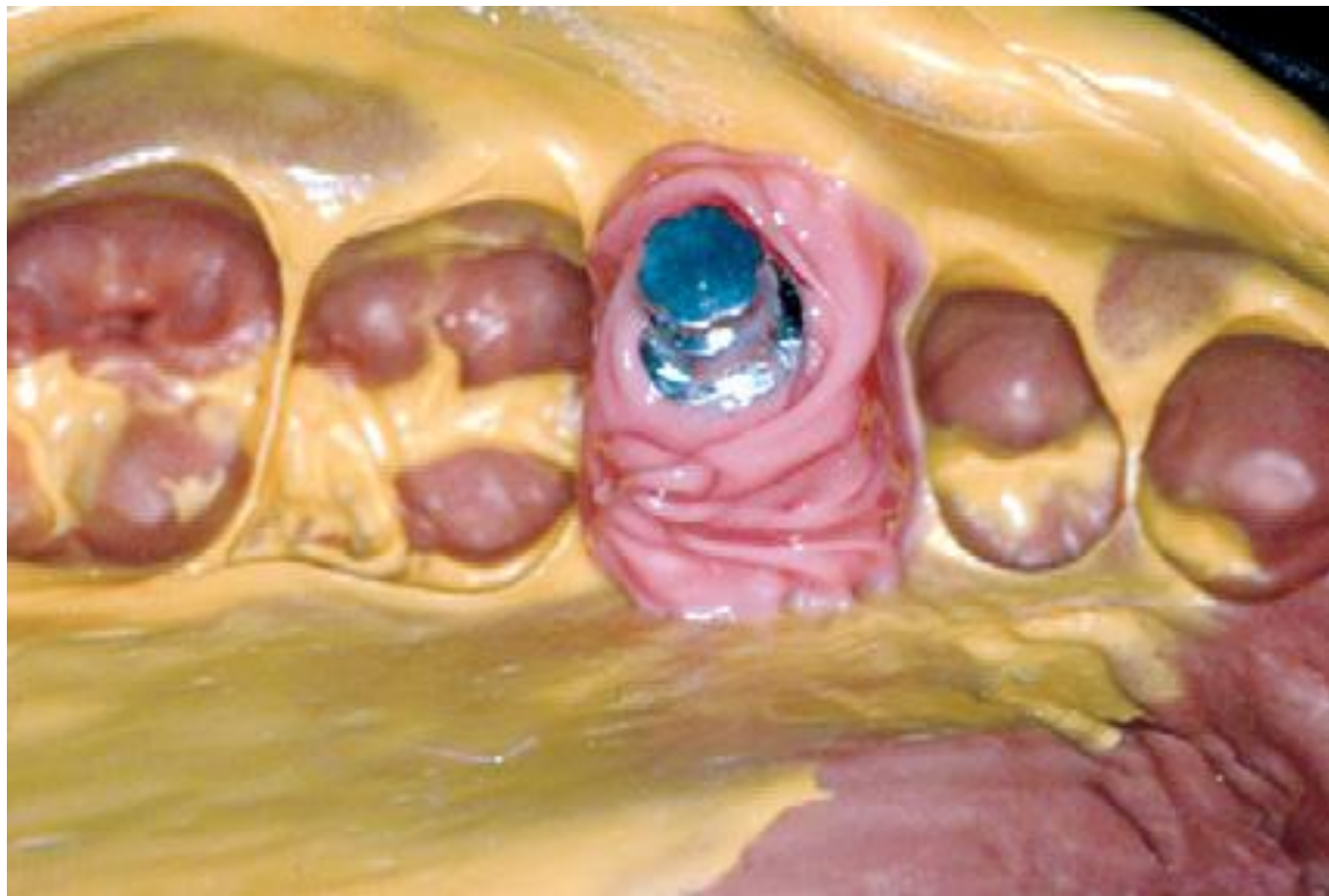Impression coping – analogue complex



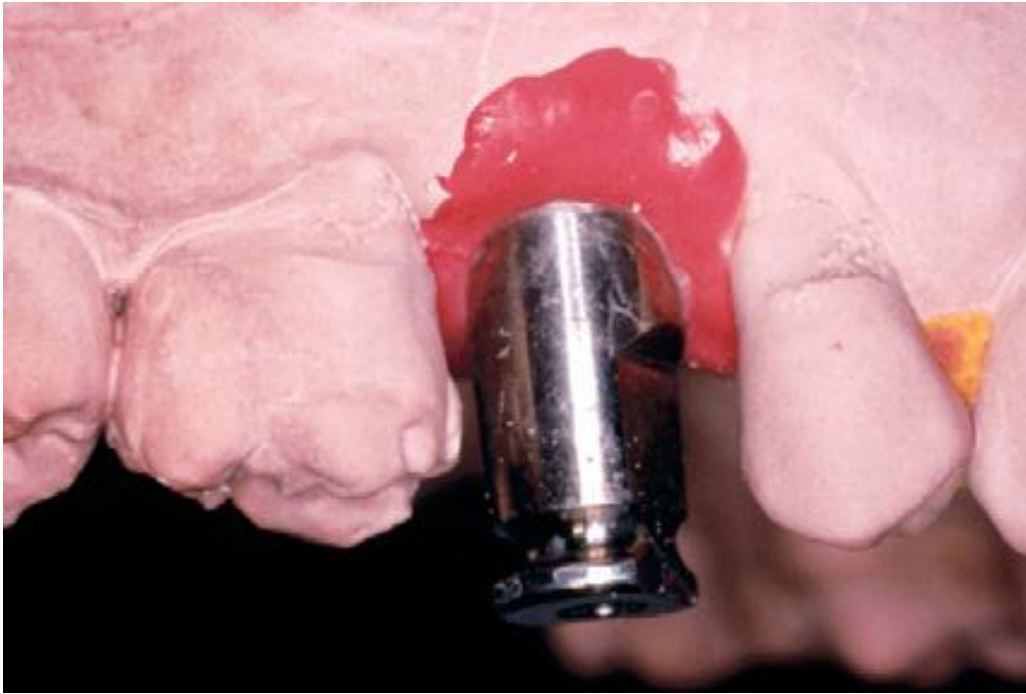
Impression coping/analog complex inserted into the impression with flat sides properly oriented



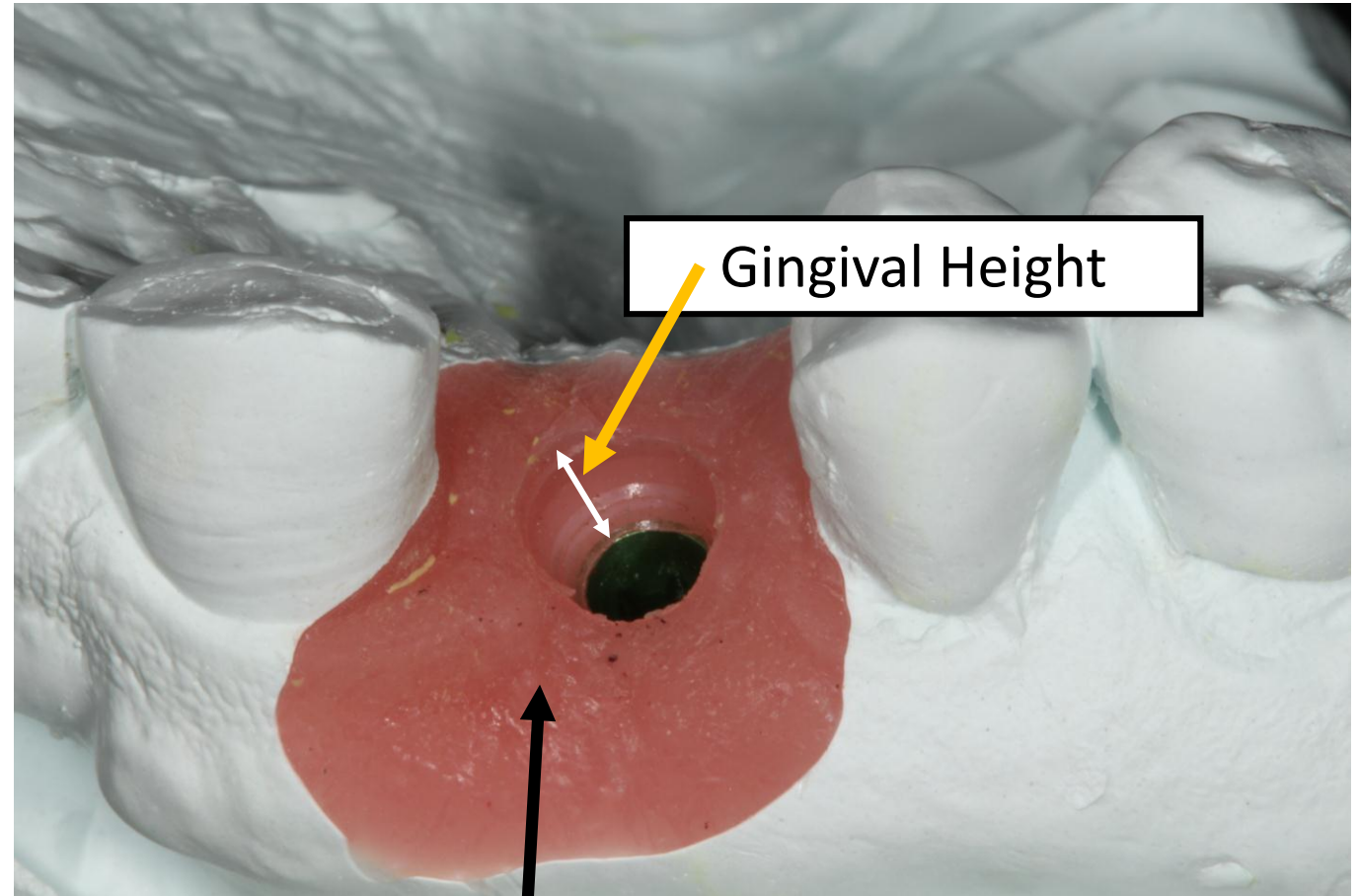
implant verification jig



Gingival mask



Impression coping orients the implant analog to the cast as the implant body is positioned in the mouth.



Gingival mask in the cast

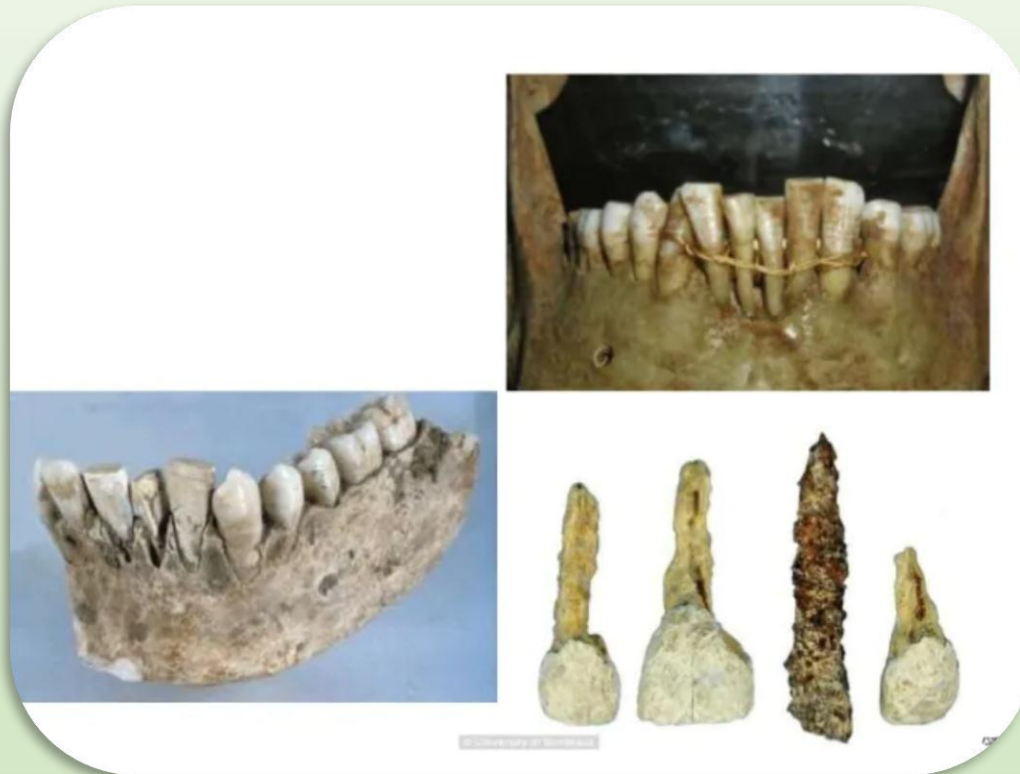Introduction to Dental Implant



15/10/2022

History of dental implant

- Early Historical Developments: In 500 BC, The Etruscans, living in what is now modern Italy, replaced missing teeth with artificial teeth carved from the bones of oxen.



History of dental implant cont.

- Ancient Egyptians used tooth shaped shells and ivory to replace teeth. In the 1700s John Linter suggested the possibility of transplanting teeth of one human into another

History of dental implant cont.

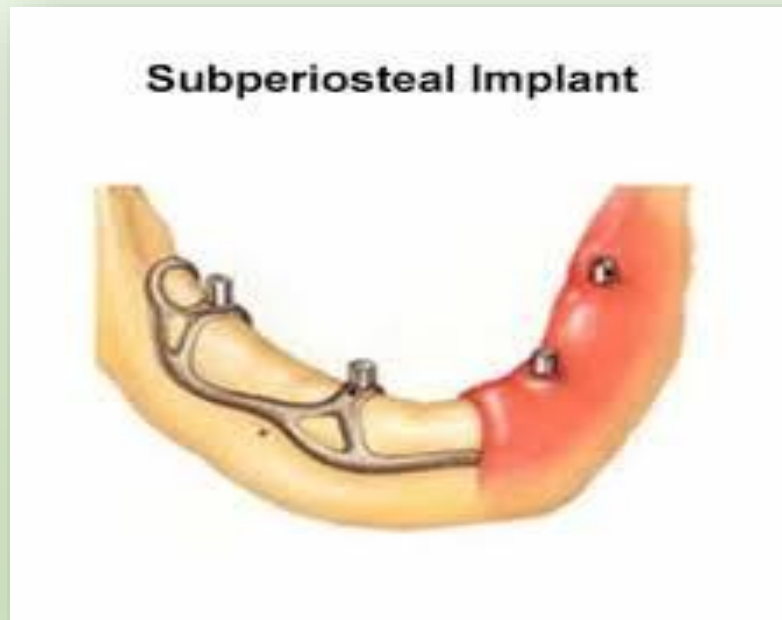- In 1809, Maggiolo fabricated a gold implant which was placed into fresh extraction sockets to which he attached a tooth after a certain healing period.

History of dental implant cont.

- Modern implant dentistry began in the early 19th century. Much experimentation was being done about what material would work best as the replacement tooth. Attempts were first made at implanting natural teeth from another person's mouth, but these implants suffered much infection and were rejected by the host.

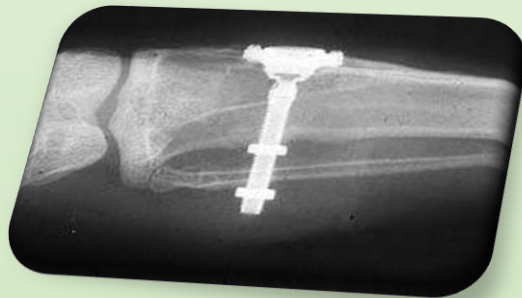History of dental implant cont.

- In 1941, Dr. Gustav Dahl of Sweden provided a retentive mechanism for jaws that were completely edentulous. This was the introduction of the subperiosteal implant.



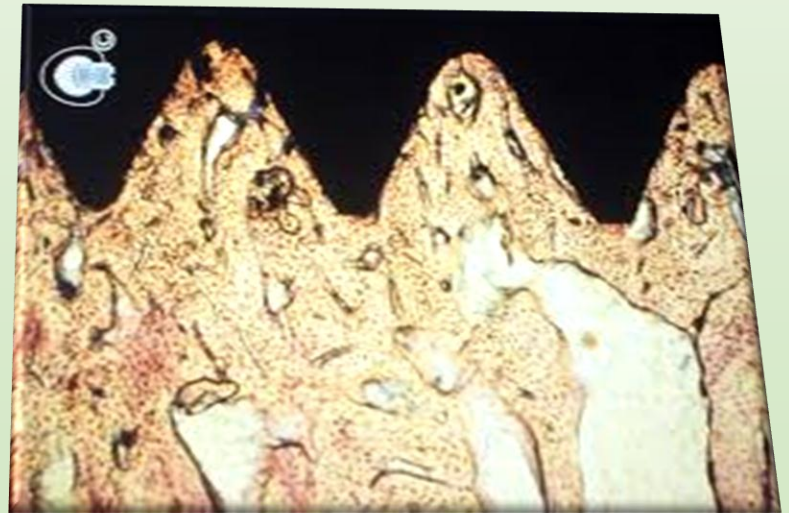
History of dental implant cont.

- **THE BREAKTHROUGH** In 1952, a startling discovery was made which had great implications for Tooth Replacement Therapy. Dr. Per-Ingvar Branemark , an Orthopedic Surgeon, discovered that the hollow titanium rod used in the study was not retrievable when the experiment was complete. Further studies showed that the animal's bone had directly attached to the titanium surface. This phenomenon was called osseointegration.



History of dental implant cont.

- The first practical application of osseointegration was the implantation of new titanium roots in an edentulous patient in 1965. More than thirty years later, the non-removable teeth attached to these roots were still functioning perfectly.

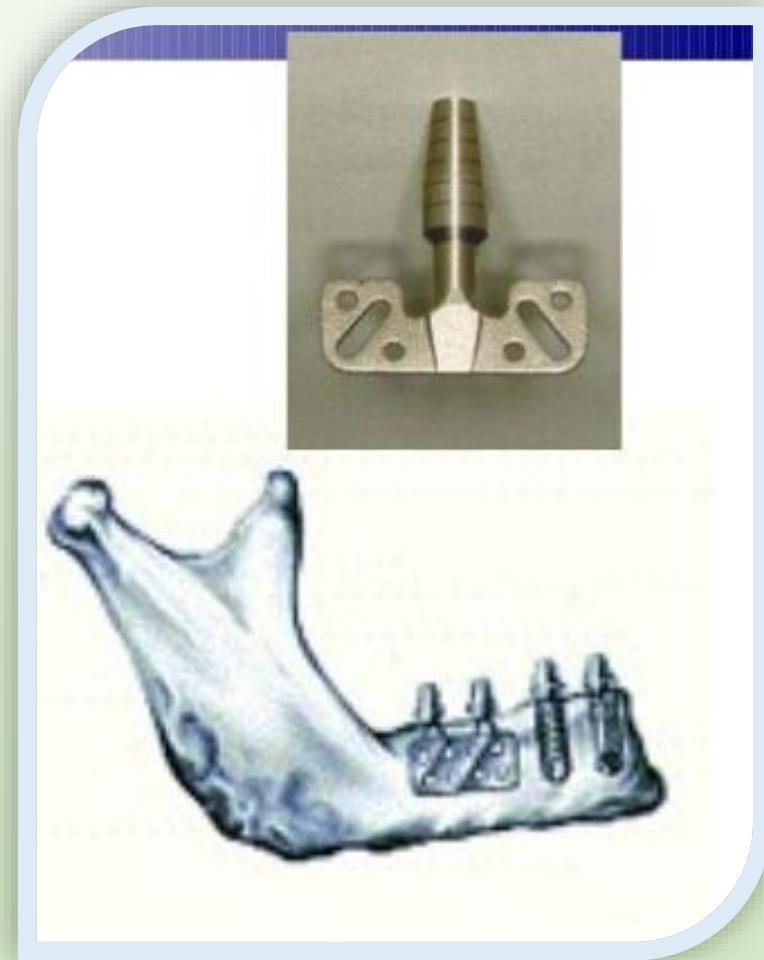


History of dental implant cont.

- In the 1960s, emphasis was placed on making the biomaterials more inert and chemically stable within biologic environments. By 1964, commercially pure titanium was accepted as the material of choice for dental implants, and since that time, almost all dental implants are made of titanium.


History of dental implant cont.

- In 1967, Dr. Leonard Linkow of New York introduced the blade form implant. These blades came in a variety of sizes and forms and were the most widely used type of implant until the 1980s.



History of dental implant cont.

- Niznick in 1980 introduced Core-vent, an endosseous screw implant manufactured with a hydroxyapatite coating. Calcitek corporation began manufacturing and marketing its synthetic polycrystalline ceramic hydroxyapatite coated cylindrical post titanium alloy implant.



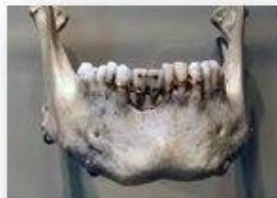History of dental implant cont.

- In 1985, Straumann Company designed plasma sprayed cylinders and screws to be inserted in a one stage operation. In 1988, a National Institute of Health (NIH) consensus development conference on osseointegration in dental implants catalyzed the acceptance and defined the criteria for success.

History of dental implant cont.

- In 1988, National Institutes of Health (NIH) Consensus and American academy of implant dentistry recognize the term “root form” . Branemark devoted 13 years conducting animal studies to determine the parameters under which osseointegration would occur. Based on his study titanium was the made the material of choice.

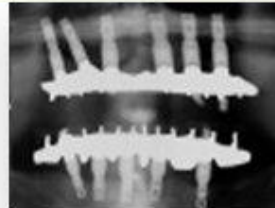The History of Dental Implants




Ancient Egyptians use shells and ivory to replace missing teeth



Roman dental work, a fixed prosthesis.



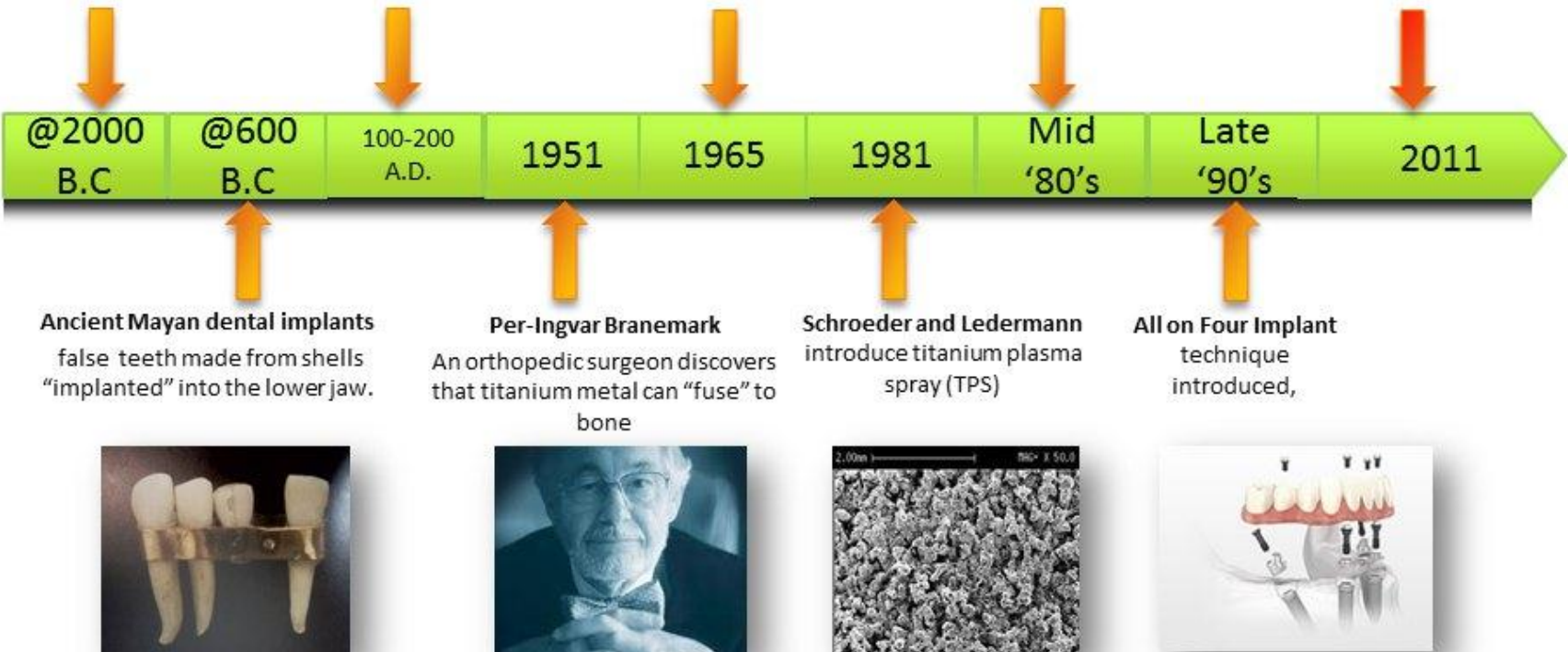
The first titanium "roots" are implanted in a patient



Dr. Stig Hansson: microtexture surface improve load distribution and helps retain crestal bone



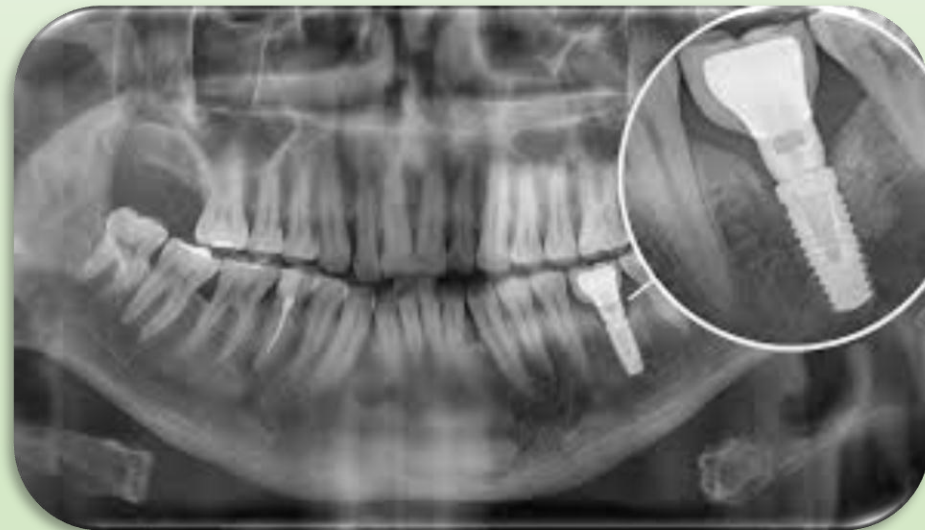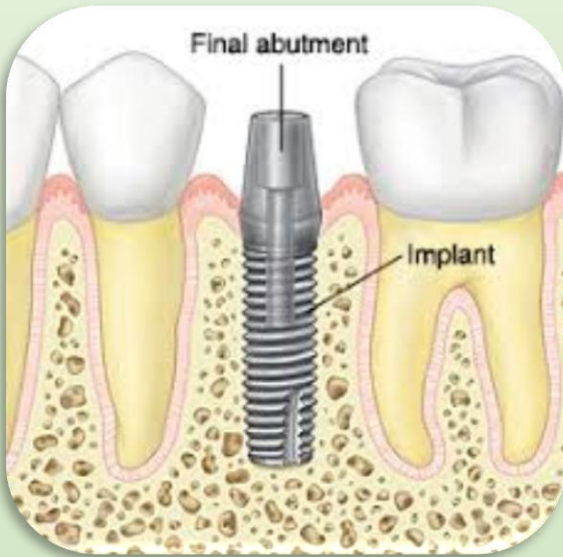Thommen Medical introduces hydrophilic surface which speeds early osseointegration



The science of dental implantology has evolved over centuries to produce the most successful and predictable tooth replacement technology ever.

INTRAORAL IMPLANT TERMINOLOGY

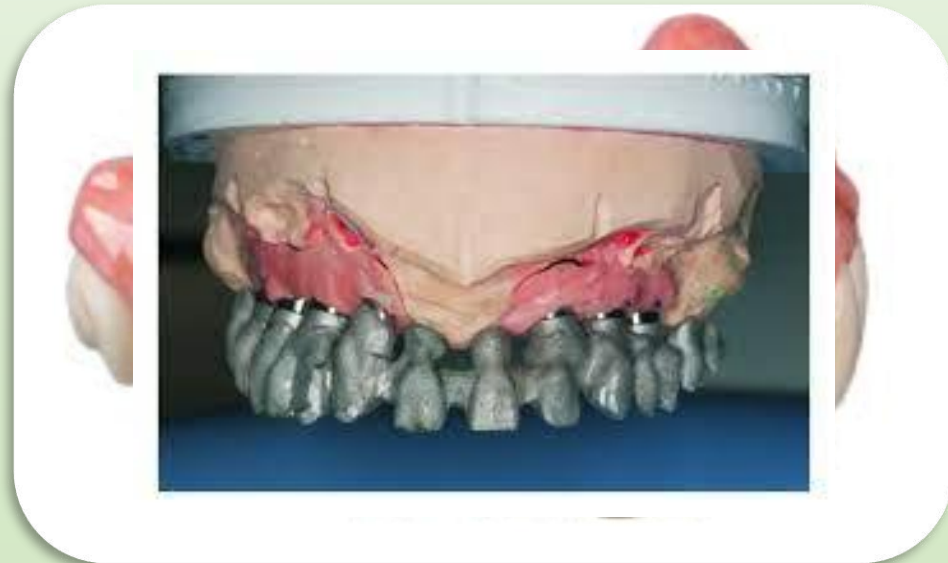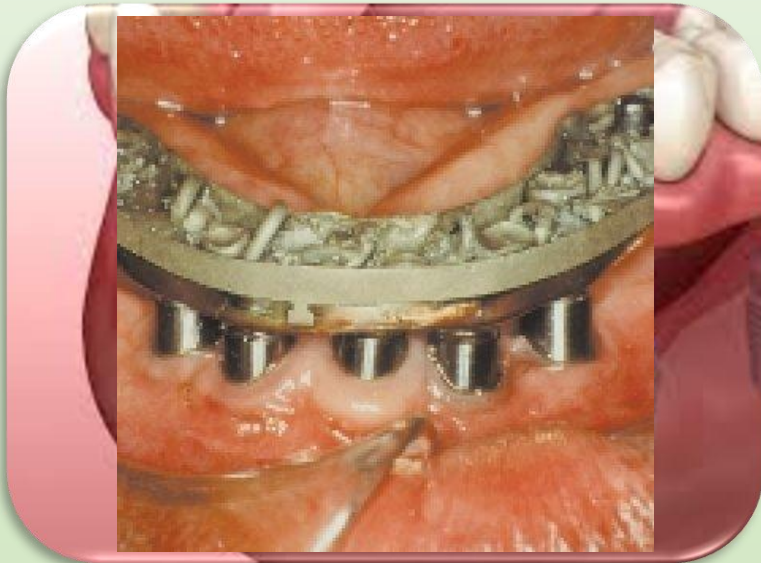
- **Implant:-** “A graft or insert set firmly or deeply into or onto the alveolar process that may be prepared for its insertion”.
- **Abutment:-** “A tooth or portion of an implant which protrudes through the mucosa into the oral cavity for the retention or support of a crown or a fixed or removable denture prosthesis



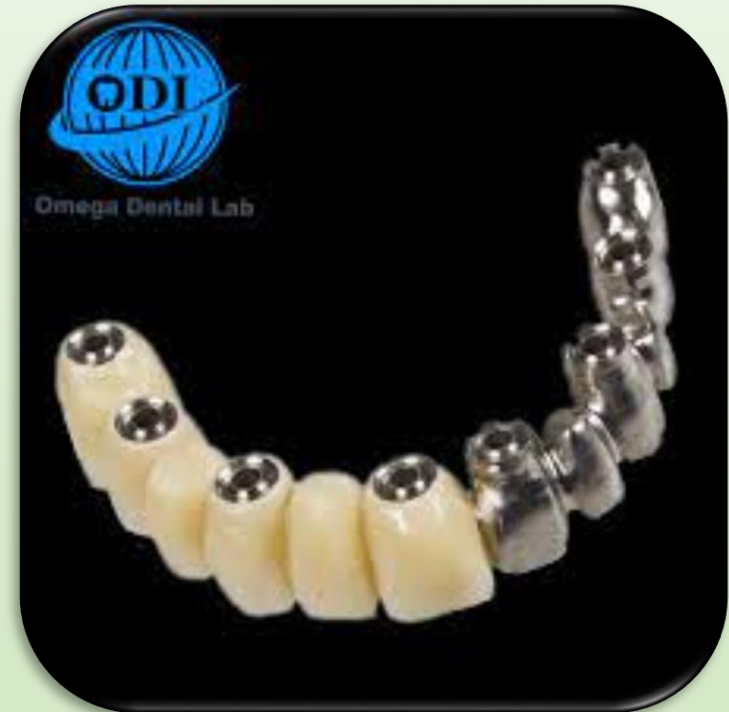➡ Oral Implantology:

“A specialized field of dentistry, dealing with the placement and restoration of dental implants”.

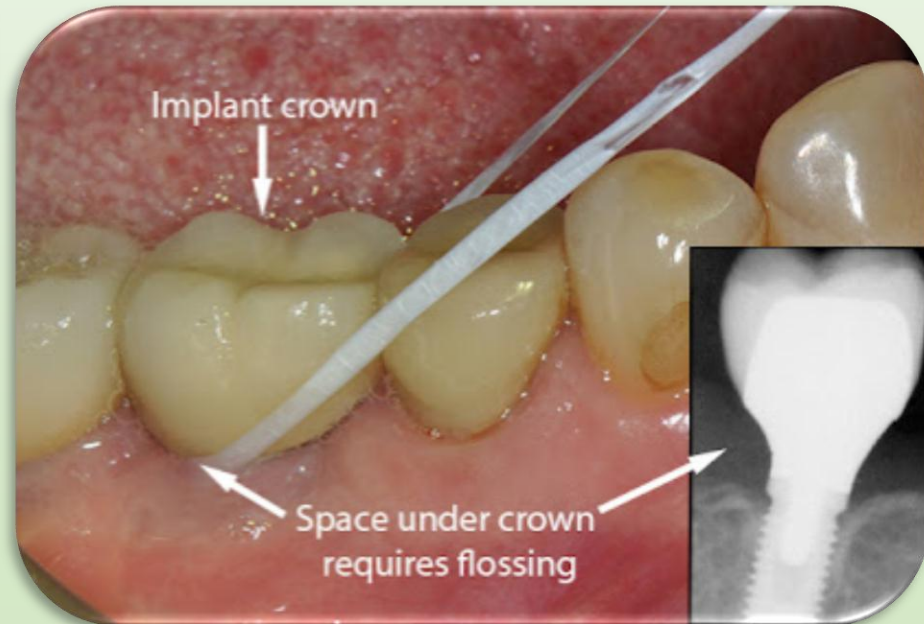
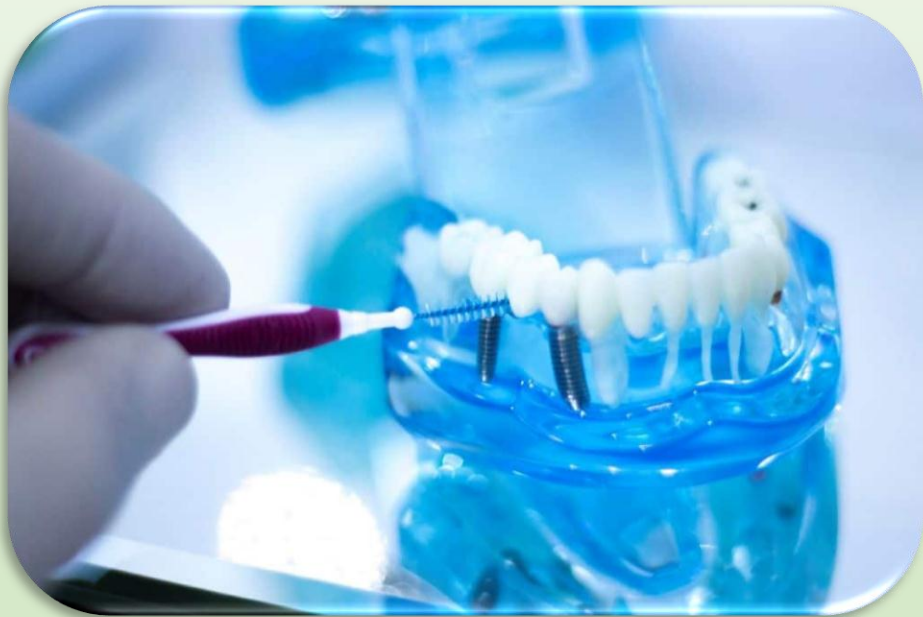- **Implant denture**:- “A denture which receives its ability and retention from the substructure which is partially or wholly implanted under the soft tissue of the denture base seat”.
- **Dental substructure**:- “The metal framework which is beneath the soft tissues and in contact with bone for the purpose of supporting an implant denture superstructure”.



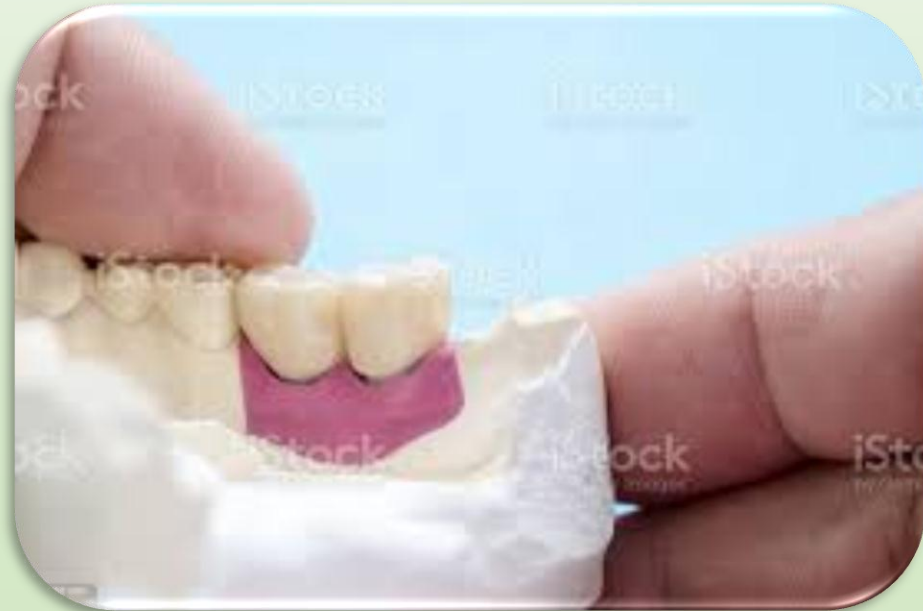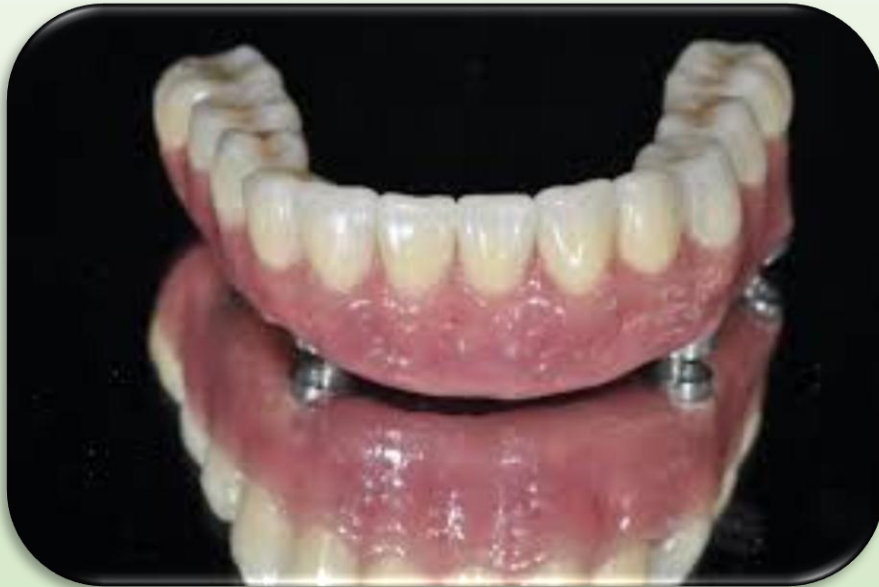- **Dental superstructure**:- “The metal framework which is retained and stabilized by the implant denture substructure”.
Edentulous (fully and partially) :- “Simply stated, fully edentulous refers to an individual that has no teeth at all in either the upper or lower jaw. Partially edentulous refers to missing one or more teeth”.



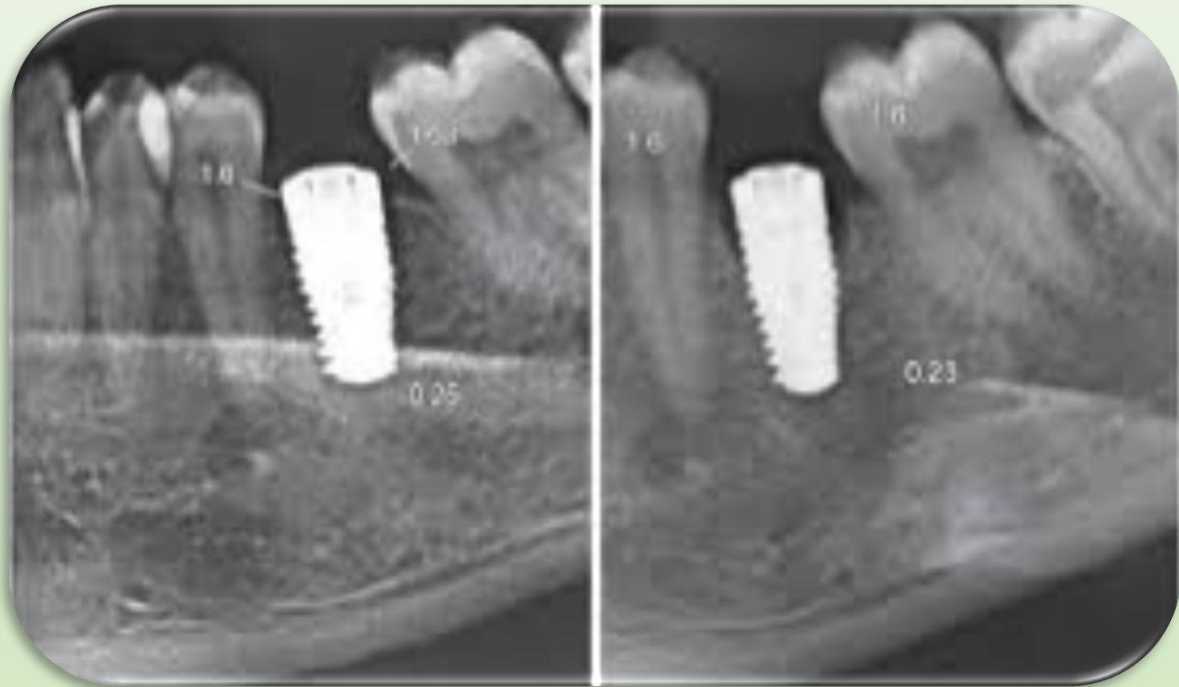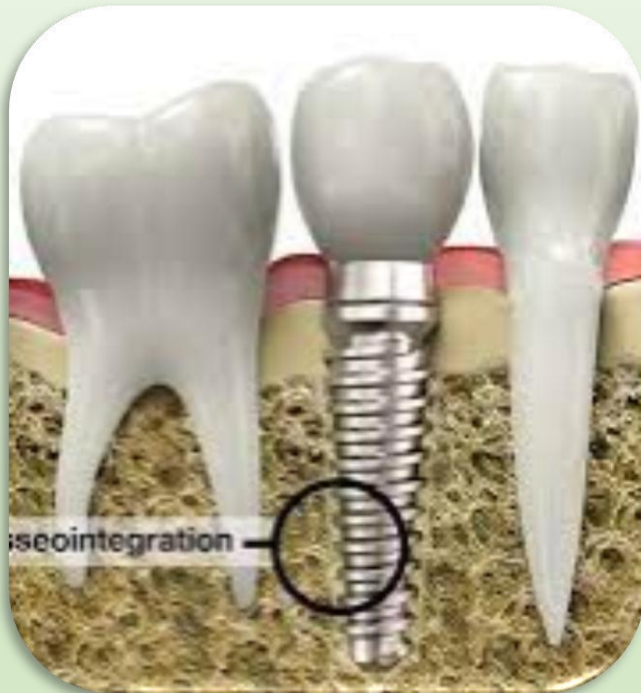- **Implant hygiene** :- “In as much as good oral hygiene habits are important; in implant dentistry they are even more important. The design of the teeth that are fixed to the implant is critical to allow the patient easy access to cleaning”

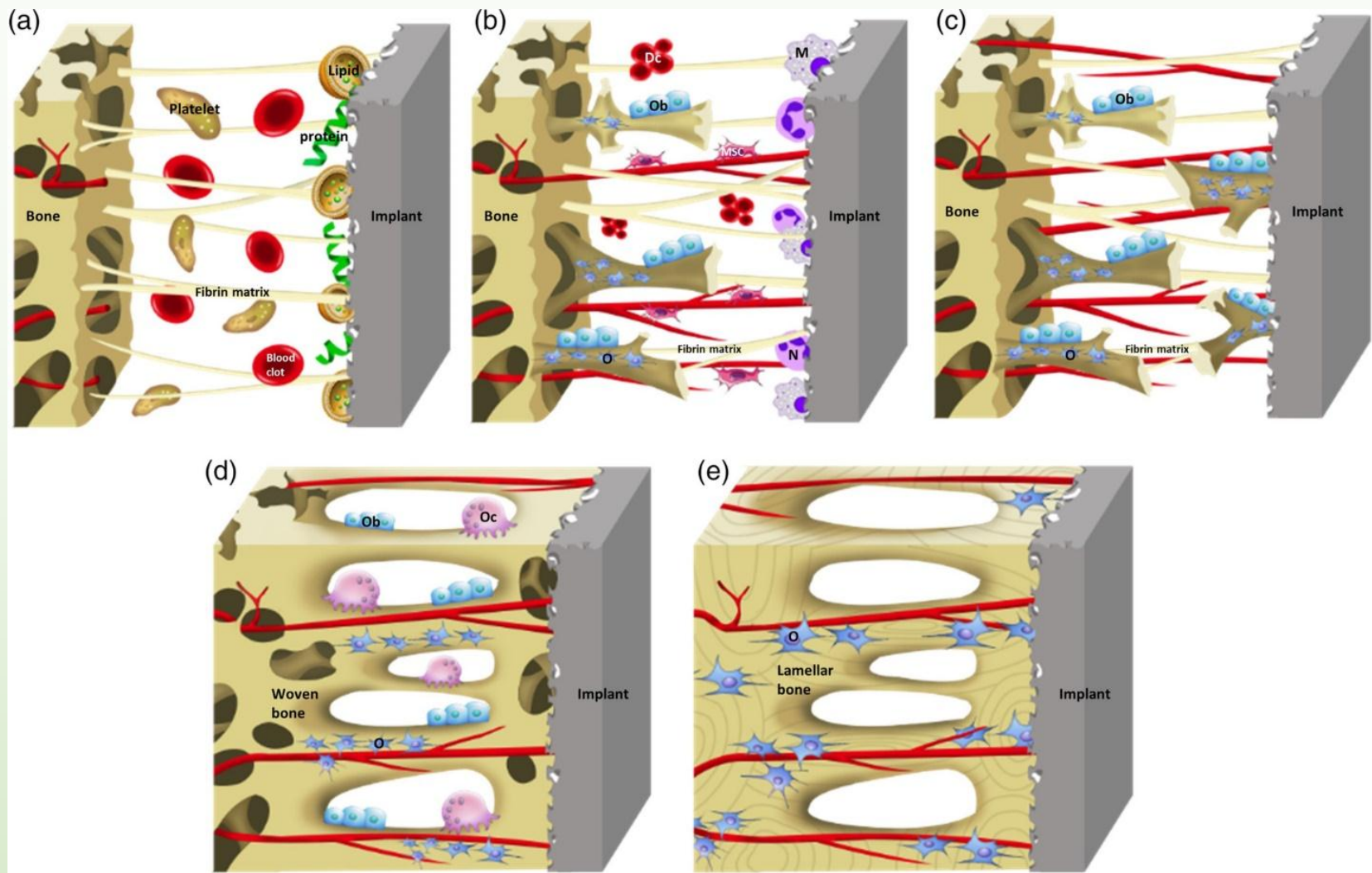


- **Implant prosthodontics** :- “This is a branch of implant dentistry that is concerned directly with the restorative phase following implant placement and the overall treatment plan before and after the placement of dental implants”



- **Osseointegration:-** “A condition that exists when a titanium implant is inserted, screwed or pressed into living bone. The result is a biological bond of living bone to the titanium implant. In essence, the two become one”





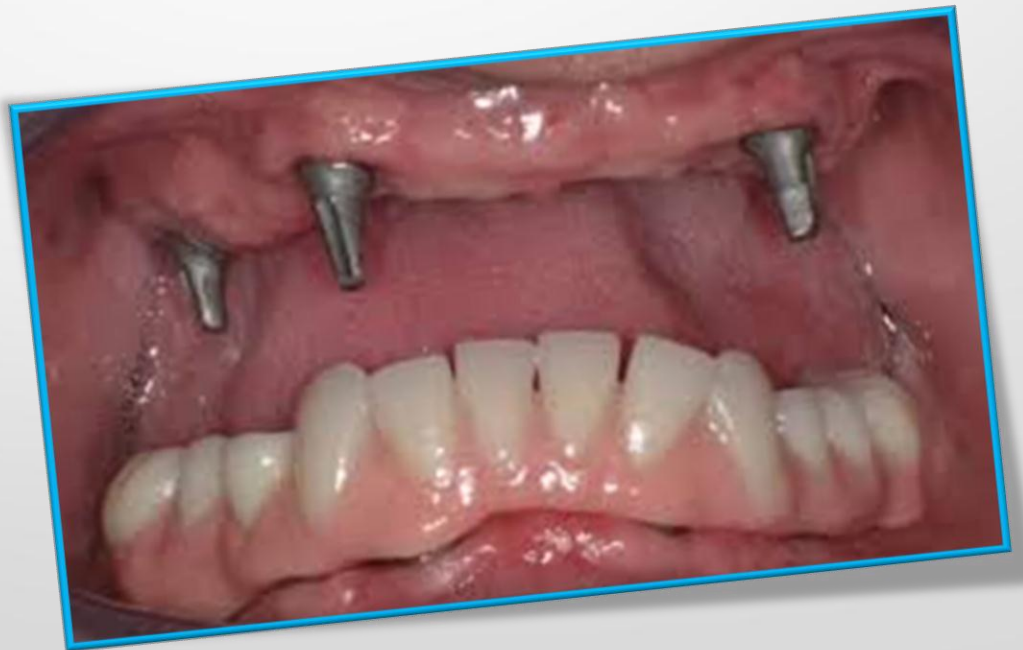. The process of OI includes the formation of the blood clot and fibrin matrix (a). Angiogenesis and woven bone formation (b). Distance osteogenesis and contact osteogenesis (c). Newborn woven bones fill up the gap and bone remodeling (d). Woven bones transform into lamellar bones (e). Dc, decomposed clot; M, macrophage; MSC, mesenchymal stem cell; N, neutrophil; O, osteocyte; Ob, osteoblast; Oc, osteoclast;

Indication and Contraindication of Dental Implant

Dental Implant Lecture 2

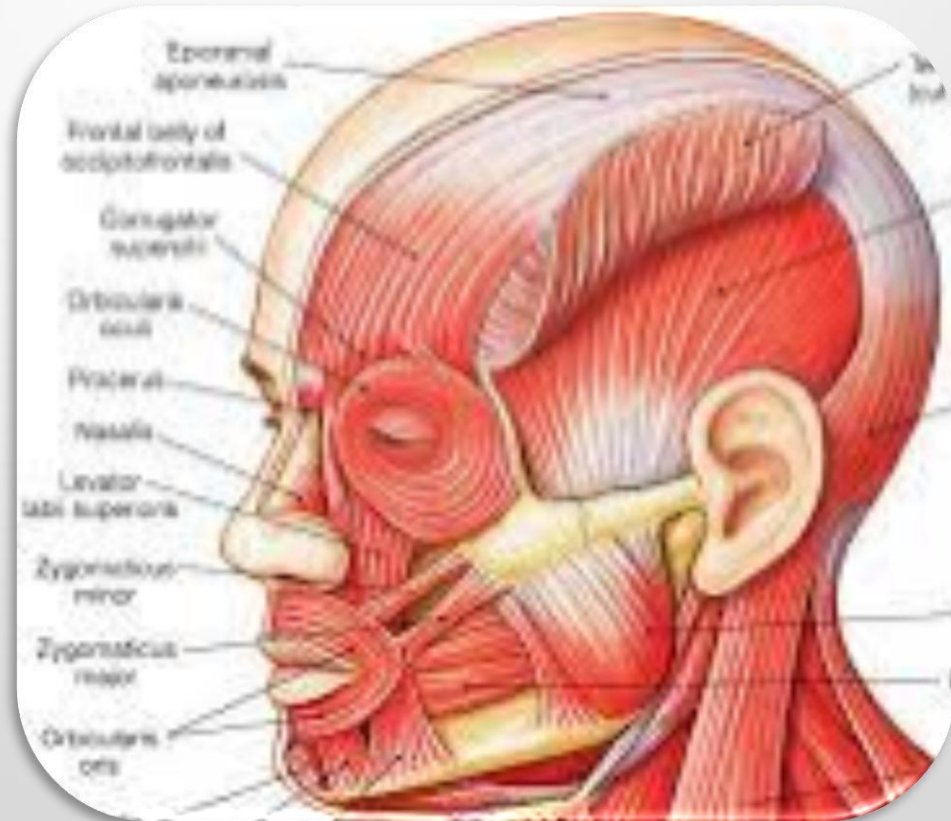Indication

- 1. Generally any edentulous area can be an indication for dental implants.
- 2. Severe morphologic compromise of denture supporting areas that significantly undermine denture retention.

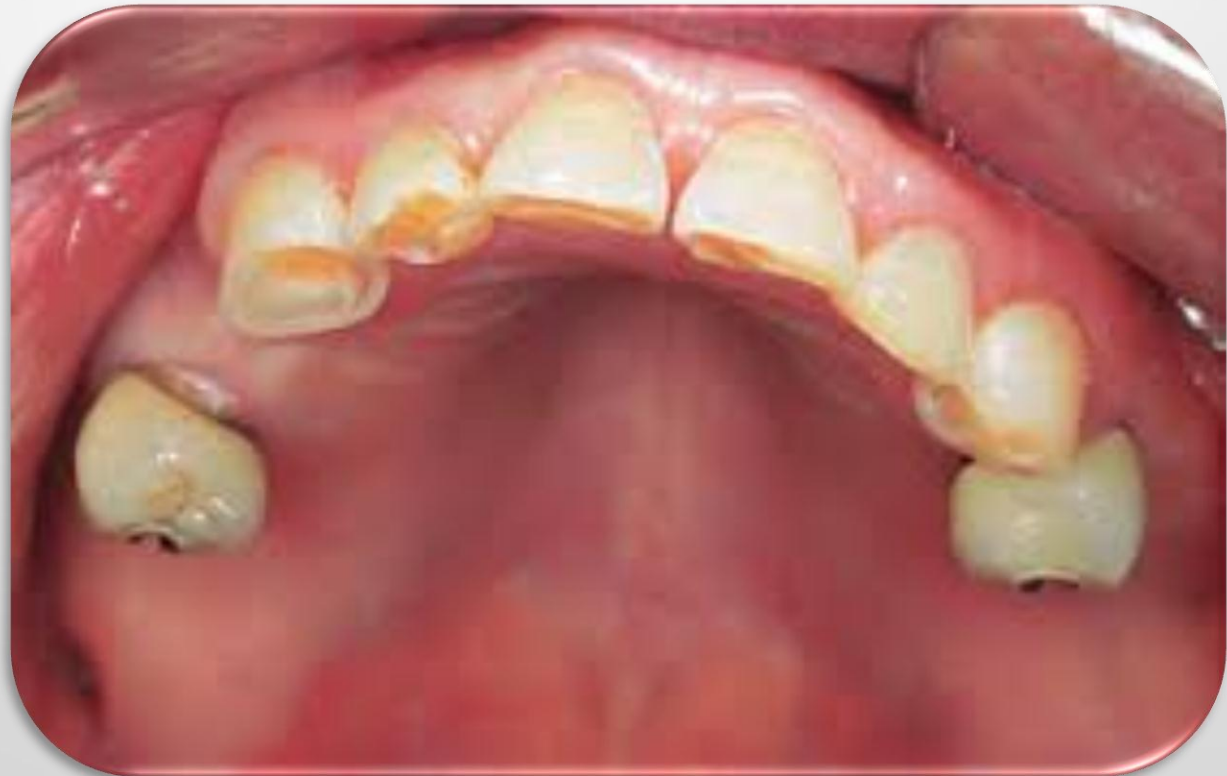

Indication

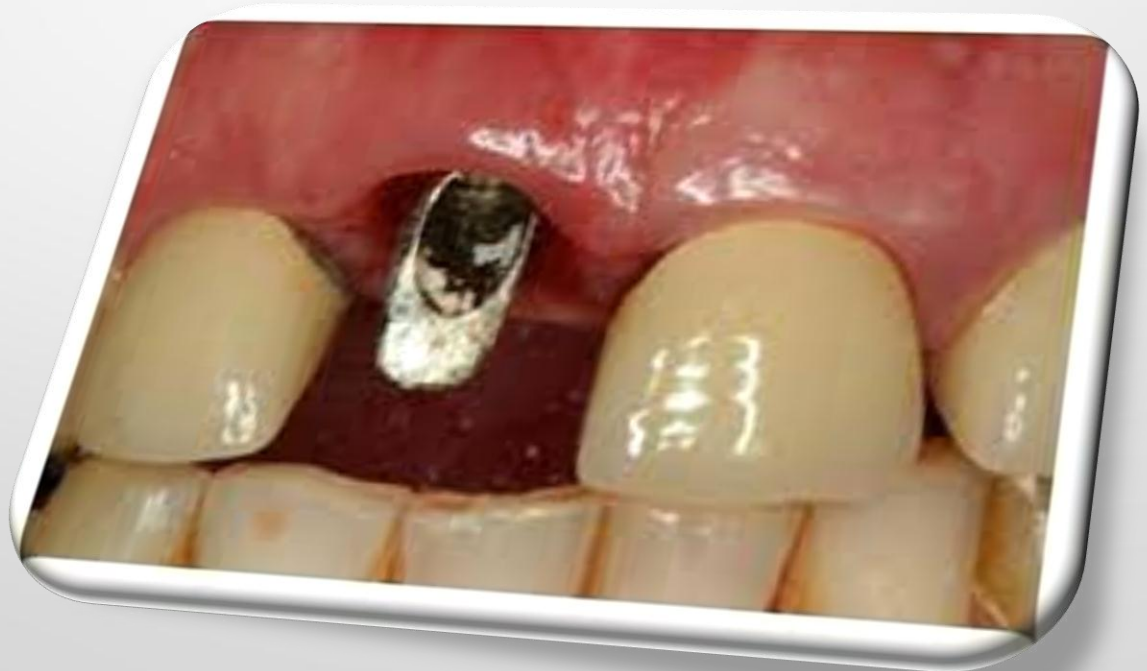- 3. Poor oral muscular coordination.
- 4. Low tolerance of mucosal tissues. Para-functional habits leading to recurrent soreness and instability of prostheses.
- 5. Active or hyper active gag reflexes, elicited by a removable prosthesis.



- 6. Psychological inability to wear a removable prosthesis even if adequate denture retention and stability is there.
- 7. Unfavorable number and location of potential abutments in a residual dentition.



- 8. Single tooth loss to avoid involving neighboring teeth as abutments.



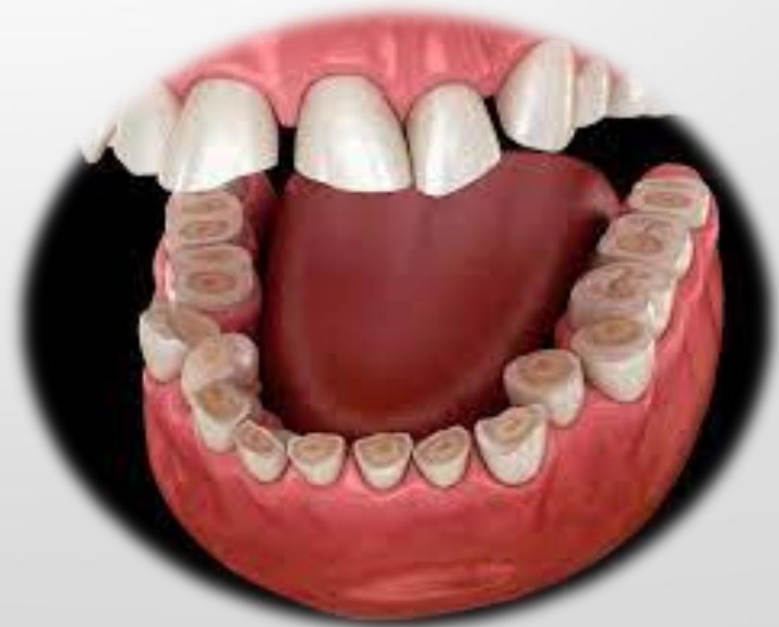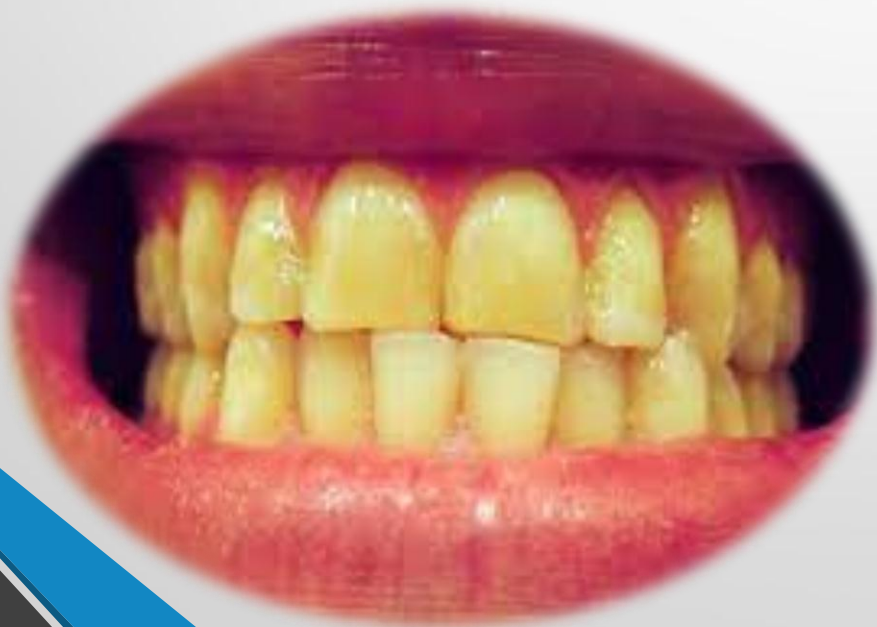Contraindications

1. Acute illness.
2. Terminal illness.
3. Pregnancy.
4. Uncontrolled metabolic disease.
5. Tumoridal radiation including the implant site.
6. History of intravenous bisphosphonate therapy.
7. Unrealistic expectation.

Contraindications

- 8. Improper motivation .
- 9. Lack of operator experience .
- 10. Unable to restore teeth prosthodontically .
- 11. Inability of patient to manage oral hygiene.
- 12. Patient hypersensitivity to specific components of the implant.

- 13. Bruxism (tooth clenching or grinding) is another consideration which may reduce the prognosis for treatment. The forces generated during bruxism are particularly detrimental to implants while bone is healing.

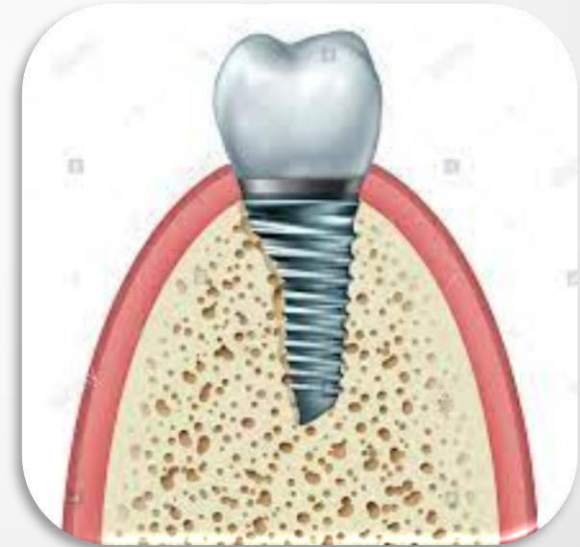


INDICATIONS FOR EACH IMPLANT TYPE ARE SPECIFIED BELOW:

1- ENDOSSEOUS:

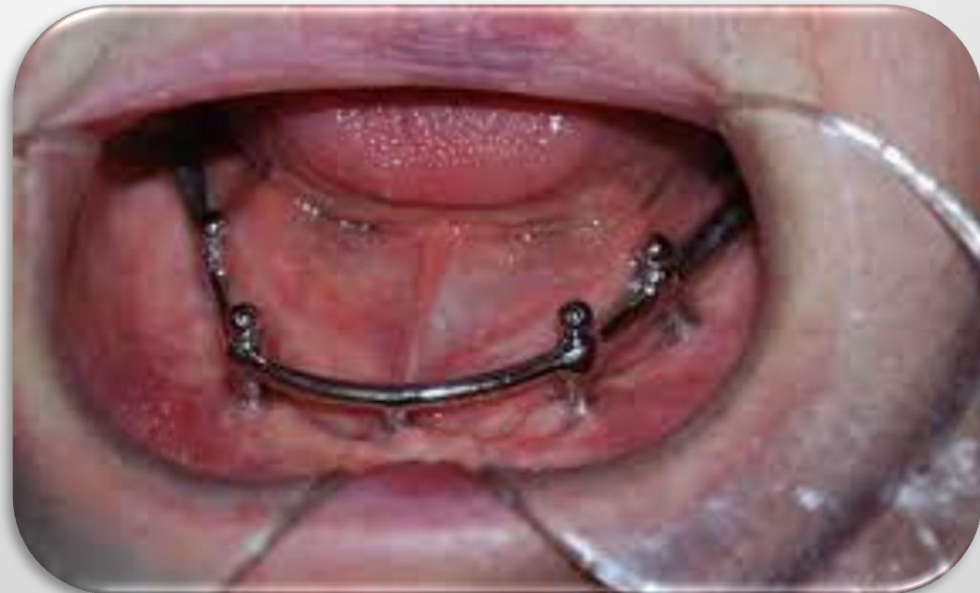Root form, blade (plate) form:

- o Adequate bone to support the implant with width and height being the primary dimensions of concern.
- o Maxillary and mandibular arch locations.
- o Completely or partially edentulous patients



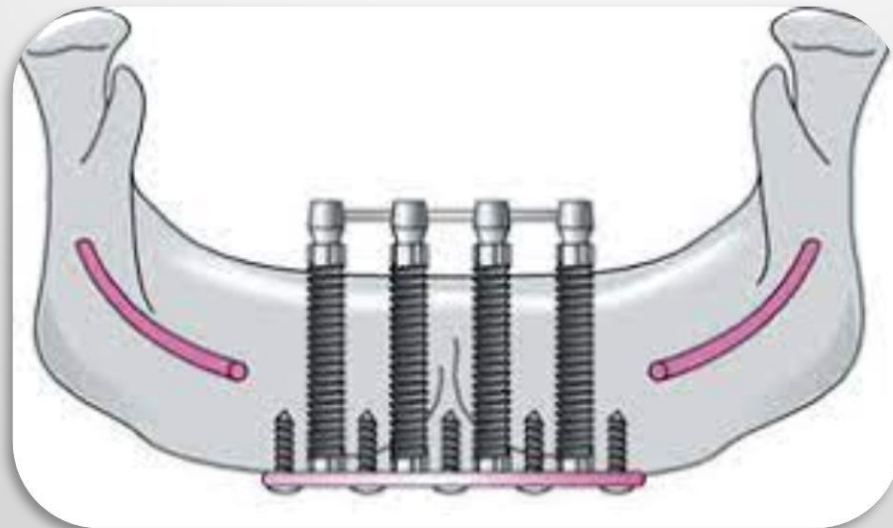
2- SUBPERIOSTEAL:

- (complete, unilateral, circumferential):
- o Atrophy of bone but with adequate bone to support the implant.
- o Maxillary and mandibular arch locations.
- o Completely and partially edentulous patients.
- o Stable bone for support.



3- TRANSOSSEOUS:

- (staple, single pin, multiple pin):
- o Adequate anterior bone to support the implant with width and height being the primary dimensions of concern.
- o Anterior mandibular arch location.





Osseointegration

Factors Affecting Osseointegration

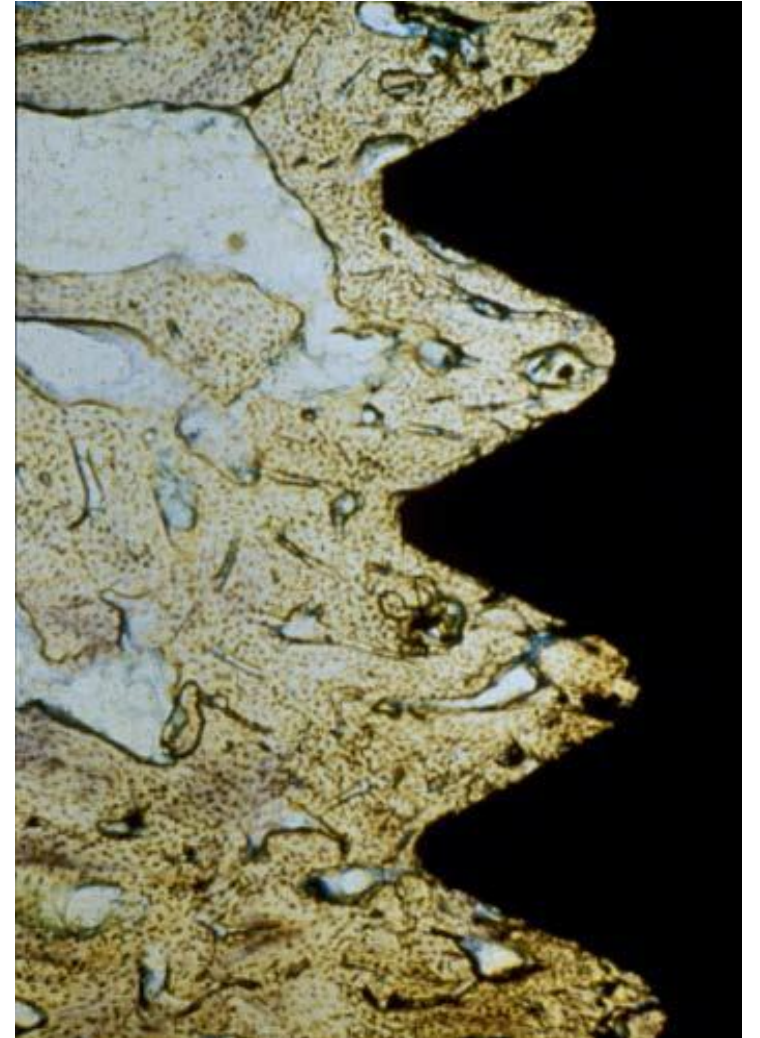
29/10/2022

Abdulrahman

Osseointegration

is a direct contact between an implant and living bone at the light microscope level.

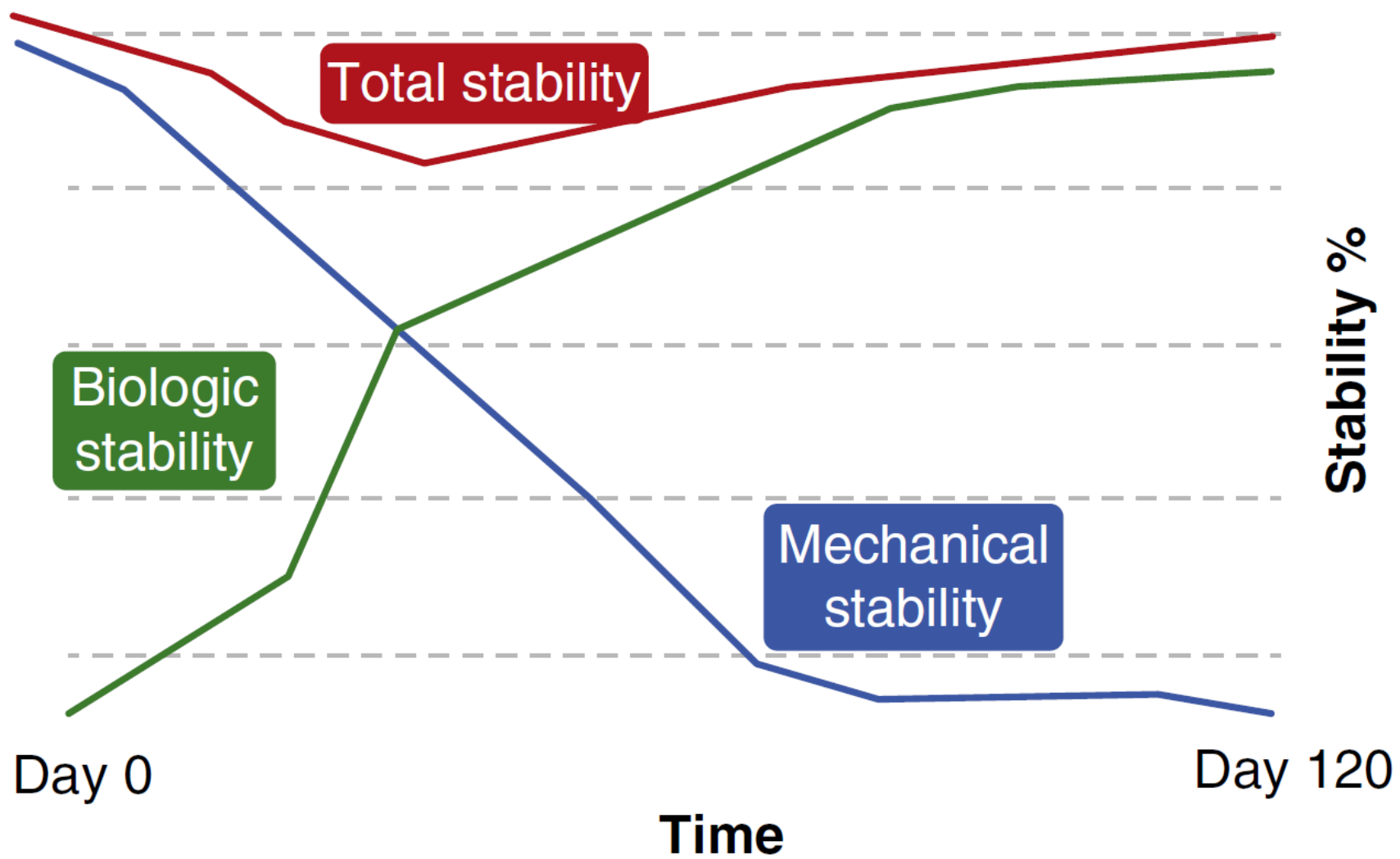
Osseointegration is also referred to as secondary stability.



Osseointegration

Primary stability: which is an initial level of mechanical or frictional stability in the bone. As the bone heals, the process of osseointegration produces secondary stability, which is responsible for the long-term success of the implant. During the bone remodeling process after implant placement, primary stability decreases while secondary stability increases from new bone formation.

Stability of implant over time



After a surgical procedure is performed on patient to insert an implant into the bone, after which a poorly organized **woven bone** is formed at the interface, thus having a relatively low inherent strength.

After a period of 3 to 6 months, woven bone is replaced by **lamellar bone** which possess adequate strength for load bearing. This bone healing process is known as osseointegration.

Criteria for an implant to be regarded as clinically successful:

- 1. The unattached implant exhibits no clinical mobility.**
- 2. Radiography demonstrates no evidence of radiolucency between implant and bone.**
- 3. Marginal bone loss is less than 0.2 mm annually after the first year of service.**
- 4. Absence of persistent pain, discomfort, or infection.**

Factors Affecting Osseointegration

Implant related factors

- 1. Material.*
- 2. Shape.*
- 3. Surface chemistry.*

Other factors

- 1. Mechanical loading.*
- 2. Surgical technique.*
- 3. Patient variables such as bone quality and quantity*

Implant related factors

1. Material.

Titanium is a metal that presents excellent biocompatibility

**Cobalt-Chromium-Molybdenum based alloys When properly fabricated,
implants from this alloy group have shown to exhibit excellent biocompatibility**

Implant related factors

2. Shape.

Macrogeometry

The larger the taper, the greater the component of compressive load delivered to the interface

Implant width Implant length

shorter and smaller diameter implants had lower survival rates than their longer or wider counterparts



Fig 1

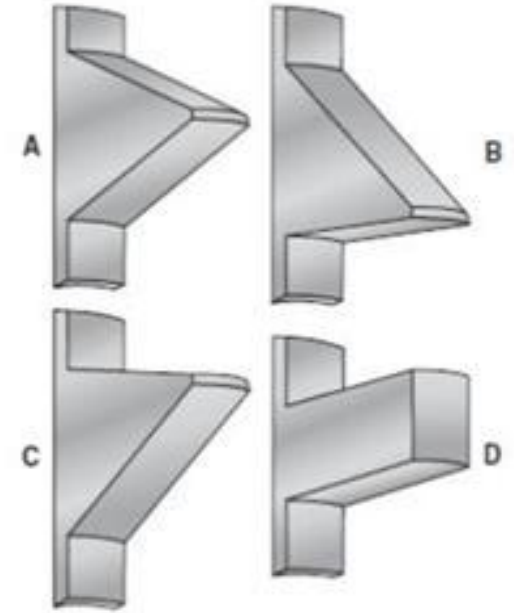


Fig 2

The square thread had less stress in compressive and more importantly shear forces

Implant related factors

3. Surface chemistry.

Microdesign

Surface modification is achieved through additive or subtractive processes. surface oxidation creates a passivation layer of titanium oxides which have ceramic like properties making it very compatible with tissues.

Basic loading protocols: Mechanical loading.

1. ***Conventional loading:*** Restoration occurs after the initial bone and soft tissue healing process, usually in 3 to 6 months, depending on bone density.
2. ***Immediate loading:*** A prosthesis is connected at the time of implant placement. This is usually a provisional restoration that is replaced with a definitive restoration after implant and soft tissue healing.
3. ***Early loading:*** The prosthesis connection occurs from 2 to 3 weeks after implant placement. This is considered to be a less predictable loading protocol because the restoration is sometimes placed during the stability dip, which is the period of lowest implant stability.
4. ***Delayed loading:*** The prosthesis is connected 6 to 12 months after implant placement. This method is often chosen in poor quality bone and in situations in which primary stability cannot be achieved during surgical placement.

The success of any implant procedure is dependent on:

- 1. Biocompatibility of the Implant material.**
- 2. Macroscopic and microscopic nature of the implant surface.**
- 3. The status of the implant bed in both a health (non-infected) and a morphologic (bone quality) context.**
- 4. The surgical technique.**
- 5. The undisturbed healing phase.**
- 6. The subsequent prosthetic design and long term loading phase.**

Implant Materials

Lecture 4

5/NOV/2022

CRITERIA OF THE MATERIALS SUITABLE FOR DENTAL IMPLANTS AND THEIR PROSTHETIC COMPONENTS

A- Biocompatibility: The material must be capable of functioning indefinitely without causing damage of the surrounding bone and tissues.

- Titanium alloys, mostly titanium alloyed with varying amounts of aluminum, vanadium, niobium, and zirconium.
- The most often used titanium alloy is grade 5 titanium, which contains 6% aluminum and 4% vanadium as alloying elements.
- Zirconia Although it is not used as frequently as titanium and titanium alloys has been proven to be biocompatible in vitro and in vivo.

CRITERIA OF THE MATERIALS SUITABLE FOR DENTAL IMPLANTS AND THEIR PROSTHETIC COMPONENTS

B- Strength: The ultimate strength of a material determines the amount of load it can withstand before yielding or breaking.

Tensile, compressive, and fatigue strength properties vary between commercially pure titanium, titanium alloy, and zirconia.

Titanium and zirconia implant materials have sufficient ultimate strength to resist clinically relevant loads provided when the implant **cross section is sufficient**.

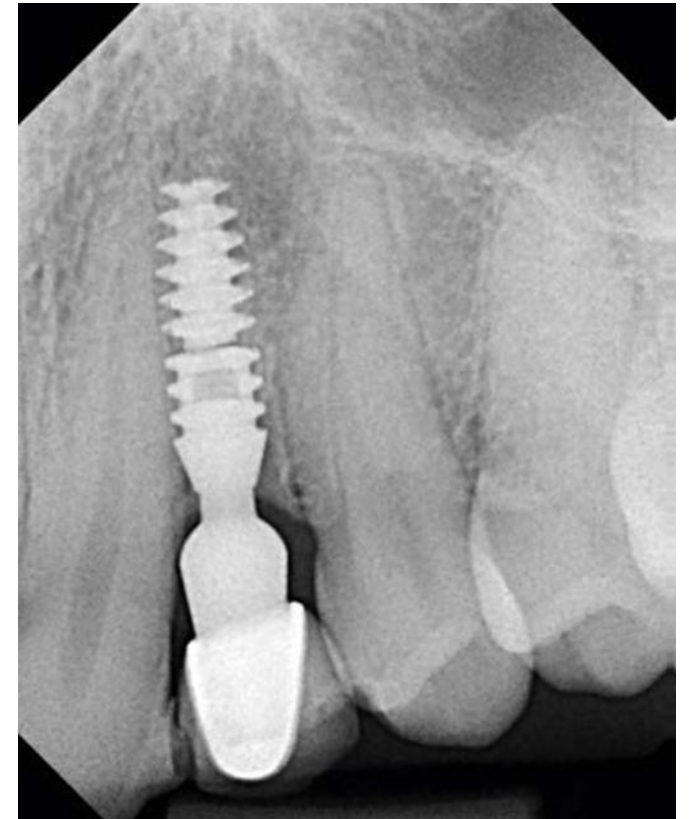


CRITERIA OF THE MATERIALS SUITABLE FOR DENTAL IMPLANTS AND THEIR PROSTHETIC COMPONENTS

More implants fail because of **fatigue fractures** than from loads that exceed the ultimate strength of the material.

Fatigue strength: the maximum cyclical load that the implant and restoration can withstand repeatedly without failure or loss of function.

it is affected to a large degree by loading conditions such as **cantilever length**, **force direction**.



CRITERIA OF THE MATERIALS SUITABLE FOR DENTAL IMPLANTS AND THEIR PROSTHETIC COMPONENTS

C- Corrosion Resistance:

- Titanium and its alloys have outstanding corrosion resistance under physiologic environmental conditions. They spontaneously form a passive titanium oxide passive film at the surface that resists corrosion very well in the oral environment and immediately reforms if it is damaged or removed by mechanical means.
- Zirconia ceramic is essentially inert in the oral environment and not susceptible to metallic corrosion.

CRITERIA OF THE MATERIALS SUITABLE FOR DENTAL IMPLANTS AND THEIR PROSTHETIC COMPONENTS

D- Modulus of Elasticity: the modulus of elasticity of the implant and the surrounding bone should be matched, for better stress transfer between the implant and the bone.

At this time, titanium alloys remain the best biomaterial for dental implants. In comparison, zirconia ceramic is very stiff and may have a higher potential for disuse atrophy related to stress at the bone-implant interface.

METALS AND ALLOYS

Titanium and Titanium-6 Aluminum-4 Vanadium

Titanium was selected as the material of choice because of its inert and biocompatible nature paired with excellent resistance to corrosion

Titanium shows a relatively low modulus of elasticity and tensile strength compared with most other alloys.

The modulus of elasticity of the alloy is slightly greater than that of titanium, being about 5.6 times that of compact bone.


Other alloys using iron, molybdenum, and other elements primary alloying agents have been developed. More recently, several new titanium alloys of **higher strength** have been introduced.

METALS AND ALLOYS

Iron-Chromium-Nickel-Based Alloys

- Because this alloy contains nickel as a major element, use in patients allergic or hypersensitive to nickel should be avoided.
- If a stainless-steel implant is modified before surgery, then recommended procedures call for repassivation to obtain an oxidized (passivated) surface condition to minimize in vivo biodegradation.

The iron-based alloys have galvanic potentials and corrosion characteristics that could result in concerns about galvanic coupling and biocorrosion if interconnected with titanium, cobalt, zirconium, or carbon implant biomaterials.

A stylized illustration of a lightning bolt striking a red wire, symbolizing electrical coupling or corrosion. The lightning bolt is depicted as a jagged, glowing blue and white line. The red wire is a thick, curved line that is broken at the point of impact. Below the wire, there are several other curved lines in various colors (blue, green, yellow, purple) that appear to be part of a larger, complex structure, possibly representing a biological or mechanical system.

For example, if a bridge of a noble or a base-metal alloy touches the abutment heads of a stainless-steel and titanium implant simultaneously, then an electrical circuit would be formed through the tissues.

METALS AND ALLOYS

Other Metals and Alloys

Gold, platinum, and palladium are metals of relatively low strength, which places limits on implant design. In addition, cost-per-unit weight and weight-per-unit volume (density) of the device along the upper arch have been suggested as possible limitations for gold and platinum.

CERAMICS AND CARBON

Ceramics are **inorganic**, **nonmetallic**, **nonpolymeric** materials manufactured by compacting and **sintering** at elevated temperatures. They can be divided into oxides or other compounds. *Oxide ceramics* were introduced for surgical implant devices because of their inertness, high strength, color and minimal thermal and electrical conductivity.

CERAMICS AND CARBON

Aluminum, Titanium, and Zirconium Oxides

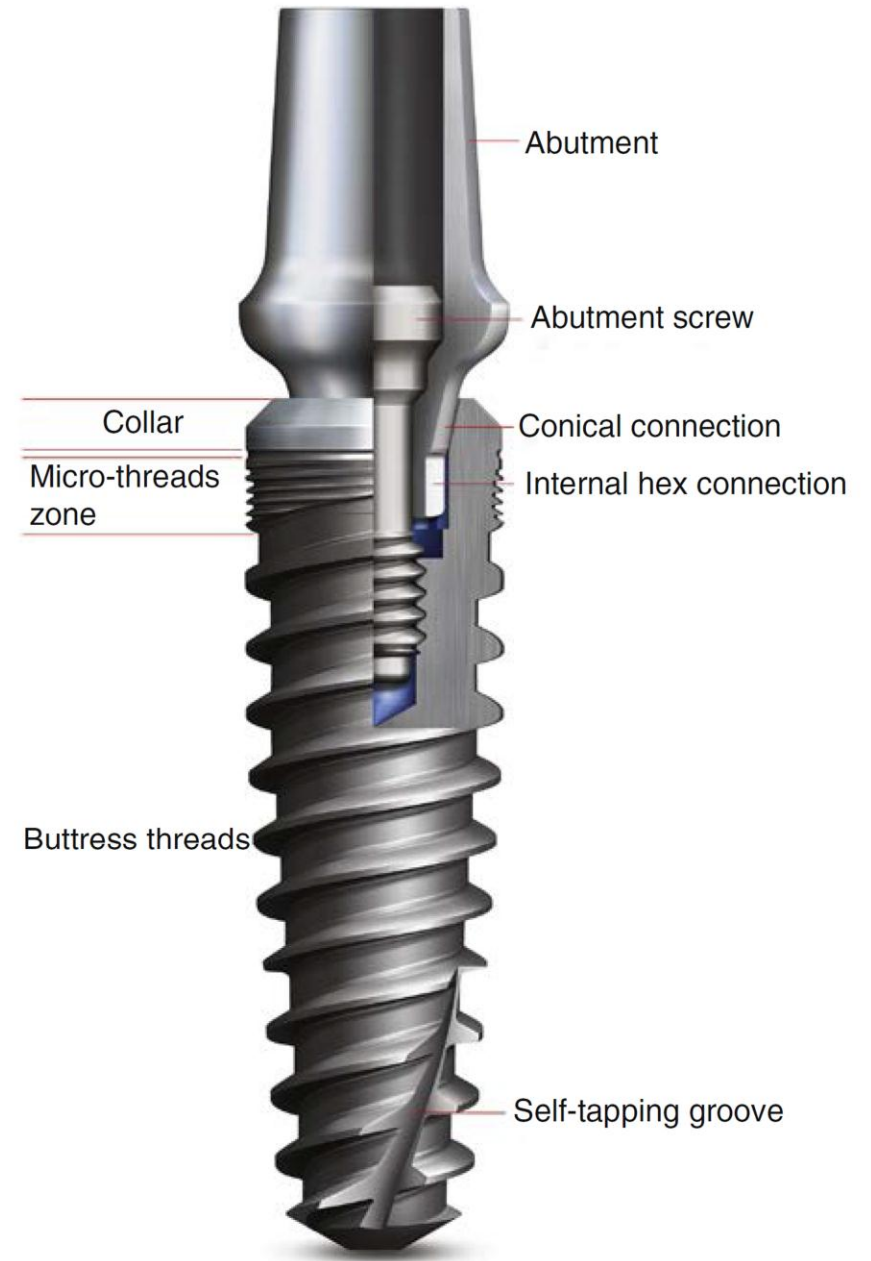
The compressive, tensile, and bending strengths exceed the strength of compact bone by three to five times. These properties, combined with high moduli of elasticity, and especially with fatigue and fracture strengths, have resulted in specialized design requirements for these classes of biomaterials.

Exhibited direct interfaces with bone, similar to an osteointegrated condition with titanium. In addition, characterization of gingival attachment zones.

IMPLANT COMPONENTS

Dental Implant

Lecture 5

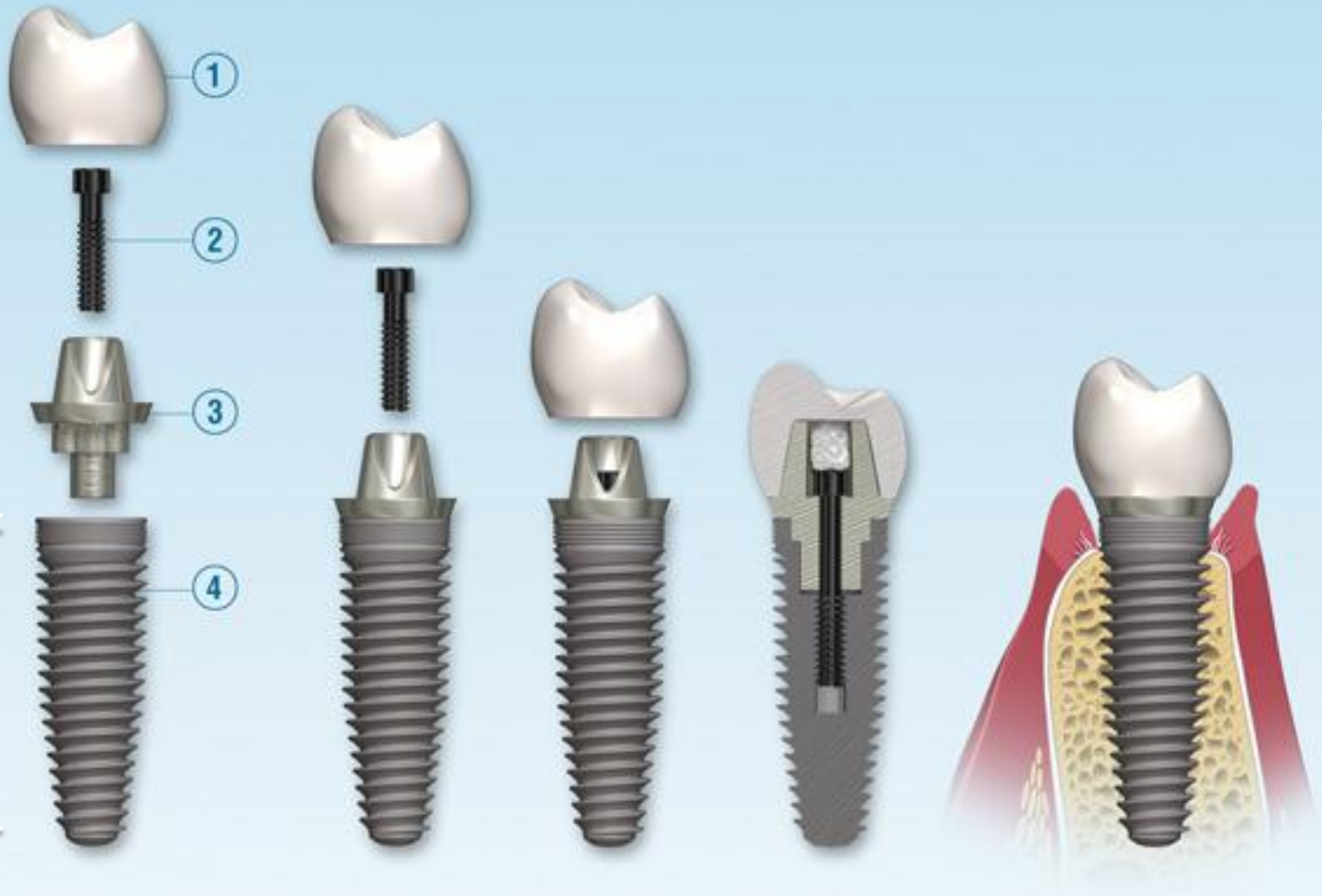

CROWN

SCREW

ABUTMENT

FIXTURE




IMPLANT BODY FIXTURE

Root form designed to use vertical column of bone , similar to root of natural tooth.

3 Different categories

1. Cylinder implants
2. Screw design implants
3. Combination



PARALLEL-SIDED SCREW-SHAPED IMPLANT AND THE TAPERED SCREW DESIGN

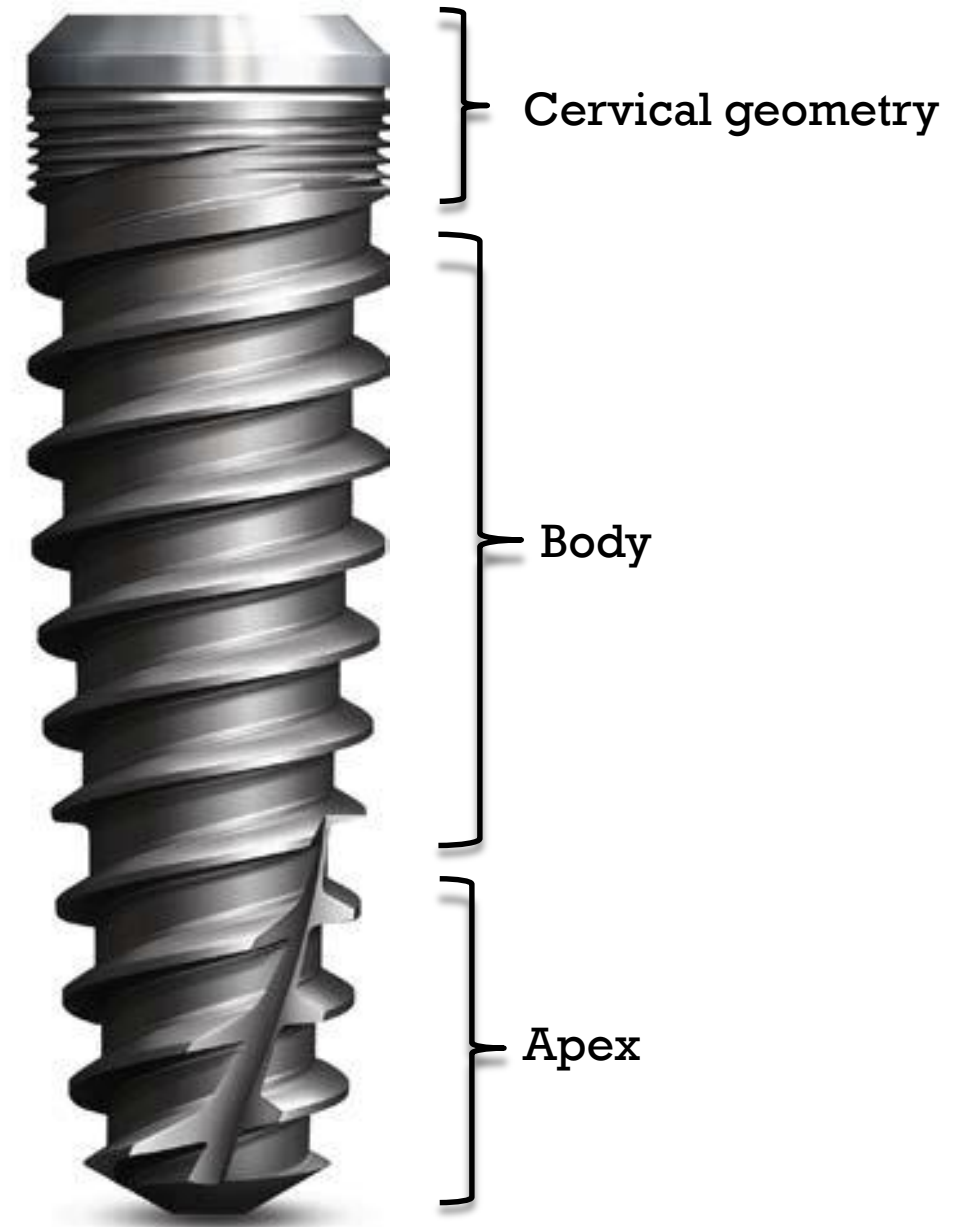
Screw-shaped implants: In which the implant body exhibits screw threads throughout most or all its length, have become the most commonly used implant design. Current designs feature improved primary stability and simplified surgical placement protocols



IMPLANT BODY REGIONS

3 Parts

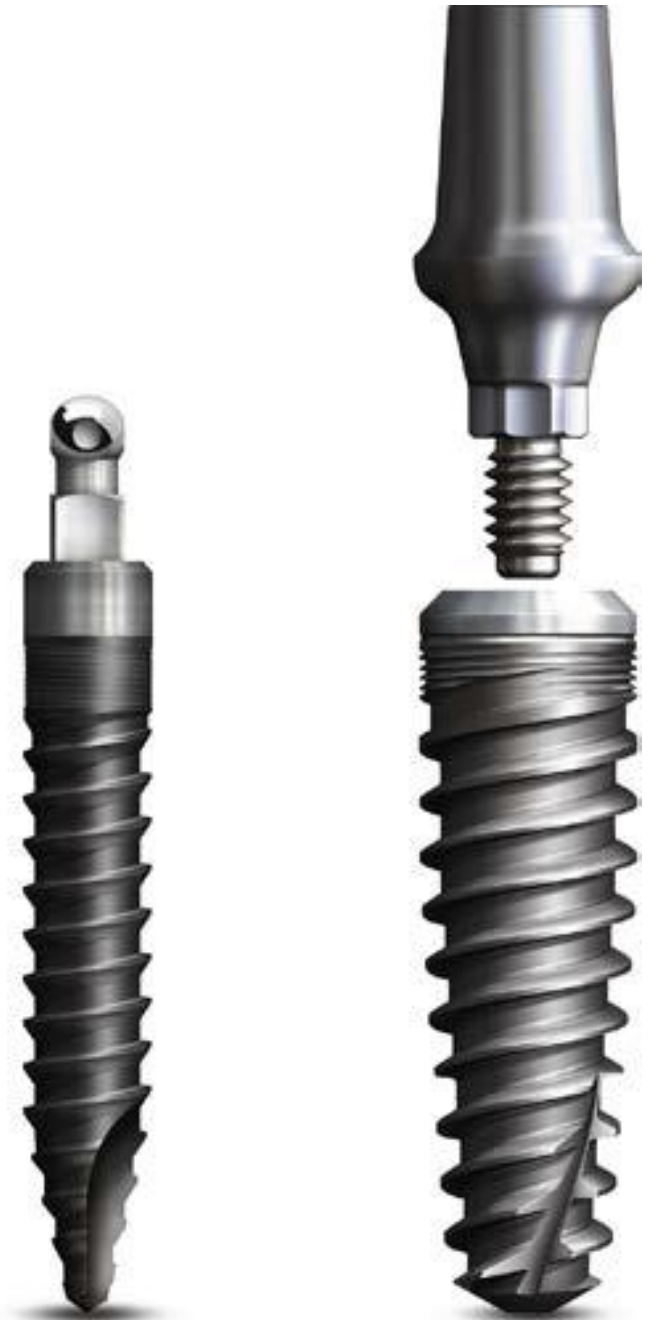1. Crest module (Cervical geometry):
 - Designed to retain the prosthetic component
 - Has a platform on which abutment is seated
2. Body: designed for implant bone interface
3. Apex



ONE-PIECE VERSUS TWO-PIECE

The two-piece implant design consists of an implant body, which provides anchorage within the bone, and a platform, which provides a connection. This connection is used to join the implant to an abutment or prosthesis.

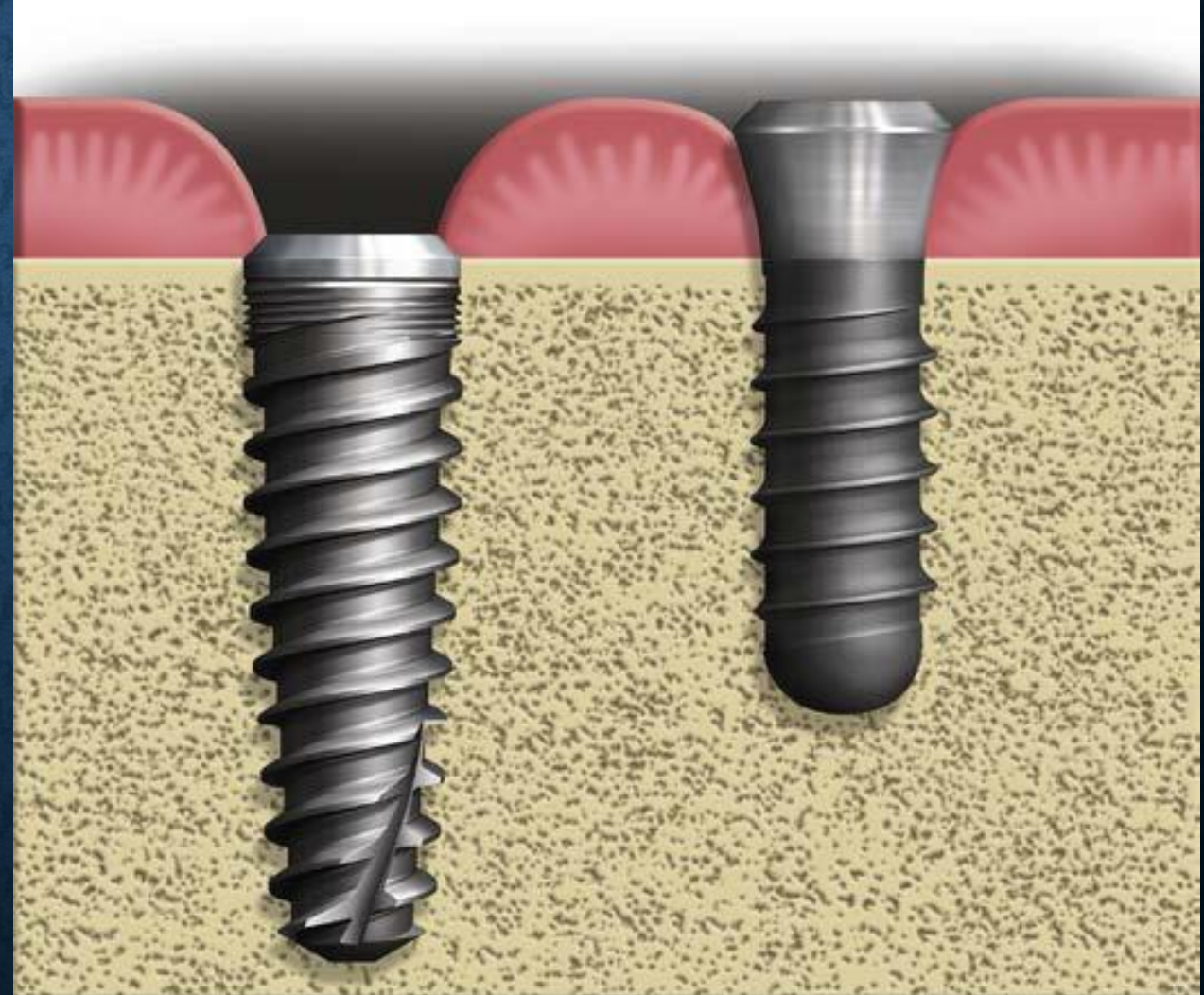
A one-piece implant has an abutment as part of the implant.



BONE-LEVEL VERSUS TISSUE-LEVEL IMPLANTS

Bone-level implants : placed with the collar at or near the bone crest. This design provides additional flexibility for creation of the soft tissue emergence profile of the implant restoration.

Tissue-level implants : placed with the collar at or near the soft tissue margin.



PLATFORM SWITCHED VERSUS PLATFORM MATCHING

Platform matched: maintained the same diameter from the implant collar to the portion of the abutment that connects to the implant in a design.

Platform switching: When the abutment is narrower than the implant at the connection.

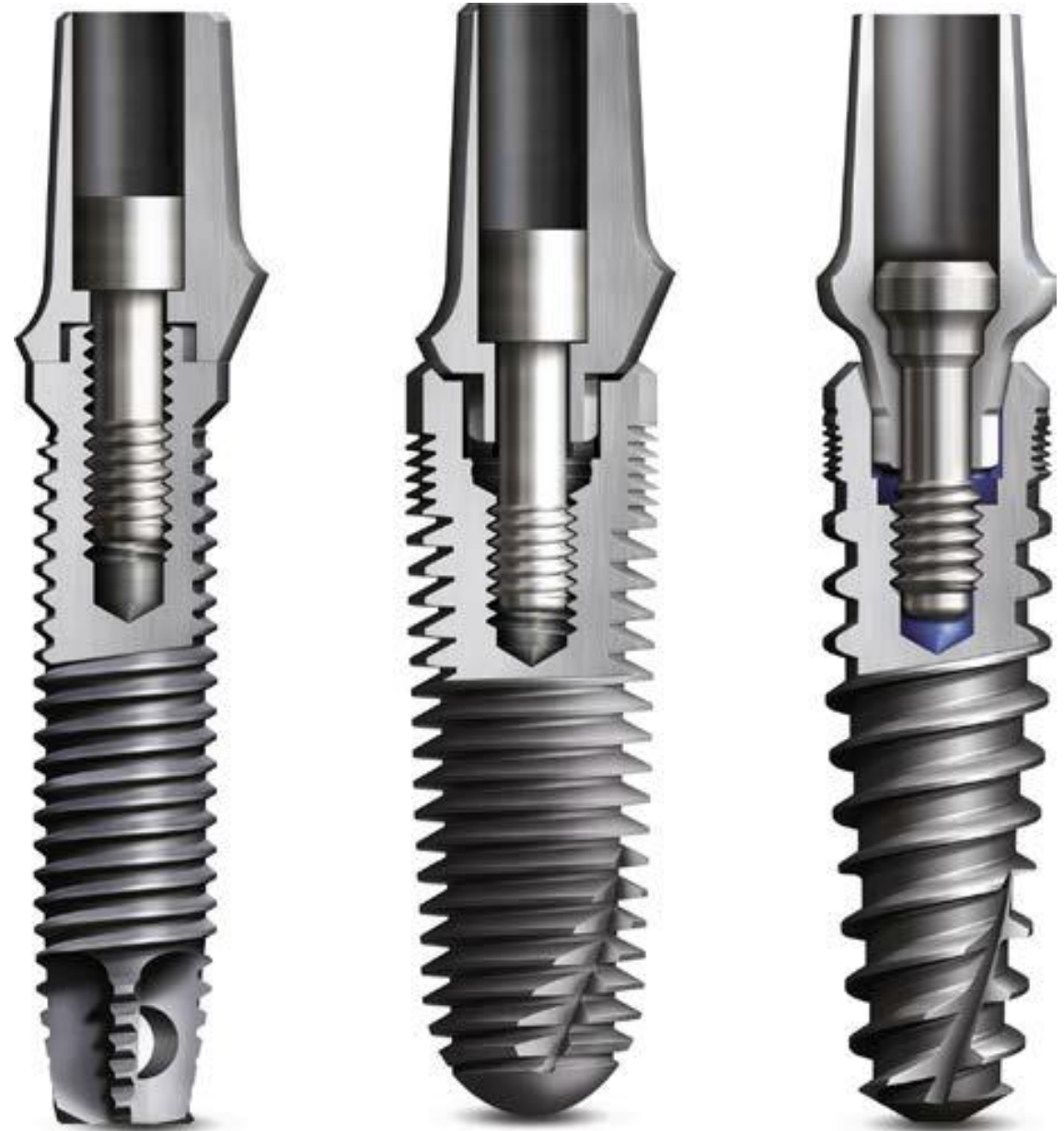

CONNECTION TYPE

Implant connections are defined by the geometry of the connecting elements.

An external hex on the implant, which mates with an internal hex on the abutment.

Screw loosening is a risk for external hex connections because greater lateral forces are transferred to the connection screw



CONNECTION TYPE

Internal connection implants feature a chamber within the implant body to which an external projection of the abutment can engage.


Commonly used internal connections include hexagon, octagon, and trichannel, and many of these include a conical interface as part of their internal geometry



CONNECTION TYPE

Morse taper connection absorbs 91% of the functional load.

The thread only takes 9% of the functional load.



IMPLANT COMPONENTS

Lecture 6

MAIN COMPONENTS



Superstructure

Abutment

Fixture

ABUTMENTS

Abutments are the component of the implant system that screw directly into the implant . It supports and retains the implant superstructure.



ABUTMENTS CLASSIFICATION

Abutments for fixed prosthesis

Prefabricated:

Standardized abutments for cemented restorations.

Multiunit abutments with screws

Custom-made

Castable abutments

CAD-CAM abutments

Abutments for removable prosthesis

Stud attachments

Bar attachments

Magnetic attachments

Telescopic attachments

STANDARDIZED ABUTMENTS FOR CEMENTED RESTORATIONS

The walls of abutments are usually smooth polished , and straight – sided .

The length range from 5-10 mm.

Angled and straight abutments available.

Collar height from 0-6 mm.

In non aesthetic areas , 1-2 mm of titanium should be allowed to penetrate the soft tissue to maximize the patient's ability to clean the prosthesis.



MULTIUNIT ABUTMENTS WITH SCREWS

Two screws are used, The main screw connect the abutment to the fixture. The second one connect the super structure to the abutment.

Opening for
main screw

Opening for
second screw

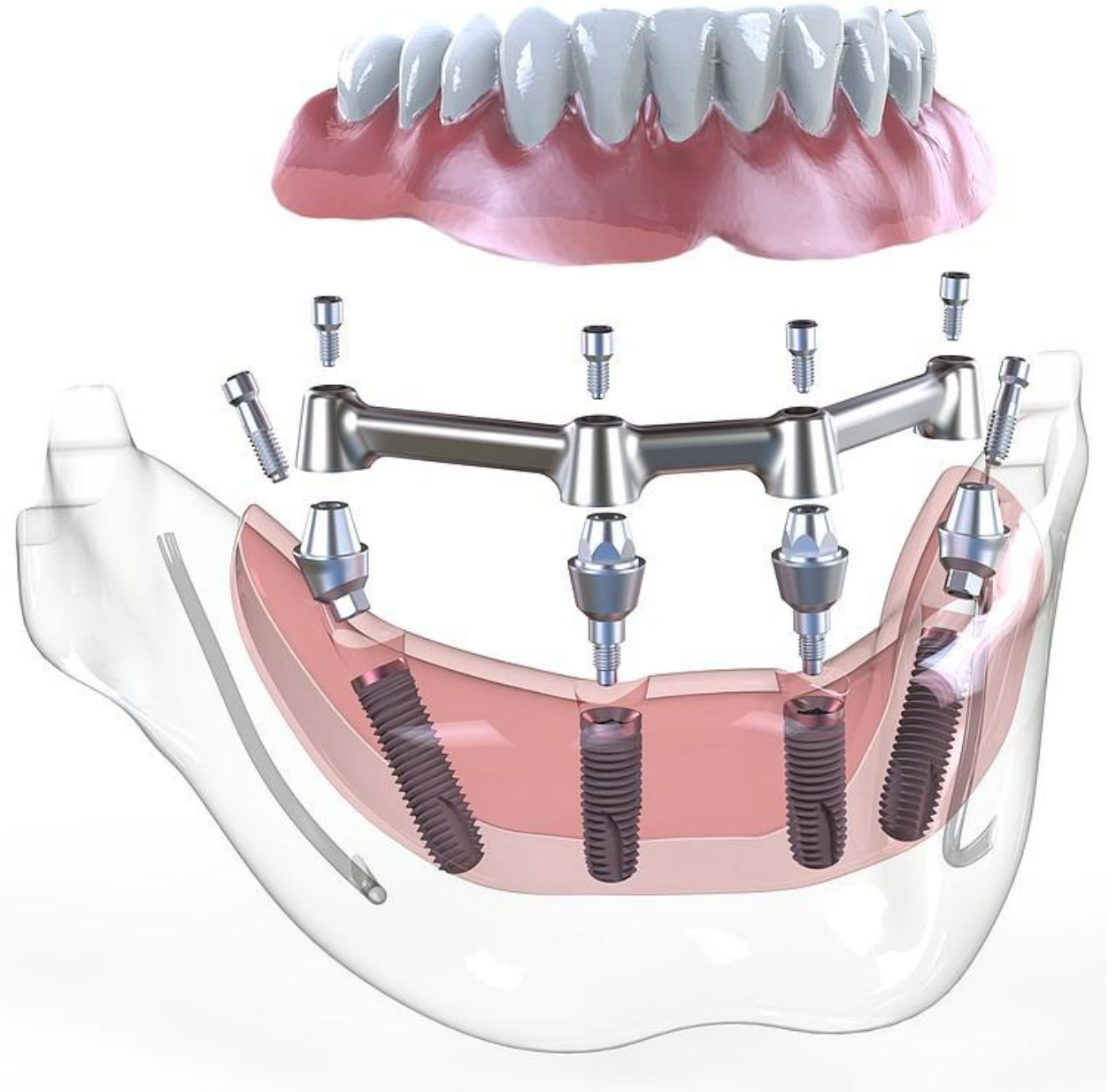

Main screw



MULTIUNIT ABUTMENTS WITH SCREWS

These standardized abutments are used for screw-retained multiple unit restorations (Superstructure) directly to the abutment by the second screw while the abutments will be connected to the implants fixture by the main screw.



CUSTOM-MADE CAD-CAM ABUTMENTS

Abutments that machined to close tolerances to ensure a precise fit.



posterior milled titanium abutment



anterior milled titanium abutment



hybrid milled zirconia bonded to
titanium abutment base

CASTABLE ABUTMENTS

Plastic burnout pattern for a castable abutment, this abutment reshaped by adding wax and cut the excess to get the wanted size and shape ,then replaced by casting metal. Can be used in single or multiple unites restorations.



ABUTMENTS FOR REMOVABLE PROSTHESIS

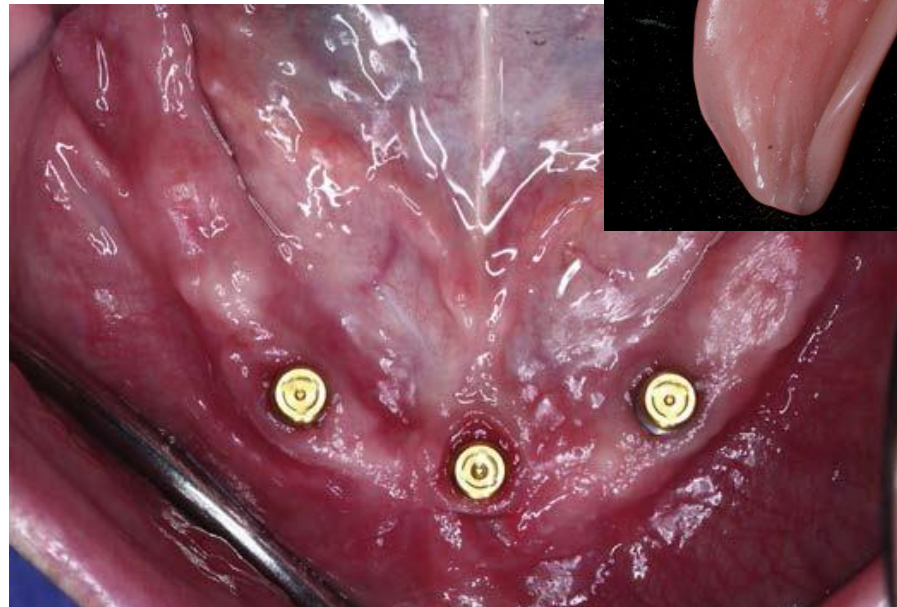
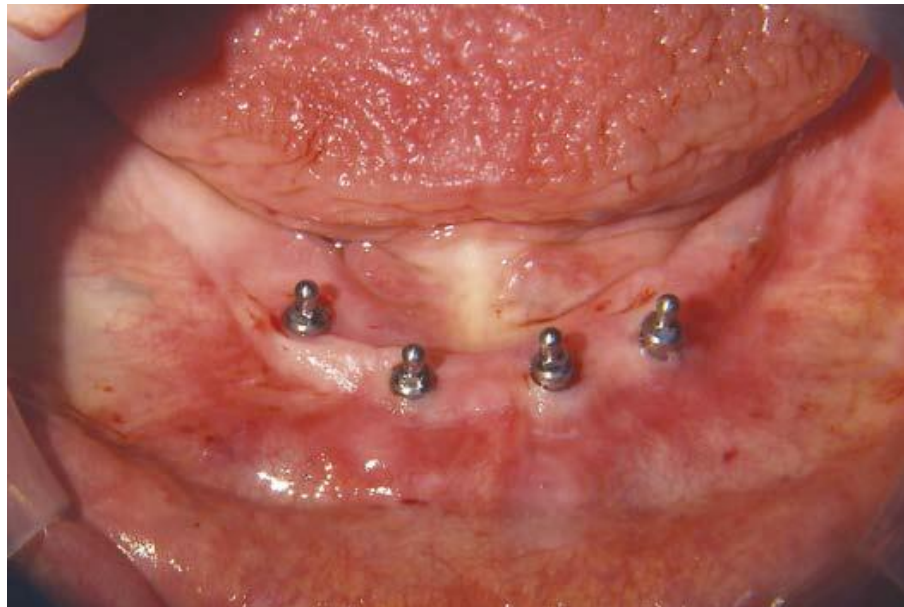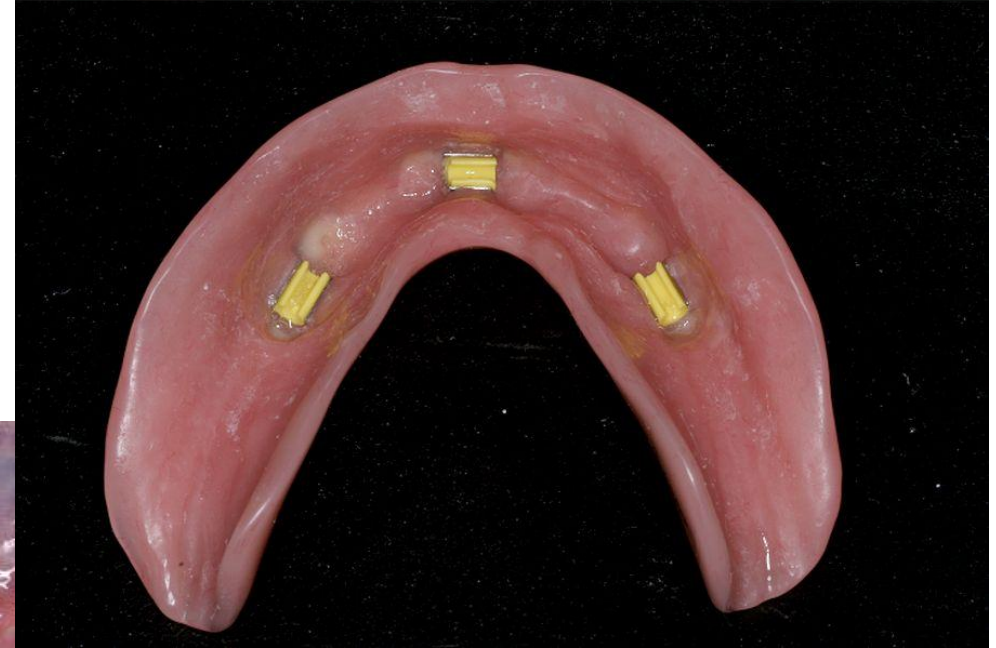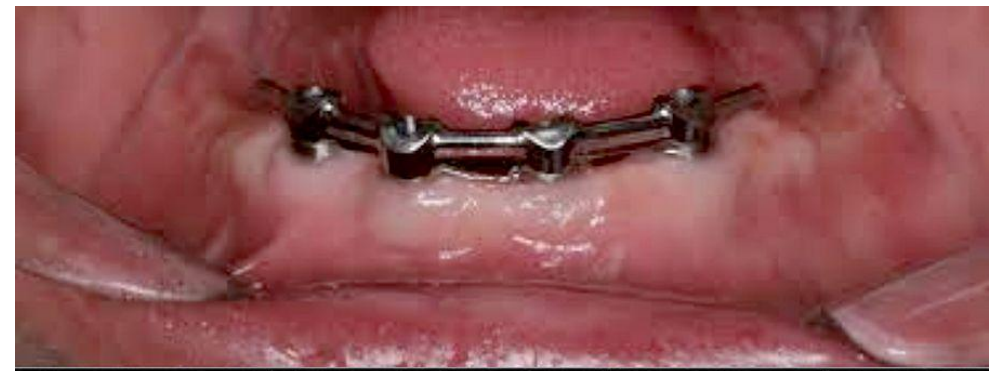Overdenture attachments are mechanical devices used to provide retention between the removable prosthesis and the implants.

For free-standing implants, the attachments are often in the form of an abutment that attaches directly to the implant, such as a ball or Locator attachment.

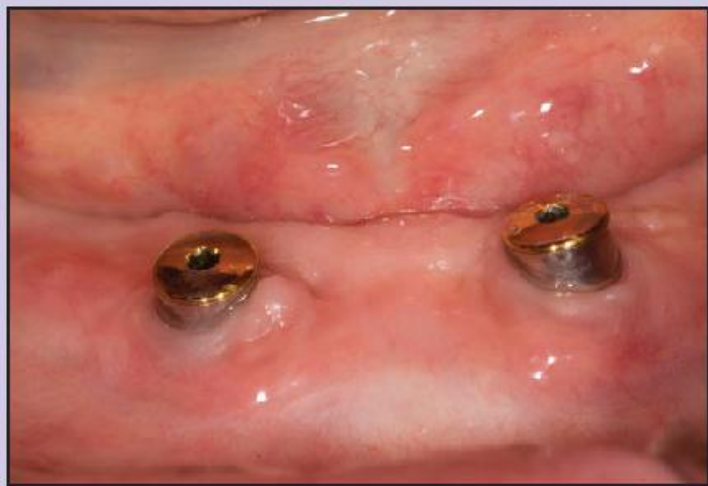

ABUTMENTS FOR REMOVABLE PROSTHESIS

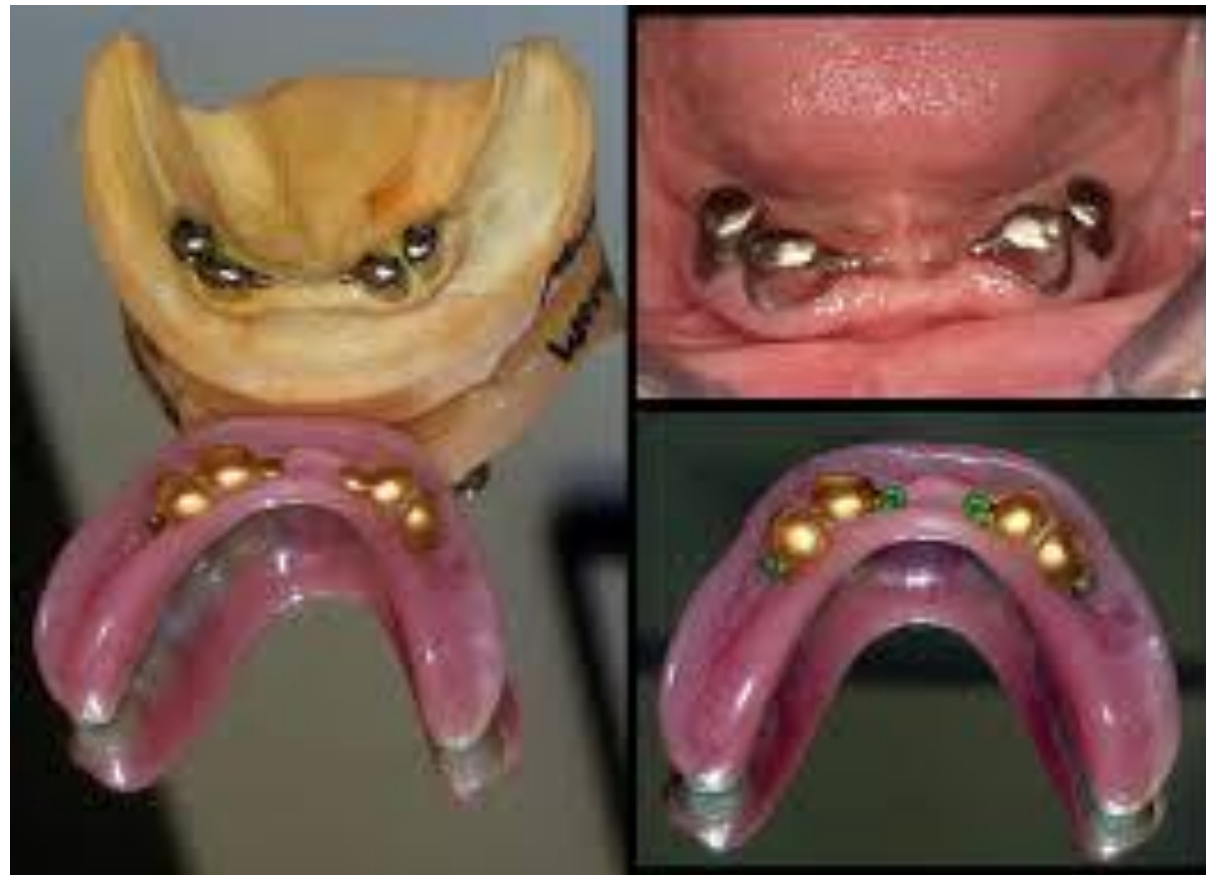For splinted overdenture cases, the attachments are normally incorporated into the design of the splinting bar.



MAGNETIC ATTACHMENTS



TELESCOPIC ATTACHMENTS



ABUTMENT SELECTION

1. The vertical distance between the fixture and opposing dentition.
2. The existing sulcular depth determine the abutment collar height.
3. For acceptable appearance , an anterior maxillary crown may require 2-3 mm of subgingival porcelain at the facial gingival margin to create the proper emergence profile and appearance.
4. In nonaesthetic areas , 1-2 mm of titanium could be allowed to penetrate the soft tissue to maximize the patient's ability to clean the prosthesis.
5. Angulation of the abutment should be suitable for the occlusal arch and adjacent teeth alignment.

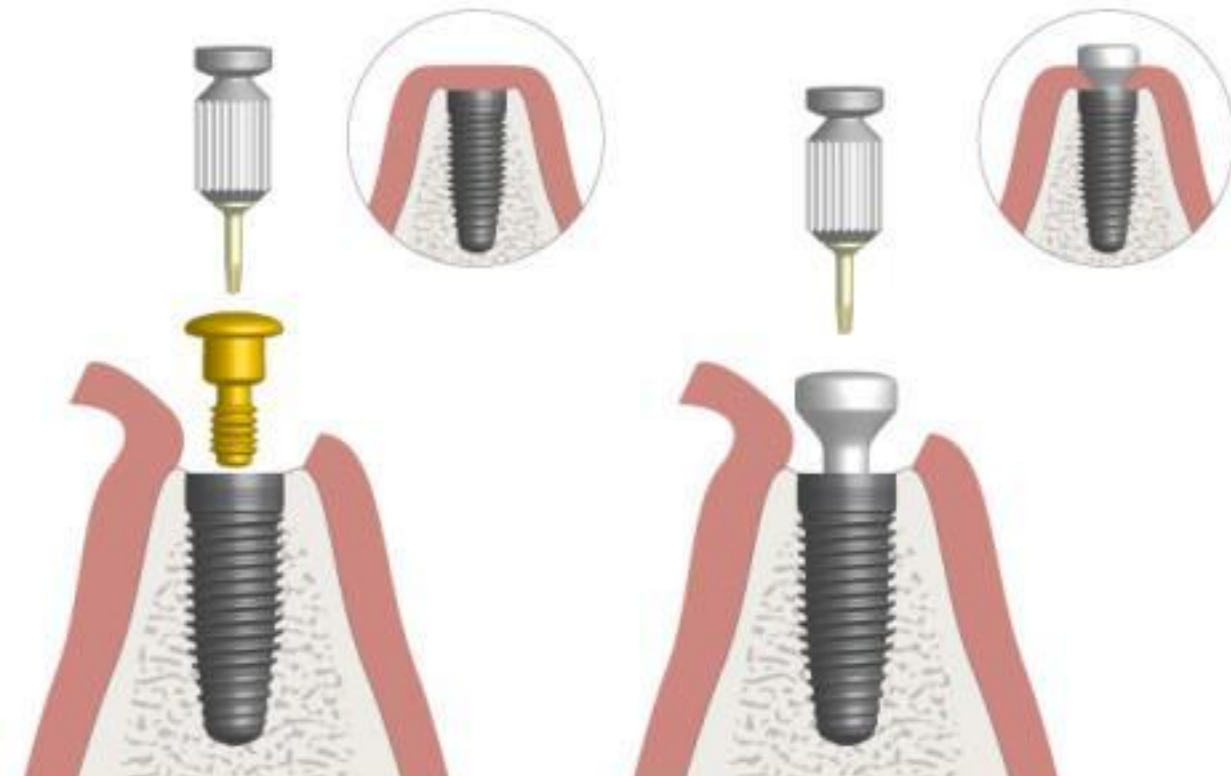


ACCESSORIES

SURGICAL ACCESSORIES

COVER SCREW


GINGIVAL FORMER



PROSTHETIC ACCESSORIES

IMPLANT ANALOGUE

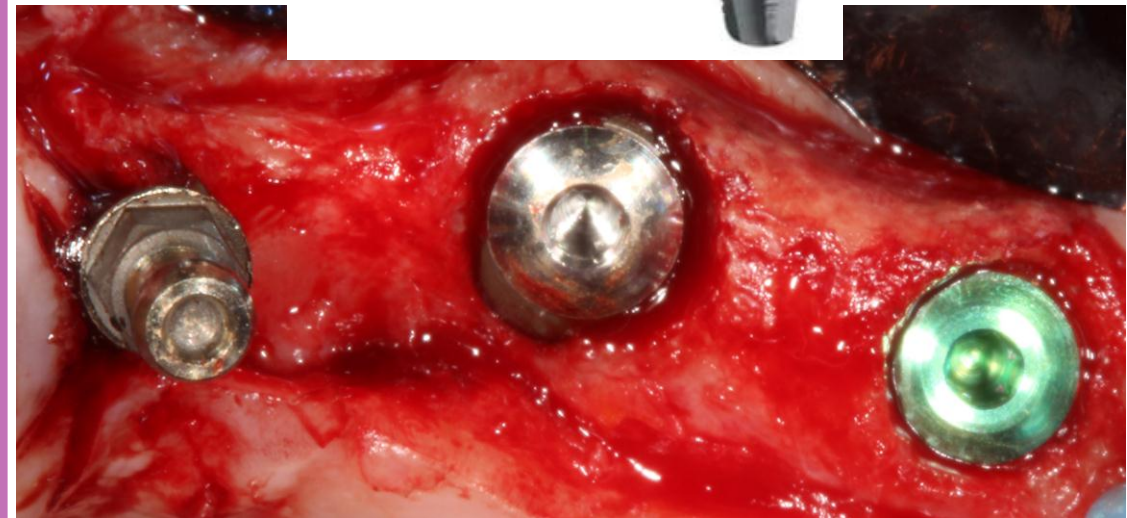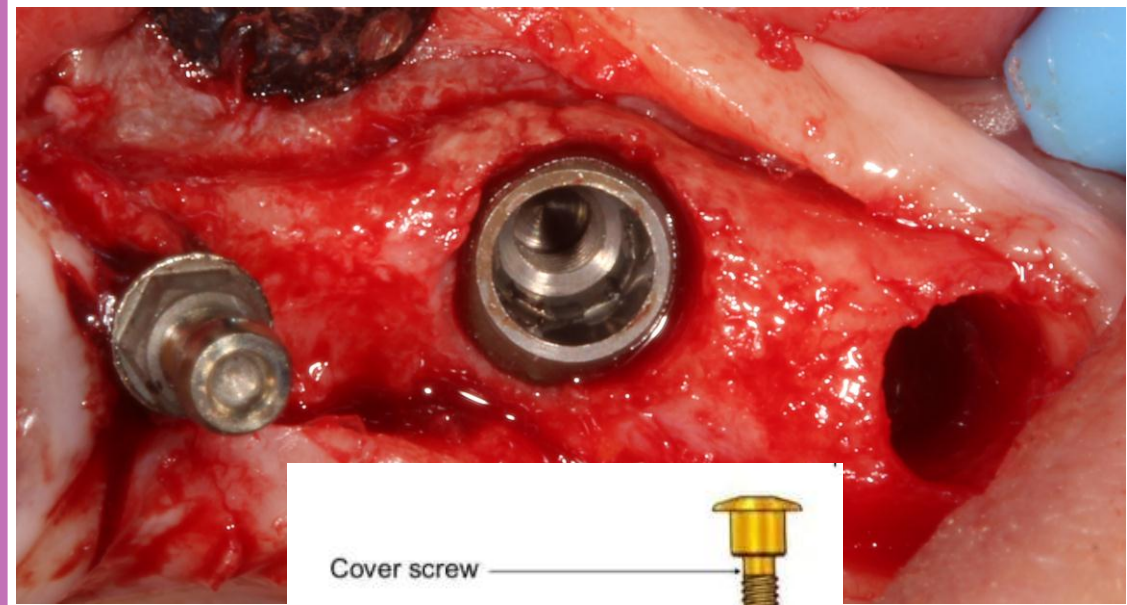
IMPRESSION COPING



COVER SCREW

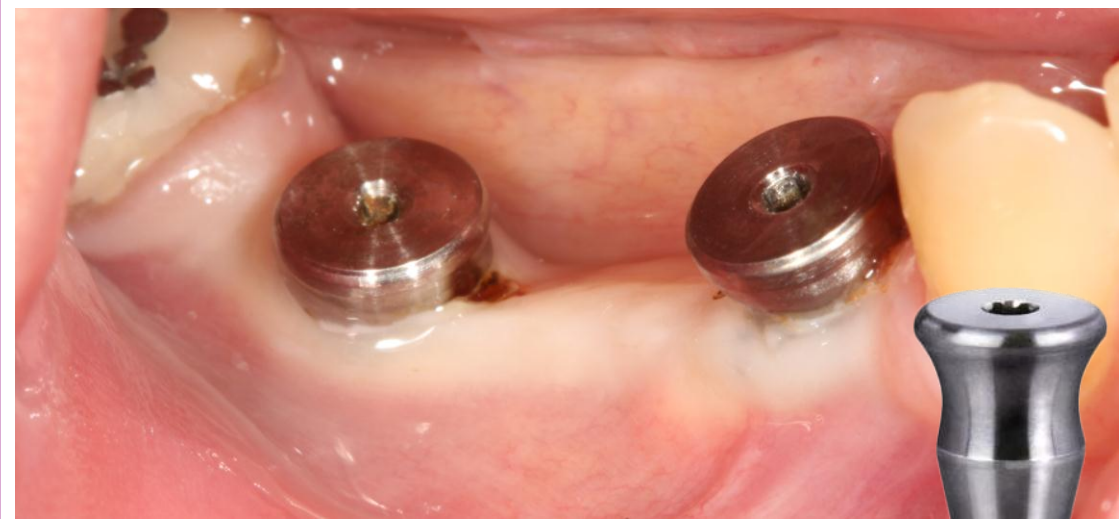is a component used to occlude the connection of the implant while submerged during a two-stage procedure

- The screw is usually low in profile to facilitate the suturing of soft tissue in two stage implant or minimize loading in the one stage implant
- At the second stage surgery , the screw is removed and placed by subsequent components.

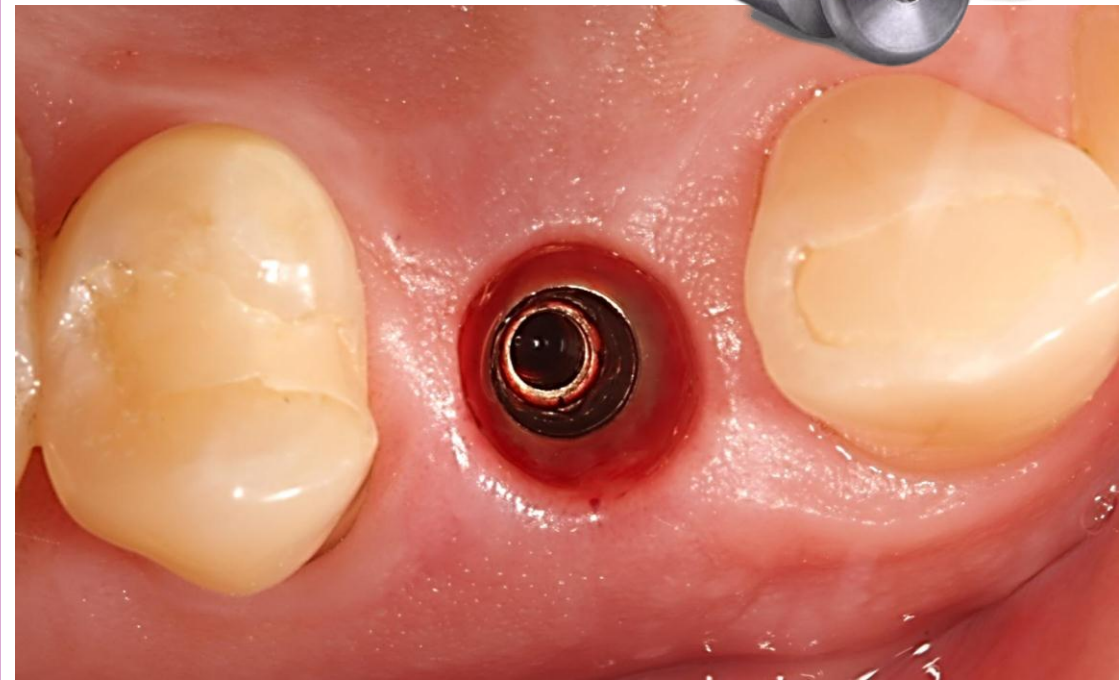
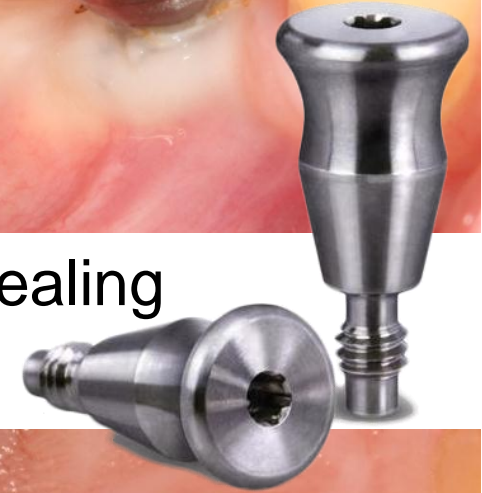

GINGIVAL FORMER

- This is required only for two-stage implants. Following the second surgery to expose the implant, the cover screws are removed and gingival formers, which are available in varying heights, are placed on the implant fixture. They extend above the soft tissue into the oral cavity and form a gingival cuff around the implant.
- They will be replaced by the abutment in final restoration so termed as Healing Abutment

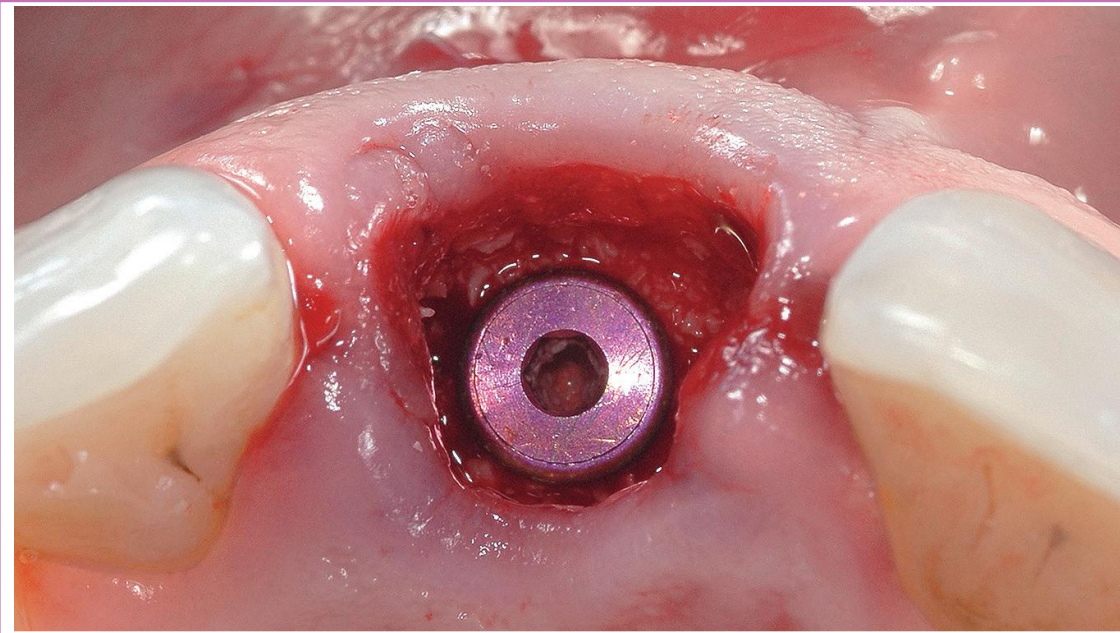
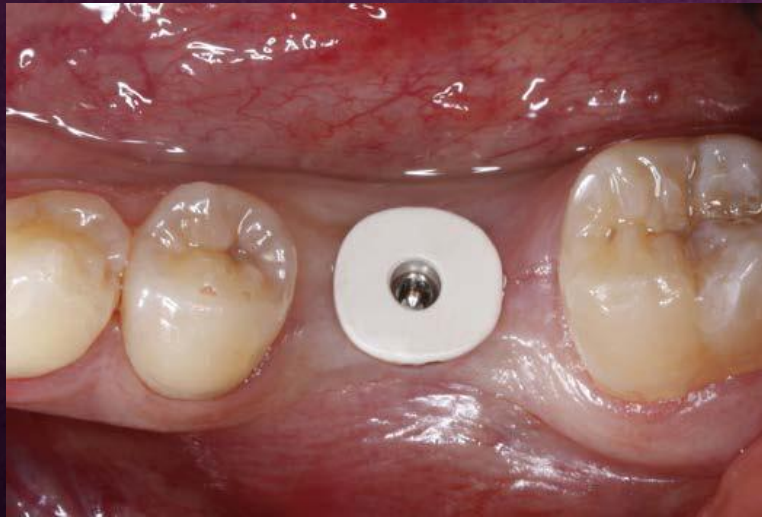


Stock/standardized healing abutments

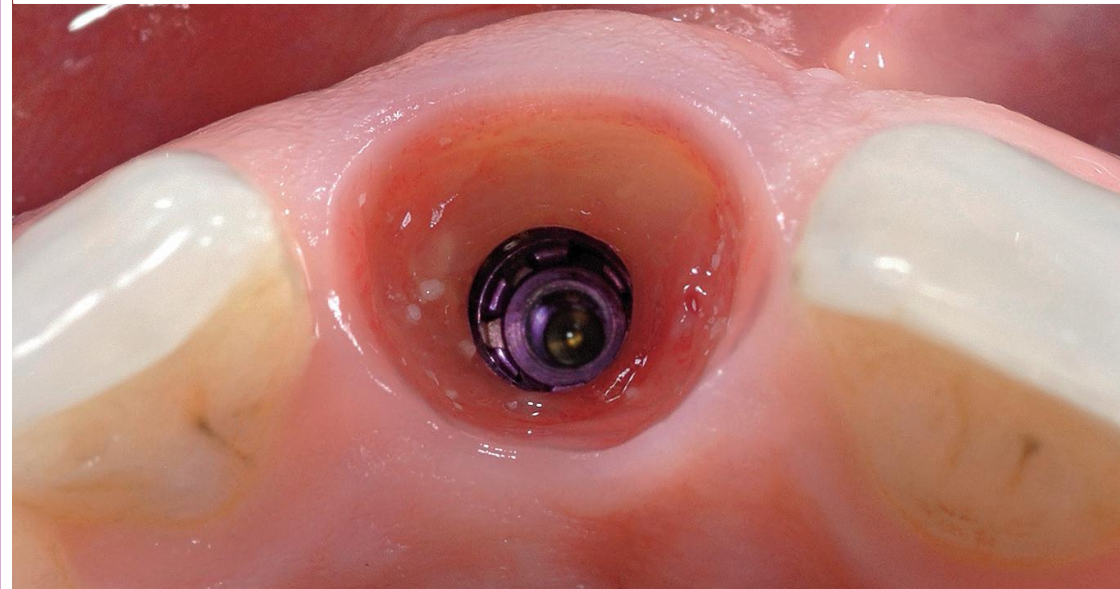


GINGIVAL FORMER

- **Custom components** are designed and fabricated for a specific site in the same way that restorations are customized for a specific patient.
- Usually placed for 2 to 5 weeks depending on the healing, following which they are removed and impression procedures are commenced.

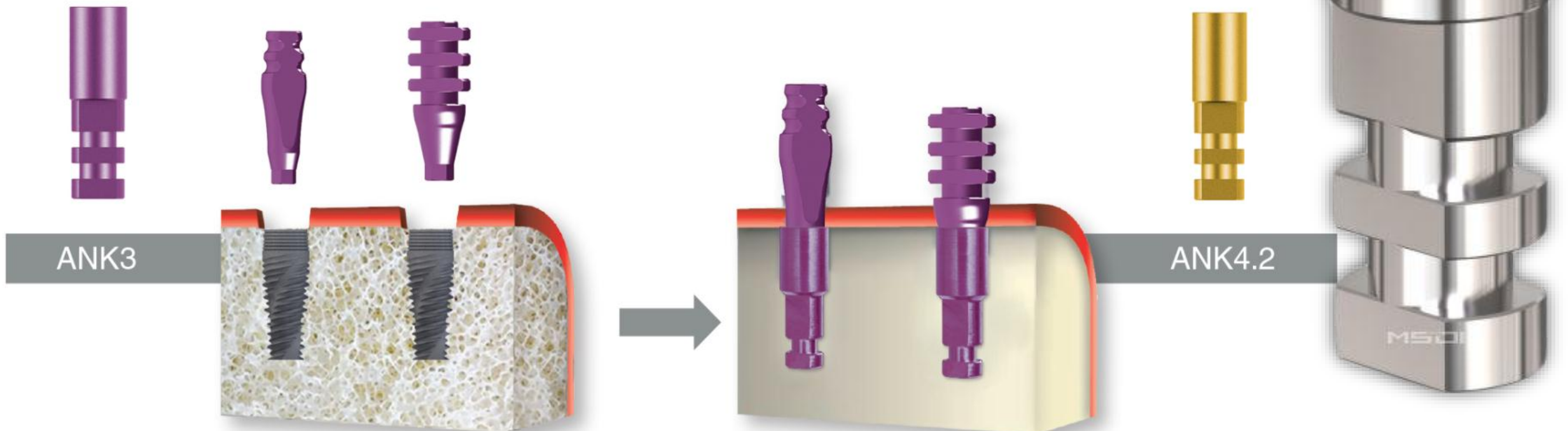


Custom healing abutment with ideal contours



IMPLANT ANALOGUE

- IMPLANT ANALOGUE: A replica of the entire dental implant.
- This is similar to the implant fixture, but used in the model to fabricate the prosthesis in laboratory.
- The abutment is fitted to the analogue and prosthesis is fabricated in the laboratory. It is also termed as Implant Replica or Lab





Closed-tray

IMPRESSION COPING

- used to provide a spatial relationship of an endosteal dental implant to the alveolar ridge and adjacent dentition or other structures.
- The coping is attached to the implant fixture during implant procedures using an impression screw. Following impression making the coping is removed from the implant fixture and attached to the implant analogue, to pour a cast. It is also called as *Impression post*, *Impression pin* or *Transfer coping*.
- Impression coping facilitate transfer of the of intraoral location of the implant or abutment to a similar position on the laboratory cast .

Types of impression coping :

1. Closed-tray. 2. Open-tray. 3. Scan bodies

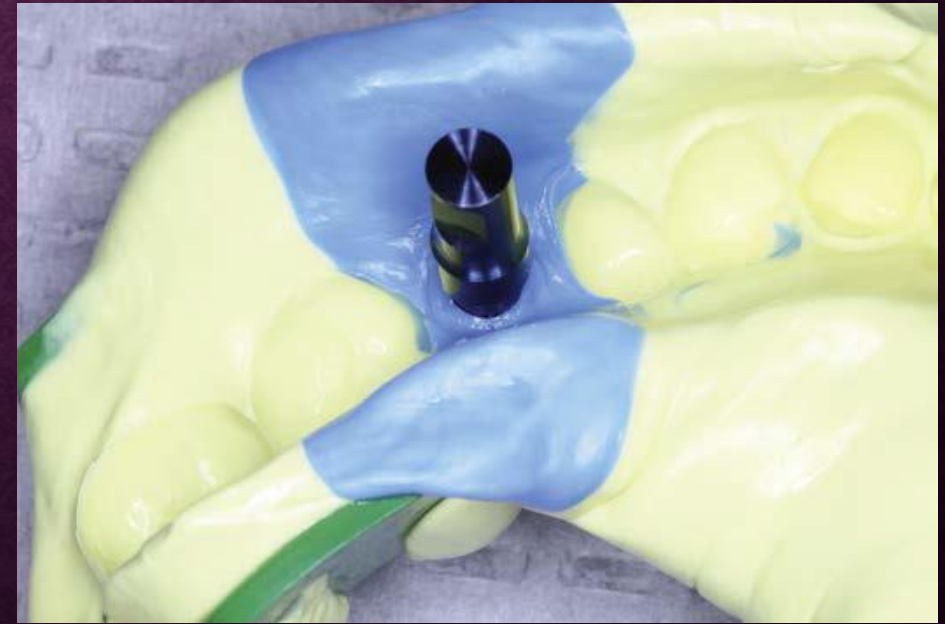
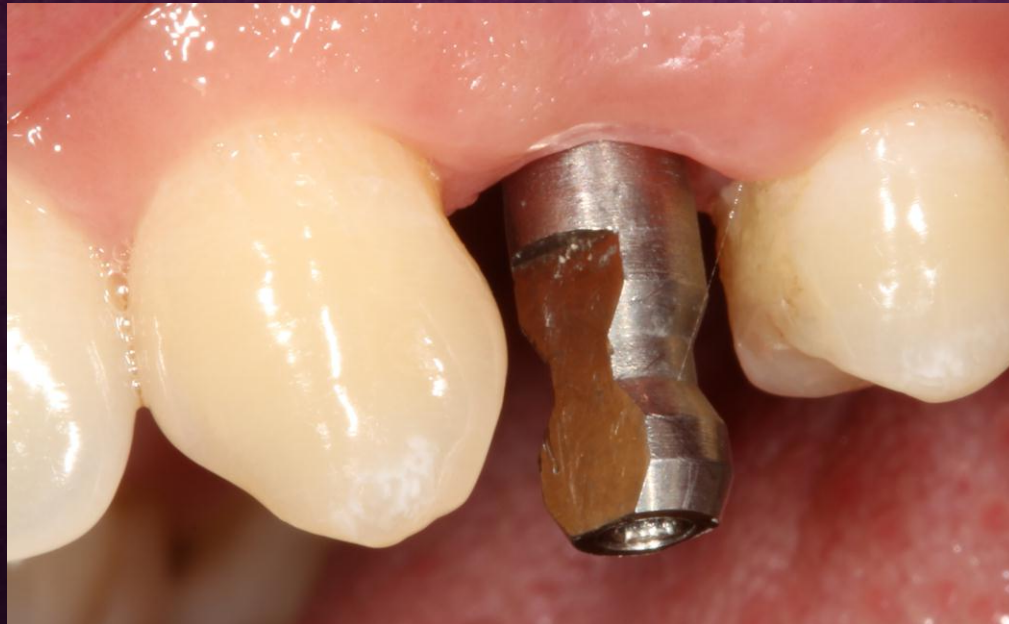
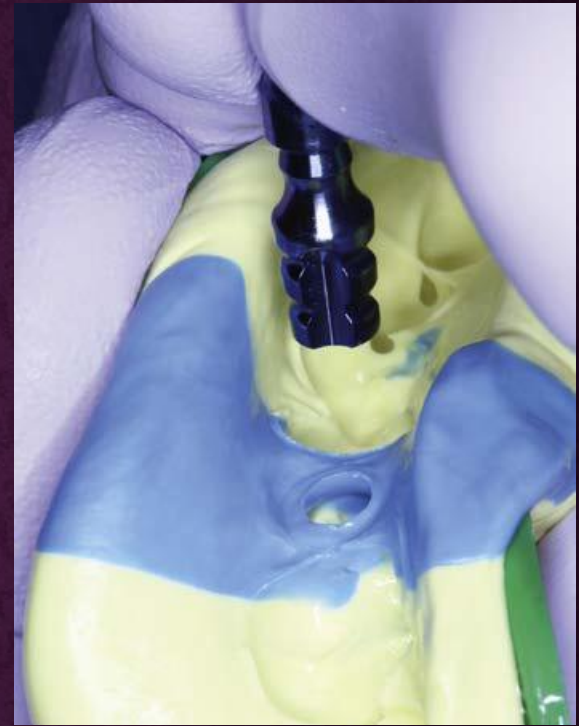Open-tray

CLOSED-TRAY

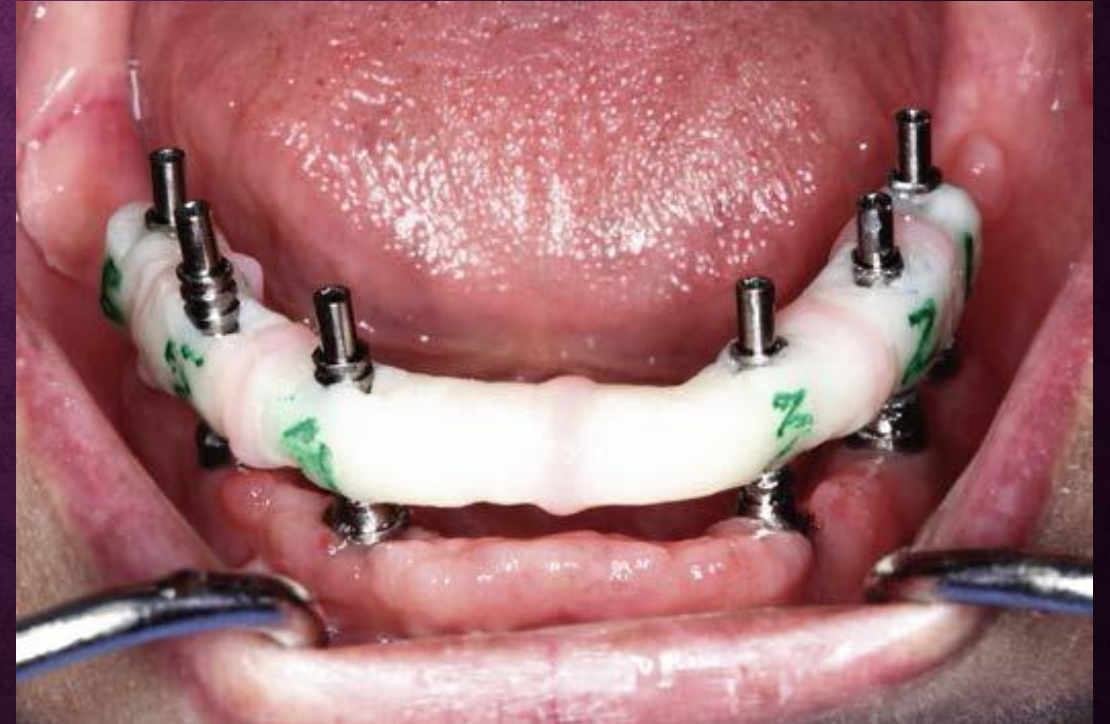
In the transfer or closed-tray technique, the impression coping has a tapered shape and is attached to the implant or abutment, and it remains attached when the impression is removed from the mouth. The copings are then removed from the mouth and inserted into the impression.

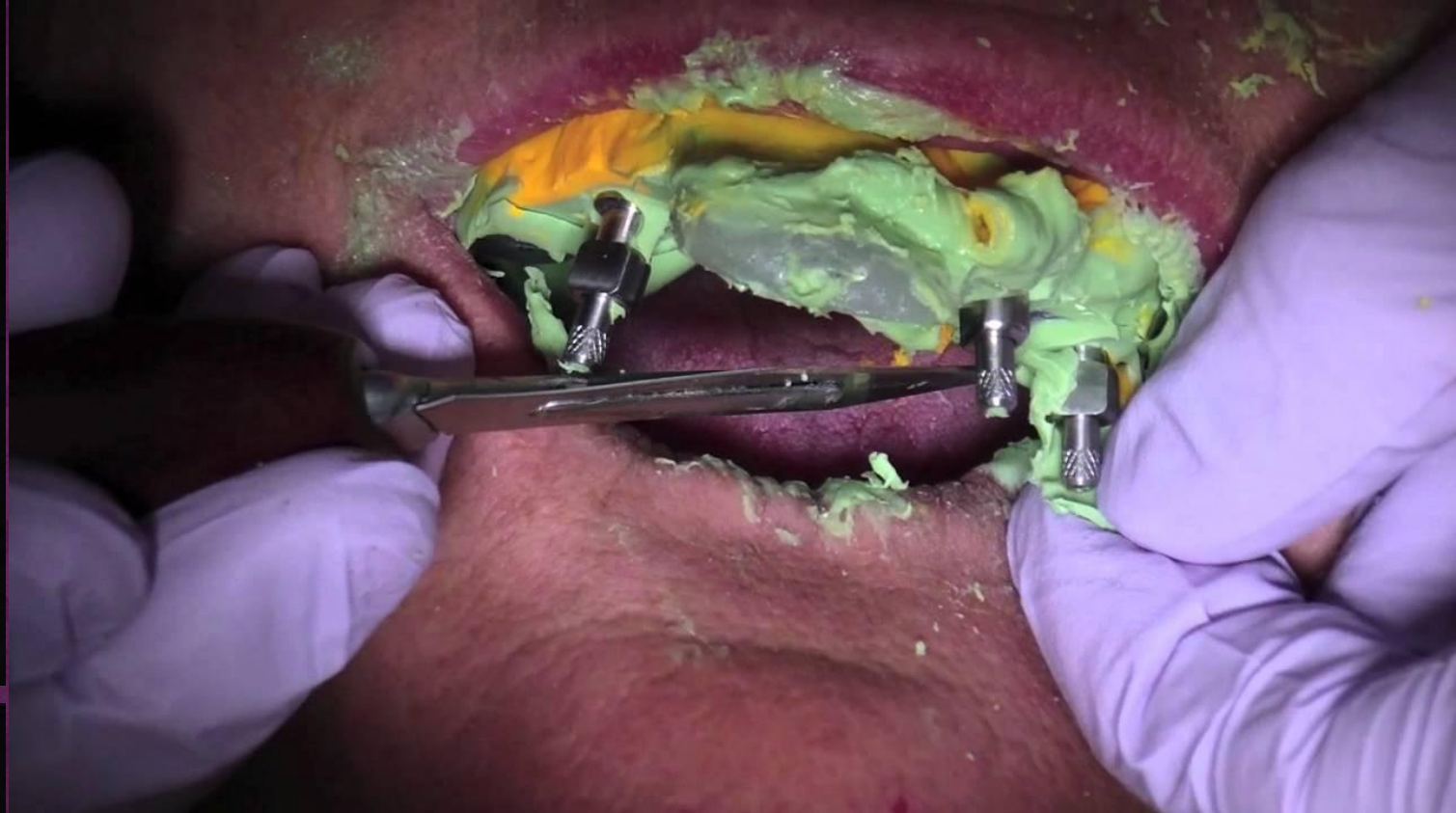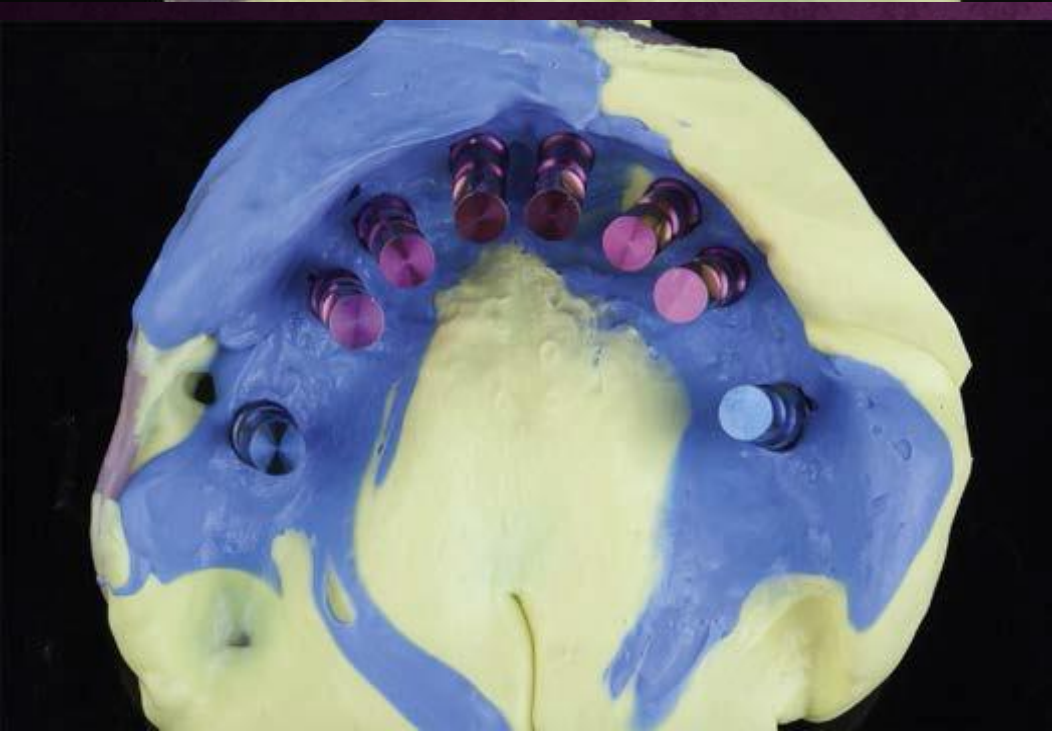
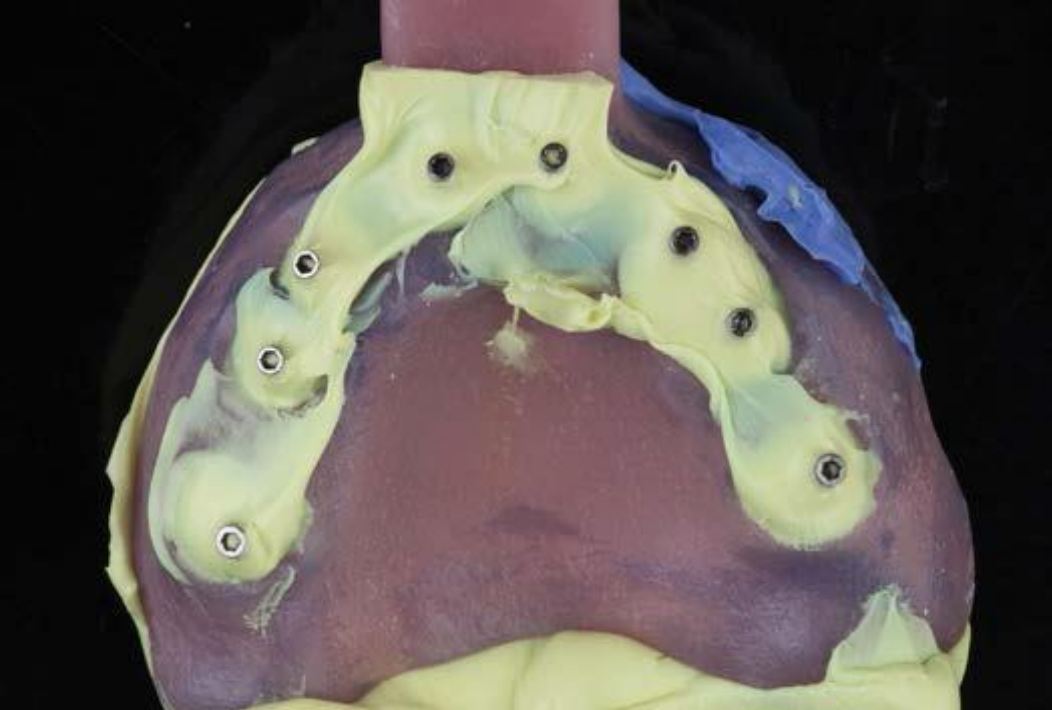
Analogs are attached to the impression copings before the insertion, and the cast is poured.



OPEN-TRAY

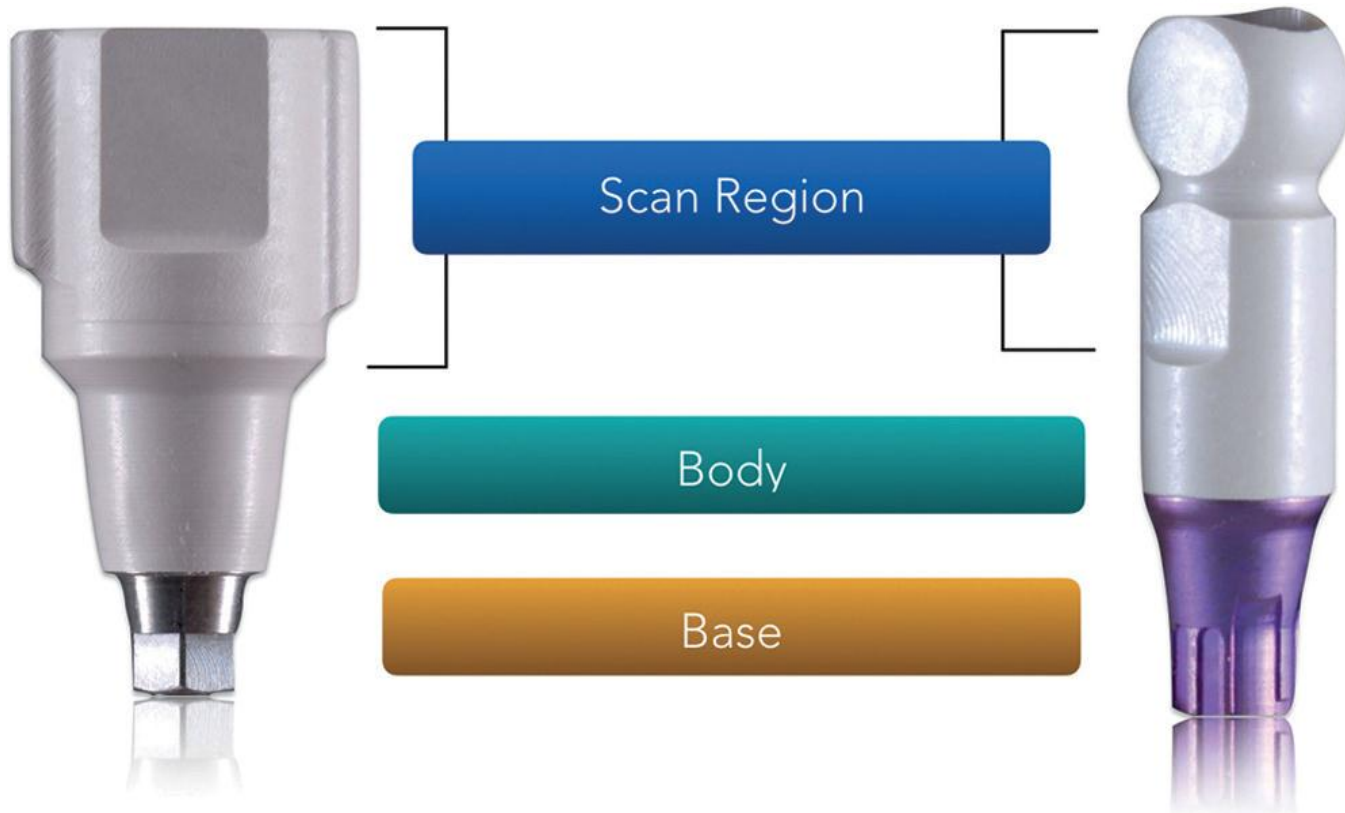
Pick-up or open-tray technique, the impression coping features squares or other retentive elements and is attached to the implant or abutment before the impression is made. The screws, which retain the impression copings, project through the impression tray and are loosened before impression removal. The impression copings are removed with the impression, analogs are connected, and the cast is poured

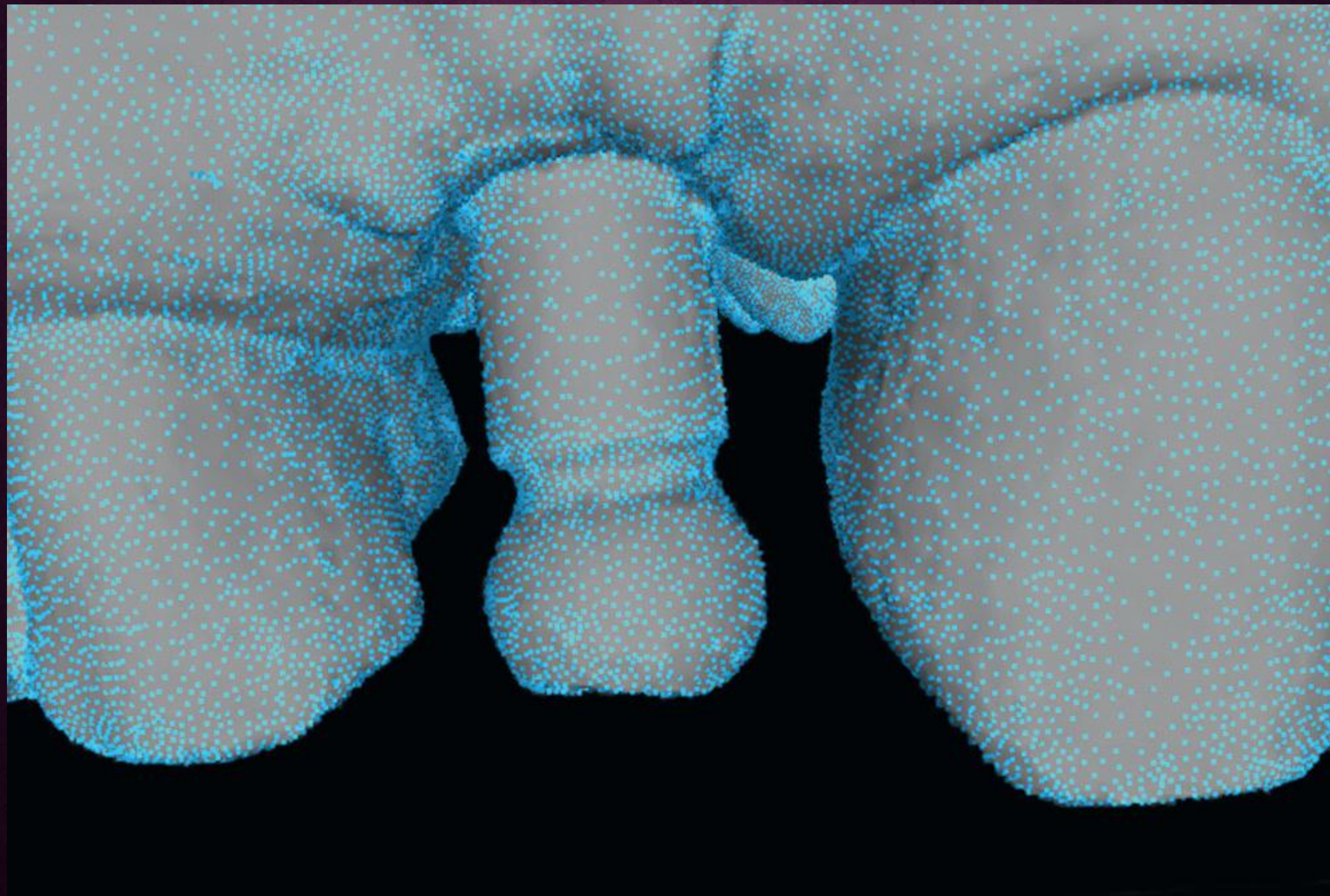


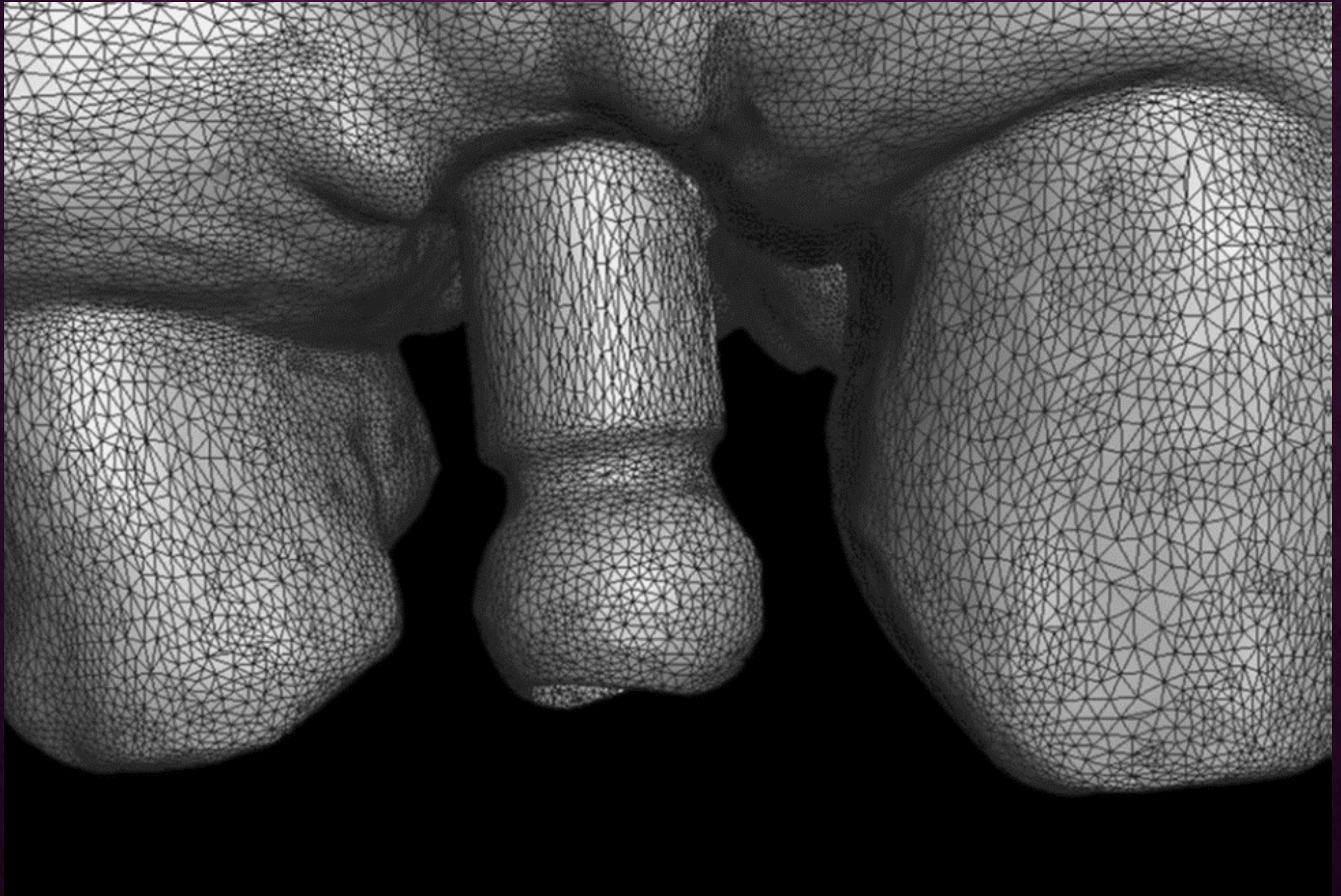


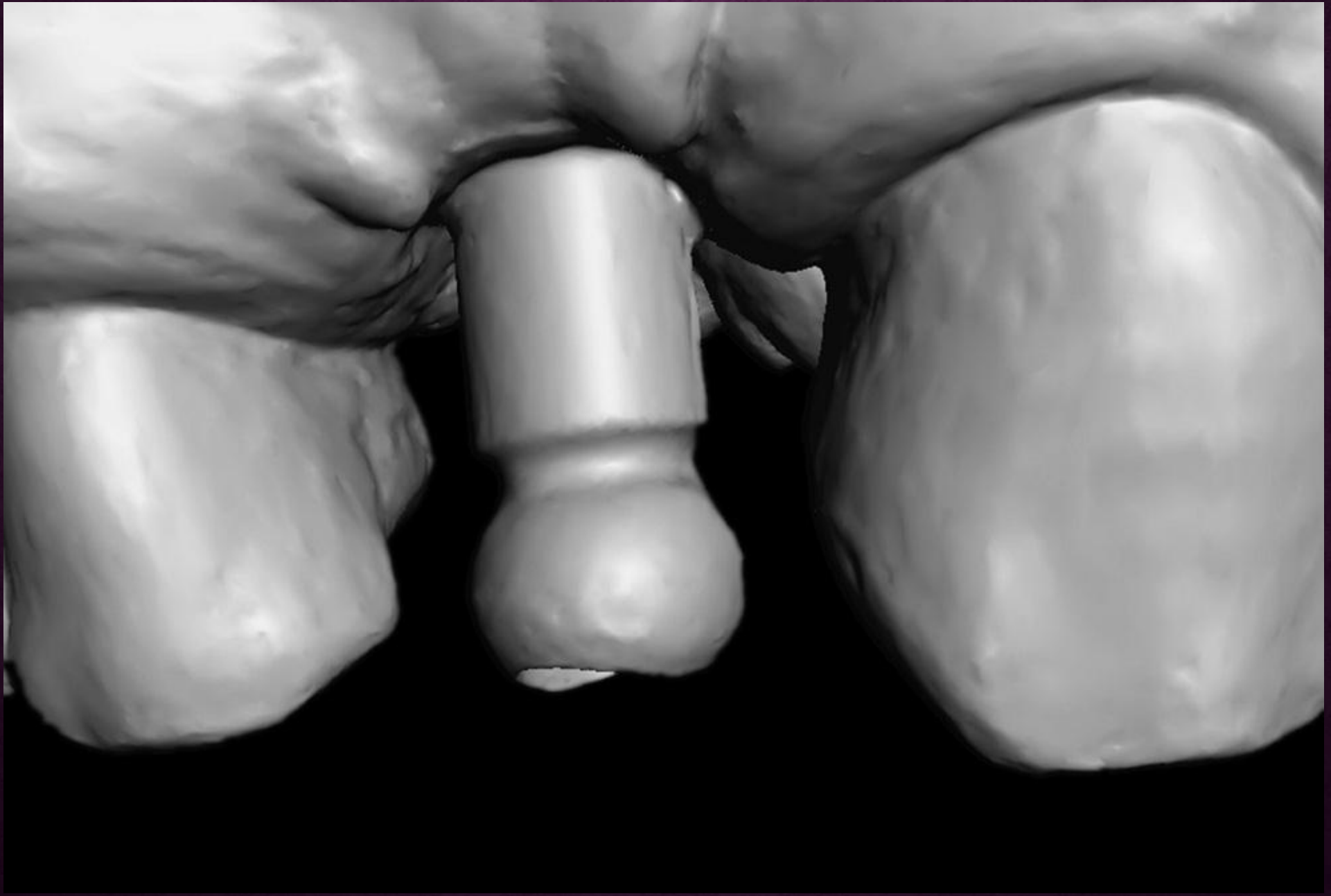
SCAN BODIES

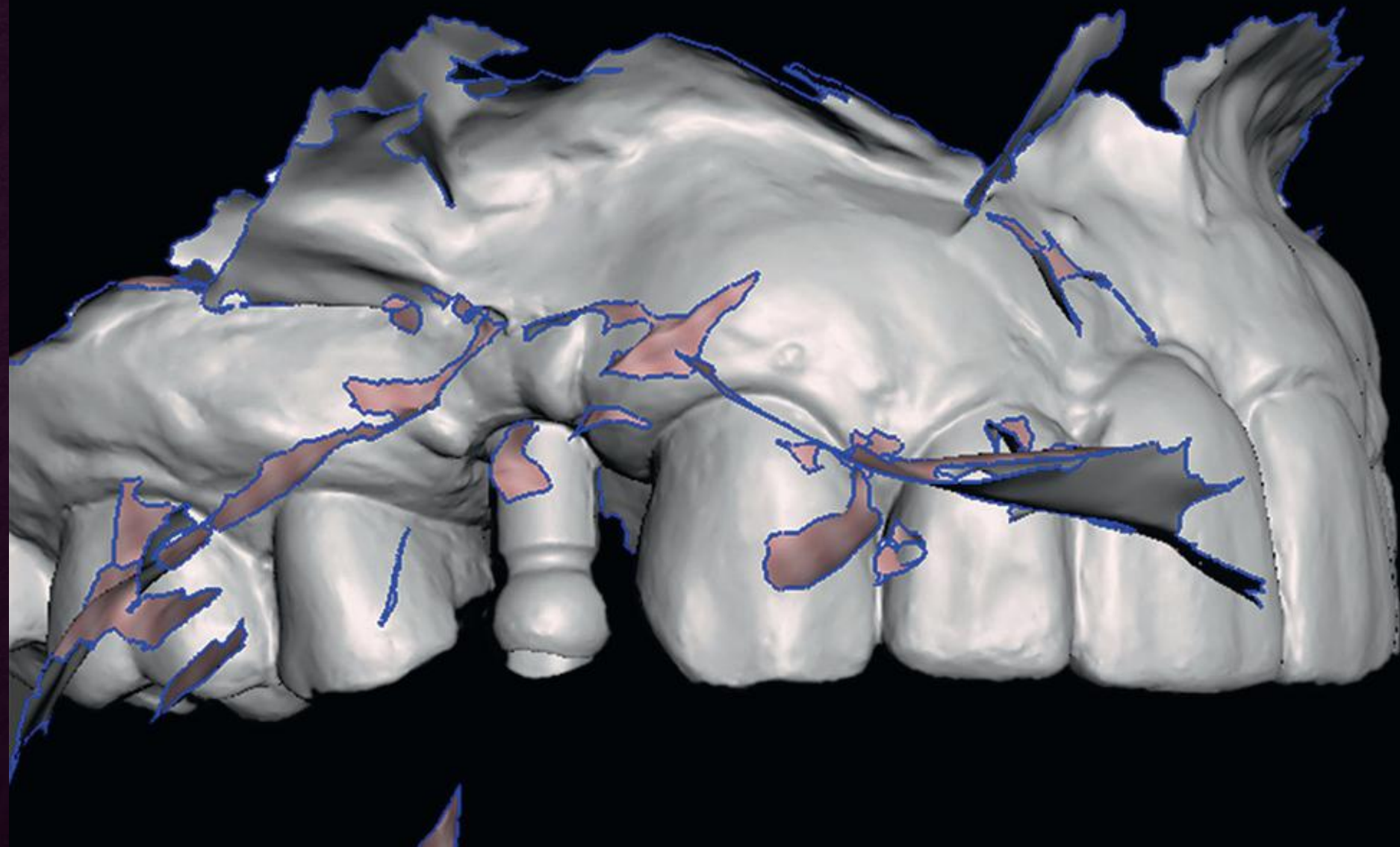
The scanning abutment are used when making digital impressions of implants using an intraoral scanner. The scanning abutment is attached to the implant before the digital scan, and it is recognized by the scanning or design software to indicate the correct implant position.

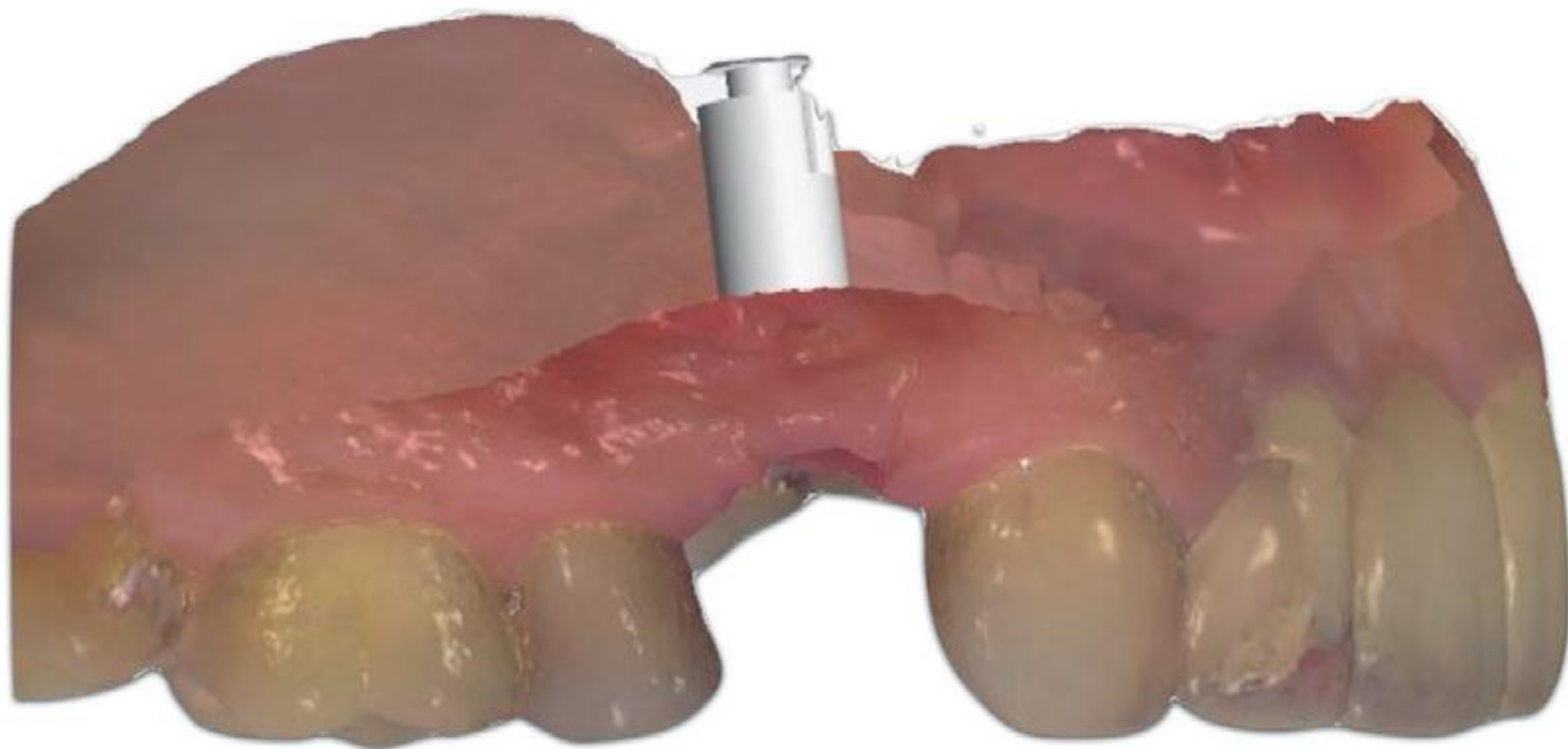
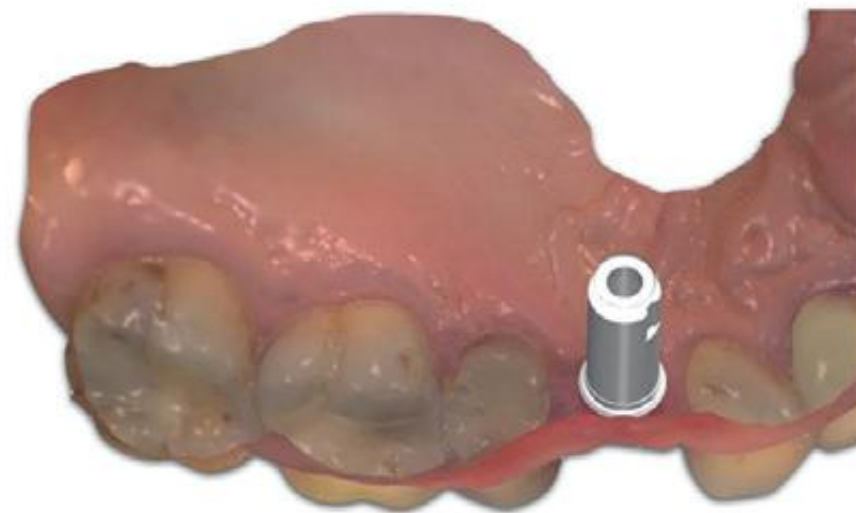
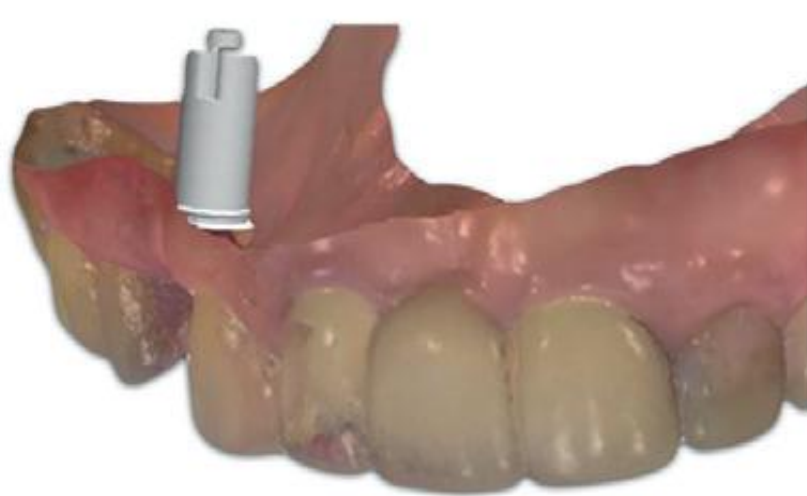


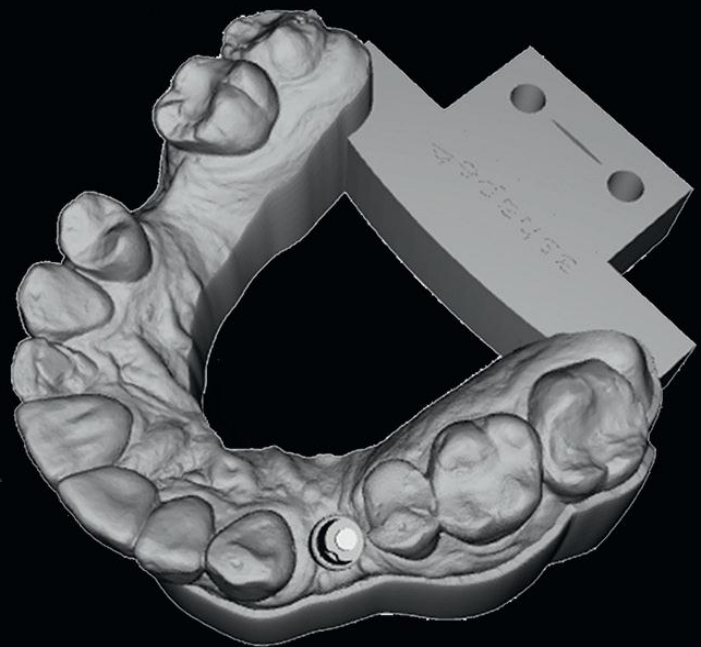




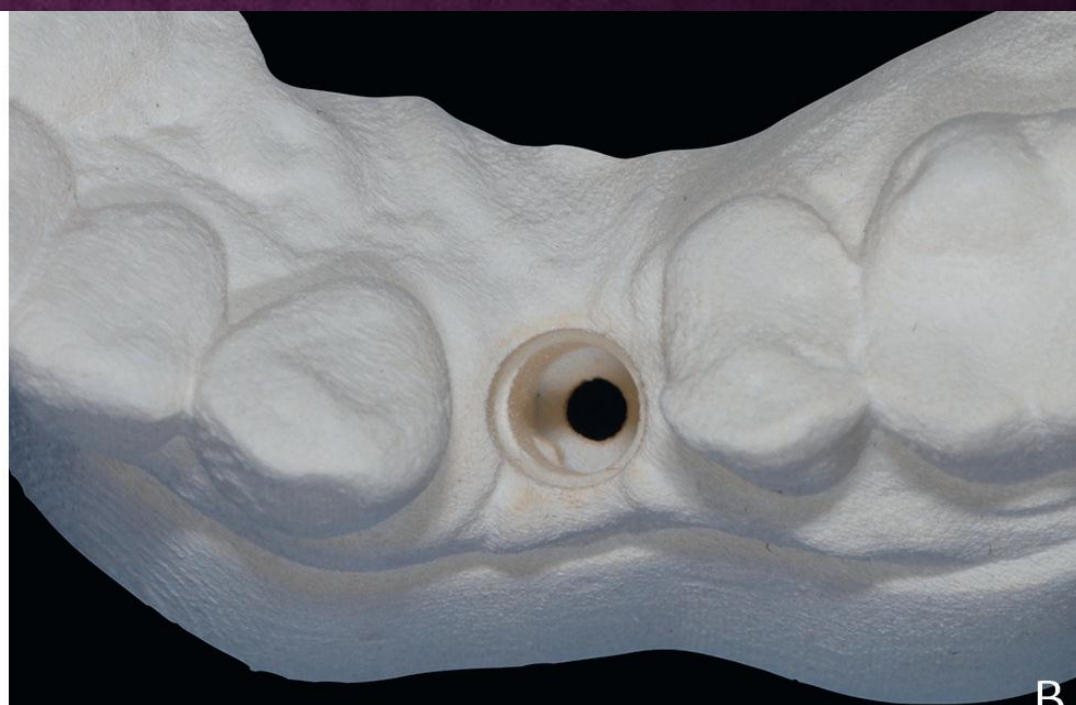

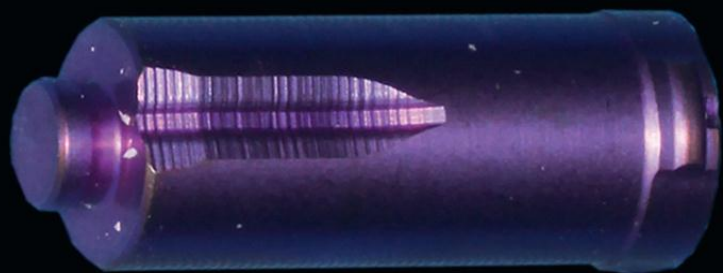




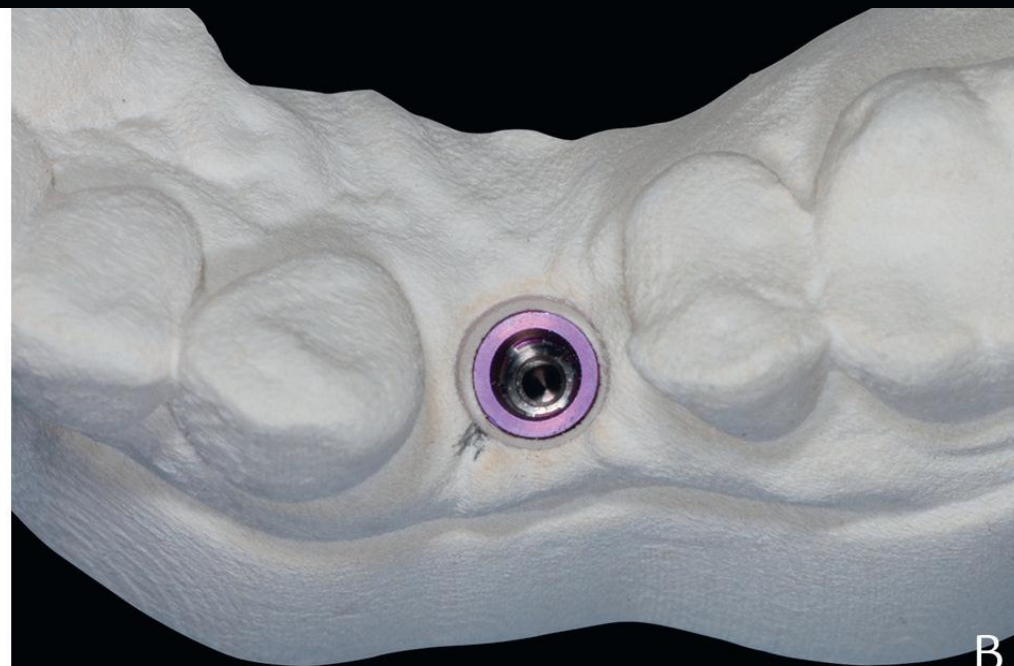A



B



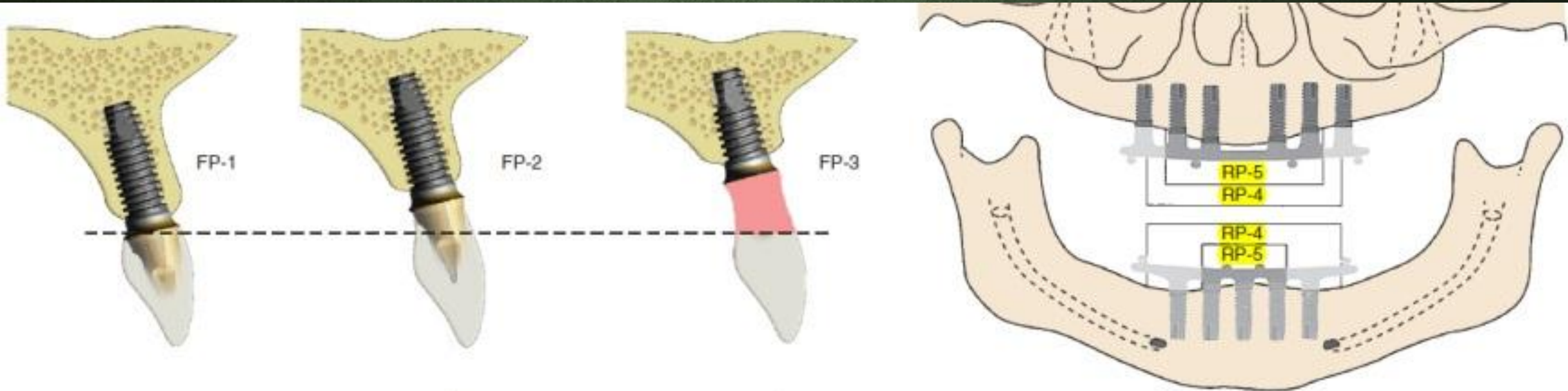
A



B

IMPLANT COMPONENTS

Lecture 8



PROSTHODONTIC CLASSIFICATION

FP-1 Fixed prosthesis; replaces only the crown; looks like a natural tooth.

FP-2 Fixed prosthesis; replaces the crown and a portion of the root; crown contour appears normal in the occlusal half but is elongated or hyper contoured in the gingival half.

FP-3 Fixed prosthesis; replaces missing crowns and gingival color and portion of the edentulous site; prosthesis most often uses denture teeth and acrylic gingiva, but may be porcelain to metal.

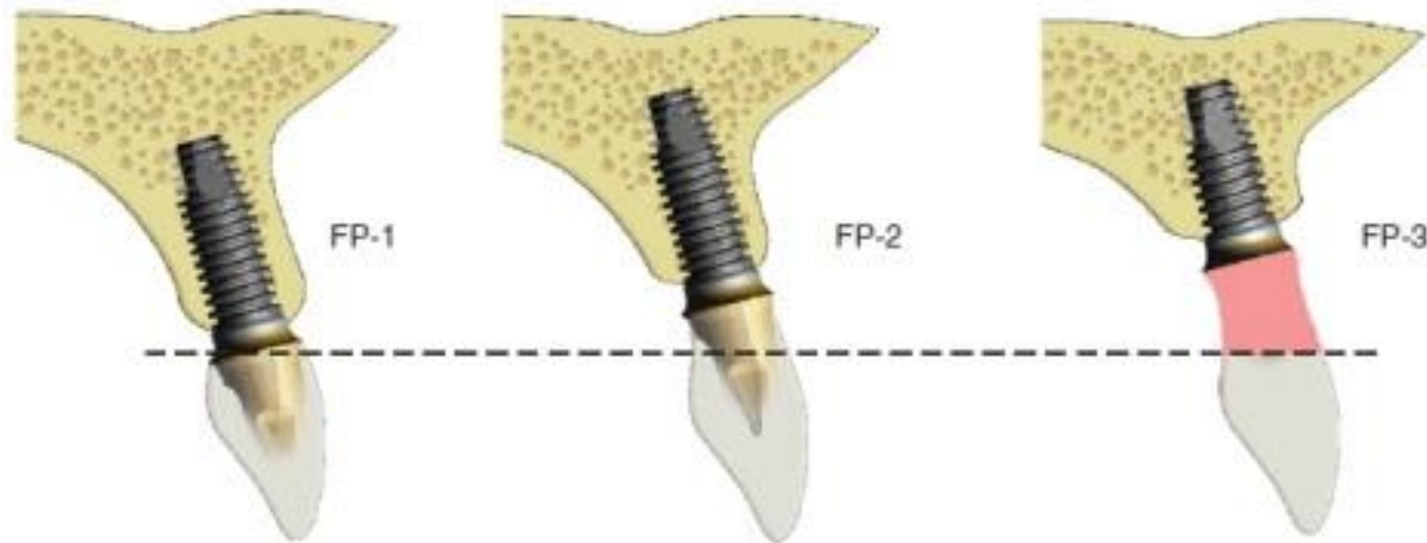
RP-4 Removable prosthesis; overdenture supported completely by implant.

RP-5 Removable prosthesis; overdenture supported by both soft tissue and implant.

PROSTHETIC OPTIONS

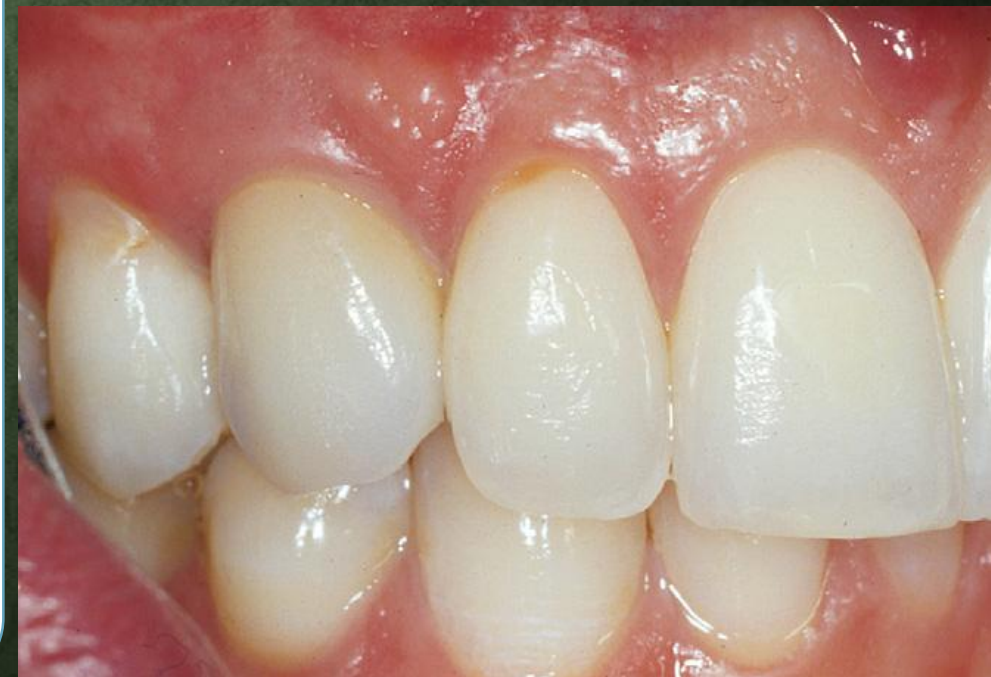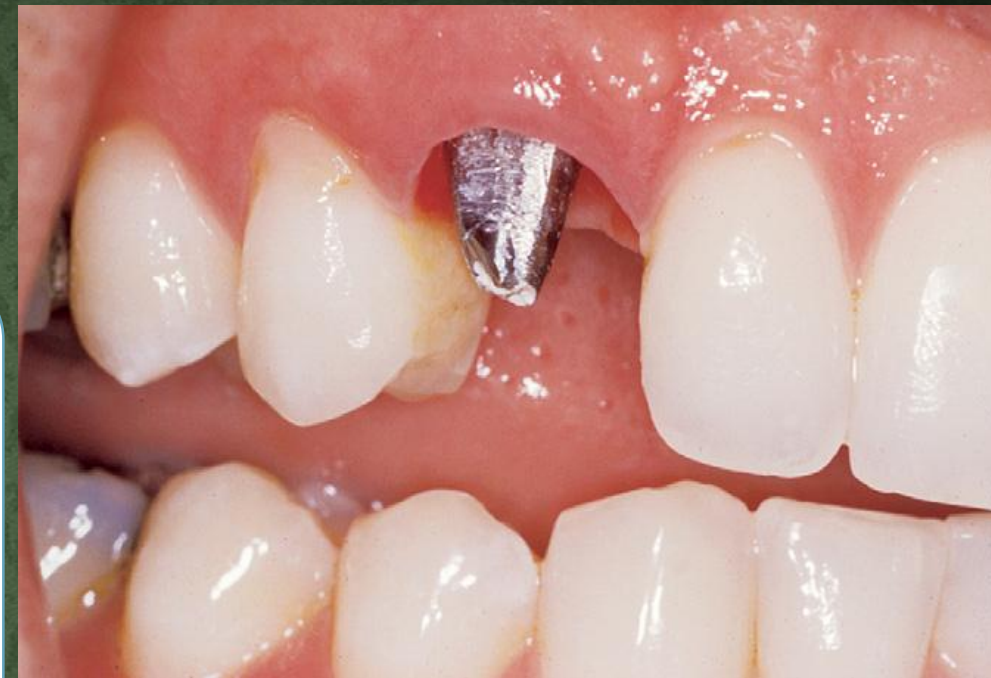The first three options are **Fixed** prostheses (FPs). These three options

- May replace partial (one tooth or several) or total dentitions
- May be cemented or screw retained
- These options depend on the **amount** of hard and soft tissue structures replaced and the **aspects** of the prosthesis in the *esthetic zone*.



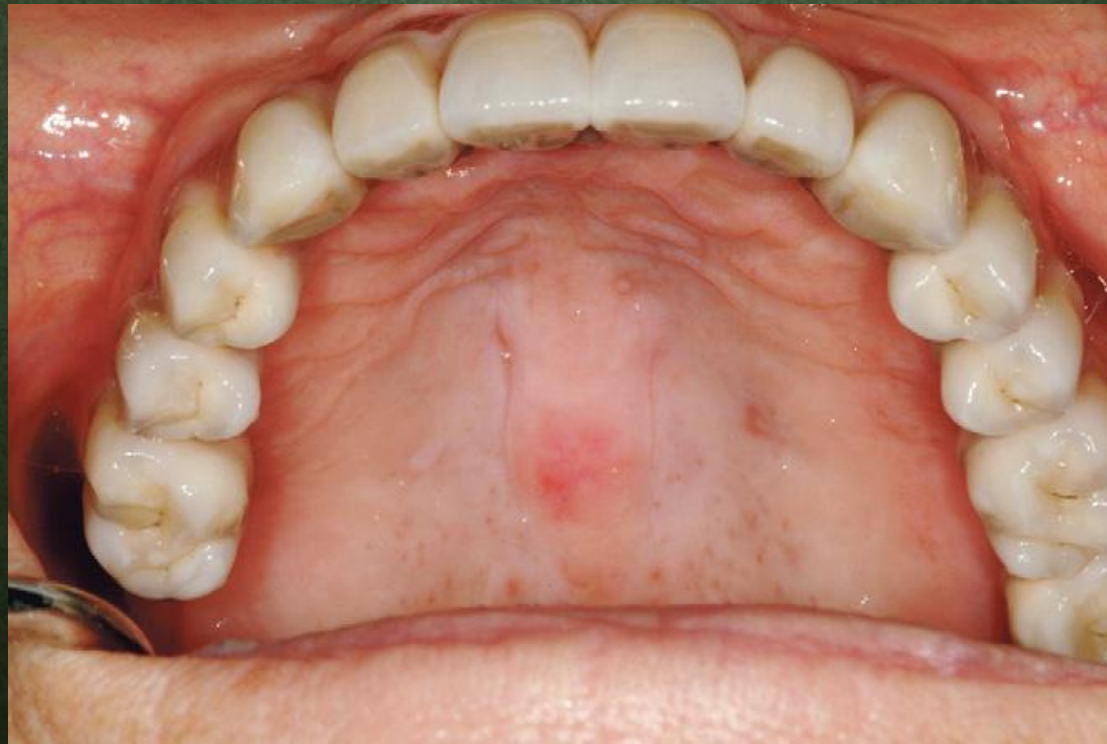FP1

- There must be minimal loss of hard and soft tissues.
- The volume and position of the residual bone must permit ideal placement of the implant in a location similar to the root of a natural tooth.
- The final restoration appears very similar in size and contour to most traditional fixed prostheses
- The restorative material of choice for an FP-1 prosthesis is metal-ceramic or zirconium crown.



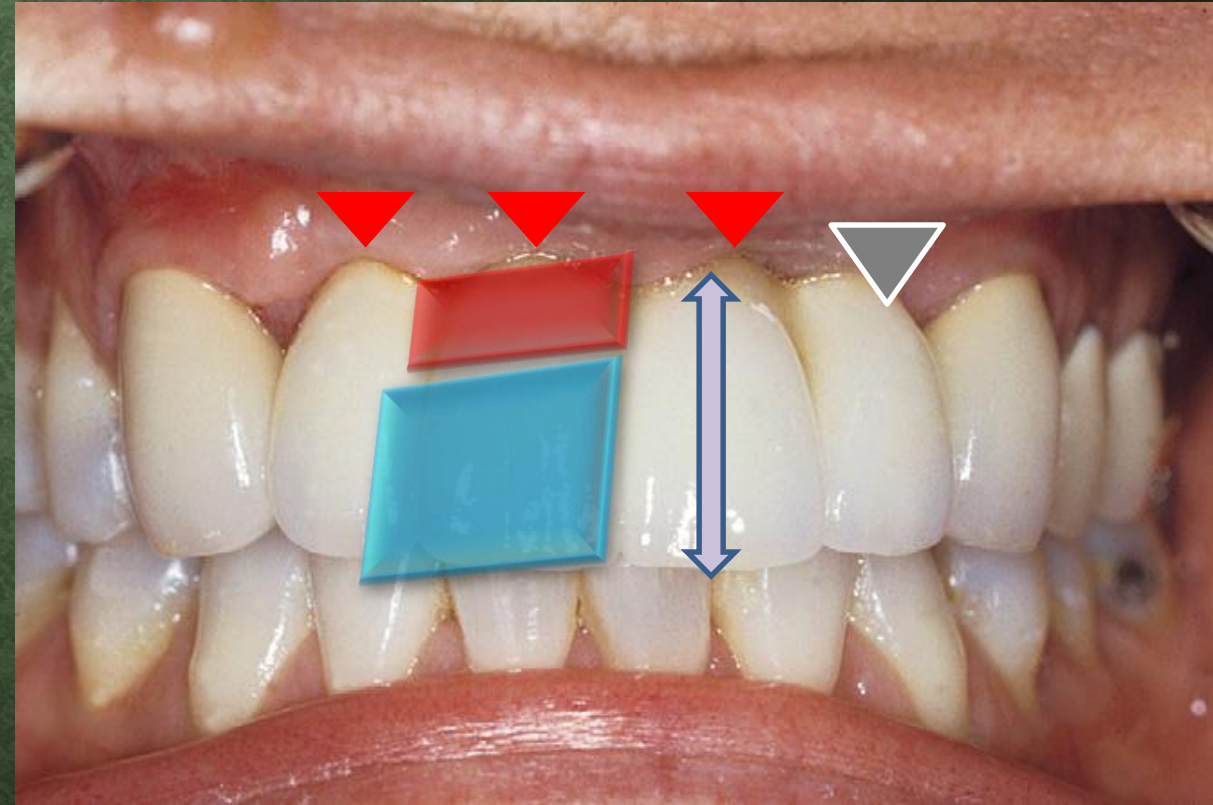
FP1

- The full-arch FP-1 prosthesis has posterior crown contours that are **narrower than natural teeth**, because the implant is smaller in diameter than the tooth.
- As a general rule, the **maxillary** arch has **reduced lingual** contours and the **mandibular** posterior has **reduced buccal** contours.



FP2

- Restore the anatomical **crown** and a **portion of the root** of the natural tooth.
- The available **bone** is more **apical** compared with the ideal bone position of a natural root (*1 to 2 mm below the cement-enamel junction*)
- Has longer clinical crowns than healthy natural teeth
- The soft tissue drape is also reduced around the prosthesis.

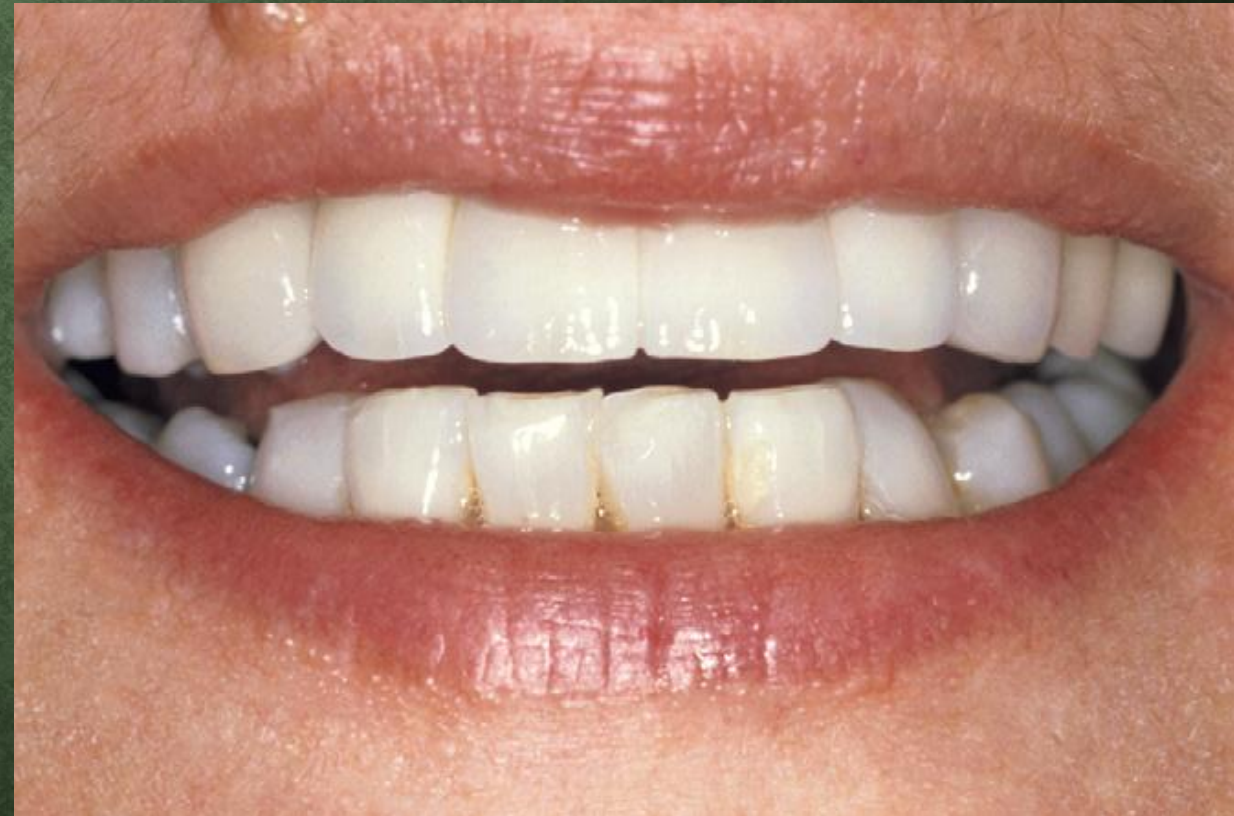

FP2

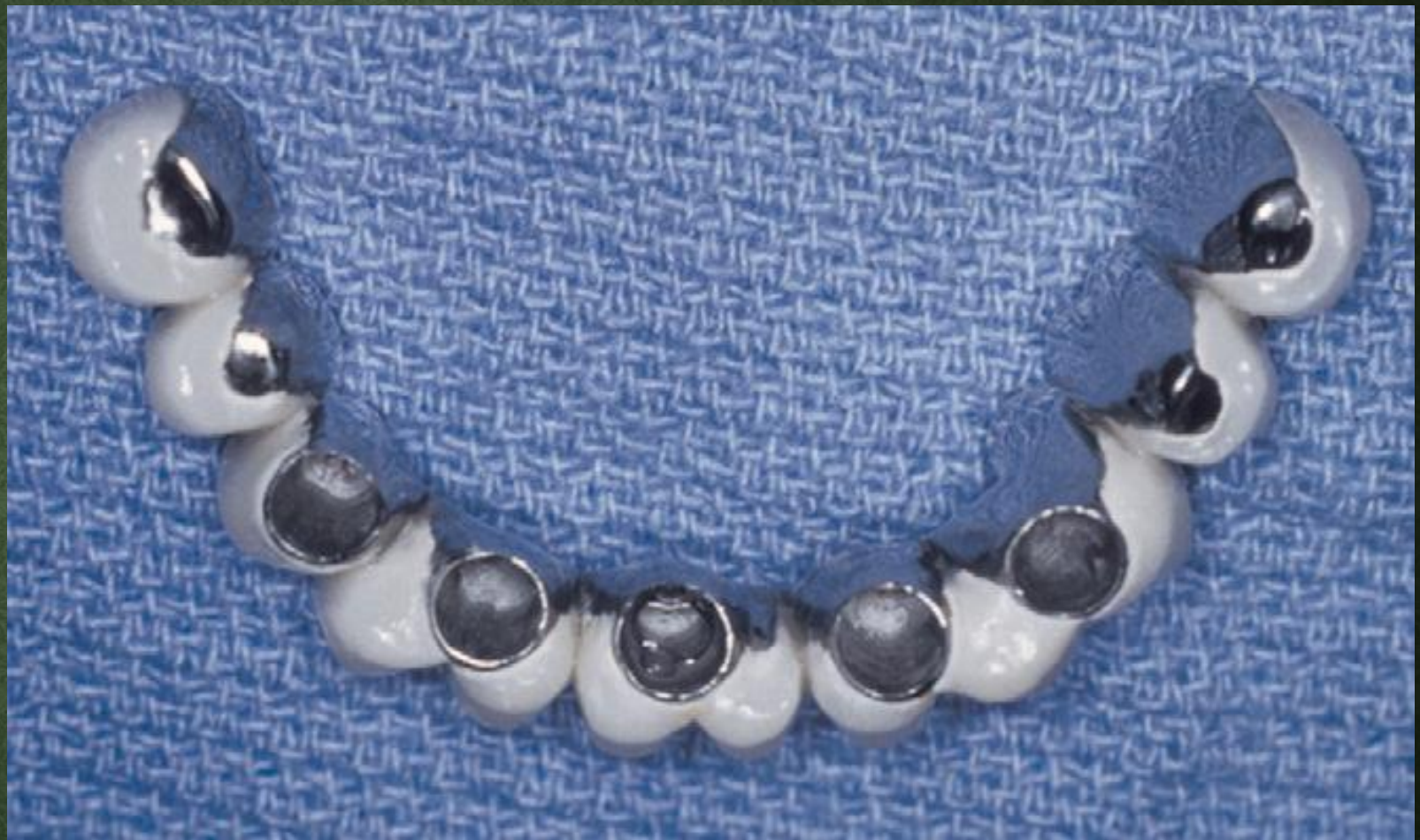➤ FP-2 prosthesis may be fabricated:

When the upper lip during smile does not expose any of the interdental papillary regions

- Mandibular lip position during sibilant sounds of speech.

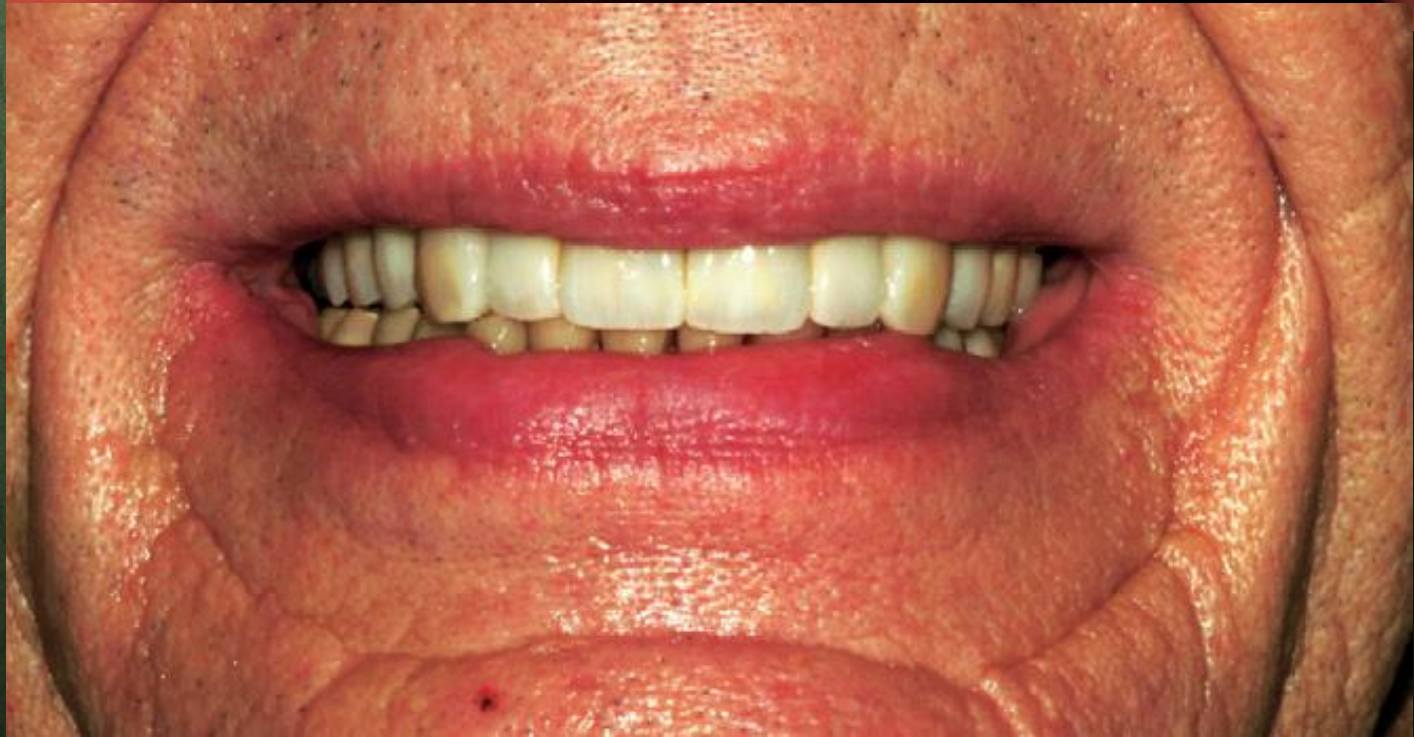
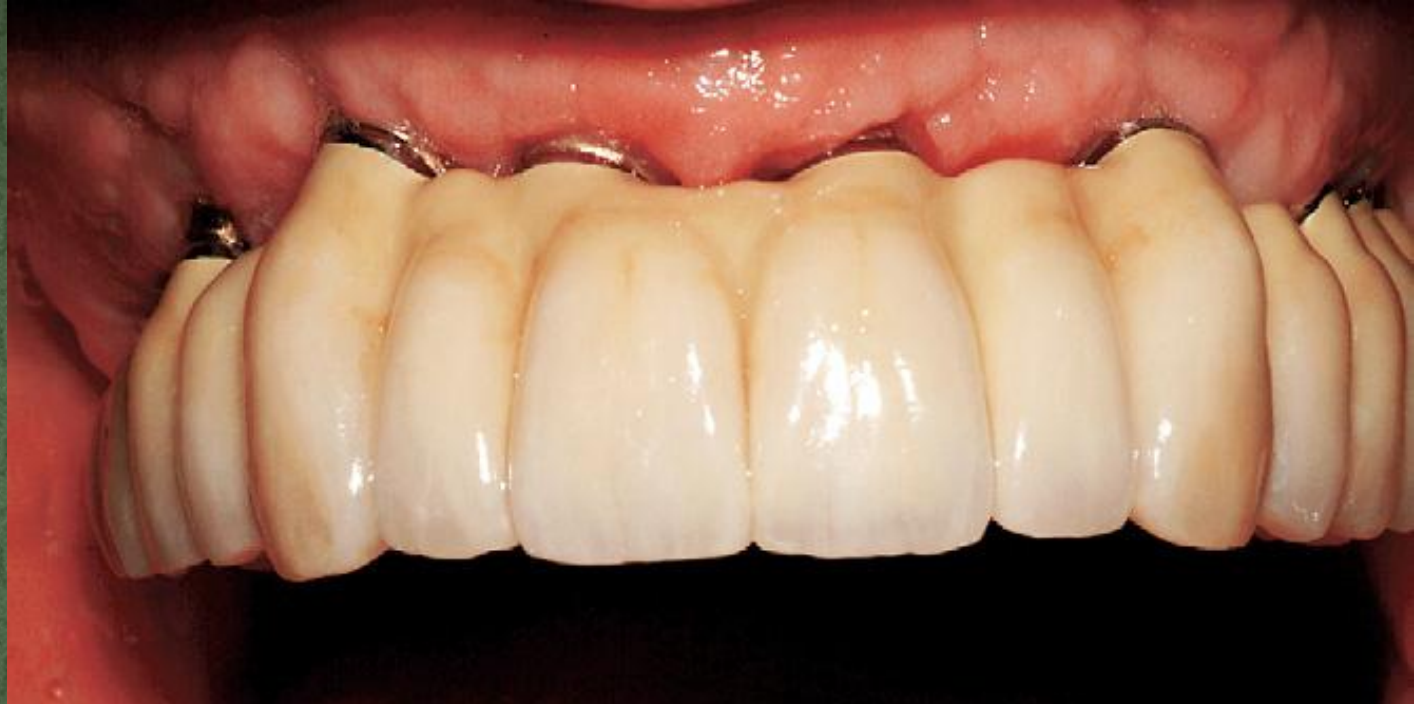
FP2

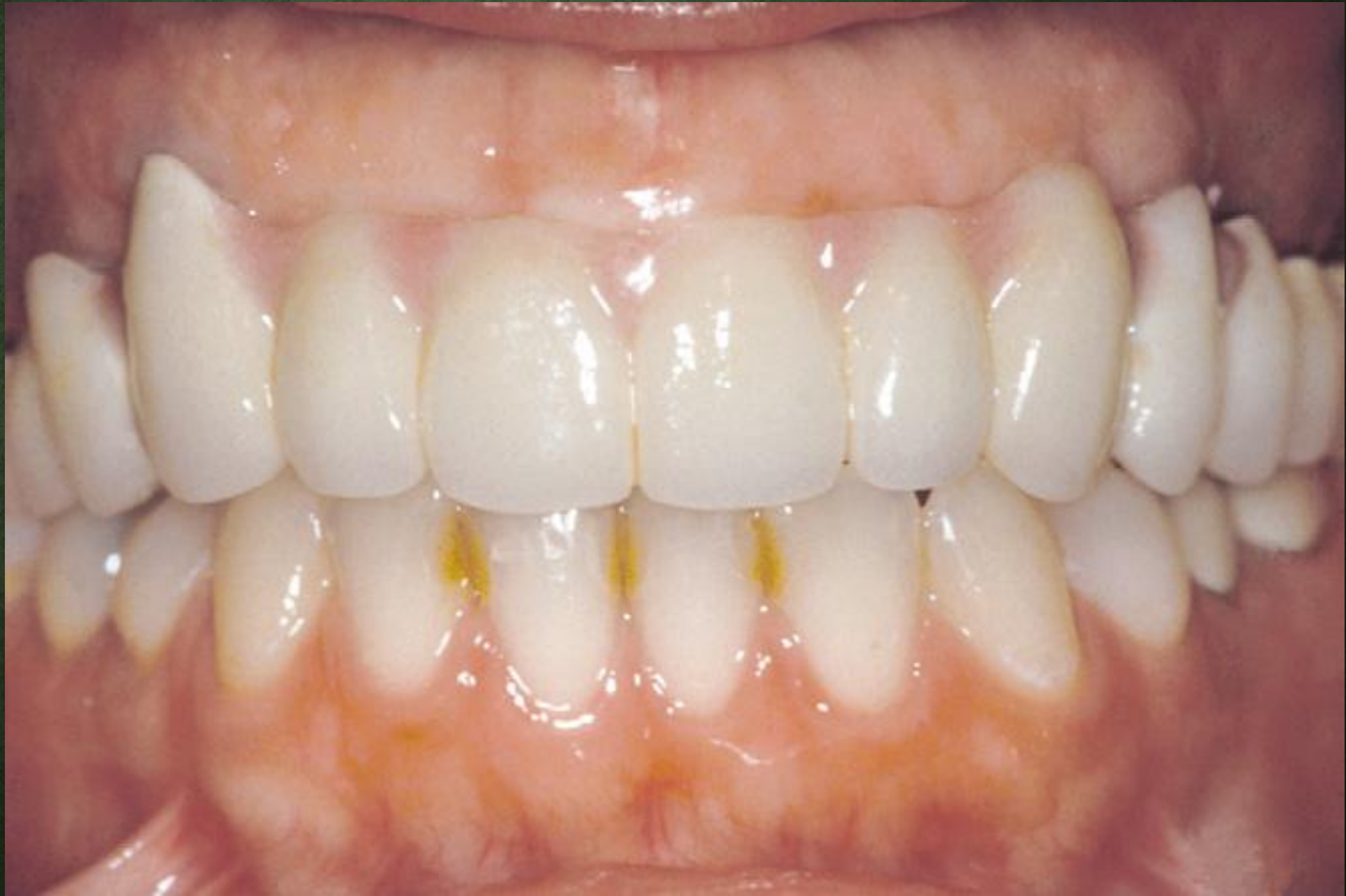

- Does not require as specific an implant position in the **mesial or distal** position because the cervical contour is **not displayed** during function.
- The material of choice for an FP-2 prosthesis is precious metal to porcelain. The amount and contour of the metal work is more relevant in an FP-2 prosthesis.

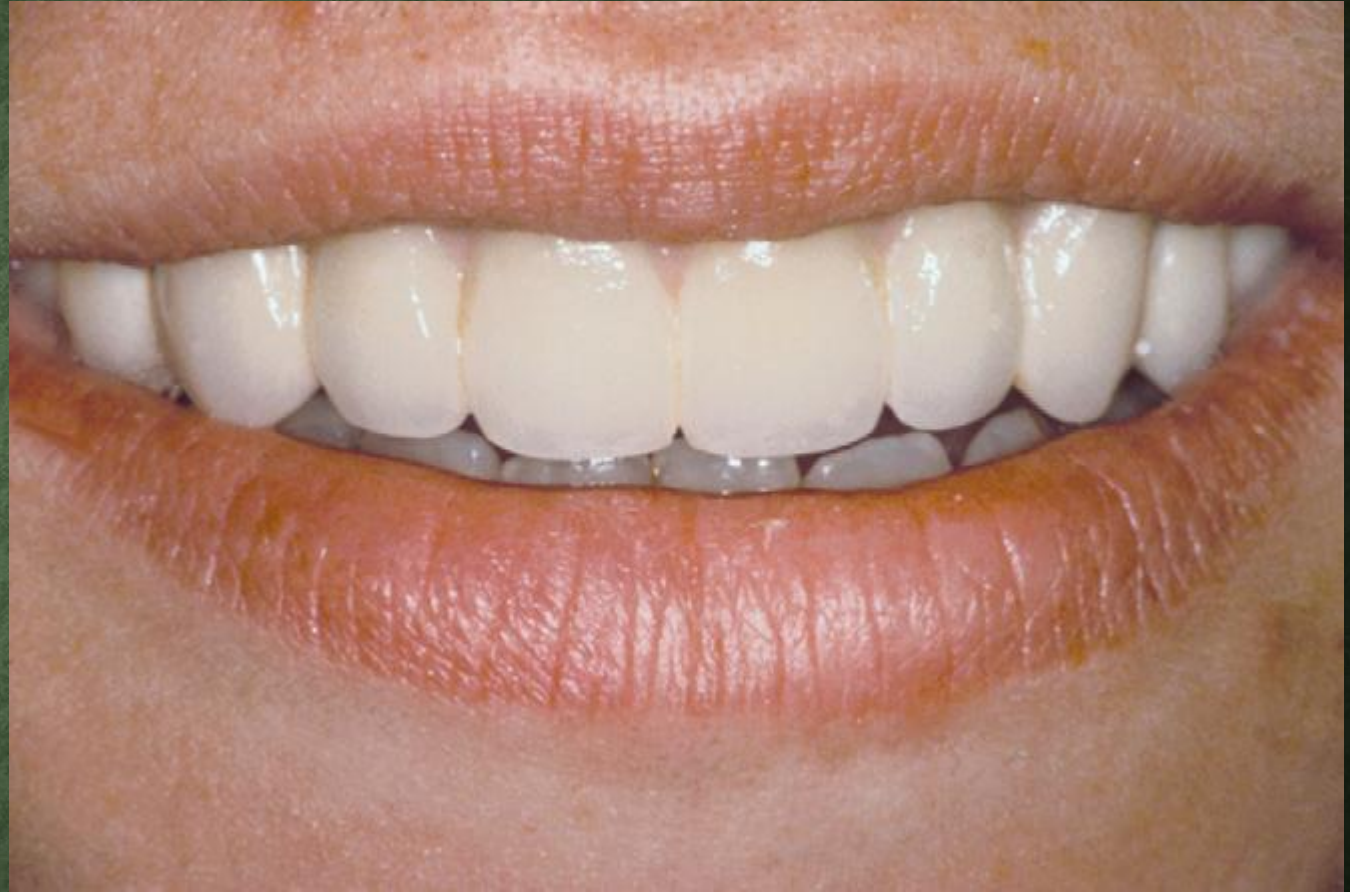FP2



FP3



FP3



As a result of the restored gingival color of the FP-3, the teeth have a ***more natural appearance*** in **size** and **shape** and the pink restorative material mimics the **interdentary papillae** and **cervical emergence** region.

FP3

There are basically two approaches for an FP-3 prosthesis:

HYBRID RESTORATION
of denture teeth and acrylic and
metal frame.

**PORCELAIN METAL
RESTORATION.**

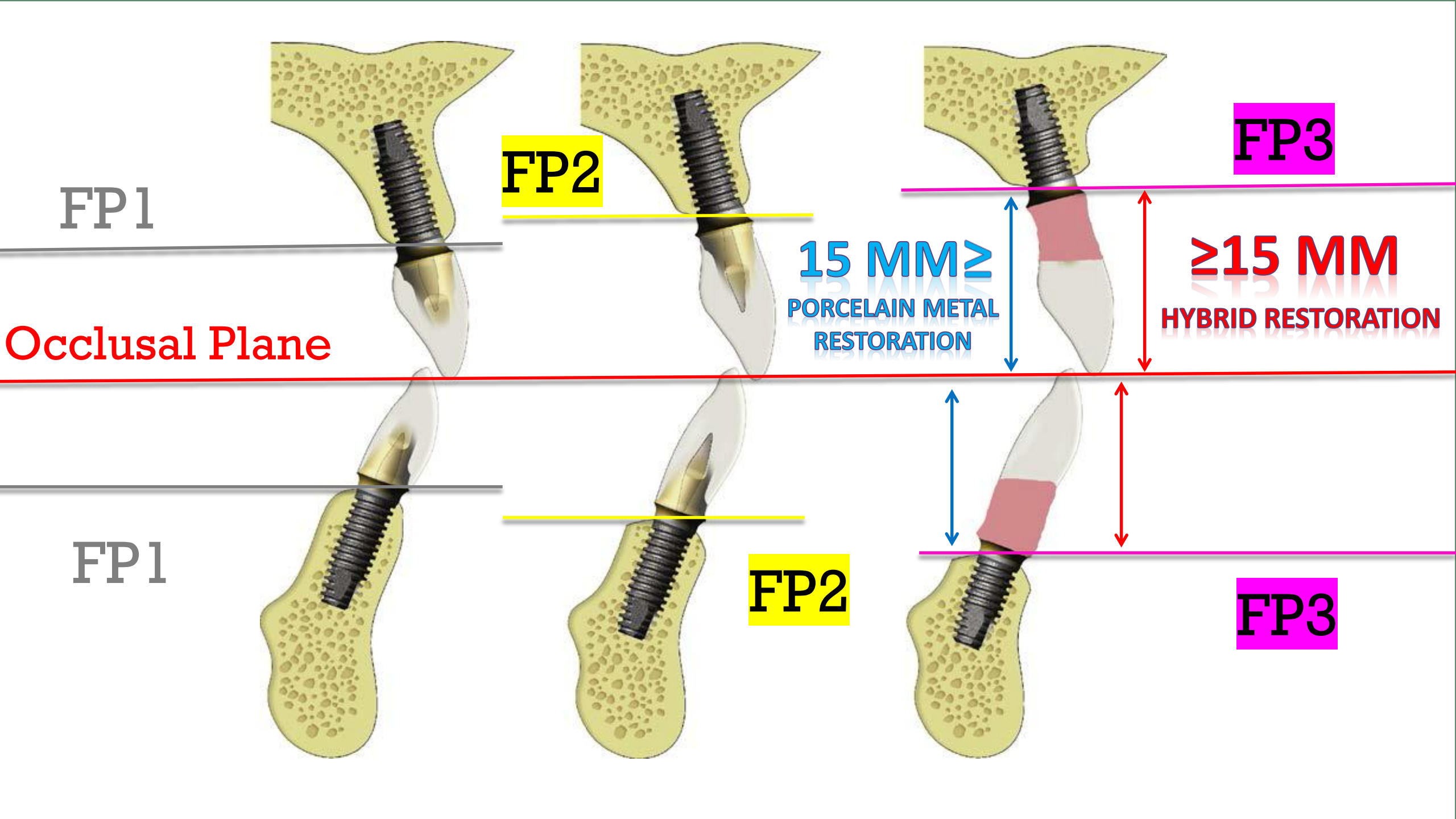
The primary factor that determines the restoration material is the amount of crown height space

Occlusal vertical dimension

≥ 15 MM

≤ 15 MM

FROM THE BONE TO THE OCCLUSAL PLANE



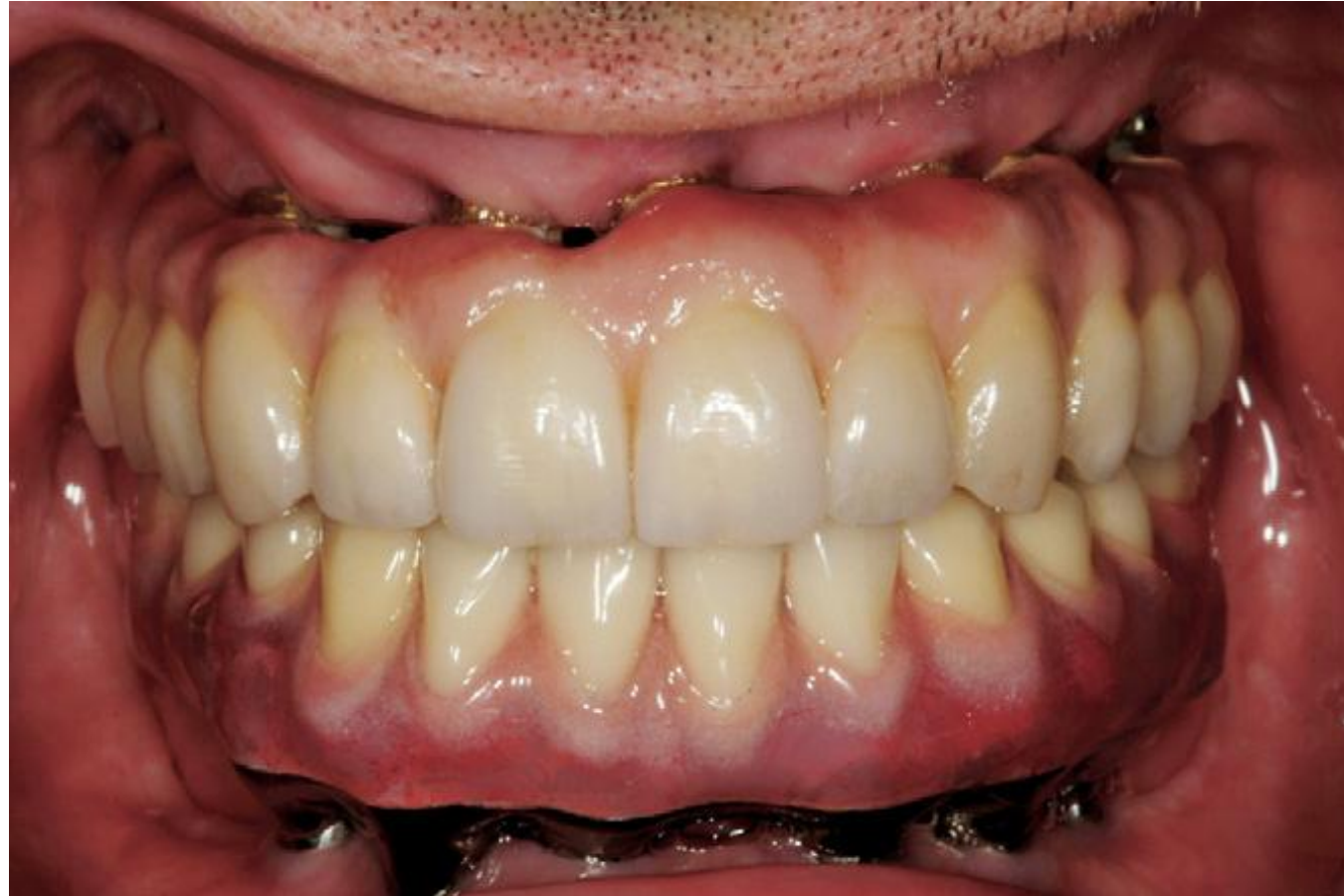ADVANTAGES OF HYBRID RESTORATION

1. Smaller metal framework with denture teeth and acrylic to join these elements together.
2. Less expensive to fabricate.
3. Highly esthetic because of the premade denture teeth and acrylic pink soft tissue replacements.
4. The intermediary acrylic between the denture teeth and framework may reduce the impact force of dynamic occlusal loads.
5. Easier to repair in porcelain fracture.
6. The greater crown heights allow the correction of incisal edge positions.

DISADVANTAGE :

The fatigue of acrylic is greater than the traditional prosthesis; therefore repair of the restoration is more commonly needed.

The maxillary FP-2 or the FP-3 prosthesis is often extended or juxtaposed to the maxillary soft tissue so that speech is not impaired. Hygiene is more difficult to control. FP-3 **porcelain-to-metal** restoration in the maxilla



The mandibular restoration may be left above the tissue. This facilitates oral hygiene in the mandible. FP-3 **hybrid acrylic-metal** denture tooth in the mandible

REMOVABLE PROSTHESES

Patients are able to remove the restoration, but not the implant supported superstructure attached to the abutments.

There are two kinds of removable prostheses, based upon support of the restoration

RP4

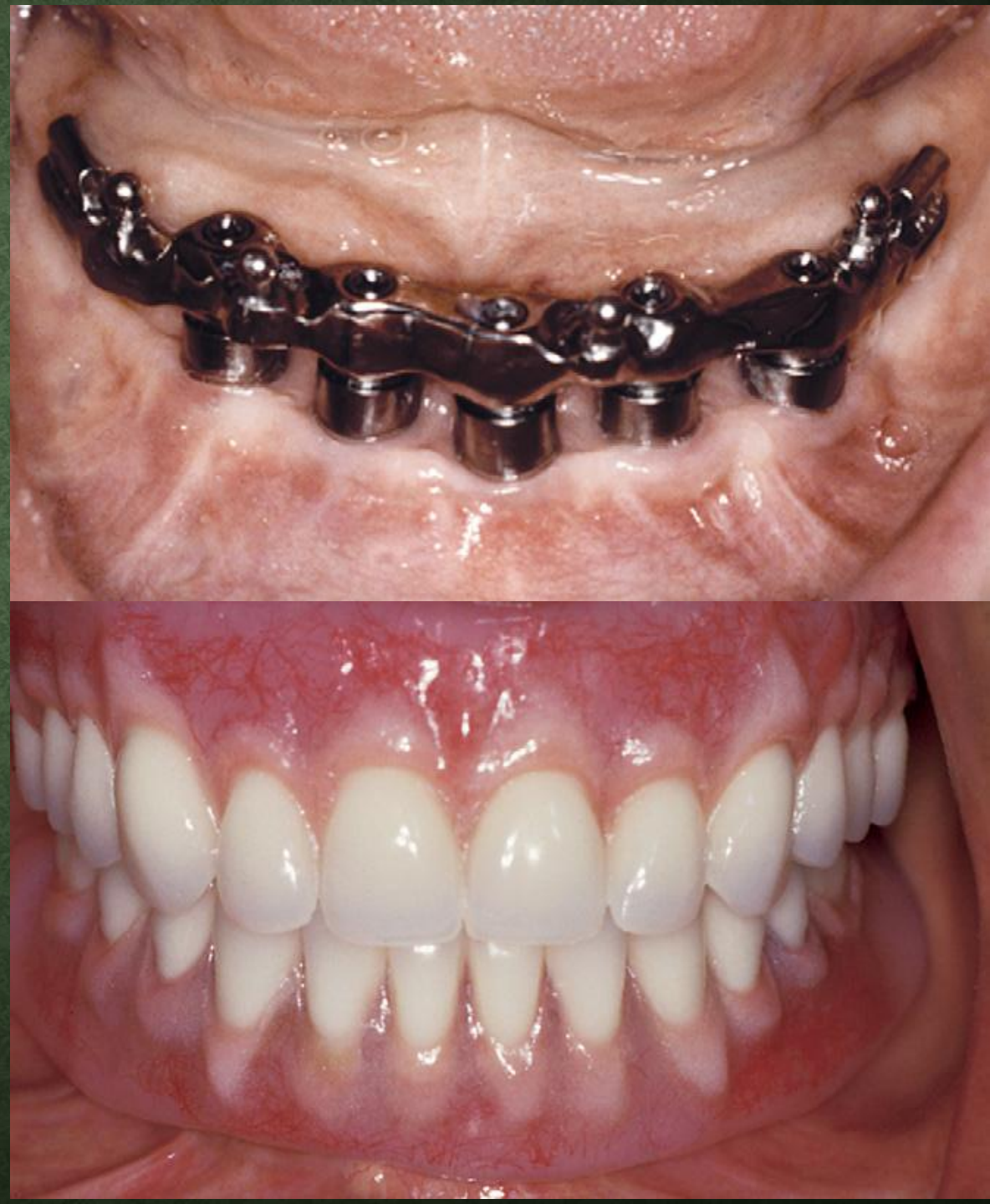completely supported by the implants, teeth, or both

RP5

combining implant and soft tissue support.

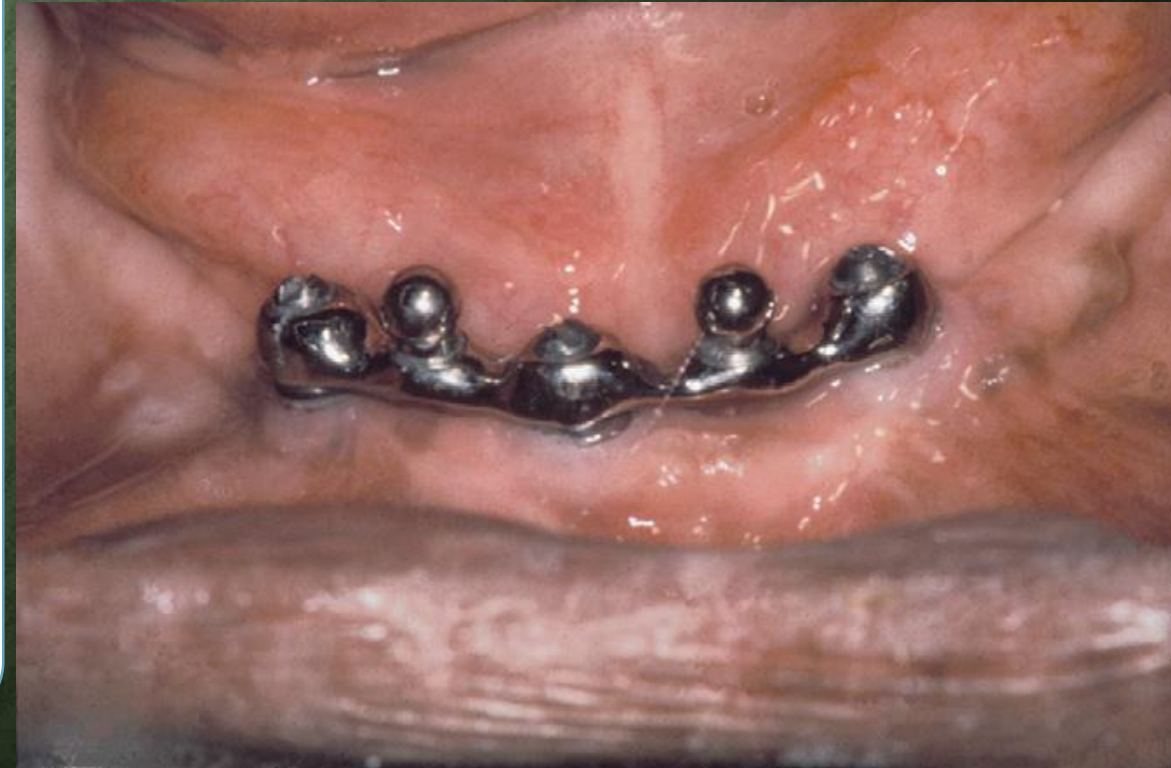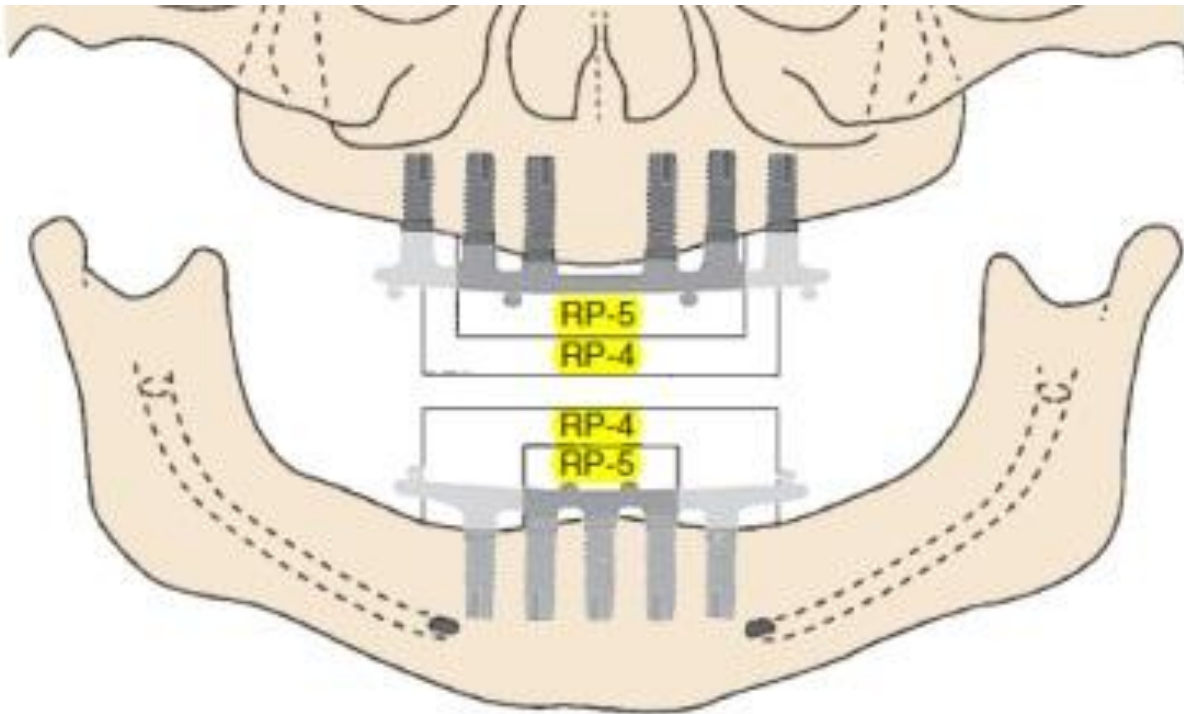
RP4

- The restoration is rigid when inserted (usually an overdenture) that is ***completely implant supported***
- **5** or **6** implants in the mandible
- **6** to **8** implants in the maxilla are required
- Requires a more lingual and apical implant placement in comparison with the implant position for a fixed prosthesis.
- The RP-4 prosthesis may have the same appearance as an FP-3 restoration



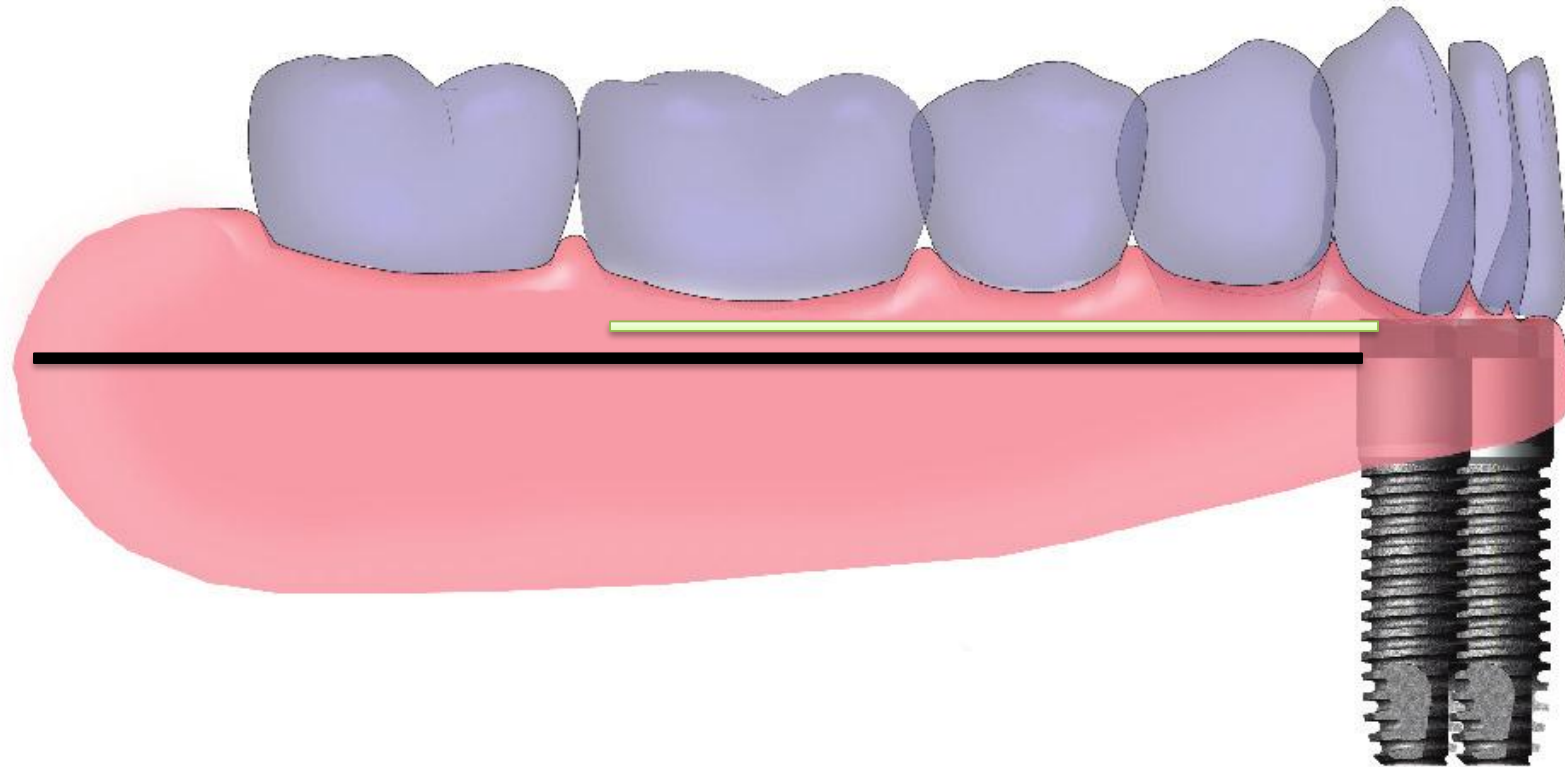
RP5

- The primary advantage of an RP-5 restoration is the reduced cost.

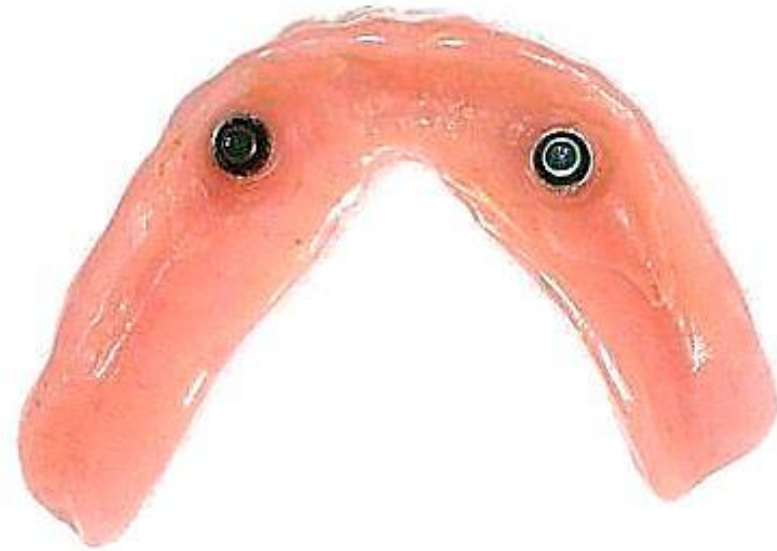
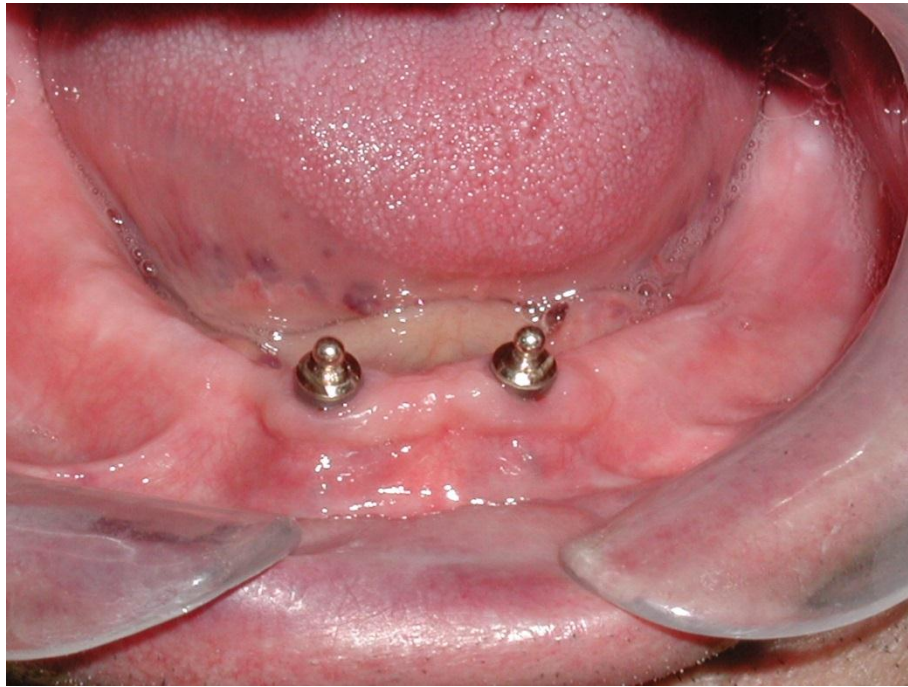
BONE RESORPTION

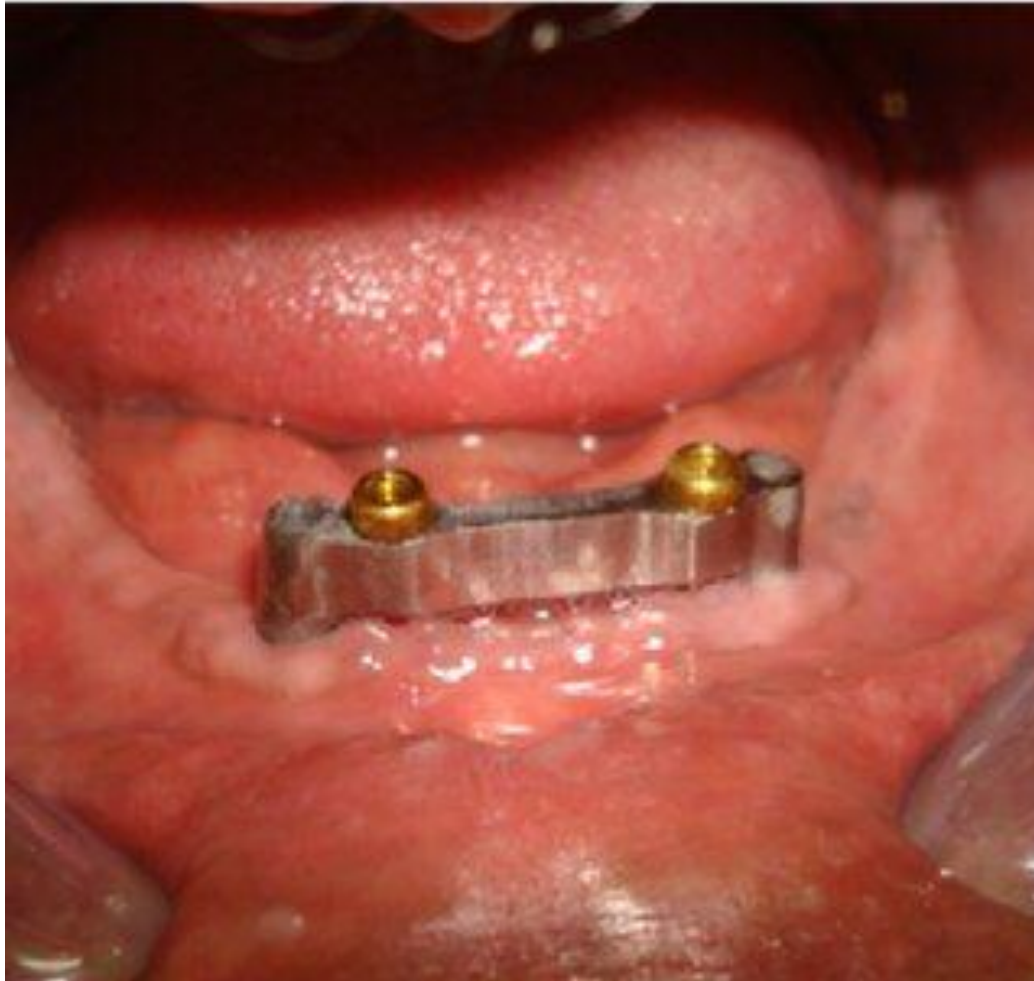- The clinician and the patient should realize that the bone will continue to resorb in the soft tissue–borne regions of the prosthesis. Relines and occlusal adjustments every few years are common maintenance requirements of an RP-5 restoration.
- overdenture restoration usually do not extend beyond the first molar. This helps prevent a hidden cantilever,



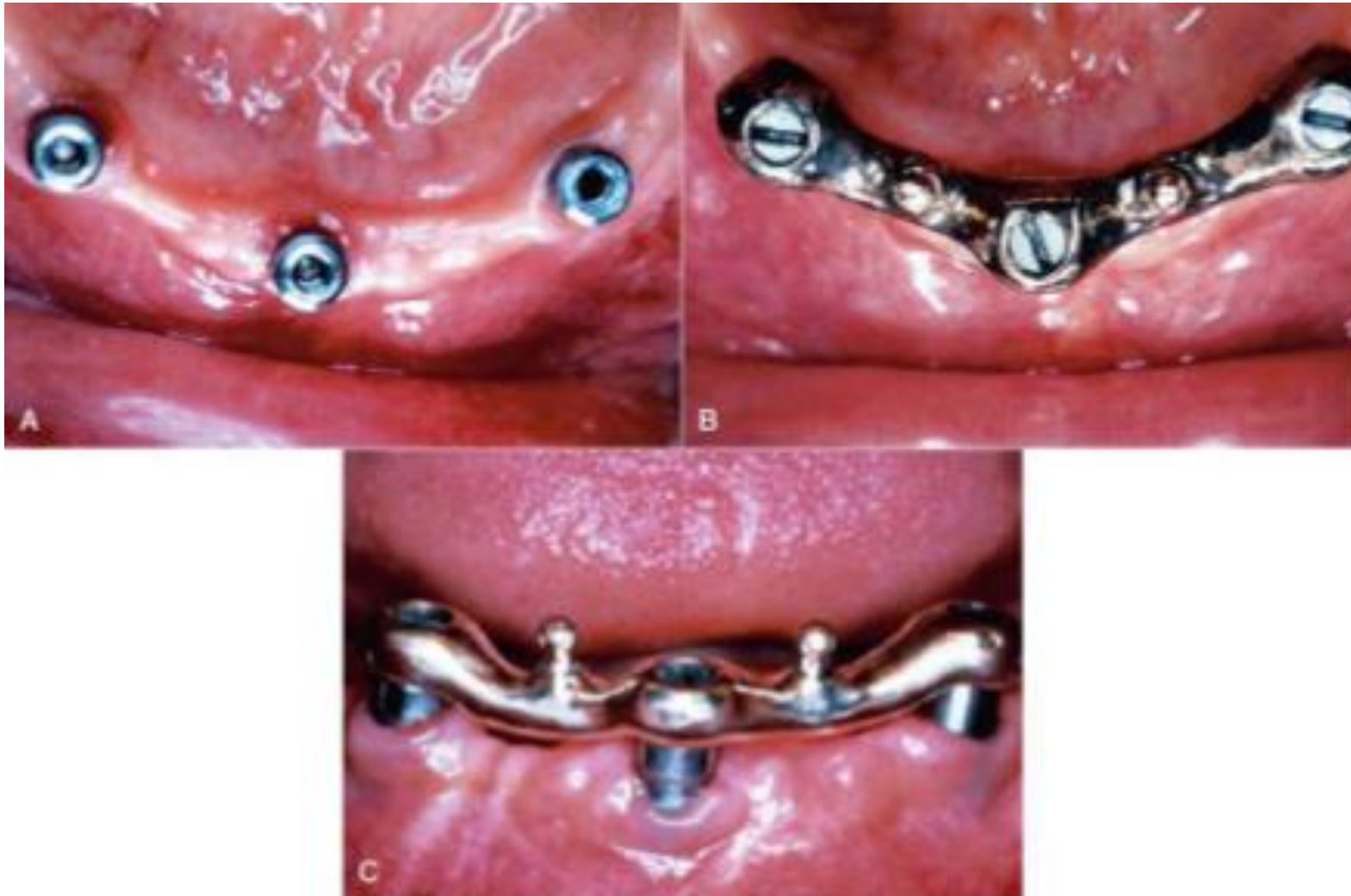The completely edentulous mandibular
overdenture may have:
(1) two anterior implants independent of each
other.



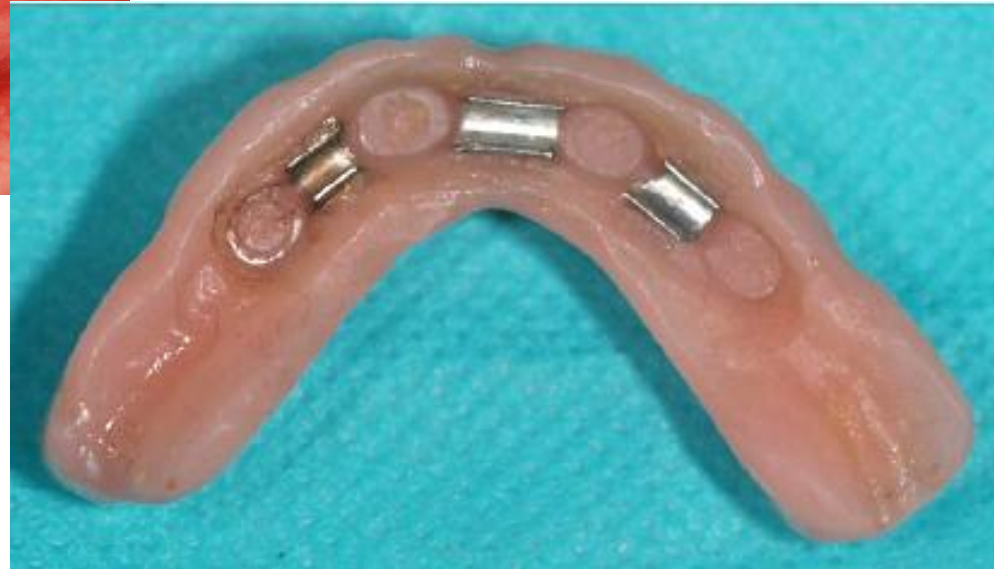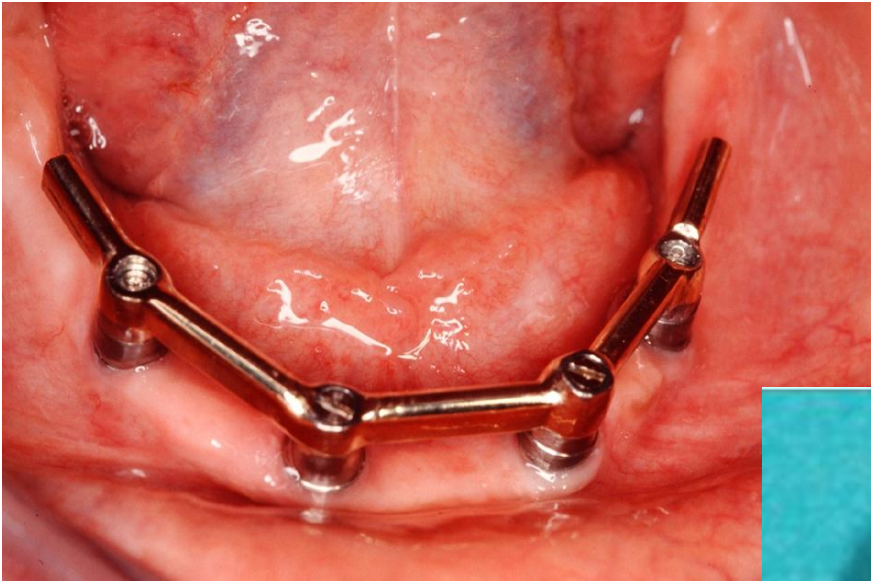
(2) splinted implants in the canine region to enhance retention.



(3) three splinted implants in the premolar and central incisor areas to provide lateral stability



(4) implants splinted with a cantilevered bar to reduce soft tissue abrasions and to limit the amount of soft tissue coverage needed for prosthesis support.



ADVANTAGES OF REMOVABLE

- Implant-Supported Prosthesis in the Completely Edentulous

1. Facial esthetics can be enhanced with labial flanges and denture teeth compared with customized metal or porcelain teeth. The labial contours of the removable restoration can replace lost bone width and height and support the labial soft tissues without hygienic compromise.
2. The prosthesis can be removed at night to manage nocturnal parafunction.
3. Fewer implants may be required.
4. Less bone augmentation may be necessary before implant insertion.
5. Shorter treatment if no bone augmentation is required.
6. The treatment may be less expensive for the patient.
7. Long-term treatment of complications is facilitated.
8. Daily home care is easier.

ADVANTAGES OF FIXED RESTORATIONS

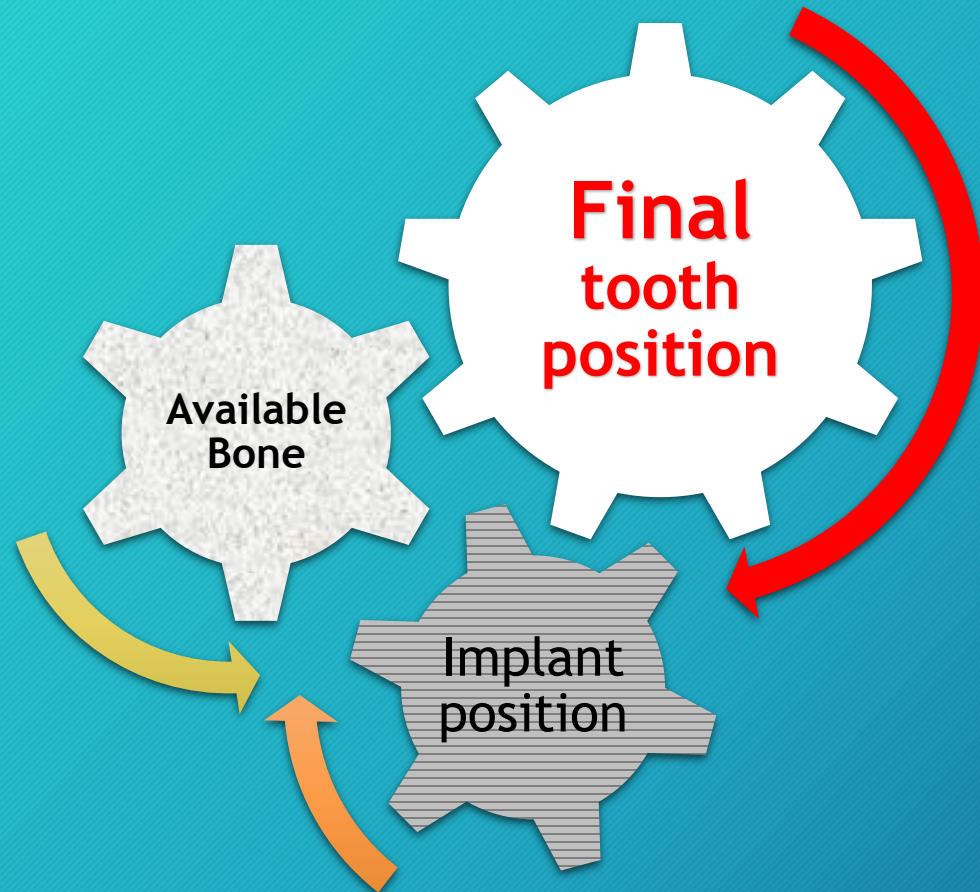
in the Partially Edentulous Patient

1. Psychological (feels more like natural teeth)
2. Less food entrapment
3. Less maintenance (no attachments to change or adjust)
4. Longevity (lasts the life of the implants)
5. Similar overhead cost as completely implant supported overdentures

Treatment Planning Principles

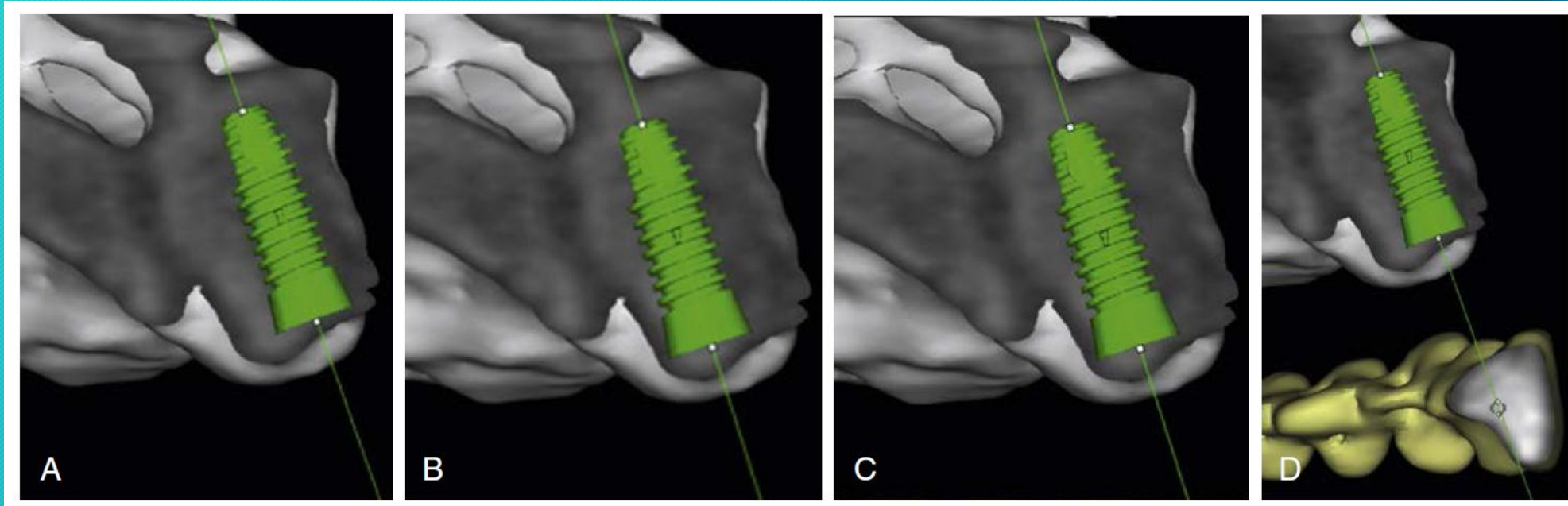
Lecture 9

Evaluation and Determination of the Ideal Implant Position Prior To Obtaining a CBCT



- The ideal location of the final tooth position of the prosthesis must be determined to correlate the positioning of the implant in relation to the available bone. Without a known prosthetically driven location, the implant may be surgically placed in an incorrect position, leading to biomechanical issues and future complications.

Fabrication of Radiographic Template (Scanning Template)



(A-C) If no correlation exists between the implant and final prosthesis, the implant may not be planned in the ideal position. (D) With a radiopaque template, the ideal implant position may be correctly transferred to the surgical treatment plan, thereby allowing for implant placement to be directly related to the final prosthesis.

Evaluation of Bone Density

- The determination of the bone density values allows for modification of the

Surgical: (drilling protocol, insertion torque, implant size determination, number of implants).

Prosthetic: (healing time, progressive bone loading) protocols.

Virtual Implant Placement

- Manual implant placement may be performed in most of the digital software, It will allow the user to place a “virtual implant” in the proposed position according to anatomic factors. Analysis may be made for ideal positioning, and modifications are easily completed.
- Most software programs have implant libraries that consist of various implant types and allow for the determination of the exact implant dimensions (i.e., the diameter, length, and thread size).
- The implant position may be evaluated and adjusted accordingly with respect to bony anatomy, prosthesis type, and location of vital structures.



1. SimPlant Start

2. Segment

3. Prepare for planning

Reorient axial images to occlusal plane

Create or change:

- Panoramic curve
- Nerve
- Virtual Teeth
- Graft volume

You can also

- Ask Dr. James ...
- Create an implant
- Create a new plan
- implant

Refined implant movements

Implant Properties & List

What to do next?

- Ask Dr. James ...
- Request SurgiGuide

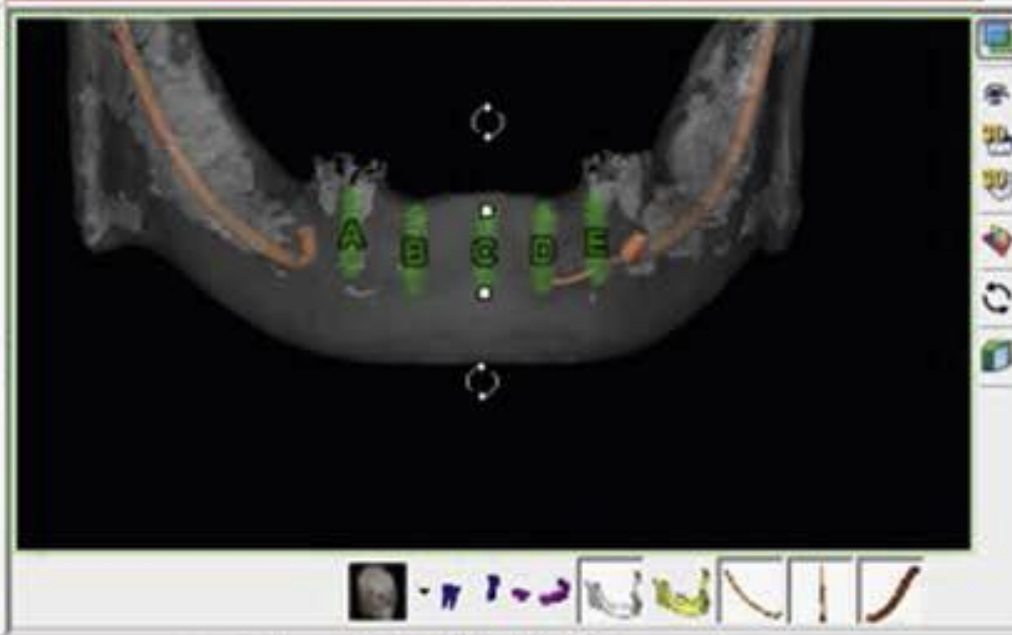
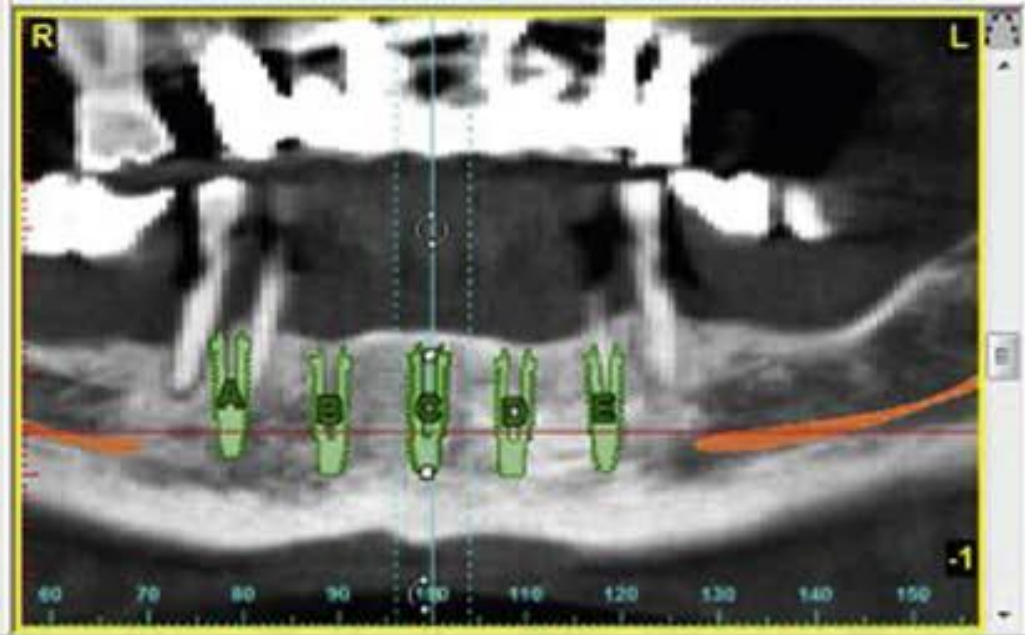
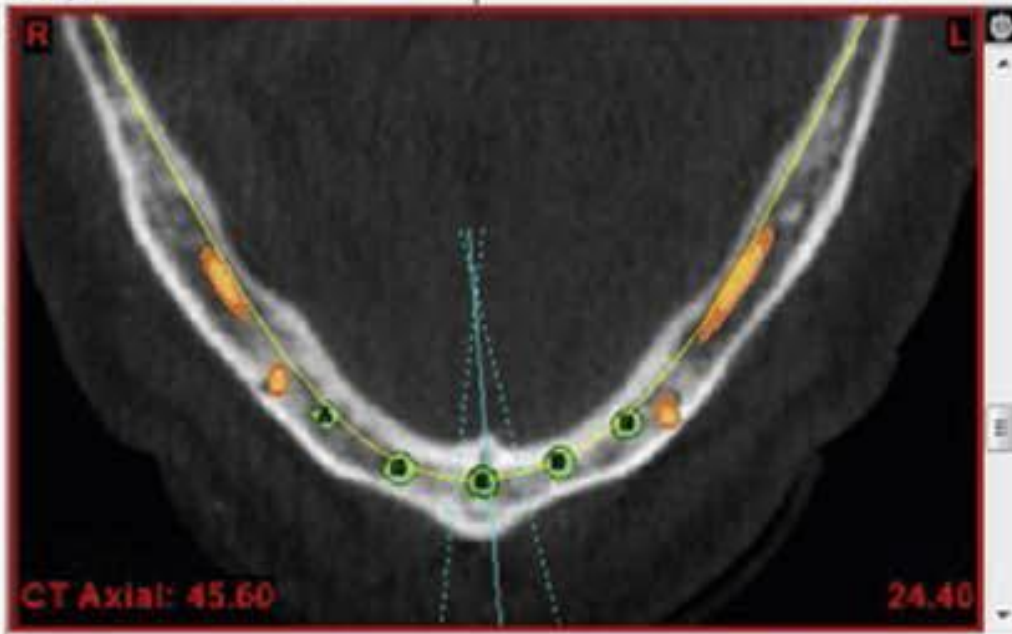
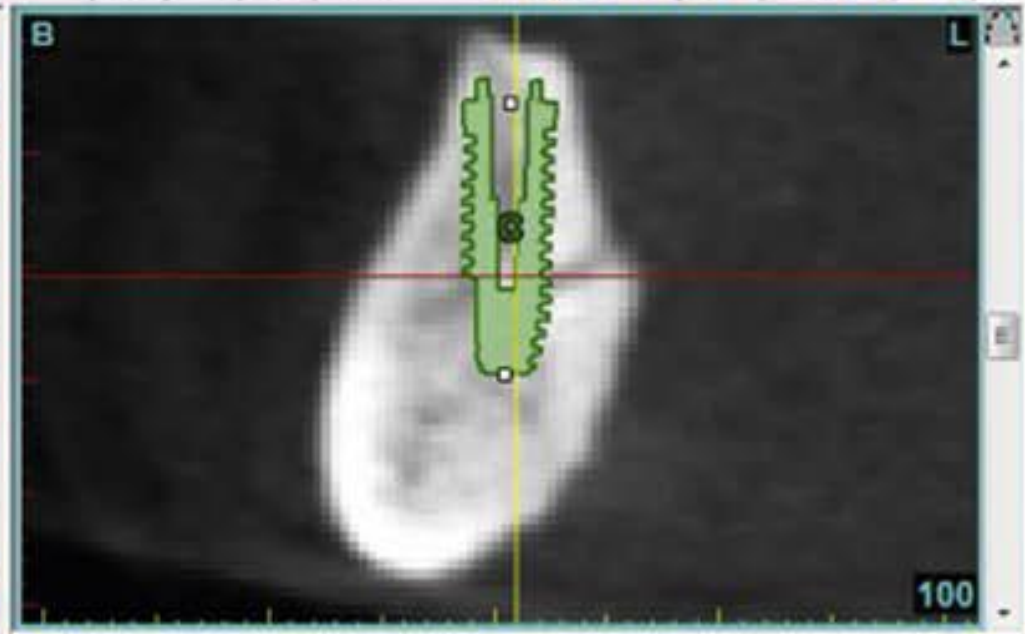
5. Order SurgiGuide

6. Communication

Tools

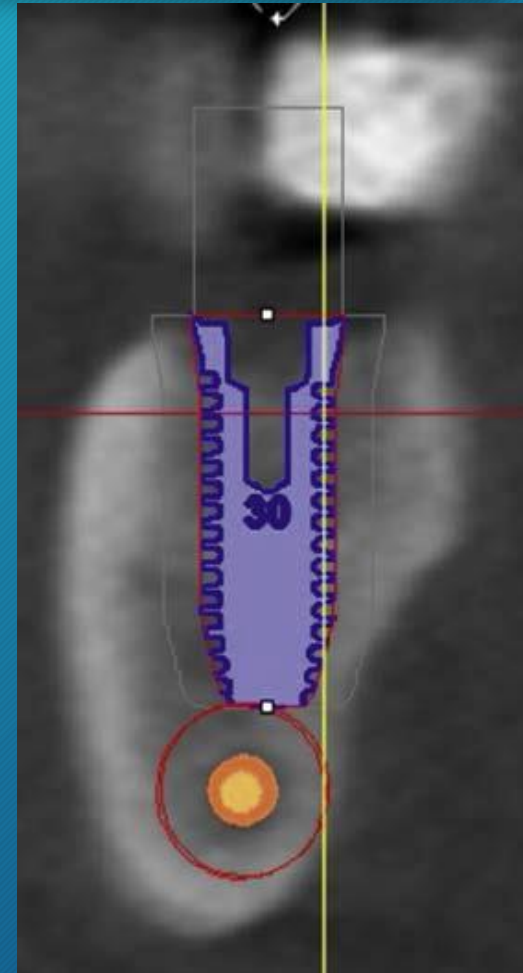
Measure

Add text annotations



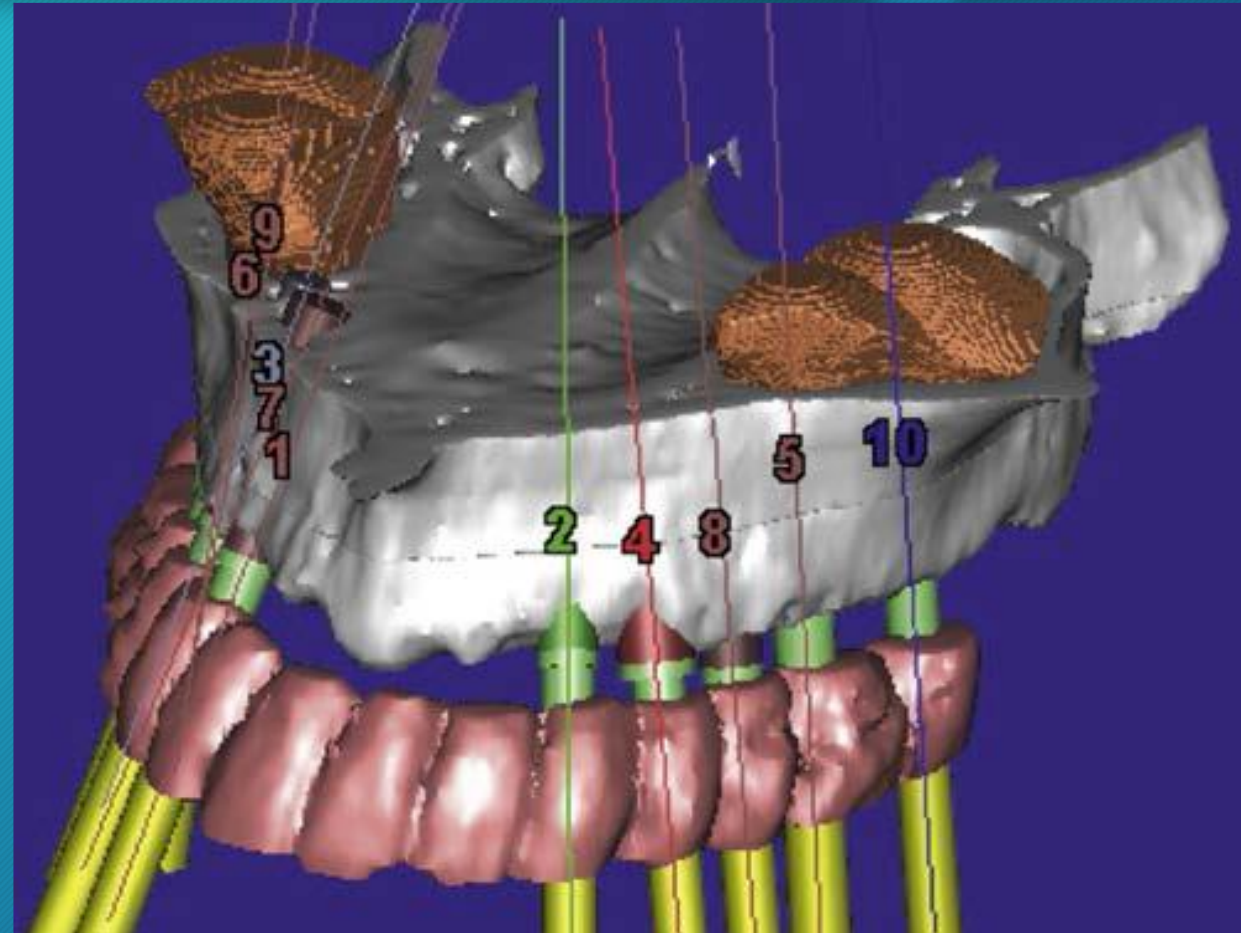
Safety Zone

Most software programs contain safety zone features that prevent implant placement too close to a vital structure (i.e., implant in approximation to the Mandibular Canal). Usually a 2-mm safety zone will be preset within the program that will prevent implant placement too close to the MC.



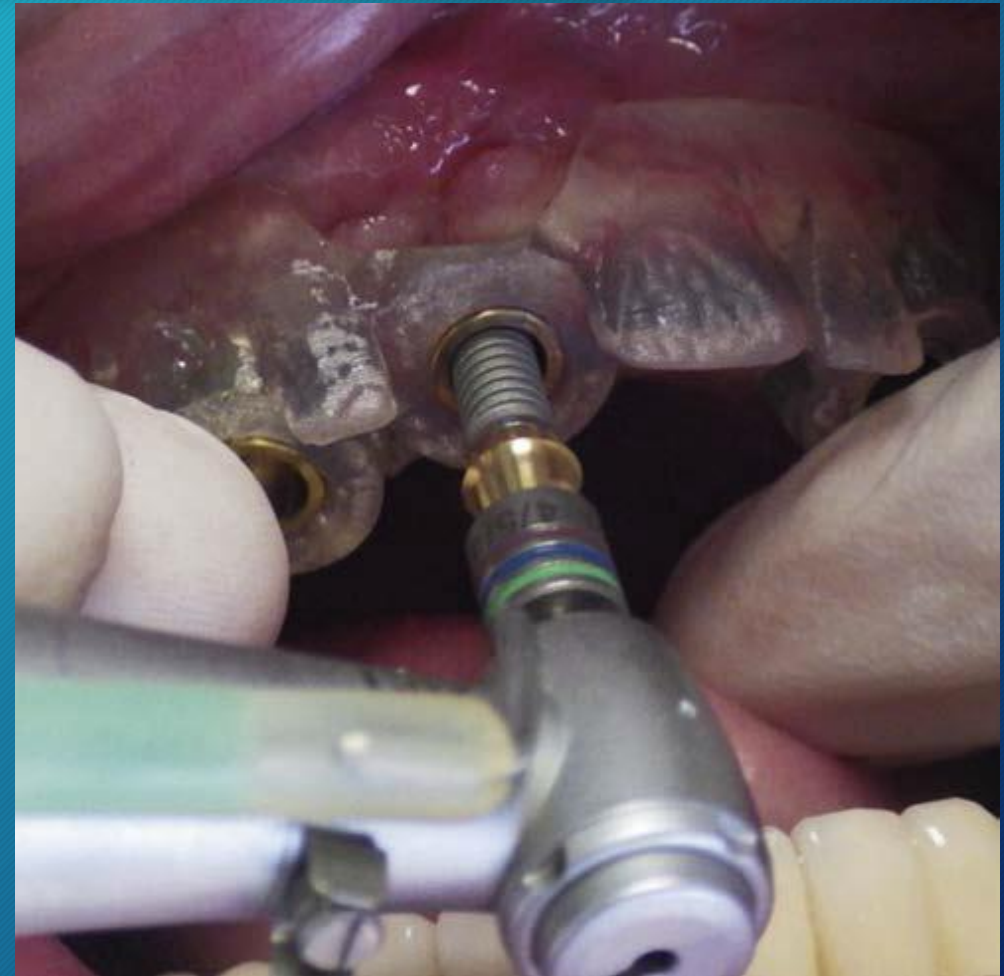Bone Graft Simulation

- When advanced cases of ridge resorption are present, bone graft in defects may need to be addressed and evaluated. Bone grafting procedures (e.g., sinus augmentation, ridge augmentation) may be simulated and completed via the interactive software programs.
- With some software programs, actual bone graft volume may be determined.



Treatment Plan to Surgical Placement

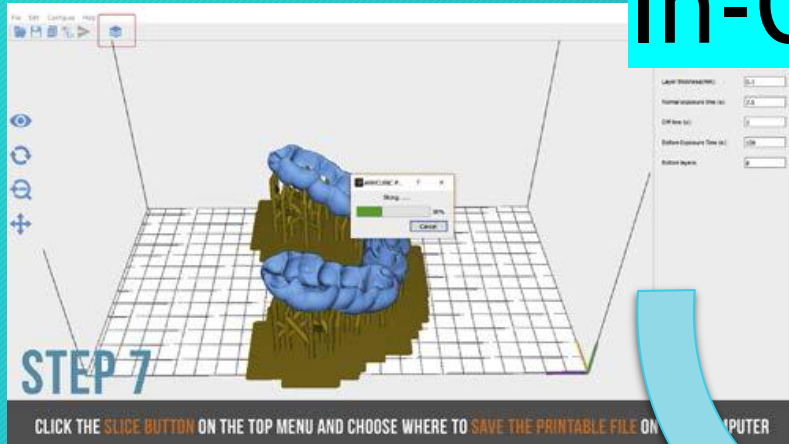
The use of surgical templates has been shown to be a reliable, accurate, precise clinical method and proven method to transfer the surgical plan to the surgical field through guided drilling templates.



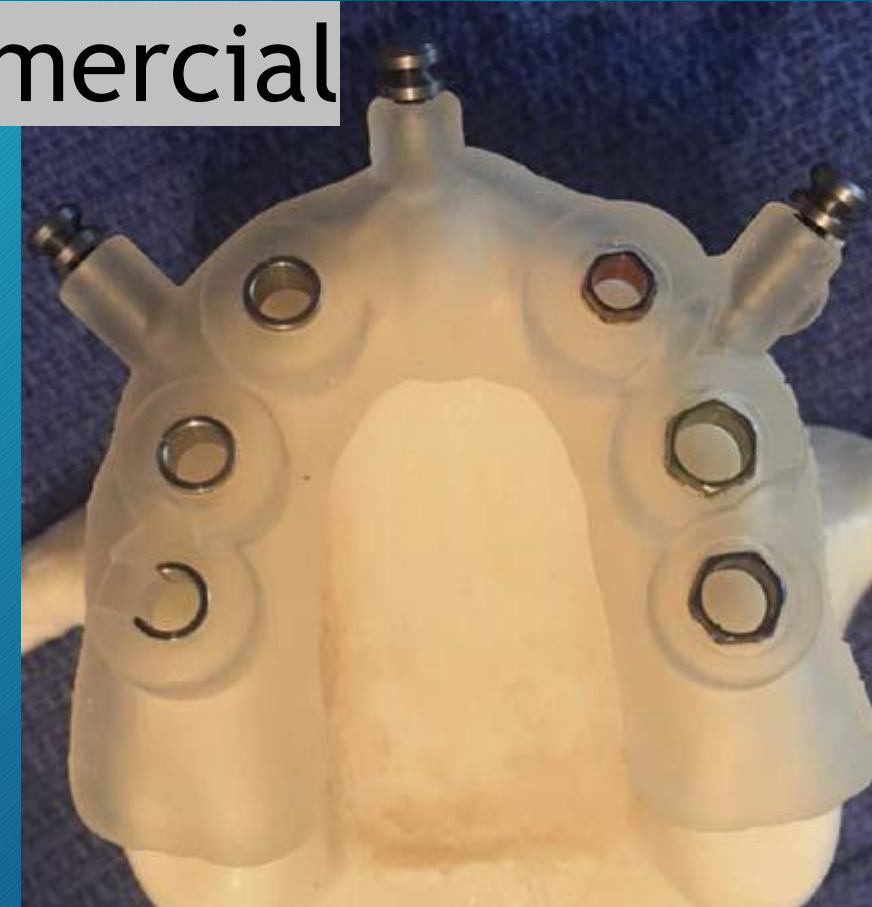

Surgical Template Fabrication

In-Office

Commercial



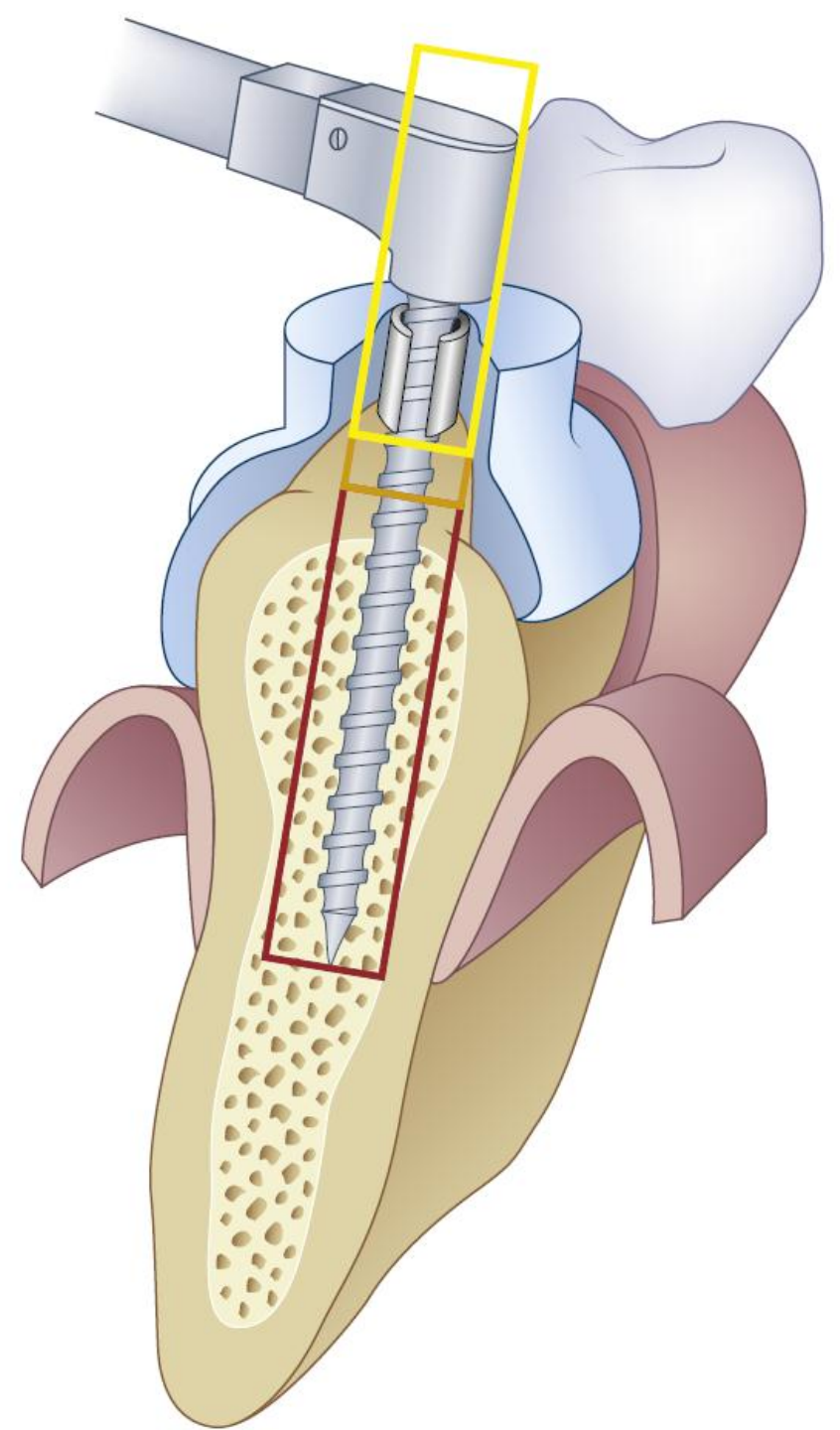
milled or 3D printed



third-party site for template fabrication

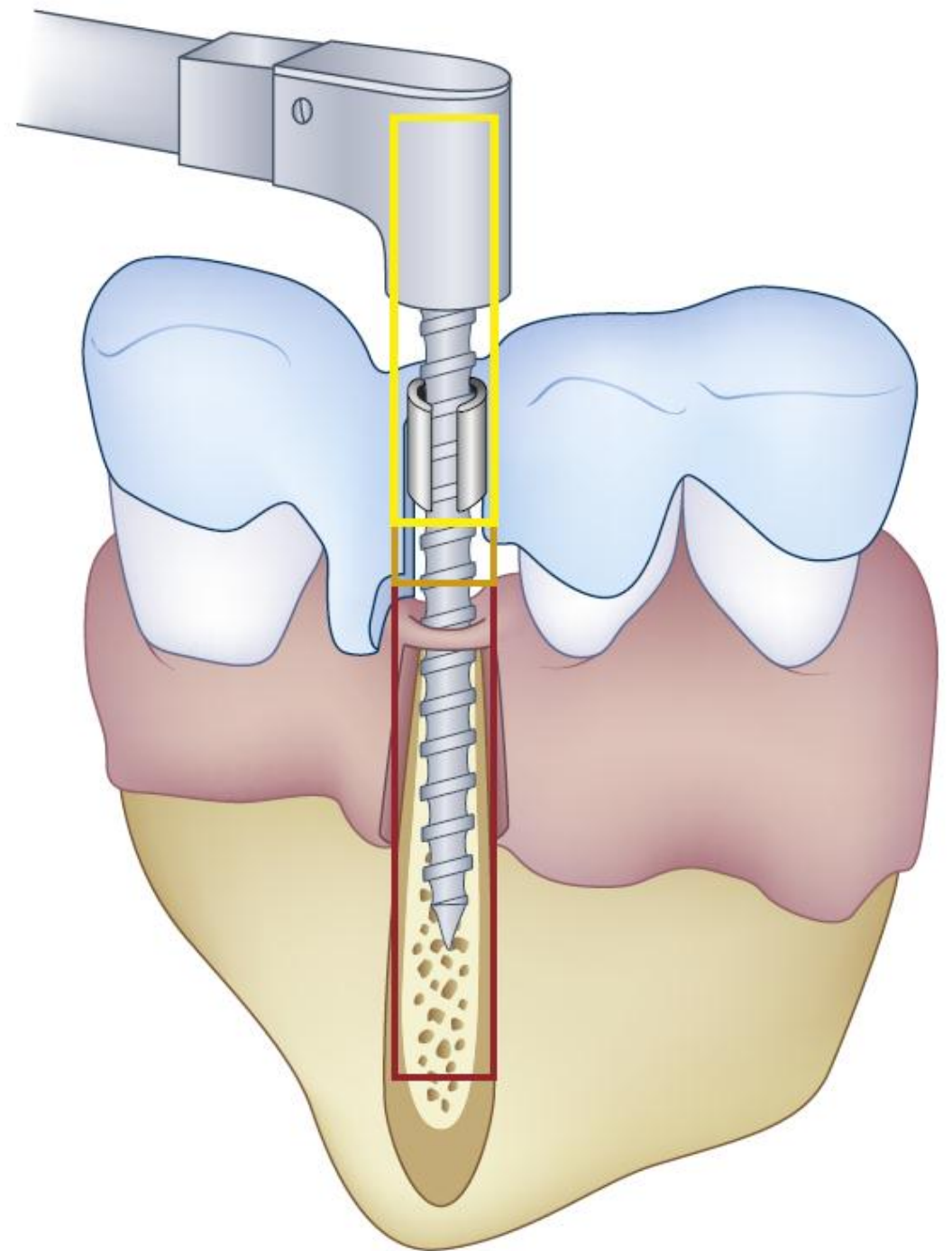
Bone-Supported Guides

- Used in partially or fully edentulous patients.
- These guides require extensive full-thickness reflection to expose the bony ridges to allow proper seating of the guide.




Tooth-Supported Guides

- Tooth-supported guides are the most accurate.
- Easiest guide to use.
- These guides are mainly used in partially edentulous patients

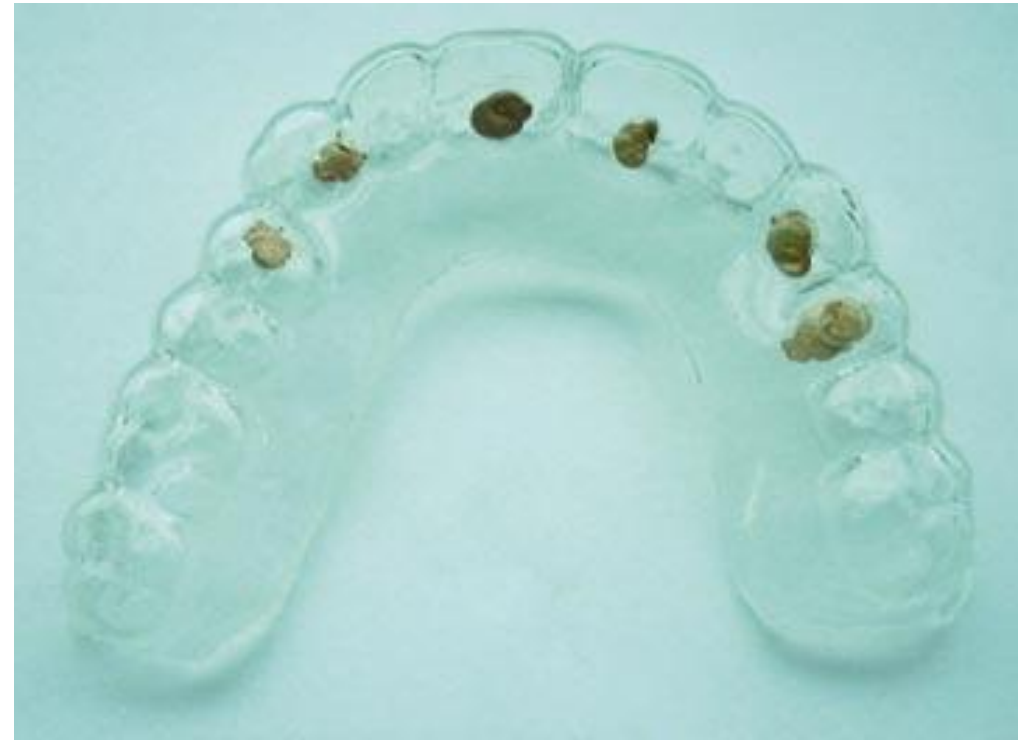
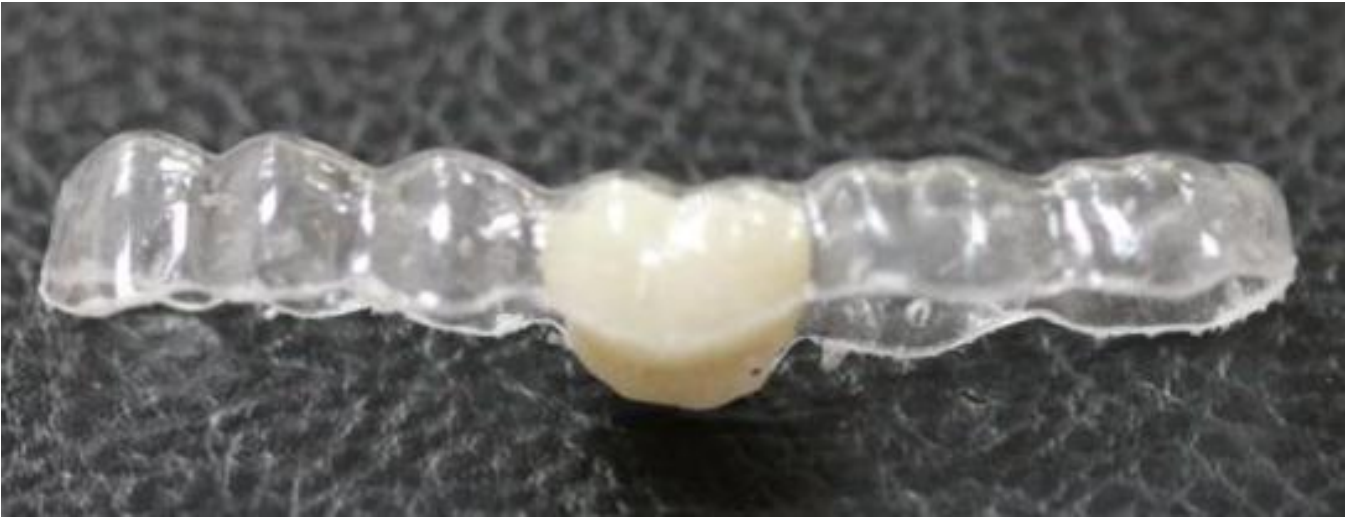
Scanning Template Fabrication

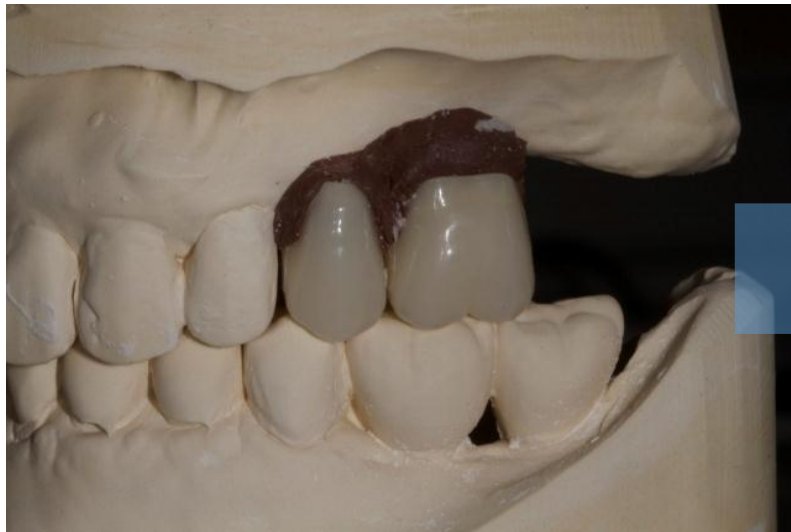Lecture 10



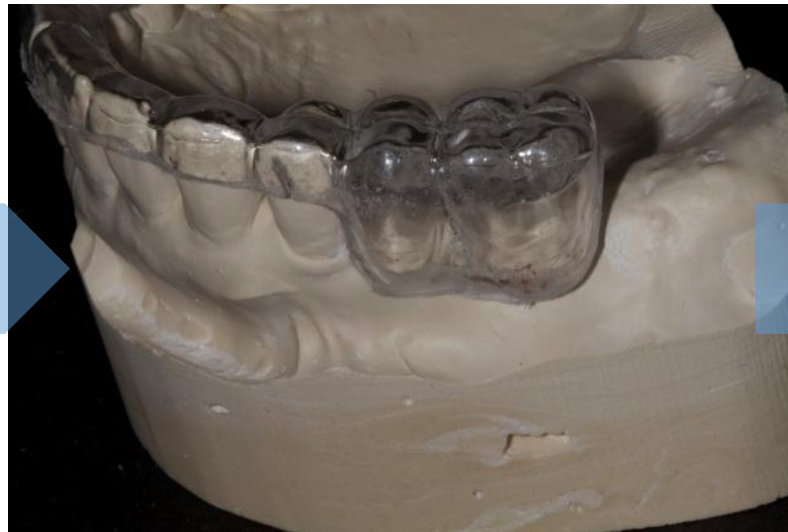- Template: A thin, transparent form duplicating the tissue surface of a dental prosthesis and used as a guide for surgically shaping the alveolar process; a guide used to assist in proper surgical placement and angulation of dental implants.



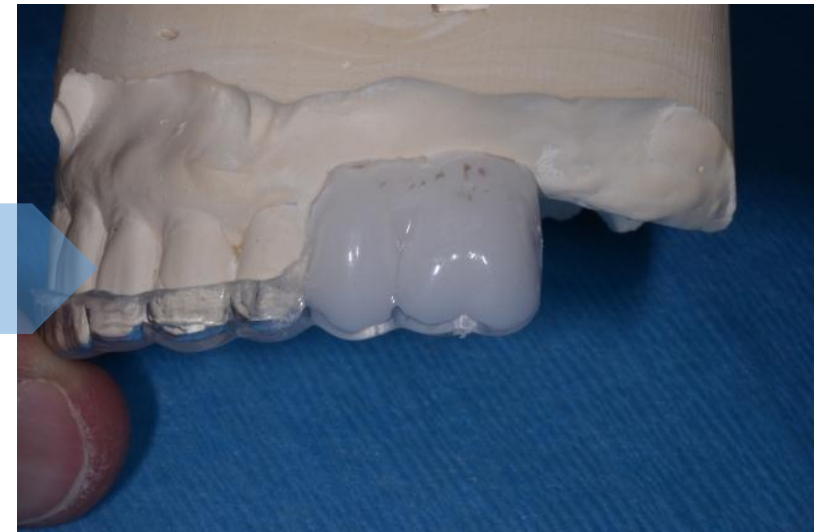- A radiopaque template describes a prosthesis that is fabricated to wear during the CBCT survey that relates the ideal prosthesis position in reference to the bone. Radiopaque templates are usually fabricated through the process of diagnostic tooth positioning via diagnostic waxing, denture teeth arrangement, or duplication of the existing prosthesis.



Waxing + denture teeth arrangement

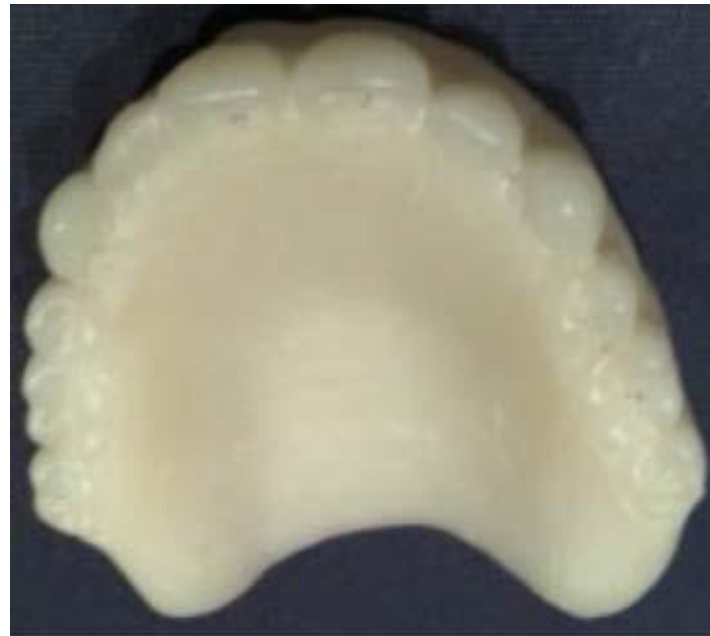

Duplication



Radiopaque Material

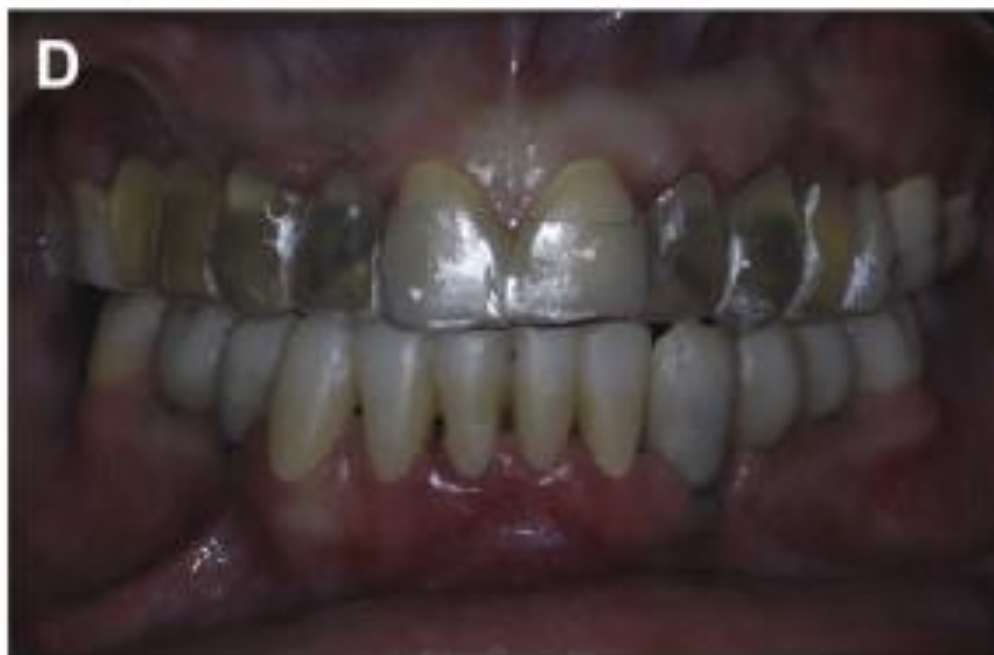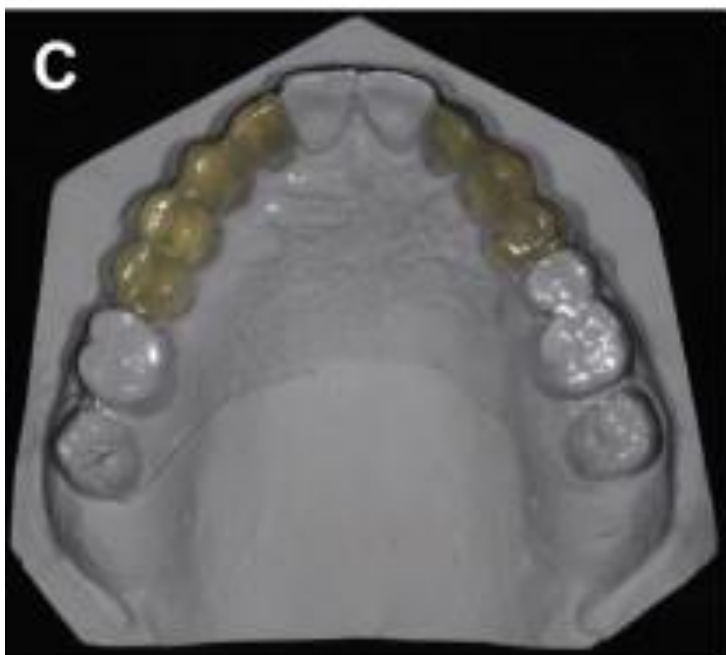
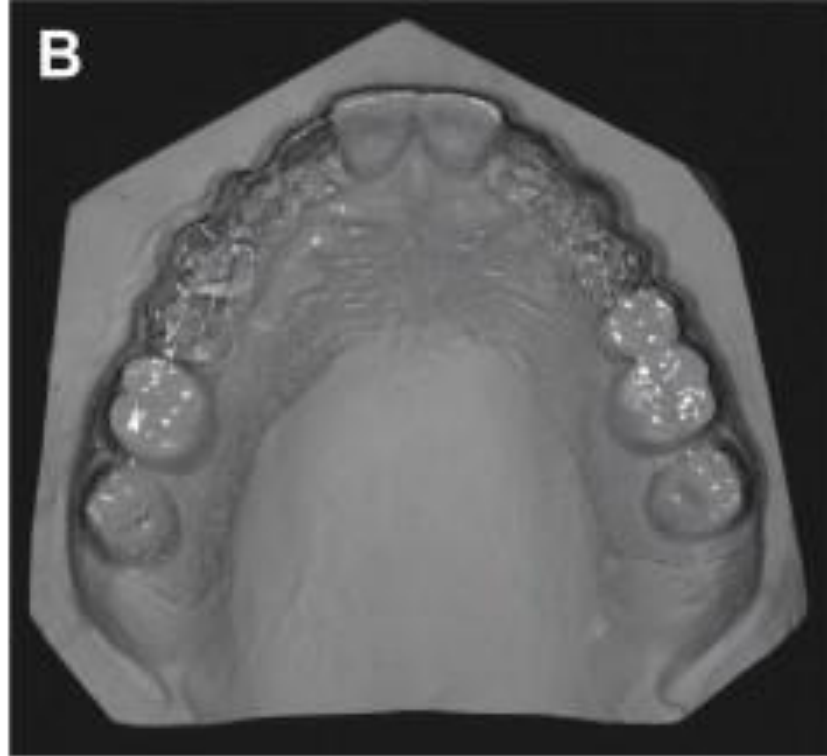
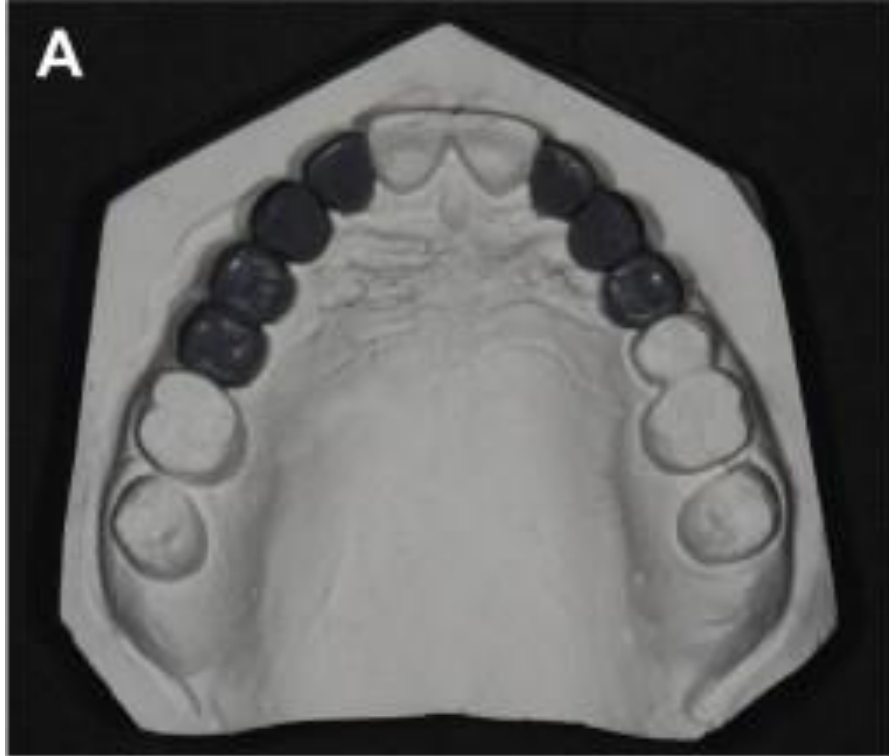
- A radiopaque material must be used to correlate tooth position and tissue in relation to available bone and vital structures.
- Many different materials have been described in the literature and may be used in the fabrication of a radiopaque template.
- The most common material used today in implant dentistry is barium sulfate (BaSO_4)



Barium sulfate complete denture (i.e., scanning appliance), which is worn by patient for the CBCT scan.

Laboratory Protocol for Partially Edentulous Radiopaque Template

1. Complete a diagnostic wax-up of the edentulous area, including the full contour of the teeth to be replaced, along with proper occlusion.
2. Duplicate the diagnostic wax-up using irreversible hydrocolloid and pour the impression in dental stone. Trim the duplicate cast.
3. Use clear thermoforming material (~0.060 inch, 5 x 5 inches) to fabricate a vacuum-formed clear template of the trimmed duplicate cast.
4. Trim the template to include a minimum of half coverage of the adjacent teeth and full coverage of the edentulous areas.
5. Block out the undercuts on the adjacent teeth to the edentulous area with wax or block-out compound. Lubricate the adjacent tooth areas as well as the edentulous space.
6. Pour a mixture of barium sulfate in the edentulous areas of the template. Remove template from cast, and trim and polish as needed.



Laboratory Steps for Radiopaque (Full Edentulism) Denture Template

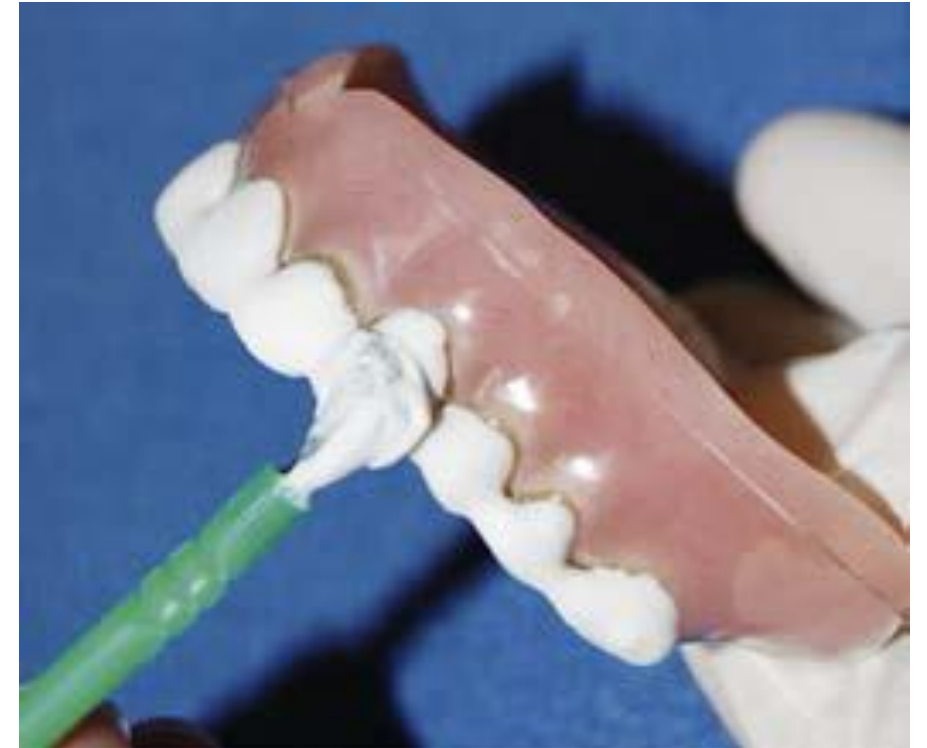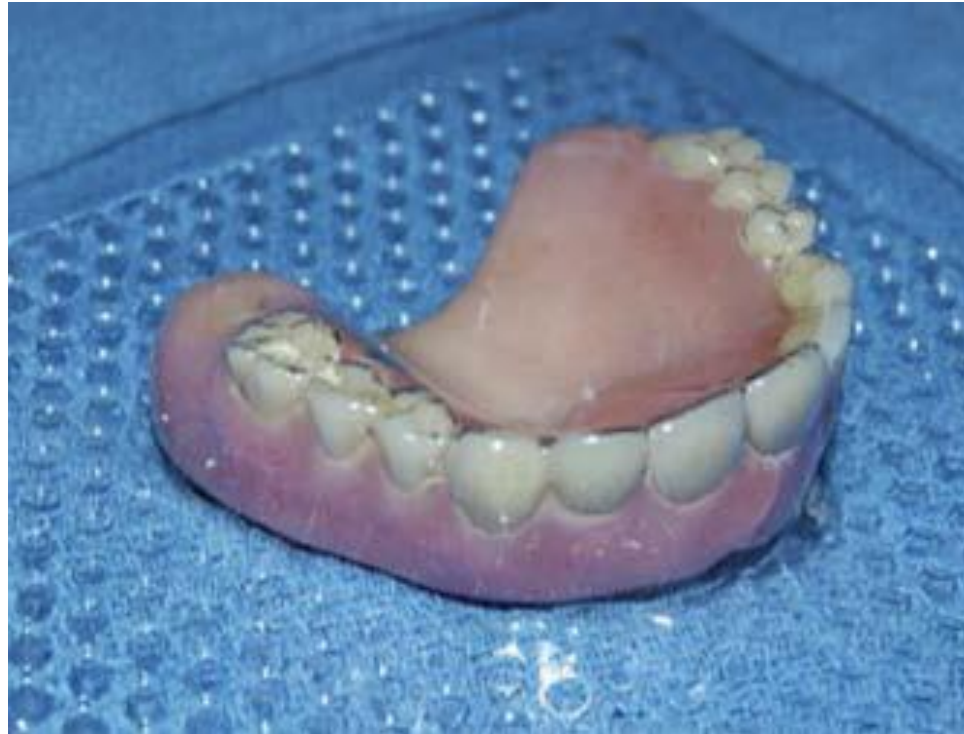Option 1: Laboratory-Fabricated Template

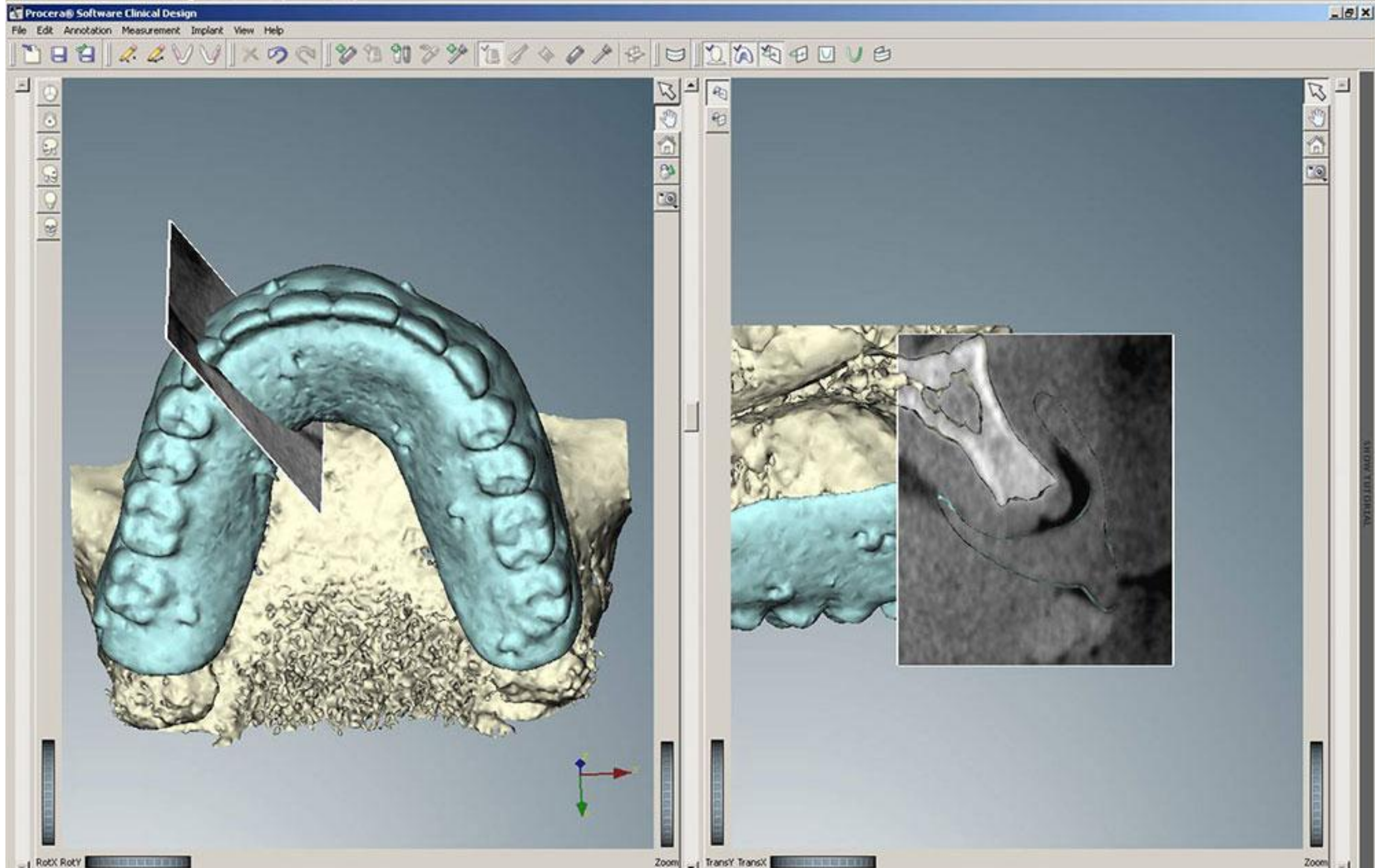
1. With the use of a denture duplicator flask mix and fill half of the flask with alginate.
2. Place the denture (teeth first) into alginate with the teeth perpendicular to the bottom of the flask.
3. After alginate is set, trim excess that covers the denture flange.
4. Lubricate the alginate and exposed denture with separating material.
5. Fill the other half of the flask, along with the ridge part of the denture, with alginate.
6. Close the flask, ensuring complete closure. After the alginate is set, open and remove the denture.
7. Pour acrylic clear acrylic resin (Clear Surgical Template) or radiopaque acrylic resin (Radiopaque Template) into the incisal and occlusal surfaces, ensuring no bubbles. Pour the remainder of the mixture into the palate or vestibule area.

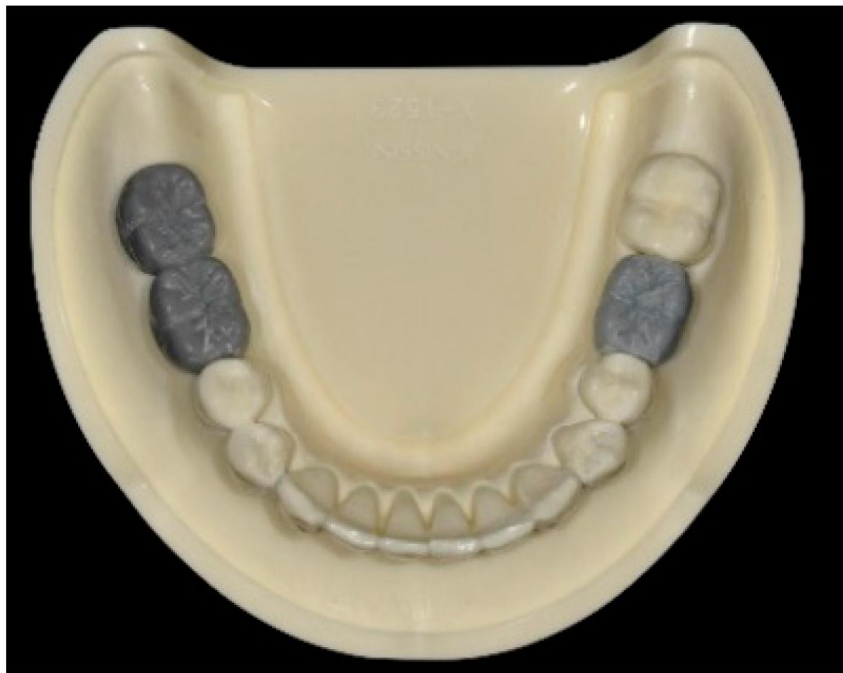8. Cure for a minimum of 20 minutes on the laboratory bench or in a pressure pot at 30 psi.
9. Trim excess and polish.

Option 2: Laboratory-Fabricated Template

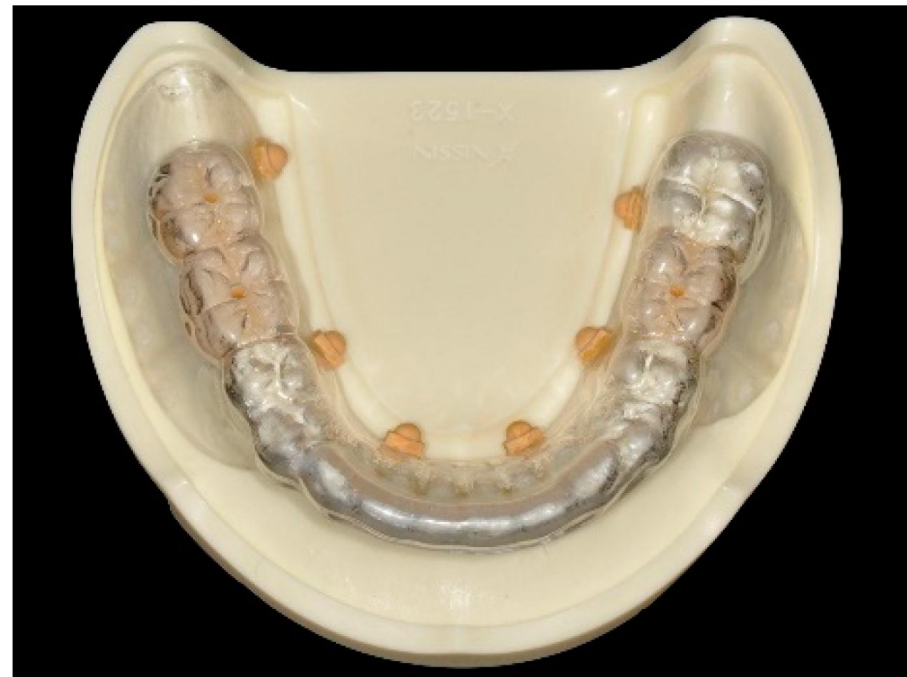1. With the patient's existing complete denture, fabricate a vacuum-formed clear template with clear thermoforming material (~0.060 inch, 5 x 5 inches).
2. Using barium sulfate monomer and polymer, paint the facial and lingual surfaces of the template. Allow it to dry.
3. Administer the cone beam computed tomography scan with the radiopaque template.
4. After scan is completed,



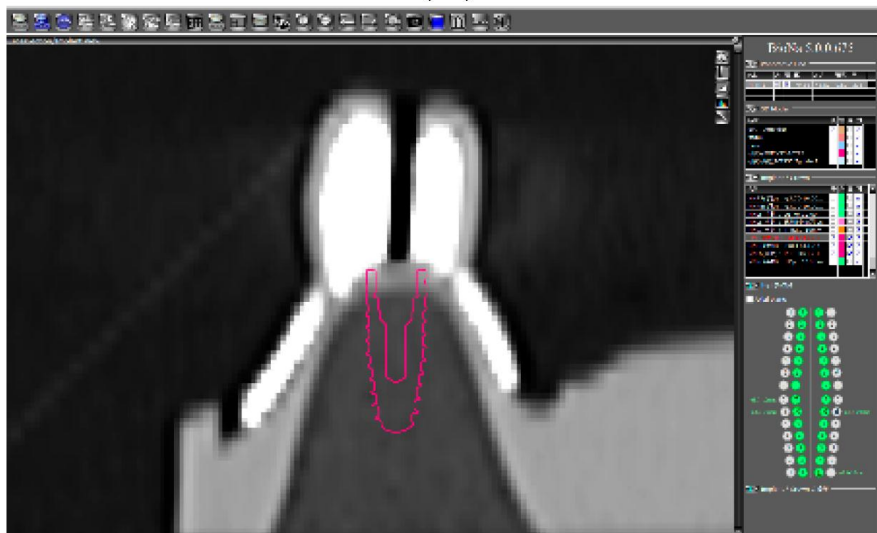




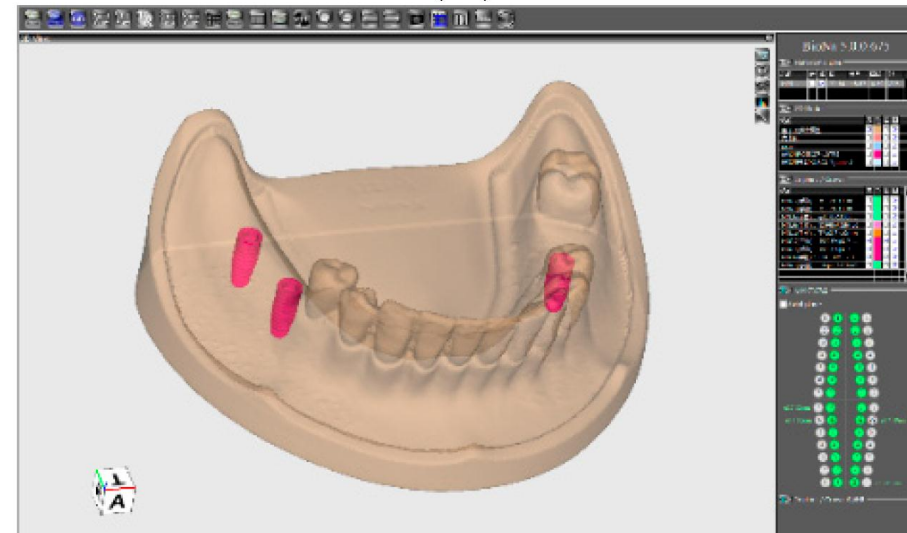
(a)



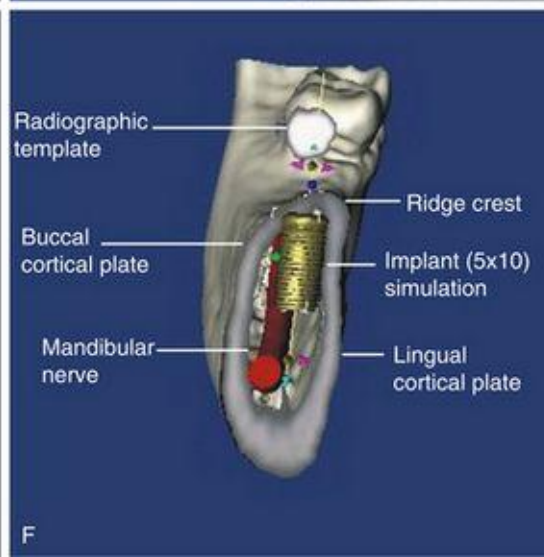
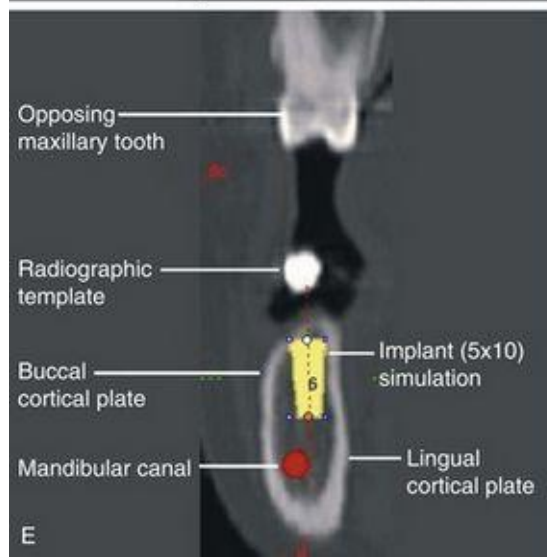
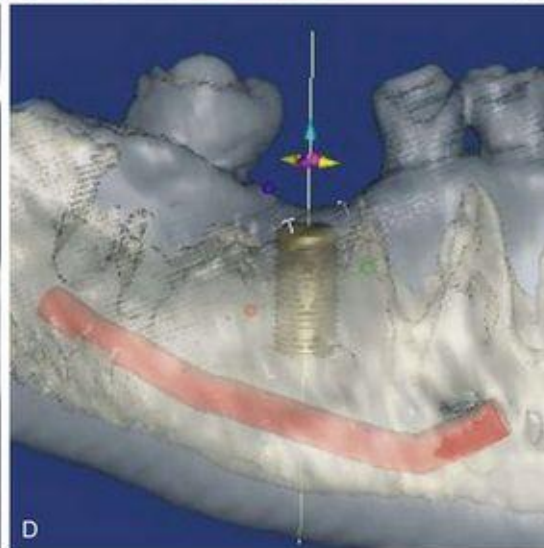
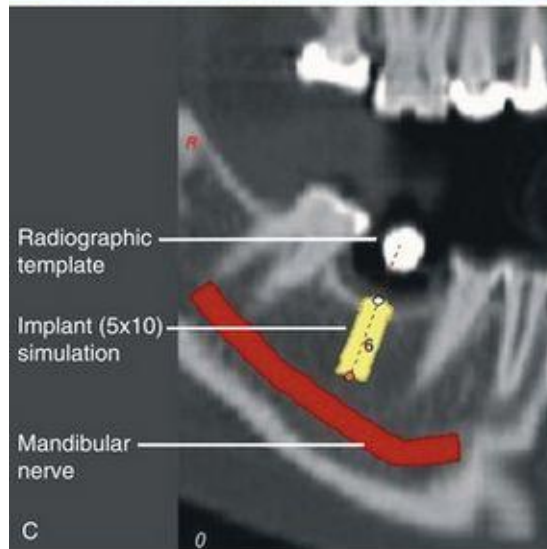
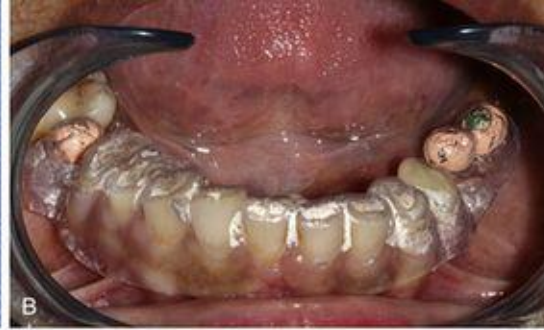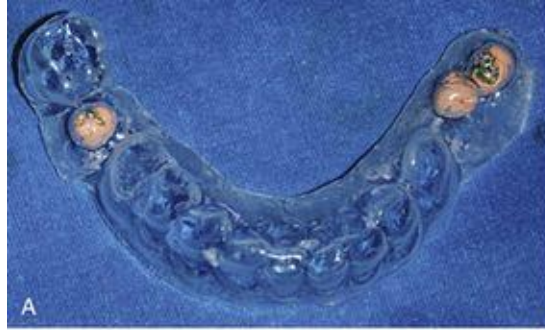(b)

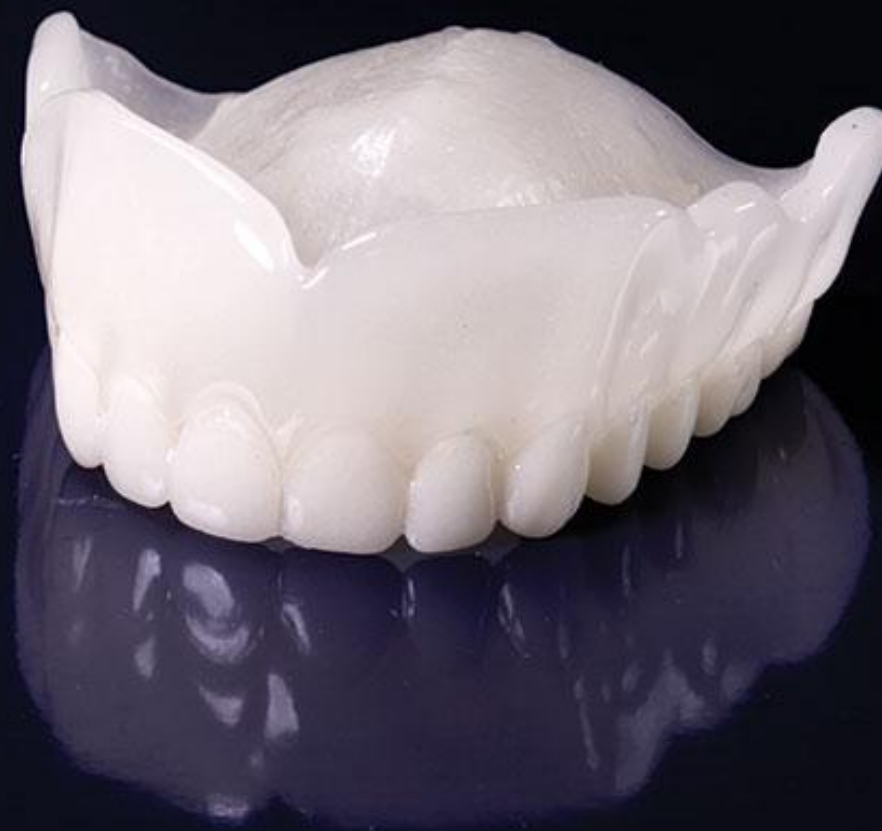
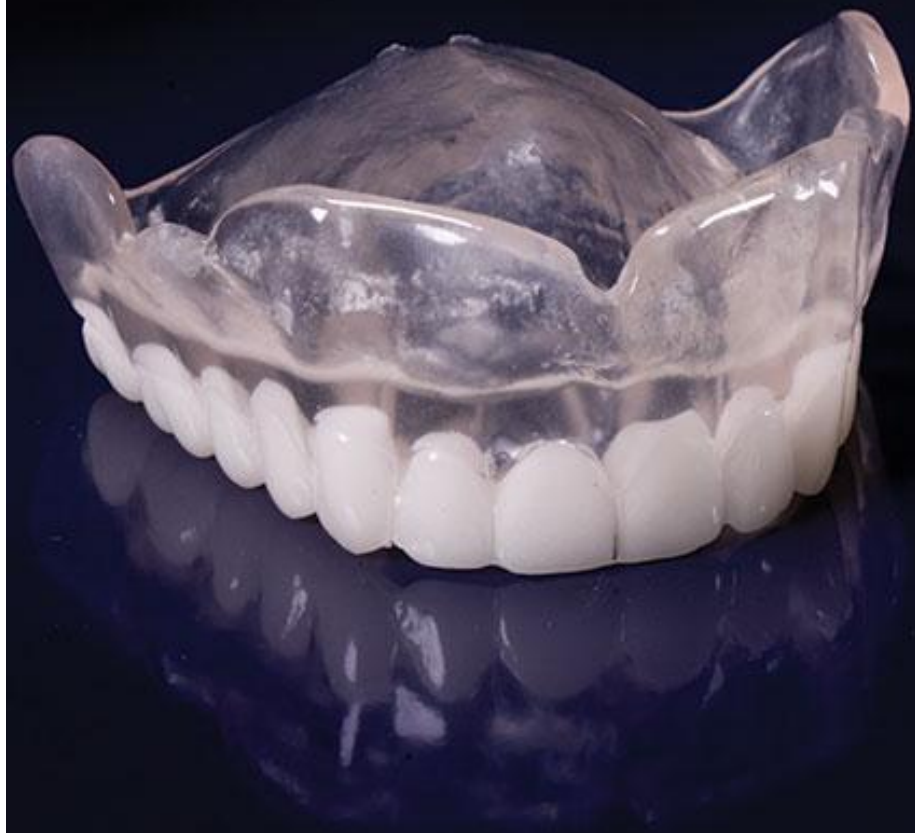
(c)



(d)





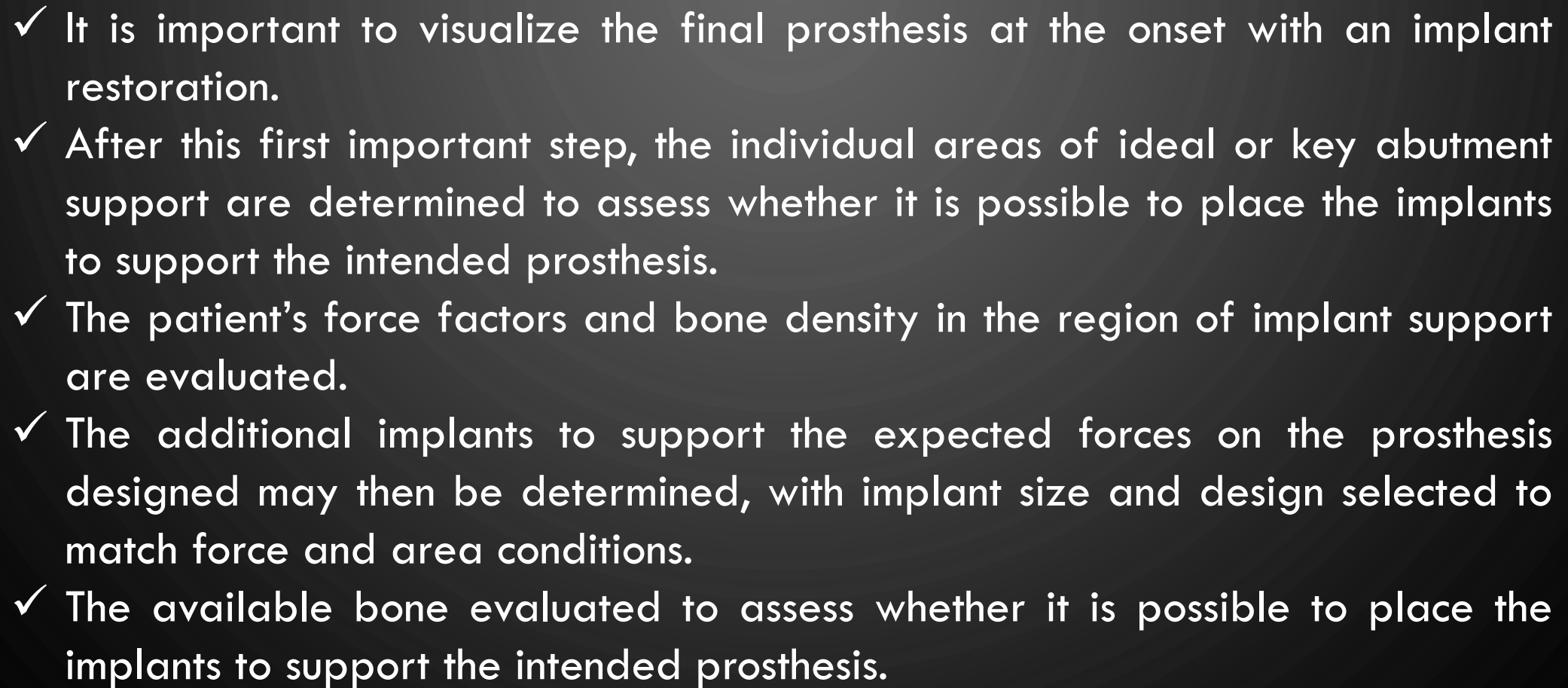
The background is a dark gray gradient. It features several realistic water droplets of various sizes, some with highlights and shadows, scattered across the frame. Faint, concentric circles are visible in the background, creating a ripple effect.

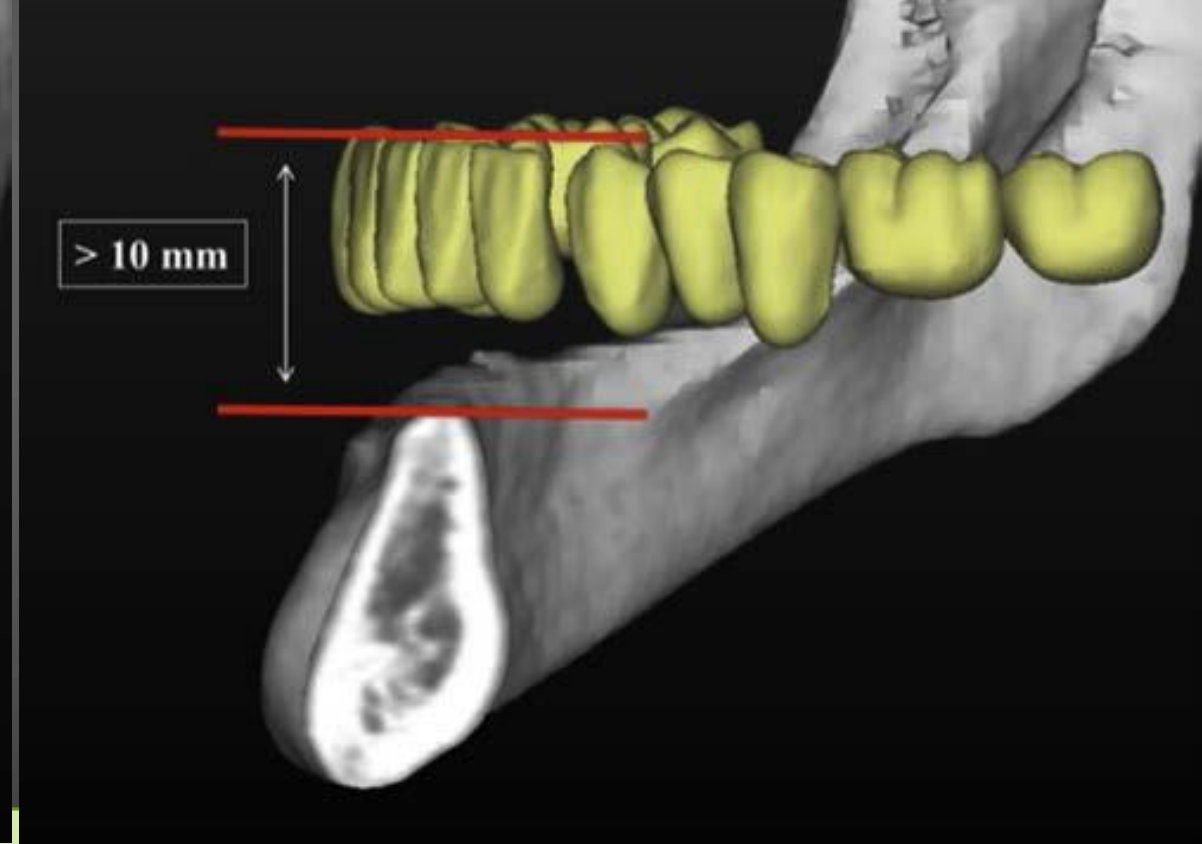
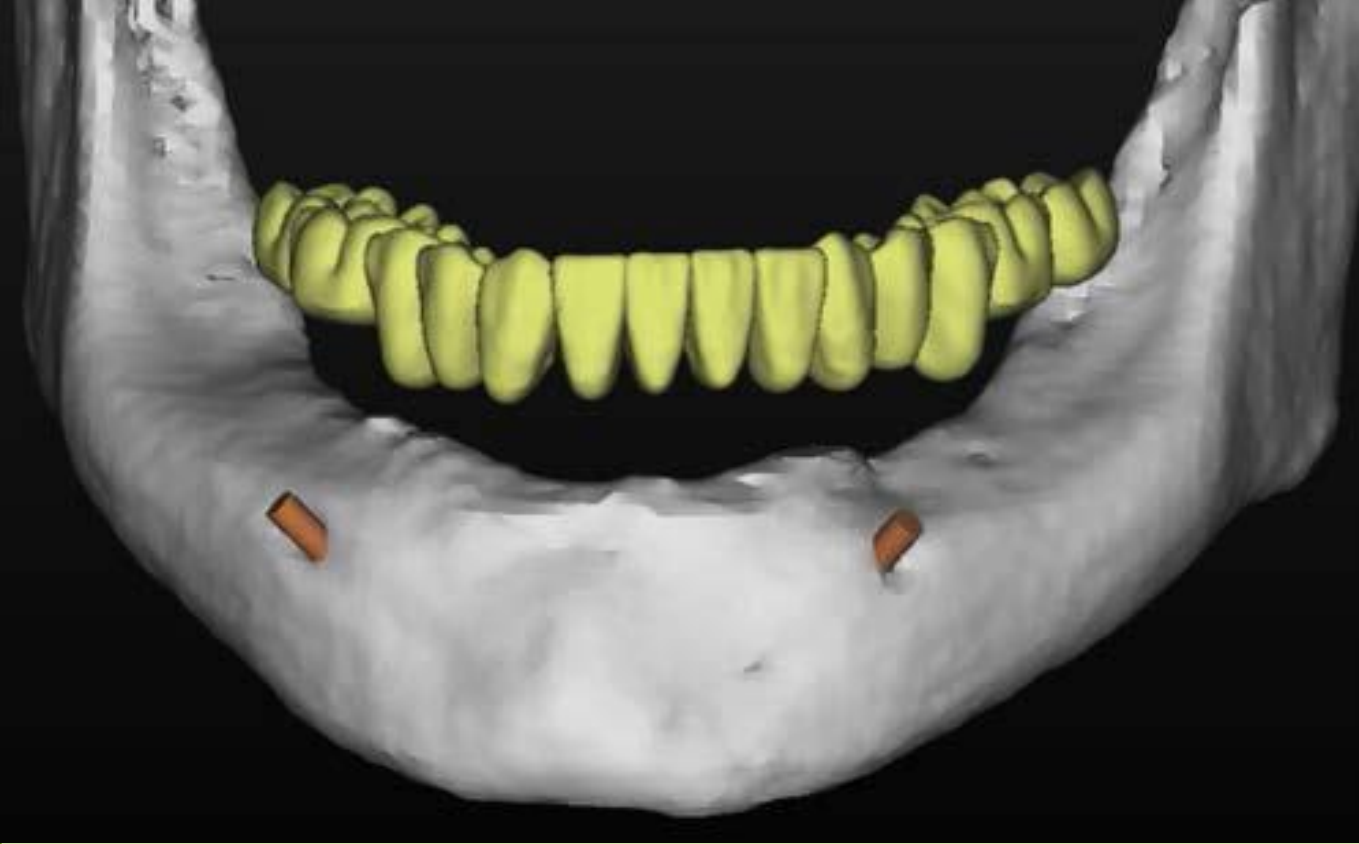
PROSTHETIC OPTIONS IN IMPLANT DENTISTRY

LECTURE 11

COMPLETELY EDENTULOUS PROSTHESIS DESIGN

- IN GENERAL A PATIENT WITH EXISTING TEETH THAT ARE TO BE EXTRACTED ARE MORE LIKELY TO HAVE INTEREST IN A FIXED-IMPLANT PROSTHESIS.
- HOWEVER, A PATIENT WITH A REMOVABLE PROSTHESIS (RPS) IS MOST COMMONLY INTERESTED IN AN OVERDENTURE PROSTHESIS.

- 
- ✓ It is important to visualize the final prosthesis at the onset with an implant restoration.
 - ✓ After this first important step, the individual areas of ideal or key abutment support are determined to assess whether it is possible to place the implants to support the intended prosthesis.
 - ✓ The patient's force factors and bone density in the region of implant support are evaluated.
 - ✓ The additional implants to support the expected forces on the prosthesis designed may then be determined, with implant size and design selected to match force and area conditions.
 - ✓ The available bone evaluated to assess whether it is possible to place the implants to support the intended prosthesis.



3D CBCT image of an edentulous arch depicting the discrepancy between the bone level and prosthesis. In this situation, the prosthesis will most likely be a FP-3. Interocclusal space is measured from the incisal edge to the alveolar crest. An FP-3 prosthesis requires a minimum of 10 mm for a monolithic zirconia, ~12 mm for a porcelain fused to metal prosthesis, and >15 mm for a hybrid prosthesis.

PARTIALLY EDENTULOUS PROSTHESIS DESIGN

- A COMMON OPTION IN TRADITIONAL PROSTHODONTICS FOR PARTIAL EDENTULISM IS TO PROVIDE A FIXED PARTIAL DENTURE WHENEVER APPLICABLE.
- THE FEWER NATURAL TEETH MISSING, THE BETTER THE INDICATION FOR A FIXED PARTIAL DENTURE.
- IDEALLY THE FIXED PARTIAL DENTURE IS COMPLETELY IMPLANT SUPPORTED RATHER THAN JOINING IMPLANTS TO TEETH.

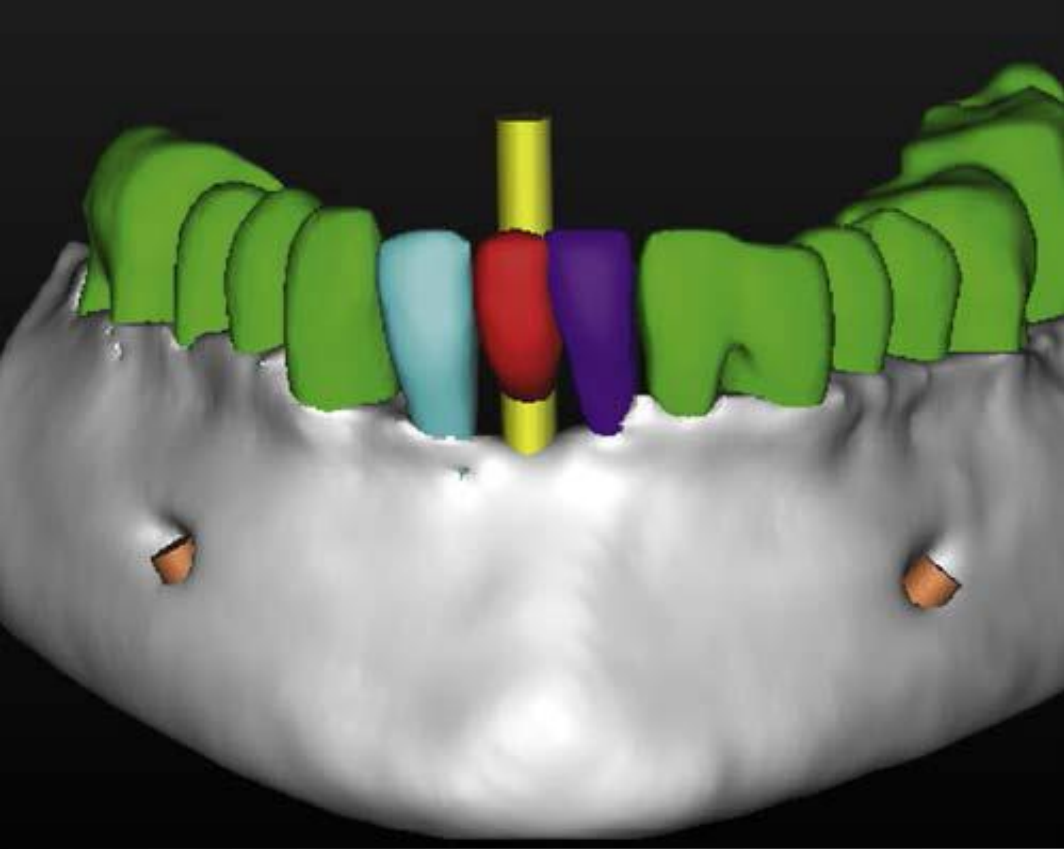
The added implants in the edentulous site result in:

Fewer pontics

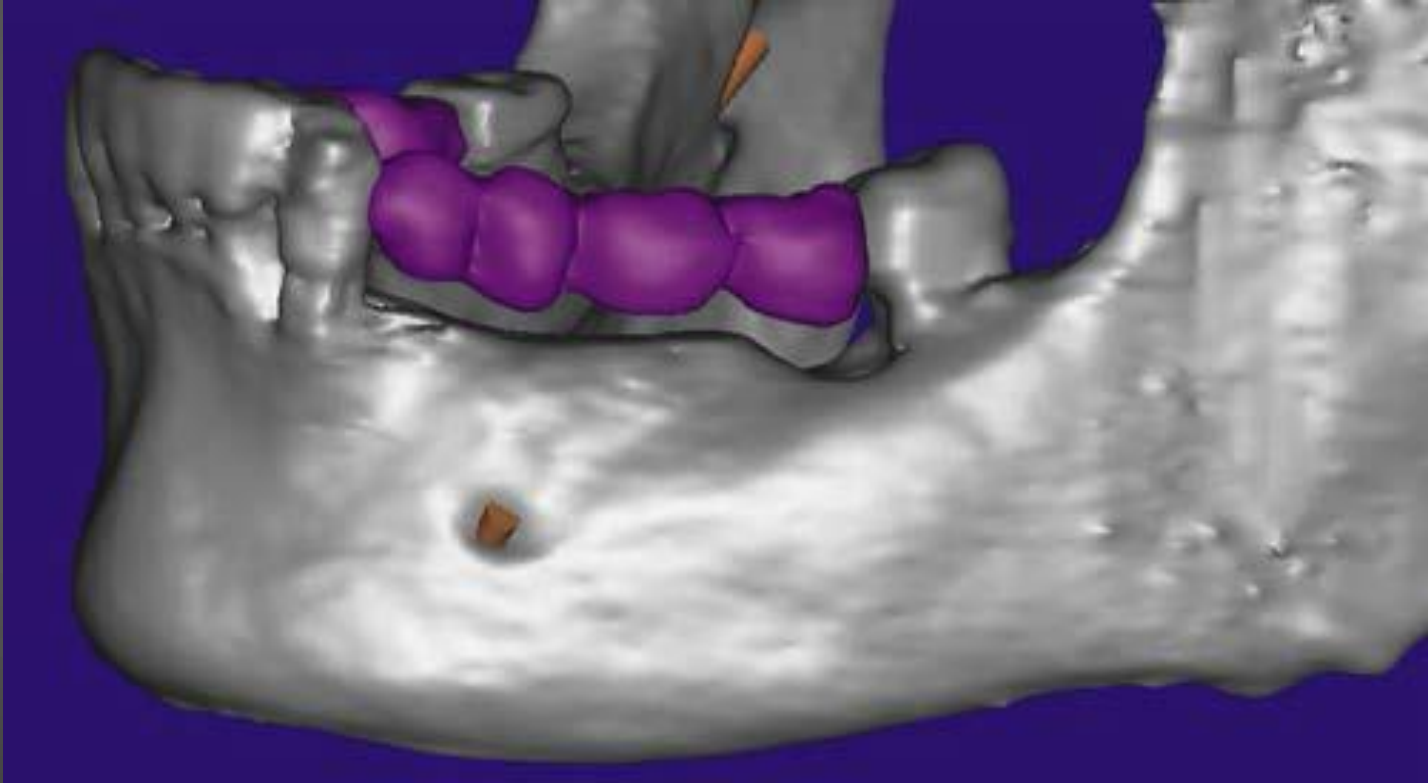
More retentive units in the restoration

Less stress to the supporting bone

complications are minimized and implant and prosthesis longevity are increased



The position of the implant to the adjacent teeth can easily be determined along with the crown height space. The final prosthesis will most likely be a FP-2.



CBCT image showing the osseous contour in relation to the clinical crown of the prosthesis. Note the vertical defect on the second molar which will most likely change the prosthesis type



LECTURE 12

Ideal Implant Positioning

Ideal Positioning for Screw and Cement-Retained Prosthesis

The following are recommendations for ideal implant positioning (implant body long axis) for screw and cement-retained prostheses.

Anterior

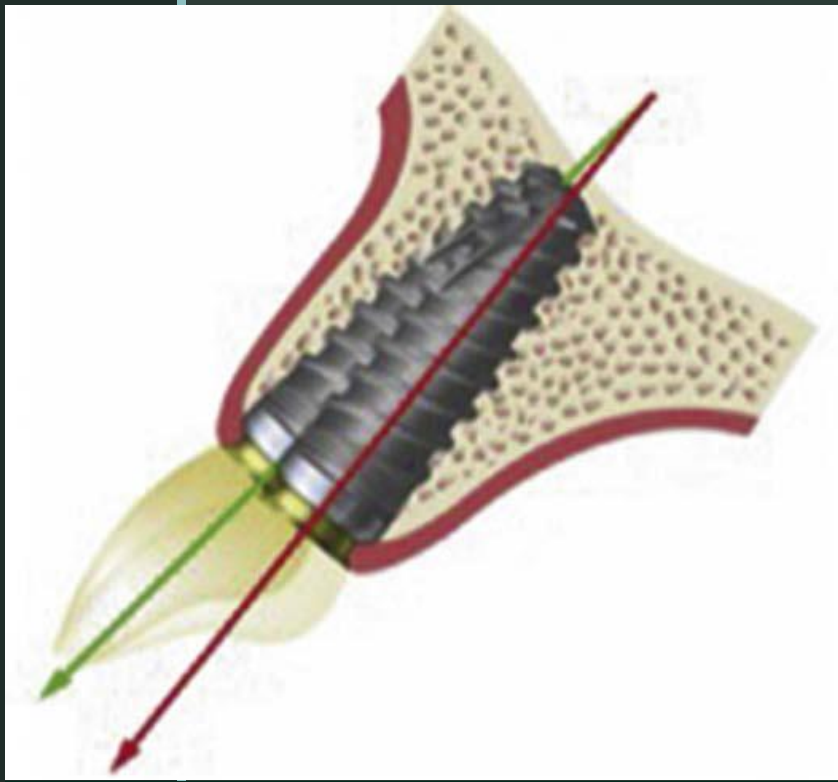
Cement retained: slightly lingual to incisal edge

Screw retained: cingulum area

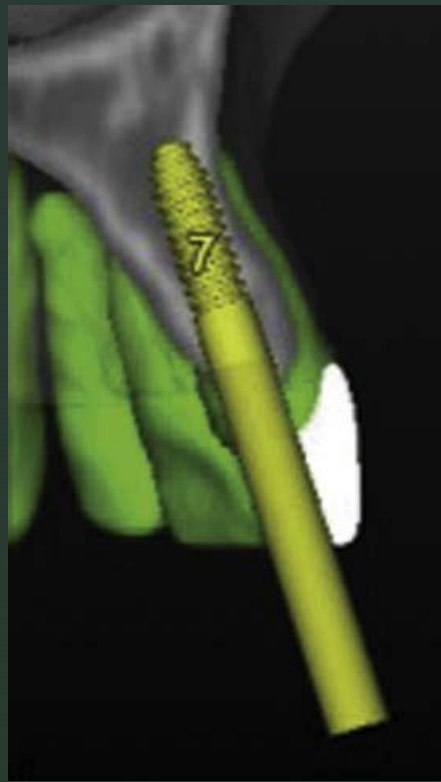
Posterior

Cement retained: central fossa

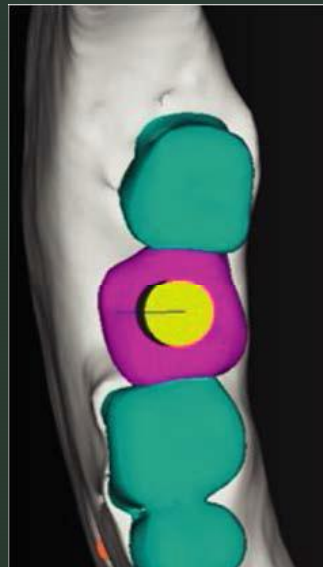Screw retained: central fossa



Cement-Retained - slightly lingual to incisor edge (green arrow) and Screw-retained - cingulum area (red arrow)



CBCT cross section depicting ideal placement for cement-retained prosthesis



posterior screw and cement retained.

➤ The Edentulous Maxilla

The long-term prognosis for implants in the maxilla has been shown to be less predictable in comparison with the mandible **Because of** :

- 1) **The resorption pattern** of the maxilla (horizontal bone loss twice as much as vertical resorption soon after extraction).
- 2) **Anatomic structures** such as the nasal cavity and the maxillary sinus.
- 3) **High prevalence of reduced quantity and quality of bone.**
- 4) **Increased esthetic demand.**

Fixed Maxillary Treatment Plans

Old articles indicated that full maxillary fixed implant–supported prostheses are fabricated on an average of **six standard-diameter** implants with **posterior molar cantilevers**. More **recently**, numerous articles have shown the success of a fixed prosthesis *on four implants*.

Core principles of treatment planning an edentulous maxillary arch for a fixed prosthesis

1. The number of implants is related to the dental arch form.
2. The arch form is dictated by the final dentition or prosthesis, not the edentulous ridge arch form.
3. Key implant positions exist: anterior, canine, premolar, and molar.
4. An RP-4 (totally implant supported removable prosthesis) prosthesis is treatment planned the same as a fixed prosthesis.

Arch form determination

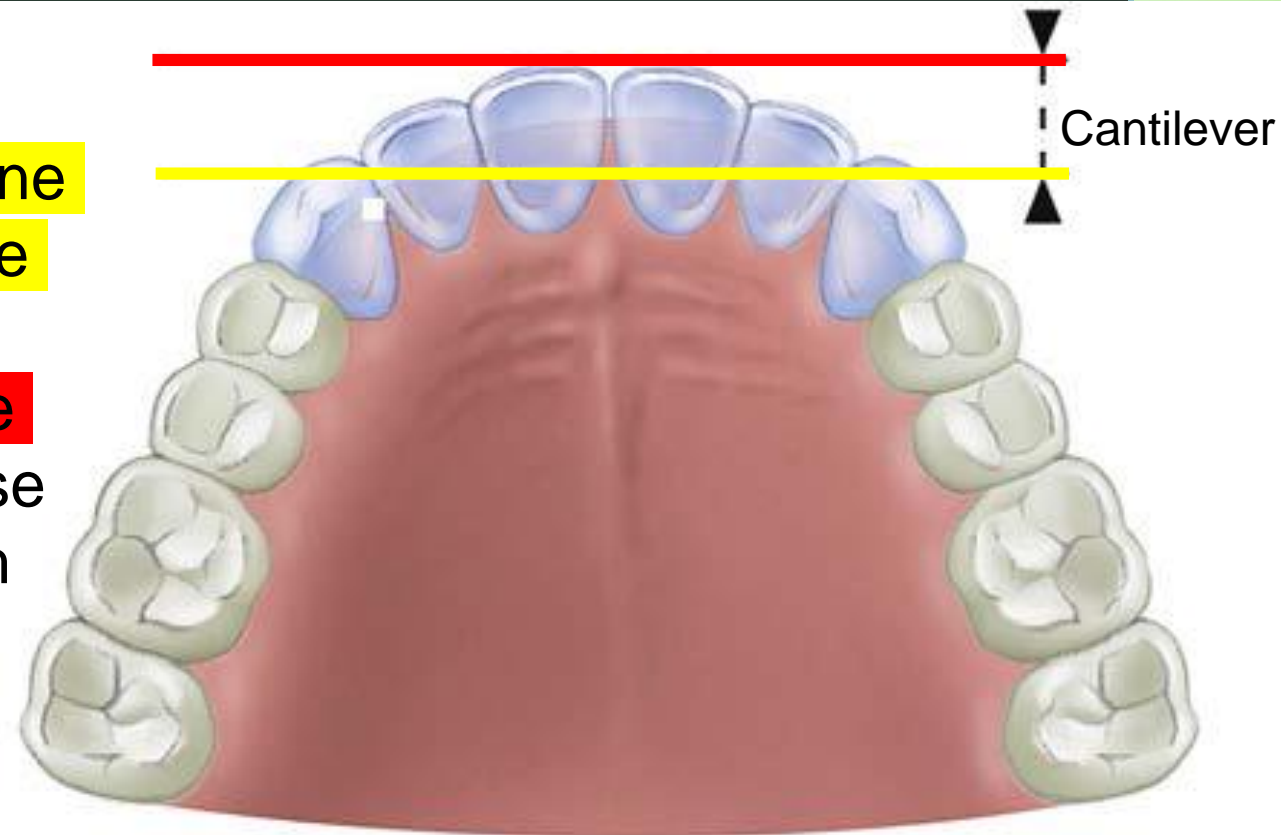
Three common dental arch forms for the maxilla exist:

Square, **Ovoid**, and **Tapering**.

The dental arch form of the patient is determined by the final teeth position in the premaxilla and not the arch shape of the residual ridge.

Dental Arch Form Determination:

Two horizontal lines are drawn. The first line bisects the incisal papilla and connects the tips of the canines. The second line is parallel and along the facial position of the central incisor. The distance between these lines determines whether the dentate arch form is square, ovoid, or tapering.




Treatment Plan for Edentulous Premaxilla


Arch Form	Anterior Cantilever (mm)	Number of Anterior Implants	Implant Position
Square	< 8	2	Canines
Ovoid	8–12	3	Two canines and one incisor
Tapering ing	>12	4	Two canines and two incisors



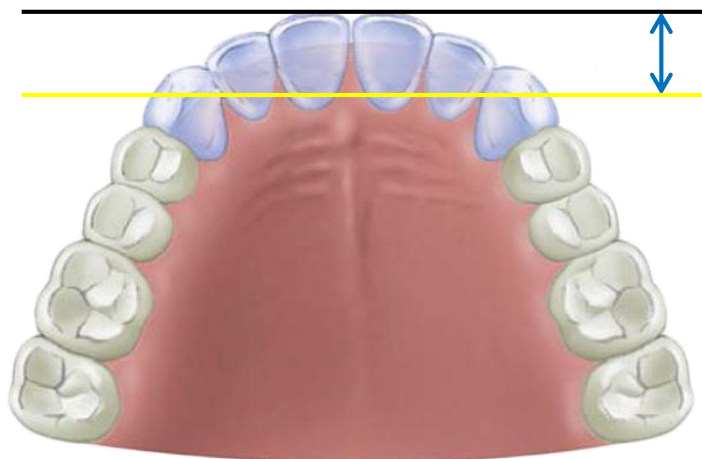
Cantilever < 8



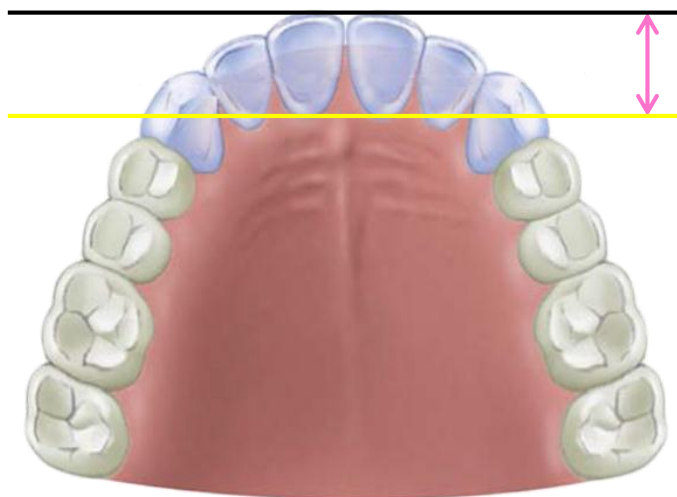
Cantilever 8 - 12



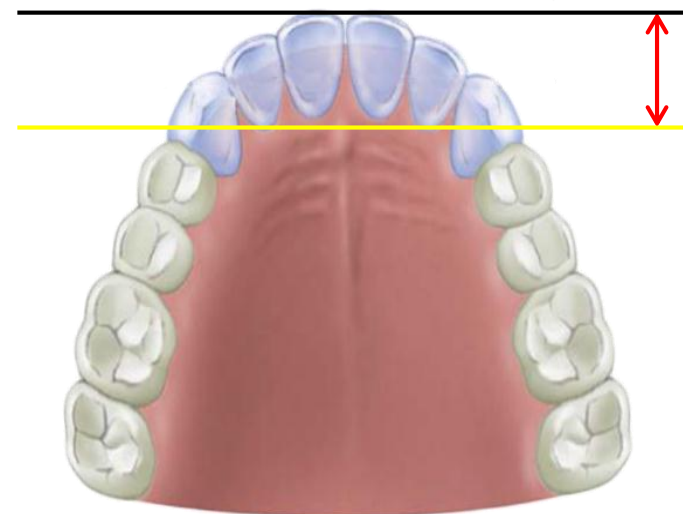
Cantilever > 12



Square



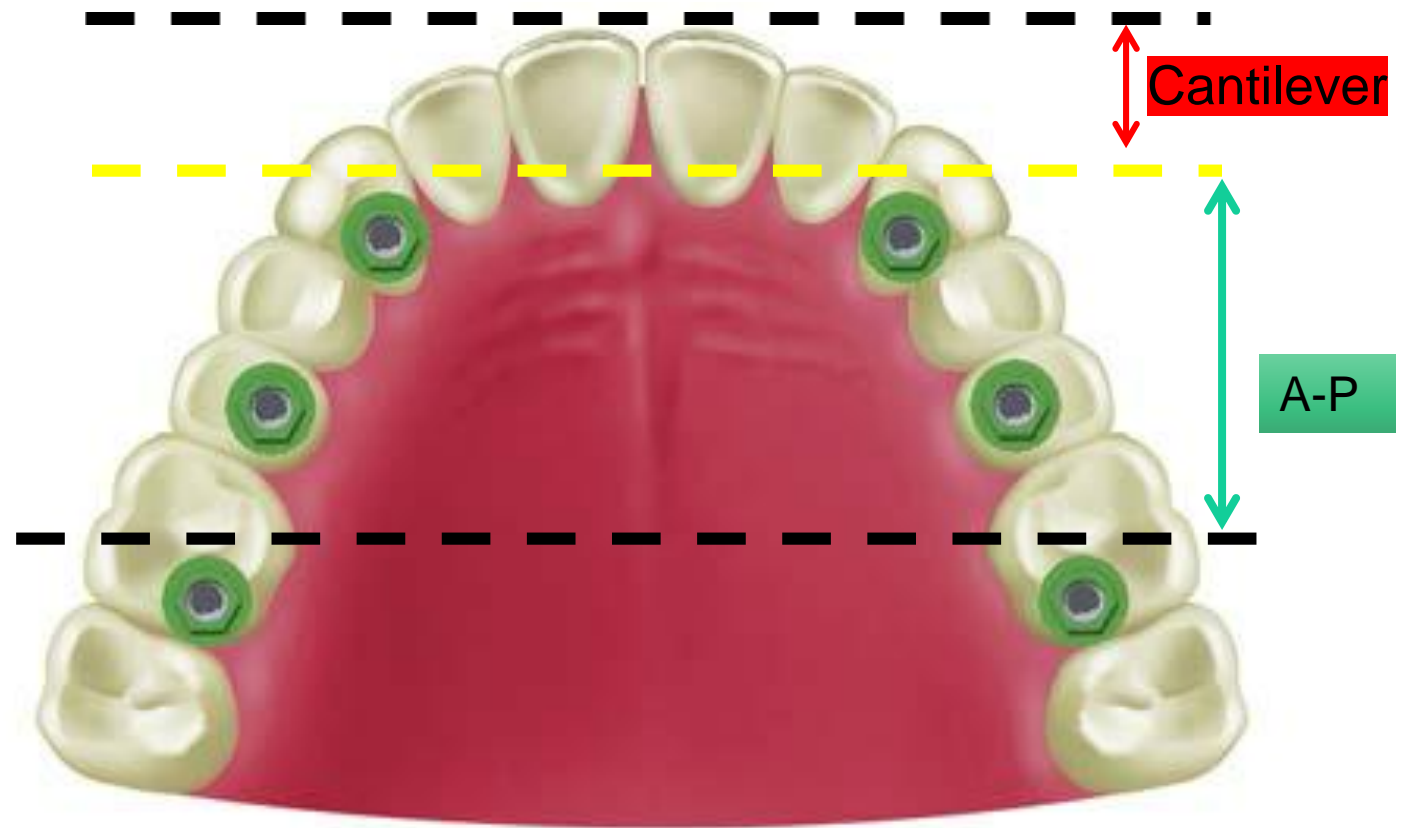
Ovoid



Tapering

Maxillary Fixed Prosthesis Treatment Option 1:

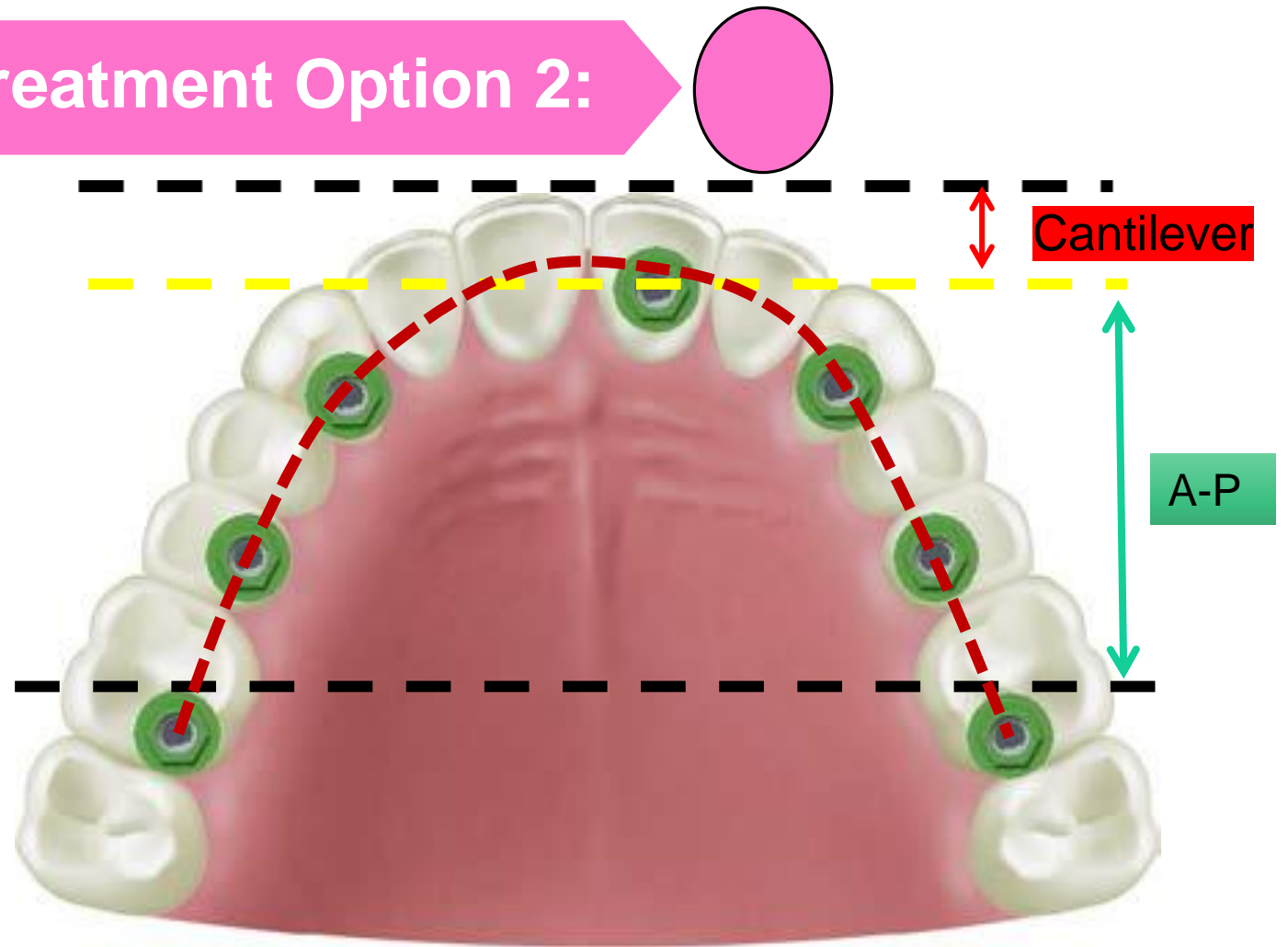
In a dental square arch form, lateral and central incisors are minimally cantilevered facially from the canine position resulting in a lesser requirement of an implant in the central or lateral position. As a result, implants in the canine position to replace the six anterior teeth may suffice when the force factors are low and if they are splinted to additional posterior implants



Fixed Treatment Plan 1: When force factors are low, a square dentate arch form may use six implants for a fixed or RP-4 (totally implant supported removable prosthesis) prosthesis. A-P, Anteroposterior distance.


Maxillary Fixed Prosthesis Treatment Option 2:

If the final teeth position is an ovoid arch form, at least three implants should be inserted into the premaxilla: one in each canine and preferably one in a central incisor position, bilateral second premolar sites, and the bilateral distal half of the maxillary first molar sites. The *seven implants should be splinted* together to function as an arch.



Fixed Treatment Plan 2: In an ovoid dentate arch form, three implants should be planned in the premaxilla: one in each canine position and one additional implant. In addition, at least four posterior implants should be splinted to form an arch.

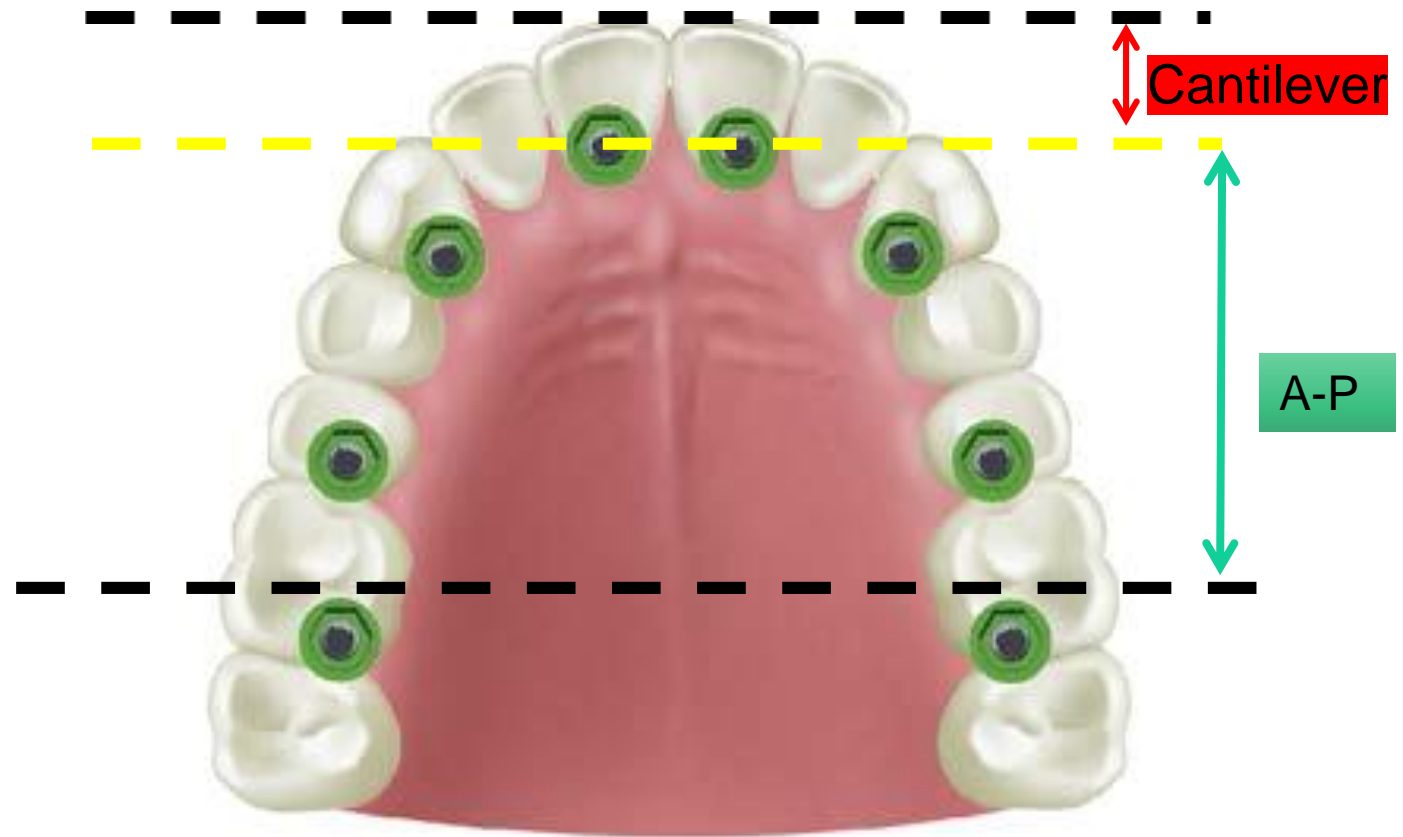
Maxillary Fixed Prosthesis Treatment Option 3:



The prosthesis treatment planned in a tapered dental arch form places the greatest forces on the anterior implants due to facial cantilever.

In treatment plan 3, when force factors are moderate or the dental arch form is tapered, the minimum implant number should increase to **eight implants.**

As such, four implants should be considered to replace the six anterior teeth. The bilateral canine and central incisor positions represent the best option.



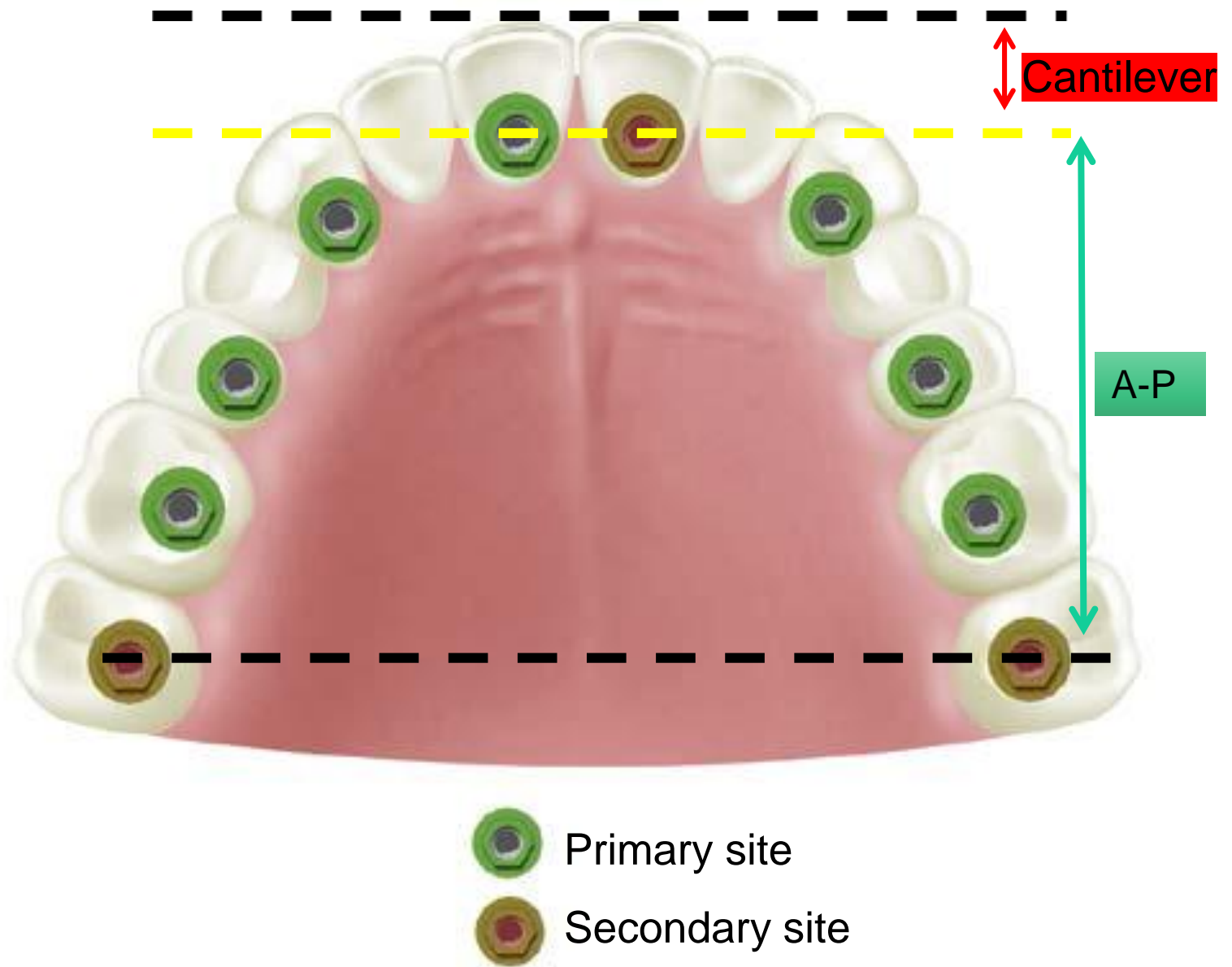
Fixed Treatment Plan 3: In a tapered arch form the anterior cantilever is greater and should be supported by implants in the premaxilla. At least four posterior implants should be added to restore the completely edentulous arch.

When force factors are greater than usual or bone density is poorer, additional implants may be used in any of the arch forms.

In the square and ovoid arch form, at least one additional implant is positioned in the premaxilla.

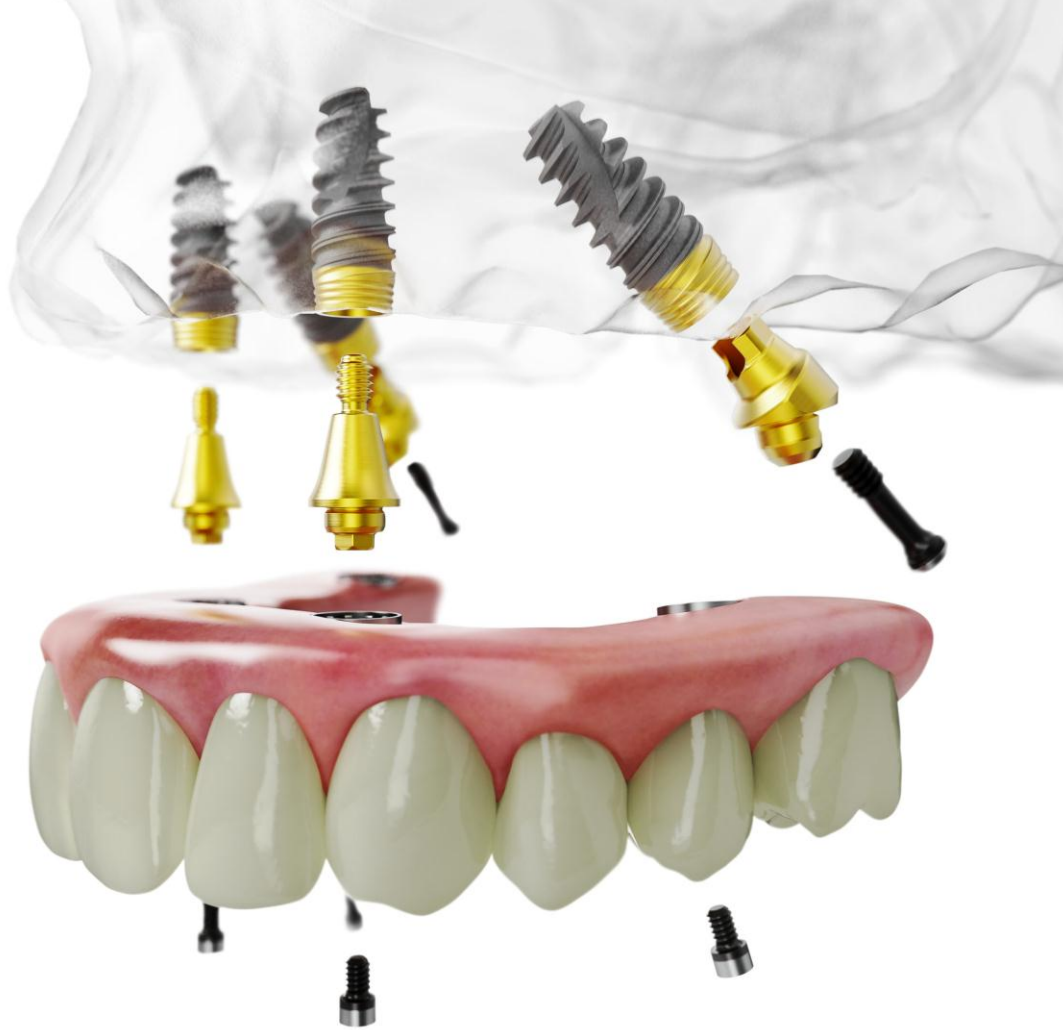For patients with higher force factors or poor bone density, two additional implants are planned in the distal half of the second molar position to improve the arch form.

This will result in an increased A-P distance compared with the first molar site, which will compensate for the increased force factors or poor bone density



In case of heavy stress factors, an additional anterior implant and bilateral second molar positions

Maxillary Fixed Prosthesis Treatment Option 4: All-on-Four



In implant dentistry today a shift in treatment options has become popular to minimize treatment time, treatment costs, and decrease patient morbidity. The all-on-four technique is most commonly used for immediate load situations

Careful patient selection, along with an experienced surgical and prosthetic clinician with an increased skill set, is essential for successful treatment results.

Two axially placed implants in the anterior and two posterior implants positioned angulated at 30 to 45 degrees. the tilted posterior implants have a biomechanical advantage in comparison with cantilevering axial placed implants

Edentulous **Mandible** Treatment Planning

LECTURE 13

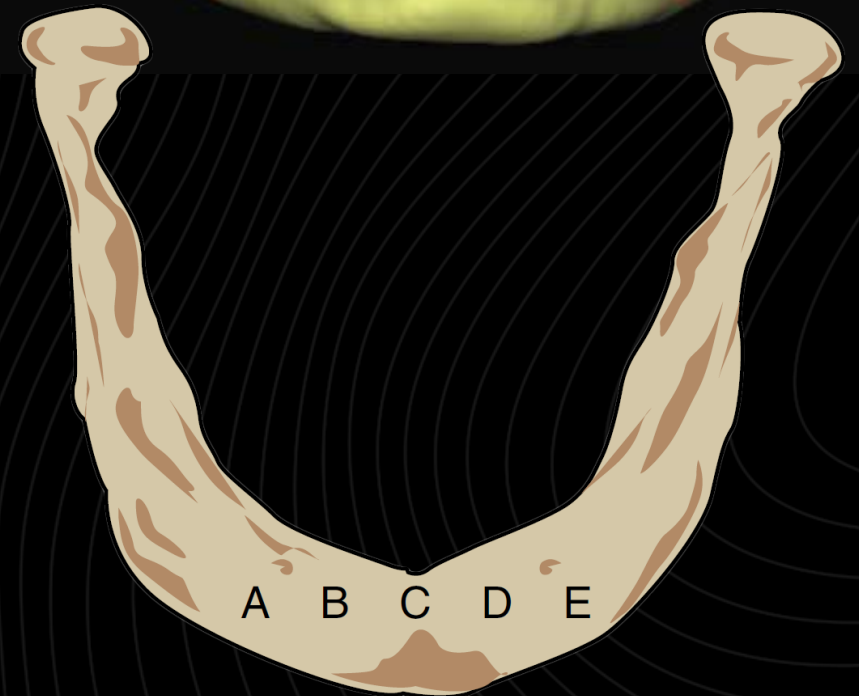
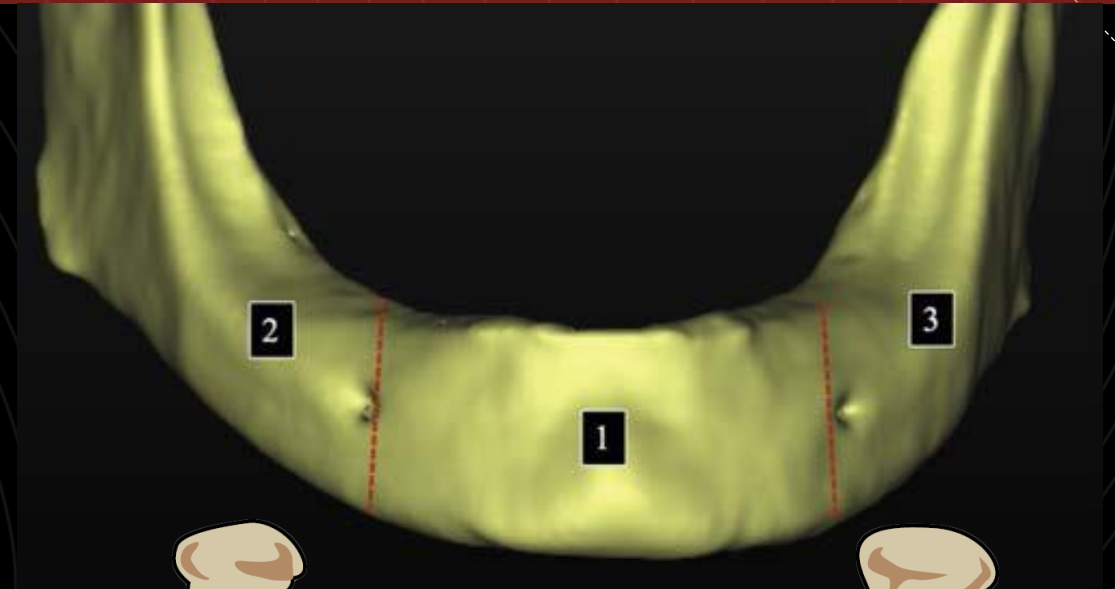
Anatomy of the Mandible

Anatomy of the Mandible

In treatment planning the mandible for a fixed or removable prosthesis, the mandible is divided into three regions:

(1) Anterior mandible (2) Posterior right (3) posterior left.

The available bone in the anterior mandible is divided into five equal columns of bone serving as potential implant sites, labeled **A, B, C, D, E** starting from the patient's right side. Regardless of the treatment option being used, all five implant sites are mapped out at the time of treatment planning and surgery.

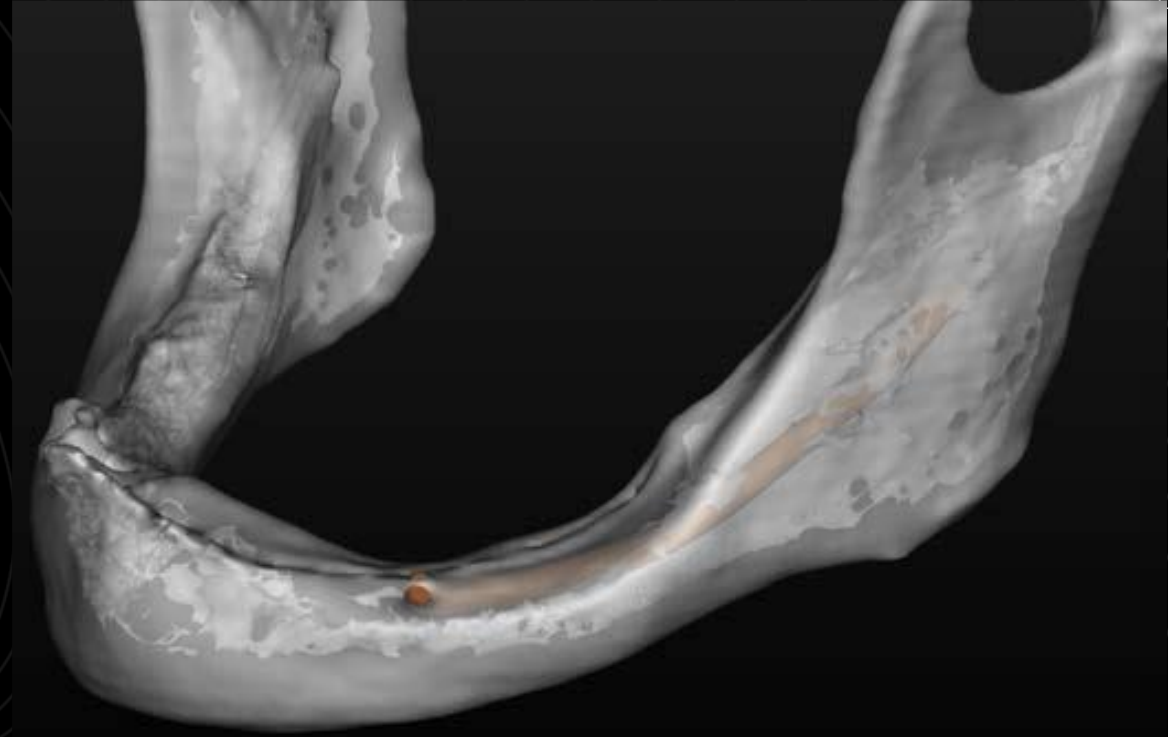


Mandibular Implant Site Selection

Mandibular Implant Site Selection

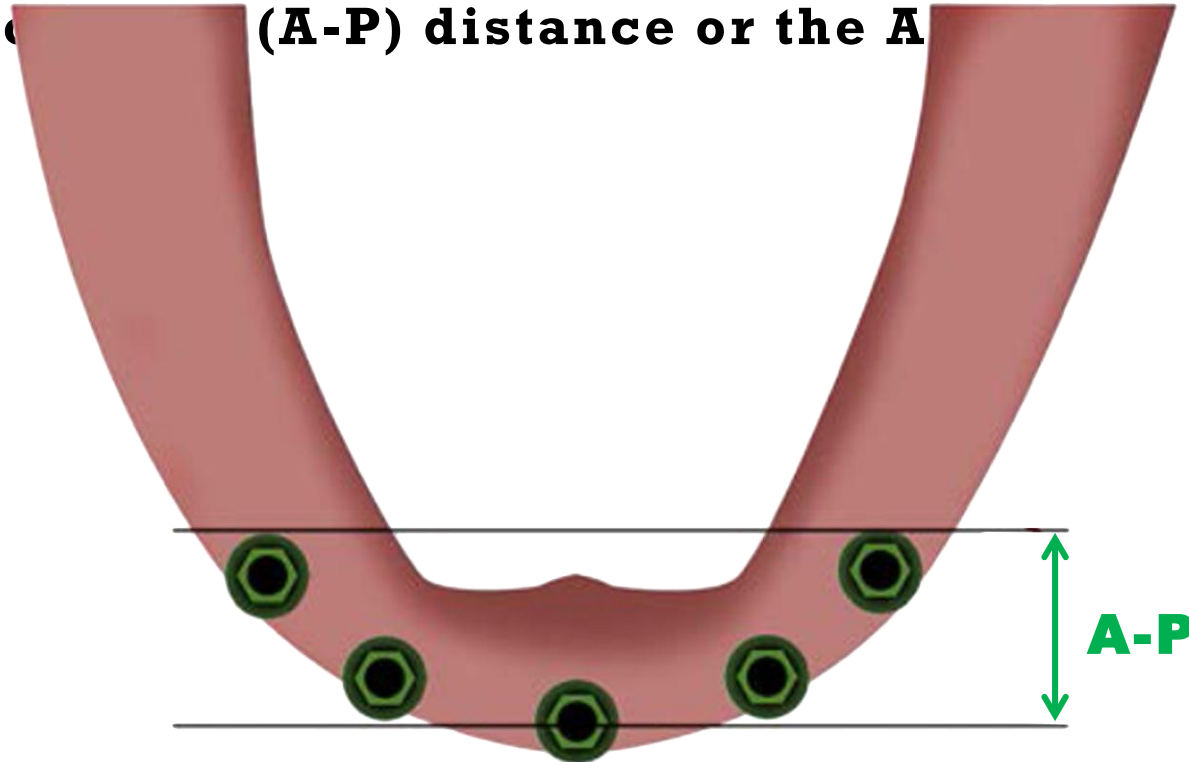
Anterior retention and stability for an overdenture offer several advantages:

1. The greatest available height of bone.
2. Usually presents a favorable bone density.
3. Overdentures with posterior movement (RP-5) gain better acceptance than removable prostheses with anterior movement.
4. Less torsion and medial mandibular movement.

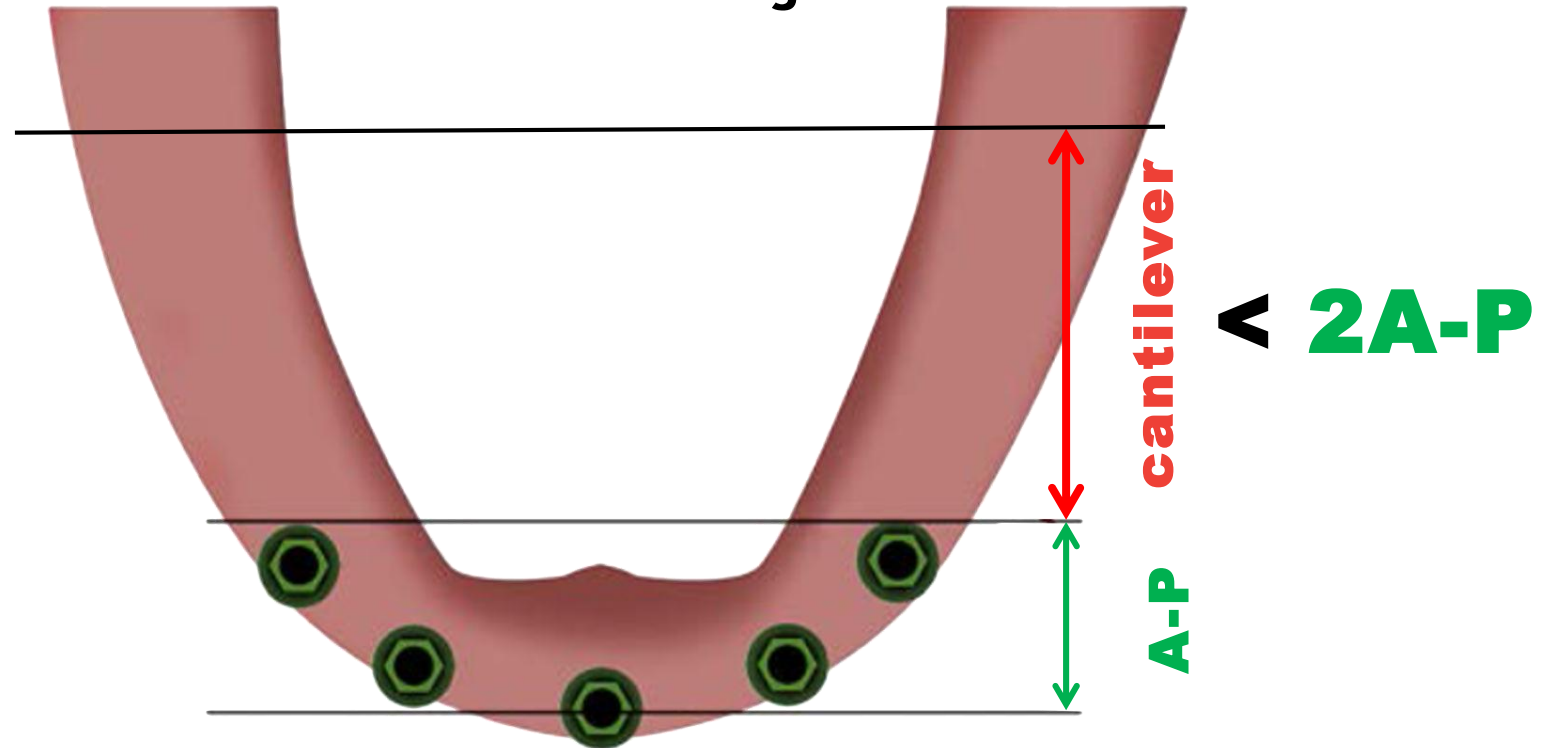


Mandibular Treatment Planning Principles

- **A-P** The distance from the center of the most anterior implant to a line joining the distal aspect of the two most distal implants on each side is called the anteroposterior (A-P) distance or the A-P distance.



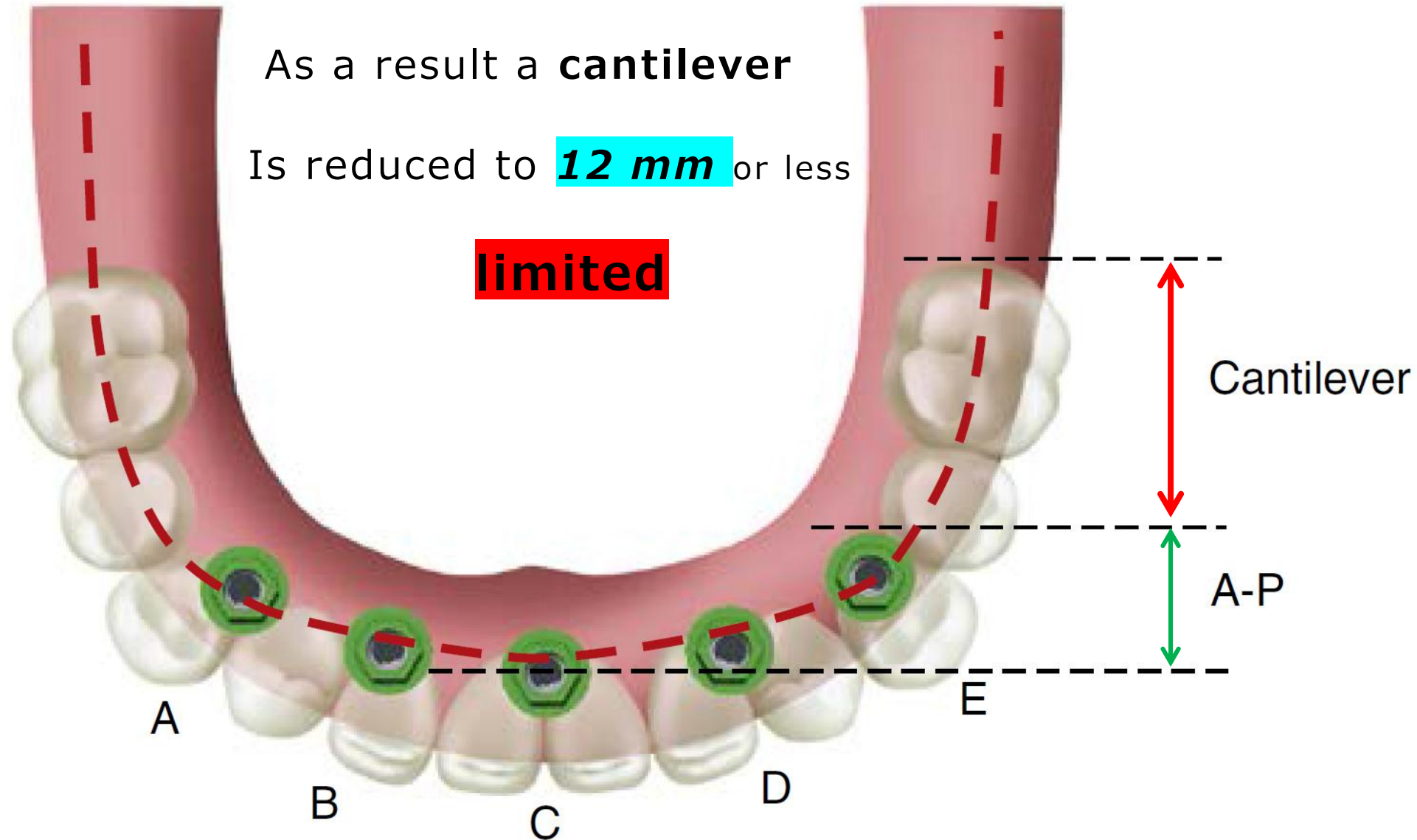
- The greater the A-P spread, the farther the distal cantilever may be extended to replace the missing posterior teeth. As a general rule, when five to six anterior implants are placed in the anterior mandible between the foramina to support a fixed prosthesis, the cantilever should **not exceed two times** the A-P spread, with all other stress factors being low.



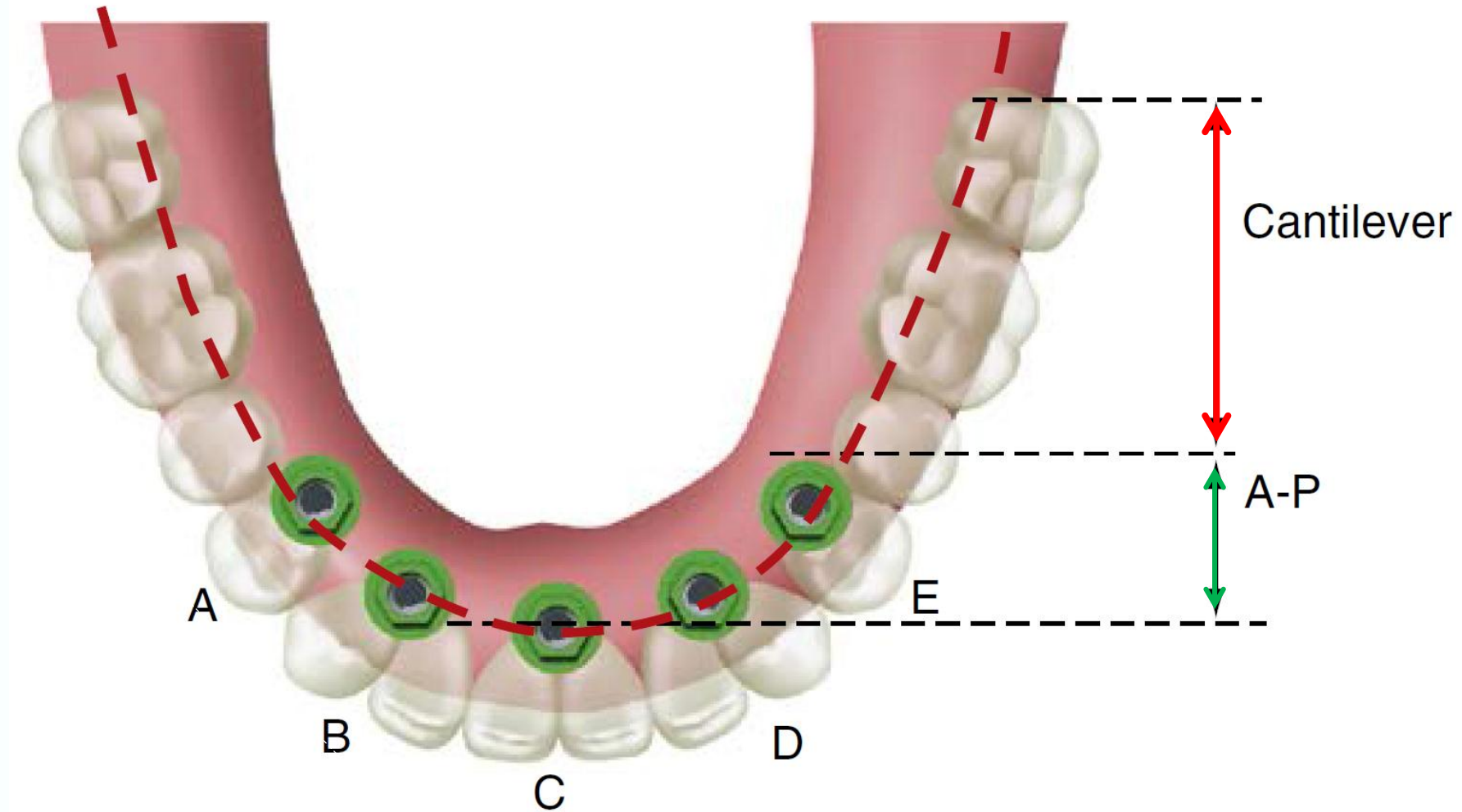
Arch Form and A-P Relation

- The A-P distance is affected by the arch form. The types of arch forms may be separated into **square**, **ovoid**, and **tapering**
- The **arch form**, the **position of the mental foramina**, **force factors**, and **bone density** are important criteria when four to six implants are placed only in the anterior segment to replace the entire mandibular arch. The anterior arch form and foramina position affect the position of the distalmost implants. Therefore a cantilever distance is variable for different patients.

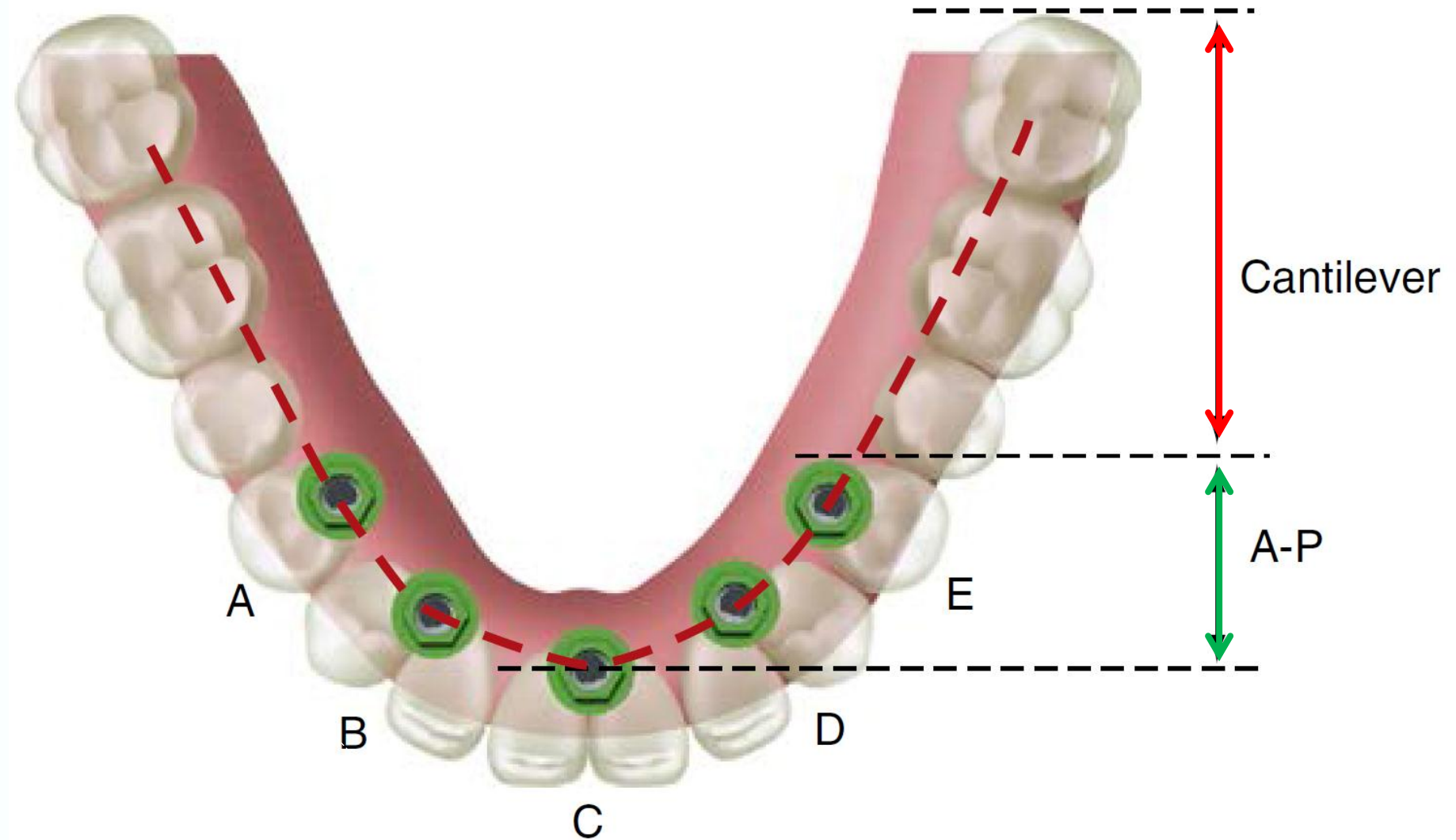
- **Square** arch form in the anterior mandible has a **0-6mm** A-P spread between the most distal and most anterior implants.



- **Ovoid** arch form has an anteroposterior (A-P) distance of **7-9mm** and is the most common type. A cantilever may extend to **18 mm**



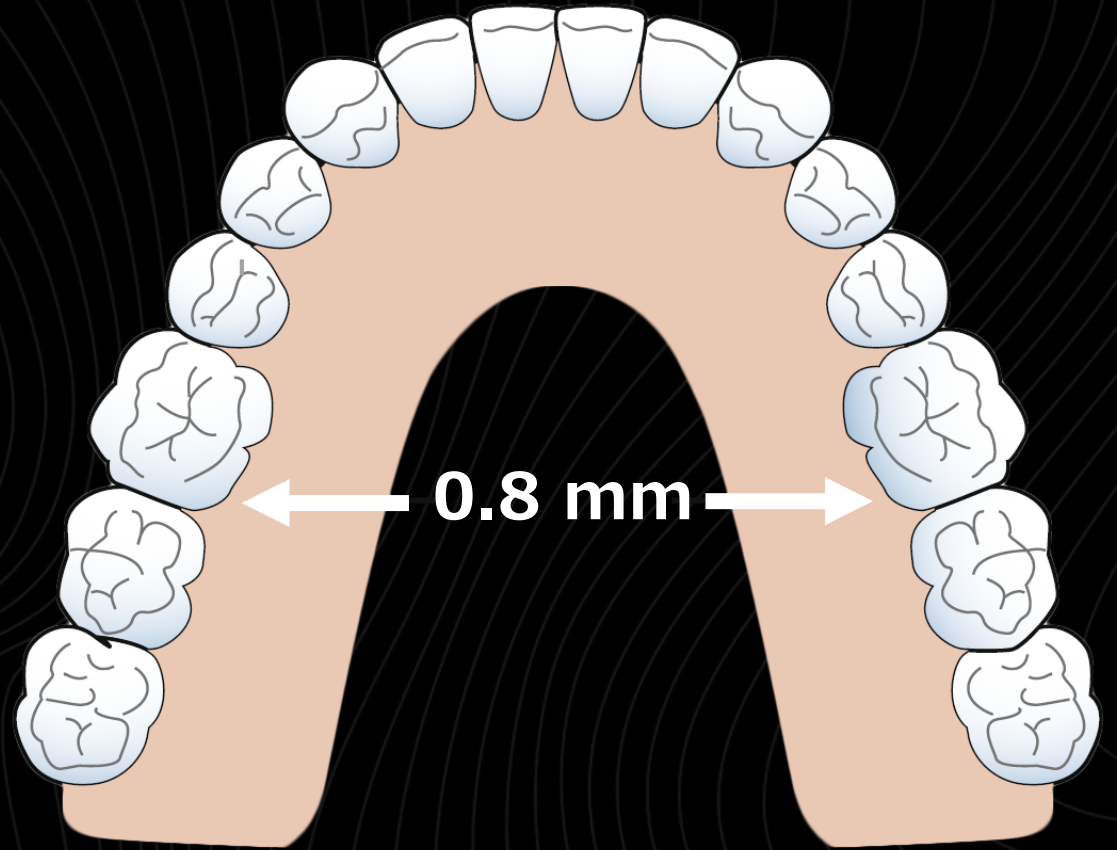
- **Tapered** arch form has an anteroposterior (A-P) distance of **greater than 9 mm** and is the type least observed it may support a **20mm** cantilever



Mandibular Treatment Planning Principles

- **Mandibular Flexure**

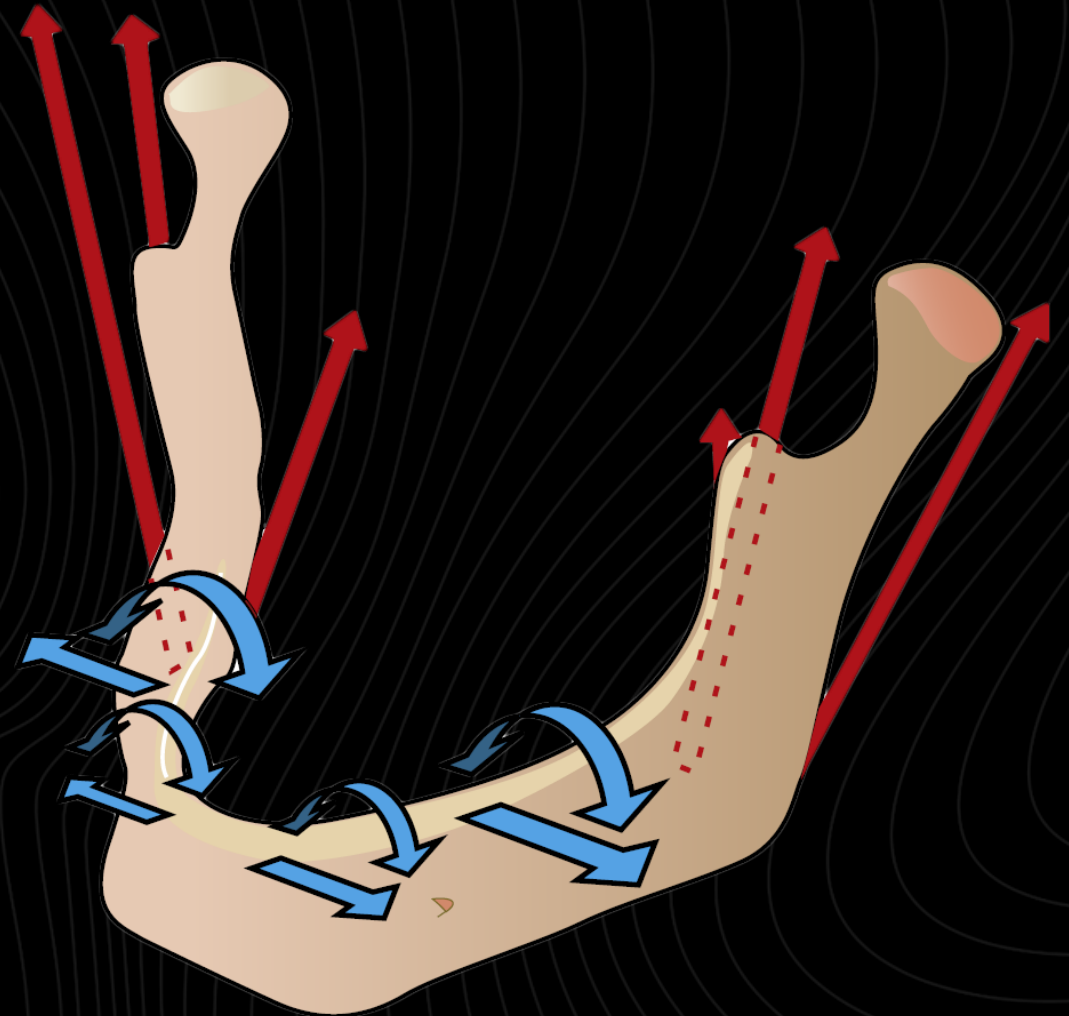
Medial Movement: The flexure of the mandible during opening and protrusive movements occurs distal to the mental foramina. The amount of flexure depends on the amount of the bone volume and the sites in question. The medial movement from the first molar to the first molar region may be 0.8 mm.



Mandibular Treatment Planning Principles

- **Mandibular Flexure**

Torsion of the mandibular body distal to the foramina has also been documented in both animal and human. The mandible flexes toward the midline on opening or during protrusive movements as a result of the internal pterygoid muscle attachments on the ramus (blue arrows). The mandible also torques, with the inferior



Factors Affecting Treatment planning

- If the stress factors are high (e.g., parafunction, crown height, masticatory musculature dynamics, opposing arch), the cantilever length of a prosthesis should be reduced and may even be contraindicated.
- The density of bone is also an important criterion. The softest bone types (D3 and D4) should not have as great of a cantilever than the denser types (D1 and D2).
- A cantilever rarely is indicated on three implants even with a similar A-P spread as five implants.

Factors Affecting Treatment planning

- The number and size of implants may also affect the cantilever length.
- The area over which the forces are applied from the prosthesis to the implants can be modified through the number, size, and design of the implants.



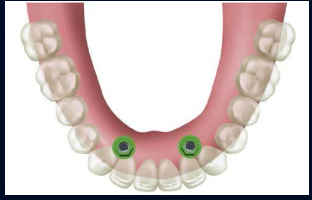Overdenture

Treatment Options

LECTURE 14

Mandibular Overdenture Treatment Planning

Evaluating the patient for an overdenture, evaluate the patient's existing dentures concerning *support*, *retention*, and *stability*. Support is related to the resistance to occlusal load. Retention describes the resistance of the prosthesis to movement away from the tissues. Stability is the lateral resistance criterion. The *patient's complaints*, *anatomy*, *desires*, and *financial commitment* determine the amount of implant support, retention, and stability required to address these conditions predictably.

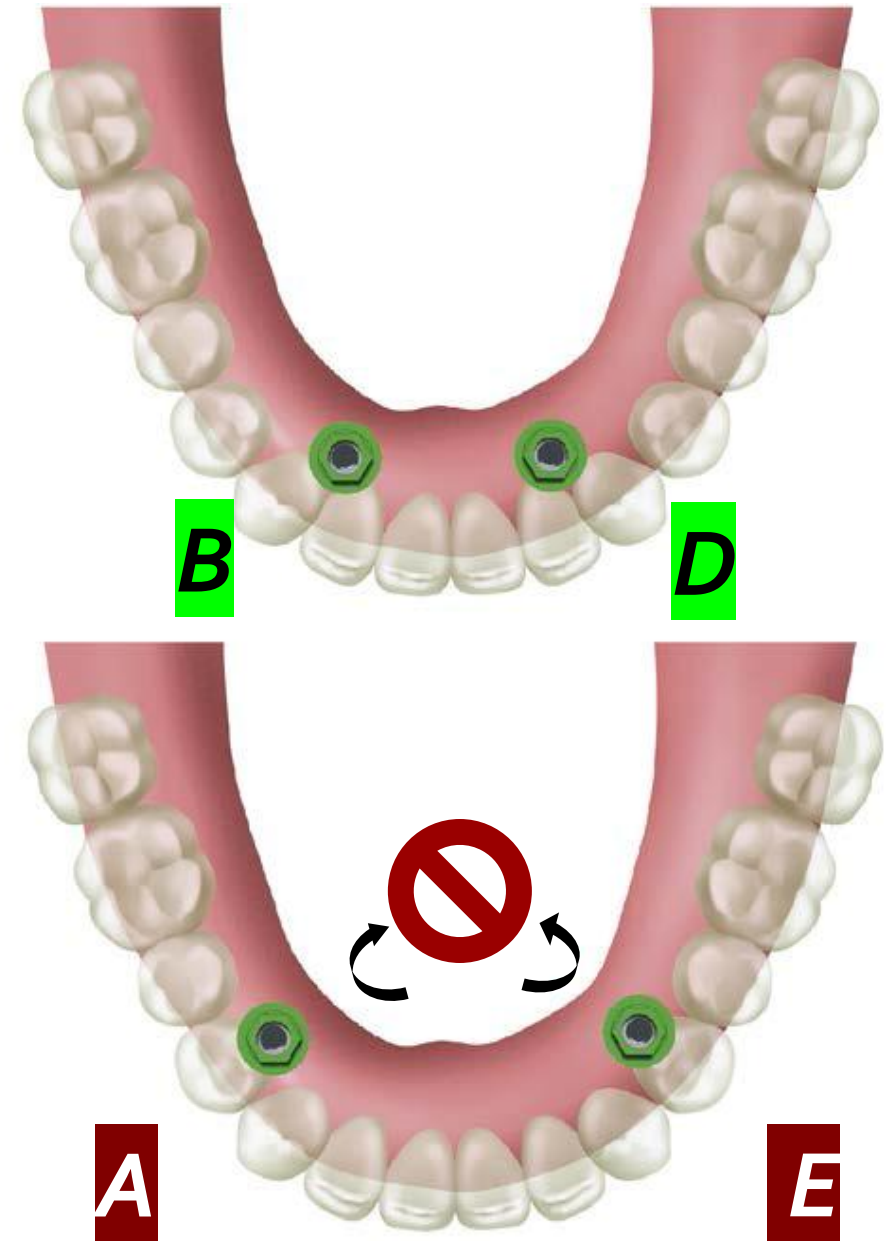


Overdenture Option 1

- Indicated primarily when **cost** is the most significant patient factor and minimal retention is required. The patient should be educated about the amount of retention.
- **Bone volume** should be abundant (Division A or B) in the anterior, and the posterior ridge form should be an inverted **U shape**, with high parallel walls for good-to-excellent anatomic conditions for conventional denture, support, and stability. The buccal shelf (primary stress bearing area) should be prominent to withstand the forces. Under these conditions, two implants may be inserted in the **B and D positions**. The implants usually remain independent of each other and are not connected with a superstructure. The most common type of attachment used in OD-1 is a **Locator** or an **O-ring design**, because there will be associated prosthesis movement.

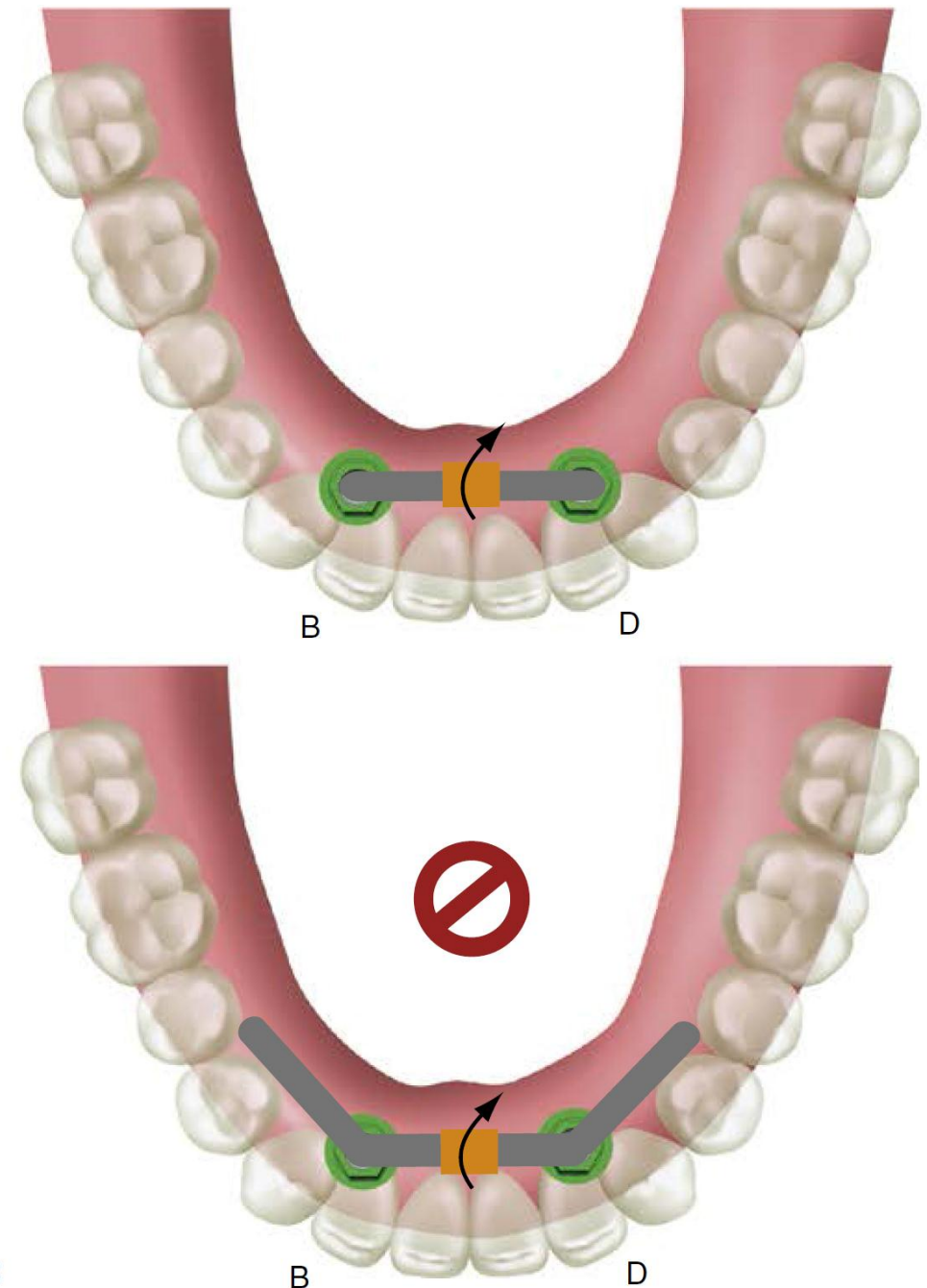
Overdenture Option 1

- *Overdenture option 1 consists of two independent implants. These are best placed in the **B and D positions** to limit the forward rocking of the restoration during function.*
- *Independent implants in the **A and E positions** allow greater rocking of the restoration and place greater leverage forces against the implants.*



Overdenture Option 1

- *Treatment option 2 has implants in the B and D positions, and a bar joins the implants. The bar should not be cantilevered off the distal side of the implants. The prosthesis movement will be reduced, and too much force on the bar and implants will increase complications. Attachments such as an O-ring or a Hader clip, which allow movement of the prosthesis, can be added to the bar. The attachments are placed at the same height at equal distance off the midline and parallel to each other*



Overdenture Option 1

• **Advantages**

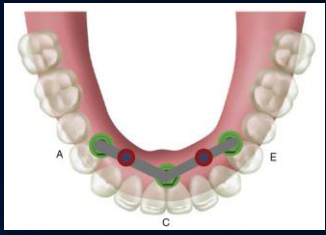
- • *Decreased cost*
- • *Greater prosthesis support than conventional denture*
- • *Less invasive surgical and prosthetic procedures*

• **Indications**

- • *Lowest cost*
- • *Less-complicated surgery*
- • *Patient who needs minimal increased retention (RP-5)*

• **Disadvantages**

- • *May not meet patient expectations*
- • *Increased maintenance appointments*
- • *Continuous cost associated with attachment replacement*
- • *Prosthesis reline must be completed more often*
- • *Relies on soft tissue for primary support*

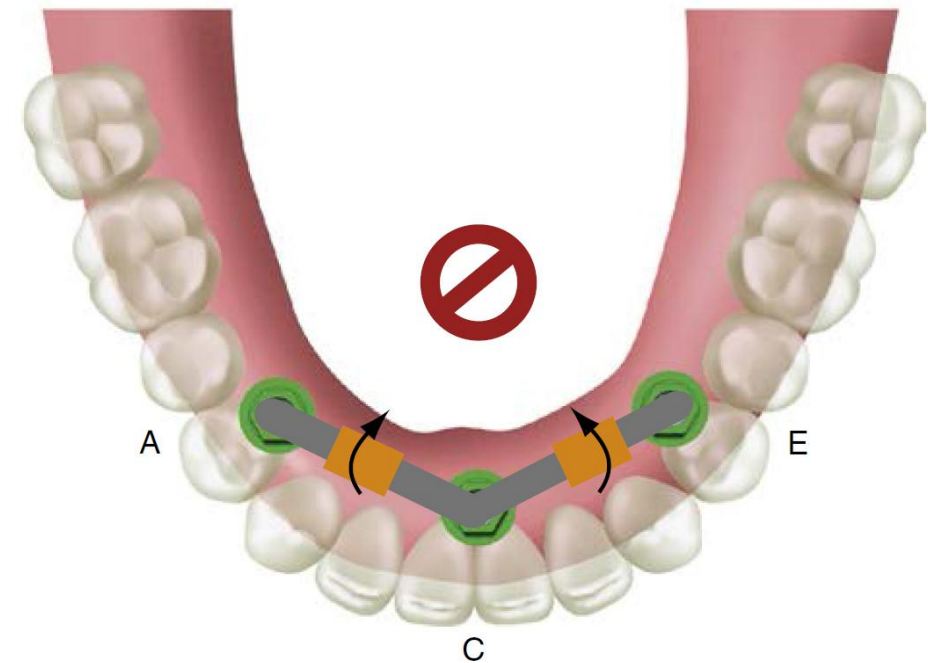
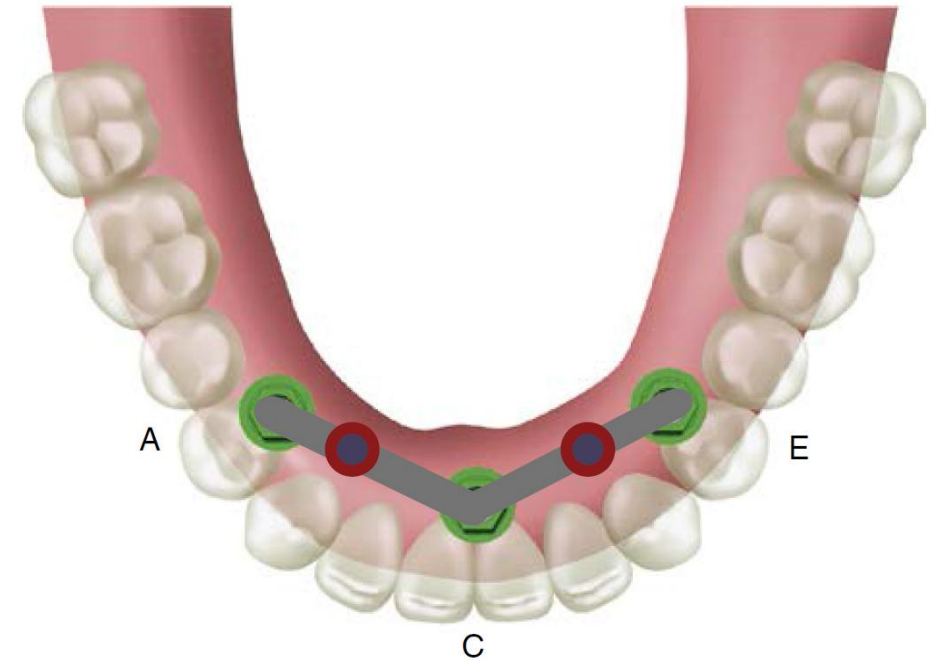


Overdenture Option 2

- *Three root form implants are placed in the A, C, and E positions.*
- *Ideally, the implants in the A, C, and E positions should not form a straight line. The C implant is anterior to the A and E implants.*
- *If the posterior ridge form is poor (Division C–h), the lack of lateral stability places additional forces on the anterior implants. Implants then are best placed in the B-C-D position to allow greater freedom of movement of the prosthesis.*
- *The greater the stress to the system, the greater **prosthesis movement/stress relief** indicated. This increases the posterior movement of the prosthesis but decreases the amount of stress placed on the implants and screw-retained bar.*

Overdenture Option 2

- *The attachments should be positioned to allow movement of the distal section of the prosthesis.*
- *Two nonaligned Hader clips will not allow movement.*



Overdenture Option 2

- **Advantages**

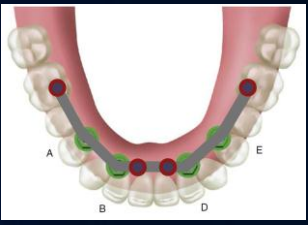
- • *Increased retention*
- • *Less invasive surgery and prosthetics*
- • *Increased A-P spread from options 1*

- **Indications**

- • *Relatively low cost*
- • *Less-complicated surgery and prosthetics*
- • *Patient who needs minimal increased retention (RP-5)*

- **Disadvantages**

- • *May not meet patient expectations (RP-5 prosthesis)*
- • *Increased maintenance appointments*
- • *Continuous cost associated with attachment replacement*
- • *Prosthesis reline must be completed more often*
- • *Relies on soft tissue for primary support*

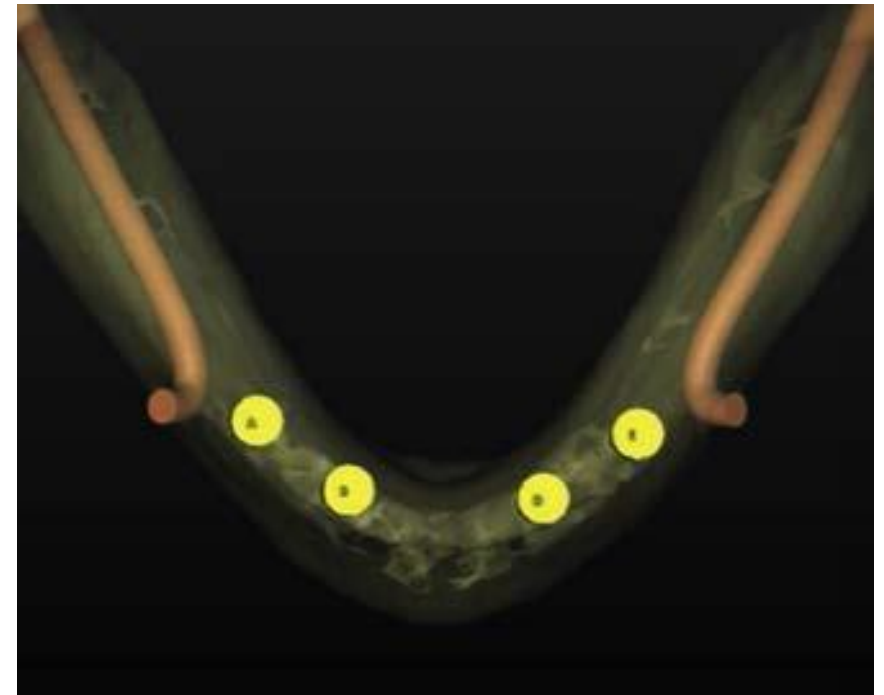
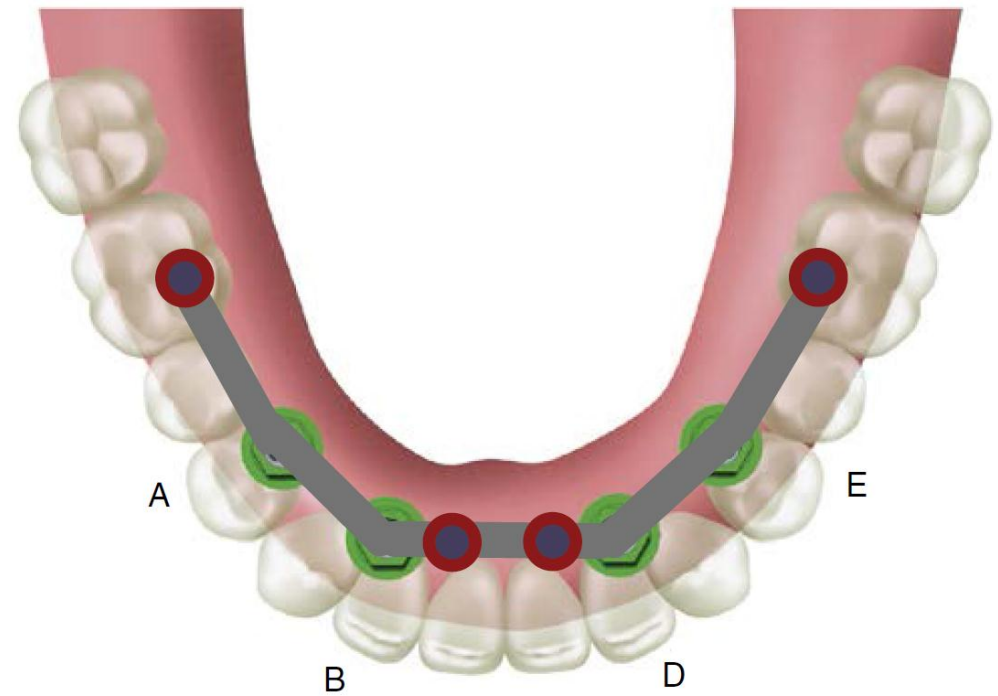


Overdenture Option 3

- *Four implants are placed in the A, B, D, and E positions. These implants usually provide sufficient support to include a distal **cantilever up to 10 mm** on each side if the stress factors are low.*
- *The patient's indications for this OD-3 include moderate to- poor posterior anatomy that causes a lack of retention and stability.*
- *The prosthesis is still RP-5, but with the least soft tissue support of all RP-5 designs.*
- *The anterior attachment must allow vertical movement for the distal aspect of the prosthesis.*

Overdenture Option 3

- *The overdenture attachments often are placed in the distal cantilevers.*
- *The A-P spread is the first factor to determine the length of the cantilever.*
- *When stress factors such as occluding forces are greater, the cantilever is decreased.*



Overdenture Option 3

• **Advantages**

- • *Increased anteroposterior spread from options 1 and 2*
- • *May cantilever with bar*
- • *May be used as an RP-4 or RP-5 according to force factors*
- • *Possible no soft tissue support (RP-4)*

• **Indications**

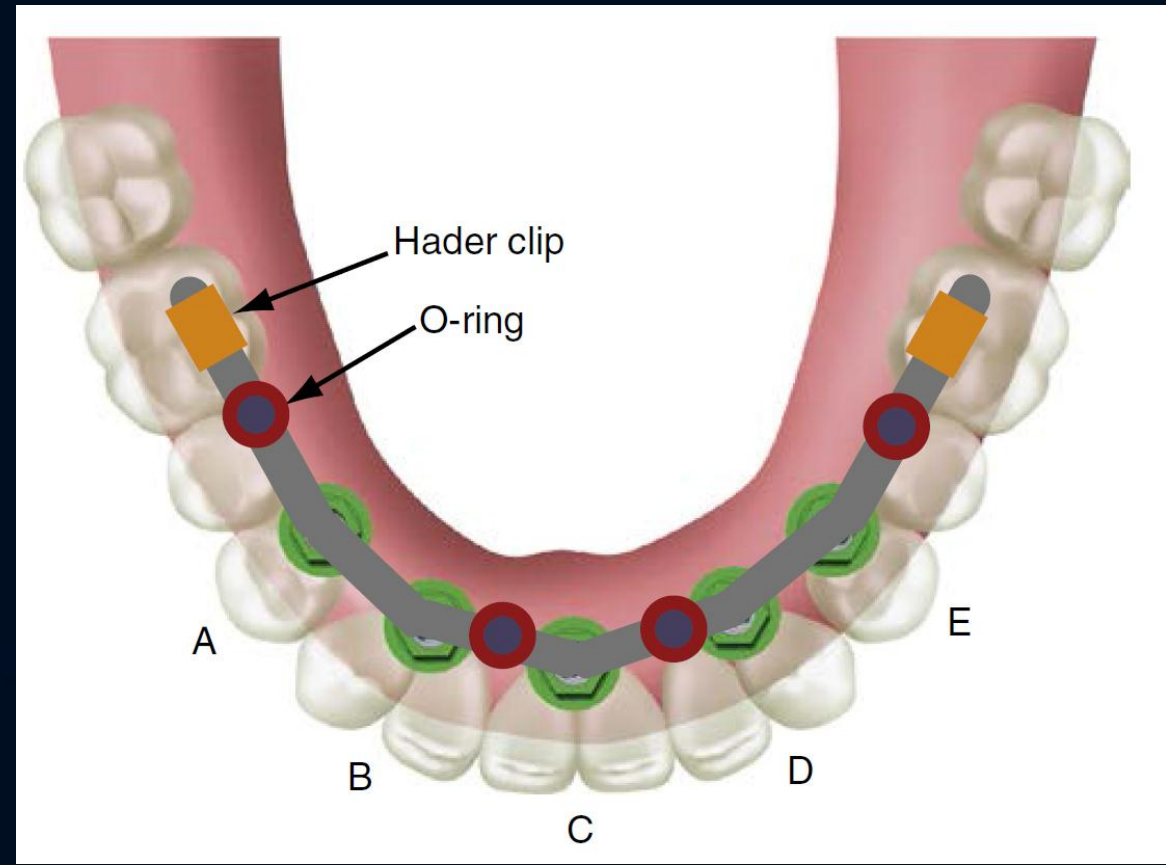
- • *Increased retention*
- • *Decreased prosthesis movement*
- • *More range of prosthetic options*

• **Disadvantages**

- • *More implants required*
- • *More expensive treatment*
- • *Surgical and prosthetic procedures more complicated*

Overdenture Option 4

- *This is a minimum treatment option for patients with moderate-to-severe problems related to a traditional restoration.*
- *Indicated when no posterior implants are inserted, the attachments, cantilevered bar, and overdenture avoid load to the residual ridge and often halt its resorption process.*
- *In the C-h anterior bone volume patient, one more implant is added to each option and OD-1 is eliminated completely.*



Overdenture Option 3

• **Advantages**

- *Increased anteroposterior spread from options 1, 2, and 3*
- *Usually bar-retained cantilever can be used*
- *RP-4 prosthesis*
- *No soft tissue support*

• **Indications**

- *Highest amount of retention for an overdenture*
- *Decreased prosthesis movement*
- *More range of prosthetic options*

• **Disadvantages**

- *More implants required*
- *More expensive treatment*
- *Surgical and prosthetic procedures more complicated*

Fixed Prosthesis

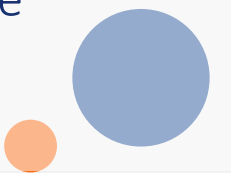
Edentulous Mandible

Lecture 15

Fixed Prosthesis Advantages



- **Psychological:** most patients do not want to be able to remove the prosthesis. A fixed prosthesis often is perceived as an actual body part of the patient.
- **Improved Speech:** overdentures to an extent, often move during mandibular jaw movements during function and speech. As a consequence the teeth may touch during speech and elicit clicking noises.
- **Decreased Soft Tissue Irritation:** An implant-supported overdenture may limit lateral movements and direct more longitudinal forces.
- **Increased Biting Force:** greater chewing efficiency and bite force in edentulous patients with fixed implant-supported prostheses
- **Less Bone Resorption:** an important advantage for a complete implant-supported prosthesis is the maintenance and possible regeneration of posterior bone in the mandible.



Fixed Prosthesis Advantages

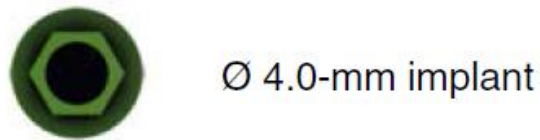
- **Less Soft Tissue Extension:** Implant-supported prostheses do not require labial extensions or extended soft tissue coverage.
- **Less Long-Term Expenses:** Locator, O-rings, or clips wear and must be replaced regularly.
- **Less Interocclusal Space Requirement:** with a fixed prosthesis, only 8mm is required for a zirconia prosthesis and 10 mm for a porcelain fused to metal prosthesis.



Implant Treatment Options for Fixed Restorations

Treatment Option 1: The Brånemark

Approach, and bilateral distal cantilevers replace the mandibular posterior teeth usually to the first molar region. The mandible does not flex or exhibit significant torsion between the mental foramina. 84% success rate using this treatment option



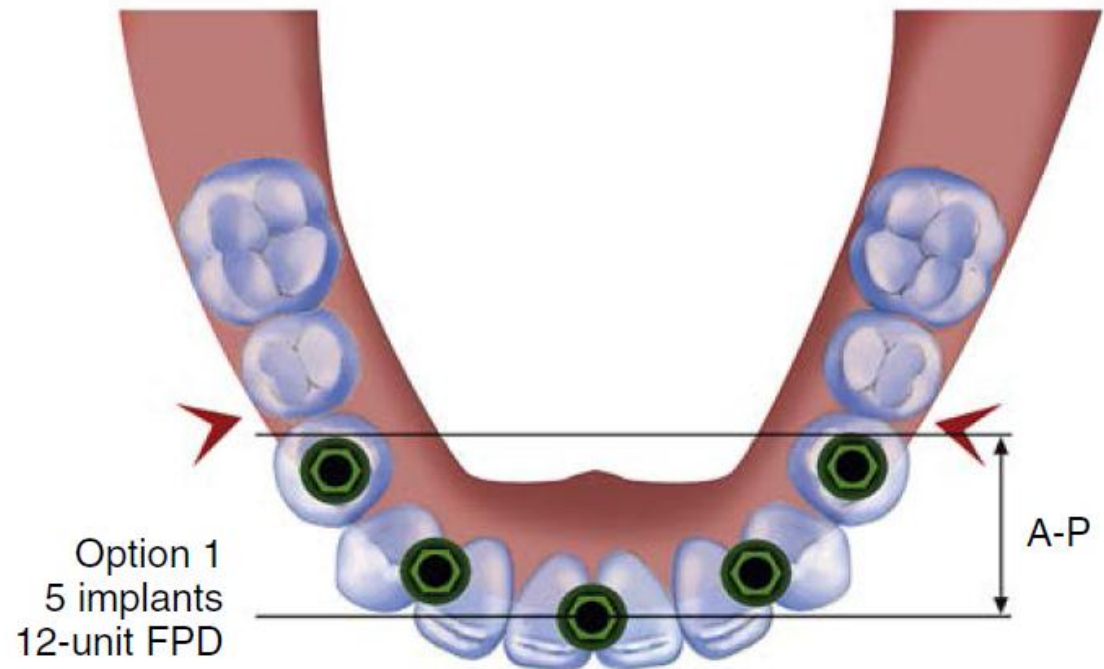
Ø 4.0-mm implant



Optional implant



Mental foramen



Fixed Treatment Option 1: Four to Six Implants Between the Foramina

Advantages

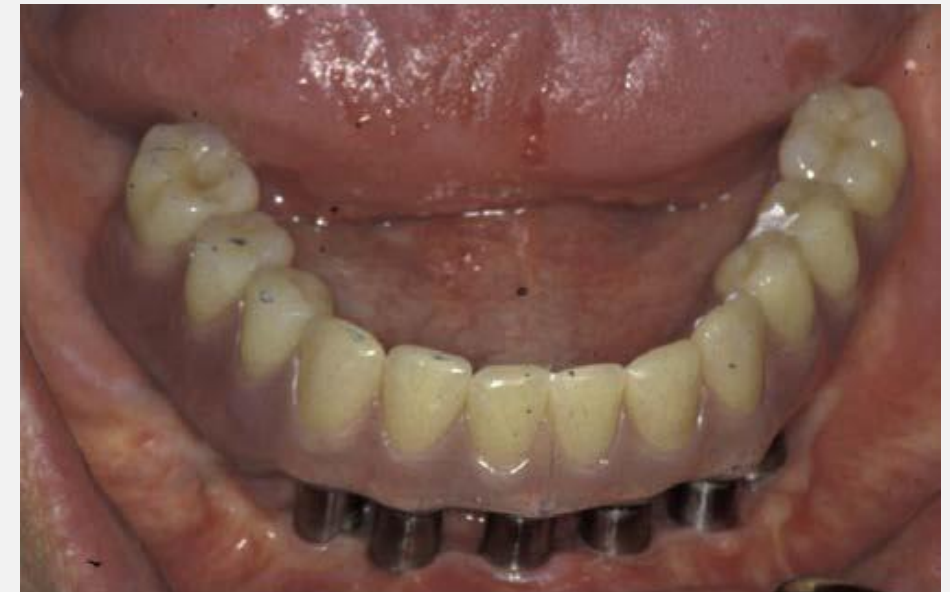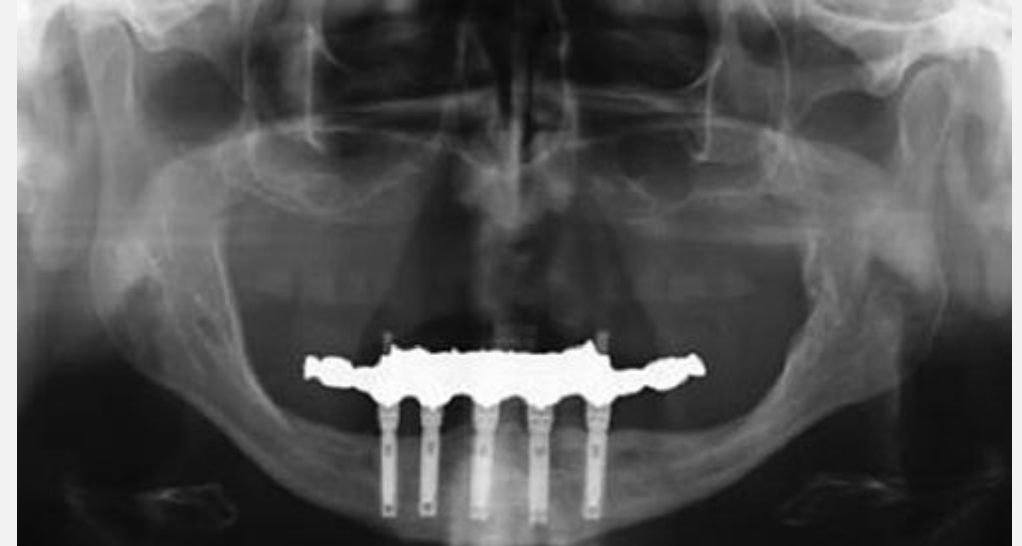- Usually sufficient bone between the foramina for implant placement
- Relatively safe area for implant placement
- Posterior bone quantity for implant is not relevant

Disadvantages

- Bilateral posterior cantilever
- Susceptible to excessive force factors

Indications

- Low force factors
- Positive anteroposterior spread (ovoid or tapering)

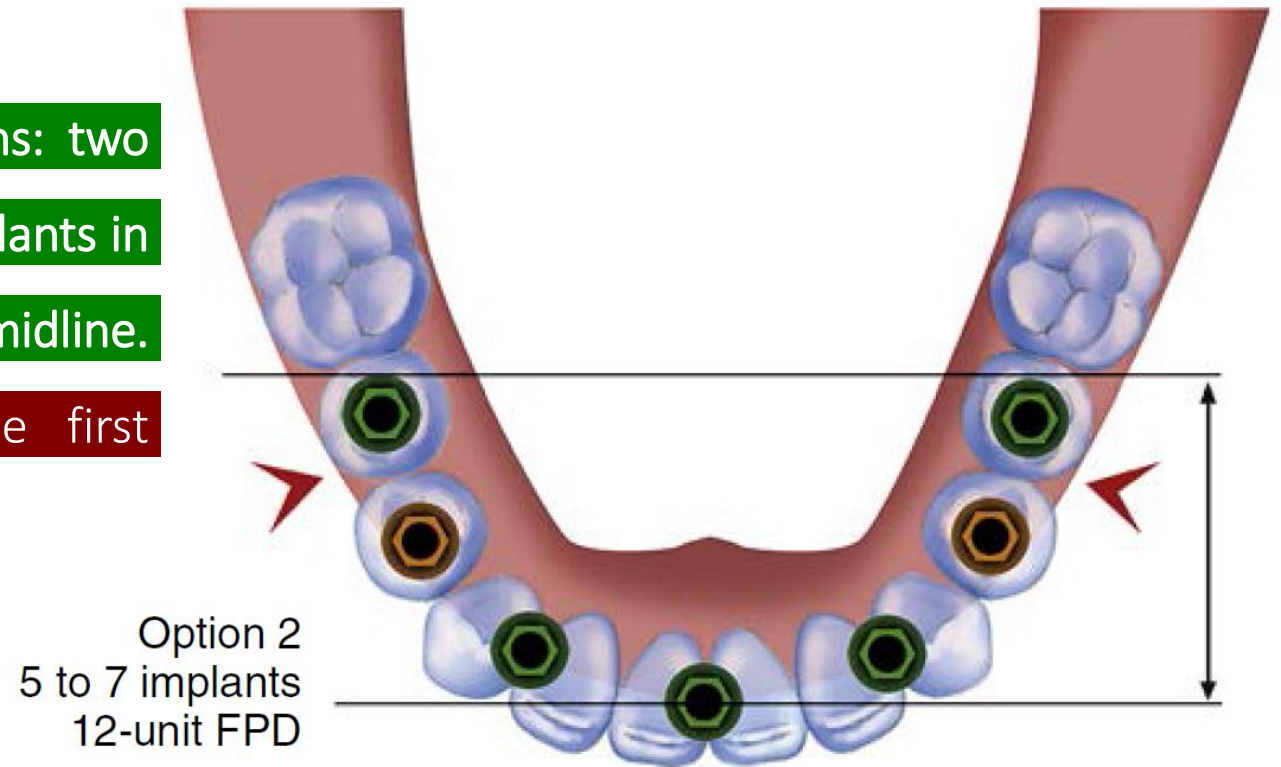


Treatment Option 2: Modified Brånemark Technique

A slight variation of the Brånemark protocol is to **place additional implants above the mental foramina** because the mandible flexes distal to the foramen.

Treatment option 2 has **five key implant positions: two implants placed over the mental foramina, two implants in the canine positions, and one implant in the midline.**

Secondary implants may be positioned in the first premolar sites. FPD, Fixed partial denture.



The two optional implant sites are the first premolar sites and are more often indicated when the patient force factors are greater than usual

Treatment Option 2: Modified Brånemark Technique

Advantages

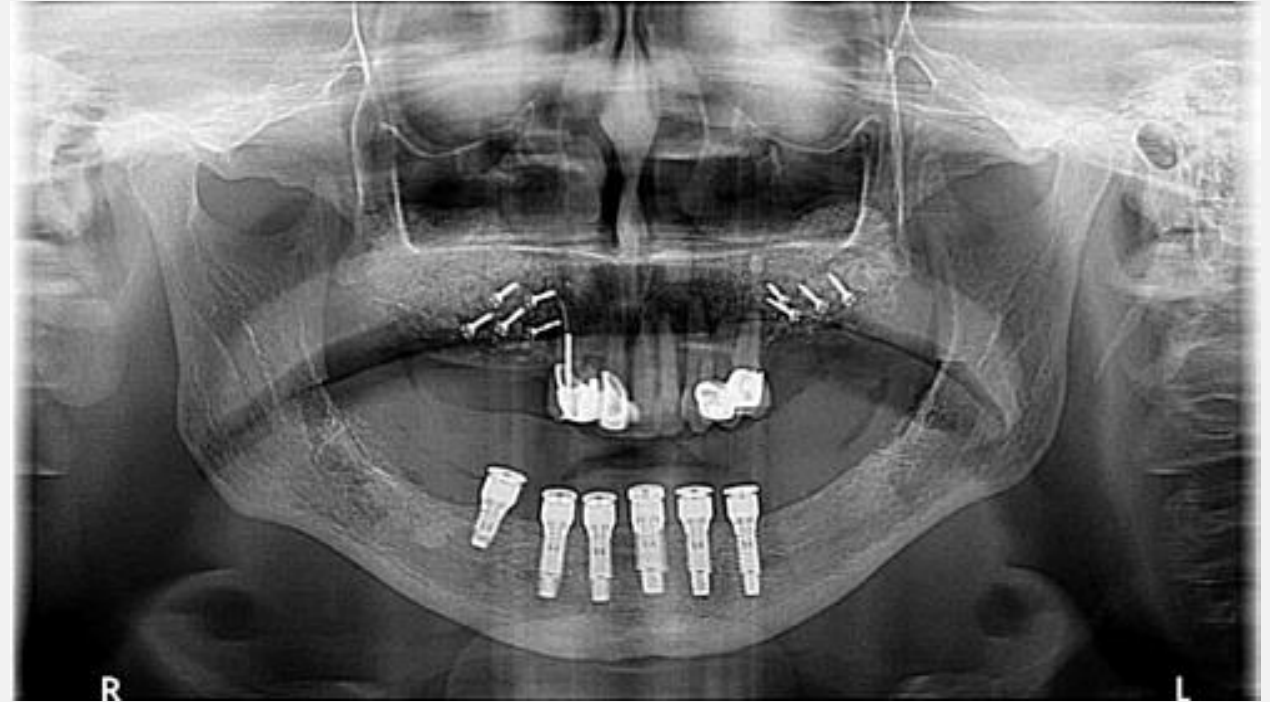
- Decreased cantilever
- Increased anteroposterior spread

Disadvantages

- Must have adequate posterior bone
- More implants required

Indications

- Higher force factors
- Square arch forms

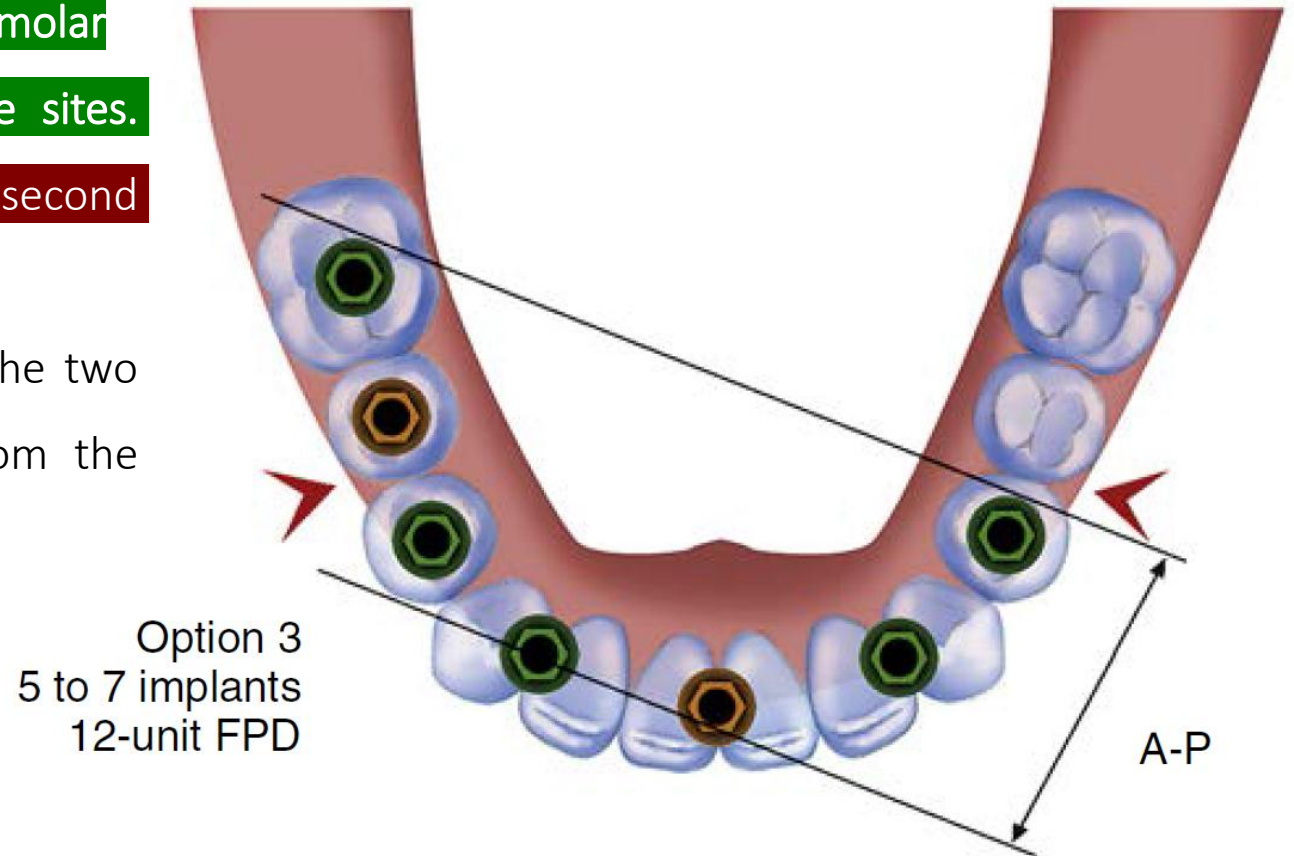


Treatment Option 3: Anterior Implants and Unilateral Posterior Implant

The third fixed treatment option is used when inadequate bone is present over the foramina and support is required more posteriorly.

Treatment option 3 has key implant positions in one first molar site, bilateral first premolar positions, and two canine sites. Secondary implants may be used in the bilateral second premolar and midline position.

The anteroposterior (A-P) distance is measured from the two distalmost implants to the anterior most implant from the cantilever.



Treatment Option 3: Anterior Implants and Unilateral Posterior Implant

Treatment option 3 is a better option than anterior implants with bilateral cantilevers (option 1 or 2) for several reasons. When one or two implants are placed distal to the foramina on one side and are joined to anterior implants between the foramina, a **considerable biomechanical advantage is gained**

Advantages


- Unilateral cantilever
- Increases anteroposterior spread

Disadvantages

- Must have adequate posterior bone
- More implants required

Indications

- Higher force factors
- Square arch forms

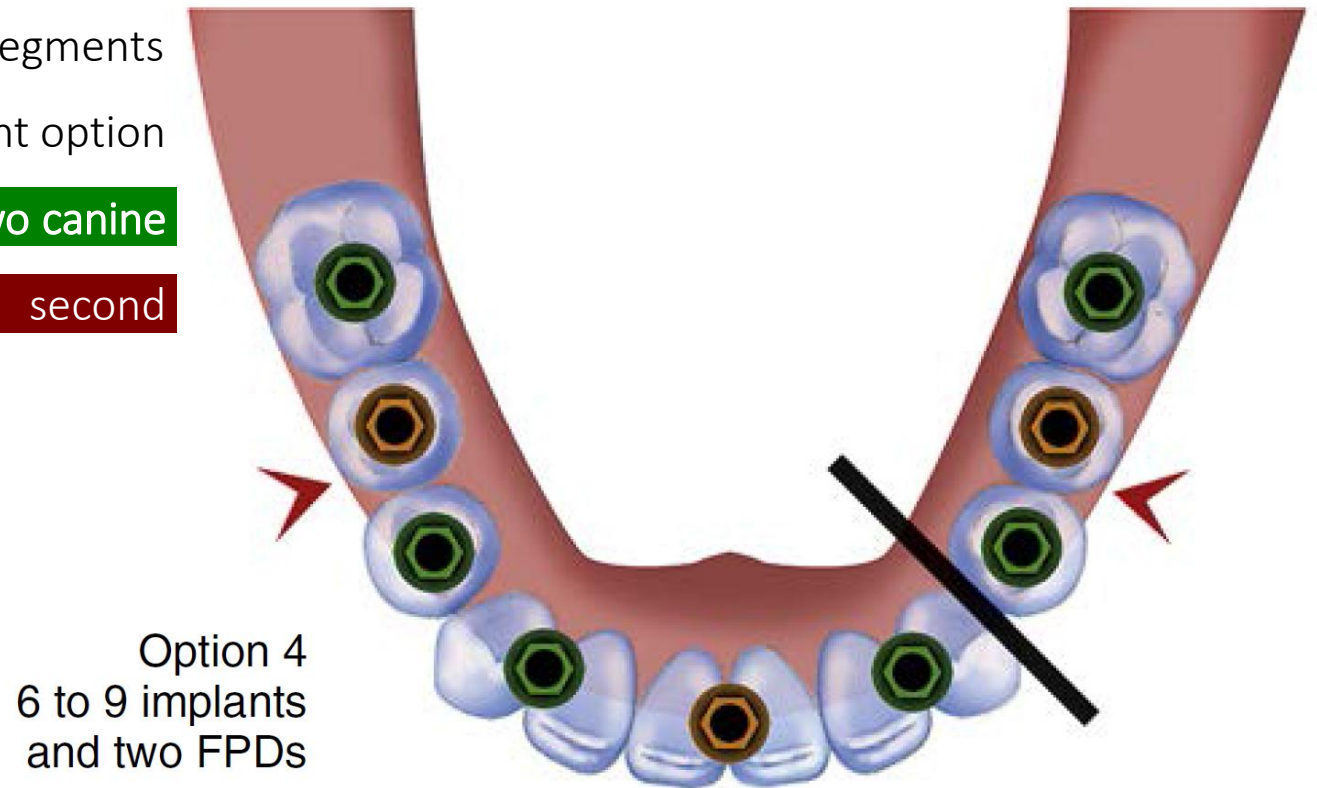


Treatment Option 4: Anterior Implants and Bilateral Posterior Implants

This option is selected when **force factors are great** or **the bone density is poor**.

In treatment option 4, implants are placed in all three segments of the mandible. Key implant positions for this treatment option include the **two first molars, two first premolars, and two canine sites**. Secondary implants may be added in the second premolars or the incisor (midline) position (or both).

The **primary advantage** of this treatment option is **the elimination of cantilevers**. As a result, **risks for occlusal overload are reduced**. Another advantage is that the prosthesis has two segments rather than one.



Treatment Option 4: Anterior Implants and Bilateral Posterior Implants

Advantages

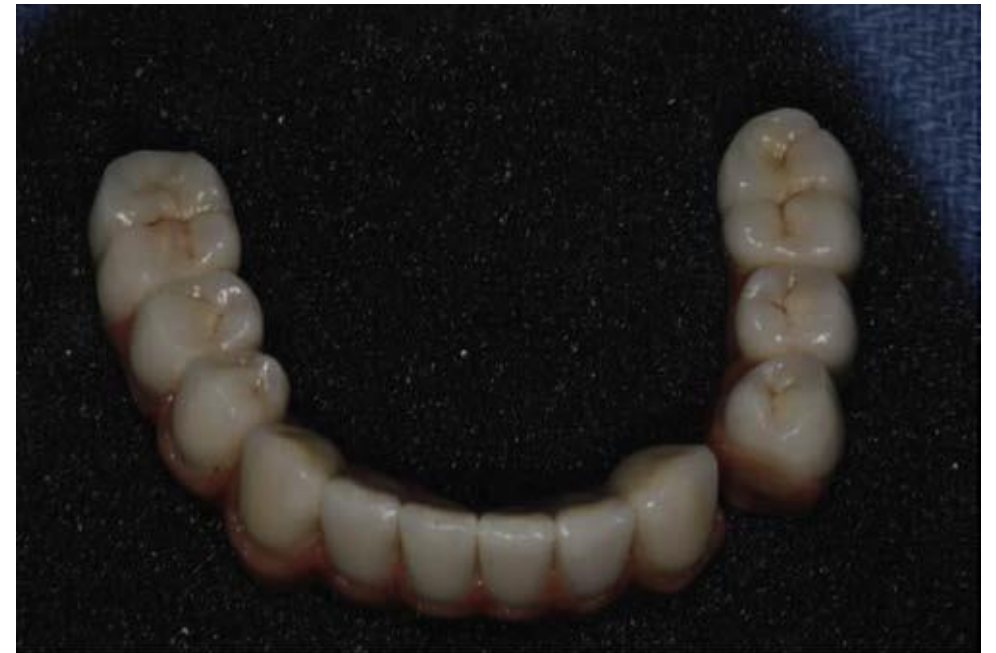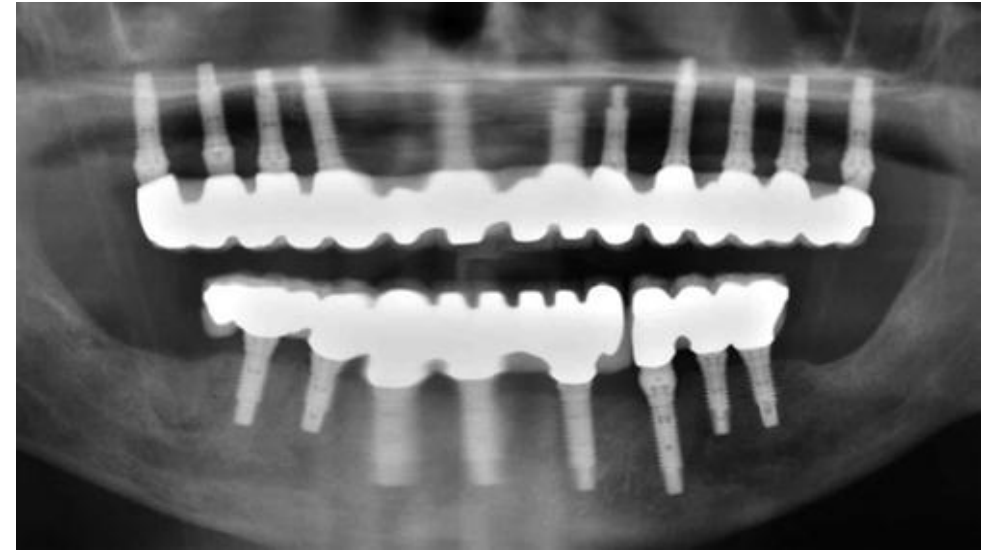
- No cantilever
- Increases anteroposterior spread
- Highest support

Disadvantages

- More implants required
- Bilateral posterior bone

Indications

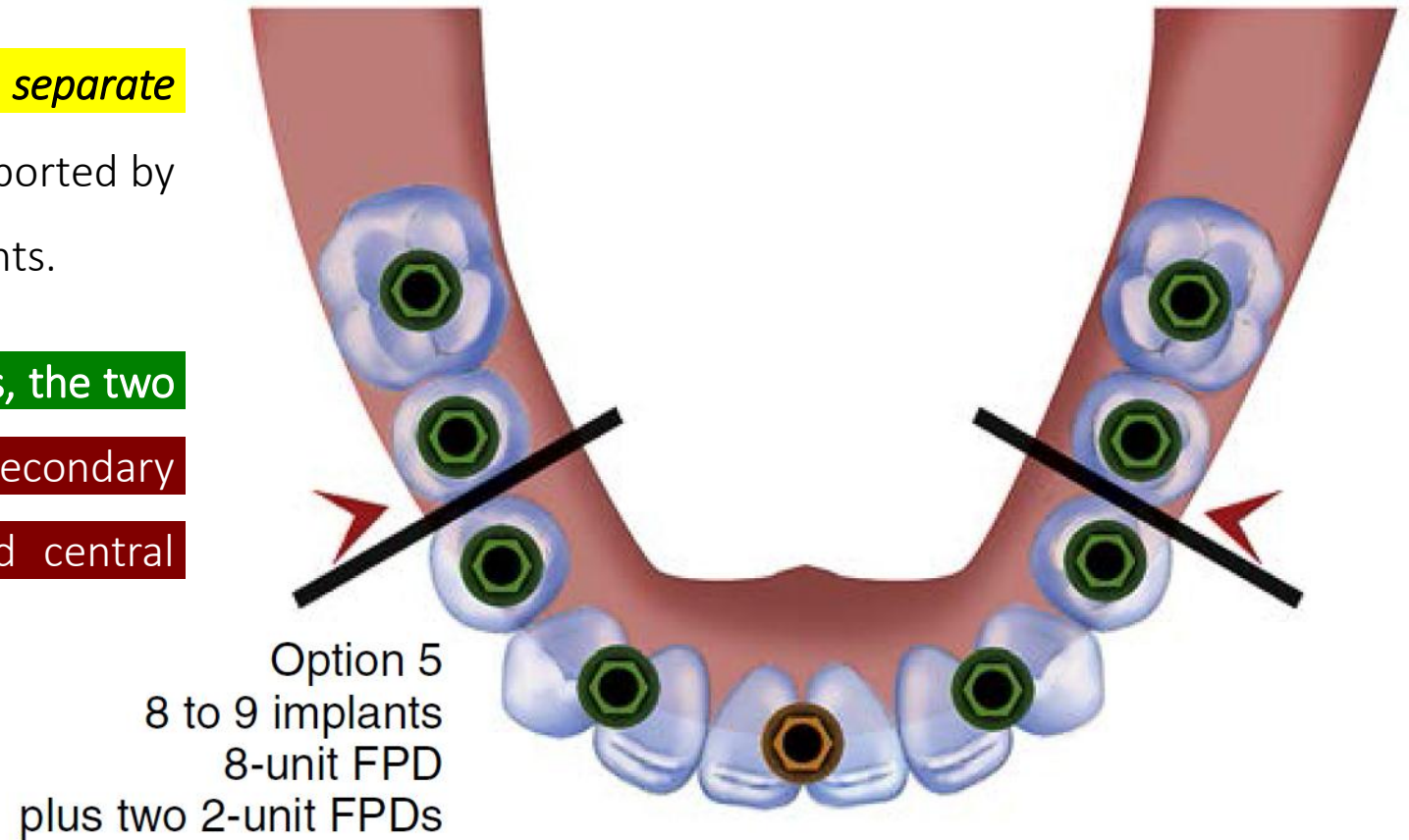
- Higher force factors
- Poor anteroposterior spread
- Poor bone density



Treatment Option 4: Anterior Implants and Bilateral Posterior Implants

Alternative prosthetic design : is for **three separate prostheses**, first premolar to first premolar supported by four or five implants, and two posterior segments.

The key implants are in the two first molar sites, the two first premolar sites, and two canine regions. Secondary positions are the two second premolar and central incisor (midline) sites.



The advantages of this option are smaller segments for individual restorations

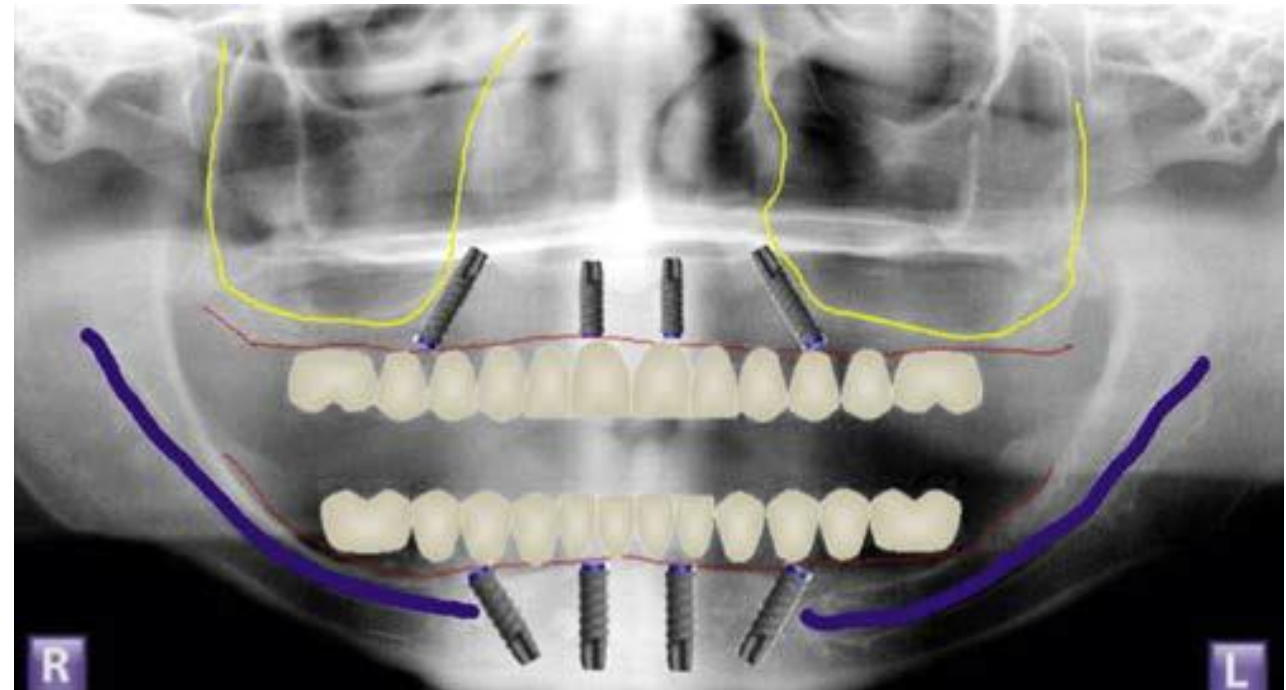
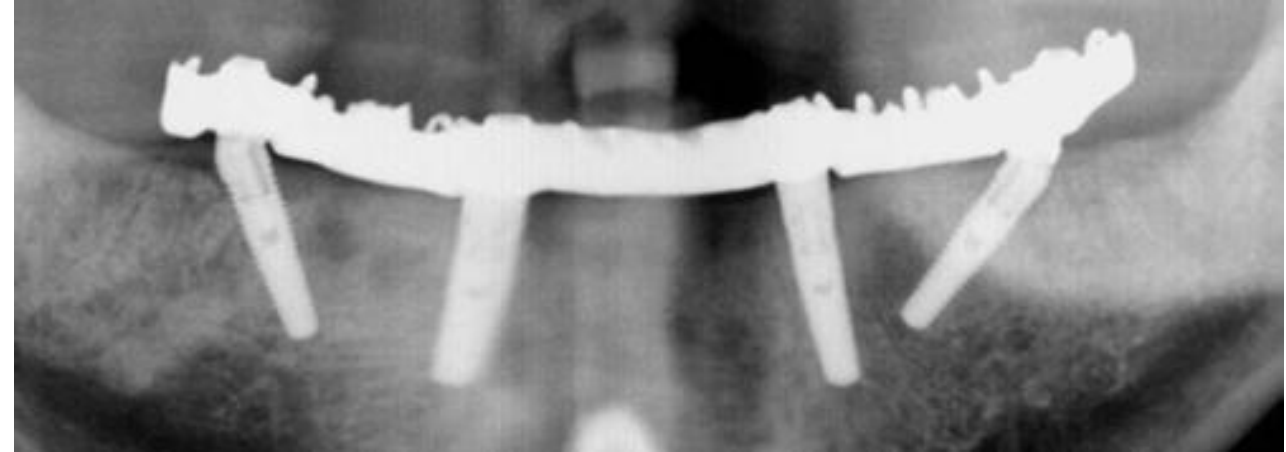


Treatment Option 5: All-on-Four Protocol

The treatment option 5 includes the **"all-on-four"** concept, which was developed to avoid regenerative procedures that potentially increase the treatment costs and patient morbidity.

Two implants are positioned in the anterior and two implants in the posterior at an angle to increase the anteroposterior spread and avoid the mental foramen.

Decreases treatment costs and treatment duration. The literature has shown high survival rates and a low incidence of complications with this procedure



Treatment Option 5: All-on-Four Protocol

Advantages


- Fixed immediate protocol
- Accepted surgical and prosthetic protocol
- Fewer implants, lower costs
- Faster treatment

Disadvantages

- Technically difficult (surgical and prosthetic)
- Complications are difficult to remedy

Indications

- Immediate placement implants
- Immediate loading





Bone Density

Lecture 16

In the early days of oral Implantology the existing bone volume was the primary factor used to develop a treatment plan. ***The internal structure of bone is described in terms of quality or density***, which reflects a number of biomechanical properties, such as **strength** and **modulus of elasticity**. The external and internal architecture of bone controls virtually every facet of the practice of implant dentistry.

The density of available bone is a determining factor in :

- 1- Treatment planning.
- 2- Implant design.
3. Surgical approach.
- 4- Healing time.
- 5- Initial progressive bone loading during prosthetic reconstruction.

The quality of bone is often **dependent on the arch position.**

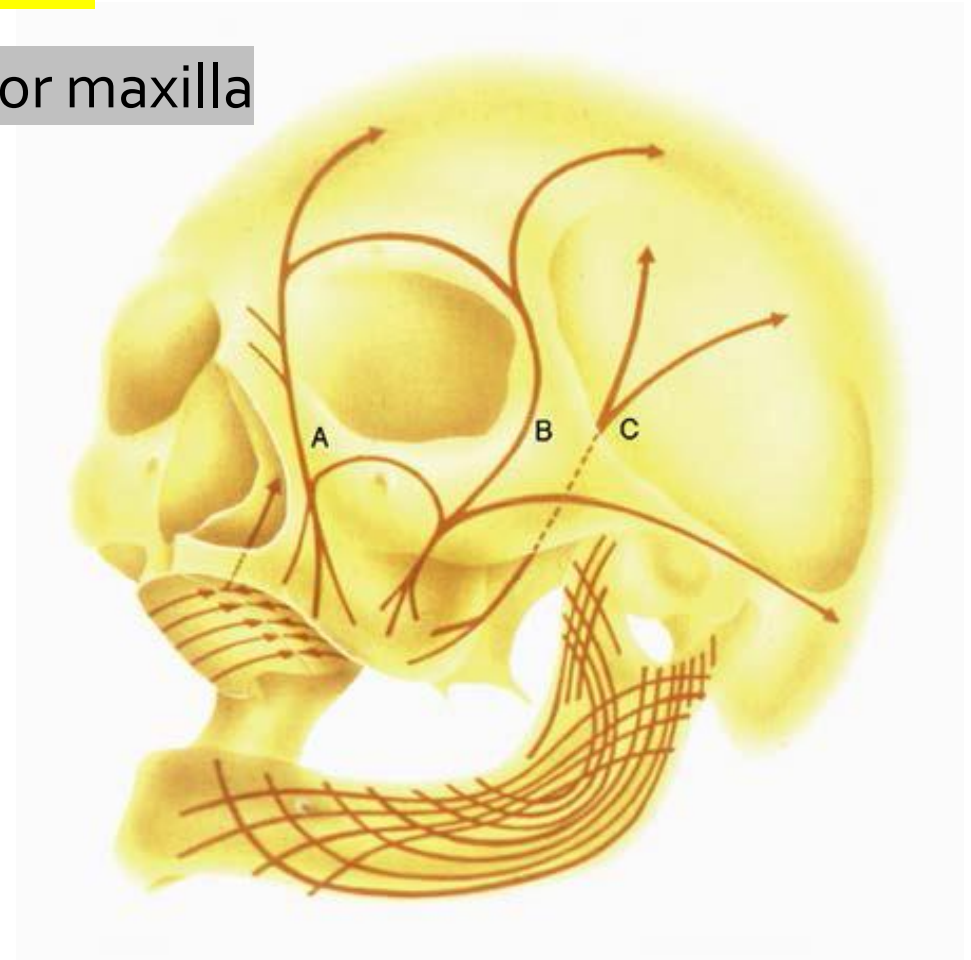
The densest bone is usually observed in the **anterior mandible**

Followed by the **anterior maxilla** and **posterior mandible**

The least dense bone is typically found in the **posterior maxilla**

The maxilla is a force distribution unit, which allows for force to be redirected away from the brain and orbit (A,B,and C).

The mandible is designed to absorb force, thereby forming denser and thick cortical bone and courser trabecular bone.

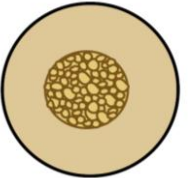

Misch Bone Density Classification

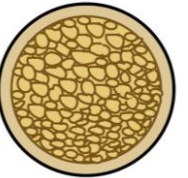Four bone qualities for the anterior region of the jaws:



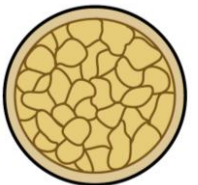Quality 1 is composed of homogenous compact bone.



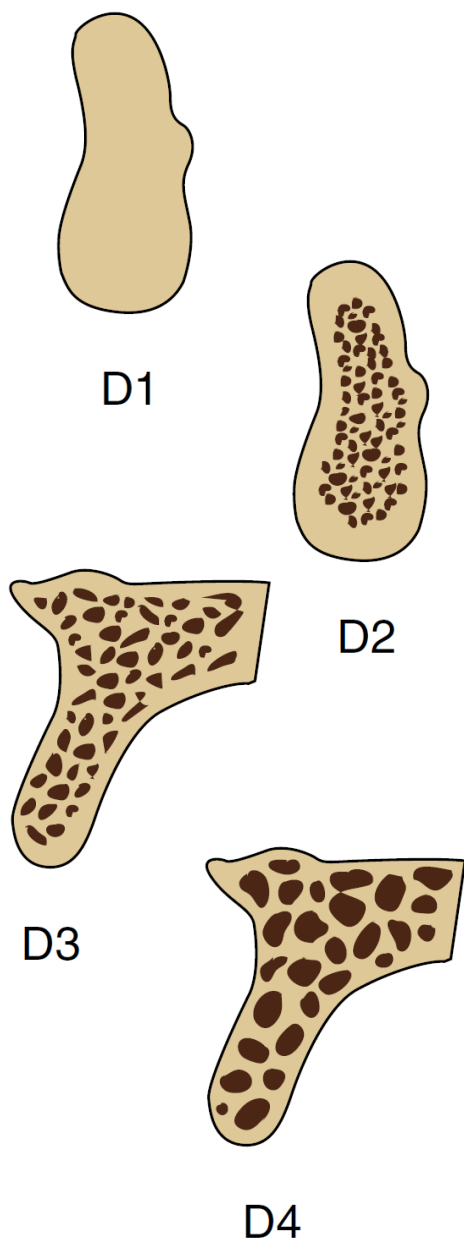
Quality 2 has a thick layer of cortical bone surrounding dense trabecular bone.



Quality 3 has a thin layer of cortical bone surrounded by dense trabecular bone of favorable strength.



Quality 4 has a thin layer of cortical bone surrounding a core of low-density trabecular bone.

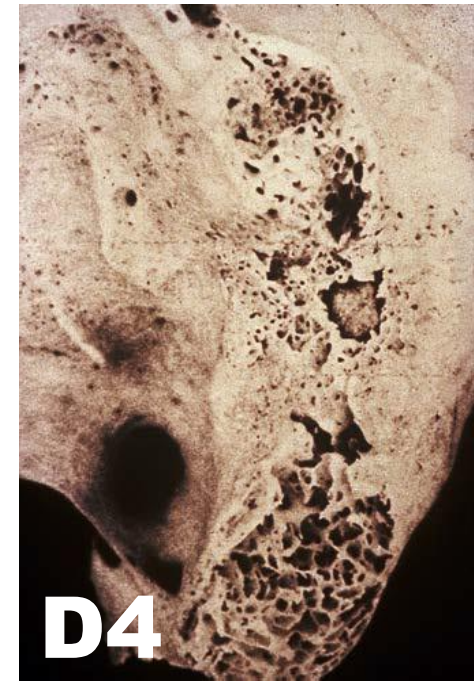
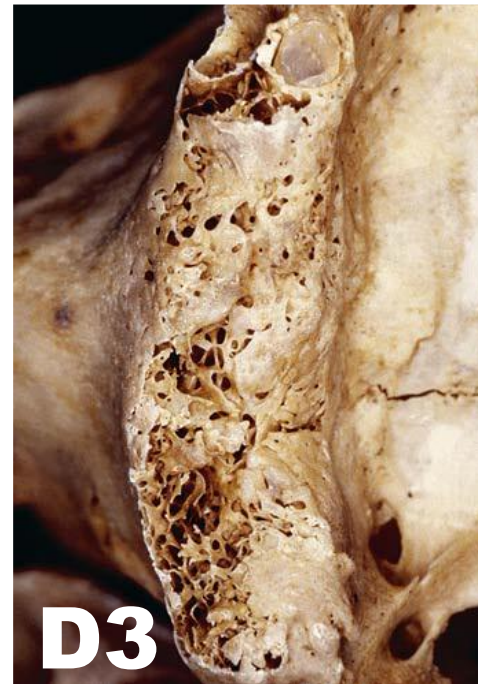
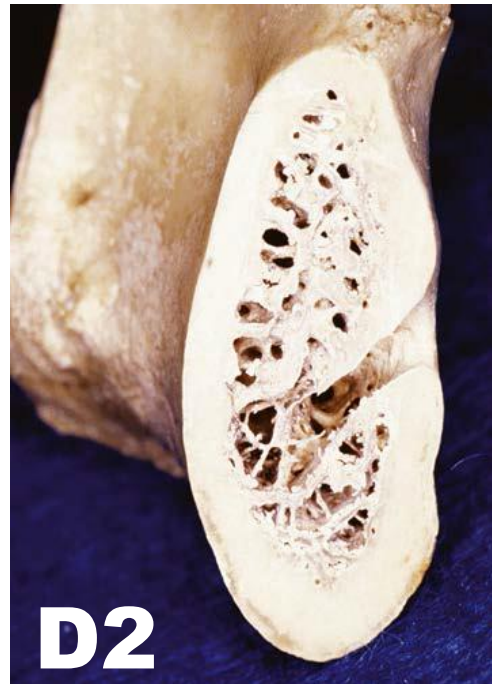
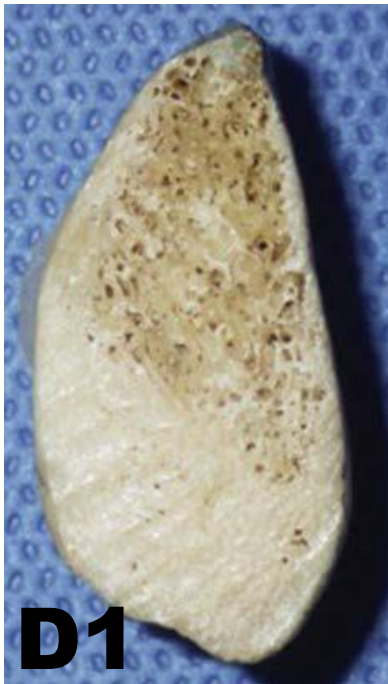Bone Density	Description	Tactile Analog	Typical Anatomic Location
D1	Dense cortical	Oak or maple wood	Anterior mandible
D2	Porous cortical and coarse trabecular	White pine or spruce wood	Anterior mandible Posterior mandible Anterior maxilla
D3	Porous cortical and fine trabecular	Balsa wood	Anterior maxilla Posterior maxilla Posterior mandible
D4	Fine trabecular	Styrofoam	Posterior maxilla Anterior maxilla
D5	Osteoid	Soft Styrofoam	Poorly mineralized bone graft

Determining Bone Density

The bone density may be determined by various techniques including:

- 1- The general location.*
- 2- Radiographic evaluation(CBCT)*
- 3- Tactile sensation, during surgery.*



The general location

Bone	Anterior Maxilla	Posterior Maxilla	Anterior Mandible	Posterior Mandible
D1	0	0	92	8
D2	8	0	66	26
D3	75	22	0	3
D4	38	40	0	22
D5	Immature, poorly mineralized bone graft			

Radiographic evaluation(CBCT)

Periapical or panoramic radiographs are minimally beneficial in determining bone density, because of their two-dimensional nature.

Bone density may be more precisely determined using cone beam computerized tomography (CBCT).

Each pixel in the CT image is assigned a number, also referred to as a Hounsfield or CT number. The CT Hounsfield scale is calibrated such that the Hounsfield unit values are based on water (0 HU) and air (−1000 HU). ***In general the higher the CT number, the denser the tissue.***

Preoperative CT scan data of areas that lead to successful and unsuccessful implant placement have been reported.

In the mandible, failed sites exhibited higher HUs than usual. This was correlated with failure in dense bone, possibly because of the lack of vascularization or overheating during surgery.

By contrast, **in the maxilla** the bone density was low for the failed sites

• **BOX 18.1** CT Determination of Bone Density

D1: >1250 HU

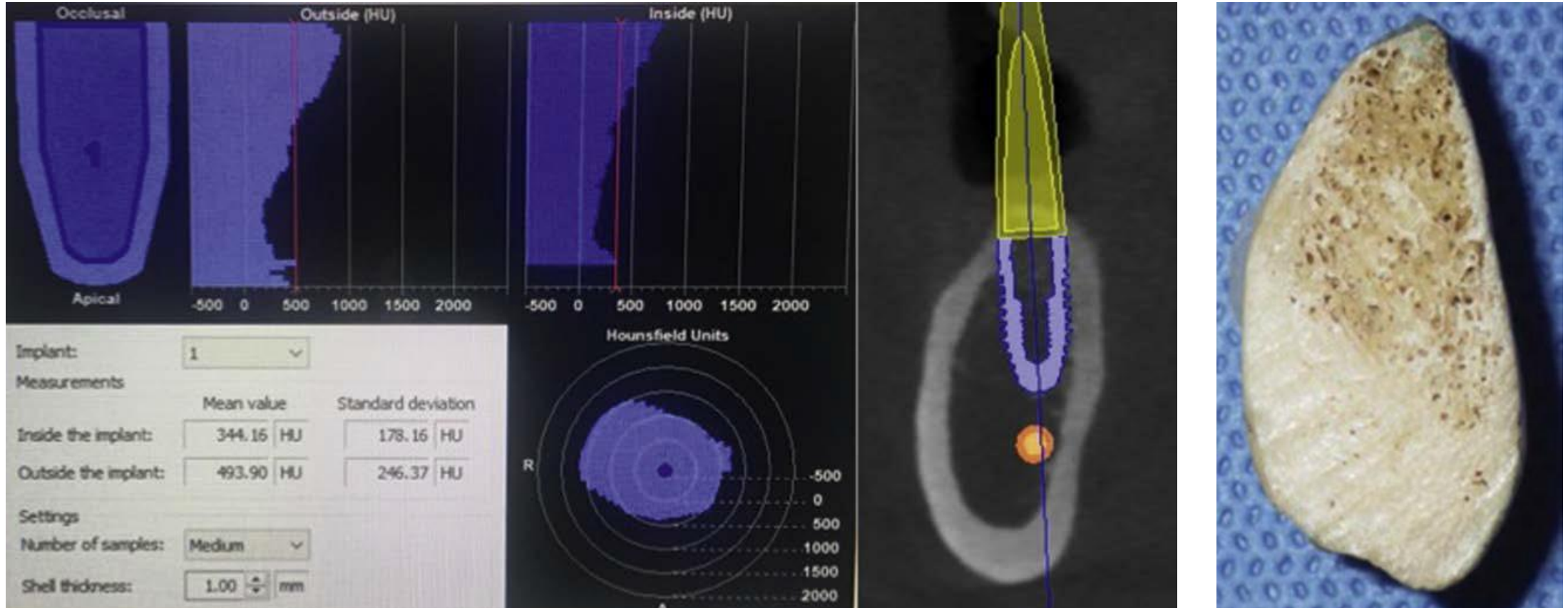
D2: 850 to 1250 HU

D3: 350 to 850 HU

D4: 0 to 350 HU


D5: <0 HU

The bone density may be different near the crest, compared with the apical region where the implant placement is planned. The most critical region of bone density is the **crestal 7 to 10 mm** of bone, because this is where most stresses are applied to an osteointegrated bone–implant interface. Therefore when the bone density varies from the most crestal to apical region around the implant, the crestal 7 to 10 mm determines the treatment-plan protocol



Tactile sensation, during surgery

There is a great difference in the tactile sensation during osteotomy preparation in different bone densities, because the density is directly related to its strength



A close-up photograph of a dental impression model. The model is made of a light-colored, waxy material. Two metal pins are inserted into the wax. The pin on the left is shorter and has a smooth, cylindrical head. The pin on the right is taller and has a wider, textured head. The background shows the intricate details of the wax impression, including a large, dark, circular cavity.

Impression

Lecture 17

Impression copings

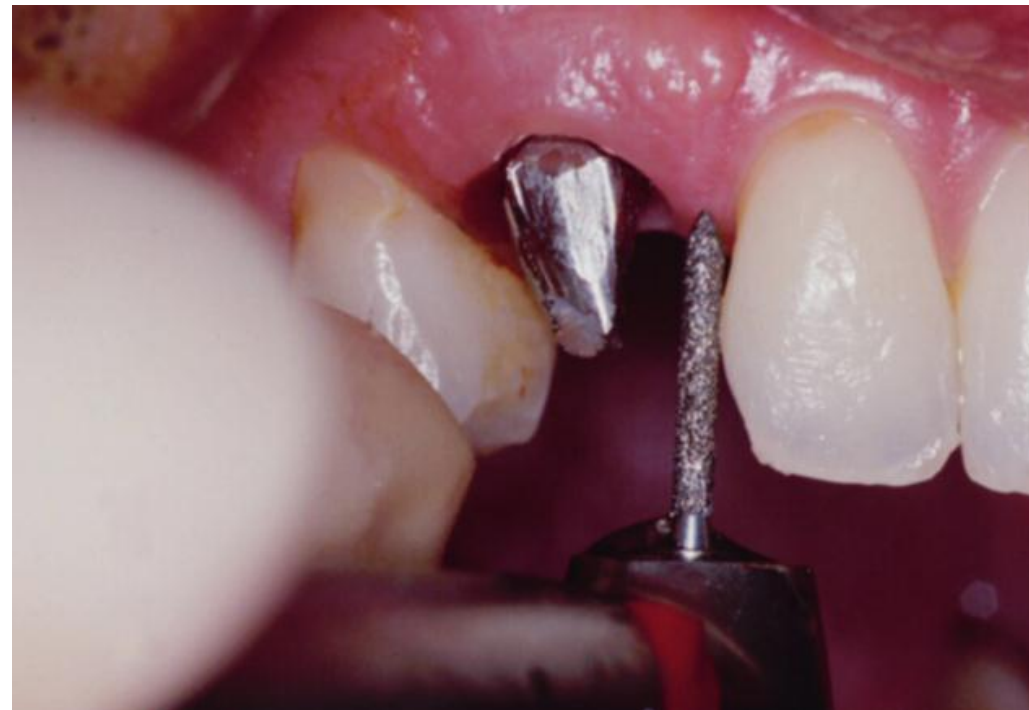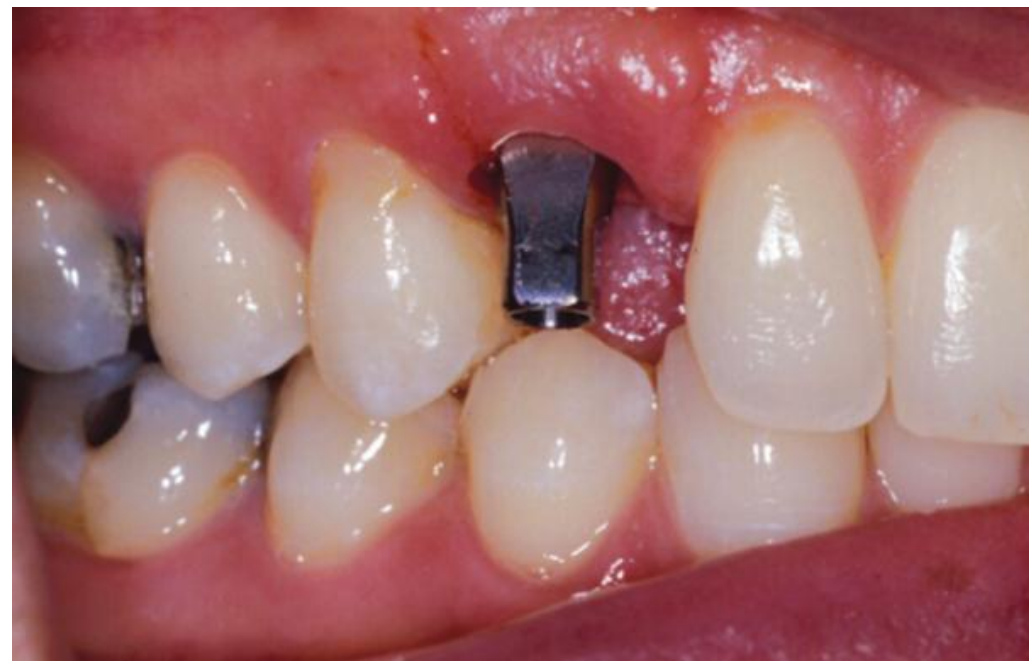Impression copings facilitate transfer of the intraoral location of the implant or abutment to a similar position on the laboratory cast.

Option 1: Direct Technique

The direct crown fabrication technique is most similar to the fabrication of a crown on a natural tooth.

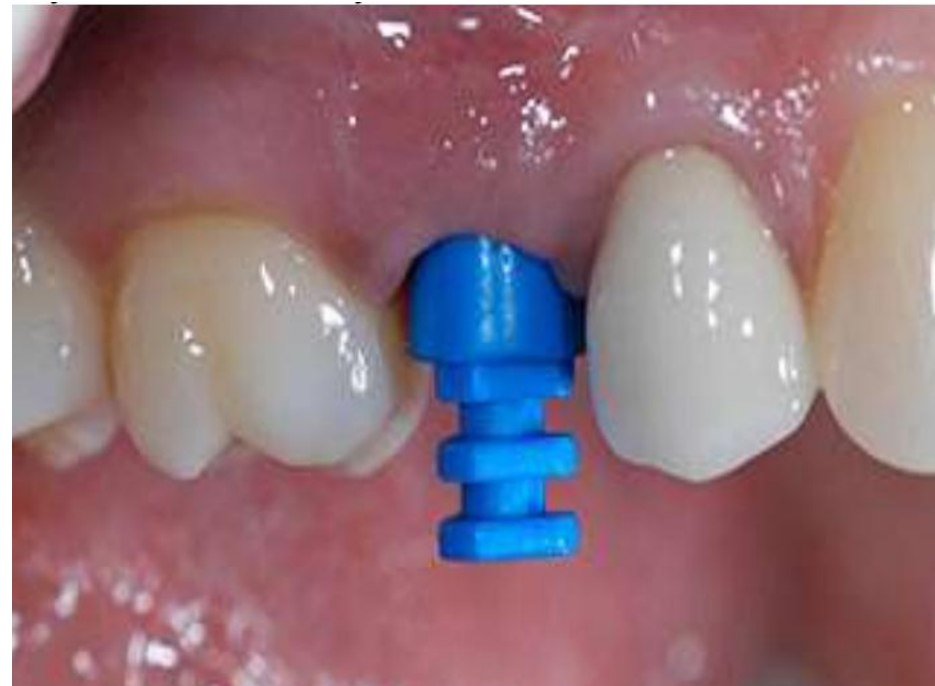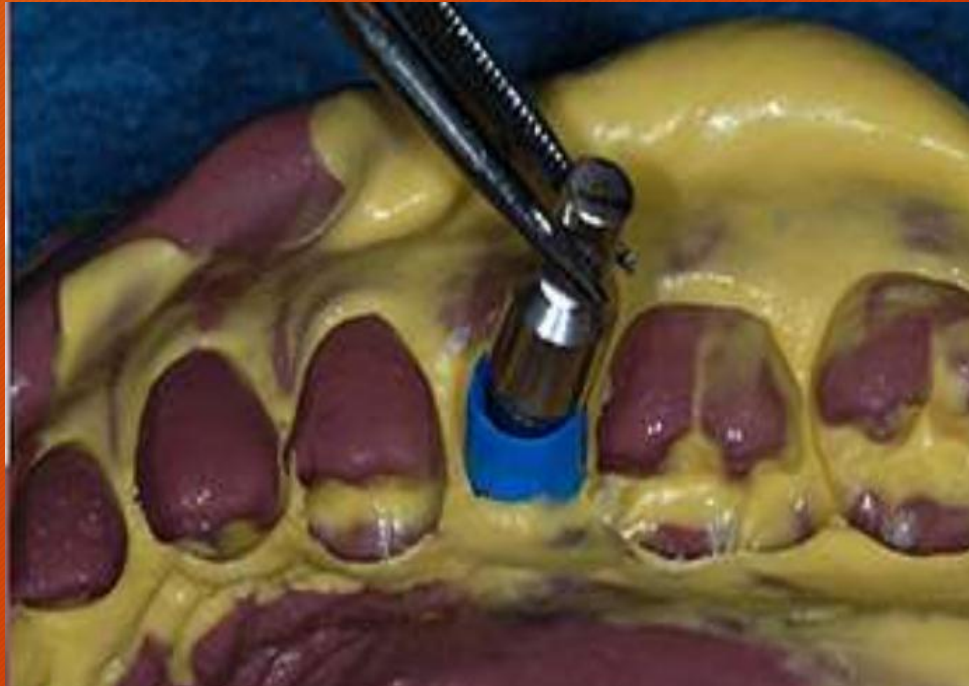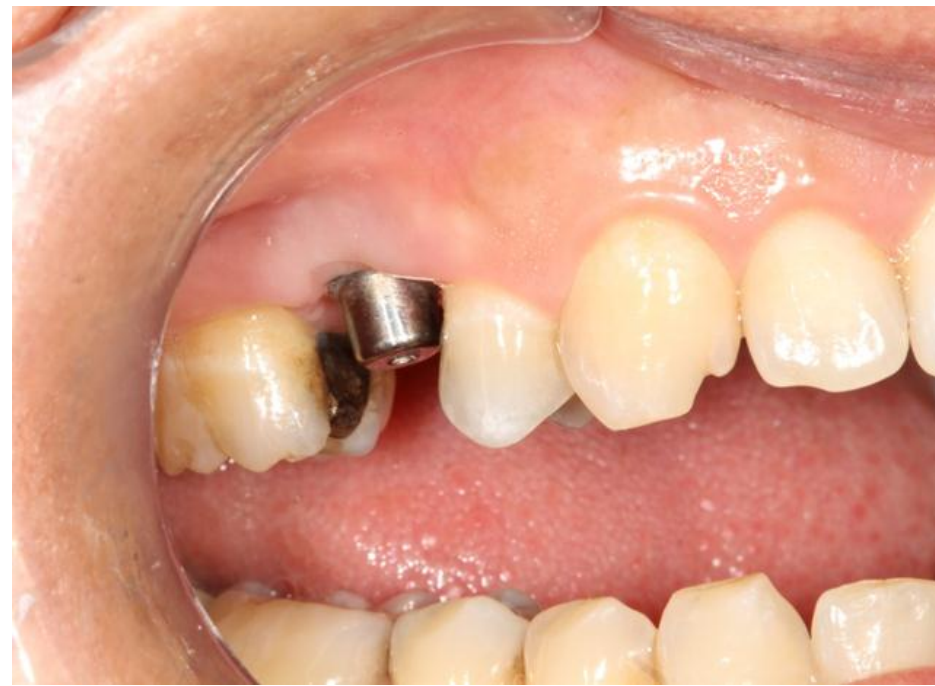The final height of the abutment should be greater than 4 mm in height, when a subgingival margin of 1 mm is used, so a

5-mm minimum abutment height is present for cement retention



Option 1: Direct Technique

The facial contour is concave and the mesial and distal subgingival contour is convex in final crown.



Option 2: Indirect Technique: Close Tray

A standard transfer impression coping is a sleeve that matches the implant diameter. A screw penetrates through its center.

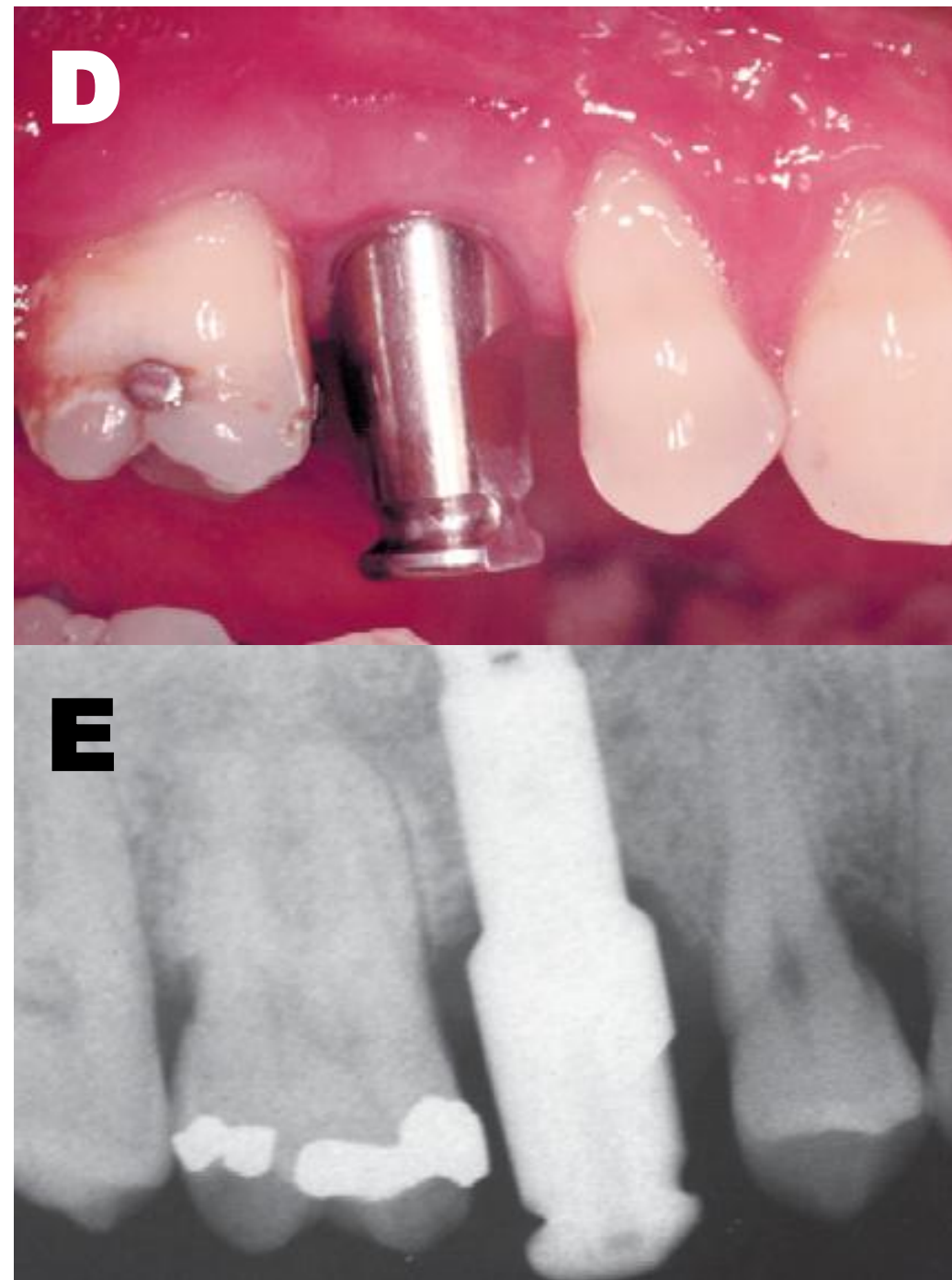
B, The screw can be placed through the impression coping sleeve and carried to the mouth with the standard hex driver



Option 2: Indirect Technique: Close Tray

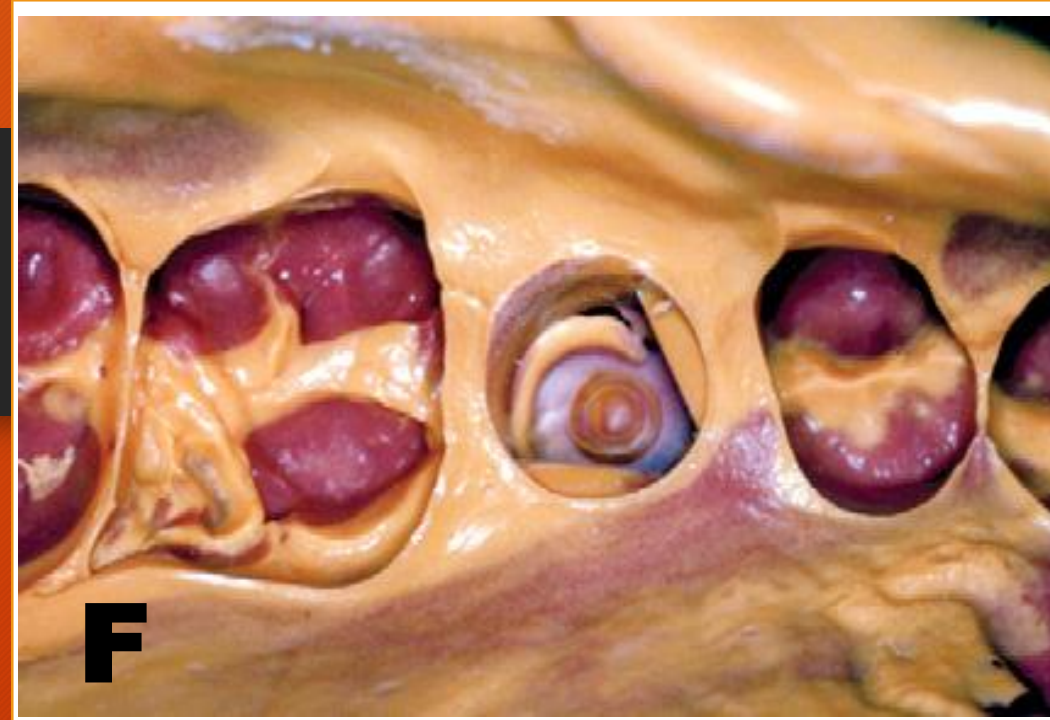D, Impression coping seated into the implant.

E, Radiograph confirming complete seating.



Option 2: Indirect Technique: Close Tray

F, Complete impression, clearly showing flat sides.



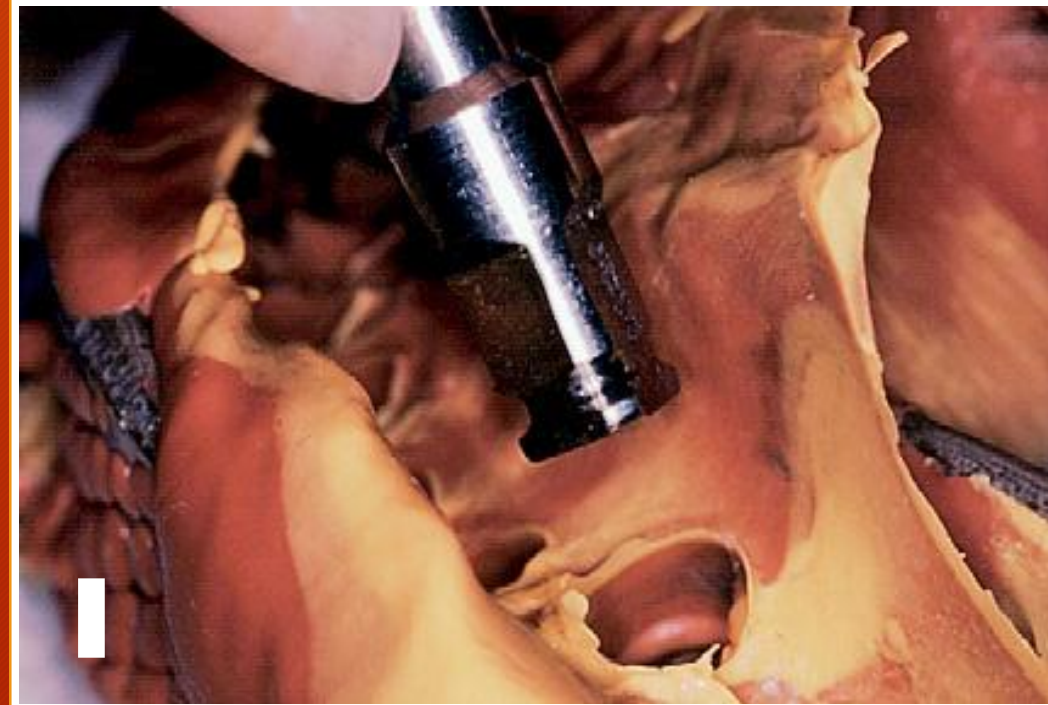G, Implant analog corresponding to the size of the implant.



Option 2: Indirect Technique: Close Tray

H, Impression coping removed from the mouth and attached to an implant analog.

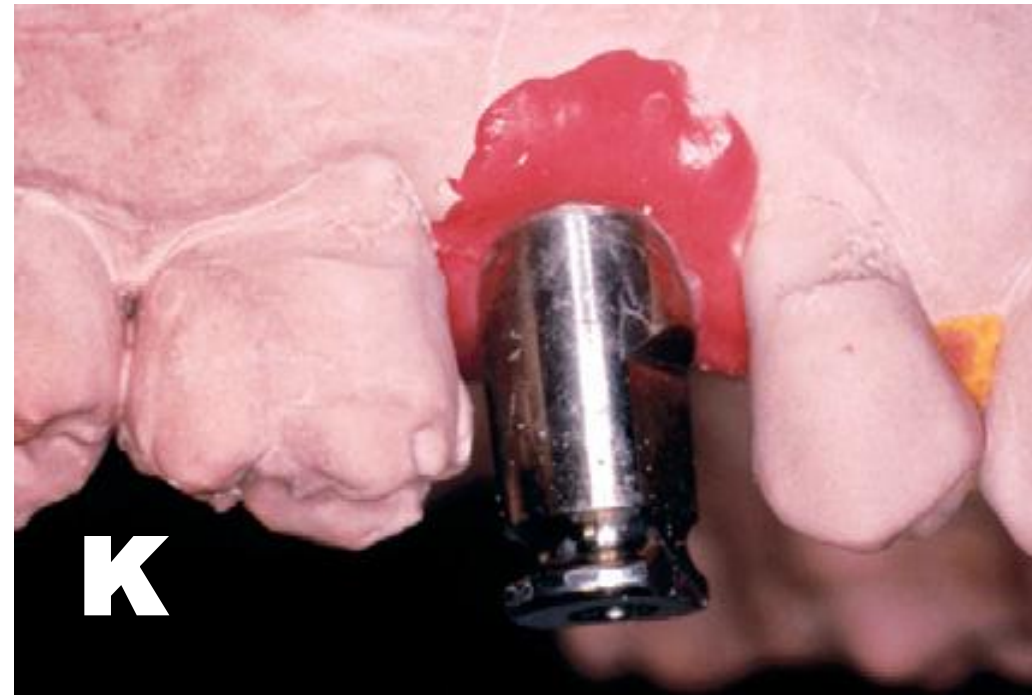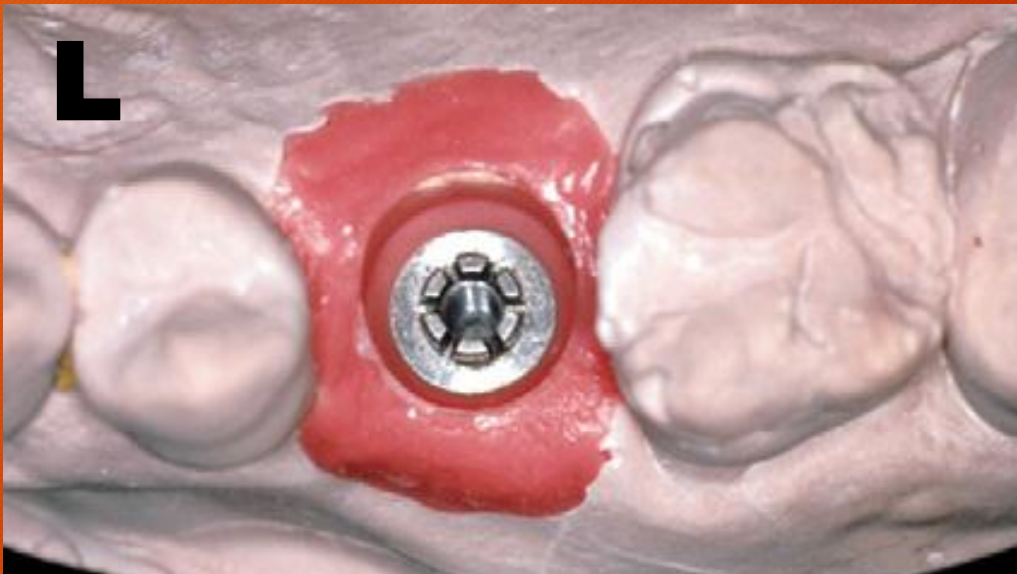
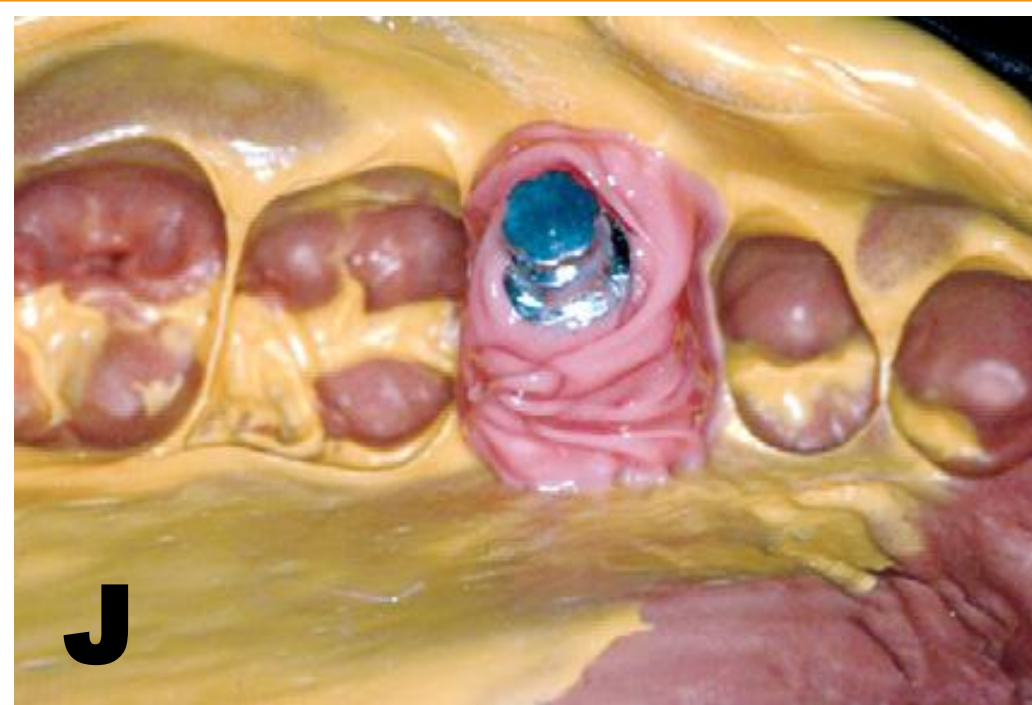I, Impression coping/analog complex inserted into the impression with flat sides properly oriented.



Option 2: Indirect Technique: Close Tray

J, Polyether impression material injected around the complex before pouring

K and L, Impression coping orients the implant analog to the cast as the implant body is positioned in the mouth.



Option 2: Indirect Technique: Open Tray

More accurate.

Need more space so some times it is difficult to be used in posterior implants in limited mouth opening patients.



Closed Tray



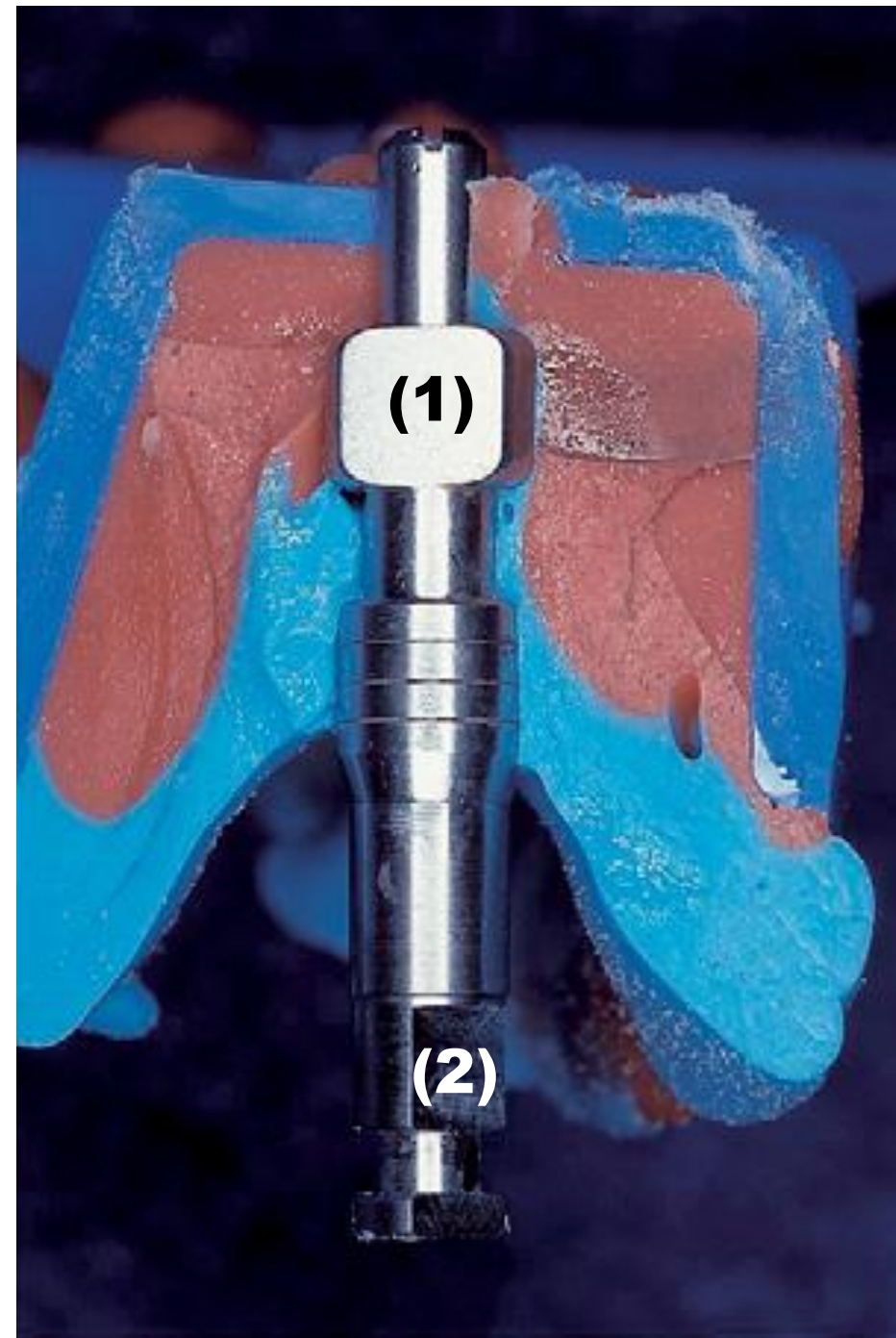
Open Tray

Option 2: Indirect Technique: Open Tray

Cross-sectional view of

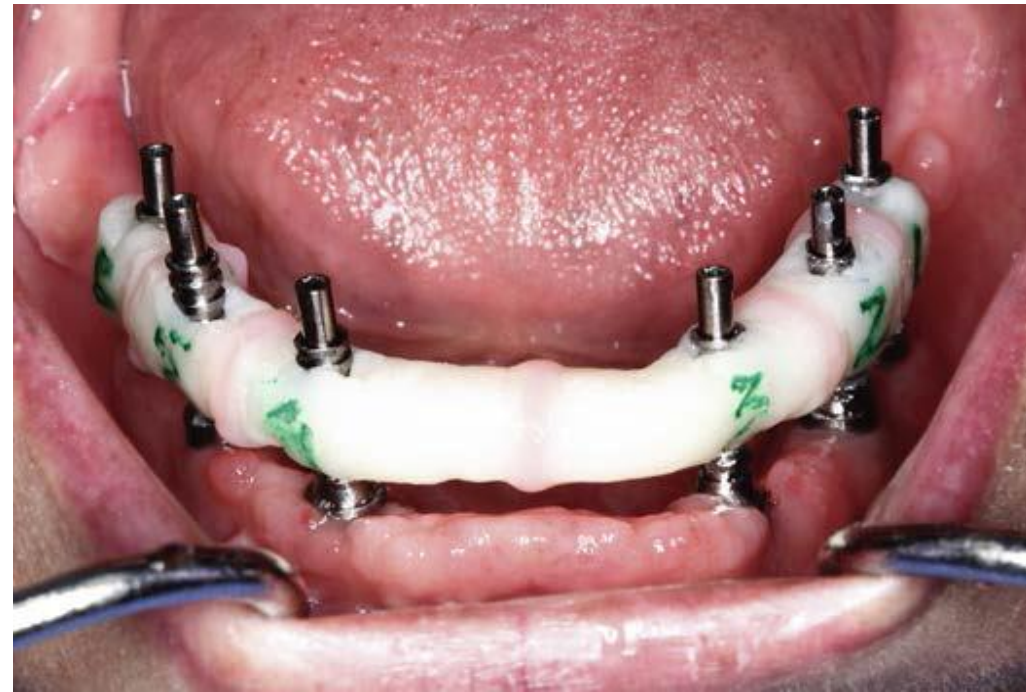(1) the impression coping and screw with the
implant analog

(2) attached. The impression coping remains
within the impression material.



Option 2: Indirect Technique:

Individual sections of the laboratory-provided implant verification jig are connected to the multiunit abutments and luted together, ensuring an accurate recording of the interimplant positions in the final impression.





Abutment **S**election **P**inciples

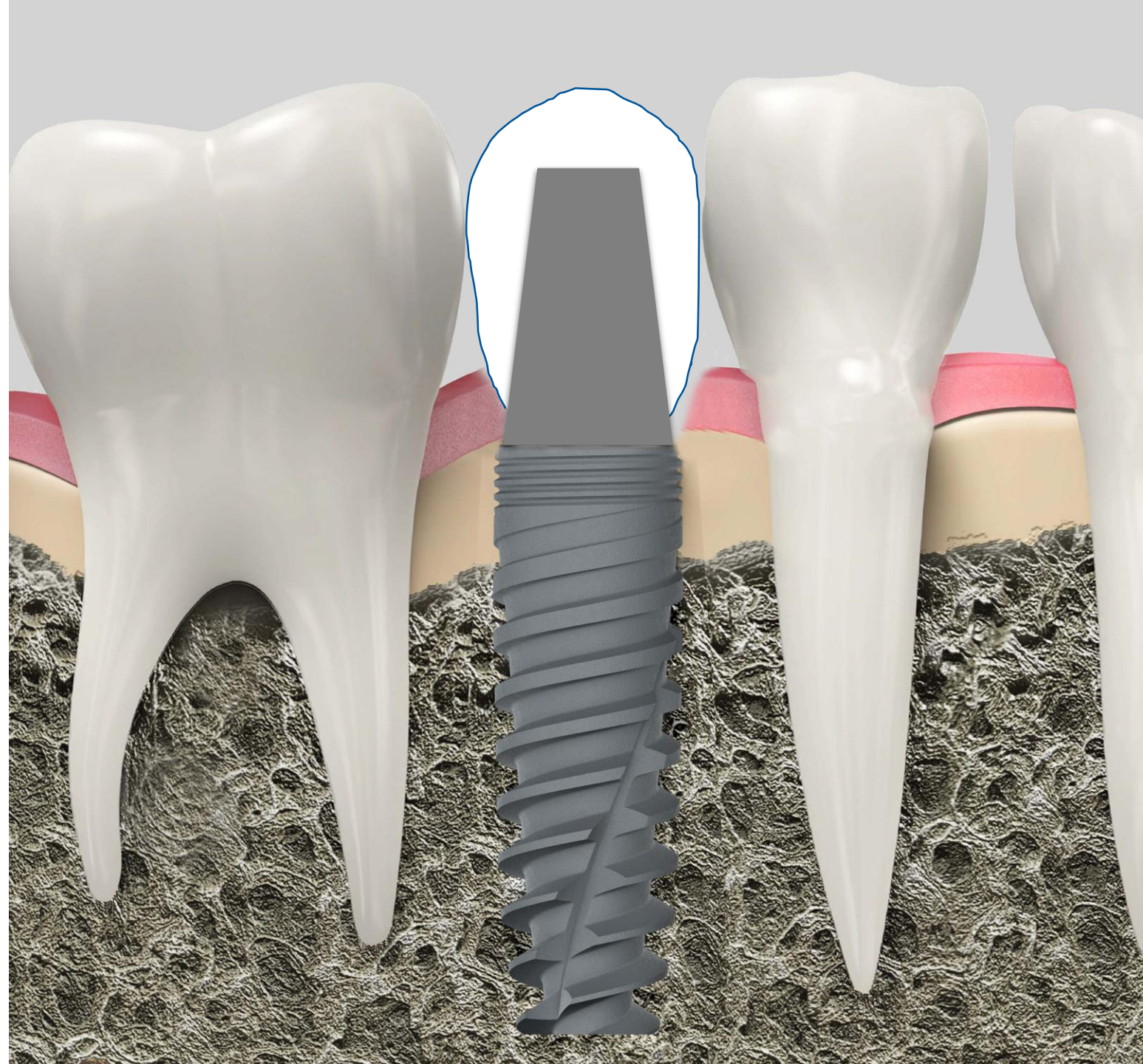
Prefabricated

A. Same size or smaller diameter than implant:

- One size of abutment may be used for almost all patients.
- Minimal preparation is required if the implant is not in ideal position (i.e., too close to a tooth or facial position)



- The margin of the crown may be a knife edge and may be placed anywhere on the abutment.
- The soft tissue is thicker, so a grayish line below the crown is less observed.

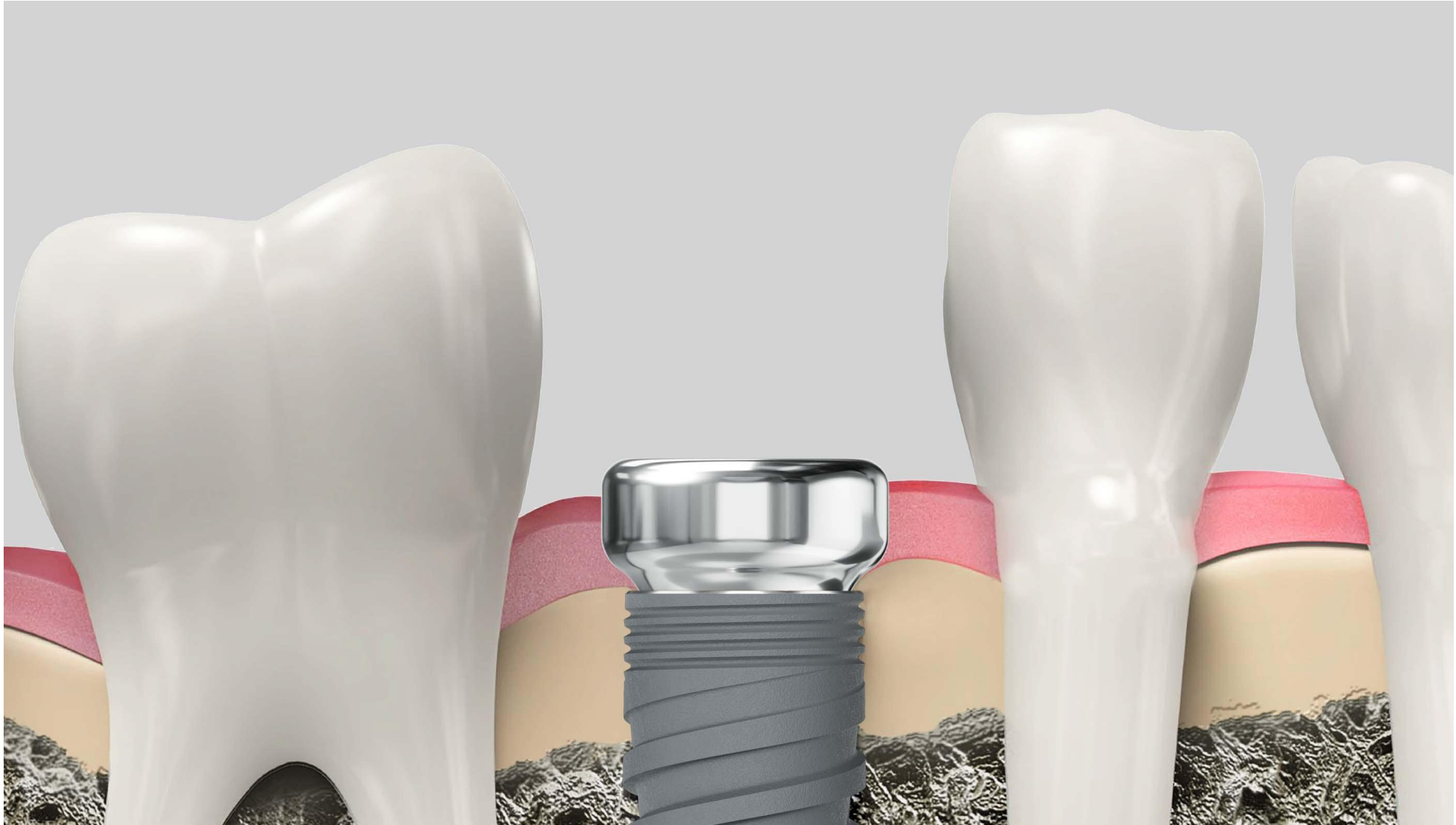

Prefabricated

B. 1-2mm flare wider than implant:

- The wider cervical region improves the emergence profile of the soft tissue starting 1 to 2 mm above the bone.
- The wider abutment also provides a greater surface area for retention
- The accuracy of fit of the premade implant–abutment interface decreases the force to the abutment screw and reduces the risk of abutment screw loosening.





Straight Abutment + Gingival Haught



1mm

2mm

3mm

4mm

5mm

Ø6

Ø6

Ø6

Ø6

Ø6

PAD60GH1M18

PAD60GH2M18

PAD60GH3M18

PAD60GH4M18

PAD60GH5M18

Anguled Abutment + Gingival Haught



Height 9.0mm
Collar 1.0mm
Degrees 25°



H 10.0mm
C 2.0mm
D 25°



H 11.0mm
C 3.0mm
D 25°



H 12.0mm
C 4.0mm
D 25°

Angulated Abutment + Gingival Haught



7.5° Angulated
Abutment



15° Angulated
Abutment



22.5° Angulated
Abutment

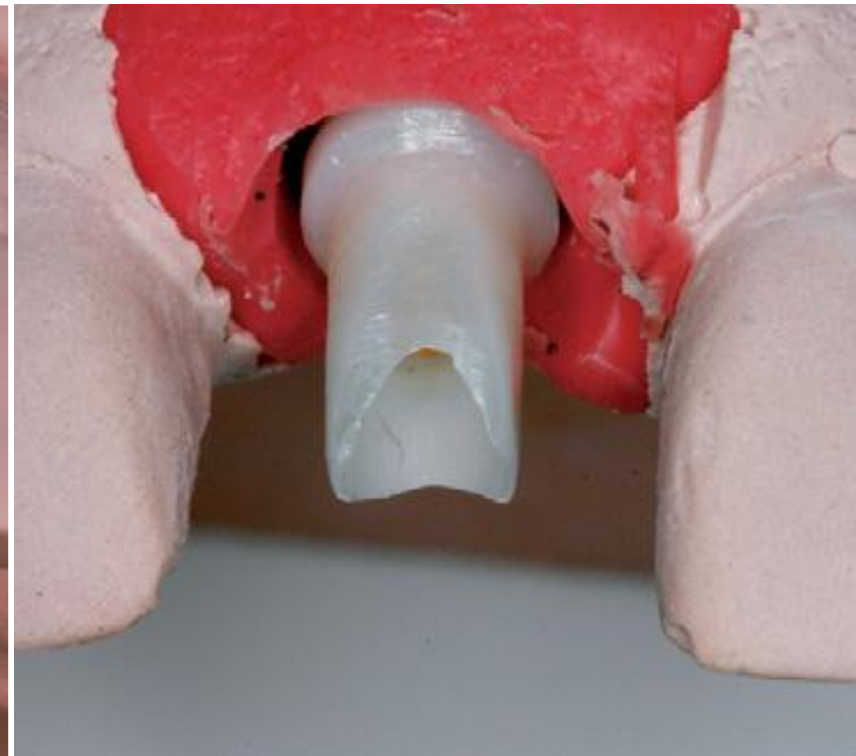
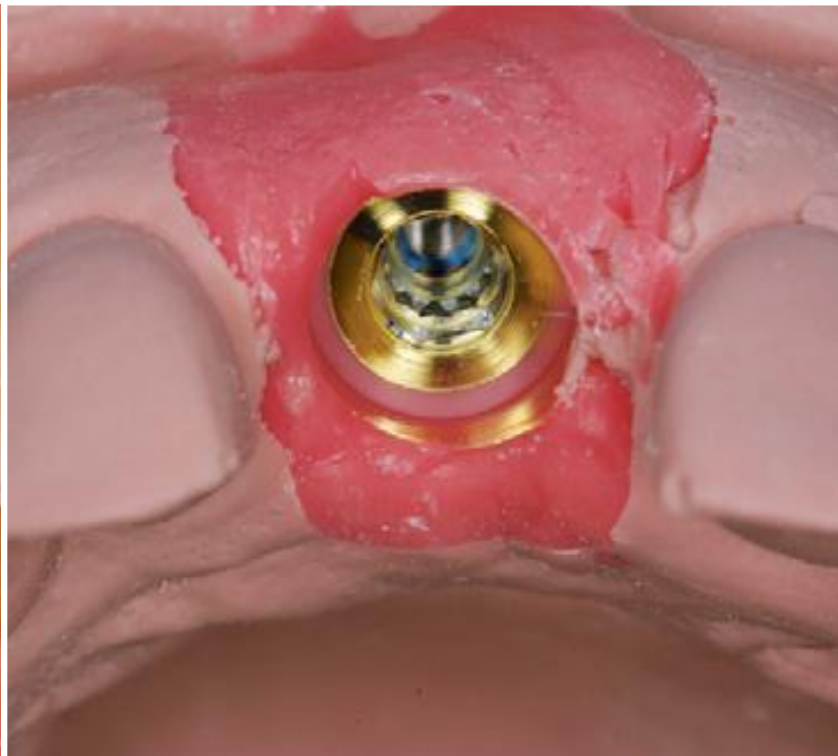
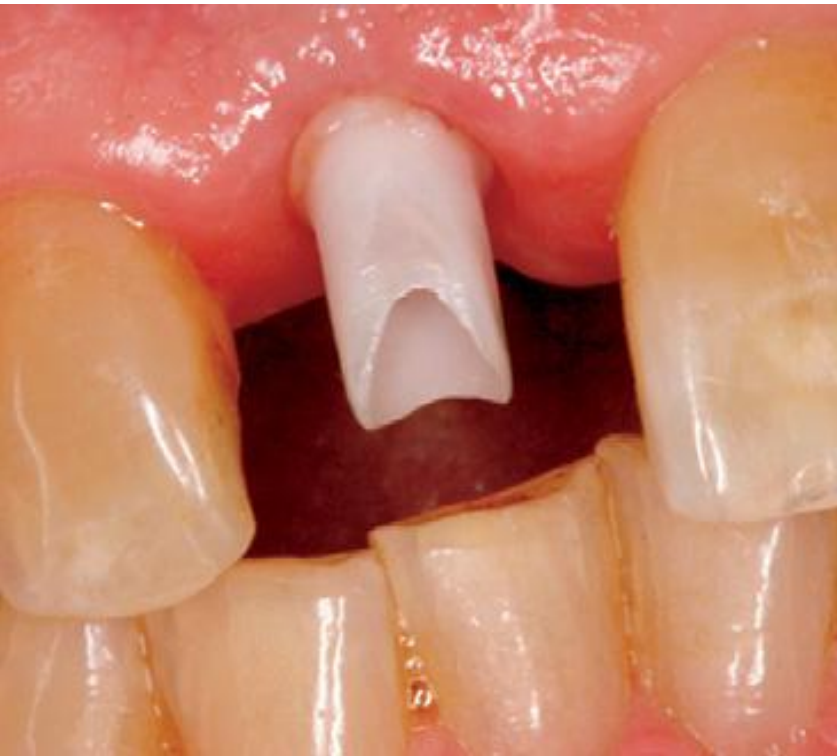

30° Angulated
Abutment

Prefabricated

C. Ceramic Abutments

The ceramic premade abutments are usually white in color . Aesthetic area consideration.

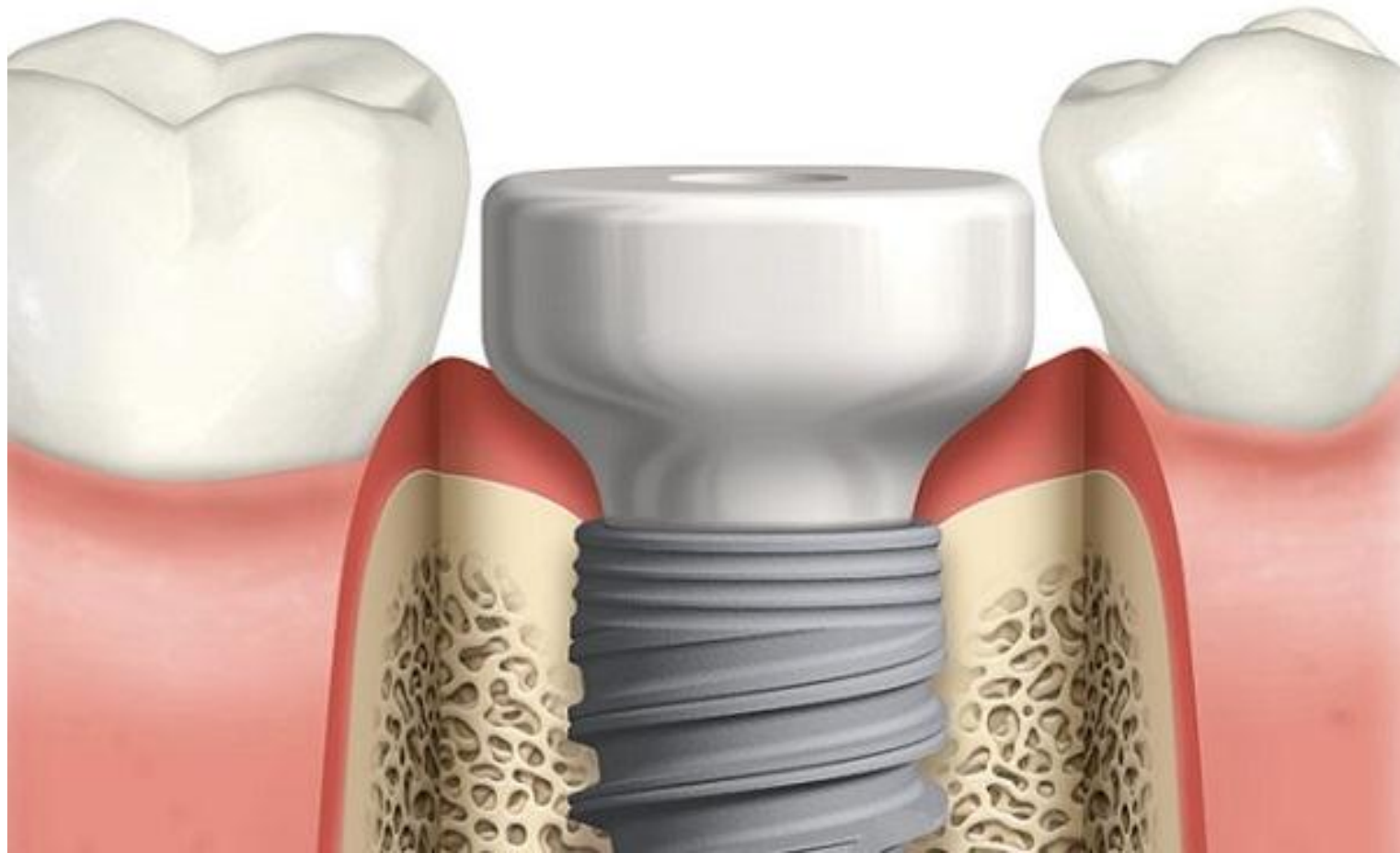


Customized Abutments

Laboratory-customized anatomical or esthetic abutments.

Fabricated for each specific patient condition.






**Anterior thick
gingiva**

**Molars with deep
gingiva**

**Anterior thin
gingiva**


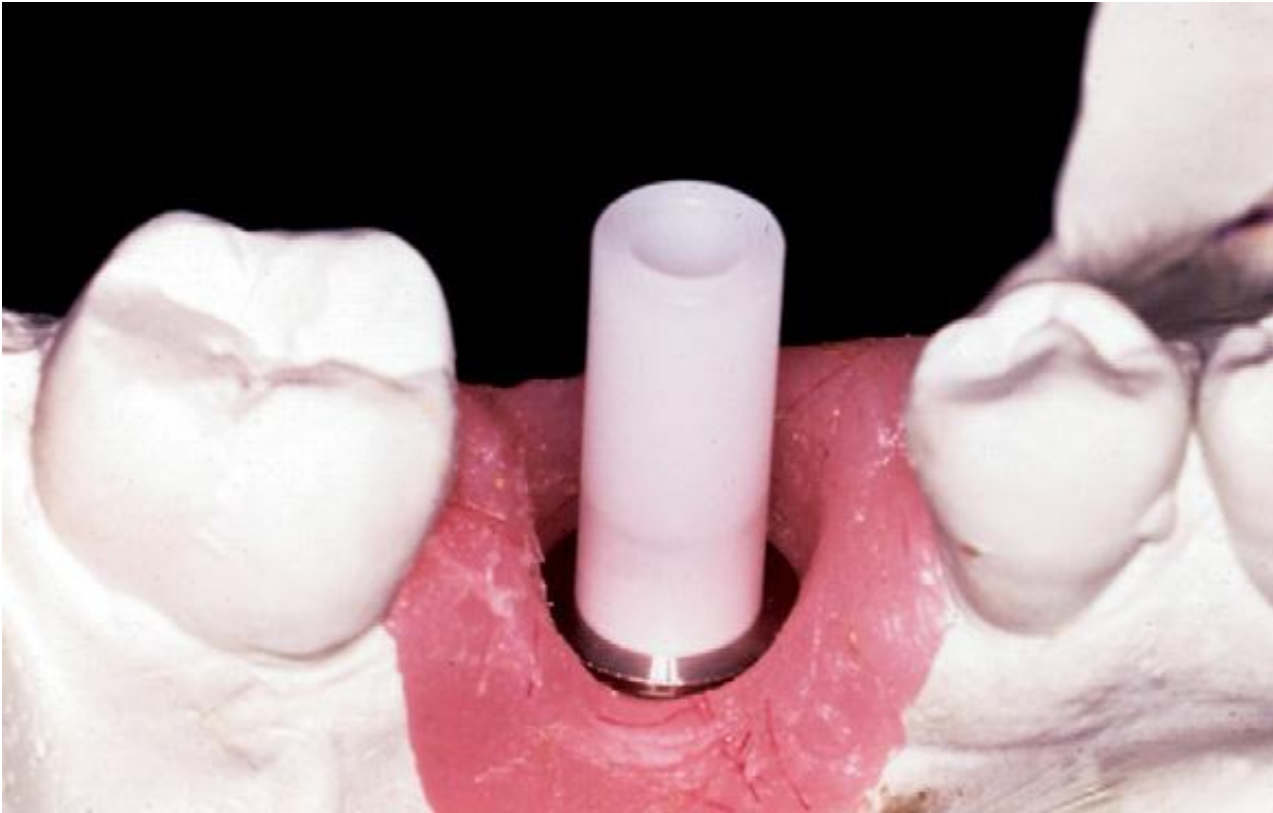
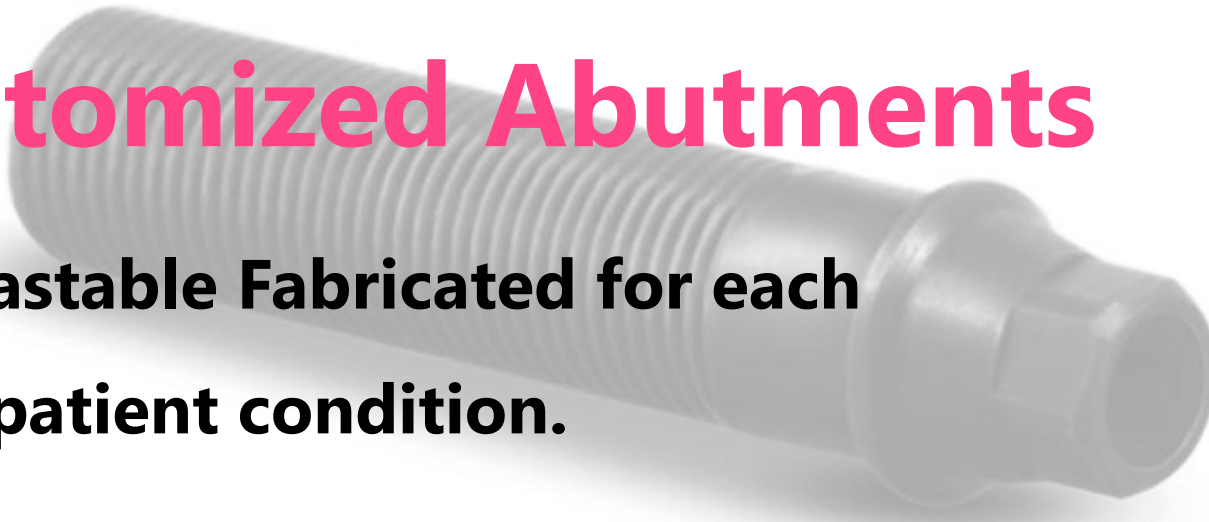
**For premolar
normal gingiva**

For premolar deep gingiva



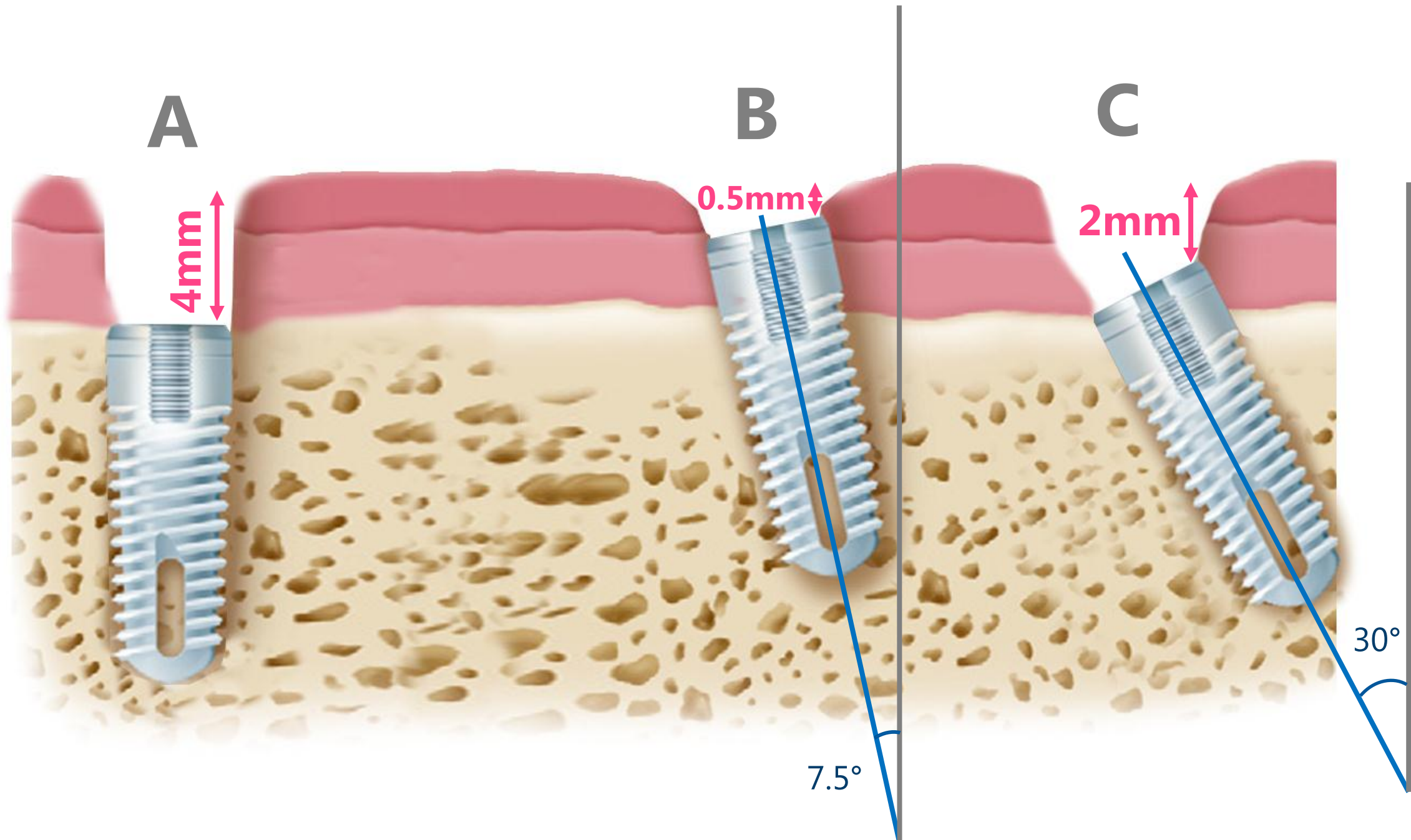
Customized Abutments

Plastic castable Fabricated for each specific patient condition.



MULTIUNIT ABUTMENTS WITH SCREWS





IMPLANT RESTORATION

LECTURE 19

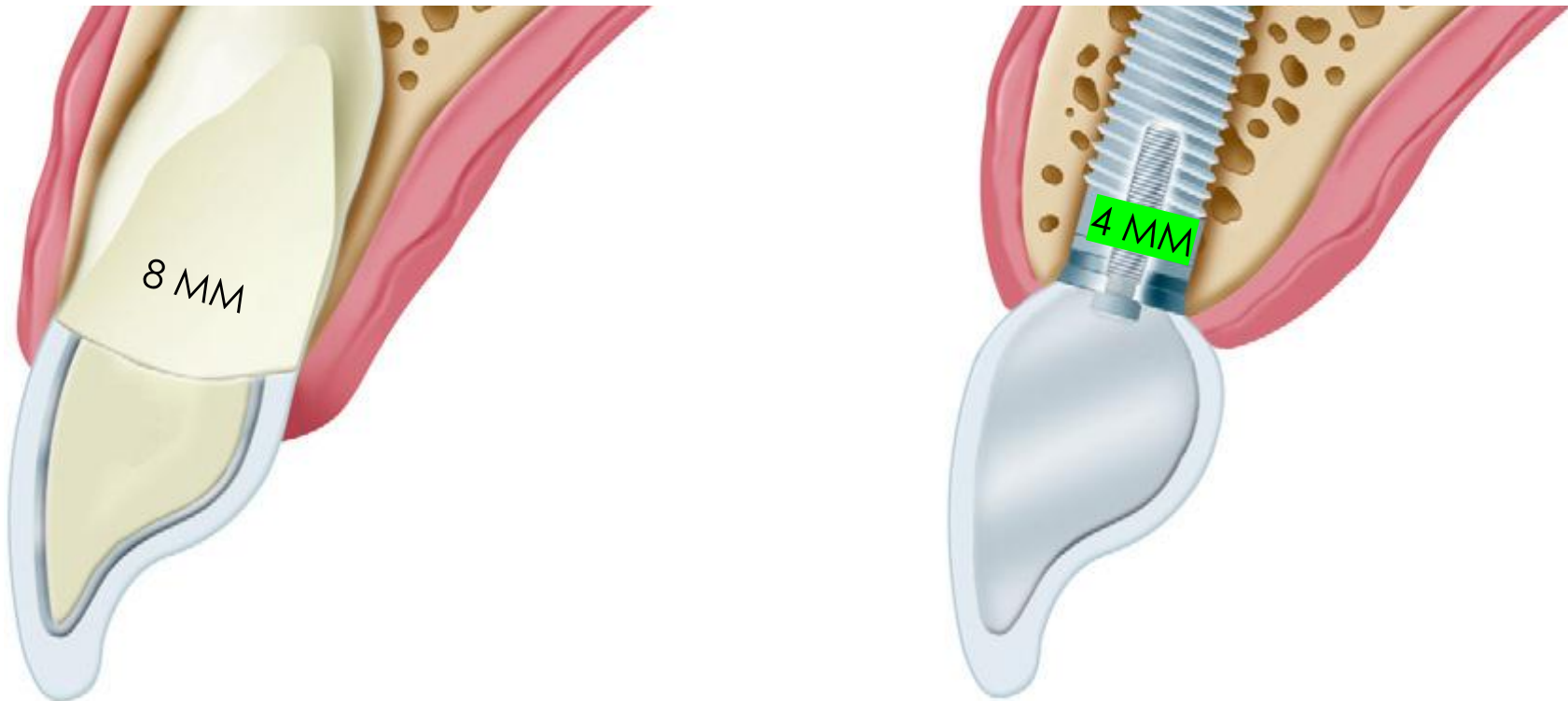
PLANING

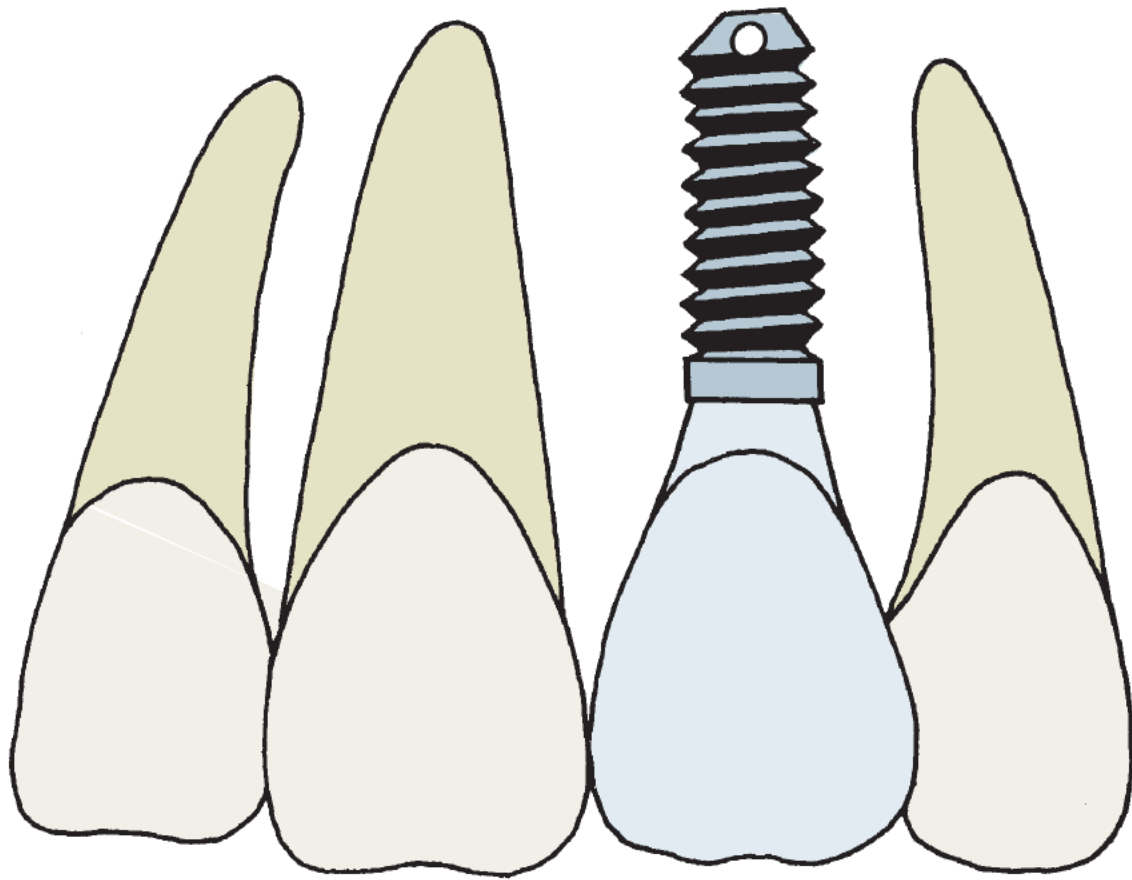
Restoration size must always be considered during the treatment planning stage so that a properly sized implant is placed in the ideal location.

The final restoration appears similar in size and contour to most traditional FPs used to restore or replace natural crowns of teeth

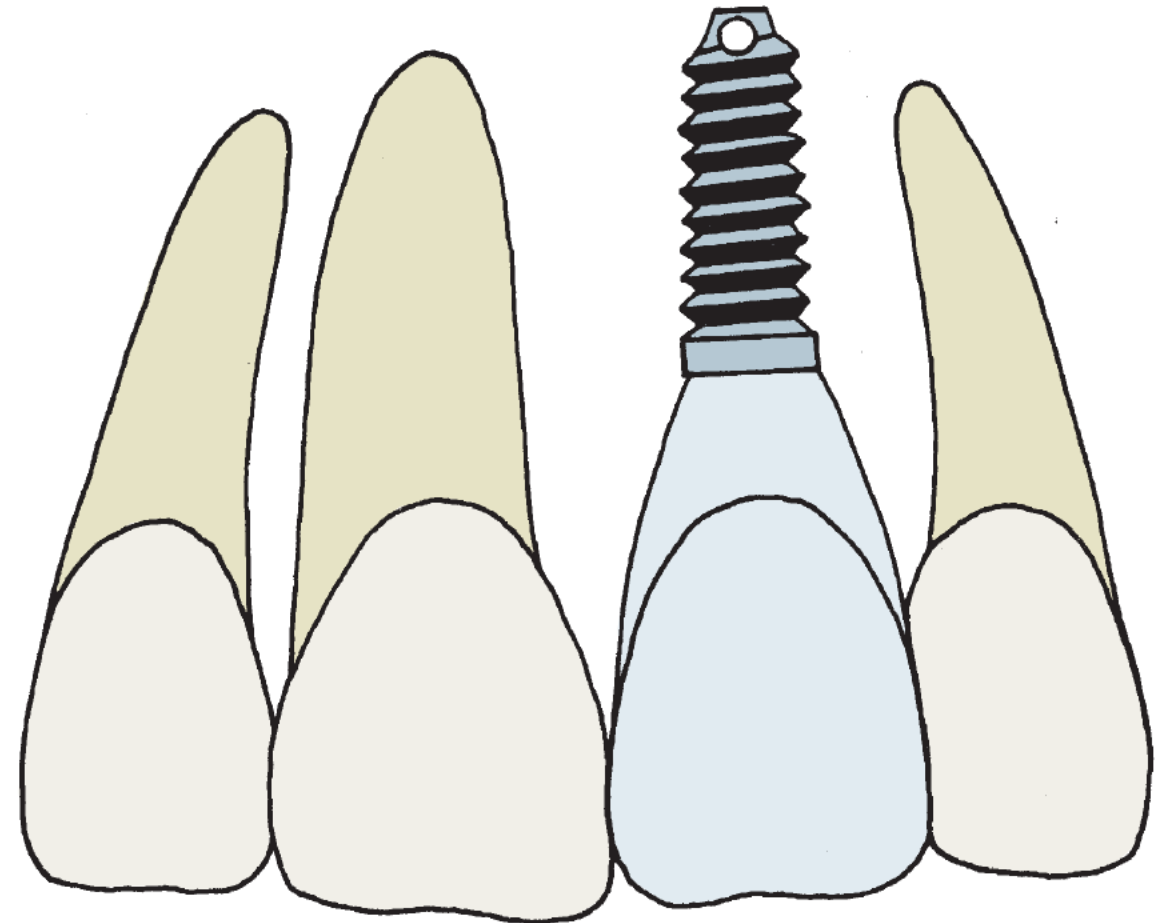
IMPLANT & RESTORATION SIZE

THE CHOICE OF IMPLANT AND ITS SUPEROINFERIOR PLACEMENT LOCATION ARE MODIFIED BY THE DIAMETER OF THE INTENDED RESTORATION AND CAN BE ADJUSTED FOR DIFFERENT SIZES OF TEETH.

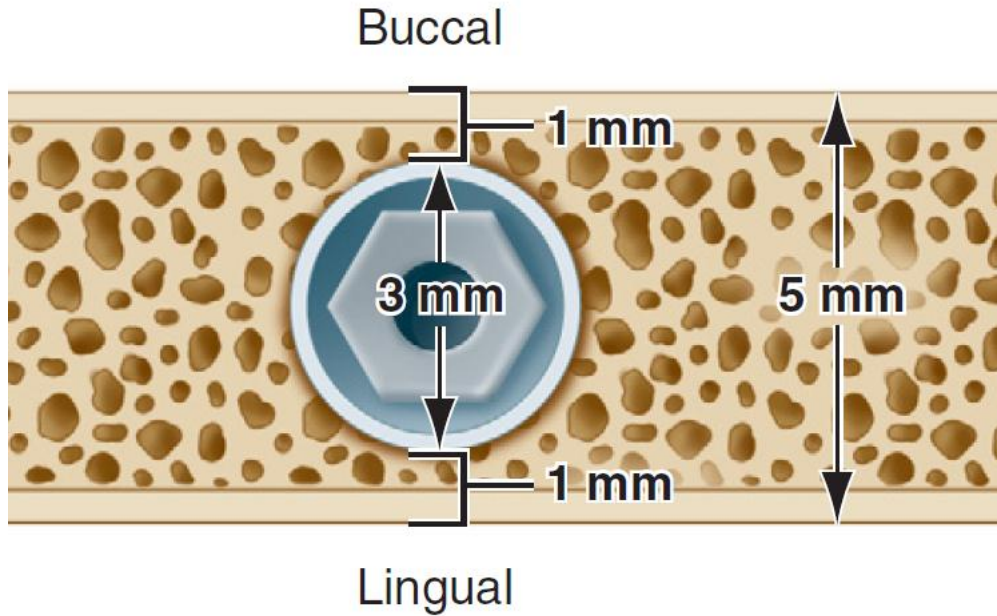




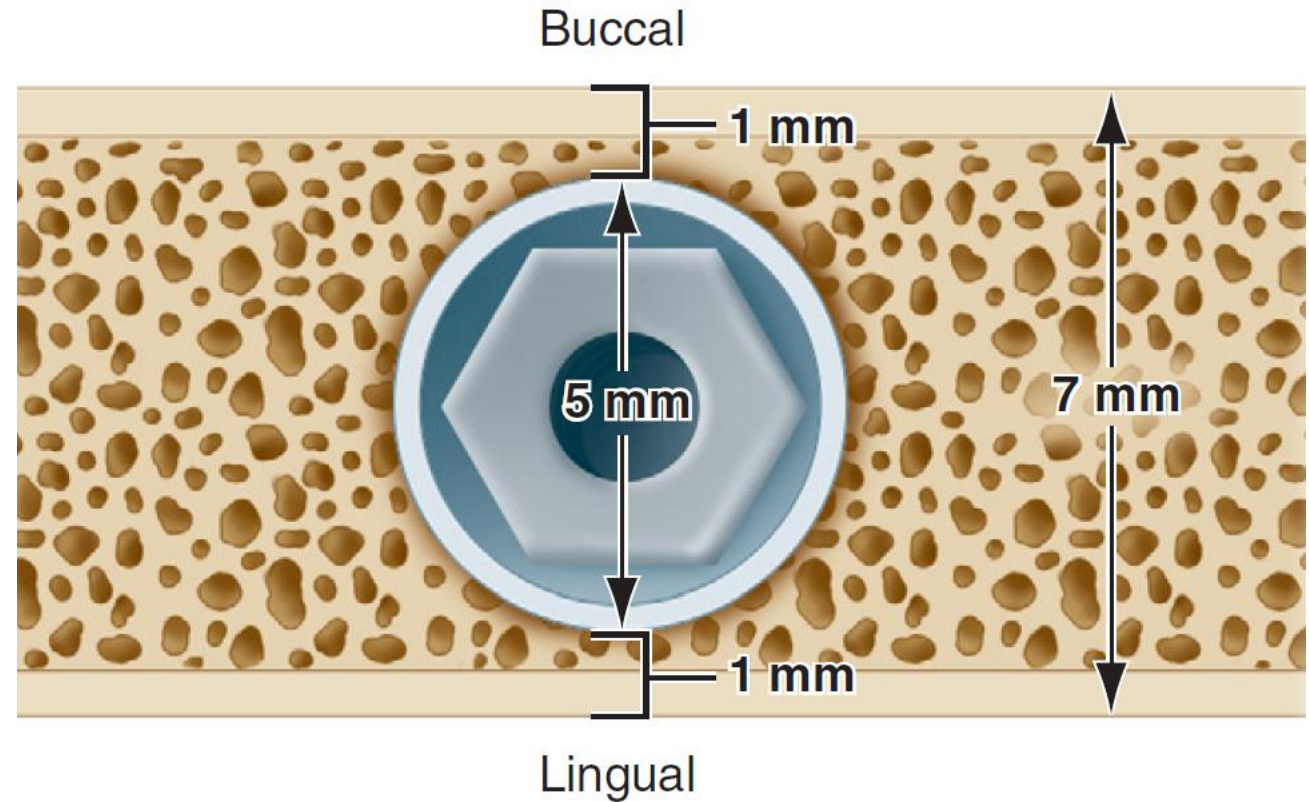
Placement 2 to 3 mm apical to the tooth emergence position is ideal.



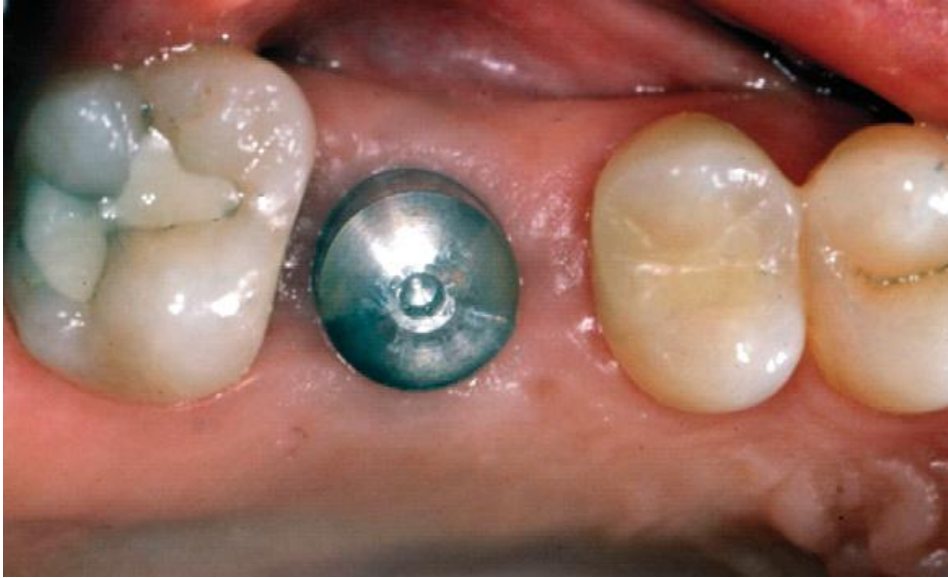
Placing the implant 4 mm apical to the crown contours may create an excessively deep gingival sulcus.



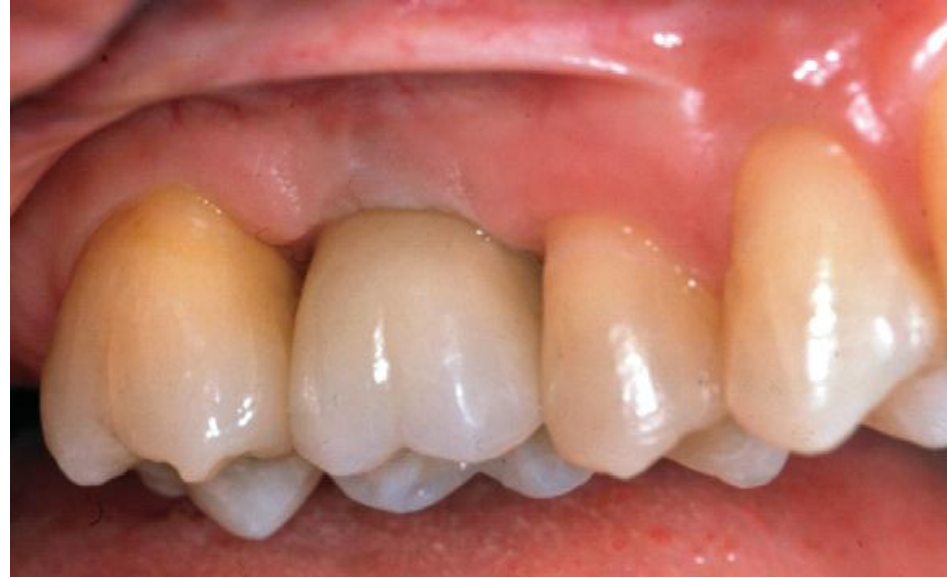The minimum bone dimension for a small diameter implant is 5 mm. Ideally, at least 1 mm of bone is still left on either side of the implant site after the osteotomy has been prepared



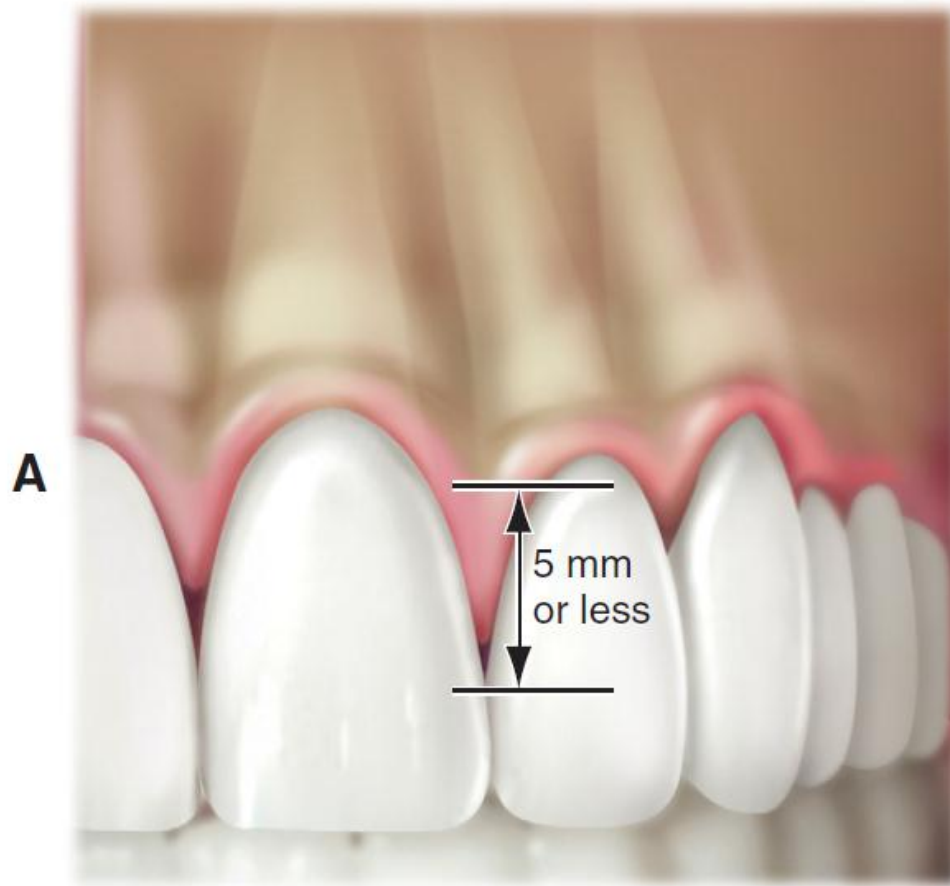
The minimum bone dimension for a wider (5 mm) implant is approximately 7 mm. At least 1 mm of bone should still remain laterally after the site has been prepared.



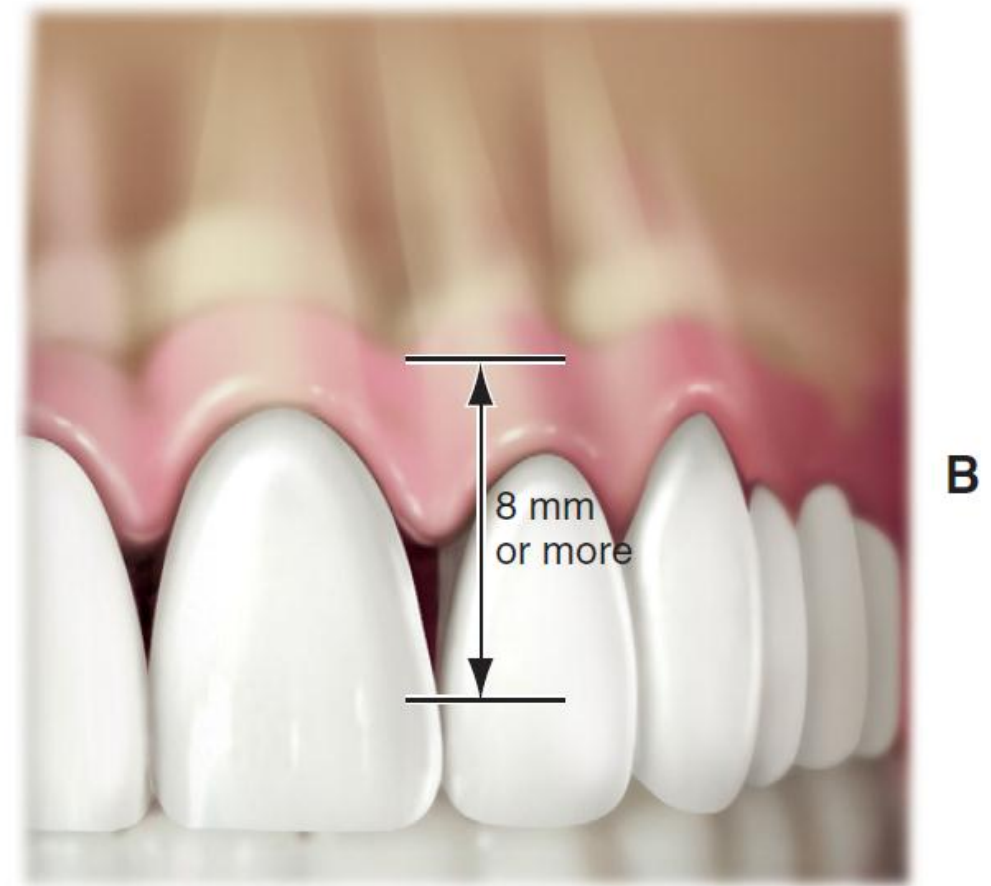
Wide-diameter (5.0 mm) implant in position to replace maxillary first molar



Completed implant restoration of the maxillary first molar



PAPILLA

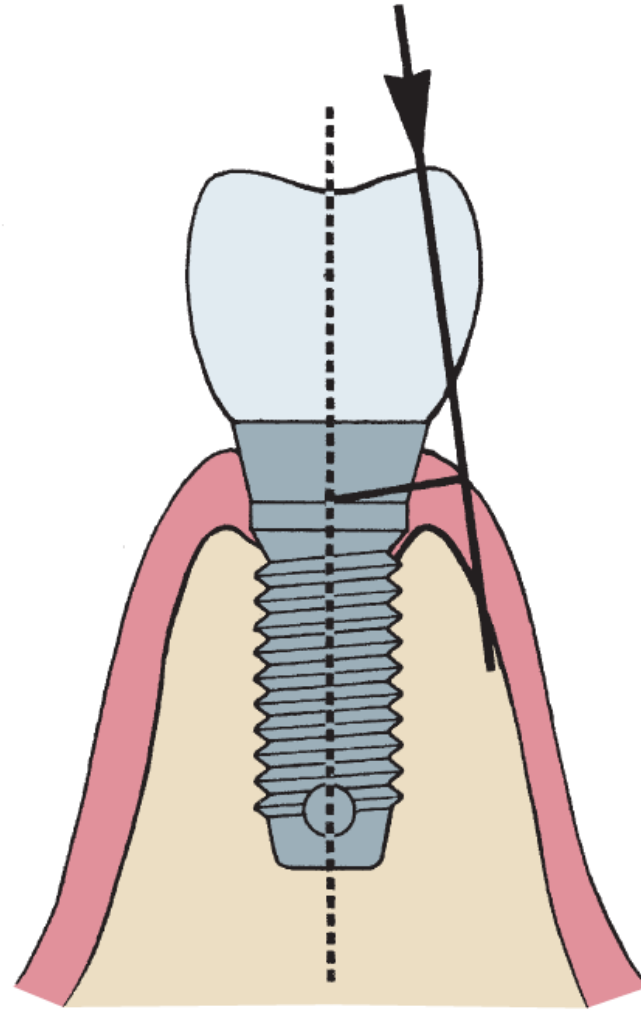
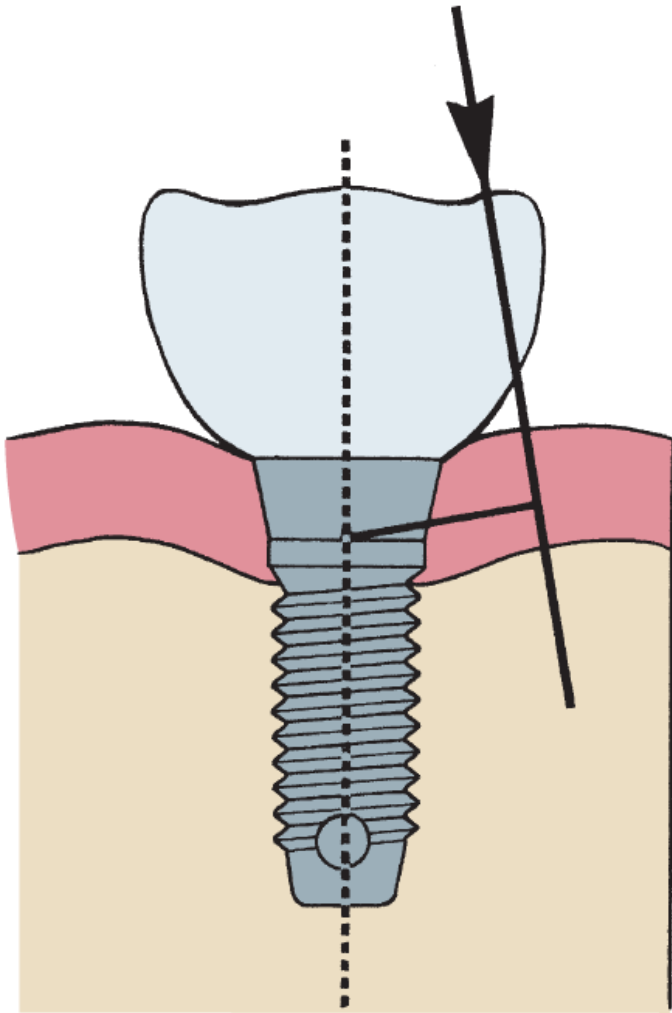


NO PAPILLA

Relationship of interdental bone to position of interproximal contacts seems to predict whether interdental papilla will be present or not. If the distance between the bone and the contact is <5 mm (A), a papilla is usually present; if the distance is >8 mm (B), there is usually no interdental papilla present.

Occlusion Consideration

1. Direct forces in long axis of the implant body.
2. Minimize lateral forces on the implant.
3. Place lateral forces when necessary as far anterior in the arch as possible.
4. When it is impossible to minimize or move lateral forces anteriorly, distribute them over as many teeth and implants as possible.



Sharper cusp inclines and wider occlusal tables increase the resultant force on implant components.

