

Parasitology :

is a branch of science that deals with the study of parasites

Or (is the science study the relationship between two (organisms one called parasite & the other is called the host

Human parasitology is concerned with the study the medical parasites including their morphology, life cycle , the relationship with host and environment

Parasites :

are living organisms, which depend on a living host for their nourishment and shelter temporarily or permanent and living in or on another organism .

Some time parasite multiply or undergo development in the host

CLASSIFICATION OF PARASITES:

The parasites in medical parasitology are

1- Protozoa. 2- Helminthes 3- Arthropods

-Protozoa (unicellular).

-Metazoa(Multicellular)Helminth, arthropods

Kingdom . Phylum. Class. Order. Family .Genus . species

scientific parasitic name is of 2 parts: Genus name and species name. ex:

Plasmodium falciparum

Entamoeba histolytica

I- Protozoa :

unicellular ,eukaryotic parasites , some are pathogenic others are non pathogenic or have free living cycles.

Protozoa (unicellular). Mainly in 2 stage:

1-Trophozoite - (active, feeding ,pathogenic stage)

2-Cyst/ oocyst -inactive and infective form

Protozoa divided into 4 classes according to the organ of locomotion:

1- Class sarcodina(Amoebas):

Parasites that move by means of pseudopodia example Entamoeba histolytica.

2-Class mastigophora (Flagellates):

Parasites that move by means of flagella

example

Giardia lamblia , Trichomonas vaginalis

3- Class ciliates(ciliata) :

parasites that move by means of cilia

example

Balantidium coli .

4- Class Sporozoa : parasites have both sexual and asexual reproductive organs.

Parasitology

Notes...

All sporozoa are parasitic and all these parasites are intracellular and they have no organ of locomotion. ex. Plasmodium parasites causing malaria.

II- Helminthes :

They are metazoa (Multicellular parasite).

they differ from protozoa in their inability to multiply in the body of the host.

Helminthes divided into 3 classes :

1.Class Nematoda (Roundworms) :

worm-like, separate-sexed, unsegmented roundworms

Example: Intestinal nematodes,

Ascaris and Enterobius

.

2 -Class Cestoda (Tapeworms) :

The tapeworms of humans are band-like and segmented worms, e.g:

Taenia spp

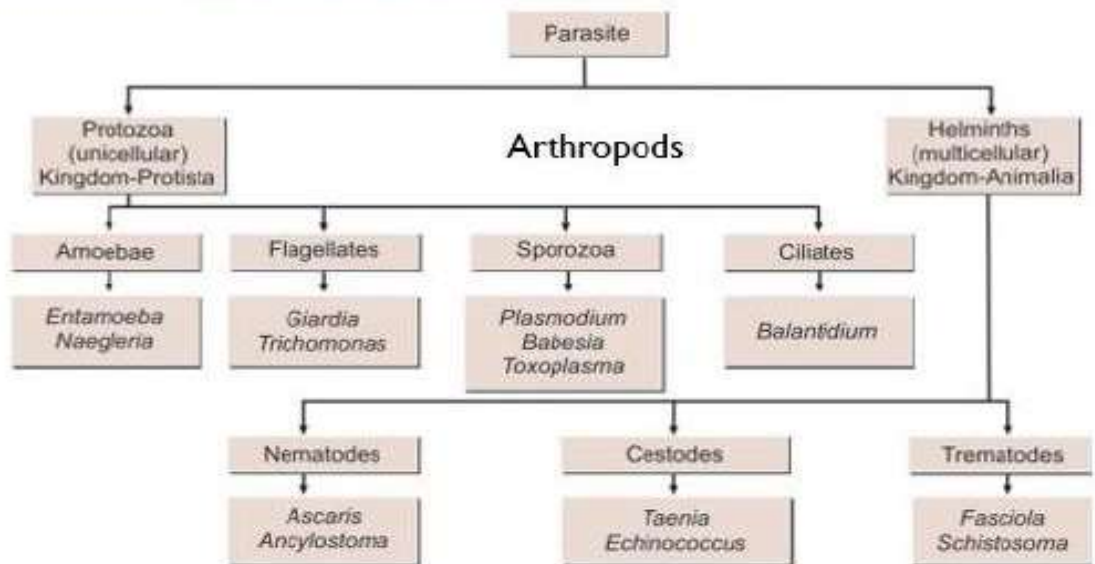
,
Echinococcus

.

3- Class Trematoda (Flukes):

They are flattened ,unsegmented , leaf- shaped worms. e.g: blood flukes

.



Parasitology

Notes...

III- Arthropods :

These parasites having exoskeleton and jointed legs, divided into 2 classes:

1- **Class Insecta** :e.g. Mosquitoes, housefly.

2- **Class Arachnida** :e.g. spiders, Ticks and mites .

GENERAL TERMINOLOGY

symbiosis (association-relationship of two or more organisms living together)

1-

Mutualism: two organisms living together, the two organisms benefit(bacteria in the bowel)

2-

Commensalism:(eating on the same table) two organisms living together, one is benefited and other no beneficial or not been affected.

3-

Parasitism:One organism is benefited at the expense of the another (host)

Zoonosis: disease of animals but can be transmitted to a man.

Anthroponosis: parasitic infection is found in man alone

Zooanthroponosis: parasitic infection mainly affect man, but animals become infected in life cycle of parasite like in taeniasis

Anthropozoonosis:parasitic infection is mainly in animals, some time may be acquired by man as in echinococcosis

Parasites can be classified as:

-Ectoparasite: a parasite lives outside on the surface of the body host without penetrating the tissue. like Lice, ticks, and mites

The term infestation used with ectoparasites.

-Endoparasite: parasite lives inside the body of the host .like Toxoplasma gondii and Plasmodium. the term infection used with endoparasite.

Parasitology

Notes...

-Most of the protozoan and helminthic parasites causing human disease are endoparasite

Parasites can be classified into:

Permanent parasite : remains in the host for life and can not survive without the host

Temporary parasite : Visits a host for a short period for food (soft ticks).

Obligate parasite: Parasite that cannot survive outside of a host e.g. Trichomonos

Facultative parasite: parasites able to live both free living and parasite living under

unfavorable environmental condition e.g. Strongyloides species

Accidental parasites: which infect an unusual host and survives, but may or may not complete life cycle.

Echinococcus granulosus infects man accidentally, giving rise to hydatid cysts humans

opportunistic parasite : produces disease and severe pathological lesions only in immunodeficient or immunosuppressed patients(AIDS) but in immunocompetent individuals producing mild or no diseases.

Wandering or Aberrant parasite : Parasite reaches a place where it can not live.

Pseudoparasite: not a true parasite but mistaken as parasite (called artifact) this includes yeast, hairs, spores

Coprozoic parasite : The organisms that have been accidentally ingested and passed through the intestine without causing any infection to the host.

Host

is defined as an organism, which provides shelter and food to other organism smaller than the host in size.

Definitive host

: Host in which the adult sexual phase of parasite development occurs .e.g.

mosquito acts as definitive host in malaria.

The definitive host may be a human or any other living being.

Intermediate host:

Host in which the larval asexual phase of parasite development occurs .

In some parasites, 2 different intermediate hosts may be required to complete different larval stages. these

are known as first and second intermediate hosts, respectively.€

Carrier host:

A person or animal with asymptomatic infection that can be transmitted to another susceptible person or animal

Reservoir host :

a continuous source of infection, reservoirs can be human ,animals or non living things

Accidental host:

in which the parasite is not usually found, e.g. man is an accidental host for cystic echinococcosis

2 Parasites having direct life cycle

Protozoa

- *Entamoeba histolytica*
- *Giardia lamblia*
- *Trichomonas vaginalis*
- *Balantidium coli*
- *Cryptosporidium parvum*
- *Cyclospora cayetanensis*
- *Isospora belli*
- *Microsporidia*

Helminths

- *Ascaris lumbricoides*
- *Enterobius vermicularis*
- *Trichuris trichiura*
- *Ancylostoma duodenale*
- *Necator americanus*
- *Hymenolepis nana*

2 Parasites having indirect life cycle

Parasite	Definitive host	Intermediate host
Protozoa		
<i>Plasmodium</i> spp.	Female Anopheles mosquito	Man
<i>Babesia</i>	Tick	Man
<i>Leishmania</i>	Man, dog	Sandfly
<i>Trypanosoma brucei</i>	Man	Tsetse fly
<i>Trypanosoma cruzi</i>	Man	Triatomine bug
<i>Toxoplasma gondii</i>	Cat	Man
Cestodes		
<i>Taenia solium</i>	Man	Pig
<i>Taenia saginata</i>	Man	Cattle
<i>Echinococcus granulosus</i>	Dog	Man
Trematodes		
<i>Fasciola hepatica</i>	Man	Snail
<i>Fasciolopsis buski</i>	Man, pig	Snail
<i>Schistosoma</i> spp.	Man	Snail
Nematodes		
<i>Trichinella spiralis</i>	Man	Pig
<i>Wuchereria bancrofti</i>	Man	Mosquito
<i>Brugia malayi</i>	Man	Mosquito
<i>Dracunculus medinensis</i>	Man	Cyclops

Parasitology

Notes...

Life Cycle of Parasites

Direct life cycle

: When a parasite requires only

Single host to complete its development.e.g. Entamoeba histolytica requires only a

human host to complete its life cycle.

Indirect life cycle

: When a parasite requires 2 or more species of host to complete its

development, e.g. malarial parasite requires both human host and mosquito to complete its life cycle

Sources of Infection

1-Contaminated soil and water:

-

Soil polluted with embryonated eggs (roundworm, whipworm) may be ingested or infected larvae in soil, may penetrate skin ,in water may be ingested (cyst of amoeba and Giardia

- Free living parasites in water may directly enter through nasopharynx (Naegleria)

2-food:

Ingestion of contaminated food or vegetables containing infective stage of parasite (amoebic cysts, Toxoplasma oocysts, Echinococcus eggs)

Parasitology

Notes...

3-Insect vectors:

A vector is an agent, usually an arthropod that transmits an infection from man to man or from other animals to man, e.g. female Anopheles is the vector of malarial parasite.

Vectors divided into

a- Biological vectors (true vectors):

which not only assists in the transfer of parasites but the parasites undergo development or multiplication in their body as well.

Mosquito—Malaria

b-Mechanical vectors

:which assists in the transfer of parasitic form between hosts but is not essential in the life cycle of the parasite.

Housefly—amoebiasis

4-Domestic animals:

^ Cow, e.g. T. saginata,

^ Pig, e.g. T. solium, Trichinella spiralis

^ Cat, e.g. Toxoplasma

^ Dog, e.g. Echinococcus granulosus

5-Self (autoinfection)

€ Finger to mouth transmission, e.g pinworm

Modes of Infection

1-Oral transmission: The most common method of transmission is through oral route by contaminated food, water.

2-Skin transmission: Entry through skin is another important mode of transmission.

3-Vector transmission: Many parasitic diseases are transmitted by insect bite

4-Direct transmission: Parasitic infection may be transmitted by person to person contact in some cases.

5-Vertical transmission: Mother to fetus transmission may take place in malaria and toxoplasmosis.

6-Iatrogenic transmission: It is seen in case of transfusion malaria and toxoplasmosis after organ transplantation.

Pathogenesis

Parasitic infections may remain inapparent or give rise to clinical disease.

Pathogenic mechanisms, which can occur in parasitic infection are

- 1-Lytic necrosis:Enzymes produced by some parasite can cause lytic necrosis.
- 2- Trauma :Attachment of hookworms on jejunal mucosa .
- 3-Allergic manifestations :Clinical illness may be caused by host immune response to parasitic Infection.
- 4-Physical obstruction: Masses of roundworm cause intestinal obstruction
- 5-Inflammatory reaction: Clinical illness may be caused by inflammatory changes and fibrosis.

Parasitology

Notes...

6-Neoplasia: A few parasitic infection have been shown to lead to malignancy

Pathogenesis of the parasitic diseases depend on

A-Host factors :

- 1) Nutritional status of the host, whether malnutrition or under nutrition.
- 2) Immune status of the host whether there is immuno-suppression or not.
- 3) The presence or absence of the co-existing disease or other physiological conditions such as pregnancy
- 4) The age and level of the immunity at the time of infection

B-Parasitic factors :

- 1) Site of the parasite .
- 2) Number of invading parasites.
- 3) Parasite strain(pathogenic or non-pathogenic) and the growth, development and multiplication of parasites

Diagnosis of parasitic diseases depends on

A) history and Clinical features : like fever, pain

b) Laboratory diagnosis

1-Microscopy 2-Culture

3- Serological test 4-Skin test

5-Molecular method 6- Animal inoculation

7-Xenodiagnosis 8-Imaging

9- Hematology

1-Microscopy

An appropriate clinical specimen should be collected for definitive diagnosis of parasitic infections.

Stool, Blood, Urine, Sputum, Cerebrospinal fluid (CSF), Tissue and aspirates, Genital specimens.

Immunity in Parasitic Infection

Like other infectious agents, parasites also elicit immunoresponses in the host, both humoral as well as cellular

But immunological protection against parasitic infections is much less efficient, than it is against bacterial or viral infections.

parasites are larger or more complex structurally and antigenically, so that immune system may not be able to focus attack on the protective antigens.

Many parasites are intracellular or in body cavity in location, and this protects them from immunological attack.

Vaccination

No effective vaccine for humans has so far been developed against parasites due to their complex life cycles, adaptive responses, and antigenic variation

Karyosome

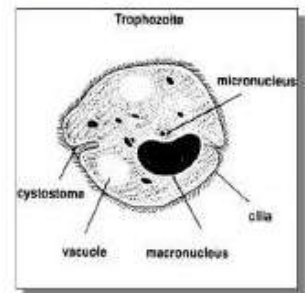
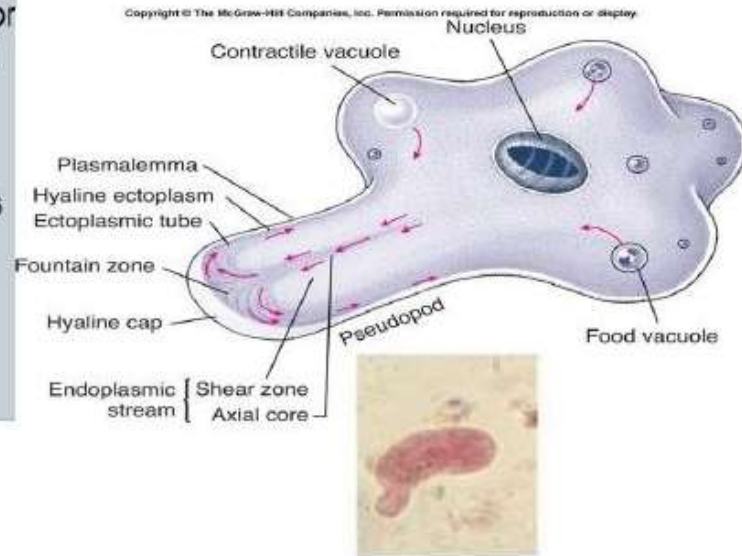
It is a DNA containing body, situated peripherally or centrally within the nucleus and found in intestinal amoeba, e.g. *E. histolytica*, *E. coli*

Kinetoplast

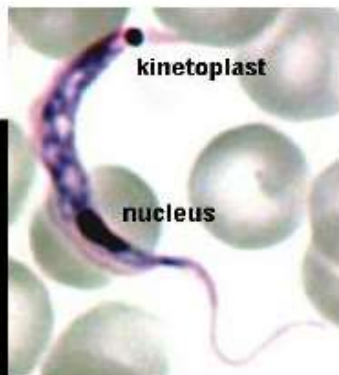
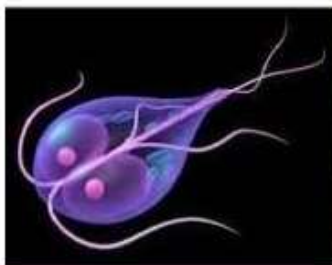
Non-nuclear DNA present in addition to nucleus is called kinetoplast. It is seen in trypanosomes.

Flagellum

originates near the kinetoplast. Point of origin of flagellum is called as basal body



Giardia Lamblia



Parasitology

Notes...

protozoan Structure

The typical protozoan cell is bounded by simple unit membrane, supported by a sheet of contractile fibrils

Cytoplasm

It has 2 portions:

Ectoplasm: Outer homogeneous part that serves as the organ for locomotion and for engulfment of food by producing pseudopodia, excretion and cyst formation.

Endoplasm: The inner granular portion of cytoplasm

Is concerned with metabolism and reproduction includes the following structures (nucleus, the golgi bodies, endoplasmic reticulum, food vacuoles, and contractile vacuoles).

Nucleus

The nucleus is usually single but may be double or multiple;

The nucleus contains one or more nucleoli or a central karyosome.

Pseudopod: A protoplasmic extension on the trophozoites of amoeba allowing them to move and engulf food.

Cilia: Hair like processes attached to a free surface of a cell; function for motility of the cell, e.g. *Balantidium coli*.

***Flagellum(flagella) :** An extension of ectoplasim which provides locomotion similar to a tail

Diagnostic methods in parasitology

Objectives:

- Discuss the various diagnostic techniques in parasitology.
- Determine the uses of each of these methods.

The following diagnostic techniques are used for the diagnosis of parasitic infections:

1. Morphological identification techniques: either macroscopically or microscopically.
2. Culture methods.
3. Immunodiagnostic methods.
4. Molecular methods.
5. Intradermal skin tests.
6. Xenodiagnostic techniques.
7. Animal inoculation methods.
8. Imaging techniques.

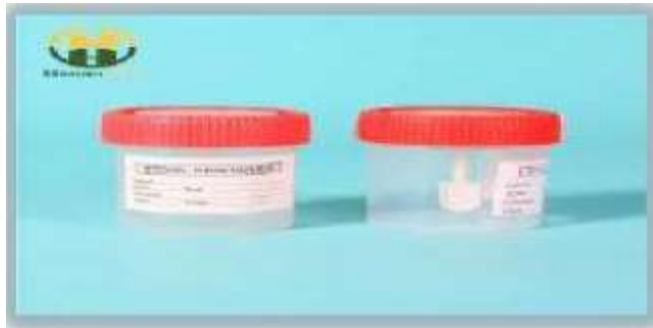MORPHOLOGICAL IDENTIFICATION TECHNIQUES

- parasites can be identified by their morphology either macroscopically or microscopically.
- Microscopically they can be visualized directly by wet mount (saline/iodine) for stool specimen or either by different staining techniques.

EXAMINATION OF STOOL

Specimen Collection:

⌘ Stool specimens should be **collected** in a wide-mouth, clean, leak-proof, screw capped container.



⌘ **Timing:** Specimen should be collected before starting antiparasitic drugs and closer to the onset of symptoms.

⌘ **Frequency:** At least three stool specimens collected on alternate days are adequate to make the diagnosis of intestinal parasitic diseases.

⌘ **When to examine:** Liquid stool specimens should be examined within 15–30 minutes. semisolid stools within 1 hour and formed stools up to 24 hours after collection.

1. Macroscopic Examination

1- **Consistency:** Hard, Soft, Loose, Watery, liquid, Formed, Semi formed.

2- **Color:** the normal stool is brown due to bile pigments. The type of food affects the color of

stool.

Clay: obstructive jaundice or presence of barium sulfate

Reddish: blood from lower gastrointestinal tract, beef consumption

Black: bleeding from upper gastrointestinal tract, iron, charcoal.

Green: ingestion of spinach, antibiotics.


3-Mucous, blood.

4- Presence of adult worms can also be seen in a freshly passed stool e.g. adult stages of *Ascaris lumbricoides* and *Enterobius vermicularis*. Proglottids of *Taenia species* can also be seen.

2. Microscopic Examination

Direct wet mount (saline and iodine mount):

Drops of saline and Lugol's iodine are placed on two corners of a slide. A small amount of feces is mixed by a stick to form a uniform smooth suspension. Cover slip is placed on the mount and examined under low power objective (10X); followed by high power objective (40X).



Following structures can be visualized by microscopic examination of stool specimen:

1. Normal constituents: Such as plant fiber, muscle fibers, pollen grains, yeast cells, bacteria, epithelial cells, and air bubbles are present.
2. Cellular elements: Like pus cells (in inflammatory diarrhea), red blood cells (RBC) (in dysentery)
3. Charcot Leyden crystals (diamond shaped): They are the breakdown products of eosinophils and may be seen in the stool or sputum of patients with parasitic diseases such as amoebic dysentery, ascariasis.
4. Trophozoites and cysts of protozoa and eggs and larvae of helminths



Epithelial cells



Pus cells



Plant hair



Air bubble



Pollen grain



Yeast cells



Fungal spores

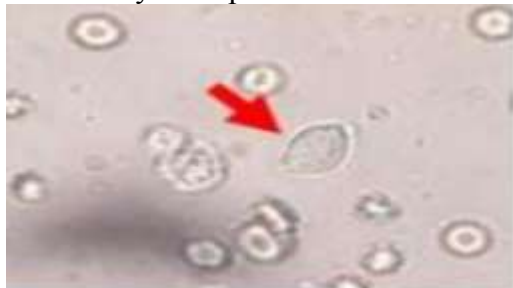

Charcot
Leyden crystal

Saline mount

Advantages

1. Useful in the detection of trophozoites and cysts of protozoa and eggs and larvae of helminths.
2. Motility of trophozoites and larvae can be demonstrated in acute infection.



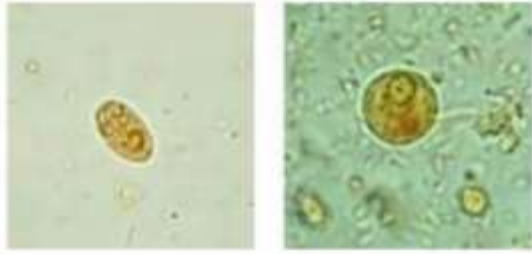
Iodine mount

Advantages

Nuclear details of cysts, helminthic eggs and larvae are better visualized; helps in species identification.

Disadvantages

Iodine immobilizes and kills parasites, hence motility of the protozoan trophozoites and helminthic larvae cannot be appreciated.



Permanent stained smear

Permanent stained smears are required for accurate diagnosis of intestinal parasites.

Commonly used stains are:

- ☞ Iron-hematoxylin stain.
- ☞ Trichrome stain.
- ☞ Modified acid-fast stain.

All these permanent stained smears help in the accurate diagnosis of cysts and trophozoites by staining their internal structures.

Concentration Techniques:

If the parasite output is low in feces and direct examination may not be able to detect the parasites, then the stool specimens need to be concentrated.

Commonly used concentration techniques are:

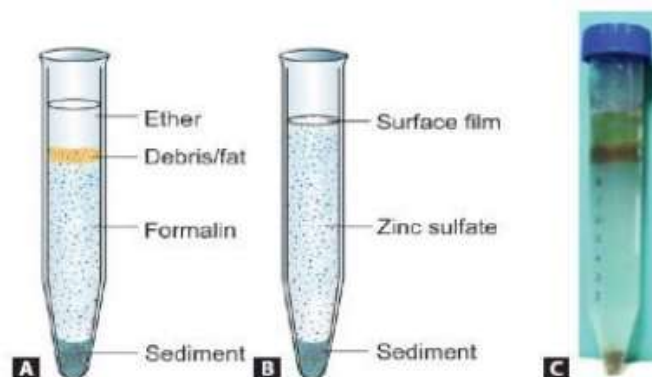
A. Sedimentation techniques

: Eggs and cysts settle down at the bottom following centrifugation.

- Formalin-ether concentration technique.
- Formalin-ethyl acetate concentration technique.
- Formalin-acetone sedimentation technique.

Principle:

The protozoan cysts and helminthic eggs are concentrated at the bottom of the tube because they have greater density than the suspending medium.



Figs 15.2A to C: (A) Formalin-ether sedimentation technique (schematic diagram); (B) zinc sulfate flotation concentration technique (schematic) diagram; (C) formalin-ether sedimentation technique (real image)

Courtesy: C- Dr Anand Janagond, Associate professor, Velammal Medical College, Madurai, Tamilnadu (with permission)

Advantages of Sedimentation techniques:

1. The sensitivity of detecting the ova or cysts increases by 8–10 folds.
2. The size and shape of the parasitic structures are maintained.
3. Inexpensive, easy to perform.
4. As formalin kills the fecal parasites, no risk of acquiring laboratory acquired infection.

Disadvantages

Trophozoite forms are killed and hence not detected in this method.

B. Floatation techniques:

The eggs and cysts float at the surface due to specific gravity gradient

- ☞ Saturated salt (sodium chloride) solution technique.
- ☞ Zinc sulphate floatation concentration technique.
- ☞ Sheather's sugar floatation technique (useful for *Cryptosporidium*, *Isospora* and *Cyclospora*).

Two commonly used concentration techniques are formalin-ether and saturated salt solution technique.

Principle:

Flotation involves suspending the specimen in a medium of greater density than that of the helminthic eggs and protozoan cysts. The eggs and cysts float to the top and are collected by placing a glass slide on the surface of the meniscus at the top of the tube.

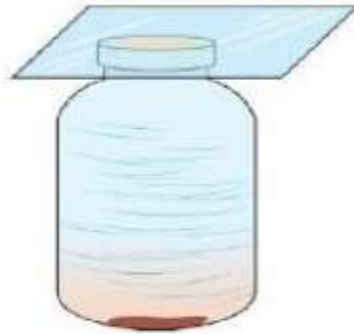


Fig. 15.3: Flotation technique (schematic diagram)

advantages of Floatation techniques

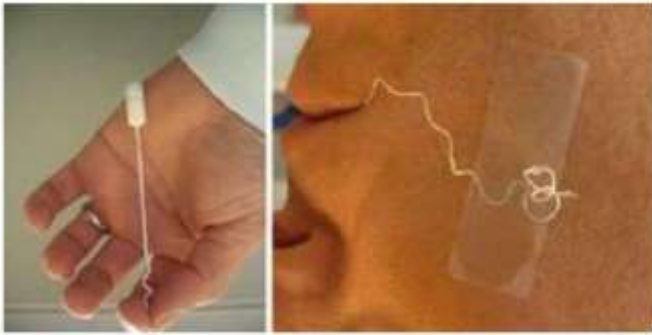
- Flotation technique is not useful for heavier eggs that do not float in the salt solution such as:
 - Unfertilized eggs of *A. lumbricoides*.
 - Larva of *Strongyloides*.
 - *Taenia* eggs.
 - Operculated eggs of trematodes.

Specimens other than stool:

Perianal swabs (cellophane tape or NIH swab):

Useful for detecting Eggs of *Enterobius vermicularis* deposited on the surface of perianal skin. It is also used for eggs of *Schistosoma mansoni* and *Taenia* species.

Duodenal contents: It is very useful for the detection of small intestine parasites like, *Giardia intestinalis* and larva of *Strongyloides stercoralis*. Duodenal fluid can be collected by intubation or by entero test.

**Blood**

Blood examination is useful in diagnosis of infections caused by blood parasites like *Plasmodium*, *Trypanosoma*, *Leishmania*, *Babesia*, *Wuchereria bancrofti*, *Brugia malayi*, and *Loa loa*.

cerebrospinal fluid (CSF)

useful for the detection of motile free-living amoebae (*Naegleria* and *Acanthamoeba*), trypanosomes.

Sputum

useful in demonstration of eggs of *Paragonimus* in cases of pulmonary paragonimiasis and trophozoites of *E. histolytica* in cases of pulmonary amoebiasis.

Urogenital Specimen

vaginal discharges are useful in detection of *Trichomonas vaginalis* trophozoites. The trophozoites can be identified by their typical jerky motility.



CULTURE TECHNIQUES IN PARASITOLOGY

Culture media are not routinely used in diagnostic parasitology. They are useful in research and teaching purpose.

Box 7: Parasites which can be cultured in the laboratory

- *Entamoeba histolytica*
- *Giardia lamblia*
- *Trichomonas vaginalis*
- *Leishmania* spp.
- *Trypanosoma* spp.
- *Acanthamoeba* spp.
- *Naegleria fowleri*
- *Balantidium coli*
- *Plasmodium* spp.

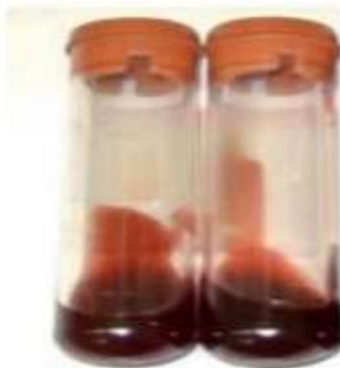It is employed for accurate identification of the parasite species. It also employed for obtaining large yields of the parasite as a source of antigen, animal inoculation, drug-sensitivity testing, experimental or physiological studies and teaching purposes.

1. Culture for *Ameba*:

1. **Boeck and Drbohlav diphasic medium:** the classical culture medium for ameba. The cultures are incubated at 37°C and sub-cultured at 48-hour intervals. Amebae can be demonstrated in the Liquid phase in unstained mounts or stained smears.
2. **Balamuth's monophasic liquid medium:** is also used commonly for cultivation of amebae and other intestinal protozoa. This is an egg yolk-Liver extract infusion medium. *B. coli* and *G. lamblia* grows well in Balamuth's medium.


2. Culture for *Leishmania* and *Trypanosomes*

1. **Novy-MacNeal-Nicolle (NNN) medium:** This is a defibrinated rabbit blood agar medium. Two bottles of culture are aseptically inoculated with 0.1 mL of specimen in each and incubated at 24°C for 4 weeks.
 - The primary culture is examined every 4 days for promastigotes in leishmaniasis and for epimastigote stages in trypanosomiasis for up to 30 days.



2. Schneider's insect tissue culture medium: It is recommended *in vitro* culture for *Leishmania*. this medium is said to be more sensitive than NNN medium.

3. Culture for Malaria Parasites



IMMUNODIAGNOSTIC METHODS

- This method involves detection of parasite specific antibodies in serum, and detection of circulating parasitic antigen in the serum.

- Immunodiagnostic methods are useful when:

I. Parasites are detected only during the early stages of the disease.

II. Parasites occur in very small numbers.

III. Parasites reside in internal organs and morphological identification is not possible.

IV. When other techniques like culture are time consuming.

1-Antibody Detection Tests)Serology

- Antibodies are detected in various parasitic infections mainly from serum, sometime from other sites like CSF (neurocysticercosis).

- Various antibody detection methods are available as: Indirect fluorescent antibody test (IFA), enzyme-linked immunosorbent assay (ELISA) and rapid Immunochromatographic tests (ICT).

Limitations of antibody detection techniques:

I. Cannot distinguish between acute and chronic infection. [However, immunoglobulin M (IgM) based assay can diagnose recent infection accurately.

II. Less specific: Cross reactive antibodies are found in unrelated infections due to heterogenicity of parasitic antigens.

Example of serological tests used in parasitology:

1. Amebiasis

- Serology is of no value in the diagnosis of acute amebic dysentery or luminal amebiasis. But in invasive amebiasis, particularly in liver abscess, serology is very useful.

2. Toxoplasmosis

- The original *Sabin-Feldman dye test*, is no longer in use. *IHA* and *CFT* were other useful tests.

- At present, *ELISA* is routinely used in *Toxoplasma* serology. It is very informative, as it provides titers of IgM and IgG antibodies separately for better interpretation of the results.

3. *Giardiasis*, 4. *Trypanosomiasis*, 5. *Leishmaniasis*, 6. *Malaria*, 7. *Cryptosporidiosis*, 8. *Trichinosis*, 9. *Toxocariasis*, 10. *Filariasis*, 11. *Echinococcosis*.

2-Antigen Detection Tests

- Most commonly used antigen detection tests are:

A. ELISA.

B. Direct fluorescent antibody assays (DFA).

MOLECULAR METHODS

- Nucleic acid probes and amplification techniques such as polymerase chain reaction (PCR), western blot and DNA hybridization techniques are increasingly used to detect parasites in specimens of blood, stool, or tissue from patients.
- These test are useful for detecting subspecies or strain level identification which is important for epidemiological studies and are also used to detect parasitic drug resistance.
- DNA probe is a highly sensitive method for the diagnosis of malaria.
- B gene of *T. gondii* can be detected by PCR of the amniotic fluid in case of congenital toxoplasmosis.
- PCR have been developed for detection of filarial DNA from patients blood.

INTRADERMAL SKIN TESTS

- **Uses:** They are employed for research and epidemiological purpose.
- **Disadvantages:**
 1. As they remain positive for longer duration, so they cannot differentiate old and recent infection.
 2. More so, non-standardized crude antigens are used, hence they lack sensitivity and specificity.
 3. There is always a danger of provoking an anaphylactic reaction in the patient.

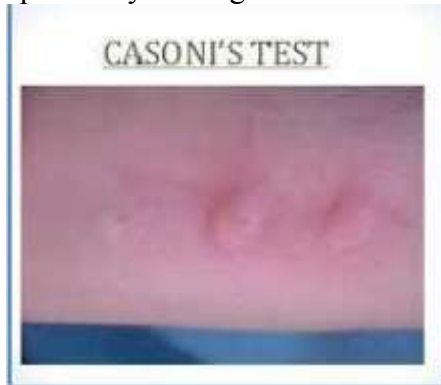Table 15.9: Intradermal skin tests in parasitic diagnosis

<i>Skin tests showing immediate hypersensitivity in</i>	<i>Showing delayed hypersensitivity in</i>
Hydatid disease (Casoni's test)	Leishmaniasis (Montenegro test)
Filariasis	Trypanosomiasis
Schistosomiasis	Toxoplasmosis
Ascariasis	
Strongyloidiasis	
Trichinellosis (Bachman test)	

Casoni's test:

The antigen is sterile hydatid fluid drawn from hydatid cysts from cattle, sheep, or

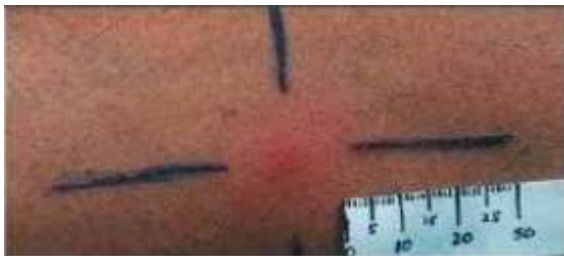humans, filtered and tested for sterility. Intradermal injection of 0.2 mL of the antigen induces a wheal and flare reaction within 20 minutes in positive cases. A saline control is used. False-positive tests are seen in schistosomiasis and some other conditions. Casoni's test is now largely replaced by serological tests



leishmanin (Montenegro) test:

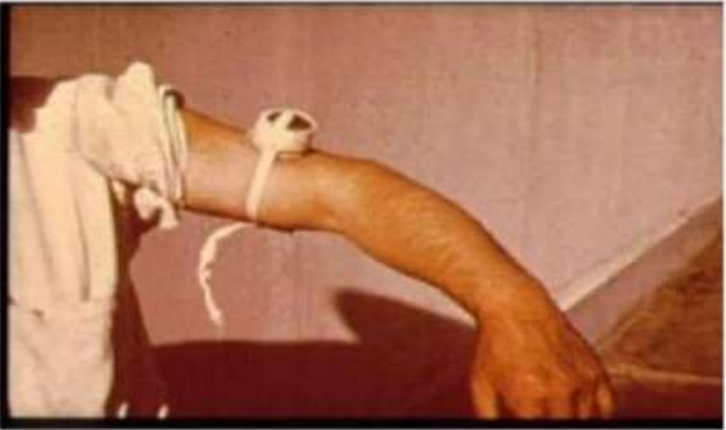
this test is used to measure delayed hypersensitivity.

Leishmanin test is sensitive and relatively specific. The antigen is obtained from cultured *Leishmania* and consists of killed promastigotes in phenol saline. Intradermal injection of 0.1 mL induces a papule of 5 mm or more in diameter in 48-72 hours. This delayed hypersensitivity test is positive in cutaneous leishmaniasis and negative in visceral leishmaniasis.



XENODIAGNOSTIC TECHNIQUES

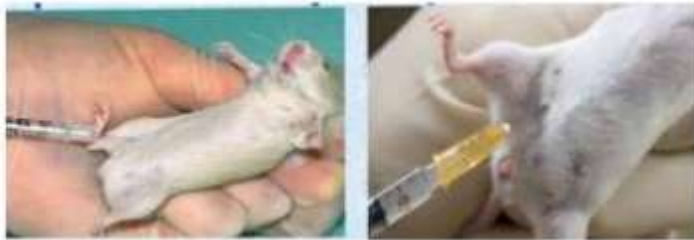- Xenodiagnosis uses laboratory reared arthropod vectors to detect low levels of parasites during chronic stages of the disease, when their numbers in the blood is very low.
- This technique is employed to diagnose Chagas' disease: In *T. cruzi*, diagnosis may be established by letting the vector *reduviid bug* feed on suspected patients. In 4-5 weeks, live flagellate forms can be seen in the feces of the bugs .
- This technique may be useful in endemic areas, but not in routine diagnostic laboratories.



ANIMAL INOCULATION

METHODS

- Animal Inoculation techniques are not routinely used in diagnosis of parasitic infections.
- 1. *Toxoplasmosis*: Lymph node or other biopsy materials are inoculated intraperitoneally in mice. Peritoneal fluid obtained 7-10 days later, may show the parasite in Giemsa-stained smears.
- 2. *Visceral leishmaniasis*: Bone marrow, liver, spleen, or lymph node aspirates from kala-azar patients, injected intraperitoneally into hamsters is a very sensitive method for diagnosing visceral leishmaniasis.
- 3. *Trypanosomiasis*: Blood from patients with trypanosomiasis can be injected intraperitoneally or into the tail vein of mice, rats or guinea pigs. These animals are susceptible to infection by *T. brucei rhodesiense*. Parasite can be demonstrated in 2 weeks.



IMAGING TECHNIQUES

Table 15.11: Imaging methods in parasitic diagnosis

<i>Disease</i>	<i>Imaging method used</i>	<i>Comments</i>
Amoebic liver abscess	USG	Detects the location of abscess and its extra hepatic extension
Hydatid disease	X-ray, USG, CT scan and MRI	<ul style="list-style-type: none"> • X-rays: It is simple, inexpensive, yet useful technique to detect hepatomegaly and calcified cysts and cysts in lungs • USG: It is the imaging method of choice because of its low cost and high diagnostic accuracy. It detects both single and multiple cystic lesions, floating membrane (Water lily sign) and daughter cysts. It is also useful to monitor the response to treatment and for epidemiological studies • CT scan: It is superior to detect smaller cysts, calcified cysts, extrahepatic cysts and to differentiate from other cystic lesions. Also used as a prognostic marker • MRI: It has a higher contrast resolution, which makes cysts clearer. It can be used as an alternate to CT scan.
<i>Trichinella spiralis</i>	X-ray	Detects calcified muscle cysts
Neurocysticercosis	CT scan and MRI	Detects: Number, location, size, of the cysts and extension and stage of the disease CT scan: For calcified cysts MRI: It is superior to CT scan, to detect extraparenchymal cysts, vesicular, necrotic lesions and non-cystic lesions
<i>Paragonimus westermani</i> infection	X-ray, MRI and CT scan	X-ray: Pulmonary cysts MRI and CT Scan: locate extrapulmonary cysts (CNS)
<i>Clonorchis</i> and <i>Opisthorchis</i>	Cholangiography	Detects site of the lesion and obstruction of the biliary tract
Filariasis	USG	<ul style="list-style-type: none"> • Serpentine movement within the lymphatic vessels of scrotum (filarial dance sign) • Dilated and tortuous lymphatic vessels

Parasitology Lecture.2 & 3 (Protozoa Entamoeba Histolytica)

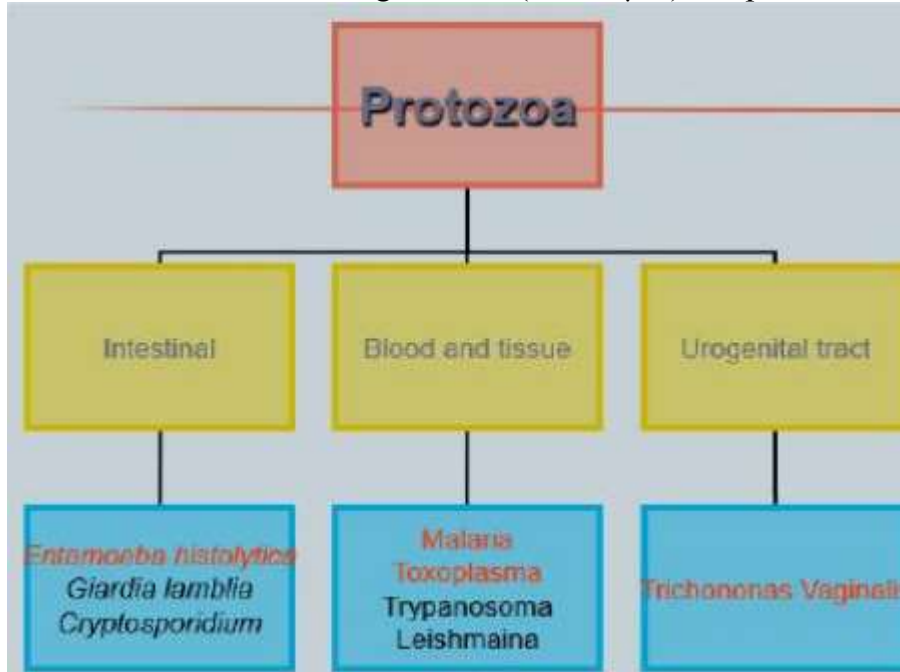
Protozoa

- Single-celled eukaryotic microorganisms.
- Protozoa(Greek protos:first: zoon: animal)
- The single protozoal cell performs all functions.

Most of the protozoa are nonpathogenic but few may cause major diseases such as malaria, leishmaniasis,

-Protozoa like *Cryptosporidium parvum*, *Toxoplasma gondii* are being recognized as opportunistic pathogens in patients affected with (HIV) and in those with immunosuppressive therapy.

-Protozoa exhibit wide range of size (1–150 μm), shape, and structure



Principal Protozoan Pathogen of Man

Species	Habitat	Disease
<i>Entameba histolytica</i>	Large intestine	Amoebic dysentery, amoebic liver abscess
<i>Naegleria fowleri</i>	CNS	Amoebic meningoencephalitis
<i>Acanthamoeba</i>	CNS, eye	Encephalitis, keratitis
<i>Giardia lamblia</i>	Small intestine	Malabsorption, diarrhea
<i>Trichomonas vaginalis</i>	Vagina, urethra	Vaginitis, urethritis
<i>Trypanosoma brucei</i>	Blood, lymphnode, CNS	Sleeping sickness
<i>Trypanosoma cruzi</i>	Macrophage of bone marrow, nerves, heart, colon etc.	Chagas' disease
<i>Leishmania donovani</i>	Reticuloendothelial system	Kala-azar, Post kala azar dermal leishmaniasis
<i>Leishmania tropica</i>	Skin	Cutaneous leishmaniasis (oriental sore)
<i>Leishmania braziliensis</i>	Naso-oral mucosa	Mucocutaneous leishmaniasis (Espundia, Chiclero's ulcer)
<i>Plasmodium</i> spp.	RBC	Malaria
<i>Babesia microti</i>	RBC	Babesiosis
<i>Isospora belli</i>	Intestine	Diarrhea in AIDS
<i>Cryptosporidium parvum</i>	Intestine	Diarrhea in AIDS
<i>Balantidium coli</i>	Large intestine	Dysentery

Amoebae are structurally simple protozoans which have no fixed shape.

classified under

Phylum: Sarcomastigophora,

Subphylum: Sarcodina,

Superclass: Rhizopoda

Order: Amoebida.

The cytoplasm of amoeba is bounded by a membrane and can be differentiated into an outer ectoplasm and inner endoplasm.

Pseudopodia are formed by the amoeba by thrusting out ectoplasm, followed by endoplasm.

These are employed for locomotion and engulfment of food by phagocytosis.

Classification of Amoebae

Intestinal amoebae	Free-living amoebae
<i>Entamoeba histolytica</i>	<i>Naegleria fowleri</i>
<i>Entamoeba dispar</i>	<i>Acanthamoeba</i> spp.
<i>Entamoeba coli</i>	<i>Balamuthia mandrillaris</i>
<i>Entamoeba polecki</i>	
<i>Entamoeba hartmanni</i>	
<i>Entamoeba gingivalis</i>	
<i>Endolimax nana</i>	
<i>Iodamoeba butschlii</i>	
Note: All intestinal amoebae are nonpathogenic, except <i>Entamoeba histolytica</i>	Note: All free-living amoebae are opportunistic pathogens

Entamoeba Histolytica

Epidemiology :

E. histolytica is worldwide in prevalence

The incidence of Amebiasis is common & high in tropical & subtropical areas. It has been found wherever sanitation is poor in all climatic zones

It has been reported that about 10% of world population and 50% of developing countries

may be infected with the parasite.

The infection about 1% of Americans being reported, While the majority of infected humans (80–95%) are Asymptomatic.

invasive amoebiasis causes disabling illness in an estimated 50 million of people and causes 50,000 deaths annually amoebiasis is the third parasitic cause of mortality after malaria and schistosomiasis

Morphology

E. histolytica occurs in 3 forms .

Trophozoite

Precyst

Cyst.

Trophozoite

Trophozoite is the vegetative or growing stage of the parasite .

It is the only form present in tissues and in intestine

The parasite, as it occurs free in the lumen as a commensal is generally smaller in size, about 15–20 μm and has been called the minuta form

Morphology (Trophozoite):

1- It is irregular in shape and varies in size (12-60 μm), actively motile in freshly passed dysenteric stools.

2- Large finger – like pseudopodia

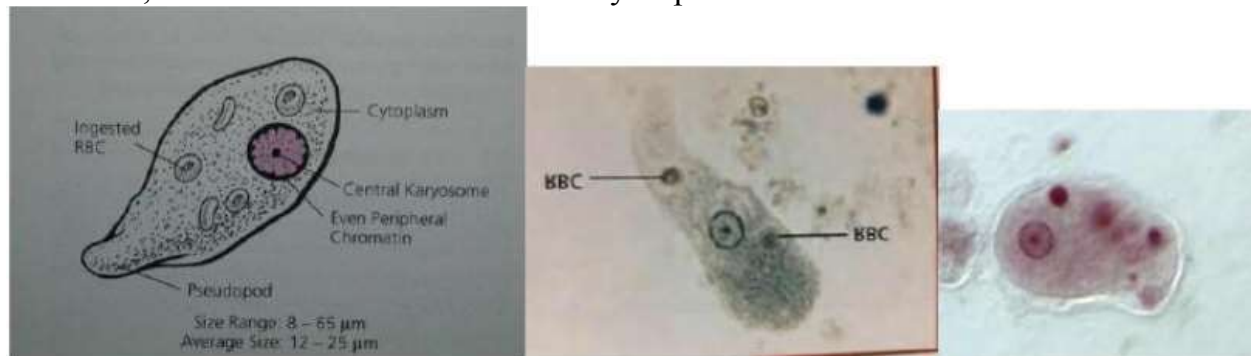
3- the Cytoplasm: is differentiated into outer Clear ectoplasm ,inner endoplasm is granular and may contain RBCs, food vacuols, granules.

4- It has one nucleus, is spherical 4–6 μm in size contain small central karyosome and fine chromatin granules arranged regularly beneath nuclear membrane.

The trophozoites divide by binary fission in every 8 hours.

Trophozoites survive upto 5 hours at 37°C and are killed by drying, heat, and chemical sterilization.

Therefore, the infection is not transmitted by trophozoites



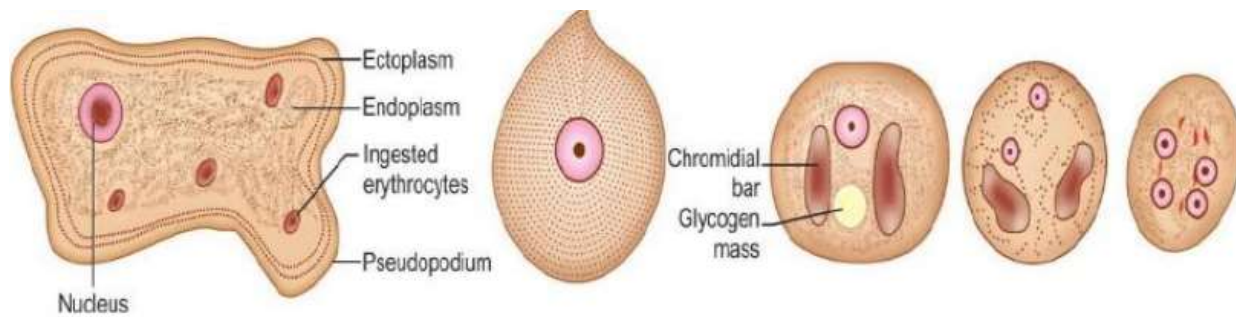
Precystic Stage

Trophozoites undergo encystment in the intestinal lumen.

Encystment does not occur in the tissues

Before encystment, the trophozoite extrudes its food vacuoles and becomes round or oval, about 10–20 μm in size.

the precystic stage of the parasite contains a large glycogen vacuole and two chromatid bars. then secretes a highly retractile cyst wall around it and becomes cyst.



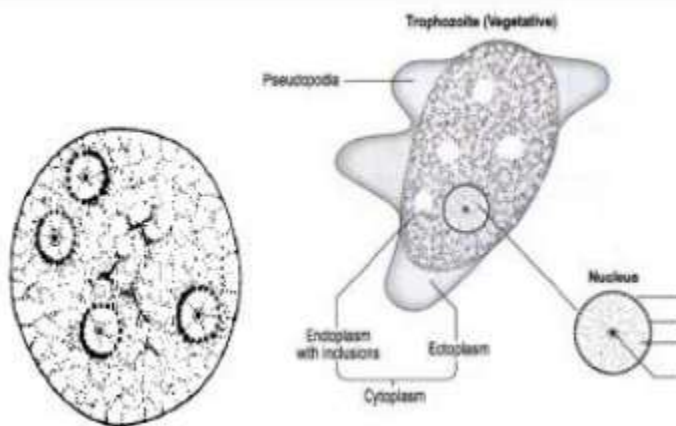
Cystic Stage

The cyst is spherical in shape about 10–20 μm in size.

The early precystic stage contains a single nucleus and two other structures—a mass of glycogen and two chromatoid bodies.

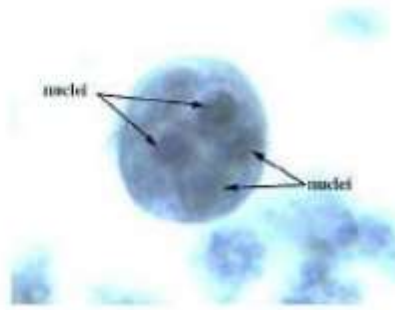
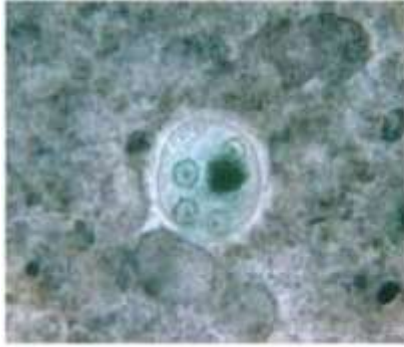
As the cyst matures, the glycogen mass and chromatoid bars disappear and the nucleus undergoes 2 successive mitotic divisions to form 2 and then 4 nuclei. The mature cyst is, thus, quadrinucleate.

The cyst wall is a highly retractile membrane, which makes it highly resistant to gastric juice and unfavorable environmental conditions.



Morphology (mature cyst) :

1- Small in size (10 – 20 μm) , spherical or oval in shape, thick wall about 0.5 micron .containing 1 - 4 nuclei ,vacuoles,glycogen . Each nucleus contain similar nuclear morphology like the trophozoite.



Transmission of amoebiasis occur through:

1. Mature cyst is the main source of the infection which passes with the feces of chronic patients or asymptomatic carrier .
2. Human being acquire the infection via contamination of food, drinks, vegetables or hands with infective cysts especially in restaurants .
3. Flies (House fly) play an important role in transmission of these cysts to the food of human .

Life Cycle

life cycle only in one host

Infective form: Mature quadrinucleate cyst .

The cysts can remain viable under moist conditions for about 10 days.

E. histolytica causes intestinal and extraintestinal amoebiasis.

Incubation period ranges from 4 days - 4 months.

As the cyst wall is resistant to action of gastric juice, the cysts pass through the stomach undamaged and enter the small intestine.

Excystation:

When the cyst reaches caecum or lower part of the ileum, due to the alkaline medium, the cyst wall is damaged by trypsin, leading to excystation. After excystation the cytoplasm gets detached from the cyst wall through which (4 amoeba) quadrinucleate amoeba is liberated into metacystic trophozoites:

The nuclei in the metacystic trophozoites immediately undergo division to form 8 nuclei, each of which gets surrounded by its own cytoplasm to become 8 small amoeba or metacystic trophozoites.

The optimal habitat for the metacystic trophozoite is the submucosal tissue of caecum

and colon and grow by binary fission

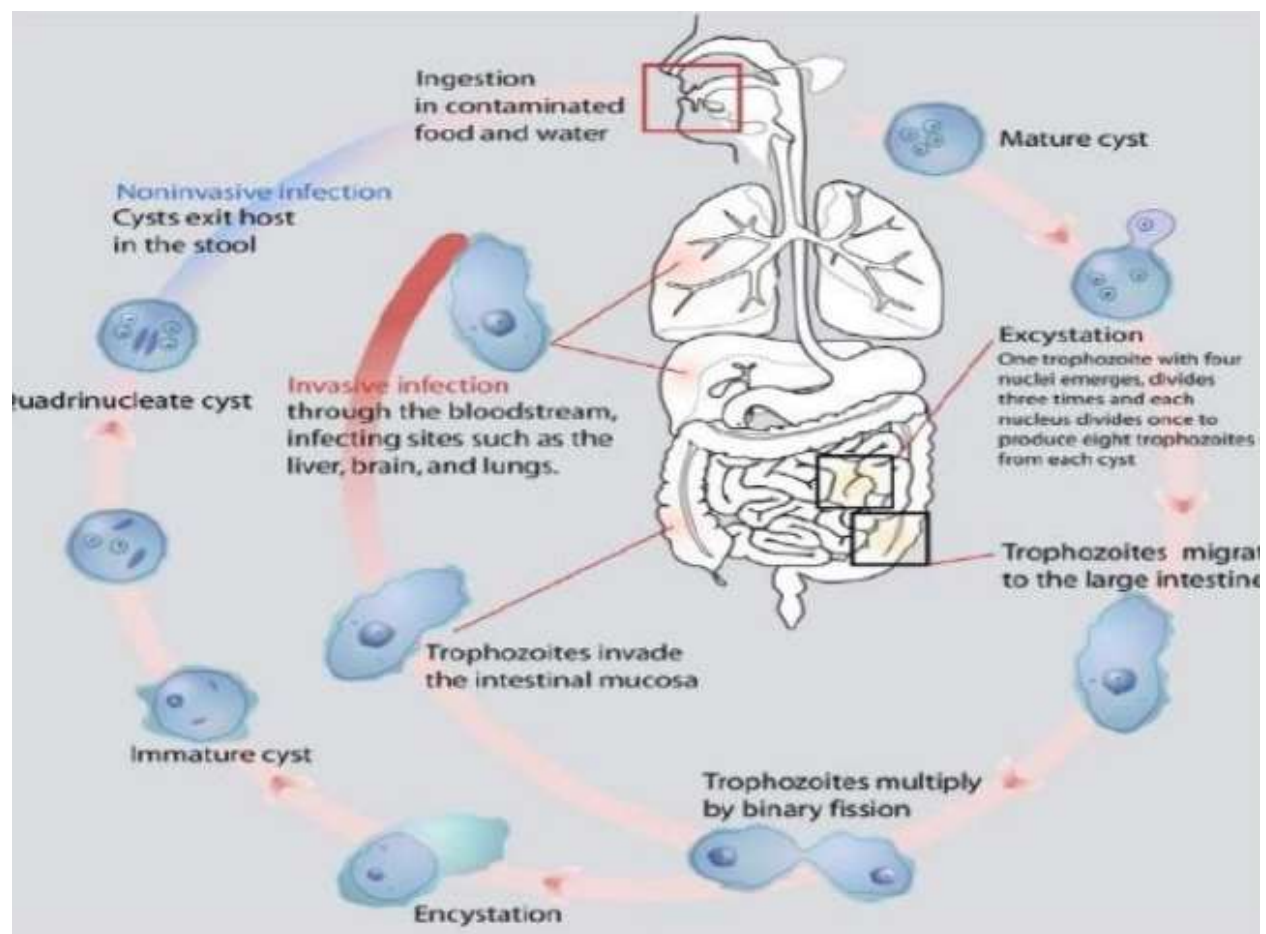
Some develop into precystic forms and cysts, which are passed in feces to repeat the cycle .

In most of the cases, *E. histolytica* remains as a commensal in the large intestine without causing any ill effects. Such persons become carriers or asymptomatic

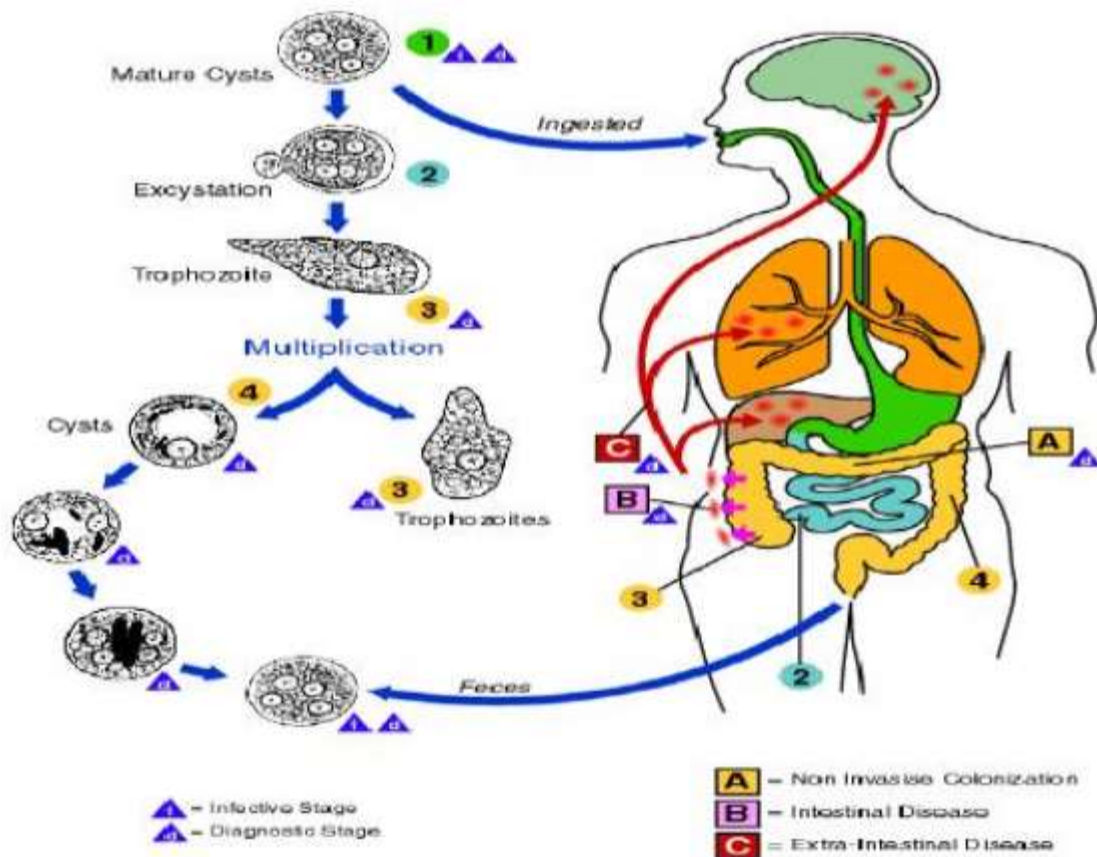
Sometimes, the infection may be activated and clinical disease ensues

In some patients the trophozoites invade the intestinal mucosa and cause intestinal disease or developed perforated ulcer .

the trophozoites migrate through the blood stream to invade the extra intestinal organs such as the liver, brain, and lungs and it will cause amoebic infection in these organs.



Life cycle of *E. histolytica*:



Pathogenesis and Clinical Features

E. histolytica causes intestinal and extraintestinal amoebiasis.

Incubation period ranges from 4 days to 4 months. Pathogenesis depend on

- 1- The resistance of the host .
- 2- The number of the amebas.
- 3- Presence of pathogenic bacteria.
4. Presence of physical & chemical injury of the mucosa

Intestinal Amoebiasis

The lumen-dwelling amoebae do not cause any illness

Amoebiasis occur only when they invade the intestinal tissues in about 10% of cases of infection, the remaining 90% being asymptomatic .

The metacystic trophozoites penetrate the columnar epithelial cells in the crypts the colon.

Penetration of the amoeba is facilitated by the motility of the trophozoites and the tissue lytic enzyme, which damages the mucosal epithelium, leading to form ulcers with pinhead center and raised edges.

Sometimes, the invasion remains superficial and heals spontaneously.

More often, the amoeba penetrates to submucosal layer and multiplies rapidly, causing abscess then breaks down to form an ulcer.

The typical amoebic ulcer is flask-shaped in cross section, with mouth and neck being narrow and large rounded base.

The amoebas usually found on the floor of the base of ulcer the ulcers may involve the muscular and serous coats of the colon, causing perforation, hemorrhage and peritonitis.

The superficial lesions generally heal without scarring, but the deep ulcers form scars which may lead to strictures, partial obstruction.

Chronic ulcer leads to amoebic granuloma or amoeboma may be mistaken for a malignant tumor.

E. histolytica in the large intestine (Flask shape ulcer)

Clinical Features of Intestinal Amoebiasis

The majority of infections with

E. histolytica

show 90% a symptoms or show symptoms

which varies from mild to intense and long lasting **general discomfort, loss of appetite, and weight loss with general malaise. Symptoms may develop within 4 days of exposure, may occur up to a year later, or may never occur.**

Amoebic dysentery (Bloody diarrhea), abdominal cramps, nausea and vomiting, and an urgent desire to defecate

Hepatic Amoebiasis

about 2–10% of the individuals infected with *E. histolytica* suffer from hepatic complications.

The history of amoebic dysentery is absent in more than 50% of cases.

Several patients with amoebic colitis develop an enlarged tender liver without detectable impairment of liver function or fever

The incidence of liver abscess is less common in women and rare in children under 10 years of age

Pulmonary Amoebiasis

ery rarely, primary amoebiasis of the lung may occur by liver direct hematogenous spread from the colon bypassing the The patient presents with severe pleuritic chest pain, dyspnea, and non-productive cough..

Metastatic Amoebiasis

Involvement of distant organs is by hematogenous spread and through lymphatics. Abscesses in kidney, brain, spleen, and adrenals have been noticed.

Spread to brain leads to severe destruction of brain tissue and is fatal.

Cutaneous Amoebiasis

It occurs by direct extension around anus, colostomy site,

Genitourinary Amoebiasis

Amoebiasis which is acquired through anal intercourse.

Differential Features of Amoebic and Bacillary Dysentery

Features	Amoebic dysentery	Bacillary dysentery
Clinical		
Onset	Slow	Acute
Fever	Absent	Present
Toxicity	Absent	Present
Abdominal tenderness	Localised	Generalised
Tenesmus	Absent	Present
Stool		
Frequency	6-8 per day	Over 10 per day
Odor	Offensive	Nil
Color	Dark red	Bright red
Nature	Feces mixed with blood and mucus	Blood and mucus with little or no feces
Consistency	Not adherent	Adherent to container
Reaction	Acid	Alkaline
Microscopy		
Cellular exudates	Scanty	Abundant
Red blood cells	Clumped yellowish brown	Discrete or in rouleaux, bright red
Macrophages	Few	Several, some with ingested red blood cells
Eosinophils	Present	Absent
Charcot-Leyden crystals	Present	Absent
Motile bacteria	Present	Absent
Amoeba	Motile trophozoites with ingested red blood cells	Absent

The complications of intestinal amoebiasis:

- 1- Appendicitis .
- 2- Intestinal perforation .

3- Hemorrhage .

4- Liver abscess.

5- Ameboma (Granulomas)

6-Fulminant amoebic colitis

7-Toxic megacolon

8-Perianal ulceration

Extraintestinal Amoebiasis

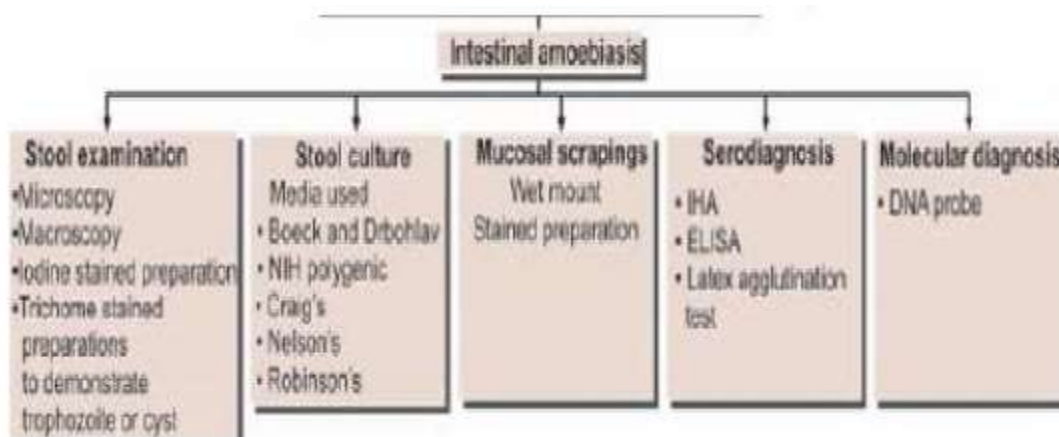
The metastasis of amoeba usually via blood stream or by direct extension after intestinal perforation to the peritonium.

The amoeba may cause local abscess or peritonitis or migrate to the liver which is the most commonly affected than other organs e.g, lungs, perianal skin and brain.

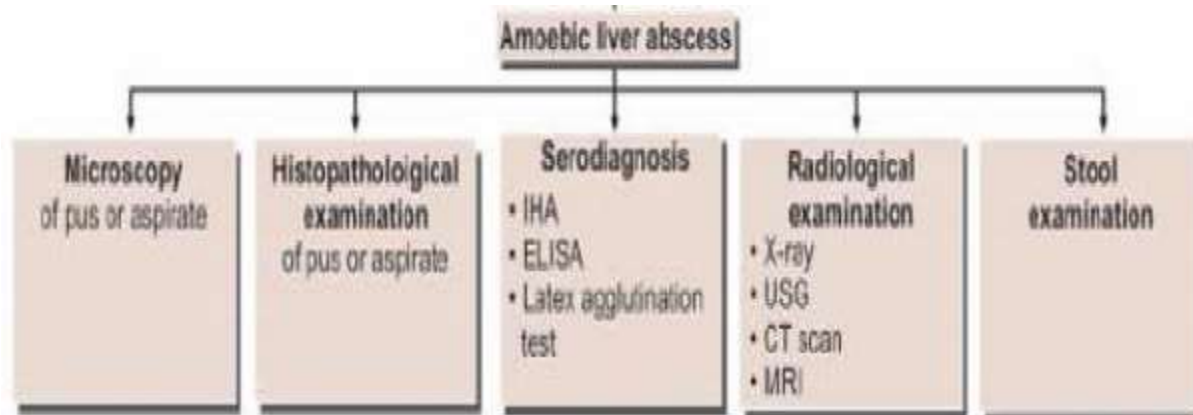
Complication of extraintestinal amoebiasis

1. Amoebic hepatitis
2. Amoebic liver abscess
3. Amoebic appendicitis and peritonitis
4. Pulmonary amoebiasis
5. Cerebral amoebiasis ,Splenic abscess
6. Cutaneous amoebiasis
7. Genitourinary amoebiasis

Laboratory diagnosis of intestinal Entamoeba histolytica



Laboratory diagnosis of amoebic liver abscess



Treatment

Three classes of drug are used in the treatment of amoebiasis.

1-Luminal amoebicides: paromomycin 30 mg/kg 4 times a day or tetracycline iodoquinol 650 mg orally, three times a day for 20 days act in the intestinal lumen but not in tissues.

2-Tissue amoebicides: Emetine, chloroquine, etc. are effective in systemic infection, but less effective in the intestine.

3-Both luminal and tissue amoebicides: Metronidazole (750 mg three times a day, orally or IV for 7 days) tinidazole 2 g/day orally for 3 days) and ornidazole act on both sites and are the drug of choice for treating amoebic colitis and amoebic liver abscess.

Patients should remain in bed rest with oral rehydration and electrolyte replacement should be done.

Prevention & Control :

1- All human infections should be treated

2- A symptomatic carriers should be treated especially those working in restaurants.

3- Effective environmental sanitation is necessary to prevent water, food, and vegetable contamination, e.g. Sewage disposal should be treated with chemicals before used as fertiliser in gardens.

4- Chlorination & filtered water supply are important to kill the *E. histolytica*.

5- Insects should be controlled by insecticides.

6- Uncooked vegetables should be washed with running water. .

NON PATHOGENIC AMOEBA

These parasites are commensals none pathogenic but they are important because they may be confused with *E.histolytica*

.

The most none pathogenic amoebas affecting human being are:

1- *E.coli*. 2- *E.gingivalis* . 3- *Dientamoeba fragilis*. 4-

Endolimax nana .

5- *Iodoamoeba butschlii* .

6- Other amoebas infecting human are morphologically very similar to *E.histolytica* e.g, *E.hartmanni* and *E.dispar* .

7- Free living amoebas are *Negleria* , *Acanthamoeba* are accidental parasites of human being .

The majority of these amoeba are non-pathogenic commensal parasites or only cause mild infection.

Entamoeba. coli

It is worldwide in distribution and a nonpathogenic commensal intestinal amoeba .
life cycle only in one host

Infective form: Mature cyst

It is a parasite of the large intestine .

the *E. coli* medical importance because it may be mistaken for *E.histolytica*

.

It has two stages (trophozoite& cyst).

The important morphological features are.

trophozoite

It is larger than *E. histolytica* about 20–50 μm with sluggish motility and contains ingested bacteria but no red blood cells

The ectoplasm is not clear and it has small pseudopodia.

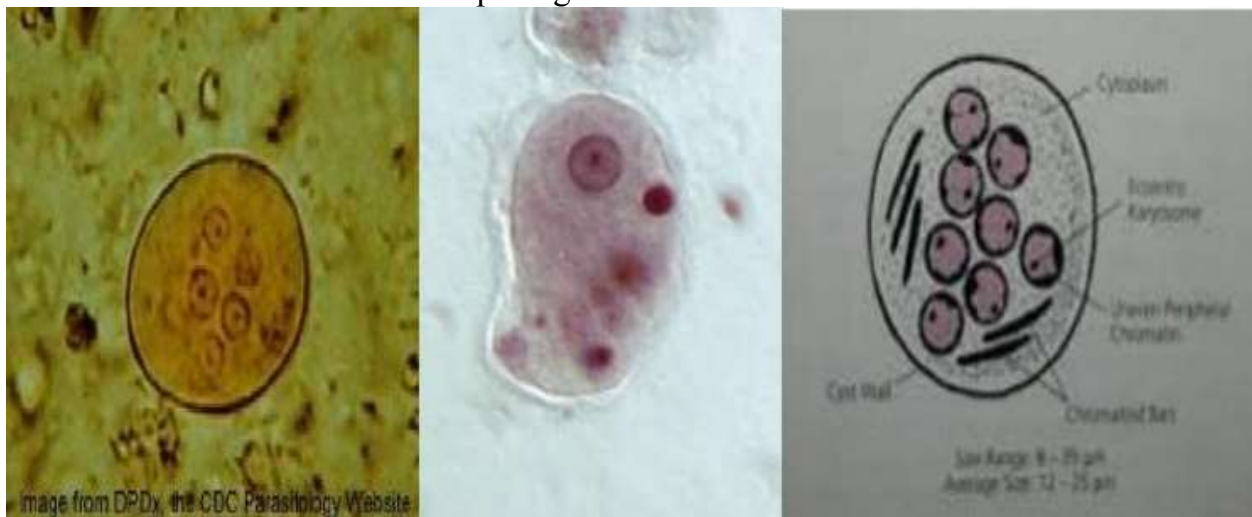
It has one nucleus contain large eccentric karyosome, and large chromatin granules arranged irregularly beneath nuclear membrane

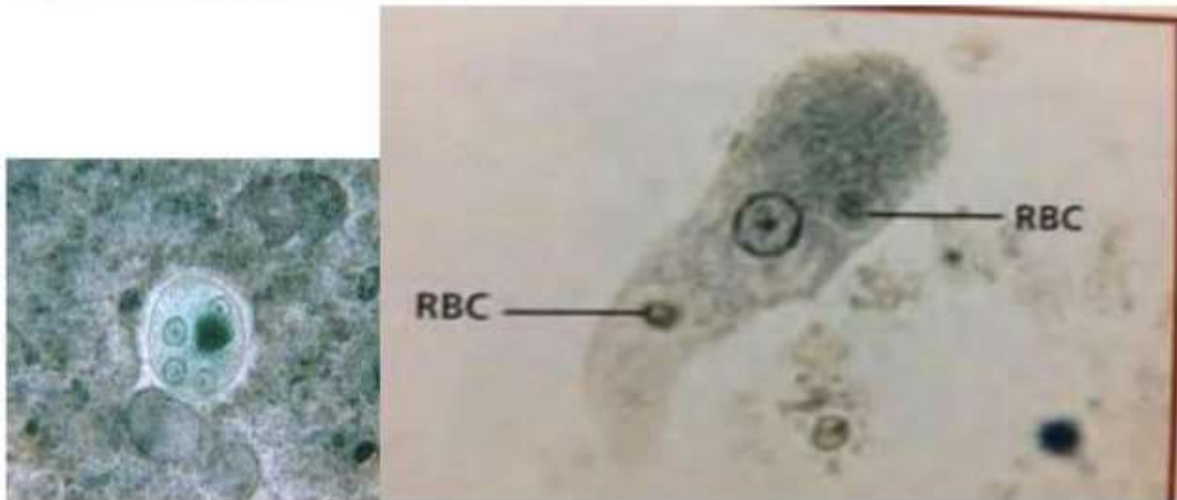
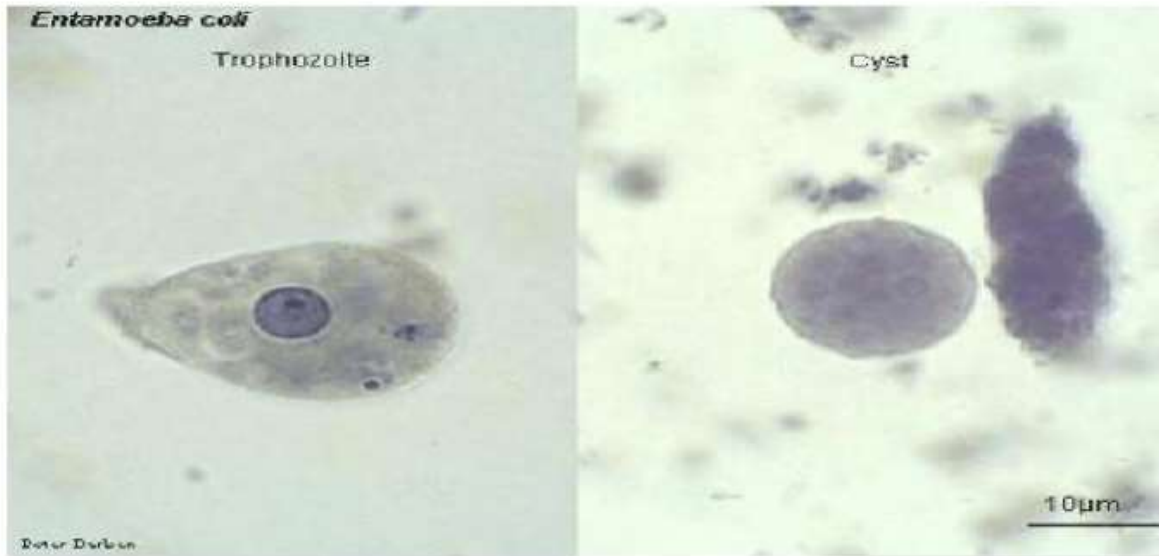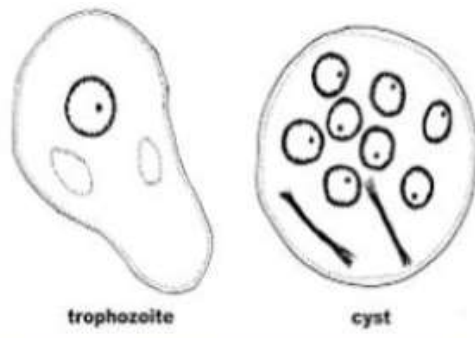
Cysts

are large oval in shape, 10–30 μm in size, with a prominent glycogen mass in the early stage.

The chromatoid bodies are splinter like and irregular. The mature cyst has 8 nuclei.

The life cycle is the same as in *E. histolytica* except that it remains a luminal commensal without tissue invasion and is nonpathogenic





Difference between *E. histolytica* and *E. coli*

	<i>E. histolytica</i>	<i>E. coli</i>
Trophozoite		
Size (µm)	12–60	20–50
Motility	Active	Sluggish
Pseudopodia	Finger-shaped, rapidly extruded	Short, blunt slowly extruded
Cytoplasm	Clearly defined into ectoplasm and endoplasm	Differentiation not distinct
Inclusions	RBCs present, no bacteria	Bacteria and other particles, no RBCs
Nucleus	Not clearly visible in unstained films	Visible in unstained films
Karyosome	Small, central	Large, eccentric
Nuclear Membrane	Delicate, with fine chromatin dots	Thick, with coarse chromatin granules
Cyst		
Size (µm)	10–15	10–30
Nuclei in mature cyst	4	8
Glycogen mass	Seen in uninucleate, but not in quadrinucleate stage	Seen up to quadrinucleate stage
chromidial	1–4 with rounded ends	Splinter like with angular ends

Parasitology Lecture.4 NON PATHOGENIC AMOEBAS

- 1- *E.coli*.
- 2- *E.gingivalis* .
- 3- *Dientamoeba fragilis*.
- 4- *Endolimax nana* .
- 5- *Iodoamoeba butschlii*
- 6- *E.hartmanni*
- 7- *E.dispar*

Endolimax Nana

This common commensal amoeba is widely distributed.

Habitat in the human large intestine.

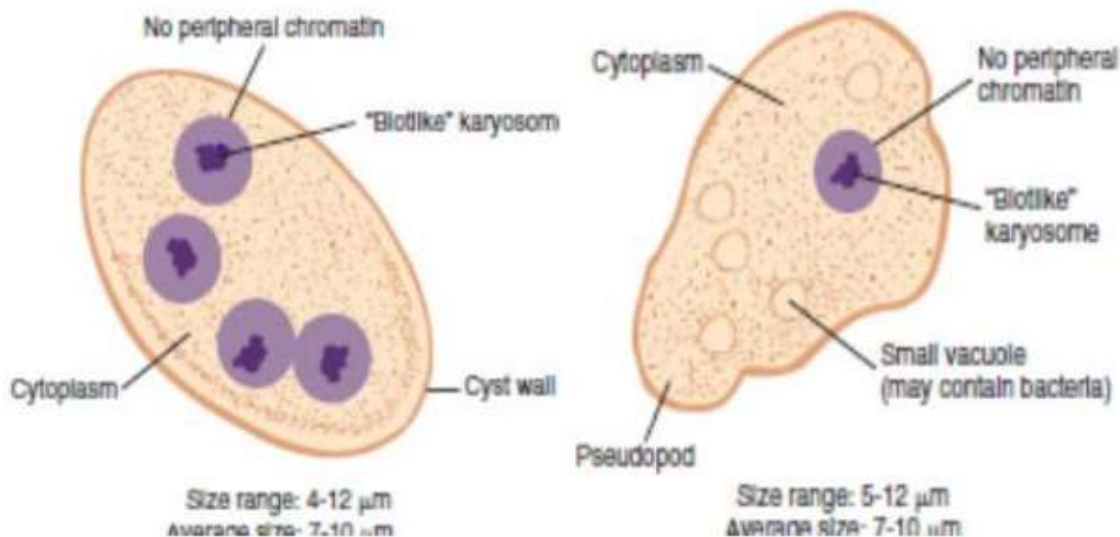
The trophozoite is small (nana: small), less than 10 μm in size with a sluggish motility .

The nucleus small contains a large blot-like(karyosome)

There is little or no peripheral chromatin

The cyst is small 5 μm size, oval in shape , and quadrinucleate with glycogen mass and chromidial bars, which are inconspicuous or absent .

It is non-pathogenic



Entamoeba Hartmanni

It occurs wherever *E. histolytica* is found.

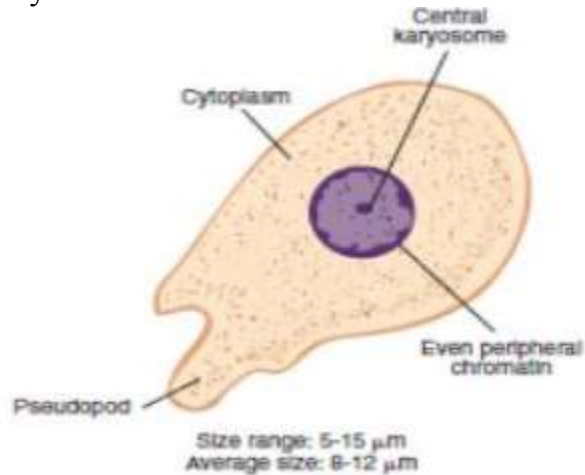
It is a separate species of non pathogenic commensal intestinal amoeba.

It is much smaller than *E. histolytica*, called (small race) of *E.histolytica*

the trophozoite measuring 4–12 μm , the cyst 5–10 μm in size with 1-4 nuclei.

Trophozoites do not ingest red cells and their motility is less vigorous.

The cyst resembles that of *Endolimax nana*.



Entamoeba Gingivalis

It is global in distribution.

It is a commensal, non pathogenic

Habitat in the mouth (gingival tissues), tonsillar crypts and bronchial mucus.

the organism thrives in diseased gums, but is not considered a causal agent, It is destroyed in stomach if swallowed.

Only the trophozoite is found; no cystic stage.

The trophozoite is about 10–20 μm , actively motile with multiple pseudopodia.

Cytoplasm contains food vacuoles with ingested bacteria, leucocytes, and epithelial cells.

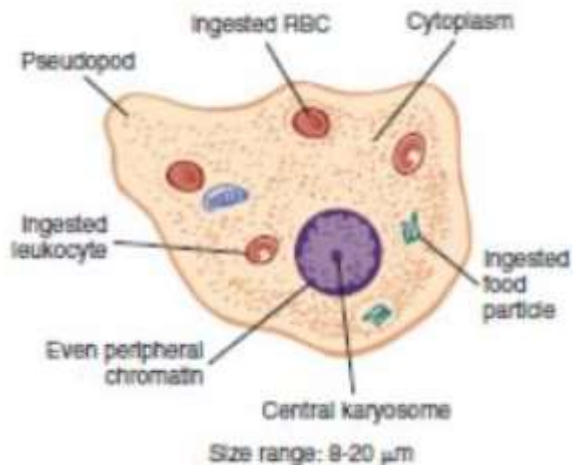
the only species which ingests leucocytes

Nucleus is round with central karyosome lined by coarse chromatin granules

The amoeba lives in gingival tissues and is abundant in unhygienic mouths.

It is transmitted by direct oral contact, kissing, contact with fomites (drinking glasses, eating utensils, etc.)

E. gingivalis have been found in bronchial washings and vaginal and cervical smears, where it can be mistaken for *E. histolytica*



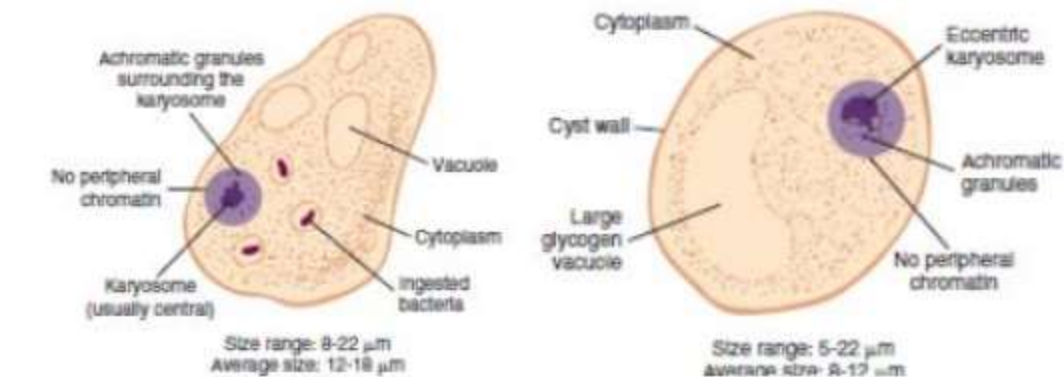
Iodamoeba butschlii

widely distributed, but less common than *E. coli* and *Endolimax Nana*.

The trophozoite is small, 6–2 μm , with single nucleus, the prominent karyosome is half the size of the nucleus having bull's eye appearance,

The cyst is oval, uniuclate, and has a prominent iodine staining glycogen mass (iodophilic body).

the cyst is often called the “iodine cyst” due to the presence of a large glycogen vacuole which stains dark brown with iodine.



Dientamoeba Fragilis

D. fragilis was previously considered as an amoeba but has now been reclassified as an amoeboflagellate.

based on electron microscopic study and antigenic similarity to *Trichomonas*.

The name *D. fragilis* is derived from the binucleate nature of trophozoite (*Dientamoeba*)

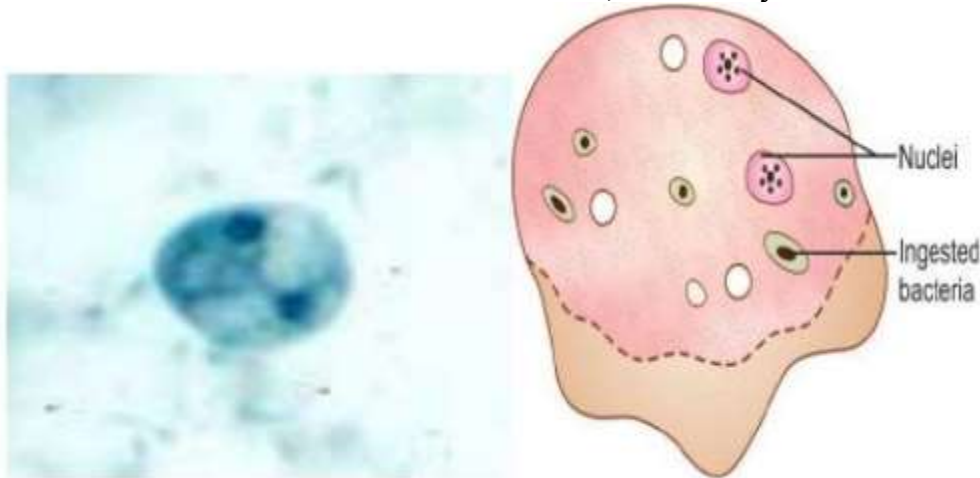
and the fragmented appearance (fragilis) of its nuclear chromatin

It is worldwide infection . the most common intestinal protozoan in Canada.

It lives in colonic mucosal crypts, feeding on bacteria. It does not invade tissues, but may rarely ingest RBCs it has only trophozoite stage ,but no cyst stage.

The trophozoite is 7–12 μm in diameter. It is motile with broad hyaline leaflike pseudopodia.

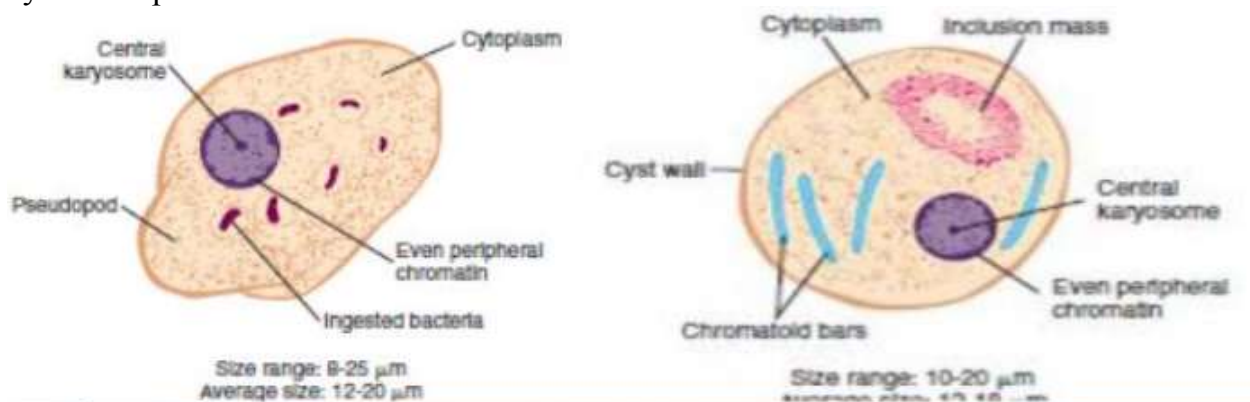
They have 1-4 nuclei; the binucleate form being the most common , with no peripheral chromatin on the nuclear Membrane transmitted by the fecaloral route or by the eggs of *Enterobius vermicularis* and other nematodes, which may serve as a vector



Entamoeba polecki

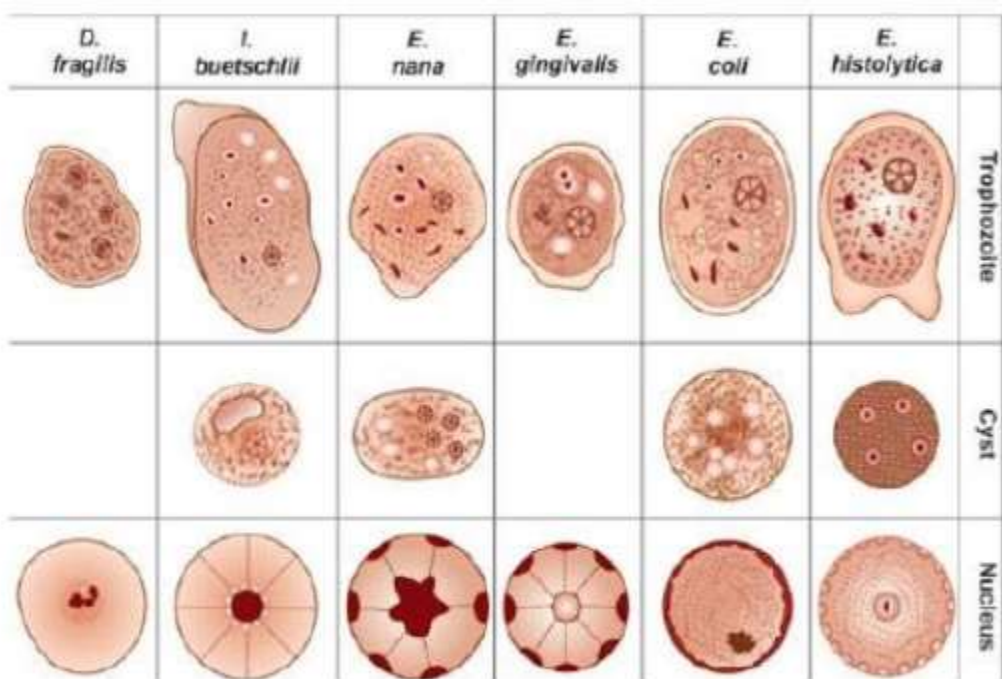
E. polecki is usually a parasite of pigs and monkeys.

rarely it occurs in humans, non pathogenic ,distinguished from *Entamoeba histolytica* the cysts of *E. polecki* have one nucleus



Parameter	Description
Size range	8-25 μm
Motility normal stools	Sluggish, nonprogressive
Motility diarrheal stools	Progressive, unidirectional
Number of nuclei	One
Karyosome	Small and central
Peripheral chromatin	Fine and evenly distributed
Cytoplasm	Granular and vacuolated
Cytoplasmic inclusions	Ingested bacteria Other food particles

Parameter	Description
Size range	10-20 μm
Shape	Spherical or oval
Number of nuclei	One
Karyosome	Small and central
Peripheral chromatin	Fine and evenly distributed
Cytoplasm	Granular
Cytoplasmic inclusions	Chromatoid bars, angular or pointed ends in young cysts Glycogen mass in young cysts Inclusion mass



Balantidium coli .

Balantidium coli belongs to the Phylum Ciliophora and Family Balantididae.

the organism was named Balantidium, which means “little bag or sac like appearance

It is the Largest ciliate protozoan parasite of humans .

It is present worldwide, but the prevalence of the infection is very low.

The most endemic area is New Guinea, where there is a close association between man and pigs .

Habitat

B. coli resides in the large intestine of man, pigs, and monkeys.

Morphology

Balantidium coli occurs in 2 stages: trophozoite, cyst

Trophozoite

The trophozoite lives in the large intestine, feeding on cell debris, bacteria, starch .

The trophozoite is actively motile and is invasive stage of the parasite found in dysenteric stool.

It is a large ovoid cell, about 50-150 μm in length and 35–50 μm wide.

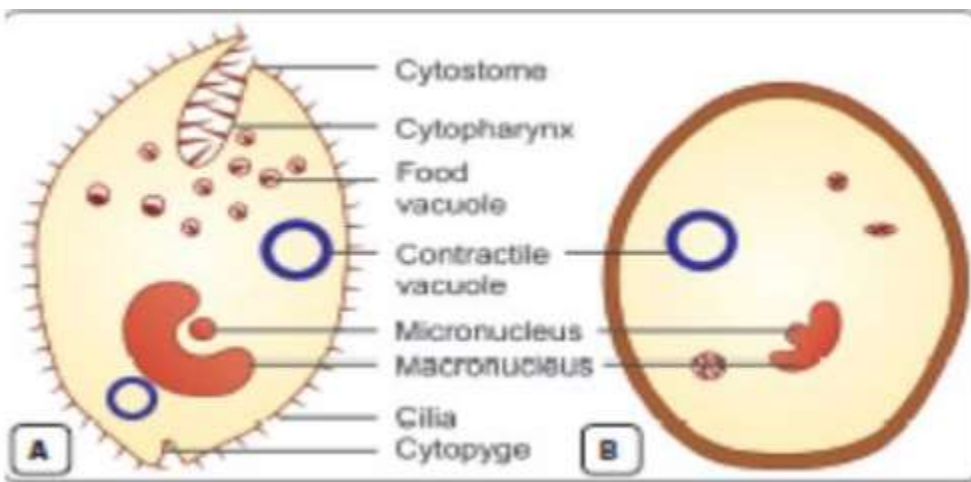
The motility of trophozoite is due to the presence of short delicate cilia over the surface of the body.

The cilia around the mouth are longer than other

Its anterior end is narrow and posterior end is broad.

At the anterior end, there is a groove (peristome) leading to the mouth (cytostome), and a short funnel shaped gullet (cytopharynx).

Posteriorly, there is a small anal pore (cytopyge).



The trophozoite has 2 nuclei—a large kidney-shaped macronucleus and lying in its concavity a small micro nucleus.

The cytoplasm has 1 or 2 contractile vacuoles and several food vacuoles.

Cyst

The cyst is spherical in shape and measures 40–60 μm in diameter.

It is surrounded by a thick and transparent double layered wall.

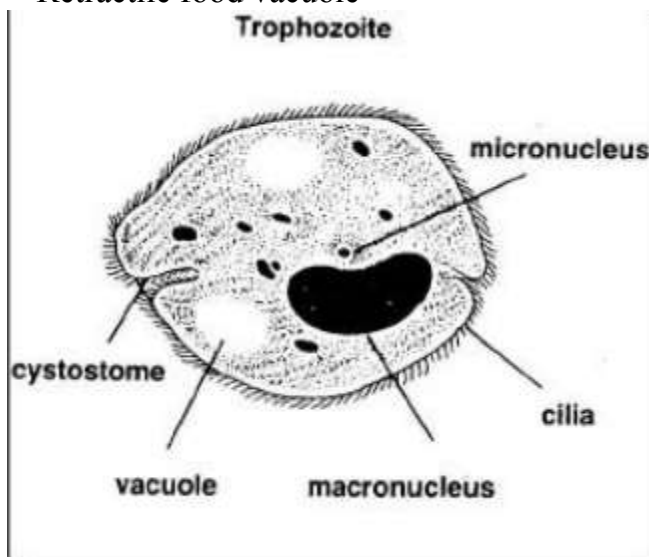
The cytoplasm is granular. Macronucleus, micro nucleus, and vacuoles are also present

in the cyst. The cyst is the infective stage of *B. coli*.

It is found in chronic cases and carriers.

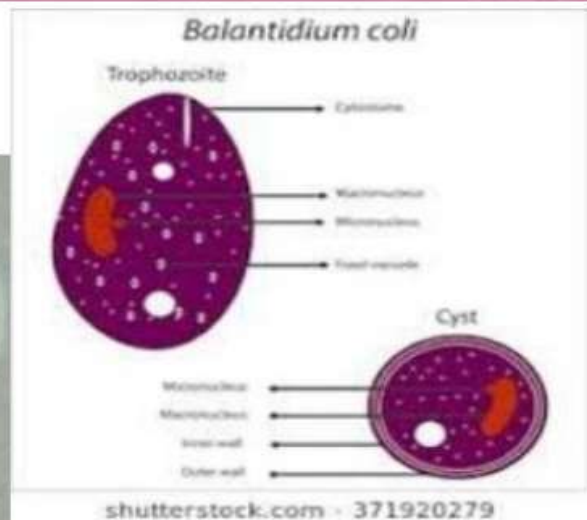
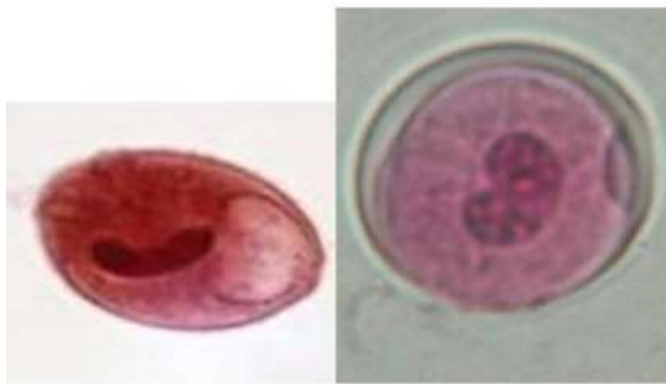
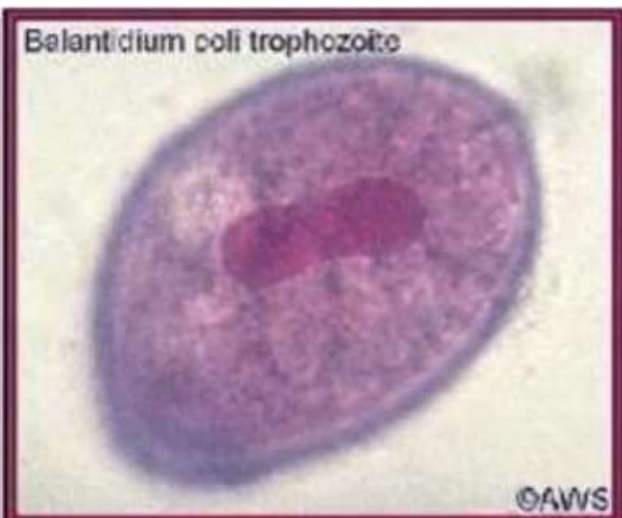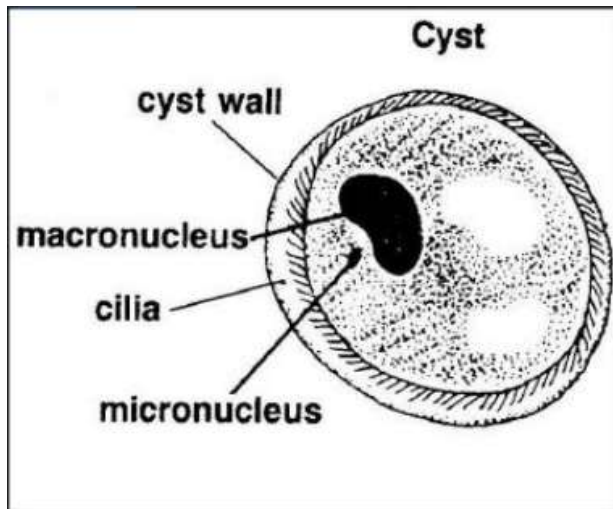
Trophozoite Morphology

- Ciliated parasite
- Oval shape
- Greenish yellow color size 50-150 μm
- Large Kidney or bean shape Macronucleus
- Small micronucleus
- Retractable food vacuole



Cyst morphology

- 40-60 μm
- Spherical shape
- Cyst wall is thick consist
- of 1-2 layers
- No cystostome
- Macronucleus ,
- micronucleus
- Contractile vacuules
- No cilia



Life Cycle

Balantidium coli need one host only.

Natural host: Pig.

Reservoirs: Pig, monkey, and rat.

Accidental host: Man

Infective form: Cyst.

Balantidiasis is a zoonosis.

Human beings acquire infection by ingestion of food and water contaminated with feces containing the cysts of B. coli.

Infection is acquired from pigs and other animal reservoirs or from human carriers.

Once the cyst is ingested, excystation occurs in the small intestine, from each cyst, a

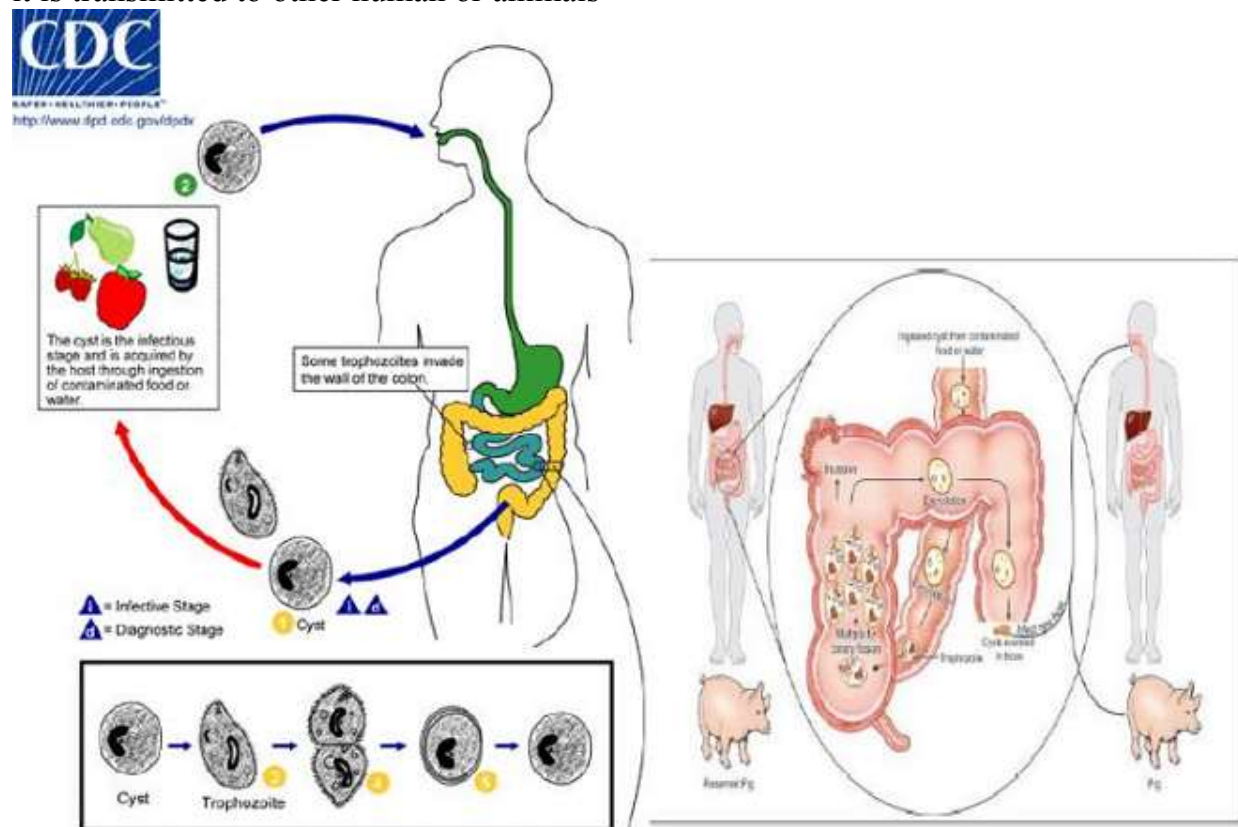
single trophozoite is produced which migrates to large intestine liberated trophozoites multiply in the large intestine by transverse binary fission .

Encystation

occurs as the trophozoite passes down the colon or in the evacuated stool.

In this process, the cell rounds up and secretes a tough cyst wall around it.

The cysts remain viable in feces for 1-2 day and may contaminate food and water, thus it is transmitted to other human or animals



Pathogenesis

Balantidium coli lives as lumen commensal and is asymptomatic

Clinical disease occurs only when the resistance of host is lowered by predisposing factors like malnourishment, alcoholism, infection by *Trichuris trichiura*, or any bacterial infection. Clinical disease results when the trophozoites burrow into the intestinal mucosa, leads to mucosal ulcers and submucosal abscesses, resembling lesions in amoebiasis. *B. coli* has been known to invade areas other than the intestine, such

has the liver, lungs, pleura, mesenteric nodes, and urogenital tract.

However, the incidence of such extraintestinal infections is rare.

Clinical Features

Most infections are asymptomatic.

balantidiasis resembles amoebiasis causing diarrhea or frank dysentery with abdominal colic, tenesmus, nausea, and vomiting.

Balantidium ulcers may be secondarily infected by bacteria.

Occasionally, intestinal perforation peritonitis and even death may occur.

Rarely involvement of urogenital tracts.

In chronic balantidiasis, patients have diarrhea alternating with constipation

Diagnosis:

1-demonstration of trophozoites and cysts in feces

2-biopsy specimens and scrapings from intestinal ulcers .

3-Culture, cultured in vitro in Locke's egg albumin medium or NIH polyxenic medium

Treatment

Tetracycline is the drug of choice and is given 500 mg, 4 times daily for 10 days.

Alternatively Doxycycline can be given.

Metronidazole and nitroimidazole have also been reported to be useful in some cases

Prophylaxis.

1- prevent contamination of food and water with human or animal feces.

2-Prevent contact of human with infected pig .

3- Treatment of infected pigs .

4- Treatment of infected man ,carriers

Blood and tissue protozoa

Objectives:

1. Introduction to kinetoplastids
2. Hemoflagellates :
 - General features
 - Leishmaniasis
 - Epidemiology, transmission and risk factors
 - Biology and life cycle
 - Clinical types of leishmaniasis :

Cutaneous leishmaniasis

Mucocutaneous leishmaniasis

Introduction

- Several pathogenic protozoa can infect human and localized in the blood and tissues:

A. Kinetoplastids

- Kinetoplastids are a large , diverse group of **flagellated protozoa characterized by a Geimsa-stained structure known as a kinetoplast**

• **The kinetoplast is a specialized region of the mitochondria and the intense staining by Geimsa stain is due to mitochondrial DNA. The kinetoplastids have more mitochondrial DNA than other eukaryotes resulting in a more intense staining.**

θ **Leishmania spp.:** that cause leishmaniasis:

- *Leishmania donovani complex*
- *L. infantum*
- *L. tropica complex*
- *L. mexicana*
- *L. braziliensis*
- *L. chagasi*

θ **Trypanosoma**

- *Trypanosoma brucei gambiense*: sleeping sickness.
- *Trypanosoma brucei rhodesiense*: sleeping sickness.
- *Trypanosoma brucei brucei*, does not infect humans.
- *Trypanosoma cruzi* causes Chagas ' disease
- *Trypanosoma rangeli*

B. Apic(K)omplexa(Sporozoa, Apikomplexia)

- Unicellular obligate intracellular (endoparasites) spore-forming protozoa.
- Possess a complex apical structure containing plastid and organelles used for penetration of a host cell.

They include:

θ *Plasmodium* : Causes malaria

- *Plasmodium vivax*
- *Plasmodium falciparum*
- *Plasmodium ovale*
- *Plasmodium malariae*

θ *Babesia* : babesiosis

θ *Toxoplasma gondii* : toxoplasmosis

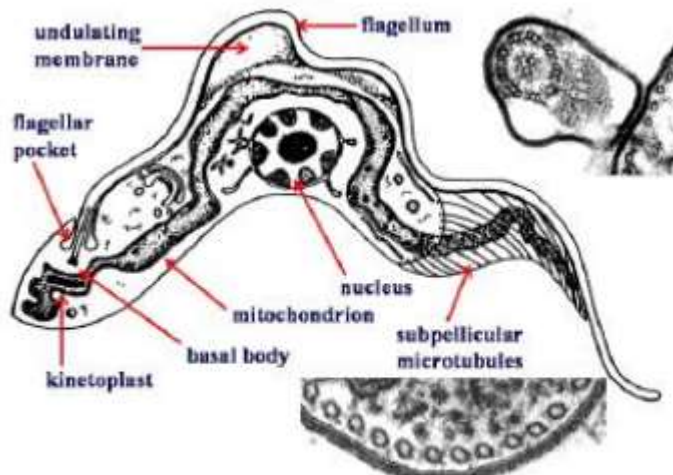
Hemoflagellates

Classification of flagellates: لاطالع

- *Phylum: Sarcomastigophora*
- *Subphylum: Mastigophora*
- *Class: Kinetoplastida*
- *Order: Trypanosomatida*
- *Family: Trypanosomatidae*
- *Genera: Leishmania and Trypanosoma*

General features of flagellates

- They live in the blood & tissues of man & other vertebrates, and in the gut of the insect vectors.
- They have a single nucleus, a kinetoplast and a single flagellum
- The flagellum is a thin, hair-like structure, which originates from the blepharoplast.
- A free flagellum at the anterior end traverses on the surface of the parasite as a narrow undulating membrane .

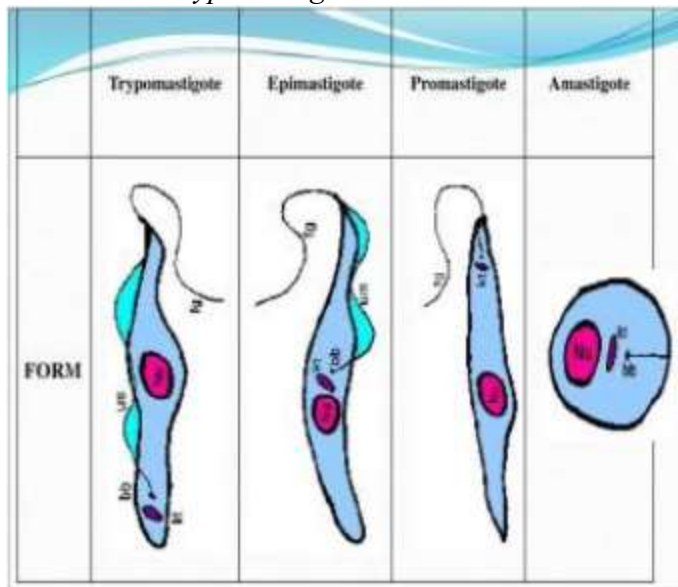


Flagellates(2)

- **Nucleus** is round or oval, and is situated in the central part of the body.

- Hemoflagellates exist in **TWO** or more of four morphological stages:

1. *Amastigote*
2. *Promastigote*,
3. *Epimastigote*
4. And *Trypomastigote*.



Forms of kinetoplastids(3).

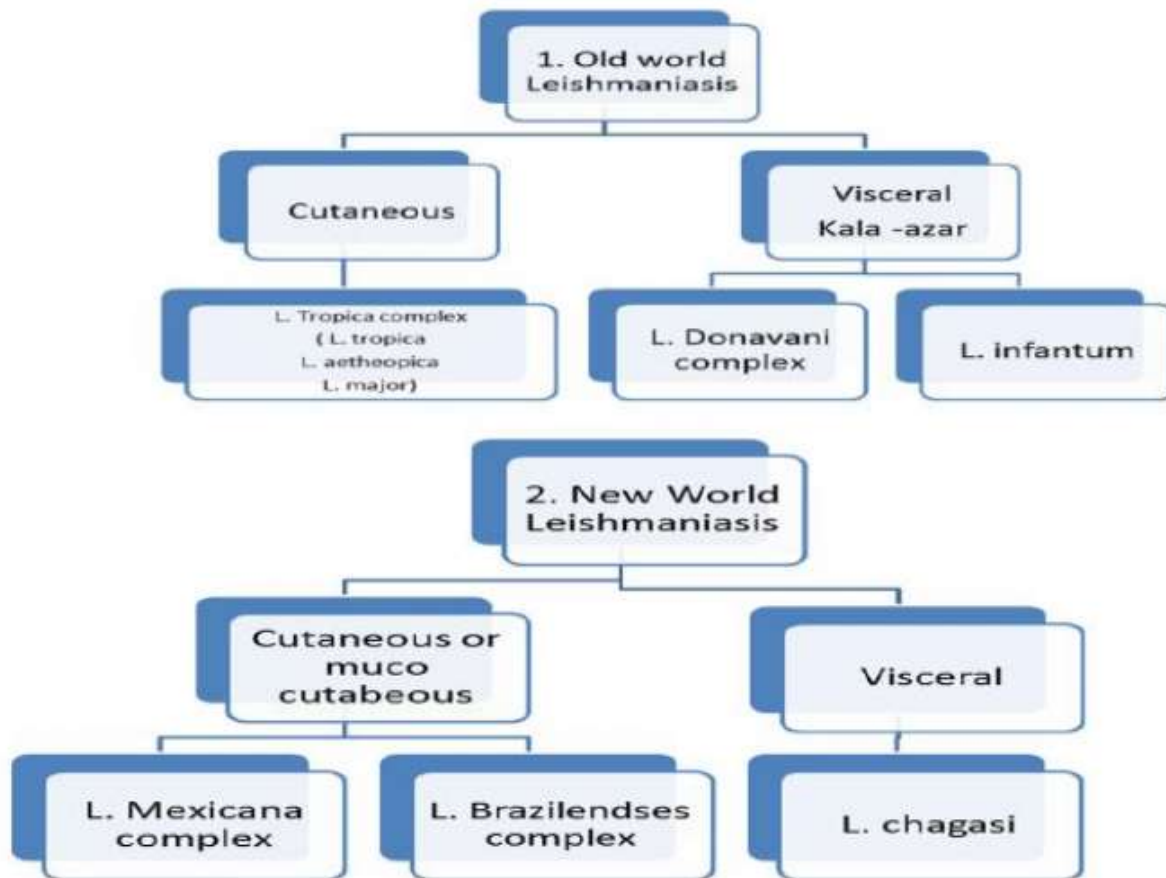
- Members of this family require an insect vector as an intermediate host.
- Multiplication in both the vertebrate and invertebrate hosts is by *binary fission*.
- Have no sexual cycle.
- **Staining characteristics :**
 - o For smears of body fluids: Romanowsky's Wrights stain, Giemsa stain and Leishman's stain are suitable for identifying internal structures. The cytoplasm appears blue, the nucleus and flagellum appear pink, and the kinetoplast appears deep red.
 - o For tissue section: Hematoxylin-eosin staining is done for demonstrating structures of the parasite.

Leishmaniasis

- Leishmaniasis is a tropical and subtropical disease caused by an intracellular parasite .
- The parasite is categorized in two main groups:
- The old world species: occur in Europe, Africa and Asia.
- The new world species : occur in America.
- More than 50 species of the parasite have been described from different regions of the world.
- 31 species are known to be parasites of mammals, 20 species are pathogenic for human

beings.

Distribution and diseases caused by *Leishmania* spp



Epidemiology

- Worldwide distribution.
- It is found in about 102 countries.
- It is endemic in Asia, Africa, the Americas, and the Mediterranean region.
- Between 12 and 15 million people in the world are infected.
- 350 million are at risk of acquiring the disease.
- An estimated 1.5 to 2 million new cases occur each year.
- It causes 70,000 deaths per year.

Transmission:

∪ *Leishmania* spp. are spread by sandflies(vectors, **intermediate host**):

- a. Genus *Phlebotomus* in the Old World
- b. Genus *Lutzomyia* in the New World

Leishmania commonly infect canids, rodents(reservoir host) , and humans (final host).

∪ Transmission via blood transfusion has been approved in animal experiments.

∪ Transmission may occur through contaminated syringes and other paraenteral routes.

People at risk:

The main risk groups to get infection are:

- Farmers
- loggers
- Hunters
- Military personnel
- Biologists
- Ecological tourists
- Elderly and children
- Malnourished and immune deficient diseases.
- Those live under overcrowding, poor housing conditions and low socioeconomic status can increase chance to get infection.

Morphological forms(variants)

Depending on the stage of their lifecycle, they exist in two structural variants:

A. Amastigote

B. Promastigote

1. Amastigote form (Leishman-Donovan (LD) body):

- It is found in the mononuclear cells, neutrophils and reticulo endothelial system.
- Round or oval in shape.
- 3-6 micron X 1.5-3.0 micron.
- Have single nucleus with large central karyosome.
- The kinetoplast (which consists from blepharoplast and parabasal body beside it) lies at right angle to the nucleus.
- No visible flagellum (non motile).
- Amastigotes are usually grown inside tissue culture cells

2. Promastigote (leptomonad) form:

- Is found in the alimentary tract of sandflies.
- Elongated (spindle in shape).
- 15-30 micron in body length and 5micron in width
- Have centrally located nucleus and the kinetoplast situated at the anterior end.
- From blepharoplast, single free flagellum projects from the anterior end.
- This form has no undulating membrane.
- **Promastigotes can be grown in vitro at 24-26° using NNN media.**

Life cycle of *Leishmania* spp.:

- Leishmaniasis is transmitted by the bite of infected female sandflies.
- The sandflies inject the infective stage (i.e., promastigotes) from their proboscis during blood meals.

- Promastigotes that reach the puncture wound are phagocytized by macrophages and other types of mononuclear phagocytic cells. Promastigotes transform in these cells into the tissue stage of the parasite (i.e., amastigotes).

The amastigotes multiply by simple division and proceed to infect other mononuclear phagocytic cells

- Parasite, host, and other factors affect whether the infection becomes symptomatic and whether cutaneous or visceral leishmaniasis result.
- Sandflies become infected by ingesting infected cells during blood meals.
- In the gut of sandflies, amastigotes transform into promastigotes.
- The promastigotes then migrate to the proboscis of the insect.
- The duration of the life cycle in the vector varies from 4 to 18 days, depending on the species of *Leishmania* and climate.
- Laboratory studies suggest that a *L. donovani* parasite load of 20,000 per mL of blood in the host is required to infect the sand fly insects.

Clinical types

Cutaneous leishmaniasis:

Muco-cutaneous leishmaniasis, cutaneous-mucosal, American cutaneous, or “Espundia”

Visceral leishmaniasis (Black fever, Dumdum fever)

Cutaneous leishmaniasis:

- The most common pathogens causing this lesion are *Leishmania tropica complex*
- Cause skin sores (also known as **oriental sore**, Baghdad boil, **tropical sore**, **Aleppo boil**, or Delhi Boil).
- It usually produces ulcers on the exposed parts of the body, such as the face, arms and legs.
- The incubation period is from 1 to 4 weeks.

Clinical forms of cutaneous leishmaniasis

- *Leishmania major*: Zoonotic cutaneous leishmaniasis: wet lesions with severe reaction
- *Leishmania tropica*: Anthroponotic cutaneous leishmaniasis: Dry lesions with minimal ulceration

Cutaneous leishmaniasis lesion is characterized by:

- Local increase in temperature, and swelling.
- An erythematous asymptomatic papule (1 to 10 mm in diameter) appears at the site of

the bite, although pruritus may be present.

- After 2 days, it turns into a vesicle and later into a pustule.
- It breaks either spontaneously or by scratching to give volcano like ulcer, with a raised edge and central crater.
- Such ulcers can last from 3 months to 20 years.
- The bottom of the ulcer shows granulation tissue that bleeds when rubbing and a pink periphery and sometimes is covered by a whitish pseudomembrane.
- The lesion is not painful if it is not secondarily infected.
- Ulcers may be solitary or multiple.
- The clinical picture is usually afebrile with regional adenopathy.

Muco-cutaneous leishmaniasis, cutaneous-mucosal, American cutaneous, or “Espundia”

- New world leishmaniasis in Central and South America. Caused by *L. braziliensis* complex and *L. mexicana* complex
- The amastigote form is seen inside the macrophages of skin and mucous membrane of the nose and buccal cavity. The promastigote form occurs in vector species *Lutzomyia*.
- It causes invasion and destruction of the nasopharyngeal mucosa.
- Usually, lesions start in the nasal mucosa and spread to the oral and pharyngeal mucosa, the larynx, and the skin of the nose and lips.
- Lesions of the oral mucosa usually produce symptoms that range from simple to severe in extreme cases.
- Early in the disease, there is inflammation of the mucosa with superficial ulcerations; later on, when the ulcers are well developed, their borders have a necrotic appearance and are torn and detached.
- The uvula, pillars of the palate roof, and tonsils can be destroyed. If the larynx is involved, the voice changes as well.
- Secondary infections usually occur.
- Destruction of the cartilaginous septum of the nose with foul smell can occur
- In extreme cases, it ends to death.

Chiclero ulcer

- also called as *self healing sore of Mexico*

Is a kind of American leishmaniasis caused by *Leishmania Mexicana*. The disease is characterized by cutaneous ulcers on the head and may last 6 months but if occurs on the pinna of the ear, it may last up to years leaving scarring and deformities.

Visceral leishmaniasis (Black fever, Dumdum fever)

Objectives:

♣Visceral leishmaniasis

- o Have an idea about history of Visceral leishmaniasis
- o Pathogenesis
- o Clinical features
- o Diagnosis
- o Treatment
- o Prevention and control

♣Leishmaniasis in Iraq

In 1900 Sir William Leishman from Scotland discovered Leishman Donavani bodies in a postmortem spleen smear of a soldier who died due to fever at Dum Dum, India.

The disease was known locally as Dum-Dum fever or Kal azar.

An Irish physician Charles Donovan also recognized the symptoms in other Kala-azar patients and published his discovery a few weeks after examining the parasite using Leishmans stain, So the parasite named Leishmania and the amastigote forms named Leishman Dnoavan bodies.

Pathogeneses:

L. donovani causes VL or kala-azar.

- Kala-azar is a reticuloendotheliosis resulting from the invasion of reticuloendothelial system by *L. donovani*.
- The parasitized macrophages disseminate the infection to all parts of the body.
- Three major surface membrane proteins of Leishmania: (1) *gp63*, (2) *lipophosphoglycan (LPG)* and (3) *glycosylphosphatidyl inositols (GPIs)* give protection against hydrolytic enzymes of macrophage phagolysosome.
- In the spleen, liver and particularly bone marrow, the amastigotes multiply enormously in the macrophages leading to "blockade" of the reticuloendothelial system, that causes marked proliferation and destruction of reticuloendothelia tissue in these organs.

Splenic changes:

- The spleen is the most affected organ.
- It is *grossly enlarged and the capsule is thickened due to perisplenitis*.
- Spleen is *soft, friable and easily ruptures due to absence of fibrosis*.
- The cut section is *red or chocolate in color due to the dilated and engorged vascular spaces*.

- Microscopically, the reticulum cells are greatly increased in numbers and are loaded with LD bodies.
- Lymphocytic infiltration is scanty, but plasma cells are numerous

Liver changes:

- The liver is enlarged.
- The Kupffer cells and vascular endothelial cells are heavily parasitized, but the hepatocytes are not affected.
- Prothrombin production is commonly decreased.
- The sinusoidal capillaries are dilated and engorged.
- Some degree of fatty degeneration is seen.
- The cut surface may show a "nutmeg" appearance.

Bone marrow and blood:

- The bone marrow is heavily infiltrated with parasitized macrophages, which may crowd the hematopoietic tissues.
- Severe anemia with haemoglobin levels of 5-10 g/Dl may occur in kala-azar, as a result of:
 - ↳ Infiltration of the bone marrow and marrow suppression by cytokines.
 - ↳ The increased destruction of erythrocytes due to hypersplenism.
 - ↳ Autoantibodies to red cells may contribute to hemolysis .
 - ↳ Hemorrhage
- Auto immune Leukopenia , neutropenia and thrombocytopenia
- Pancytopenia observed in kala-azar.

Ecological types:

θ *Indian visceral leishmaniasis: Caused by L. donovani*

- It produces the anthroponotic disease kala-azar and its sequel Post-kala-azar dermal leishmaniasis (PKDL).
- The disease is not zoonotic; human beings are the only host and reservoir.
- Vector is the sandfly, *P. argentipes*.

θ *Mediterranean leishmaniasis: Middle Eastern*

- Leishmaniasis caused by *L. donovani infantum* affecting mostly young children.
- It is a *zoonotic disease*; the reservoir being dogs and wild canines .
- Vectors are *P. perniciosus* and *P. papatasi*.

θ *American (New World) visceral leishmaniasis: Caused by L. chagasi*

- It presents in most parts of Latin America and resembles the disease caused by *L. infantum*.
- The main vector is *L. longipalpis*

Clinical features of kala-azar:

- The onset is typically insidious.
- High-grade fever which has twice daily spikes or intermittent or less commonly continuous.
- Progressive, massive, Soft, non tender splenomegaly that starts early.
- Moderate hepatomegaly
- Lymphadenopathy is common in most endemic areas.
- Skin becomes dry, rough and darkly pigmented (hence, the name kala-azar).
- The hair becomes thin and brittle.
- Cachexia , emaciation and loss of weight .
- Hematological abnormalities:
 1. Anemia always presents and is usually severe
 2. Leukopenia
 3. Thrombocytopenia is associated with epistaxis, gum bleeding gastrointestinal (GI) bleeding.
 4. Pancytopenia
 - Ascites and oedema may occur due to hypo albuminemia.
 - Renal impairment is also common.
 - Secondary infections such as herpes, measles, pneumonia, tuberculosis, bacillary dysentery may occur.
 - Most untreated patients die in about 2 years.

Diagnosis:

→ Microscopic examination:

- In Kala azar :Detection of **amastigotes** (LD bodies(Leishman-Donovan) in Giemsa stained smear of bone marrow, lymph nodes or liver.
- In cutaneous or mucocutaneous leishmaniasis: The amastigotes are found in the scraping of cutaneous or mucosal ulcerations (especially scraping of the borders) as well as in non-ulcerated lesions.
- Biopsy should be obtained from the active border of the skin and mucous lesions.

Examination of smear:

- It reveals the amastigote stage in free form or inside monocytes or less frequently in polymorphonuclear cells.
- Number of amastigotes ranges from 2 to 20 in a single cell.

→ Cultivation of aspirates:

Ø NNN (Novy- MacNeal-Nicolle) medium:

- Cultured in an incubator for a week.
- The incubation is under anaerobic conditions at 24-26°C
- Promastigotes are the parasite forms that grow in culture .

Ø Cell culture of monocytes using RPMI-1640 or Medium-199

- Incubation at 37°C
- The stage found will be amastigotes.

Note : Both techniques (microscopic exam and culture) have a sensitivity of 85%.

→ **Serology :**

↳ Detection of specific anti-leishmanial antibodies:

- IFAT (indirect immunofluorescent antibody test)
- DAT (Direct agglutination test)
- ELISA (enzyme linked immunosorbent assay): Determination of serum anti-Leishmania Abs used with a sensitivity of 90 to 100%.

↳ Leishmanin skin test (Montenegro test):

θ The Montenegro skin test is a tool for determining the degree of exposure and immunity to the parasite depending on development of delayed hypersensitivity(DHSR).

θ Intradermal injection at forearm by 0.1 ml suspension of killed promastigote.

θ Positive result is indicated by an induration of 5mm or more in 48-72 hours.

θ It is positive in cutaneous leishmaniasis.

A positive test supports the diagnosis especially when the patient does not live in endemic areas, but a negative test does not exclude it.

θ In active visceral leishmaniasis, the test is almost always negative and a positive result usually appears 2–24 months after clinical recovery. Thus this test has no role in the diagnosis of the acute disease.

→ **Molecular method:** PCR polymerase chain reaction is the most sensitive and specific diagnostic method.

Treatment:

- In general, all clinically manifest cases of visceral leishmaniasis and mucosal leishmaniasis should be treated.
- Not all cases of cutaneous leishmaniasis require treatment.

Some drugs used for treatment:

- 1- Sodium stibogluconate (Pentostam): highly effective therapy for visceral leishmaniasis.
- 2- Amphotericin B approved for treatment of visceral leishmaniasis.
3. other treatments as Pentamidine and paromomycin also used.

Post-kala-azar dermal leishmaniasis

PKDL

Post-kala-azar dermal leishmaniasis (PKDL) is a complication of visceral leishmaniasis (VL) in areas where *Leishmania donovani* is endemic.

It is characterized by:

- Hypopigmented macular rash
- Maculopapular rash
- Nodular rash.
- It usually occurs in patients who have recovered from VL .
- It usually appears 6 months to 1 or more years after apparent cure of the disease but may occur earlier or even concurrently with visceral leishmaniasis.

- It has important role in maintaining and transmission of the disease acting as a reservoir for parasites.

Diagnosis of post-kala-azar dermal leishmaniasis:

- The nodular lesions are biopsied and amastigote forms are demonstrated in stained sections.
- The biopsy material can be cultured or animal inoculation can be done.
- Immunodiagnosis has no role in the diagnosis of PKDL.

Treatment of post-kala-azar dermal leishmaniasis:

- Liposomal amphotericin-8 (AmBisome) or sodium stibogluconate (SSG)

Prevention of leishmaniasis:

- Prevention involves protection from sandfly bites by using netting, window screens, protective clothing, and insect repellents.

Leishmaniasis in Iraq:

Leishmaniasis is widespread in Iraq.

- Cutaneous leishmaniasis accounts for 2/3 of cases and visceral leishmaniasis accounts for 1/3.
- The peak transmission season typically begins in May.
- Maximum number of cases of Leishmaniasis were reported in 1992 and it was 45.5 cases per 100,000 of population

Visceral leishmaniasis:

- Is generally found in central and southeastern parts of Iraq.
- *L. donovani* and *L. Infantum* are the causative agents, with 90% of the cases reported in children under five years of age.
- It spreads through the *Phlebotomus alexandri* species of sandfly.

Cutaneous Leishmaniasis:

- Is quite prevalent in the entire country.
- Mainly caused by *L. major* and *L. tropica*.
- It is spread by *Phlebotomus sergenti* and *P. papatasi* species of sandfly.

Trichomonas:

Objectives:

The main objectives of this lecture are:

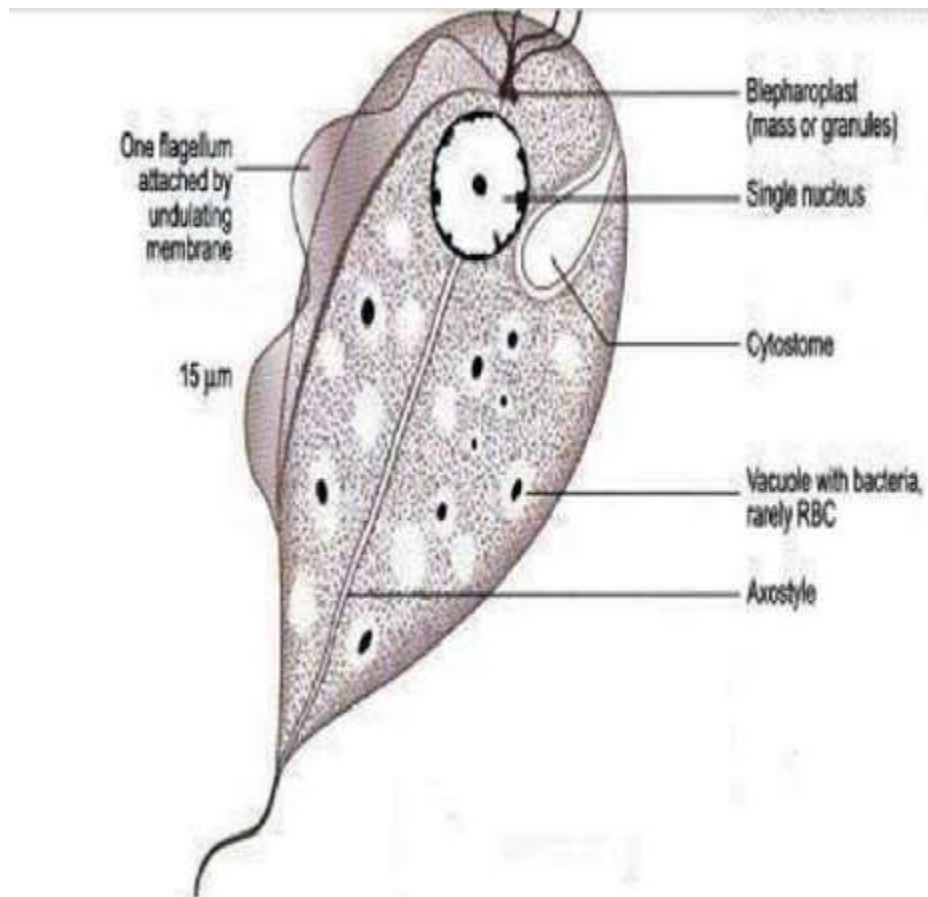
- *Trichomonas vaginalis* (Biology, transmission, pathogenesis, clinical picture, diagnosis, treatment and prevention).
- Other trichomonas as *Trichomonas tenax* and *Trichomonas hominis*

Trichomonas vaginalis:

- Trichomoniasis is the most prevalent non-viral sexually transmitted infection affecting an estimated 3.7 million persons in USA.
- It is an anerobic, flagellated motile protozoan parasite.
- Alfred Francois Donné (1801-1878) was the first to describe a procedure to diagnose trichomoniasis through "the microscopic observation of motile protozoa in vaginal or cervical secretions in 1836.

Morphology:

- *Trichomonas vaginalis* exists in only one morphological stage, a trophozoite that cannot encyst.
- The *T. vaginalis* trophozoite is oval, flagellated, pear shaped as seen on a wet-mount.
- It is slightly larger than a white blood cell, measuring $9 \times 7 \mu\text{m}$.
- Five flagella arise near the cytostome; four of these immediately extend outside the cell together, while the fifth flagellum wraps backwards along the surface of the organism. In addition, a conspicuous barb-like axostyle projects opposite the four-flagella bundle.
- The axostyle may be used for attachment to surfaces and may also participate in the tissue damage seen in trichomoniasis. While *T. vaginalis* does not have a cyst form, organisms can survive for up to 24 hours in urine, semen, or even water samples.
- Trophozoites divide by *binary fission*.



Trophozoite of T. vaginalis (2).

Transmission

- The trophozoite cannot survive outside and so infection has to be transmitted directly from person-to-person.
- **Sexual transmission is the usual mode of infection.** Trichomoniasis often coexists with other sexually transmitted diseases like candidiasis, gonorrhea, syphilis, or human immunodeficiency virus (HIV).
- Babies may get infected during birth.
- Vaginal pH of > 4.5 facilitates infection.
- Fomites such as towels may transmit infection.

Habitat

In females, it lives in vagina and cervix, and may also be found in Bartholin's glands, urethra and urinary bladder. In males, it occurs mainly in the anterior urethra, but may also be found in the prostate and preputial sac.

Infective stage:

- The *trophozoite itself is the infective form.*

Pathogenesis

- *T. vaginalis* particularly infects squamous epithelium but not columnar epithelium.
- It is an **obligate parasite and cannot live without close** association with the vaginal, urethral, or prostatic tissues.
- It secretes cysteine proteases, adhesins, lactic acid and acetic acid, which disrupt the glycogen and lower the pH of the vaginal fluid.
- Parasite causes petechial hemorrhage and mucosal capillary dilation (**strawberry mucosa**), **metaplastic** changes and desquamation of the vaginal epithelium.
- Intracellular edema and so called *chicken-like epithelium*, which is the characteristic feature of trichomoniasis

Clinical picture:

- The incubation period of trichomoniasis is 4 days to 4 weeks.
- Infection is often asymptomatic, particularly in males, although some may develop urethritis, epididymitis and prostatitis.
- In females, it may produce severe pruritic vaginitis with an offensive, yellowish green, often frothy discharge, dysuria and dyspareunia.
- Cervical erosion is common.
- Endometritis and pyosalpingitis are infrequent complications.
- Rarely, neonatal pneumonia and conjunctivitis have been reported in infants born to infected mothers.
- *T. vaginalis* infection is associated with two to threefold increased risk for HIV transmission, preterm birth, and other adverse pregnancy outcomes among pregnant women.
- Among women with HIV infection, *T. vaginalis* infection is associated with increased risk for pelvic inflammatory diseases and developing cervical cancer.

Diagnosis

- Diagnostic testing for *T. vaginalis* should be performed in women seeking care for vaginal discharge.
- Screening might be considered for persons receiving care in high-prevalence settings (e.g., sexual transmitted disease clinics) and for asymptomatic persons at high risk for infection (e.g., persons with multiple sex partners, drug addicts, or a history of STD).

Tests commonly used:

1. Microscopic wet mount examination:

The most common method for *T. vaginalis* diagnosis might be microscopic evaluation of wet preparations of genital secretions because of convenience and relatively low cost.

Unfortunately, the sensitivity of wet mount is low (51%–5%) in vaginal specimens and lower in specimens from men (e.g., urethral specimens, urine sediment, and semen).

Clinicians using wet mounts should attempt to evaluate slides immediately because sensitivity declines as evaluation is delayed, decreasing by up to 20% within 1 hour after collection

- Organisms lose motility *ex vivo* because of temperature shock, so slides should be prepared and read as soon as possible following collection in order to avoid false-negative results.
- The motile trichomonads move in a characteristic jerky and twitching pattern.

- The motile trichomonads move in a characteristic jerky and twitching pattern.
2. **Fixed smears:** may be stained with acridine orange, Papanicolaou and Giemsa stains.
 3. **NAAT (nucleic acid amplification test (Aptima *Trichomonas vaginalis* assay)):**
 - It is highly sensitive (96.5%) and highly specific (97.5%), often detecting three to five times more *T. vaginalis* infections than wet-mount microscopy.
 - It is the gold standard test.
 4. **Affirm VPIII: nucleic acid probe test:**
 - For the diagnosis of *T. vaginalis* as well as *Gardnerella vaginalis* and *Candida albicans* in females.
 - This test can be run and give results in 45 minutes with sensitivity 90-95% and specificity of 92-100%.
 5. **OSOM *Trichomonas* Rapid Test:**
 - It is used to detect *T. vaginalis* in vaginal secretions.
 - It is an antigen-detection test uses immune chromatographic capillary flow dipstick technology that can be performed at the point of care.
 - The results of the OSOM *Trichomonas* Rapid Test are available in approximately 10 minutes, with sensitivity 82%–95% and specificity 97%–100%.
 - Self-testing might become an option.
 6. **Culture with a modified diamond medium:**
 - It was considered as the gold standard method for diagnosing *T. vaginalis* infection before start of NAAT.
 - Culture has a sensitivity of 75%–96% and a specificity of up to 100%.
 - In women, vaginal secretions are the preferred specimen type for culture.
 - In men, culture specimens require a urethral swab, urine sediment, and/or semen.
 - To improve yield, multiple specimens from men can be used to inoculate a single culture.
 - Cultures are assessed by microscopy of a slide prepared from a drop of the culture medium daily for up to 7 days.
 7. **The InPouch (Biomed Diag- nostics, Santa Clara, CA) system:**
 - It contains culture medium in a pouch that can be placed on a microscope stage.
 - Thus, the entire volume of the culture can be evaluated for the presence of trichomonads.
 - The InPouch system achieved an incremental increase in sensitivity over routine culture.
 - It is used for collection , Transportation, Incubation and observation of the micro organism
 - The Inpouch culture technique is as sensitive and specific as molecular techniques in detection of TV

Treatment

- Simultaneous treatment of both partners is recommended as it is an STD.
- Metronidazole 2 g orally as a single dose or 500 mg orally twice a day for 7 days is the drug of choice.
- In patients not responding to treatment with standard regime, the dose of metronidazole may be increased or it may be administered parenterally.
- In pregnancy, metronidazole is safe in 2nd and 3rd trimesters.

Prevention

- Prevention is same as for other sexually transmitted diseases.
- Avoidance of sexual contact with infected partners and use of barrier method during intercourse prevent the disease.
- Patient's sexual partner should be tested for *T. vaginalis* when necessary.
- Treatment of both partners at the same time.

Trichomonas tenax

- *T. tenax*, also known as *T. buccalis*, is a harmless commensal which lives in mouth, in the periodontal pockets, carious tooth cavities and, less often, in tonsillar crypts .
- It is *smaller* (5-10 μm) than *T. vaginalis*.
- It is transmitted by kissing, through salivary droplets and fomites.
- There are sporadic reports of its involvement in respiratory infections and thoracic abscesses especially in severe lung diseases.
- Better oral hygiene rapidly eliminates the infection and no therapy is indicated.

Trichomonas Hominis

- *T. hominis* measures 8- 12 μm , *pyriform-shaped*, and carries *five anterior flagella* and an undulating membrane that extends the full length of the body.
- It is a *very harmless commensal* of the cecum where the organism feeds on bacteria and food debris.
- Microscopic examination of stool will reveal motile trophozoite of *T. hominis*.
- The cysts are *lemon-shaped* having a spiral projection at the anterior end. It measures 5-10 μm in length and 4-6 μm in breadth and is surrounded by a thick cyst wall.
- Both trophozoites and cysts are demonstrated in the semi-formed stool.

INTRODUCTION

- × **Malaria** is a life-threatening protozoan disease caused by *Plasmodium* species.
- × It is characterized by fever, anemia and splenomegaly. It's typically transmitted through the bite of an infective female *Anopheles* mosquito.

CLASSIFICATION

Table 1: Phylum Apicomplexa (Sporozoa)

Class	Order	Genera
Hematozoa	Hemosporida	• <i>Plasmodium</i>
	Piroplasmida	• <i>Babesia</i>
Coccidia	Eimeriida	• <i>Toxoplasma</i> • <i>Cyclospora</i> • <i>Cryptosporidium</i> • <i>Isospora</i> • <i>Sarcocystis</i>

CAUSATIVE AGENTS OF HUMAN MALARIA

1) *Plasmodium vivax*:

Benign tertian malaria (periodicity of fever is once in 48 hours, i.e. recurs every third day).

2) *Plasmodium falciparum*:

Malignant tertian or subtertian malaria (severe malaria, periodicity of fever is once in 36-48 hours, recurs every third day).

3) *Plasmodium ovale*:

Benign tertian malaria (periodicity of fever is once in 48 hours, i.e. recurs every third day).

4) *Plasmodium malariae*:

Benign quartan malaria (periodicity of fever is once in 72 hours, i.e. recurs every fourth day).

5) *P. knowlesi*:

causes quotidian malaria (fever periodicity is once in 24 hours, i.e. recurs every day). It is a parasite of monkey but can also affect humans.

History and Distribution

- × The name malaria (mal: bad, aria: air) was derived from the ancient false belief: thought to be caused by foul emissions from marshy soil.
- × French army surgeon Alphonse Laveran (1880) was the first to discover the causative agent *Plasmodium*, in the red blood cell (RBC) of a patient in Algeria.
- ***P. vivax*** is the most widely distributed, being most common in **Asia, North Africa, and Central and South America.**

- **P. falciparum** the predominant species in **Africa**, New Guinea and Haiti, is rapidly spreading in Southeast Asia and India.
- **P. ovale** is virtually confined to **West Africa** where it ranks second after **P. falciparum**.
- **P. malariae** is present in most places but is rare, except in Africa

classification of endemicity

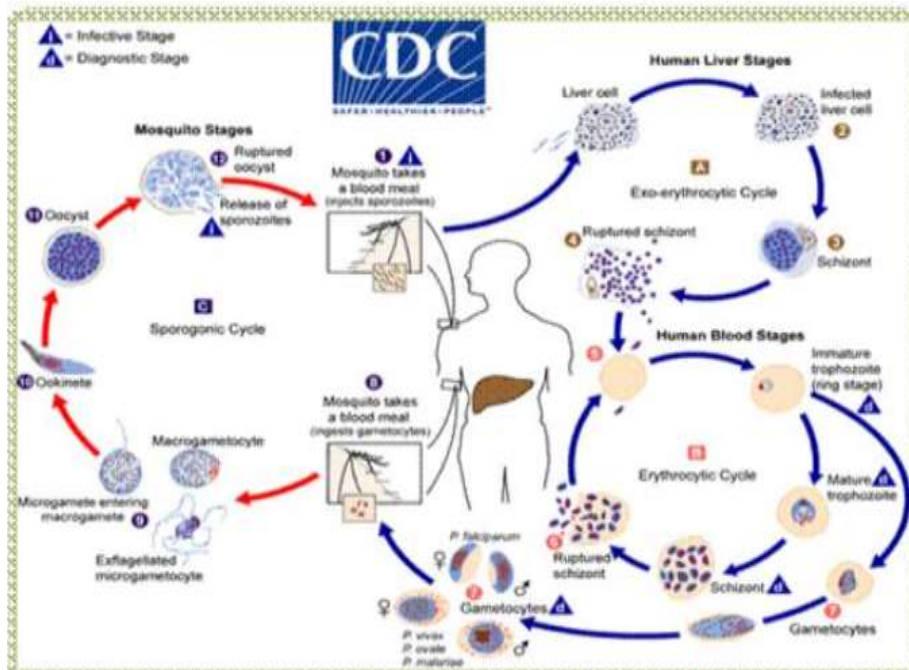
The World Health Organization (WHO) has recommended the classification of endemicity depending on the spleen or parasite rate in a statistically significant sample in the populations of children (2-9 years) and adults in to:

- ❖ **Hypoendemic** (transmission is low): Spleen or parasite rate less than 10%.
- ❖ **Mesoendemic** (transmission is moderate): Spleen or parasite rate 11-50%.
- ❖ **Hyperendemic** (transmission is intense but seasonal(rainy season)): Spleen or parasite rate 51-75%.
- ❖ **Holoendemic** (transmission is intense and constantly present): Spleen or parasite rate more than 75%.

Vector

- × Human malaria is transmitted by over 60 species of **female Anopheles mosquito**.
- × Male Anopheles doesn't feed on man and feeds exclusively on fruit juices, so that the male Anopheles doesn't transmit the disease. Whereas female Anopheles needs at least two blood meals before laying eggs.

Life Cycle



- × **Definitive host:** Female Anopheles (Anopheline) mosquito is the definitive host where the sexual cycle (sporogony) takes place.
- × **Intermediate host:** Man acts as intermediate host where the asexual cycle (schizogony) takes place. In humans, schizogony occurs in two locations, in the liver cells (**exoerythrocytic schizogony, preerythrocytic schizogony**) and in the red blood cell (**erythrocytic schizogony**).

Human Cycle (Schizogony)

- × Human infection comes through the bite of infective female Anopheles mosquito
- × The sporozoites (**infective forms**) are injected from the salivary gland of the mosquito when feeds on blood.
- × The sporozoites pass into the bloodstream, where some reach the liver and enter the hepatocytes.

Pre-erythrocytic (tissue, intrahepatic) stage or exo-erythrocytic stage:

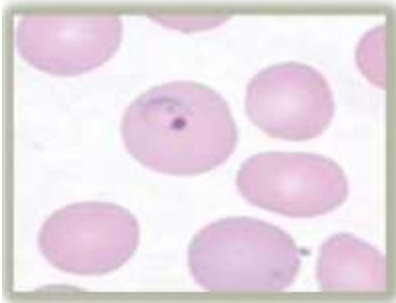
- × The circumsporozoite protein present on the surface of sporozoites binds to the receptors on the surface of hepatocytes facilitating the entry of sporozoites.
- × The sporozoites, which are elongated spindle-shaped bodies, become rounded inside the liver cells. They enlarge in size and undergo repeated division to form **pre-erythrocytic or exoerythrocytic schizont** which contain **uninucleate**

merozoites.

- Liver schizonts normally rupture in 6-15 days and release thousands of merozoites into the bloodstream.
- Duration of pre-erythrocytic schizogony varies from **5 days to 15 days** depending on the species.

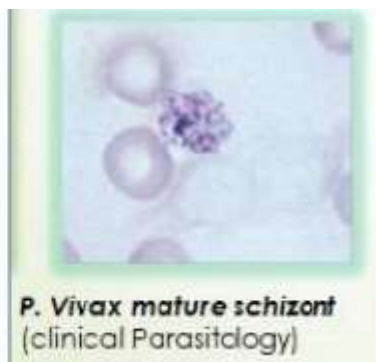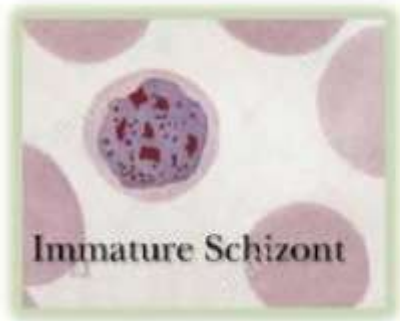Erythrocytic stage:

- × The merozoites invade the RBCs. the receptor for the merozoite is **glycophorin**, the differences in the glycophorins of red cells of different species may account for the species specificity of malaria parasites.
- × In the erythrocyte, the merozoite appears as a rounded body having a vacuole incenter with the cytoplasm pushed to the periphery and the nucleus at one pole (signet ring appearance), these the young parasites are called the **ring forms**.
- × As the ring form develops, it enlarges in size becoming irregular in shape and called the **ameboid form**.



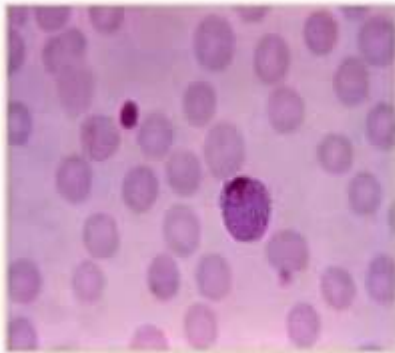
- × When the ameboid form reaches a certain stage of development, its nucleus starts dividing by mitosis (**immature schizont**) followed by a division of cytoplasm to become **mature schizonts**. The mature schizont bursts releasing the merozoites into the circulation. The merozoites invade fresh erythrocytes within which they go through the same process of development.

- × The rupture of the mature schizont releases large quantities of pyrogens (malarial pigments, cytokines and toxins). **This is responsible for the febrile paroxysms characterizing malaria.**

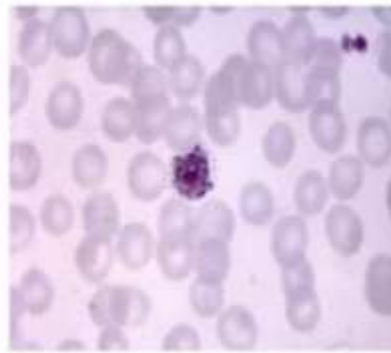


Malarial pigment

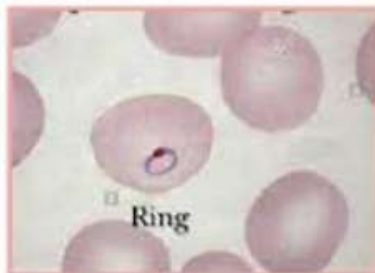- × Plasmodium parasite feeds on hemoglobin of the erythrocyte. it does not metabolize hemoglobin completely and therefore, leaves behind a hematin-globin pigment called the **malaria pigment or hemozoin pigment**, as residue.
- × The appearance of malarial pigment varies, mostly it is **brown black** in color and numerous (except in *P. vivax* it is **yellowish brown** in color and in *P. falciparum*, it is few in number) **Gametogony**
- × Some of the merozoites that infect RBCs develop into sexually differentiated forms, the **gametocytes**.
- × In all species, the female gametocyte is larger, numerous, their cytoplasm stains deep blue, nucleus is small, red and compact (**macrogametocyte**) while the male gametocyte are smaller in size, lesser in number, their cytoplasm stains pale blue, and nucleus is larger, stains red and diffuse (**microgametocyte**).
- × A person with gametocytes in blood is a carrier or reservoir and play an important role in the transmission of the disease.



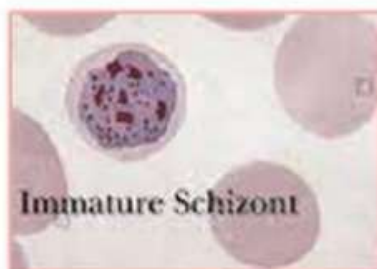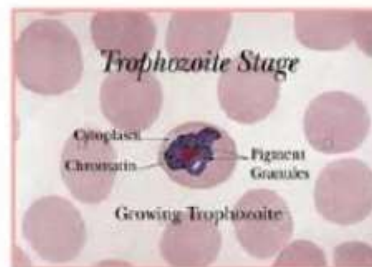plasmodium vivax, macrogametocyte



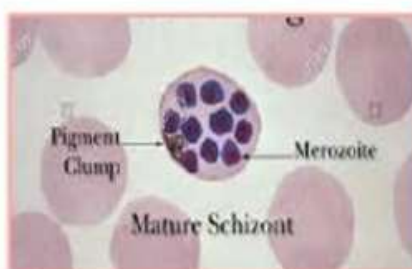
plasmodium vivax, microgametocyte



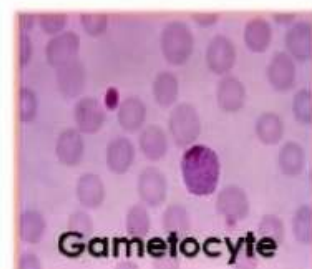Ring



Immature Schizont



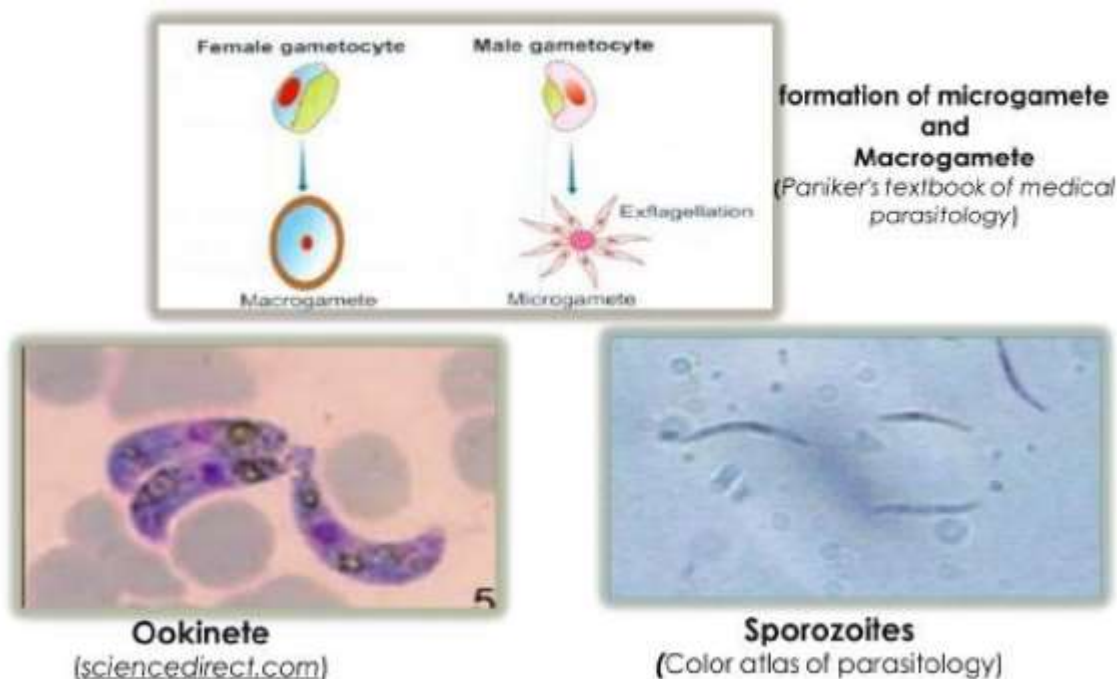
Mature Schizont



Gametocyte

The Mosquito Cycle (Sporogony)

- ❖ In the mosquito, gametocytes develop into gametes:
- ❖ Macrogamete → one macrogamete.
- ❖ Microgametocyte → 6-8 microgametes, by process called **exflagellation**.
- × **Exflagellation** The nuclear material and cytoplasm of the male gametocytes divide to produce eight microgametes with long, actively motile, whip-like filaments
- ❖ One microgamete fertilizes macrogamete to form zygote mobile ookinete.
- ❖ Ookinete penetrates the gut mucosa of mosquito to the hemocoel side (outer side) of the gut oocyte which contains the sporoblast that divides rapidly to form thousands of sporozoites break out of oocyte hemocoel salivary gland next patient.



× **incubation period:** The interval between the entry of sporozoites into the host and the earliest manifestation of clinical illness.

×

Prepatent period:

The interval between the entry of the sporozoites into the body and the first appearance of the parasites in blood (**Ring forms are the first asexual form that can be demonstrated in the peripheral blood**).

× **Recrudescence:** In *P. falciparum* and *P. malariae*, due to persistence of drug resistant parasites, even after completion of treatment, small numbers of **erythrocytic parasites** persist in the bloodstream and in a course of time; they multiply to reach significant numbers resulting in clinical disease. **no hypnozoites** are

found.

× **Relapse:** Some sporozoites of *P. vivax* and *P. ovale* remain dormant (resting phase) in liver called **hypnozoites** which cause relapse of malaria after many years

<i>Recrudescence</i>	<i>Relapse</i>
Seen in <i>P. falciparum</i> and <i>P. malariae</i>	Seen in <i>P. vivax</i> and <i>P. ovale</i>
Due to persistence of the parasite at a subclinical level in circulation	Due to reactivation of hypnozoites present in liver cells
Occurs within a few weeks or months of a previous attack	Occurs usually 24 weeks to 5 years after the primary attack
Can be prevented by adequate drug therapy or use of newer antimalarial drugs in case of drug resistance	Can be prevented by giving primaquine to eradicate hypnozoites

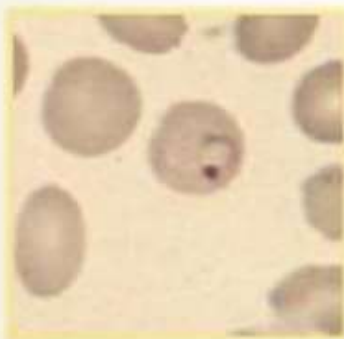
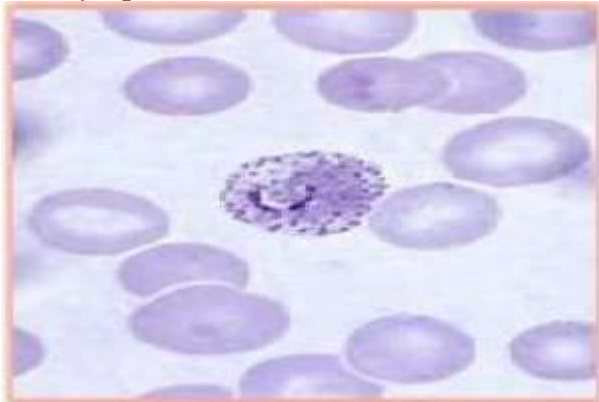
Modes of transmission:

- × Man gets infection by the bite of infective female *Anopheles* mosquito.
- × Rarely, it can also be transmitted by:
 - ❖ Blood transfusion.
 - ❖ Transplacental transmission.
 - ❖ contaminated syringes.

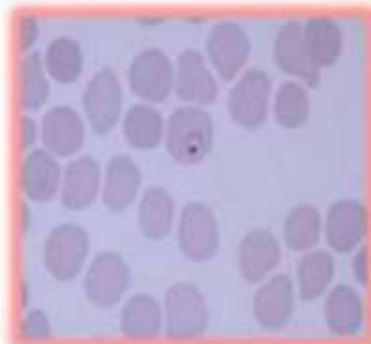
Malaria Lec.2

P. vivax

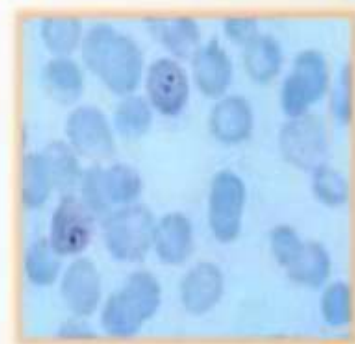
- × has the widest geographical distribution. It is the **most common species** of malaria parasite in Asia and America (account for 80% of all malaria infections), but is much less common in Africa.
- × It causes **benign tertian malaria** with frequent **relapses**.
- × Merozoites of *P. vivax* preferentially infect *reticulocytes and young erythrocytes*, the infected erythrocytes are **enlarged** and show red granules known as *Schuffner's dots* on the surface -believed to be an allergic reaction from the host to the presence of the parasite.
- × **All stages** of erythrocytic schizogony can be seen in peripheral smears.
- × The degree of parasitization is not generally heavy; not more than **2-5% of the red cells** being affected.
- × **Morphology:** The ring form has prominent central vacuole. One side of the ring is thicker and the other side thin. Nucleus is situated on the thin side of the ring (Signet ring appearance).
- × The ring is about 2.5-3 μm in diameter, about a **third** of the size of an erythrocyte. The cytoplasm is blue and the nucleus red in stained films.



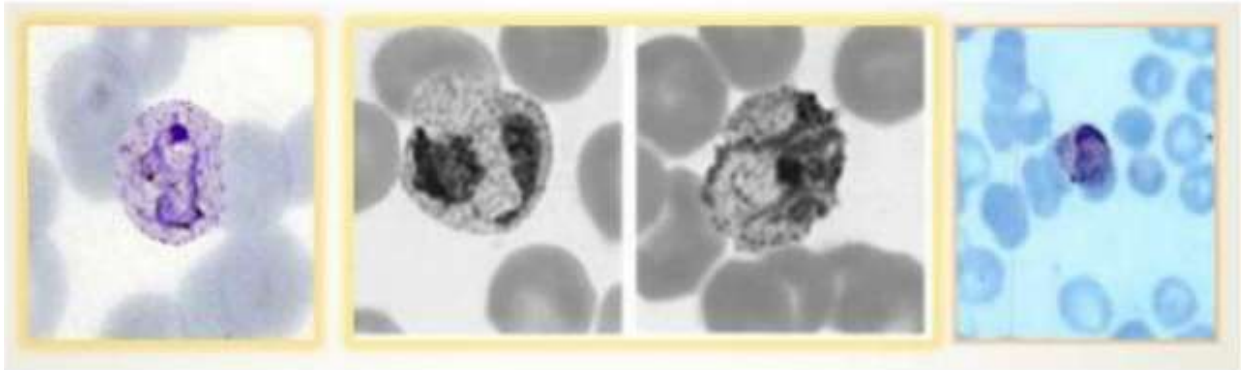
P. Vivax ring stage
(color atlas of diagnostic microbiology)



P. Vivax ring stage
(Medical Parasitology)

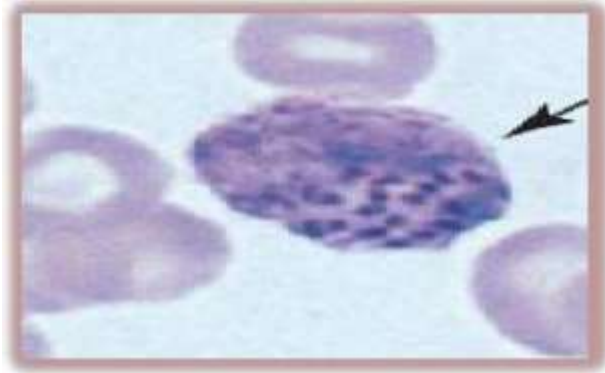


- × The ring develops rapidly to the ameboid form which is irregular in shape.



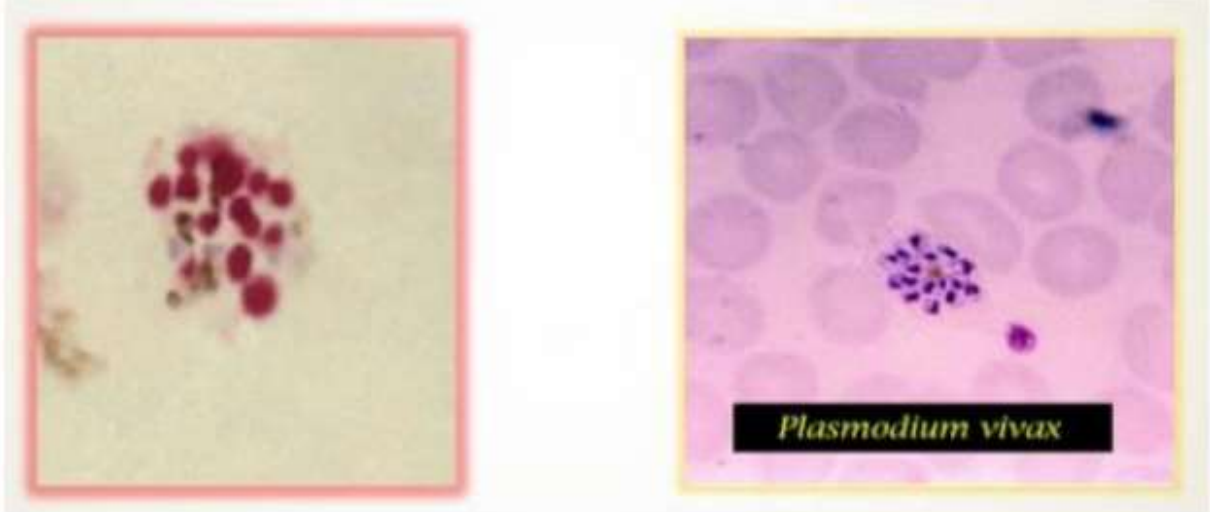
ameboid form of P. vivax

- × The immature schizont form of *P. vivax*.



P. vivax immature schizont

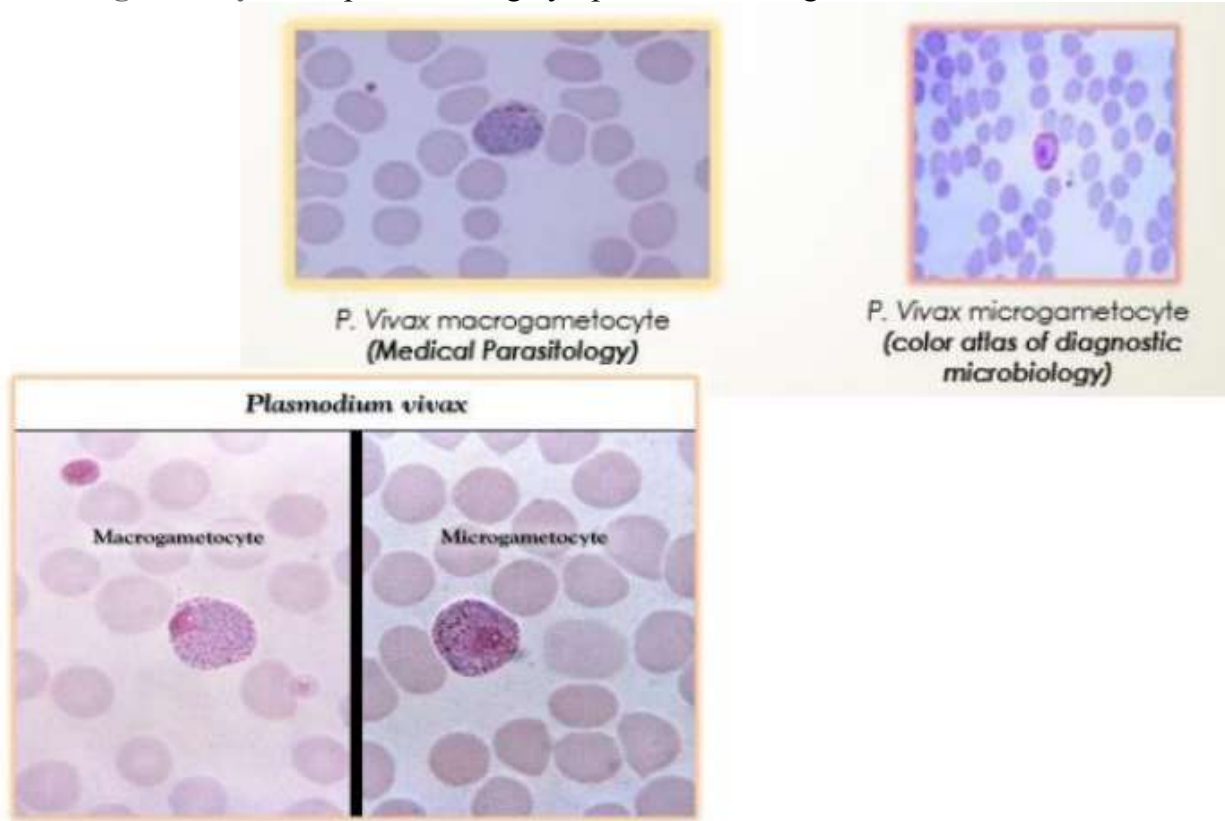
- × The mature schizont contains about 12-24 (usually 16) merozoites per schizont.



P. Vivax mature schizont (color atlas of diagnostic microbiology)


- × Both male and female gametocytes are large, nearly filling the enlarged red cell.
- × **macrogametocyte** has dense cytoplasm staining deep blue and a small compact nucleus.

- × **microgametocyte** has pale-staining cytoplasm and a large diffuse nucleus.



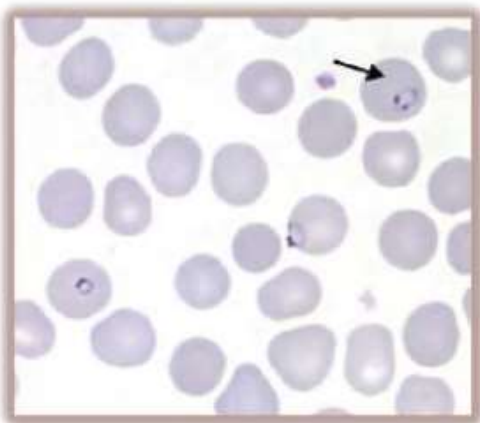
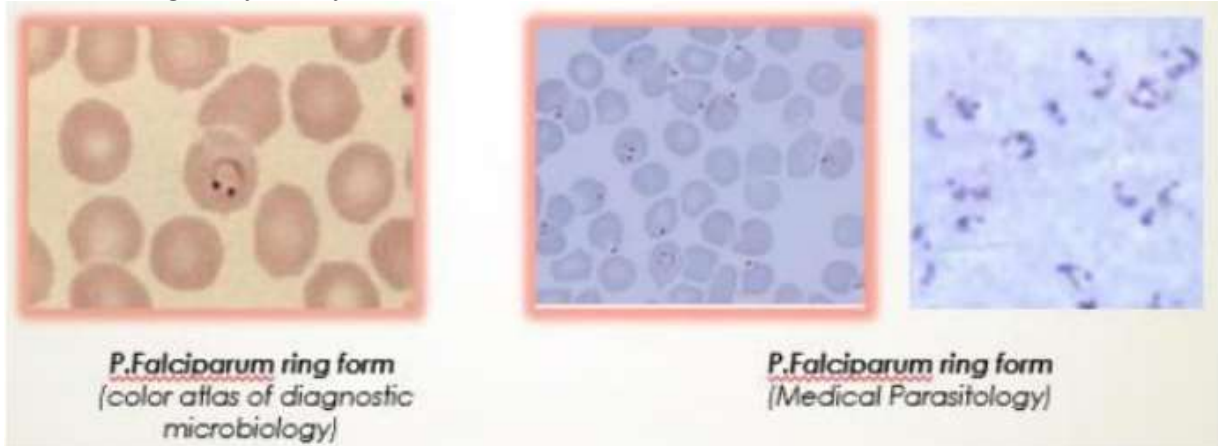
Plasmodium Falciparum

- × This is the highly pathogenic of all the plasmodia and hence, the name malignant tertian or pernicious malaria for its infection.
- × The disease has a high rate of complications and unless treated, is often fatal. This species is responsible for almost all deaths caused by malaria.
- × *Recrudescence* occur in this species. *Hypnozoites do not occur*.
- × They attack **ALL types of erythrocytes** and so the population of cells affected is very large (25% of RBC infected).
- × The infected erythrocytes are of **normal size**. They show a few (6- 12) coarse brick-red dots which are called **Maurer's clefts**.



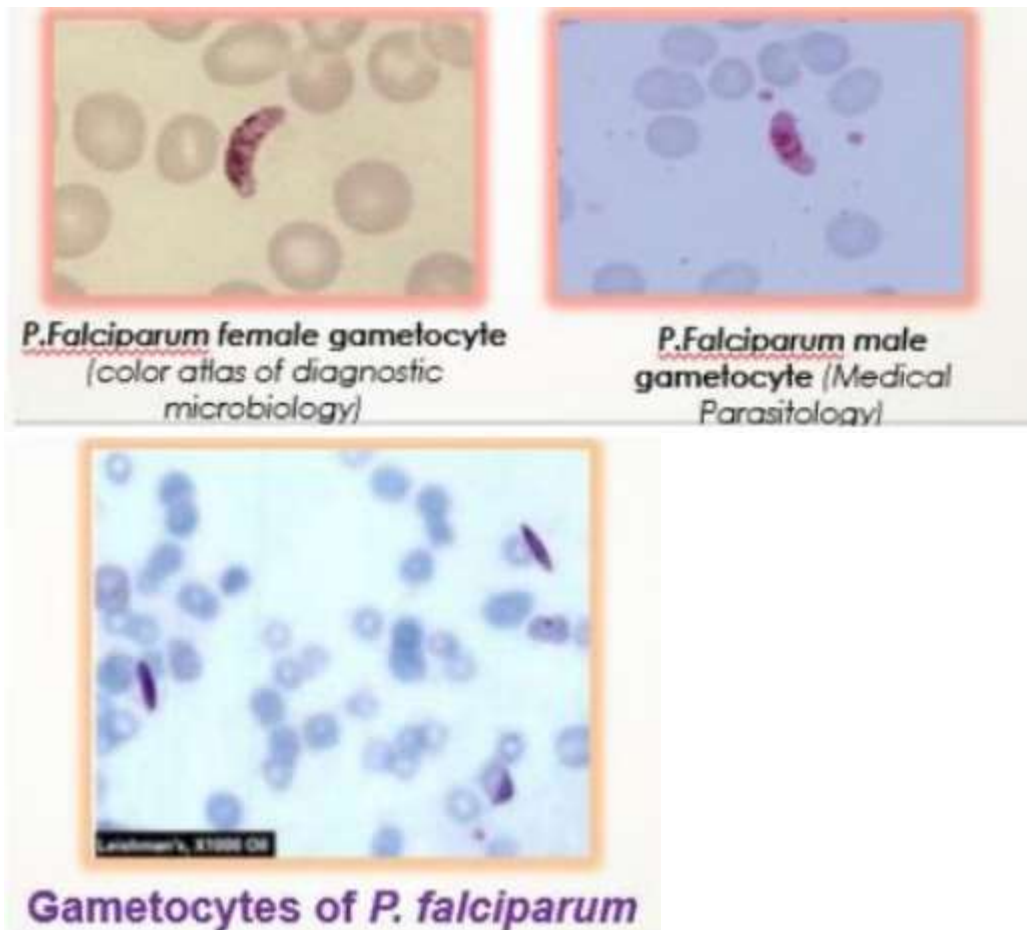
Morphology:

× **Ring form:** The ring form in the erythrocyte is very *delicate* and tiny, measuring only a *one-sixth of the red cell diameter*. Rings are often seen attached along the margin of the red cell. Binucleate rings (double chromatin) are common resembling *stereo headphones* in appearance. Several rings (multiple infection) may be seen within a single erythrocyte.



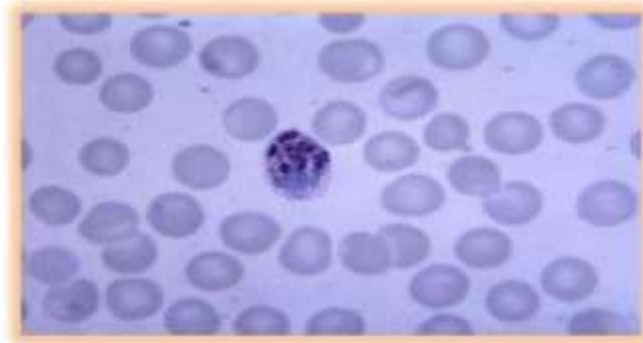
double dot (headphone shaped) ring form of Plasmodium falciparum

- × The subsequent stages of the asexual cycle- ameboid early and mature schizonts- are not seen in peripheral blood, except in very severe malaria, because these stages of erythrocytic cycle occur in the capillaries of the brain and internal organs.
- × The mature **gametocytes**, which are seen in peripheral smears are curved oblong structures, described as crescentic, kidney, *sausage*, or *banana-shaped*.
- × **Male gametocytes:** are broad and sausage-shaped or kidney-shaped, with blunt rounded ends.
- × **Female gametocytes:** are thinner and more typically crescentic, with sharply rounded or pointed ends. The mature gametocyte is longer than the diameter of the red cell and so produces gross distortion and sometimes disappearance of the infected red cell.



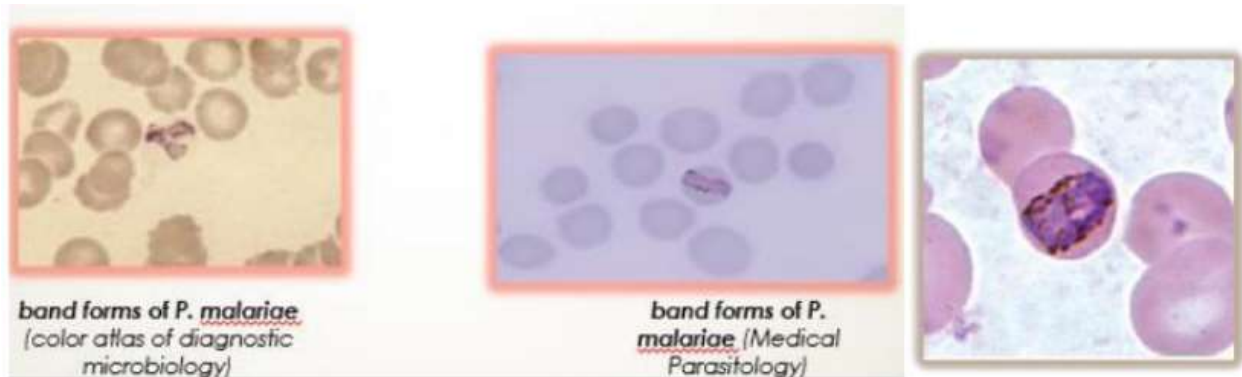
Plasmodium Malariae

- × It causes *quartan malaria*, in which febrile paroxysms occur *every 4th day*, with 72 *hours* interval between the bouts. *Recrudescence* occur in this species.
- × *Hypnozoites do not occur*.
- × *P. malariae* preferentially infects **older erythrocytes** and the degree of parasitization is the lowest. The infected erythrocytes may be of the **normal size or slightly smaller**.
- × Fine stippling, called **Ziemann's stippling**, may be seen with special stains



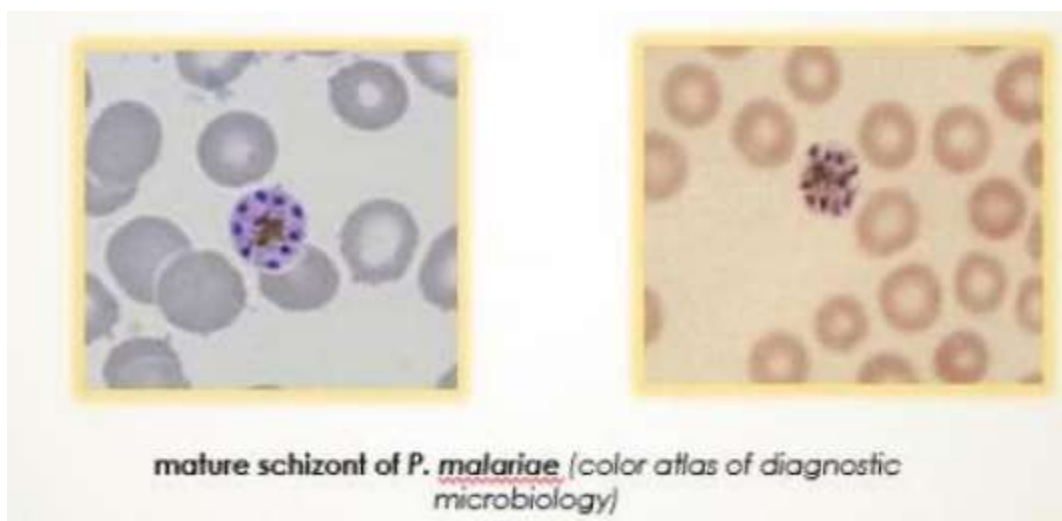
Morphology:

- × The ring forms resemble those of *P. vivax*, although thicker and more intensely stained.
- × The ameboid sometimes seen stretched across the erythrocyte as a *broad band*. These **band forms** are a unique feature of *P. malariae*.



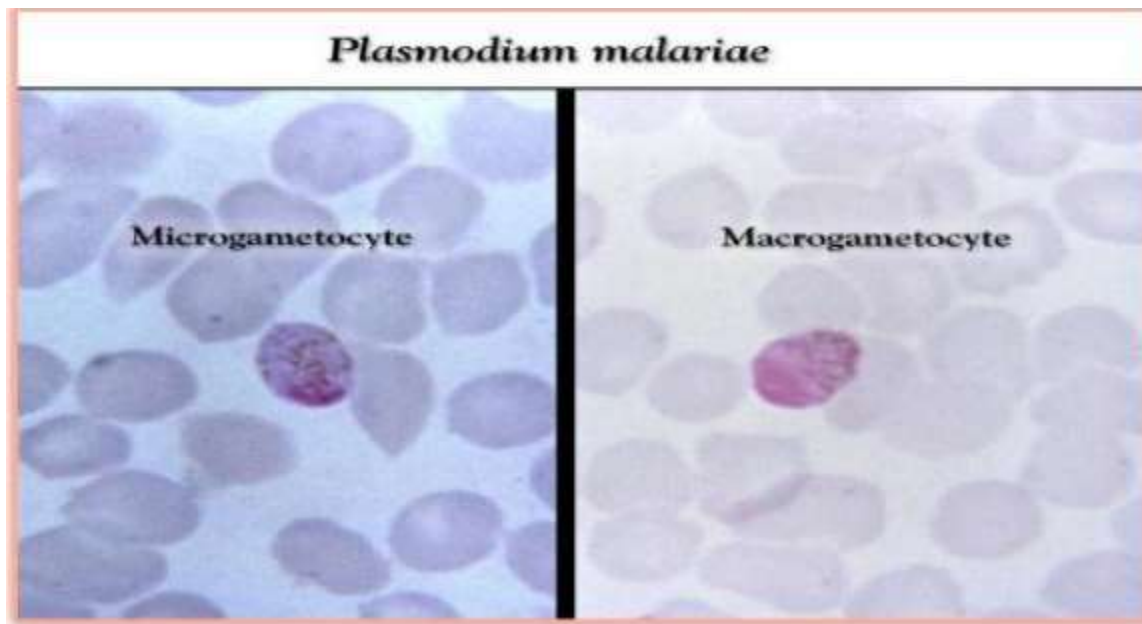
band forms of P. malariae

The mature schizont has (6-10 merozoites), which usually present a *rosette* appearance. Hemozoin pigment, brown in color, is also visible.



Gametocytes occupy nearly the entire red cell.

- × **The male** has pale blue cytoplasm with a large diffuse nucleus, while **the female** has deep blue cytoplasm and a small compact nucleus.

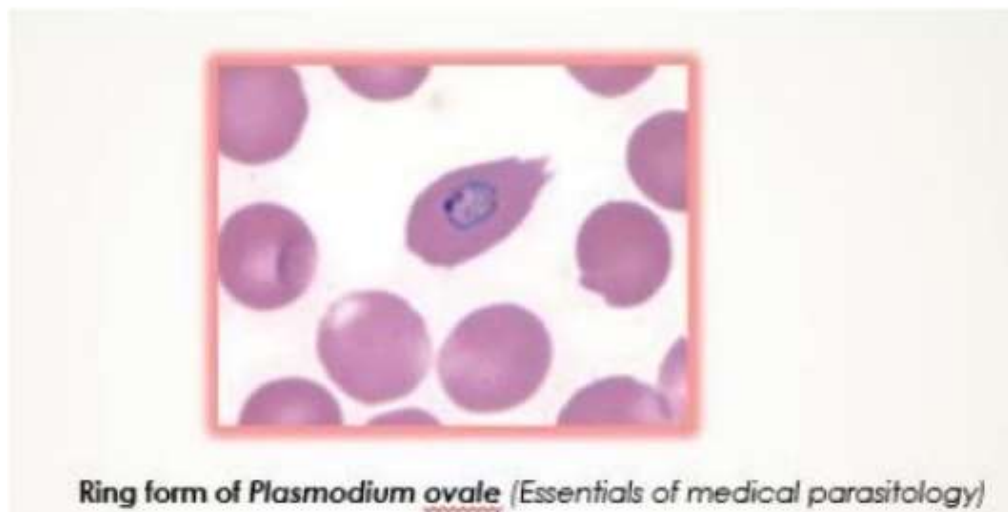


Plasmodium Ovale

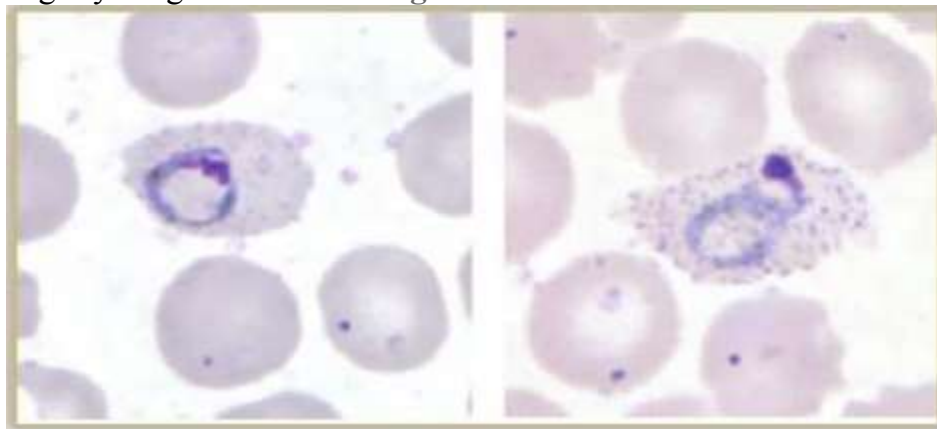
- × This parasite cause tertian fever resembling *vivax* malaria, but with milder symptoms.
- × It is *the rarest of all plasmodia* infecting humans
- × The infected erythrocytes are slightly enlarged and has irregular or fimbriated appearance of the edges of the infected R.B.C. This **oval appearance** of the infected erythrocyte is the reason for the name *ovale* given to this species.
- × *Hypnozoites are present.*

Morphology:

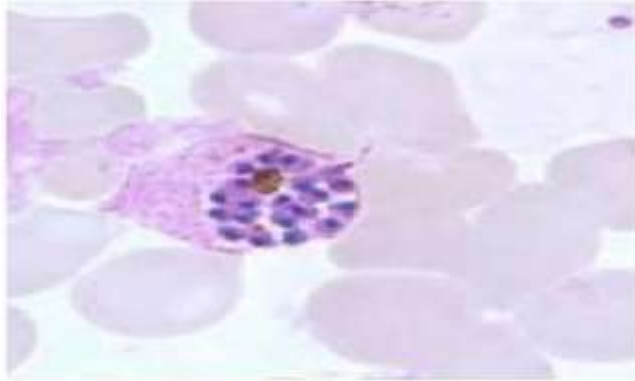
- × The trophozoites resemble those in *vivax* malaria. *Schuffner's dots* appear earlier and are more **abundant and prominent** than in *vivax* infection.
- × The schizonts resemble those of *P. malariae*, except that the pigment is *darker* and the erythrocyte is usually *oval*, with **prominent Schuffner's dots**.



Trophozoites: *P. ovale* trophozoites have large chromatin dot, and can be compact to slightly irregular and showing Schüffner's dots.



Schizonts: *P. ovale* schizonts have 6 -14 merozoites with large nuclei, clustered around a mass of dark-brown pigment.



Microgametocyte and Macrogametocyte as in P.vivax

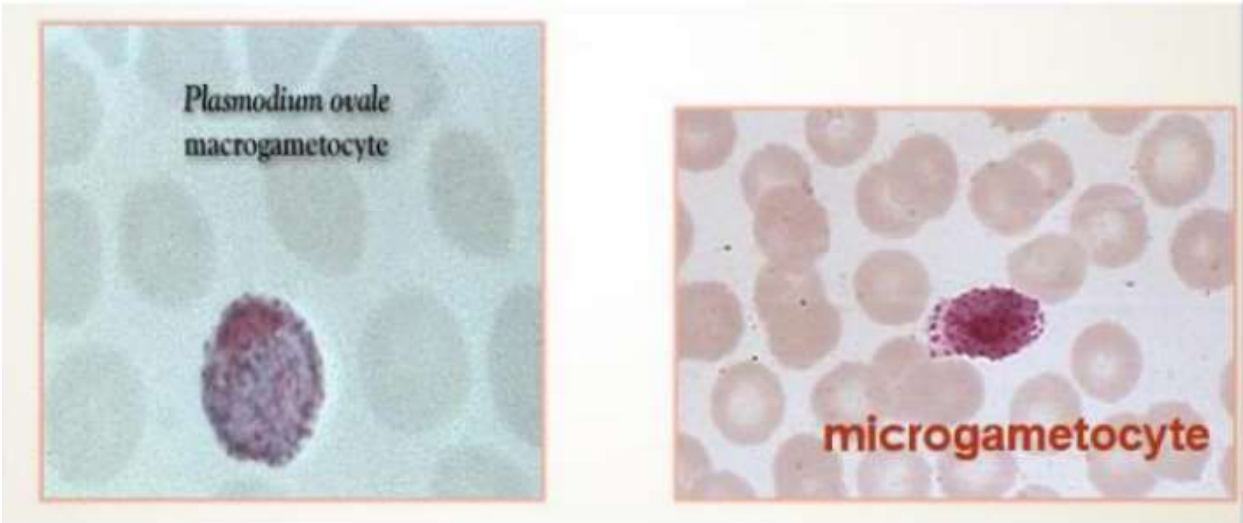


Table 6.4: Differences between the four malaria parasites

<i>Properties</i>	<i>Plasmodium vivax</i>	<i>Plasmodium falciparum</i>	<i>Plasmodium malariae</i>	<i>Plasmodium ovale</i>
Relapse (Hypnozoites)	Seen	Not seen	Not seen	Seen
Recrudescence	Not seen	Seen	Seen (Upto 60 years)	Not seen
Erythrocytic cycle	48 hours	36–48 hours	72 hours	48 hours
Prepatent period	8 days	5 days	13 days	9 days
Incubation period	14 days	12 days	28 days	17 days

Parasitic changes	<i>Plasmodium vivax</i>	<i>Plasmodium falciparum</i>	<i>Plasmodium malariae</i>	<i>Plasmodium ovale</i>
Changes in RBCs				
• RBCs infected	Young RBCs	RBCs of all age	Old RBCs	Young RBCs
• RBC size	Enlarged, Round (frequently bizarre form)	Normal in size	Normal in size	Enlarged, oval, fimbriated margin
• Stippling*	Schuffner's dots (small red dots)	Maurer's cleft (large red spots)	Ziemann's dots (small red dots)	James's dots (small red dots)
• Malarial Pigments	Yellowish brown	Dark brown	Dark brown	Dark yellowish brown

***Stippling:** Pink to red coloured dots on the surface of RBCs, are seen when stained properly. They are membrane bound structures in the cytoplasm of RBCs, infected with *Plasmodium* which help in protein transport from the parasite to the erythrocyte surface.

Pathogenesis and Clinical Features

Clinical manifestations in malaria are caused by products of erythrocytic schizogony and the host's reaction to them.

× **The disease process in malaria occurs due to:**

I. the local or systemic response of the host to parasite antigens.

II. tissue hypoxia caused by reduced oxygen delivery because of obstruction of blood flow by the parasitized erythrocytes.

× **Liver** is enlarged and congested. Kupffer cells are increased and filled with parasites.

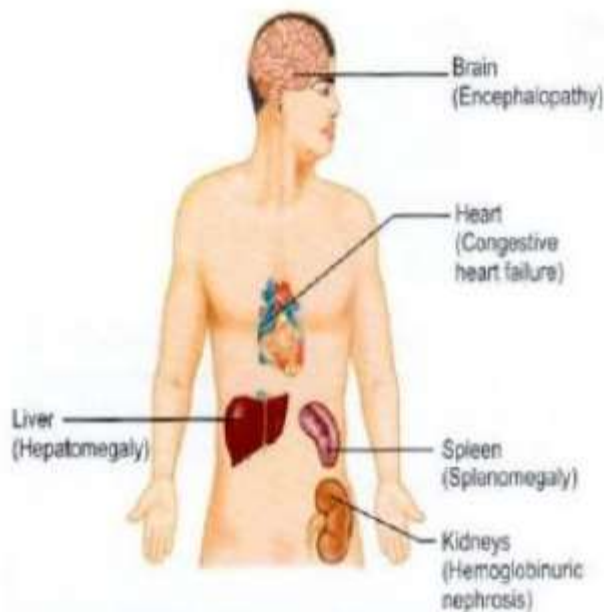
× **Spleen** is soft, moderately enlarged and congested in acute infection.

In chronic cases, spleen is hard.

× **Kidneys** are enlarged and congested.

× **The brain** in *P. falciparum* infection is congested.

× **Anemia:** After few paroxysms of fever, **normocytic and normochromic anemia** develops.



Clinical Features of Benign Malaria

× It is characterized by a triad of febrile paroxysm, anemia and splenomegaly.

Febrile paroxysm

❖ Fever comes intermittently depending on the species. It occurs every fourth day (72 hour cycle for *P. malariae*) and every third day (48 hour cycle for other three species)

× Paroxysm corresponds to the release of the successive broods of merozoites into the bloodstream, at the end of RBC cycle.

× The paroxysm usually begins in the **early afternoon** and lasts for **8-12 hours**.

❖ **Each paroxysm of fever is comprised of three stages:**

1. **Cold stage:** The patient feels intense cold with chill and rigor along with lassitude, headache and nausea. This stage lasts for **15 minutes to 1 hour**.
2. **Hot stage:** The patient feels intensely hot. The temperature mounts to 39–41 °C or higher. Headache persists but nausea commonly diminishes. This stage lasts for **2-6 hours**.
3. **Sweating stage:** Fever comes down with profuse sweating. Skin becomes cold and moist. Patient feels relieved and often asleep. This stage lasts for **2–4 hours**.

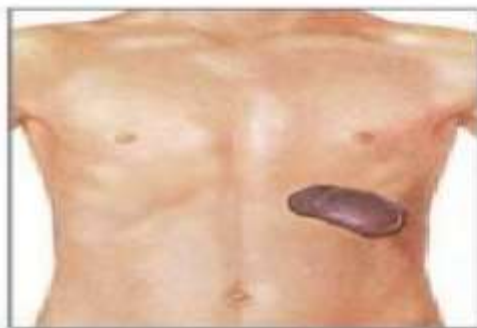Anemia

× After a few paroxysms of fever, the patient develops a **normocytic normochromic anemia**. Various factors can attribute to the development of anemia such as:

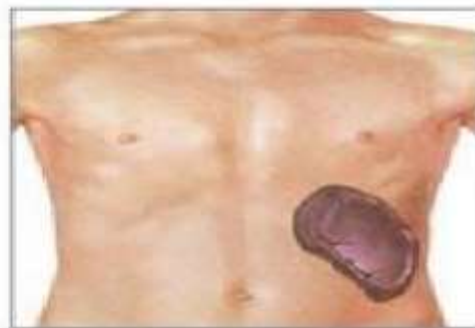1. Parasite induced RBC destruction —Lysis of RBC due to release of merozoites.
2. Splenic removal of both infected RBC and uninfected RBC coated with immune complexes.
3. Bone marrow suppression leading to decrease RBC production.
4. Increased fragility of RBCs.
5. Autoimmune lysis of coated RBCs.

Splenomegaly

× After a few weeks of febrile paroxysms, spleen gets enlarged and becomes palpable. Splenomegaly is due to massive proliferation of macrophages that engulf parasitized and non-parasitized coated RBCs.



Normal spleen



Splenomegaly

Clinical Features of Malignant Tertian Malaria

× The most serious and fatal type of malaria is malignant tertian malaria caused by *P. falciparum*. *Falciparum* malaria if not treated timely or adequately, severe life-threatening complications may develop. In severe *falciparum* malaria, parasitic load is very high. **it invades erythrocytes of all ages** (old and young).

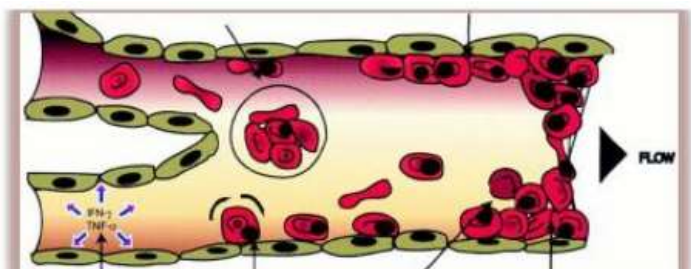
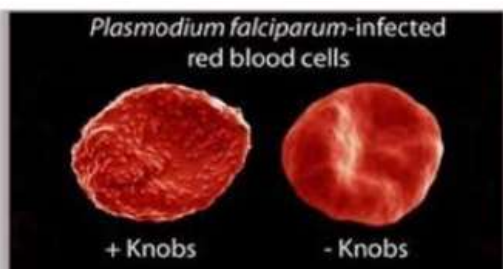
Box 5: Complications of *falciparum* malaria

- Cerebral malaria
- Algid malaria
- Septicemic malaria
- Blackwater fever
- Pulmonary edema
- Acute renal failure
- Hypoglycemia (<40 mg/dL)
- Severe anemia (Hb<5 g/dL, PCV<15%)
- Hyperpyrexia
- Metabolic acidosis and shock
- Bleeding disturbances
- Hyperparasitemia.

Abbreviations: Hb, hemoglobin; PCV, packed cell volume

1. Cerebral malaria:

- × Occurs due to plugging of brain capillaries by the rosettes of sequestered parasitized RBCs leading to vascular occlusion and cerebral anoxia.
- × Cerebral malaria manifests as diffuse symmetric encephalopathy characterized by generalized convulsion in 10% of adults and up to 50% of children.
- × Other defects are retinal hemorrhages, neurologic sequelae, repeated seizures, and rarely deep coma.
- × High mortality rate 20% among adults. and more than 15% among children.
- × Soon after invasion of the RBC, the trophozoite produce protein that is deposited in the erythrocyte surface membrane to form **knob-like deformities**, This knob produces specific adhesive proteins [*Plasmodium falciparum* erythrocyte membrane protein-1 (*PfEMP-1*)]. which promote aggregation of infected RBCs to other noninfected RBCs and to capillary endothelial cells.
- × These sequestered RBCs cause capillary plugging of cerebral microvasculature, which results in anoxia, ischemia and hemorrhage in brain.



2. Black-water fever (malarial hemoglobinuria) :

- × this syndrome is sometimes seen in *falciparum* malaria, particularly in patients, who

have experienced repeated past infections and inadequate treatment with quinine.



× Clinical manifestations include: fever, hemoglobinuria (**black colored urine**), bilious vomiting and prostration.

× The pathogenesis is believed to be **massive intravascular hemolysis caused by anti-erythrocyte antibodies**, leading to massive absorption of hemoglobin by the renal tubules. It may lead to renal failure and collapse.

3. Algid malaria:

This syndrome is characterized by peripheral circulatory failure, rapid thready pulse with low blood pressure and cold clammy skin.

4. Septicemic malaria:

It is characterized by high continuous fever with dissemination of the parasite to various organs, leading to multiorgan failure. Death occurs in 80% of the cases.

Chronic Complications of Malaria:

1. Tropical Splenomegaly Syndrome (hyper-reactive malarial splenomegaly):

condition seen in people of malaria in endemic areas, it happens from abnormal immunological response to repeated malaria infection.

Tropical splenomegaly syndrome is characterized by high level of immunoglobulin M (IgM), decreased C3 and massive splenomegaly.

2. Quartan malarial nephropathy

It is a chronic complication seen with *P. malariae* (and possibly with other malarial species). It occurs due to injury to the renal glomeruli by the immune complexes, resulting in nephrotic syndrome.

Merozoite-induced Malaria

Natural malaria is sporozoite-

induced, the infection being transmitted by sporozoites introduced through the bite of vector mosquitoes. Injection of merozoites can lead to direct infection of red cells and erythrocytic schizogony with clinical illness. Such merozoite-induced malaria may occur in the following situations:

A. Transfusion malaria: Blood transfusion can accidentally transmit malaria; if the donor is infected with malaria. The parasites may remain viable in blood bank for 1-2 weeks. **Pre-erythrocytic schizogony and hypnozoites are absent. Relapse does not occur and incubation period is short.**

B. **Congenital malaria:** where the parasite is transmitted transplacentally from mother to fetus.

C. **Renal transplantation** may lead to malaria if the donor had parasitemia.

D. **Shared syringes** among drug addicts may be responsible.

Mixed Infections Pathogenesis

In endemic areas it is not uncommon to find mixed infections with *two or more* species of malaria parasites in the same individual. Mixed infection with *P. vivax* and *P. falciparum* is the most common combination with a tendency for one or the other to predominate. The clinical picture may be *atypical* with bouts of fever occurring *daily*.

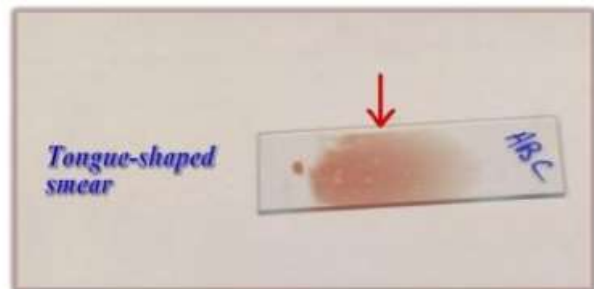
Laboratory Diagnosis

1. Microscopic examination

Peripheral Blood Smear: the simple and gold standard confirmatory test for the detection of malarial parasites.

Thin smears:

The amount of blood in thin smear is about **1- 1.5 μ L** and spread over the slide by a second slide held at an angle of 45° such that a tail is formed. Thin smears are stained by Leishman, Giemsa, or Field's stain. They are used for **determining the species of plasmodium**.



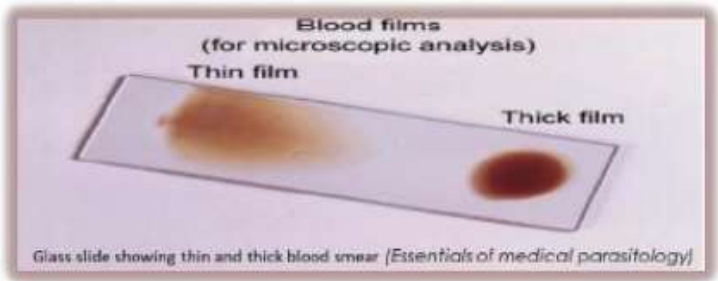
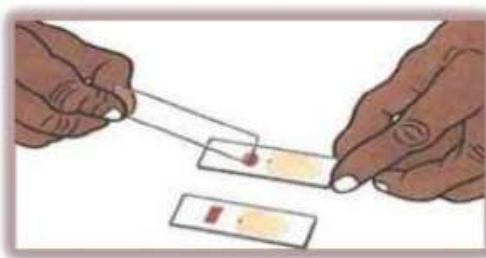
Thick smears:

In a thick film, usually **three drops** of blood are spread over a small area.

The amount of blood in a thick smear is **3-**

4 μ L. Thick film is more suitable for rapid detection of malarial parasite, particularly when they are few. thick film is *more sensitive* than thin film because it concentrates **20- 30 layers** of blood cells in a small area.

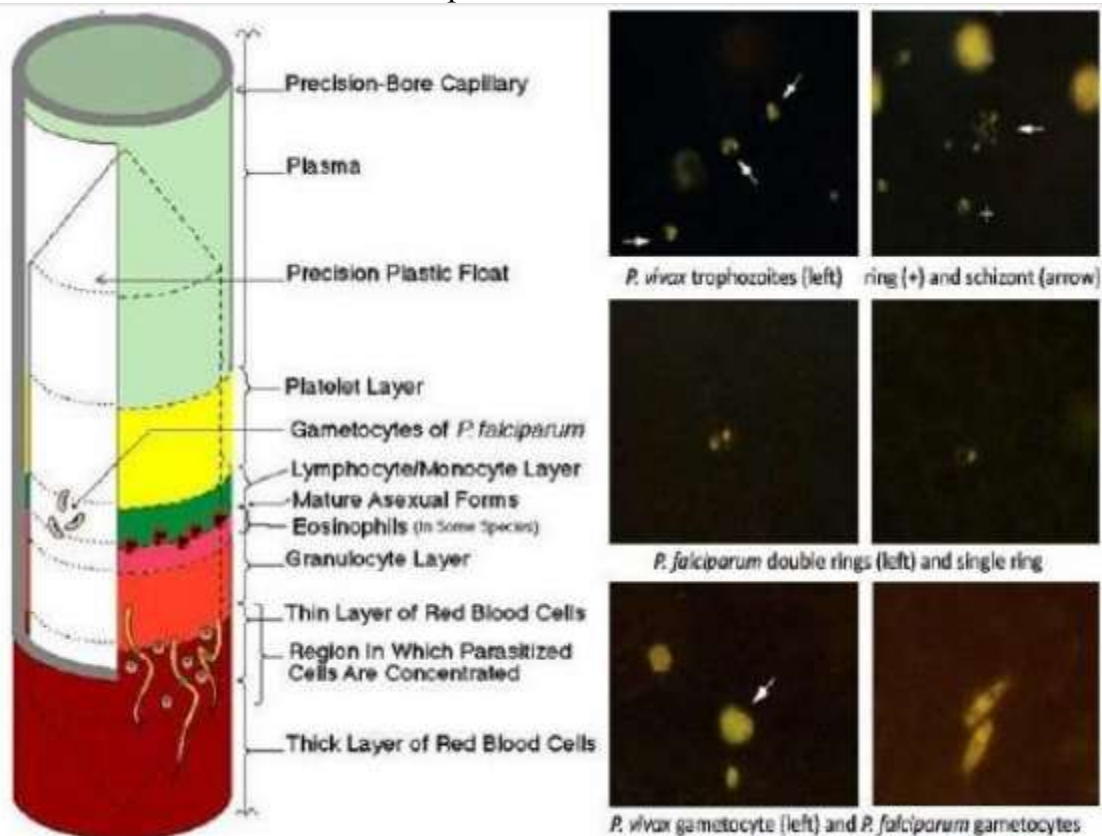
- Thin film is examined first at the tail end and if parasites are found, there is no need for examining thick film.
- It is recommended that 200 oil immersion fields should be examined before the smears are considered as negative.



2. Quantitative Buffy Coat, and immuno-Fluorescence microscope:

The nucleus of the parasite is detected by acridin-orange stains and appears as fluorescing greenish-yellow against red back ground.

× The advantage of this test is that it is faster. The disadvantage is that it is less sensitive than thick film and is expensive.



3. Serodiagnosis

it is not helpful in clinical diagnosis because it will not differentiate between an active and past infection. The tests used are indirect hemagglutination (IHA), indirect fluorescent antibody (IFA) test and enzyme-linked immunosorbent assay (ELISA).

4. Rapid antigen detection tests (RDTs) :

Rapid diagnostic test are based on the detection of antigens using immunochromatographic methods.

5. Parasite-F test:

This test is based on detection of histidine rich protein-2 (HRP-2) antigen produced by the asexual stages of *P. falciparum* expressed on the surface of red cells.

6. Culture of malaria parasite:

RPMI1640 Culture of plasmodia provides a source of the parasites for study of their antigenic structure, in seroepidemiologic surveys, drug sensitivity tests .

7. Molecular Diagnosis:

nucleic acid probe and PCR.

Treatment of Uncomplicated Malaria

- × Positive *P. vivax*, *P. ovale* and *P. malariae* cases are treated with **chloroquine 25 mg/kg** divided over **3 days** Or **hydroxychloroquine**.
- × **Primaquine** is used to eliminate the exo-erythrocytic phase (hypnozoites), so it is used for prevention of relapse, **primaquine** is given in a dose of 0.25 mg/ kg daily for **14 days**.
- × **In case of chloroquine resistance:** **Quinine** is given in a dose of 600 mg 8 hourly for 7 days along with **doxycycline 100 mg/ day**.

Treatment of Complicated (Falciparum) Malaria

- × Due to emergence of **drug resistance** of *falciparum* malaria, artemisinin-based combination therapy (ACT) (**artemisinin + sulfadoxine- pyrimethamine**) should be given to all microscopically positive *falciparum* cases for 3 days. This is accompanied by single dose of **primaquine 45 mg** (0.75 mg/kg) on day 2 as **gametocidal drug**.

Table 6.11: Antimalarial drugs and their activity

Class	Drugs	Active against parasitic stages
Quinolines and related compounds	Chloroquine	Asexual RBC stages
	Quinine	Gametocytes (except <i>Plasmodium falciparum</i>)
	Mefloquine	Asexual RBC stages
	Primaquine	Liver stages and hypnozoites, gametocytes
Artemisinin and its derivatives	Artemisinin, artemether and arte-ether	Asexual RBC stages and gametocytes
Hydroxynaphthoquinones	Atovaquone	Asexual RBC stages, Liver stages (only for <i>P. falciparum</i>)
Biguanide derivative	Proguanil	Asexual RBC stages, Liver stages (+/-)
Diaminopyrimidines	Pyrimethamine	Asexual RBC stages, Liver stages (+/-)
Sulfonamides	Sulfadiazine and sulfadoxine	Asexual RBC stages (+/-)
Tetracyclines	Tetracycline and doxycycline	Asexual RBC stages (+/-)

Abbreviations: (+/-) indicates doubtful activity; RBC, red blood cell

Immunity

- × **Immunity in malaria** could be of two types:

- (1) *innate immunity*
- (2) *acquired immunity*.

Innate Immunity :

This could be due to various factors:

- 1) **Age of red blood cells:** *P. falciparum* attacks RBCs of any age, *P. vivax* and *P. ovale* attack the young RBCs and reticulocytes where as *P. malariae* attacks older RBCs
- 2) **Duffy negative red blood cells:** Duffy blood group antigens present on RBC membrane act as receptors for *P. vivax*. So, people with Duffy negative RBCs (West Africans Black people) are resistant to vivax malaria.
- 3) **Nature of hemoglobin:** Sick cell disease, hemoglobin C and E, fetal hemoglobin and thalassemia hemoglobin are resistance to falciparum malaria
- 4) **Red blood cells with glucose-6-phosphatedehydrogenase (G6PD) deficiency** are resistant to falciparum malaria.

- 5) **Human leukocyte antigen-HLA-B53**: protect from cerebral malaria.
- 6) **nutritional status**: Patients with iron deficiency are relatively resistant to malaria.
- 7) **Pregnancy**: *Falciparum* malaria is more severe in pregnancy, particularly in primigravida and may be enhanced by iron supplementation.
- 8) **Splenectomy**: The spleen appears to play an important role in immunity against malaria. Splenectomy enhances susceptibility to malaria.

Acquired immunity

I. **Humoral immunity**: Circulating antibodies against asexual forms give protection by inhibiting red cell invasion and antibodies against sexual forms reduce transmission of malaria parasite.

II. **Cellular immunity**: Sensitized T cells release cytokines that regulate macrophage activation and stimulate B cells to produce antibodies. The activated macrophages inside liver, spleen and bone marrow phagocytose both parasitized and non-parasitized RBCs.

× Protective immunity against malaria is species specific, stage specific and strain specific.

× Immune defense of the host is sufficient to resist further infection but insufficient to destroy the parasite. Immunity lasts till the original infection remains active and prevents further infection. This is called as **infection immunity or premunition or concomitant immunity or incomplete immunity**.

Prevention and Control

1. Chemoprophylaxis

For travelers visiting endemic areas, chemoprophylaxis provides effective protection. The drugs recommended are **proguanil, chloroquine or mefloquine** weekly or **doxycycline** daily. Prophylaxis should begin 1 week before travelling and be continued while in the endemic area and for 4–6 weeks after departure from endemic area.

2. Vector Control Strategies

(a) **Insecticide residual spraying (IRS)**: The spraying of the indoor surfaces of house with residual insecticides such as DDT, malathion.

(b) **Insecticide treated bed nets (ITN)**

(c) Use of repellants, protective clothing, and screening of house.

(d) Anti-larval Measures: oiling collection of standing water or dusting them with *Paris green*.

3. Malaria Vaccine

i. **SPf66** (a cocktail of four antigens, three asexual blood stage antigens + sporozoite of Pf) was tested extensively in endemic areas in the 1990s, but clinical trials showed it to be insufficiently effective.

ii. **Merozoite surface protein 1 (MSP 1), MSP2, MSP 13** and ring-infected erythrocyte surface antigens (**RESAs**) have also been insufficient on their own.

iii. **RTS,S/AS01 (mosquirix)**: 2021 was engineered using genes from the *outer protein of P. falciparum* and a portion of *hepatitis B virus*, plus a chemical adjuvant

(AS01) to boost immune response.

- Mosquirix, is not just a first for *malaria*
— it is the first developed for any parasitic disease.
- The World Health Organization (WHO) is recommending widespread use of the RTS,S/AS01 (RTS,S) malaria vaccine in 2021 among children in sub-Saharan Africa and in other regions with moderate to high *P. falciparum* malaria transmission.
- RTS,S/AS01 malaria vaccine should be provided in a schedule of **4 doses in children from 5 months of age** for the reduction of malaria disease and burden.
- Mosquirix prevents 4 in 10 cases of *malaria*.

Malaria in Iraq

- × At 1957 malaria constituted about 20 % of infectious disease that was common in Iraq at that period. Malaria is common in parts of north and south of Iraq where Marshes are common.
- × At 1994 – 1995 an outbreak occurred and about 100 thousand cases were reported.
- × The last 2 malaria cases were reported in Iraq in 2008.
- × In 2014, 2 imported cases of malaria were diagnosed in Iraq among non-national individuals.
- × In 2015, another 2 imported cases were reported; one was national and one non-national.
- × In 2018, another imported cases were reported among non-national individual.
- × According to the latest WHO data published in 2018 Malaria Deaths in Iraq reached 0.00% of total deaths.
- × Currently, **Iraq is developing a national strategy of malaria** for 2016–2020.

The main priorities for keeping the country malaria-free include:

1. Strengthening disease surveillance.
2. Use of appropriate vector control interventions when needed.
3. Provision of free diagnostics and antimalarial medicines, including rapid diagnostic tests for areas where malaria microscopy of assured quality is not available.
4. Human resource development, particularly training courses for physicians and laboratory technicians on malaria treatment and diagnosis.

BABESIA SPECIES

- × Babesia is intra-erythrocytic sporozoan parasites that morphologically resemble *Plasmodium* and cause tick-borne malaria-like illness.
- × The parasite is present in erythrocytes and resembles the ring stage of *P. falciparum*.

CLASSIFICATION

Order: Piropasmida

Family: Babesiidae

Species: Medically important Babesia

species are:

- *B. microti* (rodent strain)
- *B. bovis* (cattle strain)

LIFE CYCLE

Definitive Host: Ixodid ticks.

Intermediate Host: Man or other mammals.

Infective Form: Sporozoites are the infective form for humans.

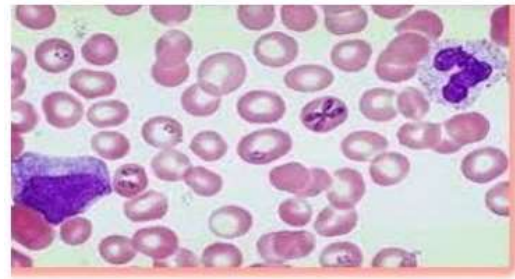
Mode of Transmission: Infection in vertebrate occurs through bite of the of Ixodid ticks.

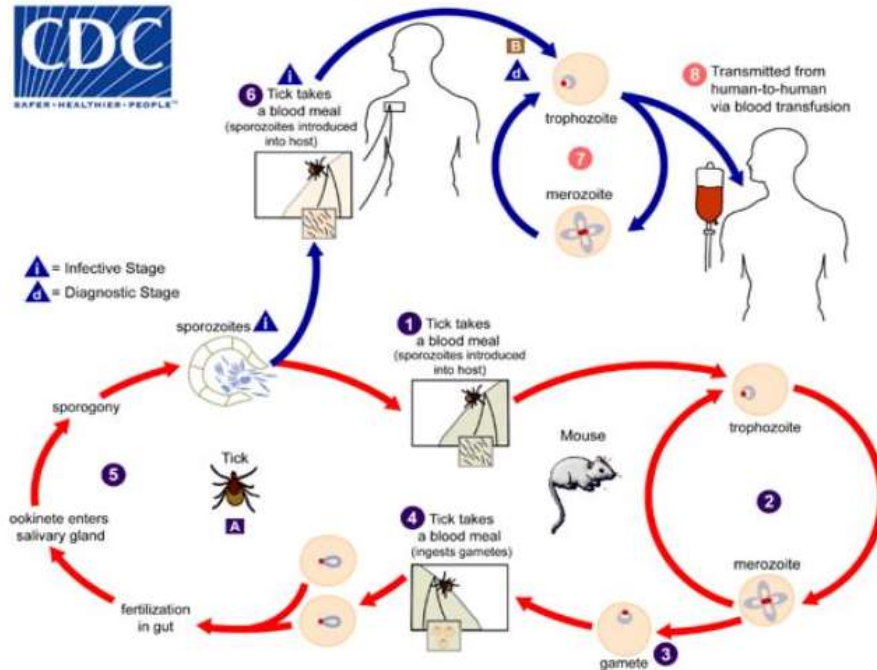
➤ Sporozoites in the salivary glands of tick are introduced into man through the bite of infected ticks.

× Sporozoites invade the RBCs and multiply asexually to form trophozoites (**ring forms in tetrad called as Maltese cross form**)

× Newly formed trophozoites are released by rupturing erythrocytes and invade new erythrocytes.

× Ticks become infected by feeding the host blood, sporozoites formed in the ticks and infect human.





PATHOGENICITY AND CLINICAL FEATURES

The incubation period varies from 1 to 6 weeks.

Mild Babesia microti illness:

It is characterized by malaise, fatigue, weakness and fever. Later on the patient develops chills, sweats, headache, myalgia, anorexia, dry cough, arthralgia and nausea.

Severe Babesia microti illness:

- × Seen when parasitemia exceeds more than 4%.
- × Predisposing factors include: more than 50 years of age, male, splenectomy, HIV/AIDS, malignancy, and immunosuppression.
- × Patient presents as severe anemia (hemoglobin level < 10 g/dL).
- × Complications may occur like: acute respiratory distress syndrome, disseminated intravascular coagulation, congestive heart failure, renal failure and splenic infarcts and rupture.

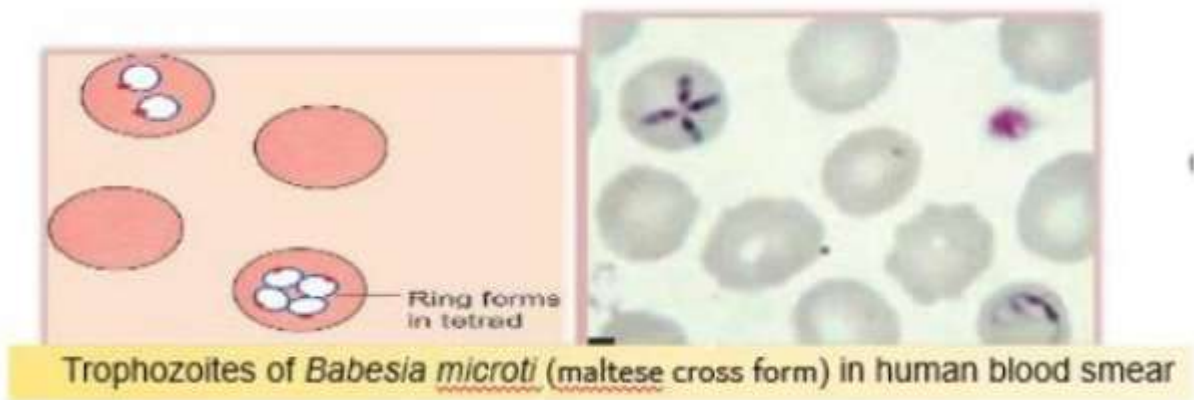
LABORATORY DIAGNOSIS

1) *Peripheral Blood microscopy*: Diagnostic feature is the demonstration of two or four rings inside the RBCs (called as maltese cross forms) in the Giemsa stained thick and thin blood smear. It is often confused with the multiple ring forms of *P. falciparum*. But can be differentiated by lack of pigments, lack of crescentic gametocytes, and the presence of pear shaped rings.

2) *Serology*: It is useful to confirm the diagnosis: Indirect fluorescent antibody (IFA) test.

3) *Polymerase Chain Reaction*.

4) Animal inoculation.



TREATMENT

B. microti infection is mild and self-limiting.

In acute severe cases chemotherapy is required:

Atovaquone along with azithromycin for a period of 7- 10 days is effective.

Alternatively, clindamycin along with quinine may be given intravenously.

Differences between Babesia and falciparum malaria

Feature	<i>Babesia</i>	<i>Falciparum malaria</i>
Vector	Tick	Female <i>Anopheles</i> mosquito
Ring forms	Pear shaped and in tetrad (maltese cross form)	Round and may be single or multiple
Gametocyte	Cannot be distinguished from asexual forms	Crescentic gametocyte
Pigments in RBC	Not seen	Seen
Asexual cycle	By budding Schizogony -asynchronous	Binary fission Schizogony—synchronous
Hemolysis	Less severe	More severe
Cerebral features	Not seen	Seen
Parasitaemia	Usually low	Usually high
Risk factor	Immunosuppression	Also seen in immunocompetent individuals
Treatment	Chloroquine not effective Clindamycin plus oral quinine is given	Chloroquine is given in milder and sensitive cases

Cestodes (tapeworms)

Objectives:

- × Define cestodes.
- × Discuss the morphology of cestodes.
- × Describe the morphology and life cycle of *Echinococcus granulosus*.

Classification:

-

Phylum: Platyhelminthes.

- class: Cestoidea.

The class Cestoidea includes 2 orders:

1-Pseudophyllidea

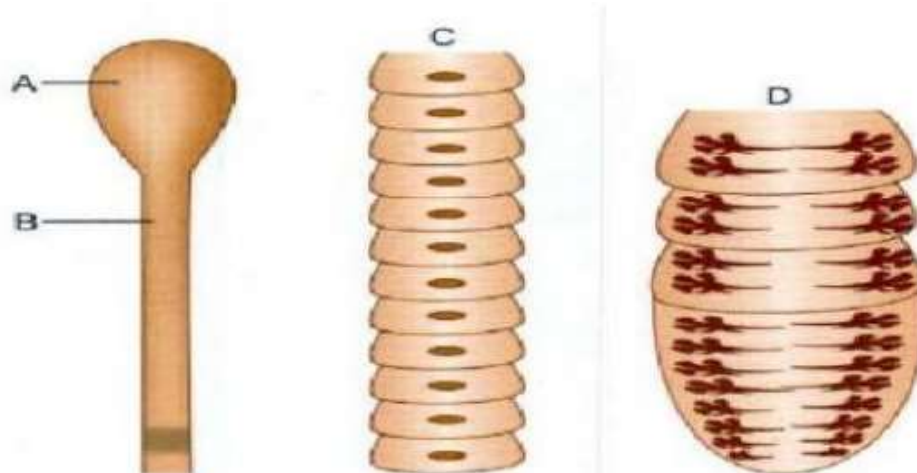
2-Cyclophyllidea

Order	Adult worm seen in human intestine	Larval stage seen in humans
Pseudophyllidea	<i>Diphyllobothrium latum</i> , the fish tapeworm	<ul style="list-style-type: none">• <i>Spirometra mansoni</i>• <i>Spirometra theileri</i>• <i>Spirometra erinace</i> (larval stage causing sparganosis)
Cyclophyllidea	<ul style="list-style-type: none">• <i>Taenia saginata</i>, the beef tapeworm• <i>Taenia solium</i>, the pork tapeworm• <i>Hymenolepis nana</i>, the dwarf tapeworm• <i>Hymenolepis diminuta</i>, the rat tapeworm (rare)• <i>Dipylidium caninum</i>, the double-pored dog tapeworm (rare)	<ul style="list-style-type: none">• <i>Taenia solium</i>, the pork tapeworm (larval form can cause cysticercus cellulosae)• <i>Echinococcus granulosus</i>, the dog tapeworm (Larval form causes hydatid disease in man)• <i>Echinococcus multifocularis</i> (larval stage causes alveolar or multilocular hydatid disease)• <i>Multiceps multiceps</i> and other species (larval stage may cause coenurosis in man)

- Cestodes (Greek keston—girdle or ribbon) are multisegmented, dorsoventrally flattened tapelike worms whose sizes vary from a few millimeters to several meters.

The adult worm consists of 3 parts:

1. Head (scolex).
2. Neck.
3. Trunk (strobila).

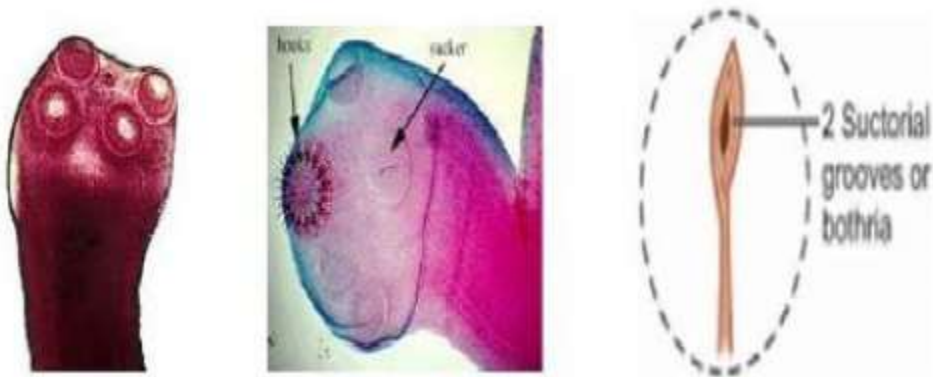


Figs 1A to D: Tapeworm. (A) Scolex or head; (B) Neck, leading to the region of growth below, showing immature segments; (C) Mature segments; and (D) Gravid segments filled with eggs

1- Head (scolex):

the organ of attachment to the intestinal mucosa of the definitive host.

- In the order cyclophyllidea, the scolex possesses 4 suckers (or acetabula). In some cyclophyllidea like *Taenia solium*, the scolex has an apical protrusion called as the rostellum. The rostellum may or may not be armed with hooks.
- In the order pseudophyllidea, the scolex does not possess suckers but possesses a pair of longitudinal grooves called as bothria, by which it attaches to the intestine of the host.

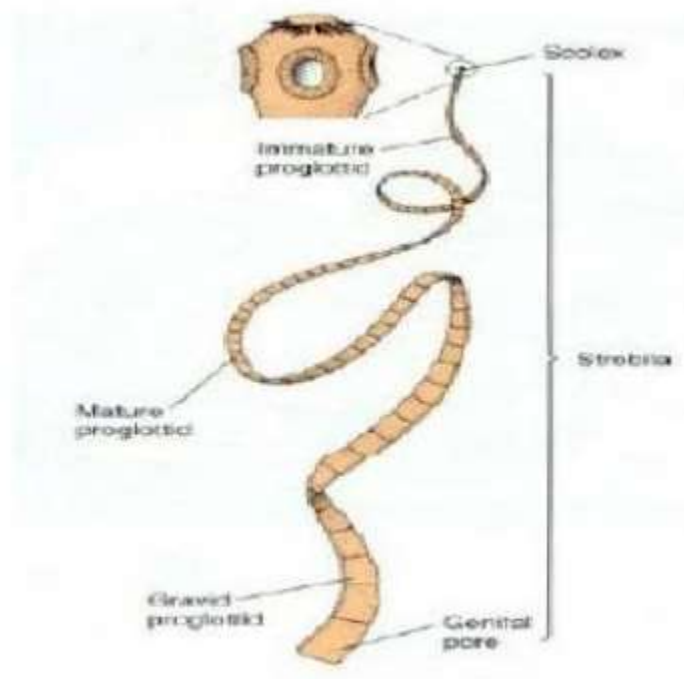


2-Neck:

It is the part, immediately behind the head and is the region of growth from where the segments of the body (proglottids) are being generated continuously.

3-Trunk (strobila):

- The trunk also called as strobila is composed of a chain of Proglottids or segments.
- The proglottids near the neck, are the young immature segments, behind them are the mature segments, and at the hind end, are the gravid segments.
- Proglottids are continuously formed posterior to the neck region by a process known as strobilization .
- Tapeworms are hermaphrodites (monoecious): mature segment contains both male and female sex organs.
- In the **immature segments**, the reproductive organs are not well-developed.
- They are well developed in **the mature segments**.
- The **gravid segments** are completely occupied by the uterus filled with eggs.
- Tapeworms do not have a body cavity or alimentary canal; absorption of nutrients is by the outer layer body wall.
- Rudimentary excretory and nervous systems are present.



Eggs

- The embryo inside the egg is called the oncosphere (meaning 'hooked ball') because it is spherical and has hooklets.
- Oncospheres of human tapeworms typically have 3 pairs of hooklets and so, are called hexacanth (meaning 6-hooked) embryos.

Cestodes complete their life cycle in 2 different hosts.

Exceptions are:

Hymenolepis nana that requires only 1 host, man .

Diphyllobothrium latum that requires 3 hosts:

1. definitive host: man;
2. first intermediate host: cyclops;
3. and second intermediate host: fish.

Echinococcus species

I. *Echinococcus granulosus*:

the most common, causing Unilocular Hydatid disease. {IRAQ}

II. *Echinococcus multilocularis*

: causing Alveolar or multilocular hydatid disease, the most dangerous one with a high fatality rate.

III. *Echinococcus vogeli* and *Echinococcus oligarthrus*:

causing Polycystic hydatid disease

Echinococcus granulosus

- **Common name:**

dog tape worm, hydatid tape worm.

- **Disease:**

unilocular hydatid disease, Echinococcosis or hydatidosis

- **Definitive host:** dog & other canine.

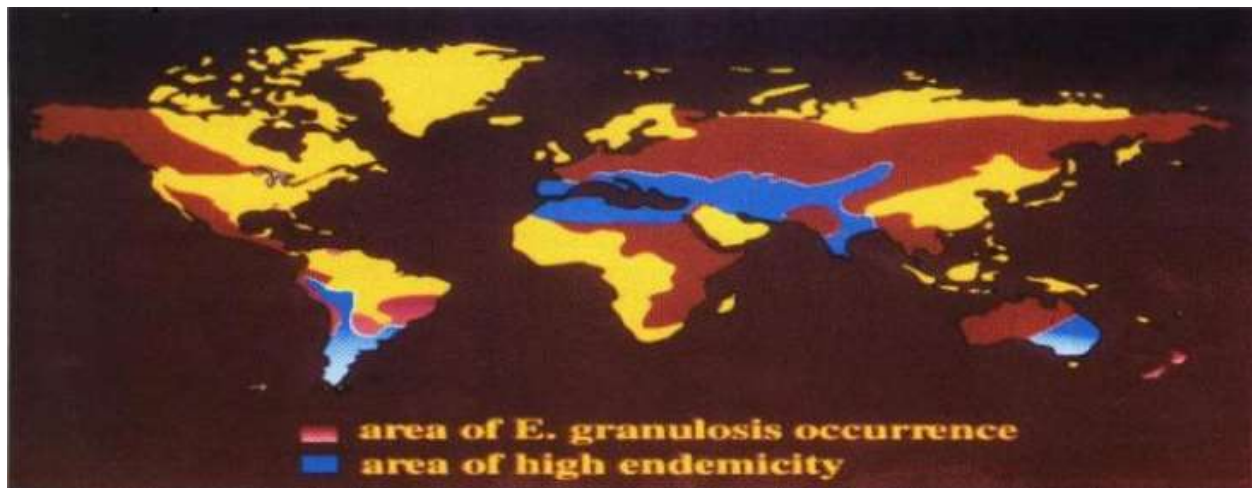
- **Intermediate host:** sheep, cattle, camel & human.

- **Infective stage:** egg.

- **Sites of hydatid:** liver, lungs, abdominal cavity, spleen, kidneys, heart, bones, central nervous system etc.

- **Man is a dead end host.**

The disease is a cosmopolitan zoonosis endemic in many parts of the world specially middle east (include **Iraq**), Australia, New Zealand, South America, Central and South Europe



-

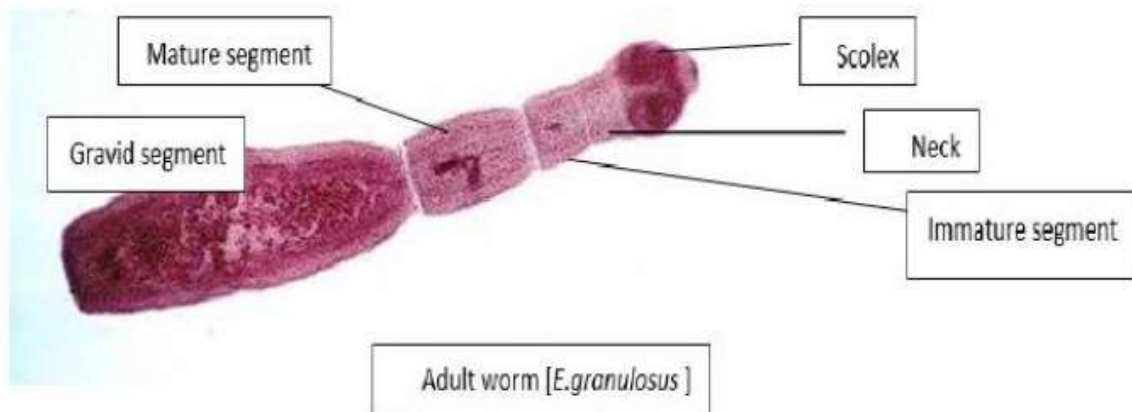
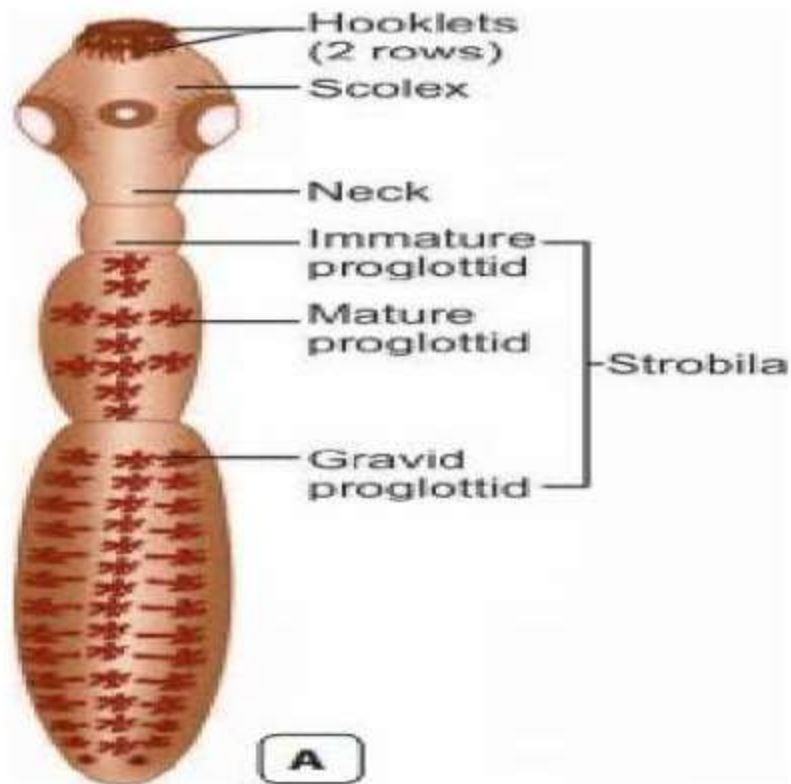
Habitat:

The adult worm lives in the duodenum and jejunum of dogs and other canine carnivora (wolf and fox).

- The larval stage (hydatid cyst) is found in humans and herbivorous animals (sheep, goat, cattle and horse).

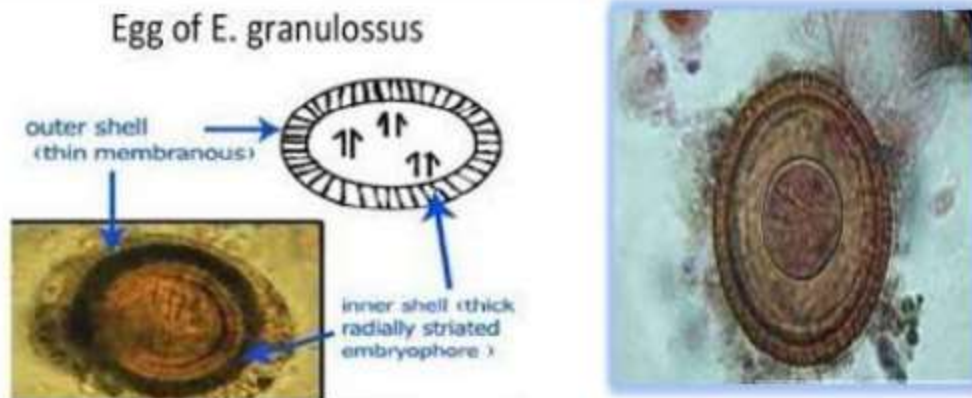
Morphology: Adult Worm

- It is a small tapeworm, measuring only 3–6 mm in length.
- It consists of a scolex, a short neck, and strobila.
- The scolex is pyriform, with 4 suckers and a prominent rostellum bearing 2 circular rows of hooklets (25–30).
- The neck is short than the rest of the worm.
- The strobila is composed of only 3 proglottids, the anterior immature, the middle mature, and the posterior gravid segment
- The terminal proglottid is longer and wider than the rest of the worm and contains a branched uterus filled with eggs.



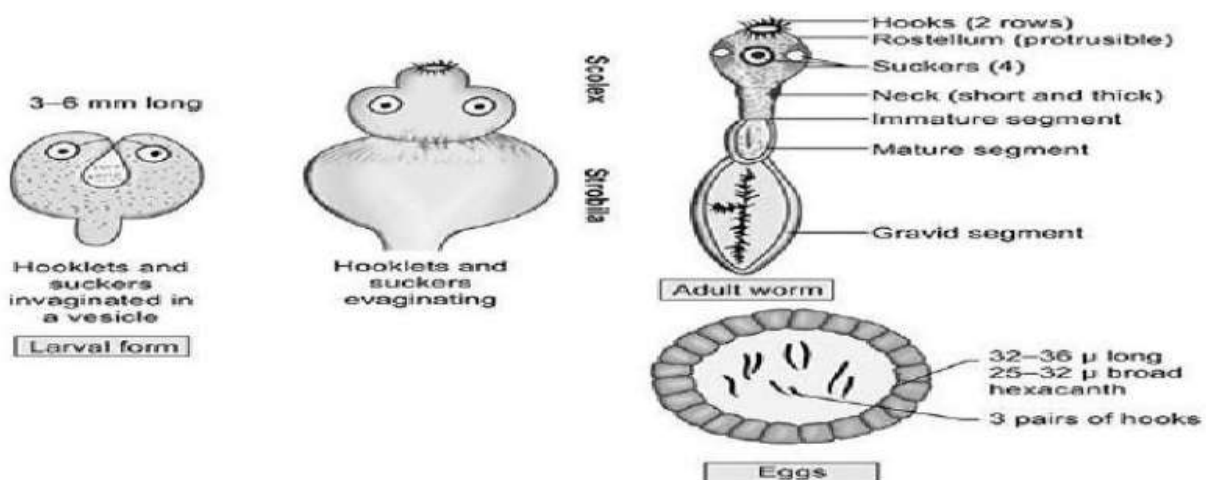
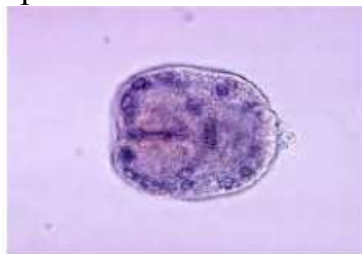Eggs

- The egg is spherical, measuring 30–40 μm in diameter.
- It has a thin hyaline embryonic membrane around it.
- The inner embryophore is radially striated and is yellow-brown due to bile staining
- In the center is a fully developed embryo (oncosphere) with 3 pairs of hooklets (hexacanth embryo).
- **The eggs of *E. granulosus* and *Teania* spp. are indistinguishable.**



Larval Form

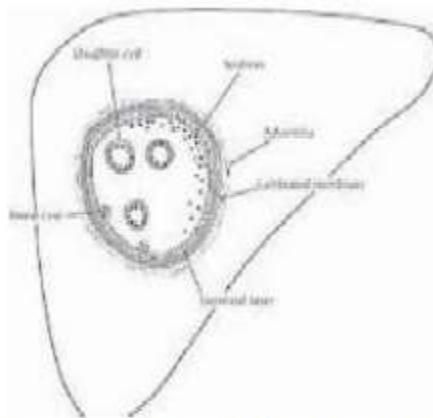
- The larval form is found within the hydatid cyst developing inside various organs of the intermediate host.
- It represents the structure of the scolex of adult worm and remains invaginated within a vesicular body.
- After entering the definitive host, the scolex with suckers and rostellar hooklets, becomes evaginated and develops into adult worm.



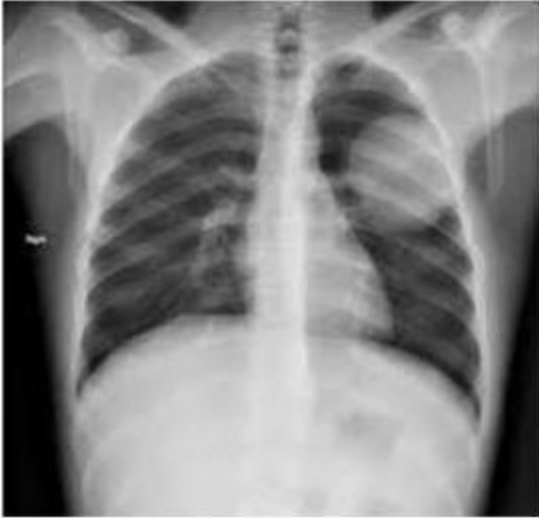Life Cycle

- The worm completes its life cycle in 2 hosts.
- Definitive hosts: Dog (optimal host), wolf, and fox.

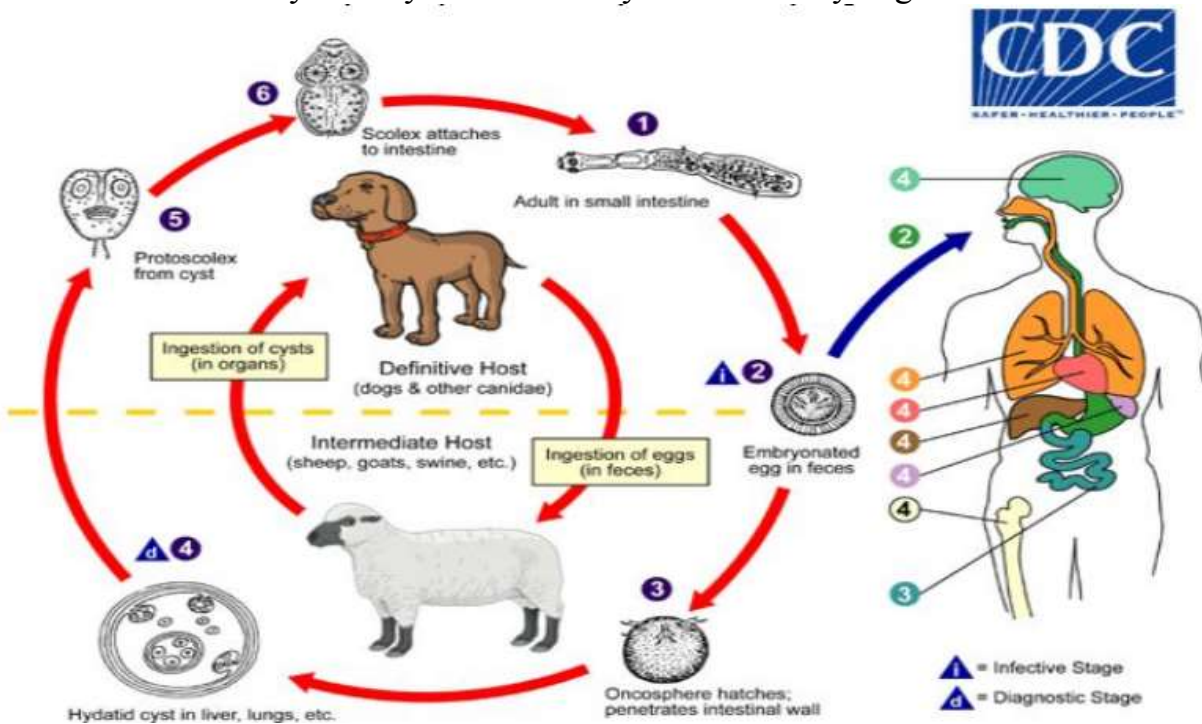
- Intermediate host: Sheep and Cattle. (Sheep is the ideal intermediate host).
- Man acts as an accidental intermediate host (dead end).
- The adult worm lives in the small intestine of dogs and other canine animals. These animals discharge numerous eggs in the feces, the intermediate hosts (sheep and cattle) ingest them while grazing.
- Human infection follows ingestion of the eggs due to intimate handling of infected dogs or by eating raw vegetables or other food items contaminated with dog feces.
- The ova ingested by man or by sheep and cattle are liberated from the chitinous wall by gastric juice liberating the hexacanth embryos which penetrate the intestinal wall and enter the portal venules, to be carried to the liver along the portal circulation.
- These are trapped in hepatic sinusoids, where they eventually develop into hydatid cyst.
- About **65%** of hydatid cyst develop in liver, which acts as the **first filter** for embryo.



- However, some embryo which pass through the liver, enter the right side of heart and are caught in pulmonary capillaries (forming pulmonary hydatid cysts 15%), so that the lung acts as the second filter.
- A few embryo enter the systemic circulation and get lodged in various other organs and tissues such as the spleen, kidneys, eyes, brain, or bones.
- The hydatid cyst may be present in any tissue except hair, nail.



- When sheep or cattle harboring hydatid cysts die or are slaughtered, dogs may feed on the carcass or offal. Dogs are infected by ingesting protoscoleces in the fertile hydatid cyst in viscera of intermediate host specially sheep, goat, cattle and camel.
- Inside the intestine of dogs, the scolices develop into the adult worms in about 6-7 week and produce eggs to repeat the life cycle.
- One dog may have up to 17120 adult worms.
- The adult worm lives from 6-30 month
- When infection occurs in humans accidentally, the cycle comes to a dead end because the human hydatid cysts are unlikely to be eaten by dogs.



Transmission of *E. granulosus* to human:

1.

Direct contact between human and dogs.

2. Indirect transmission via water sources and vegetable, contaminated by *E. granulosus* eggs deposited by infected dogs may be the most important route of transmission to humans.

3. Flies may also be implicated in transmission of the disease

4. Direct transmission of *E. granulosus* from human to human does not occur

Pathogenesis of hydatid cyst:

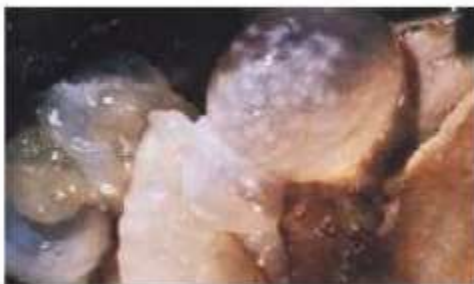→ At the site of deposition, the embryo slowly develops into a hollow bladder or cyst filled with fluid. This becomes the hydatid cyst (Greek hydatis: a drop of water).

→ The pathological effects of hydatid cyst and their clinical features are mainly due to two factors;

→ 1-localization with mechanical effects the cyst acting as any other space – occupying lesion, with subsequent complications occurring locally and possibly, leading to systemic manifestations.

→ 2-The generalized allergic reactions due to absorption of the antigenic material of the parasite or rupture of the cyst.

→ the hydatid cyst enlarges slowly and reaches a diameter of 0.5–1 cm in about 6 months. The growing cyst evokes host tissue reaction leading to the deposition of fibrous capsule around it.



- The hydatid cyst wall consists of 3 layers:

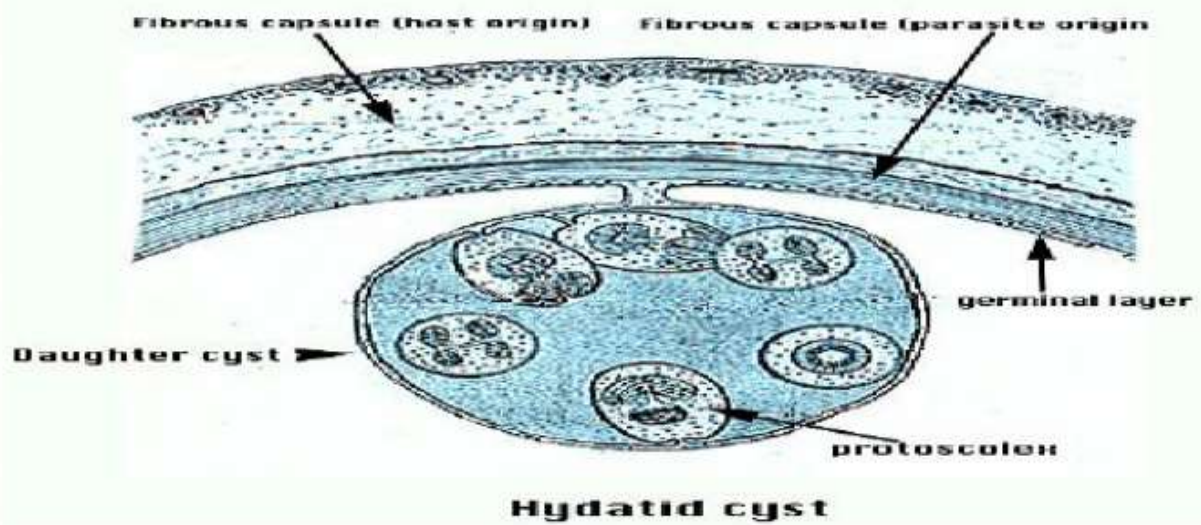
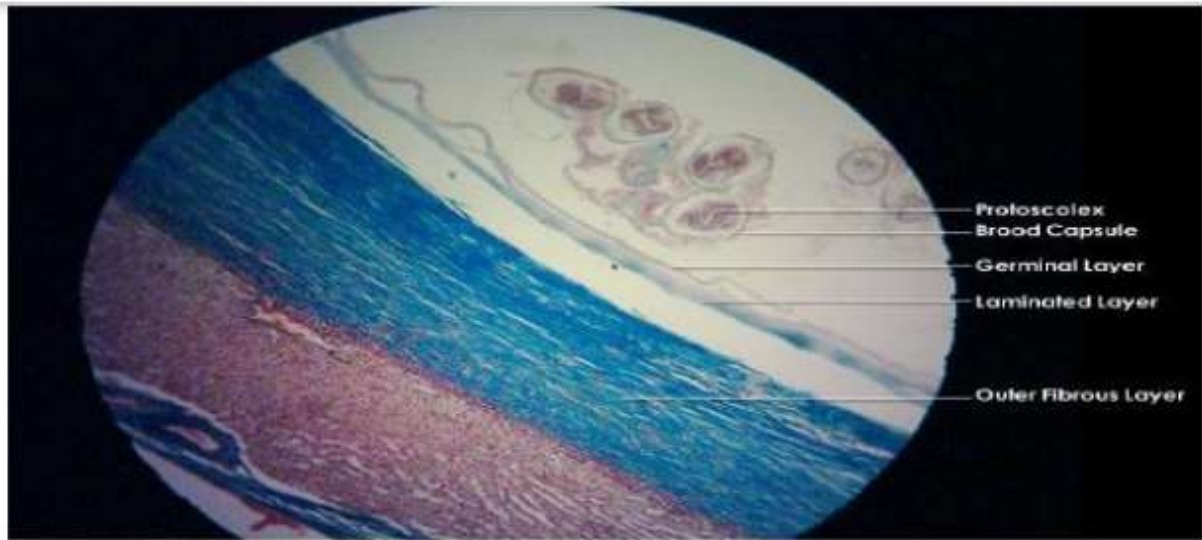
→ **Pericyst:** is the outer host inflammatory reaction consisting of fibroblastic proliferation, mononuclear cells, eosinophils, and giant cells, eventually developing into dense fibrous capsule which may even calcify.

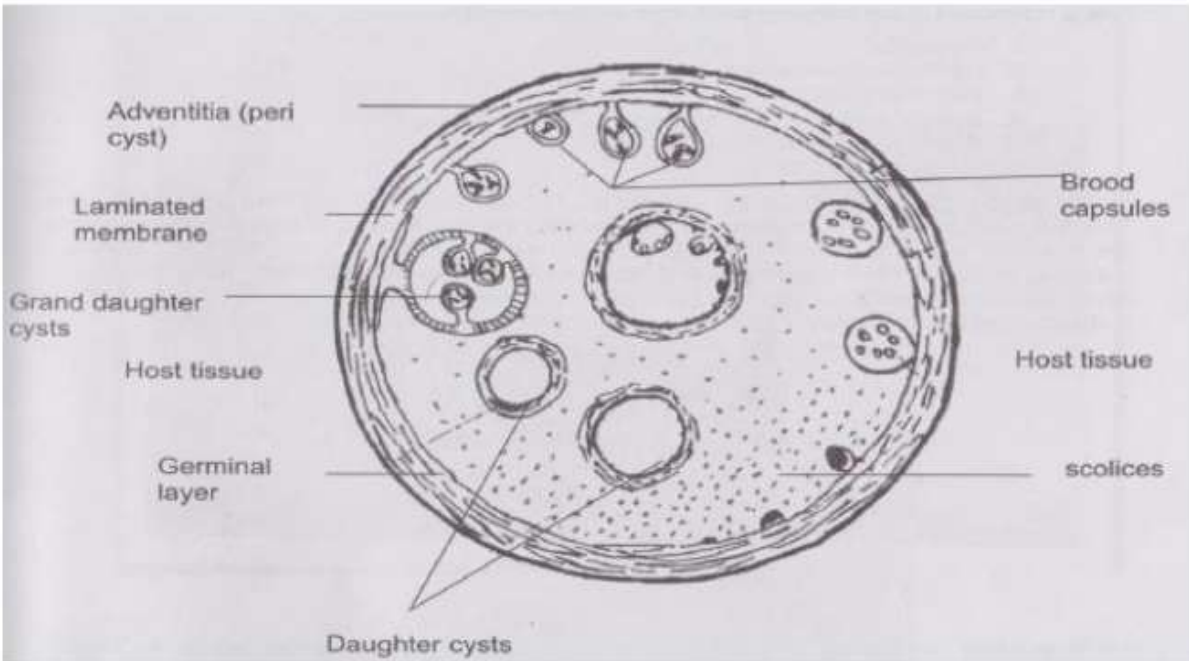
2. **Ectocyst:** is the intermediate layer composed of characteristic chitinous, laminated hyaline material. It has the appearance of the white of a hardboiled egg.

3. **Endocyst:** is the inner germinal layer which is cellular and consists of number of

nuclei embedded in a protoplasmic mass and is extremely thin.

→ The germinal layer is the vital layer of the cyst and is the site of asexual reproduction giving rise to brood capsules with scolices. It also secretes hydatid fluid, which fills the cyst.





Echinococcus species

Objectives:

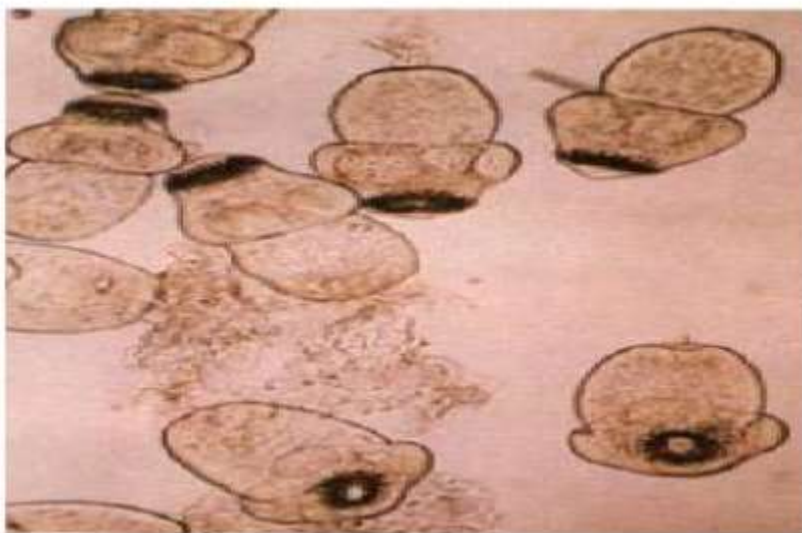
- Discuss the Hydatid fluid.
- Define Brood capsules.
- Describe the

Osseous Hydatid Cyst.

- Show the clinical features & treatment of hydatid disease.
- Discuss *E. Multilocularis* & *E. vogeli*.

Hydatid fluid:

- The interior of the cyst is filled with a clear colorless or pale-yellow fluid called as hydatid fluid.
- It contains salts (sodium chloride 0.5%, sodium sulphate, sodium phosphate, and salts of succinic acid) and proteins. **pH of the fluid is 6.7 (acidic).**
- It is antigenic and highly toxic so its liberation into the circulation gives rise to eosinophilia and may cause anaphylaxis.
- The fluid was used as the antigen for Casoni's intradermal test.
- A granular deposit or hydatid sand is found at the bottom of the cyst, consisting of free brood capsules, protoscolices and loose hooklets.

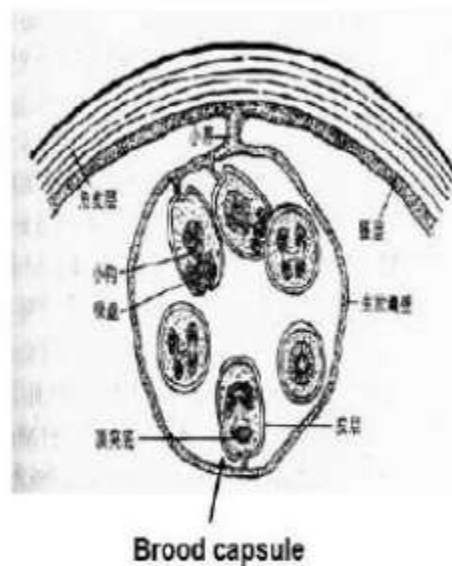
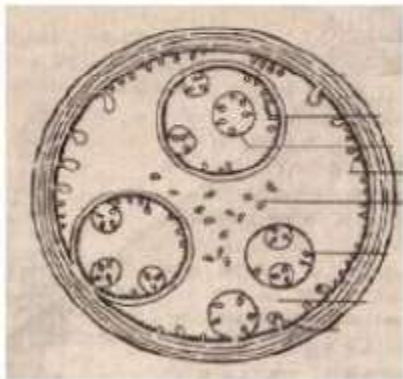


Protoscolices

Brood capsules:

From the germinal layer, small knob-like excrescences or gemmules protrude into the lumen of the cyst. these enlarge, become vacuolated, and are filled with fluid. These are called as *brood capsules*.

- It have only the germinal layer, containing protoscolices. They are initially attached to the germinal layer by a stalk, but later escape free into the fluid-filled cyst cavity,
- From the inner wall of the brood capsules, protoscolices (new larvae) develop, which represent the head of the potential worm, with invaginated scolex.
- Inside mature hydatid cysts, further generation of cyst, **daughter cysts and grand-daughter cysts** may develop. which are replicas of the mother cysts.
- The cyst grows slowly often taking 20 years or more to become big enough to cause clinical illness



Fertile hydatid cyst

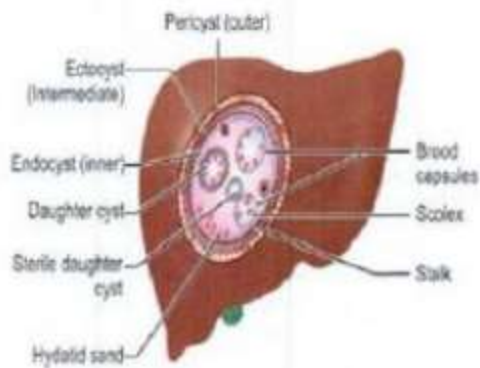
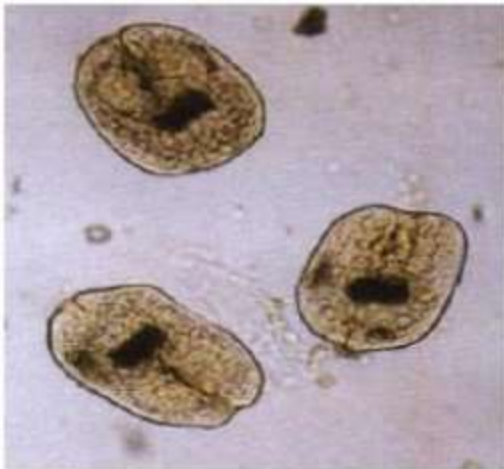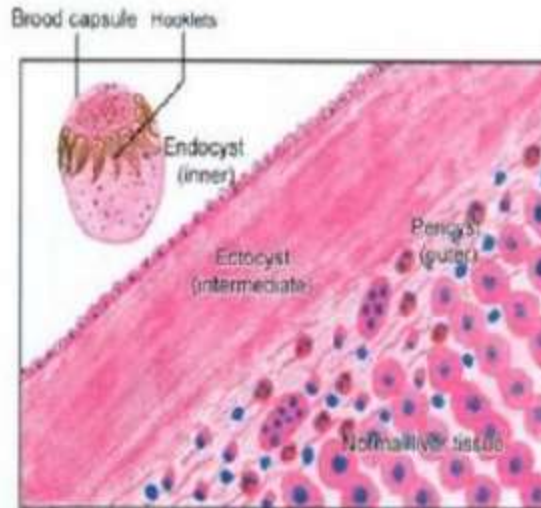
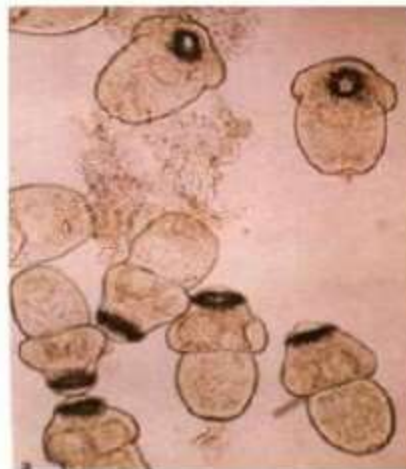


Fig. 18: Hydatid cyst in the liver



invaginated

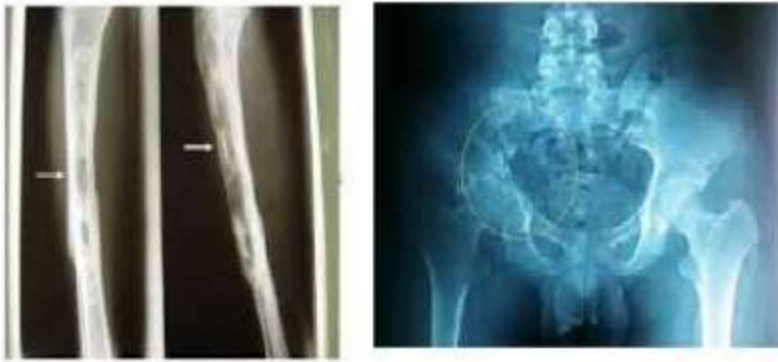

evaginated

protoscolex

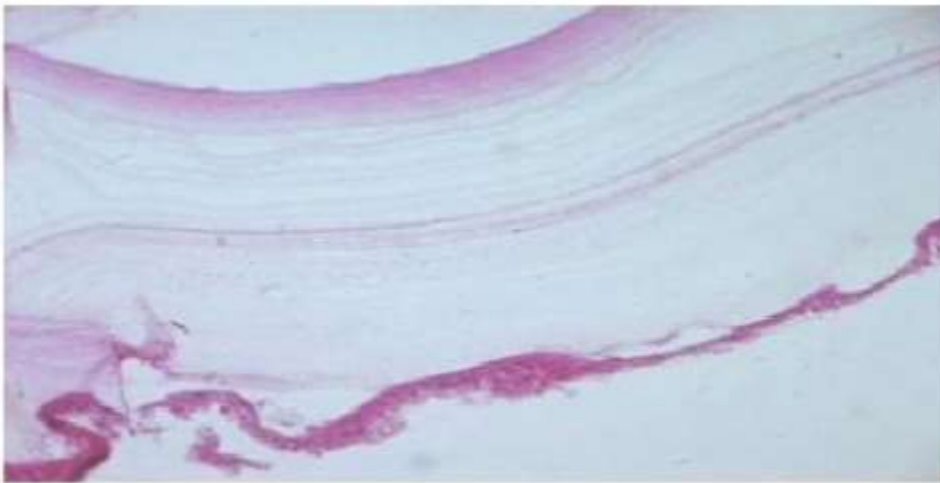
Osseous Hydatid Cyst:

- When the embryo reaches bony tissues, it will develop to osseous hydatid cyst. The external laminated layer is not produced or poorly developed.
- The larva grows as a protoplasmic stream that erodes the cancellous tissues and lead to multiple bone fractures. It occurs in the ends of long bones and pelvic arch ; it is sterile never produces brood capsule and protoscolices with little or no fluid and no fibrous capsule.



Acephalocysts

- Some cysts are sterile and may never produce brood capsules, while some brood capsule may not produce scolices. These are called acephalocysts.

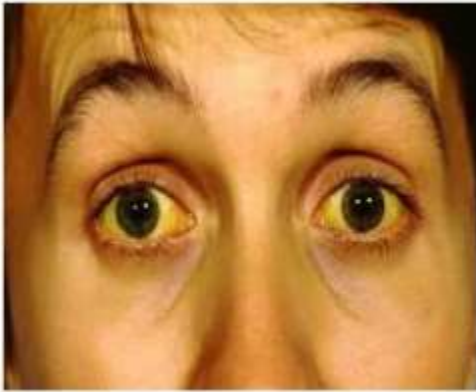

Non Fertile hydatid cyst (sterile)

Clinical manifestations

- Most of the times the infection is asymptomatic and accidentally discovered.
- Depends on the size, location and the number of cysts.
- 1. **Pressure** -
by tremendous size of the cyst. results in dysfunction of liver, lung or nervous system.
- the primary hydatid cyst occurs in liver (65%), mostly in the right lobe.

Hepatomegaly, pain, and obstructive jaundice are the usual manifestations.

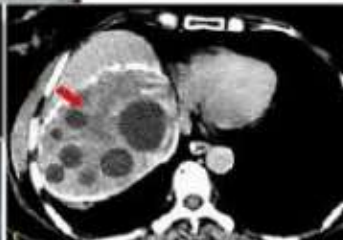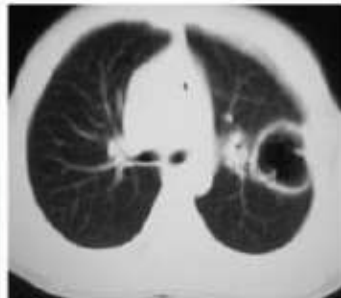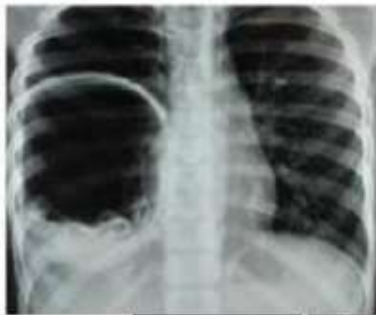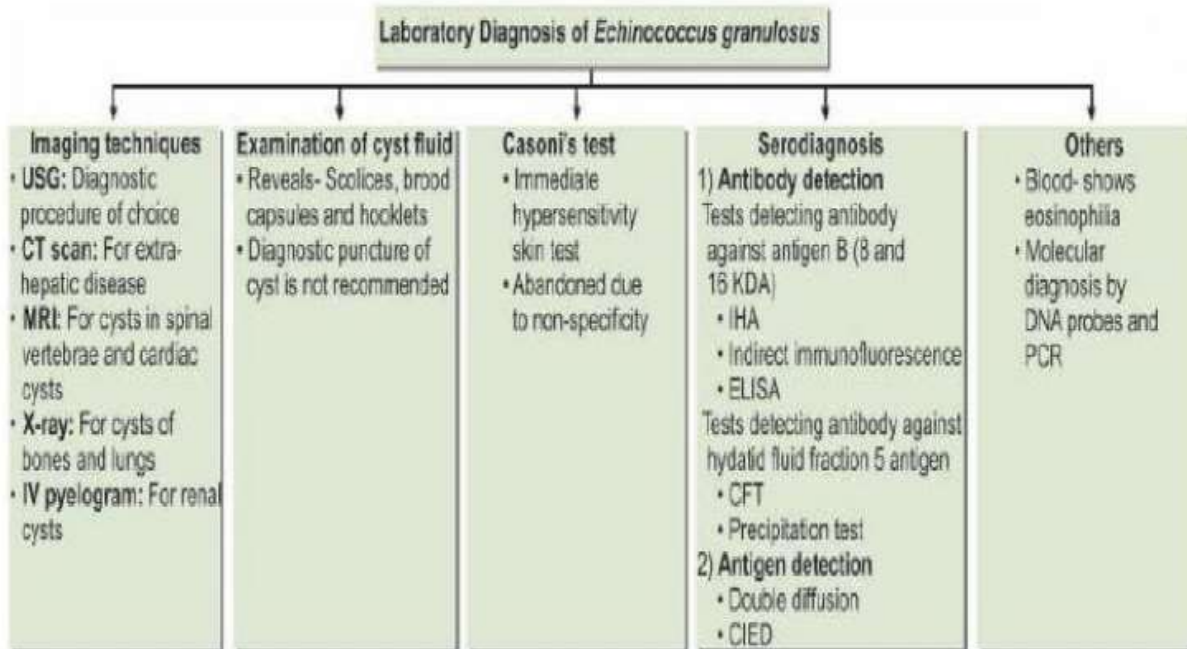


- The next common site is the lung (15%). Cough, hemoptysis, chest pain, and dyspnea constitute the clinical picture.
- In the kidney (2%), hydatid cyst causes pain and hematuria.
- Other sites affected include spleen (1%), brain (1%), pelvic organs, orbit, and bones (3%).

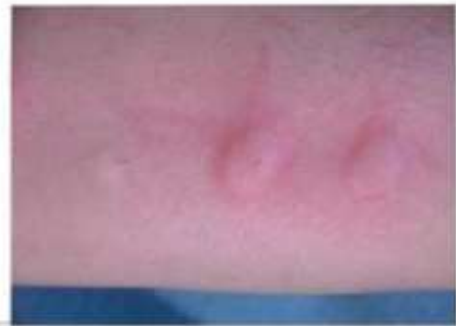

2.Allergy -due to rupture of cyst, may cause severe allergic reaction (anaphylactic shock).

3.Regeneration – due to rupture of cyst, intracystic protoscolex or germinal layer may be transplanted and result in multiple secondary infection. Primary Unilocular hydatid cyst, (developed from the ova) the two most common organs involved are liver then the lungs. Other less common sites affected by cysts include muscles, spleen, bones, kidneys and CNS.
following rupture of primary hydatid cyst, the infection may inhabit any anatomic site (Secondary hydatid cyst) developed from protoscolex.



CASONI'S TEST



Treatment

- Traditionally surgical removal was considered as the best mode of treatment of cysts.

Currently, ultrasound staging is recommended and management depends on the stage.

- In early stages, the treatment of choice is puncture, aspiration, injection, and reaspiration (**PAIR**). used in early stages of the disease.

- **The basic steps involved in PAIR include:**

1. Ultrasound or CT-guided puncture of the cyst.
2. Aspiration of cyst fluid.
3. Infusion of scolicidal agent (usually 95% ethanol; alternatively, hypertonic saline).

4. **Reaspiration** of the fluid after 5 minutes.

- Albendazole (15 mg/ kg in two divided doses) is initiated 4 days before the procedure and continued for 4 weeks afterwards.

Surgery

- It is the treatment of choice for complicated *E. granulosus* cysts like those communicating with the biliary tract and in those cysts where PAIR is not possible.
- Recurrence after surgery is common.
- Pre and postoperative chemotherapy with albendazole for 2 years after curative surgery is recommended.
- **Other new treatment modalities include.**
- 1-laparoscopic hydatid liver surgery.
- 2-percutaneous thermal ablation (PTA) of the germinal layer of the cyst using radiofrequency ablation device.

Chemotherapy

- Chemotherapy with benzimidazole agents is restricted to residual, postsurgical, and inoperable cysts.
- Albendazole and praziquantel have proved beneficial

Prevention

1. Ensuring pet dogs do not eat animal carcass or offal.
2. Periodical deworming of pet dogs.
3. Destruction of stray and infected dogs.
4. Maintaining personal hygiene such as washing of hands after touching dogs and avoidance of kissing pet dogs.
5. Uncooked vegetables should be washed with running water.

Echinococcus Multilocularis

causes rare but serious condition of alveolar or multilocular hydatid disease in humans.

It is found in the northern parts of the world, from Siberia in the East to Canada in the West.

Definitive hosts

- Wild carnivores (e.g., fox)
- dogs and cats

Intermediate hosts

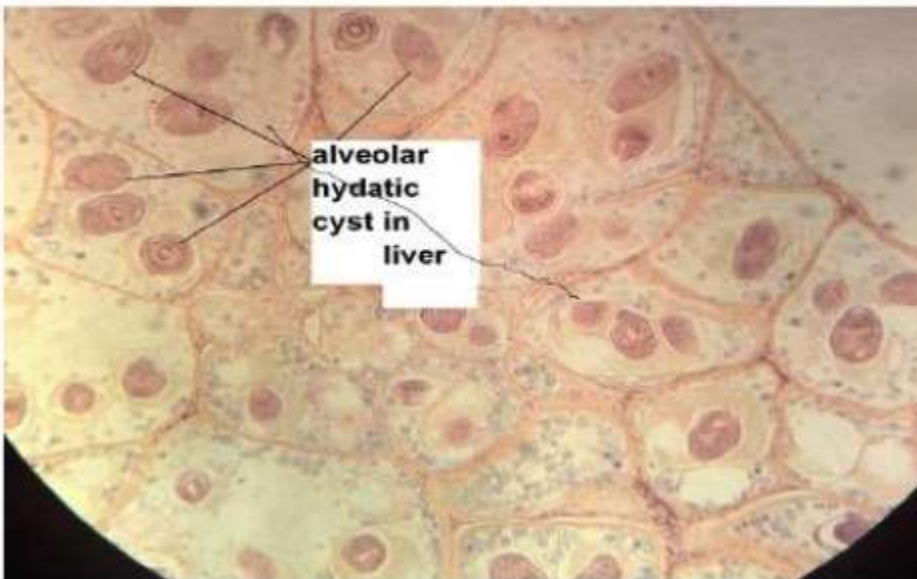
- Small mammals (rodents)
- Humans

Disease: multilocular hydatid cyst

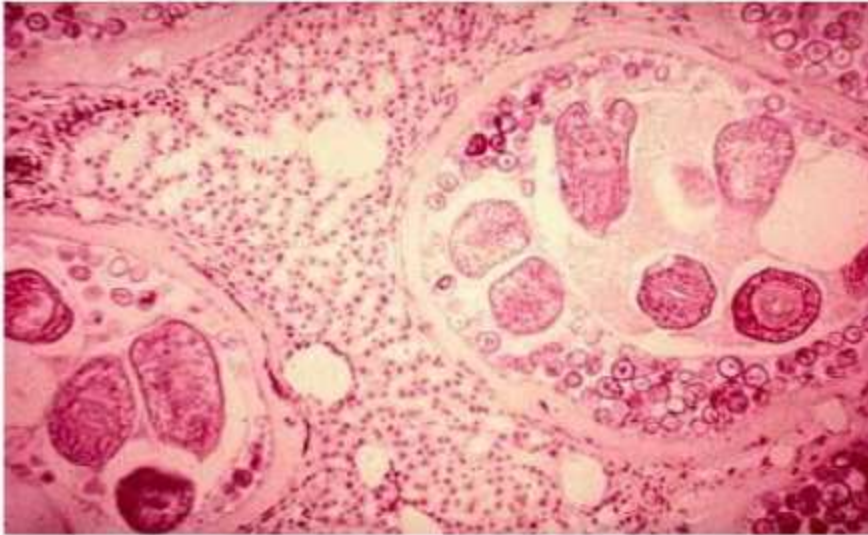


Multilocular or Alveolar Hydatid Cyst:

- It is the larval stage of *E. multilocularis*, it is composed of numerous small spaces or cavities, separated from each other by connective tissue.
- Each space filled with jelly-like matrix.
- Mostly it is sterile but occasionally it may contain protoscolices. The germinal and laminated layers are poorly developed, it has no fibrous capsule.



- The liver is the most commonly affected organ. The multilocular infiltrating lesion appears like a grossly invasive growth which can be mistaken for a malignant tumor.
- Patients present with upper quadrant and epigastric pain. Liver enlargement and obstructive jaundice may also be present. It may also metastasize to the spleen, lungs, and brain in 2% cases.
- Because of its fast growth, it is usually fatal. The prognosis is very bad if untreated.



- Surgical resection, when possible, is the best method of treatment.
- Albendazole therapy is recommended for 2 years after curative surgery. In those cases, where surgery is not possible, treatment with albendazole is recommended.

Hydatid cyst of *Echinococcus vogeli*

Disease: Polycystic hydatid disease.

Habitat: in the small intestine of bush dog (definitive host) in latin America.

natural intermediate host: Rodent.

Morphology:

Adult worm differs from *E. granulosus*, it is greater in length 3.9 - 5.6 mm.

Polycystic hydatid: is alveolar in characters but less than that of *E. Multilocularis*.

so it is intermediate between cystic and alveolar hydatid disease, present like a mass of tumor in the liver

